



132



HEALTH
SCIENCES
LIBRARY

ator of Bliss's
the first to introduce
The great




Reed

April 12th. 1875.


Dr. J. Eastman.
T. Lunt.
Mich.








WILSON'S ANATOMY.



Digitized by the Internet Archive
in 2010 with funding from
Open Knowledge Commons





J. Eastman

A SYSTEM
OF
HUMAN ANATOMY,
GENERAL AND SPECIAL.

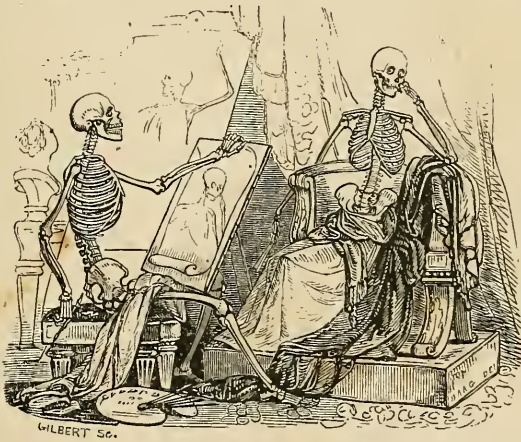
BY ERASMUS WILSON, M.D.,
LECTURER ON ANATOMY, LONDON.

SECOND AMERICAN EDITION,

EDITED BY

PAUL B. GODDARD, A. M., M. D.,

LECTURER ON ANATOMY AND DEMONSTRATOR IN THE UNIVERSITY OF PENNSYLVANIA;
MEMBER OF THE AMERICAN PHILOSOPHICAL SOCIETY; ACADEMY OF NATURAL
SCIENCES; PHILADELPHIA MEDICAL SOCIETY, ETC. ETC.



WITH OVER TWO HUNDRED ILLUSTRATIONS BY GILBERT.
FROM THE SECOND LONDON EDITION.

PHILADELPHIA:
LEA AND BLANCHARD.

1844.

Spec Coll

Hist Coll.

DM

23

W69

744

Entered, according to the Act of Congress, in the year 1842, by
LEA AND BLANCHARD,
in the Office of the Clerk of the District Court of the United States in and for
the Eastern District of Pennsylvania.

C. Sherman, Printer,
19 St. James Street.

TO

SIR ASTLEY PASTON COOPER, BART., F. R. S.,

MEMBER OF THE INSTITUTE OF FRANCE,

This Work

IS RESPECTFULLY INSCRIBED,

IN ADMIRATION OF HIS GREAT AND ACKNOWLEDGED GENIUS ;

AND OF HIS SPLENDID AND UNWEARYING LABOURS

IN THE CAUSE OF MEDICAL SCIENCE,

BY

THE AUTHOR.

P R E F A C E

TO THE FIRST ENGLISH EDITION.

THE favourable reception which my recent Work on Practical and Surgical Anatomy has received, both from the Profession and the Press, commands my first attention and grateful remembrance on again presenting myself to public notice as an aspirant for honours in the field of Medical Science. On the present occasion, I submit the Anatomist's Vade Mecum to the Members of the Profession, with the fullest assurance that they will find it to be a complete system of descriptive Anatomy, recording in its pages, in a clear, precise, and perspicuous style of expression, every important detail of human structure, and the most modern and valuable discoveries and researches in the Science of Anatomy.

To the established practitioner it is a matter of great importance that he should be possessed of the means, during the few spare hours which he can abstract from his anxious and responsible duties, of easily and agreeably refreshing his acquaintance with that science which is the acknowledged basis of all safe and skilful medical practice. Of this application of my present labours I have not been unmindful, in composing the Anatomist's Vade Mecum; and I sincerely trust that the work will prove to be the instructive and interesting companion of his important practical avocations.

The Student of Medicine, from the first moment of commencing his labours in the study of Anatomy, must be made aware of the absolute necessity that exists for clearness of thought, exactness of language, and a rigorous arrangement of ideas. He must feel confidence in the knowledge which he possesses, and he will then exhibit that confidence in the decision by which all

his actions will be characterized. As a text-book for illustrating in a precise method the materials of instruction, this work is especially designed; and the severity and inflexibility of order have not been departed from in treating of a single branch of the subject.

Among the modern investigations of great interest of which I have availed myself, I may particularly enumerate those of Sir Astley Cooper, Kiernan, Henle, Goodsir, and Searle, in addition to the important observations of other excellent anatomists.

My thanks are especially due to Sir Astley Cooper, who, with his usual urbanity, has furnished me with much useful information, and has permitted me to emblazon my pages with the flattering patronage of his name. I have regarded this condescension of so distinguished a surgeon and physiologist as a sacred trust reposed in my hands, and I have exerted myself to render my labours not unworthy of such gratifying confidence.

I hope I may be permitted to say that the Engravings are beautiful examples of a most instructive and valuable art. The advantages of such illustrations in a demonstrative science cannot be too highly appreciated. The mode in which the Engravings have been printed,—a distinct branch of art in itself,—will not pass unnoticed by those who are acquainted with the complicated process and extreme care which are necessary to the production of the delicacy and force of effect of such graphic illustrations.

In conclusion, it gives me much pleasure to express the obligations which are due from me to my friend and late pupil Mr. Oliver Thomas Miller, of Her Majesty's Navy, for the patient and industrious perseverance with which he devoted his time and ability during the summer months to assist me in the prosecution of my labours.

55 Upper Charlotte Street, Fitzroy Square,
March, 1840.

P R E F A C E

TO THE SECOND ENGLISH EDITION.

Two years have not yet elapsed since the First Edition of the Anatomist's Vade Mecum was presented to the public ; but that short period, brief though it is, has been most eventful as regards the history of this work.

The most prominent of the events to which I allude is the departure from this earthly sphere of the distinguished patron of my undertaking. When he was pleased to crown my labours with his sanction, and lend to them the brightness of his name, he was in the enjoyment of perfect health ; he was still labouring in the field of Medical Science, an untiring labourer ; he was still looking forward to a long vista of usefulness and benevolent action. Now, Sir Astley Cooper is no more. It is not my intention,—and, indeed, if I were so inclined, I should lack the ability,—to write the eulogium of that universally esteemed and noble-hearted man. I shall content myself with remarking, that in him I have lost a kind and a warm friend, the Medical Profession a distinguished ornament, and society a consolation and a resource under the torments of disease. Sir Astley Cooper was doubly eminent ; he was great as a scientific surgeon, but he was greater as a man ; and though in his former capacity his name will be remembered as long as letters endure, his memory will survive until the human heart shall cease to vibrate to the note of sympathy and benevolence.

But while I am thus humbly endeavouring to do justice to my own feelings in recording a feeble tribute towards a great debt of gratitude which I owe to the memory of Sir Astley Cooper, I do not forget that my warmest thanks are also due to my other patrons, the Medical Practitioners and Students of Great Britain, and to the conductors of the Medical Press. From the former I

take this opportunity of acknowledging the receipt of numerous letters containing the most cheering and gratifying expressions; and to the latter I am indebted for the independence of opinion, and liberality of sentiment, with which they have regarded my labours.

It has been no slight source of gratification to me, that the work should have received so much attention from the profession in distant countries. The Anatomist's Vade Mecum is to be reprinted in the United States of America; it is at this moment undergoing translation at Berlin; while repeated overtures have been made to Mr. Churchill for its publication in France.

I have endeavoured to render the present Edition more perfect than the preceding, by entering more fully into the description of such parts as were only scantily treated in the first. I regret that these additions have increased the size of the volume,—an effect that it has always been my foremost desire to avoid; for if a large and a verbose book be at any time a great evil, it is so to its fullest extent in a volume which is intended to record only facts, as is the case with a work on Anatomy.

In the present Edition, as in the former, I have availed myself of the labours of those who have been pursuing successfully separate branches of our science. Of them, I have recorded the investigations of Mr. Bowman, of King's College, on the minute anatomy of muscular fibre; of Mr. Nasmyth, on the development of the epithelium; and of Mr. Curling, of the London Hospital, on the descent of the testis in the fœtus. I have also contributed in this department some original researches, which I have myself made, on the minute structure of bone.

The principal additions to the present Edition will be found in the chapters on the ligaments, muscles, nervous system, organs of sense, and viscera. I have appended to each muscle a separate paragraph, indicating its relations to surrounding parts; and have augmented the number of wood-cut illustrations.

January, 1842.

P R E F A C E

TO THE FIRST AMERICAN EDITION.

IN republishing the present work, it was thought that its original title "Wilson's Anatomist's Vade Mecum," would lead to an incorrect appreciation of the nature and extent of the work; the term "Vade Mecum" being in this country usually applied to small and concise manuals. The present work is, as its American title implies, a complete System of Human Anatomy, brought up to the present day, and although it is written in a curt and concise style, nothing is omitted which can be deemed important by the student or the general practitioner.

In some points its author had not described parts and structures with sufficient accuracy, and had evidently neglected the contributions to the science from this side of the water; these deficiencies I have endeavoured to supply by notes and additional illustrations. Some few alterations of names have been made in the body of the work, where the author's names were too English, and not in common use in the United States.

The illustrations are by far the most beautiful which have ever appeared in any anatomical work, and much praise is due Mr. R. S. Gilbert of this city, for the masterly and spirited manner in which he has copied them. The originals were designed and executed expressly for this work, by Bagg, of London, whose reputation in this branch of art is deservedly high.

I have long been convinced that the day would come in which it would be useless to present to the public a work on science,

unless it was accompanied with numerous and exact illustrations, as the road to the mind is so much shorter and easier through the eye, than any other avenue. This fact has been appreciated by the student of anatomy for some time, and although numerous splendid works have appeared, there has been none which gave so many and exact views at so low a cost, as the present.

PAUL B. GODDARD.

Philadelphia, October, 1842.

PREFACE

TO THE SECOND AMERICAN EDITION.

THE very rapid sale of the first edition of this work, is evidence of its appreciation by the profession, and is most gratifying to the author and American editor. In preparing the present edition, no pains have been spared to render it as complete a Manual of Anatomy for the medical student as possible. A chapter on Histology has therefore been prefixed, and a considerable number of new cuts added. Among the latter are included some very fine ones of the nerves, which were almost wholly omitted from the original work. Great care has also been taken to have this edition correct, and the cuts carefully and beautifully worked, and it is confidently believed that it will give satisfaction, offering a further inducement to its general use as a **TEXT BOOK** in the various colleges.

Philadelphia, July, 1844.

CONTENTS.

CHAPTER I.

OSTEOLOGY.

<p>Definition—Chemical composition of bone — Division into classes 37</p> <p>Structure of bone 38</p> <p>Development of bone 41</p> <p>The skeleton 42</p> <p>Vertebral column 43</p> <p style="padding-left: 20px;">Cervical vertebræ 44</p> <p style="padding-left: 20px;">Atlas—Axis 44.45</p> <p style="padding-left: 20px;">Vertebra prominens 46</p> <p style="padding-left: 20px;">Dorsal vertebræ 46</p> <p style="padding-left: 20px;">Lumbar vertebræ 47</p> <p style="padding-left: 20px;">General considerations 47</p> <p style="padding-left: 20px;">Development 48</p> <p style="padding-left: 20px;">Attachment of muscles 48</p> <p style="padding-left: 20px;">Sacrum 49</p> <p style="padding-left: 20px;">Coccyx 50</p> <p>Bones of the cranium 50</p> <p style="padding-left: 20px;">Occipital bone 50</p> <p style="padding-left: 20px;">Parietal bone 53</p> <p style="padding-left: 20px;">Frontal bone 54</p> <p style="padding-left: 20px;">Temporal bone 56</p> <p style="padding-left: 20px;">Sphenoid bone 60</p> <p style="padding-left: 20px;">Ethmoid bone 64</p> <p>Bones of the face 65</p> <p style="padding-left: 20px;">Nasal 65</p> <p style="padding-left: 20px;">Superior maxillary 65</p> <p style="padding-left: 20px;">Lachrymal bone 68</p> <p style="padding-left: 20px;">Malar bone—Palate bone 68</p> <p style="padding-left: 20px;">Inferior turbinated bone 71</p> <p style="padding-left: 20px;">Inferior maxillary 71</p> <p>Table of developements, articulations, &c. 73</p> <p>Sutures 74</p>	<p>Regions of the skull 75</p> <p style="padding-left: 20px;">Base of the skull 79</p> <p style="padding-left: 20px;">Face 80</p> <p>Orbits 81</p> <p>Nasal fossæ 82</p> <p>Teeth 83</p> <p style="padding-left: 20px;">Structure 85</p> <p style="padding-left: 20px;">Development 86</p> <p style="padding-left: 20px;">Growth 89</p> <p style="padding-left: 20px;">Eruption 90</p> <p style="padding-left: 20px;">Succession 91</p> <p>Os hyoides 91</p> <p>Thorax and upper extremity 92</p> <p style="padding-left: 20px;">Sternum—Ribs 92</p> <p style="padding-left: 20px;">Costal cartilages 94</p> <p style="padding-left: 20px;">Clavicle—Scapula 94.95</p> <p style="padding-left: 20px;">Humerus 96</p> <p style="padding-left: 20px;">Ulna 98</p> <p style="padding-left: 20px;">Radius 99</p> <p style="padding-left: 20px;">Carpal bones 100</p> <p style="padding-left: 20px;">Metacarpal bones 104</p> <p style="padding-left: 20px;">Phalanges 105</p> <p>Pelvis and lower extremity 106</p> <p style="padding-left: 20px;">Os innominatum 106</p> <p style="padding-left: 20px;">Ilium—Iscium 106</p> <p style="padding-left: 20px;">Os pubis 108</p> <p>Pelvis—Its Divisions—Axes —Diameters 109</p> <p style="padding-left: 20px;">Femur 110</p> <p style="padding-left: 20px;">Patella—Tibia 113</p> <p style="padding-left: 20px;">Fibula 114</p> <p style="padding-left: 20px;">Tarsal bones 115</p> <p style="padding-left: 20px;">Metatarsal bones 118</p> <p style="padding-left: 20px;">Phalanges 120</p> <p style="padding-left: 20px;">Sesamoid bones 120</p>
---	--

CHAPTER II.

THE LIGAMENTS.

<p>Forms of articulation 122</p> <p style="padding-left: 20px;">Synarthrosis — Amphi-artrosis —Diarthrosis 122.123</p> <p>Movements of joints 124</p>	<p>Gliding—Angular movement 124</p> <p>Circumduction—Rotation 124</p> <p>General anatomy of articular structures 124</p>
---	--

Cartilage—Fibro-cartilage	- 124	Ligaments of the scapula	- - 142
Ligament—Synovial membrane	125	Shoulder-joint	- - - 142
LIGAMENTS OF THE TRUNK—AR-		Elbow-joint	- - - 143
RANGEMENT	- 126	Radio-ulnar articulation	- - 145
Articulation of the vertebral co-		Wrist-joint	- - - 146
lumn	- - - 126	Articulations of the carpal bones	147
Of the atlas with the occipital		Carpo-metacarpal articulation	- 148
bone	- - - 129	Metacarpo-phalangeal articula-	
Of the axis with the occipital		tion	- - - 149
bone	- - - 130	Articulation of the phalanges	- 149
Of the atlas with the axis	- 130	LIGAMENTS OF THE LOWER EXTRE-	
Of the lower jaw	- - 132	MITY	- - - 150
Of the ribs with the vertebræ	- 134	Hip-joint	- - - 150
Of the ribs with the sternum,		Knee-joint	- - - 151
and with each other	- 135	Articulation between the tibia	
Of the vertebral column, with		and fibula	- - - 156
the pelvis	- - - 136	Ankle-joint	- - - 157
Of the pelvis	- - - 136	Articulation of the tarsal bones	- 158
LIGAMENTS OF THE UPPER EXTRE-		Tarso-metatarsal articulation	- 160
MITY	- - - 139	Metatarso-phalangeal articula-	
Sterno-clavicular articulation	- 140	tion	- - - 161
Scapulo-clavicular articulation	- 141	Articulation of the phalanges	- 161

CHAPTER III.

THE MUSCLES.

General anatomy of muscle	- 162	Inferior labial group— <i>continued.</i>	
Nomenclature—Structure	- 163	Depressor labii inferioris	- - 176
MUSCLES OF THE HEAD AND FACE	- 166	Depressor anguli oris—Levator	
Arrangement into groups	- 167	labii inferioris	- - 176
Epieranian region—Dissection	- 167	Actions	- - - 176
Occipito-frontalis	- - 168	Maxillary group	- - - 176
Orbital group—Dissection	- 169	Masseter—Temporal muscle	176,177
Orbicularis palpebrarum	- 169	Buccinator—External ptery-	
Corrugator supercillii	- 169	goid muscle	177,178
Tensor tarsi	- - 170	Internal pterygoid muscle	- 178
Actions	- - 170	Actions	- - - 179
Ocular group—Dissection	- 170	Auricular group	- - - 179
Levator palpebræ—Rectus supe-		Dissection	- - - 179
rior	- - - 171	Attollens aurem—Attrahens	
Rectus inferior	- - - 171	aurem	- - - 179
Rectus internus	- - - 172	Retrahens aurem—Actions	- 179
Rectus externus—Obliquus su-		MUSCLES OF THE NECK	- - 180
perior	- - - 172	Arrangement into groups	- 180
Obliquus inferior—Actions	- 173	Superficial group—Dissection	- 180
Nasal group	- - - 173	Platysma myoides	- - - 181
Pyramidalis nasi	- - - 173	Sterno-cleido-mastoideus—	
Compressor nasi—Actions	- 173	Actions	- - - 181
Superior labial group	- - - 174	Depressors of the os hyoides	
Orbicularis oris—Levator labii		and larynx	- - - 183
superioris aëque nasi	- 174	Dissection	- - - 183
Levator labii superioris pro-		Sterno-hyoideus—Sterno-thy-	
prius	- - - 174	roides	- - - 183
Levator anguli oris—Zygoma-		Thyro-hyoideus—Omo-hyoi-	
tici	- - - 175	deus	- - - 183,184
Depressor labii superioris aë-		Actions	- - - 184
que nasi	- - - 175	Elevators of the os hyoides	- - 184
Actions	- - - 175	Dissection	- - - 185
Inferior labial group	- - - 176	Digastricus	- - - 185
Dissection	- - - 176	Stylo-hyoideus—mylo-hyoideus	185

Genio-hyoideus—Genio-hyoglossus	186	Muscles of the thorax	208
Actions	186	Intercostales externi et interni	208
Muscles of the tongue	186	Triangularis sterni	210
Hyo-glossus—Lingualis	187	Actions	210
Stylo-glossus	188	Muscles of the Abdomen	210
Palato-glossus—Actions	188	Dissection	210
Muscles of the pharynx	188	Obliquus externus	210
Dissection	188	Obliquus internus—Cremaster	211,212
Constrictor inferior	189	Transversalis—Rectus	213
Constrictor medius—Constrictor superior	189	Pyramidalis—Quadratus lumborum—Psoas parvus	214,215
Stylo-pharyngeus—Palato-pharyngeus—Actions	190	Diaphragm	215
Muscles of the soft palate	191	Actions	217
Dissection	191	Muscles of the perineum	218
Levator palati—Tensor palati	191	Dissection	218
Azygos uvulæ—Palato-glossus	192	Acceleratores urinæ	219
Palato-pharyngeus—Actions	192	Erector penis—Transversus perinei	219
Prævertebral muscles	193	Compressor urethræ	220
Dissection	193	Sphincter ani externus et internus	221
Rectus anticus major—Rectus anticus minor	193	Levator ani—Coccygeus	221,222
Scalenus anticus—Scalenus posticus	193	Muscles of the female perineum	222
Longus colli	194	MUSCLES OF THE UPPER EXTREMITY	223
Actions	195	Anterior thoracic region	224
MUSCLES OF THE TRUNK	195	Dissection	224
Muscles of the back—Arrangement	195	Pectoralis major	225
First layer—Dissection	195	Pectoralis minor—Subclavius—Actions	225,226
Trapezius	196	Lateral thoracic region	226
Latissimus dorsi	196	Serratus magnus—Actions	226
Second layer—Dissection	197	Anterior scapular region	226
Levator anguli scapulæ	197	Scapularis	226
Rhomboideus minor et major	197	Actions	227
Third layer—Dissection	199	Posterior scapular region	227
Serratus posticus superior et inferior	199	Supra-spinatus—Infra-spinatus	227
Splenius capitis et colli	199	Teres minor—Teres major	227,228
Fourth layer—Dissection	200	Actions	228
Sacro-lumbalis—Longissimus dorsi	200	Acromial region	228
Spinalis dorsi	200	Deltoid—Actions	228
Cervicalis ascendens—Transversalis colli	201	Anterior humeral region	229
Trachelo-mastoideus—Complexus	202	Dissection	229
Fifth layer—Dissection	202	Coraco-brachialis—Biceps	229
Semispinalis dorsi et colli	202	Brachialis anticus—Actions	230
Rectus posticus, major et minor	203	Posterior humeral region	230
Rectus lateralis—Obliquus inferior	203	Triceps	230
Obliquus superior	203	Anterior brachial region	232
Sixth layer—Dissection	203	Superficial layer—Dissection	232
Multifidus spinæ—Levatores costarum	203	Pronator radii teres	232
Supra-spinales—Inter-spinales	204	Flexor carpi radialis	232
Inter-transversales	204	Palmaris longus	232
Actions	204	Flexor sublimis digitorum	233
Table of origins and insertions of the muscles of the back	206	Flexor carpi ulnaris	234
		Deep layer—Dissection	234
		Flexor profundus digitorum	234
		Flexor longus pollicis	235
		Pronator quadratus—Actions	235
		Posterior brachial region	235
		Superficial layer—Dissection	236
		Supinator longus	236

Posterior brachial region— <i>continued</i> .	Internal femoral region—Dissec-
Extensor carpi radialis lon-	tion 252
gior 236	Iliacus internus 252
Extensor carpi radialis bre-	Psoas magnus—Pectineus—
vior 236	Abductor longus 253
Extensor communis digito-	Abductor brevis—Abductor
rum 236	magnus—Gracilis 254
Extensor minimi digiti 238	Actions 254
Extensor carpi ulnaris—An-	Posterior femoral region—Dis-
concus 238	section 255
Deep layer—Dissection 238	Biceps flexor cruris 255
Supinator brevis 238	Semi-tendinosus—Semi-mem-
Extensor ossis metacarpi pol-	branosus 255
licis 239	Actions 256
Extensor primi internodii pol-	Anterior tibial region—Dissec-
licis 239	tion 256
Extensor secundi internodii	Tibialis anticus 257
pollicis 239	Extensor longus digitorum 257
Extensor indicis 239	Peroneus tertius—Extensor
Actions 240	proprius pollicis 257
Muscles of the hand 240	Actions 258
Radial region—Dissection 240	Posterior tibial region 258
Ulnar region—Dissection 241	Superficial layer—Dissection 258
Palmar region 242	Gastrocnemius 258
Actions 244	Plantaris—Soleus—Ac-
MUSCLES OF THE LOWER EXTREMITY 244	tions 259, 260
Gluteal region—Dissection 246	Deep layer—Dissection 260
Gluteus maximus 246	Popliteus—Flexor longus
Gluteus medius et minimus 247	pollicis 260
Pyramidalis 247	Flexor longus digitorum 261
Gemellus superior—Obturator	Tibialis posticus 261
internus 248	Actions 262
Gemellus inferior—Obturator	Fibular region 262
externus 248	Peroneus longus—Peroneus
Quadratus femoris 249	brevis 262, 263
Actions 249	Actions 263
Anterior femoral region—Dissec-	Foot—Dorsal region 263
tion 249	Plantar region 264
Tensor vaginæ femoris—Sar-	First layer—Dissection 264
torius 250	Second layer—Dissection 266
Rectus—Vastus externus 251	Third layer—Dissection 266
Vastus internus—Crureus 251	Fourth layer 267
Actions 252	Actions 268

CHAPTER IV.

THE FASCIAE.

General anatomy 270	Fascia iliaca 275
FASCIAE OF THE HEAD AND NECK 271	Fascia pelvica 276
Temporal fascia 271	Obturator fascia 277
Cervical fascia 271	Superficial perineal fascia 277
FASCIAE OF THE TRUNK 272	Deep perineal fascia 278
Thoracic fascia 272	FASCIAE OF THE UPPER EXTREMITY 279
Fascia transversalis 273	FASCIAE OF THE LOWER EXTRE-
Oblique inguinal hernia 274	MITY 280
Congenital hernia 275	Fascia lata 280
Encysted hernia 275	Femoral hernia 282
Direct inguinal hernia 275	Plantar fascia 283

CHAPTER V.

THE ARTERIES.

General anatomy of arteries -	285	Subclavian artery— <i>continued.</i>	
Inosculations—Structure -	286	Superficialis cervicis—Profunda	
Aorta -	287	cervicis -	311
Table of branches -	289	Superior intercostal artery—In-	
Coronary arteries -	291	ternal mammary -	311
Arteria innominata -	291	Axillary artery -	313
Common carotid arteries -	292	Table of branches -	314
External carotid artery -	293	Brachial artery -	316
Table of branches -	294	Radial artery -	317
Superior thyroid artery -	294	Ulnar artery -	320
Lingual artery -	295	Thoracic aorta; branches -	322
Facial artery -	296	Abdominal aorta; branches -	323
Mastoid artery -	297	Phrenic arteries -	323
Occipital artery -	297	Cœliac axis—Gastric artery -	323
Posterior auricular artery -	298	Hepatic artery -	324
Parotidean arteries -	298	Splenic artery -	325
Ascending pharyngeal artery -	298	Superior mesenteric artery -	326
Transverse facial artery -	298	Spermatic arteries -	328
Temporal artery -	299	Inferior mesenteric artery -	329
Internal maxillary artery -	299	Renal arteries -	330
Internal carotid artery -	302	Common iliac arteries -	331
Ophthalmic artery -	304	Internal iliac artery -	331
Anterior cerebral artery -	305	Ischiatic -	333
Middle cerebral artery -	306	Internal pudic artery -	334
Subclavian artery -	306	External iliac artery -	337
Table of branches -	307	Femoral artery -	338
Vertebral artery -	308	Popliteal artery -	342
Basilar artery -	308	Anterior tibial artery -	343
Thyroid axis—Inferior thyroid		Dorsalis pedis artery -	345
artery -	310	Posterior tibial artery -	347
Supra-scapular artery — Poste-		Peroneal artery -	347
rior scapula -	310	Plantar arteries -	348
Circle of Willis -	310	Pulmonary artery -	350

CHAPTER VI.

THE VEINS.

General anatomy -	352	Veins of the trunk— <i>continued.</i>	
Veins of the head and neck -	354	Superior vena cava -	364
Veins of the diploë -	355	Iliac veins -	365
Cerebral and cerebellar veins -	355	Inferior vena cava -	366
Sinuses of the dura mater -	356	Azygos veins -	367
Veins of the neck -	359	Vertebral and spinal veins -	368
Veins of the upper extremity -	361	Cardiac veins -	368
Veins of the lower extremity -	363	Portal vein -	369
Veins of the trunk -	364	Pulmonary veins -	370
Venæ innominatæ -	364		

CHAPTER VII.

THE LYMPHATICS.

General anatomy -	372	Lymphatics of the viscera - . .	377
Lymphatics of the head and neck -	373	Lacteals -	937
Lymphatics of the upper extremity	374	Thoracic duct,	379
Lymphatics of the lower extremity	375	Ductus lymphaticus dexter - .	381
Lymphatics of the trunk	376		

CHAPTER VIII.

THE NERVOUS SYSTEM.

General anatomy -	382	Spinal cord -	407
The brain	387	Cranial nerves	411
Membranes of the encephalon -	387	Nerves of special sense - . .	412
Dura mater -	387	Nerves of motion -	414
Arachnoid membrane - . . .	390	Respiratory nerves -	417
Pia mater -	391	Trifacial nerve -	424
Cerebrum -	391	Spinal nerves -	429
Lateral ventricle -	392	Cervical plexus -	431
Fifth ventricle -	396	Brachial plexus -	433
Third ventricle -	398	Dorsal nerves -	440
Fourth ventricle -	399	Lumbar nerves -	442
Lining membrane of the ventri-		Sacral nerves -	446
cles -	400	Sympathetic system -	453
Cerebellum -	400	Cranial ganglia -	454
Base of the brain -	401	Cervical ganglia -	458
Medulla oblongata -	403	Thoracic ganglia -	461
Diverging fibres -	406	Lumbar ganglia -	463
Converging fibres; commissures -	406	Sacral ganglia -	463

CHAPTER IX.

ORGANS OF SENSE.

Nose -	464	Organ of hearing— <i>continued.</i>	
Nasal fossæ -	466	Tympaanum -	480
Eyeball -	467	Ossicula auditus -	481
Sclerotic coat and cornea - . .	467	Muscles of the tympaanum - .	482
Choroid coat; ciliary ligament;		Internal ear—Vestibule - . .	485
iris -	469	Semicircular canals -	486
Retina; zonula ciliaris - . . .	471	Cochlea -	487
Humours -	473	Membranous labyrinth - . . .	488
Physiological observations - .	474	Organ of taste—Tongue - . . .	491
Appendages of the eye -	475	Organ of touch—Skin -	492
Lachrymal apparatus -	477	Appendages to the skin—Nails -	495
Organ of hearing -	478	Hairs—Sebaceous glands - .	496
External ear; pinna; meatus -	478	Perspiratory ducts—Pores - .	496

CHAPTER X.

THE VISCERA.

THORAX - - - - -	497	ABDOMEN— <i>continued.</i>	
Heart - - - - -	497	Anus - - - - -	532
Pericardium - - - - -	497	Liver - - - - -	539
Adult circulation - - - - -	498	Kiernan's researches - - - - -	543
Structure of the heart—Searle's		Gall bladder - - - - -	550
researches - - - - -	504	Pancreas - - - - -	551
Organs of respiration and voice - - - - -	507	Spleen - - - - -	552
Larynx—Cartilages - - - - -	508	Supra-renal capsules - - - - -	553
Ligaments—Muscles - - - - -	509	Kidneys - - - - -	554
Trachea and Bronchi - - - - -	513	PELVIS - - - - -	557
Thyroid gland - - - - -	513	Bladder - - - - -	557
Lungs - - - - -	514	Prostatic gland - - - - -	560
Pleuræ - - - - -	517	Vesiculæ seminales - - - - -	561
Mediastinum - - - - -	517	MALE ORGANS OF GENERATION - - - - -	562
ABDOMEN—Regions - - - - -	518	Penis - - - - -	562
Peritonæum - - - - -	518	Urethra - - - - -	564
Alimentary canal - - - - -	523	Testes - - - - -	567
Lips—Cheeks—Gums—Pa-		FEMALE PELVIS - - - - -	571
late - - - - -	524	Bladder—Urethra - - - - -	572
Tonsils—Fauces - - - - -	525	Vagina - - - - -	572
Salivary glands - - - - -	525	Uterus - - - - -	573
Pharynx - - - - -	527	Fallopian tubes - - - - -	576
Stomach - - - - -	528	Ovaries - - - - -	577
Small intestine - - - - -	528	External organs of generation - - - - -	577
Large intestine - - - - -	530	MAMMARY GLANDS - - - - -	579
Structure of the intestinal canal	532		

CHAPTER XI.

ANATOMY OF THE FŒTUS.

Osseous and ligamentous system - - - - -	581	Fœtal heart - - - - -	587
Muscular system - - - - -	581	Viscera of the abdomen - - - - -	588
Vascular system - - - - -	581	Omphalo-mesenteric vessels - - - - -	588
Fœtal circulation - - - - -	581	Liver - - - - -	588
Nervous system - - - - -	584	Kidneys and supra-renal cap-	
Organs of sense—Eye—Ear—Nose	584	sules - - - - -	589
Thyroid gland - - - - -	584	Viscera of the pelvis - - - - -	589
Thymus gland - - - - -	585	Testes—Descent - - - - -	590
Fœtal lungs - - - - -	587		

TABLE OF ILLUSTRATIONS.

1. Minute structure of bone	39	36. Ulna and Radius	99
2. Id. id. id.	40	37. Bones of the carpus; posterior view	101
3. Cervical vertebra	44	38. Hand; anterior view	104
4. Atlas	45	39. Os innominatum	106
5. Axis	45	40. Femur; anterior view	111
6. Dorsal vertebra	46	41. Femur; posterior view	112
7. Lumbar vertebra	47	42. Tibia and fibula	113
8. Sacrum	49	43. Foot; dorsal surface	115
9. Occipital bone—External surface	50	44. Foot; plantar surface	119
10. Occipital bone—Internal surface	52	45. Ligaments of the vertebræ and ribs; anterior view	127
11. Parietal bone—External surface	53	46. Posterior common ligament	128
12. Parietal bone—Internal surface	54	47. Ligamenta subflava	128
13. Frontal bone—External surface	55	48. Ligaments of the atlas, axis, and occipital bone; anterior view	129
14. Frontal bone—Internal surface	56	49. Id.; posterior view	129
15. Temporal bone—External surface	57	50. Id.; internal view	130
16. Temporal bone—Internal surface	58	51. Id.; internal view	131
17. Sphenoid bone—Superior surface	61	52. Ligaments of the lower jaw; external view	132
18. Sphenoid bone—antero-inferior surface	62	53. Id.; internal view	134
19. Ethmoid bone	64	54. Id.; section	134
20. Superior maxillary bone	66	55. Ligaments of the vertebral column and ribs; posterior view	135
21. Palate bone—Internal surface	69	56. Ligaments of the pelvis and hip-joint	137
22. Palate bone—External surface	70	57. Id. id.	138
23. Inferior maxillary bone	72	58. Ligaments of the sternal end of the clavicle and costal cartilages	141
24. Skull—anterior view	76	59. Ligaments of the scapula and shoulder-joint	142
25. Base of the skull; internal view	76	60. Ligaments of the elbow; internal view	144
26. Base of the skull; external view	79	61. Id. external view	144
27. Permanent teeth	83	62. Coronary ligament of radius	145
28. Temporary teeth	84	63. Ligaments of the wrist and hand	146
29. Structure of tooth	85	64. Synovial membranes of the wrist	148
30. Rudimentary teeth	89	65. Knee-joint; anterior view	152
31. Gubernaculum dentis	90	66. Id.; posterior view	153
32. Os hyoides	91	67. Id.; internal view	154
33. Thorax	93	68. Id.; reflections of the synovial membrane	154
34. Scapula	95		
35. Humerus	97		

69. Ankle-joint; internal view -	157	109. Muscles of the sole of the foot,	
70. Id. external view -	157	deep layer -	266
71. Id. posterior view -	159	110. Dorsal interossei muscles -	268
72. Ligaments of the sole of the		111. Plantar interossei muscles -	268
foot -	160	112. Section of the neck, showing	
73. Minute structure of muscle -	163	the distribution of the deep	
74. Id. id. id. -	164	cervical fascia -	272
75. Id. id. id. -	165	113. Transverse section of the pel-	
76. Id. id. id. -	166	vis, showing the distribution	
77. Muscles of the face -	168	of the fasciæ -	276
78. Tensor tarsi muscle -	170	114. Deep perineal fascia -	277
79. Muscles of the orbit -	171	115. Distribution of the deep peri-	
80. Pterygoid muscles -	178	neal fascia, side view -	278
81. Muscles of the neck; super-		116. Distribution of the fasciæ; at	
ficial and deep -	182	the femoral arch -	281
82. Muscles of the tongue -	187	117. The great vessels of the chest	288
83. Muscles of the pharynx -	190	118. Branches of the external caro-	
84. Muscles of the soft palate -	191	tid artery -	295
85. Muscles of the prævertebral		119. Internal maxillary artery -	300
region -	193	120. Branches of the subclavian	
86. Muscles of the back; 1st, 2d,		artery -	308
and 3d layer -	198	121. The circle of Willis -	311
87. Muscles of the back; deep		122. Axillary and brachial arteries	315
layer -	201	123. Arteries of the fore-arm—Ra-	
88. Muscular of the anterior as-		dial and ulnar -	319
pect of the trunk -	209	124. Branches of the abdominal	
89. Muscles of the lateral aspect		aorta -	324
of the trunk -	214	125. Cœliac axis with its branches	326
90. Diaphragm -	216	126. The superior mesenteric ar-	
91. Muscles of the perineum -	220	tery -	327
92. Muscles of the anterior hume-		127. The inferior mesenteric ar-	
ral region -	229	tery -	329
93. Triceps extensor cubiti -	231	128. The internal iliac artery with	
94. Superficial layer of muscles		its branches -	332
of the anterior aspect of the		129. The arteries of the perineum	333
fore-arm -	233	130. The femoral artery with its	
95. Deep layer of muscles of the		branches -	338
anterior aspect of the fore-		131. The anterior tibial artery -	346
arm -	233	132. Posterior tibial and peroneal	
96. Superficial layer of muscles;		artery -	346
posterior aspect of the fore-		133. Arteries of the sole of the foot	349
arm -	237	134. Sinuses of the dura mater -	357
97. Deep layer; posterior aspect		135. Sinuses of the base of the skull	358
of the fore-arm -	237	136. Veins and nerves of the bend	
98. Muscles of the hand, anterior		of the elbow -	362
aspect -	241	137. Veins of the trunk and neck	365
99. Palmar interossei muscles -	243	138. The portal vein -	370
100. Dorsal interossei muscles -	243	139. The thoracic duct -	380
101. Muscles of the gluteal region,		140. The lateral ventricles of the	
deep layer -	247	cerebrum -	393
102. Muscles of the anterior and		141. Longitudinal section of the	
internal femoral region -	250	brain -	397
103. Muscles of the gluteal and		142. Base of the brain -	404
posterior femoral region -	256	143. Distribution of the fibres of	
104. Muscles of the anterior tibial		the brain -	405
region -	259	144. Sections of the spinal marrow	410
105. Muscles of the posterior tibial		145. Olfactory nerve, view of -	412
region, superficial layer -	259	146. Optic nerves, view of -	413
106. Muscles of the posterior tibial		147. Auditory nerve, view of -	413
region, deep layer -	261	148. 3d, 4th, and 6th nerves, view of	414
107. Muscles of the sole of the foot,		149. Nerves of the tongue and neck	415
1st layer -	265	150. Facial nerve and superficial	
108. 2d layer -	265	cervical nerves -	419

151. Origin and distribution of the eighth pair of nerves -	423	180. Anatomy of the stomach and duodenum - - -	529
152. Branches of the trifacial nerve	425	181. Columns and pouches of the rectum - - -	534
153. Axillary plexus and nerves of the upper extremity - -	434	182. Peyer's glands - - -	536
154. Nerves of front of the forearm - - -	437	183. Muscular coat of the rectum	538
155. Nerves of back of the forearm	438	184. The liver; its upper surface	539
156. Lumbar and sacral plexus, with the nerves of the lower extremity - - -	442	185. The liver; its under surface	541
157. Anterior crural nerve - -	444	186. Lobules of the liver - -	544
158. Branches of ischiatic plexus	447	187. Horizontal section of three superficial lobules - -	545
159. Branches of popliteal nerve -	450	188. Horizontal section of two superficial lobules - -	545
160. Posterior tibial nerve - -	450	189. Section of the kidney - -	555
161. Nerves of the sole of the foot	451	190. A side view of the viscera of the male pelvis - -	556
162. Anterior tibial nerve - -	452	191. Neck of the bladder - -	559
163. The cranial ganglia of the sympathetic nerve - -	454	192. A posterior view of the bladder and vesiculæ seminales	561
164. Great sympathetic nerve -	459	193. Anatomy of the urethra -	565
165. Fibro-cartilages of the nose	465	194. Transverse section of the testicle - - -	568
166. Longitudinal section of the globe of the eye - -	468	195. Human testis injected with mercury - - -	569
167. A transverse section of the globe of the eye - -	471	196. Anatomy of the testis - -	570
168. Another transverse section of the globe of the eye - -	472	197. A side view of the viscera of the female pelvis - -	573
169. A diagram of the ear - -	482	198. Uterus - - -	575
170. Anatomy of the cochlea -	487	199. Section of the uterus (transverse) - - -	575
171. Osseous and membranous labyrinth of the ear - -	489	200. Female organs of generation—External - - -	578
172. The anatomy of the skin -	493	201. Fœtal circulation - - -	582
173. Id. id. - - -	494	202. Section of the thymus gland	585
174. The heart - - -	498	203. Ducts of the thymus gland -	586
175. Muscles of the larynx - -	510	204. Descent of the testis in the fœtus - - -	590
176. Id. id. - - -	510	205. Id. id. - - -	590
177. Anatomy of the lungs and heart - - -	515	Vignette.	
178. The peritoneum - - -	519	Time and Death, Face title.	
179. The pharynx - - -	527		

PRELIMINARY CHAPTER ON HISTOLOGY.

BY THE EDITOR.

ANATOMY.

WHEN we examine the structure of an animal body we find that it is composed of a variety of textures, some of which are universally and others partially diffused through it. These textures, or more properly tissues, when studied in detail, constitute what is called General Anatomy.

When we take another view of the subject, we discover that the body is composed of a variety of organs—as the heart, brain, lungs, &c., which are constituted by these tissues, and which are possessed of a definite form, colour and consistency, the description of which constitutes Special Anatomy.

In teaching Special Anatomy we describe an organ or viscus as *isolated* from every other organ, or as if it had a separate existence. When we begin to describe the relations of neighbouring organs to each other we approach Topographical or Surgical Anatomy, which consists in a topographical division of the body, or a mapping it out into regions, and describing every tissue contained in a region with their relations to each other. This to the surgeon is by far the most important division of the subject, and from its subservience to this branch of medical science it has received the name of Surgical Anatomy.

DIVISION INTO TISSUES.

The body of every animal consists of various tissues, which may be distinctly separated from each other and recognised by characteristic properties. Some of these tissues present varieties, and might even be subdivided, but as this process would unnecessarily complicate their study, it has not been thought proper to adopt it.

The solids alone can be reckoned as tissues, although the so-called fluids contain solid organized corpuscles, and consequently may be treated of with the tissues proper.

These textures may therefore be enumerated as follows:

1. Corpuscular tissue, found in the blood, lymph and chyle.
2. Epidermoid tissue; example—epithelium, cuticle, hair, nails.
3. Pigmentary tissue, found in choroid coat of eye, lung.
4. Adipose tissue, as fat.
5. Cellular tissue.
6. Fibrous tissue.

7. Elastic tissue, ligamenta flava, middle coat of the arteries.
8. Cartilaginous tissue, including fibro-cartilage.
9. Osseous tissue.
10. Muscular tissue.
11. Nervous tissue.
12. Vascular tissue, arteries, veins and lymphatics.
13. Serous tissue, including synovial.
14. Mucous tissue.
15. Dermoid tissue.
16. Glandular tissue.
17. Refracting tissue, lens of eye, cornea.
18. Petrous tissue, enamel of teeth.

The whole of these tissues, however, may be resolved into—
 1, simple fibre; 2, homogeneous membrane; 3, cells or granules;
 and 4, amorphous matter.

PHYSICAL PROPERTIES OF THE TISSUES.

The tissues, like other forms of matter, possess certain physical properties, such as colour, consistency, and density, which it is necessary to describe under their respective heads. One property, however, is enjoyed by every tissue, and this seems to play a most important part in the maintenance of the functions of life. I allude to the transudation of the solids by the fluids, which is known by the title of *endosmosis* and *exosmosis*, names by which the process was designated by Dutrochet, its discoverer. All the tissues contain a certain quantity of water, and in some cases this amounts to four-fifths of their weight, as may be proved by drying them; and this water is essential, not only to their vitality, but confers upon them their organic properties—pliability and elasticity. As the tissues imbibe water in certain quantity, it becomes a subject of study to discover the manner by which the quantity may be increased. It is well understood how pressure from without would produce this effect, but even this would be aided by the natural tendency to imbibe and retain an additional quantity of water under favourable circumstances, which is strongly exhibited by the softer tissues. Such a tissue saturated with water placed in contact with another tissue or a fluid having a higher affinity for water, will part with its superabundance, and if not supplied from behind will even part with a portion of that which is essential to its normal condition. If, however, it is supplied from the other side, it will continue to feed the greedy fluid on one side and freely drink from the supply on the other. Thus a current will be established from the water on one side of the tissue to the fluid having a high affinity for it on the other; but this is not all: for the fluid alluded to, not content with absorbing all the water which the animal tissue supplies it with, in its turn transudes the tissue to get at and mix with the water on the other side, and thus a counter-current is set up in an opposite direction, which is slower, however, than the former one. These are the currents which are

termed endosmotic and exosmotic, and which continue until the relative disagreement of the two liquids ceases, and they are equally saturated by each other.

A curious circumstance may be mentioned as illustrative of the various affinities of different substances for water. The following substances, when of the same density, attract water from the tissues in the ratio of the numbers following them, viz: albumen, 12; sugar, 11; gum, 5.17; gelatine, 3. This peculiar action of liquids upon animal tissues is not confined to liquids, but is also exerted upon, aeriform fluids, and with exalted intensity and rapidity. It is, however, believed by many, that the gases do not pass as gases, but that they are absorbed by the water of the tissue on one side, and after transuding it in solution are given off on the other.

CHEMICAL PROPERTIES OF THE TISSUES.

These may be arranged under two heads.

1st. The properties of the elements into which the body of an animal may be resolved by decomposition; and,

2d. The properties of the definite organic compounds which form the tissues.

The following chemical elements have been obtained from the human body; the four first constituting the chief bulk of it, and those at the end of the list existing only in very minute proportion, and perhaps not essential to it.

1. Oxygen.
2. Hydrogen.
3. Carbon.
4. Nitrogen.
5. Phosphorus.
6. Sulphur.
7. Chlorine.
8. Fluorine.
9. Potassium.
10. Sodium.
11. Calcium.
12. Magnesium.
13. Iron.
14. Silicon.
15. Manganese.
16. Aluminum.
17. Copper.

The definite organic compounds of which the body is composed, possess the following leading properties. 1. They all contain carbon, oxygen and hydrogen, and the larger number nitrogen. 2. They are all decomposed by a red heat; and 3d. They are prone to putrefaction or spontaneous decomposition. They may be thus enumerated:

1st. Azotized substances, or those which contain nitrogen.

Albumen,
Fibrin,
Casein,
Gelatin,
Chondrin,
Alcoholic extractive,
Watery extractive,
Salivin,
Kreatin,
Pepsin,
Globulin,
Mucus,
Keratin,
Pigment,
Hematin,
Pyin,
Urea,
Uric acid,
and some of the biliary compounds.

2d. Non-azotized substances, or those which are destitute of nitrogen.

Fat,
Sugar of milk,
Lactic acid,
and some of the biliary compounds.

VITAL PROPERTIES.

The most prominent vital property possessed by the tissues is the power of assimilation, or of appropriating to themselves such of the organizable substances presented to them as may suit their purposes. This power is supposed to be partly due to chemical affinity, and partly to *vital affinity*. It is most probable, however, that future researches will prove that the power of assimilating is subject to the ordinary chemical laws, but under modifying circumstances, which can only exist in a living body or tissue.

Another property which is essentially vital is contractility—a phenomenon which is made manifest by the visible shrinking or contraction of a living tissue when irritated, either by mechanical or chemical stimuli. The muscular tissue exhibits this property in the highest degree. This contractility must be distinguished from the permanent contraction or crispation which a part suffers when exposed to a high temperature.

A third vital property is sensibility, which, however, requires that the tissues shall be united so as to form a continuous line from the part manifesting it to the brain. This property is enjoyed in very different degrees by the different tissues, and constitutes an important distinction between them.

DEVELOPEMENT OF THE TISSUES.

It cannot fail to excite surprise in the mind of the tyro, when he is told that all the tissues, however diversified, however unlike, originate from a similar form of matter, and in the same manner.

This fact, which recent researches have placed beyond a doubt as regards vegetable structure, is scarcely cavilled at even with regard to the complex parts of an animal body. The study of this subject is, however, still in progress, and it requires more researches to make us masters of it. In the mean time we will endeavour to explain the mode of formation of the tissues as far as is known, and for this purpose must commence with the history of the vegetable, as an introduction to the more complicated but similarly formed animal.

All vegetable structure has its origin from a minute vesicle or cell: an organized corpuscle of a rounded or oval shape in the commencement of its existence, but capable of assuming any shape on coming in contact with a fellow cell, and taking its place as a part of a higher organization.

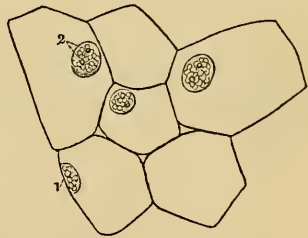
This cell consists of a thin transparent flexible wall or bag of homogeneous texture, which contains a fluid as well as a more solid body, which is generally attached to one side of the cell-wall, and is called its nucleus. As in the progress of development this nucleus occasionally disappears, some cells when examined are found to be destitute of it, and this causes us to apply the name nucleated cell to those in which it still exists, and simply cell to those from which it has disappeared. There is, however, no essential difference between these varieties, except in age, for it cannot be questioned that every cell is nucleated in the earlier portions of its existence.

The accompanying cut exhibits a group of nucleated vegetable cells.

There is also a little body which is sometimes found in the nucleus, and which appears to differ in its organization from the rest of this substance, and is called nucleolus. (See cut.)

These cells, by aggregation, form every part of the texture of a vegetable, but whilst many of them retain the cellular form, a still greater number undergo such transformations that their origin could hardly be suspected, had not the series of changes which led to the transformation been so faithfully studied and carefully verified. It may be useful to detail some of the changes which the cells undergo in being transformed into the more complex structures.

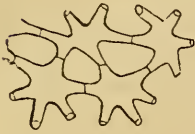1. The cells may simply enlarge, retaining their form, or they may enlarge at the same time that they alter their form.



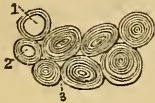1. Nucleus attached to the cell-wall. 2. Nucleoli.

2. They alter their shape: thus if many rounded cells press upon each other a polyhedral form will be produced; or they may elongate like a sausage, or they may flatten, or acquire a prismatic or conical or tubular shape.

3. Cells may coalesce with adjoining cells, and thus form tubes or ducts, as is seen in the adjoining cut, taken from the cellular tissue of the common bulrush, where they are of a hexagonal shape.



4. Changes occur in the fluid contents of the cell. Thus the contained fluid may be converted into gum, sugar, jelly, colouring matter, essential oil, &c., or it may solidify on the internal face of the cell-wall and thus thicken it, and, by a continuation of this process, may deposit layer after layer until the cavity of the cell is nearly or quite obliterated, and it becomes a solid. These internal layers are called "secondary deposits," and are well represented by the accompanying cut.



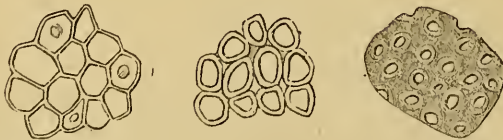5. Cells produce or generate new cells, and this may take place in several modes.

We may now apply these facts to the development of *animal tissues*, which, more complicated and containing more elements, requires a more complex process.

The animal commences from a congeries of cells, in some of which changes take place precisely analogous to those of the vegetable kingdom; in fact it may be said, that man, placed at the summit of complex organization, originates from a single cell, for in what other light can we view that portion of the ovum in which the embryo is developed?

As an instance of the analogy between animal and vegetable origin, we may examine the development of cartilage.

In the formation of this tissue the cells first coalesce, and then are thickened by a deposit on the internal paries of the cell-wall of chondrin, which finally fills up the cell so completely, that a scarcely perceptible cavity is seen in the centre. These changes are here exhibited.



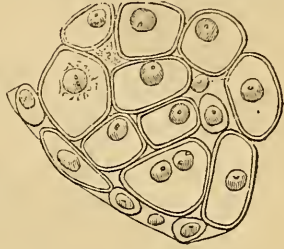
We may now examine the mode of origin of the cell itself, before proceeding to the study of the more composite changes, which are to be found solely in the bodies of animals.

A cell originates in a mass of soft or liquid matter, which is *organizable* or capable of being *organized*. In other words, a liquid

1. Cell with a secondary deposit. 2. Cell with a third deposit. 3. Cell filled with deposits.

formed of a combination of elements fitted to produce an organized structure. This substance is called "*blastema*," and has the same relation to a cell as a womb to an embryo. As an example, we may take the liquor sanguinis or the blood, excluding its globules, which in a fully formed animal is a universally diffused *blastema*.

The original cells must be formed in this blastema, but they may increase in number, both by new ones forming in it, or by the first formed cells generating others in their interior.



It is probable that the nucleus is a congeries of cell-germs, and that when one is developed we have what we call a nucleated cell, but as they are all capable of development, they may form a congeries of cells, which will consequently be destitute of nuclei.

MULTIPLICATION OF CELLS.

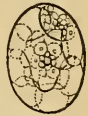Cells are multiplied in several different ways.

1st. They may be formed upon a nucleus. The mode in which cells are thus formed, is well shown by the following cut from Schleiden.

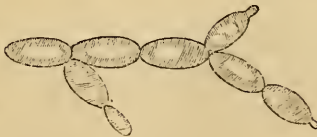

2d. The nucleus may be resolved into new cells within the primitive cell, as is shown by the following cut.

3d. Matter may collect around a cell, and a new wall be thus formed for it, which may be considered the cell, and the primitive cell take the place of its nucleus. Such cells are called *complex cells*. The best example of this is found in the development of the ovum after impregnation.



4th. A cell may arise from the wall of a previously formed cell. This occurs in diseased or abnormal deposits.



TRANSFORMATION OF ANIMAL CELLS.

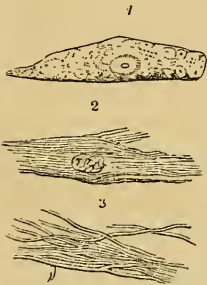
1. Cells increase in size and change their shape. The cut on the next page gives a good idea of the bizarre and erratic forms which cells occasionally assume.

2. Cells undergo an alteration of their substance and contents. Thus the cell-walls may acquire thickness, or the whole cell may flatten and its parietes coalesce, and thus a simple flat disk be the result. A cell may also change its chemical character, an instance of which is afforded by the cells of the cuticle, which, once soluble in acetic acid, become insoluble in the same after acquiring their corneous character.



New deposits may also, as has before been stated, occur within the cell, so as almost to obliterate its cavity.

3. Division into fibrils. This occurs in the formation of feathers in birds. A cell elongates and becomes filled with fibres, which on the sloughing away of the cell-wall remain and form the structure of the feathers.



4. They change their relations to each other. There is an exception to this, however, in the cells of the blood or blood-globules, which always remain isolated.

a. They may be united by an intervening substance, the remains of the blastema, which may thus form a lamina, as cuticle.

b. They may blend their parietes, as in the case of cartilage.

c. They may coalesce at certain points, and their parietes disappearing at the place of contact, a tubular canal may be formed. In this way new vessels are organized. This tubular canal becoming the seat of a new and peculiar deposit, a solid fibre results, thus muscles and nerves are formed.

TRANSFORMATION OF THE BLASTEMA.

It is supposed, in addition to the formation of tissues by cells, that the blastema may organize itself into fibres, &c., but it has been observed, that when such an occurrence takes place, that nuclei are always present. Homogeneous films and fibres are thus formed.

This can be readily understood when we reflect that a fluid is a collection of homogeneous particles which move freely on each other, and there is no difficulty in supposing these particles to approach each other and coalesce so as to form a film or a fibre.

SYSTEM OF HUMAN ANATOMY.

CHAPTER I.

OSTEOLOGY.

THE bones are the organs of support to the animal frame; they give firmness and strength to the entire fabric, afford points of connexion to the numerous muscles, and bestow individual character upon the body. In the limbs they are hollow cylinders, admirably calculated by their conformation and structure to resist violence and support weight. In the trunk and head, they are flattened and arched, to protect cavities and provide an extensive surface for attachment. In some situations they present projections of variable length, which serve as levers; and in others are grooved into smooth surfaces, which act as *trochleæ* or pulleys for the passage of tendons. Moreover, besides supplying strength and solidity, they are equally adapted, by their numerous divisions and mutual apposition, to fulfil every movement which may tend to the preservation of the creature, or be conducive to his welfare.

According to the latest analysis by Berzelius, bone is composed of about one-third of animal substance, which is almost completely reducible to gelatine by boiling, and of earthy matters; in the following proportions:

Cartilage	32·17 parts.
Blood-vessels	1·13
Phosphate of lime	51·04
Carbonate of lime	11·30
Fluate of lime	2·
Phosphate of magnesia	1·16
Soda, chloride of sodium	1·20
	<hr/>
	100·00

Bones are divisible into four classes: *Long, short, flat, and irregular.*

The *long* bones are found principally in the limbs, and they consist of a shaft and two extremities. The shaft is cylindrical or prismoid in form, dense and hard in texture, and hollowed in the interior into a medullary canal. The extremities are broad and expanded, to articulate with adjoining bones; and cellular or cancellous in their internal structure. Upon the exterior of the bone are

processes and rough surfaces for the attachment of muscles, and foramina for the transmission of vessels and nerves, and the attachment of ligaments. The character of long bones is, therefore, their general type of structure and their divisibility into a central portion and extremities, and not so much their length; for there are some long bones—as the second phalanges of the toes—which are less than a quarter of an inch in length, and are almost equal, and in some instances, exceed in breadth their longitudinal axis. The long bones are, the clavicle, humerus, radius and ulna, femur, tibia, and fibula, metacarpal bones, metatarsal, phalanges and ribs.

*Short bones** are such as have no predominance of length or breadth, but are irregularly cuboid in form: they are spongy in internal texture, and invested by a thin crust of condensed osseous tissue. The short bones are, the vertebræ, coccyx, carpal and tarsal bones, patellæ, and sesamoid bones.

Flat bones are composed of two layers of dense bone with an intermediate cellular structure, and are divisible into surfaces, borders, angles, and processes. They are adapted to enclose cavities; have processes upon their surface for the attachment of muscles; and are perforated by foramina, for the passage of nutrient vessels to their cells, and for the transmission of vessels and nerves. They articulate with long bones by means of smooth surfaces plated with cartilage, and with each other either by cartilaginous substance, as at the symphysis pubis; or by suture, as in the bones of the skull. The two condensed layers of the bones of the skull are named tables; and the intermediate cellular structure diplœe. The flat bones are the occipital, parietal, frontal, nasal, lachrymal, vomer, sternum, scapulæ, and ossa innominata.

Irregular bones are those which are not distinctly referrible to either of the above heads; but present a mixed character, being partly short and partly flat in their conformation. The bones of this class are, the temporal, sphenoid, ethmoid, superior maxillary, inferior maxillary, palate, inferior turbinated bones, os hyoides, and sacrum.

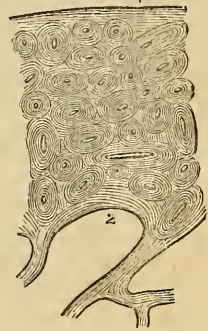Structure.—In structure, bone is composed of lamellæ, which are concentric in long, and parallel in flat bones. Between the lamellæ are situated numerous small longitudinal canals and minute oval corpuscles. The longitudinal canals (canals of Havers) contain medullary substance and vessels, and communicate with each other, and with the medullary canal or cells. Each longitudinal canal is surrounded by a series of concentric lamellæ, and between these lamellæ, as well as between the lamellæ which constitute the great medullary canal of the bone, the oval corpuscles are situated. In the extremities of long, in short, and in flat bones, the cells represent the Haversian canals, and are each surrounded by concentric lamellæ; indeed, the medullary canal of long bones may be considered as a single Haversian canal exceedingly dilated. The oval

* Wilson's classes of short and irregular bones are usually included in the title *ossa crassa* or thick bones.—G.

corpuscules* are minute cells, from which are given off a number of radiating and branching tubuli,† which anastomose with the corresponding tubuli of neighbouring cells. The cells and tubuli are filled with calcareous substance: hence they have been named calcigerous cells and tubuli.

Deutsch, in his excellent researches‡ on the minute structure of bone, has described certain radiating lines which traverse the thickness of the concentric lamellæ. They are thus referred to by Müller:§ “It is very remarkable that the thickness of the lamellæ is traversed by numerous lines which are separated by very small intervals, and which correspond in length to the thickness of the lamellæ, namely, $\frac{1}{300}$ th of a line. Deutsch supposes these lines to be tubes in which the calcareous matter of the bones is deposited(!); if one lamella be separated from another the ends of the lines are seen, he says, of a triangular form. The existence of these fine tubes(!) was hitherto quite unknown; but it is not probable that they serve for the reception of the calcareous matter, for the first appearance of ossification is in the form of a microscopic network!”¶ Having been engaged during the past summer (1841), and being still occupied with the investigation of the minute structure of bone, I have had the good fortune to discover the true nature of the lines thus alluded to by Deutsch and Müller. I have found that the corpuscules of Purkinje are arranged very differently in different kinds of bones; that in flat bones, and in the thin lamella of cellular bones, they exist in great numbers, are of considerable size, and are disposed with no regularity. Their tubuli are short, tapering, and tortuous, and proceed irregularly from every part of the surface of the corpuscules. In the long bones, the corpuscules are apparently smaller than the preceding, they are oval and flattened, and lie between the concentric lamellæ. Their tubuli are long and only slightly undulating, and diminish very gra-

Fig. 1.¶



* Discovered by Purkinje. They are about $\frac{1}{60}$ th of a line through their long diameter.

† Discovered by Müller. They are very distinct. Their larger trunks are about $\frac{1}{300}$ th of a line in diameter.

‡ De penitiori ossium structurâ observationes. Dissert. inaug. Vratisl.

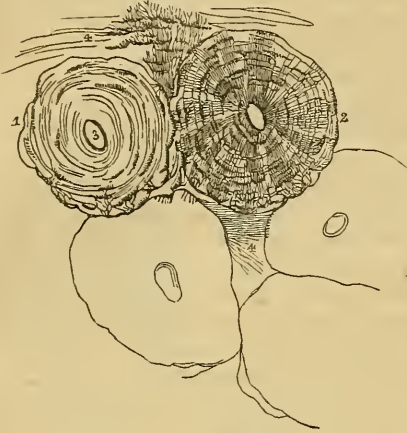
§ Physiology, Translation, p. 378.

¶ Transverse section of the compact tissue of a long bone: showing, 1. The periosteal layer. 2. The medullary layer, and the intermediate Haversian systems of lamellæ, each perforated by an H. canal.—Magnified about 15 diameters.

¶ In reference to this question, Dr. Bayly, the translator of Müller, observes, “Miescher does not confirm Deutsch’s statement as to the still more minute tubes traversing the concentric lamellæ, although he perceived the radiated appearance around the larger canals, which was produced by dots or short lines, which do not occupy the whole thickness of each lamella. Some of the lines appear to traverse more than one lamella, though the majority, as Miescher describes, are very short. They appear more like the separations between the granules of cartilage that form the lamellæ than distinct tubes.” Dr. Bayly has given the figure of a transverse section of an Haversian canal, in which Deutsch and Miescher’s views are clearly illustrated.

dually towards their termination, where they communicate with the tubuli of other corpuscules or with the corpuscules themselves. Among the concentric lamellæ of the Haversian canals, the tubuli

Fig. 2.*



are given off from the surfaces, lying in contact with the lamellæ, and they proceed straight through the lamellæ in two directions, inwards towards the area of the Haversian canal, or outwards towards the outermost lamellæ. If in their course the tubuli meet with another corpuscule, they terminate in it or communicate with its branches; but the direct course of the tubuli towards the centre is never interfered with. So evident is the tendency of all the tubuli to attain the centre, that in several corpuscules situated between the outer-

most lamellæ, I have observed the tubuli from the external surface to curve around the extremities of the corpuscule, in order to proceed with those given off from the internal surface, to their central destination. From their general appearance in relation to the lamellæ, these tubuli seem to me to deserve the title of *converging tubuli*; they all proceed towards the central canal, and those which reach that destination terminate upon its internal surface. The trunks of the tubuli not unfrequently give off one or two branches. As regards their form, the tubuli are undoubtedly cylindrical, and they probably contain calcareous substance, as do the calcigerous tubuli described by Müller.

The lines remarked by Deutsch are, therefore, according to my observations, cylindrical tubuli, traversing the concentric lamellæ of bone, communicating with the corpuscules, and with the cavity of the Haversian canal, and identical with the calcigerous tubuli of Müller.

In the fresh state bones are invested by a dense fibrous membrane, the *periosteum*, covering every part of their surface with the exception of the articular extremities, which are coated by a

* Minute structure of bone, drawn with the microscope from nature, by Bagg. Magnified 300 diameters. 1. One of the Haversian canals surrounded by its concentric lamellæ. The corpuscules are seen between the lamellæ; but the converging tubuli are omitted. 2. An Haversian canal with its concentric lamellæ, Purkinjean corpuscules, and converging tubuli. 3. The area of one of the canals. 4, 4. Direction of the lamellæ of the great medullary canal. Between the lamellæ at the upper part of the figure, several very long corpuscules with their tubuli are seen. In the lower part of the figure, the outlines of three other canals are given, in order to show their form and mode of arrangement in the entire bone.

thin layer of cartilage. The periosteum of the bones of the skull is termed *pericranium*; and the analogous membrane of external cartilages, *perichondrium*. Lining the interior of the medullary canal of long bones, the Haversian canals, the cells of the cancelli, and the cells of short, flat, and irregular bones, is the medullary membrane, which acts as an internal periosteum. It is through the medium of the vessels supplying these membranes that the changes required by nutrition occur in bones, and the secretion of medulla into the interior is effected. The medullary canal of long bones, and the cells of other bones, are filled with a yellowish oily substance—the *medulla*, which is contained in a loose cellular tissue formed by the medullary membrane.

Development of Bone.—The earliest trace of skeleton in the human embryo is observed in the presence of semi-opaque lines, which are seen through the transparent embryonic mass. This trace is composed of a consistent granular jelly, and constitutes the *gelatinous* state of osteo-genesis. In the second or *cartilaginous* state, the semi-opaque jelly becomes dense, transparent, and homogeneous, the change taking place from the surface towards the centre, and constituting *cartilagification*. In the third stage, the cartilage is traversed by vessels carrying red blood, which proceed from the fibrous investment and ramify in its interior. The cartilage immediately surrounding these vessels, becomes opaque and of a yellowish red colour. In the fourth stage,* the earthy constituents are attracted from the blood by the opaque cartilage, which becomes altered in character, and shoots into the transparent cartilage in the form of reddish gray fibres, which communicate with each other at acute angles and constitute an areolar osseous tissue. This is the state of *ossification*. The succeeding changes are those of condensation and the formation of cells, the Haversian and medullary canals.

Cartilagification is complete in the human embryo at about the sixth week; and the first point of ossification is observed in the clavicle at about the seventh week. Ossification commences at the centre, and thence proceeds towards the surface; in flat bones the osseous tissue radiates between two membranes from a central point towards the periphery, in short bones from a centre towards the circumference, and in long bones from a central portion, *diaphysis*, towards a secondary centre, *epiphysis*, situated at each extremity. Large processes, as the trochanters, are provided with a distinct centre, which is named *apophysis*.

The *growth* of the bone in length takes place at the extremity of the diaphysis, and in bulk by fresh deposition on the surface; while the medullary canal is formed and increased by absorption from within.

The *period* of *ossification*† is different in different bones; the order of succession may be thus arranged:

* The spot at which this stage commences is called the *punctum ossificationis*.—G.

† Burdach, Physiologic.

From the sixth to the eighth week, ossification commences first in the clavicle, then in the lower jaw, upper jaw, and femur.

From the eighth to the tenth week in the frontal, occipital, humerus, radius and ulna, tibia and fibula, scapulæ, ribs.

From the tenth to the twelfth week, in the temporal, sphenoid, malar, parietal, palate, nasal, vertebræ, metacarpus, metatarsus, last phalanges of the hands, and feet.

From the third to the fourth month, in the vomer, first and second phalanges, ossa innominata.

From the fourth to the fifth month, in the ethmoid, lachrymal and spongy bones.

From the fifth to the sixth month, in the sternum, carpus, and tarsus.

From the sixth to the tenth month in the os hyoides, coccyx, and cuboid bone.

At one year, in the coracoid process of the scapula, os magnum, os unciforme, and internal cuneiform bone.

At three years, in the patella, and carpal cuneiform bone.

At four years, in the external and middle cuneiform bone.

At five years, in the tarsal scaphoid bone, trapezium, and semi-lunare.

At eight years, in the carpal scaphoid.

At nine, in the trapezoid, and at the twelfth year, in the pisiform bone.

The ossicula auditûs are the only bones completely ossified at birth.

The entire osseous framework of the body constitutes the skeleton, which in the adult man is composed of two hundred and forty-six distinct bones. They may be thus arranged :

Cranium	8
Ossicula auditûs	6*
Face	14
Teeth	32
Vertebral column	24
Os hyoides, sternum, and ribs	26
Upper extremities	64
Pelvis	4
Lower extremities	60
Sesamoid bones	8

246

The *skeleton* is divisible into 1st. The vertebral column or central axis. 2. The cranium and face or superior development of the central axis. 3. The hyoid arch. 4. The thoracic arch and upper extremities. 5. The pelvic arch and lower extremities.

* Wilson describes three bones to the ear, viz: *malleus*, *incus* and *stapes*, making the *orbiculare* of other anatomists a part of the *stapes*. He also counts thirty-two teeth in this enumeration, which is not common.—G.

VERTEBRAL COLUMN.

The *Vertebral column* is the first and only rudiment of internal skeleton in the lower Vertebrata, and constitutes the type of that great division of the animal kingdom. It is also the first developed portion of the skeleton in man, and the centre around which all the other parts are produced. In its earliest formation it is a simple cartilaginous cylinder, surrounding and protecting the primitive trace of the nervous system; but, as it advances in growth and organization, it becomes divided into distinct pieces, which constitute *vertebræ*.

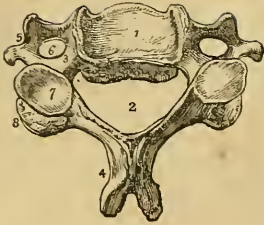
The *vertebræ* are divided into true and false. The true *vertebræ* are twenty-four in number, and are classified according to the three regions of the trunk which they occupy, into the cervical, dorsal, and lumbar. The false *vertebræ* consist of nine pieces united into two bones,—the sacrum and coccyx. The arrangement of the *vertebræ* may be better comprehended by means of the accompanying table:

True <i>vertebræ</i> 24	{	7 Cervical,
		12 Dorsal,
		5 Lumbar.
False <i>vertebræ</i> 9	{	5 Sacrum,
		4 Coccyx.

Characters of a Vertebra.—A vertebra consists of a body, two laminae, a spinous process, two transverse processes, and four articular processes. The *body* is the solid part of the vertebra; and by its articulation with adjoining *vertebræ*, gives strength and support to the trunk. It is flattened above and below, convex in front, and slightly concave behind. Its anterior surface is constricted around the middle, and pierced by a number of small openings which give passage to nutritious vessels. Upon its posterior surface is a singular irregular opening, or several, for the exit of the *vena basis vertebræ* or vertebral sinuses.

The *laminae* commence upon the sides of the posterior part of the body of the vertebra by two *pedicles*; they then expand, and arching backwards, enclose a foramen which serves for the protection of the spinal cord. The upper and lower borders of the laminae are rough for the attachment of the ligamenta subflava. The concavities above and below the pedicles are the *intervertebral notches*. The *spinous process* stands backwards from the angle of union of the laminae of the vertebra. It is the succession of these projecting processes along the middle line of the back, that has given rise to the common designation of the vertebral column—the spine. The use of the spinous process is for the attachment of muscles. The *transverse processes* project one at each side from the laminae of the vertebra; they are intended for the attachment of muscles. The *articular processes*, four in number, stand upwards and downwards from the laminae of the *vertebræ* to articulate with the vertebra above and below.

Fig. 3.*



Cervical Vertebrae.—In a cervical vertebra the body is smaller than in the other regions; it is thicker before than behind, broad from side to side, concave on the upper surface and convex below; so that when articulated, the vertebræ lock the one into the other. The *laminae* are broad and long, and the inclosed foramen large and triangular. The *superior* and *inferior intervertebral notches* are nearly equal in depth. The *spinous process* is short and bifid at the extremity, increas-

ing in length from the fourth to the seventh. The *transverse processes* are also short and bifid, and grooved along the upper surface for the cervical nerves. Through the base of the transverse process is the vertebral foramen† for the passage of the vertebral artery and vein, and vertebral plexus of nerves.‡ The transverse processes in this region are formed by two small developements, which proceed, the one from the side of the body, the other from the pedicle of the vertebra, and unite by their extremities so as to enclose the circular area of the vertebral foramen. The anterior of these developements is the rudiment of a cervical rib; and the posterior, the true transverse process analogous to the transverse processes of the vertebræ in the dorsal and lumbar regions. The extremities of these developements constitute the two tubercles of the transverse process.

The *articular processes* are oblique; the superior looking upwards and backwards; and the inferior, downwards and forwards.

There are three peculiar vertebræ in the cervical region:—The first or atlas: the second or axis;§ and the seventh or vertebra prominens.

The *Atlas* (named from supporting the head) is a simple ring of bone without body, and composed of arches and processes. The *anterior arch* has a tubercle upon its anterior surface, for the attachment of the longus colli muscle; and upon its posterior part is a smooth surface, for the articulation of the odontoid process of the axis.

The *posterior arch* is longer and more slender than the anterior, and flattened from above downwards; at its middle is a rudimentary spinous process; and upon its upper surface, near the articular processes, a shallow groove|| at each side, which represents a superior intervertebral notch, and supports the vertebral artery, previously

* A central cervical vertebra, seen upon its upper surface. 1. The body, concave in the middle, and rising on each side into a sharp ridge. 2. The lamina. 3. The pedicle rendered concave by the superior intervertebral notch. 4. The bifid spinous process. 5. The bifid transverse process. 6. The foramen for the vertebral artery. 7. The superior articular process. 8. The inferior articular process.

† There is an objection to this name, as it is liable to be confounded with the foramen for the spinal medulla.—G.

‡ Sometimes, as in a vertebra now before me, a small additional opening exists by the side of the vertebral foramen, in which case it is traversed by a second vein.

§ Usually called *vertebra dentata*.—G.

|| This groove is sometimes converted into a foramen.

to its passage through the dura mater, and the first cervical nerve. The intervertebral notches are peculiar from being situated behind the articular processes instead of before them, as in the other vertebræ. The *transverse processes* are remarkably large and long, and pierced by the foramen for the vertebral artery. The *articular processes* are situated upon the most bulky and strongest parts of the atlas. The superior are oval and concave, and look inwards, so as to form a kind of cup for the condyles of the occipital bone, and are adapted to the nodding movements of the head; the inferior are circular, and nearly horizontal, to permit of the rotary movements. Upon the inner face of the lateral mass which supports the articular processes, is a small tubercle at each side, into which the extremities of the transverse ligament are attached, a ligament which divides the ring of the atlas into two unequal segments: the smaller for receiving the odontoid process of the axis, and the latter to give passage to the spinal cord and its membranes.

The *Axis* is named from having a process upon which the head turns as on a pivot. The *body* is of a large size, and supports a strong process,—the odontoid,—which rises perpendicularly from its upper surface. The *odontoid process* (processus dentatus) presents two articulating surfaces; one on its anterior face, to articulate with the anterior arch of the atlas; the other on its posterior face, for the transverse ligament. Upon each side of its apex is a rough depression, for the attachment of the alar, or moderator ligaments. The *laminae* are large and strong, and unite posteriorly to form a long and projecting *spinous process*. The *transverse processes* are quite rudimentary, not bifid, and project only so far as to enclose the vertebral foramen, which is directed obliquely outwards instead of perpendicularly as in the other vertebræ. The *superior articulating processes* are situated upon the body of the vertebra on each side of the odontoid process.

Fig. 4.*

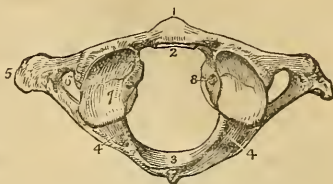
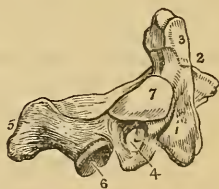


Fig. 5.†



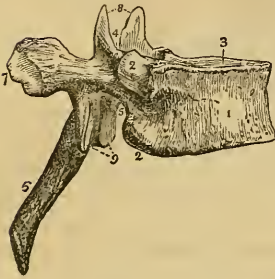
* The upper surface of the atlas. 1. The anterior tubercle projecting from the anterior arch. 2. The articular surface of the odontoid process upon the posterior surface of the anterior arch. 3. The posterior arch, with its rudimentary spinous process. 4. The intervertebral notch. 5. The transverse process. 6. The vertebral foramen. 7. Superior articular surface. 8. The tubercle for the attachment of the transverse ligament.

† A lateral view of the axis. 1. The body. 2. The odontoid process. 3. The smooth facet on the anterior surface of the odontoid process which articulates with the anterior arch of the atlas. 4. The transverse process pierced obliquely by the vertebral foramen. 5. The spinous process. 6. The inferior articular process. 7. The superior articular surface.

They are circular and nearly horizontal, having a slight inclination outwards. The *inferior articulating processes* look downwards and forwards, as do the same processes in the other cervical vertebræ. The lower surface of the body is convex, and is received into the concavity upon the upper surface of the third vertebra.

The *Vertebra prominens*, or seventh cervical, approaches in character to the upper dorsal vertebra.

Fig. 6.*



It has received its designation from having a very long spinous process, which is single and terminated by a tubercle, and forms a considerable projection on the back part of the neck; to the extremity of this process the ligamentum nuchæ is attached. The transverse processes have each a small foramen for the transmission of the vertebral vein.

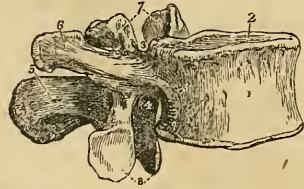
Dorsal Vertebræ.—The *body* of a dorsal vertebra is longer from before backwards than from side to side, particularly in the middle of the dorsal region; it is thicker behind than before, and marked on each side by two half-articulating surfaces for the heads of two ribs. The *pedicles* are strong and the *laminæ* broad; the *foramen* round, and the inferior *intervertebral notch* of large size. The *spinous process* is long, almost perpendicular in direction, and terminated by a tubercle. The *transverse processes* are large and strong, and directed obliquely backwards. Upon their points is a small depression for the articulation of the tubercle of a rib. The *articular processes* are vertical, the superior facing directly backwards, and the inferior directly forwards.

The peculiar vertebræ in the dorsal region are the first, ninth, tenth, eleventh, and twelfth. The *first* dorsal vertebra approaches very closely in character to the last cervical. The body is broad from side to side, and concave above. The superior articular processes are oblique, and the spinous process horizontal. It has an entire articular surface for the first rib, and a half surface for the second. The *ninth* dorsal vertebra has only one half articular surface at each side. The *tenth* has a single entire articular surface at each side. The *eleventh* and *twelfth* have each a single entire articular surface at each side; they approach in character to the lumbar vertebræ; their transverse processes are very short, and have no articulation with the corresponding ribs. The transverse processes of the twelfth dorsal vertebra are quite rudimentary.

* A lateral view of a dorsal vertebra. 1. The body. 2, 2. Articular facets for the heads of ribs. 3. The surface for joining the next vertebra above. 4. The superior intervertebral notch. 5. The inferior intervertebral notch. 6. The spinous process. 7. The extremity of the transverse process marked by an articular surface for the tubercle of a rib. 8. The two superior articular processes looking backwards. 9. The two inferior articular processes looking forwards.

Lumbar Vertebrae.—These are the largest pieces of the vertebral column. The *body* is broad and large, and thicker before than behind. The *pedicles* very strong; the *laminae* thick and narrow; the *inferior intervertebral notches* very large, and the *foramen* large and oval. The *spinous process* is thick and broad. The *transverse processes* slender, pointed, and directed only slightly backwards. The superior *articular processes* are concave, and look backwards and inwards; the inferior, convex, and look forwards and outwards. The last lumbar vertebra differs from the rest in having the body very much bevelled posteriorly, so as to be broad in front and narrow behind.

Fig. 7.*



General Considerations.—Viewed as a whole, the vertebral column represents two pyramids applied base to base, the superior being formed by all the vertebrae from the second cervical to the last lumbar, and the inferior by the sacrum and coccyx. Examined more attentively, it will be seen to be composed of four irregular pyramids, applied to each other by their smaller extremities and by their bases. The smaller extremity of the uppermost pyramid is formed by the axis, or second cervical vertebra: and its base, by the first dorsal. The second pyramid is inverted; having its base at the first dorsal, and the smaller end at the fourth. The third pyramid commences at the fourth dorsal, and gradually enlarges to the fifth lumbar. The fourth pyramid is formed by the sacrum and coccyx.

The *bodies* of the vertebrae are broad in the cervical region, narrowed almost to an angle in the middle of the dorsal, and again broad in the lumbar region. The *arches* are broad and imbricated in the cervical and dorsal regions, the inferior border of each overlapping the superior of the next. In the lumbar region they are narrow, and leave a considerable interval between them.

The *spinous processes* are horizontal in the cervical, and become gradually oblique in the upper part of the dorsal region. In the middle of the dorsal region they are nearly vertical and imbricated, and towards its lower part assume the direction of the lumbar spines, which are quite horizontal. The *transverse processes* developed in their most rudimentary form in the axis, gradually increase in length to the first dorsal vertebra. In the dorsal region they project obliquely backwards, and diminish suddenly in length in the eleventh and twelfth vertebrae, where they are very small. In the lumbar region they increase to the middle transverse process, and again subside in length to the last. The *intervertebral foramina* formed by the juxtaposition of the notches, are smallest in the cer-

* A lateral view of a lumbar vertebra. 1. The body. 2. The surface for the vertebra above. 3. The superior intervertebral notch. 4. The inferior intervertebral notch. 5. The spinous process. 6. The transverse process. 7. The superior articular processes. 8. The inferior articular processes.

vical region, and gradually increase to the last lumbar. On either side of the spinous processes, and extending the whole length of the column, is the *vertebral groove*, which is shallow in the cervical, and deeper in the dorsal and lumbar region. It lodges the principal muscles of the back.

Viewed from the side, the vertebral column presents several curves, the principal of which is situated in the dorsal region, the concavity looking forwards. In the cervical and lumbar regions the column is convex in front; and in the pelvis an anterior concave curve is formed by the sacrum and coccyx. Besides the antero-posterior curves a slight lateral curve exists in the dorsal region, having its convexity towards the right side.

Development.—The vertebræ, with the exception of the atlas, axis, and vertebra prominens, are developed by three points of ossification, one for each lamella, and one for the body. To these are afterwards added six additional centres; one for each transverse process, two (sometimes united into one) for the spinous process, and one for the upper and under surface of the body. The atlas has five centres; one (sometimes two) for the anterior arch, one for each lateral mass, and two for the posterior arch. The axis has five original centres; one (sometimes two) for the body, two for the odontoid process, and one for each lamella. The vertebra prominens has likewise five; one for the body, one for each anterior segment of the transverse process, and one for each lamella.

The ossification of the arches of the vertebræ commences from above, and proceeds gradually downwards; hence arrest of development gives rise to spina bifida, generally in the loins. Ossification of the bodies, on the contrary, commences from the centre, and proceeds from that point towards the extremities of the column; hence imperfection of the bodies occurs either in the upper or lower vertebræ.

Attachment of muscles.—To the *Atlas* are attached ten pairs of muscles: the longus colli, rectus anticus minor, rectus lateralis, rectus posticus minor, obliquus superior and inferior, splenius colli, levator anguli scapulæ, first interspinous, and first intertransverse.

To the *axis* are attached eleven pairs, viz: the longus colli, intertransversales, obliquus inferior, rectus posticus major, interspinales, semi-spinalis colli, multifidus spinæ, levator anguli scapulæ, splenius colli, transversalis colli, and scalenus posticus.

To the remaining *vertebræ* generally, thirty-two pairs: viz. *posteriorly*, the trapezius, latissimus dorsi, levator anguli scapulæ, rhomboideus minor and major, serratus posticus superior and inferior, splenius, sacro-lumbalis, longissimus dorsi, spinalis dorsi, cervicalis ascendens, transversalis colli, trachelo-mastoideus, complexus, semi-spinalis dorsi and colli, multifidus spinæ, interspinales, supraspinales, intertransversales, levatores costarum,—*anteriorly*, the rectus anticus major, longus colli, scalenus anticus and posticus, psoas magnus, psoas parvus, quadratus lumborum, diaphragm, obliquus internus and transversalis.

THE SACRUM is a triangular bone, situated at the lower extremity of the vertebral column, and formed by the consolidation of five false vertebræ. It is divisible into an anterior and posterior surface, two lateral and a superior border, and an inferior extremity.

The *anterior surface* is concave, and marked by four transverse lines, which indicate its original constitution of five separate pieces. At the extremities of these lines, on each side, are the four anterior sacral foramina, which diminish in size from above downwards, and transmit the anterior sacral nerves. The projection of the superior piece is called the *promontory* of the sacrum.

The *posterior surface* is convex. Upon the middle line is a rough crest formed by the rudiments of four spinous processes, the fifth remaining undeveloped, and exposing the lower termination of the sacral canal. The rudiments of the fifth are situated one on each side of the termination of the sacral canal; they are named the *sacral cornua*, and articulate with the cornua of the coccyx. Parallel with the middle line, on each side, are the openings of the four posterior sacral foramina; they are smaller than the anterior, and transmit the posterior sacral nerves. Immediately external to each of the posterior sacral foramina is a tubercle, representing a rudimentary transverse process. The *first transverse tubercle* corresponds with the angle of the superior border of the bone; the *second* is small, and enters into the formation of the sacro-iliac articulation; the *third* is large, and gives attachment to the oblique sacro-iliac ligament; the *fourth* and *fifth* are smaller and serve for the attachment of the sacro-ischiatic ligaments. The *lateral border* presents superiorly a broad and ear-shaped surface to articulate with the ilium; and inferiorly a sharp edge, to which the greater and lesser sacro-ischiatic ligaments are attached. On the *superior border*, in the middle line, is an oval articular surface, which corresponds with the under part of the body of the last lumbar vertebra; and on each side, a broad triangular surface which supports the lumbo-sacral nerve and psoas magnus muscle. Immediately behind the vertebral articular surface is the triangular entrance of the sacral canal; and on each side of this opening an articular process, which looks backwards and inwards, like the superior ar-

Fig. 8.

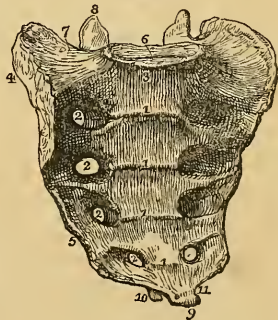


Fig. 8. The sacrum seen upon its anterior surface. 1, 1. The transverse lines marking the original constitution of the bone of four pieces. 2, 2. The anterior sacral foramina. 3. The promontory of the sacrum. 4. The ear-shaped surface which articulates with the ilium. 5. The sharp edge to which the sacro-ischiatic ligaments are attached. 6. The vertebral articular surface. 7. The broad triangular surface which supports the psoas muscle and lumbo-sacral nerve. 8. The articular process of the right side. 9. The inferior extremity, or apex of the sacrum. 10. One of the sacral cornua. 11. The notch which is converted into a foramen by the coccyx.

ticular processes of the lumbar vertebræ. In front of each articular process is an intervertebral notch. The *inferior extremity* presents a small oval surface which articulates with the coccyx; and on each side a notch, which with a corresponding notch in the upper border of the coccyx forms the foramen for the transmission of the fifth sacral nerve.

Development.—By *twenty-one* points of ossification; five for each of the three first pieces, viz.—one for the body, one for each lateral portion, and one for each lamina; and three for each of the two last, viz.—one for the body, and one for each lateral portion.

Articulations.—With *four* bones; the last lumbar vertebra, ossa innominata and coccyx.

Attachment of Muscles.—To *seven* pairs; *in front* the pyriformis, *on the side* the coccygeus, and *behind* the gluteus maximus, latissimus dorsi, longissimus dorsi, sacro-lumbalis, and multifidus spinæ.

The Coccyx (κόκκυξ cuckoo, from resembling a cuckoo's beak) is composed of four small pieces, which form the caudal termination of the vertebral column. The superior piece is broad, and expands laterally into two transverse processes: it is surmounted by an oval articular surface and two cornua; the former to articulate with the apex of the sacrum, and the latter with the sacral cornua. The three latter pieces diminish in size from above downwards, and are frequently consolidated into a single bone.

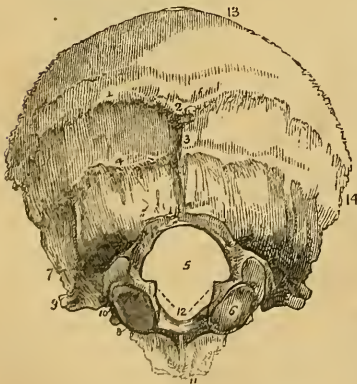Development.—By *four* centres, one for each piece.

Articulations.—With the sacrum.

Attachment of Muscles.—To *three* pairs, and one single muscle: gluteus maximus, coccygeus, posterior fibres of the levator ani and sphincter ani.

OF THE SKULL.

Fig. 9.



The skull, or superior expansion of the vertebral column, is divisible into two parts,—the cranium and the face; the former being adapted by its form, structure, and strength to contain and protect the brain, and the latter the chief organs of sense.

The CRANIUM is composed of eight separate bones; viz. the occipital, two parietal, frontal, two temporal, sphenoidal, ethmoidal.

OCCIPITAL BONE.—This bone is situated at the posterior part and base of the cranium. It is trapezoid in form, and divisible into two surfaces, four borders, and four angles.

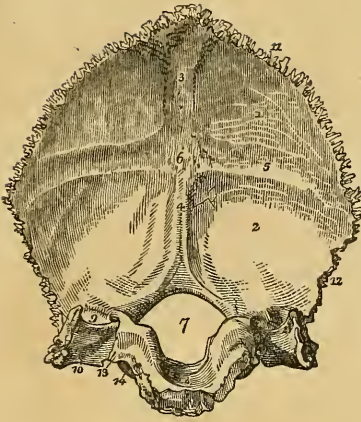
Fig. 9. The external surface of the occipital bone. 1. The superior semicircular ridge. 2. The occipital protuberance. 3. The spine. 4. The inferior semicircular ridge. 5.

External Surface.—Crossing the middle of the bone transversely, from one lateral angle to the other, is a prominent ridge, the *superior semicircular ridge*. In the middle of the ridge is a projection, called the *occipital protuberance*; and descending from it a small vertical ridge, the *spine*. Above and below the superior semicircular ridge the surface is rough, for the attachment of muscles. About three-quarters of an inch below this line is another transverse ridge, the *inferior semicircular ridge*, and beneath the latter, the *foramen magnum*. On each side of the foramen magnum, nearer to its anterior than its posterior segment, and encroaching somewhat upon the opening, is an oblong, articular surface—the *condyle*, for articulation with the atlas. The condyles approach towards each other anteriorly, and their articular surfaces look downwards and outwards. Directly behind each condyle is an irregular fossa, and a small opening, the *posterior condyloid foramen* for the transmission of a vein to the lateral sinus. In front of the condyle is the *anterior condyloid foramen*, for the hypoglossal nerve; and on each side of each condyle a projecting ridge, the *transverse process*, excavated in front by a notch which forms part of the jugular foramen. In front of the foramen magnum is a thick square mass, the *basilar process*, and in the centre of the basilar process a small tubercle for the attachment of the superior and middle constrictor muscles of the pharynx.

Internal Surface.—Upon the internal surface is a crucial ridge, which divides the bone into four fossæ; the two superior or cerebral fossæ lodging the posterior lobes of the cerebrum; and the two inferior or cerebellar, the lateral lobes of the cerebellum. The superior arm of the crucial ridge is grooved for the superior longitudinal sinus, and gives attachment to the falx cerebri; the inferior arm is sharp and prominent, for the attachment of the falx cerebelli, and slightly grooved, for the two occipital sinuses. The transverse ridge gives attachment to the tentorium cerebelli, and is deeply grooved, for the lateral sinuses. At the point of meeting of the four arms, is a projection, the *internal occipital protuberance*, which corresponds with the similar process situated upon the external surface of the bone. The convergence of the four grooves forms a slightly depressed fossa, upon which rests the torcular Herophili. In the centre of the basilar portion of the bone is the foramen magnum, oblong in form and larger behind than before, transmitting the spinal cord, spinal accessory nerves, and vertebral arteries. Upon the lateral margins of the foramen magnum are two rough eminences, which give attachment to the odontoid ligaments, and immediately above these the openings of the anterior condyloid foramina. In

The foramen magnum. 6. The condyle of the right side. 7. The posterior condyloid fossa, in which the posterior condyloid foramen is found. 8. The anterior condyloid foramen, concealed by the margin of the condyle. 9. The transverse process; this process upon the internal surface of the bone, forms the jugular eminence. 10. The notch in front of the jugular eminence which forms part of the jugular foramen. 11. The basilar process. 12, 12. The rough projections into which the odontoid ligaments are inserted. 13 and 14. Serrated borders of the bone.

Fig. 10.



front of the foramen magnum is the basilar process, grooved on its surface, for supporting the medulla oblongata; and on each side of the foramen a groove, for the termination of the lateral sinus; a smooth surface which forms part of the jugular fossa; and a projecting process which divides the two and is called the *jugular eminence*. Into the jugular fossa will be seen opening the posterior condyloid foramen.

The *superior borders* are very much serrated and assist in forming the lambdoidal suture; the *inferior* are rough, but not serrated, and articulate with the mastoid portion of the temporal bone by means of the addita-

mentum suturæ lambdoidalis. The jugular eminence and the side of the basilar process articulate with the petrous portion of the temporal bone, and the intermediate space, which is irregularly notched, forms the posterior boundary of the jugular foramen, or foramen lacerum posterius.

The *angles* of the occipital bone, are the superior, inferior, and two lateral. The *superior angle* is received into the interval formed by the union of the posterior and superior angles of the parietal bones, and corresponds with that portion of the fœtal head which is called the *posterior fontanelle*. The *inferior angle* is the articular extremity of the basilar process. The *lateral angles* at each side project into that interval formed by the articulation of the posterior and inferior angle of the parietal with the mastoid portion of the temporal bone.

Development.—By *four* centres; one (sometimes two) for the posterior portion, one for each condyle, and one for the basilar process.

Articulations.—With *six* bones; two parietal, two temporal, sphenoid, and atlas.

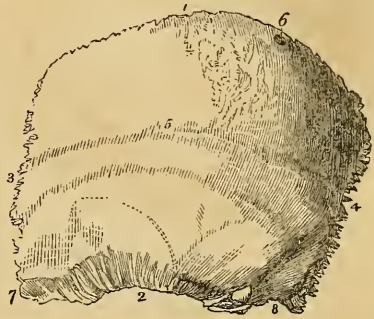
Attachment of Muscles.—To *thirteen* pairs; to the rough surface

Fig. 10. The internal surface of the occipital bone. 1. The left cerebral fossa. 2. The left cerebellar fossa. 3. The groove for the posterior part of the superior longitudinal sinus. 4. The spine for the falx cerebelli, and groove for the occipital sinus. 5. The groove for the left lateral sinus. 6. The internal occipital protuberance which lodges the torcular Herophili. 7. The foramen magnum. 8. The basilar process, grooved externally by the jugular eminence. 9. The termination of the groove for the lateral sinus, bounded externally by the jugular fossa; this fossa is completed by the petrous portion of the temporal bone. 10. The jugular fossa; this fossa is completed by the petrous portion of the temporal bone. 11. The superior border of the bone. 12. The inferior border. 13. The border which articulates with the petrous portion of the temporal bone. 14. The anterior condyloid foramen.

above the superior semicircular ridge, the occipito-frontalis; to the superior semicircular ridge, the trapezius and sterno-mastoid; to the rough space between the ridges, complexus and splenius capitis; to the space between the inferior semicircular ridge and the foramen magnum, the rectus posticus major and minor, and obliquus superior; to the transverse process, the rectus lateralis; and to the basilar process, the rectus anticus major and minor, and superior and middle constrictor muscles.

PARIETAL BONE.—The parietal bone is situated at the side and vertex of the skull; it is quadrilateral in form, and divisible into an external and internal surface, four borders and four angles. The superior border is straight, to articulate with its fellow of the opposite side. The inferior border is arched and thin, to articulate with the temporal bone. The anterior border is concave, and the posterior somewhat convex.

Fig. 11.



External Surface.—Crossing the bone in a longitudinal direction from the anterior to the posterior border, is an arched line, the *temporal ridge*, to which the temporal fascia is attached. In the middle of this line, and nearly in the centre of the bone, is the projection called the *parietal boss* or *eminence*, which marks the centre of ossification. Above the temporal ridge the surface is rough, and covered by the aponeurosis of the occipito-frontalis; below the ridge the bone is smooth for the attachment of the fleshy fibres of the temporal muscle. Near the superior border of the bone, and at about one-third from its posterior extremity, is the *parietal foramen*, which transmits a vein to the superior longitudinal sinus.

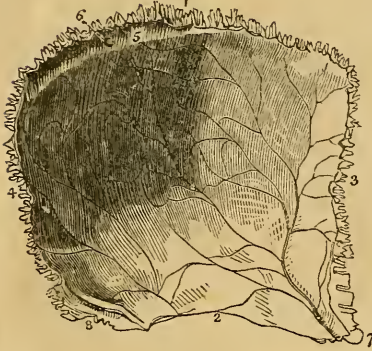Internal Surface.—The internal table is smooth, and marked over every part of its surface by numerous furrows, which correspond with the ramifications of the arteria meningeae magna. Along the upper border is part of a shallow groove, completed by the opposite parietal bone, which serves to contain the superior longitudinal sinus. Some slight pits are also observable near to this groove, which lodge the glandulae Pacchioni.

The *anterior inferior angle* is thin and lengthened, and articulates with the greater wing of the sphenoid bone. Upon its inner surface it is deeply channelled by a groove for the trunk of

Fig. 11. The external surface of the left parietal bone. 1. The superior or sagittal border. 2. The inferior or squamous border. 3. The anterior or coronal border. 4. The posterior or lambdoidal border. 5. The temporal ridge; the figure is situated immediately in front of the parietal eminence. 6. The parietal foramen, unusually large in the bone from which this figure was drawn. 7. The anterior inferior or elongated angle. 8. The posterior inferior or truncated angle.

the arteria meningea magna. This groove is frequently converted into a canal. The *posterior inferior angle* is thick, and presents a broad and shallow groove for the lateral sinus.

Fig. 12.



Development.—By a single centre.

Articulations. — With five bones; with the opposite parietal bone, the occipital, frontal, temporal, and sphenoid.

Attachment of Muscles.—To one only,—the temporal. The occipito-frontalis glides over its upper surface.

FRONTAL BONE.—The frontal bone bears some resemblance

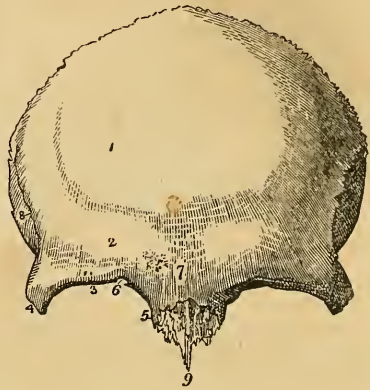
in form to the under valve of a scallop shell. It is situated at the anterior part of the cranium, forming the forehead, and assists in the construction of the roof of the orbits and nose. Hence it is divisible into a superior or frontal portion, and an inferior or orbito-nasal portion. Each of these portions presents for examination an external and internal surface, borders and processes.

External Surface.—At about the middle of each lateral half of the frontal portion is a projection, the *frontal boss* or *eminence*, which denotes the situation of the centre of ossification. Below these points are the *superciliary ridges*, large towards their inner termination, and becoming gradually smaller as they arch outwards; they support the eyebrows. Beneath the superciliary ridges are the sharp and prominent arches which form the upper margin of the orbits, the *supra-orbital ridges*. Externally the supra-orbital ridge terminates in the *external angular process*, and internally in the *internal angular process*; at the inner third of this ridge is a notch, sometimes converted into a foramen, the *supra-orbital notch*, which gives passage to the supra-orbital or frontal artery, veins, and nerve. Between the two superciliary ridges is a rough projection, the *nasal tuberosity*: the whole of this portion of the bone is somewhat prominent, and denotes the situation of the frontal sinuses. Extending upwards and backwards from the external angular process is a sharp ridge, the commencement of the *temporal ridge*, and beneath this a depressed surface that forms part of the *temporal fossa*.

Fig. 12. The internal surface of the left parietal bone. 1. The superior, or sagittal border. 2. The inferior, or squamous border. 3. The anterior, or coronal border. 4. The posterior, or lambdoidal border. 5. Part of the groove for the superior longitudinal sinus. 6. The internal termination of the parietal foramen. 7. The anterior inferior angle of the bone, on which is seen the groove for the trunk of the arteria meningea magna. 8. The posterior inferior angle, upon which is seen a portion of the groove for the lateral sinus.

The *orbito-nasal portion* of the bone consists of two thin processes, the *orbital plates*, which form the roof of the orbits, and of an intervening notch which lodges the ethmoid bone, and is called the *ethmoidal fissure*. The edges of the ethmoidal fissure are hollowed into cavities, which, by their union with the ethmoid bone, complete the ethmoidal cells; and, crossing these edges transversely, are two small grooves, sometimes canals, which open into the orbit by the anterior and posterior ethmoidal foramina. At the anterior termination of these edges, are the irregular openings which lead into the frontal sinuses; and between the two internal angular processes is a rough excavation which receives the nasal bones, and a projecting process, the *nasal spine*. Upon each orbital plate, immediately beneath the external angular process, is a shallow depression which lodges the lachrymal gland; and beneath the internal angular process a small pit, sometimes a tubercle, to which the cartilaginous pulley of the superior oblique muscle is attached.

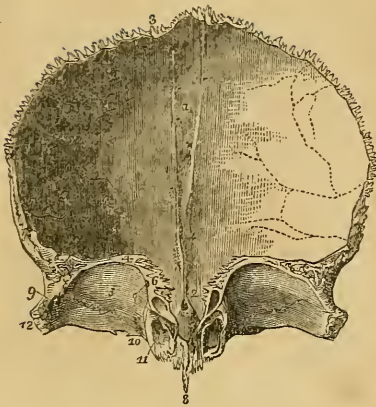
Fig. 13.



Internal Surface.—Along the middle line of this surface is a *grooved ridge*, the edges of the ridge giving attachment to the falx cerebri and the groove lodging the superior longitudinal sinus. At the commencement of the ridge is an opening, sometimes completed by the ethmoid bone, the *foramen cæcum*. This opening lodges a process of the dura mater, and occasionally gives passage to a small vein which communicates with the nasal veins. On each side of the vertical ridge are some slight depressions which lodge the glandulæ Pacchioni, and on the orbital plates a number of irregular pits called *digital fossæ*, which correspond with the convolutions of the anterior lobes of the cerebrum. The *superior border* is thick and strongly serrated, bevelled at the expense of the internal table in the middle, where it rests upon the junction of the two parietal, and at the expense of the external table, on each side, where it receives the lateral pressure of those bones. The *infe-*

Fig. 13. The external surface of the frontal bone. 1. The situation of the frontal eminence of the right side. 2. The superciliary ridge. 3. The supra-orbital ridge. 4. The external angular process. 5. The internal angular process. 6. The supra-orbital notch for the transmission of the supra-orbital nerve, and artery; in the figure it is almost converted into a foramen by a small spiculum of bone. 7. The nasal tuberosity; the swelling around this point denotes the situation of the frontal sinuses. 8. The temporal ridge commencing from the external angular process (4). The depression in which the figure 8 is situated is a part of the temporal fossa. 9. The nasal spine.

Fig. 14.



rior border is thin, irregular, and squamous, and articulates with the sphenoid bone.

Development.—By two centres, one for each lateral half.

Articulations.—With twelve bones; the two parietal, the sphenoid, ethmoid, two nasal, two superior maxillary, two lachrymal, and two malar.

Attachment of Muscles.—To four pairs; occipito-frontalis, orbicularis palpebrarum, corrugator supercillii, and temporal.

TEMPORAL BONE.—The temporal bone is situated at the side and base of the skull, and is

visible into a squamous, mastoid, and petrous portion.

The *Squamous portion*, forming the anterior part of the bone, is thin, translucent, and contains no diploë. Upon its *external surface* it is smooth, to give attachment to the fleshy fibres of the temporal muscle, and has projecting from it an arched and lengthened process, the zygoma. Near the commencement of the zygoma upon its lower border, is a projection called the *tubercle*, to which is attached the external lateral ligament of the lower jaw, and continued horizontally inwards from the tubercle a rounded eminence, the *eminentia articularis*. The process of bone which is continued from the tubercle of the zygoma into the eminentia articularis is the *inferior root* of the zygoma. The *superior root* is continued upwards from the upper border of the zygoma, and forms the posterior part of the temporal ridge, serving by its projection to mark the division of the squamous from the mastoid portion of the bone; and the *middle root* is continued directly backwards, and terminates abruptly at a narrow fissure—the *fissura Glaseri* or *glenoid fissure*. The *internal surface* of the squamous portion is marked by several shallow fossæ, which correspond with the convolutions of the cerebrum, and by a furrow for the pos-

Fig. 14. The internal surface of the frontal bone; the bone is raised in such a manner as to show the orbito-nasal portion. 1. The grooved ridge for the lodgment of the superior longitudinal sinus and attachment of the falx. 2. The foramen cæcum. 3. The superior or coronal border of the bone; the figure is situated near that part which is bevelled at the expense of the internal table. 4. The inferior border of the bone. 5. The orbital plate of the left side. 6. The cellular border of the ethmoidal fissure. The foramen cæcum (2) is seen through the ethmoidal fissure. 7. The anterior and posterior ethmoidal foramina; the anterior seen leading into its canal. 8. The nasal spine. 9. The depression within the external angular process (12) for the lachrymal gland. 10. The depression for the pulley of the superior oblique muscle of the eye; immediately to the left of this number is the supra-orbital notch, and to its right the internal angular process. 11. The opening leading into the frontal sinuses. The same parts are seen upon the opposite side of the figure. 12: The external angular process.

terior branch of the arteria meningea magna. The *superior* or *squamous border*, is very thin and bevelled at the expense of the inner surface, so as to overlap the lower and arched border of the parietal bone. The *inferior border* is thick and dentated to articulate with the spinous process of the sphenoid bone.

The *Mastoid portion* forms the posterior part of the bone; it is thick and hollowed between its tables into a loose and cellular diploë. Upon its *external surface* it is rough for the attachment of muscles, and contrasts strongly with the smooth and polished-like surface of the squamous portion; every part of this surface is pierced by small foramina, which give passage to minute arteries and veins;

one of these openings, oblique in its direction, of large size, and situated near the posterior border of the bone, the *mastoid foramen*, transmits a vein to the lateral sinus. This foramen is not unfrequently situated in the occipital bone. The inferior part of this portion is round and expanded—the *mastoid process*—and excavated in its interior into numerous cells, which form a part of the organ of hearing. In front of the mastoid process and between the superior and middle roots of the zygoma, is the large oval opening of the *meatus auditorius externus*, surrounded by a rough lip, the *processus auditorius*. Directly to the inner side, and partly concealed by the mastoid process, is a deep groove, the *digastric fossa*; and a little more internally the *occipital groove*, which lodges the occipital artery. Upon its *internal surface* the mastoid portion presents a broad and shallow groove for the lateral sinus, and terminating in this groove the internal opening of the mastoid foramen. The *superior border* of the mastoid portion is dentated, and its posterior border thick and less serrated for articulation with the inferior border of the occipital bone.

The *Petrous portion* of the temporal bone is named from its extreme hardness and density. It is a three-sided pyramid, projecting horizontally forwards into the base of the skull, the base being

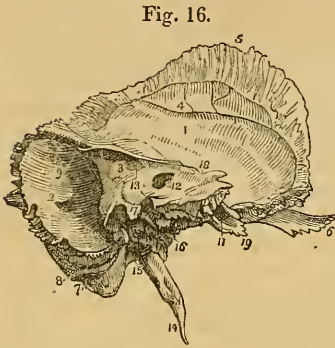
Fig. 15.

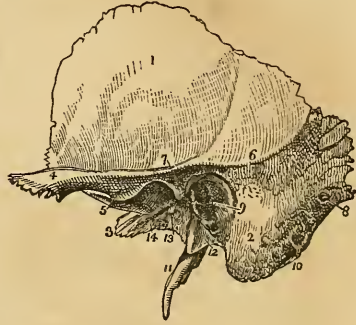

Fig. 15. The external surface of the temporal bone of the left side. 1. The squamous portion. 2. The mastoid portion. 3. The extremity of the petrous portion. 4. The zygoma. 5. Indicates the tubercle of the zygoma, and at the same time its anterior root turning inwards to form the eminentia articularis. 6. The superior root of the zygoma, forming the posterior part of the temporal ridge. 7. The middle root of the zygoma terminating abruptly at the glenoid fissure. 8. The mastoid foramen. 9. The meatus auditorius externus, surrounded by the processus auditorius. 10. The digastric fossa, situated immediately to the inner side of (2) the mastoid process. 11. The styloid process. 12. The vaginal process. 13. The glenoid or Glaserian fissure; the leading line from this number crosses the rough posterior portion of the glenoid fossa. 14. The opening and part of the groove for the Eustachian tube.

applied against the internal surface of the squamous and mastoid portions, and the apex being received into the triangular interval between the spinous process of the sphenoid and basilar process of the occipital bone. For convenience of description it is divisible into three surfaces—anterior, posterior, and basilar; and three borders—superior, anterior, and posterior.

Surfaces.—The *anterior surface*, forming the posterior boundary of the middle fossa of the interior of the base of the skull, presents for examination from base to apex, first an *eminence* caused by the projection of the perpendicular semicircular canal; next, a groove leading to an irregular oblique opening—the *hiatus Fallopii*—for the transmission of the petrosal branch of the Vidian nerve; thirdly, another and smaller oblique foramen, immediately beneath the preceding, for the passage of the nervus petrosus superficialis minor—a branch of Jacobson's nerve;



and lastly a large foramen near the apex of the bone, the termination of the carotid canal.

The *posterior surface* forms the front boundary of the posterior fossa of the base of the skull; near its middle is the oblique entrance of the *meatus auditorius internus*. The meatus pursues a course directly outwards; it is about one-third of an inch in length, and terminates in two deep depressions (nearly one-eighth of an inch in depth) separated by a sharp, horizontal ridge. The *superior depression*, the smaller of the two, is divided at its extremity, by a vertical ridge, into an anterior portion, which is the commencement of the aquæductus Fallopii, for the transmission of the facial nerve; and a posterior portion which corresponds with the upper part of the inner wall of the vestibule, and is pierced by numerous openings for

Fig. 16. The left temporal bone, seen from within. 1. The squamous portion. 2. The mastoid foramen. The number is placed immediately above the inner opening of the mastoid foramen. 3. The petrous portion. 4. The groove for the posterior branch of the arteria meningea magna. 5. The bevelled edge of the squamous border of the bone. 6. The zygoma. 7. The digastric fossa immediately internal to the mastoid process. 8. The occipital groove. 9. The groove for the lateral sinus. 10. The elevation upon the anterior surface of the petrous bone marking the situation of the perpendicular semicircular canal. 11. The opening of termination of the carotid canal. 12. The meatus auditorius internus. 13. A dotted line leads upwards from this number to the narrow fissure which lodges a process of the dura mater. Another line leads downwards to the sharp edge which conceals the opening of the aquæductus cochleæ, while the number itself is situated on the bony lamina which overlies the opening of the aquæductus vestibuli. 14. The styloid process. 15. The stylo-mastoid foramen. 16. The carotid foramen. 17. The jugular process. The deep excavation to the left of this process forms part of the jugular fossa, and that to the right is the groove for the vein of the cochlea. 18. The notch for the fifth nerve upon the upper border of the petrous bone, near to its apex. 19. The extremity of the petrous bone which gives origin to the levator palati and tensor tympani muscles.

the passage of filaments of the vestibular nerve. The *inferior depression* terminates in two oval pits, which correspond with the inferior part of the inner wall of the vestibule, and are also pierced with openings for the passage of filaments of the vestibular nerve. Upon the anterior wall of the inferior depression, and near to its termination, is a spiral groove, perforated by minute openings for the passage of the filaments of the cochlear nerve; and in the centre of the spine is a foramen larger than the rest, which leads into the central canal of the modiolus, *tubulus centralis modioli*. This groove corresponds with the base of the cochlea, and is termed the *tractus spiralis foraminulentus*. Upon the posterior wall of the depression, and opposite to the spiral groove, is a longitudinal groove leading to a foramen which transmits a considerable branch of the vestibular nerve. Above the meatus auditorius internus is a small oblique fissure, and a minute foramen; the former lodges a process of the dura mater, and the foramen gives passage to a small vein. Further outwards, towards the mastoid portion of the bone, is a small slit, almost hidden by a thin plate of bone; this is the *aquæductus vestibuli*, and transmits a small artery and vein of the vestibule and a process of dura mater. Below the meatus, and partly concealed by the margin of the posterior border of the bone, is the *aquæductus cochleæ*, through which passes a vein from the cochlea to the internal jugular vein and a process of dura mater.

The *basilar surface* is rough and irregular, and enters into the formation of the under surface of the base of the skull. Projecting downwards, near its middle, is a long sharp spine,—the *styloid process*,—occasionally connected with the bone only by cartilage, and lost during maceration, particularly in the young subject. At the base of this process is a rough sheath-like ridge, into which the styloid process appears implanted, the *vaginal process*. In front of the vaginal process is a broad triangular depression, the *glenoid fossa*, bounded in front by the eminentia articularis, behind by the vaginal process, and externally by the rough lip of the processus auditorius.

This fossa is divided transversely by the *glenoid fissure* (fissura Glaseri) which lodges the extremity of the processus gracilis of the malleus, and transmits the laxator tympani muscle, chorda tympani nerve, and anterior tympanic artery. The surface of the fossa in front of this fissure is smooth, to articulate with the condyle of the lower jaw; and that behind the fissure is rough, for the reception of a part of the parotid gland. At the extremity of the inner angle of the glenoid fossa is the foramen for the *Eustachian tube*; and separated from it by a thin lamella of bone, called *processus cochleariformis*, is a small canal for the transmission of the tensor tympani muscle. Directly behind, and at the root of the styloid process, is the *stylo-mastoid foramen*, the opening of exit to the facial nerve, and of entrance to the stylo-mastoid artery. Nearer to the apex of the bone is a large oval opening, the *carotid foramen*—the commencement of the carotid canal, which lodges the internal carotid artery and the carotid plexus. And between the stylo-mastoid and

carotid foramen in the posterior border, is an irregular excavation forming part of the jugular fossa, and divided into two parts by a ridge and a sharp spine, the *jugular process*. Upon this ridge, at the posterior margin of the carotid foramen, is a small opening leading into the canal which transmits the tympanic branch of the glosso-pharyngeal nerve (Jacobson's nerve).

Borders.—The *superior border* is sharp, and gives attachment to the tentorium cerebelli. It is grooved for the superior petrosal sinus, and near its extremity is marked by a smooth notch upon which reclines the fifth nerve.

The *anterior border* is grooved for the Eustachian tube, and forms the posterior boundary of the foramen lacerum basis cranii; by its sharp extremity it gives attachment to the tensor tympani and levator palati muscles. The *posterior border* is grooved for the inferior petrosal sinus, and excavated for the jugular fossa; it forms the anterior boundary of the foramen lacerum posterius.

Developement.—By *five* centres; one for the squamous portion, one for the mastoid, one for the petrous portion, one for the auditory process, and one for the styloid process.

Articulations.—With *five* bones; occipital, parietal, sphenoid, inferior maxillary, and malar.

Attachment of Muscles.—To *fourteen*; by the squamous portion, to the temporal; by the zygoma, to the masseter; by the mastoid portion, to the occipito-frontalis, splenius capitis, sterno-mastoid, trachelo-mastoid, digastricus and retrahens aurem; by the styloid process, to the stylo-pharyngeus, stylo-hyoideus, stylo-glossus, and two ligaments—the stylo-hyoid and stylo-maxillary; and by the petrous portion, to the levator palati, tensor tympani, and stapedius.

SPHENOIDAL BONE.—The sphenoid (σφῆν, a wedge) is an irregular bone situated at the base of the skull, wedged between the other bones of the cranium, and entering into the formation both of the cranium and face. It bears some resemblance in form to a bat with its wings extended, and is divisible into body, wings, and processes.

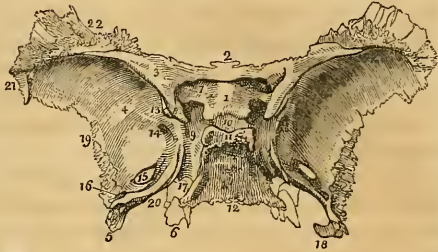
The *body* forms the central mass of the bone, from which the wings and processes are projected. From the upper and anterior part of the body extend on each side two small triangular plates,—the lesser wings; from either side and expanding laterally are the greater wings; proceeding backwards from the base of the greater wings, the spinous processes; and downwards, the pterygoid processes.

The *body* presents for examination a superior or cerebral surface, an antero-inferior surface, and a posterior surface.

Superior Surface.—At the anterior extremity of this surface is a small projecting plate, the *ethmoidal spine*, and spreading out on either side the lesser wings. Behind the ethmoidal spine in the middle line is a rounded elevation, the *olivary process*, which supports the commissure of the optic nerves. Passing outwards and forwards from the olivary process, are the *optic foramina*, which transmit the optic nerves and ophthalmic arteries. Behind the optic

foramina are two sharp tubercles, the *anterior clinoid processes*, which are the inner termination of the lesser wings. Beneath these processes, on the sides of the olivary process, are two depressions* for the last turn of the internal carotid arteries. Behind the olivary process, are

Fig. 17.



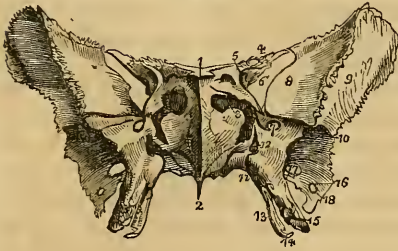
the olivary process, is the *sella Turcica*, the deep fossa which lodges the pituitary gland and circular sinus; behind and somewhat overhanging the *sella Turcica*, is a broad rough plate, bounded at each angle by a tubercle, the *posterior clinoid processes*; and behind this plate an inclining surface, which is continuous with the basilar process of the occipital bone. On either side of the *sella Turcica* is a broad groove (*carotid*) which lodges the internal carotid artery, the cavernous sinus, and its nerves. Immediately external to this groove, at the junction of the greater wings with the body, are four foramina: the first is a broad interval, the *sphenoidal fissure*, which separates the greater and lesser wings, and transmits the third, fourth, the three branches of the ophthalmic division of the fifth and the sixth nerves, and the ophthalmic vein. Behind and beneath this fissure is the *foramen rotundum* for the superior maxillary nerve; and still farther back, in the base of the spinous process, the *foramen ovale* for the inferior maxillary nerve, *arteria meningea parva*, and *nervus petrosus superficialis minor*. Behind the *foramen ovale*, near the apex of the spinous process, is the *foramen spinosum* for the *arteria meningea magna*.

Fig. 17. The superior or cerebral surface of the sphenoid bone. 1. The *processus olivaris*. 2. The *ethmoidal spine*. 3. The lesser wing of the left side. 4. The cerebral surface of the greater wing of the same side. 5. The spinous process. 6. The extremity of the pterygoid process of the same side projecting downwards from the under surface of the body of the bone. 7. The *foramen opticum*. 8. The *anterior clinoid process*. 9. The groove by the side of the *sella Turcica*; for lodging the internal carotid artery, cavernous plexus, cavernous sinus, and orbital nerves. 10. The *sella Turcica*. 11. The posterior boundary of the *sella Turcica*; its projecting angles are the posterior clinoid processes. 12. The basilar portion of the bone. 13. Part of the *sphenoidal fissure*. 14. The *foramen rotundum*. 15. The *foramen ovale*. 16. The *foramen spinosum*. 17. The angular interval which receives the apex of the petrous portion of the temporal bone. The posterior extremity of the Vidian canal terminates at this angle. 18. The spine of the spinous process; it affords attachment to the internal lateral ligament of the lower jaw. 19. The border of the greater wing and spinous process which articulates with the anterior part of the squamous portion of the temporal bone. 20. The internal border of the spinous process, which assists in the formation of the *foramen lacerum basis cranii*. 21. That portion of the greater ala which articulates with the anterior inferior angle of the parietal bone. 22. The portion of the greater ala, which articulates with the orbital process of the frontal bone.

* These depressions are occasionally, as in a skull before me, converted into foramina by the extension of a short bony pillar from the anterior clinoid process to the body of the sphenoid.

Upon the *antero-inferior surface* is a long flattened spine, the *rostrum*, which articulates with the vomer; and on each side of the

Fig. 18.



rostrum an irregular opening, leading into the sphenoidal cells; these openings are partially closed by two thin plates of bone (frequently broken away), the *sphenoidal spongy bones*. On each side of the sphenoidal cells are the outlets of the optic foramina, sphenoidal fissures, and foramina rotunda, the lesser and greater wings; and below, the pterygoid processes.

Upon the under surface of the body are two small fissures, converted into canals by the vomer, the *pterygo-palatine canals*, which transmit the pterygo-palatine arteries; and traversing the roots of the pterygoid at their union with the body, two *pterygoid* or *Vidian canals*, which give passage to the Vidian nerve and artery at each side. The *posterior surface* is flat and rough, and articulates with the basilar process of the occipital bone. In the adult this union is usually completed by bone; from which circumstance the sphenoid, in conjunction with the occipital, was described by Soemmering and Meckel as a single bone, under the name of *spheno-occipital* or *basilar bone*. This surface is continuous on each side with the spinous process, and at the angle of union is the termination of the Vidian canal or foramen pterygoideum.

The *lesser wings* (processes of Ingrassias) are thin and triangular, the base being attached to the upper and anterior part of the body of the sphenoid, and the apex extended outwards, and terminating in an acute point. The anterior border is irregularly serrated, the posterior being free and rounded, and received into the fissure of Sylvius of the cerebrum. The inner extremity of this border forms the anterior clinoid process, which is supported by a short pillar of bone, giving attachment to a part of the common tendon of the muscles of the orbit. The lesser wing forms the posterior part of the roof of the orbit, and its base is traversed by the optic foramen.

The *greater wings* present three surfaces; a superior or cerebral, which forms part of the middle fossa of the base of the skull, an

Fig. 18. The antero-inferior view of the sphenoid bone. 1. The ethmoid spine. 2. The rostrum. 3. The sphenoidal spongy bone, partly closing the left opening of the sphenoidal cells.* 4. The lesser wing. 5. The foramen opticum piercing the base of the lesser wing. 6. The sphenoidal fissure. 7. The foramen rotundum. 8. The orbital surface of the greater wing. 9. Its temporal surface. 10. The pterygoid ridge. 11. The pterygo-palatine canal. 12. The foramen of entrance to the Vidian canal. 13. The internal pterygoid plate. 14. The hamular process. 15. The external pterygoid plate. 16. The foramen spinosum. 17. The foramen ovale. 18. The extremity of the spinous process of the sphenoid.

* This is a part of the pyramid of Wistar. See description of ethmoid.—G.

anterior surface which assists in forming the outer wall of the orbit, and an external surface, divided into two parts by the *pterygoid ridge*. The superior part of the external surface enters into the formation of the temporal fossa, and the inferior portion forms part of the zygomatic fossa. The pterygoid ridge, dividing the two, gives attachment to the upper origin of the pterygoideus externus muscle.

The *spinous processes* project backwards at each side from the base of the greater wings of the sphenoid, and are received into the angular intervals between the squamous and petrous portions of the temporal bones. Piercing the base of each process is a large oval opening, the *foramen ovale*; nearer its apex a smaller opening, the *foramen spinosum*; and extending downwards from the apex a short spine, which gives attachment to the internal lateral ligament of the lower jaw and to the laxator tympani muscle. The external border of the spinous process is rough, to articulate with the lower border of the squamous portion of the temporal bone; the internal forms the anterior boundary of the foramen lacerum basis cranii, and is somewhat grooved for the reception of the Eustachian tube.

The *pterygoid processes* descend perpendicularly from the base of the greater wings, and form in the articulated skull the lateral boundaries of the posterior nares. Each process consists of an external and internal plate, and an anterior surface. The external plate is broad and thin, giving attachment, by its external surface, to the external pterygoid muscle, and by its internal surface to the internal pterygoid. This plate is sometimes pierced by a foramen, which is frequently formed by a process of communication passing between it and the spinous process. The internal pterygoid plate is long and narrow, and terminated at its extremity by a curved hook, the *hamular process*, around which plays the tendon of the tensor palati muscle. At the base of the internal pterygoid plate is a small oblong depression, the *scaphoid fossa*, from which arises the circumflexus, or tensor palati muscle. The interval between the two pterygoid plates is the *pterygoid fossa*; and the two plates are separated inferiorly by an angular notch (*palatine*), which receives the tuberosity, or *pterygoid process*, of the palate bone. The anterior surface of the pterygoid process is broad near its base, and supports Meckel's ganglion. The base of the process is pierced by the Vidian canal.

Development.—By *twelve* centres; four for the body, viz., two for its anterior, and two for its posterior part; four for the wings; two for the external pterygoid plates, and two for the sphenoidal spongy bones.

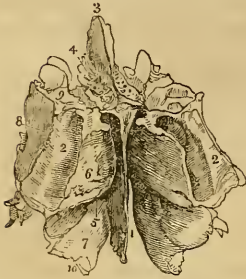Articulations.—With *twelve* bones; all the bones of the head and five of the face, viz. the two malar, two palate, and the vomer.

Attachment of Muscles.—To *twelve* pairs; temporal, external pterygoid, internal pterygoid, superior constrictor, tensor palati, laxator tympani, levator palpebræ, obliquus superior, superior rectus, internal rectus, inferior rectus, and external rectus.

ETHMOID BONE.—The ethmoid (*ἔθμωδός*, a sieve) is a square-shaped cellular bone, situated between the two orbits, at the root of the nose, and perforated upon its upper surface by a number of small openings, from which peculiarity it has received its name. It consists of a perpendicular lamella and two lateral masses.

The *perpendicular lamella* is a thin central plate, which articulates with the vomer and cartilage of the septum, and assists in forming the septum of the nose. It is surmounted superiorly by a thick and strong process, the *crista galli*, which projects into the cavity of the skull, and gives attachment to the falx cerebri. On each side of the *crista galli*, upon the upper surface of the bone, is a thin and grooved plate, perforated by a number of small openings, the *cribriform lamella*, which supports the bulb of the olfactory nerve, and gives passage to its filaments, and to the internal nasal nerve.

Fig. 19.



The cribriform lamella serves to connect the masses with the perpendicular plate.

The *lateral masses* are divisible into an internal and external surface, and four borders—superior, inferior, anterior, and posterior. The *internal surface* is rough and slightly convex, and forms the external boundary of the upper part of the nasal fossæ. Towards the posterior border of this surface is a narrow horizontal fissure,—the *superior meatus* of the nose,—the upper margin of which is thin, and somewhat curled inwards; hence it is named the *superior turbinated bone*. Below the meatus is the convex surface of another thin plate which is curled outwards, and forms the lower border of the mass, the *middle turbinated bone*. The *external surface* is quadrilateral and smooth, hence it is named *os planum*; it enters into the formation of the inner wall of the orbit.

The *superior border* is irregular and cellular, the cells being completed by the edges of the ethmoidal fissure of the frontal bone. This border is crossed by two grooves, sometimes complete canals, opening into the orbit by the anterior and posterior ethmoidal foramina. The *inferior border* is formed internally by the lower border of the middle turbinated bone, and externally by a concave irregular

Fig. 19. The ethmoid bone seen from above and behind. 1. The central lamella. 2, 2. The lateral masses; the numbers are placed on the posterior border of the lateral mass at each side. 3. The crista galli process. 4. The cribriform plate of the left side pierced by the cribriform foramina. 5. The hollow space immediately above and to the left of this number is the superior meatus. 6. The superior turbinated bone. 7. The middle turbinated bone; the numbers 5, 6, 7, are situated upon the internal surface of the left lateral mass, near its posterior part. The interval between these parts is the superior meatus. 8. The external surface of the lateral mass, or os planum. 9. The superior or frontal border of the lateral mass, grooved by the anterior and posterior ethmoidal canals. 10. Refers to the concavity of the middle turbinated bone, which is the upper boundary of the middle meatus.

fossa, the upper boundary of the middle meatus. The *anterior border* presents a number of incomplete cells, which are closed by the superior maxillary and lachrymal bones; the *posterior border* is irregularly cellular, to articulate with the sphenoid and palate bones.*

The lateral masses are composed of cells, which are divided by a thin partition into anterior and posterior ethmoidal cells. The anterior, the most numerous, communicate with the frontal sinuses, and open by means of an irregular and incomplete tubular canal, the *infundibulum*, into the middle meatus. The posterior cells, fewer in number, open into the superior meatus.

Development.—By three centres; one for each lateral mass, and one for the perpendicular lamella.

Articulations.—With thirteen bones; two of the cranium,—the frontal and sphenoid; the rest of the face, viz. the nasal, superior maxillary, lachrymal, palate, the inferior turbinated, and the vomer.

No muscles are attached to this bone.

BONES OF THE FACE.

The face is composed of fourteen bones; viz. the

Two nasal,	Two palate,
Two superior maxillary,	Two inferior turbinated,
Two lachrymal,	Vomer,
Two malar,	Inferior maxillary.

NASAL BONES.—The nasal (fig. 24) are two small quadrangular bones, forming by their union the bridge and base of the nose. Upon the upper surface they are convex, and pierced by a foramen, for a small artery; on the under surface they are somewhat concave, and marked by a groove, which lodges the nasal branch of the ophthalmic nerve. The superior border is narrow and thick, the inferior broad, thin, and irregular.

Development.—By a single centre for each bone.

Articulations.—With four bones; frontal, ethmoidal, nasal, and superior maxillary.

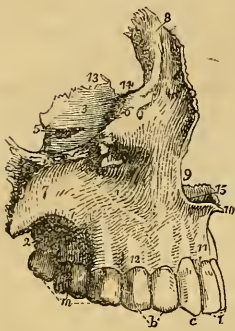
Attachment of Muscles.—It has in relation with it the pyramidalis nasi, and compressor nasi; but neither of these muscles is inserted into it.

SUPERIOR MAXILLARY BONES.—The superior maxillary are the largest bones of the face, with the exception of the lower jaw; they form, by their union, the whole of the upper jaw, and assist in the construction of the nose, the orbit, the cheek, and the palate. Each bone is divisible into a body and four processes.

* Mr. Wilson has entirely omitted the description of the *pyramids of Wistar*, which in their early stage project as thin triangular laminæ from the posterior borders of the lateral masses. As they become developed the edges of the laminæ fold over so as to form an imperfect triangular pyramid, encroaching upon the body of the sphenoid bone on its under surface, and finally coalescing with it so as to perfect the sphenoidal cells. The remains of these pyramids may be seen on the adult bone, and are called by Wilson, the *sphenoidal spongy bones*. They were first studied by Professor Wistar, and are called after him.—G.

The *body* is triangular in form, and hollowed in its interior into a large cavity, the *antrum maxillare* (antrum of Highmore). It presents for examination three sides; an external or facial, internal or nasal, and a posterior or zygomatic, and a superior surface—the orbital. The *external* or *facial surface* forms the anterior part of the bone; it is irregularly concave, and presents a deep depression towards its centre,

Fig. 20.



—the *canine fossa*, which gives attachment to two muscles, the *compressor nasi* and *levator anguli oris*. Immediately above this fossa is the *infra-orbital foramen*,—the termination of the infra-orbital canal,—transmitting the superior maxillary nerve, and infra-orbital artery; and above the infra-orbital foramen, the lower margin of the orbit, continuous externally with the rough articular surface of the malar process, and internally with a thick ascending plate, the nasal process. Towards the middle line of the face this surface is bounded by the concave border of the opening of the nose, which is projected forwards at its inferior termination into a sharp process, forming with a similar process of the opposite bone, the *nasal spine*. Beneath the nasal spine, and above the two superior incisor teeth, is a slight depression, the *incisive* or *myrtiform fossa*, which gives origin to the depressor labii superioris æqueque nasi muscle. The myrtiform fossa is divided from the canine fossa by a perpendicular ridge, corresponding with the direction of the root of the canine tooth. The inferior boundary of the facial surface is the alveolar process which contains the teeth of the upper jaw, and it is separated from the zygomatic surface by a strong projecting eminence, the malar process. The *internal*, or *nasal surface*, presents a large irregular opening, leading into the antrum maxillare; this opening is nearly closed in the articulated skull by the ethmoid, palate, lachrymal, and inferior turbinated bones. The cavity of the antrum is somewhat triangular, corresponding in shape to the form of the body of the bone. Upon its internal surface are numerous grooves, lodging branches of the superior maxillary nerve, and projecting into its floor several conical processes, corresponding with the roots of the first and second molar teeth. In front of the opening of the antrum is the

Fig. 20. The superior maxillary bones of the right side, as seen from the lateral aspect. 1. The external, or facial surface; the depression in which the figure is placed is the canine fossa. 2. The posterior, or zygomatic surface. 3. The superior, or orbital surface. 4. The infra-orbital foramen; it is situated immediately below the number. 5. The infra-orbital canal, leading to the infra-orbital foramen. 6. The inferior border of the orbit. 7. The malar process. 8. The nasal process. 9. The concavity forming the lateral boundary of the anterior nares. 10. The nasal spine. 11. The incisive, or myrtiform fossa. 12. The alveolar process. 13. The internal border of the orbital surface, which articulates with the ethmoid and palate bone. 14. The concavity which articulates with the lachrymal bone, and forms the commencement of the nasal duct. 15. The palate process. *i*. The two incisor teeth. *c*. The canine. *b*. The two bicuspidati. *m*. The three molars.

strong ascending plate of the nasal process, marked inferiorly by a rough horizontal ridge, which gives attachment to the inferior turbinated bone. The concave depression immediately above this ridge corresponds with the middle meatus of the nose, and that below the ridge with the inferior meatus. Between the nasal process and the opening of the antrum, is a deep groove, which is converted into a canal by the lachrymal bone, and constitutes the nasal duct or ductus ad nasum. The *superior border* of the nasal surface is irregularly cellular, and articulates with the lachrymal and ethmoid bone; the *posterior border* is rough, and articulates with the palate bone; the *anterior border* is sharp, and forms the free margin of the opening of the nose; and from the *inferior border* projects inwards a strong horizontal plate, the palate process.

The *posterior surface* may be called *zygomatic*, from forming part of the zygomatic fossa; it is bounded externally by the malar process, and internally by a rough and rounded border, the *tuberosity*, which is pierced by a number of small foramina, giving passage to the posterior dental nerves and branches of the superior dental artery. The lower part of this tuberosity presents a rough oval surface to articulate with the palate bone, and immediately above and to the inner side of this articular surface a smooth groove, which forms part of the posterior palatine canal. The *superior border* is smooth and rounded to form the lower boundary of the spheno-maxillary fissure, and is marked by a notch, the commencement of the infra-orbital canal. The *inferior* boundary is the alveolar process, containing the two last molar teeth.

The *orbital surface* is triangular and thin, and constitutes the floor of the orbit. It is bounded internally by an irregular edge, which articulates with the palate, ethmoid, and lachrymal bone; posteriorly, by the smooth border which enters into the formation of the spheno-maxillary fissure; and anteriorly, by a convex margin, partly smooth and partly rough, the smooth portion forming part of the lower border of the orbit, and the rough articulating with the malar bone. The middle of this surface is channelled by a deep groove and canal, the infra-orbital, which terminates at the infra-orbital foramen.

The four processes of this bone are, the nasal, malar, alveolar, and palate.

The *nasal process* ascends by the side of the nose, to which it forms the lateral boundary, and articulates with the frontal and nasal bone.

By its external surface it gives attachment to the levator labii superioris æque nasi, and to the orbicularis palpebrarum muscle; its internal surface contributes to form the inner wall of the nares, and the posterior border is thick and hollowed into a groove for the nasal duct. The margin of the nasal process, which is continuous with the lower border of the orbit, is sharp and marked by a small *tubercle* which serves as a guide to the introduction of the knife in the operation for fistula lachrymalis.

The *malar process*, large and irregular, is situated at the angle

of separation between the facial and zygomatic surfaces, and presents a large triangular surface for articulation with the malar bone.

The *alveolar process* forms the lower margin of the bone; it is spongy and cellular in texture, and excavated into deep holes for the reception of the teeth.

The *palate process* is thick and strong, and projects horizontally inwards from the inner surface of the body of the bone. Superiorly, it is concave, and forms the floor of the nares; inferiorly, it is also concave, and assists in the formation of the roof of the palate. Its internal edge is raised into a ridge, which, with a corresponding ridge in the opposite bone, forms a groove for the reception of the vomer. At the anterior extremity of its nasal surface is a foramen, which leads into a canal formed conjointly by the two superior maxillary bones,—the naso-palatine canal. The termination of this canal is situated immediately behind the incisor teeth, hence it is also named the incisive foramen.*

Developement.—By six centres; one for the body, one for each of the three processes, nasal, malar, and palate; and two for the alveolar process.

Articulations.—With nine bones, viz. with two of the cranium and with all the bones of the face, excepting the inferior maxillary. These are the frontal and ethmoid, nasal, lachrymal, malar, inferior turbinated, palate, vomer, and with its fellow of the opposite side.

Attachment of Muscles.—To nine; orbicularis palpebrarum, obliquus inferior oculi, levator labii superioris alæque nasi, levator labii superioris proprius, levator anguli oris, compressor nasi, depressor labii superioris alæque nasi, buccinator, masseter.

LACHRYMAL BONES—(os unguis, from an imagined resemblance to a finger nail). The lachrymal (fig. 24) is a thin oval-shaped plate of bone, situated at the anterior and inner angle of the orbit. It may be divided into an external and internal surface and borders. The *external surface* is smooth and marked by a vertical ridge,—the lachrymal crest,—into two portions, one of which is flat and enters into the formation of the orbit, hence may be called the orbital portion; the other is concave, and lodges the lachrymal sac, hence the lachrymal portion. The *internal surface* is rough and completes the anterior ethmoid cells, it assists in forming the wall of the nasal fossæ and nasal duct.

Developement.—By a single centre.

Articulations.—With four bones; two of the cranium, frontal and ethmoid; and two of the face, superior maxillary, and inferior turbinated bone.

Attachment of Muscles.—To one muscle, the tensor tarsi, and to an expansion of the tendo oculi, the former arising from the orbital surface, the other being attached to the lachrymal crest.

MALAR BONES—(mala, the cheek). The malar (fig. 24) is the strong quadrangular bone which forms the prominence of the

* It contains the ganglion of Cloquet from the fifth pair.—G.

cheek. It is divisible into an external and internal surface, and four processes, the frontal, orbital, maxillary, and zygomatic. The *external surface* is smooth and convex, and pierced by several small openings which give passage to filaments of the temporo-malar nerve and minute arteries. The *internal surface* is concave, partly smooth and partly rough; smooth where it forms part of the temporal fossa, and rough where it articulates with the superior maxillary bone.

The *frontal process* ascends perpendicularly to form the outer border of the orbit, and articulates with the external angular process of the frontal bone. The *orbital process* is a thick plate, which projects inwards from the frontal process, and unites with the great ala of the sphenoid to constitute the outer wall of the orbit. It is pierced by several small foramina for the passage of temporo-malar filaments of the superior maxillary nerve. The *maxillary process* is broad, and articulates with the superior maxillary bone. The *zygomatic process*, narrower than the rest, projects backwards to unite with the zygoma of the temporal bone.

Development.—By a single centre.

Articulations.—With *four* bones; three of the cranium, frontal, temporal, and sphenoid; and one of the face, the superior maxillary bone.

Attachment of Muscles.—To *six*; orbicularis palpebrarum, levator labii superioris proprius, zygomaticus minor, and major, masseter, and temporal.

PALATE BONES.—The palate bones are situated at the posterior part of the nares, where they enter into the formation of the palate, the side of the nose, and the posterior part of the floor of the orbit; hence they might with great propriety be named the palato-naso-orbital bones. Each bone resembles in general form the letter L, and is divisible into a horizontal plate, a perpendicular plate, and a pterygoid process or tuberosity.

The *horizontal plate* is quadrilateral; and presents two surfaces, one superior, which enters into the formation of the floor of the nares, the other inferior, forming the posterior

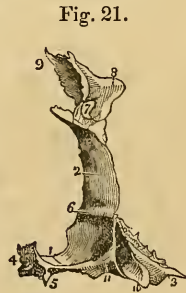

Fig. 21.

Fig. 21. A posterior view of the palate bone in its natural position; it is slightly turned to one side to obtain a sight of the internal surface of the perpendicular plate (2). 1. The horizontal plate of the bone; its upper or nasal surface. 2. The perpendicular plate; its internal or nasal surface. 3, 10, 11. The pterygoid process or tuberosity. 4. The broad internal border of the horizontal plate which articulates with the similar border of the opposite bone. 5. The pointed process, which with a similar process of the opposite bone forms the palate spine. 6. The horizontal ridge which gives attachment to the inferior turbinated bone; the concavity below this ridge enters into the formation of the inferior meatus, and the concavity (2) above the ridge enters into that of the middle and superior meatus. 7. The sphenopalatine foramen. 8. The orbital portion. 9. The pterygoid apophysis. 10. The middle facet of the tuberosity, which enters into the formation of the pterygoid fossa. The facets 11 and 3 articulate with the two pterygoid plates,—11 with the internal, and 3 with the external.

part of the hard palate. The *superior surface* is concave and rises towards the middle line, where it unites with its fellow of the opposite side and forms a crest, which articulates with the vomer. The *inferior surface* is marked by a slight transverse ridge, to which is attached the tendinous expansion of the tensor palati muscle, and near to the external border are two openings, the *posterior palatine foramina*, which transmit the posterior palatine nerves and artery. The posterior border is concave, and presents at its inner extremity a sharp point, which with a corresponding point in the opposite bone constitutes the *palate spine* for the attachment of the azygos uvulæ muscle.

The *perpendicular plate* is also quadrilateral; and presents two surfaces, one internal or nasal, forming a part of the wall of the nares; the other external, bounding the spheno-maxillary fossa and antrum. The *internal surface* is marked near its middle by a horizontal ridge, to which is united the inferior turbinated bone. The slightly concave surface below this ridge enters into the formation of the inferior meatus of the nose, and that above the ridge of the middle and superior meatus. The *external surface*, extremely irregular, is rough on each side for articulation with the neighbouring bones, and smooth in the middle to constitute the inner boundary of the spheno-maxillary fossa. This smooth surface terminates inferiorly in a deep groove, which being completed by the tuberosity of the superior maxillary bone forms the *posterior palatine canal*.

Near the upper part of the perpendicular plate is a large opening, the *spheno-palatine foramen*, which transmits the spheno-palatine nerves and artery, and serves to divide the upper extremity of the bone into two portions, an anterior or orbital, and a posterior or sphenoidal portion. The *orbital portion* presents five surfaces; three articular, and two free; the three articular are the anterior, which looks forward and articulates with the superior maxillary bone, internal with the ethmoid, and posterior with the sphenoid. The free surfaces are the superior or orbital, which forms the posterior part of the floor of the orbit, and the external, which looks into the spheno-maxillary fossa.

The *sphenoidal portion*,* much smaller than the orbital, has three surfaces, two lateral and one superior. The external lateral surface enters into the formation of the spheno-

Fig. 22.

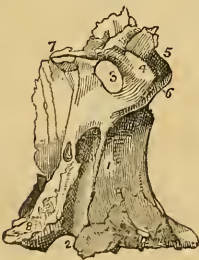

Fig. 22. The perpendicular plate of the palate bone seen upon its external or spheno-maxillary surface. 1. The rough surface of this plate, which articulates with the superior maxillary bone. 2. The posterior palatine canal, completed by the tuberosity of the superior maxillary bone. The rough surface to the left of the canal (2) articulates with the internal pterygoid plate. 3. The spheno-palatine foramen. 4, 5, 6. The orbital portion of the perpendicular plate. 4. The spheno-maxillary facet of this portion; 5. its orbital facet; 6. its maxillary facet, to articulate with the superior maxillary bone. 7. The sphenoidal portion of the perpendicular plate. 8. The pterygoid process or tuberosity of the bone.

* Called by Horner, the pterygoid apophysis.—G.

maxillary fossa ; the internal lateral forms part of the lateral boundary of the nares ; and the superior surface articulates with the under part of the body of the sphenoid bone.

The *pterygoid process* or *tuberosity* of the palate bone is the thick and rough process which stands backwards from the angle of union of the horizontal with the perpendicular portion of the bone. It is received into the angular fissure, which exists between the two plates of the pterygoid process at their inferior extremity, and presents three surfaces : one concave and smooth, which forms part of the pterygoid fossa ; and one at each side to articulate with the pterygoid plates. The anterior face of this process articulates with the superior maxillary bone.

Development.—By a single centre.

Articulations.—With *six* bones ; two of the cranium, the sphenoid and ethmoid ; and four of the face, the superior maxillary, inferior turbinated bone, vomer, and with the palate bone of the opposite side.

Attachment of Muscles.—To *four* ; the tensor palati, azygos uvulæ, internal and external pterygoid.

INFERIOR TURBINATED BONE.—The inferior turbinated or spongy bone is a thin layer of loose and spongy bone, slightly curled upon itself, and projecting inwards from the inner wall of the nares. It is developed from a single centre, and gives attachment to no muscles.

Articulations.—With *four* bones ; the ethmoid, superior maxillary, lachrymal, and palate.

VOMER.—The vomer is a thin and quadrilateral plate, forming a part of the septum of the nares. *Superiorly*, it is broad and expanded, and forms a sheath for the rostrum of the sphenoid ; *inferiorly*, it is thin, and received into a groove, formed by the articulation between the palate processes of the superior maxillary and palate bone of opposite sides. The *posterior border* is free, and divides the posterior nares ; the *anterior* is rough, and often slit into two layers, to receive the sharp edge of the perpendicular lamella of the ethmoid bone, and of the cartilage of the septum.

The vomer frequently presents a convexity to one or the other side ; it is developed by a single centre, and has no muscles attached to it.

Articulations.—With *six* bones ; the sphenoid, ethmoid, two superior maxillary, and two palate bones, and with the cartilage of the septum.

INFERIOR MAXILLARY BONE.—The *lower jaw* is the arch of bone which contains the inferior teeth ; it is divisible into a horizontal portion or body, and a perpendicular portion, the ramus, at each side.

Upon the *external surface* of the *body* of the bone, at the middle line, and extending from between the two first incisor teeth to the chin, is a slight ridge, called the *symphysis*. Immediately external to this ridge is a depression which gives origin to the depressor labii

inferioris muscle; and corresponding with the root of the lateral incisor tooth, another depression, the *incisive fossa*, for the levator labii inferioris. Further outwards is an oblique opening, the *anterior mental foramen*, for the exit of the inferior dental nerve and artery, and below this foramen, an oblique ridge which gives attachment to the depressor anguli oris, and platysma myoides. Near the posterior part of this surface is a rough impression made by the masseter muscle; and immediately in front of this impression, a groove may occasionally be seen for the facial artery. The projecting tuberosity at the posterior extremity of the lower jaw, at the point where the body and ramus meet, is the *angle*.

Upon the *internal surface* of the *body* of the bone at the symphysis, are two small pointed tubercles; immediately beneath these, two other tubercles less marked and pointed, beneath them a ridge, and beneath the ridge a rough depression of some size. These four points give attachment from above downwards to the genio-hyo-glossi, genio-hyoidei, part of the mylo-hyoidei and to the digastric muscles. Running outwards into the body of the bone from the above ridge, is a prominent line, the *mylo-hyoidean ridge*, which gives attachment to the mylo-hyoideus muscle, and by its extremity to the pterygo-maxillary ligament and superior constrictor muscle. Immediately above the ridge, and by the side of the symphysis, is a smooth concave surface, which corresponds with the sublingual gland; and below the ridge, and more externally, a deeper fossa for the submaxillary gland.

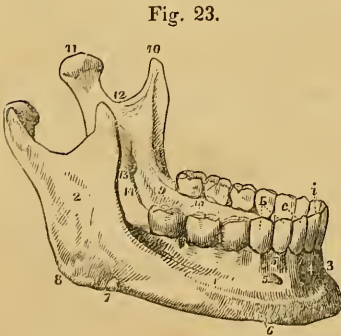
The *ramus* is a strong square-shaped process, differing in direction at various periods of life; thus,

in the fœtus and infant, it is almost parallel with the body; in youth it is oblique, and gradually increases in the vertical direction until manhood; in old age, after the loss of the teeth, it again declines and assumes the oblique direction. Upon its external surface it is rough, for the attachment of the masseter muscle; and at the junction of its posterior border with the body of the bone, is a rough tuberosity, the *angle* of the lower jaw,

which gives attachment by its inner margin to the stylo-maxillary ligament.

The upper extremity of the ramus presents two processes, separated by a concave sweep, the *sigmoid notch*. The anterior is the

Fig. 23. The lower jaw. 1. The body. 2. The ramus. 3. The symphysis. 4. The fossa for the depressor labii inferioris muscle. 5. The mental foramen. 6. The external oblique ridge. 7. The groove for the facial artery. 8. The angle. 9. The extremity of the mylo-hyoidean ridge. 10. The coronoid process. 11. The condyle. 12. The sigmoid notch. 13. The inferior dental foramen. 14. The mylo-hyoidean groove. 15. The alveolar process. *i.* The middle and lateral incisor tooth of one side. *c.* The canine tooth. *b.* The two bicuspides. *m.* The three molares.



coronoid process; it is sharp and pointed, and gives attachment by its inner surface to the temporal muscle. The anterior border of the coronoid process is grooved at its lower part of the buccinator muscle. The posterior process is the *condyle* of the lower jaw, which is flattened from before backwards, and smooth upon its upper surface, to articulate with the inter-articular fibro-cartilage. The constriction around the base of the condyle is its *neck*, into which is inserted the external pterygoid muscle. The sigmoid notch is crossed by the masseteric artery and nerve.

The *internal surface* of the ramus is marked near its centre by a large oblique foramen, the *inferior dental*,* for the inferior dental artery and nerve. Around this opening is a rough margin, to which is attached the internal lateral ligament, and passing downwards from the opening a narrow groove which lodges the mylo-hyoidean nerve. To the rough surface above, and in front of the inferior dental foramen, is attached the temporal muscle, and to that below it the internal pterygoid. The internal surface of the neck of the condyle gives attachment to the external pterygoid muscle; and the angle to the stylo-maxillary ligament.

Development.—By two centres; one for each lateral half, the two sides meeting at the symphysis, where they become united.

Articulations.—With the glenoid fossæ of the two temporal bones, through the medium of a fibro-cartilage.

Attachment of Muscles.—To fourteen pairs; by the external surface commencing at the symphysis, and proceeding outwards,—levator labii inferioris, depressor labii inferioris, depressor anguli oris, platysma myoides, buccinator and masseter; by the internal surface also commencing at the symphysis, the genio-hyo-glossus, genio-hyoideus, mylo-hyoideus, digastricus, superior constrictor, temporal, external pterygoid, and internal pterygoid.

Table of the Points of Development, Articulations and Attachment of Muscles, of the Bones of the Head.

	Development.	Articulations.	Attachment of muscles.
Occipital	4 .	6 .	13 pairs.
Parietal	1 .	5 .	1 muscle.
Frontal	2 .	12 .	4 pairs.
Temporal	5 .	5 .	14 muscles.
Sphenoid	12 .	12 .	12 pairs.
X Ethmoid	3 .	13 .	none.
† Nasal	1 .	4 .	none.
Superior maxillary	6 .	9 .	9 muscles.
Lachrymal	1 .	4 .	1 ib.
Malar	1 .	4 .	6 ib.
Palate	1 .	6 .	4 ib.
‡ Inferior turbinated	1 .	4 .	none.
‡ Vomer	1 .	6 .	none.
Lower jaw	2 .	2 .	14 pairs.

* Called also posterior mental foramen.—G.

SUTURES.

The bones of the cranium and face are connected with each other by means of sutures (*sutura*, a seam), of which there are four principal varieties,—serrated, squamous, harmonia, and schindylesis.

The *serrated suture* is formed by the union of two borders possessing serrated edges, as in the coronal, sagittal, and lambdoidal sutures. In these sutures the serrations are formed almost wholly by the external table, the edges of the internal table lying nearly in apposition.

The *squamous suture* (*squama*, a scale) is formed by the overlapping of the bevelled edges of two continuous bones, as in the articulation between the temporal and lower border of the parietal. In this suture the approximated surfaces are roughened, so as to adhere mechanically to each other.

The *harmonia suture* (*ἄρρω*, to adapt) is the simple apposition of contiguous surfaces, the surfaces being more or less rough and retentive. This suture is seen in the connexion between the superior maxillary bones, or of the palate processes of the palate bones with each other.

The *schindylesis suture* (*σχινδύλησις*, a fissure) is the reception of one bone into a sheath or fissure of another, as occurs in the articulation of the sphenoid with the vomer, or of the latter with the perpendicular lamella of the ethmoid, and with the palate processes of the superior maxillary and palate bones.

The serrated suture is formed by the interlocking of the radiating fibres along the edges of the flat bones of the cranium during growth. When this process is retarded in the infant by over-distention of the head, as in hydrocephalus, and sometimes without any such apparent cause, distinct ossific centres are developed in the interval between the edges; and, being surrounded by the suture, form independent pieces, which are called *ossa triquetra*, or *ossa Wormiana*. In the lambdoidal suture there is generally one or more of these bones; and, in a beautiful adult hydrocephalic skeleton in the possession of Mr. Liston, there are upwards of one hundred.

The *coronal suture* (fig. 24) extends transversely across the vertex of the skull, from the upper part of the greater wing of the sphenoid to the same point on the opposite side; it connects the frontal with the parietal bones. In the formation of this suture the edges of the articulating bones are bevelled, so that the parietal rest upon the frontal at each side, and in the middle the frontal rests upon the parietal bones, so as to afford each other mutual support in the consolidation of the skull.

The *sagittal suture* (fig. 24) extends longitudinally backwards along the vertex of the skull, from the middle of the coronal to the apex of the lambdoidal suture. It is very much serrated, and serves to unite the two parietal bones. Sometimes this suture is continued

through the middle of the frontal bone to the root of the nose, under the name of the frontal suture.

The *lambdoidal suture* is named from some resemblance to the Greek letter Δ , consisting of two branches, which diverge at an acute angle from the extremity of the sagittal suture. This suture connects the occipital with the parietal bones. At the posterior and inferior angle of the parietal bones, the lambdoidal suture is continued onwards in a curved direction into the base of the skull, and serves to unite the occipital bone with the mastoid portion of the temporal, under the name of the *additamentum suturæ lambdoidalis*. It is in the lambdoidal suture that the *ossa triquetra* occur most frequently.

The *squamous suture* (fig. 24) unites the squamous portion of the temporal bone with the greater ala of the sphenoid and with the parietal, overlapping the lower border of the latter. The portion of the suture which is continued backwards from the squamous portion of the bone to the lambdoidal suture, and connects the mastoid portion with the posterior inferior angle of the parietal is the *additamentum suturæ squamosæ*.

Across the upper part of the face is an irregular suture, the *transverse*, which connects the frontal bone with the nasal, superior maxillary, lachrymal, ethmoid, sphenoid, and malar bones. The other sutures are too unimportant to deserve particular names or description.

REGIONS OF THE SKULL.

The skull considered as a whole, is divisible into four regions,—a superior region, or vertex; a lateral region; an inferior region, or base; and an anterior region, the face.

The *superior region*, or vertex of the skull, is bounded anteriorly by the frontal eminences; on each side by the temporal ridge and parietal eminences; and behind by the superior curved line of the occipital bone and occipital protuberance. It is crossed transversely by the coronal suture, and marked from before backwards by the sagittal, which terminates posteriorly in the lambdoidal suture. Near the posterior extremity of the region, and on each side of the sagittal suture, is the parietal foramen. Upon the *inner, or cerebral surface* of this region, is a shallow groove, extending along the middle line from before backwards, for the superior longitudinal sinus; on either side of this groove are several small fossæ for the Pacchionian bodies, and still further outwards numerous ramified markings for lodging the branches of the *arteria meningeæ media*.

The *lateral region* of the skull is divisible into three portions; temporal, mastoid, and zygomatic.

The *temporal portion, or temporal fossa*, is bounded above and behind by the temporal ridge, in front by the external angular process of the frontal bone and by the malar bone, and below by the zygoma. It is formed by part of the frontal, great wing of the

sphenoid, parietal, squamous portion of the temporal, and malar bone, and lodges the temporal muscle.

Fig. 24.

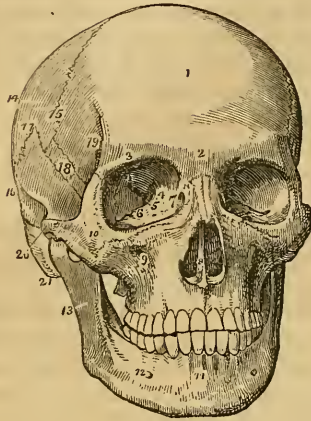
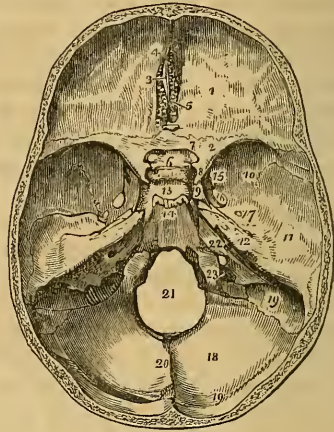


Fig. 25.



The *mastoid portion* is rough, for the attachment of muscles. Upon its posterior part is the mastoid foramen, and below, the mastoid process. In front of the mastoid process is the external auditory foramen, surrounded by the external auditory process; and

Fig. 24. A front view of the skull. 1. The frontal portion of the frontal bone. The 2 immediately over the root of the nose, refers to the nasal tuberosity; the 3 over the orbit, to the supra-orbital ridge. 4. The optic foramen. 5. The sphenoidal fissure. 6. The speno-maxillary fissure. 7. The lachrymal fossa in the lachrymal bone, the commencement of the nasal duct. The figures 4, 5, 6, 7, are within the orbit. 8. The opening of the anterior nares divided into two parts by the vomer; the number is placed upon the latter. 9. The infra-orbital foramen. 10. The malar bone. 11. The symphysis of the lower jaw. 12. The mental foramen. 13. The ramus of the lower jaw. 14. The parietal bone. 15. The coronal suture. 16. The temporal bone. 17. The squamous suture. 18. The upper part of the great ala of the sphenoid bone. 19. The commencement of the temporal ridge. 20. The zygoma of the temporal bone, assisting to form the zygomatic arch. 21. The mastoid process.

Fig. 25. The cerebral surface of the base of the skull. 1. One side of the anterior fossa; the number is placed on the roof of the orbit, formed by the orbital plate of the frontal bone. 2. The lesser wing of the sphenoid. 3. The crista galli. 4. The foramen cœcum. 5. The cribriform lamella of the ethmoid. 6. The processus olivaris. 7. The foramen opticum. 8. The anterior clinoid process. 9. The carotid groove upon the side of the sella Turcica, for the internal carotid artery and cavernous sinus. 10, 11, 12. The middle fossa of the base of the skull. 10. Marks the great ala of the sphenoid. 11. The squamous portion of the temporal bone. 12. The petrous portion of the temporal. 13. The sella Turcica. 14. The basilar portion of the sphenoid bone surmounted by the posterior clinoid processes. 15. The foramen rotundum. 16. The foramen ovale. 17. The foramen spinosum; the small irregular opening between 17. and 12 is the hiatus Fallopii. 18. The posterior fossa of the base of the skull. 19. The groove for the lateral sinus. 20. The ridge upon the occipital bone, which gives attachment to the falx cerebelli. 21. The foramen magnum. 22. The meatus auditorius internus. 23. The jugular foramen.

in front of this foramen the glenoid cavity, bounded above by the middle root of the zygoma, and in front by its tubercle.

The *zygomatic portion*, or *fossa*, is the irregular cavity below the zygoma, bounded in front by the superior maxillary bone, internally by the external pterygoid plate, above by part of the great wing of the sphenoid and squamous portion of the temporal bone, and by the temporal fossa, and externally by the zygomatic arch and ramus of the lower jaw. It contains the external pterygoid, with part of the temporal and internal pterygoid muscle, and the internal maxillary artery and inferior maxillary nerve, with their branches. At the bottom of the zygomatic fossa are two fissures, the sphenomaxillary and the pterygomaxillary.

The *sphenomaxillary fissure* is horizontal in direction, opens into the orbit and is situated between the great ala of the sphenoid and the superior maxillary bone.

The *pterygomaxillary fissure* is vertical, and descends at right angles from the extremity of the preceding. It is situated between the pterygoid process and tuberosity of the superior maxillary bone, and transmits the internal maxillary artery. At the angle of junction of these two fissures is a small cavity, the *sphenomaxillary fossa*, bounded by the sphenoid, palate, and superior maxillary bones, in which are seen the openings of five foramina,—the foramen rotundum, sphenopalatine, pterygopalatine, posterior palatine, and Vidian. It lodges Meckel's ganglion and the termination of the internal maxillary artery.

The *base of the skull* presents an internal or cerebral, and an external or basilar surface.

The *cerebral surface* is divisible into three parts, which are named the anterior, middle, and posterior fossa of the base of the cranium. The *anterior fossa* is somewhat convex on each side, where it corresponds with the roofs of the orbits; and concave in the middle, in the situation of the ethmoid bone, and the anterior part of the body and lesser wings of the sphenoid, which constitute its posterior boundary. It supports the anterior lobes of the cerebrum. In the middle line of this fossa, at its anterior part, is the *crista galli*, immediately in front of this process, the *foramen cæcum*, and on each side the *cribriform plate*, with its *foramina*, for the transmission of the filaments of the olfactory and nasal branch of the ophthalmic nerve. Farther back in the middle line is the *processus olivaris*, and on the sides of this process the *optic foramina*, *anterior clinoid processes*, and vertical *grooves* for the internal carotid arteries.

The *middle fossa* of the base, deeper than the preceding, is bounded in front by the lesser wing of the sphenoid; behind, by the petrous portion of the temporal bone; and is divided into two lateral parts by the sella Turcica. It is formed by the posterior part of the body, great ala, and spinous process of the sphenoid, and by the petrous and squamous portion of the temporal bones. In the centre of this fossa is the *sella Turcica*, which lodges the pituitary gland, bounded in front and behind by the *anterior* and *posterior clinoid*

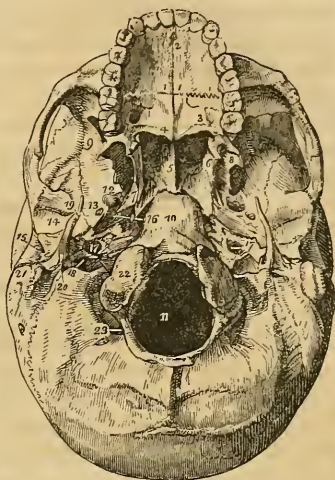
processes. On each side of the sella Turcica is the *carotid groove* for the internal carotid artery, the carotid plexus of nerves, the cavernous sinus, and the orbital nerves, and a little farther outwards the following foramina from before backwards, *sphenoidal fissure* (*foramen lacerum anterius*) for the transmission of the third, fourth, three branches of the ophthalmic division of the fifth, and the sixth nerve, and ophthalmic vein; *foramen rotundum*, for the superior maxillary nerve; *foramen ovale*, for the inferior maxillary nerve, *arteria meningea parva*, and *nervus petrosus superficialis minor*;—*foramen spinosum*, for the *arteria meningea magna*; *foramen lacerum basis cranii*, which gives passage to the internal carotid artery, carotid plexus, and petrosal branch of the Vidian nerve. On the anterior surface of the petrous portion of the temporal bone is a groove, leading to a fissured opening, the *hiatus Fallopii*, for the petrosal branch of the Vidian nerve; and immediately beneath this a smaller foramen, for the *nervus petrosus superficialis minor*. Towards the apex of this portion of bone is the notch for the fifth nerve, and below it a slight depression for the Casserian ganglion. Farther outwards is the eminence which marks the position of the perpendicular semicircular canal. Proceeding from the foramen spinosum are two grooves which mark the course of the trunks of the *arteria meningea media*. The whole fossa lodges the middle lobes of the cerebrum.

The *posterior fossa*, larger than the other two, is formed by the occipital bone, by the petrous and mastoid portion of the temporals, and by a small part of the sphenoid and parietals. It is bounded in front by the upper border of the petrous portion, and by the posterior clinoid processes, and along its posterior circumference by the groove for the lateral sinuses, and gives support to the pons *Varolii*, medulla oblongata, and cerebellum. In the centre of this fossa is the *foramen magnum* bounded on each side by a rough tubercle, which gives attachment to the odontoid ligament, and by the anterior condyloid foramen. In front of the foramen magnum is the concave surface which supports the medulla oblongata and pons *Varolii*, and on each side the following foramina from before backwards. The *internal auditory foramen*, for the auditory and facial nerve and auditory artery; behind, and external to this is a small foramen leading into the *aquæductus vestibuli*; and below it, partly concealed by the edge of the petrous bone, the *aquæductus cochleæ*; next, a long fissure, the *foramen lacerum posterius*, or jugular foramen, giving passage to the commencement of the internal jugular vein and the eighth pair of nerves. Converging towards this foramen from behind is the deep groove for the lateral sinus, and from the front the groove for the inferior petrosal sinus.

Behind the foramen magnum is a longitudinal ridge, which gives attachment to the falx cerebelli, and divides the two inferior fossæ of the occipital bone; and above the ridge is the elevation corresponding with the tubercle of the occipital bone and the transverse groove lodging the lateral sinus.

The *external surface* of the base of the skull is extremely irregular. From before backwards it is formed by the palate processes of the superior maxillary and palate bones; the vomer; the pterygoid, spinous processes, and part of the body of the sphenoid; under surface of the squamous portion, and mastoid portion of the temporals; and by the occipital bone.

Fig. 26.



The palate processes of the superior maxillary and palate bones constitute the hard palate, which is raised above the level of the rest of the base, and is surrounded by the alveolar processes containing the teeth of the upper jaw. At the anterior extremity of the hard palate, and directly behind the front incisor teeth, is the *incisive foramen*, the termination of the nasopalatine canal, which contains the nasopalatine ganglion, and transmits the anterior palatine nerves. At the posterior angles of the palate are the *posterior palatine foramina*, for the posterior palatine nerves and arteries. Passing inwards from these foramina are the *transverse ridges* to which are attached the expansions of the tensor palati muscles, and at the middle line of the posterior border the *palate spine* which gives origin to the azygos uvulæ. The hard palate is marked by a crucial suture, which distinguishes the four processes of which it is composed. Behind, and above the hard palate, are the *posterior nares*, separated by the vomer, and bounded on each side by the pterygoid processes. At the base of the vomer, and partly formed by its expansion, are the *pterygo-palatine canals*. The internal pterygoid plate is long and narrow, terminated at its apex by the hamular process, and at its base by the scaphoid fossa. The external plate is broad, and the space between the two is the pterygoid fossa, which contains part of the internal pterygoid muscle and the tensor palati. Externally to the external pterygoid

Fig. 26. The external or basilar surface of the base of the skull. 1, 1, the hard palate. The figures are placed upon the palate processes of the superior maxillary bones. 2. The incisive, or anterior palatine foramen. 3. The palate process of the palate bone. The large opening near the figure is the posterior palatine foramen. 4. The palate spine; the curved line upon which the number rests, is the transverse ridge. 5. The vomer, dividing the openings of the posterior nares. 6. The internal pterygoid plate. 7. The scaphoid fossa. 8. The external pterygoid plate. The interval between 6 and 8, (left side of the figure,) is the pterygoid fossa. 9. The zygomatic fossa. 10. The basilar process of the occipital bone. 11. The foramen magnum. 12. The foramen ovale. 13. The foramen spinosum. 14. The glenoid fossa. 15. The meatus auditorius externus. 16. The foramen lacerum basis cranii. 17. The carotid foramen of the left side. 18. The foramen lacerum posterioris, or jugular foramen. 19. The styloid process. 20. The stylo-mastoid foramen. 21. The mastoid process. 22. One of the condyles of the occipital bone. 23. The posterior condyloid foramen.

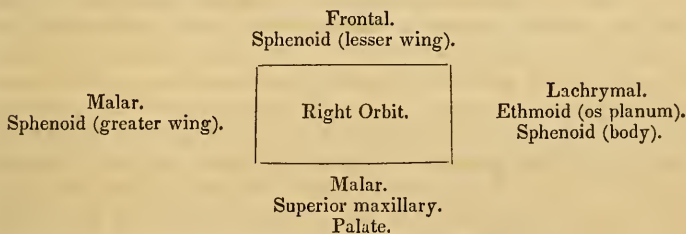
is the zygomatic fossa. Behind the nasal fossæ, in the middle line, is the under surface of the body of the sphenoid, and the basilar process of the occipital bone, and still further back, the foramen magnum. At the base of the external pterygoid plate, on each side, is the *foramen ovale*, and behind this the *foramen spinosum*, with the prominent spine which gives attachment to the internal lateral ligament of the lower jaw and the laxator tympani muscle. Running outwards from the apex of the spinous process of the sphenoid bone, is the fissura Glaseri, which crosses the glenoid fossa transversely, and divides it into an anterior smooth surface, bounded by the eminentia articularis, for the condyle of the lower jaw, and a posterior rough surface for a part of the parotid gland. Behind the foramen ovale and spinosum, is the irregular fissure between the spinous process of the sphenoid bone and the petrous portion of the temporal, the foramen lacerum basis cranii, which lodges the internal carotid artery and Eustachian tube, and in which the carotid branch of the Vidian nerve joins the carotid plexus. Following the direction of this fissure outwards is the foramen for the Eustachian tube, and that for the tensor tympani muscle, separated from each other by the processus cochleariformis. Behind the fissure is the pointed process of the petrous bone which gives origin to the levator palati muscle, and, externally to this process, the carotid foramen for the transmission of the internal carotid artery and the ascending branch of the superior cervical ganglion of the sympathetic; and behind the carotid foramen, the foramen lacerum posterius and jugular fossa. Externally, and somewhat in front of the latter, is the styloid process, and at its base the vaginal process. Behind and at the root of the styloid process is the stylo-mastoid foramen, for the facial nerve and stylo-mastoid artery, and further outwards the mastoid process. Upon the inner side of the root of the mastoid process is the digastric fossa; and a little farther internally, the occipital groove. On either side of the foramen magnum, and near to its anterior circumference, are the condyles of the occipital bone. In front of each condyle, and piercing its base, is the anterior condyloid foramen, and directly behind the condyle the irregular fossa in which the posterior condyloid foramen is situated. Behind the foramen magnum are the two curved lines of the occipital bone, the spine, and protuberance, with the rough surfaces for the attachment of muscles.

The *Face* is somewhat oval in contour, irregular in surface, and excavated for the reception of two principal organs of sense,—the eye and the nose. It is formed by part of the frontal bone and by the bones of the face. Superiorly it is bounded by the frontal eminences; beneath these are the superciliary ridges, converging towards the nasal tuberosity; beneath the superciliary ridges are the supra-orbital ridges, terminating externally in the external border of the orbit, and internally in the internal border, and presenting towards their inner third the supra-orbital notch, for the supra-orbital nerve and artery. Beneath the supra-orbital ridges are the openings of the orbits. Between the orbits is the bridge of

the nose, overarching the anterior nares; and on each side of this opening the canine fossa of the superior maxillary bone and the infra-orbital foramen, and still farther outwards the prominence of the malar bone; at the lower margin of the anterior nares is the nasal spine, and beneath this the superior alveolar arch containing the teeth of the upper jaw. Forming the lower boundary of the face is the lower jaw, containing in its alveolar process the lower teeth, and projecting inferiorly to form the chin; on either side of the chin is the mental foramen. If a perpendicular line be drawn from the inner third of the supra-orbital ridge to the inner third of the body of the lower jaw, it will be found to intersect three openings;—the supra-orbital, infra-orbital, and mental, each giving passage to one of the facial branches of the fifth nerve.

ORBITS.

The *orbits* are two quadrilateral hollow cones, situated in the upper part of the face, and intended for the reception of the eyeballs, with their muscles, vessels and nerves, and the lachrymal glands. The central axis of each orbit is directed outwards, so that the axes of the two continued into the skull through the optic foramina, would intersect over the middle of the sella Turcica.* The *superior boundary* of the orbit is formed by the orbital plate of the frontal bone, and by part of the lesser wing of the sphenoid; the *inferior*, by part of the malar bone and by the orbital processes of the superior maxillary and palate bone; the *internal* by the lachrymal bone, the os planum of the ethmoid and part of the body of the sphenoid; and the *external*, by the orbital process of the malar bone and the great ala of the sphenoid; these may be expressed more clearly in a tabular form:



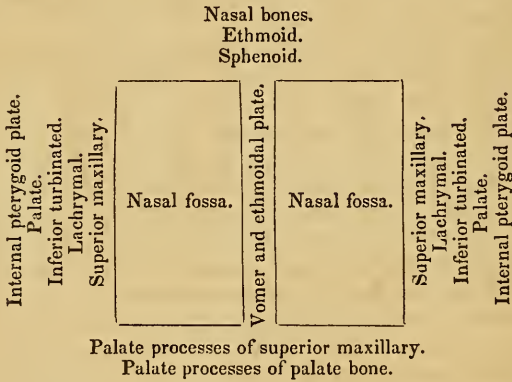
There are *nine* openings communicating with the orbit:—the *optic*, for the admission of the optic nerve and ophthalmic artery; the *sphenoidal fissure*, for the transmission of the third, fourth, the three branches of the ophthalmic division of the fifth, and the sixth nerve, and the ophthalmic vein; the *spheno-maxillary fissure*, for the passage of the superior maxillary nerve and artery to the opening of entrance of the *infra-orbital canal*; *temporo-malar foramina*—two or three small openings in the orbital process of the malar

* The axes of the orbits form an angle of 90° with each other.—G.

bone, for the passage of filaments of the orbital branch of the superior maxillary nerve; *anterior* and *posterior ethmoidal foramina* in the suture between the os planum and frontal bone, the former transmitting the nasal nerve and anterior ethmoidal artery and the latter the posterior ethmoidal artery and vein; the opening of the *nasal duct*; and the *supra-orbital notch* or foramen, for the supra-orbital nerve and artery.

NASAL FOSSÆ.

The nasal fossæ are two irregular cavities, situated in the middle of the face, and extending from before backwards. They are bounded *above* by the nasal bones, ethmoid, and sphenoid; *below* by the palate processes of the superior maxillary and palate bones; *externally* by the superior maxillary, lachrymal, inferior turbinated, ethmoid, palate, and internal pterygoid plate of the sphenoid; and the two fossæ are separated by the vomer and the perpendicular lamella of the ethmoid. These may be more clearly expressed in a tabular form :

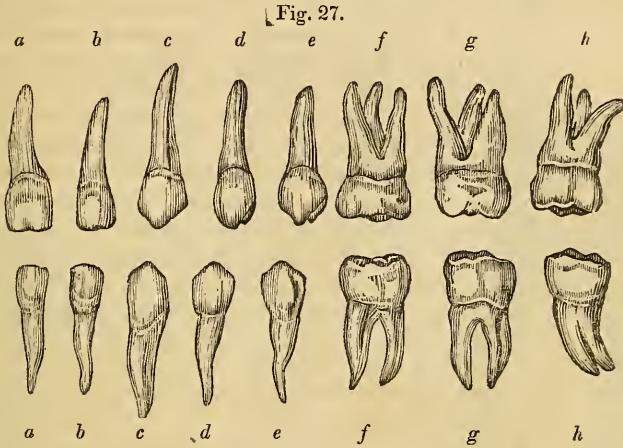

Each nasal fossa is divided into three irregular longitudinal passages, or *meatuses* by three processes of bone, which project from its outer wall,—the superior, middle, and inferior turbinated bones; the superior and middle turbinated bones being processes of the ethmoid, and the inferior a distinct bone of the face. The *superior meatus* occupies the superior and posterior part of each fossa; it is situated between the superior and middle turbinated bones, and has opening into it three foramina, viz. the opening of the posterior ethmoid cells, the opening of the sphenoid cells, and the sphenopalatine foramen. The *middle meatus* is the space between the middle and inferior turbinated bones; it also presents three foramina,—the opening of the frontal sinuses, of the anterior ethmoid cells, and of the antrum. The largest of the three passages is the *inferior meatus*, which is the space between the inferior turbinated bone and the floor of the fossa; in it there are two foramina,—the

termination of the nasal duct, and the opening of the naso-palatine canal. The nasal fossæ commence upon the face by a large irregular opening,—the anterior nares,—and terminate posteriorly in the two posterior nares.

T E E T H .

Man is provided with two successions of teeth; the first are the teeth of childhood, they are called temporary or deciduous; the second continue until old age, and are named permanent.



The *permanent teeth* are thirty-two in number, sixteen in each jaw; they are divisible into four classes,—*incisors*, of which there are four in each jaw, two central and two lateral; *canine*, two above and two below; *bicuspid*, four above and four below; and *molars*, six above and six below.

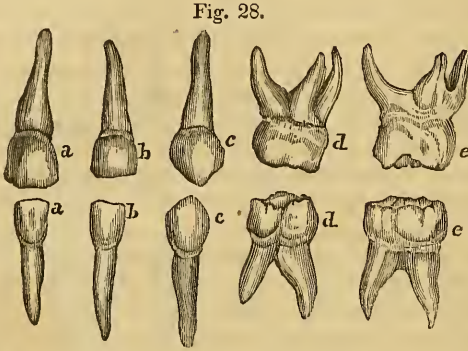
The *temporary teeth* are twenty in number (fig. 28); eight incisors, four canine, and eight molars. The temporary molars have four tubercles, and are succeeded by the permanent bicuspides, which have only two tubercles.

Each tooth is divisible into a *crown*, which is the part apparent above the gum; a constricted portion around the base of the crown, the *neck*; and a *root* or *fung*, which is contained within the alveolus. The root is invested by periosteum, which lines the alveolus, and is then reflected upon the root of the tooth as far as its neck.

The *incisor teeth* (cutting teeth) are named from presenting a sharp and cutting edge, formed at the expense of the posterior surface. The crown is flattened from before backwards, being some-

Fig. 27. Permanent teeth. *a*. Central incisor. *b*. Lateral incisor. *c*. Cuspid or canine. *d*. First bicuspid. *e*. Second bicuspid. *f*. First molar. *g*. Second molar. *h*. Third molar or *dens sapientie*.

what convex in front and concave behind; the neck is considerably constricted, and the root compressed from side to side; at its apex is a small opening for the passage of the nerve and artery of the tooth.



The *canine teeth* (*cuspidati*) follow the incisors in order from before backwards; two are situated in the upper jaw, one on each side, and two in the lower. The crown is larger than that of the incisors, convex before, and concave behind, and tapering to a blunted point. The root is longer than that of all the other teeth, compressed at each side, and marked by a slight groove.

The *bicuspid teeth* (small molars), two on each side in each jaw, follow the canine, and are intermediate in size between them and the molars. The crown is compressed from before backwards, and surmounted by two tubercles, one internal, the other external; the neck is oval; the root compressed, and marked on each side by a deep groove, and bifid near its apex. The teeth of the upper jaw have a greater tendency to the division of their roots than those of the lower, and the posterior than the anterior pair.

The *molar teeth* (grinders,) three on each side in each jaw, are the largest of the permanent set. The crown is quadrilateral, and surmounted by four tubercles, the neck large and round, and the root divided into several fangs. In the upper jaw the first and second molar teeth have three roots, sometimes four, which are more or less widely separated from each other, two of the roots being external, the other internal. In the lower there are but two roots, which are anterior and posterior; they are flattened from behind forwards, and grooved so as to mark a tendency to division. The third molars, or *dentes sapientiæ*, are smaller than the other two; they present three tubercles on the surface of the crown; and the root is single and grooved, appearing to be made up of four or five fangs compressed together, or partially divided. In the

Fig. 28. Temporary teeth. a. Central incisor. b. Lateral incisor. c. Canine. d. First molar. e. Second molar.

lower jaw the fangs are frequently separated to some distance from each other, and much curved, so as to offer considerable resistance in the operation of extraction.*

Structure.†—The base of the crown of each tooth is hollowed into a small cavity, which is continuous with a canal passing through the middle of each fang. The cavity and canal, or canals, constitute the *cavitas pulpæ*, and contain a soft and secreting vascular organ,—the *pulp*, which receives its supply of vessels and nerves through the small opening at the apex of each root.

The tooth is composed of three distinct structures; the ivory or tooth-bone, enamel, and a cortical substance or cementum. The *ivory* consists of microscopic undulating and branching tubuli, which open by their larger extremities upon the walls of the *cavitas pulpæ* and radiate towards the surface of the ivory, where they terminate in ramifications of infinite minuteness. These tubuli have distinct walls, are separated from each other by intervals equal in breadth to the diameter of two or three tubes, and composed of dense dental substance, and they contain within their cylinders a calcareous substance disposed in irregular masses.‡ As the growth of the tooth takes place from the surface towards the centre, the most minute ramifications are first formed, and the trunks of the tubuli are the last deposited.

The *enamel* forms a crust over the whole exposed surface of the crown of the tooth to the commencement of its root; it is thickest over the upper part of the crown, and becomes gradually thinner as it approaches the neck. It is composed of minute hexagonal crystalline fibres, resting by one extremity against the surface of the ivory, and constituting by the other the free surface of the crown. The enamel is separated from the ivory by a thin layer of membrane, continuous with a thin organic sheath which encloses each enamel fibre, and marks it by means of trans-

Fig. 29.

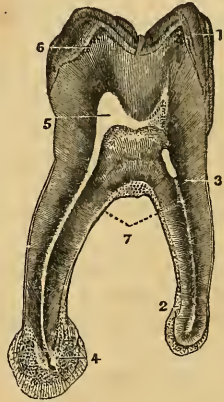


Fig. 29. Microscopic section of a molar tooth. 1. Enamel with its columns and laminated structure. 2. Cortical substance or cementum on the outside of the fang. 3. Ivory, showing tubuli. 4. Foramen entering the dental cavity from the end of the fang. This fang has a bulbous enlargement in consequence of a hypertrophy of the cementum. 5. Dental cavity. 6. A few osseous corpuscles in the ivory just under the enamel.

* See a valuable little practical work, "On the Structure, Economy, and Pathology of the Teeth," by Mr. Lintott.

† The structure of the teeth was discovered by Purkinje and Retzius, and has been farther prosecuted in this country by Mr. Nasmyth, to whose beautiful work, "Researches on the Development, Structure and Diseases of the Teeth," I must refer those who may feel interested in this important subject.

‡ The disintegrated condition of the calcareous substance is probably the effect of desiccation; it is very remarkable in decayed teeth.

verse lines into irregular divisions. Mr. Nasmyth is of opinion, that the enamel is invested by a thin layer of membrane, which is continued over the root, and is reflected through the opening in the apex of the fang into the *cavitas pulpæ*, which it lines throughout. This membrane is considered by Mr. Nasmyth to be the "*persistent dental capsule*."

The *cortical substance*, or *cementum*, forms a thin coating over the root of the tooth, from the termination of the enamel to the opening of the apex of the fang. In structure it consists of true bone, characterized by the existence of numerous calcigerous cells and tubuli. The *cementum* increases in thickness with the advance of age, and gives rise to those exostosed appearances occasionally seen in the teeth of very old persons, or in those who have taken much mercury. In old age the *cavitas pulpæ* is often found filled up and obliterated by osseous substance analogous to the *cementum*.

Development.—The development of the teeth in the human subject has been most successfully investigated by our countryman, Mr. Goodsir, to whose interesting researches I am indebted for the following narrative:*

The inquiries of Mr. Goodsir commenced as early as the sixth week after conception, in an embryo, which measured seven lines and a half in length and weighed fifteen grains. At this early period each jaw presents two semicircular folds around its circumference; the most external is the true lip; the internal, the rudiment of the palate; and between these is a deep groove, lined by the common mucous membrane of the mouth. A little later a ridge is developed from the floor of this groove in a direction from behind forwards, this is the rudiment of the external alveolus; and the arrangement of the appearances from without inwards at this period is the following:—Most externally, and forming the boundary of the mouth, is the *lip*; next we find a *deep groove*, which separates the lip from the future jaw; then comes the *external alveolar ridge*; fourthly, another groove, in which the germs of the teeth are developed, the *primitive dental groove*; fifthly, a rudiment of the *internal alveolar ridge*; and sixthly, the rudiment of the *future palate* bounding the whole internally. At the seventh week the germ of the first deciduous molar of the upper jaw has made its appearance, in the form of a "simple, free, granular papilla" of the mucous membrane, projecting from the floor of the primitive dental groove; at the eighth week, the papilla of the canine tooth is developed; at the ninth week the papillæ of the four incisors (the middle preceding the lateral) appear; and at the tenth week, the papilla of the second molar is seen behind the anterior molar in the primitive dental groove. So that at this early period, the tenth week, the papillæ or germs of the whole of the ten deci-

* "On the Origin and Development of the Pulpæ and Sacs of the Human Teeth," by John Goodsir, jun., in the *Edinburgh Medical and Surgical Journal*, January 1839.

duous teeth of the upper jaw are quite distinct. Those of the lower jaw are a little more tardy; the papilla of the first molar is merely a slight bulging at the seventh week, and the tenth papilla is not apparent until the eleventh week.

From about the eighth week the primitive dental groove becomes contracted before and behind the first deciduous molar, and laminae of the mucous membrane are developed around the other papillæ, which increase in growth and enclose the papillæ in follicles with open mouths. At the tenth week the follicle of the first molar is completed, then that of the canine; during the eleventh and twelfth weeks the follicles of the incisors succeed, and at the thirteenth week the follicle of the posterior deciduous molar.

During the thirteenth week the papillæ undergo an alteration of form, and assume the shape of the teeth they are intended to represent. And at the same time small membranous processes are developed from the mouths of the follicles; these processes are intended to serve the purpose of opercula to the follicles, and they correspond in shape with the form of the crowns of their appertaining teeth. To the follicles of the incisor teeth there are two opercula; to the canine, three; and to the molars a number relative to the number of their tubercles, either four or five. During the fourteenth and fifteenth weeks the opercula have completely closed the follicles, so as to convert them into *dental sacs*, and at the same time the papillæ have become *pulps*.

The deep portion of the primitive dental groove, viz. that which contains the dental sacs of the deciduous teeth, being thus closed in, the remaining portion, that which is nearer the surface of the gum, is still left open, and to this Mr. Goodsir has given the title of *secondary dental groove*; as it serves for the developement of all the permanent teeth, with the exception of the anterior molars. During the fourteenth and fifteenth weeks small lunated inflexions of the mucous membrane are formed, immediately to the inner side of the closing opercula of the deciduous dental follicles, commencing behind the incisors and proceeding onwards through the rest; these are the rudiments of the follicles or *cavities of reserve* of the four permanent incisors, two permanent canines, and the four bicuspides. As the secondary dental groove gradually closes, these follicular inflexions of the mucous membrane are converted into closed *cavities of reserve*, which recede from the surface of the gum and lie immediately to the inner side and in close contact with the dental sacs of the deciduous teeth, being enclosed in their submucous cellular tissue. At about the fifth month the anterior of these cavities of reserve dilate at their distal extremities, and a fold or papilla projects into their fundus, constituting the rudiment of the germ of the permanent tooth; at the same time two small opercular folds are produced at their proximal or small extremities, and convert them into true dental sacs.

During the fifth month the posterior part of the primitive dental groove behind the sac of the last deciduous tooth has remained

open, and in it has developed the papilla and follicle of the first permanent molar. Upon the closure of this follicle by its opercula, the secondary dental groove upon the summit of its crown forms a large cavity of reserve, lying in contact with the dental sac upon the one side and with the gum upon the superficial side. At this period the deciduous teeth, and the sacs of the ten anterior permanent teeth, increase so much in size, without a corresponding lengthening of the jaws, that the first permanent molars are gradually pressed backwards and upwards into the maxillary tuberosity in the upper jaw, and into the base of the coronoid process of the lower jaw; a position which they occupy at the eighth and ninth months of fetal life. In the infant of seven or eight months the jaws have grown in length, and the first permanent molar returns to its proper position in the dental range. The cavity of reserve, which had been previously elongated by the upward movement of the first permanent molar, now dilates into the cavity which that tooth has just quitted; a papilla is developed from its fundus, the cavity becomes constricted, and the dental sac of the second molar tooth is formed, still leaving a portion of the great cavity of reserve in connexion with the superficial side of the sac. As the jaws continue to grow in length, the second permanent dental sac descends from its elevated position and advances forwards into the dental range, following the same curve with the first permanent molar. The remainder of the cavity of reserve, already lengthened backwards by the previous position of the second molar, again dilates for the last time, develops a papilla and sac in the same manner with the preceding, and forms the third permanent molar or wisdom tooth, which, at the age of nineteen or twenty, upon the increased growth of the jaw, follows the course of the first and second molars into the dental range.

From a consideration of the foregoing phenomena, Mr. Goodsir has divided the process of dentition into three natural stages:—1, follicular; 2, saccular; 3, eruptive. The first, or *follicular stage*, he makes to include all the changes which take place from the first appearance of the dental groove and papillæ to the closure of their follicles; occupying a period which extends from the sixth week to the fourth or fifth month of intra-uterine existence. The second, or *saccular stage*, comprises the period when the follicles are shut sacs, and the included papillæ, pulps; it commences at the fourth and fifth months of intra-uterine existence, and terminates for the median incisors, at the seventh or eighth month of infantile life, and for the wisdom teeth at about the twenty-first year. The third, or *eruptive stage*, includes the completion of the teeth, the eruption and shedding of the temporary set; the eruption of the permanent, and the necessary changes in the alveolar processes. It extends from the seventh month till the twenty-first year.

“The *anterior permanent molar*,” says Mr. Goodsir, “is the most remarkable tooth in man, as it forms a transition between the milk and the permanent set.” If considered anatomically, *i. e.* in its

development from the primitive dental groove, by a papilla and follicle, "it is decidedly a milk tooth;" if physiologically, "as the most efficient grinder in the adult mouth, we must consider it a permanent tooth." "It is a curious circumstance, and one which will readily suggest itself to the surgeon, that laying out of view the wisdom teeth, which sometimes decay at an early period from other causes, the anterior molars are the permanent teeth which most frequently give way first, and in the most symmetrical manner and at the same time, and frequently before the milk set."

Growth of Teeth.—Immediately that the dental follicles have been closed by their opercula, the pulps become moulded into the form of the future teeth; and the bases of the molars divided into two or three portions, representing the future fangs. The dental sac is composed of two layers, an internal or vascular layer, which was originally a part of the mucous surface of the mouth, and a cellulofibrous layer, analogous to the corium of the mucous membrane. Upon the formation of this sac by the closure of the follicle, the mucous membrane resembles a serous membrane in being a shut sac, and may be considered as consisting of a tunica propria, which invests the pulp; and a tunica reflexa, which is adherent by its outer surface with the structures in the jaw, and by the inner surface is free, being separated from the pulp by an intervening cavity. As soon as the moulding of the pulp has commenced, this cavity increases and becomes filled with a gelatinous granular substance, the *enamel organ*, which is adherent to the whole internal surface of the tunica reflexa, but not to the tunica propria and pulp. At the same period, viz., during the fourth or fifth month, a thin lamina of ivory is secreted by the pulp, and deposited upon its most prominent point: if the tooth be incisor or canine, the secreted layer has the form of a small hollow cone; if molar, there will be four or five small cones corresponding with the number of tubercles on its crown. These cones are united by the secretion of additional layers, the pulp becomes gradually surrounded and diminishes in size, depositing fresh layers during its retreat into the jaws until the entire tooth with its fangs is completed, and the small *cavitas pulpæ* of the perfect tooth alone remains, communicating through the opening in the apex of each fang with the dental vessels and nerves. The number of roots appears to depend upon the number of nervous filaments sent to each pulp. When the secretion of the ivory has commenced, the enamel organ becomes transformed into a laminated tissue, corresponding with the direction of the fibres of the enamel, and the

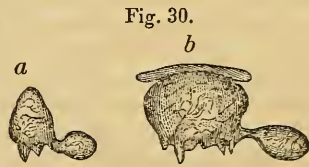


Fig. 30.

Fig. 30. *a.* Capsule of a temporary incisor with the rudiment of the corresponding permanent tooth attached. *b.* Capsule of a molar in the same state. A part of the gum is seen above it and in contact.

crystalline substance of the enamel is secreted into its meshes by the vascular lining of the sac.

The *cementum* appears to be formed at a later period of life, either by a deposition of osseous substance by that portion of the dental sac which continues to enclose the fang, and acts as its periosteum, or by the conversion of that membrane itself into bone; the former supposition is the more probable.

The secretion of ivory commences in the first permanent molar previously to birth.

Eruption.—When the crown of the tooth has been formed and coated with enamel, and the fang has grown to the bottom of its socket by the progressive lengthening of the pulp, the deposition of ivory, and the adhesion of the ivory to the contiguous portion of the sac, the pressure of the socket causes the reflected portion of the sac and the edge of the tooth to approach, and the latter to pass through the gum. The sac has thereby resumed* its original follicular condition, and has become continuous with the mucous membrane of the mouth. The opened sac now begins to shorten more rapidly than the fang lengthens, and the tooth is quickly drawn upwards by the contraction, leaving a space between the extremity of the unfinished root and the bottom of the socket, in which the growth and completion of the fang is more speedily effected.

During the changes which have here been described as taking place among the dental sacs contained within the jaws, the septa between the sacs, which at first were composed of spongy tissue, soon became fibrous, and were afterwards formed of bone, which was developed from the surface and proceeded by degrees more deeply into the jaws, to constitute the alveoli. The sacs of the ten anterior permanent teeth, at first enclosed in the submucous cellular tissue of the deciduous dental sacs, and received during their growth into crypts situated behind the deciduous teeth, advanced by degrees beneath the fangs of those teeth, and became separated from them by distinct osseous alveoli. The necks of the sacs of the permanent teeth, by which they originally communicated with the mucous lining of the secondary groove, still exist, in the form of minute ob-

Fig. 31.



literated cords, separated from the deciduous teeth by their alveolus, but communicating through a minute osseous canal with the fibrous tissue of the palate, immediately behind the corresponding deciduous teeth. "These cords and foramina are not obliterated in the child," says Mr. Goodsir, "either because the cords are to become useful as '*gubernacula*,' and the canals as '*itineria dentium*;' or, much more probably, in virtue of a law, which appears to be a general one in the development of animal bodies, viz. : *that parts, or organs,*

Fig. 31. Temporary tooth with the capsule of its permanent successor attached to it by the gubernaculum dentis.

* Mr. Nasmyth is of opinion that it is by "a process of absorption, and not of disruption, that the tooth is emancipated." *Medico-chirurgical Transactions.* 1839.

which have once acted an important part, however atrophied they may afterwards become, yet never altogether disappear, so long as they do not interfere with other parts or functions."

Succession.—The periods of appearance of the teeth are extremely irregular; it is necessary, therefore, to have recourse to an average, which, for the temporary teeth, may be stated as follows, the teeth of the lower jaw preceding those of the upper by a short interval:

7th month, two middle incisors. 18th month, canine.
9th month, two lateral incisors. 24th month, two last molares.
12th month, first molares.

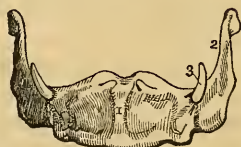The periods for the permanent teeth are,

6½ year, first molares. 10th year, second bicuspides.
7th year, two middle incisors. 11th to 12th year, canine.
8th year, two lateral incisors. 12th to 13th year, second molares.
9th year, first bicuspides. 17th to 21st year, last molares.

OS HYOIDES.

The *os hyoides* forms the second arch developed from the cranium, and gives support to the tongue, and attachment to numerous muscles in the neck. It is named from its resemblance to the Greek letter ν , and consists of a central portion, or body, of two larger cornua, which project backwards from the body, and two lesser cornua, which ascend from the angles of union between the body and the greater cornua.

Fig. 32.



The body is somewhat quadrilateral, rough and convex on its anterior surface, where it gives attachment to muscles; concave and smooth on the posterior surface, by which it lies in contact with the epiglottis. The greater cornua are flattened from above downwards, and terminated posteriorly in a tubercle; and the lesser cornua, conical in form, give attachment to the stylo-hyoid ligaments. In early age and in the adult, the cornua are connected with the body by cartilaginous surfaces and ligamentous fibres; but in old age they become united by bone.

Development.—By five centres, one for the body, and one for each cornu.

Attachment of Muscles.—To eleven pairs; sterno-hyoid, thyro-hyoid, omo-hyoid, pulley of the digastricus, stylo-hyoid, mylo-hyoid, genio-hyoid, genio-hyo-glossus, hyo-glossus, lingualis, and middle constrictor of the pharynx. It also gives attachment to the stylo-hyoid, thyro-hyoid, and hyo-epiglottic ligaments, and to the thyrohyoidean membrane.

Fig. 32. The *os hyoides* seen from before. 1. The anterior convex side of the body. 2. The great cornu of the left side. 3. The lesser cornu of the same side. The cornua were ossified to the body of the bone in the specimen from which this figure was drawn.

THORAX AND UPPER EXTREMITY.

The bones of the thorax are the sternum and ribs; and, of the upper extremity, the clavicle, scapula, humerus, ulna, and radius, bones of the carpus, metacarpus, and phalanges.

STERNUM.—The sternum (fig. 33) is situated in the middle line of the front of the chest; it is flat, or slightly concave in front, and convex behind; broad and thick above, and flattened and pointed below. It consists of three pieces; superior, middle, and inferior.

The *superior* (1) is nearly quadrilateral; broad and thick above, and somewhat narrowed at its junction with the middle piece. At each superior angle is a deep articular depression for the clavicle, and on either side two notches, for the articulation of the cartilage of the first rib, and one half of the second.

The *middle piece* (2), considerably longer than the superior, is broad in the middle, and somewhat narrower at each extremity. It presents on each side six articular notches, for the lower half of the second rib, the four next ribs, and the upper half of the seventh.

The *inferior piece*, or *ensiform cartilage* (3), is the smallest of the three, often merely cartilaginous, and very various in appearance, being sometimes pointed, at other times broad and thin, and at other times again, perforated by a round hole, or bifid. It presents a notch at each side for the articulation of the lower half of the cartilage of the seventh rib.

Developement.—By a number of centres, varying from six to fourteen.

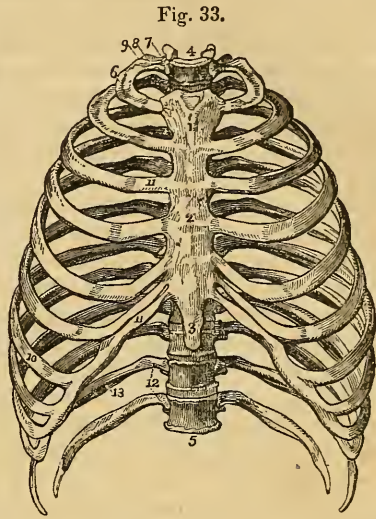
Articulations.—With *sixteen* bones; viz. with the clavicle, and with seven true ribs at each side.

Attachment of Muscles.—To *nine* pairs and one single muscle; viz. to the pectoralis major, sterno-mastoid, sterno-hyoid, sterno-thyroid, triangularis sterni, aponeurosis of the obliquus externus, internus, and transversalis muscles, rectus, and diaphragm.

RIBS.—The ribs are twelve in number at each side; the seven first are connected with the sternum, and hence named *true*; the remaining five are the *false* ribs; and the two last shorter than the rest, and free at their extremities, are the *floating* ribs. The ribs increase in length from the first to the eighth, whence they again diminish to the twelfth; in breadth they diminish gradually from the first to the last. Each rib presents an external and internal surface, a superior and inferior border, and two extremities; it is curved to correspond with the arch of the thorax, and twisted upon itself, so that when laid upon its side, one end is tilted up, while the other rests upon the surface.

The *external surface* is convex, and marked by the attachment of muscles; the *internal* is flat, and corresponds with the pleura; the *superior border* is rounded; and the *inferior* sharp and grooved upon its inner side, for the attachment of the intercostal muscles. Near its vertebral extremity, the rib is suddenly bent upon itself; and opposite the bend, upon the external surface, is a rough oblique

ridge, which gives attachment to a tendon of the sacro-lumbalis muscle, and is called the *angle*. The distance between the vertebral extremity and the angle increases gradually, from the second to the eleventh rib. Beyond the angle is a rough elevation, the *tuberosity*; and immediately at the base and rather below the tuberosity a smooth surface for articulation with the extremity of the transverse process of the corresponding vertebra. Beyond the tuberosity is the *neck*; and at the extremity of the neck an oval surface, the *head*, divided by a ridge into two facets for articulation with two contiguous vertebræ. The posterior surface of the neck is rough, for the attachment of the middle costo-transverse ligament; and upon its upper border is a crest, which gives attachment to the anterior costo-transverse ligament. The sternal extremity is flattened, and presents an oval depression, into which the costal cartilage is received.



The ribs that demand especial consideration are the first, and the three last.

The *first* is the shortest rib; it is broad and flat, and placed horizontally at the upper part of the thorax, the surfaces looking upwards and downwards, in place of forwards and backwards as in the other ribs. At about the anterior third of the upper surface of the bone, and near its internal border, is a tubercle which gives attachment to the scalenus anticus muscle, and immediately before and behind this tubercle, a shallow oblique groove, the former for the subclavian vein, and the latter for the subclavian artery. Near the posterior extremity of the bone is a thick and prominent tuberosity, with a smooth articular surface for the transverse process of the first dorsal vertebra. There is no angle. Beyond the tuberosity is a narrow constricted neck; and quite at the extremity, a head, presenting a single articular surface. The second rib approaches in some of its characters to the first.

Fig. 33. An anterior view of the thorax. 1. The superior piece of the sternum 2. The middle piece. 3. The inferior piece, or ensiform cartilage. 4. The first dorsal vertebra. 5. The last dorsal vertebra. 6. The first rib. 7. Its head. 8. Its neck. 9. Its tuberosity. 10. The seventh or last true rib. 11. The costal cartilages of the true ribs. 12. The two last false ribs—the floating ribs. 13. The groove along the lower border of the rib for the lodgment of the intercostal vessels and nerve.

The *tenth* rib has a single articular surface on its head.

The *eleventh* and *twelfth* have each a single articular surface on the head, no neck or tuberosity, and are pointed at the extremity. The eleventh has a slight ridge, representing the angle, and a shallow groove on the lower border; the twelfth has neither.

COSTAL CARTILAGES.—The costal cartilages (fig. 33. 11, 11) serve to prolong the ribs forwards to the anterior part of the chest, and contribute mainly to the elasticity of the thorax. They are broad at their attachment to the ribs, and taper slightly towards their opposite extremities; they gradually diminish in breadth from the first to the last, and increase in length from the first to the seventh, and then diminish to the last.

The seven first cartilages articulate with the sternum; the three next with the lower border of the cartilage immediately preceding. All the cartilages of the false ribs terminate by pointed extremities.

Development—The ribs are developed by *three* centres; one for the central part, one for the head, and one for the tuberosity. The two last have only one centre.

Articulations.—Each rib articulates with two vertebræ, and one costal cartilage, with exception of the first, tenth, eleventh, and twelfth, which articulate each with a single vertebra only.

Attachment of Muscles.—To the ribs and their cartilages are attached *twenty-two* pairs, and *one* single muscle. To the *cartilages*, the subclavius, sterno-thyroid, pectoralis major, internal oblique, rectus, transversalis, diaphragm, triangularis sterni, internal and external intercostals. To the *ribs*, the intercostal muscles, scalenus anticus, scalenus posticus, pectoralis minor, serratus magnus, obliquus externus, obliquus internus, latissimus dorsi, quadratus lumborum, serratus posticus superior, serratus posticus inferior, sacrolumbalis, longissimus dorsi, cervicalis ascendens, levatores costarum, transversalis, and diaphragm.

CLAVICLE.—The clavicle is a long bone shaped somewhat like the italic letter *S*, the convexity at one end being anterior and internal, at the other posterior and external. The inner half of the bone is rounded or irregularly quadrilateral, and terminates in a broad articular surface. The outer half is flattened from above downwards, and broad at its extremity, the articular surface occupying only part of its extent. The upper surface is smooth and convex, and partly subcutaneous; while the under surface is rough and depressed, for the insertion of the subclavius muscle. At the sternal extremity of the under surface is a very rough prominence, which gives attachment to the rhomboid ligament; and at the other extremity a rough tubercle and ridge, for the coraco-clavicular ligament. The opening for the nutritious vessels is seen upon the under surface of the bone.

Development.—By *two* centres; one for the shaft, and one for the anterior prominence of the sternal extremity.

Articulations.—With the sternum and scapula.

Attachment of Muscles.—To *six*; the sterno-mastoid, trapezius, pectoralis major, deltoid, subclavius, and sterno-hyoid.

SCAPULA.—The *scapula* is a flat triangular bone, situated upon the posterior aspect and side of the thorax. It is divisible into an anterior and posterior surface, superior, inferior, and posterior border, anterior, superior, and inferior angle and processes.

The *anterior surface*, or subscapular fossa, is concave and irregular, and marked by several oblique ridges. The whole concavity is occupied by the subscapularis muscle, with the exception of a small triangular portion near the superior angle. The *posterior surface* or dorsum is convex, and unequally divided into two portions by the spine; that portion above the spine is the supra-spinous fossa; and that below, the infra-spinous fossa.

The *superior border* is the shortest of the three; it is thin and concave, and terminated at one extremity by the superior angle, and at the other by the coracoid process. At its inner termination, and formed partly by the base of the coracoid process, is the supra-scapular notch, for the transmission of the supra-scapular nerve.

The *inferior* or *anterior border* is thick, and marked by several grooves and depressions; it terminates superiorly at the glenoid cavity, and inferiorly at the inferior angle. Immediately below the glenoid cavity is a rough ridge, which gives origin to the long head of the triceps muscle. Upon the posterior surface of the border is a depression for the teres minor; and upon its anterior surface a deeper groove for the teres major; near the inferior angle is a projecting lip, which increases the surface of origin of the latter muscle. The *posterior border*, the longest of the three is also named the *base*. It is intermediate in thickness between the superior and inferior, and convex, being considerably inflected forwards towards the superior angle.

The anterior angle is the thickest part of the bone, and forms the *head* of the scapula; it is immediately surrounded by a depressed surface, the *neck*. The head presents a shallow pyriform articular surface, the *glenoid cavity*, having the pointed extremity upwards; and at its apex is a rough depression, which gives attachment to the long tendon of the biceps. The superior

Fig. 34.

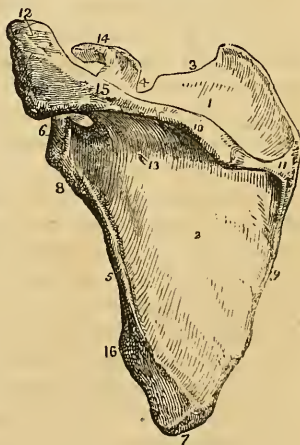


Fig. 34. A posterior view of the scapula. 1. The supra-spinous fossa. 2. The infra-spinous fossa. 3. The superior border. 4. The supra-scapular notch. 5. The anterior or inferior border. 6. The head of the scapula and glenoid cavity. 7. The inferior angle. 8. The neck of the scapula, the ridge opposite to the number gives origin to the long head of the triceps. 9. The posterior border or base of the scapula. 10. The spine. 11. The triangular smooth surface, over which the tendon of the trapezius glides. 12. The acromion process. 13. One of the nutritive foramina. 14. The coracoid process.

angle is thin and pointed. The inferior angle is thick and smooth upon the external surface for the origin of the *teres major*, and for a large bursa over which the upper border of the *latissimus dorsi* muscle plays.

The *spine* of the scapula crosses the upper part of its dorsum; it commences at the posterior border by a smooth triangular surface over which the *trapezius* glides upon a bursa, and terminates at the point of the shoulder in the *acromion* process. The upper border of the spine is rough and subcutaneous, and gives attachment by two projecting lips to the *trapezius* and *deltoid* muscles.

The *acromion* is somewhat triangular and flattened from above downwards; it overhangs the *glenoid* cavity, the upper surface being rough and subcutaneous, the lower smooth and corresponding with the shoulder-joint. Near its extremity is an oval articular surface, for the end of the *clavicle*. The nutritious foramina of the scapula are situated in the base of the spine.

The *coracoid process* is a thick, round, and curved process of bone arising from the upper part of the neck of the scapula, and overarching the *glenoid* cavity. It is about two inches in length and very strong; it gives attachment to several ligaments and muscles.

Development—By six centres; one for the body, one for the *coracoid* process, two for the *acromion*, one for the posterior border, and one for the inferior angle.

Articulations.—With the *clavicle* and *humerus*.

Attachment of Muscles.—To sixteen; by its anterior surface to the *subscapularis*; posterior surface, *supra-spinatus* and *infra-spinatus*; superior border, *omo-hyoid*; posterior border, *levator anguli scapulæ*, *rhomboideus minor*, *rhomboideus major*, and *serratus magnus*; anterior border, long head of the *triceps*, *teres minor*, and *teres major*; upper angle of the *glenoid* cavity, to the long tendon of the *biceps*; spine and *acromion*, to the *trapezius* and *deltoid*; *coracoid* process, to the *pectoralis minor*, short head of the *biceps*, and *coraco-brachialis*. The ligaments attached to the *coracoid* process are, the *coracoid*, *coraco-clavicular*, and *coraco-humeral*, and the *costo-coracoid* membrane.

HUMERUS.—The *humerus* is a long bone divisible into a shaft and two extremities.

The *superior extremity* presents a rounded *head*; a constriction immediately around the base of the head, the *neck*; a *greater* and a *lesser tuberosity*. The greater tuberosity is situated most externally, and is separated from the lesser by a vertical furrow—the *bicipital groove*,—which lodges the long tendon of the *biceps*. The edges of this groove below the head of the bone are raised and rough, and are called the *anterior* and *posterior bicipital ridge*; the former serves for the insertion of the *pectoralis major* muscle, and the latter for the *teres major*.

The constriction of the bone below the tuberosities is the sur-

gical neck, and is so named, in contradistinction to the true neck, from being the seat of the accident called by surgical writers *fracture of the neck of the humerus*.

The *shaft* of the bone is prismoid at its upper part, and flattened from before backwards below. Upon its outer side, at about its middle, is a rough triangular eminence, which gives insertion to the deltoid; and immediately on each side of this eminence is a smooth depression, corresponding with the two heads of the brachialis anticus. Upon the inner side of the middle of the shaft is a ridge, for the attachment of the coraco-brachialis muscle; and behind, an oblique and shallow-groove, which lodges the musculospiral nerve and superior profunda artery. The foramen for the medullary vessels is situated upon the inner surface of the shaft of the bone, a little below the coraco-brachial ridge; it is directed downwards.

The *lower extremity* is flattened from before backwards, and is terminated inferiorly by a long articular surface, divided into two parts by an elevated ridge. The external portion of the articular surface is a rounded protuberance, which articulates with the cup-shaped depression on the head of the radius; the internal portion is a concave and pulley-like surface, which articulates with the ulna. Projecting beyond the articular surface on each side are the *external* and *internal condyle*, the latter being considerably the longer; and running upwards from the condyles upon the borders of the bone are the condyloid ridges, of which the external is the most prominent. Immediately in front of the articular surface is a small depression, for receiving the coronoid process of the ulna during flexion of the fore-arm; and immediately behind it a large and deep fossa, for containing the olecranon process in extension.

Development.—By seven centres; one for the shaft, one for the upper extremity, one for the greater tuberosity, one for the rounded protuberance, and one for the trochlear portion of the articular surface, and one for each condyle.

Articulations.—With the glenoid cavity of the scapula, and with the ulna and radius.

Attachment of Muscles.—To *twenty-four*; by the greater tuberosity to the supra-spinatus, infra-spina-

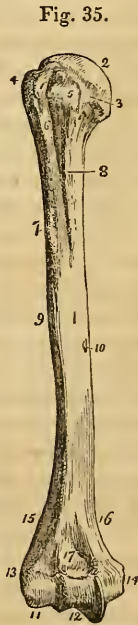

Fig. 35. The humerus of the right side; its anterior surface. 1. the shaft of the bone. 2. The head. 3. The anatomical neck. 4. The greater tuberosity. 5. The lesser tuberosity. 6. The bicipital groove. 7. The anterior bicipital ridge. 8. The posterior bicipital ridge. 9. The rough surface into which the deltoid is inserted. 10. The nutritious foramen. 11. The rounded protuberance of the articular surface. 12. The pulley-like surface. 13. The external condyle. 14. The internal condyle. 15. The external condyloid ridge. 16. The internal condyloid ridge. 17. The fossa for the coronoid process of the ulna.

tus, and teres minor; lesser tuberosity, subscapularis; anterior bicipital ridge, pectoralis major; posterior bicipital ridge and groove, teres major and latissimus dorsi; shaft, external and internal heads of the triceps, deltoid, coraco-brachialis, and brachialis anticus; external condyloid ridge and condyle, extensors and supinators of the forearm, viz. supinator longus, extensor carpi radialis longior, extensor carpi radialis brevior, extensor communis digitorum, extensor minimi digiti, extensor carpi ulnaris, anconeus and supinator brevis; internal condyle, flexors and one pronator, viz. pronator radii teres, flexor carpi radialis, palmaris longus, flexor sublimis digitorum, and flexor carpi ulnaris.

ULNA.—The ulna is a long bone, divisible into a shaft and two extremities. The upper extremity is large, and forms principally the articulation of the elbow; while the lower extremity is small, and excluded from the wrist-joint by an inter-articular fibro-cartilage.

The *superior extremity* presents a semilunar concavity of large size, the *greater sigmoid notch*, for articulation with the humerus; and upon the outer side a *lesser sigmoid notch*, which articulates with the head of the radius. Bounding the greater sigmoid notch posteriorly is the *olecranon process*; and overhanging it in front, a pointed eminence with a rough triangular base—the *coronoid process*. Behind the lesser sigmoid notch, and extending downwards on the side of the olecranon, is a triangular rough surface, for the anconeus muscle; and upon the posterior surface of the olecranon another triangular surface, which is subcutaneous.

The *shaft* is prismoid in form, and presents three surfaces,—anterior, posterior, and internal; and three borders. The *anterior surface* is occupied by the flexor profundus digitorum for the upper three-fourths of its extent; and below by a depression, for the pronator quadratus muscle. A little above its middle is the nutritious foramen, which is directed upwards. Upon the *posterior surface* at the upper part of the bone is the triangular rough depression for the anconeus muscle, bounded inferiorly by an oblique ridge which runs downwards from the posterior extremity of the lesser sigmoid notch. Below the ridge the surface is marked into several grooves, for the attachment of the extensor ossis metacarpi, extensor secundi internodii, and extensor indicis muscle. The *internal surface* is covered in for its whole extent by the flexor carpi ulnaris. The *anterior border* is rounded, and gives origin by its lower fourth to the pronator quadratus; the *posterior* is more prominent, and affords attachment to the flexor carpi ulnaris and extensor carpi ulnaris. At its upper extremity it expands into the triangular subcutaneous surface of the olecranon. The *external or radial border* is sharp and prominent, for the attachment of the interosseous membrane.

The *lower extremity* terminates in a small rounded head, from the side of which projects the *styloid process*. Upon the posterior surface of the head is a groove for the tendon of the flexor carpi

ulnaris ; and upon the side opposite to the styloid process a smooth surface, for articulation with the side of the radius.

Development.—By four centres ; one for the shaft, one for each extremity, and one for the olecranon.

Articulations.—With two bones ; the humerus and radius.

Attachment of Muscles.—To twelve ; by the olecranon, to the triceps extensor cubiti, one head of the flexor carpi ulnaris, and to the anconeus ; by the coronoid process, to the brachialis anticus, pronator radii teres, flexor sublimis digitorum, and flexor profundus digitorum ; by the shaft, to the flexor profundus digitorum, flexor carpi ulnaris, pronator quadratus, anconeus, extensor carpi ulnaris, extensor ossis metacarpi pollicis, extensor secundi internodii pollicis, and extensor indicis.

RADIUS.—The radius is the rotatory bone of the fore-arm ; it is divisible into a shaft and two extremities : unlike the ulna, its upper extremity is small, and merely accessory to the formation of the elbow-joint ; while the lower extremity is large, and forms almost solely the joint of the wrist.

The *superior extremity* presents a rounded *head*, depressed upon its upper surface into a shallow cup. Around the margin of the head is a smooth articular surface, which is broad on the inner side, where it articulates with the lesser sigmoid notch of the ulna, and narrow in the rest of its circumference, to play in the orbicular ligament. Beneath the head is a round constricted *neck* ; and beneath the neck on its internal aspect a prominent process—the *tuberosity*. The surface of the tuberosity is partly smooth, and partly rough ; rough below, where it receives the attachment of the tendon of the biceps ; and smooth above, where a bursa is interposed between the tendon and the bone.

The *shaft* of the bone is prismoid, and presents three surfaces. The *anterior surface* is somewhat concave superiorly, where it lodges the flexor longus pollicis ; and flat below, where it supports the pronator quadratus. At about the upper third of this surface is the nutritious foramen, which is directed upwards. The *posterior surface* is round above, where it supports the supinator brevis muscle, and marked by several shallow oblique grooves below, which afford attachment to the extensor

Fig. 36.

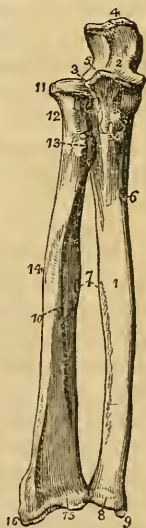


Fig. 36. The two bones of the fore-arm seen from the front. 1. The shaft of the ulna. 2. The greater sigmoid notch. 3. The lesser sigmoid notch, with which the head of the radius is articulated. 4. The olecranon process. 5. The coronoid process. 6. The nutritious foramen. 7. The sharp ridges upon the two bones to which the interosseous membrane is attached. 8. The rounded head at the lower extremity of the ulna. 9. The styloid process. 10. The shaft of the radius. 11. Its head surrounded by the smooth border for articulation with the orbicular ligament. 12. The neck of the radius. 13. Its tuberosity. 14. The oblique line. 15. The lower extremity of the bone. 16. Its styloid process.

muscles of the thumb. The *external surface* is rounded and convex, and marked by an *oblique ridge*, which extends from the tuberosity to the styloid process at the lower extremity of the bone. Upon the inner margin of the bone is a sharp and prominent crest, which gives attachment to the interosseous membrane. The *lower extremity* of the radius is broad and triangular, and provided with two articular surfaces; one at the side of the bone, which is concave to receive the rounded head of the ulna; the other at the extremity, and marked by a slight ridge into two facets,—one external and triangular, corresponding with the scaphoid; the other square, with the semilunar bone. Upon the outer side of the extremity is a strong conical projection, the *styloid process*, which gives attachment by its base to the tendon of the supinator longus, by its apex to the external lateral ligament of the wrist joint, and by its inner side to the triangular interarticular cartilage.

Immediately in front of the styloid process is a groove, which lodges the tendons of the extensor ossis metacarpi pollicis, and extensor primi internodii: and behind the process a broader groove, for the tendons of the extensor carpi radialis longior and brevior, and extensor secundi internodii; behind this is a prominent ridge, and a deep and narrow groove, for the tendon of the extensor indicis; and still farther back part of a broad groove, completed by the ulna, for the tendons of the extensor communis digitorum.

Development.—By three centres; one for the shaft, and one for each extremity.

Articulations.—With four bones; humerus, ulna, scaphoid, and semilunar.

Attachment of Muscles.—To nine; by the tuberosity and oblique ridge, to the biceps, supinator brevis, pronator radii teres, flexor sublimis digitorum, and pronator quadratus; by the anterior surface, to the flexor longus pollicis and pronator quadratus; by the posterior surface, to the extensor ossis metacarpi pollicis, and extensor primi internodii; and by the styloid process, to the supinator longus.

CARPUS.—The bones of the carpus are eight in number, they are arranged in two rows. In the first row, commencing from the radial side, are the os scaphoides, semilunare, cuneiforme, pisiforme; and in the second row, in the same order, the os trapezium, trapezoides, os magnum and unciforme.

The *scaphoid* bone is named from bearing some resemblance to the shape of a boat, being broad at one end, narrowed like a prow, at the opposite, concave on one side, and convex upon the other. It is, however, more similar in form to a cashew nut, flattened and concave upon one side. If carefully examined, it will be found to present a *convex* and a *concave surface*, a *convex* and a *concave border*, a *broad* end, and a *narrow* and pointed *extremity*—the tuberosity.

To ascertain to which hand it belongs, let the student hold it horizontally, so that the convex surface may look backwards (*i. e.* towards himself,) and the convex border upwards; the broad ex-

tremity will indicate its appropriate hand ; if it be directed to the right, the bone belongs to the right ; and if to the left, to the left carpus.

Articulations.—With *five* bones ; by its convex surface with the radius ; by its concave surface, with the os magnum and semilunare ; and by the extremity of its upper or dorsal border, with the trapezium and trapezoides.

Attachments.—By its tuberosity to the abductor pollicis, and annular ligament.

The *semilunar* bone may be known by having a crescentic concavity, and a somewhat crescentic outline. It presents for examination four articular surfaces and two extremities ; the *articular surfaces* are, one *concave*, one *convex*, and two *lateral*—one lateral surface being crescentic ; the other nearly circular, and divided generally into two facets : and the *extremities*, one *dorsal*, which is quadrilateral, flat, and indented, for the attachment of ligaments ; the other *palmar*, which is convex, rounded, and of larger size.

To determine to which hand it belongs, let the bone be held perpendicularly, so that the dorsal or flat extremity look upwards, and the convex side backwards (towards the holder). The circular lateral surface will point to the side corresponding with the hand to which the bone belongs.

Articulations.—With *five* bones, but occasionally with only four ; by its convex surface, with the radius ; by its concave surface, with the os magnum ; by its crescentic lateral facet, with the scaphoid ; and by the circular surface, with the cuneiform bone and with the point of the unciform. This surface is divided into two parts by a ridge, when it articulates with the unciform as well as with the cuneiform bone.

The *cuneiform* bone, although somewhat wedge-shaped in form, may be best distinguished by a circular and isolated facet, which articulates with the pisiform bone. It presents for examination *three surfaces*, a *base* and an *apex*. One surface is very rough and irregular ; the opposite forms a concave articular surface,

Fig. 37.

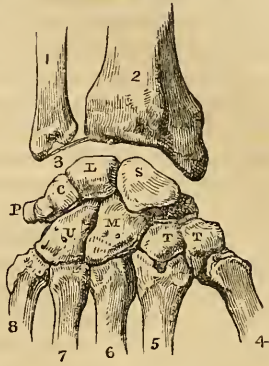


Fig. 37. A diagram showing the dorsal surface of the bones of the carpus, with their articulations.—The right hand. 2. The lower end of the radius. 1. The lower extremity of the ulna. 3. The inter-articular fibro-cartilage attached to the styloid process of the ulna, and to the margin of the articular surface of the radius. S. The scaphoid bone. L. The semilunare articulating with five bones. C. The cuneiforme, articulating with three bones. P. The pisiforme, articulating with the cuneiforme only. T. The first bone of the second row—the trapezium, articulating with four bones. T. The second bone—the trapezoides, articulating also with four bones. M. The os magnum, articulating with seven. U. The unciforme articulating with five.

while the third is partly rough and partly smooth, and presents that circular facet which is characteristic of the bone. The base is an articular surface, and the apex is rough and pointed.

To distinguish its appropriate hand, let the base be directed backwards and the pisiform facet upwards; the concave articular surface will point to the hand to which it belongs.

Articulations.—With *three* bones, and with the triangular fibrocartilage. By the base, with the semilunare; by the concave surface, with the unciforme; by the circular facet, with the pisiforme; and by the superior angle of the rough surface, with the fibrocartilage.

The *pisiform* bone may be recognised by its small size, and by possessing a single articular facet. If it be examined carefully, it will be observed to present four sides and two extremities; one side is articular, the smooth facet approaching nearer to the superior than the inferior extremity. The side opposite to this is rounded, and the remaining sides are, one slightly concave, the other slightly convex.

If the bone be held so that the articular facet shall look downwards, and the extremity which overhangs the articular facet forwards, the concave side will point to the hand to which it belongs.

Articulations.—With the cuneiform bone only.

Attachments.—To *two* muscles—the flexor carpi ulnaris, and abductor minimi digiti; and to the annular ligament.

The *trapezium* is too irregular in form to be compared to any known object; it may be distinguished by a deep groove for the tendon of the flexor carpi radialis muscle. It is somewhat compressed, and may be divided into two surfaces which are smooth and articular, and three rough borders. One of the *articular surfaces* is *oval*, concave in one direction, and convex in the other; the other is marked into *three facets*. One of the *borders* presents the groove for the tendon of the flexor carpi radialis, which is surmounted by a prominent tubercle for the attachment of the annular ligament; the other two borders are rough and form the outer side of the carpus. The grooved border is narrow at one extremity and broad at the other, where it presents the groove and tubercle.

If the bone be held so that the grooved border look upwards while the apex of this border be directed forwards, and the base with the tubercle backwards, the concavo-convex surface will point to the hand to which the bone belongs.

Articulations.—With *four* bones; by the concavo-convex surface, with the metacarpal bone of the thumb; and by the three facets of the other articular surface, with the scaphoid, trapezoid, and second metacarpal bone.

Attachments.—To *two* muscles—flexor ossis metacarpi, and flexor brevis pollicis; and by the tubercle, to the annular ligament.

The *trapezoides* is a small, oblong, and quadrilateral bone, bent

near its middle upon itself. It presents four articular surfaces and two extremities. One of the surfaces is *concavo-convex*,—*i. e.* concave in one direction and convex in the other; another, contiguous to the preceding, is *concave*, so as to be almost angular in the middle, and is often marked by a small rough depression, for an interosseous ligament; the two remaining sides are *flat*, and present nothing remarkable. One of the two extremities is broad and of large size,—the *dorsal*; the other, or *palmar*, is small and rough.

If the bone be held perpendicularly, so that the broad extremity be upwards, and the concavo-convex surface forwards, the angular concave surface will point to the hand to which the bone belongs.

Articulations.—With *four* bones; by the concavo-convex surface with the second metacarpal bone; by the angular concave surface with the os magnum; and by the other two surfaces, with the trapezium and scaphoid.

Attachments.—To the flexor brevis pollicis muscle.

The *os magnum* is the largest bone of the carpus, and is divisible into a body and head. The *head* is round for the greater part of its extent, but is flattened on one side. The *body* is irregularly quadrilateral, and presents four sides and a smooth extremity. Two of the sides are rough, the one being square and flat—the dorsal, the other rounded and prominent—the palmar; the other two sides are articular, the one being concave, the other convex. The extremity is a triangular articular surface, divided into three facets.

If the bone be held perpendicularly, so that the articular extremity look upwards and the broad dorsal surface backwards (towards the holder), the concave articular surface will point to the hand to which the bone belongs.

Articulations.—With *seven* bones; by the rounded head, with the cup formed by the scaphoid and semilunar bone; by the side of the convex surface, with the trapezoides; by the concave surface, with the unciforme; and by the extremity, with the second, third, and fourth metacarpal bones.

Attachments.—To the flexor brevis pollicis muscle.

The *unciforme* is a triangular-shaped bone, remarkable for a long and curved process, which projects from its palmar aspect. It presents five surfaces;—three articular, and two free. One of the articular surfaces is divided by a slight ridge into two facets; the other two converge, and meet at a flattened angle.* One of the free surfaces—the dorsal—is rough and triangular; the other—palmar, also triangular, but somewhat smaller, gives origin to the unciform process.

If the bone be held perpendicularly, so that the articular surface with two facets look upwards, and the unciform process backwards (towards the holder), the concavity of the unciform process will point to the hand to which the bone belongs.

Articulations.—With *five* bones; by the two facets on its base,

* When the unciforme does not articulate with the semilunare, this angle is sharp.

with the fourth and fifth metacarpal bones; by the two lateral articulating surfaces, with the magnum and cuneiforme; and by the flattened angle of its apex, with the semilunare.

Attachments.—To two muscles—the adductor minimi digiti, and flexor brevis minimi digiti; and to the annular ligament.

Development.—The bones of the carpus are each developed by a single centre.

The number of articulations which each bone of the carpus presents with surrounding bones, may be expressed in figures, which will materially facilitate their recollection; the number for the first row is 5531, and for the second 4475.

METACARPUS.—The bones of the metacarpus are five in number. They are long bones, divisible into a head, shaft, and base.

The *head* is rounded at the extremity, and flattened at each side, for the insertion of strong ligaments; the *shaft* is prismoid, and marked deeply on each side, for the attachment of the interossei muscles; and the *base* is irregularly quadrilateral and rough, for the insertion of tendons and ligaments. The *base* presents three articular surfaces, one at each side, for the adjoining metacarpal bones; and one at the extremity for the carpus.

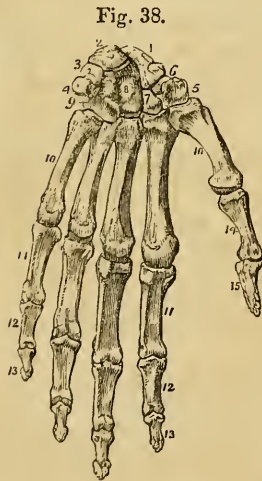


Fig. 38.

The metacarpal bone of the thumb is one-third shorter than the rest, flattened and broad on its dorsal aspect, and convex on its palmar side; the articular surface of the head is not so round as that of the other metacarpal bones; and the base has a single concavo-convex surface, to articulate with the similar surface of the trapezium.

The metacarpal bones of the different fingers may be distinguished by certain obvious characters. The base of the metacarpal bone of the index finger is the largest of the four, and presents four articular surfaces. That of the middle finger may be distinguished by a rounded projecting process upon the radial side of its base, and two small circular facets upon its ulnar lateral surface. The base of the metacarpal bone of the ring-finger is small and square, and has two small circular facets to correspond with those of the middle metacarpal. The metacarpal bone of the little finger has only one lateral articular surface.

Fig. 38. The hand viewed upon its anterior or palmar aspect. 1. The scaphoid bone, 2. The semilunare. 3. The cuneiforme. 4. The pisiforme. 5. The trapezium. 6. The groove in the trapezium that lodges the tendon of the flexor carpi radialis. 7. The trapezoides. 8. The os magnum. 9. The unciforme. 10, 10. The five metacarpal bones. 11, 11. The first row of phalanges. 12, 12. The second row. 13, 13. The third row, or ungual phalanges. 14. The first phalanx of the thumb. 15. The second and last phalanx of the thumb.

Development.—By two centres; one for the shaft, and one for the digital extremity.

Articulations.—The first with the trapezium; second, with the trapezium, trapezoides, and os magnum, and with the middle metacarpal bone; third, or middle, with the os magnum, and adjoining metacarpal bones; fourth, with the os magnum and unciforme, and with the adjoining metacarpal bones; and fifth, with the unciforme, and with the metacarpal bone of the ring-finger.

The figures resulting from the number of articulations which each metacarpal bone possesses, taken from the radial to the ulnar side, are 13121.

Attachment of Muscles.—To the metacarpal bone of the thumb, *three*—the flexor ossis metacarpi, extensor ossis metacarpi and first dorsal interosseous; of the index finger, *five*—the extensor carpi radialis longior, flexor carpi radialis, first and second dorsal interosseous, and first palmar interosseous; of the middle finger, *four*—the extensor carpi radialis brevior, adductor pollicis, and second and third dorsal interosseous; of the ring-finger, *three*—the third and fourth dorsal interosseous, and second palmar; and of the little finger, *four*—extensor carpi ulnaris, adductor minimi digiti, fourth dorsal and third palmar interosseous.

PHALANGES.—The phalanges are the bones of the fingers; they are named from their arrangement in rows, and are fourteen in number,—three to each finger, and two to the thumb. In conformation they are long bones, divisible into a shaft, and two extremities.

The *shaft* is compressed from before backwards convex on its posterior surface, and flat with raised edges in front. The metacarpal extremity of the first row is a simple concave articular surface—of the other two rows a double concavity, separated by a slight ridge. The digital extremities of the first and second row present a pulley-like surface, concave in the middle, and convex on each side. The unguial extremity of the last phalanx is broad, rough and expanded into a semilunar crest.

Development.—By two centres; one for the shaft, and one for the metacarpal extremity.

Articulations.—The first row, with the metacarpal bones and second row of phalanges; the second row, with the first and third; and the third, with the second row.

Attachment of Muscles.—To the base of the *first phalanx* of the thumb *four* muscles—abductor pollicis, flexor brevis pollicis, adductor pollicis, and extensor primi internodii; and to the *second phalanx* *two*—the flexor longus pollicis, and extensor secundi internodii. To the *first phalanx* of the second, third, and fourth fingers, one dorsal and one palmar interosseous, and to the first phalanx of the little finger, the abductor minimi digiti, flexor brevis minimi digiti, and one palmar interosseous. To the *second phalanges* the flexor sublimis and extensor communis digitorum; and to the

last phalanges—the flexor profundus and extensor communis digitorum.

PELVIS AND LOWER EXTREMITY.

The bones of the pelvis are the two ossa innominata, the sacrum, and the coccyx; and of the lower extremity, the femur, patella, tibia and fibula, tarsus, metatarsus, and phalanges.

OS INNOMINATUM.—The os innominatum is an irregular flat bone, consisting in the young subject of three parts, which meet at the acetabulum. Hence it is usually described in the adult as divisible into three portions,—ilium, ischium, and pubis. The *ilium* is the superior broad and expanded portion which forms the prominence of the hip, and articulates with the sacrum. The *ischium* is the inferior and strong part of the bone on which we sit. The *pubis* is that portion which forms the front of the pelvis, and gives support to the external organs of generation.

The *ilium* may be described as divisible into an internal and external surface, a crest, and an anterior and posterior border.

The *internal surface* is bounded above by the crest, below by a prominent line—the *linea ilio-pectinea*, and before and behind by

the anterior and posterior borders; it is concave and smooth for the anterior two-thirds of its extent, and lodges the iliacus muscle. The posterior third is rough, for articulation with the sacrum, and is divided into two parts by a deep groove;—an anterior or *auricular portion*, which is shaped like the pinna, and coated by cartilage in the fresh bone; and a posterior portion, which is very rough, for the attachment of interosseous ligaments.

The *external surface* is rough, partly convex, and partly concave; it is bounded above by the crest; below, by a prominent arch, which forms

Fig. 39.

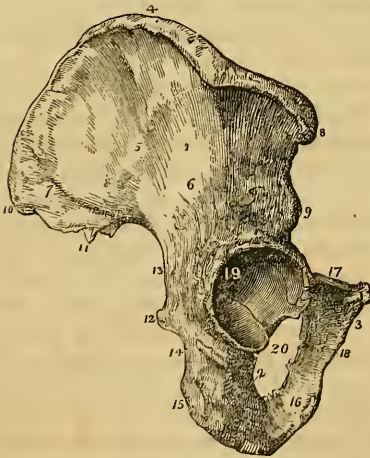


Fig. 39. The os innominatum of the right side. 1. The ilium; its external surface. 2. The ischium. 3. The os pubis. 4. The crest of the ilium. 5. The superior curved line. 6. The inferior curved line. 7. The surface for the glutens maximus. 8. The anterior superior spinous process. 9. The anterior inferior spinous process. 10. The posterior superior spinous process. 11. The posterior inferior spinous process. 12. The spine of the ischium. 13. The great sacro-ischiatic notch. 14. The lesser sacro-ischiatic notch. 15. The tuberosity of the ischium, showing its three facets. 16. The ramus of the ischium. 17. The body of the os pubis. 18. The ramus of the pubis. 19. The acetabulum. 20. The foramen thyroideum.

the upper segment of the acetabulum; and before and behind by the anterior and posterior borders. Crossing this surface in an arched direction, from the anterior extremity of the crest to a notch upon the lower part of the posterior border, is a groove, which lodges the gluteal vessels and nerve—the *superior curved line*; and below this, at a short distance, a rough ridge,—the *inferior curved line*. The surface included between the superior curved line and the crest, gives origin to the gluteus medius muscle; that between the curved lines, to the gluteus minimus; and the rough interval between the inferior curved line and the arch of the acetabulum, to one head of the rectus. The posterior sixth of this surface is rough and raised, and gives origin to part of the gluteus maximus.

The *crest* of the ilium is arched and sigmoid in its direction, being bent inwards at its anterior termination, and outwards towards the posterior. It is broad for the attachment of three planes of muscles, which are connected with its external and internal borders or lips, and with the intermediate space.

The *anterior border* is marked by two projections,—the *anterior superior spinous process*, which is the anterior termination of the crest, and the *anterior inferior spinous process*; the two processes being separated by a notch for the attachment of the sartorius muscle. This border terminates inferiorly in the lip of the acetabulum. The *posterior border* also presents two projections,—the *posterior superior* and the *posterior inferior spinous process*,—separated by a notch. Inferiorly this border is broad and arched, and forms the upper part of the great sacro-ischiatic notch.

The ischium is divisible into a thick and solid portion—the *body*, and into a thin and ascending part—the *ramus*; it may be considered also, for convenience of description, as presenting an external and internal surface, and three borders,—posterior, inferior, and superior.

The *external surface* is rough, for the attachment of muscles; and broad and smooth above, where it enters into the formation of the acetabulum. Below the inferior lip of the acetabulum is a notch, which lodges the obturator externus muscle in its passage outwards to the trochanteric fossa of the femur. The *internal surface* is smooth, and somewhat encroached upon at its posterior border by the spine.

The *posterior border* of the ischium presents towards its middle a remarkable projection,—the *spine*. Immediately above the spine is a notch of large size—the *great sacro-ischiatic*, and below the spine the *lesser sacro-ischiatic notch*; the former being converted into a foramen by the lesser sacro-ischiatic ligament, gives passage to the pyriformis muscle, and to the gluteal vessels and nerve, pudic vessels and nerve, and ischiatic vessels and nerves; and the lesser completed by the great sacro-ischiatic ligament, to the obturator internus muscle, and to the internal pudic vessels and nerve. The *inferior border* is thick and broad, and is called the *tuberosity*. The surface of the tuberosity is divided into three facets; one anterior, which is

rough for the origin of the semi-membranosus; and two posterior, which are smooth, and separated by a slight ridge for the semi-tendinosus and biceps muscles. The inner margin of the tuberosity is bounded by a sharp ridge, which gives attachment to a prolongation of the great sacro-ischiatic ligament. The *superior border* of the ischium is thin, and forms the lower circumference of the obturator foramen. The *ramus* of the ischium is continuous with the ramus of the pubis, and is slightly everted.

The *pubis* is divided into a horizontal portion or *body*, and a descending portion or *ramus*; it presents for examination an external and internal surface, a superior and inferior border, and symphysis.

The *external surface* is rough, for the attachment of muscles; and prominent at its outer extremity, where it forms part of the acetabulum. The *internal surface* is smooth. The *superior border* is marked by a rough ridge—the *crest*; the inner termination of the crest is the *angle*; and the outer end, the *spine* or *tuberosity*. Running outwards from the spine is a sharp ridge, the *pectineal line*—or *linea ilio-pectinea*, which marks the brim of the true pelvis. In front of the pectineal line is a smooth depression, which supports the femoral vein, and a little more externally an elevated prominence, the *pectineal eminence*, which divides the surface for the vein from another depression which overhangs the acetabulum, and lodges the psoas and iliacus muscles. The *inferior border* is broad and deeply grooved, for the passage of the obturator vessels and nerve; and sharp upon the side of the ramus, to form part of the boundary of the obturator foramen. The *symphysis* is the inner extremity of the body of the bone; it is oval and rough, for the attachment of a ligamentous structure analogous to the intervertebral substance. The *ramus* of the pubis descends, and is continuous with the ramus of the ischium. Its inner border is considerably everted, to afford a strong attachment to the crus penis.

The *acetabulum* is a deep cup-shaped cavity, situated at the point of union between the ilium, ischium, and pubis; a little less than two-fifths being formed by the ilium, a little more than two-fifths by the ischium, and the remaining fifth by the pubis. It is bounded by a deep rim or lip, which is broad and strong above, where most resistance is required, and marked in front by a deep notch, which transmits the nutrient vessels into the joint. At the bottom of the cup, and communicating with the notch, is a deep and circular pit, which lodges a mass of fat, and gives attachment to the broad extremity of the ligamentum teres.

The *obturator* or *thyroid foramen* is a large oval interval between the ischium and pubis, bounded by a narrow rough margin, to which a ligamentous membrane is attached. The upper part of the foramen is increased in depth by the groove in the under surface of the os pubis, which lodges the obturator vessels and nerve.

Development.—By *eight* centres; three principal—one for the ilium, one for the ischium, and one for the pubis; and five secondary—one for the crest of the ilium, and one for its anterior inferior

spinous process, one for the centre of the acetabulum, one for the tuberosity of the ischium, and one (not constant) for the angle of the pubis.

Articulations.—With *three* bones ; sacrum, opposite innominatum, and femur.

Attachment of Muscles and Ligaments.—To *thirty-five* muscles ; to the ilium, *thirteen* ; by the outer lip of the crest, to the obliquus externus for two-thirds, and to the latissimus dorsi for one-third its length, and to the tensor vaginæ femoris by its anterior fourth ; by the middle of the crest, to the internal oblique for three-fourths its length, by the remaining fourth to the erector spinæ ; by the internal lip, to the transversalis for three-fourths, and to the quadratus lumborum by the posterior part of its middle third. By the external surface, to the gluteus medius, minimus and maximus, and to one head of the rectus ; by the internal surface, to the iliacus ; and by the anterior border, to the sartorius, and the other head of the rectus. To the ischium *sixteen* ; by its external surface, the adductor magnus and obturator externus ; by the internal surface, the obturator internus and levator ani ; by the spine, the gemellus superior, levator ani, coccygeus, and lesser sacro-ischiatic ligament ; by the tuberosity, the biceps, semi-tendinosus, semi-membranosus, gemellus inferior, quadratus femoris, erector penis, transversus perinei, and great sacro-ischiatic ligament ; and by the ramus, the gracilis, accelerator urinæ, and compressor urethræ. To the pubis *fifteen* ; by its upper border, the obliquus externus, obliquus internus, transversalis, rectus, pyramidalis, pectineus, and psoas parvus ; by its external surface, the adductor longus, adductor brevis and gracilis ; by its internal surface, the levator ani, compressor urethræ, and obturator internus ; and by the ramus, the adductor magnus, and accelerator urinæ.

PELVIS.

The pelvis considered as a whole is divisible into a *false* and *true* pelvis ; the former is the expanded portion, bounded on each side by the ossa ilii, and separated from the true pelvis by the linea ilio-pectinea. The true pelvis is all that portion which is situated beneath the linea ilio-pectinea. This line forms the margin or *brim* of the true pelvis, while the included area is called the *inlet*. The form of the inlet is heart-shaped, obtusely pointed in front at the symphysis pubis, expanded on each side, and encroached upon behind by a projection of the upper part of the sacrum, which is named the promontory. The cavity is somewhat encroached upon at each side by a smooth quadrangular plane of bone, corresponding with the internal surface of the acetabulum, and leading to the spine of the ischium. In front are two fossæ around the obturator foramina, for lodging the obturator internus muscle, at each side. The inferior termination of the pelvis is very irregular, and is termed the *outlet*. It is bounded in front by the convergence of the rami of the ischium

and pubis, which constitute the arch of the pubis; on each side by the tuberosity of the ischium, and by two irregular fissures formed by the greater and lesser sacro-ischiatic notches; and behind by the inferior borders of the sacrum, and by the coccyx.

The pelvis is placed obliquely with regard to the trunk of the body, so that a line drawn through the central axis of the inlet, would touch by one extremity the lower part of the sacrum, and by the other would pass through the umbilicus. The *axis of the inlet* is therefore directed *downwards and backwards*, while that of the *outlet* points *downwards and forwards*, and corresponds with a line drawn from the upper part of the sacrum, through the centre of the outlet. The axis of the cavity represents a curve, the extremities of which will be indicated by the central points of the inlet and outlet. A knowledge of the direction of these axes is most important to the surgeon, as indicating the line in which instruments should be used in operations upon the viscera of the pelvis, and the direction of force in the removal of calculi from the bladder; and to the accoucheur, as explaining the course of the fœtus during parturition.

There are certain striking differences between the male and female pelvis. In the male the bones are thicker, stronger, and more solid, and the cavity deeper and narrower. In the female the bones are lighter and more delicate, the iliac fossæ are large and the ilia projecting; the inlet, and the outlet, and the cavity are large, and the acetabula farther removed from each other; the cavity is shallow, the tuberosities widely separated—the obturator foramina triangular, and the arch of the pubis wide. The precise diameter of the inlet and outlet, and the depth of the cavity, are very important considerations to the accoucheur.

The diameters* of the inlet or brim are three:—1. Antero-posterior, sacro-pubic or conjugate; 2, transverse; and 3, oblique. The *antero-posterior* extends from the symphysis pubis to the middle of the promontory of the sacrum, and measures four inches and a half. The *transverse* extends from the middle of the brim on one side to the same point on the opposite, and measures five inches and a quarter. The *oblique* extends from the sacro-iliac symphysis on one side, to the margin of the brim corresponding with the acetabulum on the opposite, and measures five inches and one-eighth.

The diameters of the outlet are two, antero-posterior, and transverse. The *antero-posterior* diameter extends from the lower part of the symphysis pubis, to the apex of the coccyx; and the *transverse* from the first part of one tuberosity to the same point on the opposite side; they both measure four inches. The cavity of the pelvis measures in depth four inches and a half, posteriorly; three inches and a half in the middle; and one and a half at the symphysis pubis.

FEMUR.—The femur is a long bone, divisible, like other bones of the same class, into a shaft, a superior and an inferior extremity.

* These diameters are quoted from an excellent "Manual of Practical Midwifery," by Dr. James Reid.

At the *superior extremity* is a rounded *head*, directed upwards and inwards, and marked just below its centre by an oval depression for the ligamentum teres. The head is supported by a *neck*, which varies in length and obliquity at various periods of life, being long and oblique in the adult—short and almost horizontal in the aged. Externally to the neck is a large process,—the *trochanter major*, which presents upon its anterior surface an oval facet, for the attachment of the tendon of the gluteus minimus muscle; and above, a double facet, for the insertion of the gluteus medius. On its posterior side is a vertical ridge—the *linea quadrati*, for the attachment of the quadratus femoris muscle. Upon the inner side of the trochanter major is a deep pit, *trochanteric* or *digital fossa*, in which are inserted the tendons of the pyriformis, gemellus superior and inferior, and obturator externus and internus muscles. Passing downwards from the trochanter major in front of the bone is an oblique ridge, which forms the inferior boundary of the neck,—the *anterior intertrochanteric line*; and behind, another oblique ridge, the *posterior intertrochanteric line*, which terminates in a rounded tubercle upon the posterior and inner side of the bone, the *trochanter minor*.

Fig. 40.



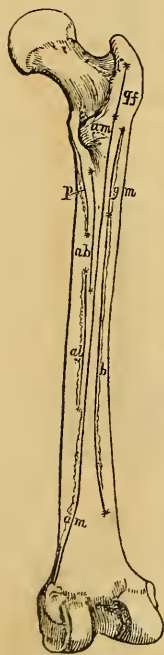The *shaft* of the femur is convex and rounded in front, and covered with muscles; and somewhat concave and raised into a rough and prominent ridge behind, the *linea aspera*. The *linea aspera* near the upper extremity of the bone divides into three branches. The anterior branch is continued forwards in front of the lesser trochanter, and is continuous with the anterior intertrochanteric line; the middle is continued directly upwards into the *linea quadrati*; and the posterior, broad and strongly marked, ascends to the base of the trochanter major. Towards the lower extremity of the bone the *linea aspera* divides into two ridges, which descend to the two condyles, and enclose a triangular space upon which rests the popliteal artery. The internal condyloid ridge is less marked than the external, and presents a broad and shallow groove, for the passage of the femoral artery. The nutritious foramen is situated in or near the *linea aspera*, at about one-third from its upper extremity, and is directed obliquely from below upwards.

Fig. 40. The right femur, seen upon the anterior aspect. 1. The shaft. 2. The head. 3. The neck. 4. The great trochanter. 5. The anterior intertrochanteric line. 6. The lesser trochanter. 7. The external condyle. 8. The internal condyle. 9. The tuberosity for the attachment of the external lateral ligaments. 10. The groove for the tendon of origin of the popliteus muscle. 11. The tuberosity for the attachment of the internal lateral ligament.

The *lower extremity* of the femur is broad and porous, and divided by a smooth depression in front, and by a considerable notch behind, into two condyles.

The *external condyle* is the broadest and most projecting, and the internal the narrowest and longest; the difference in length depending upon the obliquity of the femur, in consequence of the separation of the two bones at their upper extremities by the breadth of the pelvis. The external condyle is marked upon its outer side by a prominent tuberosity, which gives attachment to the external lateral ligaments; and immediately beneath this is the groove which lodges the tendinous origin of the popliteus. By the internal surface it gives attachment to the anterior crucial ligament of the knee-joint; and by its upper and posterior part, to the external head of the gastrocnemius and to the plantaris. The *internal condyle* projects upon its inner side into a tuberosity, to which is attached the internal lateral ligament; above this tuberosity, at the extremity of the internal condyloid ridge, is a tubercle, for the insertion of the tendon of the adductor magnus; and beneath the tubercle, upon the upper surface of the condyle, a depression, from which the internal head of the gastrocnemius arises. The outer side of the internal condyle is rough and concave, for the attachment of the posterior crucial ligament.

Fig. 41.



Development.—By five centres; one for the shaft, one for each extremity, and one for each trochanter.

Articulations.—With three bones; with the os innominatum, tibia, and patella.

Attachment of Muscles.—To twenty-three; by the greater trochanter, to the gluteus medius and minimus, pyriformis, gemellus superior, obturator internus, gemellus inferior, obturator externus, and quadratus femoris; by the lesser trochanter, to the common tendon of the psoas and iliacus. By the linea aspera, its outer lip, to the vastus externus, gluteus maximus, and short head of the biceps; by its inner lip, to the vastus internus, pectineus, adductor brevis, and adductor longus; by its middle to the adductor magnus; by the anterior part of the bone, to the cruræus and subcruræus; by its condyles, to the gastrocnemius, plantaris and popliteus.

Fig. 41. A diagram of the posterior aspect of the right femur, showing the lines of attachment of the muscles. The muscles attached to the inner lip are,—*p*, the pectineus; *a b*, the adductor brevis; and *a l*, the adductor longus. The middle portion is occupied for its whole extent by *a m*, the adductor magnus; and is continuous superiorly with *g f*, the linea quadrati, into which the quadratus femoris is inserted. The outer lip is occupied by *g m*, the gluteus maximus; and *b*, the short head of the biceps.

PATELLA.—The patella is a sesamoid bone, developed in the tendon of the quadriceps extensor muscle, and usually described as a bone of the lower extremity. It is heart-shaped in figure, the broad side being directed upwards and the apex downwards, the external surface convex, and the internal divided by a ridge into two smooth surfaces, to articulate with the condyles of the femur. The external articular surface corresponding with the external condyle is the larger of the two, and serves to indicate the leg to which the bone belongs.

Articulations.—With the two condyles of the femur.

Attachment of Muscles.—To four; the rectus, cruræus, vastus internus, and vastus externus, and to the ligamentum patellæ.

TIBIA.—The tibia is the large bone of the leg; it is prismoid in form, and divisible into a shaft, an upper and lower extremity.

The *upper extremity*, or head, is large, and expanded on each side into two *tuberosities*. Upon the upper surface the tuberosities are smooth, to articulate with the condyles of the femur; the internal articular surface being oval and oblong, to correspond with the internal condyle; and the external broad and nearly circular. Between the two articular surfaces is a *spinous process*; and in front and behind the spinous process a rough depression giving attachment to the anterior and posterior crucial ligaments. Between the two tuberosities on the front aspect of the bone is a prominent elevation,—the *tubercle*,—for the insertion of the ligamentum patellæ, and immediately above the tubercle, a smooth surface corresponding with a bursa. Upon the outer side of the external tuberosity is an articular surface, for the head of the fibula; and upon the posterior part of the internal tuberosity a depression, for the insertion of the tendon of the semi-membranosus muscle.

The *shaft* of the tibia presents three surfaces; *internal*, which is subcutaneous and superficial; *external*, which is concave and marked by a sharp ridge, for the insertion of the interosseous membrane; and *posterior*, grooved for the attachment of muscles. Near the upper extremity of the posterior surface, is an oblique ridge,—the *popliteal line*, for the attachment of the fascia of the popliteus muscle; and immediately below the oblique line, the nutritious canal, which is directed downwards.

The *inferior extremity* of the bone is somewhat quadrilateral, and

Fig. 42.



Fig. 42. The tibia and fibula of the right leg, articulated and seen from the front. 1. The shaft of the tibia. 2. The inner tuberosity. 3. The outer tuberosity. 4. The spinous process. 5. The tubercle. 6. The internal subcutaneous surface of the shaft. 7. The lower extremity of the tibia. 8. The internal malleolus. 9. The shaft of the fibula. 10. Its upper extremity. 11. Its lower extremity, the external malleolus.

prolonged on its inner side into a large process, the *internal malleolus*. Behind the internal malleolus, is a broad and shallow groove, for lodging the tendons of the tibialis posticus and flexor longus digitorum; and farther outwards another groove, for the tendon of the flexor longus pollicis. Upon the outer side the surface is concave and triangular,—rough above, for the attachment of the interosseous ligament; and smooth below, to articulate with the fibula. Upon the extremity of the bone is a triangular smooth surface, for articulating with the astragalus.

Development.—By three centres; one for the shaft, and one for each extremity.

Articulations.—With three bones; femur, fibula, and astragalus.

Attachment of Muscles.—To ten; by the internal tuberosity, to the sartorius, gracilis, semitendinosus, and semimembranosus; by the external tuberosity, to the tibialis anticus and extensor longus digitorum; by the tubercle, to the ligamentum patellæ; by the external surface of the shaft, to the tibialis anticus; and by the posterior surface, to the popliteus, soleus, flexor longus digitorum, and tibialis posticus.

FIBULA.—The fibula is a long and slender prismoid bone, divisible into a shaft and two extremities.

The *superior extremity* or head is thick and large, and depressed upon the upper part by a concave surface, which articulates with the external tuberosity of the tibia. Externally to this surface is a thick and rough prominence, for the attachment of the external lateral ligaments of the knee-joint, terminated behind by a styloid process, for the insertion of the tendon of the biceps.

The *lower extremity* is flattened from without inwards, and prolonged downwards beyond the articular surface of the tibia, forming the *external malleolus*. Its external side presents a rough and triangular surface, which is subcutaneous. Upon the internal surface is a smooth triangular facet, to articulate with the astragalus; and a rough depression, for the attachment of the interosseous ligament. The *anterior border* is thin and sharp, and the *posterior*, broad and grooved, for the tendons of the peronei muscles.

To place the bone in its proper position, and ascertain to which leg it belongs, let the inferior or flattened extremity be directed downwards, and the narrow border of the malleolus forwards; the triangular subcutaneous surface will then point to the side corresponding with the limb of which the bone forms a part.

The *shaft* of the fibula is prismoid, and presents three surfaces; external, internal, and posterior; and three borders. The *external surface* is the broadest of the three; it commences upon the anterior part of the bone above, and curves around it so as to terminate upon its posterior side below. The surface is completely occupied by the two peronei muscles. The *internal surface* commences on the side of the superior articular surface, and terminates below, by narrowing to a ridge, which is continuous with the anterior border

of the malleolus. It is marked along its middle by the *interosseous ridge*, which is lost above and below in the inner border of the bone.

The *posterior surface* is twisted like the external, it commences above on the posterior side of the bone, and terminates below on its internal side; at about its middle is the *nutritious foramen*, which is directed downwards.

The *internal border* commences superiorly in common with the interosseous ridge, and bifurcates inferiorly into two lines, which bound the triangular subcutaneous space of the external malleolus. The *external border* begins at the base of the styloid process upon the head of the fibula, and winds around the bone, following the direction of the corresponding surface. The *posterior border* is sharp and prominent, and is lost inferiorly in the interosseous ridge.

Development.—By three centres; one for the shaft, and one for each extremity.

Articulations.—With the tibia and astragalus.

Attachment of Muscles.—To nine; by the head, to the tendon of the biceps and soleus; by the shaft,—its external surface,—to the peroneus longus and brevis; internal surface, to the extensor longus digitorum, extensor proprius pollicis, peroneus tertius, and tibialis posticus; by the posterior surface, to the popliteus and flexor longus pollicis.

TARSUS.—The bones of the tarsus are seven in number; viz. the astragalus, os calcis, scaphoid, internal, middle, and external cuneiform and cuboid.

The **ASTRAGALUS** may be recognised by a rounded head, a broad articular facet upon its convex surface, and two articular facets, separated by a deep groove, upon its concave surface.

The bone is divisible into a superior and inferior surface, an external and internal border, and an anterior and posterior extremity. The *superior surface* is convex, and presents a large quadrilateral and smooth facet, somewhat broader in front than behind, to articulate with the tibia. The *inferior surface* is concave, and divided by a deep and rough groove, which lodges a strong interosseous ligament, into two facets—the posterior large and quadrangular, and the anterior smaller and elliptic,—which articulate with the os calcis. The *internal border* is flat and irregu-

Fig. 43.

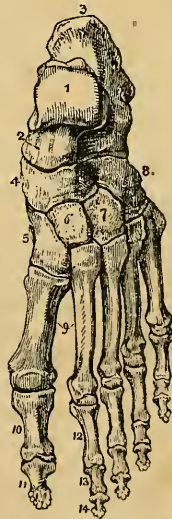


Fig. 43. The dorsal surface of the left foot. 1. The astragalus; its superior quadrilateral and articular surface. 2. The anterior extremity of the astragalus, which articulates with (4) the scaphoid bone. 3. The os calcis. 4. The scaphoid bone. 5. internal cuneiform bone. 6. The middle cuneiform bone. 7. The external cuneiform bone 8. The cuboid bone. 9. The metatarsal bones of the first and second toes. 10. The first phalanx of the great toe. 11. The second phalanx of the great toe. 12. The first phalanx of the second toe. 13. Its second phalanx. 14. Its third phalanx.

lar, and marked by a pyriform articular surface, for the inner malleolus. The *external* presents a large triangular articular facet, for the external malleolus, and is rough and concave in front. The *anterior extremity* presents a rounded head, surrounded by a constriction somewhat resembling a neck; and the *posterior extremity* is narrow, and marked by a deep groove, for the tendon of the flexor longus pollicis.

Hold the astragalus with the broad articular surface upwards, and the rounded head forwards; the triangular lateral articular surface will point to the side to which the bone belongs.

Articulations.—With four bones; tibia, fibula, calcis and scaphoid.

The OS CALCIS may be known by its large size and oblong figure, by the large and irregular portion which forms the heel, and by two articular surfaces, separated by a deep groove upon its upper side.

The os calcis is divisible into four surfaces,—superior, inferior, external, and internal; and two extremities,—anterior and posterior. The *superior surface* is convex behind and irregularly concave in front, where it presents two and sometimes three articular facets, divided by a broad and shallow groove, for the interosseous ligament. The *inferior surface* is convex and rough, and bounded posteriorly by the two inferior tuberosities, of which the internal is broad and large, and the external smaller and prominent. The *external surface* is convex and subcutaneous, and marked towards its anterior third by two grooves, often separated by a tubercle for the tendons of the peroneus longus and brevis. The *internal surface* is concave and grooved, for the tendons and vessels which pass into the sole of the foot. At the anterior extremity of this surface is a projecting process, which supports the anterior articulating surface for the astragalus, and serves as a pulley to the tendon of the flexor longus digitorum. Upon the *anterior extremity* is a flat articular surface surmounted by a rough projection, which affords one of the guides to the surgeon in the performance of Chopart's operation. The *posterior extremity* is prominent and convex, and constitutes the *posterior tuberosity*; it is smooth for the upper half of its extent, where it corresponds with a bursa; and rough below, for the insertion of the tendo Achillis; the lower part of this surface is bounded by the two inferior tuberosities.

Articulations.—With two bones; the astragalus and cuboid.

Attachment of Muscles.—To nine; by the posterior tuberosity, to the tendo Achillis and plantaris; by the inferior tuberosities and under surface, to the abductor pollicis, abductor minimi digiti, flexor brevis digitorum, flexor accessorius, and flexor brevis pollicis, and to the plantar fascia; and by the external surface, to the extensor brevis digitorum.

The SCAPHOID bone may be distinguished by its boat-like figure, concave on one side, and convex with three facets upon the other. It presents for examination an anterior and posterior surface, a superior and inferior border, and two extremities—one broad, the other

pointed and thick. The *anterior surface* is convex, and divided into three facets, to articulate with the three cuneiform bones; and the *posterior* concave, to articulate with the rounded head of the astragalus. The *superior border* is convex and rough, and the *inferior* somewhat concave and irregular. The *external extremity* is broad and rough, and the *internal* pointed and projecting, so as to form a tuberosity.

If the bone be held so that the convex surface with three facets look forwards, and the convex border upwards, the broad extremity will point to the side corresponding with the foot to which the bone belongs.

Articulations.—With *four* bones; astragalus and three cuneiform bones.

Attachment of Muscles.—To the tendon of the tibialis posticus.

The INTERNAL CUNEIFORM may be known by its irregular wedge-shape, and by being larger than the two other bones bearing the same name. It presents for examination a convex and a concave surface, a long and a short articular border, and a small and a large extremity.

Place the bone so that the small extremity may look upwards and the long articular border forwards, the concave surface will point to the side corresponding with the foot to which it belongs.

The *convex surface* is internal and free, and assists in forming the inner border of the foot, and the *concave* is external, and in apposition with the middle cuneiform and second metatarsal bone; the *long border* articulates with the metatarsal bone of the great toe, and the *short border* with the scaphoid bone. The small extremity is sharp, and the larger extremity rounded into a broad tuberosity.

Articulations.—With *four* bones; a scaphoid, middle cuneiform, and the two first metatarsal bones.

Attachment of Muscles.—To the tibialis anticus, and posticus.

The MIDDLE CUNEIFORM is the smallest of the three; it is wedge-shaped, the broad extremity being placed upwards, and the sharp end downwards in the foot. It presents for examination four articular surfaces and two extremities. The *anterior* and *posterior surfaces* have nothing worthy of remark. One of the *lateral surfaces* has a long articular facet, extending its whole length for the internal cuneiform; the *other* has only a partial articular facet for the external cuneiform bone.

If the bone be held so that the square extremity looks upwards, the broadest side of the square being towards the holder, the small and partial articular surface will point to the side to which the bone belongs.

Articulations.—With *four* bones; scaphoid, internal and external cuneiform, and second metatarsal bone.

Attachment of Muscles.—To the flexor brevis pollicis.

The EXTERNAL CUNEIFORM is intermediate in size between the two preceding, and placed, like the middle, with the broad end upwards and the sharp extremity downwards. It presents for examination

five surfaces, and a superior and an inferior extremity. The *upper extremity* is flat, of an oblong square form, and bevelled posteriorly at the expense of the outer surface, into a sharp edge.

If the bone be held so that the square extremity look upwards and the sharp border backwards, the bevelled surface will point to the side corresponding with the foot to which the bone belongs.

Articulations.—With *six* bones; scaphoid, middle cuneiform, cuboid, and second, third, and fourth metatarsal bones.

Attachment of Muscles.—To its inferior extremity, the flexor brevis pollicis.

The CUBOID BONE is irregularly cuboid in form, and marked upon its under surface by a deep groove, for the tendon of the peroneus longus muscle. It presents for examination six surfaces, three articular and three non-articular. The *non-articular surfaces* are the *superior*, which is slightly convex, and assists in forming the dorsum of the foot; the *inferior*, marked by a prominent ridge and a deep groove, for the tendon of the peroneus longus; and an *external*, the smallest of the whole, and deeply notched by the commencement of the peroneal groove. The *articular surfaces* are the *posterior*, which is of large size, and concavo-convex, to articulate with the os calcis; *anterior*, of smaller size, divided by a ridge into two facets for the fourth and fifth metatarsal bones; and *internal*, a small oval articular facet, upon a large and quadrangular surface, for the external cuneiform bone.

If the bone be held so that the plantar surface, with the peroneal groove, look downwards, and the largest articular surface backwards, the small non-articular surface, marked by the deep notch, will point to the side corresponding with the foot to which the bone belongs.

Articulations.—With *four* bones; os calcis, external cuneiform, and fourth and fifth metatarsal bones.

Attachment of Muscles.—To *three*; the flexor brevis pollicis, adductor pollicis, and flexor brevis minimi digiti.

Upon a consideration of the tarsus it will be observed, that each bone articulates with four adjoining bones, with the exception of the os calcis, which articulates with two, and the external cuneiform with six.

Development.—By a single centre for each bone, with the exception of the os calcis, which has two centres of ossification; the second centre makes its appearance at about the ninth year, and is not united with the preceding until the fifteenth.

The METATARSAL BONES, *five* in number, are long bones, and divisible therefore into a shaft and two extremities. The shaft is prismoid, and compressed from side to side; the posterior extremity, or base, is square-shaped, to articulate with the tarsal bones and with each other; and the anterior extremity presents a rounded head, circumscribed by a neck, to articulate with the first row of phalanges.

Peculiar Metatarsal Bones.—The first is shorter and larger than the rest, forming the inner border of the foot; its posterior extremity presents only one articular surface on the side, and an oval rough surface upon a prominent process beneath, for the insertion of the tendon of the peroneus longus. The anterior extremity has, upon its plantar surface, two grooved facets, for sesamoid bones.

The *second* is the longest and largest of the remaining metatarsal bones; it presents at its base three articular facets, for the three cuneiform bones; a large oval facet, but often no articular surface, on its inner side, to articulate with the metatarsal bone of the great toe, and two externally for the metatarsal bone.

The *third* may be known by two facets upon the outer side of its base, corresponding with the second, and may be distinguished by its smaller size.

The *fourth* may be distinguished by its smaller size, and by having a single articular surface on each side of the base.

The *fifth* is recognised by its broad base, and by the absence of an articular surface upon its outer side.

Development.—Each bone by *two* centres; one for the body and one for the digital extremity in the four outer metatarsal bones; and one for the body, the other for the base in the metatarsal bone of the great toe.

Articulations.—With the tarsal bones by one extremity, and with the first row of phalanges by the other. The number of tarsal bones with which each metatarsal articulates from within outwards, is the same as between the metacarpus and carpus,—one for the first, three for the second, one for the third, two for the fourth, and one for the fifth; forming the cipher 13121.

Attachment of Muscles.—To *fourteen*; to the first, the peroneus longus and first dorsal interosseous muscle; to the second, two dorsal interossei and transversus pedis; to the third, two dorsal and one plantar interosseous, adductor pollicis and transversus pedis; to the fourth, two dorsal and one plantar interosseous and adductor pollicis; to the fifth, one dorsal and one plantar interosseous, pero-

Fig. 44.

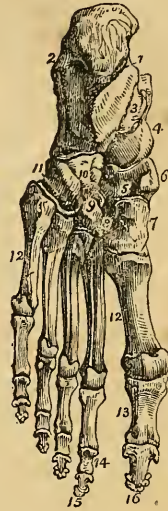


Fig. 44. The sole of the left foot. 1. The inner tuberosity of the os calcis. 2. The outer tuberosity. 3. The groove for the tendon of the flexor longus digitorum. 4. The rounded head of the astragalus. 5. The scaphoid bone. 6. Its tuberosity. 7. The internal cuneiform bone; its broad extremity. 8. The middle cuneiform bone. 9. The external cuneiform bone. 10, 11. The cuboid bone. 11. Refers to the groove for the tendon of the peroneus longus. 12, 12. The metatarsal bones. 13, 13. The first phalanges. 14, 14. The second phalanges of the four lesser toes. 15, 15. The third, or ungual phalanges of the four lesser toes. 16. The last phalanx of the great toe.

neus brevis, peroneus tertius, abductor minimi digiti, flexor brevis minimi digiti, and transversus pedis.

PHALANGES.—There are two phalanges in the great toe, and three in the other toes, as in the hand. They are long bones, divisible into a central portion and extremities.

The phalanges of the first row are convex above, concave upon the under surface, and compressed from side to side. The posterior extremity has a single concave articular surface, for the head of the metatarsal bone; and the anterior extremity, a pulley-like surface, for the second phalanx.

The *second phalanges* are short and diminutive, but somewhat broader than the first row.

The *third, or ungual phalanges*, including the second phalanx of the great toe, are flattened from above downwards, and spread out laterally at the base, to articulate with the second row, and, at the opposite extremity, to support the nail and the rounded extremity of the toe.

Development.—By two centres; one for the body and one for the metacarpal extremity.

Articulations.—The first row with the metatarsal bones and second phalanges; the second, of the great toe with the first phalanx, and of the other toes with the first and third phalanges; and the third, with the second row.

Attachment of Muscles.—To *twenty-three*; to the *first phalanges*; *great toe*, the innermost tendon of the extensor brevis digitorum, abductor pollicis, adductor pollicis, flexor brevis pollicis, and transversus pedis; *second toe*, first dorsal and first palmar interosseous and lumbricalis; *third toe*, second dorsal and second palmar interosseous and lumbricalis; *fourth toe*, third dorsal and third palmar interosseous and lumbricalis; *fifth toe*, fourth dorsal interosseous, abductor minimi digiti, flexor brevis minimi digiti, and lumbricalis. *Second phalanges*; *great toe*, extensor longus pollicis, and flexor longus pollicis; *other toes*, one slip of the common tendon of the extensor longus digitorum, and extensor brevis digitorum, and flexor brevis digitorum. *Third phalanges*; two slips of the common tendon of the extensor longus and extensor brevis digitorum, and the flexor longus digitorum.

SESAMOID BONES.—These are small osseous masses, developed in those tendons which exert a certain degree of force upon the surface over which they glide, or where, by continued pressure and friction, the tendon would become a source of irritation to neighbouring parts, as to joints. The best example of a sesamoid bone is the patella, developed in the common tendon of the quadriceps extensor, and resting upon the front of the knee-joint. Besides the patella, there are four pairs of sesamoid bones included in the number of pieces which compose the skeleton, two upon the metacarpophalangeal articulation of each thumb, and existing in the tendons of insertion of the flexor brevis pollicis, and two upon the corresponding joint in the foot, in the tendons of the muscles inserted into the

base of the first phalanx. In addition to these there is often a sesamoid bone upon the metacarpophalangeal joint of the little finger, and upon the corresponding joint in the foot, in the tendons inserted into the base of the first phalanx; there is one also in the tendon of the peroneus longus muscle, where it glides through the groove in the cuboid bone; sometimes in the tendons, as they wind around the inner and outer malleolus; in the psoas and iliacus, where they glide over the body of the os pubis; and in the external head of the gastrocnemius.

The bones of the tympanum, belonging to the apparatus of hearing, will be described with the anatomy of the ear.

CHAPTER II.

ON THE LIGAMENTS.

THE bones are variously connected with each other in the construction of the skeleton, and the connexion between any two bones constitutes a joint or articulation. If the joint be immovable, the surfaces of the bones are applied in direct contact; but if motion be intended, the opposing surfaces are expanded, and coated by an elastic substance, named cartilage; a fluid secreted by a membrane closed on all sides lubricates their surface, and they are firmly held together by means of short bands of glistening fibres, which are called ligaments (ligare, to bind). The study of ligaments is named syndesmology (σύν together, δεσμός, bond), which, with the anatomy of the articulations, forms the subject of the present chapter.

The forms of articulation met with in the human frame may be considered under three classes:—Synarthrosis, Amphi-artrosis and Diarthrosis.

SYNARTHROSIS (σύν, ἄρθρωσις, articulation) is expressive of the fixed form of joint in which the bones are immovably connected with each other. The kinds of synarthrosis are four in number. 1. *Sutura*. 2. *Harmonia*. 3. *Schindylesis*. 4. *Gomphosis*. The characters of the three first have been sufficiently explained in the preceding chapter, p. 74. It is here only necessary to state that in the construction of sutures, the substance of the bones is not in immediate contact, but it is separated by a layer of membrane which is continuous externally with the pericranium and internally with the dura mater. It is the latter connexion which gives rise to the great difficulty sometimes experienced in tearing the calvarium from the dura mater. Cruveilhier describes this interposed membrane as the *sutural cartilage*: I never saw any structure in the sutures, which could be regarded as cartilage, and the history of the formation of the cranial bones would seem to point to a different explanation. The fourth, Gomphosis (γόμφος, a nail) is expressive of the insertion of one bone into another, in the same manner that a nail is fixed into a board; this is illustrated in the articulation of the teeth with the alveoli of the maxillary bones.

AMPHI-ARTHROSIS (ἀμφί, both, ἄρθρωσις) is a joint intermediate in aptitude for motion between the immovable synarthrosis and the movable diarthrosis. It is constituted by the approximation of surfaces partly coated with cartilage lined by synovial membrane, and partly connected by the interosseous ligaments, or by the interven-

tion of an elastic fibro-cartilage which adheres to the ends of both bones. Examples of this articulation are seen in the union between the bodies of the vertebræ, of the sacrum with the coccyx, of the two first pieces of the sternum, the sacro-iliac and pubic symphyses, (*σύν, φέειν*, to grow together), and according to some, of the necks of the ribs, with the transverse processes.

DIARTHROSIS (*διά*, through, *ἀρθρωσις*) is the movable articulation, which constitutes by far the greater number of the joints of the body. The degree of motion in this class has given rise to a subdivision into three genera, *Arthrodia*, *Ginglymus*, and *Enarthrosis*.

Arthrodia is the movable joint in which the extent of motion is slight and limited, as in the articulation of the clavicle, of the ribs, articular processes of the vertebræ, axis with the atlas, radius with the ulna, fibula with the tibia, carpal and metacarpal, tarsal and metatarsal bones.

Ginglymus (*γίγγλυμος*, a hinge) or hinge-joint, is the movement of bones upon each other in two directions only, viz. forwards and backwards; but the degree of motion may be very considerable. The instances of this form of joint are numerous; they comprehend the elbow, wrist, metacarpo-phalangeal and phalangeal joints in the upper extremity; and the knee, ankle, metatarso-phalangeal and phalangeal joints in the lower extremity. The lower jaw may also be admitted into this category, as partaking more of the character of the hinge-joint than of the less movable *arthrodia*.

The form of the ginglymoid joint is somewhat quadrilateral, and each of its four sides is provided with a ligament, which is named from its position, *anterior*, *posterior*, *internal* or *external lateral*. The *lateral ligaments* are thick and strong, and are the chief bond of union between the bones. The *anterior* and *posterior* are thin and loose in order to permit the required extent of movement.

Enarthrosis (*ἐν*, in, *ἀρθρωσις*) is the most extensive in its range of motion of all movable joints. From the manner of connexion and form of the bones in this articulation, it is called the ball and socket joint. There are three instances in the body, viz. the hip, the shoulder, and the articulation of the metacarpal bone of the thumb with the trapezium.

The ball and socket joint has a circular form; and, in place of the four distinct ligaments of the ginglymus, is enclosed in a bag of ligamentous membrane, called a *capsular ligament*.

The kinds of articulation may probably be conveyed in a more satisfactory manner in the tabular form, thus:

Examples.

Synarthrosis	{	Sutura bones of the skull.
		Harmonia . . . superior maxillary bones.
		Schindylesis . . vomer with rostrum.
		Gomphosis . . . teeth with alveoli.
Amphi-artrosis		Bodies of the vertebræ . Symphyses.
Diarthrosis	{	Arthrodia . . . carpal and tarsal bones.
		Ginglymus . . . elbow, wrist, knee, ankle.
		Enarthrosis . . hip, shoulder.

The motions permitted in joints may be referred to four heads, viz.: 1. Gliding. 2. Angular movement. 3. Circumduction. 4. Rotation.

1. *Gliding* is the simple movement of one articular surface upon another, and exists to a greater or less extent in all the joints. In the least movable joints, as in the carpus and tarsus, this is the only motion which is permitted.

2. *Angular movement* may be performed in four different directions, either forwards and backwards, as in flexion and extension; or inwards and outwards, constituting adduction and abduction. Flexion and extension are illustrated in the ginglymoid joint, and exist in a large proportion of the joints of the body. Adduction and abduction conjoined with flexion and extension, are met with complete only in the most movable joints, as in the shoulder, the hip, and the thumb. In the wrist and in the ankle adduction and abduction are only partial.

3. *Circumduction* can be performed only in the shoulder and hip joints; it consists in the slight degree of motion which takes place in the head of a bone against its articular cavity, while the extremity of the limb is made to describe a large circle upon a plane surface.

4. *Rotation* is the movement of a bone upon its own axis, and is illustrated in the hip and shoulder, or better in the rotation of the cup of the radius, against the rounded articular protuberance of the humerus. Rotation is also observed in the movements of the atlas upon the axis, in which the odontoid process serves as a pivot around which the atlas turns.

The structures entering into the composition of a joint are bone, cartilage, fibro-cartilage, ligament, and synovial membrane.

Cartilage is an elastic and apparently homogeneous substance of a pearly whiteness, which forms the thin incrustation upon the articular surfaces of bones. Upon convex surfaces it is thickest in the centre, and thin towards the circumference, and presents upon concave surfaces an opposite arrangement. It is composed of a number of minute fibres placed perpendicularly to the surface, attached by one extremity to the bone, and forming by the other a smooth plane, covered by synovial membrane.

Fibro-cartilage, as expressed in its name, is a compound structure, consisting in the combination of fibrous and cartilaginous tissues in variable proportions. It is found in joints under three forms: 1. Of interarticular fibro-cartilages. 2. Of fibro-cartilages of circumference. 3. Of intervertebral substance.

The *interarticular fibro-cartilages* (menisci,) composed chiefly of cartilage, are found in the articulations of the lower jaw, sternal and acromial end of the clavicle, knee and wrist-joint. The triangular cartilage of the wrist is not admitted by Dr. Todd* among the fibro-cartilages, but is considered by him to be merely an exten-

* Cyclopædia of Anatomy and Physiology, article, ARTICULATION.

sion of the cartilaginous incrustation of the inferior extremity of the radius.

The *fibro-cartilages of circumference* contain a large proportion of fibrous tissue; they are situated upon the margins of the glenoid and cotyloid cavities, and serve to deepen those articulations, and at the same time to protect the edges from injurious pressure.

The *intervertebral substance* is composed of concentric lamellæ of fibrous structure, surrounding, towards the centre, a soft cartilaginous and almost pulpy mass. The fibres of which the lamellæ are formed, interlace with each other obliquely; the intervening meshes being filled with a soft cartilaginous substance, and becoming larger towards the central pulp.

Ligament is composed of numerous straight fibres collected together, and arranged into short bands (fasciculi) of various breadth, or interwoven so as to form a broad layer, which completely surrounds the articular extremities of the bones, and constitutes a capsular ligament.

All the ligaments of the joints consist of fibres of this kind, which are white, glistening and inelastic. But besides these there are other ligaments, which are composed of *yellow elastic tissue*, and serve to connect parts which are subject to frequent and considerable separation, as the arches of the vertebræ, where they form the ligamenta subflava.

The *synovial membrane* is a thin membranous layer, which invests the articular cartilages of the bones, and is thence reflected upon the surfaces of the ligaments which surround and enter into the composition of a joint. It resembles the serous membranes in being a shut sac, and secretes a transparent and viscous fluid, which is named synovia. Synovia is an alkaline secretion, containing albumen, which is coagulable at a boiling temperature. The continuation of this membrane over the surface of the articular cartilage, a much agitated question, has lately been decided by the interesting discoveries of Henle, who has ascertained the existence of an epithelium upon cartilage identical with that secreted by the reflected portion of the membrane. In some of the joints the synovial membrane is pressed into the articular cavity by a cushion of fat, which serves the purpose of facilitating the movements of the surfaces. This mass was called by Havers the synovial gland, from an incorrect supposition that it was the source of the synovia. It is found in the hip and in the knee-joint. In the knee-joint, moreover, the synovial membrane forms folds, which are most improperly named ligaments,—as the mucous and alar ligaments,—the two latter being an appendage to the cushion of fat. Besides the synovial membranes entering into the composition of joints, there are numerous smaller sacs of a similar kind interposed between surfaces which move upon each other so as to cause friction; they are often associated with the articulations. These are the *bursæ mucosæ*; they are shut sacs, analogous in structure to synovial membranes, and secreting a similar synovial fluid.

ARTICULATIONS.

The joints may be arranged, according to a natural division, into those of the trunk, those of the upper extremity, and those of the lower extremity.

LIGAMENTS OF THE TRUNK.—The articulations of the trunk are divisible into nine groups, viz. :

1. Of the vertebral column.
2. Of the atlas with the occipital bone.
3. Of the axis, with the occipital bone.
4. Of the atlas, with the axis.
5. Of the lower jaw.
6. Of the ribs, with the vertebræ.
7. Of the ribs, with the sternum, and with each other.
8. Of the vertebral column, with the pelvis.
9. Of the pelvis.

1. *Articulation of the Vertebral Column.*—The ligaments connecting together the different pieces of the vertebral column, admit of the same arrangement with that of the vertebræ themselves. Thus the ligaments

Of the <i>bodies</i> are the—	Anterior common ligament. Posterior common ligament. Intervertebral substance.
Of the <i>arches</i> ,—	Ligamenta subflava.
Of the <i>articular processes</i> ,—	Capsular ligaments. Synovial membranes.
Of the <i>spinous processes</i> ,—	Inter-spinous. Supra-spinous.
Of the <i>transverse processes</i> ,—	Inter-transverse.

BODIES.—The *anterior common ligament* is a broad and riband-like band of ligamentous fibres, extending along the front surface of the vertebral column, from the axis to the sacrum. It is intimately connected with the intervertebral substances, and less closely with the bodies of the vertebræ.

The anterior common ligament is thicker in the dorsal than in the cervical and lumbar regions, and consists of a median and two lateral portions, separated from each other by a series of openings for the passage of vessels. The ligament is composed of fibres of various length closely interwoven with each other; the *deeper* and shorter crossing the intervertebral substances from one vertebra to the next; and the *superficial* and longer fibres crossing three or four vertebræ.

Relations.—The anterior common ligament is in relation by its *posterior* or *vertebral surface*, with the intervertebral substances, the

bodies of the vertebræ and with the vessels, principally veins, which separate its central from its lateral portions. By its *anterior* or *visceral surface* it is in relation in the neck, with the longus colli muscles, the pharynx and the œsophagus; in the thoracic region, with the aorta, the vena azygos, and thoracic duct; and in the lumbar region, with the aorta, right renal artery, right lumbar arteries, arteria sacra media, vena cava inferior, left lumbar veins, receptaculum chyli, the commencement of the thoracic duct, and the tendons of the lesser muscle of the diaphragm with the fibres of which the ligamentous fibres interlace.

The *posterior common ligament* lies upon the posterior surface of the bodies of the vertebræ, and extends from the axis to the sacrum. It is broad opposite the intervertebral substances, to which it is closely adherent; and narrow and thick over the bodies of the vertebræ, from which it is separated by the veins of the base of the vertebræ. It is composed like the anterior ligament of shorter and longer fibres which are disposed in a similar manner.

Relations.—The posterior common ligament is in relation by its *anterior surface* with the intervertebral substances, the bodies of the vertebræ, and with the venæ basis vertebræ; and by its *posterior surface* with the dura mater of the spinal cord, some loose cellular tissue and numerous small veins being interposed.

The *intervertebral substance* is a lenticular disc of fibro-cartilage, interposed between each of the vertebræ from the axis to the sacrum, and retaining them firmly in connexion with each other. It differs in thickness in different parts of the column, and varies in depth at different points of its extent; thus, it is thickest in the lumbar region, deepest in front in the cervical and lumbar regions, and behind in the dorsal region; and contributes, in a great measure, to the formation of the natural curves of the vertebral column.

ARCHES.—The *ligamenta subflava* are composed of yellow elastic tissue, and are situated between the arches of the vertebræ, from the axis to the sacrum. From the imbricated position of the laminae they are attached to the posterior surface of the vertebra below, and to the anterior surface of the arch of the vertebra above, and are separated from each other at the middle line by a slight fissure. They counteract, by their elasticity, the efforts of the flexor muscles

Fig. 45.

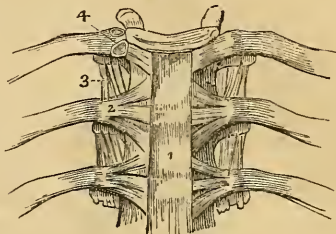


Fig. 45. The anterior ligaments of the vertebræ, and ligaments of the ribs. 1. The anterior common ligament. 2. The anterior costo-vertebral or stellate ligament. 3. The anterior costo-transverse ligament. 4. The interarticular ligament connecting the head of the rib to the intervertebral substance, and separating the two synovial membranes of this articulation.

of the trunk; and by preserving the upright position of the spine, limit the expenditure of muscular force. They are longer in the cervical than in the other regions of the spine, and are thickest in the lumbar region.

Fig. 46.

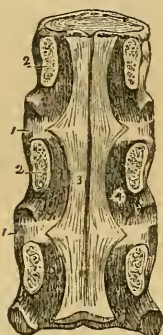
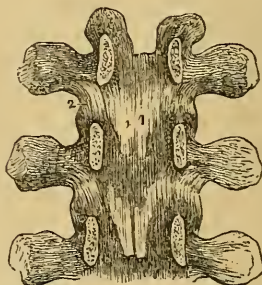


Fig. 47.



Relations.—The ligamenta subflava are in relation by both surfaces with the meningo-rachidian veins, and internally they are separated from the dura mater of the spinal cord by those veins and some loose cellular tissue.

ARTICULAR PROCESSES.—The ligaments of the articular processes of the vertebræ, are loose synovial *capsules*, which surround the articulating surfaces. They are protected on their external side by a thin layer of ligamentous fibres.

SPINOUS PROCESSES.—The *inter-spinous* ligaments are thin and membranous, and are extended between the spinous process in the dorsal and lumbar regions. They are thickest in the latter region; and are in *relation* with the multifidus spinæ muscle at each side.

The *supra-spinous* ligament is a strong and inelastic fibrous cord, which extends from the apex of the spinous process of the last cervical vertebra to the sacrum, being attached to each spinous process in its course; it is thickest in the lumbar region. The continuation of this ligament upwards to the tuberosity of the occipital bone, constitutes the rudimentary ligamentum nuchæ of man. It is strengthened, as in animals, by a thin slip from the spinous process of each of the cervical vertebræ.

TRANSVERSE PROCESSES.—The *inter-transverse ligaments* are thin

Fig. 46. A posterior view of the bodies of three dorsal vertebræ, connected by their intervertebral substance (1, 1.) The laminae (2) have been sawn away near to the bodies of the vertebræ, and the arches and processes removed, in order to show (3) the posterior common ligament. A part of one of the openings in the posterior surface of the vertebra, for the transmission of the vena basis vertebræ, is seen at 4, by the side of the narrow and unattached portion of the ligament.

Fig. 47. An internal view of the arches of the vertebræ. To obtain this view the laminae have been divided through their pedicles. 1. One of the ligamenta subflava. 2. The capsular ligament of one side.

and membranous; they are found only between the transverse processes of the lower dorsal vertebræ.

2. *Articulation of the Atlas with the Occipital bone.*—The ligaments of this articulation are seven in number.

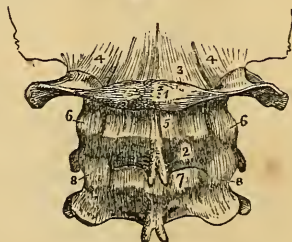
Two anterior occipito-atloid.
 Posterior occipito-atloid.
 Lateral occipito-atloid.
 Two capsular.

Of the two *anterior ligaments* one is a *rounded* cord, situated in the middle line, and superficially to the other. It is attached above, to the basilar process of the occipital bone; and below, to the anterior tubercle of the atlas. The deeper ligament is a *broad* membranous layer, attached above, to the margin of the occipital foramen; and below, to the whole length of the anterior arch of the atlas. It is in relation in front with the recti antici minores and behind with the dura mater.

Fig. 48.

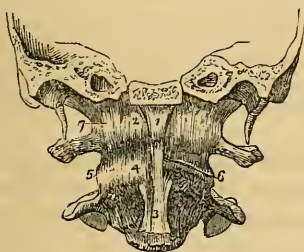

Fig. 49.



The *posterior ligament* is extremely thin and membranous; it is attached above, to the margin of the occipital foramen; and below, to the posterior arch of the atlas. It is closely adherent to the dura mater, by its inner surface; and forms a ligamentous arch at each side, for the passage of the vertebral arteries and first cervical nerves. It is in relation posteriorly with the recti postici minores.

The *lateral ligaments* are strong fasciculi of ligamentous fibres,

Fig. 48. An anterior view of the ligaments connecting the atlas, the axis, and the occipital bone. A transverse section has been carried through the base of the skull, dividing the basilar process of the occipital bone and the petrous portions of the temporal bones. 1. The anterior round occipito-atloid ligament. 2, 2. The anterior broad occipito-atloid ligament. 3. The commencement of the anterior common ligament. 4. The anterior atlo-axoid ligament, which is continuous inferiorly with the commencement of the anterior common ligament. 5. One of the atlo-axoid capsular ligaments; the one on the opposite side (6) has been removed, to show the approximated surfaces of the articular process. 7. One of the occipito-atloid capsular ligaments. The most external of these fibres constitute the lateral occipito-atloid ligament.

Fig. 49. The posterior ligaments of the occipito-atloid, and atlo-axoid articulations. 1. The atlas. 2. The axis. 3. The posterior ligament of the occipito-atloid articulation. 4, 4. The capsular and lateral ligaments of this articulation. 5. The posterior ligaments of the atlo-axoid articulation. 6, 6. Its capsular ligaments. 7. The first of the ligamenta subflava passing between the axis and the third cervical vertebra. 8, 8. Their capsular ligaments.

attached below, to the base of the transverse process of the atlas at each side, and above to the transverse process of the occipital bone. With a ligamentous expansion derived from the vaginal process of the temporal bone, these ligaments form a strong sheath around the vessels and nerves which pass through the carotid and jugular foramen.

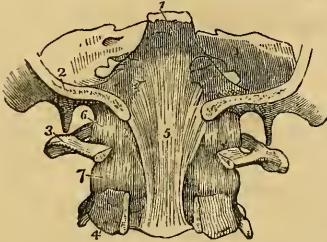
The *capsular ligaments* are the thin and loose ligamentous capsules, which surround the synovial membranes of the articulations, between the condyles of the occipital bone and the superior articular processes of the atlas. The ligamentous fibres are most numerous upon the anterior and external part of the articulation.

The *movements* taking place between the cranium and atlas, are those of flexion and extension, giving rise to the forward nodding of the head. When this motion is increased to any extent the whole of the cervical region concurs in its production.

3. *Articulation of the Axis with the Occipital bone.*—The ligaments of this articulation are *three* in number,—

Occipito-axoid,
Two odontoid.

Fig. 50.



The *occipito-axoid ligament* (*apparatus ligamentosus colli*) is a broad band, which covers in the odontoid process and its ligaments. It is attached below to the body of the axis, and is continuous with the posterior common ligament; superiorly it is inserted by a broad expansion, into the basilar groove of the occipital bone. It is firmly connected opposite the body of the axis, with the *dura mater*. It is sometimes described as consisting of a central and two lateral portions; this however is an unnecessary refinement.

The *odontoid ligaments* (*alar*) are two short and thick fasciculi of fibres, which pass outwards from the apex of the odontoid process, to the sides of the occipital foramen and condyles. A third and smaller fasciculus also proceeds from the apex of the odontoid process, to the anterior margin of the foramen magnum.*

These ligaments serve to limit the extent to which rotation of the head may be carried, hence they are termed *check ligaments*.

4. *Articulation of the Atlas with the Axis.*—The ligaments of this articulation are *five* in number :

Fig. 50. The upper part of the vertebral canal, opened from behind in order to show the occipito-axoid ligament. 1. The basilar portion of the sphenoid bone. 2. Section of the occipital bone. 3. The atlas, its posterior arch removed. 4. The axis, the posterior arch also removed. 5. The occipito-axoid ligament, rendered prominent at its middle by the projection of the odontoid process. 6. Lateral and capsular ligament of the occipito-atloid articulation. 7. Capsular ligament between the articulating process of the atlas and axis.

* Called *middle straight ligament*.—G.

Anterior atlo-axoid.
Posterior atlo-axoid.

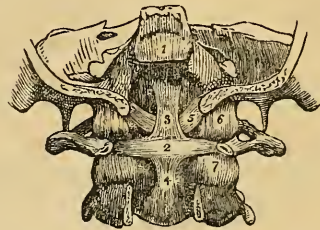
Two capsular.
Transverse.

The *anterior ligament* consists of ligamentous fibres, which pass from the anterior tubercle and arch of the atlas to the base of the odontoid process and body of the axis, where they are continuous with the commencement of the anterior common ligament.*

The *posterior ligament* is a thin and membranous layer, passing between the posterior arch of the atlas and the laminae of the axis.

The *capsular ligaments* surround the articular processes of the atlas and axis; they are loose, to permit of the freedom of movement which subsists between the atlas and axis. The ligamentous fibres are most numerous on the outer and anterior part of the articulation, and the synovial membrane usually communicates with the synovial cavity between the transverse ligament and the odontoid process.

Fig. 51.



The *transverse ligament* is a strong ligamentous band, which arches across the area of the ring of the atlas from a rough tubercle upon the inner surface of one articular process to a similar tubercle on the other. It serves to retain the odontoid process of the axis in connexion with the anterior arch of the atlas. As it crosses the odontoid process, some fibres are sent downwards to be attached to the body of the axis, and others pass upwards to be inserted into the basilar process of the occipital bone;† hence the ligament has a cross-like appearance, and has been denominated *cruciform*. A synovial membrane is situated between the transverse ligament and the odontoid process; and another between that process and the inner surface of the anterior arch of the atlas.

Actions.—It is the peculiar disposition of this ligament in relation to the odontoid process, that enables the atlas, and with it the entire cranium, to rotate upon the axis; the perfect freedom of movement between these bones being insured by the two synovial membranes. The lower part of the ring, formed by the transverse ligament with the atlas, is smaller than the upper, while the summit of the odontoid process is larger than its base; so that the process is still retained in

Fig. 51. A posterior view of the ligaments connecting the atlas, the axis, and the occipital bone. The posterior part of the occipital bone has been sawn away, and the arches of the atlas and axis removed. 1. The superior part of the occipito-axoid ligament, which has been cut away in order to show the ligaments beneath. 2. The transverse ligament of the atlas. 3, 4. The ascending and descending slips of the transverse ligament, which have obtained for it the title of cruciform ligament. 5. One of the odontoid ligaments. 6. One of the occipito-atloid capsular ligaments. 7. One of the atlo-axoid capsular ligaments.

* Usually considered a part of the *anterior vertebral ligament*.—G.

† These bands are called the *appendices* of the transverse ligament.—G.

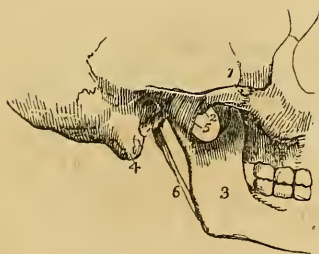
its position by the transverse ligament, when the other ligaments are cut through. The extent to which the rotation of the head upon the axis can be carried is determined by the odontoid ligaments. The odontoid process with its ligaments is covered in by the occipito-axoid ligament.

5. *Articulation of the Lower Jaw.*—The lower jaw has properly but one ligament, the *external lateral*; the ligaments usually described are *three* in number; to which may be added, as appertaining to the mechanism of the joint, an interarticular fibro-cartilage, and two synovial membranes:—

External lateral,
Internal lateral,
Capsular.
Interarticular fibro-cartilage.
Two synovial membranes.

The *external lateral ligament* is a short and thick band of fibres, passing obliquely forwards from the tubercle of the zygoma, to the external surface of the neck of the lower jaw. It is in relation, externally with the integument of the face, and internally with the synovial membranes of the articulation, and with the interarticular fibro-cartilage. The external lateral ligament acts conjointly with its fellow of the opposite side of the head in the movements of the jaw.

Fig. 52.



The *internal lateral ligament* has no connexion with the articulation of the lower jaw, and is incorrectly named in relation to the joint; it is a thin aponeurotic expansion, extending from the extremity of the spinous process of the sphenoid bone to the margin of the dental foramen. It is pierced at its insertion by the mylo-hyoidean nerve.

A triangular space is left between the internal lateral ligament and the neck of the jaw, in which are situated the internal maxillary artery and auricular nerve, the inferior dental artery and nerve, and a part of the external pterygoid muscle; internally it is in relation with the internal pterygoid.

The *capsular ligament* consists of a few irregular ligamentous fibres, which pass from the edge of the glenoid cavity to the neck of the lower jaw, upon the inner and posterior side of the articula-

Fig. 52. An external view of the articulation of the lower jaw. 1. The zygomatic arch. 2. The tubercle of the zygoma. 3. The ramus of the lower jaw. 4. The mastoid portion of the temporal bone. 5. The external lateral ligament. 6. The stylo-maxillary ligament.

tion. These fibres scarcely deserve consideration as a distinct ligament.

The *interarticular fibro-cartilage* is a thin oval plate, thicker at the edges than in the centre, and placed horizontally between the head of the condyle of the lower jaw and the glenoid cavity. It is connected by its outer border with the external lateral ligament, and in front receives some fibres of insertion of the external pterygoid muscles. Occasionally it is incomplete in the centre. It divides the joint into two distinct cavities, the one being above and the other below the cartilage.

The *synovial membranes* are situated the one above, the other below the fibro-cartilage, the former being the larger of the two. When the fibro-cartilage is perforate, the synovial membranes communicate with each other.

Besides the lower jaw, there are several other joints provided with a complete interarticular fibro-cartilage, and consequently, with two synovial membranes; they are, the *sterno-clavicular articulation*, the *acromio-clavicular*, and the *articulation of the ulna with the cuneiform bone*.

The interarticular fibro-cartilages of the *knee joint* are partial, and there is but one synovial membrane.

The articulations of the heads of the ribs with the vertebræ have two synovial membranes, separated by an interarticular ligament without fibro-cartilage.

Actions.—The movements of the lower jaw are *depression*, by

Fig. 53. An internal view of the articulation of the lower jaw. 1. A section through the petrous portion of the temporal bone and spinous process of the sphenoid. 2. An internal view of the ramus, and part of the body of the lower jaw. 3. The internal portion of the capsular ligament. 4. The internal lateral ligament. 5. A small interval at its insertion through which the mylo-hyoidean nerve passes. 6. The stylo-maxillary ligament, a process of the deep cervical fascia.

Fig. 54. In this sketch a section has been carried through the joint, in order to show the natural position of the interarticular fibro-cartilage, and the manner in which it is adapted to the difference of form of the articulating surfaces. 1. The glenoid fossa. 2. The eminentia articularis. 3. The interarticular fibro-cartilage. 4. The superior synovial cavity. 5. The inferior synovial cavity. 6. An interarticular fibro-cartilage, removed from the joint, in order to show its oval and concave form; it is seen from below.

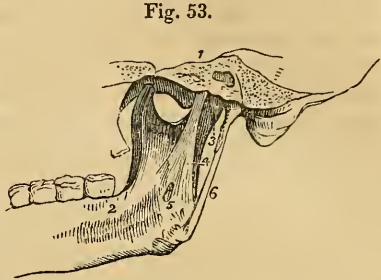


Fig. 53.

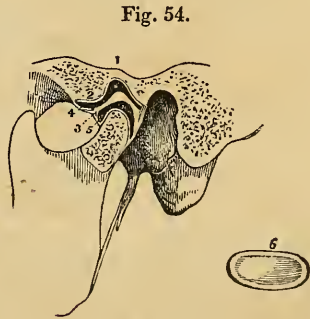


Fig. 54.

which the mouth is opened; *elevation*, by which it is closed; a *forward* and *backward* movement, and a movement from *side* to *side*.

In the movement of *depression* the interarticular cartilage glides forwards on the eminentia articularis, carrying with it the condyle. If this movement be carried too far, the superior synovial membrane is ruptured, and dislocation of the fibro-cartilage with its condyle into the zygomatic fossa occurs. In *elevation* the fibro-cartilage and condyle are returned to their original position. The *forward* and *backward* movement is a gliding of the fibro-cartilage upon the glenoid articular surface, in the antero-posterior direction; and the movement from *side* to *side*, in the lateral direction.

6. *Articulation of the Ribs with the Vertebrae*.—The ligaments of these articulations are so strong as to render dislocation impossible, the neck of the rib would break before displacement could occur; they are divisible into two groups:—1. Those connecting the *head of the rib* with the *vertebræ*; and 2. Those connecting the *neck and tubercle of the rib* with the *transverse processes*. They are

1st Group.

Anterior costo-vertebral or stellate,
Capsular,
Interarticular ligament,
Two synovial membranes.

2d Group.

Anterior costo-transverse,
Middle costo-transverse,
Posterior costo-transverse.

The *anterior costo-vertebral* or *stellate ligament* (fig. 45) consists of three short bands of ligamentous fibres, that radiate from the anterior part of the head of the rib. The *superior band* passes upwards, and is attached to the vertebra above; the *middle fasciculus* is attached to the intervertebral substance; and the *inferior*, to the vertebra below.

In the *first, eleventh, and twelfth* ribs, the three fasciculi are attached to the body of the corresponding vertebra.

The *capsular ligament* is a thin layer of ligamentous fibres surrounding the joint in the interval left by the anterior ligament; it is thickest above and below the articulation, and protects the synovial membranes.

The *interarticular ligament* passes between the sharp crest on the head of the rib and the intervertebral substance. It divides the joint into two cavities, which are each furnished with a separate *synovial membrane*. The *first, eleventh, and twelfth* ribs have no interarticular ligament, and consequently but one synovial membrane.

The *anterior costo-transverse ligament* is a broad band composed

of several fasciculi, which ascend from the crest upon the neck of the rib, to the transverse process immediately above. This ligament separates the anterior from the posterior branch of the intercostal nerves.

The *middle costo-transverse ligament* is a very strong interosseous ligament, passing directly between the posterior surface of the neck of the rib, and the transverse process against which it rests.

The *posterior costo-transverse ligament* is a small but strong fasciculus, passing obliquely from the tubercle of the rib, to the apex of the transverse process. The articulation between the tubercle of the rib and the transverse process is provided with a small synovial membrane.

There is no anterior costo-transverse ligament to the first rib; and only rudimentary posterior costo-transverse to the eleventh and twelfth ribs.

Actions.—The movements permitted by the articulations of the ribs, are *upwards* and *downwards*, and slightly *forwards* and *backwards*; the movement increasing in extent from the head to the extremity of the rib. The forward and backward movement is very trifling in the seven superior, but greater in the inferior ribs; the eleventh and twelfth are very movable.

7. *Articulation of the Ribs with the Sternum, and with each other.*
—The ligaments of the costo-sternal articulations are,

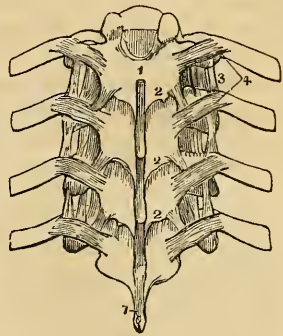
Anterior costo-sternal,
Posterior costo-sternal,
Superior costo-sternal,
Inferior costo-sternal,
Synovial membranes.

The *anterior costo-sternal ligament* is a thin band of ligamentous fibres, that passes in a radiated direction from the extremity of the costal cartilage to the anterior surface of the sternum, and intermingles its fibres with those of the ligament of the opposite side, and with the tendinous fibres of origin of the pectoralis major muscle.

The *posterior costo-sternal ligament* is much smaller than the anterior, and consists of only a thin fasciculus of fibres situated on the posterior surface of the articulation.

Fig. 55. A posterior view of a part of the thoracic portion of the vertebral column, showing the ligaments connecting the vertebræ with each other and the ribs with the vertebræ. 1. The supra-spinous ligament. 2. 2. The ligamenta subflava, connecting the laminae. 3. The anterior costo-transverse ligament. 4. The posterior costo-transverse ligaments.

Fig. 55.



The *superior* and *inferior costo-sternal* ligaments are narrow fasciculi corresponding with the breadth of the cartilage, and connecting its superior and inferior border with the side of the sternum.

The *synovial membrane* is absent in the articulation of the first rib, its cartilage being usually continuous with the sternum; that of the second rib has an inter-articular ligament, with two synovial membranes.

The *sixth* and *seventh* ribs have several fasciculi of strong ligamentous fibres, passing from the extremity of their cartilages to the anterior surface of the ensiform cartilage, which they are intended to support. They may be named the *costo-xiphoid ligaments*.

The *sixth*, *seventh*, and *eighth*, and sometimes the *fifth* and the *ninth* costal cartilages, have articulations with each other, and a perfect synovial membrane. They are connected by ligamentous fibres which pass from one cartilage to the other, *external* and *internal ligaments*.

The *ninth* and *tenth* are connected at their extremities by ligamentous fibres, but have no synovial membranes.

Actions.—The movements of the costo-sternal articulations are very trifling; they are limited to a slight sliding motion. The first rib is the least, and the second the most movable.

8. *Articulation of the Vertebral Column with the Pelvis*.—The last lumbar vertebra is connected with the sacrum by the same ligaments with which the various vertebræ are connected to each other; viz. the anterior and posterior common ligaments, intervertebral substance, ligamenta subflava, capsular ligaments, and inter and supraspinous ligaments.

There are only *two* proper ligaments connecting the vertebral column with the pelvis; these are, the

Lumbo-sacral,
Lumbo-iliac.

The *lumbo-sacral ligament* is a thick triangular fasciculus of ligamentous fibres, connected above, with the transverse process of the last lumbar vertebra; and below, with the posterior part of the upper border of the sacrum.

The *lumbo-iliac ligament* passes from the apex of the transverse process of the last lumbar vertebra to that part of the crest of the ilium which surmounts the sacro-iliac articulation. It is triangular in form.

9. *The Articulations of the Pelvis*.—The ligaments belonging to the articulations of the pelvis are divisible into four groups:—1. Those connecting the *sacrum* and *ilium*; 2, those passing between the *sacrum* and *ischium*; 3, between the *sacrum* and *coccyx*; and 4, between the *two pubic bones*.

1st, *Between the sacrum and ilium.*

Sacro-iliac anterior,
Sacro-iliac posterior.

2nd, *Between the sacrum and ischium.*

Sacro-ischiatic anterior (*short*),
Sacro-ischiatic posterior (*long*).

3d, *Between the sacrum and coccyx.*

Sacro-coccygean anterior,
Sacro-coccygean posterior.

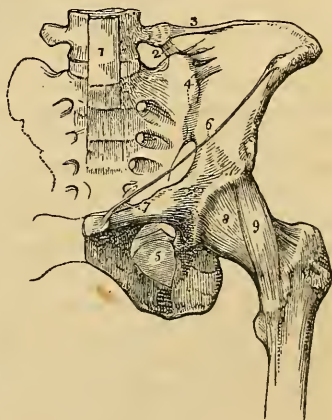
4th, *Between the ossa pubis.*

Anterior pubic,
Posterior pubic,
Superior pubic,
Sub-pubic,
Interosseous fibro-cartilage.

1. *Between the Sacrum and Ilium.*—The anterior sacro-iliac ligament consists of numerous short ligamentous fibres, passing from bone to bone on the anterior surface of the joint.

The posterior sacro-iliac or interosseous ligament* is composed of numerous strong fasciculi of ligamentous fibres, which pass horizontally between the rough surfaces, in the posterior half of the sacro-iliac articulation, and constitute the principal bond of connexion between the sacrum and the ilium. One fasciculus of this ligament, longer and larger than the rest, is distinguished, from its direction, by the name of the oblique sacro-iliac ligament. It is attached by one extremity, to the posterior superior spine of the ilium; and by the other, to the third transverse tubercle on the posterior surface of the sacrum.

Fig. 56.



The surfaces of the two bones forming the sacro-iliac articulation, are partly covered with cartilage, and partly rough and connected by the interosseous ligament. The anterior or auricular half is coated with cartilage, which is thicker on the sacrum than on the ilium. The surface of the cartilage is irregular, and provided with a very delicate synovial mem-

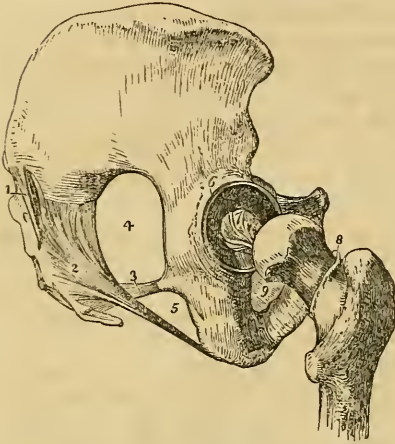
Fig. 56. The ligaments of the pelvis and hip-joint. 1. The lower part of the anterior common ligament of the vertebrae, extending downwards over the front of the sacrum. 2. The lumbo-sacral ligament. 3. The lumbo-iliac ligament. 4. The anterior sacro-iliac ligaments. 5. The obturator membrane. 6. Poupert's ligament. 7. Gimbernat's ligament. 8. The capsular ligament of the hip-joint. 9. The ilio-femoral or accessory ligament.

* This includes Horner's sacro-spinous ligament.—G.

brane, which cannot be demonstrated in the adult ; but it is apparent in the young subject, and in the female during pregnancy.

2. *Between the Sacrum and Ischium.*—The *anterior or lesser sacro-ischiatic ligament* is thin, and triangular in form ; it is attached by its apex to the spine of the ischium ; and by its broad extremity to the side of the sacrum and coccyx, interlacing its fibres with the succeeding.

Fig. 57.



The *anterior sacro-ischiatic ligament* is *in relation* in front, with the coccygeus muscle, and behind with the posterior ligament, with which its fibres are intermingled. By its upper border it forms a part of the lower boundary of the great sacro-ischiatic foramen, and by the lower part of the lesser sacro-ischiatic foramen.

The *posterior or greater sacro-ischiatic ligament*, considerably larger, thicker, and more posterior than the preceding, is narrower in the middle than at each extremity. It is attached by its smaller end, to the inner margin of the tuberosity and ramus of the ischium, where it forms a falciform process, which protects the internal pudic artery, and is continuous with the obturator fascia. By its larger extremity it is inserted into the side of the coccyx, sacrum, and posterior inferior spine of the ilium.

The *posterior sacro-ischiatic ligament* is *in relation* in front with the anterior ligament, and behind with the gluteus maximus, to some of the fibres of which it gives origin. By its superior border it forms part of the lesser ischiatic foramen, and by its lower border, a part of the boundary of the perineum. It is pierced by the coccygeal branch of the ischiatic artery. The two ligaments convert the sacro-ischiatic notches into foramina.

3. *Between the Sacrum and Coccyx.*—The *anterior sacro-coccygeal ligament* is a thin fasciculus, passing from the anterior surface of the sacrum to the front of the coccyx.

The *posterior sacro-coccygeal ligament* is a thick ligamentous layer,

Fig. 57. Ligaments of the pelvis and hip-joint. The view is taken from the side. 1. The oblique sacro-iliae ligament. The other fasciuli of the posterior sacro-iliae ligaments are not seen in this view of the pelvis. 2. The posterior sacro-ischiatic ligament. 3. The anterior sacro-ischiatic ligament. 4. The great sacro-ischiatic foramen. 5. The lesser sacro-ischiatic foramen. 6. The cotyloid ligament of the acetabulum. 7. The ligamentum teres. 8. The cut edge of the capsular ligament, showing its extent posteriorly as compared with its anterior attachment. 9. The obturator membrane only partly seen.

which completes the lower part of the sacral canal, and connects the sacrum with the coccyx posteriorly, extending as far as the apex of the latter bone.

Between the two bones is a thin disc of a soft intervertebral substance. In females there is frequently a small synovial membrane. This articulation admits of a certain degree of movement backwards during parturition.

The ligaments connecting the different pieces of the coccyx consist of a few scattered *anterior* and *posterior* fibres, and a thin disc of intervertebral substance; they exist only in the young subject, in the adult the pieces become ossified.

4. *Between the Ossa Pubis.*—The *anterior pubic ligament* is composed of ligamentous fibres, which pass obliquely across the union of the two bones from side to side, and form an interlacement in front of the symphysis.

The *posterior pubic ligament* consists of a few irregular fibres uniting the pubic bones posteriorly.

The *superior pubic ligament* is a thick band of fibres connecting the angles of the pubic bones superiorly, and filling the inequalities upon the surface of the bones.

The *sub-pubic ligament* is a thick arch of fibres, connecting the two bones inferiorly, and forming the upper boundary of the pubic arch.

The *interosseous fibro-cartilage* unites the two surfaces of the pubic bones, in the same manner that the intervertebral substance connects the bodies of the vertebræ. It resembles the intervertebral substance also in being composed of oblique fibres disposed in concentric layers, which are more dense towards the surface than near the centre. It is broad in front, and narrow behind. A thin synovial membrane is sometimes found in the posterior half of the articulation.

This articulation becomes movable towards the latter term of pregnancy, and admits of a slight degree of separation of its surfaces.

The *obturator ligament* or *membrane* is not a ligament of articulation, but simply a tendino-fibrous membrane stretched across the obturator foramen. It gives attachment by its surfaces, to the two obturator muscles; and leaves a space in the upper part of the foramen, for the passage of the obturator vessels and nerve.

The numerous vacuities in the walls of the pelvis, and their closure by ligamentous structures, as in the case of the sacro-ischiatic fissures and obturator foramina, serve to diminish very materially the pressure of the soft parts during the passage of the head of the fœtus through the pelvis in parturition.

LIGAMENTS OF THE UPPER EXTREMITY.

The *Ligaments of the upper extremity* may be arranged in the order of the articulation between the different bones; they are, the

1. Sterno-clavicular articulation.
2. Scapulo-clavicular articulation.
3. Ligaments of the scapula.
4. Shoulder joint.
5. Elbow joint.
6. Radio-ulnar articulation.
7. Wrist joint.
8. Articulation between the carpal bones.
9. Carpo-metacarpal articulation.
10. Metacarpo-phalangeal articulation.
11. Articulation of the phalanges.

1. *Sterno-clavicular Articulation.*—The sterno-clavicular is an arthrodial articulation ; its ligaments are,

Anterior sterno-clavicular,
 Posterior sterno-clavicular,
 Inter-clavicular,
 Costo-clavicular (*rhomboid*),
 Interarticular fibro-cartilage,
 Two synovial membranes.

The *anterior sterno-clavicular ligament* is a broad ligamentous layer, extending obliquely downwards and forwards, and covering the anterior aspect of the articulation. This ligament is *in relation* by its anterior surface with the integument and with the sternal origin of the sterno-mastoid muscle ; and behind with the interarticular fibro-cartilage and synovial membranes.

The *posterior sterno-clavicular ligament* is a broad fasciculus, covering the posterior surface of the articulation. It is *in relation* by its anterior surface with the interarticular fibro-cartilage and synovial membranes, and behind with the sterno-hyoid muscle.

The two ligaments are continuous at the upper and lower part of the articulation, so as to form a complete capsule around the joint.

The *inter-clavicular ligament* is a cord-like band which crosses from the extremity of one clavicle to the other, and is closely connected with the upper border of the sternum. It is separated by cellular tissue from the sterno-thyroid muscles.

The *costo-clavicular ligament (rhomboid)* is a thick fasciculus of fibres, connecting the sternal extremity of the clavicle with the cartilage of the first rib. It is situated obliquely between the rib and the under surface of the clavicle. It is *in relation* in front with the tendon of origin of the subclavius muscle, and behind with the subclavian vein.

Actions.—The movements of the sterno-clavicular articulation, are a *gliding movement* of the fibro-cartilage with the clavicle, upon the articular surface of the sternum in the direction forwards, backwards, upwards, and downwards ; and *circumduction*. This articulation is the centre of the movement of the shoulder.

The rupture of the rhomboid ligament in dislocation of the sternal end of the clavicle, gives rise to the deformity peculiar to this accident.

The *interarticular fibro-cartilage* is nearly circular in form, and thicker at the edges than in the centre. It is attached above, to the clavicle; below to the cartilage of the first rib; and throughout the rest of its circumference to the anterior and posterior sterno-clavicular ligament; it divides the joint into two cavities, which are lined by distinct *synovial membranes*. This cartilage is sometimes pierced through its centre, and not unfrequently absorbed to a greater or less extent, particularly at its lower part.

2. *Scapulo-clavicular Articulation*.—The ligaments of the scapular end of the clavicle are, the

- Superior acromio-clavicular,
- Inferior acromio-clavicular,
- Coraco-clavicular (*trapezoid* and *conoid*),
- Interarticular fibro-cartilage,
- Two synovial membranes.

The *superior acromio-clavicular ligament* is a moderately thick plane of superimposed fibres passing between the extremity of the clavicle and the acromion, upon the upper surface of the joint.

The *inferior acromio-clavicular ligament* is a thin plane situated upon the under surface. These two ligaments are continuous with each other in front and behind, and form a complete capsule around the joint.

The *coraco-clavicular ligament* (*trapezoid*, *conoid*) is a thick fasciculus of ligamentous fibres, passing obliquely between the base of the coracoid process and the under surface of the clavicle, and holding the end of the clavicle in firm connexion with the scapula. When seen from *before*, it has a quadrilateral form: hence it is named *trapezoid*; and, examined from *behind*, it has a triangular form, the base being upwards; hence another name, *conoid*.

The *interarticular fibro-cartilage* is often indistinct, from having partial connexions with the fibro-cartilaginous surfaces of the two bones between which it is placed, and not unfrequently absent. When partial, it occupies the upper part of the articulation. The

Fig. 58.

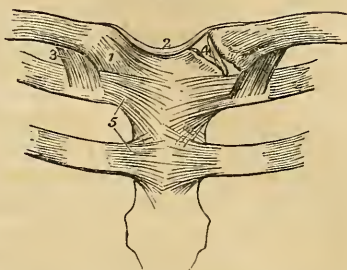


Fig. 58. The ligaments of the sternoclavicular and costo-sternal articulations. 1. The anterior sternoclavicular ligament. 2. The inter-clavicular ligament. 3. The costo-clavicular or rhomboid ligament, seen on both sides. 4. The interarticular fibro-cartilage, brought into view by the removal of the anterior and posterior ligaments. 5. The anterior costo-sternal ligaments of the first and second ribs.

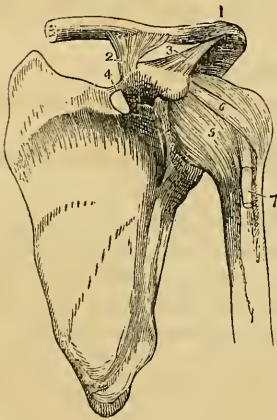
synovial membranes are very delicate. There is only one, when the fibro-cartilage is incomplete.

Actions.—The acromio-clavicular articulation admits of two movements, the *gliding* of the surfaces upon each other; and the *rotation* of the scapula, upon the extremity of the clavicle.

3. The *Proper ligaments of the Scapula* are the
Coraco-acromial,
Transverse.

The *coraco-acromial ligament* is a broad and thick triangular band, which forms a protecting arch over the shoulder joint. It is attached by its apex to the point of the acromion process, and by its base to the external border of the coracoid process its whole length. This ligament is *in relation* above with the under surface of the deltoid muscle; and below with the tendon of the supra-spinatus muscle, a bursa mucosa being usually interposed.

Fig. 59.



The *transverse* or *coracoid ligament* is a narrow but strong fasciculus, which crosses the notch in the upper border of the scapula, from the base of the coracoid process, and converts it into a foramen. The supra-scapular nerve passes through this foramen.

4. *Shoulder joint*.—The scapulo-humeral articulation is an enarthrosis, or ball and socket joint—its ligaments are, the

Capsular,
Coraco-humeral,
Glenoid.

The *capsular ligament* completely encircles the articulating head of the scapula and the head of the humerus, and is attached to the neck of each bone. It is thick above, where resistance is most

required, and is strengthened by the tendons of the supra-spinatus, infra-spinatus, teres minor, and subscapularis muscles; below it is thin and loose. The capsule is incomplete at the point of contact with the tendons, so that they obtain upon their inner surface a covering of synovial membrane.

The *coraco-humeral ligament* is a broad band which descends obliquely outwards from the border of the coracoid process to the greater tuberosity of the humerus, and serves to strengthen the superior and anterior part of the capsular ligament.

The *glenoid ligament* is the prismoid band of fibro-cartilage,

Fig. 59. The ligaments of the scapula and shoulder joint. 1. The superior acromio-clavicular ligament. 2. The coraco-clavicular ligament; this aspect of the ligament is named trapezoid. 3. The coraco-acromial ligament. 4. The transverse ligament. 5. The capsular ligament. 6. The coraco-humeral ligament. 7. The long tendon of the biceps issuing from the capsular ligament, and entering the bicipital groove.

which is attached around the margin of the glenoid cavity for the purpose of protecting its edges, and deepening its cavity. It divides superiorly into two slips which are continuous with the long tendon of the biceps; hence the ligament is frequently described as being formed by the splitting of that tendon. The cavity of the articulation is traversed by the long tendon of the biceps, which is enclosed in a sheath of synovial membrane in its passage through the joint.

The *synovial membrane* of the shoulder joint is very extensive; it communicates anteriorly through an opening into the capsular ligament with a large bursal sac, which lines the under surface of the tendon of the subscapularis muscle. Superiorly, it frequently communicates through another opening in the capsular ligament with a bursal sac belonging to the infra-spinatus muscle; and it moreover forms a sheath around that portion of the tendon of the biceps, which is included within the joint.

The muscles immediately surrounding the shoulder joint are the subscapularis, supra-spinatus, infra-spinatus, teres minor, long head of the triceps, and deltoid; the long tendon of the biceps is within the capsular ligament.

Actions.—The shoulder joint is capable of every variety of motion, viz. of movement forwards and backwards, of abduction, and adduction, of circumduction and rotation.

5. *Elbow Joint.*—The elbow is a ginglymoid articulation; its ligaments are *four* in number:

Anterior,
Posterior,
Internal lateral,
External lateral.

The *anterior ligament* is a broad and thin membranous layer, descending from the anterior surface of the humerus, immediately above the joint, to the coronoid process of the ulna and orbicular ligament. On each side it is connected with the lateral ligaments. It is composed of fibres which pass in three different directions, vertical, transverse, and oblique, the latter being extended from within outwards to the orbicular ligament, into which they are attached inferiorly. This ligament is covered in by the brachialis anticus muscle.

The *posterior ligament* is a broad and loose fold, passing between the posterior surface of the humerus and the anterior surface of the base of the olecranon, and connected at each side with the lateral ligaments. It is covered in by the tendon of the triceps.

The *internal lateral ligament* is a thick triangular layer, attached above, by its apex, to the internal condyle of the humerus; and below, by its expanded border, to the margin of the greater sigmoid cavity of the ulna, extending from the coronoid process to the olecranon. At its insertion it is intermingled with some trans-

verse fibres. The internal lateral ligament is in relation posteriorly with the ulnar nerve.

Fig. 60.

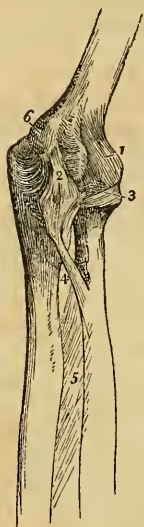
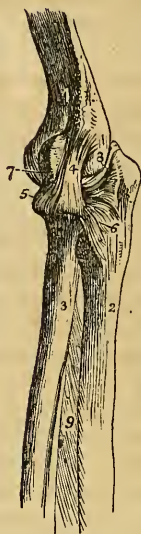
Fig. 61.



The *external lateral ligament* is a strong and narrow band, which descends from the external condyle of the humerus, to be inserted into the orbicular ligament, and into the ridge on the ulna, with which the posterior part of the lateral ligament is connected. This ligament is closely united with the tendon of origin of the supinator brevis muscle.

The *synovial membrane* is extensive, and is reflected from the cartilaginous surfaces of the bones upon the inner surface of the ligaments. It surrounds inferiorly the head of the radius, and forms an articulating sac between it and the lesser sigmoid notch.

The muscles immediately surrounding, and in contact with, the elbow joint, are *in front*, the brachialis anticus; to the *inner side*, the pronator radii teres, flexor sublimis digitorum, and flexor carpi ulnaris; *externally*, the extensor carpi radialis brevis, extensor

Fig. 60. An internal view of the ligaments of the elbow joint. 1. The anterior ligament. 2. The internal lateral ligament. 3. The orbicular ligament. 4. The oblique ligament. 5. The interosseous ligament. 6. The internal condyle of the humerus, which conceals the posterior ligament.

Fig. 61. An external view of the elbow joint. 1. The humerus. 2. The ulna. 3. The radius. 4. The external lateral ligament inserted inferiorly into (5) the orbicular ligament. 6. The posterior extremity of the orbicular ligament spreading out at its insertion into the ulna. 7. The anterior ligament, scarcely apparent in this view of the articulation. 8. The posterior ligament, thrown into folds by the extension of the joint.

communis digitorum, extensor carpi ulnaris, anconeus, and supinator brevis; and *behind*, the triceps.

Actions.—The movements of the elbow-joint are *flexion* and *extension*, which are performed with remarkable precision. The extent to which these movements are capable of being effected, is limited, in front by the coronoid process, and behind by the olecranon.

6. The *Radio-ulnar Articulation.*—The radius and ulna are firmly held together by ligaments which are connected with both extremities of the bones, and with the shaft; they are, the

Orbicular,	Anterior inferior,
Oblique,	Posterior inferior,
Interosseous,	Interarticular fibro-cartilage.

The *orbicular ligament* (*annular, coronary*) is a firm band several lines in breadth, which surrounds the head of the radius, and is attached by each end to the extremities of the lesser sigmoid cavity. It is strongest behind where it receives the external lateral ligament, and is lined on its inner surface by a reflection of the synovial membrane of the elbow joint.

The rupture of this ligament permits of the dislocation of the head of the radius.

The *oblique ligament* is a narrow slip of ligamentous fibres, descending obliquely from the base of the coronoid process of the ulna to the lower part of the tuberosity of the radius.

The *interosseous ligament* is a broad and thin plane of aponeurotic fibres, passing obliquely downwards from the sharp ridge on the radius to that on the ulna. It is deficient superiorly, is broader in the middle than at each extremity, and is perforated at its lower part for the passage of the anterior interosseous artery. The posterior interosseous artery passes backwards between the oblique ligament and the upper border of the interosseous ligament. This ligament affords an extensive surface for the attachment of muscles.

The interosseous ligament is *in relation, in front*, with the flexor profundus digitorum, the flexor longus pollicis, and pronator quadratus muscle, and with the anterior interosseous artery and nerve, and *behind* with the supinator brevis, extensor ossis metacarpi pollicis, extensor primi internodii pollicis, extensor secundi internodii pollicis, and extensor indicis muscle, and near the wrist with the anterior interosseous artery and posterior interosseous nerve.

The *anterior inferior ligament* is a thin fasciculus of fibres, passing transversely between the radius and ulna.

Fig. 62.

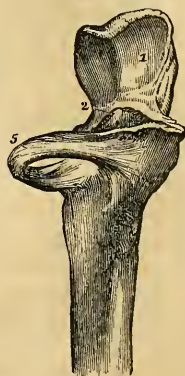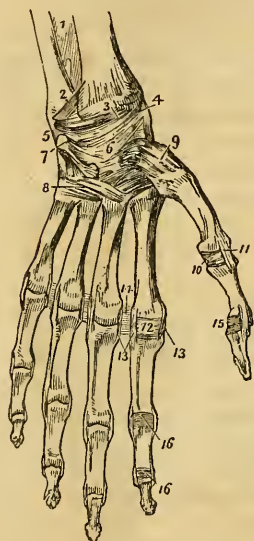


Fig. 62. 1. Articular surface of olecranon process of the ulna. 2. Coronoid process. 3. Orbicular ligament surrounding the neck of the radius.

The *posterior inferior ligament* is also thin and loose, and has the same disposition on the posterior surface of the articulation.

The *interarticular*, or *triangular fibro-cartilage*, acts the part of a ligament between the lower extremities of the radius and ulna. It is attached by its apex to a depression on the inner surface of the styloid process of the ulna, and by its base to the edge of the radius. This fibro-cartilage is lined upon its upper surface by a synovial membrane, which forms a duplicature between the radius and ulna, and is called the *membrana sacciformis*. By its lower surface it enters into the articulation of the wrist joint.

Fig. 63.



Anterior,
Posterior,

Internal lateral.
External lateral.

Actions.—The movements taking place between the radius and the ulna, are the rotation of the former upon the latter; rotation forwards being termed *pronation*, and rotation backwards *supination*. In these movements the head of the radius turns upon its own axis, within the orbicular ligament and the lesser sigmoid notch of the ulna; while inferiorly the radius presents a concavity which moves upon the rounded head of the ulna. The movements of the radius are chiefly limited by the anterior and posterior inferior ligaments, hence these are not unfrequently ruptured in great muscular efforts.

7. *Wrist Joint.*—The wrist is a ginglymoid articulation; the articular surfaces entering into its formation being the radius and under surface of the triangular fibro-cartilage above, and the rounded surfaces of the scaphoid, semilunar, and cuneiform bone below; its ligaments are *four* in number,

Fig. 63. The ligaments of the anterior aspect of the wrist and hand. 1. The lower part of the interosseous membrane. 2. The anterior inferior radio-ulnar ligament. 3. The anterior ligament of the wrist joint. 4. Its external lateral ligament. 5. Its internal lateral ligament. 6. The palmar ligaments of the carpus. 7. The pisiform bone, with its ligaments. 8. The ligaments connecting the second range of carpal bones with the metacarpal, and the metacarpal with each other. 9. The capsular ligament of the carpo-metacarpal articulation of the thumb. 10. Anterior ligament of the metacarpophalangeal articulation of the thumb. 11. One of the lateral ligaments of that articulation. 12. Anterior ligament of the metacarpophalangeal articulation of the index finger; these ligaments have been removed in the other fingers. 13. Lateral ligaments of the same articulation; the corresponding ligaments are seen in the other articulations. 14. Transverse ligament connecting the heads of the metacarpal bones of the index and middle fingers; the same ligament is seen between the other fingers. 15. Anterior and one lateral ligament of the phalangeal articulation of the thumb. 16. Anterior and lateral ligaments of the phalangeal articulations of the index finger; the anterior ligaments are removed in the other fingers.

The *anterior ligament* is a broad and membranous layer consisting of three fasciculi, which pass between the lower part of the radius, and the scaphoid, semilunar, and cuneiform bones.

The *posterior ligament*, also thin and loose, passes between the posterior surface of the radius, and the posterior surface of the semilunar and cuneiform bones.

The *internal lateral ligament* extends from the styloid process of the ulna to the cuneiform and pisiform bone.

The *external lateral ligament* is attached by one extremity to the styloid process of the radius, and by the other to the side of the scaphoid bone. The radial artery rests on this ligament as it passes backwards to the first metacarpal space.

The *synovial membrane* of the wrist joint lines the under surface of the radius and interarticular fibro-cartilage above, and the first row of bones of the carpus below.

The *relations* of the wrist joint are the flexor and extensor tendons by which it is surrounded, and the radial and ulnar artery,

Actions.—The movements of the wrist joint are *flexion*, *extension*, *adduction*, *abduction*, and *circumduction*. In these motions the articular surfaces glide upon each other.

Articulations between the Carpal bones.—These are amphiarthrodial joints, with the exception of the conjoined head of the os magnum and unciforme, which is received into a cup formed by the scaphoid, semilunar, and cuneiform bones, and constitutes an enarthrosis. The ligaments are,

Dorsal,
Palmar,
Interosseous,
Anterior annular.

The *dorsal ligaments*, are ligamentous bands, that pass from bone to bone in every direction, upon the dorsal surface of the carpus.

The *palmar ligaments* are fasciculi of the same kind, but stronger than the dorsal, having the like disposition upon the palmar surface.

The *interosseous ligaments* are situated between the adjoining bones in each range: in the upper range they close the upper part of the spaces between the scaphoid, semilunar, and cuneiform bones; in the lower range they are stronger than in the upper, and connect the os magnum on the one side to the unciforme, on the other to the trapezoides, and leave intervals through which the synovial membrane is continued to the bases of the metacarpal bones.

The *anterior annular ligament* is a firm ligamentous band, which connects the bones of the two sides of the carpus. It is attached by one extremity to the trapezium and scaphoid, and by the other to the unciform process of the unciforme and the base of the pisiform bone, and forms an arch over the anterior surface of the

carpus, beneath which the tendons of the long flexors and the median nerve pass into the palm of the hand.

The articulation of the *pisiform bone* with the cuneiform, is provided with a distinct synovial membrane, which is protected by fasciculi of ligamentous fibres, forming a kind of capsule around the joint; they are inserted into the cuneiforme, unciforme and base of the metacarpal bone of the little finger.

Synovial membranes.—There are *five* synovial membranes entering into the composition of the articulations of the carpus:

The *first* is situated between the lower end of the ulna and the interarticular fibro-cartilage; it is called *sacciform*, from forming a sacculus between the lateral articulation of the ulna with the radius.

The *second* is situated between the lower surface of the radius and interarticular fibro-cartilage *above*, and the first range of bones of the carpus *below*.

The *third* is the most extensive of the synovial membranes of the wrist; it is situated between the two rows of carpal bones, and passes between the bones of the second range to invest the carpal extremities of the four metacarpal bones of the fingers.

The *fourth* is the synovial membrane of the articulation of the metacarpal bone of the thumb with the trapezium.

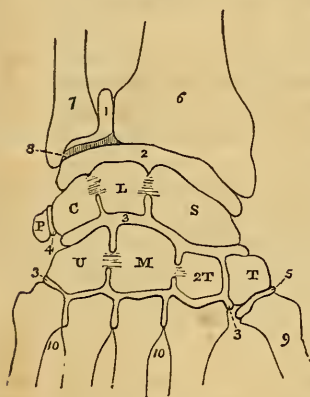
The *fifth* is situated between the pisiform and cuneiform bone.

Actions.—Very little movement exists between the bones in each range, but more is permitted between the two ranges. The motions in the latter situation are those of flexion and extension.

9. The *Carpo-metacarpal Articulation.*—The second row of bones of the carpus articulates with the metacarpal bones of the four fingers by *dorsal* and *palmar* ligaments; and the metacarpal bone of the thumb with the trapezium by a true *capsular ligament*.

The *dorsal ligaments* are strong fasciculi which pass from the second range of carpal to the metacarpal bones.

Fig. 64. A diagram showing the disposition of the five synovial membranes of the wrist joint. 1. The sacciform membrane. 2. The second synovial membrane. 3, 3. The third, or large synovial membrane. 4. The synovial membrane between the pisiform bone and the cuneiforme. 5. The synovial membrane of the metacarpal articulation of the thumb. 6. The lower extremity of the radius. 7. The lower extremity of the ulna. 8. The interarticular fibro-cartilage. S. The scaphoid bone. L. The semilunare. C. The cuneiforme; the interosseous ligaments are seen passing between these three bones and separating the articulation of the wrist (2) from the articulation of the carpal bones (3). P. The pisiforme. T. The trapezium. ²T. The trapezoides. M. The os magnum. U. The unciforme; interosseous ligaments are seen connecting the os magnum with the trapezoides and unciforme. 9. The base of the metacarpal bone of the thumb. 10, 10. The bases of the other metacarpal bones.



The *palmar ligaments* are thin fasciculi arranged upon the same plan on the palmar surface.

The *synovial membrane* is a continuation of the great synovial membrane of the two rows of carpal bones.

The *capsular ligament* of the thumb is one of the three true capsular ligaments of the skeleton; the other two being the shoulder-joint and hip-joint. The articulation has a proper *synovial membrane*.

The *metacarpal bones* of the four fingers are firmly connected at their bases by means of dorsal and palmar ligaments, which extend transversely from one bone to the other, and by interosseous ligaments which pass between their contiguous surfaces. Their lateral articular facets are lined by a reflection of the great synovial membrane of the two rows of carpal bones.

Actions.—The movements of the metacarpal on the carpal bones, are restricted to a slight degree of sliding motion, with the exception of the articulation of the metacarpal bone of the thumb with the trapezium. In the latter articulation, the movements are, *flexion, extension, adduction, abduction, and circumduction*.

10. *Metacarpo-phalangeal Articulation*.—The metacarpo-phalangeal articulation is a ginglymoid joint: its ligaments are four in number.

Anterior,
Two lateral,
Transverse.

The *anterior ligaments* are thick and fibro-cartilaginous, and form part of the articulating surface of the joints. They are grooved externally for the lodgment of the flexor tendons, and by their internal aspect form part of the articular surface for the head of the metacarpal bone.

The *lateral ligaments* are strong narrow fasciculi, holding the bones together at each side.

The *transverse ligaments* are strong ligamentous bands passing between the anterior ligaments, and connecting together the heads of the metacarpal bones of the four fingers.

The expansion of the extensor tendon over the back of the fingers takes the place of a posterior ligament.

Actions.—This articulation admits of movement in four different directions, viz. of *flexion, extension, adduction* and *abduction*, the two latter being limited to a small extent. It is also capable of *circumduction*.

11. *Articulation of the Phalanges*.—These articulations are ginglymoid joints: they are formed by three ligaments.

Anterior,
Two lateral.

The *anterior ligament* is firm and fibro-cartilaginous, and forms

part of the articular surface for the head of the phalanges. Externally it is grooved for the reception of the flexor tendons.

The *lateral ligaments* are very strong; they are the principal bond of connexion between the bones.

The extensor tendon takes the place and performs the office of a posterior ligament.

Actions.—The movements of the phalangeal joints are *flexion* and *extension*, these movements being more extensive between the first and second phalanges than between the second and third.

LIGAMENTS OF THE LOWER EXTREMITY.

The *ligaments of the lower extremity*, like those of the upper, may be arranged in the order of the joints to which they belong; these are, the

1. Hip joint.
2. Knee joint.
3. Articulation between the tibia and fibula.
4. Ankle joint.
5. Articulation of the tarsal bones.
6. Tarso-metatarsal articulation.
7. Metatarso-phalangeal articulation.
8. Articulation of the phalanges.

1. *Hip Joint.*—The articulation of the head of the femur with the acetabulum constitutes an enarthrosis, or ball and socket joint. The articular surfaces are the cup-shaped cavity of the acetabulum and the rounded head of the femur; the ligaments are *five* in number, viz:

Capsular,
Ilio-femoral,
Teres,
Cotyloid,
Transverse.

The *capsular ligament* (fig. 56, 8) is a strong ligamentous capsule, embracing the acetabulum superiorly, and inferiorly the neck of the femur, and connecting the two bones firmly together. It is much thicker upon the upper part of the joint, where more resistance is required, than upon the under part, and extends farther upon the neck of the femur on the anterior and superior than on the posterior and inferior side, being attached to the intertrochanteric line in front, to the base of the great trochanter above, and to the middle of the neck of the femur behind.

The *ilio-femoral ligament** (fig. 56, 9) is an accessory and radiating band, which descends obliquely from the anterior inferior spinous

* Called also *ligamentum adscititium*.—G.

process of the ilium to the anterior intertrochanteric line, and strengthens the anterior portion of the capsular ligament.

The *ligamentum teres* (fig. 57, 7), triangular in shape, is attached by a rounded apex to the depression just below the middle of the head of the femur, and by its base, which divides into two fasciculi, into the borders of the notch of the acetabulum. It is formed by a fasciculus of fibres of variable size, surrounded by synovial membrane; sometimes the synovial membrane alone exists, or the ligament is wholly absent.

The *cotyloid ligament* (fig. 57, 7) is a prismoid cord of fibro-cartilage, attached around the margin of the acetabulum, and serving to deepen the cavity and protect its edges. It is much thicker upon the upper and outer border of the acetabulum than in front, and consists of fibres which arise from the whole circumference of the brim, and interlace with each other at acute angles.

The *transverse ligament* is a strong fasciculus of ligamentous fibres, continuous with the cotyloid ligament, and extended across the notch in the acetabulum. It converts the notch into a foramen, through which the articular branches of the internal circumflex and obturator arteries enter the joint.

The fossa at the bottom of the acetabulum is filled by a mass of fat, covered with synovial membrane, which serves as an elastic cushion to the head of the bone during its movements. This was considered by Havers as the synovial gland.

The *synovial membrane* is extensive; it invests the head of the femur, and is continued around the ligamentum teres into the acetabulum; it is thence reflected upon the inner surface of the capsular ligament.

The muscles immediately surrounding and in contact with the hip joint are, *in front*, the psoas and iliacus, which are separated from the capsular ligament by a large synovial bursa; *above*, the short head of the rectus, and the gluteus minimus; *behind*, the pyriformis, gemellus superior, obturator internus, gemellus inferior, and quadratus femoris; and to the *inner side*, the obturator externus and pectineus.

Actions.—The movements of the hip joint are very extensive; they are *flexion, extension, adduction, abduction, circumduction, and rotation*.

2. *Knee Joint*.—The knee is a ginglymoid articulation of a large size, and is provided with numerous ligaments; they are thirteen in number.

Anterior or ligamentum patellæ,
 Posterior or ligamentum posticum Winslowi,
 Internal lateral,
 Two external lateral,
 Anterior or external crucial,
 Posterior or internal crucial,
 Transverse,

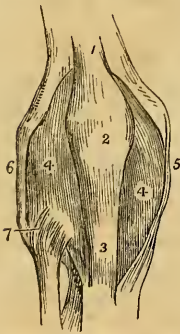
Two coronary,
 Ligamentum mucosum, } *false*.
 Ligamenta alaria, }
 Two semilunar fibro-cartilages,
 Synovial membrane.

The *five* first are *external* to the articulation; the *five* next are *internal* to the articulation; the three remaining are mere folds of synovial membrane, and have no title to the name of ligaments. In addition to the ligaments, there are two fibro-cartilages, which are sometimes very erroneously considered among the ligaments; and a synovial membrane, which is still more improperly named the *capsular ligament*.

The *anterior ligament* or *ligamentum patellæ*, is the prolongation of the tendon of the extensor muscles of the thigh downwards to the tubercle of the tibia. It is, therefore, no ligament; and, as we have before stated, that the patella is simply a sesamoid bone, developed in the tendon of the extensor muscles for the defence of the front of the knee joint, it has no title to consideration, either as a ligament of the knee joint or as a ligament of the patella.

A small *bursa mucosa* is situated between the ligamentum patellæ, near to its insertion, and the front of the tibia, and another of larger size is placed between the patella and the fascia lata, which extends over its anterior surface.

Fig. 65.



The *posterior ligament*—*ligamentum posticum Winslowi*,*—is a broad expansion of ligamentous fibres, which covers the whole of the posterior part of the joint. It is divisible into two lateral portions, which invest the condyles of the femur, and a central portion, which is depressed and formed by the interlacement of fasciculi passing in different directions. The strongest of these fasciculi is that which is derived from the tendon of the semimembranosus, and passes obliquely upwards and outwards, from the posterior part of the inner tuberosity of the tibia to the external condyle. Other accessory fasciculi are given off by the tendon of the popliteus and by the heads of the gastrocnemius. The middle portion of the ligament supports the popliteal artery and vein, and is perforated by several

Fig. 65. The anterior view of the ligaments of the knee-joint. 1. The tendon of the quadriceps extensor muscle of the leg. 2. The patella. 3. The anterior ligament, or ligamentum patellæ, near its insertion. 4, 4. The synovial membrane. 5. The internal lateral ligament. 6. The long external lateral ligament. 7. The anterior superior tibio-fibular ligament.

* In a recent dissection in Sydenham College, Mr. Joseph Chapman observed a small fleshy muscle, connected by one extremity with the external condyle of the femur, and inserted by the other into that portion of this ligament which is derived from the tendon of the semimembranosus.

openings for the passage of branches of the azygos articular artery, and for the nerves of the joint.

The *internal lateral ligament* is a broad and trapezoid layer of ligamentous fibres, attached above to the tubercle on the internal condyle of the femur, and below to the side of the inner tuberosity of the tibia. It is crossed at its lower part by the tendons of the inner hamstring, from which it is separated by a synovial bursa, and it covers in the anterior slip of the semi-membranosus tendon and the inferior internal articular artery.

External lateral ligaments.—The *long external lateral ligament* is a strong rounded cord, which descends from the posterior part of the tubercle upon the external condyle of the femur to the outer part of the head of the fibula. The *short external lateral ligament* is an irregular fasciculus situated behind the preceding, arising from the external condyle near the origin of the head of the gastrocnemius muscle, and inserted into the posterior part of the head of the fibula. It is firmly connected with the external semilunar fibro-cartilage, and appears principally intended to connect that cartilage with the fibula. The long external lateral ligament is covered in by the tendon of the biceps, and has passing beneath it the tendon of the origin of the popliteus muscle, and the inferior external articular artery.

The true ligaments *within the joint* are the crucial, transverse and coronary.

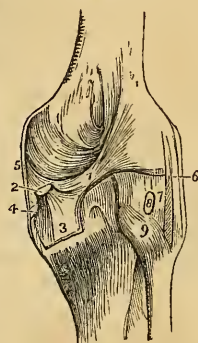
The *anterior or external crucial ligament*, arises from the depression upon the head of the tibia in front of the spinous process, and passes upwards and backwards to be inserted into the inner surface of the outer condyle of the femur, as far as its posterior border. It is smaller than the posterior.

The *posterior, or internal crucial ligament*, arises from the depression upon the head of the tibia, behind the spinous process, and passes upwards and forwards to be inserted into the inner condyle of the femur. This ligament is less oblique and larger than the anterior.

The *transverse ligament* is a small slip of fibres, which extends transversely from the external semilunar fibro-cartilage, near its anterior extremity, to the anterior convexity of the internal cartilage.

Fig. 66. A posterior view of the ligaments of the knee-joint. 1. The fasciculus of the ligamentum posticum Winslowi, which is derived from, 2. The tendon of the semi-membranosus muscle; the latter is cut short. 3. The process of the tendon which spreads out in the fascia of the popliteus muscle. 4. The process which is sent inwards beneath the internal lateral ligament. 5. The posterior part of the internal lateral ligament. 6. The long external lateral ligament. 7. The short external lateral ligament. 8. The tendon of the popliteus muscle cut short. 9. The posterior superior tibio-fibular ligament.

Fig. 66.



The *coronary ligaments* are the short fibres by which the convex borders of the semilunar cartilages are connected to the head of the tibia, and to the ligaments surrounding the joint.

Fig. 67.

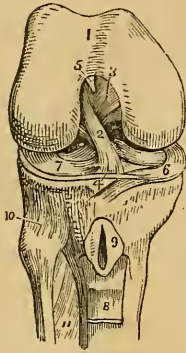
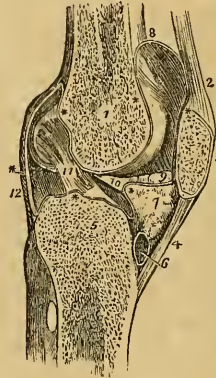


Fig. 68.



The *semilunar fibro-cartilages*, are two falciform plates of fibro-cartilage, situated around the margin of the head of the tibia, and serving to deepen the surface of articulation for the condyles of the femur. They are thick along their convex border, and thin and sharp along the concave edge.

The *internal semilunar fibro-cartilage* forms an oval cup for the

Fig. 67. The right knee joint laid open from the front, in order to show the internal ligaments. 1. The cartilaginous surface of the lower extremity of the femur with its two condyles; the figure 5 rests upon the external; the figure 3 upon the internal condyle. 2. The anterior crucial ligament. 3. The posterior crucial ligament. 4. The transverse ligament. 5. The attachment of the ligamentum mucosum, the rest has been removed. 6. The internal semilunar fibro-cartilage. 7. The external fibro-cartilage. 8. A part of the ligamentum patellæ turned down. 9. The bursa, situated between the ligamentum patellæ and the head of the tibia; it has been laid open. 10. The anterior superior tibio-fibular ligament. 11. The upper part of the interosseous membrane, the opening above this membrane is for the passage of the anterior tibial artery.

Fig. 68. A longitudinal section of the left knee joint, showing the reflections of its synovial membrane. 1. The cancellous structure of the lower part of the femur. 2. The tendon of the extensor muscles of the leg. 3. The patella. 4. The ligamentum patellæ. 5. The cancellous structure of the head of the tibia. 6. A bursa situated between the ligamentum patellæ and the head of the tibia. 7. The mass of fat projecting into the cavity of the joint below the patella. ** The synovial membrane. 8. The pouch of synovial membrane, which ascends between the tendon of the extensor muscles of the leg, and the front of the lower extremity of the femur. 9. One of the alar ligaments; the other has been removed with the opposite section. 10. The ligamentum mucosum left entire; the section being made to its inner side. 11. The anterior or external crucial ligament. 12. The posterior ligament. The scheme of the synovial membrane which is here presented to the student, is divested of all unnecessary complications. It may be traced from the sacculus (at 8), along the inner surface of the patella; then over the adipose mass (7) from which it throws off the mucous ligament (10); then over the head of the tibia, forming a sheath to the crucial ligaments; then upwards along the posterior ligament and condyles of the femur, to the sacculus whence its examination commenced.

reception of the internal condyle; it is connected by its convex border to the head of the tibia, and to the internal and posterior ligaments, by means of its coronary ligament; and by its two extremities is firmly implanted into the depression in front and behind the spinous process. The *external semilunar fibro-cartilage* bounds a circular fossa for the external condyle; it is connected by its convex border with the head of the tibia, and to the external and posterior ligaments, by means of its coronary ligament; by its two extremities it is inserted into the depression between the two projections which constitute the spinous process of the tibia. The two extremities of the external cartilage being inserted into the same fossa, form almost a complete circle, and the cartilage being somewhat broader than the internal, nearly covers the articular surface of the tibia. The external semilunar fibro-cartilage, besides giving off a fasciculus from its anterior border to constitute the transverse ligament, is continuous by some of its fibres with the extremity of the anterior crucial ligament; posteriorly it divides into three slips, one, a strong cord, ascends obliquely forwards and is inserted into the anterior part of the inner condyle in front of the posterior crucial ligament; another is the fasciculus of insertion into the fossa of the spinous process; and the third, of small size, is continuous with the posterior part of the anterior crucial ligament.

The *ligamentum mucosum* is a slender conical process of synovial membrane, enclosing a few ligamentous fibres which proceed from the transverse ligament. It is connected by its apex with the anterior part of the condyloid notch, and by its base is lost in the mass of fat which projects into the joint beneath the patella.

The *alar ligaments* are two fringed folds of synovial membrane, extending from the ligamentum mucosum, along the edges of the mass of fat to the sides of the patella.

The *synovial membrane* of the knee joint is by far the most extensive in the skeleton. It invests the cartilaginous surface of the condyles of the femur, of the head of the tibia, and of the inner surface of the patella; it covers both surfaces of the semilunar fibro-cartilages, and is reflected upon the crucial ligaments, and upon the inner surface of the ligaments which form the circumference of the joint. On each side of the patella, it lines the tendinous aponeuroses of the vastus internus and vastus externus muscles, and forms a pouch of considerable size between the extensor tendon and the front of the femur. It also forms the folds in the interior of the joint, called "ligamentum mucosum," and "ligamenta alaria." The superior pouch of the synovial membrane is supported and raised during the movements of the limb by a small muscle, the *subcrureus*, which is inserted into it.

Beneath the ligamentum patellæ and the synovial membrane is a considerable mass of fat, which presses the membrane towards the interior of the joint, and occupies the fossa between the two condyles.

Besides the proper ligaments of the articulation, the joint is pro-

tected on its anterior part by the fascia lata, which is thicker upon the outer than upon the inner side, by a tendinous expansion from the vastus internus, and by some scattered ligamentous fibres which are inserted into the sides of the patella.

Actions.—The knee joint is one of the strongest of the articulations of the body, while at the same time it admits of the most perfect degree of movement in the directions of *flexion* and *extension*. During flexion the articular surface of the tibia glides forward on the condyles of the femur, the lateral ligaments, the posterior, and crucial ligaments are relaxed, while the ligamentum patellæ being put upon the stretch, serves to press the adipose mass into the vacuity formed in the front of the joint. In *extension* all the ligaments are put upon the stretch with the exception of the ligamentum patellæ. When the knee is semi-flexed, a partial degree of *rotation* is permitted.

3. *Articulation between the Tibia and Fibula.*—The tibia and fibula are held firmly connected by means of *seven* ligaments, viz.

Anterior, } above.
Posterior, }

Interosseous membrane,
Interosseous inferior.

Anterior, } below.
Posterior, }
Transverse.

The *anterior superior ligament* is a strong fasciculus of parallel fibres, passing obliquely downwards and outwards from the inner tuberosity of the tibia, to the anterior surface of the head of the fibula.

The *posterior superior ligament* is disposed in a similar manner upon the posterior surface of the articulation.

There is a distinct *synovial membrane* in this articulation.

The *interosseous membrane* or *superior interosseous ligament* is a broad layer of aponeurotic fibres, passing obliquely downwards and outwards, from the sharp ridge on the tibia, to the inner edge of the fibula, and crossed at an acute angle by a few fibres passing in the opposite direction. The ligament is deficient above, leaving a considerable interval between the bones, through which the anterior tibial artery takes its course forwards to the anterior aspect of the leg, and near its lower third there is an opening for the anterior peroneal artery and vein.

The interosseous membrane is *in relation, in front*, with the tibialis anticus, extensor longus digitorum, and extensor proprius pollicis muscle, with the anterior tibial vessels and nerve, and with the anterior peroneal artery; and *behind* with the tibialis posticus, and flexor longus digitorum muscle, and with the posterior peroneal artery.

The *inferior interosseous ligament* consists of short and strong fibres, which hold the bones firmly together, inferiorly where they

are nearly in contact. This articulation is so firm that the fibula is likely to be broken in the attempt to rupture the ligament.

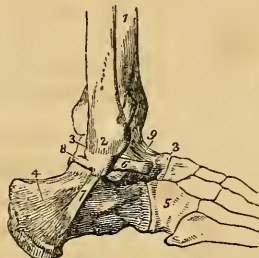
The *anterior inferior ligament* is a broad band, consisting of two fasciculi of parallel fibres that pass obliquely across the anterior aspect of the articulation of the two bones at their inferior extremity, from the tibia to the fibula.

The *posterior inferior ligament* (fig. 71. 2) is a similar band upon the posterior surface of the articulation. Both ligaments project somewhat below the margin of the bones, and serve to deepen the cavity of articulation for the astragalus.

Fig. 69.

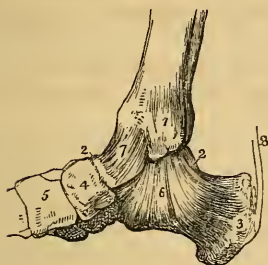

Fig. 70.



The *transverse ligament* (fig. 71. 3) is a narrow band of ligamentous fibres, continuous with the preceding, and passing transversely across the back of the ankle joint between the two malleoli.

The *synovial membrane* of the inferior tibio-fibular articulation, is a duplicature reflected upwards for a short distance between the two bones.

Actions.—An obscure movement exists between the tibia and fibula, which is principally calculated to enable the latter to resist injury by yielding for a trifling extent to the pressure exerted.

4. *Ankle joint.*—The ankle is a ginglymoid articulation, the surfaces entering into the formation of the joint are the under surface of the tibia with its malleolus and the malleolus of the fibula, above; and the surface of the astragalus with its two lateral facets, below. The ligaments are three in number :

Anterior,
Internal lateral,
External lateral.

Fig. 69. An internal view of the ankle joint. 1. The internal malleolus of the tibia. 2, 2. Part of the astragalus; the rest is concealed by the ligaments. 3. The os calcis. 4. The scaphoid bone. 5. The internal cuneiform bone. 6. The internal lateral or deltoid ligament. 7. The anterior ligament. 8. The tendo Achillis; a small bursa is seen interposed between this tendon and the tuberosity of the os calcis.

Fig. 70. An external view of the ankle joint. 1. The tibia. 2. The external malleolus of the fibula. 3, 3. The astragalus. 4. The os calcis. 5. The cuboid bone. 6. The anterior fasciculus of the external lateral ligament attached to the astragalus. 7. Its middle fasciculus, attached to the os calcis. 8. Its posterior fasciculus, attached to the astragalus. 9. The anterior ligament of the ankle.

The *anterior ligament* is a thin membranous layer, passing from the margin of the tibia to the astragalus in front of the articular surface. It is *in relation, in front*, with the extensor tendons of the great and lesser toes, with the tendon of the tibialis anticus and peroneus tertius, and with the anterior tibial vessels and nerve. *Posteriorly* it lies in contact with the extra-synovial adipose tissue and with the synovial membrane.

The *internal lateral ligament* or *deltoid*, is a triangular layer of fibres attached superiorly by its apex to the internal malleolus, and inferiorly by an expanded base to the astragalus, os calcis, and scaphoid bone. Beneath the superficial layer of this ligament is a much stronger and thicker fasciculus of fibres, which connects the apex of the internal malleolus with the side of the astragalus.

This internal lateral ligament is covered in and partly concealed by the tendon of the tibialis posticus, and its posterior part is in relation with the tendon of the flexor longus digitorum, and of the flexor longus pollicis.

The *external lateral ligament* consists of three strong fasciculi, which proceed from the inner side of the external malleolus, and diverge in three different directions. The *anterior fasciculus* passes forwards, and is attached to the astragalus; the *posterior* backwards, and is connected with the astragalus posteriorly; and the *middle*, longer than the other two, descends to be inserted into the outer side of the os calcis.

“It is the strong union of this bone,” says Sir Astley Cooper, “with the tarsal bones by means of the external lateral ligaments, which leads to its being more frequently fractured than dislocated.”

The transverse ligament of the tibia and fibula occupies the place of a posterior ligament. It is *in relation, behind*, with the posterior tibial vessels and nerve, and with the tendon of the tibialis posticus muscle; and *in front*, with the extra-synovial adipose tissue, and synovial membrane.

The *Synovial membrane* invests the cartilaginous surfaces of the tibia and fibula, sending a duplicature upwards between their lower ends; and the upper surface and two sides of the astragalus. It is then reflected upon the anterior and lateral ligaments, and upon the transverse ligament posteriorly.

Actions.—The movements of the ankle joint are *flexion* and *extension* only, without lateral motion.

5. *Articulations of the Tarsal Bones.*—The ligaments which connect the seven bones of the tarsus to each other are of three kinds,—

Dorsal,
Plantar,
Interosseous.

The *dorsal ligaments* are small fasciculi of parallel fibres, which pass from each bone to all the neighbouring bones with which it articulates. The only dorsal ligaments deserving of particular mention are, the external and posterior calcaneo-astragaloid, which,

with the interosseous ligament, complete the articulations of the astragalus with the os calcis; the superior and internal calcaneo-cuboid ligaments; and the superior astragalo-scaploid ligament. The internal calcaneo-cuboid and the superior calcaneo-scaploid ligament, which are closely united posteriorly in the deep groove which intervenes between the astragalus and os calcis, separate anteriorly to reach their respective bones, and form the principal bond of connexion between the first and second range of bones of the foot. It is the division of this portion of these ligaments that demands the especial attention of the surgeon in performing Chopart's operation.

The *plantar ligaments* have the same disposition on the plantar surface of the foot; three of them, however, are of large size and have especial names, viz. the

Calcaneo-scaploid,
Long calcaneo-cuboid,
Short calcaneo-cuboid.

The *inferior calcaneo-scaploid ligament* is a broad and fibro-cartilaginous band of ligament, which passes forwards from the anterior and inner border of the os calcis to the edge of the scaphoid bone. In addition to connecting the os calcis and scaphoid, it supports the astragalus, and forms part of the cavity in which its rounded head is received. It is lined upon its upper surface by the synovial membrane of the astragalo-scaploid articulation.

The firm connexion of the os calcis with the scaphoid bone, and the feebleness of the astragalo-scaploid articulation are conditions favourable to the occasional dislocation of the head of the astragalus.

The *long calcaneo-cuboid*, or *ligamentum longum plantæ*, is a long band of ligamentous fibres, which proceeds from the under surface of the os calcis to the rough surface on the under part of the cuboid bone, its fibres being continued onwards to the bases of the third and fourth metatarsal bones.

This ligament forms the inferior boundary of a canal in the cuboid bone, through which the tendon of the peroneus longus passes to its insertion into the base of the metatarsal bone of the great toe.

The *short calcaneo-cuboid*, or *ligamentum breve plantæ*, is situated nearer to the bones than the long plantar ligament, from which it is separated by adipose tissue; it is broad and extensive, and ties the under surface of the os calcis and cuboid bone firmly together.

The *interosseous ligaments* are five in number; they are short

Fig. 71.

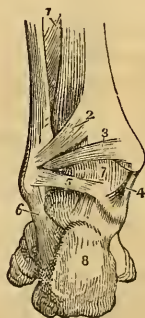
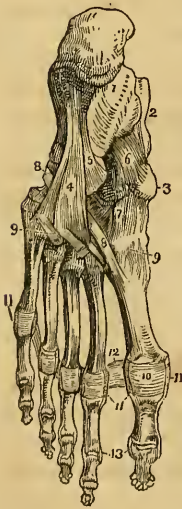


Fig. 71. A posterior view of the ankle joint. 1. The lower part of the interosseous membrane. 2. The posterior inferior ligament connecting the tibia and fibula. 3. The transverse ligament. 4. The internal lateral ligament. 5. The posterior fasciculus of the external lateral ligament. 6. The middle fasciculus of the external ligament. 7. The synovial membrane of the ankle joint. 8. The os calcis.

and strong ligamentous fibres situated between adjoining bones, and firmly attached to their rough surfaces. One of these, the *calcaneo-astragaloid*, is lodged in the groove between the upper surface of the os calcis, and the lower of the astragalus. It is large and very strong, consists of vertical and oblique fibres, and serves to unite the os calcis and astragalus solidly together. The second interosseous ligament, also very strong, is situated between the sides of the scaphoid and cuboid bone; while the three remaining ligaments connect strongly together the three cuneiform bones and the cuboid.

The *synovial membranes* of the tarsus are four in number; *one*, for the posterior calcaneo-astragaloid articulation; *a second*, for the anterior calcaneo-astragaloid and astragalo-scaphoid articulation. Occasionally an additional small synovial membrane is found in the anterior calcaneo-astragaloid joint; *a third*, for the calcaneo-cuboid articulation; and *a fourth*, the large tarsal synovial membrane, for the articulations between the scaphoid and three cunei-

Fig. 72.



form bones, the cuneiform bones with each other, the external cuneiform bone with the cuboid, and the two external cuneiform bones with the bases of the second and third metatarsal bones. The prolongation which reaches the metatarsal bones passes forwards between the internal and middle cuneiform bones. A small synovial membrane is sometimes met with between the contiguous surfaces of the scaphoid and cuboid bone.

Actions.—The movements permitted by the articulation between the astragalus and os calcis, are a slight degree of gliding, in the directions *forwards* and *backwards* and *laterally* from side to side. The movements of the second range of tarsal bones are very trifling, being greater between the scaphoid and three cuneiform bones than in the other articulations. The movements occurring between the first and second range are the most considerable; they are *adduction* and *abduction*, and, in a minor degree, *flexion*, which increases the arch of the foot, and *extension*, which flattens the arch.

6. *Tarso-metatarsal Articulations.*—The ligaments of this articulation are,

Fig. 72. The ligaments of the sole of the foot. 1. The os calcis. 2. The astragalus. 3. The tuberosity of the scaphoid bone. 4. The long calcaneo-cuboid ligament. 5. Part of the short calcaneo-cuboid ligament. 6. The calcaneo-scaphoid ligament. 7. The plantar tarsal ligaments. 8, 8. The tendon of the peroneus longus muscle. 9, 9. Plantar tarso-metatarsal ligaments. 10. Plantar ligament of the metatarso-phalangeal articulation of the great toe; the same ligament is seen upon the other toes. 11. Lateral ligaments of the metatarso-phalangeal articulation. 12. Transverse ligament. 13. The lateral ligaments of the phalanges of the great toe; the same ligaments are seen upon the other toes.

Dorsal,
Plantar,
Interosseous.

The *dorsal ligaments* connect the metatarsal to the tarsal bones, and the metatarsal bones with each other.

The *plantar ligaments* have the same disposition on the plantar surface.

The *interosseous ligaments* are situated between the bases of the metatarsal bones of the four lesser toes, and also between the base of the second metatarsal bone, and the internal and external cuneiform bone.

The metatarsal bone of the second toe is implanted by its base between the internal and external cuneiform bones, and is the most strongly articulated of all the metatarsal bones. This disposition must be recollected in amputation at the tarso-metatarsal articulation.

The *synovial membranes* of this articulation are three in number: one for the metatarsal bone of the great toe; one for the second and third metatarsal bones, which is continuous with the great tarsal synovial membrane; and one for the fourth and fifth metatarsal bones.

Actions.—The movements of the metatarsal bones upon the tarsal and upon each other are very slight; they are such only as contribute to the strength of the foot by permitting a certain degree of yielding to opposing forces.

7. *Metatarso-phalangeal Articulation.*—The ligaments of this articulation, like those of the articulation between the first phalanges and metacarpal bones of the hand, are,

Anterior or plantar,
Two lateral,
Transverse.

The *anterior* or *plantar ligaments* are thick and fibro-cartilaginous, and form part of the articulating surface of the joint.

The *lateral ligaments* are short and very strong, and situated on each side of the joints.

The *transverse ligaments* are strong bands, which pass transversely between the anterior ligaments.

The expansion of the extensor tendon supplies the place of a dorsal ligament.

Actions.—The movements of the first phalanges upon the rounded heads of the metatarsal bones are *flexion*, *extension*, *adduction* and *abduction*.

8. *Articulation of the Phalanges.*—The ligaments of the phalanges are the same as those of the fingers, and have the same disposition; their actions are also similar. They are,

Anterior or plantar,
Two lateral.

CHAPTER III.

ON THE MUSCLES.

MUSCLES are the moving organs of the animal frame: they constitute by their size and number the great bulk of the body, upon which they bestow form and symmetry. In the limbs they are situated around the bones, which they invest and defend, while they form to some of the joints a principal protection. In the trunk they are spread out to enclose cavities, and constitute a defensive wall capable of yielding to internal pressure, and again returning to its original form.

Their colour presents the deep red which is characteristic of flesh, and their form is variously modified, to execute the varied range of movements which they are required to effect.

Muscle is composed of a number of parallel fibres placed side by side, and supported and held together by a delicate web of cellular tissue; so, that if it were possible to remove the muscular substance, we should have remaining a beautiful cellular framework, possessing the exact form and size of the muscle without its colour and solidity. Towards the extremity of the organ the muscular fibre ceases, and the cellular structure becomes aggregated and modified, so as to constitute those glistening fibres and cords by which the muscle is tied to the surface of bone, and which are called *tendons*. Almost every muscle in the body is connected with bone, either by tendinous fibres, or by an aggregation of those fibres constituting a tendon; and the union is so firm, that, under extreme violence, the bone itself rather breaks than permits of the separation of the tendon from its attachment. In the broad muscles the tendon is spread so as to form an expansion, called *aponeurosis* ($\acute{\alpha}\pi\delta$, long; $\nu\sigma\tilde{\upsilon}\rho\omicron\nu$,* *nervus*—a nerve widely spread out).

Muscles present various modifications in the arrangement of their fibres in relation to their tendinous structure. Sometimes they are completely longitudinal, and terminate at each extremity in tendon, the entire muscle being *fusiform* in its shape; in other situations they are disposed like the rays of a fan, converging to a tendinous point, as the temporal, pectoral, glutei, &c., and constitute a *radiate* muscle. Again, they are *penniform*, converging like the plumes of a pen to one side of a tendon which runs the whole length of the

* The ancients named all the white fibres of the body $\nu\sigma\tilde{\upsilon}\rho\omicron\nu$; the term has since been limited to the nerves.

muscle, as in the peronei; or *bipenniform*, converging to both sides of the tendon. In other muscles the fibres pass obliquely from the surface of a tendinous expansion spread out on one side, to that of another extended on the opposite side, as in the semi-membranosus; or they are composed of penniform or bipenniform fasciculi as in the deltoid, and constitute a compound muscle.

The nomenclature of the muscles is defective and confused, and is generally derived from some prominent character which each muscle presents: thus, some are named from their situation, as the tibialis, peroneus; others from their uses, as the flexors, extensors, adductors, abductors, levators, tensors, &c. Some again from their form, as the trapezius, triangularis, deltoid, &c.; and others from their direction, as the rectus, obliquus, transversalis, &c. Some muscles have received names expressive of their attachments, as the sterno-mastoid, sterno-hyoid, &c.; and others, of their divisions, as the biceps, triceps, digastricus, complexus, &c.

In the description of a muscle we express its attachment by the words "origin" and "insertion;" the term *origin* being generally applied to the more fixed or central attachment, or to the point towards which the motion is directed while *insertion* is assigned to the more movable point, or to that, most distant from the centre; but there are many exceptions to this principle, and as many muscles pull equally by both extremities, the use of such terms must be regarded as purely arbitrary.

In structure, muscle is composed of bundles of fibres of variable size called fasciculi, which are enclosed in a cellular membranous investment or sheath, and the latter is continuous with the cellular framework of the fibres. Each *fasciculus* is composed of a number of smaller bundles, and these of single fibres, which, from their minute size and independent appearance, have been distinguished by the name of ultimate fibres. The *ultimate fibre* is found

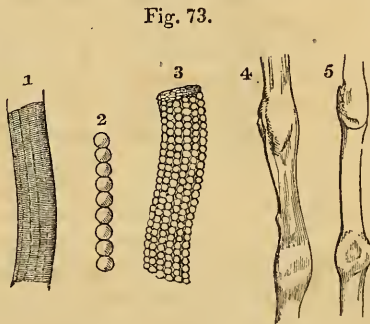


Fig. 73. 1. A muscular fibre of animal life enclosed in its myolemma; the transverse and longitudinal striæ are seen.

2. An ultimate fibril of muscular fibre of animal life.

3. A muscular fibre of animal life, similar to 1 but more highly magnified. Its myolemma is so thin and transparent as to permit the ultimate fibrils to be seen through. The true nature of the longitudinal striæ is seen in this fibre as well as the mode of formation of the transverse striæ.

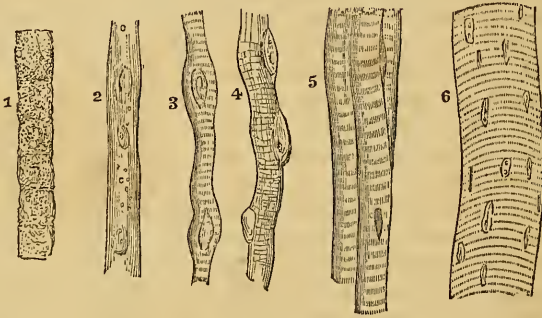
4. A muscular fibre of organic life from the urinary bladder, magnified 600 times, linear measure. Two of the nuclei are seen.

5. A muscular fibre of organic life, from the stomach, magnified 600 times. The diameter of this and of the preceding fibre, midway between the nuclei, was 1-4750th of an inch.

by microscopic investigation, to be itself made up of a number of *ultimate fibrils* enclosed in a delicate sheath or myolemma.* Two kinds of ultimate muscular fibre exist in the animal economy; viz., that of voluntary or animal life, and that of involuntary or organic life.

The *fibre of animal life* is recognised from being marked by transverse and slightly waving striæ. The *fibre of organic life* has no transverse striæ, and is much smaller than the fibre of animal life. It is polygonal in form or nearly cylindrical, and appears to consist of a number of minute parallel filaments enclosed in a myolemma. The most remarkable character of the organic fibre is the existence from point to point of swellings somewhat larger than the diameter of the fibre, and produced by the nuclei of the original nucleated cells from which the fibre was developed.

Fig. 74.



The *ultimate fibrils* are minute beaded filaments in the fibre of animal life, and cylindrical and uniform in the organic fibre.

According to the researches of Mr. Bowman† the *ultimate fibres* (primitive fasciculi) are polygonal, a form which is well suited to admit of their being collected into bundles. In size they are very variable, not only in the different classes and genera of animals, but also in the same animal and even in the same muscle. He

Fig. 74. Development of muscular fibre. 1. Primitive cells in a linear series. 2. The cells united and the nuclei separated. 3 and 4. The transverse striæ are becoming apparent. 5. Transverse striæ formed and nuclei disappearing. 6. A fully formed muscular fibre treated with acetic acid, which develops the nuclei previously concealed. The whole magnified 300 diameters.

* In the summer of 1836, while engaged with Dr. Jones Quain in the examination of the animal tissues, with a simple dissecting microscope, constructed by Powell, I first saw that the ultimate fibre of muscle was invested by a proper sheath, for which I proposed the term "Myolemma;" a term which was adopted by Dr. Quain in the fourth edition of his "Elements of Anatomy." We at that time believed that the transverse folding of that sheath gave rise to the appearance of transverse striæ, an opinion which subsequent examinations proved to be incorrect. Mr. Bowman employs the term "Sarcolemma" as synonymous with Myolemma.

† On the Minute Structure and Movements of Voluntary Muscle. By Wm. Bowman, Esq. From the Philosophical Transactions for 1840.

has observed, moreover, that they are somewhat smaller in the female than in the male; thus the average diameter of the ultimate fibre in the female, is $\frac{1}{4\frac{1}{5}4}$; in the male $\frac{1}{3\frac{1}{5}2}$; the average of both being $\frac{1}{4\frac{1}{0}3}$. In the different classes of animals examined by Mr. Bowman, the largest ultimate fibre was met with in fishes, in which the average diameter is $\frac{1}{2\frac{1}{2}2}$; next in man; and then in other classes in the following order: insects, $\frac{1}{4\frac{1}{9}9}$; reptiles, $\frac{1}{4\frac{1}{8}4}$; mammalia, $\frac{1}{5\frac{1}{6}1}$; birds, $\frac{1}{8\frac{1}{0}7}$.

The *ultimate fibrils*, (primitive fibrillæ) consist of segments separated from each other by constrictions, which give to the entire fibril the appearance of a string of beads. The constrictions are narrower than the segments, and their component substance is probably less dense than that which forms the segments. An ultimate fibre consists of a bundle of fibrils, which are so disposed that all the segments and all the constrictions correspond, and these give rise to the alternate light and dark lines of the transverse striæ. The fibrils are connected together with very different degrees of closeness in different

animals; in man they are but slightly adherent, and distinct longitudinal lines of junction may be observed between them,—they also separate very easily when macerated for some time. Besides the more usual separation of the ultimate fibre into fibrils, it breaks, when stretched, into transverse sections, corresponding with the dark line of the striæ, and consequently with the constrictions of the fibrillæ. When this division occurs with the greatest facility, the longitudinal lines are indistinct or scarcely perceptible. "In fact," says Mr. Bowman, "the primitive fasciculus seems to consist of primitive component segments or particles, arranged so as to form, in one sense, fibrillæ, and in another sense, discs; and which of these two may happen to present themselves to the observer, will depend on the amount of adhesion, endways or sideways, existing between the segments. Generally, in a recent fasciculus, there are transverse striæ, showing divisions into discs, and longitudinal striæ, marking its composition by fibrillæ."

Mr. Bowman has observed that in the substance of the ultimate

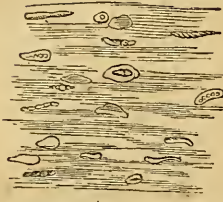
Fig. 75.

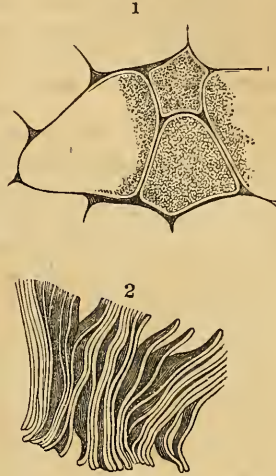

Fig. 75. 1. Transverse section of ultimate fibres of the biceps, copied from the illustrations to Mr. Bowman's paper. In this figure the polygonal form of the fibres is seen, and their composition of ultimate fibrils.

2. An ultimate fibre, in which the transverse splitting into discs, in the direction of the constrictions of the ultimate fibrils is seen. From Mr. Bowman's paper.

Fig. 76.



fibres there exist minute "oval or circular discs, frequently concave on one or both surfaces, and containing, somewhere near the centre, one, two or three minute dots or granules." Occasionally they are seen to present irregularities of form, which Mr. Bowman is inclined to regard as accidental. They are situated between, and are connected with, the fibrils, and are distributed in pretty equal numbers through the fibre. These corpuscles are the nuclei of the nucleated cells from which the muscular fibre was originally developed.

From observing, however, that their "absolute number is far greater in the adult than in the fœtus, while their number, relatively to the bulk of the fasciculi, at these two epochs, remains nearly the same," Mr. Bowman regards it as certain, that "during development, and subsequently, a further and successive deposit of corpuscles" takes place. The corpuscles are only brought into view when the muscular fibre is acted upon by a solution of "one of the milder acids, as the citric."

Muscles are divided into two great classes, voluntary and involuntary, to which may be added as an intermediate and connecting link, the muscle of the vascular system, the heart.

The *voluntary*, or *system of animal life*, is developed from the external or serous layer of the germinal membrane, and comprehends the whole of the muscles of the limbs and of the trunk. The *involuntary* or *organic system* is developed from the internal or mucous layer, and constitutes the thin muscular structure of the intestinal canal, bladder, and internal organs of generation. At the commencement of the alimentary canal in the œsophagus, and near its termination in the rectum, the muscular coat is formed by a blending of the fibres of both classes. The heart is developed from the middle, or vascular layer of the germinal membrane; and although involuntary in its action, is composed of ultimate fibres having the transverse striæ of the muscle of animal life.

The muscles may be arranged in conformity with the general division of the body into,—1. Those of the head and neck. 2. Those of the trunk. 3. Those of the upper extremity. 4. Those of the lower extremity.

1. MUSCLES OF THE HEAD AND NECK.

The muscles of the head and neck admit of a subdivision into those of the head and face, and those of the neck.

Fig. 76. Mass of ultimate fibres from the pectoralis major of the human fœtus, at nine months. These fibres have been immersed in a solution of tartaric acid, and their "numerous corpuscles, turned in various directions, some presenting nucleoli," are shown. From Mr. Bowman's paper.

Muscles of the Head and Face.—These muscles may be divided into groups corresponding with the natural regions of the head and face; the groups are eight in number, viz.:

- | | |
|-------------------|---------------------------|
| 1. Cranial group. | 5. Superior labial group. |
| 2. Orbital group. | 6. Inferior labial group. |
| 3. Ocular group. | 7. Maxillary group. |
| 4. Nasal group. | 8. Auricular group. |

The muscles of each of these groups may be thus arranged—

- | | |
|--|--|
| 1. <i>Cranial group.</i>
Occipito-frontalis. | Levator labii superioris proprius, |
| 2. <i>Orbital group.</i>
Orbicularis palpebrarum,
Corrugator supercillii,
Tensor tarsi. | Levator anguli oris,
Zygomaticus major,
Zygomaticus minor,
Depressor labii superioris alæque nasi. |
| 3. <i>Ocular group.</i>
Levator palpebræ,
Rectus superior,
Rectus inferior,
Rectus internus,
Rectus externus,
Obliquus superior,
Obliquus inferior. | 6. <i>Inferior labial group.</i>
(Orbicularis oris,)*
Depressor labii inferioris,
Depressor anguli oris,
Levator labii inferioris. |
| 4. <i>Nasal group.</i>
Pyramidalis nasi,
Compressor nasi. | 7. <i>Maxillary group.</i>
Masseter,
Temporalis,
Buccinator,
Pterygoideus externus,
Pterygoideus internus. |
| 5. <i>Superior labial group.</i>
(Orbicularis oris),
Levator labii superioris alæque nasi, | 8. <i>Auricular group.</i>
Attolens aurem,
Attrahens aurem,
Retrahens aurem. |

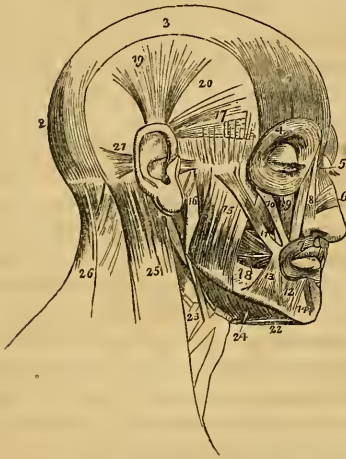
Dissection.—The *occipito-frontalis* is to be dissected by making a longitudinal incision along the vertex of the head, from the tubercle on the occipital bone to the root of the nose; and a second incision along the forehead and around the side of the head, to join the two extremities of the preceding. Dissect the integument and superficial fascia carefully outwards, beginning at the anterior angle of the flap, where the muscular fibres are thickest, and remove it altogether. This dissection requires care; for the muscle is very thin, and without attention would be raised with the integument. There is no deep fascia on the face and head, nor is it required; for here

* The orbicularis oris, from encircling the mouth, belongs necessarily to both the superior and inferior labial regions; it is therefore enclosed within brackets in both.

the muscles are closely applied against the bones upon which they depend for support, whilst in the extremities the support is derived from the dense layer of fascia by which they are invested, and which forms for each a distinct sheath.

The *occipito-frontalis* is a broad musculo-tendinous layer, which covers the whole of one side of the vertex of the skull, from the occiput to the eyebrow. It *arises* by tendinous fibres from the outer two-thirds of the superior curved line of the occipital bone, and from the mastoid portion of the temporal; it is *inserted* into the orbicularis palpebrarum muscle and the internal angular process of the frontal bone. The muscle is fleshy in front over the frontal bone and behind over the occipital, the portions being connected by a broad aponeurosis. The two muscles cover the whole of the vertex of the skull, hence their designation *galea capitis*; they are loosely adherent to the pericranium, but very closely to the integument, particularly over the forehead.

Fig. 77.



Relations.—This muscle is in relation by its *external surface* from before backwards, with the frontal and supra-orbital vessels, the supra-orbital and fascial nerve, the temporal vessels and nerve, the occipital vessels and nerves, and with the integument, to which it is very closely adherent. Its *under surface* is attached to the

pericranium by a loose cellular tissue which admits of considerable movement.

Action.—To raise the eyebrows, thereby throwing the integument of the forehead into transverse wrinkles. Some persons have the

Fig. 77. The muscles of the head and face. 1. The frontal portion of the occipito-frontalis. 2. Its occipital portion. 3. Its aponeurosis. 4. The orbicularis palpebrarum, which conceals the corrugator supercillii and tensor tarsi. 5. The pyramidalis nasi. 6. The compressor nasi. 7. The orbicularis oris. 8. The levator labii superioris alæque nasi. The figure is placed on the nasal portion. 9. The levator labii superioris proprius; the lower part of the levator anguli oris is seen between the muscles 10 and 11. 10. The zygomaticus minor. 11. The zygomaticus major. 12. The depressor labii inferioris. 13. The depressor anguli oris. 14. The levator labii inferioris. 15. The superficial portion of the masseter. 16. Its deep portion. 17. The retrahens aurem. 18. The buccinator. 19. The attonens aurem. 20. The temporal fascia which covers in the temporal muscle. 21. The retrahens aurem. 22. The anterior belly of the digastric muscle; the tendon is seen passing through its aponeurotic pulley. 23. The stylo-hyoid muscle pierced by the posterior belly of the digastric. 24. The mylo-hyoideus muscle. 25. The upper part of the sterno-mastoid. 26. The upper part of the trapezius. The muscle between 25 and 26 is the splenius.

power of moving the entire scalp upon the pericranium by means of these muscles.

Dissection.—The dissection of the face is to be effected by continuing the longitudinal incision of the vertex of the previous dissection onwards to the tip of the nose, and thence downwards to the margin of the upper lip; then carry an incision along the margin of the lip to the angle of the mouth, and transversely across the face to the angle of the lower jaw. Lastly, divide the integument in front of the external ear upwards to the transverse incision which was made for exposing the occipito-frontalis. Dissect the integument and superficial fascia carefully from the whole of the region included by these incisions, and the three next groups of muscles will be brought into view.

2. *Orbital group.*—Orbicularis palpebrarum,
Corrugator supercillii,
Tensor tarsi.

The *orbicularis palpebrarum* is a sphincter muscle, surrounding the orbit and eyelids. It *arises* from the internal angular process of the frontal bone, from the nasal process of the superior maxillary, and from a short tendon (*tendo oculi*) which extends between the nasal process of the superior maxillary bone, and the inner extremities of the tarsal cartilages of the eyelids. The fibres encircle the orbit and eyelids, forming a broad and thin muscular plane, which is *inserted* into the lower border of the *tendo oculi* and into the nasal process of the superior maxillary bone. Upon the eyelids the fibres are very thin and pale, and possess an involuntary action. The *tendo oculi*, in addition to its insertion into the nasal process of the superior maxillary bone, sends a process inwards, which expands over the lachrymal sac, and is attached to the ridge of the lachrymal bone: this is the reflected aponeurosis of the *tendo oculi*.

Relations.—By its *superficial surface* it is closely adherent to the integument, from which it is separated over the eyelids by a loose serous cellular tissue. By its *deep surface* it lies in contact *above* with the upper border of the orbit, with the corrugator supercillii muscle, and with the frontal and supra-orbital vessels and supra-orbital nerve; *below*, with the lachrymal sac, with the origins of the labii superioris alæque nasi, levator labii superioris proprius, zygomaticus major and minor muscles, and malar bone; and *externally* with the temporal fascia. Upon the eyelid it is in relation with the broad tarsal ligament and tarsal cartilages, and by its upper border gives attachment to the occipito-frontalis muscle.

The *corrugator supercillii* is a small narrow and pointed muscle, situated immediately above the orbit and beneath the upper segment of the orbicularis palpebrarum muscle. It *arises* from the inner extremity of the superciliary ridge, and is *inserted* into the under surface of the orbicularis palpebrarum.

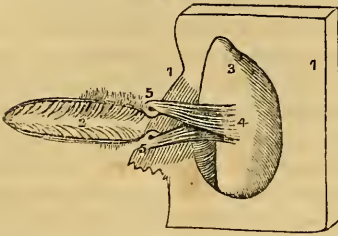
Relations.—By its *superficial surface*, with the pyramidalis nasi,

occipito-frontalis and orbicularis palpebrarum muscle; and by its *deep surface* with the supra-orbital vessels and nerve.

The *tensor tarsi* (Horner's* muscle) is a thin plane of muscular fibres, about three lines in breadth and six in length. It is best dissected by separating the eyelids of the eye, and turning them over the nose without disturbing the tendo oculi; then dissect away the small fold of mucous membrane called plica semilunaris, and some loose cellular tissue under which the muscle is concealed. It arises from the orbital surface of the lachrymal bone, and passing across the lachrymal sac divides into two slips, which are *inserted* into the lachrymal canals as far as the puncta.

Actions.—The palpebral portion of the orbicularis acts involuntarily in closing the lids, and from the greater curve of the upper lid, upon that principally. The entire muscle acts as a sphincter, drawing at the same time, by means of its osseous attachment, the integument and lids inwards towards the nose. The corrugatores superciliarum draw the eyebrows downwards and inwards, and produce the vertical wrinkles of the forehead. The *tensor tarsi*, or

Fig. 78.



lachrymal muscle, draws the extremities of the lachrymal canals inwards, so as to place the puncta in the best position for receiving the tears. It serves also to keep the lids in relation with the surface of the eye, and compresses the lachrymal sac. Dr. Horner is acquainted with two persons who have the voluntary power of drawing the lids inwards by these muscles so as to bury the puncta in the angle of the eye.

3. *Ocular group.*—Levator palpebræ,
 Rectus superior,
 Rectus inferior,
 Rectus internus,
 Rectus externus.
 Obliquus superior,
 Obliquus inferior.

Dissection.—To open the orbit (the calvarium and brain having been removed) the frontal bone must be sawn through at the inner extremity of the orbital ridge; and, externally, at its outer extremity. The roof of the orbit may then be comminuted by a few light blows with the hammer; a process easily accomplished, on account of the thinness of the orbital plate of the frontal bone and lesser wing of

Fig. 78. A view of the tensor tarsi muscle. 1, 1. Bony margins of the orbit. 2. Opening between the eyelids. 3. Internal face of the orbit. 4. Origin of the tensor tarsi. 5, 5. Insertion into the neighbourhood of the puncta lachrymalia.

* W. E. Horner, M.D., Professor of Anatomy in the University of Pennsylvania. The notice of this discovery is contained in a work published in Philadelphia in 1827, entitled "Lessons in Practical Anatomy."

the sphenoid. The superciliary portion of the orbit may now be driven forwards by a smart blow, and the broken fragments of the roof of the orbit removed. The periosteum will then be exposed unbroken and undisturbed. Remove the periosteum from the whole of the upper surface of the exposed orbit, and the muscles may then be examined.

The *levator palpebræ* is a long, thin, and triangular muscle; it *arises* from the upper margin of the optic foramen, and from the fibrous sheath of the optic nerve, and is *inserted* into the upper border of the superior tarsal cartilage.

Relations.—By its *upper surface* with the fourth nerve, the supra-orbital nerve and artery, the periosteum of the orbit, and in front with the broad tarsal ligament.

By its *under surface* it rests upon the superior rectus muscle, and the globe of the eye; it receives its nerve and artery by this aspect, and in front is lined for a short distance by the conjunctiva.

The *rectus superior* (*attollens*) *arises* from the upper margin of the optic foramen, and from the fibrous sheath of the optic nerve, and is *inserted* into the upper surface of the globe of the eye at a point somewhat more than three lines from the margin of the cornea.

Relations.—By its *upper surface* with the levator palpebræ muscle; and by the *under surface* with the optic nerve, the ophthalmic artery and nasal nerve, from which it is separated by a layer of fascia and by the adipose tissue of the orbit, and in front with the globe of the eye, the tendon of the superior oblique muscle being interposed.

The *rectus inferior* (*depressor*) *arises* from the inferior margin of the optic foramen by a tendon (ligament of Zinn) which is common to it, the internal and the external rectus, and from the fibrous sheath of the optic nerve; it is *inserted* into the inferior surface of the globe of the eye at a little more than two lines from the margin of the cornea.

Relations.—By its *upper surface* with the optic nerve, the inferior oblique branch of the third nerve, the adipose tissue of the orbit, and the under surface of the globe of the eye. By its *under*

Fig. 79.

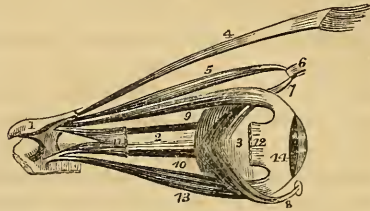


Fig. 79. The muscles of the eyeball; the view is taken from the outer side of the right orbit. 1. A small fragment of the sphenoid bone around the entrance of the optic nerve into the orbit. 2. The optic nerve. 3. The globe of the eye. 4. The levator palpebræ muscle. 5. The superior oblique muscle. 6. Its cartilaginous pulley. 7. Its reflected tendon. 8. The inferior oblique muscle, the small square knob at its commencement is a piece of its bony origin broken off. 9. The superior rectus. 10. The internal rectus almost concealed by the optic nerve. 11. Part of the external rectus, showing its two heads of origin. 12. The extremity of the external rectus at its insertion; the intermediate portion of the muscle having been removed. 13. The inferior rectus. 14. The tunica albuginea, formed by the expansion of the tendons of the four recti.

surface with the periosteum of the floor of the orbit, and with the inferior oblique muscle.

The *rectus internus* (adductor), the thickest and shortest of the straight muscles, *arises* from the common tendon, and from the fibrous sheath of the optic nerve; and is *inserted* into the inner surface of the globe of the eye at two lines from the margin of the cornea.

Relations.—By its *internal surface* with the optic nerve, the adipose tissue of the orbit and the eyeball. By its *outer surface* with the periosteum of the orbit, and by its *upper border* with the anterior and posterior ethmoidal vessels, the nasal and supra-trochlear nerve.

The *rectus externus* (abductor), the longest of the straight muscles, *arises* by two distinct heads, one from the common tendon, the other with the origin of the superior rectus from the margin of the optic foramen; the nasal, third and sixth nerves passing between its heads. It is *inserted* into the outer surface of the globe of the eye at a little more than two lines from the margin of the cornea.

Relations.—By its *internal surface* with the third, the nasal, the sixth, and the optic nerve, the ciliary ganglion and nerves, the ophthalmic artery and vein, the adipose tissue of the orbit, the inferior oblique muscle, and the eyeball. By its *external surface* with the periosteum of the orbit; and by the *upper border* with the lachrymal vessels and nerve and the lachrymal gland.

The recti muscles present several characters which are common to all: thus, they are thin, have the form of an isosceles triangle, bear the same relation to the globe of the eye, and are inserted in a similar manner into the sclerotica, at about two lines from the circumference of the cornea. The points of difference relate to thickness and length; the internal rectus is the thickest and most short, the external rectus the longest of the four, and the superior rectus the most thin. The insertion of the four recti muscles into the globe of the eye forms a tendinous expansion, which is continued as far as the margin of the cornea, and is called the tunica albuginea.

The *obliquus superior* (trochlearis) is a fusiform muscle, *arising* from the margin of the optic foramen and from the fibrous sheath of the optic nerve; it passes forwards to the pulley beneath the internal angular process of the frontal bone; its tendon is then reflected beneath the superior rectus muscle, to the outer and posterior part of the globe of the eye, where it is *inserted* into the sclerotic coat, near the entrance of the optic nerve. The tendon is surrounded by a synovial membrane, while passing through the cartilaginous pulley.

Relations.—By its *superior surface* with the fourth nerve, the supra-trochlear nerve, and with the periosteum of the orbit. By the *inferior surface* with the adipose tissue of the orbit, the upper border of the internal rectus, and the vessels and nerves in relation with that border.

The *obliquus inferior*, a thin and narrow muscle, *arises* from the inner margin of the superior maxillary bone, immediately external

to the lachrymal groove, and passes beneath the inferior rectus, to be *inserted* into the outer and posterior part of the eyeball, at about two lines from the entrance of the optic nerve.

Relations.—By its *superior surface* with the inferior rectus muscle and with the eyeball; and by the *inferior surface* with the periosteum of the floor of the orbit and the external rectus muscle.

According to Mr. Ferrall* the muscles of the orbit are separated from the globe of the eyeball and from the structures immediately surrounding the optic nerve, by a distinct fascia, which is continuous with the broad tarsal ligament and with the tarsal cartilages. This fascia the author terms, the *tunica vaginalis oculi*; † it is pierced anteriorly for the passage of the six orbital muscles by six openings, through which the tendons of the muscles play, as through pulleys. The use assigned to it by Mr. Ferrall is to protect the eyeball from the pressure of its muscles during their action. By means of this structure the recti muscles are enabled to impress a rotatory movement upon the eyeball; and in animals provided with a retractor muscle, they also act as antagonists to its action.

Actions.—The levator palpebræ raises the upper eyelid. The four recti, acting singly, pull the eyeball in the four directions of upwards, downwards, inwards, and outwards. Acting by pairs, they carry the eyeball in the diagonal of these directions, viz. upwards and inwards, upwards and outwards, downwards and inwards, or downwards and outwards. Acting altogether, they directly retract the globe within the orbit. The superior oblique muscle, acting alone, rolls the globe inwards and forwards, and carries the pupil outwards and downwards to the lower and outer angle of the orbit. The inferior oblique, acting alone, rolls the globe outwards and backwards, and carries the pupil outwards and upwards to the upper and outer angle of the eye. Both muscles acting together, draw the eyeball forwards, and give the pupil that slight degree of eversion which enables it to admit the largest field of vision.

4. *Nasal group.*—Pyramidalis nasi. ‡
Compressor nasi.

The *pyramidalis nasi* is a small pyramidal slip of muscular fibres sent downwards upon the nose by the occipito-frontalis. It is *inserted* into the tendinous expansion of the compressores nasi.

Relations.—By its *upper surface* with the integument; by its *under surface* with the periosteum of the nasal bone. Its *outer border* corresponds with the edge of the orbicularis palpebrarum, and its *inner border* with its fellow, from which it is separated by a slight interval.

The *compressor nasi* is a thin and triangular muscle; it *arises* by its apex from the canine fossa of the superior maxillary bone, and

* In a paper read before the Royal Society, on the 10th of June, 1841.

† This fascia was first described by Mr. Dalrymple in his work on the "Anatomy of the Human Eye." 1834.

‡ This is described by Horner as one of the insertions of the occipito-frontalis.—G.

spreads out upon the side of the nose into a thin tendinous expansion, which is continuous across its ridge with the muscle of the opposite side.

Relations.—By its *superficial surface* with the levator labii superioris proprius, the levator labii superioris alæque nasi, and the integument; by its *deep surface* with the superior maxillary and nasal bone, and with the alar and lateral cartilages of the nose.

Actions.—The pyramidalis nasi, as a point of attachment of the occipito-frontalis, assists that muscle in its action; it also draws down the inner angle of the eyebrow, and by its insertion fixes the aponeurosis of the compressores nasi. The compressores nasi appear to act in expanding rather than in compressing the nares; hence probably the compressed state of the nares from paralysis of these muscles in the last moments of life, or in compression of the brain.

5. *Superior Labial group.*—Orbicularis oris,
 Levator labii superioris alæque nasi,
 Levator labii superioris proprius,*
 Levator anguli oris,
 Zygomaticus major,
 Zygomaticus minor,
 Depressor labii superioris alæque nasi.

The *orbicularis oris* is a sphincter muscle, completely surrounding the mouth, and possessing consequently neither origin nor insertion. It is composed of two thick semicircular planes of fibres, which embrace the rima of the mouth, and interlace at their extremities, where they are continuous with the fibres of the buccinator, and of the other muscles connected with the angle of the mouth. The upper segment is attached by means of a small muscular fasciculus (*naso-labialis*) to the columnna of the nose.

Relations.—By its *superficial surface* with the integument of the lips, with which it is closely connected. By its *deep surface* with the mucous membrane of the mouth, the labial glands and coronary arteries being interposed. By its *circumference* with the numerous muscles which move the lips, and by the inner border with the mucous membrane of the rima of the mouth.

The *levator labii superioris alæque nasi* is a thin triangular muscle; it *arises* from the nasal process of the superior maxillary bone; and, becoming broader as it descends, is *inserted* by two distinct portions into the integument of the ala of the nose and upper lip.

Relations.—By its *superficial surface* with a part of the orbicularis palpebrarum muscle, the facial artery, and the integument. By its *deep surface* with the compressor nasi and alar cartilage.

The *levator labii superioris proprius* is a thin quadrilateral muscle; it *arises* from the lower border of the orbit, and is *inserted* into the integument of the upper lip.

Relations.—By its *superficial surface* with the lower segment of

* These two levators are described as one by Horner.—G.

the orbicularis palpebrarum, with the facial artery, and with the integument. By its *deep surface* with the origins of the compressor nasi and levator anguli oris muscle, and with the infra-orbital artery and nerve.

The *levator anguli oris* arises from the canine fossa of the superior maxillary bone, and passes outwards to be *inserted* into the angle of the mouth, intermingling its fibres with those of the orbicularis, zygomatici and depressor anguli oris.

Relations.—By its *superficial surface* with the levator labii superioris proprius, the branches of the infra-orbital artery and nerve, and inferiorly with the integument. By its *deep surface* with the superior maxillary bone and buccinator muscle.

The *zygomatic* muscles are two slender fasciculi of fibres which arise from the malar bone, and are *inserted* into the angle of the mouth, where they are continuous with the other muscles attached to this part. The zygomaticus minor is situated in front of the major, and is continuous at its insertion with the levator labii superioris proprius; it is not unfrequently wanting.

Relations.—The *zygomaticus major* muscle is in relation by its *superficial surface* with the lower segment of the orbicularis palpebrarum above, and the fat of the cheek and integument for the rest of its extent. By its *deep surface* with the malar bone, the masseter, and buccinator muscle, and the facial vessels. The *zygomaticus minor* being in front of the major, has no relation with the masseter muscle, while inferiorly it rests upon the levator anguli oris.

The *depressor labii superioris alæque nasi* (myrtiformis) is seen by drawing upwards the upper lip, and raising the mucous membrane. It is a small oval slip of muscle, situated at each side of the frænum, arising from the incisive fossa, and passing upwards to be *inserted* into the upper lip and ala of the nose. This muscle is continuous by its outer border with the edge of the compressor nasi.

Relations.—By its *superficial surface* with the mucous membrane of the mouth, the orbicularis oris and levator labii superioris alæque nasi muscle; and by its *deep surface* with the superior maxillary bone.

Actions.—The orbicularis oris produces the direct closure of the lips by means of its continuity at the angles of the mouth, with the fibres of the buccinator. When acting singly in the forcible closure of the mouth, the integument is thrown into wrinkles in consequence of its firm connexion with the surface of the muscle. The levator labii superioris alæque nasi lifts the upper lip with the ala of the nose, and expands the opening of the nares. The depressor labii superioris alæque nasi is the antagonist to this muscle, drawing the upper lip and ala of the nose downwards, and diminishing the opening of the nares. The levator labii superioris proprius is the proper elevator of the upper lip; acting singly, it draws the lip a little to one side. The levator anguli oris lifts the angle of the mouth and draws it inwards, while the zygomatici pull it upwards and outwards, as in laughing.

6. *Inferior Labial group*.—Depressor labii inferioris,
Depressor anguli oris,
Levator labii inferioris.

Dissection.—To dissect the inferior labial region, continue the vertical section from the margin of the lower lip to the point of the chin. Then carry an incision along the margin of the lower jaw to its angle. Dissect off the integument and superficial fascia from the whole of this surface, and the muscles of the inferior labial region will be exposed.

The *depressor labii inferioris* (quadratus menti) arises from the oblique line by the side of the symphysis of the lower jaw, and passing upwards and inwards is inserted into the orbicularis muscle and integument of the lower lip.

Relations.—By its *superficial surface* with a part of the depressor anguli oris, and with the integument of the chin, with which it is closely connected. By the *deep surface* with the levator labii inferioris, the labial glands and mucous membrane of the lower lip, and with the mental nerve and artery.

The *depressor anguli oris* (triangularis oris) is a triangular plane of muscle, arising by a broad base from the external oblique ridge of the lower jaw, and inserted by its apex into the angle of the mouth, where it is continuous with the levator anguli oris and zygomaticus major.

Relations.—By its *superficial surface* with the integument, and by its *deep surface* with the depressor labii inferioris, the platysma myoides, the buccinator and the branches of the mental nerve and artery.

The *levator labii inferioris* (levator menti) is a small conical slip of muscle, arising from the incisive fossa of the lower jaw, and inserted into the integument of the chin. It is in relation with the mucous membrane of the mouth, with its fellow, and with the depressor labii inferioris.

Actions.—The depressor labii inferioris draws the lower lip directly downwards, and at the same time a little outwards. The depressor anguli oris, from the radiate direction of its fibres, will pull the angle of the mouth either downwards and inwards, or downwards and outwards, and be expressive of grief; or acting with the levator anguli oris and zygomaticus major, it will draw the angle of the mouth directly backwards. The levator labii inferioris raises and protrudes the integument of the chin.

7. *Maxillary Group*.—Masseter,
Temporalis,
Buccinator,
Pterygoideus externus,
Pterygoideus internus.

Dissection.—The masseter has been already exposed by the preceding dissection.

The *masseter* (μασσοῦμαι, to chew,) is a short and thick and somewhat quadrilateral muscle, composed of two planes of fibres, superficial and deep. The *superficial layer* arises by a strong aponeuro-

sis from the tuberosity of the superior maxillary bone, and from the lower border of the malar bone and zygoma, and passes backwards to be *inserted* into the ramus and angle of the inferior maxilla. The *deep layer arises* from the posterior part of the zygoma, and passes forwards, to be *inserted* into the upper half of the ramus. This muscle is tendinous and muscular in its structure.

Relations.—By its *external surface* with the zygomaticus major and risorius Santorini muscle, the parotid gland and Stenon's duct, the transverse facial artery, the pes anserinus and the integument. By its *internal surface* with the temporal muscle, the buccinator, from which it is separated by a large mass of fat, and with the ramus of the lower jaw. By its *posterior border* with the parotid gland; and by the *anterior border* with the facial artery and vein.

Dissection.—Make an incision along the upper border of the zygoma, for the purpose of separating the temporal fascia from its attachment. Then saw through the zygomatic process of the malar bone, and through the root of the zygoma, near to the meatus auditorius. Draw down the zygoma, and with it the origin of the masseter, and dissect the latter muscle away from the ramus and angle of the inferior maxilla. Now remove the temporal fascia from the rest of its attachment, and the whole of the temporal muscle will be exposed.

The *temporal* is a broad and radiating muscle, occupying a considerable extent of the side of the head and filling the temporal fossa. It is covered in by a very dense fascia (temporal fascia), which is attached along the temporal ridge on the side of the skull, extending from the external angular process of the frontal bone to the mastoid portion of the temporal; inferiorly, it is connected to the upper border of the zygoma. The muscle *arises* by tendinous fibres from the whole length of the temporal ridge, and by muscular fibres from the temporal fascia and from the entire surface of the temporal fossa. Its fibres converge to a strong and narrow tendon, which is *inserted* into the apex of the coronoid process, and for some way down upon its inner surface.

Relations.—By its *external surface* with the temporal fascia, which separates it from the attollens and attrahens aurem muscle, the temporal vessels and nerves; and with the zygoma and masseter. By its *internal surface* with the bones forming the temporal fossa, the external pterygoid muscle, a part of the buccinator, and the internal maxillary artery, with its deep temporal branches.

By sawing through the coronoid process near to its base, and pulling it upwards, together with the temporal muscle, which may be dissected from the fossa, we obtain a view of the entire extent of the buccinator and of the external pterygoid muscle.

The *buccinator* (*buccina*, a trumpet), the trumpeter's muscle, *arises* from the alveolar process of the superior maxillary and from the external oblique line of the inferior maxillary bone, as far forward as the second bicuspid tooth, and from the pterygo-maxillary ligament. This ligament is the raphé of union between the buccinator and superior constrictor muscle, and is attached by one extre-

mity to the hamular process of the internal pterygoid plate, and by the other to the extremity of the molar ridge. The fibres of the muscle converge towards the angle of the mouth where they cross each other, the superior being continuous with the inferior segment of the orbicularis oris, and the inferior with the superior segment. The muscle is invested externally by a thin fascia.

Relations.—By its *external surface*, posteriorly with a large and rounded mass of fat, which separates the muscle from the ramus of the lower jaw, the temporal, and the masseter; *anteriorly* with the risorius Santorini, the zygomatici, the levator anguli oris, and the depressor anguli oris. It is also in relation with a part of Stenon's duct, which pierces it opposite to the second molar tooth of the upper jaw, with the transverse facial artery, the branches of the facial and buccal nerve, and the facial artery and vein. By its *internal surface* with the buccal glands and mucous membrane of the mouth.

The *external pterygoid* is a short and thick muscle, broader at its origin than at its insertion. It *arises* by two heads, *one* from the pterygoid ridge on the great ala of the sphenoid; the *other* from the external pterygoid plate and tuberosity of the palate bone. The fibres pass backwards to be *inserted* into the neck of the lower jaw and the interarticular fibro-cartilage. The internal maxillary artery frequently passes between the two heads of this muscle.

Relations.—By its *external surface* with the ramus of the lower jaw, the temporal muscle, and internal maxillary artery; by its *internal surface* with the internal pterygoid muscle, and the inferior maxillary nerve; and by its *upper border* with the muscular branches of the inferior maxillary nerve; the internal maxillary artery passes between the two heads of this muscle, and its lower origin is pierced by the buccal nerve.

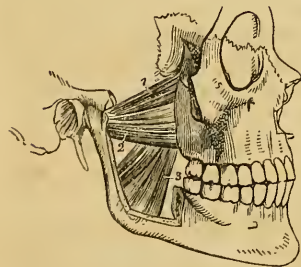


Fig. 80.

The external pterygoid muscle must now be removed, the ramus of the lower jaw sawn through its lower third, and the head of the bone dislocated from its socket and withdrawn, for the purpose of seeing the pterygoideus internus.

The *internal pterygoid* is a thick quadrangular muscle. It *arises* from the pterygoid fossa, and descends obliquely backwards, to be *inserted* into the ramus and angle of the lower jaw; it resembles the masseter in appearance and direction, and was named by Winslow the internal masseter.

Relations.—By its *external surface* with the internal pterygoid,

Fig. 80. The two pterygoid muscles. The zygomatic arch and greater part of the ramus of the lower jaw have been removed in order to bring these muscles into view. 1. The sphenoid origin of the external pterygoid muscle. 2. Its pterygoid origin. 3. The internal pterygoid muscle.

the inferior maxillary nerve and its branches, the internal maxillary artery and branches, the internal lateral ligament, and the ramus of the lower jaw. By its *internal surface* with the tensor palati and superior constrictor of the pharynx with its fascia; and by its posterior border with the parotid gland.

Actions.—The maxillary muscles are the active agents in mastication, and form an apparatus beautifully fitted for that office. The buccinator circumscribes the cavity of the mouth, and with the aid of the tongue keeps the food under the immediate pressure of the teeth. By means of its connexion with the superior constrictor, it shortens the cavity of the pharynx, from before backwards, and becomes an important auxiliary in deglutition. The temporal, the masseter, and the internal pterygoid are the bruising muscles, drawing the lower jaw against the upper with great force. The two latter, by the obliquity of their direction, assist the external pterygoid in grinding the food by carrying the lower jaw forward upon the upper; the jaw being brought back again by the deep portion of the masseter and posterior fibres of the temporal. The whole of these muscles, acting in succession, produce a rotatory movement of the teeth upon each other, which, with the direct action of the lower jaw against the upper, effects the proper mastication of the food.

8. *Auricular Group.*—Attollens aurem,
Attrahens aurem,
Retrahens aurem.

Dissection.—The three small muscles of the ear may be exposed by removing a square of integument from around the auricula. This operation must be performed with care, otherwise the muscles, which are extremely thin, will be raised with the superficial fascia.

The *attollens aurem* (superior auris), the largest of the three, is a thin triangular plane of muscular fibres, *arising* from the edge of the aponeurosis of the occipito-frontalis, and *inserted* into the upper part of the concha.

It is *in relation* by its external surface with the integument, and by the internal with the temporal aponeurosis.

The *attrahens aurem* (anterior auris), also triangular, *arises* from the edge of the aponeurosis of the occipito-frontalis, and is *inserted* into the anterior part of the concha, covering in the anterior and posterior temporal arteries.

It is *in relation* by its external surface with the integument, and by the internal with the temporal aponeurosis and with the temporal artery and veins.

The *retrahens aurem* (posterior auris), *arises* by three or four muscular slips from the mastoid process. They are *inserted* into the posterior surface of the concha.

It is *in relation* by its external surface with the integument, and by its internal surface with the mastoid portion of the temporal bone.

Actions.—The muscles of the auricular region possess but little

action in man; they are the analogues of important muscles in brutes. Their use is sufficiently explained by their names.

Muscles of the Neck.—The muscles of the neck may be arranged into eight groups, corresponding with the natural divisions of the region; they are the—

1. Superficial group.
2. Depressors of the os hyoides and larynx.
3. Elevators of the os hyoides and larynx.
4. Lingual group.
5. Pharyngeal group.
6. Soft palate group.
7. Prævertebral group.
8. Proper muscles of the larynx.

And each of these groups consist of the following muscles:—viz.

- | | |
|--|---|
| <p>1. <i>Superficial Group.</i></p> <p>Platysma myoides,
Sterno-cleido-mastoideus.</p> | <p>5. <i>Muscles of the pharynx.</i></p> <p>Constrictor inferior,
Constrictor medius,
Constrictor superior,
Stylo-pharyngeus,
Palato-pharyngeus.</p> |
| <p>2. <i>Depressors of the os hyoides and larynx.</i></p> <p>Sterno-hyoideus,
Sterno-thyroideus,
Thyro-hyoideus,
Omo-hyoideus.</p> | <p>6. <i>Muscles of the soft Palate.</i></p> <p>Levator palati,
Tensor palati,
Azygos uvulæ,
Palato-glossus,*
Palato-pharyngeus.</p> |
| <p>3. <i>Elevators of the os hyoides and larynx.</i></p> <p>Digastricus,
Stylo-hyoideus,
Mylo-hyoideus,
Genio-hyoideus,
Genio-hyo-glossus.</p> | <p>7. <i>Prævertebral Group.</i></p> <p>Rectus anticus major,
Rectus anticus minor,
Scalenus anticus,
Scalenus posticus,
Longus colli.</p> |
| <p>4. <i>Muscles of the tongue.</i></p> <p>Genio-hyo-glossus,
Hyo-glossus,
Lingualis,
Stylo-glossus,
Palato-glossus.*</p> | <p>8. <i>Muscles of the Larynx.</i></p> <p>Crico-thyroideus,
Crico-arytænoideus, posticus,
Crico-arytænoideus, lateralis,
Thyro-arytænoideus,
Arytænoideus.</p> |

Dissection.—The dissection of the neck should be commenced by making an incision along the middle line of the neck from the chin to the sternum, and bounding it superiorly and inferiorly by two

* Described by Horner as the *Constrictor isthmii faucium*.—G.

transverse incisions; the superior one being carried along the margin of the lower jaw, and across the mastoid process to the tubercle on the occipital bone, the inferior one along the clavicle to the acromion process. The square flap of integument thus included should be turned back from the entire side of the neck, which brings into view the superficial fascia, and on the removal of a thin layer of it the platysma myoides will be exposed.

The *platysma myoides* (πλατύς, μύς, εἶδος,) broad muscle-like lamella, is a thin plane of muscular fibres, situated between the two layers of the superficial cervical fascia; it *arises* from the integument over the pectoralis major and deltoid muscles, and passes obliquely upwards and inwards along the side of the neck to be *inserted* into the side of the chin, oblique line of the lower jaw, the angle of the mouth, and into the cellular tissue of the face. The most anterior fibres are continuous beneath the chin, with the muscle of the opposite side; the next interlace with the depressor anguli oris, and depressor labii inferioris, and the most posterior fibres are disposed in a transverse direction across the side of the face, arising in the cellular tissue covering the parotid gland, and inserted into the angle of the mouth, constituting the risorius Santorini. The entire muscle is analogous to the cutaneous muscle of brutes, the panniculus carnosus.

Relations.—By its *external surface* with the integument, with which it is closely adherent below, but loosely above. By its *internal surface*, below the clavicle, with the pectoralis major and deltoid; in the neck, with the external jugular vein and deep cervical fascia; on the face, with the parotid gland, the masseter, the facial artery and vein, the buccinator, the depressor anguli oris, and the depressor labii inferioris.

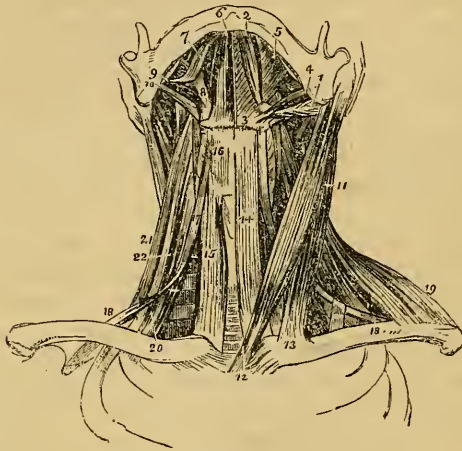On raising the platysma throughout its whole extent, the sternomastoid is brought into view.

The *sterno-cleido-mastoid* is the largest oblique muscle of the neck, and is situated between two layers of the deep cervical fascia. It *arises*, as implied in its name, from the sternum and clavicle (κλειδίον), and passes obliquely upwards and backwards to be *inserted* into the mastoid process and into the superior curved line of the occipital bone. The sternal portion arises by a rounded tendon, increases in breadth as it ascends, and spreads out to a considerable extent at its insertion. The clavicular portion is broad and fleshy, and separate from the sternal portion below, but becomes gradually blended with its posterior surface as it ascends.

Relations.—By its *superficial surface* with the integument, the platysma myoides, the external jugular vein, superficial branches of the anterior cervical plexus of nerves, and the anterior layer of the deep cervical fascia. By its *deep surface* with the deep layer of the cervical fascia; with the sterno-clavicular articulation, the sterno-hyoid, sterno-thyroid, omo-hyoid, scaleni, levator anguli scapulæ, splenii, and posterior belly of the digastric muscle; with the phrenic nerve, and the posterior, and supra-scapular artery; with

the deep lymphatic glands, the sheath of the common carotid artery and internal jugular vein, the descendens noni nerve, the external carotid artery and its posterior branches, the commencement of the internal carotid artery; with the cervical plexus of nerves, the pneumogastric, the spinal accessory, the hypoglossal, the sympathetic and the facial nerve, and with the parotid gland. It is pierced on this aspect by the spinal accessory nerve and by the

Fig. 81.



branches of the mastoid artery. The *anterior border* of the muscle is the posterior boundary of the great anterior triangle, the other two boundaries being the middle line of the neck in front, and the lower border of the jaw above. It is the guide to the operations for the ligature of the common carotid artery and arteria innominata, and for œsophagotomy. The *posterior border* is the anterior boundary of the great posterior triangle; the other two boundaries being the anterior border of the trapezius behind, and the clavicle below.

Actions.—The platysma produces a muscular traction on the integument of the neck, which prevents it from falling so flaccid in

Fig. 81. The muscles of the anterior aspect of the neck; on the left side the superficial muscles are seen, and on the right the deep. 1. The posterior belly of the digastricus muscle. 2. Its anterior belly. The aponeurotic pulley, through which its tendon is seen passing, is attached to the body of the os hyoides 3. 4. The stylo-hyoideus muscle, transfixed by the posterior belly of the digastricus. 5. The mylo-hyoideus. 6. The genio-hyoideus. 7. The tongue. 8. The hyo-glossus. 9. The stylo-glossus. 10. The stylo-pharyngeus. 11. The sterno-mastoid muscle. 12. Its sternal origin. 13. Its clavicular origin. 14. The sterno-hyoid. 15. The sterno-thyroid of the right side. 16. The thyro-hyoid. 17. The hyoid portion of the omo-hyoid. 18, 18. Its scapular portion; on the left side, the tendon of the muscle is seen to be bound down by a portion of the deep cervical fascia. 19. The clavicular portion of the trapezius 20. The scalenus anticus, of the right side. 21. The scalenus posticus.

old persons as would be the case if the extension of the skin were the mere result of elasticity. It draws also upon the angle of the mouth, and is one of the depressors of the lower jaw. The transverse fibres draw the angle of the mouth outwards and slightly upwards. The sterno-mastoid muscles are the great anterior muscles of connexion between the thorax and the head. Both muscles acting together will bow the head directly forwards. The clavicular portions, acting more forcibly than the sternal, give stability and steadiness to the head in supporting great weights. Either muscle acting single would draw the head towards the shoulder of the same side, and carry the face towards the opposite side.

Second Group.—Depressors of the Os Hyoides and Larynx.

Sterno-hyoid,
Sterno-thyroid,
Thyro-hyoid,
Omo-hyoid.

Dissection.—These muscles are brought into view by removing the deep fascia from off the front of the neck between the two sterno-mastoid muscles. The omo-hyoid to be seen in its whole extent requires that the sterno-mastoid muscle be divided from its origin and turned aside.

The *sterno-hyoideus* is a narrow riband-like muscle, arising from the posterior surface of the first bone of the sternum and inner extremity of the clavicle. It is inserted into the lower border of the body of the os hyoides. The sterno-hyoidei are separated by a considerable interval at the root of the neck, but approach each other as they ascend; they are frequently traversed by a tendinous intersection.

Relations.—By its *external surface* with the deep cervical fascia, the platysma myoides and sterno-mastoid muscle; by its *internal surface* with the sterno-thyroid and thyro-hyoid muscle, the thyroid gland, and the superior thyroid artery.

The *sterno-thyroideus*, broader than the preceding, beneath which it lies, arises from the posterior surface of the upper bone of the sternum, and from the cartilage of the first rib; and is inserted into the oblique line, on the great ala of the thyroid cartilage. The inner borders of these muscles lie in contact along the middle line, and they are generally marked by a tendinous intersection at their lower part.

Relations.—By its *external surface*, with the sterno-hyoid, omo-hyoid, and sterno-mastoid muscle; by its *internal surface*, with the trachea and inferior thyroid veins, with the thyroid gland, the lower part of the larynx, the sheath of the common carotid artery and internal jugular vein, with the subclavian vein and vena innominata, and on the right side with the arteria innominata. The middle thyroid vein lies along its inner border.

The *thyro-hyoideus* is the continuation upwards of the sterno-thyroid muscle. It arises from the oblique line on the thyroid cartilage,

and is *inserted* into the lower border of the body and great cornu of the os hyoides.

Relations.—By its *external surface* with the sterno-hyoid and omo-hyoid muscle; by its *internal surface* with the great ala of the thyroid cartilage, the thyro-hyoidean membrane and the superior laryngeal artery and nerve.

The *omo-hyoideus* (ωμος, shoulder) is a double-bellied muscle, passing obliquely across the neck from the scapula to the os hyoides; it forms an obtuse angle behind the sterno-mastoid muscle, by means of a process of the deep cervical fascia which is connected to the inner border of its tendon. It *arises* from the upper border of the scapula, and from the transverse ligament of the supra-scapular notch, and is *inserted* into the lower border of the body of the os hyoides.

Relations.—By its *superficial surface* with the trapezius, the subclavius and clavicle, the deep cervical fascia and platysma myoides, the sterno-mastoid, and the integument. By its *deep surface* with the brachial plexus, the scaleni muscles, the phrenic nerve, the sheath of the common carotid artery and jugular vein, the descendens noni nerve, and the sterno-thyroid, and thyro-hyoid muscle. The scapular portion of the muscle divides the great posterior triangle into a superior or *occipital triangle*; and an inferior or *subclavian triangle*, which contains the subclavian artery and brachial plexus of nerves; the other two boundaries of the latter being the sterno-mastoid in front and the clavicle below. The hyoid portion of the muscle divides the great anterior triangle into an *inferior carotid triangle*, situated below the muscle, and into a superior triangle, which lies above the muscle and is again subdivided by the digastricus muscle into the *submaxillary triangle* and the *superior carotid triangle*. The other two boundaries of the inferior carotid triangle, are the middle line of the neck in front and the anterior border of the sterno-mastoid behind. The other boundaries of the superior carotid triangle, are the posterior belly of the digastricus muscle above and the anterior border of the sterno-mastoid behind.

Actions.—The four muscles of this group are the depressors of the os hyoides and larynx. The three former drawing these parts downwards in the middle line, and the two omo-hyoidei regulating their traction to the one or other side of the neck, according to the position of the head. The omo-hyoid muscles, by means of their connexion with the cervical fascia, are rendered tensors of that portion of the deep cervical fascia which covers in the lower part of the neck, between the two sterno-mastoid muscles.

Third Group.—Elevators of the Os Hyoides.

Digastricus.
Stylo-hyoid,
Mylo-hyoid,
Genio-hyoid,
Genio-hyo-glossus.

Dissection.—These are best dissected by placing a high block beneath the neck, and throwing the head backwards. The integument has been already dissected away, and the removal of the cellular tissue and fat bring them clearly into view.

The *digastricus* (δῖς, twice, γαστήρ, belly) is a small muscle situated immediately beneath the side of the body of the lower jaw; it is fleshy at each extremity, and tendinous in the middle. It *arises* from the digastric fossa, upon the inner side of the mastoid process of the temporal bone, and is *inserted* into a depression on the inner side of the lower jaw close to the symphysis. The middle tendon is held in connexion with the body of the os hyoides by an aponeurotic loop, through which it plays as through a pulley; the loop being lubricated by a synovial membrane. A thin layer of aponeurosis is given off from the tendon of the digastricus at each side, which is connected with the body of the os hyoides, and forms a strong plane of fascia between the anterior portions of the two muscles. This fascia is named the *supra-hyoidean*.

Relations.—By its *superficial surface* with the platysma myoides, the sterno-mastoid, the anterior fasciculus of the stylo-hyoid muscle, the parotid gland, and submaxillary gland. By its *deep surface* with the styloid muscles, the hyo-glossus, the mylo-hyoid muscle, the external carotid artery, the lingual and the facial arteries, the internal carotid artery, the jugular vein, and the hypo-glossal nerve. The digastric muscle forms the two inferior boundaries of the submaxillary triangle, the superior boundary being the side of the body of the lower jaw. In the posterior half of the submaxillary triangle is situated the submaxillary gland and the facial artery.

The *stylo-hyoideus* is a small and slender muscle, situated in immediate relation with the posterior belly of the digastricus muscle, being pierced by its tendon. It *arises* from the middle of the styloid process, and is *inserted* into the body of the os hyoides near to the middle line.

Relations.—By its *superficial surface* with the posterior belly of the digastricus, the parotid gland and submaxillary gland; its deep relations are similar to those of the posterior belly of the digastricus.

The digastricus and stylo-hyoideus must be removed from their connexion with the lower jaw and os hyoides, and turned aside in order to see the next muscle.

The *mylo-hyoideus* (μύλη, mola, *i. e.* attached to the molar ridge of the lower jaw) is a broad triangular plane of muscular fibres, forming, with its fellow of the opposite side, the inferior wall or floor of the mouth. It *arises* from the molar ridge on the lower jaw, and proceeds obliquely inwards to be *inserted* into the *raphé* of the two muscles and into the body of the os hyoides; the *raphé* is sometimes deficient at its anterior part.

Relations.—By its *superficial* or inferior *surface*, with the platysma myoides, the digastricus, the supra-hyoidean fascia, the submaxillary gland and the submental artery. By its *deep* or superior

surface, with the genio-hyoideus, the genio-hyo-glossus, the hyo-glossus, the stylo-glossus, the gustatory nerve, the hypo-glossal nerve, Wharton's duct, the sublingual gland, and the mucous membrane of the floor of the mouth.

After the mylo-hyoideus has been examined, it should be cut away from its origin and insertion, and completely removed. The view of the next muscles would also be greatly improved by dividing the lower jaw a little to one side of the symphysis, and drawing it outwards, or by removing it altogether if the ramus have been already cut across in dissecting the internal pterygoid muscle. The tongue may then be drawn out of the mouth by means of a hook.

The *genio-hyoideus* ($\gamma\epsilon\nu\epsilon\iota\omicron\nu$, the chin) *arises* from a small tubercle upon the inner side of the symphysis of the lower jaw, and is *inserted* into the upper part of the body of the os hyoides. It is a short and slender muscle, very closely connected with the border of the following.

Relations.—By its *superficial* or inferior surface, with the mylo-hyoideus; by the *deep* or superior surface with the lower border of the genio-hyo-glossus.

The *genio-hyo-glossus* ($\gamma\lambda\tilde{\omega}\sigma\sigma\alpha$, the tongue) is a triangular muscle, narrow and pointed at its origin from the lower jaw, broad and fan-shaped at its attachment to the tongue. It *arises* from a tubercle immediately above that of the genio-hyoideus, and spreads out to be *inserted* into the whole length of the tongue, from its base to the apex, and into the body of the os hyoides.

Relations.—By its *inner surface* with its fellow of the opposite side. By its *outer surface* with the mylo-hyoideus, the hyo-glossus, the stylo-glossus, lingualis, the sublingual gland, the lingual artery and the hypo-glossal nerve. By its *upper border* with the mucous membrane of the floor of the mouth, by the side of the frænum lingue; and by the *lower border* with the genio-hyoideus.

Actions.—The whole of this group of muscles acts upon the os hyoides, when the lower jaw is closed, and upon the lower jaw when the os hyoides is drawn downwards, and fixed by the depressors of the os hyoides and larynx. The genio-hyo-glossus is, moreover, a muscle of the tongue; its action upon that organ shall be considered with the next group.

Fourth Group.—Muscles of the Tongue.

Genio-hyo-glossus,
Hyo-glossus,
Lingualis,
Stylo-glossus,
Palato-glossus.

These are already exposed by the preparation we have just made; there remains, therefore, only to dissect and examine them.

The *genio-hyo-glossus*, the first of these muscles, has been described with the last group.

The *hyo-glossus* is a square-shaped plane of muscle, arising from the whole length of the great cornu and from the body of the os hyoides, and inserted between the stylo-glossus and lingualis into the side of the tongue. The direction of the fibres of that portion of the muscle which arises from the body is obliquely backwards; and that from the great cornu obliquely forwards; hence they are described by Albinus as two distinct muscles, under the names of the basio-glossus, and cerato-glossus, to which he added a third fasciculus, arising from the lesser cornu, and spreading along the side of the tongue, the chondro-glossus. The basio-glossus slightly overlaps the cerato-glossus at its upper part, and is separated from it by the transverse portion of the stylo-glossus.

Relations.—By its *external surface* with the digastric muscle, the stylo-hyoideus, stylo-glossus and mylo-hyoideus; with the gustatory nerve, the hypo-glossal nerve, Wharton's duct and the sublingual gland. By its *internal surface* with the middle constrictor of the pharynx, and lingualis, the genio-hyo-glossus, the lingual artery, and the glosso-pharyngeal nerve.

The *lingualis*.—The fibres of this muscle may be seen towards the apex of the tongue, issuing from the interval between the hyo-glossus and genio-hyo-glossus; it is best examined by removing the preceding muscle. It consists of a small fasciculus of fibres, running longitudinally from the base, where it is attached to the os hyoides, to the apex of the tongue. It is in relation by its under surface with the ranine artery.

Fig. 82.

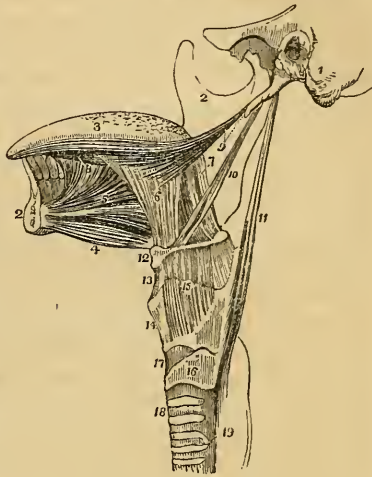


Fig. 82. The styloid muscles and the muscles of the tongue. 1. A portion of the temporal bone of the left side of the skull, including the styloid and mastoid processes, and the meatus auditorius externus. 2, 2. The right side of the lower jaw, divided at its symphysis: the left side having been removed. 3. The tongue. 4. The genio-hyoideus muscle. 5. The genio-hyo-glossus. 6. The hyo-glossus muscle; its basio-glossus portion. 7. Its cerato-glossus portion. 8. The anterior fibres of the lingualis issuing from between the hyo-glossus and genio-hyo-glossus. 9. The stylo-glossus muscle, with a small portion of the stylo-maxillary ligament. 10. The stylo-hyoid. 11. The stylo-pharyngeus muscle. 12. The os hyoides. 13. The thyro-hyoidean membrane. 14. The thyroid cartilage. 15. The thyro-hyoideus muscle arising from the oblique line on the thyroid cartilage. 16. The cricoid cartilage. 17. The crico-thyroid membrane, through which the operation of laryngotomy is performed. 18. The trachea. 19. The commencement of the œsophagus.

The *stylo-glossus* arises from the apex of the styloid process, and from the stylo-maxillary ligament; and divides upon the side of the tongue into two portions, one transverse, which passes transversely inwards between the two portions of the *hyo-glossus*, and is lost among the transverse fibres of the substance of the tongue, and another longitudinal, which spreads out upon the side of the tongue as far as its tip.

Relations.—By its *external surface* with the internal pterygoid muscle, the gustatory nerve, the parotid gland, sublingual gland, and the mucous membrane of the floor of the tongue. By its *internal surface* with the tonsil, the superior constrictor muscle of the pharynx, and the *hyo-glossus* muscle.

The *palato-glossus** passes between the soft palate, and the side of the base of the tongue, forming a projection of the mucous membrane, which is called the anterior pillar of the soft palate. Its fibres are lost superiorly among the muscular fibres of the palato-pharyngeus, and inferiorly among the fibres of the *stylo-glossus* upon the side of the tongue. This muscle with its fellow constitutes the constrictor *isthmii faucium*.

Actions.—The *genio-hyo-glossus* muscle effects several movements of the tongue, as might be expected from its extent. When the tongue is steadied and pointed by the other muscles, the posterior fibres of the *genio-hyo-glossus* would dart it from the mouth, while its anterior fibres would restore it to its original position. The whole length of the muscle acting upon the tongue, would render it concave along the middle line, and form a channel for the current of fluid towards the pharynx, as in sucking. The apex of the tongue is directed to the roof of the mouth, and rendered convex from before backwards by the *linguales*. The *hyo-glossi*, by drawing down the sides of the tongue, render it convex along the middle line. It is drawn upwards at its base by the *palato-glossi*, and backwards or to either side by the *stylo-glossi*. Thus the whole of the complicated movements of the tongue may be explained, by reasoning upon the direction of the fibres of the muscles, and their probable actions.

Fifth Group.—Muscles of the Pharynx.

Constrictor inferior,
 Constrictor medius,
 Constrictor superior,
 Stylo-pharyngeus,
 Palato-pharyngeus.

Dissection.—To dissect the pharynx, the trachea, and œsophagus are to be cut through at the lower part of the neck, and drawn upwards by dividing the loose cellular tissue which connects the

* Called also *constrictor isthmii faucium*.—G.

pharynx to the vertebral column. The saw is then to be applied behind the styloid processes, and the base of the skull sawn through. The vessels and loose structures should be removed from the preparation, and the pharynx stuffed with tow or wool for the purpose of distending it, and rendering the muscles more easy of dissection. The pharynx is invested by a proper pharyngeal fascia.

The *constrictor inferior*, the thickest of the three muscles of this class, *arises* from the upper rings of the trachea, from the cricoid and the side of the thyroid cartilage. Its fibres spread out and are *inserted* into the fibrous *raphé* of the middle of the pharynx, the inferior fibres being almost horizontal, and the superior oblique, and overlapping the middle constrictor.

Relations.—By its *external surface* with the anterior surface of the vertebral column, the longus colli, the sheath of the common carotid artery, the sterno-thyroid muscle, the thyroid gland, and some lymphatic glands. By its *internal surface* with the middle constrictor, the stylo-pharyngeus, the palato-pharyngeus, and the mucous membrane of the pharynx. By its *lower border*, near to the cricoid cartilage, it is in relation with the recurrent nerve; and by the *upper border* with the superior laryngeal nerve.

This muscle must be removed before the next can be examined.

The *constrictor medius* *arises* from the great cornu of the os hyoides, from the lesser cornu, and from the stylo-hyoidean ligament. It radiates from its origin upon the side of the pharynx, the lower fibres descending and being overlapped by the constrictor inferior, and the upper fibres ascending so as to cover in the constrictor superior. It is *inserted* into the *raphé* and by a fibrous aponeurosis into the basilar process of the occipital bone.

Relations.—By its *external surface* with the vertebral column, the longus colli, rectus anticus major, the carotid vessels, inferior constrictor, hyo-glossus muscle, lingual artery, pharyngeal plexus of nerves, and some lymphatic glands. By its *internal surface*, with the superior constrictor, stylo-pharyngeus, palato-pharyngeus, and mucous membrane of the pharynx.

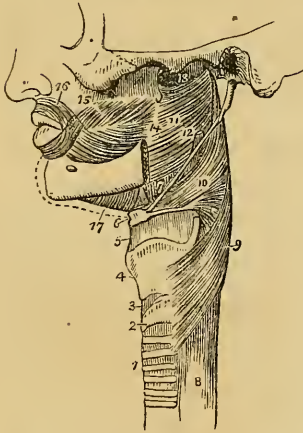
The upper portion of this muscle must be turned down, to bring the whole of the superior constrictor into view; in so doing, the stylo-pharyngeus muscle will be seen passing beneath its upper border.

The *constrictor superior* is a thin and quadrilateral plane of muscular fibres, *arising* from the extremity of the molar ridge of the lower jaw, from the pterygo-maxillary ligament, and from the lower half of the internal pterygoid plate, and *inserted* into the *raphé* and basilar process of the occipital bone. Its superior fibres are arched and leave an interval between its upper border and the basilar process which is deficient in muscular fibres, and it is overlapped inferiorly by the middle constrictor. Between the side of the pharynx and the ramus of the lower jaw is a triangular interval, the *maxillo-pharyngeal space*, which is bounded on the *inner* side by the supe-

rior constrictor muscle; on the *outer* side by the internal pterygoid muscle; and *behind* by the rectus anticus major and vertebral column. In this space are situated the internal carotid artery, the internal jugular vein, and the glosso-pharyngeal, pneumogastric, spinal accessory, and hypo-glossal nerve.

Relations.—By its *external surface* with the vertebral column and its muscles, behind; with the vessels and nerves contained in the *maxillo-pharyngeal space* laterally, the middle constrictor, stylo-pharyngeus, and tensor palati muscle. By its *internal surface* with the levator palati, palato-pharyngeus, tonsil, and mucous membrane of the pharynx, the pharyngeal fascia being interposed.

Fig. 83.



The *stylo-pharyngeus* is a long and slender muscle, *arising* from the inner side of the base of the styloid process: it descends between the superior and middle constrictor muscles and spreads out beneath the mucous membrane of the pharynx, its inferior fibres being *inserted* into the posterior border of the thyroid cartilage.

Relations.—By its *external surface* with the stylo-glossus muscle, external carotid artery, parotid gland, and the middle constrictor. By its *internal surface* with the internal carotid artery, internal jugular vein, superior constrictor, palato-pharyngeus, and mucous membrane. Along its lower border is seen the glosso-pharyngeal nerve which crosses it, opposite the root of the tongue.

The *palato-pharyngeus* is described with the muscles of the soft palate. It *arises* from the soft palate, and is *inserted* into the inner surface of the pharynx, and posterior border of the thyroid cartilage.

Actions.—The three constrictor muscles contract upon the morsel of food as soon as it is received by the pharynx, and convey it gradually downwards into the œsophagus. The stylo-pharyngei draw the pharynx upwards and widen it laterally. The palato-pharyngei also draw it upwards, and narrow the opening of the fauces.

Fig. 83. A side view of the muscles of the pharynx. 1. The trachea. 2. The cricoid cartilage. 3. The erico-thyroid membrane. 4. The thyroid cartilage. 5. The thyro-hyoidean membrane. 6. The os hyoides. 7. The stylo-hyoidean ligament. 8. The œsophagus. 9. The inferior constrictor. 10. The middle constrictor. 11. The superior constrictor. 12. The stylo-pharyngeus muscle passing down between the superior and middle constrictor. 13. The upper concave border of the superior constrictor; at this point the muscular fibres of the pharynx are deficient. 14. The pterygo-maxillary ligament. 15. The buccinator muscle. 16. The orbicularis oris. 17. The mylo-hyoideus.

Sixth Group.—Muscles of the soft Palate.

Levator palati,
Tensor palati,
Azygos uvulæ,
Palato-glossus,
Palato-pharyngeus.

Dissection.—To examine these muscles, the pharynx must be opened from behind, and the mucous membrane carefully removed from off the posterior surface of the soft palate.

The *levator palati*, a moderately thick muscle, *arises* from the extremity of the petrous bone and from the posterior and inferior aspect of the Eustachian tube, and passing down by the side of the posterior nares spreads out in the structure of the soft palate as far as the middle line.

Relations.—*Externally* with the tensor palati and superior constrictor muscle; *internally* and *posteriorly* with the mucous membrane of the pharynx and soft palate; and by its lower border with the palato-pharyngeus.

This muscle must be turned down from its origin on one side, and removed, and the superior constrictor dissected away from its pterygoid origin, to bring the next muscle into view.

The *tensor palati* (circumflexus) is a slender and flattened muscle; it *arises* from the scaphoid fossa at the base of the internal pterygoid plate and from the anterior aspect of the Eustachian tube. It descends to the hamular process, around which it turns, and expands into a tendinous aponeurosis, which is *inserted* into the transverse ridge on the horizontal portion of the palate bone, and into the *raphé*.

Relations.—By its *external surface* with the internal pterygoid

Fig. 84.

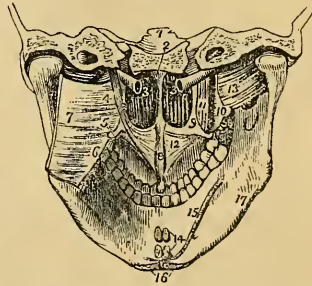


Fig. 84. The muscles of the soft palate. 1. A transverse section through the middle of the base of the skull, dividing the basilar process of the occipital bone in the middle line, and the petrous portion of the temporal bone at each side. 2. The vomer covered by mucous membrane and separating the two posterior nares. 3, 3. The Eustachian tubes. 4. The levator palati muscle of the left side; the right has been removed. 5. The hamular process of the internal pterygoid plate of the left side, around which the aponeurosis of the tensor palati is seen turning. 6. The pterygo-maxillary ligament. 7. The superior constrictor muscle of the left side, turned aside. 8. The azygos uvulæ muscle. 9. The internal pterygoid plate. 10. The external pterygoid plate. 11. The tensor palati muscle. 12. Its aponeurosis expanding in the structure of the soft palate. 13. The external pterygoid muscle. 14. The attachments of two pairs of muscles cut short; the superior pair belong to the genio-hyo-glossi muscles; the inferior pair, to the genio-hyoidei. 15. The attachment of the mylo-hyoideus of one side and part of the opposite. 16. The anterior attachments of the digastric muscles. 17. The depression on the lower jaw corresponding with the submaxillary gland. The depression above the mylo-hyoideus, on which the number 15 rests, corresponds with the sublingual gland.

muscle; by its *internal surface* with the levator palati, internal pterygoid plate and superior constrictor. In the soft palate, its tendinous expansion is placed in front of the other muscles and in contact with the mucous membrane.

The *azygos uvulæ* is not a single muscle, as might be inferred from its name, but a pair of small muscles placed side by side in the middle line of the soft palate. They *arise* from the spine of the palate bone, and are *inserted* into the uvula. By their anterior surface they are in contact with the tendinous expansion of the levatores palati, and by the posterior with the mucous membrane.

The two next muscles are brought into view throughout the whole of their extent, by raising the mucous membrane from off the pillars of the soft palate at each side.

The *palato-glossus* (constrictor isthmii faucium) is a small fasciculus of fibres that *arises* in the soft palate, and descends to be *inserted* into the side of the tongue. It is the projection of this small muscle covered by mucous membrane, that forms the anterior pillar of the soft palate. It has been named constrictor isthmii faucium from a function it performs in common with the palato-pharyngeus, viz., of constricting the opening of the fauces.

The *palato-pharyngeus* forms the posterior pillar of the fauces; it *arises* by an expanded fasciculus from the lower part of the soft palate where its fibres are continuous with those of the muscle of the opposite side; and is *inserted* into the posterior border of the thyroid cartilage. This muscle is broad above where it forms the whole thickness of the lower half of the soft palate, narrow in the posterior pillar, and again broad and thin in the pharynx where it spreads out previously to its insertion.

Relations.—In the soft palate it is in relation with the mucous membrane both by its *anterior* and *posterior* surface; *above*, with the muscular layer formed by the levator palati, and *below* with the mucous glands situated along the margin of the arch of the palate. In the posterior pillar of the palate, it is surrounded for two-thirds of its extent by mucous membrane. In the pharynx, it is in relation by its *outer surface* with the superior and middle constrictor muscles, and by its *inner surface* with the mucous membrane of the pharynx, the pharyngeal fascia being interposed.

Actions.—The *azygos uvulæ* shortens the uvula. The levator palati raises the soft palate, while the tensor spreads it out laterally so as to form a septum between the pharynx and posterior nares during deglutition. Taking its fixed point from below, the tensor palati will dilate the Eustachian tube. The palato-glossus and pharyngeus constrict the opening of the fauces, and by drawing down the soft palate they serve to press the mass of food from the dorsum of the tongue into the pharynx.

Seventh Group.—Prævertebral Muscles.

Rectus anticus major,
 Rectus anticus minor,
 Scalenus anticus,
 Scalenus posticus,
 Longus colli.

Dissection.—These muscles have already been exposed, by the removal of the face from the anterior aspect of the vertebral column; all that is further needed is the removal of the fascia by which they are invested.

The *rectus anticus major*, broad and thick above, and narrow and pointed below, *arises* from the anterior tubercles of the transverse processes of the third, fourth, fifth, and sixth cervical vertebræ, and is *inserted* into the basilar process of the occipital bone.

Relations.—By its *anterior surface* with the pharynx, the internal carotid artery, internal jugular vein, superior cervical ganglion, sympathetic nerve, pneumogastric, and spinal accessory nerve. By its *posterior surface* with the longus colli, rectus anticus minor, and superior cervical vertebræ.

The *rectus anticus minor* *arises* from the anterior border of the lateral mass of the atlas, and is *inserted* into the basilar process; its fibres being directed obliquely upwards and inwards.

Relations.—By its *anterior surface* with the rectus anticus major, and externally with the superior cervical ganglion of the sympathetic. By its *posterior surface* with the articulation of the condyle of the occipital bone with the atlas, and with the anterior occipito-atloid ligament.

The *scalenus anticus** is a triangular muscle, as its name implies, situated at the root of the neck and appearing like a continuation of the rectus anticus major; it *arises* from the anterior tubercles of the transverse processes of the third, fourth, fifth, and sixth cervical

Fig. 85.

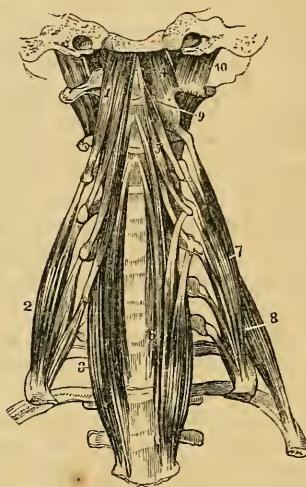


Fig. 85. The prævertebral group of muscles of the neck. 1. The rectus anticus major muscle. 2. The scalenus anticus. 3. The lower part of the longus colli of the right side; it is concealed superiorly by the rectus anticus major. 4. The rectus anticus minor. 5. The upper portion of the longus colli muscle. 6. Its lower portion; the figure rests upon the seventh cervical vertebra. 7, 8. The scalenus posticus. 9. One of the intertransversales muscles. 10. The rectus lateralis of the left side.

* Horner describes three scaleni, viz.: anticus, medius, and posticus; the anticus arising from the fourth, fifth, and sixth; the medius from all the cervical vertebræ; and the posticus from the fifth and sixth. I have always had a difficulty in separating the medius and posticus.—G.

vertebræ, and is *inserted* into the tubercle upon the inner border of the first rib.

Relations.—By its *anterior surface* with the sterno-mastoid and omo-hyoid muscle, with the cervicalis ascendens, and posterior scapular artery, with the phrenic nerve, and with the subclavian vein, by which it is separated from the subclavius muscle and clavicle. By its *posterior surface* with the nerves which go to form the brachial plexus, and below with the subclavian artery. By its *inner side* it is separated from the longus colli by the vertebral artery. Its relations with the subclavian artery and vein are very important, the vein being before and the artery behind the muscle.*

The *scalenus posticus* arises from the posterior tubercles of all the cervical vertebræ excepting the first. It is *inserted* by two fleshy slips into the first and second ribs. The anterior of the two slips is very large, and occupies all the surface of the rib between the groove for the subclavian artery and the tuberosity. The posterior is small. Hence the scalenus medius and posticus of some anatomists.

Relations.—By its *anterior surface* with the brachial plexus and subclavian artery; *posteriorly* with the levator anguli scapulæ, cervicalis ascendens, transversalis colli and sacro-lumbalis; *internally* with the first intercostal muscle, the first rib, the inter-transverse muscles, and cervical vertebræ; and *externally* with the sterno-mastoid, omo-hyoid, supra-scapular, and posterior scapular arteries.

The *longus colli* is a long and flat muscle, consisting of two portions. The *upper* arises from the anterior tubercle of the atlas, and is *inserted* into the transverse processes of the third, fourth, and fifth cervical vertebræ. The *lower* portion arises from the bodies of the second and third, and transverse processes of the fourth and fifth, and passes down the neck, to be *inserted* into the bodies of the three lower cervical and three upper dorsal vertebræ. We should thus arrange these attachments in a tabular form:

	<i>Origin.</i>	<i>Insertion.</i>
Upper portion.	} Atlas } 2d and 3d bodies } 4th and 5th transverse processes	{ 3d, 4th, and 5th transverse processes. { 3 lower cervical vertebræ bodies. { 3 upper dorsal bodies.
Lower portion.		

In general terms, the muscle is attached to the bodies and transverse processes of the five superior cervical vertebræ above, and to the bodies of the three last cervical and three first dorsal below.

Relations.—By its *anterior surface* with the pharynx, œsophagus, the sheath of the common carotid internal jugular vein and pneumogastric nerve, the sympathetic nerve, inferior laryngeal nerve, and inferior thyroid artery. By its *posterior surface* it rests upon the cervical and upper dorsal vertebræ.

* In a subject dissected in the school of the Middlesex Hospital during the last winter, by Mr. Joseph Rogers, the subclavian artery of the left side was placed with the vein in front of the scalenus anticus muscle.

Actions.—The rectus anticus major and minor preserve the equilibrium of the head upon the atlas; and acting conjointly with the longus colli, they flex and rotate the head and the cervical portion of the vertebral column. The scalmi muscles, taking their fixed point from below, are flexors of the vertebral column; and from above, elevators of the ribs, and therefore inspiratory muscles.

Eighth Group.—Muscles of the Larynx.

These muscles are described with the anatomy of the larynx, in Chapter X.

MUSCLES OF THE TRUNK.

The muscles of the trunk may be subdivided into four natural groups; viz.

1. Muscles of the back.
2. Muscles of the thorax.
3. Muscles of the abdomen.
4. Muscles of the perineum.

1. *Muscles of the back.*—The *region of the back*, in consequence of its extent, is common to the neck, the upper extremities, and the abdomen. The muscles of which it is composed are numerous, and may be arranged into six layers.

First Layer.

Trapezius,
Latissimus dorsi.

Transversalis colli,
Trachelo-mastoideus,
Complexus.

Second Layer.

Levator anguli scapulæ,
Rhomboides minor,
Rhomboides major.

Fifth Layer.

(Dorsal Group.)
Semi-spinalis dorsi,
Semi-spinalis colli.
(Cervical Group.)

Third Layer.

Serratus posticus superior,
Serratus posticus inferior,
Splenius capitis,
Splenius colli.

Rectus posticus major,
Rectus posticus minor,
Rectus lateralis,
Obliquus inferior,
Obliquus superior.

Fourth Layer.

(Dorsal Group.)

Sacro lumbalis,
Longissimus dorsi,
Spinalis dorsi.
(Cervical Group.)
Cervicalis ascendens,

Sixth Layer.

Multifidus spinæ,
Levatores costarum,
Supra-spinales,
Inter-spinales,
Inter-transversales.

First Layer.

Dissection.—The muscles of this layer are to be dissected by making an incision along the middle line of the back, from the tubercle on the occipital bone to the coccyx. From the upper

point of this incision carry a second along the side of the neck, to the middle of the clavicle. Inferiorly, an incision must be made from the extremity of the sacrum, along the crest of the ilium, to about its middle. For convenience of dissection, a fourth may be carried from the middle of the spine to the acromion process. The integument and superficial fascia, together, are to be dissected off the muscles, in the course of their fibres, over the whole of this region.

The *trapezius* muscle (trapezium, a quadrangle with unequal sides) arises from the superior curved line or semicircular ridge, of the occipital bone, from the ligamentum nuchæ, supra-spinous ligament, and spinous processes of the last cervical and all the dorsal vertebræ. The fibres converge from these various points, and are inserted into the scapular third of the clavicle, the acromion process, and the whole length of the upper border of the spine of the scapula. The inferior fibres become tendinous near to the scapula, and glide over the triangular surface at the posterior extremity of its spine, upon a bursa mucosa. When the trapezius is dissected on both sides, the two muscles resemble a trapezium, or diamond-shaped quadrangle, on the posterior part of the shoulders: hence the muscle was formerly named cucullaris (cucullus, a monk's cowl.) The cervical and upper part of the dorsal portion of the muscle is tendinous at its origin, and forms, with the muscle of the opposite side, a kind of tendinous ellipse.

Relations.—By its *superficial surface* with the integument and superficial fascia, to which it is closely adherent by its cervical portion, loosely by its dorsal portion. By its *deep surface*, from above downwards, with the complexus, splenius, levator anguli scapulæ, supra-spinatus, a small portion of the serratus posticus superior, rhomboideus minor, rhomboideus major, intervertebral aponeurosis which separates it from the erector spinæ, and with the latissimus dorsi. The *anterior border* of the cervical portion of this muscle forms the posterior boundary of the posterior triangle of the neck. The clavicular insertion of the muscle sometimes advances to the middle of the clavicle, or as far as the outer border of the sternomastoid, and occasionally it has been seen to overlap the latter. This is a point of much importance to be borne in mind in the operation for ligature of the subclavian artery. The spinal accessory nerve passes beneath the anterior border, near to the clavicle, previously to its distribution to the muscle.

The ligamentum nuchæ is a thin cellulo-fibrous layer extended from the tubercle and spine of the occipital bone, to the spinous process of the seventh cervical vertebra, where it is continuous with the supra-spinous ligament. It is connected with the spinous processes of the rest of the cervical vertebræ, with the exception of the atlas, by means of a small fibrous slip which is sent off by each. It is the analogue of an important elastic ligament in animals.

The *latissimus dorsi* muscle covers the whole of the lower part of the back and loins. It arises from the spinous processes of the

six inferior dorsal vertebræ,* from all the lumbar and sacral spinous processes, from the posterior third of the crest of the ilium, and from the three lower ribs; the latter origin takes place by muscular slips, which indigitate with the external oblique muscle of the abdomen. The fibres from this extensive origin converge as they ascend, and cross the inferior angle of the scapula; they then curve around the lower border of the teres major muscle, and terminate in a short quadrilateral tendon,† which lies in front of the tendon of the teres, and is *inserted* into the bicipital groove. A synovial bursa is interposed between the muscle and the lower angle of the scapula, and another between its tendon and that of the teres major. The muscle frequently receives a small fasciculus from the scapula as it crosses its inferior angle.

Relations.—By its *superficial surface* with the integument and superficial fascia; the latter is very dense and fibrous in the lumbar region; and with the trapezius. By its *deep surface*, from below upwards, with the erector spinæ, serratus posticus inferior, intercostal muscles and ribs, rhomboideus major, inferior angle of the scapula and teres major. The latissimus dorsi with the teres major forms the posterior border of the axilla.

Second Layer.

Dissection.—This layer is brought into view by dividing the two preceding muscles near to their insertion, and turning them to the opposite side.

The *levator anguli scapulæ* arises by distinct slips, from the posterior tubercles of the transverse processes of the four upper cervical vertebræ, and is *inserted* into the upper angle and posterior border of the scapula, as far as the triangular smooth surface at the root of its spine.

Relations.—By its *superficial surface* with the trapezius, sternomastoid, and integument. By its *deep surface* with the splenius colli, transversalis colli, cervicalis ascendens, scalenus posticus, and serratus posticus superior. The tendons of origin are interposed between the attachments of the scalenus posticus in front and the splenius colli behind.

The *rhomboideus minor* (rhombus, a parallelogram with four equal sides) is a narrow slip of muscle, detached from the rhomboideus major by a slight cellular interspace. It arises from the spinous process of the last cervical vertebra and ligamentum nuchæ, and is *inserted* into the edge of the triangular surface, on the posterior border of the scapula.

The *rhomboideus major* arises from the spinous processes of the four upper dorsal vertebræ and from the supra-spinous ligament; it is *inserted* into the posterior border of the scapula as far as its

* Horner says seven.—G.

† A small muscular fasciculus from the pectoralis major is sometimes found connected with this tendon.

inferior angle. The upper and middle portion of the insertion is effected by means of a tendinous arch.

Relations.—By their *superficial surface* the two rhomboid muscles are in relation with the trapezius, and the rhomboideus major with the latissimus dorsi and integument. By their *deep surface* they cover in the serratus posticus superior, part of the erector spinæ, the intercostal muscles and ribs.

Fig. 86.

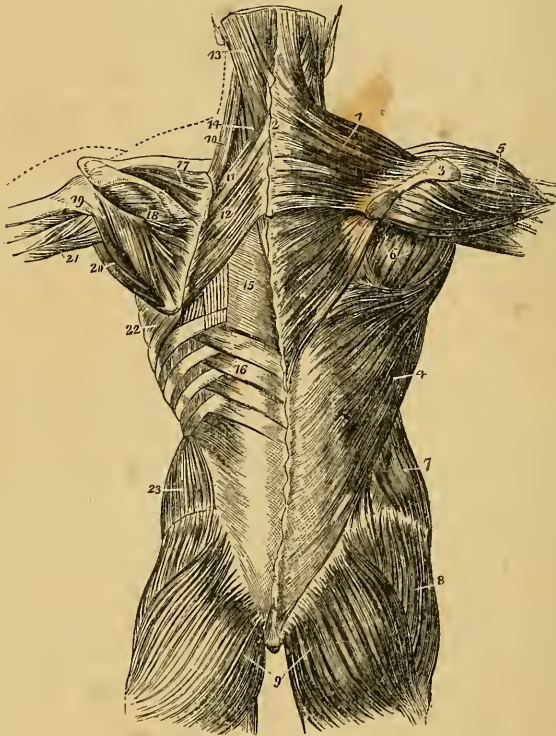


Fig. 86. The first and second and part of the third layer of muscles of the back; the first layer being shown upon the right, and the second on the left side. 1. The trapezius muscle. 2. The tendinous portion which, with a corresponding portion in the opposite muscle, forms the tendinous ellipse on the back of the neck. 3. The acromion process and spine of the scapula. 4. The latissimus dorsi muscle. 5. The deltoid. 6. The muscles of the dorsum of the scapula, infra-spinatus, teres minor, and teres major. 7. The external oblique muscle. 8. The gluteus medius. 9. The glutei maximi. 10. The levator anguli scapulae. 11. The rhomboideus minor. 12. The rhomboideus major. 13. The splenius capitis; the muscle immediately above, and overlaid by the splenius, is the complexus. 14. The splenius colli, only partially seen; the common origin of the splenius is seen attached to the spinous processes below the lower border of the rhomboideus major. 15. The vertebral aponeurosis. 16. The serratus posticus inferior. 17. The supra-spinatus muscle. 18. The infra-spinatus. 19. The teres minor muscle. 20. The teres major. 21. The long head of the triceps, passing between the teres minor and major to the upper arm. 22. The serratus magnus, proceeding forwards from its origin at the base of the scapula. 23. The internal oblique muscle.

Third Layer.

Dissection.—The *third layer* consists of muscles which arise from the spinous processes of the vertebral column, and pass outwards. It is brought into view by dividing the levator anguli scapulæ near its insertion, and reflecting the two rhomboid muscles upwards from their insertion into the scapula. The latter should be removed altogether.

The *serratus posticus superior* is situated at the upper part of the thorax; it *arises* from the ligamentum nuchæ, and from the spinous process of the last cervical and two upper dorsal vertebræ; it is *inserted* by four serrations into the upper border of the second, third, fourth, and fifth ribs.

Relations.—By its *superficial surface* with the trapezius, rhomboideus major and minor, and serratus magnus. By its *deep surface* with the splenius, the upper part of the erector spinæ, the intercostal muscles and ribs.

The *serratus posticus inferior* *arises* from the spinous processes of the two last dorsal and two upper lumbar vertebræ, and is *inserted* by four serrations into the lower border of the four lower ribs.

Relations.—By its *superficial surface* with the latissimus dorsi, its tendinous origin being inseparably connected with the aponeurosis of that muscle. By its *deep surface* with the aponeurosis of the obliquus internus, with which it is also closely adherent; with the erector spinæ, the intercostal muscles and lower ribs. The *upper border* is continuous with a thin tendinous layer, the *vertebral aponeurosis*. This aponeurosis consists of longitudinal and transverse fibres, and extends the whole length of the thoracic region. It is attached mesially to the spinous processes of the dorsal vertebræ, and externally to the angles of the ribs; superiorly it is continued upwards beneath the serratus posticus superior, with the lower border of which it is sometimes connected. It serves to bind down the erector spinæ, and separates it from the superficial muscles.

The serratus posticus superior must be removed from its origin and turned outwards, to bring into view the whole extent of the splenius muscle.

The *splenius muscle* is single at its origin, but divides soon after into two portions, which are destined to distinct insertions. It *arises* from the lower half of the ligamentum nuchæ, from the spinous process of the last cervical vertebra, and from the spinous processes of the six upper dorsal* and supra-spinous ligament; it divides as it ascends the neck into the splenius capitis and colli. The *splenius capitis* is *inserted* into the rough surface of the occipital bone between the two semicircular ridges, and into the mastoid portion of the temporal bone.

The *splenius colli* is *inserted* into the posterior tubercles of the transverse processes of the three or four upper cervical vertebræ.

* Horner makes it to arise but from four dorsal vertebræ.—G.

Relations.—By its *superficial surface* with the trapezius, sternomastoid, levator anguli scapulæ, rhomboideus minor and major, and serratus posticus superior. By its *deep surface* with the spinalis dorsi, longissimus dorsi, semi-spinalis colli, complexus, trachelo-mastoid, and transversalis colli. The tendons of insertion of the splenius colli are interposed between the insertions of the levator anguli scapulæ in front, and the transversalis colli behind.

The splenii of opposite sides of the neck leave between them a triangular interval, in which the complexus is seen.

Fourth Layer.

Dissection.—The two serrati and two splenii must be removed by cutting them away from their origins and insertions, to bring the fourth layer into view.

Three of these muscles, viz. sacro-lumbalis, longissimus dorsi, and spinalis dorsi, are associated under the name of erector spinæ. They occupy the lumbar and dorsal portion of the back. The remaining four are situated in the cervical region.

The *sacro-lumbalis* and *longissimus dorsi* arise by a common origin from the posterior third of the crest of the ilium, from the posterior surface of the sacrum, and from the lumbar vertebræ; opposite the last rib a line of separation begins to be perceptible between the two muscles. The *sacro-lumbalis* is inserted by separate tendons into the angles of the six lower ribs. On turning the muscle a little outwards, a number of tendinous slips will be seen taking their origin from the ribs, and terminating in a muscular fasciculus, by which the sacro-lumbalis is prolonged to the upper part of the thorax. This is the *musculus accessorius ad sacro-lumbalem*; it arises from the angles of the six lower ribs, and is inserted by separate tendons into the angles of the six upper ribs.

The *longissimus dorsi* is inserted into all the ribs, between their tubercles and angles.*

The *spinalis dorsi* arises from the spinous processes of the two upper lumbar and two lower dorsal vertebræ, and is inserted into the spinous processes of all the upper dorsal vertebræ; the two muscles form an ellipse, which appears to enclose the spinous processes of all the dorsal vertebræ.

Relations.—The erector spinæ muscle is in relation by its *superficial surface* (in the lumbar region) with the conjoined aponeurosis of the transversalis and internal oblique muscle, which separates it from the aponeurosis of the serratus posticus inferior, and longissimus dorsi; (in the dorsal region) with the vertebral aponeurosis, which separates it from the latissimus dorsi, trapezius, and serratus posticus superior, and with the splenius. By its *deep surface* (in the lumbar region) with the multifidus spinæ, transverse processes of the lumbar vertebræ, and with the middle layer of the aponeurosis of the transversalis abdominis, which separates it from the quadratus lumborum; (in the dorsal region) with the multifidus spinæ,

* It is also inserted into the ends of the transverse processes of all the dorsal vertebræ.—G.

semi-spinalis dorsi, levatores costarum, intercostal muscles, and ribs as far as their angles. *Internally* or mesially with the multifidus spinæ, and semi-spinalis dorsi, which separate it from the spinous processes and arches of the vertebræ.

The two layers of aponeurosis of the transversalis abdominis, together with the spinal column in the lumbar region, and the vertebral aponeurosis with the ribs and spinal column in the dorsal region, form a complete osseo-aponeurotic sheath for the erector spinæ.

CERVICAL GROUP.—The *cervicalis ascendens** is the continuation of the sacro-lumbalis upwards into the neck. It *arises* from the angles of the four upper ribs, and is *inserted* by slender tendons into the posterior tubercles of the transverse processes of the four lower cervical vertebræ.

Relations.—By its *superficial surface* with the levator anguli scapulæ; by its *deep surface* with the upper intercostal muscles and ribs, and with the intertransverse muscles; *externally* with the scalenus posticus; and *internally* with the transversalis colli. The tendons of insertion are interposed between the attachments of the scalenus posticus and transversalis colli.

The *transversalis colli* would appear to be the continuation upwards into the neck of the longissimus dorsi; it *arises* from the transverse processes of the third, fourth, fifth, and sixth dorsal vertebræ, and is *inserted* into the posterior tubercles of the transverse processes of the four or five inferior cervical vertebræ.

Relations.—By its *superficial surface* with the levator anguli scapulæ, splenius and longissimus dorsi. By its *deep surface* with the complexus, trachelo-mastoideus and vertebræ; *externally* with the musculus accessorius ad sacro-lumbalem, and cervicalis ascendens; *internally* with the trachelo-mastoideus and complexus. The tendons of insertion of this muscle are interposed between the tendons of in-

Fig. 87.

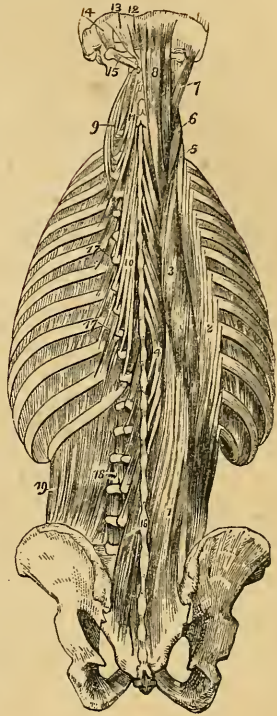


Fig. 87. The fourth and fifth, and part of the sixth layer of the muscles of the back. 1. The common origin of the erector spinæ muscle. 2. The sacro-lumbalis. 3. The longissimus dorsi. 4. The spinalis dorsi. 5. The cervicalis ascendens. 6. The transversalis colli. 7. The trachelo-mastoideus. 8. The complexus. 9. The transversalis colli, showing its origin. 10. The semispinalis dorsi. 11. The semispinalis colli. 12. The rectus posticus minor. 13. The rectus posticus major. 14. The obliquus superior. 15. The obliquus inferior. 16. The multifidus spinæ. 17. The levatores costarum. 18. Intertransversales. 19. The quadratus lumborum.

* Called commonly the cervicalis descendens.—G.

sersion of the cervicalis ascendens on the outer side, and of origin of the trachelo-mastoid on the inner side.

The *trachelo-mastoid* is likewise a continuation upwards from the longissimus dorsi. It is a very slender and delicate muscle, *arising* from the transverse processes of the four upper dorsal, and four lower cervical vertebræ, and *inserted* into the mastoid process to the inner side of the digastric fossa.

Relations.—The same as those of the preceding muscle, excepting that it is interposed between the transversalis colli and the complexus. Its tendons of attachment are the most posterior of those which are connected with the posterior tubercles of the transverse processes of the cervical vertebræ.

The *complexus* is a large muscle, and with the splenius forms the great bulk of the back of the neck. It crosses the direction of the splenius, *arising* from the transverse processes of the four upper dorsal,* and from the transverse and articular processes of the four lower cervical vertebræ—and is *inserted* into the rough surface on the occipital bone between the two curved lines, near to the occipital spine. A portion of the complexus muscle is named *biventer cervicis*, from consisting of a central tendon, with two fleshy bellies.

Relations.—By its *superficial surface* with the trapezius, splenius, trachelo-mastoid, transversalis colli, and longissimus dorsi. By its *deep surface* with the semi-spinalis dorsi and colli, the recti and obliqui. It is separated from its fellow of the opposite side by the ligamentum nuchæ, and from the semi-spinalis colli by the profunda cervicis artery, and princeps cervicis branch of the occipital, and by the posterior cervical plexus of nerves.

Fifth Layer.

Dissection.—The muscles of the preceding layer are to be removed by dividing them transversely through the middle, and turning one extremity upwards, the other downwards. In this way the whole of the muscles of the fourth layer may be got rid of, and the remaining muscles of the spine brought into a state to be examined.

The semi-spinales muscles are connected with the transverse and spinous processes of the vertebræ, spanning one-half of the vertebral column, hence their name semi-spinales.

The *semi-spinalis dorsi* arises from the transverse processes of the six lower dorsal vertebræ, and is *inserted* into the spinous processes of the four upper dorsal, and two lower cervical vertebræ.

The *semi-spinalis colli* arises from the transverse processes of the four upper dorsal vertebræ, and is *inserted* into the spinous processes of the four upper cervical vertebræ, commencing with the axis.

Relations.—By their *superficial surface* the semi-spinales are in relation from below upwards with the spinalis dorsi, longissimus dorsi, complexus, splenius, and with the profunda cervicis and princeps cervicis artery, and posterior cervical plexus of nerves. By their *deep surface* with the multifidus spinæ muscle.

* Horner describes its origin from seven dorsal and four cervical.—G.

Occipital Group.—This group of small muscles is intended for the varied movements of the cranium on the atlas, and the atlas on the axis. They are extremely pretty in appearance.

The *rectus posticus major* arises from the spinous process of the axis, and is inserted into the inferior curved line, on the occipital bone.

The *rectus posticus minor* arises from the spinous tubercle of the atlas, and is inserted into the rough surface on the occipital bone, beneath the inferior curved line.

The *rectus lateralis* is extended between the transverse process of the atlas and the occipital bone; it arises from the transverse process of the atlas, and is inserted into the rough surface of the occipital bone, external to the condyle.

The *obliquus inferior* arises from the spinous process of the axis, and passes obliquely outwards to be inserted into the extremity of the transverse process of the atlas.

The *obliquus superior* arises from the extremity of the transverse process of the atlas, and passes obliquely inwards to be inserted into the rough surface of the occipital bone, between the curved lines.

Relations.—By their *superficial surface* the recti and obliqui are in relation with a strong aponeurosis which separates them from the complexus. By their *deep surface* with the atlas and axis, and their articulations. The *rectus posticus major* partly covers in the *rectus minor*.

The *rectus lateralis* is in relation by its *anterior surface* with the internal jugular vein, and by its *posterior surface* with the vertebral artery.

Sixth Layer.

Dissection.—The semi-spinales muscles must both be removed to obtain a good view of the multifidus spinæ which lies beneath them, and fills up the concavity between the spinous and transverse processes, the whole length of the vertebral column.

The *multifidus spinæ* consists of a great number of fleshy fasciculi, extending between the transverse and spinous processes of the vertebræ, from the sacrum to the axis. Each fasciculus arises from a transverse process, and is inserted into the spinous process of the first or second vertebra above.

Relations.—By its *superficial surface* with the longissimus dorsi, semi-spinalis dorsi, and semi-spinalis colli. By its *deep surface* with the arches and spinous processes of the vertebral column, and in the cervical region with the ligamentum nuchæ.

The *levator costarum*, twelve in number on each side, arise from the transverse processes of the dorsal vertebræ, and pass obliquely outwards and downwards to be inserted into the rough surface between the tubercle and angle of the rib below them. The first of these muscles arises from the transverse process of the last cervical vertebra, and the last from that of the eleventh dorsal.

Relations.—By their *superficial surface* with the longissimus dorsi

and sacro-lumbalis. By their *deep surface* with the intercostal muscles and ribs.

The *supra-spinales* are little fleshy bands lying on the spinous processes of the vertebræ in the cervical region.

The *inter-spinales* are a succession of little pairs of muscles, lying between the bifid tubercles of the spinous processes of the cervical vertebræ. There are five pairs of these muscles; the first being situated between the axis and third vertebra, and the last between the last cervical and first dorsal.

The *inter-transversales* are also arranged in pairs, and pass between the bifid tubercles of the transverse processes of the cervical vertebræ.

The inter-transversales, situated between the atlas and the occipital bone, are the recti laterales. They are sometimes found in the lumbar regions.

Relations.—In *front* with the rectus anticus major and longus colli; and *behind* by the muscles of the back of the neck. They are separated from each other by the anterior branch of the cervical nerves, and by the vertebral artery and veins.

With regard to the origin and insertion of the muscles of the back, the student should be informed that no regularity attends their attachments. At the best, a knowledge of their exact connexions, even were it possible to retain it, would be but a barren information, if not absolutely injurious, as tending to exclude more valuable learning. I have therefore endeavoured to arrange a plan, by which they may be more easily recollected, by placing them in a tabular form, that the student may see at a single glance, the origin and insertion of each, and compare the natural grouping and similarity of attachments of the various layers. In this manner also their actions will be better comprehended, and learnt with greater facility.

Actions.—The upper fibres of the trapezius draw the shoulder upwards and backwards; the middle fibres, directly backwards; and the lower, downwards and backwards. The lower fibres also act by producing rotation of the scapula upon the chest. If the shoulder be fixed the upper fibres will flex the spine towards the corresponding side. The latissimus dorsi is a muscle of the arm, drawing it backwards and downwards, and at the same time rotating it inwards; if the arm be fixed, the latissimus dorsi will draw the spine to that side, and raising the lower ribs be an inspiratory muscle; and if both arms be fixed, the two muscles will draw the whole trunk forwards, as in climbing or walking on crutches. The levator anguli scapulæ lifts the upper angle of the scapula, and with it the entire shoulder, and the rhomboidei carry the scapula and shoulder upwards and backwards.

The serrati are respiratory muscles acting in opposition to each other—the *serratus posticus superior* drawing the ribs upwards, and thereby expanding the chest; and the *inferior*, drawing the lower ribs downwards and diminishing the cavity of the chest. The

former is an inspiratory, the latter an expiratory muscle. The splenii muscles of one side draw the vertebral column backwards and to one side, and rotate the head towards the corresponding shoulder. The muscles of opposite sides acting together, will draw the head directly backwards. They are the natural antagonists of the sterno-mastoid muscles.

The *sacro-lumbalis* with its *accessory muscle*, the *longissimus dorsi* and *spinalis dorsi*, are known by the general term of *erector spinæ*, which sufficiently expresses their actions. They keep the spine supported in the vertical position by their broad origin from below, and by means of their insertion by distinct tendons into the ribs and spinous processes. Being made up of a number of distinct fasciculi, which alternate in their actions, the spine is kept erect without fatigue, even when they have to counterbalance a corpulent abdominal development. The continuations upwards of these muscles into the neck preserve the steadiness and uprightness of that region. When the muscles of one side act alone, the neck is rotated upon its axis. The *complexus*, by being attached to the occipital bone, draws the head backwards, and counteracts the muscles on the anterior part of the neck. It assists also in the rotation of the head.

The *semi-spinales* and *multifidus spinæ* muscles act directly on the vertebræ, and contribute to the general action of supporting the vertebral column erect.

The four little muscles situated between the occiput and the two first vertebræ, effect the various movements between these bones; the *recti* producing the antero-posterior actions, and the *obliqui* the rotary motions of the atlas on the axis.

The actions of the remaining muscles of the spine, the *supra* and *inter-spinales* and *inter-transversales*, are expressed in their names. They approximate their attachments and assist the more powerful muscles in preserving the erect position of the body.

The *levator costarum* raise the posterior parts of the ribs, and are probably more serviceable in preserving the articulation of the ribs from dislocation, than in raising them in inspiration.

In examining the following table, the student will observe the constant recurrence of the number *four* in the origin and insertion of the muscles. Sometimes the *four* occurs at the top or bottom of a region of the spine, and frequently includes a part of two regions, and takes two from each, as in the case of the serrati. Again, he will perceive that the muscles of the upper half of the table take their origin from spinous processes, and pass outwards to transverse, whereas the lower half arise mostly from transverse processes. To the student, then, we commit these reflections, and leave it to the peculiar tenor of his own mind to make such arrangements as will be best retained by his memory.

ORIGIN.				
Layers.	Spinous Processes.	Transverse Processes.	Ribs.	Additional.
<i>1st Layer.</i>				
Trapezius . . .	last cervical, 12 dorsal	occipital bone, and ligamentum nuchæ } sacrum and ilium }
Latissimus dorsi	6 lower dorsal, 5 lumbar	3 lower	
<i>2d Layer.</i>				
Levator anguli scapulæ	4 upper cervical
Rhomboideus min.	lig. nuchæ, last cervical
Rhomboideus	4 upper dorsal
<i>3d Layer.</i>				
Serratus posticus superior . . .	lig. nuchæ, last cervical, 2 upper dorsal
Serratus posticus inferior . . .	2 lower dorsal, 2 upper lumbar
Splenius capitis	lig. nuchæ, last cervical,
Splenius colli . .	6 upper dorsal
<i>4th Layer.</i>				
Sacro-lumbalis	sacrum and ilium .
— accessorius ad sacro-lumbalem }	angles of 6 lower
Longissimus dorsi	sacrum and lumbar vertebræ . . . }
Spinalis dorsi . .	2 lower dorsal, 2 upper lumbar
Cervicalis ascendens	angles of 4 upper
Transversalis colli	3d, 4th, 5th, and 6th dorsal
Trachelo-mas- toideus }	4 upper dorsal, 4 lower cervical
Complexus	4 upper dorsal, 4 lower cervical
<i>5th Layer.</i>				
Semi-spinalis dorsi	6 lower dorsal
Semi-spinalis colli	4 upper dorsal
Rectus posticus maj.	axis
Rectus posticus min.	atlas
Rectus lateralis	atlas
Obliquus inferior .	axis
Obliquus superior	axis
<i>6th Layer.</i>				
Multifidus spine	from sacrum to 3d cervical
Levatores costarum	last cervical and eleven dorsal
Supra-spinales . . .	cervical
Inter-spinales . . .	cervical
Inter-transversales	cervical

INSERTION.			
Spinous Processes.	Transverse Processes.	Ribs.	Additional.
.	} clavicle and spine of the scapula. } posterior bicipital ridge of the humerus.
.	
.	} angle and base of the scapula. } base of the scapula. } base of the scapula.
.	
.	
.	2d, 3d, 4th, and 5th.	
.	4 lower ribs.	} occipital and mastoid portion of temporal bone.
.	4 upper cervical.	
.	angles of 6 lower.	
.	angles of 6 upper.	
.	} all the ribs between the tubercles and angles.	
8 upper dorsal.		
.	4 lower cervical.	
.	4 lower cervical.	
.	mastoid process.
.	} occipital bone between the curved lines.
.	
} 4 upper dorsal, } 2 lower cervical.	occipital bone.
	} 4 upper cervical, } except atlas.
.
.	atlas.	occipital bone.
.	
} from last lumbar to axis.	} all the ribs between the tubercles and angles.	
		
cervical.		
cervical.	cervical.		

Muscles of the Thorax.

The principal muscles situated upon the thorax belong in their actions to the upper extremity, with which they will be described. They are the pectoralis major and minor, subclavius and serratus magnus. The true thoracic muscles are few in number, and appertain exclusively to the actions of the ribs; they are, the—

Intercostales externi,
Intercostales interni,
Triangularis sterni.

The intercostal muscles are two planes of muscular and tendinous fibres directed obliquely between the adjacent ribs and closing the intercostal spaces. They are seen partially upon the removal of the pectoral muscles, or upon the inner surface of the chest. The triangularis sterni is within the chest, and requires the removal of the anterior part of the thorax to bring it into view.

The *intercostales externi*, eleven on each side, commence posteriorly at the vertebral column, and advance forwards to the costal cartilages, where they terminate in a thin aponeurosis which is continued onwards to the sternum: Their fibres are directed obliquely downwards and inwards, pursuing the same line with those of the external oblique muscle of the abdomen. They are thicker than the internal intercostals.

The *intercostales interni*, also eleven on each side, commence anteriorly at the sternum, and extend backwards as far as the angles of the ribs, whence they are prolonged to the vertebral column by a thin aponeurosis. Their fibres are directed obliquely downwards and backwards, and correspond in direction with those of the internal oblique muscle of the abdomen. The two muscles cross each other in the direction of their fibres.

In structure the intercostal muscles consist of an admixture of muscular and tendinous fibres. They *arise* from the two lips of the lower border of the ribs, the external from the outer lip, the internal from the inner, and are *inserted* into the upper border.

Relations.—The external intercostals, by their *external surface* with the muscles which immediately invest the chest, viz., with the pectoralis major and minor, the serratus magnus, serratus posticus superior and inferior, scalenus posticus; sacro-lumbalis, and longissimus dorsi, with their continuations, the cervicalis ascendens and transversalis colli; the levatores costarum, and the obliquus externus abdominis. By their *internal surface* with the internal intercostals, the intercostal vessels and nerves, and a thin aponeurosis, and posteriorly with the pleura. The internal intercostals, by their *external surface* with the external intercostals, and intercostal vessels and nerves; by their *internal surface* with the pleura costalis, the triangularis sterni and diaphragm.

Connected with the internal intercostals are a variable number of

muscular fasciculi which pass from the inner surface of one rib near its middle to the next or next but one below; these are the subcostal or more correctly the *intracostal muscles*.

Fig. 88.

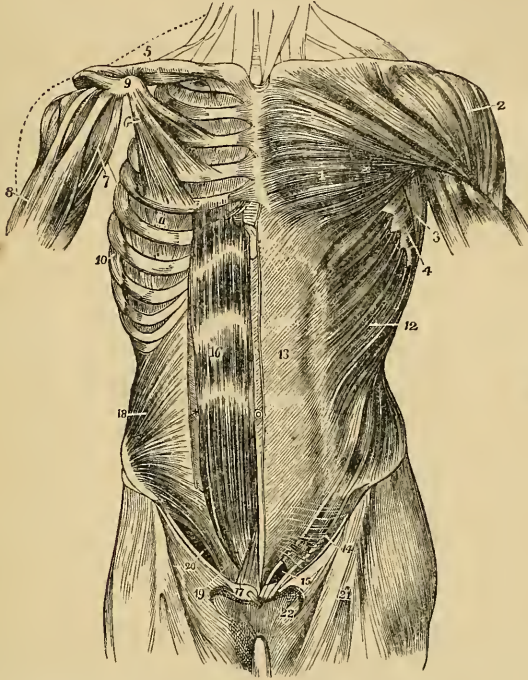


Fig. 88. The muscles of the anterior aspect of the trunk; on the left side the superficial layer is seen, and on the right the deeper layer. 1. The pectoralis major muscle. 2. The deltoid; the interval between these muscles lodges the cephalic vein. 3. The anterior border of the latissimus dorsi. 4. The serrations of the serratus magnus. 5. The subclavius muscle of the right side. 6. The pectoralis minor. 7. The coracobrachialis muscle. 8. The upper part of the biceps muscle, showing its two heads. 9. The coracoid process of the scapula. 10. The serratus magnus of the right side. 11. The external intercostal muscle of the fifth intercostal space. 12. The external oblique muscle. 13. Its aponeurosis; the median line to the right of this number is the linea alba; the flexuous line to its left is the linea semilunaris; and the transverse lines above and below the number, the lineæ transversæ, of which there were only three in this subject. 14. Poupart's ligament. 15. The external abdominal ring; the margin above the ring is the superior or internal pillar; the margin below the ring, the inferior or external pillar; the curved intercolumnar fibres are seen proceeding upwards from Poupart's ligament to strengthen the ring. The numbers 14 and 15 are situated upon the fascia lata of the thigh; the opening immediately to the right of 15 is the saphenous opening. 16. The rectus muscle of the right side brought into view by the removal of the anterior segment of its sheath: * the posterior segment of its sheath with the divided edge of the anterior segment. 17. The pyramidalis muscle. 18. The internal oblique muscle. 19. The conjoined tendon of the internal oblique and transversalis descending behind Poupart's ligament to the pectineal line. 20. The arch formed between the lower curved border of the internal oblique muscle and Poupart's ligament; it is beneath this arch that the spermatic cord and hernia pass.

The *triangularis sterni*, situated upon the inner wall of the front of the chest, *arises* by a thin aponeurosis from the side of the sternum, ensiform cartilage, and sternal extremities of the costal cartilages; and is *inserted* by fleshy digitations into the cartilages of the third, fourth, fifth and sixth ribs, and often into that of the second.

Relations.—By its *external surface* with the sternum, the ensiform cartilage, the costal cartilages, internal intercostal muscles, and internal mammary vessels. By its *internal surface* with the pleura costalis, the cellular tissue of the anterior mediastinum and the diaphragm.

Actions.—The intercostal muscles raise the ribs when they act from above, and depress them when they take their fixed point from below. They are, therefore, both inspiratory and expiratory muscles. The *triangularis sterni* draws down the costal cartilages, and is therefore an expiratory muscle.

Muscles of the Abdomen.

The muscles of this region are the—

Obliquus externus (descendens),
 Obliquus internus (ascendens),
 Cremaster,
 Transversalis,
 Rectus,
 Pyramidalis,
 Quadratus lumborum,
 Psoas parvus,
 Diaphragm.

Dissection.—The dissection of the abdominal muscles is to be commenced by making three incisions:—the first, *vertical*, in the middle line, from over the lower part of the sternum to the pubes; the second, *oblique*, from the umbilicus, upwards and outwards, to the outer side of the chest, as high as the fifth or sixth rib; and the third, *oblique*, from the umbilicus, downwards and outwards, to the middle of the crest of the ilium. The three flaps included by these incisions should then be dissected back in the direction of the fibres of the external oblique muscle, beginning at the angle of each. The integument and superficial fascia should be dissected off together so as to expose the fibres of the muscle at once.

If the external oblique muscle be dissected on both sides, a white tendinous line will be seen along the middle of the abdomen, extending from the ensiform cartilage to the os pubis; this is the *linea alba*. A little external to it, on each side, two curved lines will be observed extending from the sides of the chest to the os pubis, and bounding the recti muscles: these are the *lineæ semilunares*. Some transverse lines, *lineæ transversæ*, three or four in number, connect the *lineæ semilunares* with the *linea alba*.

The *external oblique muscle* (*obliquus externus abdominis*, descen-

dens) is the external flat muscle of the abdomen. Its name is derived from the obliquity of its direction, and the descending course of its fibres. It *arises* by fleshy digitations from the external surface of the eight inferior ribs. The five upper digitations being received between corresponding processes of the serratus magnus, and the three lower of the latissimus dorsi; it spreads out into a broad aponeurosis, which is *inserted* into the outer lip of the crest of the ilium for one half its length, the anterior superior spinous process of the ilium, spine of the os pubis, pectineal line, front of the os pubis, and linea alba.

The lower border of the aponeurosis, which is stretched between the anterior superior spinous process of the ilium and the spine of the os pubis, is folded inwards, forming *Poupart's ligament*; the insertion into the pectineal line is *Gimbernat's ligament*.

Just above the crest of the os pubis is the *external abdominal ring*, a triangular opening formed by the separation of the fibres of the aponeurosis of the external oblique. It is oblique in its direction, and corresponds with the course of the fibres of the aponeurosis. It is bounded below by the crest of the os pubis; on either side, by the borders of the aponeurosis, which are called *pillars*; and above by some curved fibres (*inter-columnar*), which originate from Poupart's ligament, and cross the upper angle of the ring, so as to give it strength. The *external pillar*, which is at the same time *inferior*, from the obliquity of the opening is inserted into the spine of the os pubis; the internal or superior pillar forms an interlacement with its fellow of the opposite side over the front of the symphysis pubis. The external abdominal ring gives passage to the spermatic cord in the male, and round ligament in the female; they are both invested in their passage through it by a thin fascia derived from the edges of the ring, and called *inter-columnar fascia*, or fascia spermatica.

The pouch of inguinal hernia, in passing through this opening, receives the *inter-columnar fascia*, as one of its coverings.

Relations.—By its *external surface* with the superficial fascia and integument, and with the cutaneous vessels and nerves, particularly the superficial epigastric and superficial circumflex ilii vessels. It is generally overlapped posteriorly by the latissimus dorsi. By its *internal surface* with the internal oblique, the lower part of the eight inferior ribs and intercostal muscles, the cremaster, the spermatic cord in the male, and the round ligament in the female.

The external oblique is now to be removed by making an incision across the ribs, just below its origin, to its posterior border; and another along Poupart's ligament and the crest of the ilium. Poupart's ligament should be left entire, as it gives attachment to the next muscles. The muscle may then be turned forwards towards the linea alba, or removed altogether.

The *internal oblique muscle* (*obliquus internus abdominis, ascendens*) is the middle flat muscle of the abdomen. It *arises* from the outer half of Poupart's ligament, from the middle of the crest of the

ilium for two-thirds of its length, and by a thin aponeurosis from the spinous processes of the lumbar vertebræ.* Its fibres diverge from their origin, so that those from Poupart's ligament curve downwards, those from the anterior part of the crest of the ilium pass transversely, and the rest ascend obliquely. The muscle is *inserted* into the pectineal line, crest of the os pubis, linea alba, and lower borders of the five inferior ribs.

Along the upper three-fourths of the linea semilunaris, the aponeurosis of the internal oblique separates into two lamellæ, which pass one in front and the other behind the rectus muscle to the linea alba, where they are inserted; along the lower fourth, the aponeurosis passes altogether in front of the rectus without separation. The two layers which thus enclose the rectus, form for it a partial sheath.

The lowest fibres of the internal oblique are inserted into the pectineal line in common with those of the transversalis muscle. Hence the tendon of this insertion is called the *conjoined tendon of the internal oblique and transversalis*. This structure corresponds with the external abdominal ring, and forms a protection to what would otherwise be a weak point in the abdomen. Sometimes it is insufficient to resist the pressure from within, and becomes forced through the external ring: it then forms the distinctive covering of *direct inguinal hernia*.

The spermatic cord passes beneath the arched border of the internal oblique muscle, between it and Poupart's ligament. During its passage some fibres are given off from the lower border of the muscle, which accompany the cord downwards to the testicle, and form loops around it: this is the cremaster muscle. In the descent of oblique inguinal hernia, which travels the same course with the spermatic cord, the cremaster muscle forms one of its coverings.

The *cremaster*, considered as a distinct muscle, *arises* from the middle of Poupart's ligament, and forms a series of loops upon the spermatic cord. A few of its fibres are inserted into the tunica vaginalis, the rest ascend along the inner side of the cord, to be *inserted*, with the conjoined tendon, into the pectineal line of the os pubis.

Relations.—The internal oblique is in relation by its *external surface* with the external oblique, latissimus dorsi, spermatic cord and external abdominal ring. By its *internal surface* with the transversalis muscle, the fascia transversalis, the internal abdominal ring, and spermatic cord. By its *lower and arched border* with the spermatic cord, forming the upper boundary of the spermatic canal.

The cremaster is in relation by its *external surface* with the aponeurosis of the external oblique and inter-columnar fascia; and by its *internal surface* with the fascia propria of the spermatic cord.

The internal oblique muscle is to be removed by separating it

* From the three inferior lumbar spinous processes and all those of the sacrum.—G.

from its attachment to the ribs above, and to the crest of the ilium and Poupart's ligament below. It should be divided behind by a vertical incision extending from the last rib to the crest of the ilium, as its lumbar attachment cannot at present be examined. The muscle is then to be turned forwards. Some degree of care will be required in performing this dissection, from the difficulty of distinguishing between this muscle and the one beneath. A thin layer of cellular tissue is all that separates them for the greater part of their extent. Near the crest of the ilium the circumflex ilii artery ascends between the two muscles, and forms a valuable guide to their separation. Just above Poupart's ligament they are so closely connected that it is impossible to divide them.

The *transversalis* is the internal flat muscle of the abdomen; it is transverse in the direction of its fibres, as is implied in its name. It arises from the outer third of Poupart's ligament, from the internal lip of the crest of the ilium, its anterior two thirds; from the spinous and transverse processes of the lumbar vertebræ,* and from the inner surfaces of the six inferior ribs, indigitating with the diaphragm. Its lower fibres curve downwards, to be inserted, with the lower fibres of the internal oblique, into the pectineal line, and form the conjoined tendon. Throughout the rest of its extent it is inserted into the crest of the os pubis and linea alba. The lower fourth of its aponeurosis passes in front of the rectus to the linea alba; the upper three-fourths with the posterior lamella of the internal oblique, behind it.

The posterior aponeurosis of the transversalis divides into three lamellæ;—*anterior*, which is attached to the bases of the transverse processes of the lumbar vertebræ; *middle*, to the apices of the transverse processes; and *posterior*, to the apices of the spinous processes. The anterior and middle lamellæ enclose the quadratus lumborum muscle; and the middle and posterior, the erector spinæ. The union of the posterior lamella of the transversalis with the posterior aponeurosis of the internal oblique, serratus posticus inferior, and latissimus dorsi, constitutes the lumbar fascia.

Relations.—By its external surface with the internal oblique, the internal surfaces of the lower ribs, and internal intercostal muscles. By its internal surface with the transversalis fascia, which separates it from the peritoneum, with the psoas magnus, and with the lower part of the rectus and pyramidalis. The spermatic cord and oblique inguinal hernia pass beneath the lower border, but have no direct relation with it.

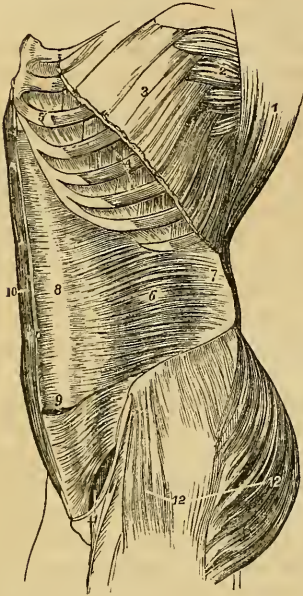
To dissect the *rectus muscle*, the sheath should be opened by a vertical incision extending from over the cartilages of the lower ribs to the front of the os pubis. The sheath may then be dissected off and turned to either side: this is easily done excepting at the lineæ transversæ, where a close adhesion subsists between the muscle

* From the transverse processes of the last dorsal and four superior lumbar vertebræ.—G.

and the external boundary of the sheath. The sheath contains the rectus and pyramidalis muscle.

The *rectus muscle* arises by a flattened tendon from the crest of the os pubis, and is *inserted* into the cartilages of the fifth, sixth, and seventh ribs. It is traversed by several tendinous zigzag lines, called lineæ transversæ. One of these is usually situated at the umbilicus, two above that point, and sometimes one below. They are vestiges of the abdominal ribs of reptiles, and very rarely extend completely through the muscle.

Fig. 89.



Relations.—By its *external surface* with the anterior lamella of the aponeurosis of the internal oblique, below with the aponeurosis of the transversalis, and pyramidalis. By its *internal surface* with the ensiform cartilage, the cartilages of the fifth, sixth, seventh, eighth and ninth ribs, with the posterior lamella of the internal oblique, the peritoneum, and the epigastric artery and veins.

The *pyramidalis muscle* arises from the crest of the os pubis in front of the rectus, and is *inserted* into the linea alba at about midway between the umbilicus and the pubis. It is enclosed in the same sheath with the rectus,* and rests against the lower part of that muscle. This muscle is sometimes wanting.

The rectus may now be divided across the middle, and the two ends drawn aside for the purpose of examining the mode of formation of its sheath.

The *sheath of the rectus* is formed *in front* for the upper three-fourths of its extent, by the aponeurosis of the external oblique and the anterior lamella of the internal oblique, and *behind* by the poste-

Fig. 89. A lateral view of the trunk of the body, showing its muscles, and particularly the transversalis abdominis. 1. The costal origin of the latissimus dorsi muscle. 2. The serratus magnus. 3. The upper part of the external oblique muscle divided in the direction best calculated to show the muscles beneath without interfering with its indigitations with the serratus magnus. 4. Two of the external intercostal muscles. 5. Two of the internal intercostals. 6. The transversalis muscle. 7. Its posterior aponeurosis. 8. Its anterior aponeurosis forming the most posterior layer of the sheath of the rectus. 9. The lower part of the left rectus with the aponeurosis of the transversalis passing in front. 10. The right rectus muscle. 11. The arched opening left between the lower border of the transversalis muscle and Poupart's ligament, through which the spermatic cord and hernia pass. 12. The gluteus maximus, and medius, and tensor vaginae femoris muscles invested by fascia lata.

* This is not precisely the fact, as there is a separate sheath for the pyramidalis.—G.

rior lamella of the internal oblique and the aponeurosis of the transversalis. At the commencement of the lower fourth, the posterior wall of the sheath terminates in a thin curved margin, the aponeuroses of the three muscles passing altogether in front of the rectus.

The two next muscles can only be examined when the whole of the viscera are removed. To see the quadratus lumborum, it is also necessary to divide and draw aside the psoas muscle and the anterior lamella of the aponeurosis of the transversalis.

The *quadratus lumborum* muscle is concealed from view by the anterior lamella of the aponeurosis of the transversalis muscle, which is inserted into the bases of the transverse processes of the lumbar vertebræ, and ligamentum arcuatum externum. When this lamella is divided, the muscle will be seen *arising* from the last rib, and from the transverse processes of the four upper lumbar vertebræ. It is *inserted* into the crest of the ilium. If the muscle be cut across or removed, the middle lamella of the transversalis will be seen attached to the apices of the transverse processes; the quadratus being enclosed between the two lamellæ as in a sheath.

Relations.—Enclosed in the sheath formed by the transversalis muscle, it is in relation *in front*, with the kidney, the colon, the psoas magnus and the diaphragm. *Behind*, but also separated by the sheath, with the erector spinæ.

The *psoas parvus* arises from the tendinous arches and intervertebral substance of the last dorsal and first lumbar vertebræ, and terminates in a long slender tendon which is *inserted* into the pectineal line of the os pubis. The tendon is continuous by its outer border with the iliac fascia.

Relations.—It rests upon the psoas magnus, and is covered in by the peritoneum; superiorly it passes beneath the ligamentum arcuatum of the diaphragm. It is occasionally wanting.

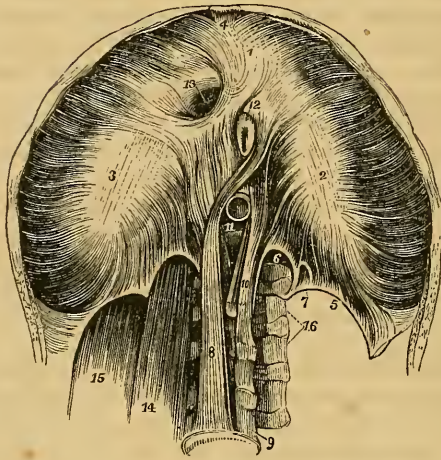
Diaphragm.—To obtain a good view of this important inspiratory muscle, the peritoneum should be dissected from its under surface. It is the muscular septum between the thorax and abdomen, and is composed of two portions, a greater and a lesser muscle. The *greater muscle* arises from the ensiform cartilage; from the inner surfaces of the six inferior ribs, indigitating with the transversalis; and from the ligamentum arcuatum externum and internum. From these points which form the internal circumference of the trunk, the fibres converge and are *inserted* into the central tendon.

The *ligamentum arcuatum externum* is the upper border of the anterior lamella of the aponeurosis of the transversalis: it arches across the origin of the quadratus lumborum muscle, and is attached by one extremity to the extremity of the transverse process of the first lumbar vertebra, and by the other to the apex and lower margin of the last rib.

The *ligamentum arcuatum internum*, or *proprium*, is a tendinous arch thrown across the psoas magnus muscle as it emerges from the chest. It is attached by one extremity to the transverse pro-

cess of the first lumbar vertebra, and by the other to the body of the second.

Fig. 90.



The *tendinous centre* of the diaphragm is shaped like a trefoil leaf, of which the central leaflet points to the ensiform cartilage, and is the largest; the lateral leaflets, right and left, occupy the corresponding portions of the muscle; the right being the larger and more rounded, and the left smaller and lengthened in its form.

Between the sides of the ensiform cartilage and the cartilages of the adjoining ribs, is a small triangular space where the muscular fibres of the diaphragm are deficient. This space is closed only by peritoneum on the side of the abdomen, and by pleura within the chest. It is therefore a weak point, and a portion of the contents of the abdomen might, by violent exertion, be forced through it, producing phrenic, or diaphragmatic hernia.

The *lesser muscle* of the diaphragm takes its origin from the bodies

Fig. 90. The under or abdominal side of the diaphragm. 1, 2, 3. The greater muscle; the figure 1 rests upon the central leaflet of the tendinous centre; the number 2 on the left or smallest leaflet; and number 3 on the right leaflet. 4. The thin fasciculus which arises from the ensiform cartilage; a small triangular space is left on either side of this fasciculus, which is closed only by the serous membranes of the abdomen and chest. 5. The ligamentum arcuatum externum of the left side. 6. The ligamentum arcuatum internum. 7. A small arched opening occasionally found, through which the lesser splanchnic nerve passes. 8. The right or larger tendon of the lesser muscle; a muscular fasciculus from this tendon curves to the left side of the greater muscle between the œsophageal and aortic openings. 9. The fourth lumbar vertebra. 10. The left or shorter tendon of the lesser muscle. 11. The aortic opening occupied by the aorta, which is cut short off. 12. A portion of the œsophagus issuing through the œsophageal opening. 13. The opening for the inferior vena cava, in the tendinous centre of the diaphragm. 14. The psoas magnus muscle passing beneath the ligamentum arcuatum internum: it has been removed on the opposite side to show the arch more distinctly. 15. The quadratus lumborum passing beneath the ligamentum arcuatum externum; this muscle has also been removed on the left side.

of the lumbar vertebræ by two tendons. The *right*, larger and longer than the left, arises from the anterior surface of the bodies of the second, third, and fourth vertebræ; and the *left* from the side of the second and third. The tendons form two large fleshy bellies (*crura*), which ascend to be inserted into the central tendon. The inner fasciculi of the two crura cross each other in front of the aorta, and again diverge to surround the œsophagus, so as to present the appearance of a figure of eight. The anterior fasciculus of the decussation is formed by the right crus.

The *openings in the diaphragm* are three: one, quadrilateral, in the tendinous centre, at the union of the right and middle leaflets, for the passage of the *inferior vena cava*; a muscular opening of an elliptic shape formed by the two crura, for the transmission of the *œsophagus* and *pneumogastric nerves*; and a third, the *aortic*, which is formed by a tendinous arch thrown from the tendon of one crus to that of the other, across the vertebral column, beneath which pass the *aorta*, the *right vena azygos*, and *thoracic duct*. The great splanchnic nerves pass through openings in the lesser muscle on each side, and the lesser splanchnic nerves through the fibres which arise from the ligamentum arcuatum internum.

Relations.—By its *superior surface* with the pleuræ, the pericardium, the heart, and the lungs. By its *inferior surface* with the peritoneum; on the left with the stomach and spleen; on the right with the convexity of the liver; and behind with the kidneys, the suprarenal capsules, the duodenum and the solar plexus. By its *circumference* with the ribs and intercostal muscles, and with the vertebral column.

Actions.—The external oblique muscle, acting singly, would draw the thorax towards the pelvis, and twist the body to the opposite side. Both muscles, acting together, would flex the thorax directly on the pelvis. The internal oblique of one side draws the chest downwards and outwards: both together bend it directly forwards. Either transversalis muscle, acting singly, will diminish the size of the abdomen on its own side, and both together will constrict the entire cylinder of the cavity. The recti muscles, assisted by the pyramidales, flex the thorax upon the chest, and, through the medium of the lineæ transversæ, are enabled to act when their sheath is curved inwards by the action of the transversales. The pyramidales are tensors of the linea alba. The abdominal are expiratory muscles, and the chief agents of expulsion; by their action the fœtus is expelled from the uterus, the urine from the bladder, the fæces from the rectum, the bile from the gall-bladder, the ingesta from the stomach and bowels in vomiting, and the mucus and irritating substances from the bronchial tubes, trachea, and nasal passages during coughing and sneezing. To produce these efforts they all act together. Their violent and continued action produces hernia; and, acting spasmodically, they may occasion rupture of the viscera. The quadratus lumborum draws the last rib downwards, and is an expiratory muscle; it also serves to bend the vertebral column to

one or the other side. The psoas parvus is a tensor of the iliac fascia, and, taking its fixed origin from below, it may assist in flexing the vertebral column forwards. The diaphragm is an inspiratory muscle, and the sole agent in tranquil inspiration. When in action, the muscle is drawn downwards, its plane being rendered oblique from the level of the ensiform cartilage, to that of the upper lumbar vertebra. During relaxation it is convex, and encroaches considerably on the cavity of the chest, particularly at the sides, where it corresponds with the lungs. It assists the abdominal muscles powerfully in expulsion, every act of that kind being preceded or accompanied by a deep inspiration. Spasmodic action of the diaphragm produces hiccough and sobbing, and its rapid alternation of contraction and relaxation, combined with laryngeal and facial movements, laughing and crying.

Muscles of the Perineum.

The muscles of the perineum are situated in the outlet of the pelvis, and consist of two groups, one of which belongs especially to the organs of generation and urethra, the other to the termination of the alimentary canal. To these may be added the only pair of muscles which is proper to the pelvis, the coccygeus. The muscles of this region in the male, are the

Accelerator urinæ,
Erector penis,
Transversus perinei,
Compressor urethræ,
Sphincter ani,
Levator ani,
Coccygeus.

Dissection.—To dissect the perineum, the subject should be fixed in the position for lithotomy, that is, the hands should be bound to the soles of the feet, and the knees kept apart. An easier plan is the drawing of the feet upwards by means of a cord passed through a hook in the ceiling. Both of these plans of preparation have for their object the full exposure of the perineum. And as this is a dissection which demands some degree of delicacy and nice manipulation, a strong light should be thrown upon the part. Having fixed the subject, and drawn the scrotum upwards by means of a string or hook, carry an incision from the base of the scrotum along the ramus of the pubis and ischium and tuberosity of the ischium, to a point parallel with the apex of the coccyx; then describe a curve over the coccyx to the same point on the opposite side; and continue the incision onwards along the opposite tuberosity, and along the ramus of the ischium and of the pubis, to the opposite side of the scrotum, where the two extremities may be connected by a transverse incision. This incision will completely surround the perineum, following very nearly the outline of its boundaries. Now let the stu-

dent dissect off the integument carefully from the whole of the included space, and he will expose the fatty cellular structure of the common superficial fascia, which exactly resembles the superficial fascia in every other situation. The common superficial fascia is then to be removed to the same extent, exposing the superficial perineal fascia. This layer is also to be turned aside, when the muscles of the genital region of the perineum will be brought into view.

The *Acceleratores urinæ* arise from a tendinous point in the centre of the perineum and from the raphé. From these origins the fibres diverge, like the plumes of a pen: the posterior fibres to be *inserted* into the ramus of the pubis and ischium; the middle to encircle the corpus spongiosum, and meet upon its upper side; and the anterior to spread out upon the corpus cavernosum on each side, and be inserted, partly into its fibrous structure, and partly into the fascia of the penis. The posterior and middle insertions of these muscles are best seen, by carefully raising one muscle from the corpus spongiosum and tracing its fibres.

Relations.—By their *superficial surface* with the superficial perineal fascia, the dartos, the superficial vessels and nerves of the perineum, and on each side with the erector penis. By their *deep surface* with the corpus spongiosum and bulb of the urethra.

The *Erector penis* arises from the ramus and tuberosity of the ischium, and curves around the root of the penis, to be *inserted* into the upper surface of the corpus cavernosum, where it is continuous with a strong fascia which covers the dorsum of the organ, the fascia penis.

Relations.—By its *superficial surface* with the superficial perineal fascia, the dartos, and the superficial perineal vessels and nerve. By its *deep surface* with the corpus cavernosum penis.

The *Transversus perinei* arises from the tuberosity of the ischium on each side, and is *inserted* into the central tendinous point of the perineum.*

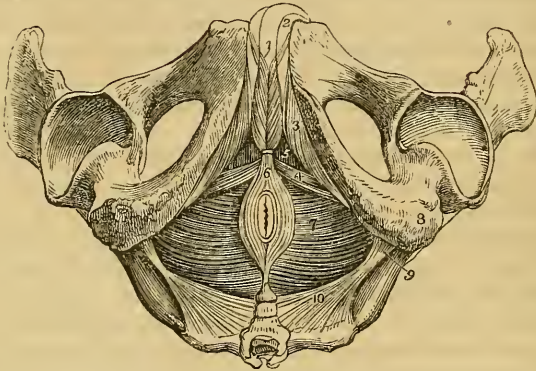
Relations.—By its *superficial surface* with the superficial perineal fascia, and superficial perineal artery. By its *deep surface* with the deep perineal fascia, and internal pudic artery and veins. By its *posterior border* it is in relation with that portion of the superficial perineal fascia which passes back to become continuous with the deep fascia.

To dissect the *compressor urethræ*, the whole of the preceding muscles should be removed, so as to render the glistening surface of the deep perineal fascia quite apparent. The anterior layer of this fascia should then be carefully dissected away, and the corpus

* I once dissected a perineum in which the transversus perinei was of large size, and spread out as it approached the middle line so as to become fan-shaped. The posterior fibres were continuous with those of the muscle of the opposite side; but the anterior were continued forwards upon the bulb and corpus spongiosum of the urethra as far as the middle of the penis, forming a broad layer which usurped the place and office of the accelerator urinæ.

spongiosum penis divided through its middle, separated from the corpus cavernosum, and drawn forwards, to put the membranous portion of the urethra, upon which the muscle is spread out, upon the stretch. The muscle is, however, better seen in a dissection made from within the pelvis, after having turned down the bladder from its attachment to the os pubis, and removed a plexus of veins and the posterior layer of the deep perineal fascia.

Fig. 91.



The *Compressor urethræ* (Wilson's and Guthrie's muscles), consists of two portions; one of which is *transverse* in its direction, and passes inwards, to embrace the membranous urethra; the other is *perpendicular*, and descends from the pubis. The *transverse portion*, particularly described by Mr. Guthrie, *arises* by a narrow tendinous point, from the upper part of the ramus of the ischium, on each side, and divides into two fasciculi, which pass inwards and slightly upwards, and embrace the membranous portion of the urethra and Cowper's glands. As they pass towards the urethra, they spread out and become fan-shaped, and are *inserted* into a tendinous raphé upon the upper and lower surfaces of the urethra, extending from the apex of the prostate gland, to which they are attached posteriorly, to the bulbous portion of the urethra, with which they are connected in front. When seen from above, these portions resemble two fans, connected by their expanded border along the middle line of the membranous urethra, from the prostate to the bulbous portion of the urethra. The same appearance is obtained by viewing them from below.

Fig. 91. The muscles of the perineum. 1. The acceleratores urinæ muscles; the figure rests upon the corpus spongiosum penis. 2. The corpus cavernosum of one side. 3. The erector penis of one side. 4. The transversus perinei of one side. 5. The triangular space through which the deep perineal fascia is seen. 6. The sphincter ani; its anterior extremity is cut off. 7. The levator ani of the left side; the deep space between the tuberosity of the ischium (8) and the anus, is the ischio-rectal fossa; the same fossa is seen upon the opposite side. 9. The spine of the ischium. 10. The left coccygeus muscle. The boundaries of the perineum are well seen in this engraving.

The *perpendicular portion** described by Mr. Wilson, *arises* by two tendinous points from the inner surface of the arch of the pubis, on each side of, and close to the symphysis. The tendinous origins soon become muscular, and descend perpendicularly, to be *inserted* into the upper fasciculus of the transverse portion of the muscle; so that it is not a distinct muscle surrounding the membranous portion of the urethra, and supporting it as in a sling, as described by Mr. Wilson, but merely an upper origin of the transverse muscle.

The compressor urethræ may be considered either as two symmetrical muscles meeting at the raphé, or as a single muscle: I have adopted the latter course in the above description, as appearing to me the more consistent with the general connexions of the muscle, and with its actions.

The *Sphincter ani* is a thin and elliptical plane of muscle, closely adherent to the integument, and surrounding the opening of the anus. It *arises* posteriorly in the superficial fascia around the coccyx, and by a fibrous raphé from the apex of that bone; and is *inserted* anteriorly into the tendinous centre of the perineum, and into the raphé of the integument, nearly as far forwards as the commencement of the scrotum.

Relations.—By its *superficial surface* with the integument. By its *deep surface* with the internal sphincter, the levator ani, the cellular tissue and fat in the ischio-rectal fossa, and in front with the superficial perineal fascia.

The *Sphincter ani internus* is a muscular ring embracing the extremity of the intestine, and formed by an aggregation of the circular muscular fibres of the rectum.

Part of the levator ani may be seen during the dissection of the anal portion of the perineum by removing the fat which surrounds the termination of the rectum in the ischio-rectal fossa. But to study the entire muscle, a lateral section of the pelvis must be made by sawing through the pubis a little to one side of the symphysis, separating the bones behind at the sacro-iliac symphysis, and turning down the bladder and rectum. The pelvic fascia is then to be carefully raised, beginning at the base of the bladder and proceeding upwards, until the whole extent of the muscle be exposed.

The *Levator ani* is a thin plane of muscular fibres, situated on each side of the pelvis. It *arises* from the inner surface of the os pubis, from the spine of the ischium, and between those points from the angle of division between the obturator and the pelvic fascia. Its fibres descend to be *inserted* into the extremity of the coccyx into a fibrous raphé in front of that bone, into the lower part of the rectum, base of the bladder, and prostate gland.

* Mr. Tyrrell, who has made many careful dissections of the muscles of the perineum, has not observed this portion of the muscle; he considers Wilson's muscle (with some other anatomists) to be the anterior fibres of the levator ani, not uniting beneath the urethra as described by Mr. Wilson; but inserted into a portion of the pelvic fascia situated between the prostate gland and rectum,—the recto-vesical fascia.

In the female this muscle is inserted into the coccyx and fibrous raphé, extremity of the rectum and vagina.

Relations.—By its *external* or *perineal surface*, with a thin layer of fascia, by which and by the obturator fascia it is separated from the obturator internus muscle; with the fat in the ischio-rectal fossa, the deep perineal fascia, the levator ani, and posteriorly with the gluteus maximus. By its *internal* or *pelvic surface*, with the pelvic fascia, which separates it from the viscera of the pelvis and peritoneum.

The *Coccygeus muscle* is a tendino-muscular layer of a triangular form. It *arises* from the spine of the ischium, and is *inserted* into the side of the coccyx and lower part of the sacrum.

Relations.—By its *internal* or *pelvic surface*, with the rectum; by its *external surface* with the lesser and greater sacro-ischiatic ligaments.

The muscles of the perineum in the female are the same as in the male, and have received analogous names. They are smaller in size, and are modified to suit the different form of the organs; they are—

Constrictor vaginæ,
Erector clitoridis,
Transversus perinei,
Compressor urethræ,
Sphincter ani,
Levator ani,
Coccygeus.

The *Constrictor vaginæ* is analogous to the acceleratores urinæ; it is continuous posteriorly with the sphincter ani, interlacing with its fibres, and is *inserted* anteriorly into the sides of the corpora cavernosa, and fascia of the clitoris.

The *Transversus perinei* is *inserted* into the side of the constrictor vaginæ, and the levator ani into the side of the vagina.

The other muscles are precisely similar in their attachments to those in the male.

Actions.—The acceleratores urinæ being continuous at the middle line, and attached on each side to the bone, by means of their posterior fibres will support the bulbous portion of the urethra, and acting suddenly will propel the semen, or the last drops of urine from the canal. The posterior and middle fibres, according to Krause,* contribute towards the erection of the corpus spongiosum, by producing compression upon the venous structure of the bulb; and the anterior fibres, according to Tyrrell,† assist in the erection of the entire organ by compressing the venâ dorsalis, by means of their insertion into the fascia penis. The erector penis becomes entitled

* Müller, Archiv für Anatomie, Physiologie, &c. 1837.

† Lectures in the College of Surgeons. 1839.

to its name from spreading out upon the dorsum of the organ, into a membranous expansion (*fascia penis*), which, according to Krause, compresses the dorsal vein during the action of the muscle, and especially after the erection of the organ has commenced. The transverse muscles serve to steady the tendinous centre, that the muscles attached to it may obtain a firm point of support. According to Cruveilhier, they draw the anus backwards during the expulsion of the *fæces*, and antagonize the *levator ani* which carry the anus forwards. The compressor urethræ, taking its fixed point from the ramus of the ischium at each side, can, says Mr. Guthrie, "compress the urethra so as to close it; I conceive, completely after the manner of a sphincter." The transverse portion will also have a tendency to draw the urethra downwards; whilst the perpendicular portion will draw it upwards towards the *os pubis*. The inferior fasciculus of the transverse muscle, enclosing Cowper's glands, will assist those bodies in evacuating their secretion. The *external sphincter* being a cutaneous muscle contracts the integument around the anus, and by its attachments to the tendinous centre, and to the point of the *coccyx*, assists the *levator ani* in giving support to the opening during expulsive efforts. The *internal sphincter* contracts the extremity of the cylinder of the intestine. The use of the *levator ani* is expressed in its name. It is the antagonist of the diaphragm and the rest of the expulsive muscles, and serves to support the rectum and vagina during their expulsive efforts. The *levator ani* acts in unison with the diaphragm, and rises and falls like that muscle in forcible respiration. Yielding to the propulsive action of the abdominal muscles, it enables the outlet of the pelvis to bear a greater force than a resisting structure, and on the remission of such actions it restores the perineum to its original form. The *coccygei* muscles restore the *coccyx* to its natural position, after it has been pressed backwards during defæcation or during parturition.

MUSCLES OF THE UPPER EXTREMITY.

The muscles of the upper extremity may be arranged into groups corresponding with the different regions of the limb thus:

Anterior thoracic region.

Pectoralis major,
Pectoralis minor,
Subclavius.

Lateral thoracic region.

Serratus magnus.

Anterior scapular region.

Subscapularis.

Posterior scapular region.

Supra-spinatus,
Infra-spinatus,
Teres minor,
Teres major,

Acromial region.

Deltoid.

Anterior humeral region.

Coraco-brachialis,
Biceps,
Brachialis anticus.

Posterior humeral region.

Triceps.

*Anterior brachial region.**Superficial layer.*

Pronator radii teres,
Flexor carpi radialis,
Palmaris longus,
Flexor sublimis digitorum,
Flexor carpi ulnaris.

*Posterior brachial region.**Superficial layer.*

Supinator longus,
Extensor carpi radialis longior,
Extensor carpi radialis brevior,
Extensor communis digitorum,
Extensor minimi digiti,
Extensor carpi ulnaris,
Anconeus.

Deep layer.

Flexor profundus digitorum,
Flexor longus pollicis,
Pronator quadratus.

Deep layer.

Supinator brevis,
Extensor ossis metacarpi pollicis,
Extensor primi internodii pollicis,
Extensor secundi internodii pollicis,
Extensor indicis.

H A N D.

Radial region.

Abductor pollicis,
Flexor ossis metacarpi (opponens),
Flexor brevis pollicis,
Abductor pollicis.

Ulnar region.

Palmaris brevis,
Abductor minimi digiti,
Flexor brevis minimi digiti,
Adductor minimi digiti.

Palmar region.

Lumbricales,
Interossei palmares,
Interossei dorsales.

Anterior thoracic region.

Pectoralis major,
Pectoralis minor,
Subclavius.

Dissection.—Make an incision along the line of the clavicle, from the upper part of the sternum to the acromion process; a second along the lower border of the great pectoral muscle, from the lower end of the sternum to the insertion of its tendon into the humerus; and connect the two by a third, carried longitudinally along the middle of the sternum. The integument and superficial fascia are to be dissected together from off the fibres of the muscle, and always

in the direction of their course. For this purpose the dissector, if he have the right arm, will commence with the lower angle of the flap; if the left, with the upper angle. He will thus expose the pectoralis major muscle in its whole extent.

The *Pectoralis major* muscle arises from the sternal two-thirds of the clavicle, from one half the breadth of the sternum its whole length, and from the cartilages of all the true ribs, excepting the first. It is inserted by a broad tendon into the anterior bicipital ridge of the humerus.

That portion of the muscle which arises from the clavicle, is separated from that connected with the sternum by a distinct cellular interspace; hence we speak of the *clavicular* portion and *sternal* portion of the pectoralis major. The fibres from this very extensive origin converge towards a narrow insertion, giving the muscle a radiated appearance. But there is a peculiarity about the formation of its tendon which must be carefully noted. The whole of the lower border is folded inwards upon the upper portion, so that the tendon is doubled upon itself. Another peculiarity results from this arrangement: the fibres of the upper portion of the muscle are inserted into the lower part of the ridge; and those of the lower portion, into the upper part.

Relations.—By its *external surface* with the fibres of origin of the platysma myoides, the mammary gland, the superficial fascia and integument. By its *internal surface*, on the thorax, with the clavicle, the sternum, the costal cartilages, intercostal muscles, subclavius, pectoralis minor, and serratus magnus; in the axilla, with the axillary vessels and glands. By its *external border* with the deltoid, from which it is separated by a cellular interspace lodging the cephalic vein and the descending branch of the thoracico-acromialis artery. Its *lower border* forms the anterior boundary of the axillary space.

The pectoralis major is now to be removed by dividing its fibres along the lower border of the clavicle, and then carrying the incision perpendicularly downwards, parallel to the sternum, and at about three inches from its border. Divide some loose cellular tissue, and several small branches of the thoracic arteries, and reflect the muscle outwards. We thus bring into view a region of considerable interest, in the middle of which is situated the pectoralis minor.

The *Pectoralis minor* arises by three digitations from the third, fourth, and fifth ribs, and is inserted into the anterior border of the coracoid process of the scapula by a broad tendon.

Relations.—By its *anterior surface* with the pectoralis major and superior thoracic vessels and nerves. By its *posterior surface* with the ribs, the intercostal muscles, serratus magnus, axillary space, and axillary vessels and nerves. Its *upper border* forms the lower boundary of a triangular space bounded above by the costo-coracoid membrane, and internally by the ribs. In this space are found the axillary vessels and nerves, and in it the subclavian artery is tied below the clavicle.

The *Subclavius* muscle *arises* by a round tendon from the cartilage of the first rib, and is *inserted* into the under surface of the clavicle. This muscle is concealed by the costo-coracoid membrane, an extension of the deep cervical fascia, by which it is invested.

Relations.—By its *upper surface* with the clavicle. By the *lower* with the subclavian artery and vein, and brachial plexus, which separate it from the first rib. In *front* with the pectoralis major, the costo-coracoid membrane being interposed.

Actions.—The pectoralis major draws the arm against the thorax, while its upper fibres assist the upper part of the trapezius in raising the shoulder, as in supporting weights. The lower fibres depress the shoulder with the aid of the latissimus dorsi. Taking its fixed point from the shoulder, the pectoralis major assists the pectoralis minor, subclavius, and serratus magnus, in drawing up and expanding the chest. The pectoralis minor, in addition to this action, draws upon the coracoid process, and assists in rotating the scapula upon the chest. The subclavius draws the clavicle downwards and forwards, and thereby assists in steadying the shoulder. All the muscles of this group are agents in forced respiration, but are unable to act until the shoulders be fixed.

Lateral thoracic region.

Serratus magnus.

The *Serratus magnus* (serratus, indented like the edge of a saw,) *arises* by fleshy serrations from the nine upper ribs excepting the first, and extends backwards upon the side of the chest, to be *inserted* into the whole length of the base of the scapula. It indigitates by means of its five lower serrations with the obliquus externus abdominis.

Relations.—By its *superficial surface* with the pectoralis major and minor, the subscapularis, and the axillary vessels and nerves. By its *deep surface* with the ribs and intercostal muscles, to which it is connected by an extremely loose cellular tissue.

Actions.—The serratus magnus is the great external inspiratory muscle, raising the ribs when the shoulders are fixed, and thereby increasing the cavity of the chest. Acting upon the scapula, it draws the shoulder forwards, as we see to be the case in diseased lungs, where the chest has become almost fixed from apprehension of the expanding action of the respiratory muscles.

Anterior scapular region.

Subscapularis.

The *Subscapularis* muscle *arises* from the whole of the under surface of the scapula excepting the superior angle, and terminates by a broad and thick tendon, which is *inserted* into the lesser tube-

rosity of the humerus. The tendon of this muscle forms a part of the capsule of the joint, glides over a large bursa which separates it from the base of the coracoid process, and is lined by a prolongation of the synovial membrane of the articulation.

Relations.—By its anterior surface with the serratus magnus, the coraco-brachialis, deltoid, and with the axillary vessels and nerves. By its *posterior surface* with the scapula, the subscapular vessels and nerves, and the shoulder joint.

Actions.—It rotates the head of the humerus inwards, and is a powerful defence to the joint. When the arm is raised, it draws the humerus downwards.

Posterior scapular region.

Supra-spinatus,	Teres minor,
Infra-spinatus,	Teres major.

The *Supra-spinatus* muscle, (*supra*, above; *spina*, the spine) *arises* from the whole of the supra-spinous fossa, and is *inserted* into the uppermost depression on the great tuberosity of the humerus. The tendon of this muscle cannot be well seen without cutting away the acromion process with a saw.

Relations.—By its upper surface with the trapezius, the clavicle, acromion, and coraco-acromial ligament. From the trapezius it is separated by a strong fascia. By its *lower surface* with the supra-spinous fossa, the supra-scapular vessels and nerve, and the upper part of the shoulder joint, forming part of the capsular ligament.

The *Infra-spinatus* (*infra*, beneath; *spina*, the spine,) is covered in by a layer of tendinous fascia, which must be removed before the fibres of the muscle can be seen, the deltoid muscle having been previously turned down from its scapular origin. It *arises* from the whole of the infra-spinous fossa, and from the fascia above-mentioned, and is *inserted* into the middle depression upon the greater tuberosity of the humerus.

Relations.—By its *posterior surface* with the deltoid, latissimus dorsi and integument. By its *anterior surface* with the infra-spinous fossa, superior and dorsal scapular vessels, and shoulder joint; its tendon being lined by a prolongation from the synovial membrane. By its *upper border* it is in relation with the spine of the scapula, and by the *lower* with the *teres minor*, with which it is closely united.

The *Teres minor* muscle (*teres*, round) *arises* from the middle third of the inferior border of the scapula, and is *inserted* into the lower depression on the great tuberosity of the humerus. The tendons of these three muscles, with that of the subscapularis, are in immediate contact with the joint, and form part of its ligamentous capsule, thereby preserving the solidity of the articulation. They are therefore the structures most frequently ruptured in dislocation of the shoulder joint with violence.

Relations.—By its *posterior surface* with the deltoid, latissimus dorsi and integument. By its *anterior surface* with the inferior bor-

der and part of the dorsum of the scapula, the dorsalis scapulæ vessels, scapular head of the triceps, and shoulder joint. By its *upper border* with the infra-spinatus; and by the *lower* with the latissimus dorsi, teres major, and long head of the triceps.

The *Teres major* muscle arises from the lower third of the inferior border of the scapula, encroaching a little upon its dorsal aspect, and is inserted into the posterior bicipital ridge. Its tendon lies immediately behind that of the latissimus dorsi, from which it is separated by a synovial membrane.

Relations.—By its *posterior surface* with the latissimus dorsi, scapular head of the triceps and integument. By its *anterior surface* with the subscapularis, latissimus dorsi, coraco-brachialis, short head of the biceps, axillary vessels, and branches of the brachial plexus. By its *upper border* it is in relation with teres minor, from which it is separated by the scapular head of the triceps, and by the *lower* it forms with the latissimus dorsi the lower and posterior border of the axilla.

A large triangular space exists between the two teres muscles, which is divided into two minor spaces by the long head of the triceps.

Actions.—The supra-spinatus raises the arm from the side; but only feebly, from the disadvantageous direction of its force. The infra-spinatus and teres minor are rotators of the head of the humerus outwards. The most important use of these three muscles is the protection of the joint, and defence against displacement of the head of the humerus, in which action they co-operate with the subscapularis. The teres major combines, with the latissimus dorsi, in rotating the arm inwards, and at the same time carrying it towards the side, and somewhat backwards.

Acromial region.

Deltoid.

The convexity of the shoulder is formed by a large triangular muscle, the *deltoid* (Δ , delta; εἶδος, resemblance), which arises from the outer third of the clavicle, from the acromion process, and from the whole length of the spine of the scapula. The fibres from this broad origin converge to the middle of the outer side of the humerus, where they are inserted into a rough triangular elevation. This muscle is remarkable for its coarse texture, and the combination of tendinous and muscular fibres. The deltoid muscle may now be cut away from its origin, and turned down, for the purpose of bringing into view the muscles and tendons placed immediately around the shoulder joint. In so doing, a large bursa will be seen between the under surface of the muscle and the head of the humerus.

Relations.—By its *superficial surface* with a thin aponeurotic fascia, a few fibres of the platysma myoides, the superficial fascia and integument. By its *deep surface* with the shoulder joint, from which it is separated by a thin tendinous fascia, and by a synovial bursa; with the coraco-acromial ligament, coracoid process, pectoralis minor, coraco-brachialis, both heads of the biceps, tendon of

the pectoralis major, tendon of the supra-spinatus, infra-spinatus, teres minor, teres major, scapular and external head of the triceps, the circumflex vessels anterior and posterior, and humerus. By its *anterior border* with the external border of the pectoralis major, from which it is separated by a cellular interspace, lodging the cephalic vein and descending branch of the thoracico-acromialis artery. Its *posterior border* is thin above, where it is connected with the aponeurotic covering of the infra-spinatus muscle, and thick below.

Actions.—The deltoid is the elevator muscle of the arm in a direct line, and by means of its extensive origin can carry the arm forwards or backwards so as to range with the hand a considerable segment of a large circle. The arm, raised by the deltoid, is a good illustration of a lever of the third power, so common in the animal machine, by which velocity is gained at the expense of power. In this lever, the weight (hand) is at one extremity, the fulcrum (the glenoid cavity) at the opposite end, and the power (the insertion of the muscle) between the two, but nearer to the fulcrum than to the weight.

Anterior humeral region.

Coraco-brachialis,
Biceps,
Brachialis anticus.

Dissection.—These muscles are exposed, on the removal of the integument and fascia from the anterior half of the upper arm, and clearing away the cellular tissue.

The *Coraco-brachialis*, a name composed of its points of origin and insertion, *arises* from the coracoid process in common with the short head of the biceps; and is *inserted* into a rough line on the inner side of the middle of the humerus.

Relations.—By its *anterior surface* with the deltoid, and pectoralis major. By its *posterior surface* with the shoulder joint, the humerus, subscapularis, teres major, latissimus dorsi, short head of the triceps, and anterior circumflex vessels. By its *internal border* with the axillary and brachial vessels and nerves, particularly with the median and external cutaneous nerve, by the latter of which it is pierced. By the *external border* with the short head of the biceps and brachial anticus.

The *Biceps* (*bis*—*κεφαλαί*, two heads) *arises*

Fig. 92.

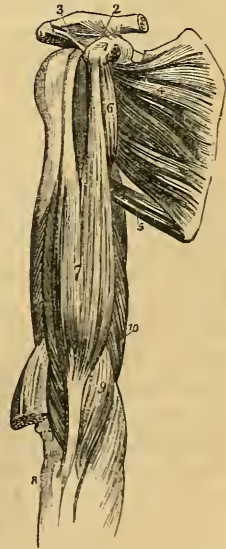

Fig. 92. The muscles of the anterior aspect of the upper arm. 1. The coracoid process of the scapula. 2. The coraco-clavicular ligament (trapezoid), passing upwards to the scapular end of the clavicle. 3. The coraco-acromial ligament, passing outwards to the acromion. 4. The subscapularis muscle. 5. The teres major. 6. The coraco-brachialis. 7. The biceps. 8. The upper end of the radius. 9. The brachialis anticus. 10. The internal head of the triceps.

by two tendons, one the *short head*, from the coracoid process in common with the coraco-brachialis; the other the *long head*, from the upper part of the glenoid cavity. The muscle is *inserted* by a rounded tendon, into the tubercle of the radius. The long head, a long slender tendon, passes through the capsular ligament of the shoulder joint enclosed in a sheath of the synovial membrane; after leaving the cavity of the joint, it is lodged in the deep groove that separates the two tuberosities of the humerus, the bicipital groove. A small synovial bursa is interposed between the tendon of insertion, and the tubercle of the radius. *At the bend of the elbow*, the tendon of the biceps gives off from its inner side a broad tendinous band, which protects the brachial artery, and is continuous with the fascia of the fore-arm.

Relations.—By its *anterior surface* with the deltoid, pectoralis major, superficial and deep fascia and integument. By its *posterior surface* the short head rests upon the subscapularis, from which it is separated by a bursa. In the rest of its extent the muscle is in relation with the humerus, the teres major, latissimus dorsi, and brachialis anticus, from which it is separated by the external cutaneous nerve. By its *inner border* with the coraco-brachialis, brachial artery and veins, and median nerve; the brachial vessels crossing its tendon at the bend of the elbow. By its *outer border* with the deltoid and supinator longus.

The *Brachialis anticus* is a broad muscle, covering the whole of the anterior surface of the lower part of the humerus; it *arises* by two fleshy serrations from the depression on either side of the insertion of the deltoid, and from the anterior surface of the humerus. Its fibres converge to be *inserted* into the coracoid process of the ulna.

Relations.—By its *anterior surface* with the biceps, external cutaneous nerve, brachial artery and veins, and median nerve. By its *posterior surface* with the humerus, and anterior ligament of the elbow joint. By its *external border* with the supinator longus, extensor carpi radialis longior, musculo-spiral nerve, and recurrent radial artery. By its *internal border* with the intermuscular aponeurosis, which separates it from the triceps and ulnar nerve, and with the pronator radii teres.

Actions.—The coraco-brachialis draws the humerus inwards, and assists in flexing it upon the scapula. The biceps and brachialis anticus are flexors of the fore-arm, and the former a supinator. The brachialis anticus is a powerful protection to the elbow-joint.

Posterior humeral region.

Triceps extensor cubiti.

Dissection.—Remove the integument and fascia from the posterior aspect of the upper arm.

The *Triceps* (τρεις κεφαλαι, three heads,) *arises* by three heads.

Considered in relation to their length, these heads have been named long, short, and middle; and in reference to their position, internal, external and middle; the term middle, in the former case, referring to the external head, and in the latter case to the long head. This has given rise to much confusion and misunderstanding. I shall, therefore, confine myself to the designations derived from their relations. The external head *arises* from the humerus immediately below the insertion of the *teres minor*. The internal head (short) *arises* from the humerus immediately below the insertion of the *teres major*. The scapular head (long) lies between the two others, and *arises* from the upper third of the inferior border of the scapula. The three heads unite to form a broad muscle, which is *inserted* by an aponeurotic tendon into the olecranon process of the ulna; a small bursa is situated between its tendon and the upper part of the olecranon.

The scapular head of the triceps passes between the *teres minor* and *major*, and divides the triangular space between those two muscles into two smaller spaces, one of which is triangular, the other quadrangular. The *triangular space* is bounded by the *teres minor*, *teres major*, and scapular head of the triceps; it gives passage to the *dorsalis scapulæ* artery and veins. The *quadrangular space* is bounded on three sides by the three preceding muscles, and on the fourth by the humerus. Through this space pass the posterior circumflex artery and veins, and circumflex nerve.

Relations.—By its *posterior surface* with the deep and superficial fascia and integument. By its *anterior surface* with the superior profunda artery, musculo-spiral nerve, humerus, intermuscular aponeurosis, which separates it from the *brachialis anticus*, and with the elbow joint. The *scapular head* is in relation posteriorly with the *deltoid* and *teres minor*; anteriorly with the *subscapularis*, *teres major*, and *latissimus dorsi*; and externally with the posterior circumflex vessels and nerve.

Actions.—The triceps is an extensor of the fore-arm.

Fig. 93.

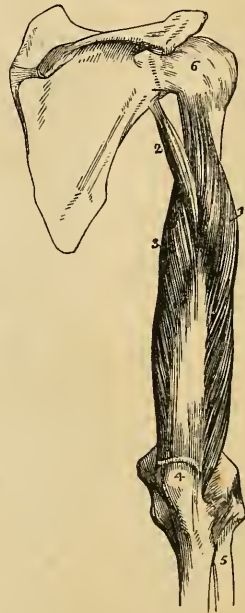

Fig. 93. A posterior view of the upper arm, showing the triceps muscle. 1. Its external head. 2. Its long, or scapular head. 3. Its internal, or short head. 4. The olecranon process of the ulna. 5. The radius. 6. The capsular ligament of the shoulder-joint.

*Anterior brachial region.**Superficial layer.*

Pronator radii teres,
 Flexor carpi radialis,
 Palmaris longus,
 Flexor sublimis digitorum,
 Flexor carpi ulnaris.

Dissection.—These muscles are seen by making an incision through the integument along the middle line of the fore-arm, crossing each extremity by a transverse incision, and turning aside the flaps. The superficial and deep fascia are then to be removed.

The *Pronator radii teres* arises by two heads; one from the inner condyle of the humerus, fascia of the fore-arm and intermuscular aponeurosis; the other, from the coronoid process of the ulna; the median nerve passing between them. Its tendon is *inserted* into the middle third of the oblique ridge of the radius. The two heads of this muscle are best seen by cutting away that which arises from the inner condyle, and turning it aside. The second head will then be seen with the median nerve lying across it.

Relations.—By its *anterior surface* with the fascia of the fore-arm, the supinator longus, extensor carpi radialis longior and brevior, radial artery and veins, and radial nerve. By its *posterior surface* with the brachialis anticus, flexor sublimis digitorum, the ulnar artery and veins, and the median nerve after it has passed between the two heads of the muscle. By its *upper border* it forms the inner boundary of the triangular space, in which the termination of the brachial artery is situated. By its *lower border* it is in relation with the flexor carpi radialis.

The *Flexor carpi radialis* arises from the inner condyle and the sheath of fascia which surrounds it. Its tendon passes through a groove formed by the scaphoid bone and trapezium, to be *inserted* into the base of the metacarpal bone of the index finger.

Relations.—By its *anterior surface* with the fascia of the fore-arm, and at the wrist with the tendinous canal through which its tendon passes. By its *posterior surface* with the flexor sublimis digitorum, flexor longus pollicis, wrist-joint, and groove in the scaphoid and trapezium bones. By its *outer border* with the pronator radii teres, and radial artery and veins. By its *inner border* with the palmaris longus. The tendon is surrounded by a synovial membrane where it plays through the tendinous canal of the wrist.

The *Palmaris longus* muscle arises from the inner condyle, and from the sheath of fascia which surrounds it. It is *inserted* into the palmar fascia. Occasionally this muscle is wanting.

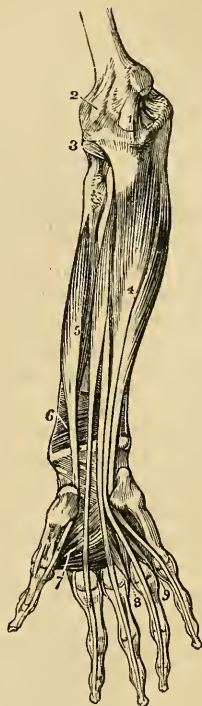
Relations.—By its *anterior surface* with the fascia of the fore-arm. By the *posterior surface* with the flexor sublimis digitorum; to the *external side* by the flexor carpi radialis; and to the *internal side* by the flexor carpi ulnaris.

Cut the flexor carpi radialis and palmaris longus from their origins, in order to obtain a good view of the whole extent of origin of the flexor sublimis digitorum.

Fig. 94.

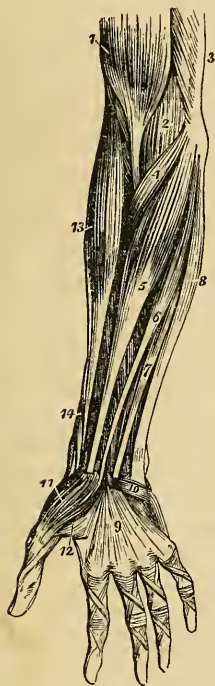

Fig. 95.



The *Flexor sublimis digitorum* (perforatus) arises from the inner condyle, coronoid process of the ulna, and oblique line of the radius.

Fig. 94. Superficial layer of muscles of the fore-arm. 1. The lower part of the biceps, with its tendon. 2. A part of the brachialis anticus seen beneath the biceps. 3. A part of the triceps. 4. The pronator radii teres. 5. The flexor carpi radialis. 6. The palmaris longus. 7. One of the fasciculi of the flexor sublimis digitorum; the rest of the muscle is seen beneath the tendons of the palmaris longus and flexor carpi radialis. 8. The flexor carpi ulnaris. 9. The palmar fascia. 10. The palmaris brevis muscle. 11. The abductor pollicis muscle. 12. One portion of the flexor brevis pollicis; the leading line crosses a part of the adductor pollicis. 13. The supinator longus muscle. 14. The extensor ossis metacarpi, and extensor primi internodii pollicis, curving around the lower border of the fore-arm.

Fig. 95. The deep layer of muscles of the fore-arm. 1. The internal lateral ligament of the elbow-joint. 2. The anterior ligament. 3. The orbicular ligament of the head of the radius. 4. The flexor profundus digitorum muscle. 5. The flexor longus pollicis. 6. The pronator quadratus. 7. The adductor pollicis muscle. 8. The dorsal interosseous muscle of the middle finger, and palmar interosseous of the ring-finger. 9. The dorsal interosseous muscle of the ring-finger, and palmar interosseous of the little finger.

The median nerve and ulnar artery pass between its origins. It divides into four tendons, which pass beneath the annular ligament into the palm of the hand, and are *inserted* into the base of the second phalanges of the fingers, splitting at their terminations to give passage to the tendons of the deep flexors; thence its designation *perforatus*.

Relations.—In the fore-arm. By its *anterior surface* with the pronator radii teres, flexor carpi radialis, palmaris longus, flexor carpi ulnaris, and the deep fascia of the fore-arm. By its *posterior surface* with the flexor profundus digitorum, flexor longus pollicis, ulnar artery, veins and nerve, and median nerve. This muscle usually sends a fasciculus to the flexor longus pollicis. In the hand: its tendons, after passing beneath the annular ligament, are in relation *superficially* with the superficial palmar arch, and palmar fascia; and *deeply* with the tendons of the deep flexor and lumbricales.

The *Flexor carpi ulnaris* arises by two heads, one from the inner condyle, the other from the olecranon and upper two-thirds of the inner border of the ulna. Its tendon is *inserted* into the pisiform bone, and base of the metacarpal bone of the little finger.

Relations.—By its *anterior surface* with the fascia of the fore-arm, with which it is closely united superiorly. By its *posterior surface* with the flexor sublimis digitorum, flexor profundus, pronator quadratus, and ulnar artery, veins, and nerve. By its *radial border* with the palmaris longus, and in the lower third of the fore-arm with the ulnar vessels and nerve. The ulnar nerve, and the posterior ulnar recurrent artery, pass between its two heads of origin.

Deep layer.

Flexor profundus digitorum,
Flexor longus pollicis,
Pronator quadratus.

Dissection.—This group is brought into view by removing the flexor sublimis, and drawing aside the pronator radii teres.

Flexor profundus digitorum (perforans) arises from the upper two-thirds of the ulna and part of the interosseous membrane, and terminates in four tendons, which pass beneath the annular ligament, and between the two slips of the tendons of the flexor sublimis (hence its designation, perforans), to be *inserted* into the base of the last phalanges. The tendon of the index finger is always distinct from the rest, the other three tendons being more or less intimately connected by cellular tissue and tendinous slips.

Four little muscular fasciculi, called *lumbricales*, are connected with the tendons of this muscle in the palm. They will be described with the muscles of the hand.

Relations.—In the fore-arm. By its *anterior surface* with the flexor sublimis digitorum, flexor carpi ulnaris, median nerve, and ulnar artery, veins, and nerve. By its *posterior surface* with the ulna, the interosseous membrane, the pronator quadratus, and the

wrist joint. By its *radial border* with the flexor longus pollicis, the anterior interosseous artery and nerve being interposed. By its *ulnar border* with the flexor carpi ulnaris. In the hand: its tendons are in relation *superficially* with the tendons of the superficial flexor; and *deeply* with the interossei muscles, adductor pollicis, and deep palmar arch. In the fingers: the tendons of the deep flexor are interposed between the tendons of the superficial flexor and the phalanges.

The *Flexor longus pollicis* arises from the upper two-thirds of the radius, and part of the interosseous membrane. Its tendon passes beneath the annular ligament, to be *inserted* into the base of the last phalanx of the thumb.

Relations.—By its *anterior surface* with the flexor sublimis digitorum, flexor carpi radialis, supinator longus, and radial artery and veins. By its *posterior surface* with the radius, interosseous membrane, pronator quadratus and wrist joint. By its *ulnar border* it is separated from the flexor profundus digitorum by the anterior interosseous artery and nerve. In the hand: after passing beneath the annular ligament, it is lodged in the interspace between the two portions of the flexor brevis pollicis, and afterwards in the tendinous theca of the phalanges.

If the tendons of the two last muscles be drawn aside or divided, the third muscle of this group will be brought into view, lying across the lower part of the two bones.

The *Pronator quadratus* arises from the ulna, and is *inserted* into the lower fourth of the oblique line, on the outer side of the radius. This muscle occupies about the lower fourth of the two bones, is broad at its origin, and narrower at its insertion.

Relations.—By its *anterior surface* with the tendons of the supinator longus, flexor carpi radialis, flexor longus pollicis, flexor profundus digitorum, and flexor carpi ulnaris, radial artery and veins, and ulnar artery, veins, and nerve. By its *posterior surface* with the radius, ulna, and interosseous membrane.

Actions.—The pronator radii teres and pronator quadratus muscles rotate the radius upon the ulna, and render the hand prone. The remaining muscles are flexors:—two flexors of the wrist, flexor carpi radialis and ulnaris; two of the fingers, flexor sublimis and profundus, the former flexing the second phalanges, the latter the last; one flexor of the last phalanx of the thumb, flexor longus pollicis. The palmaris longus is a tensor of the palmar fascia.

Posterior brachial region.

Superficial layer.

Supinator longus,
 Extensor carpi radialis longior,
 Extensor carpi radialis brevior,
 Extensor communis digitorum,
 Extensor minimi digiti,
 Extensor carpi ulnaris,
 Anconeus.

Dissection.—The integument is to be divided and turned aside, and the fasciæ removed in the same manner as for the anterior brachial region.

The *Supinator longus* muscle is placed along the radial border of the fore-arm. It *arises* from the external condyloid ridge of the humerus, nearly as high as the insertion of the deltoid, and is *inserted* into the base of the styloid process of the radius.

Relations.—By its *superficial surface* with the extensor ossis metacarpi pollicis, extensor primi internodii pollicis, and fascia of the fore-arm. By its *deep surface* with the brachialis anticus, extensor carpi radialis longior, tendon of the biceps, supinator brevis, pronator radii teres, flexor carpi radialis, flexor sublimis digitorum, flexor longus pollicis, pronator quadratus, radius, musculo-spiral nerve, radial and posterior interosseous nerve, and radial artery and veins. This muscle must be divided through the middle, and the two ends turned to either side to expose the next muscle.

The *Extensor carpi radialis longior* *arises* from the external condyloid ridge below the preceding. Its tendon passes through a groove in the radius, immediately behind the styloid process, to be *inserted* into the base of the metacarpal bone of the index finger.

Relations.—By its *superficial surface* with the supinator longus, extensor ossis metacarpi pollicis, extensor primi internodii pollicis, extensor secundi internodii pollicis, radial nerve and fascia of the fore-arm, and posterior annular ligament. By its *deep surface* with the brachialis anticus, extensor carpi radialis brevior, radius and wrist joint.

The *Extensor carpi radialis brevior* is seen by drawing aside the former muscle. It *arises* from the external condyle of the humerus, and is *inserted* into the base of the metacarpal bone of the middle finger. Its tendon is lodged in the same groove on the radius with the extensor carpi radialis longior.

Relations.—By its *superficial surface* with the extensor carpi radialis longior, extensor ossis metacarpi pollicis, extensor primi internodii pollicis, extensor secundi internodii pollicis, fascia of the fore-arm, and posterior annular ligament. By its *deep surface* with the supinator brevis, tendon of the pronator radii teres, radius and wrist joint. By its *ulnar border* with the extensor communis digitorum.

The *Extensor communis digitorum* *arises* from the external condyle, and divides into four tendons, which are *inserted* into the second and third phalanges of the fingers. At the metacarpo-phalangeal articulation each tendon becomes narrow and thick, and sends a thin fasciculus upon each side of the joint. It then spreads out and receiving the tendon of the lumbricalis forms a broad aponeurosis, which covers the whole of the posterior aspect of the finger. At the first phalangeal joint the aponeurosis divides into three slips. The middle slip is inserted into the base of the second phalanx, and the two lateral portions are continued onwards on each side of the joint, to be inserted into the last. Little oblique tendinous slips con-

nect the tendons of the middle, ring, and little finger as they cross the back of the hand.

Fig. 96.

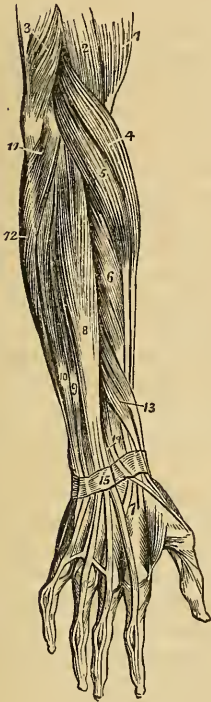
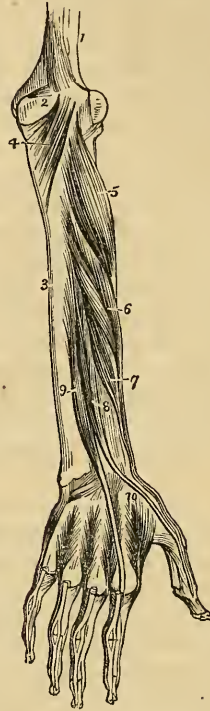


Fig. 97.



Relations.—By its *superficial surface* with the fascia of the forearm and back of the hand, and with the posterior annular ligament. By its *deep surface* with the supinator brevis, extensor ossis meta-

Fig. 96. The superficial layer of muscles of the posterior aspect of the forearm. 1. The lower part of the biceps. 2. Part of the brachialis anticus. 3. The lower part of the triceps, inserted into the olecranon. 4. The supinator longus. 5. The extensor carpi radialis longior. 6. The extensor carpi radialis brevior. 7. The tendons of insertion of these two muscles. 8. The extensor communis digitorum. 9. The extensor minimi digiti. 10. The extensor carpi ulnaris. 11. The anconeus. 12. Part of the flexor carpi ulnaris. 13. The extensor ossis metacarpi and extensor primi internodii muscle, lying together. 14. The extensor secundi internodii; its tendon is seen crossing the two tendons of the extensor carpi radialis longior and brevior. 15. The posterior annular ligament. The tendons of the common extensor are seen upon the back of the hand, and their mode of distribution on the dorsum of the fingers.

Fig. 97. The deep layer of muscles on the posterior aspect of the forearm. 1. The lower part of the humerus. 2. The olecranon. 3. The ulna. 4. The anconeus muscle. 5. The supinator brevis muscle. 6. The extensor ossis metacarpi pollicis. 7. The extensor primi internodii pollicis. 8. The extensor secundi internodii pollicis. 9. The extensor indicis. 10. The first dorsal interosseous muscle. The other three dorsal interossei are seen between the metacarpal bones of their respective fingers.

carpi pollicis, extensor primi internodii, extensor secundi internodii, extensor indicis, posterior interosseous artery and nerve, wrist joint, metacarpal bones and interossei muscles and phalanges. By its *radial border* with the extensor carpi radialis longior and brevior. By the *ulnar border* with the extensor minimi digiti, and extensor carpi ulnaris.

The *Extensor minimi digiti* (auricularis) is an off-set from the extensor communis, with which it is connected by means of a tendinous slip. Passing down to the inferior extremity of the ulna it traverses a distinct fibrous sheath, and at the metacarpo-phalangeal articulation unites with the tendon derived from the long extensor. The common tendon then spreads out into a broad expansion which divides into three slips to be *inserted* as in the other fingers into the two last phalanges. It is to this muscle that the little finger owes its power of separate extension; and from being called into action when the point of the finger is introduced into the meatus of the ear, for the purpose of removing unpleasant sensations, or producing titillation, the muscle was called by the older writers "auricularis."

The *Extensor carpi ulnaris* arises from the external condyle and from the upper two-thirds of the border of the ulna. Its tendon passes through the posterior groove in the lower extremity of the ulna to be *inserted* into the base of the metacarpal bone of the little finger.

Relations.—By its *superficial surface* with the fascia of the forearm, and posterior annular ligament. By its *deep surface* with the supinator brevis, extensor ossis metacarpi pollicis, extensor secundi internodii, extensor indicis, ulna and wrist joint. By its *radial border* it is in relation with the extensor communis digitorum, and extensor minimi digiti, and by the *ulnar border* with the anconeus.

The *Anconeus* appears to be the continuation of the triceps; it arises from the outer condyle, and is *inserted* into the olecranon and triangular surface on the upper extremity of the ulna.

Relations.—By its *superficial surface* with a strong tendinous aponeurosis derived from the triceps. By its *deep surface* with the elbow joint, orbicular ligament, and slightly with the supinator brevis.

Deep layer.

Supinator brevis,
Extensor ossis metacarpi pollicis,
Extensor primi internodii pollicis,
Extensor secundi internodii pollicis,
Extensor indicis.

Dissection.—The muscles of the superficial layer should be removed, in order to bring the deep group completely into view.

The *Supinator brevis* cannot be seen in its entire extent, until the radial extensors of the carpus are divided from their origin. It arises from the external condyle, from the external lateral and orbicular ligament, and from the ulna, and winds around the upper part

of the radius, to be *inserted* into the upper third of its oblique line. The posterior interosseous artery and nerve are seen perforating the lower border of this muscle.

Relations.—By its *superficial surface* with the pronator radii teres, supinator longus, extensor carpi radialis longior and brevior, extensor communis digitorum, extensor carpi ulnaris, anconeus, the radial artery and veins, the musculo-spiral nerve, radial, and posterior interosseous nerve. By its *deep surface* with the elbow joint and its ligaments, the interosseous membrane, and the radius.

The *Extensor ossis metacarpi pollicis* is placed immediately below the supinator brevis. It *arises* from the ulna, interosseous membrane, and radius, and is *inserted*, as its name implies, into the base of the metacarpal bone of the thumb. Its tendon passes through the groove immediately in front of the styloid process of the radius.

Relations.—By its *superficial surface* with the extensor carpi ulnaris, extensor minimi digiti, extensor communis digitorum, fascia of the fore-arm, and annular ligament. By its *deep surface* with the ulna, interosseous membrane, radius, tendons of the extensor carpi radialis longior and brevior, and supinator longus, and at the wrist with the radial artery. By its *upper border* with the edge of the supinator brevis. By its *lower border* with the extensor secundi and primi internodii. The muscle is crossed by branches of the posterior interosseous artery and nerve.

The *Extensor primi internodii pollicis*, the smallest of the muscles in this layer, *arises* from the interosseous membrane and radius, and passes through the same groove with the extensor ossis metacarpi, to be *inserted* into the base of the first phalanx of the thumb.

Relations.—The same as those of the preceding muscle with the exception of the extensor carpi ulnaris. The muscle accompanies the extensor ossis metacarpi.

The *Extensor secundi internodii pollicis* *arises* from the ulna and interosseous membrane. Its tendon passes through a distinct canal in the annular ligament, and is *inserted* into the base of the last phalanx of the thumb.

Relations.—By its *external surface* with the same relations as the extensor ossis metacarpi. By its *deep surface* with the ulna, interosseous membrane, radius, wrist joint, radial artery, and metacarpal bone of the thumb. The muscle is placed between the extensor primi internodii and extensor indicis.

The *Extensor indicis* *arises* from the ulna as high up as the extensor ossis metacarpi pollicis, and from the interosseous membrane. Its tendon passes through a distinct groove in the radius, and is *inserted* into the aponeurosis formed by the common extensor tendon of the index finger.

Relations.—The same as those of the preceding muscle, with the exception of the hand, where the tendon rests upon the metacarpal bone of the fore-finger and interosseous muscle, and has no relation with the radial artery.

The tendons of the extensors, as of the flexor muscles of the

fore-arm, are provided with synovial bursæ as they pass beneath the annular ligaments: those of the back of the wrist have distinct sheaths, formed by the posterior annular ligament.

Actions.—The anconeus is associated in its action with the triceps extensor cubiti: it assists in extending the fore-arm upon the arm. The supinator longus and brevis effect the supination of the fore-arm, and antagonize the two pronators. The extensor carpi radialis longior and brevior, and ulnaris, extend the wrist in opposition to the two flexors of the carpus. The extensor communis digitorum restores the fingers to the straight position, after being flexed by the two flexors, sublimis and profundus. The extensor ossis metacarpi, primi internodii, and secundi internodii pollicis, are the especial extensors of the thumb, and serve to balance the actions of the flexor ossis metacarpi, flexor brevis, and flexor longus pollicis. The extensor indicis gives the character of extension to the index finger, and is hence named “indicator,” and the extensor minimi digiti supplies that finger with the power of exercising a distinct extension.

MUSCLES OF THE HAND.

Radial region.

Abductor pollicis,
Flexor ossis metacarpi (opponens),
Flexor brevis pollicis,
Adductor pollicis.

Dissection.—The hand is best dissected by making an incision along the middle of the palm, from the wrist to the base of the fingers, and crossing it at each extremity by a transverse incision, then turning aside the flaps of integument. For exposing the muscles of the radial region, the removal of the integument and fascia on the radial side will be sufficient.

The *Abductor pollicis* arises from the scaphoid bone and annular ligament. It is inserted into the base of the first phalanx.

Relations.—By its *superficial surface* with the external portion of the palmar fascia. By its *deep surface* with the flexor ossis metacarpi. On its *inner side* it is separated by a narrow cellular interspace from the flexor brevis pollicis.

This muscle must be divided from its origin and turned upwards, in order to see the next.

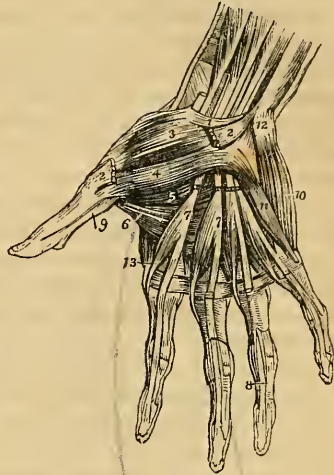
The *Flexor ossis metacarpi* (opponens), arises from the trapezium and annular ligament, and is inserted into the whole length of the metacarpal bone.

Relations.—By its *superficial surface* with the abductor pollicis. By its *deep surface* with the trapezio-metacarpal articulation and with the metacarpal bone. *Internally*, with the flexor brevis pollicis.

The flexor ossis metacarpi may now be divided from its origin and turned aside, in order to show the next muscle.

The *Flexor brevis pollicis* consists of two portions, between which lies the tendon of the flexor longus pollicis. The external portion *arises* from the trapezium and annular ligament; the internal portion from the trapezoides and os magnum. They are both *inserted* into the base of the first phalanx of the thumb, having a sesamoid bone in each of their tendons to protect the joint.

Fig. 98.



Relations.—By its *superficial surface* with the external portion of the palmar fascia. By its *deep surface* with the adductor pollicis, tendon of the flexor carpi radialis, and trapezio-metacarpal articulation. By its *external surface* with the flexor ossis metacarpi and metacarpal bone. By its *inner surface* with the tendons of the long flexor muscles and first lumbricalis.

The *Adductor pollicis* is a triangular muscle; it *arises* from the whole length of the metacarpal bone of the middle finger; the fibres converge to its *insertion* into the base of the first phalanx.

Relations.—By its *anterior surface* with the flexor brevis pollicis, tendons of the deep flexor of the fingers, lumbricales, and deep palmar arch. By its *posterior surface* with the metacarpal bones of the index and middle fingers, the interossei of the second interosseous space, and the abductor indicis.

Ulnar region.

Palmaris brevis,
Abductor minimi digiti,
Flexor brevis minimi digiti,
Flexor ossis metacarpi (adductor).

Dissection.—Turn aside the ulnar flap of integument in the palm

Fig. 98. The muscles of the hand. 1. The annular ligament. 2, 2. The origin and insertion of the abductor pollicis muscle; the middle portion has been removed. 3. The flexor ossis metacarpi, or opponens pollicis. 4. One portion of the flexor brevis pollicis. 5. The deep portion of the flexor brevis pollicis. 6. The adductor pollicis. 7, 7. The lumbricales muscles, arising from the deep flexor tendons, upon which the numbers are placed. The tendons of the flexor sublimis have been removed from the palm of the hand. 8. One of the tendons of the deep flexor, passing between the two terminal slips of the tendon of the flexor sublimis to reach the last phalanx. 9. The tendon of the flexor longus pollicis, passing between the two portions of the flexor brevis to the last phalanx. 10. The abductor minimi digiti. 11. The flexor brevis minimi digiti. The edge of the flexor ossis metacarpi, or adductor minimi digiti, is seen projecting beyond the inner border of the flexor brevis. 12. The prominence of the pisiform bone. 13. The first dorsal interosseous muscle.

of the hand; in doing this, a small subcutaneous muscle, the palmaris brevis, will be exposed. After examining this muscle, remove it with the deep fascia, in order to bring into view the muscles of the little finger.

The *Palmaris brevis* arises from the palmar fascia, and passes transversely inwards, to be inserted into the integument on the inner border of the hand.

Relations.—By its *superficial surface* with the fat and integument of the ball of the little finger. By its *deep surface* with the internal portion of the palmar fascia, which separates it from the ulnar artery, veins, and nerve, and from the muscles of the inner border of the hand.

The *Abductor minimi digiti* arises from the pisiform bone, and is inserted into the base of the first phalanx of the little finger.

Relations.—By its *superficial surface* with the internal portion of the deep fascia and the palmaris brevis; by its *deep surface* with the flexor ossis metacarpi and metacarpal bone. By its *inner border* with the flexor brevis minimi digiti.

The *Flexor brevis minimi digiti* arises from the unciform bone and annular ligament, and is inserted into the base of the first phalanx. It is sometimes wanting.

Relations.—By its *superficial surface* with the internal portion of the palmar fascia, and the palmaris brevis. By its *deep surface* with the flexor ossis metacarpi, and metacarpal bone. *Externally* with the abductor minimi digiti, from which it is separated near its origin by the deep palmar branch of the ulnar nerve and communicating artery. *Internally* with the tendons of the flexor sublimis and profundus.

The *Flexor ossis metacarpi* (adductor, opponens) arises from the unciform bone and annular ligament, and is inserted into the whole length of the metacarpal bone of the little finger.

Relations.—By its *superficial surface* with the flexor brevis and abductor minimi digiti. By its *deep surface* with the interossei muscles of the last metacarpal space, the metacarpal bone, and the flexor tendons of the little finger.

Palmar region.

Lumbricales,
Interossei palmares,
Interossei dorsales.

The *Lumbricales*, four in number, are accessories to the deep flexor muscle. They arise from the tendons of the deep flexor; the first and second from the palmar side, the third from the ulnar, and the fourth from the radial side; and are inserted into the aponeurotic expansion of the extensor tendons on the radial side of the fingers. The third, or that of the tendon of the ring finger, sometimes bifurcates, or is inserted wholly into the extensor tendon of the middle finger.

Relations.—In the palm of the hand with the flexor tendons; at their insertion with the tendons of the interossei and metacarpophalangeal articulations.

The *palmar interossei*, three in number, are placed upon the metacarpal bones, rather than between them. They *arise* from the base of the metacarpal bone of one finger, and are *inserted* into the base of the first phalanx and aponeurotic expansion of the extensor tendon of the same finger. The first belongs to the index finger; the second, to the ring finger; and the third, to the little finger; the middle finger being excluded.

Fig. 99.

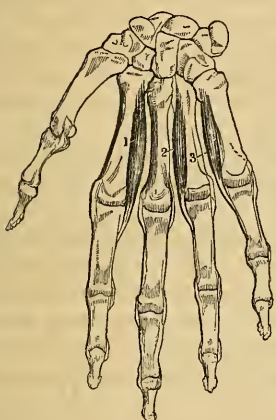
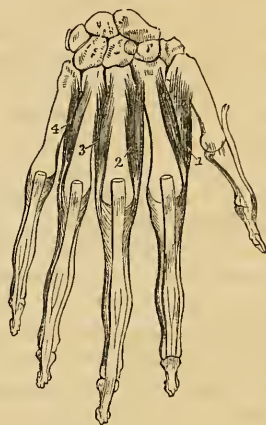


Fig. 100.



Relations.—By their *palmar surface* with the flexor tendons and with the deep muscles in the palm of the hand. By their *dorsal surface* with the dorsal interossei. On one side with the metacarpal bone, on the other with the corresponding dorsal interosseous.

On turning to the dorsum of the hand, the four *dorsal interossei* are seen in the four spaces between the metacarpal bones. They are bipenniform muscles, and *arise* by two heads from the adjoining sides of the base of the metacarpal bones. They are *inserted* into the base of the first phalanges, and aponeurosis of the extensor tendons.

The first is inserted into the index finger, and from its use is called abductor indicis; the second and third are inserted into the middle finger, compensating its exclusion from the palmar group; the fourth is attached to the ring finger; so that each finger is provided with two interossei, with the exception of the little finger, as may be shown by the adjoining table:

Fig. 99. Palmar interossei. 1. Adductor indicis. 2. Abductor annularis. 3. Interosseus auricularis.

Fig. 100. Dorsal interossei. 1. Abductor indicis. 2. Abductor medii. 3. Adductor medii. 4. Adductor annularis.

Index finger { one dorsal (abductor indicis),
 { one palmar.

Middle finger, two dorsal.

Ring finger { one dorsal,
 { one palmar.

Little finger, remaining palmar.

Relations.—By their *dorsal surface* with a thin aponeurosis which separates them from the tendons on the dorsum of the hand. By their *palmar surface* with the muscles and tendons in the palm of the hand. By one side with the metacarpal bone; by the other with the corresponding palmar interosseous. The abductor indicis is in relation by its palmar surface, with the adductor pollicis, the arteria magna pollicis being interposed. The radial artery passes into the palm of the hand between the two heads of the first dorsal interosseous muscle and the perforating branches of the deep palmar arch, between the heads of the other dorsal interossei.

Actions.—The actions of the muscles of the hand are expressed in their names. Those of the radial region belong to the thumb, and provide for three of its movements, *abduction*, *adduction*, and *flexion*. The ulnar group, in like manner, is subservient to the same motions of the little finger, and the interossei are abductors and adductors of the several fingers. The lumbricales are accessory in their actions to the deep flexors: they were called by the earlier anatomists, *fidicinii*, *i. e.* fiddlers' muscles, from an idea that they might effect the fractional movements by which the performer is enabled to produce the various notes on that instrument.

In relation to the axis of the hand, the four *dorsal* interossei are *abductors*, and the three palmar, *adductors*. It will therefore be seen that each finger is provided with its proper adductor, and abductor, two flexors, and (with the exceptions of the middle and ring fingers,) two extensors. The thumb has moreover a flexor and extensor, of the metacarpal bone; and the little finger a flexor of the metacarpal bone without an extensor.

MUSCLES OF THE LOWER EXTREMITY.

The muscles of the lower extremity may be arranged into groups corresponding with the different regions of the hip, thigh, leg, and foot, as in the following table:

HIP.

Gluteal region.

Gluteus maximus,
Gluteus medius,
Gluteus minimus,
Pyriformis,
Gemellus superior,
Obturator internus,
Gemellus inferior,
Obturator externus,
Quadratus femoris.

T H I G H.

Anterior femoral region.

Tensor vaginæ femoris,
Sartorius,
Rectus,
Vastus internus,
Vastus externus,
Crureus.

Internal femoral region.

Iliacus internus,
Psoas magnus,
Pectineus,
Adductor longus,
Adductor brevis,
Adductor magnus,
Gracilis.

Posterior femoral region.

Biceps,
Semitendinosus,
Semimembranosus.

L E G.

Anterior tibial region.

Tibialis anticus,
Extensor longus digitorum,
Peroneus tertius,
Extensor longus pollicis.

*Posterior tibial region.**Superficial group.*

Gastrocnemius,
Plantaris,
Soleus.

Fibular region.

Peroneus longus.
Peroneus brevis.

Deep [posterior] layer.

Popliteus,
Flexor longus pollicis,
Flexor longus digitorum,
Tibialis posticus.

F O O T.

Dorsal region.

Extensor brevis digitorum,
Interossei dorsales.

*Plantar region.**First layer.*

Abductor pollicis,
Abductor minimi digiti,
Flexor brevis digitorum.

Third layer.

Flexor brevis pollicis,
Adductor pollicis,
Flexor brevis minimi digiti,
Transversus pedis.

Second layer.

Musculus accessorius,
Lunbricales.

Fourth layer.

Interossei plantares.

Gluteal region.

Gluteus maximus,	Obturator internus,
Gluteus medius,	Gemellus inferior,
Gluteus minimus,	Obturator externus,
Pyriformis,	Quadratus femoris.
Gemellus superior,	

Dissection.—The subject being turned on its face, and a block placed beneath the os pubis to support the pelvis, the student commences the dissection of this region, by carrying an incision from the apex of the coccyx along the crest of the ilium to its anterior superior spinous process; or *vice versa*, if he be on the left side. He then makes an incision from the posterior fifth of the crest of the ilium, to the apex of the trochanter major—this marks the upper border of the gluteus maximus; and a third incision from the apex of the coccyx along the fleshy margin of the lower border of the gluteus maximus, to the outer side of the thigh, about four inches below the apex of the trochanter major. He then reflects the integument, superficial fascia, and deep fascia, which latter is very thin over this muscle, from the gluteus maximus, following rigidly the course of its fibres; and having exposed the muscle in its entire extent, he dissects the integument and superficial fascia from off the deep fascia which binds down the gluteus medius, the other portion of this region.

The *Gluteus maximus* ($\gamma\lambda\omicron\upsilon\tau\omicron\varsigma$, nates) is the thick, fleshy mass of muscle, of a quadrangular shape, which forms the convexity of the nates. In structure, it is extremely coarse, being made up of large fibres, which are collected into fasciculi, and these again into distinct muscular masses, separated by deep cellular furrows. It *arises* from the posterior fifth of the crest of the ilium, from the border of the sacrum and coccyx, from the great sacro-ischiatic ligament. It passes obliquely outwards and downwards, to be *inserted* into the rough line leading from the trochanter major to the linea aspera, and is continuous by means of its tendon with the fascia lata covering the outer side of the thigh. A large bursa is situated between the broad tendon of this muscle and the femur.

Relations.—By its *superficial surface* with a thin aponeurotic fascia, which separates it from the superficial fascia and integument, and with the vastus externus, a bursa being interposed. By its *deep surface* with the gluteus medius, pyriformis, gemelli, obturator internus, quadratus femoris, sacro-ischiatic foramina, great sacro-ischiatic ligament, tuberosity of the ischium, semi-membranosus, semi-tendinosus, biceps, and adductor magnus; the gluteal vessels and nerves, ischiatic vessels and nerves, and internal pudic vessels and nerve. By its *upper border* it overlaps the gluteus medius; and by the *lower border* forms the lower margin of the nates.

The gluteus maximus must be turned down from its origin, in order to bring the next muscles into view.

The *Gluteus medius* is placed in front of, rather than beneath the gluteus maximus; and is covered in by a process of the deep fascia, which is very thick and dense. It arises from the outer lip of the crest of the ilium for four-fifths of its length, from the surface of bone between that border and the superior curved line on the dorsum ilii, and from the dense fascia above mentioned. Its fibres converge to the upper part of the trochanter major, into which its tendon is inserted.

Relations.—By its *superficial surface* with the tensor vaginæ femoris, gluteus maximus, and a very thick fascia. By its *deep surface* with the gluteus minimus, and gluteal vessels and nerves. By its *lower border* with the piriformis muscle.

This muscle should now be removed from its origin and turned down, so as to expose the next which is situated beneath it.

The *Gluteus minimus* is a radiated muscle, arising from the surface of the dorsum ilii, between the superior and inferior curved lines; its fibres converge to the anterior border of the trochanter major, into which it is inserted by means of a rounded tendon. There is no distinct line of separation between the gluteus medius and minimus anteriorly.

Relations.—By its *superficial surface* with the gluteus medius, and gluteal vessels. By its *deep surface* with the surface of the ilium, the long tendon of the rectus femoris, and the capsule of the hip joint.

The *Piriformis* muscle (pyrum, a pear, *i. e.* pear-shaped) arises from the anterior surface of the sacrum, by little slips that are interposed between the anterior sacral foramina. It passes out of the pelvis, through the great sacro-ischiatic foramen, and is inserted by a rounded tendon into the trochanteric fossa of the femur.

Relations.—By its *superficial or external surface* with the sacrum and gluteus maximus. By its *deep or pelvic surface* with the rectum, the sacral plexus of nerves, the branches

Fig. 101.

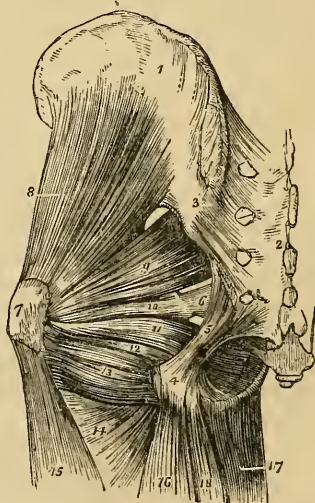


Fig. 101. The deep muscles of the gluteal region. 1. The external surface of the ilium. 2. The posterior surface of the sacrum. 3. The posterior sacro-iliac ligaments. 4. The tuberosity of the ischium. 5. The great or posterior sacro ischiatic ligament. 6. The lesser or anterior sacro-ischiatic ligament. 7. The trochanter major. 8. The gluteus minimus. 9. The piriformis. 10. The gemellus superior. 11. The obturator internus muscle, passing out of the lesser sacro-ischiatic foramen. 12. The gemellus inferior. 13. The quadratus femoris. 14. The upper part of the adductor magnus. 15. The vastus externus. 16. The biceps. 17. The gracilis. 18. The semi-tendinosus.

of the internal iliac artery, the great sacro-ischiatic notch, and the capsule of the hip-joint. By its *upper border* with the gluteus medius and gluteal vessels and nerves. By its *lower border* with the gemellus superior, ischiatic vessels and nerves, and internal pudic vessels and nerve.

Immediately below the pyriformis is a small slip of muscle, the *gemellus superior* (gemellus, double twin); it *arises* from the spine of the ischium, and is *inserted* into the upper border of the tendon of the obturator internus, and into the trochanteric fossa of the femur. The gemellus superior is not unfrequently wanting.

Relations.—By its *superficial surface* with the gluteus maximus, the ischiatic vessels and nerves, and internal pudic vessels and nerve. By its *deep surface* with the pelvis and capsule of the hip-joint.

The *Obturator internus* *arises* from the inner surface of the anterior wall of the pelvis, being attached to the margin of bone around the obturator foramen, and to the obturator membrane. It passes out of the pelvis through the lesser sacro-ischiatic foramen, and is *inserted* by a flattened tendon into the trochanteric fossa of the femur. The lesser sacro-ischiatic notch, over which this muscle plays as through a pulley, is faced with cartilage, and provided with a synovial bursa to facilitate its movements. The tendon of the obturator is supported on each side by the two gemelli muscles (hence their names), which are inserted into the sides of the tendon, and appear to be auxiliaries or superadded portions of the obturator internus.

Relations.—By its *superficial* or *posterior surface* with the internal pudic vessels and nerve, the obturator fascia, which separates it from the levator ani and viscera of the pelvis, the sacro-ischiatic ligaments, gluteus maximus, and ischiatic vessels and nerves. By its *deep* or *anterior surface* with the obturator membrane and the margin of bone surrounding it, the cartilaginous pulley of the lesser ischiatic foramen, the external surface of the pelvis, and the capsular ligament of the hip joint. By its *upper border* within the pelvis, with the obturator vessels and nerve; external to the pelvis, with the gemellus superior. By its *lower border* with the gemellus inferior.

The *Gemellus inferior* *arises* from the posterior point of the tuberosity of the ischium, and is *inserted* into the lower border of the tendon of the obturator internus, and into the trochanteric fossa of the femur.

Relations.—By its *superficial surface* with the gluteus maximus, and ischiatic vessels and nerves. By its *deep surface* with the external surface of the pelvis and capsule of the hip joint. By its *upper border* with the tendon of the obturator internus. By its *lower border* with the tendon of the obturator externus and quadratus femoris.

In this region the tendon only of the obturator externus can be seen, situated deeply between the gemellus inferior and the upper border of the quadratus femoris. To expose this muscle fully, it is

necessary to dissect it from the anterior part of the thigh, after the removal of the pectineus and adductor longus and brevis muscles.

The *Obturator externus* muscle (obturare, to stop up) arises from the obturator membrane, and from the surface of bone immediately surrounding it, viz., from the body and ramus of the os pubis and ischium: its tendon passes behind the neck of the femur, to be inserted with the external rotator muscles, into the trochanteric fossa of the femur.

Relations.—By its *superficial* or *anterior surface* with the tendon of the psoas and iliacus, pectineus, adductor brevis and magnus, the obturator vessels and nerve. By its *deep* or *posterior surface* with the obturator membrane and the margin of bone which surrounds it, the lower part of the capsule of the hip joint and the quadratus femoris.

The *Quadratus femoris* (square-shaped) arises from the external border of the tuberosity of the ischium, and is inserted into a rough line on the posterior border of the trochanter major, which is thence named *linea quadrati*.

Relations.—By its *posterior surface* with the gluteus maximus, and ischiatic vessels and nerves. By its *anterior surface* with the tendon of the obturator externus and trochanter minor; a synovial bursa often separating it from the latter. By its *upper border* with the gemellus inferior; and by the *lower border* with the adductor magnus.

Actions.—The glutei muscles are abductors of the thigh, when they take their fixed point from the pelvis. Taking their fixed point from the thigh, they steady the pelvis on the head of the femur—this action is peculiarly obvious in standing on one leg; they assist also in carrying the leg forward, in progression. The gluteus minimus being attached to the anterior border of the trochanter major, rotates the limb slightly inwards. The gluteus medius and maximus, from their insertion into the posterior aspect of the bone, rotate the limb outwards; the latter is, moreover, a tensor of the fascia of the thigh. The other muscles rotate the limb outwards, everting the knee and foot; hence they are named external rotators.

Anterior femoral region.

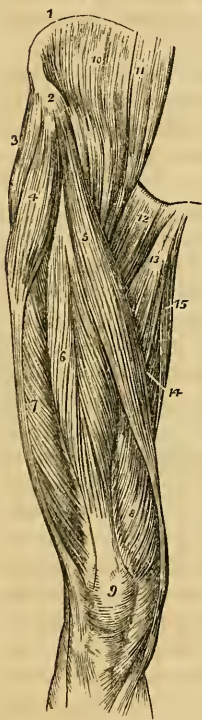
Tensor vaginæ femoris,
Sartorius,
Rectus,
Vastus internus,
Vastus externus,
Crureus.

Dissection.—Make an incision along the line of Poupart's ligament, from the anterior superior spinous process of the ilium to the spine of the os pubis; and a second, from the middle of the preceding down the inner side of the thigh, and across the inner condyle of the femur, to the head of the tibia, where it may be bounded

by a transverse incision. Turn back the integument from the whole of this region, and examine the superficial fascia; which is next to be removed in the same manner. After the deep fascia has been well considered, it is likewise to be removed, by dissecting it off in the course of the fibres of the muscles. As it might not be convenient to the junior student to expose so large a surface at once as ordered in this dissection, the vertical incision may be crossed by one or two transverse incisions; as may be deemed most proper.

The *Tensor vaginae femoris* (stretcher of the sheath of the thigh) is a short flat muscle, situated on the outer side of the hip. It arises from the crest of the ilium, near to its anterior superior spinous process, and is inserted between two layers of the fascia lata at about one-fourth down the thigh.

Fig. 102.



Relations.—By its *superficial surface* with the fascia lata and integument. By its *deep surface* with the internal layer of the fascia lata, gluteus medius, rectus and vastus externus. By its *inner border*, near its origin, with the sartorius.

The *Sartorius* (tailor's muscle) is a long ribband-like muscle, arising from the anterior superior spinous process of the ilium, and from the notch immediately below that process; it crosses obliquely the upper third of the thigh, descends behind the inner condyle of the femur, and is inserted by an aponeurotic expansion into the inner tuberosity of the tibia. This expansion covers in the insertion of the tendons of the gracilis and semi-tendinosus muscles. The inner border of the sartorius muscle is the guide to the operation for tying the femoral artery in the middle of its course.

Relations.—By its *superficial surface* with the fascia lata and some cutaneous nerves. By its *deep surface* with the psoas and iliacus, rectus, sheath of the femoral vessels and saphenous nerves, vastus internus, adductor longus, adductor magnus, gracilis, long saphenous nerve, internal lateral ligament of the knee joint. By its expanded insertion with the tendons of the gracilis and semi-tendinosus, a synovial bursa being interposed. At the knee joint its *posterior border* is in relation with the internal saphenous vein. At the upper third of the

Fig. 102. The muscles of the anterior femoral region. 1. The crest of the ilium. 2. Its anterior superior spinous process. 3. The gluteus medius. 4. The tensor vaginae femoris; its insertion into the fascia lata is shown inferiorly. 5. The sartorius. 6. The rectus. 7. The vastus externus. 8. The vastus internus. 9. The patella. 10. The iliacus internus. 11. The psoas magnus. 12. The pectineus. 13. The adductor longus. 14. Part of the adductor magnus. 15. The gracilis.

thigh the sartorius forms, with the lower border of the adductor longus, an isosceles triangle, whereof the base corresponds with Poupart's ligament. A perpendicular line, drawn from the middle of the base to the apex of this triangle, immediately overlies the femoral artery with its sheath.

The *Rectus* (straight) muscle is fusiform in its shape and bipenniform in the disposition of its fibres. It *arises* by two round tendons—one from the anterior inferior spinous process of the ilium, the other from the upper lip of the acetabulum. It is *inserted* by a broad and strong tendon, into the upper border of the patella. It is more correct to consider the patella as a sesamoid bone, developed within the tendon of the rectus; and the ligamentum patellæ as the continuation of the tendon to its insertion into the spine of the tibia.

Relations.—By its *superficial surface* with the gluteus medius, psoas and iliacus, sartorius; and for the lower three fourths of its extent, with the fascia lata. By its *deep surface* with the capsule of the hip joint, the external circumflex vessels, crureus, and vastus internus and externus.

The rectus must now be divided through its middle, and the two ends turned aside, to bring clearly into view the next muscles.

The three next muscles are generally considered collectively under the name of triceps extensor cruris. Adopting this view, the muscle surrounds the whole of the femur, excepting the rough line (linea aspera) upon its posterior aspect. Its division into three parts is not well defined; the fleshy mass upon each side being distinguished by the names of vastus internus and externus, the middle portion by that of crureus.

The *Vastus externus*, narrow below and broad above, *arises* from the outer border of the patella, and is *inserted* into the femur and outer side of the linea aspera, as high as the base of the trochanter major.

Relations.—By its *superficial surface* with the fascia lata, rectus, biceps, semi-membranosus and gluteus maximus, a synovial bursa being interposed. By its *deep surface* with the crureus and femur.

The *Vastus internus*, broad below and narrow above, *arises* from the inner border of the patella, and is *inserted* into the femur and inner side of the linea aspera as high up as the anterior inter-trochanteric line.

Relations.—By its *superficial surface* with the psoas and iliacus, rectus, sartorius, femoral artery and vein and saphenous nerves, pectineus, adductor longus, brevis, and magnus, and fascia lata. By its *deep surface* with the crureus and femur.

The *Crureus* (crus, the leg) *arises* from the upper border of the patella, and is *inserted* into the front aspect of the femur, as high as the anterior inter-trochanteric line. When the crureus is divided from its insertion, a small muscular fasciculus is often seen upon the lower part of the femur, which is inserted into the pouch of synovial membrane that extends upwards from the knee-joint, behind the

patella. This is named, from its situation, *sub-crureus*, and would seem to be intended to support the synovial membrane.

Relations.—By its *superficial surface* with the external circumflex vessels, the rectus, and the vastus internus and externus. By its *deep surface* with the femur, the sub-crureus, and synovial membrane of the knee joint.

Actions.—The tensor vaginæ femoris renders the fascia lata tense, and slightly inverts the limb. The sartorius flexes the leg upon the thigh, and, continuing to act, the thigh upon the pelvis, at the same time carrying the leg across that of the opposite side, into the position in which tailors sit; hence its name. Taking its fixed point from below, it assists the extensor muscles in steadying the leg, for the support of the trunk. The other four muscles have been collectively named *quadriceps extensor*, from the similarity of action. They extend the leg upon the thigh, and obtain a great increase of power by their attachment to the patella, which acts as a fulcrum. Taking their fixed point from the tibia, they steady the femur upon the leg; and the rectus, by being attached to the pelvis, serves to balance the trunk upon the lower extremity.

Internal femoral region.

Iliacus internus,
Psoas magnus,
Pectineus,
Adductor longus,
Adductor brevis,
Adductor magnus,
Gracilis.

Dissection.—These muscles are exposed by the removal of the inner flap of integument recommended in the dissection of the anterior femoral region. The iliacus and psoas arising from within the abdomen can only be seen in their entire extent after the removal of the viscera from that cavity.

The *Iliacus internus* is a flat radiated muscle. It *arises* from the inner concave surface of the ilium; and, after joining with the tendon of the psoas, is *inserted* into the trochanter minor of the femur.

Relations.—By its *anterior surface*, within the pelvis, with the external cutaneous nerve, and with the iliac fascia, which separates the muscle from the peritoneum, on the right from the cæcum, and on the left from the sigmoid flexure of the colon; *externally* to the pelvis, with the fascia lata, rectus, and sartorius. By its *posterior surface* with the iliac fossa, margin of the pelvis, and with the capsule of the hip joint, a synovial bursa of large size being interposed, which is sometimes continuous with the synovial membrane of the articulation. By its *inner border* with the psoas magnus and crural nerve.

The *Psoas magnus* (Ψά, lumbus, a loin), situated by the side of the vertebral column in the loins, is a long, fusiform muscle. It *arises* from the intervertebral substances, part of the bodies and bases of the transverse processes, and from a series of tendinous arches, thrown across the constricted portion of the last dorsal and four upper lumbar vertebræ. These arches are intended to protect the lumbar arteries and sympathetic filaments of nerves from pressure, in their passage beneath the muscle. The tendon of the *psaos magnus* unites with that of the iliacus, and the conjoined tendon is *inserted* into the posterior part of the trochanter major, a bursa being interposed.

Relations.—By its *anterior surface* with the ligamentum arcuatum internum of the diaphragm, the kidney, the *psaos parvus*, genito-crural nerve, sympathetic nerve, its proper fascia, the peritoneum and colon, and along its pelvic border with the common and external iliac artery and vein. By its *posterior surface* with the lumbar vertebræ, the lumbar arteries, quadratus lumborum, from which it is separated by the anterior layer of the aponeurosis of the transversalis, and with the crural nerve, which near Poupart's ligament gets to its outer side. The lumbar plexus of nerves is situated in the substance of the posterior part of the muscle. In the thigh the muscle is in relation with the fascia lata in front; the border of the pelvis and hip-joint, from which it is separated by the synovial membrane, common to it and the preceding muscle, behind; with the crural nerve, and iliacus to the outer side; and with the femoral artery, by which it is slightly overlapped, to the inner side.

The *Pectineus* is a flat and quadrangular muscle; it *arises* from the pectineal line (pecten, a crest) of the os pubis, and is *inserted* into the line leading from the anterior inter-trochanteric line to the linea aspera of the femur.

Relations.—By its *anterior surface* with the pubic portion of the fascia lata, which separates it from the femoral artery and vein and internal saphenous nerve, and lower down with the profunda artery. By its *posterior surface* with the capsule of the hip-joint, and with the obturator externus and adductor brevis, the obturator vessels being interposed. By its *external border* with the *psaos*, the femoral artery resting upon the line of interval. By its *internal border* with the outer edge of the adductor longus. Obturator hernia is situated directly behind this muscle, which forms one of its coverings.

The *Adductor longus* (adducere, to draw to), the most superficial of the three adductors, *arises* by a round and thick tendon from the angle of the os pubis; and, assuming a flattened form, is *inserted* into the middle third of the linea aspera.

Relations.—By its *anterior surface* with the pubic portion of the fascia lata, and near its insertion with the femoral artery and vein. By its *posterior surface* with the adductor brevis and magnus, the anterior branches of the obturator vessels and nerves, and near its insertion with the profunda artery and vein. By its *outer border* with the pectineus, and by the *inner border* with the gracilis.

The pectineus must be divided near its origin and turned outwards, and the adductor longus through its middle turning its ends to either side, to bring into view the adductor brevis.

The *Adductor brevis*, placed beneath the pectineus and adductor longus, is fleshy, and thicker than the adductor longus; it *arises* from the body and ramus of the os pubis, and is *inserted* into the upper third of the linea aspera.

Relations.—By its *anterior surface* with the pectineus, adductor longus, and anterior branches of the obturator vessels and nerve. By its *posterior surface* with the adductor magnus, and posterior branches of the obturator vessels and nerve. By its *outer border* with the obturator externus, and conjoined tendon of the psoas and iliacus. By its *inner border* with the gracilis and adductor magnus. The adductor brevis is pierced near its insertion by the middle perforating artery.

The adductor brevis may now be divided from its origin and turned outwards, or its inner two-thirds may be cut away entirely, when the adductor magnus muscle will be exposed in its entire extent.

The *Adductor magnus* is a broad triangular muscle, forming a septum of division between the muscles situated on the anterior and those on the posterior aspect of the thigh. It *arises* by fleshy fibres from the ramus and side of the tuberosity of the ischium; and radiating in its passage outwards is *inserted* into the whole length of the linea aspera, and inner condyle of the femur. The adductor magnus is pierced by five openings; the three superior, for the three perforating arteries; and the fourth, for the termination of the profunda. The fifth is the large oval opening in the tendinous portion of the muscle, that gives passage to the femoral vessels.

Relations.—By its *anterior surface* with the pectineus, adductor brevis, adductor longus, femoral artery and vein, profunda artery and vein, with their branches, and with the posterior branches of the obturator vessels and nerve. By its *posterior surface* with the semi-tendinosus, semi-membranosus, biceps, and gluteus maximus. By its *inner border* with the gracilis and sartorius. By its *upper border* with the obturator externus, and quadratus femoris.

The *Gracilis* (slender) is situated along the inner border of the thigh. It *arises* by a broad but very thin tendon, from the edge of the ramus of the os pubis and ischium; and is *inserted* by a rounded tendon into the inner tuberosity of the tibia, beneath the expansion of the sartorius.

Relations.—By its *inner or superficial surface* with the fascia lata, and below with the sartorius and internal saphenous nerve; the internal saphenous vein crosses it lying superficially to the fascia lata. By its *outer or deep surface* with the adductor longus, brevis, and magnus, and the internal lateral ligament of the knee-joint, from which it is separated by a synovial bursa common to the tendons of the gracilis and semi-tendinosus.

Actions.—The iliacus, psoas, pectineus, and adductor longus mus-

cles bend the thigh upon the pelvis, and, at the same time, from the obliquity of their insertion into the lesser trochanter and linea aspera, rotate the entire limb outwards; the pectineus and adductors adduct the thigh powerfully; and, from the manner of their insertion into the linea aspera, they assist in rotating the limb outwards. The gracilis is likewise an adductor of the thigh; but contributes also to the flexion of the leg, by its attachment to the inner tuberosity of the tibia.

Posterior femoral region.

Biceps,
Semi-tendinosus,
Semi-membranosus.

Dissection.—Remove the integument and fascia on the posterior part of the thigh by two flaps, as on the anterior region, and turn aside the gluteus maximus from the upper part; the muscles may then be examined.

The *Biceps flexor cruris* (bis, double, κεφαλή, head) arises by two heads, one by a common tendon with the semi-tendinosus; the other muscular, and much shorter, from the lower two-thirds of the external border of the linea aspera. This muscle forms the outer hamstring, and is inserted by a strong tendon into the head of the fibula.

Relations.—By its *superficial* or *posterior surface* with the gluteus maximus and fascia lata. By its *deep* or *anterior surface* with the semi-membranosus, adductor magnus, vastus externus, the great sciatic nerve, popliteal artery and vein, and near its insertion with the external head of the gastrocnemius and plantaris. By its *inner border* with the semi-tendinosus, and in the popliteal space with the popliteal artery and vein.

The *Semi-tendinosus*, remarkable for its long tendon, arises in common with the long head of the biceps, from the tuberosity of the ischium. It is inserted into the inner tuberosity of the tibia.

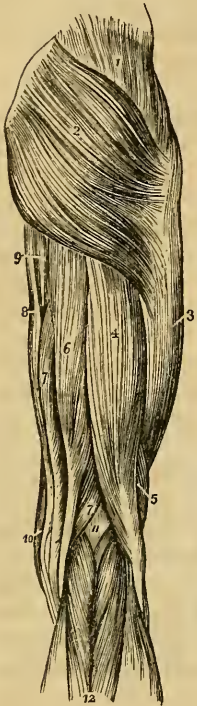
Relations.—By its *superficial surface* with the gluteus maximus, fascia lata, and at its insertion with the synovial bursa which separates its tendon from the expansion of the sartorius. By its *deep surface* with the semi-membranosus, adductor magnus, internal head of the gastrocnemius, and internal lateral ligament of the knee-joint, the synovial bursa common to it, and the tendon of the gracilis being interposed. By its *inner border* with the gracilis; and by its *outer border* with the biceps.

These two muscles must be dissected from the tuberosity of the ischium, to bring into view the origin of the next.

The *Semi-membranosus*, remarkable for the tendinous expansion upon its anterior and posterior surface, arises from the tuberosity of the ischium, in front of the common origin of the two preceding muscles. It is inserted into the posterior part of the inner tuberosity of the tibia; at its insertion the tendon splits into three portions, one

of which is inserted in a groove on the inner side of the head of the tibia, beneath the internal lateral ligament. The second is continuous with an aponeurotic expansion that binds down the popliteus muscle—the popliteal fascia; and the third turns upwards and outwards to the external condyle of the femur, forming the middle portion of the posterior ligament of the knee-joint (ligamentum posticum Winslowii).

Fig. 103.



The tendons of the two last muscles, viz. the semi-tendinosus and semi-membranosus, with those of the gracilis and sartorius, form the inner hamstring.

Relations.—By its *superficial surface* with the gluteus maximus, biceps, semi-tendinosus, fascia lata, and at its insertion with the tendinous expansion of the sartorius. By its *deep surface* with the quadratus femoris, adductor magnus, internal head of the gastrocnemius, the knee-joint, from which it is separated by a synovial membrane, and the popliteal artery and vein.

By its *inner border* with the gracilis. By its *outer border* with the great ischiatic nerve, and in the popliteal space, with the popliteal artery and vein.

If the semi-membranosus muscle be turned down from its origin, the student will bring into view the broad and radiated expanse of the adductor magnus, upon which the three flexor muscles above described rest.

Actions.—These three hamstring muscles are the direct flexors of the leg upon the thigh; and, by taking their origin from below, they balance the pelvis on the lower extremities. The biceps from the obliquity of its direction everts the leg when partly flexed, and the semi-tendinosus turns the leg inwards when in the same state of flexion.

Anterior tibial region.

Anterior tibial region.

Tibialis anticus,
Extensor longus digitorum,
Peroneus tertius,
Extensor proprius pollicis.

Fig. 103. The muscles of the posterior femoral and gluteal region. 1. The gluteus medius. 2. The gluteus maximus. 3. The vastus externus covered in by fascia lata. 4. The head of the biceps. 5. Its short head. 6. The semi-tendinosus. 7. The semi-membranosus. 8. The gracilis. 9. A part of the inner border of the adductor magnus. 10. The edge of the sartorius. 11. The popliteal space. 12. The gastrocnemius muscle; its two heads. The tendon of the biceps forms the outer hamstring; and the tendons of the gracilis, semi-tendinosus, and semi-membranosus, the inner hamstring.

Dissection.—The dissection of the anterior tibial region is to be commenced by carrying an incision along the middle of the leg, midway between the tibia and the fibula, from the knee to the ankle, and bounding it inferiorly by a transverse incision, extending from one malleolus to the other. And to expose the tendons on the dorsum of the foot, the longitudinal incision may be carried onwards to the outer side of the base of the great toe, and be terminated by another incision directed across the heads of the metatarsal bones.

The *Tibialis anticus* muscle (flexor tarsi tibialis) arises from the upper two-thirds of the tibia, from the interosseous membrane, and from the deep fascia; its tendon passes through a distinct sheath in the annular ligament, and is inserted into the inner side of the internal cuneiform bone, and base of the metatarsal bone of the great toe.

Relations.—By its *anterior surface* with the deep fascia, from which many of its superior fibres arise, and with the anterior annular ligament. By its *posterior surface* with the interosseous membrane, tibia, ankle-joint, and bones of the tarsus with their articulations. By its *internal surface* with the tibia. By the *external surface* with the extensor longus digitorum, extensor proprius pollicis, and with the anterior tibial vessels and nerve.

The *Extensor longus digitorum* arises from the head of the tibia, from the upper three-fourths of the fibula, from the interosseous membrane, and from the deep fascia. Below, it divides into four tendons, which pass beneath the annular ligament, to be inserted into the second and third phalanges of the four lesser toes. The mode of insertion of the extensor tendons, both in the hand and in the foot, is remarkable; each tendon spreads into a broad aponeurosis over the first phalanx; this aponeurosis divides into three slips, the middle one is inserted into the base of the second phalanx, and the two lateral slips are continued onwards, to be inserted into the base of the third.

Relations.—By its *anterior surface* with the deep fascia of the leg and foot, and with the anterior annular ligament. By its *posterior surface* with the interosseous membrane, fibula, ankle-joint, extensor brevis digitorum, which separates its tendons from the tarsus, and with the metatarsus and phalanges. By its *inner surface* with the tibialis anticus, extensor proprius pollicis, and anterior tibial vessels. By its *outer border* with the peroneus longus and brevis.

The *Peroneus tertius* (flexor tarsi fibularis) arises from the lower fourth of the fibula, and is inserted into the base of the metatarsal bone of the little toe. Although apparently but a mere division or continuation of the extensor longus digitorum, this muscle may be looked upon as analogous to the flexor carpi ulnaris of the fore-arm. Sometimes it is altogether wanting.

The *Extensor proprius pollicis* lies between the tibialis anticus and extensor longus digitorum. It arises from the lower two-thirds of the fibula and interosseous membrane. Its tendon passes through

a distinct sheath in the annular ligament, and is *inserted* into the base of the last phalanx of the great toe.

Relations.—By its *anterior surface* with the deep fascia of the leg and foot, and with the anterior annular ligament. By its *posterior surface* with the interosseous membrane, the fibula, the tibia, the ankle-joint, the extensor brevis digitorum, and the bones and articulations of the great toe. It is crossed upon this aspect by the anterior tibial vessels and nerve. By its *outer side* with the extensor longus digitorum, and in the foot with the dorsalis pedis artery and veins; the outer side of its tendon upon the dorsum of the foot being the guide to these vessels. By its *inner side* with the tibialis anticus, and with the anterior tibial vessels.

Actions.—The tibialis anticus and peroneus tertius are direct flexors of the tarsus upon the leg; acting in conjunction with the tibialis posticus they direct the foot inwards, and with the peroneus longus and brevis outwards. They assist also in preserving the flatness of the foot during progression. The extensor longus digitorum and extensor proprius pollicis, are direct extensors of the phalanges; but continuing their action, they assist the tibialis anticus and peroneus tertius, in flexing the entire foot upon the leg. Taking their origin from below, they increase the stability of the ankle-joint.

Posterior tibial region.

Superficial group.

Gastrocnemius,
Plantaris,
Soleus.

Dissection.—Make an incision from the middle of the popliteal space down the middle of the posterior part of the leg to the heel, bounding it inferiorly by a transverse incision passing between the two malleoli. Turn aside the flaps of integument and remove the fasciæ from the whole of this region; the gastrocnemius muscle will then be exposed.

The *Gastrocnemius* (*γαστροκνήμιον*, the bellied part of the leg) *arises* by two heads from the two condyles of the femur, the inner head being the longest. They unite to form the beautiful muscle so characteristic of this region of the limb. It is *inserted*, by means of the tendo Achillis, into the lower part of the posterior tuberosity of the os calcis, a synovial bursa being placed between that tendon and the upper part of the tuberosity. The gastrocnemius must be removed from its origin, and turned down, in order to expose the next muscle.

Relations.—By its *superficial surface* with the deep fascia of the leg, which separates it from the external saphenous vein, and with the external saphenous nerve. By its *deep surface* with the lateral portions of the posterior ligament of the knee-joint, the popliteus,

plantaris, and soleus. The internal head of the muscle rests against the posterior surface of the internal condyle of the femur; the external head against the outer side of the external condyle. In the latter a sesamoid bone is sometimes found.

Fig. 104.

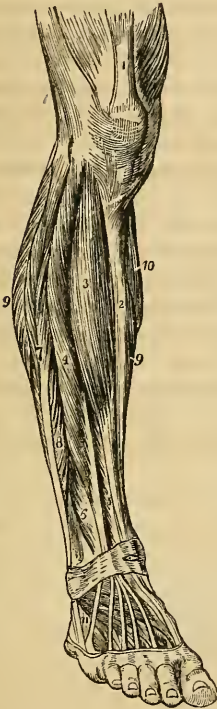
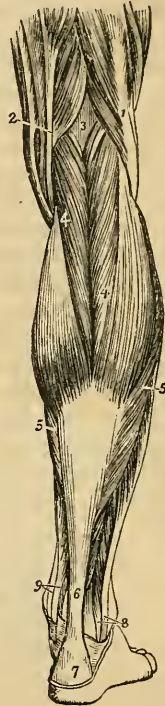


Fig. 105.



The *Plantaris* (planta, the sole of the foot), an extremely diminutive muscle situated between the gastrocnemius and soleus, *arises* from the outer condyle of the femur; and is *inserted*, by its long and delicately slender tendon, into the inner side of the posterior tube-

Fig. 104. The muscles of the anterior tibial region. 1. The extensor muscles inserted into the patella. 2. The subcutaneous surface of the tibia. 3. The tibialis anticus. 4. The extensor communis digitorum. 5. The extensor proprius pollicis. 6. The peroneus tertius. 7. The peroneus longus. 8. The peroneus brevis. 9, 9. The borders of the soleus muscle. 10. A part of the inner belly of the gastrocnemius. 11. The extensor brevis digitorum; the tendon in front of this number is that of the peroneus tertius; and that behind it, the tendon of the peroneus brevis.

Fig. 105. The superficial muscles of the posterior aspect of the leg. 1. The biceps muscle forming the outer hamstring. 2. The tendons forming the inner hamstring. 3. The popliteal space. 4. The gastrocnemius muscle. 5, 5. The soleus. 6. The tendo Achillis. 7. The posterior tuberosity of the os calcis. 8. The tendons of the peroneus longus and brevis muscles passing behind the outer ankle. 9. The tendons of the deep layer passing into the foot behind the inner ankle.

rosity of the os calcis, by the side of the tendo Achillis; having crossed obliquely between the two muscles.

The *Soleus* (solea, a sole) is the broad muscle upon which the plantaris rests. It *arises* from the head and upper third of the fibula, from the oblique line and middle third of the tibia. Its fibres converge to the tendo Achillis, by which it is *inserted* into the posterior tuberosity of the os calcis. Between the fibular and tibial origins of this muscle is a tendinous arch, beneath which the popliteal vessels and nerve pass into the leg.

Relations.—By its *superficial surface* with the gastrocnemius and plantaris. By its *deep surface* with the intermuscular fascia, which separates it from the flexor longus digitorum, tibialis posticus, flexor longus pollicis, from the posterior tibial vessels and nerve, and from the peroneal vessels.

Actions.—The three muscles of the calf draw powerfully on the os calcis, and lift the heel; continuing their action, they raise the entire body. This action is attained by means of a lever of the second power, the fulcrum (the toes) being at one end, the weight (the body supported on the tibia) in the middle, and the power (these muscles) at the other extremity.

They are, therefore, the walking muscles, and perform all movements that require the support of the whole body from the ground, as dancing, leaping, &c. Taking their fixed point from below, they steady the leg upon the foot.

Deep layer.

Popliteus,
Flexor longus pollicis,
Flexor longus digitorum,
Tibialis posticus.

Dissection.—After the removal of the soleus, the deep layer will be found bound down by an inter-muscular fascia, which is to be dissected away; the muscles may then be examined.

The *Popliteus* muscle (poples, the ham of the leg) forms the floor of the popliteal region at its lower part, and is bound tightly down by a strong fascia derived from the middle slip of the tendon of the semi-membranosus muscle. It *arises* by a rounded tendon from a deep groove on the outer side of the external condyle of the femur, beneath the external lateral ligament; and spreading obliquely over the head of the tibia, is *inserted* into the surface of bone above its oblique line. This line is often called, from being the limit of insertion of the popliteus muscle, the popliteal line.

Relations.—By its *superficial surface* with a thick fascia which separates it from the two heads of the gastrocnemius, the plantaris, and the popliteal vessels and nerve. By its *deep surface* with the articulation of the knee-joint and with the upper part of the tibia.

The *Flexor longus pollicis* is the most superficial of the three next muscles. It *arises* from the lower two-thirds of the fibula, passes

through a groove in the astragalus and os calcis, which is converted by tendinous fibres into a distinct sheath lined by a synovial membrane into the sole of the foot; it is *inserted* into the base of the last phalanx of the great toe.

Relations.—By its *superficial surface* with the intermuscular fascia, which separates it from the soleus and tendo Achillis. By its *deep surface* with the tibialis posticus, fibula, fibular vessels, interosseous membrane, and ankle-joint. By its *outer border* with the peroneus longus and brevis. By its *inner border* with the flexor longus digitorum. In the foot, the tendon of the flexor longus pollicis is connected with that of the flexor longus digitorum by a short tendinous slip.

The *Flexor longus digitorum* (perforans) arises from the surface of the tibia, immediately below the popliteal line. Its tendon passes through a sheath common to it and the tibialis posticus behind the inner malleolus; it then passes through a second sheath which is connected with a groove in the astragalus and os calcis, into the sole of the foot, where it divides into four tendons, which are *inserted* into the base of the last phalanx of the four lesser toes, perforating the tendons of the flexor brevis digitorum.

Relations.—By its *superficial surface* with the intermuscular fascia, which separates it from the soleus, and with the posterior tibial vessels and nerve. By its *deep surface* with the tibia and tibialis posticus. In the *sole of the foot* its tendon is in relation with the abductor pollicis and flexor brevis digitorum, which lie superficially to it, and it crosses the tendon of the flexor longus pollicis. At the point of crossing it receives the tendinous slip of communication from the latter.

The flexor longus pollicis must now be removed from its origin, and the flexor longus digitorum drawn aside, to bring into view the entire extent of the tibialis posticus.

The *Tibialis posticus* (extensor tarsi tibialis) lies upon the interosseous membrane, between the two bones of the leg. It arises by two heads from the adjacent sides of the tibia and fibula their

Fig. 106.

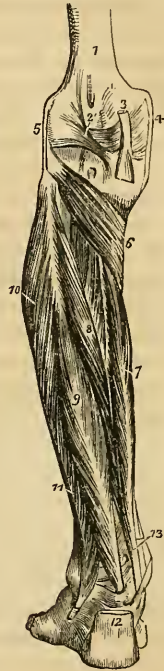


Fig. 106. The deep layer of muscles of the posterior tibial region. 1. The lower extremity of the femur. 2. The ligamentum posticum Winslowii. 3. The tendon of the semi-membranosus muscle dividing into its three slips. 4. The internal lateral ligament of the knee-joint. 5. The external lateral ligament. 6. The popliteus muscle. 7. The flexor longus digitorum. 8. The tibialis posticus. 9. The flexor longus pollicis. 10. The peroneus longus muscle. 11. The peroneus brevis. 12. The tendo Achillis divided at its insertion into the os calcis. 13. The tendons of the tibialis posticus and flexor longus digitorum muscles, just as they are about to pass beneath the internal annular ligament of the ankle; the interval between the latter tendon and the tendon of the flexor longus pollicis is occupied by the posterior tibial vessels and nerve.

whole length, and from the interosseous membrane. Its tendon passes inwards beneath the tendon of the flexor longus digitorum, and runs in the same sheath; it then passes through a proper sheath over the deltoid ligament, and beneath the calcaneo-scaphoid articulation, to be *inserted* into the tuberosity of the scaphoid and internal cuneiform bone. While in the common sheath behind the internal malleolus, the tendon of the tibialis posticus lies internally to that of the flexor longus digitorum, from which it is separated by a thin fibrous partition. A sesamoid bone is usually met with in the tendon close to its insertion.

Relations.—By its *superficial surface* with the intermuscular septum, the flexor longus pollicis, flexor longus digitorum, posterior tibial vessels and nerve, peroneal vessels, and in the sole of the foot with the abductor pollicis. By its *deep surface* with the interosseous membrane, the fibula and tibia, the ankle joint, and the astragalus. The anterior tibial artery passes between the two heads of the muscle.

The student will observe that the two latter muscles change their relative position to each other in their course. Thus, in the leg, the position of the three muscles from within outwards, is—flexor longus digitorum, tibialis posticus, flexor longus pollicis. At the inner malleolus, the relation of the tendon is—tibialis posticus, flexor longus digitorum, both in the same sheath; then a broad groove, which lodges the posterior tibial artery, venæ comites, and nerve; and lastly, the flexor longus pollicis.

Actions.—The popliteus is a flexor of the tibia upon the thigh, carrying it at the same time inwards so as to invert the leg. The flexor longus pollicis, and flexor longus digitorum are the long flexors of the toes; their tendons are connected in the foot by a short tendinous band, hence they necessarily act together. The tibialis posticus is an extensor of the tarsus upon the leg, and an antagonist to the tibialis anticus. It combines with the tibialis anticus in adduction of the foot.

Fibular region.

Peroneus longus,
Peroneus brevis.

Dissection.—These muscles are exposed by continuing the dissection of the anterior tibial region outwards beyond the fibula, to the border of the posterior tibial region.

The *Peroneus longus* (περὸν, fibula, extensor tarsi fibularis longior) muscle *arises* from the upper third of the outer side of the fibula, and terminates in a long tendon, which passes behind the external malleolus, and obliquely across the sole of the foot, through the groove in the cuboid bone, to be *inserted* into the base of the metatarsal bone of the great toe. Its tendon is thickened when it glides behind the external malleolus, and a sesamoid bone is developed in that part which plays upon the cuboid bone.

Relations.—By its *superficial surface* with the fascia of the leg and foot. By its *deep surface* with the fibula, peroneus brevis, os calcis, and cuboid bone, and near the head of the fibula with the fibular nerve. By its *anterior border* it is separated from the extensor longus digitorum by the attachment of the fascia of the leg to the fibula; and by the *posterior border* by the same medium from the soleus and flexor longus pollicis. The peroneus longus is furnished with three tendinous sheaths and as many synovial membranes; the first is situated behind the external malleolus, and is common to this muscle and the peroneus brevis, the second on the outer side of the os calcis, and the third on the cuboid bone.

The *Peroneus brevis* (extensor tarsi fibularis brevior) lies beneath the peroneus longus; it *arises* from the lower two-thirds of the fibula, and terminates in a tendon which passes behind the external malleolus and through a groove in the os calcis, to be *inserted* into the base of the metatarsal bone of the little toe.

Relations.—By its *superficial surface* with the peroneus longus and fascia of the leg and foot. By its *deep surface* with the fibula, the os calcis and cuboid bone. The lateral relations are the same as those of the peroneus longus. The tendon of the peroneus brevis has but two tendinous sheaths and two synovial membranes;—one behind the external malleolus and common to both peronei, the other upon the side of the os calcis.

Actions.—The peronei muscles are extensors of the foot, conjointly with the tibialis posticus. They antagonize the tibialis anticus and peroneus tertius, which are flexors of the foot. The whole of these muscles acting together, tend to maintain the flatness of the foot so necessary to security in walking.

FOOT.

Dorsal region.

Extensor brevis digitorum,
Interossei dorsales.

The *Extensor brevis digitorum* muscle *arises* from the outer side of the os calcis, crosses the foot obliquely, and terminates in four tendons, the innermost of which is *inserted* into the base of the first phalanx of the great toe, and the other three into the sides of the long extensor tendons of the second, third, and fourth toes.

Relations.—By its *upper surface* with the tendons of the extensor longus digitorum, peroneus brevis, and with the deep fascia of the foot. By its *under surface* with the tarsal and metatarsal bones. Its *inner border* is in relation with the dorsalis pedis artery, and the innermost tendon of the muscle crosses that artery just before its division.

The *Dorsal interossei* muscles are placed between the metatarsal bones; they resemble the analogous muscles in the hand in *arising* by two heads from the adjacent sides of the metatarsal bones; their

tendons are *inserted* into the base of the first phalanx, and into the digital expansion of the tendons of the long extensor.

The *first dorsal interosseous* is *inserted* into the inner side of the second toe, and is therefore an *adductor*; the other three are *inserted* into the outer side of the second, third, and fourth toes, and are consequently *abductors*.

Relations.—By their *upper surface* with a strong fascia which separates them from the extensor tendons. By their *under surface* with the plantar interossei. Each of the muscles gives passage to a small artery (posterior perforating) which communicates with the external plantar artery. And between the heads of the first interosseous muscle the communicating artery of the *dorsalis pedis* takes its course.

Plantar region.

First layer.

Abductor pollicis,
Abductor minimi digiti,
Flexor brevis digitorum.

Dissection.—The sole of the foot is best dissected by carrying an incision around the heel, and along the inner and outer borders of the foot, to the great and little toes. This incision should divide the integument and superficial fascia, and both together should be dissected from the deep fascia, as far forward as the base of the phalanges, where they may be removed from the foot altogether. The deep fascia should then be removed, and the first layer of muscles will be brought into view.

The *Abductor pollicis* lies along the inner border of the foot; it *arises* by two heads, between which the tendons of the long flexors, arteries, veins, and nerves enter the sole of the foot. One head *arises* from the inner tuberosity of the *os calcis*, the other from the internal annular ligament and plantar fascia. *Insertion*, into the base of the first phalanx of the great toe, and into the internal sesamoid bone.

Relations.—By its *superficial surface* with the internal portion of the plantar fascia. By its *deep surface* with the flexor brevis pollicis, musculus accessorius, tendons of the flexor longus digitorum and flexor longus pollicis, tendons of the tibialis anticus and posticus, the plantar vessels and nerves and the tarsal bones. On its *outer border* with the flexor brevis digitorum, from which it is separated by a vertical septum of the plantar fascia.

The *Abductor minimi digiti* lies along the outer border of the foot. It *arises* from the outer tuberosity of the *os calcis*, and from the base of the metatarsal bone of the little toe, and is *inserted* into the base of the first phalanx of the little toe.

Relations.—By its *superficial surface* with the external portion of the plantar fascia. By its *deep surface* with the musculus acces-

sorius, flexor brevis minimi digiti, with the tarsal bones, and with the metatarsal bone of the little toe. By its *inner side* with the flexor brevis digitorum, from which it is separated by the vertical septum of the plantar fascia.

Fig. 107.

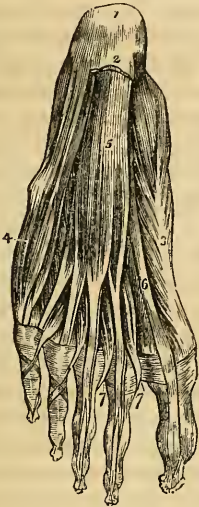
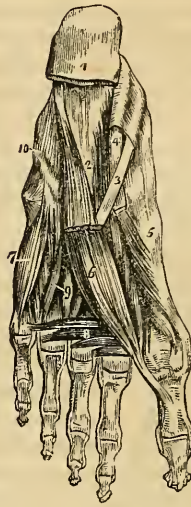


Fig. 108.



The *Flexor brevis digitorum* (perforatus) is placed between the two preceding muscles. It arises from the under surface of the os calcis and plantar fascia, and is inserted by four tendons into the base of the second phalanx of the four lesser toes. Each tendon divides, previously to its insertion, to give passage to the tendon of the long flexor; hence its cognomen *perforatus*.

Relations.—By its *superficial surface* with the plantar fascia. By its *deep surface* with a thin layer of fascia which separates it from the musculus accessorius, tendons of the flexor longus digitorum and flexor longus pollicis, and plantar vessels and nerves. By its *borders*

Fig. 107. The first layer of muscles in the sole of the foot; this layer is exposed by the removal of the plantar fascia. 1. The os calcis. 2. The posterior part of the plantar fascia divided transversely. 3. The abductor pollicis. 4. The abductor minimi digiti. 5. The flexor brevis digitorum. 6. The tendon of the flexor longus pollicis muscle. 7, 7. The lumbricales. On the second and third toes, the tendons of the flexor longus digitorum are seen passing through the bifurcation of the tendons of the flexor brevis digitorum.

Fig. 108. The third and a part of the second layer of muscles of the sole of the foot. 1. The divided edge of the plantar fascia. 2. The musculus accessorius. 3. The tendon of the flexor longus digitorum, previous to its division. 4. The tendon of the flexor longus pollicis. 5. The flexor brevis pollicis. 6. The adductor pollicis. 7. The flexor brevis minimi digiti. 8. The transversus pedis. 9. Interossei muscles, plantar and dorsal. 10. A convex ridge formed by the tendon of the peroneus longus muscle in its oblique course across the foot.

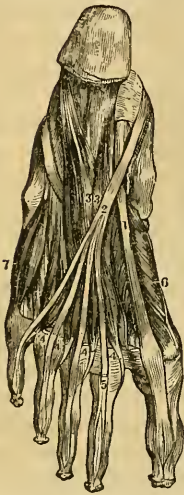with the vertical septa of the plantar fascia, which separate the muscle, on the one side from the abductor pollicis, and on the other from the abductor minimi digiti.

Second layer.

Musculus accessorius,
Lumbricales.

Dissection.—The three preceding muscles must be divided from their origin, and anteriorly through their tendons, and removed, in order to bring into view the second layer.

Fig. 109.



The *Musculus accessorius* arises by two slips from either side of the under surface of the os calcis; the inner slip being fleshy, the outer tendinous. The muscle is inserted into the outer side of the tendon of the flexor longus digitorum.

Relations.—By its *superficial surface* with the three muscles of the superficial layer, from which it is separated by their fascial sheaths, and with the external plantar vessels and nerves. By its *deep surface* with the under surface of the os calcis and the long calcaneo-cuboid ligament.

The *Lumbricales* (lumbricus, an earthworm) are four little muscles arising from the tibial side of the tendons of the flexor longus digitorum, and inserted into the expansion of the extensor tendons, and into the base of the first phalanx of the four lesser toes.

Relations.—By their *superficial surface* with the tendons of the flexor longus digitorum. By their *deep surface* with the third layer of muscles of the sole of the foot. They pass between the digital slips of the deep fascia to reach their insertion.

Third layer.

Flexor brevis pollicis,
Adductor pollicis,
Flexor brevis minimi digiti,
Transversus pedis.

Dissection.—The tendons of the long flexors and the muscles connected with them must be removed, to see clearly the attachments of the third layer.

Fig. 109. Deep-seated muscles in the sole of the foot. 1. Tendon of the flexor longus pollicis. 2. Tendon of the flexor communis digitorum pedis. 3. Flexor accessorius. 4, 4. Lumbricales. 5. Flexor brevis digitorum. 6. Flexor brevis pollicis pedis. 7. Flexor brevis minimi digiti pedis.

The *Flexor brevis pollicis* arises by a pointed tendinous process from the os calcis, the side of the cuboid, and from the external and middle cuneiform bones; and is *inserted* by two heads into the base of the first phalanx of the great toe. Two sesamoid bones are developed in the tendons of insertion of these two heads, and the tendon of the flexor longus pollicis lies in the groove between them.

Relations.—By its *superficial surface* with the abductor pollicis, tendon of the flexor longus pollicis, and plantar fascia. By its *deep surface* with the tarsal bones and their ligaments, the metatarsal bone of the great toe, and the insertion of the tendon of the peroneus longus. By its *inner border* with the abductor pollicis. By its *outer border* with the adductor pollicis.

The *Adductor pollicis* arises from the cuboid bone, from the sheath of the tendon of the peroneus longus, and from the base of the third and fourth metatarsal bones. It is *inserted* into the base of the first phalanx of the great toe.

Relations.—By its *superficial surface* with the tendons of the flexor longus and flexor brevis digitorum, the musculus accessorius, and lumbricales. By its *deep surface* with the tarsal bones and ligaments, the external plantar artery and veins, the interossei muscles, tendon of the peroneus longus, and metatarsal bone of the great toe. By its *inner border* with the flexor brevis pollicis.

The *Flexor brevis minimi digiti* arises from the base of the metatarsal bone of the little toe, and from the sheath of the tendon of the peroneus longus. It is *inserted* into the base of the first phalanx of the little toe.

Relations.—By its *superficial surface* with the tendons of the flexor longus and flexor brevis digitorum, the fourth lumbricalis, abductor minimi digiti, and plantar fascia. By its *deep surface* with the plantar interosseous muscle of the fourth metatarsal space, and the metatarsal bone.

The *Transversus pedis* arises by fleshy slips, from the heads of the metatarsal bones of the four lesser toes. Its tendon is *inserted* into the base of the first phalanx of the great toe.

Relations.—By its *superficial surface* with the tendons of the flexor longus and flexor brevis digitorum, and the lumbricales. By its *deep surface* with the interossei, and heads of the metatarsal bones.

Fourth layer.

Interossei plantares.

The *Plantar interossei* muscles are three in number, and are placed *upon* rather than between the metatarsal bones. They *arise* from the base of the metatarsal bones of the three outer toes, and are *inserted* into the inner side of the extensor tendon and base of the first phalanx of the same toes. In their action they are all *adductors*.

Relations.—By their *superficial surface* with the dorsal interossei

and the metatarsal bones. By their *deep surface* with the external plantar artery and veins with their branches, the adductor pollicis, transversus pedis, and flexor minimi digiti.

Fig. 110.

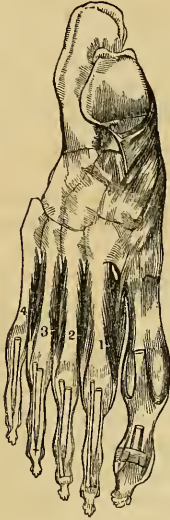

Fig. 111.



Actions.—All the preceding muscles act upon the toes; and the movements which they are capable of executing may be referred to four heads, viz. flexion, extension, adduction, and abduction. In these actions they are grouped in the following manner:

Flexion.

Flexor longus digitorum,
Flexor brevis digitorum,
Flexor accessorius,
Flexor minimi digiti.

Extension.

Extensor longus digitorum,
Extensor brevis digitorum.

Adduction.

Interossei, { one dorsal,
 { three plantar.

Abduction.

Interossei, three dorsal,
Abductor minimi digiti.

The great toe, like the thumb in the hand, enjoys an independent action, and is provided with distinct muscles to perform its move-

Fig. 110. Dorsal interossei. 1. Abductor secundi. 2. Adductor secundi. 3. Adductor tertii. 4. Adductor quarti.

Fig. 111. Plantar interossei. 1. Abductor tertii. 2. Abductor quarti. 3. Interosscous minimi digiti.

ments. These movements are precisely the same as those of the other toes, viz. :

Flexion.

Flexor longus pollicis,
Flexor brevis pollicis,

Extension.

Extensor proprius pollicis,
Extensor brevis digitorum.

Adduction.

Adductor pollicis.

Abduction.

Abductor pollicis.

The only muscles excluded from this table are the lumbricales, four small muscles, which from their attachments to the tendons of the long flexor, appear to be assistants to their action ; and the transversus pedis, a small muscle placed transversely in the foot across the heads of the metatarsal bones, which has for its office the drawing together of the toes.

CHAPTER IV.

ON THE FASCIÆ.

FASCIA (fascia, a bandage,) is the name assigned to laminæ of various extent and thickness, which are distributed through the different regions of the body, for the purpose of investing or protecting the softer and more delicate organs. From a consideration of their structure, these fasciæ may be arranged in three classes:—cellular fasciæ, cellulo-fibrous fasciæ, and tendino-fibrous fasciæ.

The *cellular fascia* is best illustrated in the common subcutaneous investment of the entire body, the superficial fascia. This structure is situated immediately beneath the integument over every part of the frame, and is the medium of connexion between that layer and the deeper parts. It is composed of cellular tissue containing in its areolæ a considerable abundance of adipose vesicles. The fat, being a bad conductor of caloric, serves to retain the warmth of the body, while it forms at the same time a yielding tissue, through which the minute vessels and nerves may pass to the papillary layer of the skin, without incurring the risk of obstruction from injury or pressure upon the surface. By dissection, the superficial fascia may be separated into *two layers*, between which are found the superficial or cutaneous vessels and nerves; as, the superficial epigastric artery, the saphenous veins, the radial and ulnar veins, the superficial lymphatic vessels, also the cutaneous muscles, as the platysma myoides, orbicularis palpebrarum, sphincter ani, &c. In some situations where the deposition of fat would have been injurious to the functions of the part, the cells of the cellular fascia are moistened by a serous exhalation, analogous to the secretion of serous membranes, as in the eyelids and scrotum.

The *cellulo-fibrous fascia* appears to result from a simple condensation of cellular tissue deprived of its fat, and intermingled with strong fibres disposed in various directions, so as to constitute an inelastic membrane of considerable strength. Of this structure is the deep fascia of the neck, some of the fasciæ of the cavities of the trunk, as the thoracic and transversalis fasciæ, and the sheaths of vessels.

The *tendino-fibrous fascia* is the strongest of the three kinds of investing membrane; it is composed of strong tendinous fibres, running parallel with each other, and connected by other fibres of the same kind passing in different directions. When freshly exposed, it is brilliant and nacreous, and is tough, inelastic, and unyielding. In the limbs it forms the deep fascia, enclosing and forming distinct

sheaths to all the muscles and tendons. It is thick upon the outer and least protected side of the limb, and thinner upon its inner side. It is firmly connected to the bones and to the prominent points of each region, as to the pelvis, knee, and ankle, in the lower, and to the clavicle, scapula, elbow, and wrist in the upper extremity. It assists the muscles in their action, by keeping up a tonic pressure on their surface; aids materially in the circulation of the fluids in opposition to the laws of gravity; and in the palm of the hand and sole of the foot is a powerful protection to the structures which enter into the formation of these regions. In some situations its tension is regulated by muscular action, as by the tensor vaginæ femoris and gluteus maximus in the thigh, by the biceps in the leg, and by the biceps and palmaris longus in the arm; in other situations it affords an extensive surface for the origin of the fibres of muscles.

The fascia may be arranged like the other textures of the body into—1. Those of the head and neck. 2. Those of the trunk. 3. Those of the upper extremity. 4. Those of the lower extremity.

FASCIÆ OF THE HEAD AND NECK.

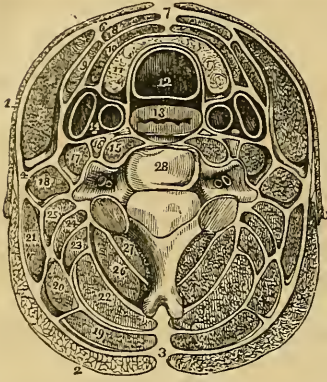
The *temporal fascia* is a strong tendino-fibrous membrane which covers in the temporal muscle at each side of the head, and gives origin by its internal surface to the superior muscular fibres. It is attached to the whole extent of the temporal ridge above, and to the zygomatic arch below; in the latter situation it is thick and divided into two layers, the external being connected to the upper border of the arch, and the internal to its inner surface. A small quantity of fat is usually found between these two layers, together with the orbital branch of the temporal artery.

The *superficial cervical fascia* contains between its layers the platysma myoides muscle.

The *deep cervical fascia* is a strong cellulo-fibrous layer which invests the muscles of the neck, and retains and supports the vessels and nerves. It commences posteriorly at the ligamentum nuchæ, and passes forwards at each side beneath the trapezius muscle to the posterior border of the sterno-mastoid; here it divides into two layers which embrace that muscle and unite upon its anterior border to be prolonged onwards to the middle line of the neck, where it becomes continuous with the fascia of the opposite side. Besides thus constituting a sheath for the sterno-mastoid, it also forms sheaths for the other muscles of the neck over which it passes. If the superficial layer of the sheath of the sterno-mastoid be traced upwards, it will be found to pass over the parotid gland and masseter muscle, and to be inserted into the zygomatic arch; and if it be traced downwards, it will be seen to pass in front of the clavicle and become lost upon the pectoralis major muscle. If the deep layer of the sheath be examined superiorly, it will be found attached

to the styloid process, from which it is reflected to the angle of the

Fig. 112.



lower jaw, forming the stylo-maxillary ligament; and if it be followed downwards, it will be found connected with the tendon of the omohyoid muscle, and may thence be traced behind the clavicle where it encloses the subclavius muscle, and being extended from the cartilage of the first rib to the coracoid process, constitutes the costo-coracoid membrane. In front of the sterno-mastoid muscle, the deep fascia is attached to the border of the lower jaw and os hyoides, and forms a distinct sheath for the sub-maxillary gland. Inferiorly it divides into two layers, one of which

passes in front of the sternum, while the other is attached to its superior border.

FASCIE OF THE TRUNK.

The *thoracic fascia** is a dense layer of cellulo-fibrous membrane stretched horizontally across the superior opening of the thorax. It is firmly attached to the concave margin of the first rib, and to the inner surface of the sternum. In front it leaves an opening for the connexion of the cervical with the thoracic portion of the thymus gland, and behind it forms an arch across the vertebral column, to give passage to the œsophagus.

At the point where the great vessels and trachea pass through the thoracic fascia, it divides into an ascending and descending layer. The *ascending layer* is attached to the trachea, and becomes continuous with the sheath of the carotid vessels, and with the deep

Fig. 112. A transverse section of the neck, showing the deep cervical fascia and its numerous prolongations, forming sheaths for the different muscles. As the figure is symmetrical, the figures of reference are placed only on one side. 1. The platysma myoides. 2. The trapezius. 3. The ligamentum nuchæ, from which the fascia may be traced forwards beneath the trapezius, enclosing the other muscles of the neck. 4. The point at which the fascia divides, to form a sheath for the sterno-mastoid muscle. 6. The point of reunion of the two layers of the sterno-mastoid sheath. 7. The point of union of the deep cervical fascia of opposite sides of the neck. 8. Section of the sterno-hyoid. 9. Omo-hyoid. 10. Sterno-thyroid. 11. The lateral lobe of the thyroid gland. 12. The trachea. 13. The œsophagus. 14. The sheath containing the common carotid artery, internal jugular vein, and pneumogastric nerve. 15. The longus colli. The nerve in front of the sheath of this muscle is the sympathetic. 16. The rectus anticus major. 17. Scalenus anticus. 18. Scalenus posticus. 19. The splenius capitis. 20. Splenius colli. 21. Levator anguli scapulæ. 22. Complexus. 23. Trachelo-mastoid. 24. Transversalis colli. 25. Cervicalis ascendens. 26. The semi-spinalis colli. 27. The multifidus spinæ. 28. A cervical vertebra. The transverse processes are seen to be traversed by the vertebral artery and vein.

* For an excellent description of this fascia, see Sir Astley Cooper's work on the "Anatomy of the Thymus Gland."

cervical fascia; the *descending layer* descends upon the trachea to its bifurcation, surrounds the large vessels arising from the arch of the aorta, and the upper part of the arch itself, and is continuous with the fibrous layer of the pericardium. It is connected also with the venæ innominatæ and superior cava, and is attached to the cellular capsule of the thymus gland.

“The thoracic fascia,” writes Sir Astley Cooper, “performs three important offices:

“1st. It forms the upper boundary of the chest, as the diaphragm does the lower.

“2nd. It steadily preserves the relative situation of the parts which enter and quit the thoracic opening.

“3d. It attaches and supports the heart in its situation, through the medium of its connexion with the aorta and large vessels which are placed at its curvature.”

ABDOMINAL FASCIÆ.

The lower part of the parietes of the abdomen, and the cavity of the pelvis, are strengthened by a layer of fascia which lines their internal surface, and at the bottom of the latter cavity is reflected inwards to the sides of the bladder. This fascia is continuous throughout the whole of the surface; but for convenience of description it is considered under the several names of transversalis fascia, iliac fascia, and pelvic fascia; the two former meet at the crest of the ilium, and Poupart's ligament, and the latter is confined to the cavity of the true pelvis.

The *fascia transversalis* (Fascia Cooperi)* is a cellulo-fibrous lamella which lines the inner surface of the transversalis muscle. It is thick and dense below, near the lower part of the abdomen; but becomes thinner as it ascends, and is gradually lost in the subserous cellular tissue. It is attached inferiorly to the reflected margin of Poupart's ligament and to the crest of the ilium; internally, to the border of the rectus muscle; and at the inner third of the femoral arch, is continued beneath Poupart's ligament, and forms the anterior segment of the crural canal, or sheath of the femoral vessels.

The internal abdominal ring is situated in this fascia, at about midway between the spine of the os pubis, and the anterior superior spine of the ilium, and half an inch above Poupart's ligament; it is bounded upon its inner side by a well-marked falciform border, but is ill defined around its outer margin. From the circumference of this ring is given off an infundibuliform process which surrounds the testicle and spermatic cord, constituting the fascia propria of the latter, and forms the first investment to the sac of oblique inguinal hernia. It is the strength of this fascia, in the interval between the head of the rectus and the internal abdominal ring, that defends this

* Sir Astley Cooper first described this fascia in its important relation to inguinal hernia.

portion of the parietes from the frequent occurrence of direct inguinal hernia.

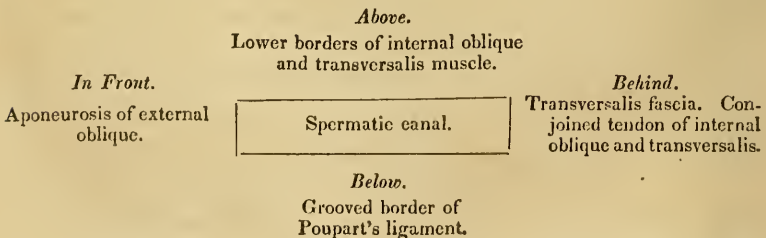
INGUINAL HERNIA.

Inguinal hernia is of two kinds, oblique, and direct.

In *oblique inguinal hernia* the intestine escapes from the cavity of the abdomen into the spermatic canal, through the *internal abdominal ring*, pressing before it a pouch of peritoneum which constitutes the *hernial sac*, and distending the infundibuliform process of the transversalis fascia. After emerging through the internal abdominal ring, it passes *first* beneath the lower and arched border of the transversalis muscle; *then* beneath the lower border of the internal oblique muscle; and *finally* through the external abdominal ring in the aponeurosis of the external oblique. From the transversalis muscle it receives no investment; while passing beneath the lower border of the internal oblique it obtains the cremaster muscle; and, upon escaping at the external abdominal ring, receives the intercolumnar fascia. So that the coverings of an oblique inguinal hernia, after it has emerged through the external abdominal ring, are, from the surface to the intestine, the

Integument,
Superficial fascia,
Intercolumnar fascia,
Cremaster muscle,
Transversalis, or infundibuliform fascia,
Peritoneal sac.

The spermatic canal, which, in the normal condition of the abdominal parietes serves for the passage of the spermatic cord in the male, and the round ligament with its vessels in the female, is about one inch and a half in length. It is bounded *in front* by the aponeurosis of the external oblique muscle; *behind* by the transversalis fascia, and by the conjoined tendon of the internal oblique and transversalis muscle; *above* by the arched borders of the internal oblique and transversalis; *below* by the grooved border of Poupart's ligament; and at each extremity by one of the abdominal rings, the internal ring at the inner termination, the external ring at the outer extremity. These relations may be more distinctly illustrated by the following plan—



There are three varieties of oblique inguinal hernia :—common, congenital, and encysted.

Common oblique hernia is that which has been described above.

Congenital hernia results from the nonclosure of the pouch of peritoneum carried downwards into the scrotum by the testicle, during its descent in the fœtus.

The intestine at some period of life is forced into this canal, and descends through it into the tunica vaginalis where it lies in contact with the testicle ; so that congenital hernia has no proper sac, but is contained within the tunica vaginalis. The other coverings are the same as those of common inguinal hernia.

Encysted hernia (*hernia infantilis*, of Hey) is that form of protrusion in which the pouch of peritoneum forming the tunica vaginalis, being only partially closed, and remaining open externally to the abdomen, admits of the hernia passing into the scrotum, behind the tunica vaginalis. So that the surgeon in operating upon this variety, requires to divide three layers of serous membrane ; the first and second layers being those of the tunica vaginalis ; and the third, the true sac of the hernia.

*Direct inguinal hernia** has received its name from passing *directly* through the external abdominal ring, and forcing before it the opposing parietes. This portion of the wall of the abdomen is strengthened by the conjoined tendon of the internal oblique and transversalis muscle, which is pressed before the hernia, and forms one of its investments. Its coverings are, the

Integument,
Superficial fascia,
Intercolumnar fascia,
Conjoined tendon,
Transversalis fascia,
Peritoneal sac.

Direct inguinal hernia differs from oblique in never attaining the same bulk, in consequence of the resisting nature of the conjoined tendon of the internal oblique and transversalis and of the transversalis fascia ; in its direction, having a tendency to protrude from the middle line rather than towards it. Thirdly, in making for itself a new passage through the abdominal parietes, instead of following a natural channel ; and fourthly, in the relation of the neck of its sac to the epigastric artery : that vessel lying to the outer side of the opening of the sac of direct hernia, and to the inner side of oblique hernia.

All the forms of inguinal hernia are designated *scrotal*, when they have descended into that cavity.

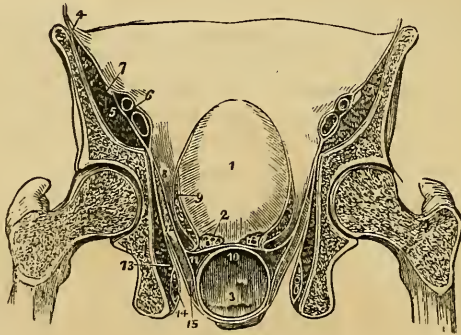
The *fascia iliaca* is the tendino-fibrous investment of the psoas and iliacus muscles ; and, like the fascia transversalis, is thick below, and becomes gradually thinner as it ascends. It is attached

* Also known by the name *ventro-inguinal* hernia.—G.

superiorly along the edge of the psoas, to the anterior lamella of the aponeurosis of the transversalis muscle, to the ligamentum arcuatum internum, and to the bodies of the lumbar vertebræ, leaving arches corresponding with the constricted portions of the vertebræ for the passage of the lumbar vessels. Lower down it passes beneath the external iliac vessels, and is attached along the margin of the true pelvis; externally, it is connected to the crest of the ilium; and, inferiorly, to the outer two-thirds of Poupart's ligament, where it is continuous with the fascia transversalis. Passing beneath Poupart's ligament, it surrounds the psoas and iliacus muscles to their termination, and beneath the inner third of the femoral arch forms the posterior segment of the sheath of the femoral vessels.

The *fascia pelvica* is attached to the inner surface of the os pubis and along the margin of the brim of the pelvis, where it is continuous with the iliac fascia. From this extensive origin it descends into the pelvis, and divides into two layers, the pelvic and obturator.

Fig. 113.



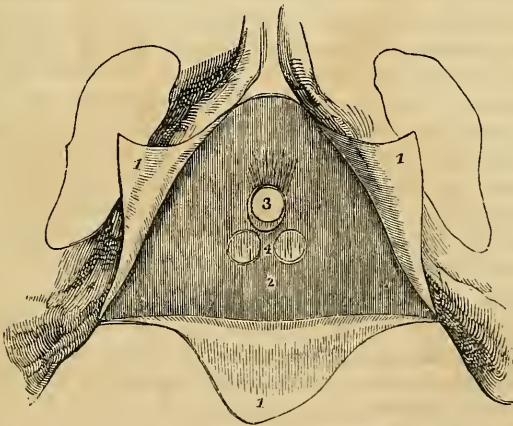
The *pelvic layer* or *fascia*, when traced from the internal surface of the os pubis near to the symphysis, is seen to be reflected inwards to the neck of the bladder, so as to form the *anterior vesical ligaments*. Traced backwards, it passes between the sacral plexus of nerves and the internal iliac vessels, and is attached to the anterior surface of the sacrum; and followed from the sides of the pelvis, it descends to the base of the bladder and divides into three layers, one *ascending*, is reflected to the side of that viscus, encloses the

Fig. 113. A transverse section of the pelvis, showing the distribution of the pelvic fascia. 1. The bladder. 2. The vesiculæ seminales divided across. 3. The rectum. 4. The iliac fascia covering in the iliacus and psoas muscles (5); and forming a sheath for the external iliac vessels (6). 7. The anterior crural nerve excluded from the sheath. 8. The pelvic fascia. 9. Its ascending layer, forming the lateral ligament of the bladder of one side, and a sheath to the vesical plexus of veins. 10. The recto-vesical fascia of Mr. Tyrrell formed by the middle layer. 11. The inferior layer surrounding the rectum and meeting at the middle line with the fascia of the opposite side. 12. The levator ani muscle. 13. The obturator internus muscle, covered in by the obturator fascia, which also forms a sheath for the internal pudic vessels and nerve (14). 15. The layer of fascia which invests the under surface of the levator ani muscle, the anal fascia.

vesical plexus of veins, and forms the lateral ligaments of the bladder. A *middle layer* passes inwards between the base of the bladder and the upper surface of the rectum, and is named by Mr. Tyrrell the *recto-vesical fascia*; and an *inferior layer* passes behind the rectum, and, with the layer of the opposite side, completely invests that intestine.

The *obturator fascia* passes directly downwards from the splitting of the layers of the pelvic fascia, and covers in the obturator internus muscle and the internal pudic vessels and nerve; it is attached to the ramus of the os pubis and ischium in front, and below to the falciform margin of the great sacro-ischiatic ligament. Lying between these two layers of fascia is the levator ani muscle, which arises from their angle of separation. The levator ani is covered in inferiorly by a third layer of fascia, which is given off by the obturator fascia, and is continued downwards upon the inferior surface of the muscle to the extremity of the rectum, where it is lost. This layer may be named from its position and inferior attachment the *anal fascia*.

Fig. 114.



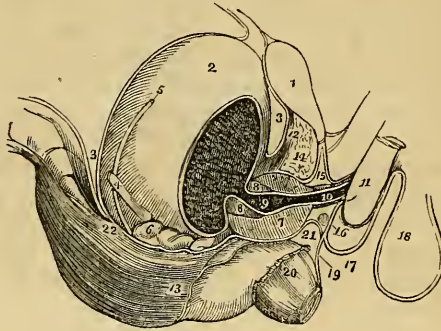
In the perineum there are two fasciæ of much importance, the superficial and deep perineal fascia.

The *superficial perineal fascia* is a thin tendino-fibrous layer, which covers in the muscles of the genital portion of the perineum and the root of the penis. It is firmly attached at each side to the

Fig. 114. The pubic arch with the attachments of the perineal fasciæ. 1, 1, 1. The superficial fascia divided by a V shaped incision into three flaps; the lateral flaps are turned over the ramus of the os pubis and ischium at each side, to which they are firmly attached; the posterior flap is continuous with the deep perineal fascia. 2. The deep perineal fascia. 3. The opening for the passage of the membranous portion of the urethra, previously to entering the bulb. 4. Two projections of the anterior layer of the deep perineal fascia, corresponding with Cowper's glands.

ramus of the os pubis and ischium ; posteriorly it is reflected backwards beneath the transversus perinei muscles to become connected with the deep perineal fascia ; while anteriorly it is continuous with the dartos of the scrotum.

Fig. 115.



The *deep perineal fascia* (Camper's ligament, triangular ligament) is situated behind the root of the penis, and is firmly stretched across between the ramus of the os pubis and ischium of each side so as to constitute a strong septum of defence to the outlet of the pelvis. At its inferior border it divides into two layers, one of which is continued forwards, and is continuous with the superficial perineal fascia ; while the other is prolonged backwards to the rectum, and joining with the anal fascia assists in supporting the extremity of that intestine. The deep perineal fascia is composed of two layers, which are separated from each other by several important parts, and traversed by the membranous portion of the urethra. The ante-

Fig. 115. A side view of the viscera of the pelvis, showing the distribution of the perineal and pelvic fasciæ. 1. The symphysis pubis. 2. The bladder. 3. The recto-vesical fold of peritoneum, passing from the anterior surface of the rectum to the posterior part of the bladder ; from the upper part of the fundus of the bladder it is reflected upon the abdominal parietes. 4. The ureter. 5. The vas deferens crossing the direction of the ureter. 6. The vesicula seminalis of the right side. 7, 7. The prostate gland divided by a longitudinal section. 8, 8. The section of a ring of elastic tissue encircling the prostatic portion of the urethra at its commencement. 9. The prostatic portion of the urethra. 10. The membranous portion, enclosed by the compressor urethræ muscle. 11. The commencement of the corpus spongiosum penis, the bulb. 12. The anterior ligaments of the bladder formed by the reflection of the pelvic fascia, from the internal surface of the os pubis to the neck of the bladder. 13. The edge of the pelvic fascia at the point where it is reflected upon the rectum. 14. An interval between the pelvic fascia and deep perineal fascia, occupied by a plexus of veins. 15. The deep perineal fascia ; its two layers. 16. Cowper's gland of the right side situated between the two layers below the membranous portion of the urethra. 17. The superficial perineal fascia ascending in front of the root of the penis to become continuous with the dartos of the scrotum (18). 19. The layer of the deep fascia which is prolonged to the rectum. 20. The lower part of the levator ani ; its fibres are concealed by the anal fascia. 21. The inferior segment of the funnel-shaped process given off from the posterior layer of the deep perineal fascia, which is continuous with the recto-vesical fascia of Tyrrell. The attachment of this fascia to the recto-vesical fold of peritoneum is seen at 22.

rior layer is nearly plane in its direction, and sends a sheath forwards around the anterior termination of the membranous urethra to be attached to the posterior part of the bulb. The posterior layer is oblique and sends a funnel-shaped process backwards, which invests the commencement of the membranous urethra and the prostate gland. The inferior segment of this funnel-shaped process is continued backwards beneath the prostate gland and the vesiculæ seminales, and is continuous with the recto-vesical fascia of Tyrrell, which is attached posteriorly to the recto-vesical fold of peritoneum, and serves the important office of retaining that duplicature in its proper situation.

Between the two layers of the deep perineal fascia are situated, therefore, the whole extent of the membranous portion of the urethra, the compressor urethræ muscle, Cowper's glands, the internal pudic and bulbous arteries, and a plexus of veins. Mr. Tyrrell considers the anterior lamella alone as the deep perineal fascia, and the posterior lamella as a distinct layer of fascia covering in a considerable plexus of veins.

FASCIÆ OF THE UPPER EXTREMITY.

The *superficial fascia* of the upper extremity contains between its layers the superficial veins and lymphatics, and the superficial nerves.

The *deep fascia* is thin over the deltoid and pectoralis major muscles, and in the axillary space, but thick upon the dorsum of the scapula, where it binds down the infra-spinatus muscle. It is attached to the clavicle, acromion process, and spine of the scapula. In the upper arm it is somewhat stronger, and is inserted into the condyloid ridges, forming the intermuscular septa. In the fore-arm it is very strong, and at the bend of the elbow its thickness is augmented by a broad band, which is given off from the inner side of the tendon of the biceps. It is firmly attached to the olecranon process, to the ulna, and to the prominent points about the wrist. Upon the front of the wrist it is continuous with the anterior annular ligament, which is considered by some anatomists to be formed by the deep fascia, but which I am more disposed to regard as a ligament of the wrist. On the posterior aspect of this joint it forms a strong transverse band, the *posterior annular ligament*, beneath which the tendons of the extensor muscles pass, in distinct sheaths.

The tendons as they pass beneath the annular ligaments are surrounded by synovial bursæ. The dorsum of the hand is invested by a thin fascia, which is continuous with the posterior annular ligament.

The *palmar fascia* is divided into three portions. A central portion, which occupies the middle of the palm, and two lateral portions, which spread out over the sides of the hand, and are continuous with the dorsal fascia. The central portion is strong and tendinous; it is narrow at the wrist, where it is attached to the annular liga-

ment, and broad over the heads of the metacarpal bones, where it divides into eight slips, which are inserted into the sides of the bases of the phalanges of each finger. The fascia is strengthened at its point of division into slips by strong fasciculi of transverse fibres, and the arched interval left between the slips gives passage to the tendons of the flexor muscles. The arches between the fingers transmit the digital vessels and nerves, and lumbricales muscles.

FASCIAE OF THE LOWER EXTREMITY.

The *superficial fascia* contains between its two layers the superficial vessels and nerves of the lower extremity. At the groin these two layers are separated from each other by the superficial lymphatic glands, and the deeper layer is attached to Poupart's ligament, while the superficial layer is continuous with the superficial fascia of the abdomen.

The *deep fascia* of the thigh is named, from its great extent, the *fascia lata*; it is thick and strong upon the outer side of the limb, and thinner upon its inner and posterior side. That portion of fascia which invests the gluteus maximus is very thin, but that which covers in the gluteus medius is excessively thick, and gives origin, by its inner surface, to the superficial fibres of that muscle. The fascia lata is attached superiorly to Poupart's ligament, the crest of the ilium, sacrum, coccyx, tuberosity of the ischium, ramus of the ischium and os pubis and body of the os pubis; in the thigh it is inserted into the linea aspera, and around the knee is connected with the prominent points of that joint. It possesses also two muscular attachments,—by means of the tensor vaginæ femoris, which is inserted between its two layers on the outer side, and the gluteus maximus which is attached to it behind.

In addition to the smaller openings in the fascia lata which transmit the small cutaneous vessels and nerves, there exists at the upper and inner extremity of the thigh an oblique foramen, which gives passage to the superficial lymphatic vessels, and the large subcutaneous vein of the lower extremity, the internal saphenous vein, and is thence named the *saphenous opening*. The existence of this opening has given rise to the division of the upper part of the fascia lata into two portions, an iliac portion and a pubic portion.

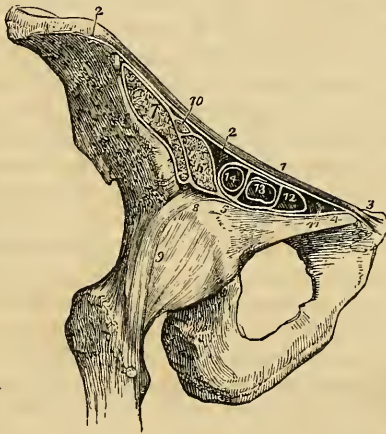
The *iliac portion* is situated upon the iliac side of the opening. It is attached to the crest of the ilium, and along Poupart's ligament to the spine of the os pubis, where it is reflected downwards and outwards in an arched direction, and forms a falciform border, which constitutes the outer boundary of the saphenous opening. The edge of this border immediately overlies, and is reflected upon, the sheath of the femoral vessels, and the lower extremity of the curve is continuous with the pubic portion.

The *pubic portion*, occupying the pubic side of the saphenous opening, is attached to the spine of the os pubis and pectineal line; and, passing outwards behind the sheath of the femoral vessels,

divides into two layers; the anterior layer is continuous with that portion of the iliac fascia which forms the sheath of the iliacus and psoas muscles, and the posterior layer is lost upon the capsule of the hip-joint.

The interval between the falciform border of the iliac portion and the opposite surface of the pubic portion is closed by a fibrous layer, which is pierced by numerous openings for the passage of lymphatic vessels, and is thence named *cribriform fascia*. The cribriform fascia is connected with the sheath of the femoral vessels, and forms one of the coverings of femoral hernia. When the iliac portion of the fascia lata is removed from its attachment to Poupart's ligament and is turned aside, the sheath of the femoral vessels (the *femoral* or *crural canal*) is brought into view; and if Poupart's ligament be

Fig. 116.



carefully divided, the sheath may be isolated, and its continuation with the transversalis and iliac fascia clearly demonstrated. In this view the sheath of the femoral vessels is an infundibuliform continuation of the abdominal fasciæ, closely adherent to the vessels, a little way down the thigh, but much larger than the vessels it contains at

Fig. 116. A section of the structures which pass beneath the femoral arch. 1. Poupart's ligament. 2, 2. The iliac portion of the fascia lata, attached along the margin of the crest of the ilium, and along Poupart's ligament, as far as the spine of the os pubis (3). 4. The pubic portion of the fascia lata, continuous at 3 with the iliac portion, and passing outwards behind the sheath of the femoral vessels to its outer border at 5, where it divides into two layers; one is continuous with the sheath of the psoas (6) and iliacus (7); the other (8) is lost upon the capsule of the hip-joint (9). 10. The femoral nerve, enclosed in the sheath of the psoas and iliacus. 11. Gimbernat's ligament. 12. The femoral ring, within the femoral sheath. 13. The femoral vein. 14. The femoral artery: the two vessels and the ring are surrounded by the femoral sheath, and thin septa are sent between the anterior and posterior wall of the sheath, dividing the artery from the vein, and the vein from the femoral ring.

Poupart's ligament. If the sheath be opened, the artery and vein will be found lying side by side, and occupying the outer two-thirds of the sheath, leaving an infundibuliform interval between the vein and the inner wall of the sheath. The superior opening of this space is named the *femoral ring*; it is bounded in front by Poupart's ligament, behind by the os pubis, internally by Gimbernat's ligament, and externally by the femoral vein. The interval itself serves for the passage of the superficial lymphatic vessels from the saphenous opening to a lymphatic gland, which generally occupies the femoral ring; and from thence they proceed into the current of the deep lymphatics. The femoral ring is closed merely by a thin layer of subserous cellular tissue,* which retains the lymphatic gland in its position, and is named *septum crurale*; and by the peritoneum. It follows from this description, that the femoral ring must be a weak point in the parietes of the abdomen, particularly in the female, where the *femoral arch*, or space included between Poupart's ligament and the border of the pelvis, is larger than in the male, while the structures which pass through it are smaller. It happens consequently, that if violent or continued pressure be made upon the abdominal viscera, a portion of intestine may be forced through the femoral ring into the infundibuliform space in the sheath of the femoral vessels, carrying before it the peritoneum and the septum crurale,—this constitutes *femoral hernia*. If the causes which give rise to the formation of this hernia continue, the intestine, unable to extend further down the sheath, from its close connexion to the vessels, will in the next place be forced forwards through the saphenous opening in the fascia lata, carrying before it two additional coverings, the sheath of the vessels, or fascia propria, and the cribriform fascia, and then curving upwards over Poupart's ligament, will become placed beneath the superficial fascia and integument.

The direction which femoral hernia takes in its descent is at first *downwards*, then *forwards*, and then *upwards*; and in endeavouring to reduce it, the application of the taxis must have reference to this course, and be directed in precisely the reverse order. The coverings of femoral hernia are the

Integument,
Superficial fascia,
Cribriform fascia,
Fascia propria,
Septum crurale,
Peritoneal sac.

The *fascia of the leg* is strong in the anterior tibial region, and gives origin by its inner surface to the upper part of the tibialis anticus, and extensor longus digitorum muscles.

* This cellular tissue is sometimes very considerably thickened by a deposit of fat within its cells, and forms a thick stratum over the hernial sac.

It is firmly attached to the tibia and fibula at each side, and becomes thickened inferiorly into a narrow band, the *anterior annular ligament*, beneath which the tendons of the extensor muscles pass into the dorsum of the foot in distinct sheaths, lined by synovial bursæ. Upon the outer side it forms a distinct sheath which envelopes the peronei muscles, and ties them to the fibula. The anterior annular ligament is attached by one extremity to the outer side of the os calcis, and divides in front of the joint into two bands; one of which is inserted into the inner malleolus, while the other spreads over the inner side of the foot, and becomes continuous with the internal portion of the plantar fascia.

The *fascia of the dorsum of the foot* is a thin layer given off from the lower border of the anterior annular ligament; it is continuous at each side with the lateral portions of the plantar fascia.

The *fascia of the posterior part of the leg* is much thinner than the anterior, and consists of two layers, superficial and deep. The *superficial* layer is continuous with the posterior fascia of the thigh, and is increased in thickness upon the outer side of the leg by an expansion derived from the tendon of the biceps; it terminates inferiorly in the external and internal annular ligaments. The *deep layer* is stretched across between the tibia and fibula, and forms the *intermuscular fascia* between the superficial and deep layer of muscles. It covers superiorly the popliteus muscle, receiving a tendinous expansion from the semi-membranosus muscle, and is attached to the oblique line of the tibia.

The *internal annular ligament* is a strong fibrous band attached above to the internal malleolus, and below to the side of the inner tuberosity of the os calcis. It is continuous above with the posterior fascia of the leg, and below with the plantar fascia, forming sheaths for the passage of the flexor tendons and vessels, into the sole of the foot.

The *external annular ligament*, shorter than the internal, extends from the extremity of the outer malleolus to the side of the os calcis, and serves to bind down the tendons of the peronei muscles in their passage beneath the external ankle.

The *plantar fascia* consists of three portions, a middle and two lateral.

The *middle portion* is thick and dense, and is composed of strong tendinous fibres, closely interwoven with each other. It is attached posteriorly to the inner tuberosity of the os calcis, and terminates under the heads of the metatarsal bones in five fasciculi. Each of these fasciculi divides into two slips, which are inserted into each side of the bases of the first phalanges of the toes, leaving an interval between them for the passage of the flexor tendons. The point of division of this fascia into fasciculi and slips, is strengthened by transverse bands, which preserve the solidity of the fascia at its broadest part. The intervals between the toes give passage to the digital arteries and nerves and the lumbricales muscles.

The *lateral portions* are thin, and cover the sides of the sole of

the foot ; they are continuous behind with the internal and external annular ligaments ; on the inner side with the middle portion, and externally with the dorsal fascia.

Besides constituting a strong layer of investment and defence to the soft parts situated in the sole of the foot, these three portions of fascia send processes inwards, which form sheaths for the different muscles. A strong septum is given off from each side of the middle portion of the plantar fascia, which is attached to the tarsal bones, and divides the muscles into three groups, a middle and two lateral ; and transverse septa are stretched between these to separate the layers. The superficial layer of muscles derive a part of their origin from the plantar fascia.

CHAPTER V.

ON THE ARTERIES.

THE arteries are the cylindrical tubes which convey the blood from the ventricles of the heart to every part of the body. They are dense in structure, and preserve for the most part the cylindrical form when emptied of their blood, which is their condition after death: hence they were considered by the ancients, as the vessels for the transmission of the vital spirits,* and were therefore named arteries (*ἀρῆς τρεψίν*, to contain air).

The artery proceeding from the left ventricle of the heart contains the pure or arterial blood, which is distributed throughout the entire system, and constitutes with its returning veins the *greater* or *systemic circulation*. That which emanates from the right ventricle, conveys the impure blood to the lungs; and with its corresponding veins establishes the *lesser* or *pulmonary circulation*.

The whole of the arteries of the systemic circulation proceed from a single trunk, named the *aorta*, from which they are given off as branches, and divide and subdivide to their ultimate ramifications, constituting the great arterial tree which pervades by its minute subdivisions every part of the animal frame. The mode in which the division into branches takes place is deserving of remark. From the aorta the branches, for the most part, pass off at right angles, as if for the purpose of checking the impetus with which the blood would otherwise rush along their cylinders from the main trunk; but in the limbs a very different arrangement is adopted; the branches are given off from the principal artery at an acute angle, so that no impediment may be offered to the free circulation of the vital fluid. The division of arteries is usually dichotomous, as of the aorta into the two common iliacs, common carotid into the external and internal, &c.; but in some few instances a short trunk divides suddenly into several branches which proceed in different directions; this mode of division is termed an *axis*, as the thyroid and celiac axis.

In the division of an artery into two branches, it is observed that the combined area of the two branches are greater than that of the single trunk; and if the combined area of all the branches at the periphery of the body were compared with that of the aorta, it would be seen that the blood, in passing from the aorta into the

* To Galen is due the honour of having discovered that arteries contained blood, and not air.

numerous distributing branches, was flowing through a conical tube of which the apex might be represented by the aorta, and the base by the surface of the entire body. The advantage of this important principle in facilitating the circulation is sufficiently obvious; for the increased channel which is thus provided for the current of the blood, serves to compensate the retarding influence of friction, resulting from the distance of the heart and the division of the vessels.

Communications between arteries are very free and numerous, and increase in frequency with the diminution in the size of the branches; so that through the medium of the minute ramifications, the entire body may be considered as one uninterrupted circle of *inosculations* or *anastomoses* (ἀνά between, στόμα mouth). This increase in the frequency of anastomosis in the smaller branches is a provision for counteracting the greater liability to impediment existing in them than in the larger branches. Where freedom of circulation is of vital importance, this communication of the arteries is very remarkable, as in the circle of Willis in the cranium, or in the distribution of the arteries of the heart. It is also strikingly seen in situations where obstruction is most likely to occur, as in the distribution to the alimentary canal, around joints, or in the hand and foot. Upon this free communication existing every where between arterial branches is founded the principle of cure in the ligature of large arteries; the ramifications of the branches given off from the artery above the ligature inosculate with those which proceed from the trunk of the vessel below the ligature; these anastomosing branches enlarge and constitute a *collateral circulation*, in which, as is shown in the beautiful preparations made by Sir Astley Cooper, several large branches perform the office of the single obliterated trunk.*

The arteries do not terminate directly in veins; but in an intermediate system of vessels, which, from their minute size, are termed *capillaries* (capillus, a hair). The capillaries constitute a microscopic network, which is distributed through every part of the body, so as to render it impossible to introduce the smallest needle-point beneath the skin without wounding several of these fine vessels. It is through the medium of the capillaries that all the phenomena of nutrition and secretion are performed. They are remarkable for their uniformity of diameter, and for the constant divisions and communications which take place between them without any alteration of size. They inosculate on one hand with the terminal ramusculi of the arteries; and on the other with the minute radicles of the veins.

Arteries are composed of three coats, external, middle, and internal. The *external* or *cellular coat* is firm and strong, and serves at the same time as the chief means of resistance of the vessel, and

* I have a preparation, showing the collateral circulation in a dog, in whom I tied the abdominal aorta; the animal died from over-feeding nearly two years after the operation.

of connexion to surrounding parts. It consists of condensed cellular tissue, strengthened by an interlacement of glistening fibres which partially encircle the cylinder of the tube in an oblique direction. Upon the surface the cellular tissue is loose, to permit of the movements of the artery in distention and contraction.

The *middle* or *fibrous coat* is composed of yellowish fibres of elastic tissue, which are disposed in an oblique direction around the cylinder of the vessel, and cross each other in their course. This coat is elastic and fragile, and thicker than the external coat. Its elasticity enables the vessel to accommodate itself to the quantity of blood which it may contain; its fragility is exhibited in some cases of aneurism, and in the division of the two internal coats of an artery by a ligature.

The *internal coat* is a thin serous membrane which lines the interior of the artery, and gives it the smooth polish which that surface presents. It is continuous with the lining membrane of the heart, and through the medium of the capillaries with the venous system. The internal is connected to the fibrous coat by a close cellular tissue, which is very liable to disease and depositions of various kinds; and is the seat of the first changes which precede aneurism. The researches of Henle have demonstrated an epithelium, composed of vesicles and scales, with central nuclei, upon the surface of this internal coat, analogous to the epithelium of serous and mucous membranes.

The arteries in their distribution through the body are included in a loose cellular investment which separates them from the surrounding tissues, and is called a *sheath*. Around the principal vessels the sheath is an important structure; it is composed of cellulofibrous tissue, intermingled with tendinous fibres, and is continuous with the fasciæ of the region in which the arteries are situated, as with the thoracic and cervical fasciæ in the neck, transversalis and iliac fasciæ, and fascia lata in the thigh, &c. The sheath of the arteries contains also their accompanying veins, and sometimes a nerve.

The coats of arteries are supplied with blood like other organs of the body, and the vessels which are distributed to them are named *Vasa vasorum*. They are also provided with nerves; but the mode of distribution of the nerves is at present undiscovered.

In the consideration of the arteries, we shall first describe the aorta, and the branches of that trunk, with their subdivisions, which together constitute the efferent portion of the systemic circulation; and then the pulmonary artery as the efferent trunk of the pulmonary circulation.

AORTA.

The *Aorta* arises from the left ventricle, at the middle of the root of the heart, opposite the articulation of the fourth costal cartilage with the sternum. At its commencement it presents three dilata-

tions, called the sinus aortici, which correspond with the semilunar valves. It ascends at first to the right, then curves backwards and to the left, and descends on the left side of the vertebral column to the fourth lumbar vertebra. Hence it is divided into—ascending—arch—and descending aorta.

Relations.—The *ascending aorta* has in relation with it, *in front*, the trunk of the pulmonary artery, thoracic fascia, and pericardium; *behind*, the right pulmonary veins and artery; to the *right side*, the right auricle and superior cava; and to the *left*, the left auricle and the trunk of the pulmonary artery.

Fig. 117.

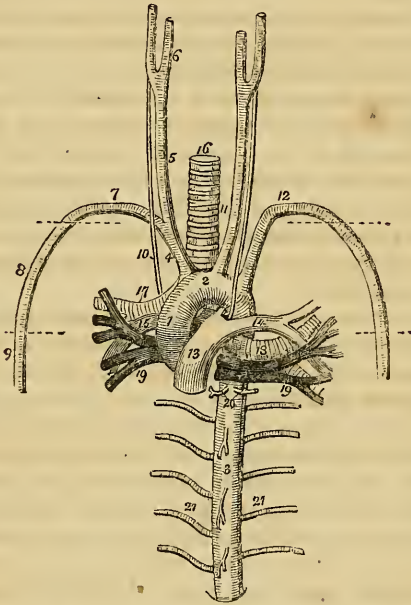
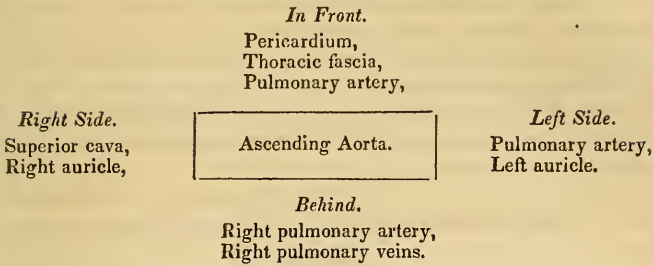


Fig. 117. The large vessels which proceed from the root of the heart, with their relations; the heart has been removed. 1. The ascending aorta. 2. The arch. 3. The thoracic portion of the descending aorta. 4. The arteria innominata dividing into, 5, the right carotid, which again divides at 6, into the external and internal carotid; and 7, the right subclavian artery. 8. The axillary artery; its extent is designated by a dotted line. 9. The brachial artery. 10. The right pneumogastric nerve running by the side of the common carotid, in front of the right subclavian artery, and behind the root of the right lung. 11. The left common carotid, having to its outer side the left pneumogastric nerve, which crosses the arch of the aorta, and as it reaches its lower border is seen to give off the left recurrent nerve. 12. The left subclavian artery becoming axillary, and brachial in its course, like the artery of the opposite side. 13. The trunk of the pulmonary artery connected to the concavity of the arch of the aorta by a fibrous cord, the remains of the ductus arteriosus. 14. The left pulmonary artery. 15. The right pulmonary artery. 16. The trachea. 17. The right bronchus. 18. The left bronchus. 19, 19. The pulmonary veins. 17, 15, and 19, on the right side, and 14, 18, and 19, on the left, constitute the roots of the corresponding lungs, and the relative position of these vessels is carefully preserved. 20. Bronchial arteries. 21, 21, Intercostal arteries; the branches from the front of the aorta above and below the number 3 are pericardiac and œsophageal branches.

Plan of the *relations* of the ascending Aorta.



Arch.—The upper border of the arch is parallel with the upper border of the second sterno-costal articulation of the right side in front, and the second dorsal vertebra behind, and terminates opposite the lower border of the third.

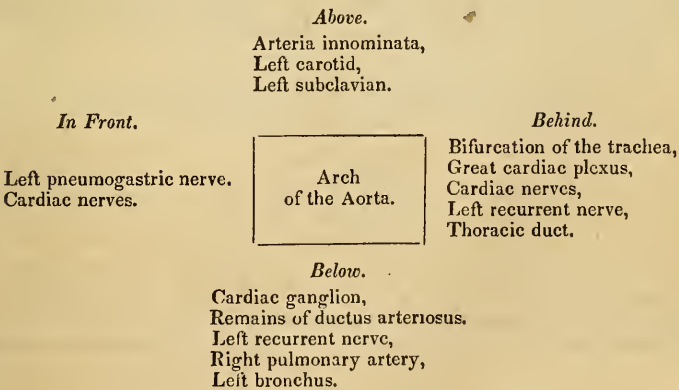
The *anterior surface* of the arch is crossed by the left pneumogastric nerve, and by the cardiac branches of that nerve, and of the sympathetic.

The *posterior surface* of the arch is in relation with the bifurcation of the trachea and great cardiac plexus, the cardiac nerves, left recurrent nerve, and the thoracic duct.

The *superior border* gives off the three great arteries, viz. the innominate, left carotid, and left subclavian.

The *inferior border*, or concavity of the arch, is in relation with the remains of the ductus arteriosus, the cardiac ganglion and left recurrent nerve, and has passing beneath it the right pulmonary artery and left bronchus.

Plan of the *relations* of the arch of the Aorta.

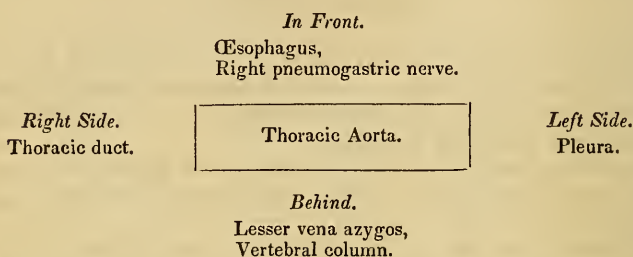


The *descending aorta* is subdivided, in correspondence with the two great cavities of the trunk, into the thoracic and abdominal aorta.

The *thoracic aorta* is situated to the left side of the vertebral column, but approaches the middle line as it descends, and at the aortic opening of the diaphragm is altogether in front of the column. After entering the abdomen it again falls back to the left side.

Relations.—It is in relation, *behind* with the vertebral column and lesser vena azygos; *in front* with the œsophagus and right pneumogastric nerve; to the *left side* with the pleura; and to the *right* with the thoracic duct.

Plan of the *relations* of the thoracic Aorta.

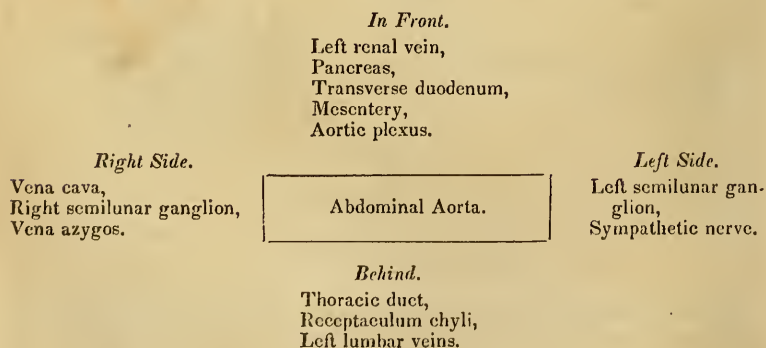


The *abdominal aorta* enters the abdomen through the aortic opening of the diaphragm, and descends, lying rather to the left side of the vertebral column, to the fourth lumbar vertebra, where it divides into the two common iliac arteries.

Relations.—It is crossed, *in front* by the left renal vein, pancreas, transverse duodenum, and mesentery, and is embraced by the aortic plexus: *behind* it is in relation with the thoracic duct, receptaculum chyli, and left lumbar veins.

On its *left side* is the left semilunar ganglion and sympathetic nerve; and on the *right* the vena cava, right semilunar ganglion, and the commencement of the vena azygos.

Plan of the *relations* of the abdominal Aorta.



Branches.—The branches of the aorta, arranged in a tabular form, are—

<i>Ascending aorta.</i>	. . .	Coronary.	
<i>Arch of the aorta.</i>	. . .	{ Arteria innominata, { Left carotid, { Left subclavian.	{ Right carotid, { Right subclavian.
<i>Thoracic aorta</i>	. . .	{ Pericardiac, { Bronchial, { Œsophageal, { Intercostal.	
<i>Abdominal aorta</i>	. . .	{ Phrenic, { Cœliac axis, { Supra-renal, or capsular, { Renal, or emulgent, { Superior mesenteric, { Spermatic, { Inferior mesenteric, { Lumbar, { Sacra-media, { Common iliacs.	{ Gastric, { Hepatic, { Splenic.

The *coronary arteries* arise from the aortic sinuses at the commencement of the ascending aorta, immediately above the free margin of the semilunar valves. The *left*, or *anterior coronary* passes forwards, between the pulmonary artery and left appendix auriculæ, and divides into two branches; one of which winds around the base of the left ventricle, in the auriculo-ventricular groove, and inosculates with the right coronary, forming an arterial circle around the base of the heart, while the other passes along the line of union of the two ventricles, upon the anterior aspect of the heart to its apex, where it anastomoses with the descending branch of the right coronary. It supplies the left auricle and the adjoining sides of both ventricles.

The *right*, or *posterior coronary* passes forwards, between the root of the pulmonary artery and the right auricle, and winds along the auriculo-ventricular groove, to the posterior median furrow, where it descends upon the posterior aspect of the heart to its apex, and inosculates with the left coronary. It is distributed to the right auricle and to the posterior surface of both ventricles, and sends a large branch along the sharp margin of the right ventricle to the apex of the heart.

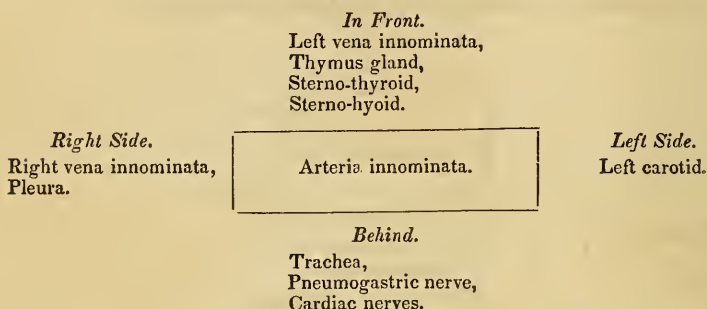
ARTERIA INNOMINATA.

The *Arteria innominata* (fig. 117, No. 4.) is the first artery given off by the arch of the aorta. It is an inch and a half in length, and

ascends obliquely to the right sterno-clavicular articulation, where it divides into the right carotid and right subclavian artery.

Relations.—It is in relation, *in front* with the left vena innominata, the thymus gland, and the origins of the sterno-thyroid and sterno-hyoid muscles, which separates it from the sternum. *Behind* with the trachea, pneumogastric nerve and cardiac nerves; *externally* with the right vena innominata and pleura; and *internally* with the origin of the left carotid.

Plan of the *relations* of the Arteria Innominata.



The arteria innominata occasionally gives off a small branch which ascends along the middle of the trachea to the thyroid gland. This branch was described by Neubauer, and Dr. Harrison names it the *middle thyroid artery*. A knowledge of its existence is extremely important in performing the operation of tracheotomy.

COMMON CAROTID ARTERIES.

The common carotid arteries (*κάρα*, the head) arise, the *right* from the bifurcation of the arteria innominata opposite the right sterno-clavicular articulation, the *left* from the arch of the aorta. It follows, therefore, that the right carotid is shorter than the left; it is also more anterior; and, in consequence of proceeding from a branch instead of from the main trunk, it is larger than its fellow.

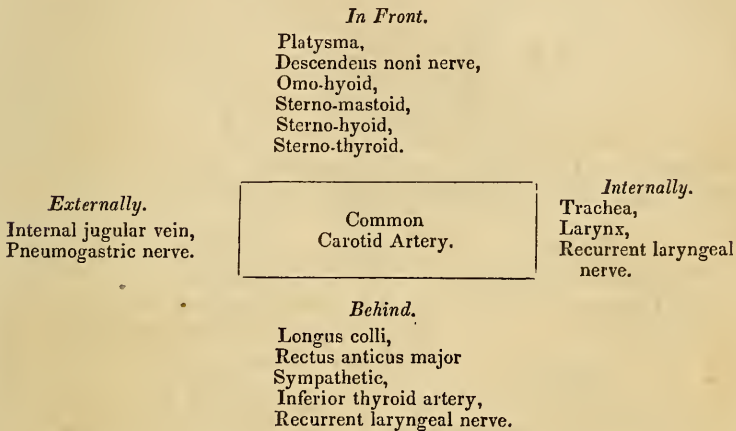
The *Right common carotid artery* (fig. 117, No. 5) ascends the neck perpendicularly, from the right sterno-clavicular articulation to a level with the upper border of the thyroid cartilage, where it divides into the external and internal carotid.

The *Left common carotid* (fig. 117, No. 11) passes somewhat obliquely outwards from the arch of the aorta to the side of the neck, and thence upwards to a level with the upper border of the thyroid cartilage, where it divides like the right common carotid into the external and internal carotid.

Relations.—The right common carotid rests, first upon the longus colli muscle, then upon the rectus anticus major, the sympathetic nerve being interposed. The inferior thyroid artery and recurrent laryngeal nerve pass behind it at its lower part. To its *inner side* is the trachea, recurrent laryngeal nerve, and larynx; to its *outer side*, and enclosed in the same sheath, the jugular vein and pneumo-

gastric nerve; and *in front* the sterno-thyroid, sterno-hyoid, sternomastoid, omo-hyoid, and platysma muscles, and the descendens noni nerve. The left common carotid, in addition to the relations just enumerated, which are common to both, is crossed near its commencement by the left vena innominata; it lies upon the trachea; then gets to its side, and is in relation with the œsophagus and thoracic duct: to facilitate the study of these relations, I have arranged them in a tabular form.

Plan of *relations* of the Common Carotid Artery.



Additional relations of the Left Common Carotid.

<i>In Front.</i>	<i>Behind.</i>	<i>Internally.</i>	<i>Externally.</i>
Left vena innominata.	Trachea, Thoracic duct.	Arteria innominata, Æsophagus.	Pleura.

EXTERNAL CAROTID ARTERY.

The *External carotid artery* ascends nearly perpendicularly from opposite the upper border of the thyroid cartilage, to the space between the neck of the lower jaw and the meatus auditorius, where it divides into the temporal and internal maxillary artery.

Relations.—*In front* it is crossed by the posterior belly of the digastricus, stylo-hyoideus, and platysma myoides muscles; by the lingual nerve near its origin; higher up it is situated in the substance of the parotid gland, and is crossed by the facial nerve. *Behind* it is separated from the internal carotid by the stylo-pharyngeus and stylo-glossus muscles, glosso-pharyngeal nerve, and part of the parotid gland.

Plan of the *relations* of the External Carotid Artery.*In Front.*

Platysma,
 Digastricus,
 Stylo-hyoid,
 Lingual nerve,
 Facial nerve,
 Parotid gland.

External Carotid Artery.

Behind.

Stylo-pharyngeus,
 Stylo-glossus,
 Glosso-pharyngeal nerve,
 Parotid gland.

Branches.—The branches of the external carotid are eleven in number, and may be arranged into four groups, viz.

Anterior.

1. Superior thyroid,
2. Lingual,
3. Facial.

Posterior.

4. Mastoid,
5. Occipital,
6. Posterior auricular.

Superior.

7. Parotidean,
8. Ascending pharyngeal,
9. Transverse facial.

Terminal.

10. Temporal,
11. Internal maxillary.

The *anterior branches* arise from the commencement of the external carotid, within a short distance of each other. The lingual and facial bifurcate, not unfrequently, from a common trunk.

1. The SUPERIOR THYROID ARTERY (the first of the branches of the external carotid) curves downwards to the thyroid gland to which it is distributed, anastomosing with its fellow of the opposite side, and with the inferior thyroid arteries. In its course it passes beneath the omo-hyoid, sterno-thyroid, and sterno-hyoid muscle.

Branches.

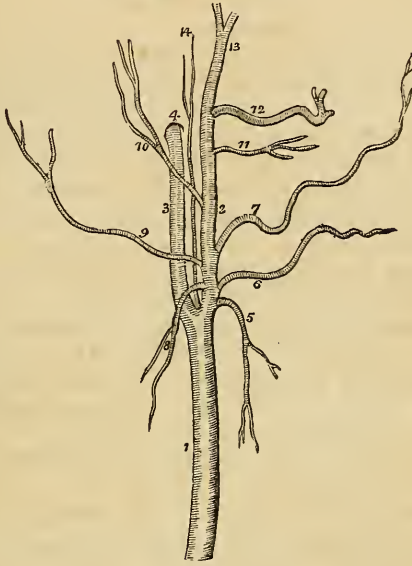Hyoid,
 Superior laryngeal,
 Inferior laryngeal,
 Muscular.

The *Hyoid* branch passes forwards beneath the thyro-hyoideus, and is distributed to the insertion of the depressor muscles into the os hyoides.

The *Superior laryngeal* pierces the thyro-hyoidean membrane, in company with the superior laryngeal nerve, and supplies the mucous membrane and muscles of the larynx, sending a branch upwards to the epiglottis.

The *Inferior laryngeal* is a small branch which crosses the crico-thyroidean membrane along the lower border of the thyroid cartilage. It sends branches through the membrane to supply the mucous lining of the larynx, and inosculates with its fellow of the opposite side.

Fig. 118.



The *muscular* branches are distributed to the depressor muscles of the os hyoides and larynx. One of these branches crosses the sheath of the common carotid to the under surface of the sternomastoid muscle.

2. The LINGUAL ARTERY ascends obliquely from its origin, it then passes forwards parallel with the os hyoides; thirdly, it ascends to the under surface of the tongue; and fourthly, runs forward in a serpentine direction to its tip, under the name of *ranine artery*, where it terminates by inosculating with its fellow of the opposite side.

Relations.—The *first* part of its course rests upon the middle constrictor muscle of the pharynx, being covered in by the tendon of the digastricus and the stylo-hyoid muscle; the *second* is situated between the middle constrictor and hyo-glossus muscle, the latter

Fig. 118. The carotid arteries with the branches of the external carotid. 1. The common carotid. 2. The external carotid. 3. The internal carotid. 4. The carotid foramen in the petrous portion of the temporal bone. 5. The superior thyroid artery. 6. The lingual artery. 7. The facial artery. 8. The mastoid artery. 9. The occipital. 10. The posterior auricular. 11. The transverse facial artery. 12. The internal maxillary. 13. The temporal. 14. The ascending pharyngeal artery.

separating it from the lingual nerve; in the *third* part of its course it lies between the hyo-glossus and genio-hyo-glossus; and in the fourth (ranine) rests upon the lingualis to the tip of the tongue.

Branches.

Hyoid,
Dorsalis linguæ,
Sublingual.

The *Hyoid* branch runs along the upper border of the os hyoides, and is distributed to the origins of the elevator muscles of the os hyoides, inosculating with its fellow of the opposite side.

The *Dorsalis linguæ* ascends along the posterior border of the hyo-glossus muscle to the dorsum of the tongue, and is distributed to the tongue, the fauces and epiglottis, anastomosing with its fellow of the opposite side.

The *Sublingual* branch, frequently considered as a branch of bifurcation of the lingual, runs along the anterior border of the hyo-glossus, and is distributed to the sublingual gland and to the muscles of the tongue. It is situated between the mylo-hyoideus and genio-hyo-glossus, generally accompanies Wharton's duct for a part of its course, and sends a branch to the frænum linguæ. It is the latter branch which affords the considerable hæmorrhage which sometimes accompanies the operation of snipping the frænum in children.

3. FACIAL ARTERY.—The *Facial artery* arises a little above the great cornu of the os hyoides, and ascends obliquely to the submaxillary gland, in which it lies embedded. It then curves around the body of the lower jaw, close to the anterior inferior angle of the masseter muscle, ascends to the angle of the mouth, and thence to the angle of the eye, where it is named the *angular artery*. The facial artery is very tortuous in its course over the buccinator muscle, to accomodate itself to the movement of the jaws.

Relations.—Below the jaw it passes beneath the digastricus and stylo-hyoid muscles; on the body of the lower jaw it is covered by the platysma myoides, and at the angle of the mouth by the depressor anguli oris and zygomatic muscles. It rests upon the submaxillary gland, the lower jaw, buccinator, orbicularis oris, levator anguli oris, levator labii superioris proprius, and levator labii superioris alæque nasi.

Its *branches* are divided into those which are given off below the jaw and those on the face: they may be thus arranged:

Below the Jaw.

Inferior palatine,
Submaxillary,
Submental,
Pterygoid.

On the Face.

Masseteric,
 Inferior labial,
 Inferior coronary,
 Superior coronary,
 Lateralis nasi.

The *Inferior palatine* branch ascends between the stylo-glossus and stylo-pharyngeus muscles, to be distributed to the tonsil and soft palate, and anastomoses with the posterior palatine branch of the internal maxillary artery.

The *Submaxillary* are four or five branches which supply the submaxillary gland.

The *Submental* branch runs forwards upon the mylo-hyoid muscle, under cover of the body of the lower jaw, and anastomoses with branches of the sublingual and inferior dental artery.

The *Pterygoid* branch is distributed to the internal pterygoid muscle.

The *Masseteric* branches are distributed to the masseter and buccinator muscles.

The *Inferior labial* branch is distributed to the muscles and integument of the lower lip.

The *Inferior coronary* runs along the edge of the lower lip, between the mucous membrane and labial glands, and the orbicularis oris; it inosculates with the corresponding artery of the opposite side.

The *Superior coronary* follows the same course along the upper lip, inosculating with the opposite superior coronary artery, and at the middle of the lip it sends a branch upwards to supply the septum of the nose and the mucous membrane.

The *Lateralis nasi* is distributed to the ala and septum of the nose.

The *Inosculations* of the facial artery are very numerous: thus it anastomoses with the sublingual branch of the lingual, with the ascending pharyngeal and posterior palatine arteries, with the inferior dental as it escapes from the mental foramen, infra-orbital at the infra-orbital foramen, transverse facial on the side of the face, and at the angle of the eye with the nasal and frontal branches of the ophthalmic artery.

The facial artery is subject to considerable varieties in its extent; it not unfrequently terminates at the angle of the nose or mouth, and is rarely symmetrical on both sides of the face.

4. The **MASTOID ARTERY** turns downwards, to be distributed to the sterno-mastoid muscle, and to the lymphatic glands of the neck; sometimes it is replaced by two small branches.

5. The **OCCIPITAL ARTERY**, smaller than the preceding branches, passes backwards beneath the posterior belly of the digastricus, the

trachelo-mastoid and sterno-mastoid muscles, to the occipital groove in the mastoid portion of the temporal bone. It then ascends between the splenius and complexus muscles, and divides into two branches which are distributed upon the occiput, anastomosing with the opposite occipital, the posterior auricular, and temporal artery. The lingual nerve curves around this artery near to its origin from the external carotid.

Branches.—It gives off only two branches deserving of name, the inferior meningeal and princeps cervicis.

The *Inferior meningeal* ascends by the side of the internal jugular vein and passes through the foramen lacerum posterius, to be distributed to the dura mater.

The *Arteria princeps cervicis* is a large and irregular branch. It descends the neck between the complexus and semi-spinalis colli, and inosculates with the profunda cervicis of the subclavian. This branch is the means of establishing a very important collateral circulation between the branches of the carotid and subclavian, in ligature of the common carotid artery.

6. The POSTERIOR AURICULAR ARTERY arises from the external carotid, above the digastric and stylo-hyoid muscles, and ascends beneath the lower border of the parotid gland, and behind the concha, to be distributed by two branches to the external ear and side of the head, anastomosing with the occipital and temporal arteries; some of its branches pass through fissures in the fibro-cartilage, to be distributed to the anterior surface of the pinna. The anterior auricular arteries are branches of the temporal.

Branches.—The posterior auricular gives off but one named branch, the *stylo-mastoid*, which enters the stylo-mastoid foramen to be distributed to the aquæductus Fallopii and tympanum.

7. The PAROTIDEAN ARTERIES are four or five large branches which are given off from the external carotid whilst that vessel is situated in the parotid gland. They are distributed to the structure of the gland, their terminal branches reaching the integument and the side of the face.

8. The ASCENDING PHARYNGEAL ARTERY, the smallest of the branches of the external carotid, arises from that trunk near to its bifurcation, and ascends between the internal carotid and the side of the pharynx to the base of the skull, where it divides into two branches; *meningeal*, which enters the foramen lacerum posterius, to be distributed to the dura mater; and *pharyngeal*. It supplies the pharynx, tonsils, and Eustachian tube.

9. The TRANSVERSALIS FACIEI arises from the external carotid whilst that trunk is lodged within the parotid gland; it crosses the masseter muscle, lying parallel with and a little above Stenon's duct; and is distributed to the temporo-maxillary articulation, and to the muscles and integument on the side of the face, inosculating with the infra-orbital and facial artery. This artery is not unfrequently a branch of the temporal.

10. The **TEMPORAL ARTERY** is one of the two terminal branches of the external carotid. It ascends over the root of the zygoma; and at about an inch and a half above the zygomatic arch, divides into an anterior and a posterior temporal branch. The *anterior temporal* is distributed over the front of the temple and arch of the skull, and anastomoses with the opposite anterior temporal, and with the supra-orbital and frontal artery. The *posterior temporal* curves upwards and backwards, and inosculates with its fellow of the opposite side, with the posterior auricular and occipital artery.

The trunk of the temporal artery is covered in by the parotid gland and by the *atrahens aurem* muscle, and rests upon the temporal fascia.

Branches.

Orbitar,
Anterior auricular,
Middle temporal.

The *Orbitar artery* is a small branch, not always present, which passes forwards immediately above the zygoma, between the two layers of the temporal fascia, and inosculates beneath the *orbicularis palpebrarum* with the palpebral arteries.

The *Anterior auricular arteries* are distributed to the anterior portion of the pinna.

The *Middle temporal branch* passes through an opening in the temporal fascia immediately above the zygoma, and supplies the temporal muscle inosculating with the deep temporal arteries.

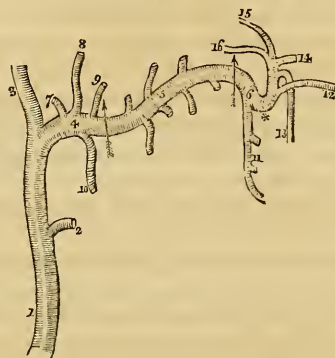
11. The **INTERNAL MAXILLARY ARTERY**, the other terminal branch of the external carotid, has next to be examined.

Dissection.—The *Internal maxillary artery* passes inwards behind the neck of the lower jaw to the deep structures in the face; we require, therefore, to remove several parts for the purpose of seeing it completely. To obtain a good view of the vessel, the zygoma should be sawn across in front of the external ear, and the malar bone near to the orbit. Turn down the zygomatic arch with the masseter muscle. In doing this, a small artery and nerve will be seen crossing the sigmoid arch of the lower jaw, and entering the masseter muscle (the *masseteric*). Cut away the tendon of the temporal muscle from its insertion into the coronoid process, and turn it upwards towards its origin; some vessels will be seen entering its under surface; these are the *deep temporal*. Then saw the ramus of the jaw across its middle, and dislocate it from its articulation with the temporal bone. Be careful in doing this to carry the blade of the knife close to the bone, lest any branches of nerves should be injured. Next raise this portion of bone, and with it the external pterygoid muscle. The artery, together with the deep branches of the inferior maxillary nerve, will be seen lying upon the pterygoid

muscles. These are to be carefully freed of fat and cellular tissue, and then examined.

This artery (118, 12; and 119) commences in the substance of the parotid gland, opposite the meatus auditorius externus, it passes in the first instance horizontally forwards behind the neck of the lower jaw; next, curves around the lower border of the external pterygoid muscle near its origin, and ascends obliquely forwards upon the outer side of that muscle; it then passes between the two heads of the external pterygoid and enters the pterygo-maxillary fossa. Occasionally it passes between the two pterygoid muscles, without appearing on the outer surface of the external pterygoid. In consideration of its course this artery may be divided into three portions; maxillary, pterygoid, and pterygo-maxillary.

Fig. 119.



Relations.—The *Maxillary* portion is situated between the ramus of the jaw and the internal lateral ligament, lying parallel with the auricular nerve; the *pterygoid* portion between the external pterygoid muscle, and the masseter and temporal muscle. The *pterygo-maxillary* portion lies between the two heads of the external ptery-

Fig. 119. 1. The external carotid artery. 2. The trunk of the transverse facial artery. 3, 4. The two terminal branches of the external carotid. 3. The temporal artery; and 4. The internal maxillary, the first or *maxillary* portion of its course: the limit of this portion is marked by an arrow. 5. The second, or *pterygoid* portion, of the artery; the limits are bounded by the arrows. 6. The third or *pterygo-maxillary* portion. The branches of the maxillary portion are, 7. A tympenic branch. 8. The arteria meningeae magna. 9. The arteria meningeae parva. 10. The inferior dental artery. The branches of the second portion are wholly muscular, the ascending ones being distributed to the temporal, and the descending to the four other muscles of the inter-maxillary region, viz. the two pterygoids, the masseter and buccinator. The branches of the pterygo-maxillary portion of the artery are, 11. The superior dental artery. 12. The infra-orbital artery. 13. The posterior palatine. 14. The sphenopalatine or nasal. 15. The pterygo-palatine. 16. The Vidian, * The remarkable bend which the third portion of the artery makes as it turns inwards to enter the pterygo-maxillary fossa.

goid muscle, and in the spheno-maxillary fossa is in relation with Meckel's ganglion.

Branches.

<i>Maxillary portion</i>	{	Tympanic, Inferior dental, Arteria meningea magna, Arteria meningea parva.
<i>Pterygoid portion</i>	{	Deep temporal branches, External pterygoid, Internal pterygoid, Masseteric, Buccal.
<i>Pterygo-maxillary portion</i>	{	Superior dental, Infra-orbital, Pterygo-palatine, Spheno-palatine, Posterior palatine, Vidian.

The *Tympanic* branch is small and not likely to be seen in an ordinary dissection; it is distributed to the temporo-maxillary articulation and meatus, and passes into the tympanum through the fissura Glaseri.

The *Inferior dental* descends to the dental foramen, and enters the canal of the lower jaw in company with the dental nerve. Opposite the bicuspid teeth it divides into two branches, one of which is continued onwards within the bone as far as the symphysis, to supply the incisor teeth, while the other escapes with the nerve at the mental foramen, and anastomoses with the inferior labial and submental branch of the facial. It supplies the teeth of the lower jaw, sending small branches along the canals in their roots.

The *Arteria meningea magna* ascends behind the temporo-maxillary articulation to the foramen spinosum in the spinous process of the sphenoid bone, and entering the cranium divides into an anterior and a posterior branch. The *anterior branch* crosses the great ala of the sphenoid to the groove or canal in the anterior inferior angle of the parietal bone, and divides into branches, which ramify upon the external surface of the dura mater, and anastomose with the corresponding branches from the opposite side. The posterior branch crosses the squamous portion of the temporal bone, to the posterior part of the dura mater and cranium. The branches of the arteria meningea magna are distributed chiefly to the bones of the skull; and in the middle fossa it sends a small branch through the hiatus Fallopii to the facial nerve.

The *Meningea parva* is a small branch which ascends to the foramen ovale, and passes into the skull to be distributed to the

Casserian ganglion and dura mater. It gives off a small branch to the nasal fossæ and soft palate.

The *Muscular branches* are distributed, as their names imply, to the five muscles of the maxillary region; the *temporal* branches are two in number.

The *Superior dental* artery is given off from the internal maxillary, just as that vessel is about to make its turn into the sphenomaxillary fossa. It descends upon the tuberosity of the superior maxillary bone, and sends its branches through several small foramina to supply the posterior teeth of the upper jaw, and the antrum. The terminal branches are continued forwards upon the alveolar process, to be distributed to the gums and to the sockets of the teeth.

The *Infra-orbital* would appear, from its size, to be the proper continuation of the artery. It runs along the infra-orbital canal with the superior maxillary nerve, sending branches into the orbit and downwards through canals in the bone, to supply the mucous lining of the antrum and the teeth of the upper jaw, and escapes from the infra-orbital foramen. The branch which supplies the incisor teeth is the *anterior dental artery*; on the face it inosculates with the facial and transverse facial arteries.

The *Pterygo-palatine* is a small branch which passes through the pterygo-palatine canal, and supplies the upper part of the pharynx and Eustachian tube.

The *Spheno-palatine*, or nasal, enters the superior meatus of the nose through the spheno-palatine foramen in company with the nasal branches of Meckel's ganglion, and divides into two branches; one of which is distributed in the mucous membrane of the septum; while the other supplies the mucous membrane of the lateral wall of the nares, together with the sphenoid and ethmoid cells.

The *Posterior palatine* artery descends along the posterior palatine canal, in company with the posterior palatine branches of Meckel's ganglion, to the posterior palatine foramen; it then curves forwards lying in a groove upon the bone, and is distributed to the palate, while in the posterior palatine canal it sends a small branch backwards, through the small posterior palatine foramen to supply the soft palate, and anteriorly it supplies a branch to the anterior palatine canal, which reaches the nares and inosculates with the branches of the spheno-palatine artery.

The *Vidian branch* passes backwards along the pterygoid canal, and is distributed to the sheath of the Vidian nerve, and to the Eustachian tube.

INTERNAL CAROTID ARTERY.

The internal carotid artery curves slightly outwards from the bifurcation of the common carotid, and then ascends nearly perpendicularly through the maxillo-pharyngeal space* to the carotid foramen in the petrous bone. It next passes *inwards* along the carotid

* For the boundaries of this space see page 189.

canal, *forwards* by the side of the sella turcica, and *upwards* by the anterior clinoid process, where it pierces the dura mater and divides into three terminal branches. The course of this artery is remarkable from the number of angular curves which it forms; one or two of these flexures are sometimes seen in the cervical portion of the vessel near to the base of the skull; and by the side of the sella turcica it resembles the italic letter *s*, placed horizontally.

Relations.—In consideration of its connexions, the artery is divisible into a cervical, petrous, cavernous and cerebral portion. The *Cervical portion* is in relation *posteriorly* with the rectus anticus major, sympathetic nerve, pharyngeal and laryngeal nerves which cross behind it, and near the carotid foramen with the glosso-pharyngeal, pneumogastric and lingual nerves, and partially with the internal jugular vein. *Internally* it is in relation with the side of the pharynx, the tonsil, and the ascending pharyngeal artery. *Externally* with the internal jugular vein, glosso-pharyngeal, pneumogastric and lingual nerves, and *in front* with the stylo-glossus, and stylo-pharyngeus muscle, glosso-pharyngeal nerve, and parotid gland.

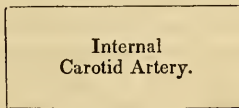
Plan of the *relations* of the *cervical portion* of the internal carotid artery.

In Front.

Parotid gland,
Stylo-glossus muscle,
Stylo-pharyngeus muscle,
Glosso-pharyngeal nerve.

Internally.

Pharynx,
Tonsil,
Ascending pharyngeal artery.



Externally.

Jugular vein,
Glosso-pharyngeal,
Pneumogastric,
Lingual nerve.

Behind.

Superficial cervical ganglion,
Pneumogastric nerve,
Glosso-pharyngeal,
Pharyngeal nerve,
Superior laryngeal nerve,
Sympathetic nerve,
Rectus anticus major.

The *Petrous portion* is separated from the bony wall of the carotid canal by a lining of dura mater; it is in relation with the carotid plexus, and is covered in by the Casserian ganglion.

The *Cavernous portion* is situated on the inner wall of the cavernous sinus, and is in relation by its outer side with the lining membrane of the sinus, the sixth nerve, and the ascending branches of the carotid plexus. The third, fourth, and ophthalmic nerves are placed in the outer wall of the cavernous sinus, and are separated from the artery by the lining membrane of the sinus.

The *Cerebral portion* of the artery is enclosed in a sheath of the arachnoid, and is in relation with the optic nerve. At its point of division it is situated in the fissure of Sylvius.

Branches.—The cervical portion of the internal carotid gives off no branches: from the other portions are derived the following:

Tympanic,
Anterior meningeal,
Ophthalmic,
Anterior cerebral,
Middle cerebral,
Posterior communicating,
Choroidean.

The *Tympanic* is a small branch which enters the tympanum through a minute foramen in the carotid canal.

The *Anterior meningeal* is distributed to the dura mater and Casserian ganglion.

The *Ophthalmic artery* arises from the cerebral portion of the internal carotid, and enters the orbit through the foramen opticum, immediately to the outer side of the optic nerve. It then crosses the optic nerve to the inner wall of the orbit, and runs along the lower border of the superior oblique muscle, to the inner angle of the eye, where it divides into two terminal branches, the frontal and nasal.

Branches.—The branches of the ophthalmic artery may be arranged into two groups:—first, those distributed to the orbit and surrounding parts; and secondly, those which supply the muscles and globe of the eye. They are—

<i>First group.</i>	<i>Second group.</i>
Lachrymal,	Muscular,
Supra-orbital,	Anterior ciliary,
Posterior ethmoidal,	Ciliary short and long,
Anterior ethmoidal,	Centralis retinae.
Palpebral,	
Frontal,	
Nasal.	

The *Lachrymal* is the first branch of the ophthalmic artery, and is usually given off immediately before that artery enters the optic foramen. It follows the course of the lachrymal nerve, along the upper border of the external rectus muscle, and is distributed to the lachrymal gland. The small branches which escape from the gland supply the conjunctiva and upper eyelid. The lachrymal artery gives off a *malar branch* which passes through the malar bone into the temporal fossa and inosculates with the deep temporal arteries, while some of its branches become subcutaneous on the cheek and anastomose with the transverse facial.

The *Supra-orbital* artery follows the course of the frontal nerve, resting on the levator palpebrae muscle: it passes through the supra-orbital foramen, and divides into a superficial and deep branch which are distributed to the muscles and integument of the forehead and to the pericranium. At the supra-orbital foramen it sends a branch inwards to the diploë.

The *Ethmoidal* arteries, *posterior* and *anterior*, pass through the ethmoidal foramina, and are distributed to the falx cerebri and to the ethmoidal cells and nasal fossæ. The latter accompanies the nasal nerve.

The *Palpebral* arteries, *superior* and *inferior*, are given off from the ophthalmic, near to the inner angle of the orbit; they encircle the eyelids, forming a superior and inferior arch near to the borders of the lids, between the orbicularis palpebrarum and tarsal cartilage. At the outer angle of the eyelids the superior palpebral inosculates with the orbital branch of the temporal artery. The inferior palpebral artery sends a branch to the nasal duct.

The *Frontal* artery, one of the terminal branches of the ophthalmic, emerges from the orbit at its inner angle, and ascends along the middle of the forehead. It is distributed to the integument, muscles, and pericranium.

The *Nasal* artery, the other terminal branch of the ophthalmic, passes out of the orbit above the tendo oculi, and divides into two branches; one of which inosculates with the angular artery, while the other, the *dorsalis nasi*, runs along the ridge of the nose and is distributed to its entire surface. The nasal artery sends a small branch to the lachrymal sac.

The *Muscular branches*, usually two in number, *superior* and *inferior*, supply the muscles of the orbit; and upon the anterior aspect of the globe of the eye give off the *anterior ciliary* arteries, which pierce the sclerotic near its margin of connexion with the cornea, and are distributed to the iris. It is the congestion of these vessels that gives rise to the vascular zone around the cornea in iritis.

The *Ciliary arteries* are divisible into three groups,—short, long, and anterior.

The *Short ciliary* are very numerous; they pierce the sclerotic around the entrance of the optic nerve, and supply the choroid coat and ciliary processes. The *long ciliary*, two in number, pierce the sclerotic upon opposite sides of the globe of the eye, and pass forwards between it and the choroid to the iris. They form an arterial circle around the circumference of the iris by inosculating with each other, and from this circle branches are given off which ramify in the substance of the iris, and form a second circle around the pupil. The *anterior ciliary* are branches of the muscular arteries; they terminate in the great arterial circle of the iris.

The *Centralis retinæ* artery pierces the optic nerve obliquely, and passes forwards in the centre of its cylinder to the retina, where it divides into branches, which ramify in the inner layer of that membrane. It supplies the retina, hyaloid membrane, and zonula ciliaris; and, by means of a branch sent forwards through the centre of the vitreous humour in a tubular sheath of the hyaloid membrane, the capsule of the lens.

The *Anterior cerebral artery* passes forwards in the great longitudinal fissure between the two hemispheres of the brain; then curves backwards along the corpus callosum to its posterior extre-

mity. It gives branches to the olfactory and optic nerves, to the under surface of the anterior lobes, the third ventricle, the corpus callosum, and the inner surface of the hemispheres. The two anterior cerebral arteries are connected soon after their origin by a short anastomosing trunk, the *anterior communicating*.

The *Middle cerebral artery*, larger than the preceding, passes outwards along the fissure of Sylvius, and divides into three principal branches, which supply the anterior and middle lobes, and the island of Reil. Near to its origin it gives off the numerous small branches which enter the substantia perforata to be distributed to the corpus striatum.

The *Posterior communicating artery*, very variable in size, sometimes double, and sometimes altogether absent, passes backwards and inosculates with the posterior cerebral, a branch of the basilar artery. Occasionally it is so large as to take the place of the posterior cerebral artery.

The *Choroidean* is a small branch which is given off from the internal carotid, near to the origin of the posterior communicating artery, and passes beneath the edge of the middle lobe of the brain to enter the descending cornu of the lateral ventricle. It is distributed to the choroid plexus, and to the walls of the middle cornu.

SUBCLAVIAN ARTERY.

The *Subclavian artery*, on the right side, arises from the *arteria innominata*, opposite the sterno-clavicular articulation, and on the left, from the arch of the aorta. The right is consequently shorter than the left, and is situated nearer to the anterior wall of the chest; it is also somewhat greater in diameter, from being a branch of a branch, in place of a division from the main trunk.

The course of the subclavian artery is divisible, for the sake of precision and surgical observation, into three portions. The first portions of the right and left arteries differ in their course and relations in correspondence with their dissimilarity of origin. The other two portions are precisely alike on both sides.

The *first portion*, on the *right side*, ascends obliquely outwards to the inner border of the scalenus anticus. On the *left side* it ascends perpendicularly to the inner border of that muscle. The *second portion* curves outwards behind the scalenus anticus; and the *third portion* passes downwards and outwards beneath the clavicle, to the lower border of the first rib, where it becomes the axillary artery.

Relations.—The *first portion*, on the *right side*, is in relation in *front* with the internal jugular and subclavian vein at their point of junction, and is crossed by the pneumogastric nerve, cardiac nerves, and phrenic nerve. *Behind* and *beneath* it is invested by the pleura, is crossed by the right recurrent laryngeal nerve and vertebral vein, and is in relation with the transverse process of the seventh cervical vertebra. The *first portion* on the *left side* is in relation in *front* with the pleura, the vena innominata, the pneumogastric and phrenic nerves (which lie parallel to it), and the left carotid artery. To its

inner side is the œsophagus; to its *outer side* the pleura; and *behind*, the thoracic duct, longus colli, and vertebral column.

Plan of the *relations* of the *first portion* of the *Right Subclavian Artery*.

In Front.

Internal jugular vein,
Subclavian vein,
Pneumogastric nerve,
Cardiac nerves,
Phrenic nerve.

Right Subclavian Artery.

Behind and beneath.

Pleura,
Recurrent laryngeal nerve,
Vertebral vein,
Transverse process of the 7th cervical vertebra

Plan of the *relations* of the *first portion* of the *Left Subclavian Artery*.

In Front.

Pleura,
Vena innominata,
Pneumogastric nerve,
Phrenic nerve,
Left carotid.

Inner Side.
œsophagus.

Left Subclavian Artery.

Outer Side.
Pleura.

Behind.

Thoracic duct,
Longus colli,
Vertebral column.

The *Second portion* is situated between the two scalmi, and is supported by the margin of the first rib. The scalenus anticus separates it from the subclavian vein and phrenic nerve. Behind it is in relation with the brachial plexus.

The *Thyroid portion* is in relation, *in front* with the subclavian vein and subclavius muscle; *behind* with the brachial plexus and scalenus posticus; *below* with the first rib; and *above* with the supra-scapular artery and platysma.

Plan of the *relations* of the *third portion* of the Subclavian Artery.

Above.

Supra-scapular artery,
Platysma myoides.

In Front.
Subclavian vein,
Subclavius.

Subclavian Artery,
Third portion.

Behind.
Brachial plexus,
Scalenus posticus.

Below.

First rib.

Branches.—The greater part of the branches of the subclavian are given off from the artery before it arrives at the margin of the

first rib. The profunda cervicis and superior intercostal frequently encroach upon the second portion, and not unfrequently a branch or branches may be found proceeding from the third portion.

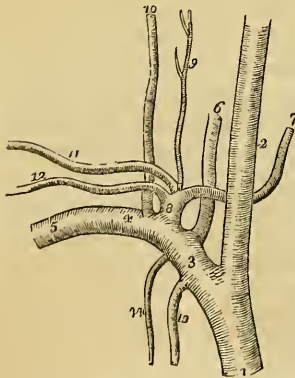
The primary branches are five in number, the three first being ascending, and the latter descending; they are the—

Vertebral,	{	Inferior thyroid, Supra-scapular,* Posterior scapular, Superficialis cervicis.
Thyroid axis,		
Profunda cervicis,		
Superior intercostal,		
Internal mammary.		

The VERTEBRAL ARTERY is the first and the largest of the branches of the subclavian artery; it ascends through the foramina in the transverse processes of all the cervical vertebræ, excepting the last; then winds backwards around the articulating process of the atlas; and piercing the dura mater enters the skull through the foramen magnum. The two arteries unite at the lower border of the pons Varolii, to form the *basilar artery*. In the foramina of the transverse processes of the vertebræ the artery lies in front of the cervical nerves.

Dr. John Davy† has observed that, when the vertebral arteries

Fig. 120.



differ in size, the left is generally the larger: thus in ninety-eight cases he found the left vertebral the larger twenty-six times, and the right only eight. In the same number of cases he found a small band stretching across the cylinder of the basilar artery, near the junction of the two vertebral arteries, seventeen times, and in a few instances a small communicating trunk between the two vertebral arteries previously to their union. I have several times seen this communicating branch, and have a preparation now before me in which it is exhibited.

The BASILAR ARTERY, so named from its position at the base of the brain, runs forwards to the anterior border of the pons Varolii, where it divides into four ultimate branches, two to either side.

Fig. 120. The branches of the right subclavian artery. 1. The arteria innominata. 2. The right carotid. 3. The first portion of the subclavian artery. 4. The second portion. 5. The third portion. 6. The vertebral artery. 7. The inferior thyroid. 8. The thyroid axis. 9. The superficialis cervicis. 10. The profunda cervicis. 11. The posterior scapular or transversalis colli. 12. The supra-scapular. 13. The internal mammary artery. 14. The superior intercostal.

* This is usually described as arising from the axillary, but I have most frequently found it to arise from the subclavian.—G.

† Edinburgh Medical and Surgical Journal, 1839.

Branches.—The branches of the vertebral and basilar arteries are the following :

<i>Vertebral,</i>	{	Lateral spinal, Posterior meningeal, Anterior spinal, Posterior spinal, Inferior cerebellar.
<i>Basilar,</i>	{	Transverse, Superior cerebellar, Posterior cerebral.

The *Lateral spinal* branches enter the intervertebral foramina, and are distributed to the spinal cord and to its membranes. Where the vertebral artery curves around the articular process of the atlas, it gives off several muscular branches.

The *Posterior meningeal* are one or two small branches, which enter the cranium through the foramen magnum, to be distributed to the dura mater of the cerebellar fossæ, and to the falx cerebelli. One branch, described by Soemmering, passes into the cranium along the first cervical nerve.

The *Anterior spinal* is a small branch which unites with its fellow of the opposite side, on the front of the medulla oblongata. The artery formed by the union of these two vessels descends along the anterior aspect of the spinal cord, to which it distributes branches.

The *Posterior spinal* winds around the medulla oblongata to the posterior aspect of the cord, and descends on either side, communicating very freely with the spinal branches of the intercostal and lumbar arteries. Near its commencement it sends a branch upwards to the fourth ventricle.

The *Inferior cerebellar* arteries wind around the upper part of the medulla oblongata to the under surface of the cerebellum, to which they are distributed. They pass between the filaments of origin of the hypoglossal nerve in their course, and anastomose with the superior cerebellar arteries.

The *Transverse* branches of the basilar artery supply the pons Varolii, and adjacent parts of the brain. One of these branches, larger than the rest, passes along the crus cerebelli to be distributed to the anterior border of the cerebellum. This may be called the middle cerebellar artery.

The *Superior cerebellar* arteries, two of the terminal branches of the basilar, wind around the crus cerebri on each side in relation with the fourth nerve, and are distributed to the upper surface of the cerebellum inosculating with the inferior cerebellar. This artery gives off a small branch which accompanies the seventh pair of nerves into the meatus auditorius internus.

The *Posterior cerebral* arteries, the other two terminal branches of the basilar, wind around the crus cerebri at each side, and are distributed to the posterior lobes of the cerebrum. They are sepa-

rated from the superior cerebellar artery, near the origin, by the third pair of nerves, and are in close relation with the fourth pair in their course around the crura cerebri. Anteriorly, near their origin, they give off a tuft of small vessels, which enter the locus perforatus, and they receive the posterior communicating arteries from the internal carotid. They also send a branch to the velum interpositum and plexus choroides.

The communications established between the anterior cerebral arteries in front, and the internal carotids and posterior cerebral arteries behind, by the communicating arteries, constitute the circle of Willis. This remarkable communication at the base of the brain is formed by the anterior communicating branch, anterior cerebrals, and internal carotid arteries in front, and by the posterior communicating, posterior cerebrals, and basilar artery behind.

The THYROID AXIS is a short trunk which divides almost immediately after its origin into four branches, some of which are occasionally branches of the subclavian artery itself.

The INFERIOR THYROID ARTERY ascends obliquely in a serpentine course behind the sheath of the carotid vessels, to the inferior part of the thyroid gland, to which it is distributed, and sends branches to the trachea, lower part of the larynx, and œsophagus. It is in relation with the middle cervical ganglion of the sympathetic, which lies in front of it.

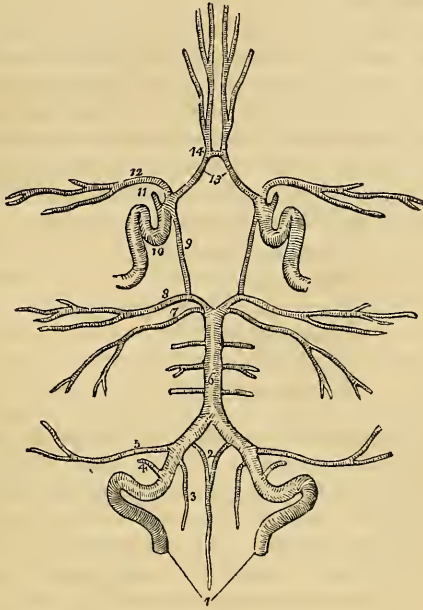
The SUPRA-SCAPULAR ARTERY (*transversalis humeri*) passes obliquely outwards behind the clavicle, and over the ligament of the supra-scapular notch, to the supra-spinatus fossa. It crosses in its course the scalenus anticus muscle, phrenic nerve and subclavian artery, is distributed to the muscles on the dorsum of the scapula, and inosculates with the posterior scapular, and beneath the acromion process with the dorsal branch of the subscapular artery. At the supra-scapular notch it sends a large branch to the trapezius muscle. The supra-scapular artery is not unfrequently a branch of the subclavian.

The POSTERIOR SCAPULAR ARTERY (*transversalis colli*) passes transversely across the subclavian triangle at the root of the neck, to the superior angle of the scapula. It then descends along the posterior border of that bone to its inferior angle, where it inosculates with the subscapular artery, a branch of the axillary. In its course across the neck it passes in front of the scalenus anticus, and across the brachial plexus; in the rest of its course it is covered in by the trapezius, levator anguli scapulæ, rhomboideus minor, and rhomboideus major muscles. Sometimes it passes behind the scalenus anticus, and between the nerves which constitute the brachial plexus. This artery, which is very irregular in its origin, proceeds more frequently from the third portion of the subclavian artery than from the first.

The posterior scapular gives branches to the neck, and opposite the angle of the scapula inosculates with the profunda cervicis. It supplies the muscles along the posterior border of the scapula, and

establishes an important anastomotic communication between the branches of the external carotid, subclavian, and axillary arteries.

Fig. 121.



The **SUPERFICIALIS CERVICIS ARTERY** (*cervicalis anterior*) is a small vessel, which ascends upon the anterior tubercles of the transverse processes of the cervical vertebræ, lying in the groove between the *scalenus anticus* and *rectus anticus major*. It is distributed to the deep muscles and glands of the neck, and sends branches through the intervertebral foramina to supply the spinal cord and its membranes.

The **PROFUNDA CERVICIS** (*cervicalis posterior*) passes backwards between the transverse processes of the seventh cervical and first dorsal vertebra, and then ascends the back part of the neck, between the *complexus* and *semi-spinalis colli* muscles. It inoscu-

Fig. 121. The circle of Willis. The branches of the arteries have references only on one side, on account of their symmetrical distribution. 1. The vertebral arteries. 2. The two anterior spinal branches uniting to form a single vessel. 3. One of the posterior spinal arteries. 4. The posterior meningeal. 5. The inferior cerebellar. 6. The basilar artery giving off its transverse branches to either side. 7. The superior cerebellar artery. 8. The posterior cerebral. 9. The posterior communicating branch of the internal carotid. 10. The internal carotid, showing the curvatures it makes within the skull. 11. The ophthalmic artery divided across. 12. The middle cerebral artery. 13. The anterior cerebral arteries connected by, 14. The anterior communicating artery.

lates above with the princeps cervicis of the occipital artery, and below, by a descending branch, with the posterior scapular.

The SUPERIOR INTERCOSTAL ARTERY descends behind the pleura upon the necks of the first two ribs, and inosculates with the first aortic intercostal. It gives off two branches which supply the two first intercostal spaces.

The INTERNAL MAMMARY ARTERY descends by the side of the sternum, resting upon the costal cartilages, to the diaphragm: it then pierces the anterior fibres of the diaphragm, and enters the sheath of the rectus, where it inosculates with the epigastric artery, a branch of the external iliac. In the upper part of its course it is crossed by the phrenic nerve, and lower down lies between the triangularis sterni and the internal intercostal muscles.

The *Branches* of the internal mammary are,—

Anterior intercostal,
Mammary,
Comes nervi phrenici,
Mediastinal,
Pericardiac,
Musculo-phrenic.

The *Anterior intercostals* supply the intercostal muscles of the front of the chest, and inosculate with the aortic intercostal arteries. Each of the three first anterior intercostals gives off a large branch to the mammary gland, which anastomoses freely with the thoracic branches of the axillary artery; the corresponding branches from the remaining intercostals supply the integument and pectoralis major muscle. There are usually two anterior intercostal arteries in each space.

The *Comes nervi phrenici* is a long and slender branch which accompanies the phrenic nerve.

The *mediastinal* and *pericardiac* branches are small vessels distributed to the anterior mediastinum, the thymus gland, and pericardium.

The *Musculo-phrenic* artery winds along the attachment of the diaphragm to the ribs, supplying that muscle and sending branches to the inferior intercostal spaces. “The mammary arteries,” says Dr. Harrison, “are remarkable for the number of their inosculations, and for the distant parts of the arterial system which they serve to connect. They anastomose with each other, and their inosculations, with the thoracic aorta, encircle the thorax. On the parietes of this cavity their branches connect the axillary and subclavian arteries; on the diaphragm they form a link in the chain of inosculations between the subclavian artery and abdominal aorta, and in the parietes of the abdomen they form an anastomosis most remarkable for the distance between those vessels which it serves to connect; namely, the arteries of the superior and inferior extremities.”

Varieties of the Subclavian Arteries.—Varieties in these arteries are rare; that which most frequently occurs is the origin of the right

subclavian, from the left extremity of the arch of the aorta, below the left subclavian artery. The vessel, in this case, curves behind the œsophagus and right carotid artery, and sometimes between the œsophagus and trachea, to the upper border of the first rib, on the right side of the chest, where it assumes its ordinary course. In a case* of subclavian aneurism on the right side, above the clavicle, which happened during the present summer, Mr. Liston proceeded to perform the operation of tying the carotid and subclavian arteries at their point of division from the innominata. Upon reaching the point where the bifurcation should have existed, he found that there was no subclavian artery. With that admirable self-possession which distinguishes this eminent surgeon in all cases of emergency, he continued his dissection more deeply, towards the vertebral column, and succeeded in securing the artery. It was ascertained after death, that the arteria innominata was extremely short, and that the subclavian was given off within the chest from the posterior aspect of its trunk, and pursued a deep course to the upper margin of the first rib. In a preparation which was shown to me in Heidelberg some years since by Professor Tiedemann, the right subclavian artery arose from the thoracic aorta, as low down as the fourth dorsal vertebra, and ascended from that point to the border of the first rib. Varieties in the branches of the subclavian are not unfrequent; the most interesting is the origin of the left vertebral, from the arch of the aorta, of which I possess several preparations.

AXILLARY ARTERY.

The *axillary artery* forms a gentle curve through the middle of the axillary space from the lower border of the first rib to the lower border of the latissimus dorsi, where it becomes the brachial.

Relations.—After emerging from beneath the margin of the costocoracoid membrane, it is in relation with the axillary vein, which lies at first to the inner side and then in front of the artery. Near the middle of the axilla it is embraced by the two heads of the median nerve, and is covered in by the pectoral muscles. Upon the *inner* or *thoracic side* it is in relation, first, with the first intercostal muscle; it next rests upon the first serration of the serratus magnus; and is then separated from the chest by the brachial plexus of nerves. By its *outer* or *humeral side* it is at first separated from the brachial plexus by a triangular cellular interval; it next rests against the tendon of the subscapularis muscle; and thirdly upon the coracobrachialis muscle.

* This case is recorded in the *Lancet*, Vol. I. 1839—40, pp. 37 and 419.

The *relations* of the axillary artery may be thus arranged :

<i>In front.</i>	<i>Inner or thoracic side.</i>	<i>Outer or humeral side.</i>
Pectoralis major,	First intercostal muscle,	Plexus of nerves,
Pectoralis minor,	First serration of ser-	Tendon of sub-
Pectoralis major.	ratus magnus,	scapularis,
	Plexus of nerves.	Coraco-brachialis.

Branches.—The branches of the *Axillary artery* are seven in number :

Thoracica acromialis,
Superior thoracic,
Inferior thoracic,
Thoracica axillaris,
Subscapular,
Circumflex anterior,
Circumflex posterior.

The *thoracica acromialis* and *superior thoracic* are found in the triangular space above the *pectoralis minor*.

The *inferior thoracic* and *thoracica axillaris*, below the *pectoralis minor*.

And the three remaining branches below the lower border of the *subscapularis*.

The *Thoracica acromialis* is a short trunk which ascends to the space above the *pectoralis minor* muscle, and divides into three branches,—*thoracic*, which is distributed to the pectoral muscles and mammary gland; *acromial*, which passes outwards to the acromion, and inosculates with the branches of the supra-scapular artery; and *descending*, which follows the interspace between the deltoid and *pectoralis major* muscles, and is in relation with the cephalic vein.

The *Superior thoracic* (short), very frequently arises by a common trunk with the preceding; it runs along the upper border of the *pectoralis minor*, and is distributed to the pectoral muscles and mammary gland, inosculating with the intercostal and mammary arteries.

The *Inferior thoracic* (long external mammary) descends along the lower border of the *pectoralis minor* to the side of the chest. It is distributed to the *pectoralis major* and *minor*, *serratus magnus*, and *subscapularis* muscle, to the axillary glands and mammary gland; inosculating with the superior thoracic, intercostal, and mammary arteries.

The *Thoracica axillaris* is a small branch distributed to the plexus of nerves and glands in the axilla. It is frequently derived from one of the other thoracic branches.

The *Subscapular artery*, the largest of the branches of the axillary, runs along the lower border of the *subscapularis* muscle, to the inferior angle of the scapula, where it inosculates with the posterior scapular, a branch of the subclavian. It supplies, in its course, the muscles on the under surface, and inferior border of the

scapula, and the side of the chest. At about an inch and a half from the axillary, it gives off a large branch, the *dorsalis scapulae*, which passes backwards through the triangular space bounded by the teres minor, teres major and scapular head of the triceps, and beneath the infra-spinatus to the dorsum of the scapula, where it is distributed, inosculating with the supra-scapular and posterior scapular arteries.

The *Circumflex arteries* wind around the neck of the humerus: The *anterior*, very small, passes beneath the coraco-brachialis and short head of the biceps, and sends a branch upwards along the bicipital groove to supply the shoulder-joint.

The *Posterior circumflex*, of larger size, passes backwards through the quadrangular space bounded by the teres minor and major, the scapular head of the triceps and the humerus, and is distributed to the deltoid muscle and joint. Sometimes this artery is a branch of the superior profunda of the brachial. It then ascends behind the tendon of the teres major, and is distributed to the deltoid without passing through the quadrangular space. The posterior circumflex artery sends branches to the shoulder-joint.

Varieties of the Axillary Artery.—The most frequent peculiarity of this kind is the division of the vessel into two trunks of equal size; a muscular trunk, which gives off some of the ordinary axillary branches and supplies the upper arm, and a continued trunk, which represents the brachial artery. The next most frequent variety is the high division of the ulnar, which passes down the arm by the

Fig. 122.

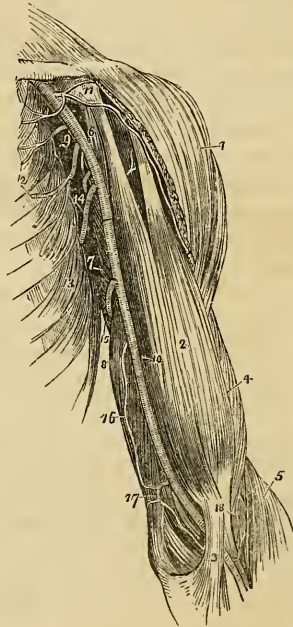


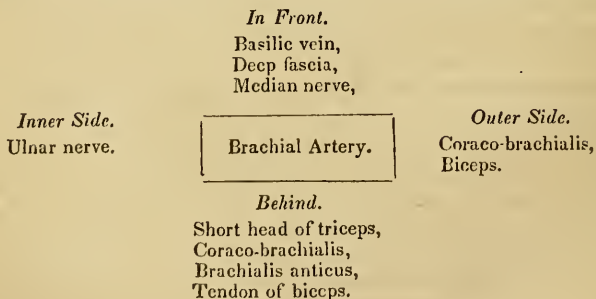
Fig. 122. The axillary and brachial artery, with their branches. 1. The deltoid muscle. 2. The biceps. 3. The tendinous process given off from the tendon of the biceps, to the deep fascia of the fore-arm. It is this process which separates the median basilic vein from the brachial artery. 4. The outer border of the brachialis anticus muscle. 5. The supinator longus. 6. The coraco-brachialis. 7. The middle portion of the triceps muscle. 8. Its inner head. 9. The axillary artery. 10. The brachial artery;—a dark line marks the limit between these two vessels. 11. The thoracica acromialis artery dividing into its three branches; the number rests upon the coracoid process. 12. The superior and inferior thoracic arteries. 13. The serratus magnus muscle. 14. The subscapular artery. The posterior circumflex and thoracica axillaris branches are seen in the figure between the inferior thoracic and subscapular. The anterior circumflex is observed, between the two heads of the biceps, crossing the neck of the humerus. 15. The superior profunda artery. 16. The inferior profunda. 17. The anastomotica magna inosculating inferiorly, with the anterior ulnar recurrent. 18. The termination of the superior profunda, inosculating with the radial recurrent in the interspace between the brachialis anticus and supinator longus.

side of the brachial artery, and superficially to the muscles proceeding from the inner condyle, to its ordinary distribution in the hand. In this course it lies immediately beneath the deep fascia of the forearm, and may be seen and felt pulsating beneath the integument. The high division of the radial from the axillary is rare. In one instance, I saw the axillary artery divide into three branches of nearly equal size, which passed together down the arm, and at the bend of the elbow resolved themselves into radial, ulnar, and interosseous. But the most interesting variety, both in a physiological and surgical sense, is that described by Dr. Quain in his "Elements of Anatomy." "I found in the dissecting-room, a few years ago, a variety not hitherto noticed: it was at first taken for the ordinary high division of the ulnar artery. The two vessels descended from the point of division at the border of the axilla, and lay parallel with one another in their course through the arm; but instead of diverging, as is usual at the bend of the elbow, they converged, and united so as to form a short trunk, which soon divided again into the radial and ulnar arteries in the regular way." In a subject, dissected during the past winter in Sydenham College, this variety existed in both arms; and I have seen several other instances of a similar kind.

BRACHIAL ARTERY.

The *Brachial artery* passes down the inner side of the arm, from the lower border of the latissimus dorsi to the bend of the elbow, where it divides into the radial and ulnar arteries.

Relations.—In its course downwards, it rests upon the coracobrachialis muscle, internal head of the triceps, brachialis anticus, and the tendon of the biceps. To its inner side is the ulnar nerve; to the outer side, the coraco-brachialis and biceps muscles; in front it has the basilic vein, and is crossed by the median nerve. Its relations, within its sheath, are the venæ comites.

Plan of the *relations* of the Brachial Artery.

The *branches* of the brachial artery are, the—

Superior profunda,
Inferior profunda,
Anastomotica magna,
Muscular.

The *Superior profunda* arises opposite the lower border of the latissimus dorsi, and winds around the humerus, between the triceps and the bone, in the space between the brachialis anticus and supinator longus, where it inosculates with the radial recurrent branch. It accompanies the musculo-spiral nerve. In its course it gives off the posterior articular artery, which descends to the elbow-joint, and a more superficial branch, which inosculates with the interosseous articular artery.

The *Inferior profunda* arises from about the middle of the brachial artery, and descends to the space between the inner condyle and olecranon in company with the ulnar nerve, where it inosculates with the posterior ulnar recurrent.

The *Anastomotica magna* is given off nearly at right angles from the brachial, at about two inches above the joint. It passes directly inwards, and divides into two branches, which inosculate with the anterior and posterior ulnar recurrent arteries and with the inferior profunda.

The *Muscular branches* are distributed to the muscles in the course of the artery, viz. to the coraco-brachialis, biceps, deltoid, brachialis anticus and triceps.

Varieties of the Brachial Artery.—The most frequent peculiarity in the distribution of branches from this artery is the high division of the radial, which arises generally from about the upper third of the brachial artery and descends to its normal position at the bend of the elbow. The ulnar artery sometimes arises from the brachial at about two inches above the elbow, and pursues either a superficial or deep course to the wrist; and in more than one instance I have seen the interosseous artery arise from the brachial a little above the bend of the elbow. The two profunda arteries occasionally arise by a common trunk, or there may be two superior profundæ.

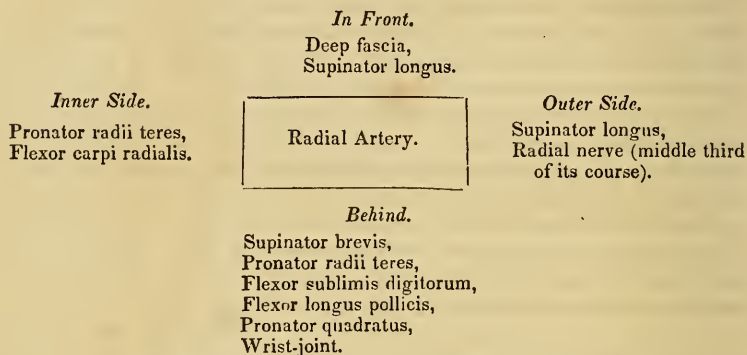
RADIAL ARTERY.

The *Radial artery*, one of the divisions of the brachial, appears from its direction to be the continuation of that trunk. It runs along the radial side of the fore-arm, from the bend of the elbow to the wrist; it there turns round the base of the thumb, beneath its extensor tendons, and passes between the two heads of the first dorsal interosseous muscle, into the palm of the hand. It then crosses the metacarpal bones to the ulnar side of the hand, forming the *deep palmar arch*, and terminates by inosculating with the superficial palmar arch.

In the upper half of its course, the radial artery is situated between the supinator longus muscle, by which it is overlapped superiorly, and the pronator radii teres; in the lower half, between the tendons of the supinator longus and flexor carpi radialis. It rests in its course downwards, upon the supinator brevis, pronator radii teres, radial origin of the flexor sublimis, flexor longus pollicis, and pro-

nator quadratus; and it is covered in by the integument and fasciæ. At the wrist it is situated in contact with the dorsal carpal ligaments and beneath the extensor tendons of the thumb; and in the palm of the hand, beneath the flexor tendons. It is accompanied by venæ comites throughout its course, and for its middle third is in close relation with the radial nerve.

Plan of the *relations* of the Radial Artery in the fore-arm.



The *Branches* of the radial artery may be arranged into three groups, corresponding with the three regions, the fore-arm, the wrist, and the hand; they are—

<i>Fore-arm,</i>	{	Recurrent radial, Muscular.
<i>Wrist,</i>	{	Superficialis volæ, Carpalis anterior, Carpalis posterior, or dorsalis carpi, Metacarpalis, Dorsales pollicis.
<i>Hand,</i>	{	Princeps, or magna pollicis, Radialis indicis, Interosseæ, Perforantes.

The *Recurrent* branch is given off immediately below the elbow; it ascends in the space between the supinator longus and brachialis anticus to supply the joint, and inosculates with the terminal branches of the superior profunda. This vessel gives off numerous muscular branches.

The *Muscular branches* are distributed to the muscles on the radial side of the fore-arm.

The *Superficialis volæ* is given off from the radial artery while at the wrist. It passes between the fibres of the abductor pollicis muscle, and inosculates with the termination of the ulnar artery, completing the superficial palmar arch. This artery is very variable

in size, being sometimes as large as the continuation of the radial, and at other times a mere muscular ramusculus, or entirely wanting; when of large size it supplies the palmar side of the thumb and the radial side of the index finger.

The *Carpal* branches are intended for the supply of the wrist, the anterior carpal *in front*, and the posterior, the larger of the two, *behind*. The *carpalis posterior* crosses the carpus transversely to the ulnar border of the hand, where it inosculates with the posterior carpal branch of the ulnar artery. Superiorly it sends branches which inosculate with the termination of the anterior interosseous artery; inferiorly, it gives off *posterior interosseous branches*, which anastomose with the perforating branches of the deep palmar arch, and then run forwards upon the dorsal interossei muscles.

The *Metacarpal* branch runs forwards on the second dorsal interosseous muscle, and inosculates with the digital branch of the superficial palmar arch, which supplies the adjoining sides of the index and middle fingers. Sometimes it is of large size, and the true continuation of the radial artery.

The *Dorsales pollicis* are two small branches which run along the sides of the dorsal aspect of the thumb.

The *Princeps pollicis* descends along the border of the metacarpal bone, between the abductor indicis and adductor pollicis to the base of the first phalanx, where it divides into two branches, which are distributed to the two sides of the palmar aspect of the thumb.

The *Radialis indicis* is also situated between the abductor indicis

Fig. 123.

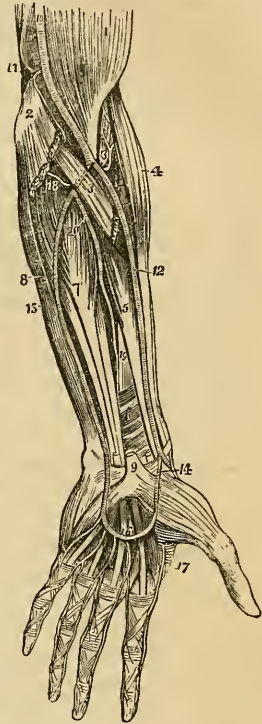


Fig. 123. The arteries of the fore-arm. 1. The lower part of the biceps muscle. 2. The inner condyle of the humerus with the humeral origin of the pronator radii teres and flexor carpi radialis divided across. 3. The deep portion of the pronator radii teres. 4. The supinator longus muscle. 5. The flexor longus pollicis. 6. The pronator quadratus. 7. The flexor profundus digitorum. 8. The flexor carpi ulnaris. 9. The annular ligament with the tendons passing beneath it into the palm of the hand; the figure is placed on the tendon of the palmaris longus muscle, divided close to its insertion. 10. The brachial artery. 11. The anastomotica magna inosculating superiorly with the inferior profunda, and inferiorly with the anterior ulnar recurrent. 12. The radial artery. 13. The radial recurrent artery inosculating with the termination of the superior profunda. 14. The superficialis volæ. 15. The ulnar artery. 16. Its superficial palmar arch giving off digital branches to three fingers and a half. 17. The magna pollicis and radialis indicis arteries. 18. The posterior ulnar recurrent. 19. The anterior interosseous artery. 20. The posterior interosseous, as it is passing through the interosseous membrane.

and adductor pollicis, and runs along the radial side of the index finger, forming its collateral artery. This vessel is frequently a branch of the princeps pollicis.

The *Interosseæ*, three or four in number, are branches of the deep palmar arch; they pass forwards upon the interossei muscles and inosculate with the digital branches of the superficial arch, opposite the heads of the metacarpal bones.

The *Perforantes*, three in number, pass directly backwards between the heads of the dorsal interossei muscles, and inosculate with the posterior interosseous arteries.

ULNAR ARTERY.

The *Ulnar artery*, the other division of the brachial artery, crosses the arm obliquely to the commencement of its middle third; it then runs down the ulnar side of the fore-arm to the wrist, crosses the annular ligament, and forms the superficial palmar arch, which terminates by inosculating with the superficialis volæ.

Relations.—In the upper or oblique portion of its course, it lies upon the brachialis anticus, and flexor profundus digitorum; and is covered in by the superficial layer of muscles of the fore-arm and the median nerve. In the second part of its course, it is placed upon the flexor profundus, and pronator quadratus, lying between the flexor carpi ulnaris and flexor sublimis digitorum. While crossing the annular ligament it is protected from injury by a strong tendinous arch thrown over it from the pisiform bone: and in the palm it rests upon the tendons of the flexor sublimis, being covered in by the palmaris brevis muscle and palmar fascia. It is accompanied in its course by the venæ comites, and is in relation with the ulnar nerve for the lower two-thirds of its extent.

Plan of the *relations* of the Ulnar Artery.

In Front.

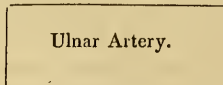
Deep fascia,
Superficial layer of muscles,
Median nerve.

In the Hand.

Tendinous arch, from the pisiform bone,
Palmaris brevis muscle,
Palmar fascia,

Inner Side.

Flexor carpi ulnaris,
Ulnar nerve (lower two-thirds.)



Outer Side.

Flexor sublimis digitorum.

Behind.

Brachialis anticus,
Flexor profundus digitorum,
Pronator quadratus.

In the Hand.

Annular ligament,
Tendons of the flexor sublimis digitorum.

The *Branches* of the *ulnar artery* may be arranged like those of the radial into three groups :

<i>Fore-arm</i>	{	Anterior ulnar recurrent,	
		Posterior ulnar recurrent,	
		Interosseous	{ Anterior interosseous, Posterior interosseous,
	{	Muscular.	
<i>Wrist</i>	{	Carpalis anterior,	
		Carpalis posterior, or dorsalis manus.	
<i>Hand</i>		Digitales.	

The *Anterior ulnar recurrent* arises immediately below the elbow, and ascends in front of the joint between the pronator radii teres and brachialis anticus, where it inosculates with anastomotica magna and inferior profunda. The two recurrent arteries frequently arise by a common trunk.

The *Posterior ulnar recurrent*, larger than the preceding, arises immediately below the elbow-joint, and passes backwards beneath the origins of the superficial layer of muscles; it then ascends between the two heads of the flexor carpi ulnaris, and beneath the ulnar nerve, and inosculates with the inferior profunda and anastomotica magna.

The *Common interosseous artery* is a short trunk which arises from the ulnar, opposite to the bicapital tuberosity of the radius. It divides into two branches, the anterior and posterior interosseous arteries.

The *Anterior interosseous* passes down the fore-arm upon the interosseous membrane, between the flexor profundus digitorum and flexor longus pollicis, and behind the pronator quadratus it pierces that membrane and descends to the back of the wrist, where it inosculates with the posterior carpal branches of the radial and ulnar. It is retained in connexion with the interosseous membrane by means of a thin aponeurotic arch.

The anterior interosseous artery sends a branch to the median nerve, which it accompanies into the hand. The *median* artery is sometimes of large size, and I have seen it take the place of the superficial palmar arch.

The *Posterior interosseous* artery passes backwards through an opening between the upper part of the interosseous membrane and the oblique ligament, and is distributed to the muscles on the posterior aspect of the fore-arm. It gives off a *recurrent branch*, which returns upon the elbow between the anconeus, extensor carpi ulnaris and supinator brevis muscles, and anastomoses with the posterior terminal branches of the superior profunda.

The *Muscular branches* supply the muscles situated along the ulnar border of the fore-arm.

The *Carpal branches, anterior and posterior*, are distributed to the

anterior and posterior aspects of the wrist-joint, where they inosculate with corresponding branches of the radial artery.

The *Digital branches* are given off from the superficial palmar arch, and are four in number. The first and smallest is distributed to the ulnar side of the little finger. The other three are short trunks, which divide between the heads of the metacarpal bones, and form the collateral branch of the radial side of the little finger, the collateral branches of the ring and middle fingers, and the collateral branch of the ulnar side of the index finger.

The *Superficial palmar arch* receives the termination of the deep palmar arch from between the abductor minimi digiti and flexor brevis minimi digiti near to their origins, and terminates by inosculating with the superficialis volæ upon the ball of the thumb. The communication between the superficial and deep arch is generally described as the *communicating branch* of the ulnar artery.

The mode of distribution of the arteries to the hand is subject to great variety.

BRANCHES OF THE THORACIC AORTA.

Bronchial,
Œsophageal,
Intercostal.

The BRONCHIAL ARTERIES are four in number, and vary both in size and origin. They are distributed to the bronchial glands and tubes, and send branches to the œsophagus, pericardium, and left auricle of the heart. These are the nutritious vessels of the lungs.

The ŒSOPHAGEAL ARTERIES are numerous small branches; they arise from the anterior part of the aorta, are distributed to the œsophagus, and establish a chain of anastomosis along that tube: the superior inosculate with the bronchial arteries, and with œsophageal branches of the inferior thyroid arteries; and the inferior with similar branches of the phrenic and gastric arteries.

The INTERCOSTAL, or posterior intercostal arteries, arise from the posterior part of the aorta; they are nine in number on each side, the two superior spaces being supplied by the superior intercostal artery, a branch of the subclavian. The right intercostals are longer than the left, on account of the position of the aorta. They ascend somewhat obliquely from their origin, and cross the vertebral column behind the thoracic duct, vena azygos major, and sympathetic nerve, to the intercostal spaces, the left passing beneath the superior intercostal vein, the vena azygos minor and sympathetic. In the intercostal spaces, or rather, upon the external intercostal muscles, each artery gives off a *dorsal branch*, which passes back between the transverse processes of the vertebræ, lying internally to the middle costo-transverse ligament, and divides into a spinal branch, which supplies the spinal cord and vertebræ, and a muscular branch which is distributed to the muscles and integument of the back. It then comes into relation with its vein and nerve,

the former being above, and the latter below, and divides into two branches which run along the borders of the contiguous ribs between the two planes of intercostal muscles, and anastomose with the anterior intercostal arteries, branches of the internal mammary. The branch corresponding with the lower border of each rib is the larger of the two. They are protected from pressure during the action of the intercostal muscles, by little tendinous arches thrown across and attached by each extremity to the bone.

BRANCHES OF THE ABDOMINAL AORTA.

Phrenic,
 Cæliac axis $\left\{ \begin{array}{l} \text{Gastric,} \\ \text{Hepatic,} \\ \text{Splenic,} \end{array} \right.$
 Superior mesenteric,
 Spermatic,
 Inferior mesenteric,
 Supra-renal, or capsular,
 Renal, or emulgent,
 Lumbar,
 Sacra media.

The PHRENIC ARTERIES are given off from the anterior part of the aorta as soon as that trunk has passed through the aortic opening. Passing obliquely outwards upon the under surface of the diaphragm, each artery divides into two branches, an *internal branch* which runs forwards and inosculates with its fellow of the opposite side in front of the œsophageal opening; and an *external branch* which proceeds outwards towards the great circumference of the muscle, and sends branches to the supra-renal capsules. The phrenic arteries inosculate with branches of the internal mammary, inferior intercostal, epigastric, œsophageal, gastric, hepatic, and supra-renal arteries. They are frequently derived from the cæliac axis, or from one of its divisions, and sometimes they give off the supra-renal arteries.

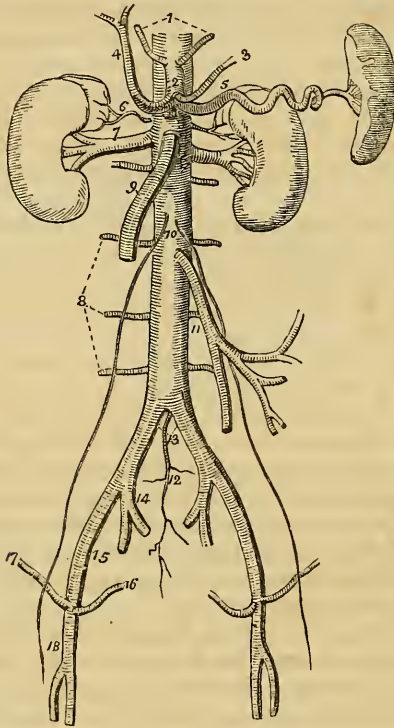
The CÆLIAC AXIS ($\kappa\omicron\iota\lambda\acute{\iota}\alpha$, ventriculus) is the first single trunk given off from the abdominal aorta. It arises opposite the upper border of the first lumbar vertebræ, is about half an inch in length, and divides into three large branches—gastric, hepatic, and splenic.

Relations.—The trunk of the cæliac axis has in relation with it, *in front* the lesser omentum; on the *right side* the right semilunar ganglion and lobulus Spigelii of the liver; on the *left side* the left semilunar ganglion and cardiac portion of the stomach; and *below* the upper border of the pancreas and lesser curve of the stomach. It is completely surrounded by the solar plexus.

The GASTRIC ARTERY (coronaria ventriculi), the smallest of the three branches of the cæliac axis, ascends between the two layers of the lesser omentum to the cardiac orifice of the stomach, then runs along the lesser curvature to the pylorus, and inosculates with

the pyloric branch of the hepatic. It is distributed to the lower extremity of the œsophagus and lesser curve of the stomach, and anastomoses with the œsophageal arteries and vasa brevia of the splenic artery.

Fig. 124.



The HEPATIC ARTERY curves forwards, and ascends along the right border of the lesser omentum to the liver, where it divides into two branches (right and left), which enter the transverse fissure, and are distributed along the portal canals to the right and left lobes.* It is in relation in the right border of the lesser omentum, with the ductus communis choledochus and portal vein, and is surrounded by the

Fig. 124. The abdominal aorta with its branches. 1. The phrenic arteries. 2. The cœliac axis. 3. The gastric artery. 4. The hepatic artery, dividing into the right and left hepatic branches. 5. The splenic artery, passing outwards to the spleen. 6. The supra-renal artery of the right side. 7. The right renal artery, which is longer than the left, passing outwards to the right kidney. 8. The lumbar arteries. 9. The superior mesenteric artery. 10. The two spermatic arteries. 11. The inferior mesenteric artery. 12. The sacra media. 13. The common iliacs. 14. The internal iliac of the right side. 15. The external iliac artery. 16. The epigastric artery. 17. The circumflexa ili artery. 18. The femoral artery.

* For the mode of distribution of the hepatic artery within the liver, see the "Minute Anatomy" of that organ in the Chapter on the Viscera.

hepatic plexus of nerves and numerous lymphatics. There are sometimes two hepatic arteries, in which case one is derived from the superior mesenteric artery.

The *Branches* of the hepatic artery are the

Pyloric,	
Gastro-duodenalis,	{ Gastro-epiploica dextra,
	{ Pancreatico-duodenalis.
Cystic.	

The *Pyloric branch*, given off from the hepatic near to the pylorus, is distributed to the commencement of the duodenum and to the lesser curve of the stomach, where it inosculates with the gastric artery.

The *Gastro-duodenalis artery* is a short but large trunk, which descends behind the pylorus, and divides into two branches, the gastro-epiploica dextra, and pancreatico-duodenalis. Previously to its division, it gives off some *inferior pyloric* branches to the small end of the stomach.

The *Gastro-epiploica dextra* runs along the great curve of the stomach lying between the two layers of the great omentum, and inosculates at about its middle with the gastro-epiploica sinistra, a branch of the splenic artery. It supplies the great curve of the stomach and the great omentum; hence the derivation of its name.

The *Pancreatico-duodenalis* curves along the fixed border of the duodenum, partly concealed by the attachment of the pancreas, and is distributed to the pancreas and duodenum. It inosculates inferiorly with the first jejunal and with the pancreatic branches of the superior mesenteric artery.

The *Cystic artery*, generally a branch of the right hepatic, is of small size, and ramifies between the coats of the gall bladder, previously to its distribution to the mucous membrane.

The **SPLenic ARTERY**, the largest of the three branches of the cœliacæ axis, passes horizontally to the left along the upper border of the pancreas, and divides into five or six large branches which enter the hilum of the spleen and are distributed to its structure. In its course it is tortuous and serpentine, and frequently makes a complete turn upon itself. It lies in a narrow groove in the upper border of the pancreas, and is accompanied by the splenic vein, and by the splenic plexus of nerves.

The *Branches* of the splenic artery are—

Pancreaticæ parvæ,
 Pancreatica magna,
 Vasa brevia,
 Gastro-epiploica sinistra.

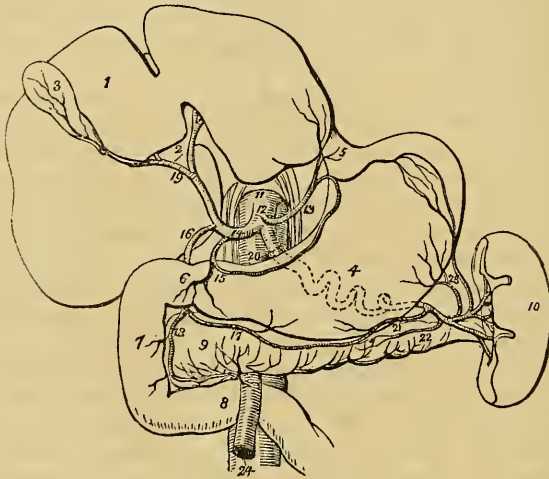
The *Pancreaticæ parvæ* are numerous small branches distributed to the pancreas, as the splenic artery runs along its upper border.

One of these, larger than the rest, follows the course of the pancreatic duct, and is called *pancreatica magna*.

The *Vasa brevia* are five or six branches of small size which pass from the extremity of the splenic artery and its terminal branches, between the layers of the gastro-splenic omentum, to the great end of the stomach, to which they are distributed, inosculating with branches of the gastric artery and of the gastro-epiploica sinistra.

The *Gastro-epiploica sinistra* appears to be the continuation of the splenic artery; it passes forwards from left to right, along the great curve of the stomach, lying between the layers of the great omentum, and inosculates with the gastro-epiploica dextra. It is distributed to the greater curve of the stomach and to the great omentum.

Fig. 125.



The SUPERIOR MESENTERIC ARTERY, the second of the single trunks, and next in size to the cœliac axis, arises from the aorta

Fig. 125. The distribution of the branches of the cœliac axis. 1. The liver. 2. Its transverse fissure. 3. The gall bladder. 4. The stomach. 5. The entrance of the œsophagus. 6. The pylorus. 7. The duodenum, its descending portion. 8. The transverse portion of the duodenum. 9. The pancreas. 10. The spleen. 11. The aorta. 12. The cœliac axis. 13. The gastric artery. 14. The hepatic artery. 15. Its pyloric branch. 16. The gastro-duodenalis. 17. The gastro-epiploica dextra. 18. The pancreatico-duodenalis, inosculating with a branch from the superior mesenteric artery. 19. The division of the hepatic artery into its right and left branches; the right giving off the cystic branch. 20. The splenic artery, traced by dotted lines behind the stomach to the spleen. 21. The gastro-epiploica sinistra, inosculating along the great curvature of the stomach with the gastro-epiploica dextra. 22. The pancreatico-duodenalis. 23. The vasa brevia to the great end of the stomach, inosculating with branches of the gastric artery. 24. The superior mesenteric artery, emerging from between the pancreas and the transverse portion of the duodenum.

immediately below that vessel and behind the pancreas. It passes forwards between the pancreas and transverse duodenum, and descends within the layers of the mesentery, to the right iliac fossa, where it terminates, very much diminished in size. It forms a curve in its course, the convexity being directed towards the left, and the concavity to the right. It is in relation near its commencement with the portal vein; and is accompanied by two veins, and the superior mesenteric plexus of nerves.

The *branches* of the superior Mesenteric Artery are—

Vasa intestini tenuis,
Ileo-colica,
Colica dextra,
Colica media.

Fig. 126.

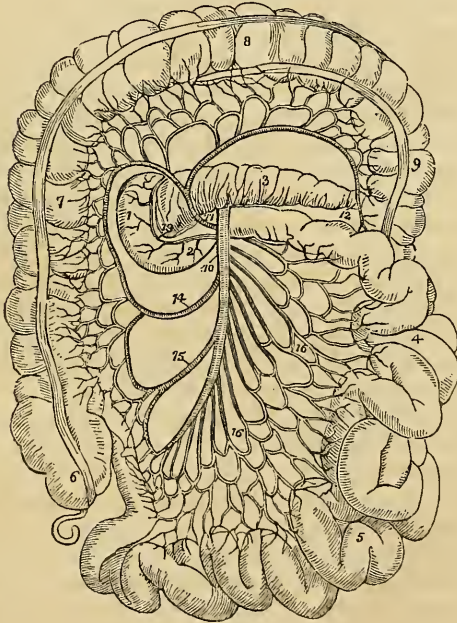

Fig. 126. The course and distribution of the superior mesenteric artery. 1. The descending portion of the duodenum. 2. The transverse portion. 3. The pancreas. 4. The jejunum. 5. The ileum. 6. The cæcum, from which the appendix vermiformis is seen projecting. 7. The ascending colon. 8. The transverse colon. 9. The commencement of the descending colon. 10. The superior mesenteric artery. 11. The colica media. 12. The branch which inosculates with the colica sinistra. 13. The branch of the superior mesenteric artery, which inosculates with the pancreatico-duodenalis. 14. The colica dextra. 15. The ileo-colica. 16, 16. The branches from the convexity of the superior mesenteric to the small intestines.

The *Vasa intestini tenuis* arise from the convexity of the superior mesenteric artery. They vary from fifteen to twenty in number, and are distributed to the small intestine from the duodenum to the termination of the ileum. In their course between the layers of the mesentery, they form a series of arches by the inosculation of their larger branches; from these are developed secondary arches, and from the latter a third series of arches, from which the branches arise which are distributed to the coats of the intestine. From the middle branches a fourth and sometimes even a fifth series of arches is produced. By means of these arches a direct communication is established between all the branches given off from the convexity of the superior mesenteric artery; the superior branches moreover supply the pancreas and duodenum, and inosculate with the pancreatico-duodenalis; and the inferior with the ileo-colica.

The *Ileo-colica artery* is the last branch given off from the concavity of the superior mesenteric. It descends to the right iliac fossa, and divides into branches which communicate and form arches, from which branches are distributed to the termination of the ileum, the cæcum, and the commencement of the colon. This artery inosculates on the one hand with the last branches of the vasa intestini tenuis, and on the other with the colica dextra.

The *Colica dextra* arises from about the middle of the concavity of the superior mesenteric, and divides into branches which form arches, and are distributed to the ascending colon. Its descending branches inosculate with the ileo-colica, and the ascending with the colica media.

The *Colica media* arises from the upper part of the concavity of the superior mesenteric, and passes forwards between the layers of the transverse mesocolon, where it forms arches, and is distributed to the transverse colon. It inosculates on the right with the colica dextra; and on the left with the colica sinistra, a branch of the inferior mesenteric artery.

The SPERMATIC ARTERIES are two small vessels which arise from the front of the aorta below the superior mesenteric; from this origin each artery passes obliquely outwards, and accompanies the corresponding ureter along the front of the psoas muscle to the border of the pelvis, where it is in relation with the external iliac artery. It is then directed outwards to the internal abdominal ring, and follows the course of the spermatic cord along the spermatic canal, and through the scrotum to the testicle, to which it is distributed. The right spermatic artery lies in front of the vena cava, and both vessels are accompanied by their corresponding veins and by the spermatic plexuses of nerves.

The spermatic arteries in the female descend into the pelvis and pass between the two layers of the broad ligaments of the uterus, to be distributed to the ovaries, Fallopian tubes, and round ligaments; along the latter they are continued to the inguinal canal and labium at each side.

They inosculate with the uterine arteries.

The INFERIOR MESENTERIC ARTERY, smaller than the superior, arises from the abdominal aorta, about two inches below the origin of that vessel, and descends between the layers of the left mesocolon, to the left iliac fossa, where it divides into three *branches* :

Colica sinistra, superior,
 Sigmoideæ, or colica sinistra media and inferior,
 Superior hæmorrhoidal.

The *Colica sinistra* is distributed to the descending colon, and ascends to inosculate with the colica media. This is the largest arterial inosculature in the body.

Fig. 127.

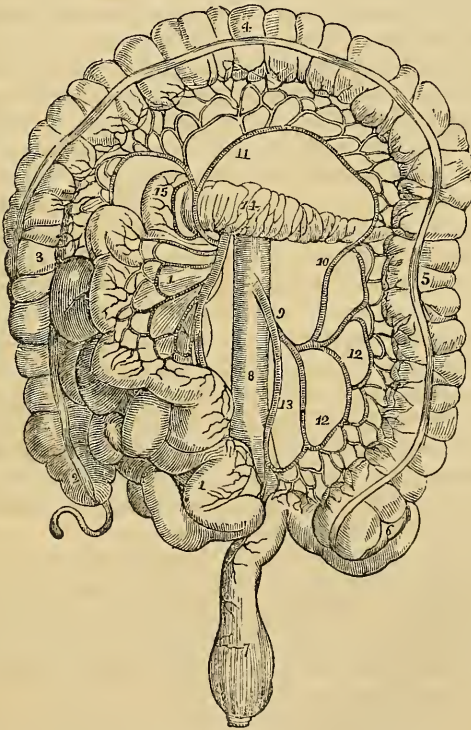


Fig. 127. The distribution and branches of the inferior mesenteric artery. 1, 1. The superior artery with its branches and the small intestines turned over to the right side. 2. The cæcum and appendix cæci. 3. The ascending colon. 4. The transverse colon raised upwards. 5. The descending colon. 6. Its sigmoid flexure. 7. The rectum. 8. The aorta. 9. The inferior mesenteric artery. 10. The colica sinistra, inosculating with 11. The colica media, a branch of the superior mesenteric artery. 12, 12. Sigmoid branches. 13. The superior hæmorrhoidal artery. 14. The pancreas. 15. The descending portion of the duodenum.

The *Sigmoideæ* are several large branches which are distributed to the sigmoid flexure of the descending colon. They form arches, and inosculate above with the colica sinistra, and below with the superior hæmorrhoidal artery.

The *Superior hæmorrhoidal* artery is the continuation of the inferior mesenteric. It crosses the ureter and common iliac artery of the left side, and descends between the two layers of the mesorectum as far as the middle of the rectum to which it is distributed, anastomosing with the middle and external hæmorrhoidal arteries.

The SUPRA-RENAL are two small vessels which arise from the aorta immediately above the renal arteries, and are distributed to the supra-renal capsules. They are sometimes branches of the phrenic or of the renal arteries.

The RENAL ARTERIES (emulgent) are two large trunks given off from the sides of the aorta immediately below the superior mesenteric artery; the right is longer than the left on account of the position of the aorta, and passes behind the vena cava to the kidney of that side. The left is somewhat higher than the right. They divide into several large branches previously to entering the kidney, and ramify very minutely in its vascular portion. The renal arteries supply several small branches to the supra-renal capsules.

The LUMBAR ARTERIES correspond with the intercostals in the chest; they are four or five in number on each side, and curve around the bodies of the lumbar vertebræ beneath the psoas muscles, and divide into two branches; one of which passes backwards between the transverse processes and is distributed to the vertebræ and spinal cord and to the muscles of the back, whilst the other takes its course behind the quadratus lumborum muscle and supplies the abdominal muscles. The first lumbar artery runs along the lower border of the last rib, and the last along the crest of the ilium. In passing between the psoas muscles and the vertebræ, they are protected by a series of tendinous arches, which defend them and the communicating branches of the sympathetic nerve from pressure during the action of the muscle.

The SACRA MEDIA arises from the posterior part of the aorta at its bifurcation, and descends along the middle of the anterior surface of the sacrum to the first piece of the coccyx, where it terminates by inosculating with the lateral sacral arteries. It distributes branches to the rectum and anterior sacral nerves, and inosculates on either side with the lateral sacral arteries.

Varieties in the Branches of the Abdominal Aorta.—The phrenic arteries are very rarely both derived from the aorta. One or both may be branches of the celiac axis; one may proceed from the gastric artery, from the renal, or from the upper lumbar artery. There are occasionally three or more phrenic arteries. The celiac axis is very variable in length, and gives off its branches irregularly. There are sometimes two or even three hepatic arteries, one of which may be derived from the gastric or even from the superior mesenteric. The colica media is sometimes derived from the hepatic

artery. The spermatic arteries are very variable both in origin and number. The right spermatic may be a branch of the renal artery, and the left a branch of the inferior mesenteric. The supra-renal arteries may be derived from the phrenic or renal arteries. The renal arteries present several varieties in number; there may be three or even four arteries on one side and one only on the other. When there are several renal arteries on one side, one may arise from the common iliac artery, from the front of the aorta near its lower part, or from the internal iliac.

COMMON ILIAC ARTERIES.

The abdominal aorta divides opposite the fourth lumbar vertebræ into the two common iliac arteries. Sometimes the bifurcation takes place as high as the third, and occasionally as low as the fifth lumbar vertebra. The common iliac arteries are about two inches and a half in length; they diverge from the termination of the aorta, and pass downwards and outwards on each side to the margin of the pelvis opposite the sacro-iliac symphysis, where they divide into the internal and external iliac arteries. In old persons the common iliac arteries are more or less dilated and curved in their course.

The *Right common iliac* is somewhat longer than the left and forms a more obtuse angle with the termination of the aorta; the angle of bifurcation is greater in the female than in the male.

Relations.—The relations of the two arteries are different on the two sides of the body. The *right* common iliac is in relation in front with the peritoneum, and is crossed at its bifurcation by the ureter. It is in relation posteriorly with the two common iliac veins, and externally with the psoas magnus. The *left* is in relation in front with the peritoneum, and is crossed by the rectum and superior hæmorrhoidal artery, and at its bifurcation by the ureter. It is in relation behind with the left common iliac vein, and externally with the psoas magnus.

INTERNAL ILIAC ARTERY.

The Internal Iliac Artery is a short trunk, varying in length from an inch to two inches. It descends obliquely to a point opposite the upper margin of the great sacro-ischiatic foramen, where it divides into an anterior and a posterior trunk.

Relations.—This artery rests externally upon the sacral plexus and upon the origin of the pyriformis muscle; posteriorly it is in relation with the internal iliac vein, and anteriorly with the ureter.

Branches.—The branches of the anterior trunk are the—

Umbilical,	Ischiatic,
Middle vesical,	Internal pudic.
Middle hæmorrhoidal,	

And in the female the—

Uterine,	Vaginal.
----------	----------

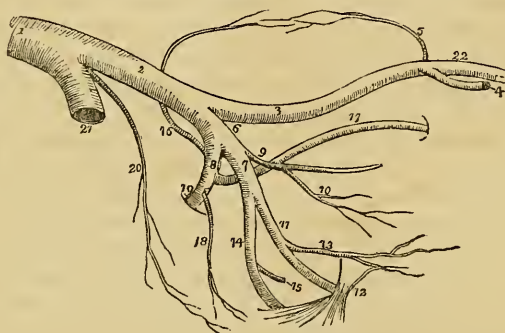
And of the posterior trunk the—

Ilio-lumbar,
Obturator,

Lateral sacral,
Gluteal.

The *umbilical artery* is the commencement of the fibrous cord into which the umbilical artery of the fœtus is converted after birth. In after life, the cord remains pervious for a short distance, and constitutes the umbilical artery of the adult, from which the *superior vesical artery* is given off to the fundus and anterior aspect of the bladder. The cord may be traced forwards by the side of the fundus of the bladder to near its apex, whence it ascends by the side of the *linea alba* and *urachus* to the umbilicus.

Fig. 128.



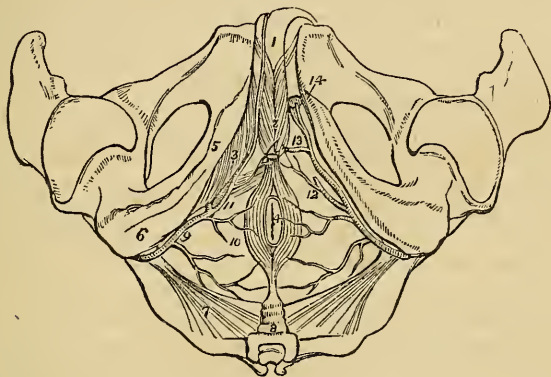
The *Middle vesical artery* is generally a branch of the umbilical, and sometimes of the internal iliac. It is somewhat larger than the superior vesical, and is distributed to the posterior part of the body of the bladder, the vesiculæ seminales, and prostate gland.

The *Middle hæmorrhoidal artery* is as frequently derived from the ischiatic or internal pudic as from the internal iliac. It is of variable size, and is distributed to the rectum, base of the bladder, vesiculæ seminales, and prostate gland; and inosculates with the superior and external hæmorrhoidal arteries.

Fig. 128. The distribution and branches of the iliac arteries. 1. The aorta. 2. The left common iliac artery. 3. The external iliac. 4. The epigastric artery. 5. The circumflexa ilii. 6. The internal iliac artery. 7. Its anterior trunk. 8. Its posterior trunk. 9. The umbilical artery giving off (10) the superior vesical artery. After the origin of this branch, the umbilical artery becomes converted into a fibrous cord—the umbilical ligament. 11. The internal pudic artery passing behind the spine of the ischium (12) and lesser sacro-ischiatic ligament. 13. The middle hæmorrhoidal artery. 14. The ischiatic artery, also passing behind the anterior sacro-ischiatic ligament to escape from the pelvis. 15. Its inferior vesical branch. 16. The ilio-lumbar, the first branch of the posterior trunk (8) ascending to inosculate with the circumflexa ilii artery (5) and form an arch along the crest of the ilium. 17. The obturator artery. 18. The lateral sacral. 19. The gluteal artery escaping from the pelvis through the upper part of the great sacro-ischiatic foramen. 20. The sacra media. 21. The right common iliac artery cut short. 22. The femoral artery.

The ISCHIATIC ARTERY is the larger of the two terminal branches of the anterior division of the internal iliac. It passes downwards between the posterior border of the levator ani, and the pyriformis, resting upon the sacral plexus of nerves and lying behind the internal pudic artery, to the lower border of the great ischiatic notch, where it escapes from the pelvis below the pyriformis muscle. It then descends in the space between the trochanter major and the tuberosity of the ischium in company with the ischiatic nerves, and divides into branches.

Fig. 129.



Its branches within the pelvis are the inferior *hæmorrhoidal*, which supplies the rectum conjointly with the middle hæmorrhoidal and sometimes takes the place of that artery, and the *inferior vesical*, which is distributed to the base and neck of the bladder, the vesiculæ seminales, and prostate gland. The branches external to the pelvis, are four in number—coccygeal, inferior gluteal, comes nervi ischiatici, and muscular branches.

The *Coccygeal* branch pierces the great sacro-ischiatic ligament, and is distributed to the coccygeus and levator ani muscles, and to the integument around the anus and coccyx.

Fig. 129. The arteries of the perineum; on the right side the superficial arteries are seen, and on the left the deep. 1. The penis, consisting of corpus spongiosum and corpus cavernosum. The crus penis on the left side is cut through. 2. The acceleratores urinæ muscles, enclosing the bulbous portion of the corpus spongiosum. 3. The erector penis, spread out upon the crus penis of the right side. 4. The anus, surrounded by the sphincter ani muscle. 5. The ramus of the ischium and os pubis. 6. The tuberosity of the ischium. 7. The lesser sacro-ischiatic ligament, attached by its small extremity to the spine of the ischium. 8. The coccyx. 9. The internal pudic artery, crossing the spine of the ischium, and entering the perineum. 10. Inferior hæmorrhoidal branch. 11. The superficialis perinei artery, giving off a small branch, transversalis perinei, upon the transversus perinei muscle. 12. The same artery on the left side cut off. 13. The artery of the bulb. 14. The two terminal branches of the internal pudic artery; one is seen entering the divided extremity of the crus penis, the artery of the corpus cavernosum; the other, the dorsalis penis, ascends upon the dorsum of the organ.

The *Inferior gluteal* branches supply the gluteus maximus muscle.

The *Comes nervi ischiatici* is a small but regular branch, which accompanies the great ischiatic nerve to the lower part of the thigh.

The *Muscular* branches supply the muscles of the posterior part of the hip and thigh, and inosculate with the internal and external circumflex arteries, with the obturator, and with the superior perforating artery.

The INTERNAL PUDIC ARTERY, the other terminal branch of the anterior trunk of the internal iliac, descends in front of the ischiatic artery to the lower border of the great ischiatic foramen. It emerges from the pelvis through the great sacro-ischiatic foramen below the pyriformis muscle, crosses the spine of the ischium, and re-enters the pelvis through the lesser sacro-ischiatic foramen; it then crosses the internal obturator muscle to the ramus of the ischium, being situated at about an inch from the margin of the tuberosity, and bound down by the obturator fascia; it next ascends the ramus of the ischium, enters between the two layers of the deep perineal fascia lying along the border of the ramus of the os pubis, and at the symphysis, pierces the anterior layer of the deep perineal fascia, and very much diminished in size reaches the dorsum of the penis, along which it runs, supplying that organ under the name of the dorsalis penis.

Branches.—The branches of the internal pudic artery within the pelvis are several small ramuscles to the base of the bladder, the vesiculæ seminales, and the prostate gland; and the *hæmorrhoidal* branch which supplies the middle of the rectum, and frequently takes the place of the middle hæmorrhoidal branch of the internal iliac.

The *branches*, external to the pelvis, are the

Inferior hæmorrhoidal,
Superficialis perinei,
 Transversalis perinei,
Arteria bulbosa,
Arteria corporis cavernosi,
Arteria dorsalis penis.

The *Inferior hæmorrhoidal artery* is given off by the internal pudic while behind the tuberosity of the ischium. It is distributed to the anus, and to the muscles, the fascia, and the integument in the anal region of the perineum.

The *Superficial perineal artery* is given off near the attachment of the crus penis; it pierces the connecting layer of the superficial and deep perineal fascia, and runs forwards across the transversus perinei muscle, and along the groove between the accelerator urinæ and erector penis to the septum scroti, upon which it ramifies under the name of arteria septi. It distributes branches to the scrotum, and to the perineum in its course forwards. One of the latter, larger than the rest, crosses the perineum, resting on the transversus perinei muscle, and is named the *transversalis perinei*.

The *Artery of the bulb* is given off from the pudic nearly opposite the opening for the transmission of the urethra; it passes nearly transversely inwards between the two layers of the deep perineal fascia, and pierces the anterior layer to enter the corpus spongiosum at its bulbous extremity. It is distributed to the corpus spongiosum.

The *Artery of the corpus cavernosum* pierces the crus penis, and runs forward in the interior of the corpus cavernosum, by the side of the septum pectiniforme. It ramifies in the parenchyma of the venous structure of the corpus cavernosum.

The *Dorsal artery of the penis* ascends between the two crura and symphysis pubis to the dorsum penis, and runs forward through the suspensory ligament in the groove of the corpus cavernosum to the glans, distributing branches in its course to the body of the organ and to the integument.

The *Internal pudic* artery in the female is smaller than in the male; its branches, with their distribution, are in principle the same. The superficial perineal artery supplies the analogue of the lateral half of the scrotum, viz. the greater labium. The artery of the bulb supplies the meatus urinarius, and the vestibule; the artery of the corpus cavernosum, the cavernous body of the clitoris, and the arteria dorsalis clitoridis, the dorsum of that organ.

The UTERINE and VAGINAL arteries of the female are derived either from the internal iliac, or from the umbilical, internal pudic, or ischiatic arteries. The former are very tortuous in their course, and ascend between the layers of the broad ligament, to be distributed to the uterus. The latter ramify upon the exterior of the vagina, and supply its mucous membrane.

Branches of the posterior trunk.

The *Ilio-lumbar artery* ascends beneath the external iliac vessels and psoas muscle, to the posterior part of the crest of the ilium, where it divides into two branches, a *lumbar branch*, which supplies the psoas and iliacus muscles, and sends a ramuscle through the fifth intervertebral foramen to the spinal cord and its membranes; and an *iliac branch*, which passes along the crest of the ilium, distributing branches to the iliacus and abdominal muscles, and inosculating with the lumbar and gluteal arteries, and with the circumflexa ilii.

The OBTURATOR ARTERY is exceedingly variable in point of origin; it generally proceeds from the posterior trunk of the internal iliac artery, and passes forwards a little below the brim of the pelvis to the upper border of the obturator foramen. It there escapes from the pelvis through a tendinous arch formed by the obturator membrane, and divides into two branches; an *internal branch*, which curves inwards around the bony margin of the obturator foramen, between the obturator externus muscle and the ramus of the ischium, and distributes branches to the obturator muscles, the pectineus, the adductor muscles, and to the organs of generation,

and inosculates with the internal circumflex artery. And an *external branch*, which pursues its course along the outer margin of the obturator foramen to the space between the gemellus inferior and quadratus femoris, where it inosculates with the ischiatic artery. In its course backwards it anastomoses with the internal circumflex, and sends a branch through the notch in the acetabulum to the hip-joint. Within the pelvis the obturator artery gives off a branch to the iliacus muscle, and a small ramuscle which inosculates with the epigastric artery.

The LATERAL SACRAL ARTERIES are generally two in number on each side; superior and inferior. The *superior* passes inwards to the first sacral foramen, and is distributed to the contents of the spinal canal, from which it escapes by the posterior sacral foramen, and supplies the integument on the dorsum of the sacrum. The *inferior* passes down by the side of the anterior sacral foramina to the coccyx; it first pierces and then rests upon the origin of the pyriformis, and sends branches into the sacral canal to supply the sacral nerves. Both arteries inosculate with each other and with the sacra media.

The GLUTEAL ARTERY is the continuation of the posterior trunk of the internal iliac: it passes backwards between the lumbo-sacral and first lumbar nerve through the upper part of the great sacro-ischiatic foramen, and above the pyriformis muscle, and divides into three branches—superficial, deep superior, and deep inferior.

The *Superficial branch* is directed forwards between the gluteus maximus and medius, and divides into numerous branches, which are distributed to the upper part of the gluteus maximus and to the integument of the gluteal region.

The *Deep superior branch* passes along the superior curved line of the ilium, between the gluteus medius and minimus to the anterior superior spinous process, where it inosculates with the superficial circumflexa ilii and external circumflex artery. There are frequently two arteries which follow this course.

The *Deep inferior branches* are several large arteries which cross the gluteus minimus obliquely to the trochanter major, where they inosculate with branches of the external circumflex artery, and send branches through the gluteus minimus to supply the capsula of the hip-joint.

Varieties in the Branches of the Internal Iliac.—The most important of the varieties occurring among these branches is the origin of the dorsal artery of the penis from the internal iliac or ischiatic. The artery in this case passes forwards by the side of the prostate gland, and through the upper part of the deep perineal fascia. It would be endangered in the operation for lithotomy. The dorsal artery of the penis is sometimes derived from the obturator, and sometimes from one of the external pudic arteries. The artery of the bulb, in its normal course, passes almost transversely inwards to the corpus spongiosum. Occasionally, however, it is so oblique in its direction as to render its division in lithotomy unavoidable.

The obturator artery may be very small or altogether wanting, its place being supplied by a branch from the external iliac or epigastric.

EXTERNAL ILIAC ARTERY.

The external iliac artery of each side passes obliquely downwards along the inner border of the psoas muscle, from opposite the sacroiliac symphysis to the femoral arch, where it becomes the femoral artery.

Relations.—It is in relation *in front* with the spermatic vessels, the peritoneum, and a thin layer of fascia, derived from the iliac fascia, which surrounds the artery and vein. At its commencement it is crossed by the ureter, and near its termination by the crural branch of the genito-crural nerve and the circumflexa ili vein. *Externally* it lies against the psoas muscle, from which it is separated by the iliac fascia; and *posteriorly* it is in relation with the external iliac vein, which, at the femoral arch, becomes placed to its inner side. The artery is surrounded throughout the whole of its course by lymphatic vessels and glands.

Branches.—Besides several small branches which supply the glands surrounding the artery, the external iliac gives off two branches, the—

Epigastric,
Circumflexa ili.

The *Epigastric artery* arises from the external iliac near to Poupart's ligament; and passing forwards between the peritoneum and transversalis fascia, ascends obliquely to the border of the sheath of the rectus. It enters the sheath near to its lower third, passes upwards behind the rectus muscle, to which it is distributed, and in the substance of that muscle it inosculates near the ensiform cartilage with the termination of the internal mammary artery. It lies internally to the internal abdominal ring, and immediately above the femoral ring, and is crossed near its origin by the vas deferens in the male, and by the round ligament in the female.

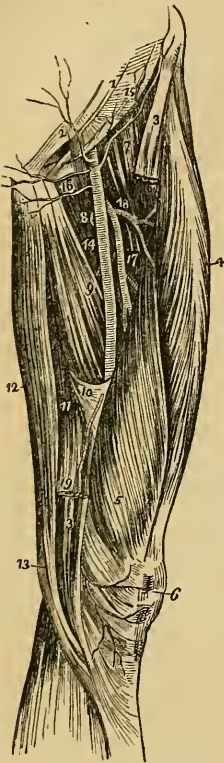
The only branches of the epigastric artery worthy of distinct notice are the *Cremasteric*, which accompanies the spermatic cord and supplies the cremaster muscle; and the ramusculus which inosculates with the obturator artery.

The Epigastric artery forms a projection of the peritoneum which divides the iliac fossa into an internal and an external portion; it is from the former that direct inguinal hernia issues, and from the latter, oblique inguinal hernia.

The *Circumflexa ili* arises from the outer side of the external iliac, nearly opposite to the epigastric artery. It ascends obliquely along Poupart's ligament, and curving around the crest of the ilium between the attachments of the internal oblique and transversalis

muscle, inosculates with the ilio-lumbar and inferior lumbar artery.

Fig. 130.



Opposite the anterior superior spinous process of the ilium it gives off a large *ascending branch*, which passes upwards between the internal oblique and transversalis, and divides into numerous branches which supply the abdominal muscles, and inosculates with the inferior intercostal and with the lumbar arteries.

Varieties in the branches of the external iliac.—The epigastric artery not unfrequently gives off the obturator,* which descends in contact with the external iliac vein, to the obturator foramen. In this situation the artery would lie to the outer side of the femoral ring, and would not be endangered in the operation for dividing the stricture of femoral hernia. But occasionally the obturator passes along the free margin of Gimbernat's ligament in its course to the obturator foramen, and would completely encircle the neck of the hernial sac; a position in which it could scarcely escape the knife of the operator.

In a preparation in my anatomical collection the branch of communication between the epigastric and obturator arteries is very much enlarged, and takes this dangerous course.

FEMORAL ARTERY.

Emerging from beneath Poupart's ligament, the external iliac artery enters the thigh and becomes the femoral. The femoral artery passes down

Fig. 130. A view of the anterior and inner aspect of the thigh, showing the course and branches of the femoral artery. 1. The lower part of the aponeurosis of the external oblique muscle; its inferior margin is Poupart's ligament. 2. The external abdominal ring. 3, 3. The upper and lower part of the sartorius muscle; its middle portion having been removed. 4. The rectus. 5. The vastus internus. 6. The patella. 7. The iliacus and psoas; the latter being nearest the artery. 8. The pectineus. 9. The adductor longus. 10. The tendinous canal for the femoral artery formed by the adductor magnus, and vastus internus muscles. 11. The adductor magnus. 12. The gracilis. 13. The tendon of the semi-tendinosus. 14. The femoral artery. 15. The superficial circumflexa ilii artery taking its course along the line of Poupart's ligament, to the crest of the ilium. 16. The superficial epigastric artery. 17. The profunda artery giving off 18, its external circumflex branch; and lower down the three perforantes. A small bend of the internal circumflex artery (8) is seen behind the inner margin of the femoral, just below the deep external pudic artery. 19. The anastomotica magna, descending to the knee, upon which it ramifies (6).

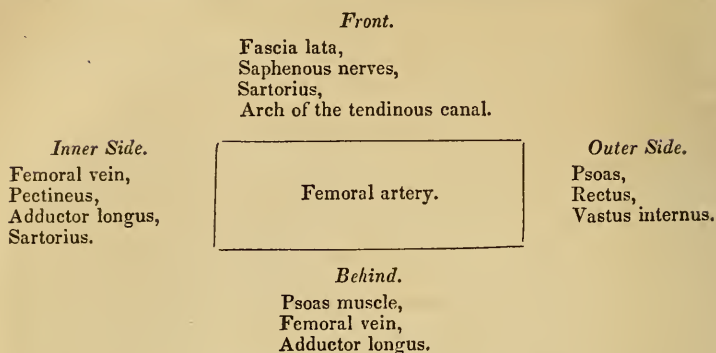
* The proportion in which high division of the obturator artery from the epigastric occurs, is stated to be one in three. In two hundred and fifty subjects examined by Cloquet with a view to ascertain how frequently the high division took place, he found the obturator arising from the epigastric on both sides one hundred and fifty times; on one side twenty-eight times, and six times it arose from the femoral artery.

the inner side of the thigh, from Poupart's ligament, at a point midway between the anterior superior spinous process of the ilium and the symphysis pubis, to the hole in the adductor magnus, at the junction of the middle with the inferior third of the thigh, where it becomes the popliteal artery.

The femoral artery and vein are enclosed in a strong sheath, *femoral* or *crural canal*, which is formed for the greater part of its extent by fibrous and cellular tissue, and by a process of fascia sent inwards from the fascia lata. Near Poupart's ligament this sheath is much larger than the vessels it contains, and is continuous with the fascia transversalis, and iliac fascia. If the sheath be opened at this point, the artery will be seen to be situated in contact with the outer wall of the sheath. The vein lies next to the artery, being separated from it by a fibrous septum, and between the vein and the inner wall of the sheath, and divided from the vein by another thin fibrous septum, is a triangular interval, into which the sac is protruded in femoral hernia. This space is occupied in the normal state of the parts by loose cellular tissue, and by lymphatic vessels which pierce the inner wall of the sheath to make their way to a gland, situated in the femoral ring.

Relations.—The upper third of the femoral artery is superficial, being covered only by the integument, inguinal glands, and by the superficial and deep fasciæ. The lower two-thirds are covered by the sartorius muscle. To its *outer side* the artery is first in relation with the psoas, next with the rectus, and then with the vastus internus. *Behind* it rests upon the inner border of the psoas muscle; it is next separated from the pectineus by the femoral vein, profunda vein and artery, and then lies on the adductor longus, to its termination: near the lower border of the adductor longus, it is placed in an aponeurotic canal, formed by an arch of tendinous fibres, thrown from the border of the adductor longus, and the border of the opening in the adductor magnus, to the side of the vastus internus. To its *inner side* it is in relation at its upper part with the femoral vein, and lower down with the pectineus, the adductor longus, and sartorius.

The immediate relations of the artery are the femoral vein, and two saphenous nerves. The vein at Poupart's ligament lies to the inner side of the artery; but lower down gets altogether behind it. The short saphenous nerve lies to the outer side, and somewhat upon the sheath for the lower two-thirds of its extent; and the long saphenous nerve is situated within the sheath for the same extent.

Plan of the *relations* of the Femoral Artery.

Branches.—The branches of the Femoral Artery are the—

Superficial circumflexa ilii,
Superficial epigastric,
Superficial external pudic,
Deep external pudic,
Profunda { External circumflex,
 { Internal circumflex,
 { Three perforating.
Muscular,
Anastomotica magna.

The *Superficial circumflexa ilii* artery arises from the femoral, immediately below Poupart's ligament, pierces the fascia lata, and passes obliquely towards the umbilicus between the two layers of superficial fascia. It distributes branches to the inguinal glands and integument, and inosculates with branches of the deep epigastric and of the internal mammary artery.

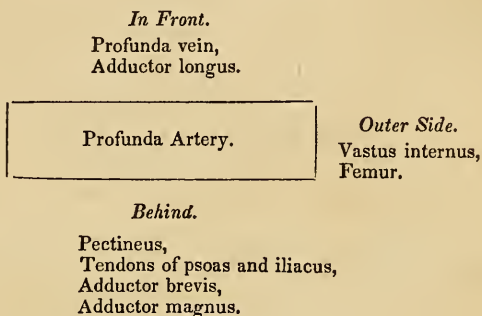
The *Superficial external pudic* arises near to the superficial epigastric artery; it pierces the fascia lata, at the saphenous opening, and passes transversely inwards crossing the spermatic cord, to be distributed to the integument of the penis and scrotum in the male, and to the labia in the female.

The *Deep external pudic* arises from the femoral, a little lower down than the preceding; it crosses the femoral vein immediately below the termination of the internal saphenous vein, and piercing the pubic portion of the fascia lata passes beneath that fascia to the inner border of the thigh, where it again pierces the fascia; having become superficial, it is distributed to the integument of the scrotum and perineum.

The *PROFUNDA FEMORIS* arises from the femoral artery at two inches below Poupart's ligament; it passes downwards and backwards, and a little outwards, behind the adductor longus muscle, pierces the adductor magnus, and is distributed to the flexor muscles on the posterior part of the thigh.

Relations.—In its course downwards it rests successively upon the pectineus, the conjoined tendon of the psoas and iliacus, adductor brevis and adductor magnus muscles. To its *outer side* the tendinous insertion of the vastus internus muscle intervenes between it and the femur; and *in front* it is separated from the femoral artery, *above* by the profunda vein and femoral vein; and *below* by the adductor longus muscle.

Plan of the *relations* of the Profunda Artery.



Branches.—The branches of the profunda artery are the external circumflex, internal circumflex, and three perforating arteries.

The *External circumflex* artery passes outwards between the divisions of the crural nerve, then between the rectus and crureus muscle, and divides into three branches; *ascending*, which inosculates with the terminal branches of the gluteal artery; *descending*, which inosculates with the superior external articular artery; and *middle*, which continues the original course of the artery around the thigh, and anastomoses with branches of the ischiatic, internal circumflex, and superior perforating artery. It supplies the muscles on the anterior and outer side of the thigh.

The *Internal circumflex* artery is larger than the external; it winds around the inner side of the neck of the femur, passing between the pectineus and psoas, and along the border of the external obturator muscle, to the space between the quadratus femoris and upper border of the adductor magnus, where it anastomoses with the ischiatic, external circumflex, and superior perforating artery. It supplies the muscles on the upper and inner side of the thigh, anastomosing with the obturator artery, and sends a small branch through the notch in the acetabulum into the hip-joint.

The *Superior perforating* artery passes backwards between the pectineus and adductor brevis, pierces the adductor magnus near to the femur, and is distributed to the posterior muscles of the thigh; inosculating freely with the circumflex and ischiatic artery, and with the branches of the middle perforating artery.

The *Middle perforating* artery pierces the tendons of the adductor brevis and magnus, and is distributed like the superior; inosculating

with the superior and inferior perforantes. This branch frequently gives off the nutritious artery of the femur.

The *Inferior perforating* artery is given off below the adductor brevis, and pierces the tendon of the adductor magnus, supplying it and the flexor muscles, and inosculating with the middle perforating artery above, and with the articular branches of the popliteal below. It is through the medium of these branches that the collateral circulation is maintained in the limb after ligature of the femoral artery.

The *Muscular branches* are given off by the femoral artery throughout the whole of its course. They supply the muscles in immediate proximity with the artery, particularly those of the anterior aspect of the thigh. One of these branches, larger than the rest, arises from the femoral immediately below the origin of the profunda, and passing outwards between the rectus and sartorius divides into branches which are distributed to all the muscles of the anterior aspect of the thigh. It may be named the *superior muscular artery*.

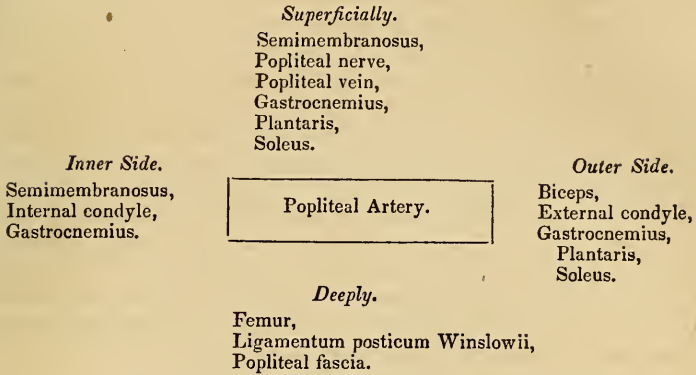
The *Anastomotica magna* arises from the femoral while in the tendinous canal formed by the adductors and vastus internus. It runs along the tendon of the adductor magnus to the inner condyle, and inosculates with the superior internal articular artery; some of its branches are distributed to the vastus internus muscle and to the crureus, and terminate by anastomosing with the branches of the external circumflex and superior external articular artery.

POPLITEAL ARTERY.

The popliteal artery commences from the termination of the femoral at the opening in the adductor magnus muscle, and passes obliquely outwards through the middle of the popliteal space to the lower border of the popliteus muscle, where it divides into the anterior and posterior tibial artery.

Relations.—In its course downwards it rests first on the femur, then on the posterior ligament of the knee-joint, then on the fascia, covering the popliteus muscle. *Superficially* it is in relation with the semimembranosus muscle, next with a quantity of fat which separates it from the deep fascia, and near its termination with the gastrocnemius, plantaris, and soleus; superficial and external to it is the popliteal vein, and still more superficial and external, the popliteal nerve. By its *inner side* it is in relation with the semimembranosus, internal condyle of the femur, and inner head of the gastrocnemius; and by its *outer side* with the biceps, external condyle of the femur, the outer head of the gastrocnemius, the plantaris and the soleus.

Plan of the *relations* of the Popliteal Artery.



Branches.—The branches of the popliteal artery are the—

- Superior external articular,
- Superior internal articular,
- Azygos articular,
- Inferior external articular,
- Inferior internal articular,
- Sural.

The *Superior articular* arteries, *external* and *internal*, wind around the femur immediately above the condyles, to the front of the knee-joint, anastomosing with each other, with the external circumflex, the anastomotica magna, the inferior articular, and the recurrent of the anterior tibial. The external passes beneath the tendon of the biceps, and the internal through an arched opening beneath the tendon of the abductor magnus. They supply the knee-joint and the lower part of the femur.

The *Azygos articular* artery pierces the posterior ligament of the joint, the ligamentum posticum Winslowii, and supplies the synovial membrane in its interior. There are frequently several posterior articular arteries.

The *Inferior articular* arteries wind around the head of the tibia immediately below the joint, and anastomose with each other, the superior articular arteries, and the recurrent of the anterior tibial. The external passes beneath the two external lateral ligaments of the joint, and the internal beneath the internal lateral ligament. They supply the knee-joint and the heads of the tibia and fibula.

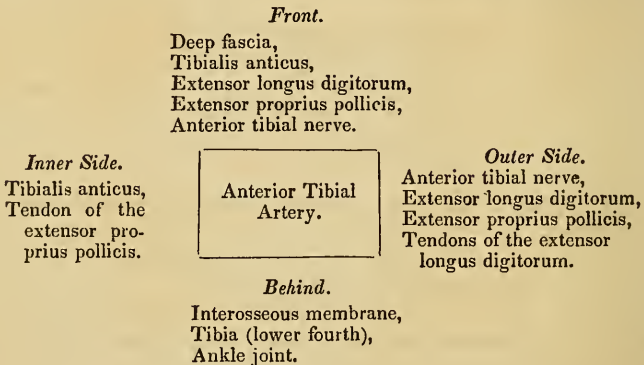
The *Sural* arteries (sura, the calf) are two large muscular branches, which are distributed to the two heads of the gastrocnemius muscle.

The anterior tibial artery passes forwards between the two heads of the tibialis posticus muscle, and through the opening in the upper

part of the interosseous membrane, to the anterior tibial region. It then runs down the anterior aspect of the leg to the ankle-joint, where it becomes the dorsalis pedis.

Relations.—In its course downwards it rests upon the interosseous membrane (to which it is connected by a little tendinous arch which is thrown across it), the lower part of the tibia, and the anterior ligament of the joint. In the upper third of its course it is situated between the tibialis anticus and extensor longus digitorum; lower down between the tibialis anticus and extensor proprius pollicis; and just before it reaches the ankle it is crossed by the tendon of the extensor proprius pollicis, and becomes placed between that tendon and the tendons of the extensor longus digitorum. Its immediate relations are the venæ comites and the anterior tibial nerve, which lies at first to its outer side, and at about the middle of the leg becomes placed superficially to the artery.

Plan of the *relations* of the Anterior Tibial Artery.



Branches.—The branches of the Anterior Tibial Artery are the—

Recurrent,
 Muscular,
 External malleolar,
 Internal malleolar.

The *Recurrent* branch passes upwards beneath the origin of the tibialis anticus muscle to the front of the knee-joint, upon which it is distributed, anastomosing with the articular arteries.

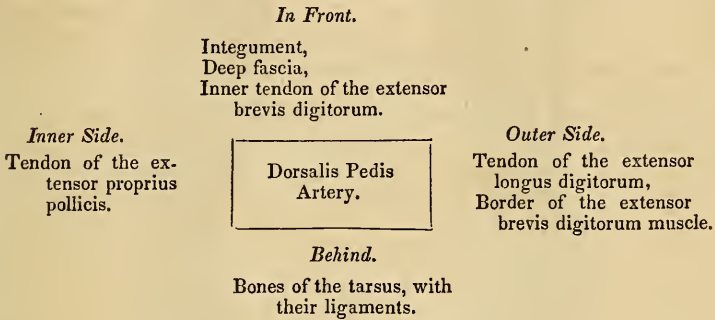
The *Muscular* branches are very numerous, they supply the muscles of the anterior tibial region.

The *Malleolar arteries* are distributed to the ankle-joint; the *external*, passing beneath the tendons of the extensor longus digitorum and peroneus tertius, inosculates with the anterior peroneal artery and with the branches of the dorsalis pedis; the *internal*, beneath the tendons of the extensor proprius pollicis and tibialis anticus, inosculates with branches of the posterior tibial and of the internal plantar artery. They supply branches to the ankle-joint.

The *DORSALIS PEDIS ARTERY* is continued forwards along the tibial side of the dorsum of the foot, from the ankle to the base of the metatarsal bone of the great toe, where it divides into two branches, the *dorsalis hallucis* and *communicating*.

Relations.—The *dorsalis pedis* is situated along the outer border of the tendon of the *extensor proprius pollicis*; on its fibular side is the innermost tendon of the *extensor longus digitorum*, and near to its termination it is crossed by the inner tendon of the *extensor brevis digitorum*. It is accompanied by *venæ comites*, and has the continuation of the anterior tibial nerve to its outer side.

Plan of the *relations* of the *Dorsalis Pedis Artery*.



Branches.—The branches of this artery are the—

Tarsea,
Metatarsea,—*interosseæ*,
Dorsalis hallucis,—*collateral digital*,
Communicating.

The *Tarsea* arches transversely across the tarsus, beneath the *extensor brevis digitorum* muscle, and supplies the articulations of the tarsal bones and the outer side of the foot; it anastomoses with the external malleolar, the peroneal arteries, and with the external plantar.

The *Metatarsea* forms an arch across the base of the metatarsal bones, and supplies the outer side of the foot, anastomosing with the *tarsea* and with the external plantar artery. The *metatarsea* gives off three branches, the *interosseæ*, which pass forwards upon the dorsal *interossei* muscles, and divide into two collateral branches for the adjoining toes. At their commencement these *interosseous* branches receive the posterior perforating arteries from the plantar arch, and opposite the heads of the metatarsal bones they are joined by the anterior perforating branches from the digital arteries.

The *Dorsalis hallucis* runs forward upon the first dorsal *interosseous* muscle, and at the base of the first phalanx divides into two branches, one of which passes inwards beneath the tendon of the *extensor proprius pollicis*, and is distributed to the inner border of

Fig. 131.

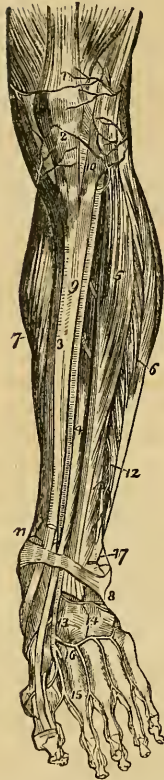


Fig. 132.

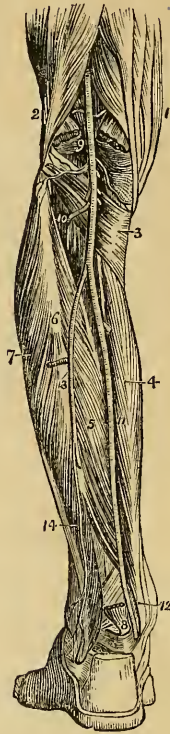


Fig. 131. The anterior aspect of the leg and foot, showing the anterior tibial and dorsalis pedis arteries, with their branches. 1. The tendon of insertion of the quadriceps extensor muscle. 2. The insertion of the ligamentum patellæ into the lower border of the patella. 3. The tibia. 4. The extensor proprius pollicis muscle. 5. The extensor longus digitorum. 6. The peronei muscles. 7. The inner belly of the gastrocnemius and the soleus. 8. The annular ligament beneath which the extensor tendons and the anterior tibial artery pass into the dorsum of the foot. 9. The anterior tibial artery. 10. Its recurrent branch inosculating with (2) the inferior articular, and (1) the superior articular artery, branches of the popliteal. 11. The internal malleolar artery. 17. The external malleolar inosculating with the anterior peroneal artery 12. 13. The dorsalis pedis artery. 14. The tarsea and metatarsæ arteries; the tarsea is nearest the ankle, the metatarsæ is seen giving off the interosscæ. 15. The dorsalis hallucis artery. 16. The communicating branch.

Fig. 132. A posterior view of the leg, showing the popliteal and posterior tibial artery. 1. The tendons forming the inner hamstring. 2. The tendon of the biceps forming the outer hamstring. 3. The popliteus muscle. 4. The flexor longus digitorum. 5. The tibialis posticus. 6. The fibula; immediately below the figure is the origin of the flexor longus pollicis; the muscle has been removed in order to expose the peroneal artery. 7. The peronei muscles, longus and brevis. 8. The lower part of the flexor longus pollicis muscle with its tendon. 9. The popliteal artery giving off its articular and muscular branches; the two superior articular are seen in the upper part of the popliteal space passing above the two heads of the gastrocnemius muscle, which are cut through near to their origin. The two inferior are in relation with the popliteus muscle. 10. The anterior tibial artery passing through the angular interspace between the two heads of the tibialis posticus muscle. 11. The posterior tibial artery. 12. The relative position of the tendons and artery at the inner ankle from within outwards, previously to their passing beneath the internal annular ligament. 13. The peroneal artery, dividing into two branches; the anterior peroneal is seen piercing the interosseous membrane. 14. The posterior peroneal.

the great toe, while the other bifurcates for the supply of the adjacent sides of the great and second toes.

The *Communicating artery* passes into the sole of the foot between the two heads of the first dorsal interosseous muscle, and inosculates with the termination of the external plantar artery.

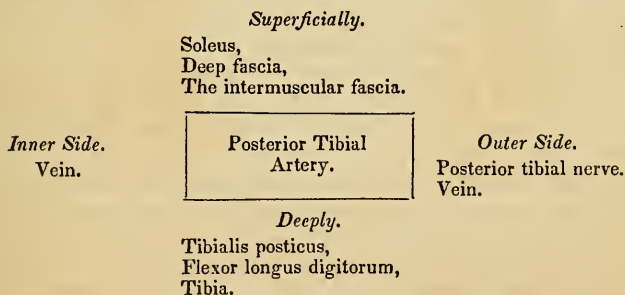
Besides the preceding, numerous branches are distributed to the bones and articulations of the foot, particularly along the inner border of the latter.

POSTERIOR TIBIAL ARTERY.

The posterior tibial artery passes obliquely downwards along the tibial side of the leg from the lower border of the popliteus muscle to the concavity of the os calcis, where it divides into the internal and external plantar artery.

Relations.—In its course downwards it lies upon the tibialis posticus, next upon the flexor longus digitorum, and then upon the tibia; it is covered in by the intermuscular fascia which separates it above from the soleus, and below from the deep fascia of the leg and the integument. It is accompanied by its venæ comites, and by the posterior tibial nerve, which lies at first to its outer side, then superficially to it, and again to its outer side.

Plan of the *relations* of the Posterior Tibial Artery.



Branches.—The branches of the posterior tibial artery are the—

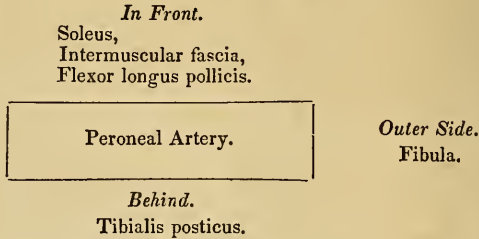
Peroneal,
Nutritious,
Muscular,
Internal calcanean,
Internal plantar,
External plantar.

The *Peroneal artery* is given off from the posterior tibial at about two inches below the lower border of the popliteus muscle; it is nearly as large as the anterior tibial artery, and passes obliquely outwards to the fibula. It then runs downwards along the inner border of the fibula to its lower third, where it divides into the anterior and posterior peroneal artery.

Relations.—The peroneal artery rests upon the tibialis posticus

muscle, and is covered in by the soleus, the intermuscular fascia and the flexor longus pollicis, having the fibula to its outer side.

Plan of the *relations* of the Peroneal Artery.



Branches.—The branches of the peroneal artery are *muscular* to the neighbouring muscles, particularly to the soleus, and the two terminal branches anterior and posterior peroneal.

The *Anterior peroneal* pierces the interosseous membrane at the lower third of the leg, and is distributed on the front of the outer malleolus, anastomosing with the external malleolar and tarsal artery. This branch is very variable in size.

The *Posterior peroneal* continues onwards along the posterior aspect of the outer malleolus to the side of the os calcis, to which and to the muscles arising from it, it distributes *external calcanean* branches. It anastomoses with the anterior peroneal, tarsal, external plantar, and posterior tibial artery.

The *Nutritious artery* of the tibia arises from the trunk of the tibial, frequently above the origin of the peroneal, and proceeds to the nutritive canal, which it traverses obliquely from below upwards.

The *Muscular branches* of the posterior tibial artery are distributed to the soleus and to the deep muscles on the posterior aspect of the leg. One of these branches is deserving of notice, a *recurrent branch*, which arises from the posterior tibial above the origin of the peroneal artery, pierces the soleus, and is distributed upon the inner side of the tibia, anastomosing with the inferior internal articular.

The *Internal calcanean branches*, three or four in number, proceed from the posterior tibial artery immediately before its division; they are distributed to the inner side of the os calcis, to the integument, and to the muscles which arise from its inner tuberosity, and they anastomose with the external calcanean branches, and with all the neighbouring arteries.

PLANTAR ARTERIES.

The *Internal plantar artery* proceeds from the bifurcation of the posterior tibial at the inner malleolus, and passes along the inner border of the foot between the abductor pollicis and flexor brevis digitorum muscles, supplying the inner border of the foot and great toe.

The *External plantar artery*, much larger than the internal, passes obliquely outwards between the first and second layers of the plantar muscles, to the fifth metatarsal space. It then turns horizontally inwards between the second and third layers, to the first metatarsal space, where it inosculates with the communicating branch from the dorsalis pedis. The horizontal portion of the artery describes a slight curve, having the convexity forwards; this is the plantar arch.

Branches.—The branches of the external plantar artery are the—

Muscular,
Articular,
Digital,—anterior perforating,
Posterior perforating.

The *Muscular branches* are distributed to the muscles in the sole of the foot.

The *Articular branches* supply the ligaments of the articulations of the tarsus, and their synovial membranes.

The *Digital branches* are four in number:—the first is distributed to the outer side of the little toe; the three others pass forwards to the cleft between the toes, and divide into collateral branches, which supply the adjacent sides of the three external toes, and the outer side of the second. At the bifurcation of the toes, a small branch is sent upwards from each digital artery, to inosculate with the interosseous branches of the metatarsæ; these are the *anterior perforating arteries*.

The *Posterior perforating* are three small branches which pass upwards between the heads of the three external dorsal interossei muscles, to inosculate with the arch formed by the metatarsæ artery.

Varieties in the Arteries of the lower extremity.—The femoral artery occasionally divides at Poupart's ligament into two branches, and sometimes into three; the former is an instance of the high division of the profunda artery; and in a case of the latter kind which occurred during my dissections, the branches were the profunda, the superficial femoral, and internal circumflex artery. Dr. Quain in his "Elements of Anatomy," records an instance of a high

Fig. 133.



Fig. 133. The arteries of the sole of the foot; the first and a part of the second layer of muscles having been removed. 1. The under and posterior part of the os calcis; to which the origins of the first layer of muscles remain attached. 2. The musculus accessorius. 3. The long flexor tendons. 4. The tendon of the peroneus longus. 5. The termination of the posterior tibial artery. 6. The internal plantar. 7. The external plantar artery. 8. The plantar arch giving off four digital branches, which pass forwards on the interossei muscles to divide into collateral branches.

division of the femoral artery, in which the two vessels became again united in the popliteal region. The point of origin of the profunda artery varies considerably in different subjects, being sometimes nearer to and sometimes farther from Poupart's ligament, but more frequently the former. The branches of the popliteal artery are very liable to variety in size; and in all these cases the compensating principle, so constant in the vascular system, is strikingly manifested. When the anterior tibial is of small size, the peroneal is large; and, in place of dividing into two terminal branches at the lower third of the leg, descends to the lower part of the interosseous membrane, and emerges upon the front of the ankle, to supply the dorsum of the foot; or the posterior tibial and plantar arteries are large, and the external plantar is continued between the heads of the first dorsal interosseous muscle, to be distributed to the dorsal surface of the foot. Sometimes the posterior tibial artery is small and threadlike; and the peroneal, after descending to the ankle, curves inwards to the inner malleolus, and divides into the two plantar arteries. If in this case the posterior tibial be sufficiently large to reach the ankle, it inosculates with the peroneal previously to its division. The internal plantar artery sometimes takes the distribution of the external plantar, which is short and diminutive, and the latter not unfrequently replaces a deficient dorsalis pedis.

The varieties of arteries are interesting in the practical application of a knowledge of their principal forms to surgical operations; in their transcendental anatomy, as illustrating the normal distribution in animals; or in many cases, as diverticula permitted by Nature, to teach her observers two important principles:—*first*, in respect to herself, that, however, in her means she may indulge in change, the end is never overlooked, and a limb is as surely supplied by a leash of arteries, various in their course, as by those which we are pleased to consider normal in distribution; and *secondly*, with regard to us; that we should ever be keenly alive to what is passing beneath our observation, and ever ready in the most serious operation to deviate from our course and avoid,—or give eyes to our knife, that it may see—the concealed dangers which it is our pride to be able to contend with and vanquish.

PULMONARY ARTERY.

The pulmonary artery arises from the left side of the base of the right ventricle in front of the origin of the aorta, and ascends obliquely to the under surface of the arch of the aorta, where it divides into the right and left pulmonary arteries. In its course upwards and backwards it inclines to the left side, crossing the commencement of the aorta, and is connected to the under surface of the arch by a ligamentous cord, the remains of the ductus arteriosus.

Relations.—It is enclosed for one half of its extent by the pericardium, and receives the attachment of the fibrous portion of the peri-

cardium by its upper portion. Behind, it rests against the ascending aorta; on either side is the appendix of the corresponding auricle and a coronary artery; and above, the cardiac ganglion and the remains of the ductus arteriosus.

The *Right pulmonary artery* passes beneath the arch and behind the ascending aorta, and in the root of the lungs divides into three branches for the three lobes.

The *Left pulmonary artery*, rather larger than the right, passes in front of the descending aorta, to the root of the left lung, to which it is distributed. These arteries divide and subdivide in the structure of the lungs, and terminate in capillary vessels which form a network around the bronchial cells, and become continuous with the radicles of the pulmonary veins.

Relations.—In the root of the *right lung*, examined from above downwards, the pulmonary artery is situated between the bronchus, and pulmonary veins; the former being above, the latter below; while in the *left lung* the artery is the highest, next the bronchus, and then the veins. On both sides, from before backwards, the artery is situated between the veins and bronchi, the former being in front, and the latter behind.

CHAPTER VI.

ON THE VEINS.

THE veins are the vessels which return the blood to the auricles of the heart, after it has been circulated by the arteries through the various tissues of the body. They are much thinner in structure than the arteries, so that when emptied of their blood they become flattened and collapsed. The veins of the systemic circulation convey the dark-coloured and impure or *venous blood* from the capillary system to the right auricle of the heart, and they are found after death to be more or less distended with that fluid. The veins of the pulmonary circulation resemble the arteries of the systemic circulation in containing during life the pure or arterial blood, which they transmit from the capillaries of the lungs to the left auricle.

The veins commence by minute radicles in the capillaries which are every where distributed through the textures of the body, and converge to constitute larger and larger branches, till they terminate in the large trunks which convey the venous blood directly to the heart. In diameter they are much larger than the arteries, and like those vessels their combined area would constitute an imaginary cone, whereof the apex is placed at the heart, and the base at the surface of the body. It follows from this arrangement, that the blood in returning to the heart is passing from a larger into a smaller channel, and therefore increases in rapidity during its course.

Veins admit of a threefold division, into superficial, deep, and sinuses.

The *Superficial veins* return the blood from the integument and superficial structures, and take their course between the layers of the superficial fascia; they then pierce the deep fascia in the most convenient and protected situations, and terminate in the deep veins. They are unaccompanied by arteries, and are the vessels usually selected for venesection.

The *Deep veins* are situated among the deeper structures of the body, and generally in relation with the arteries; in the limbs they are enclosed in the same sheath with those vessels, and they return the venous blood from the capillaries of the deep tissues. In company with all the smaller, and also with the secondary arteries, as the brachial, radial, and ulnar in the upper, and the tibial and peroneal in the lower extremity, there are two veins, placed one on each side of the artery, and named *venæ comites*. The larger arteries, as the axillary, subclavian, carotid, popliteal, femoral, &c., are accom-

panied by a single venous trunk. *Sinuses* differ from veins in their structure, and also in their mode of distribution, being confined to especial organs, situated within their substance. The principal venous sinuses are those of the dura mater, of the diploë, of the cancellous structure of bone, and of the uterus.

The communications between veins are even more frequent than those of arteries, and they take place between the larger as well as among the smaller vessels; the *venæ comites* communicate with each other very frequently in their course, by means of short transverse branches which pass from one to the other. These communications are strikingly exhibited in the frequent inosculations of the spinal veins, and in the various venous plexuses, as the spermatic plexus, vesical plexus, &c. The office of these inosculations is very apparent, as tending to obviate the obstructions to which the veins are particularly liable from the thinness of their coats, and from their inability to overcome much impediment by the force of their current.

Veins are composed of three tunics, external, middle, and internal.

The *External* or *Cellular coat* is dense and resisting, and resembles the cellular tunic of arteries. The *middle coat* is *fibrous* like that of arteries, but extremely thin; so that its existence is questioned by some anatomists. The *internal coat* is *serous*, and also similar to that of arteries; it is continuous with the lining membrane of the heart at one extremity, and with the lining of the capillaries at the other. At certain intervals the internal coat forms folds or duplicatures, which constitute valves. The valves of veins are generally composed of two semilunar folds, one on each side of the cylinder of the vessel, occasionally of a single duplicature, having a spiral direction, and in rare instances of three. The free extremity of the valvular folds is concave, and directed forwards, so that while the current of blood would be permitted to flow freely towards the heart, the valves would become distended and the current intercepted if the stream became retrograde in its course. Upon the cardiac side of each valve the vein is expanded into two pouches (*sinuses*), corresponding with the segments of the valves, which give to the distended or injected vein a knotted appearance. The valves are most numerous in the veins of the extremities, particularly in the deeper veins, and they are generally absent in the smaller veins, and in the veins of the viscera, as in the portal and cerebral veins: they are also absent in the large trunks, as in the *venæ cavæ*, *venæ azygos*, *innominatæ*, and *iliac veins*.

Sinuses are venous channels, excavated in the structure of an organ, and lined by the internal coat of the veins; of this structure are the sinuses of the dura mater, whose external covering is the fibrous tissue of the membrane, and the internal, the serous layer of the veins. The external investment of the sinuses of the uterus is the tissue of that organ; and that of the bones, the lining membrane of the cells and canals.

Veins, like arteries, are supplied with nutritious vessels, the *vasa vasorum*; and it is to be presumed that nervous filaments are distributed to their coats.

I shall describe the veins according to the primary division of the body; taking first, those of the head and neck; next, those of the upper extremity; then those of the lower extremity; and lastly, the veins of the trunk.

VEINS OF THE HEAD AND NECK.

The veins of the head and neck may be arranged into three groups, viz.: 1. Veins of the exterior of the head. 2. Veins of the diploë and interior of the cranium. 3. Veins of the neck.

The veins of the exterior of the head are the—

Facial,
Internal maxillary,
Temporal,
Temporo-maxillary,
Posterior auricular,
Occipital.

The *Facial vein* commences upon the anterior part of the skull in a venous plexus, formed by the communications of the branches of the temporal, and descends along the middle line of the forehead, under the name of *frontal vein*, to the root of the nose, where it is connected with its fellow of the opposite side by a communicating trunk which constitutes the *nasal arch*. There are usually two frontal veins which communicate by a transverse inosculation; but sometimes the vein is single and bifurcates at the root of the nose, into the two angular veins. From the nasal arch, the frontal is continued downwards by the side of the root of the nose, under the name of the *angular vein*; it then passes beneath the zygomatic muscles and becomes the facial vein, and descends along the anterior border of the masseter muscle, crossing the body of the lower jaw, by the side of the facial artery, to the submaxillary gland, and from thence to the internal jugular vein, in which it terminates.

The *branches* which the facial vein receives in its course are, the *supra-orbital*, which joins the frontal vein; the *dorsal veins* of the nose which terminate in the nasal arch; the *ophthalmic*, which communicates with the angular vein; the *palpebral* and *nasal*, which also open into the angular vein; a considerable trunk, the *alveolar*, which returns the blood from the spheno-maxillary fossa, from the infra-orbital, palatine, vidian and spheno-palatine, and joins the facial beneath the zygomatic process of the superior maxillary bone, and the veins corresponding with the branches of the facial artery.

The *Internal maxillary vein* receives the branches from the zygomatic and pterygoid fossæ; these are so numerous and communicate so freely as to constitute a *pterygoid plexus*. Passing

backwards behind the neck of the lower jaw, the internal maxillary joins with the temporal vein, and the common trunk resulting from this union constitutes the *temporo-maxillary vein*.

The *Temporal vein* commences on the vertex of the head by a plexiform network which is continuous with the frontal, the temporal, auricular, and occipital veins. The ramifications of this plexus form an anterior and a posterior branch which unite immediately above the zygoma; the trunk is here joined by another large vein, the *middle temporal*, which collects the blood from the temporal muscle, and around the outer segment of the orbit, and pierces the temporal fascia near the root of the zygoma. The temporal vein then descends between the meatus auditorius externus and the condyle of the lower jaw, and unites with the internal maxillary vein to form the temporo-maxillary.

The *Temporo-maxillary vein*, formed by the union of the temporal and internal maxillary, passes downwards in the substance of the parotid gland to its lower border, where it becomes the external jugular vein. It receives in its course the *anterior auricular, masseteric, transverse facial* and *parotid veins*, and near its termination is joined by the posterior auricular vein.

The *Posterior auricular vein* communicates with the plexus upon the vertex of the head, and descends behind the ear to the temporo-maxillary vein, immediately before that vessel merges in the external jugular. It receives in its course the veins from the external ear and the *stylo-mastoid vein*.

The *Occipital vein*, commencing posteriorly in the plexus of the vertex of the head, follows the direction of the occipital artery, and passing deeply beneath the muscles of the back part of the neck, terminates in the external jugular vein. This vein communicates with the lateral sinus by means of a large branch which passes through the mastoid foramen, the *mastoid vein*.

VEINS OF THE DIPLOE.

The diploë of the bones of the head is furnished in the adult with irregular sinuses, which are formed by a continuation of the serous membrane of the veins into the osseous canals in which they are lodged. At the middle period of life these sinuses are confined to the particular bones; but in old age, after the ossification of the sutures, they may be traced from one bone to the next. They receive their blood from the capillaries supplying the cellular structure of the diploë, and terminate externally in the veins of the pericranium, and internally in the veins and sinuses of the dura mater. These veins are separated from the bony walls of the canals by a thin layer of marrow.

CEREBRAL AND CEREBELLAR VEINS.

The cerebral veins are remarkable for the absence of valves, and for the extreme tenuity of their coats. They may be divided into the superficial, and deep or ventricular veins.

The *Superficial cerebral veins* are situated upon the surface of the hemispheres, lying in the grooves formed by the convexities of the convolutions. They are named from the position which they may chance to occupy upon the surface of this organ, either superior or inferior, internal or external, anterior or posterior.

The *Superior cerebral veins*, seven or eight in number on each side, pass obliquely forwards, and terminate in the superior longitudinal sinus, in the opposite direction to the course of the stream of blood in the sinus.

The *Deep or Ventricular veins* commence within the lateral ventricles by two vessels, the *vena corporis striati* and the *veins* of the *choroid plexus*, which unite to form the two *venæ Galeni*.

The *Venæ Galeni* pass backwards in the structure of the *velum interpositum*; and escaping through the fissure of *Bichât*, terminate in the straight sinus.

The *Cerebellar veins* are disposed, like those of the cerebrum, on the surface of the lobes of the cerebellum; they are situated some upon the superior, and some upon the inferior surface, while others occupy the borders of the organ. They terminate in the lateral and petrosal sinuses.

SINUSES OF THE DURA MATER.

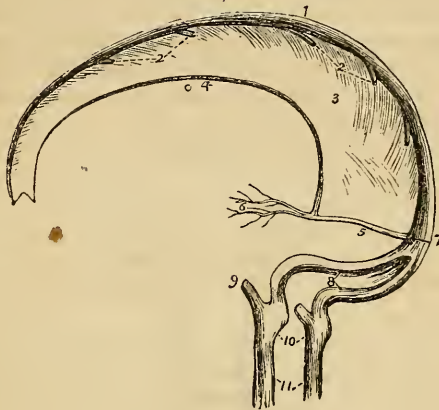
The sinuses of the dura mater are irregular channels, formed by the splitting of the layers of that membrane, and lined upon their inner surface by a continuation of the serous layer of the veins. They may be divided into two groups:—1. Those situated at the upper and back part of the skull. 2. The sinuses at the base of the skull. The former are, the—

Superior longitudinal sinus,
Inferior longitudinal sinus,
Straight sinus, or sinus quartus,
Occipital sinuses,
Lateral sinuses.

The *Superior longitudinal sinus*, is situated in the attached margin of the *falx cerebri*, and extends along the middle line of the arch of the skull, from the *foramen cæcum* in the frontal, to the inner tuberosity of the occipital bone, where it divides into the two lateral sinuses. It is triangular in form, is small in front, and increases gradually in size as it passes backwards; it receives the superior cerebral veins which open into it obliquely, numerous small veins from the *diploë*, and near the posterior extremity of the sagittal suture the *parietal veins*, from the *pericranium* and scalp. Examined upon its interior, it presents numerous transverse fibrous bands, the *chordæ Willisii*, which are stretched across its inferior angle; and some small white granular masses, the *glandulæ Pacchioni*; the oblique openings of the cerebral veins, with their valve-like margin, are also seen upon the walls of the sinus.

The termination of the superior longitudinal sinus in the two lateral sinuses forms a considerable dilatation, into which the straight sinus opens from the front, and the occipital sinuses from below. This dilatation is named the *torcular Herophili*,* and is the point of communication of six sinuses—the superior longitudinal, two lateral, two occipital, and the straight.

Fig. 134.



The *Inferior longitudinal sinus* is situated in the free margin of the falx cerebri; it is cylindrical in form and extends from near the crista galli to the anterior border of the tentorium, where it terminates in the straight sinus. It receives in its course several veins from the falx.

The *straight* or *fourth sinus* is the sinus of the tentorium; it is situated at the line of union of the falx with the tentorium; is prismoid in form, and extends across the tentorium, from the termination of the inferior longitudinal sinus to the torcular Herophili. It receives the venæ Galeni, the cerebral veins from the inferior part of the posterior lobes, and the superior cerebellar veins.

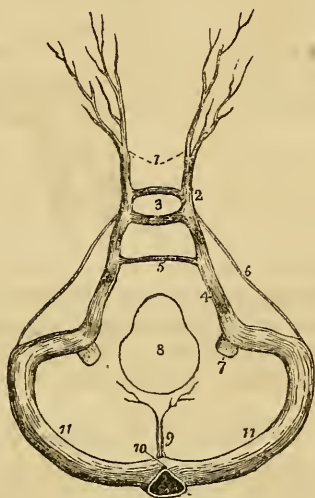
The *Occipital sinuses* are two canals of small size, situated in the attached border of the falx cerebelli; they commence by several small veins around the foramen magnum, and terminate by separate openings in the torcular Herophili. They not unfrequently communicate with the termination of the lateral sinuses.

Fig. 134. The sinuses of the upper and back part of the skull. 1. The superior longitudinal sinus. 2, 2. The cerebral veins opening into the sinus from behind forwards. 3. The falx cerebri. 4. The inferior longitudinal sinus. 5. The straight or fourth sinus. 6. The venæ Galeni. 7. The torcular Herophili. 8. The two lateral sinuses with the occipital sinuses between them. 9. The termination of the inferior petrosal sinus of one side. 10. The dilatations corresponding with the jugular fossæ. 11. The internal jugular veins.

* Torcular (a press), from a supposition entertained by the older anatomists that the columns of blood, coming in different directions, compressed each other at this point.

The *Lateral sinuses*, commencing at the torcular Herophili, pass horizontally outwards, in the attached margin of the tentorium, and curve downwards and inwards along the base of the petrous portion of the temporal bone, at each side, to the foramina lacera posteriora, where they terminate in the internal jugular veins. Each sinus rests successively in its course upon the transverse groove of the occipital bone, posterior inferior angle of the parietal, mastoid portion of the temporal, and again on the occipital bone. They receive the cerebral veins from the inferior surface of the posterior lobes, the inferior cerebellar veins, the superior petrosal sinuses, the mastoid, and posterior condyloid veins, and, at their termination, the inferior petrosal sinuses. These sinuses are often unequal in size, the right being much larger than the left.

Fig. 135.



The sinuses of the base of the skull are the—

Cavernous,
Inferior petrosal,
Circular,
Superior petrosal,
Transverse.

The *Cavernous sinuses* are named from presenting a cellular structure in their interior. They are situated on each side of the sella

Fig. 135. The sinuses of the base of the skull. 1. The ophthalmic veins. 2. The cavernous sinus of one side. 3. The circular sinus; the figure occupies the position of the pituitary gland in the sella turcica. 4. The inferior petrosal sinus. 5. The transverse or anterior occipital sinus. 6. The superior petrosal sinus. 7. The internal jugular vein. 8. The foramen magnum. 9. The occipital sinuses. 10. The torcular Herophili. 11, 11. The lateral sinuses.

turcica, receiving, anteriorly, the ophthalmic veins through the sphenoidal fissures, and terminating posteriorly in the inferior petrosal sinuses. In the internal wall of each cavernous sinus is the internal carotid artery, accompanied by several filaments of the carotid plexus, and crossed by the sixth nerve; and, in its external wall, the third, fourth, and ophthalmic nerves. These structures are separated from the blood flowing through the sinus, by the tubular lining membrane. The cerebral veins from the under surface of the anterior lobes, open into the cavernous sinuses. They communicate by means of the ophthalmic veins with the facial veins, by the circular sinus with each other, and by the superior petrosal with the lateral sinuses.

The *Inferior petrosal sinuses* are the continuations of the cavernous sinuses backwards along the lower border of the petrous portion of the temporal bone at each side of the base of the skull, to the foramina lacera posteriora, where they terminate with the lateral sinuses in the commencement of the internal jugular veins.

The *Circular sinus* is situated in the sella turcica, surrounding the pituitary gland, and communicates on each side with the cavernous sinus.

The *Superior petrosal sinuses* pass obliquely backwards along the attached border of the tentorium, on the upper margin of the petrous portion of the temporal bone, and establish a communication between the cavernous and lateral sinus at each side. They receive one or two cerebral veins from the inferior part of the middle lobes, and a cerebellar vein from the anterior border of the cerebellum.

The *Transverse sinus* (basilar, anterior occipital) passes transversely across the basilar process of the occipital bone, forming a communication between the two inferior petrosal sinuses.

VEINS OF THE NECK.

The veins of the neck which return the blood from the head are the—

External jugular,
Anterior jugular,
Internal jugular,
Vertebral.

The *External jugular vein* is formed by the union of the posterior auricular vein with the temporo-maxillary, and commences at the lower border of the parotid gland, in front of the sterno-mastoid muscle. It descends the neck in the direction of a line drawn from the angle of the lower jaw to the middle of the clavicle, crosses the sterno-mastoid, and terminates near the posterior and inferior attachment of that muscle in the subclavian vein. In its course downwards it lies upon the anterior lamella of the deep cervical fascia, which separates it from the sterno-mastoid muscle, and is

covered in by the platysma myoides and superficial fascia. At the root of the neck it pierces the deep cervical fascia; it is accompanied, for the upper half of its course, by the auricularis magnus nerve. The *branches* which it receives are the occipital and posterior cervical cutaneous, and, near its termination, the supra and posterior scapular.

The external jugular vein is very variable in size, and is occasionally replaced by two veins. In the parotid gland it receives a large communicating branch from the internal jugular vein.

The *Anterior jugular vein* is a trunk of variable size, which collects the blood from the integument and superficial structures on the fore part of the neck. It passes downwards along the anterior border of the sterno-mastoid muscle, and opens into the subclavian vein, near to the termination of the external jugular. The two veins communicate with each other, with the external and with the internal jugular vein.

The *Internal jugular vein*, formed by the convergence of the lateral and inferior petrosal sinus, commences at the foramen lacerum posterius on each side of the base of the skull, and descends the side of the neck, lying, in the first instance, to the outer side of the internal carotid, and then upon the outer side of the common carotid artery, to the root of the neck, where it unites with the subclavian, and constitutes the vena innominata. At its commencement, the internal jugular vein is posterior and external to the internal carotid artery, and to the eighth and ninth pairs of nerves; lower down, the vein and artery are on the same plane, the glosso-pharyngeal and hypoglossal nerves passing forwards between them, the pneumogastric being between and behind in the same sheath, and the nervus accessorius crossing obliquely behind the vein.

The *Branches* which the internal jugular receives in its course are, the *facial*, the *lingual*, the *inferior pharyngeal*, the *occipital*, and the *superior* and *inferior thyroid* veins.

The *Vertebral vein* descends by the side of the vertebral artery in the canal formed by the foramina in the transverse processes of the cervical vertebræ, and terminates at the root of the neck in the commencement of the vena innominata. In the lower part of the vertebral canal it frequently divides into two branches, one of which advances forwards, while the other passes through the foramen in the transverse process of the seventh cervical vertebra, before opening into the vena innominata.

The *Branches* which it receives in its course are the *posterior condyloid* vein, *muscular* branches, the *cervical meningo-rachidian* veins, and, near its termination, the *superficial* and *deep cervical* veins.

The *Inferior thyroid veins*, two, and frequently more in number, are situated on one side of the trachea, and receive the venous blood from the thyroid gland. They communicate with each other and with the superior thyroid veins, and form a plexus upon the

front of the trachea. The right vein terminates in the right vena innominata, just at its union with the superior cava, and the left in the left vena innominata.

VEINS OF THE UPPER EXTREMITY.

The veins of the upper extremity are the deep and superficial. The *deep* veins accompany the branches and trunks of the arteries, and constitute their *venæ comites*. The *venæ comites* of the radial and ulnar arteries are enclosed in the same sheath with those vessels, and terminate at the bend of the elbow in the brachial veins. The brachial *venæ comites* are situated one on each side of the artery, and open into the axillary vein; the axillary becomes the subclavian, and the subclavian unites with the internal jugular to form the vena innominata.

The *Superficial veins* of the fore-arm are the—

Anterior ulnar vein,
Posterior ulnar vein,
Basilic vein,
Radial vein,
Cephalic vein,
Median vein,
Median basilic,
Median cephalic.

The *Anterior ulnar vein* collects the venous blood from the inner border of the hand, and from the vein of the little-finger, *vena salvatella*, and ascends the inner side of the fore-arm to the bend of the elbow, where it becomes the basilic vein.

The *Posterior ulnar vein*, irregular in size and frequently absent, commences also upon the inner border and posterior aspect of the hand, and, ascending the fore-arm, terminates in front of the inner condyle, in the anterior ulnar vein.

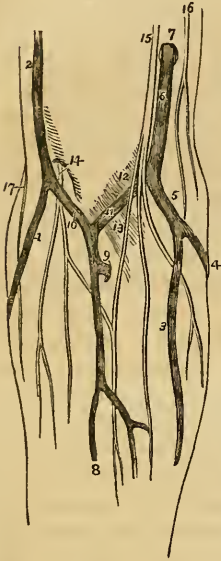
The *Basilic vein* (*βασιλικός*, royal, or principal) ascends from the common ulnar vein, formed by the two preceding, along the inner side of the upper arm, and near its middle pierces the fascia; it then passes upwards to the axilla, and becomes the axillary vein.

The *Radial vein* commences in the large vein of the thumb, on the outer and posterior aspect of the hand, and ascends along the outer border of the fore-arm to the bend of the elbow, where it becomes the cephalic vein.

The *Cephalic vein* (*κεφαλή*, the head) ascends along the outer side of the arm to its upper third; it then enters the groove between the pectoralis major and deltoid muscles, where it is in relation with the descending branch of the thoracico-acromialis artery, and terminates beneath the clavicle in the subclavian vein. A large communicating branch sometimes crosses the clavicle be-

tween the external jugular and this vein, which gives it the appearance of being derived directly from the head—hence its appellation.

Fig. 136.



The *Median vein* is intermediate between the anterior ulnar and radial vein; it collects the blood from the anterior aspect of the fore-arm, communicating with the two preceding. At the bend of the elbow it receives a branch from the deep veins, and divides into two branches, the median cephalic and median basilic.

The *Median cephalic vein*, generally the smaller of the two, passes obliquely outwards, in the groove between the biceps and the supinator longus, to join the cephalic vein. The branches of the external cutaneous nerve pass behind it.

The *Median basilic vein* passes obliquely inwards, in the groove between the biceps and pronator radii teres, and terminates in the basilic vein. This vein is crossed by one or two filaments of the internal cutaneous nerve, and is separated from the brachial artery by the aponeurotic slip given off by the tendon of the biceps.

AXILLARY VEIN.

The axillary vein is formed by the union of the venæ comites of the brachial artery with the basilic vein. It lies in front of the artery, and receives numerous branches from the collateral veins of the branches of the axillary artery, and, at the lower border of the first rib becomes the subclavian vein.

SUBCLAVIAN VEIN.

The subclavian vein crosses over the first rib and beneath the clavicle, and unites with the internal jugular vein to form the vena innominata. It lies at first in front of the subclavian artery, and then in front of the scalenus anticus, which separates it from that vessel. The phrenic and pneumogastric nerves pass between the

Fig. 136. The veins of the fore-arm and bend of the elbow. 1. The radial vein. 2. The cephalic vein. 3. The anterior ulnar vein. 4. The posterior ulnar vein. 5. The trunk formed by their union. 6. The basilic vein, piercing the deep fascia at 7. 8. The median vein. 9. A communicating branch between the deep veins of the forearm and the upper part of the median vein. 10. The median cephalic vein. 11. The median basilic. 12. A slight convexity of the deep fascia, formed by the brachial artery. 13. The process of fascia, derived from the tendon of the biceps, and separating the median basilic vein from the brachial artery. 14. The external cutaneous nerve, piercing the deep fascia, and dividing into two branches, which pass behind the median cephalic vein. 15. The internal cutaneous nerve, dividing into branches, which pass in front of the median basilic vein. 16. The intercosto-humeral cutaneous nerve. 17. The spiral cutaneous nerve, a branch of the musculo-spiral.

artery and vein. The veins opening into the subclavian are the cephalic below the clavicle, and the external and anterior jugulars above; occasionally some small veins from the neighbouring parts also terminate in it.

VEINS OF THE LOWER EXTREMITY.

The veins of the lower extremity are the deep and superficial. The *deep veins* accompany the branches of the arteries in pairs, and form the venæ comites of the anterior and posterior tibial and peroneal arteries. These veins unite in the popliteal region to form a single vein of large size—the popliteal—which successively becomes in its course the femoral and the external iliac vein.

POPLITEAL VEIN.

The popliteal vein ascends through the popliteal region, lying, in the first instance, directly upon the artery, and then getting somewhat to its outer side. It receives several muscular and articular veins, and the external saphenous vein. The valves in this vein are four or five in number.

FEMORAL VEIN.

The femoral vein, passing through the opening in the adductor magnus muscle, ascends the thigh in the sheath of the femoral artery, and entering the pelvis beneath Poupart's ligament, becomes the external iliac vein. In the lower part of its course it is situated upon the outer side of the artery; it then becomes placed behind that vessel, and, at Poupart's ligament, lies to its inner side. It receives the muscular veins, and the profunda, and, through the saphenous opening, the internal saphenous vein. The valves in this vein are four or five in number.

The *Profunda vein* is formed by the convergence of the numerous small veins which accompany the branches of the artery; it is a vein of large size, lying in front of the profunda artery, and terminates in the femoral at about an inch and a half below Poupart's ligament.

The *Superficial veins* are the external or short, and the internal or long saphenous.

The *External saphenous vein* collects the blood from the outer side of the foot and leg. It passes behind the outer ankle, ascends along the posterior aspect of the leg, lying in the groove between the two bellies of the gastrocnemius muscle, and pierces the deep fascia in the popliteal region to join the popliteal vein. It receives several cutaneous branches in the popliteal region before passing through the deep fascia, and is accompanied in its course by the external saphenous nerve.

The *Internal saphenous vein* commences upon the dorsum and inner side of the foot. It ascends in front of the inner ankle, and along the inner side of the leg; it then passes behind the inner condyle of the femur, and along the inner side of the thigh to the saphenous vein.

nous opening, where it pierces the sheath of the femoral vessels, and terminates in the femoral vein, at about one inch and a half below Poupart's ligament.

It receives in its course the cutaneous veins of the leg and thigh, and communicates freely with the deep veins. At the saphenous opening it is joined by the superficial epigastric and circumflexa ilii veins, and by the external pudic. The situation of this vein in the thigh is not unfrequently occupied by two or even three trunks of nearly equal size.

VEINS OF THE TRUNK.

The veins of the trunk may be divided into 1. The superior vena cava, with its formative branches. 2. The inferior vena cava, with its formative branches. 3. The azygos veins. 4. The vertebral and spinal veins. 5. The cardiac veins. 6. The portal vein. 7. The pulmonary veins.

SUPERIOR VENA CAVA, WITH ITS FORMATIVE BRANCHES.

Venæ Innominatæ.

The *Venæ innominatæ* are two large trunks, formed by the union of the internal jugular and subclavian vein, at each side of the root of the neck.

The *Right vena innominata*, about an inch and a quarter in length, lies superficially and externally to the arteria innominata, and descends almost vertically, to unite with its fellow of the opposite side in the formation of the superior cava. At the junction of the jugular and subclavian veins it receives from behind the ductus lymphaticus dexter, and lower down it has opening into it the *right vertebral*, *right internal mammary*, and *right inferior thyroid* vein.

The *Left vena innominata*, considerably longer than the right, extends almost horizontally across the roots of the three arteries arising from the arch of the aorta, to the right side of the mediastinum, where it unites with the right vena innominata, to constitute the superior cava.

It is in relation in front with the left sterno-clavicular articulation and the first piece of the sternum. At its commencement it receives the thoracic duct, which opens into it from behind, and in its course is joined by the *left vertebral*, *left inferior thyroid*, *left mammary* and by the *superior intercostal vein*. It also receives some small veins from the mediastinum and thymus gland. There are no valves in the venæ innominatæ.

SUPERIOR VENA CAVA.

The superior cava is a short trunk about three inches in length, formed by the junction of the two venæ innominatæ. It descends perpendicularly on the right side of the mediastinum, and entering the pericardium terminates in the upper part of the right auricle.

It is in relation *in front* with the thoracic fascia, which separates it from the thymus gland, and with the pericardium; *behind* with the right pulmonary artery, and the right superior pulmonary vein;

internally with the ascending aorta; *externally* with the right phrenic nerve, and right lung. Immediately before entering the pericardium it receives the vena azygos major.

INFERIOR VENA CAVA, WITH ITS FORMATIVE BRANCHES.

Iliac Veins.

The *External iliac vein* lies to the inner side of the corresponding artery at the os pubis; but gradually gets behind it as it passes upwards along the brim of the pelvis, and terminates opposite the sacro-iliac symphysis by uniting with the internal iliac, to form the common iliac vein. Immediately above Poupart's ligament it receives the epigastric and the circumflexa ilii veins; it has no valves.

The *Internal iliac vein* is formed by vessels which correspond with the branches of the internal iliac artery; it receives the returning blood from the gluteal, ischiatic, internal pudic, and obturator veins, externally to the pelvis; and from the vesical and uterine plexuses within the pelvis. The vein lies to the inner side of the internal iliac artery, and terminates by uniting with the external iliac vein, to form the common iliac.

The *Vesical and prostatic plexus* is an important plexus of veins which surrounds the neck and base of the bladder and prostate gland, and receives its blood from the great dorsal vein of the penis, and from the veins of the external organs of generation. It is retained in connexion with the sides of the bladder by a reflection of the pelvic fascia.

The *Uterine plexus* is situated around the vagina, and upon the sides of the uterus, between the two layers of the

Fig. 137.

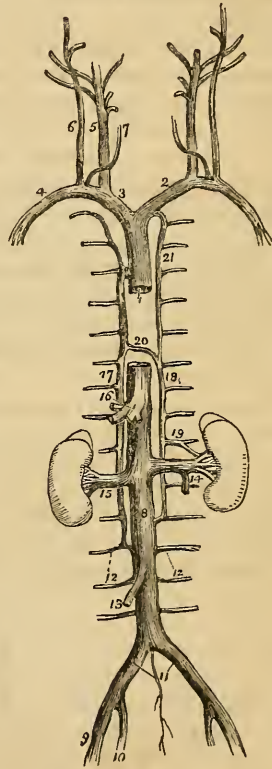


Fig. 137. The veins of the trunk and neck. 1. The superior vena cava. 2. The left vena innominata. 3. The right vena innominata. 4. The right subclavian vein. 5. The internal jugular vein. 6. The external jugular. 7. The anterior jugular. 8. The inferior vena cava. 9. The external iliac vein. 10. The internal iliac vein. 11. The common iliac veins; the small vein between these is the vena sacra media. 12, 12. Lumbar veins. 13. The right spermatic vein. 14. The left spermatic, opening into the left renal vein. 15. The right renal vein. 16. The trunk of the hepatic veins. 17. The greater vena azygos, commencing inferiorly in the lumbar veins. 18. The lesser vena azygos, also commencing in the lumbar veins. 19. A branch of communication with the left renal vein. 20. The termination of the lesser in the greater vena azygos. 21. The superior intercostal vein; communicating inferiorly with the lesser vena azygos, and terminating superiorly in the left vena innominata.

broad ligaments. The veins forming the vesical and uterine plexus are very subject to the production of phlebolitis.

The *Common iliac veins* are formed by the union of the external and internal iliac vein on each side of the pelvis. The *right* common iliac, shorter than the left, ascends obliquely behind the corresponding artery; and upon the intervertebral substance between the fourth and fifth lumbar vertebræ, unites with the vein of the opposite side, to form the inferior cava. The *left* common iliac, longer and more oblique than the right, ascends behind and a little internally to the corresponding artery, and passes beneath the right common iliac artery, near to its origin, to unite with the right vein in the formation of the inferior vena cava. The right common iliac vein has no branch opening into it; the left receives the vena sacra media. These veins have no valves.

INFERIOR VENA CAVA.

The inferior vena cava is formed by the union of the two common iliac veins, upon the intervertebral substance between the fourth and fifth lumbar vertebra. It ascends along the front of the vertebral column, on the right side of the abdominal aorta, and passing through the fissure in the posterior border of the liver and the quadrilateral opening in the tendinous centre of the diaphragm, terminates in the inferior and posterior part of the right auricle. There are no valves in this vein.

It is in *relation* from below upwards, *in front* with the mesentery, transverse duodenum, portal vein, pancreas and liver, which nearly and sometimes completely surround it; *behind* it rests upon the vertebral column and right crus of the diaphragm, from which it is separated by the right renal and lumbar arteries; to the *right* it has the peritoneum and sympathetic nerve; and to the *left* the aorta.

The *Branches* which the inferior cava receives in its course, are the—

Lumbar,
Right spermatic,
Renal,
Supra-renal,
Phrenic,
Hepatic.

The *Lumbar veins*, three or four in number on each side, collect the venous blood from the muscles and integument of the loins, and from the spinal veins; the left are longer than the right from the position of the vena cava.

The *Right spermatic vein* is formed by the two veins which return the blood from the venous plexus, situated in the spermatic cord. These veins follow the course of the spermatic artery, and unite to form the single trunk which opens into the inferior vena cava. The *left spermatic vein* terminates in the left renal vein.

The *Ovarian veins* represent the spermatic veins of the male, and

collect the venous blood from the ovaries, round ligaments, and Fallopian tubes, and communicate with the uterine sinuses. They terminate as in the male.

The *Renal* or *emulgent veins* return the blood from the kidneys; their branches are situated in front of the divisions of the renal arteries, and the left opens into the vena cava somewhat higher than the right. The *left* is longer than the right in consequence of the position of the vena cava, and crosses the aorta immediately below the origin of the superior mesenteric artery. It receives the *left spermatic vein*, which terminates in it at right angles: hence the more frequent occurrence of varicocele on the left than on the right side.

The *Supra-renal veins* terminate partly in the renal veins, and partly in the inferior vena cava.

The *Phrenic veins* return the blood from the ramifications of the phrenic arteries; they open into the inferior cava.

The *Hepatic veins* form two principal trunks and numerous smaller veins which open into the inferior cava, while that vessel is situated in the posterior border of the liver. The hepatic veins commence in the liver by minute venules, the *intra-lobular veins* in the centre of each lobule; these pour their blood into larger vessels, the *sublobular veins*; and the sublobular veins constitute by their convergence and union, the hepatic trunks, which terminate in the inferior vena cava.

AZYGOS VEINS.

The azygos veins form a system of communication between the superior and inferior vena cava, and serve to return the blood from that part of the trunk in which those vessels are deficient, on account of their connexion with the heart. This system consists of three vessels, the—

Vena azygos major,
Vena azygos minor,
Superior intercostal vein.

The *Vena azygos major* commences in the lumbar region by a communication with the lumbar veins; sometimes it is joined by a branch directly from the inferior vena cava, or by one from the renal vein. It passes through the aortic opening in the diaphragm, and ascends upon the right side of the vertebral column to the third dorsal vertebra, where it arches forwards over the right bronchus, and terminates in the superior cava. It receives all the intercostal veins of the right side, the vena azygos minor, and the bronchial veins.

The *Vena azygos minor* commences in the lumbar region, on the left side, by a communication with the lumbar or renal veins. It passes beneath the border of the diaphragm, and ascending upon the left side of the vertebral column crosses the fifth or sixth dorsal vertebra to open into the vena azygos major. It receives the six

or seven lower intercostal veins of the left side. The azygos veins have no valves.

The *Superior intercostal vein* is the trunk formed by the union of the five or six upper intercostal veins of the left side. It communicates below with the vena azygos minor, and ascends to terminate in the left vena innominata.

VERTEBRAL AND SPINAL VEINS.

The numerous venous plexuses of the vertebral column and spinal cord may be arranged into three groups:—

Dorsi-spinal,
Meningo-rachidian,
Medulli-spinal.

The *Dorsi-spinal veins* form a plexus around the spinous, transverse and articular processes and arches of the vertebræ. They receive the returning blood from the dorsal muscles and surrounding structures, and transmit it, in part to the meningo-rachidian, and in part to the vertebral, intercostal, lumbar, and sacral veins.

The *Meningo-rachidian veins* are situated between the theca vertebralis and the vertebræ. They communicate freely with each other by means of a complicated plexus. In front they form two longitudinal trunks, which extend the whole length of the column on each side of the posterior common ligament, and are joined on the body of each vertebra by transverse trunks, which pass beneath the ligament, and receive the large vertebral veins from the interior of each vertebra. They pour their blood into the vertebral veins in the neck, into the intercostal veins in the thorax, and into the lumbar and sacral veins in the loins and pelvis, by means of communicating trunks, which escape at the intervertebral foramina.

The *Medulli-spinal veins* are situated between the pia mater and arachnoid; they communicate freely with each other, and form plexuses, and send branches through the intervertebral foramina with each of the spinal nerves, to join the veins of the trunk.

CARDIAC VEINS.

The veins returning the blood from the substance of the heart, are the—

Great cardiac vein,
Posterior cardiac veins,
Anterior cardiac veins,
Venæ Thebesii.

The *Great cardiac vein* (coronary) commences at the apex of the heart, and ascends along the anterior ventricular groove to the base of the ventricles; it then curves around the left auriculo-ventricular groove to the posterior part of the heart, where it terminates in the

right auricle. It receives in its course the left cardiac veins from the left auricle and ventricle, and the posterior cardiac veins from the posterior ventricular groove.

The *Posterior cardiac vein*, frequently two in number, commences also at the apex of the heart, and ascends along the posterior ventricular groove, to terminate in the great cardiac vein. It receives the veins from the posterior aspect of the two ventricles.

The *Anterior cardiac veins* collect the blood from the anterior surface of the right ventricle; one larger than the rest runs along the right border of the heart and joins the trunk formed by these veins, which curves around the right auriculo-ventricular groove, to terminate in the great cardiac vein near to its entrance into the right auricle.

The *Venæ Thebesii* are numerous minute venules which convey the venous blood directly from the substance of the heart into its four cavities. Their existence is denied by some anatomists.

PORTAL SYSTEM.

The portal system is composed of four large veins which return the blood from the chylopoietic viscera; they are the—

Inferior mesenteric vein,
Superior mesenteric vein,
Splenic vein,
Gastric veins.

The *Inferior mesenteric vein* receives its blood from the rectum by means of the hæmorrhoidal veins, and from the sigmoid flexure and descending colon, and ascends beneath the transverse duodenum and pancreas, to terminate in the splenic vein. Its hæmorrhoidal branches inosculate with the branches of the internal iliac vein, and thus establish a communication between the portal and general venous system.

The *Superior mesenteric vein* is formed by branches which collect the venous blood from the capillaries of the superior mesenteric artery; they constitute by their junction a large trunk which ascends by the side of the corresponding artery, crosses the transverse duodenum, and unites behind the pancreas with the splenic in the formation of the portal vein.

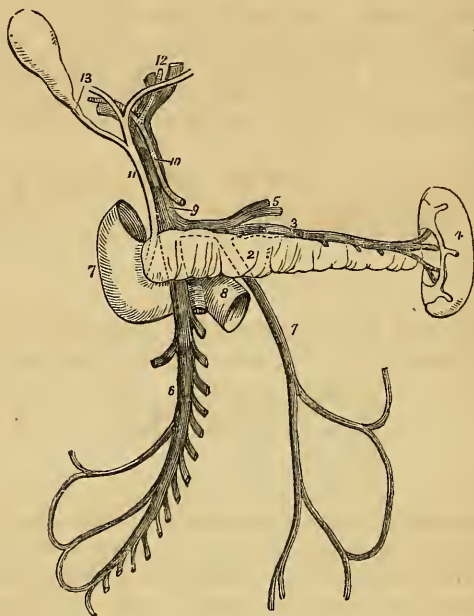
The *Splenic vein* commences in the structure of the spleen, and quits that organ by several large veins; it is larger than the splenic artery, and perfectly straight in its course. It passes horizontally inwards behind the pancreas, and terminates near its greater end by uniting with the superior mesenteric and forming the portal vein. It receives in its course the gastric and pancreatic veins, and near its termination the inferior mesenteric vein.

The *Gastric veins* correspond with the gastric, gastro-epiploic, and vasa brevia arteries, and terminate in the splenic vein.

The *VENA PORTÆ*, formed by the union of the splenic and supe-

rior mesenteric vein behind the pancreas, ascends through the right border of the lesser omentum to the transverse fissure of the liver, where it divides into two branches, one for each lateral lobe. In the right border of the lesser omentum it is situated behind and between the hepatic artery and ductus communis choledochus, and is

Fig. 138.



surrounded by the hepatic plexus of nerves and lymphatics. At the transverse fissure each primary branch divides into numerous secondary branches, which ramify through the portal canals, and give off vaginal and interlobular veins, which terminate in the lobular venous plexus of the lobules of the liver. The portal vein within the liver receives the venous blood from the capillaries of the hepatic artery.

PULMONARY VEINS.

The pulmonary veins, four in number, return the arterial blood from the lungs to the left auricle of the heart; they differ from the

Fig. 138. The portal vein. 1. The inferior mesenteric vein: it is traced by means of dotted lines behind the pancreas (2) to terminate in the splenic vein (3). 4. The spleen. 5. Gastric veins, opening into the splenic vein. 6. The superior mesenteric vein. 7. The descending portion of the duodenum. 8. Its transverse portion, which is crossed by the superior mesenteric vein and by a part of the trunk of the superior mesenteric artery. 9. The portal vein. 10. The hepatic artery. 11. The ductus communis choledochus. 12. The divisions of the duct and vessels at the transverse fissure of the liver. 13. The cystic duct leading to the gall-bladder.

veins in general, in the area of their cylinders being very little larger than the corresponding arteries, and in accompanying singly each branch of the pulmonary artery. They commence in the capillaries upon the parietes of the bronchial cells, and unite to form a single trunk for each lobe. The vein of the middle lobe of the right lung unites with the superior vein so as to form the two trunks which open into the left auricle. Sometimes they remain separate, and then there are three pulmonary veins on the right side. The right pulmonary veins pass behind the superior vena cava to the left auricle, and the left behind the pulmonary artery; they both pierce the pericardium. Within the lung the branches of the pulmonary veins are behind the bronchial tubes, and those of the pulmonary artery in front; but at the root of the lungs the veins are in front, next the arteries, and then the bronchi. There are no valves in the pulmonary veins.

CHAPTER VII.

ON THE LYMPHATICS.

THE lymphatic vessels, or absorbents, have received their double appellation from certain phenomena which they present; the former name is derivable from the peculiar limpid fluid (lymph, water,) which they convey; and the latter, from their supposed property of absorbing foreign substances into the system. They are minute and delicate vessels, having a knotted appearance, and are distributed through every part of the body. Their office is to collect the products of digestion, and the detrita of nutrition, and to convey them into the venous circulation near to the heart.

Lymphatic vessels commence in a delicate network which is distributed upon the cutaneous surface of the body, upon the various surfaces of organs and throughout their internal structure; and from this network the lymphatic vessels proceed, nearly in straight lines, in a direction towards the root of the neck. In their course they are intercepted by numerous small oval or rounded bodies—*lymphatic glands*—in which the entering or *inferent vessels* ramify to an extreme minuteness, and from which proceed the escaping or *effluent vessels* somewhat larger in size and fewer in number, to be again and again subdivided into other glands, and each time to be a little more increased in size.

Lymphatic vessels admit of a threefold division into superficial, deep, and lacteals. The *superficial lymphatic vessels*, upon the surface of the body, follow the course of the veins, and pierce the deep fascia in convenient situations, to join the deep lymphatics. Upon the surface of organs they converge to the nearest lymphatic trunks.

The *Superficial lymphatic glands* are placed in the most protected situations of the superficial fascia, as in the hollow of the ham and groin in the lower extremity, and upon the inner side of the arm in the upper extremity. The *deep lymphatics* accompany the deeper veins; those from the lower parts of the body converging to the numerous glands seated around the iliac veins and inferior vena cava, and terminating in a large trunk situated upon the vertebral column—the thoracic duct. From the upper part of the trunk on the left side, and from the left side of the head and neck, they also proceed to the thoracic duct. Those on the right side of the head, and neck, right upper extremity, and right side of the thorax, form a distinct duct which terminates at the point of junction of the subclavian with the internal jugular vein on the right side of the root of the neck.

The *lacteals* are the lymphatics of the small intestines; they have received their distinctive appellation from conveying the milk-like product of digestion—the chyle—to the great centre of the lymphatic system—the thoracic duct. They are situated in the mesentery, and pass through the numerous mesenteric glands in their course.

The communications between lymphatic vessels are less frequent than those of arteries or veins; their anastomoses take place by means of branches of equal calibre that unite at acute angles, and constitute a combined trunk, which is scarcely larger than either of the single branches by which it is formed.

Lymphatic vessels are composed of two coats; an external or cellular, and an internal or serous.

The *External coat* resembles the external tunic of veins and arteries, but is extremely thin and dense. The *Internal coat* is continuous with the internal lining of the veins; and, like that membrane, is most probably provided with an epithelium. At short intervals this coat forms semilunar folds which are disposed in pairs in the cylinder of the vessel and constitute the valves. It is to these valves, which are extremely numerous in lymphatics, that their peculiar knotted appearance is due, when filled with injection.

The lymphatic glands are small oval and somewhat flattened or rounded bodies, composed of a plexus of minute lymphatic vessels, associated with a plexus of blood-vessels, and enclosed in a thin cellular capsule. The larger glands have a lobed or cellular appearance. The lymphatic vessels and glands are supplied with arteries, veins, and nerves, like other structures.

I shall describe the lymphatic vessels and glands according to the arrangement adopted for the veins, commencing with those of the head and neck, and proceeding next to those of the upper extremity, lower extremity, and trunk.

LYMPHATICS OF THE HEAD AND NECK.

The *Superficial lymphatic glands of the head and face* are small and few in number; they are the *occipital*, which are situated near the origin of the occipito-frontalis muscle; *posterior auricular*, behind the ear; *parotid*, in the parotid gland; *zygomatic*, in the zygomatic fossa; *buccal*, upon the buccinator muscle; and *sub-maxillary*, beneath the margin of the lower jaw. There are no deep lymphatic glands within the cranium.

The *Superficial cervical lymphatic glands* are few in number; they are situated in the course of the external jugular vein, between the sterno-mastoid and trapezius muscles, at the root of the neck and about the larynx.

The *Deep cervical glands* are very numerous and of large size; they are situated around the internal jugular vein and sheath of the arteries, by the side of the pharynx, œsophagus, and trachea, and extend from the base of the skull to the root of the neck, where

they are in communication with the lymphatic vessels and glands of the thorax.

The *Superficial lymphatic vessels of the head and face* are disposed in three groups; *occipital*, which take the course of the occipital vein to the occipital and deep cervical glands; *temporal*, which follow the branches of the temporal vein to the parotid and deep cervical glands; and *facial*, which accompany the facial vein to the submaxillary lymphatic glands.

The *Deep lymphatic vessels of the head* are the *meningeal* and *cerebral*; the former are situated in connexion with the meningeal veins, and escape through foramina at the base of the skull, to join the deep cervical glands. The *cerebral lymphatics*, according to Fohmann, are situated upon the surface of the pia mater. They pass most probably through the foramina at the base of the skull, to terminate in the deep cervical glands.

The *Deep lymphatic vessels of the face* proceed from the nasal fossæ, mouth, and pharynx, and terminate in the submaxillary and deep cervical glands.

The *Superficial and deep cervical lymphatic vessels*, accompany the jugular veins, passing from gland to gland, and at the root of the neck communicate with the thoracic lymphatic vessels, and terminate, on the right side, in the ductus lymphaticus dexter, and, on the left, in the thoracic duct, near to its termination.

LYMPHATICS OF THE UPPER EXTREMITY.

The *Superficial lymphatic glands* of the arm are not more than four or five in number, and of very small size. One or two are situated near the median basilic, and cephalic veins, at the bend of the elbow; and one or two near to the basilic vein, on the inner side of the upper arm, immediately above the elbow.

The *Deep glands* in the fore-arm are excessively small and infrequent; two or three may generally be found in the course of the radial and ulnar vessels. In the upper arm there is a chain of small glands, accompanying the brachial artery.

The *Axillary glands* are numerous and of large size. Some are closely adherent to the vessels, others are dispersed in the loose cellular tissue of the axilla, and a small chain may be observed extending along the lower border of the pectoralis major to the mammary gland. Two or three subclavian glands, are situated beneath the clavicle, and serve as the medium of communication between the axillary and deep cervical lymphatic glands.

The *Superficial lymphatic vessels* of the upper extremity commence at the extremities of the fingers, and pass along the borders of the fingers to the dorsum of the hand; they next ascend the fore-arm, some on its posterior and some on its anterior aspect, observing particularly the direction of the veins. At the bend of the elbow they converge, to form two groups which accompany the basilic and cephalic veins. The lymphatics of the basilic group communi-

cate with the glands situated immediately above the elbow, and ascend to join the axillary gland. Those of the cephalic group for the most part cross the upper part of the biceps muscle, and also enter the axillary glands, while two or three are continued onwards along the cephalic vein, in the interspace between the pectoralis major and deltoid muscle, to communicate with the subclavian glands.

The *Deep lymphatics* accompany the vessels of the upper extremity, and communicate occasionally with the superficial lymphatics.

They enter the axillary and subclavian glands, and at the root of the neck terminate on the left side in the thoracic duct, and on the right side in the ductus lymphaticus dexter.

LYMPHATICS OF THE LOWER EXTREMITY.

The *Superficial lymphatic glands* of the lower extremity are those of the groin, the *inguinal*, and one or two situated in the superficial fascia of the posterior aspect of the thigh, just above the popliteal region.

The *Inguinal glands* are divisible into two groups, a superior group of small size, situated along the course of Poupart's ligament, and receiving the lymphatic vessels from the parietes of the abdomen and genital organs; and an inferior group of larger glands clustered around the internal saphenous vein near to its termination, and receiving the superficial lymphatic vessels from the lower extremity.

The *Deep lymphatic glands* are the *anterior tibial*, *popliteal*, *deep inguinal*, *gluteal*, and *ischiatric*.

The *Anterior tibial* is generally a single gland, placed on the interosseous membrane, by the side of the anterior tibial artery in the upper part of its course.

The *Popliteal glands*, four or five in number, are embedded in the loose cellular tissue and fat of the popliteal space.

The *Deep inguinal glands*, less numerous and smaller than the superficial, are situated near the femoral vessels in the groin, beneath the fascia lata.

The *Gluteal* and *ischiatric glands* are placed above and below the pyriformis muscle at the great ischiatic foramen.

The *Superficial lymphatic vessels* are divisible into two groups, internal and external; the *internal* and principal group commencing on the dorsum and inner side of the foot, ascend the leg by the side of the internal saphenous vein, and passing behind the inner condyle of the femur, follow the direction of that vein to the groin, where they join the saphenous group of superficial inguinal glands. The greater part of the efferent vessels from these glands pierce the cribriform fascia of the saphenous opening and the sheath of the femoral vessels, to join the lymphatic gland situated in the femoral ring, which serves to establish a communication between the lymphatics of the lower extremity and those of the trunk. The other

effluent vessels pierce the fascia lata to join the deep glands. The vessels which pass upwards from the outer side of the dorsum of the foot, ascend upon the outer side of the leg, and curve inwards just below the knee, to unite with the lymphatics of the inner side of the thigh. The *external group* consists of a few lymphatic vessels which commence upon the outer side of the foot and posterior part of the ankle, and accompany the external saphenous vein to the popliteal region, where they enter the popliteal glands.

The *Deep lymphatic vessels* accompany the deep veins, and communicate with the various glands in their course. After joining the deep inguinal glands they pass beneath Poupart's ligament, to communicate with the numerous glands situated around the iliac vessels. The deep lymphatics of the gluteal region follow the course of the branches of the gluteal and ischiatic arteries. The former join the glands situated upon the upper border of the pyriformis muscle, and the latter, after communicating with the lymphatics of the thigh, enter the ischiatic glands.

LYMPHATICS OF THE TRUNK.

The lymphatics of the trunk may be arranged under three heads, superficial, deep, and visceral.

The *Superficial lymphatic vessels* of the upper half of the trunk pass upwards and outwards on each side, and converge, some to the axillary glands, and the others to the glands at the root of the neck. The lymphatics from the mammary glands follow the lower border of the pectoralis major, communicating by means of a chain of lymphatic glands, with the axillary glands. The superficial lymphatic vessels of the lower half of the trunk, of the gluteal region, perineum, and external organs of generation, converge to the superior group of superficial inguinal glands. Some small glands are situated on each side of the dorsal vein of the penis, near to the suspensory ligament; from these, as from the superficial lymphatics, the effluent vessels pass into the superior group of superficial inguinal glands.

The *Deep lymphatic glands of the thorax* are the intercostal, internal mammary, anterior mediastinal, and posterior mediastinal.

The *Intercostal glands* are of small size, and are situated on each side of the vertebral column, near to the articulations of the heads of the ribs, and in the course of the intercostal arteries.

The *Internal mammary glands*, also very small, are placed in the intercostal spaces, by the side of the internal mammary arteries.

The *Anterior mediastinal glands* occupy the loose cellular tissue of the anterior mediastinum, resting some on the diaphragm, but the greater number upon the large vessels at the root of the heart.

The *Posterior mediastinal glands* are situated along the course of the aorta and œsophagus in the posterior mediastinum, and communicate above with the deep cervical glands, on each side with the intercostal, and below with the abdominal glands.

The *Deep lymphatic vessels of the thorax* are the intercostal, internal mammary, and diaphragmatic.

The *Intercostal* lymphatic vessels follow the course of the arteries of the same name; and reaching the vertebral column curve downwards, to terminate in the thoracic duct.

The *Internal mammary* lymphatics commence in the parietes of the abdomen, communicating with the epigastric lymphatics. They ascend by the side of the internal mammary vessels, being joined in their course by the anterior intercostals, and terminate on the right side in the tributaries of the ductus lymphaticus dexter; and on the left side in the thoracic duct. The *diaphragmatic* lymphatics pursue the direction of their corresponding veins, and terminate, some *in front* in the internal mammary vessels, and some *behind*, in the posterior mediastinal lymphatics.

The *Deep lymphatic glands of the abdomen* are the lumbar glands; they are very numerous, and are seated around the common iliac vessels, the aorta and vena cava.

The deep lymphatic glands of the pelvis are the external iliac, internal iliac, and sacral.

The *External iliac* are placed around the external iliac vessels, being in continuation by one extremity with the femoral lymphatics, and by the other with the lumbar glands.

The *Internal iliac* glands are situated in the course of the internal iliac vessels, and the *sacral* glands are supported by the concave surface of the sacrum.

The *Deep lymphatic vessels* are continued upwards from the thigh, beneath Poupart's ligament, and along the external iliac vessels to the lumbar glands, receiving in their course the epigastric, circumflex ilii, and ilio-lumbar lymphatic vessels. Those from the parietes of the pelvis, and from the gluteal, ischiatic, and obturator vessels, follow the course of the internal iliac arteries, and unite with the lumbar lymphatics. And the lumbar lymphatic vessels, after receiving all the lymphatics from the lower extremities, pelvis, and loins, terminate by several large trunks in the receptaculum chyli.

LYMPHATICS OF THE VISCERA.

The *Lymphatic vessels of the lungs* are distributed over every part of the surface, and through the texture of these organs; they converge to the numerous glands situated around the bifurcation of the trachea and roots of the lungs—the bronchial glands. Some of these glands of small size, may be traced in connexion with the bronchial tubes for some distance into the lungs. The efferent vessels from the bronchial glands unite with the tracheal and œsophageal glands, and terminate principally in the thoracic duct at the root of the neck, and partly in the ductus lymphaticus dexter. The *bronchial glands*, in the adult, present a variable tint of brown, and in old age a deep black colour. In infancy they have none of this pigment, and are not to be distinguished from lymphatic glands in other situations.

The *Lymphatic vessels of the heart* originate in the subserous cellular tissue of the surface, and in the deeper tissues of the organ, and follow the course of the vessels, principally, along the right border of the heart to the glands situated around the arch of the aorta and bronchial glands, whence they proceed to the thoracic duct.

The *Pericardiac* and *thymic* lymphatic vessels proceed to join the anterior mediastinal and bronchial glands.

The *Lymphatic vessels of the liver* are divisible into the deep and superficial. The former take their course through the portal canals, and through the right border of the lesser omentum, to the lymphatic glands, situated in the course of the hepatic artery and along the lesser curve of the stomach. The *superficial* lymphatics are situated in the cellular structure of the proper capsule, over the whole surface of the liver. Those of the convex surface are divided into two sets:—1. Those which pass from before backwards. 2. Those which advance from behind forwards. The former unite to form trunks, which enter between the folds of the lateral ligaments at the right and left extremities of the organ, and of the coronary ligament in the middle. Some of these pierce the diaphragm and join the posterior mediastinal glands; others converge to the lymphatic glands situated around the inferior cava. Those which pass from behind forwards consist of two groups: one ascends between the folds of the broad ligament, and perforates the diaphragm, to terminate in the anterior mediastinal glands; the other curves around the anterior margin of the liver to its concave surface, and from thence to the glands in the right border of the lesser omentum. The lymphatic vessels of the concave surface are variously distributed, according to their position: those from the right lobe terminate in the lumbar glands; those from the gall-bladder, which are large and form a remarkable plexus, enter the glands in the right border of the lesser omentum; and those from the left lobe converge to the lymphatic glands, situated along the lesser curve of the stomach.

The *Lymphatic glands of the spleen* are situated around its hilus, and those of the *pancreas* in the course of the splenic vein. The *lymphatic vessels* of these organs pass through their respective glands, and join the aortic glands, previously to terminating in the thoracic duct.

The *Lymphatic glands of the stomach* are of small size, and are situated along the lesser and greater curves of that organ. The *lymphatic vessels*, as in other viscera, are superficial and deep, the former originating in the subserous and the latter in the submucous tissue; they pass from the stomach in four different directions; some ascend to the glands situated along the lesser curve,—others descend to those occupying the greater curve,—a third set passes outwards to the splenic glands, and a fourth to the glands situated near the pylorus and to the aortic glands.

The *Lymphatic glands of the small intestine* are situated between the layers of the mesentery, in the meshes formed by the superior

mesenteric artery, and thence named *mesenteric glands*. These glands are most numerous and largest, superiorly, near to the duodenum; and, inferiorly, near to the termination of the ileum.

The *Lymphatic vessels* of the small intestine are of two kinds: those of the structure of the intestine, which ramify upon its surface previously to entering the mesenteric glands; and those which commence in the villi, upon the surface of the mucous membrane, and are named lacteals.

The *Lacteals* according to the most recent and best researches—those of Dr. Henle of Berlin—commence in the centre of each villus as a cœcal tubulus, which opens into a fine network, situated in the submucous tissue. From this areolar network the lacteal vessels proceed to the mesenteric glands, and from thence to the thoracic duct, in which they terminate.

The *Lymphatic glands of the large intestines* are situated along the attached margin of the intestine, in the meshes formed by the arteries previously to their distribution. The *lymphatic* vessels take their course in two different directions; those of the cœcum, ascending and transverse colon, after traversing their proper glands, proceed to the mesenteric, and those of the descending colon and rectum to the lumbar glands.

The *Lymphatic vessels of the kidney* follow the direction of the blood-vessels to the lumbar ganglia situated around the aorta and inferior vena cava; those of the supra-renal capsules, which are very large and numerous, terminate in the renal lymphatics.

The *Lymphatic vessels of the viscera of the pelvis* terminate in the sacral and lumbar ganglia.

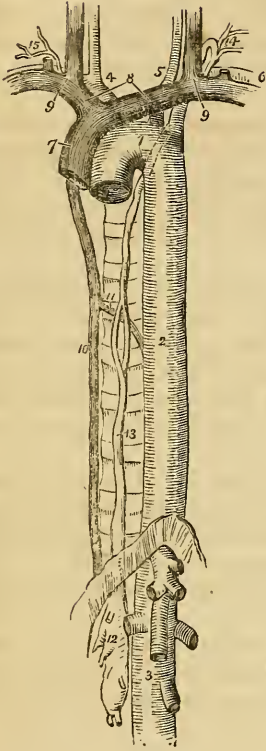
The *Lymphatic vessels of the testicle* take the course of the spermatic cord, where they are of large size, as is shown in the beautiful injections made by Sir Astley Cooper; they terminate in the lumbar ganglia.

THORACIC DUCT.

The thoracic duct commences in the abdomen, by a considerable and somewhat triangular dilatation, the *receptaculum chyli*, which is situated upon the front of the body of the second lumbar vertebra, behind and between the aorta and inferior vena cava, and close to the tendon of the right crus of the diaphragm. From the upper part of the receptaculum chyli, the thoracic duct ascends through the aortic opening in the diaphragm, and along the front of the vertebral column, lying between the thoracic aorta and vena azygos, to the fourth dorsal vertebra. It then inclines to the left side, passes behind the arch of the aorta, and ascends by the side of the œsophagus and behind the perpendicular portion of the left subclavian artery to the root of the neck opposite the seventh cervical vertebra, where it makes a sudden curve forwards and downwards, and terminates at the point of junction of the left subclavian with the left internal jugular vein.

The thoracic duct is equal in size to the diameter of a goose-quill at its commencement from the receptaculum chyli, diminishes considerably in diameter towards the middle of the posterior mediastinum, and again becomes dilated near its termination. At about the middle of its course it frequently divides into two branches of equal size, which reunite after a short course; and sometimes it gives off several branches, which assume a plexiform arrangement in this situation. Occasionally the thoracic duct bifurcates at the upper part of the thorax into two branches, one of which opens into the point of junction between the right subclavian and jugular veins, while the other proceeds to the normal termination of the duct on the left side. In rare instances the duct has been found to terminate in the vena azygos, which is its normal destination in some Mammalia.

Fig. 139.



The thoracic duct presents fewer valves in its course than lymphatic vessels generally; at its termination it is provided with a pair of semilunar valves which prevent the admission of venous blood into its cylinder.

Branches.—The thoracic duct receives at its commencement four or five large lymphatic trunks which unite to form the receptaculum chyli; it next receives the trunks of the lacteal vessels. Within the thorax it is joined by a large lymphatic trunk from the liver, and in its course through the posterior mediastinum, receives the lymphatic vessels both from the viscera and from the parietes of the thorax. At its curve forwards in the neck

Fig. 139. The course and termination of the thoracic duct. 1. The arch of the aorta. 2. The thoracic aorta. 3. The abdominal aorta; showing its principal branches divided near their origin. 4. The arteria innominata, dividing into the right carotid and right subclavian arteries. 5. The left carotid. 6. The left subclavian. 7. The superior cava, formed by the union of 8, the two venæ innominatæ; and these by the junction 9, of the internal jugular and subclavian vein at each side. 10. The greater vena azygos. 11. The termination of the lesser in the greater vena azygos. 12. The receptaculum chyli; several lymphatic trunks are seen opening into it. 13. The thoracic duct, dividing opposite the middle of the dorsal vertebræ into two branches which soon reunite; the course of the duct behind the arch of the aorta and left subclavian artery is shown by a dotted line. 14. The duct making its turn at the root of the neck and receiving several lymphatic trunks previously to terminating in the posterior aspect of the junction of the internal jugular and subclavian vein. 15. The termination of the trunk of the ductus lymphaticus dexter.

it is joined by the lymphatic trunks from the left side of the head and neck, left upper extremity, and from the upper part of the thorax, and thoracic viscera.

The *Ductus lymphaticus dexter* is a short trunk which receives the lymphatic vessels from the right side of the head and neck, right upper extremity and right side of the thorax, and terminates at the junction of the right subclavian with the right internal jugular vein, at the point where these veins unite to form the right vena innominata. It is provided at its termination with a pair of semilunar valves, which prevent the entrance of blood from the veins.

CHAPTER VIII.

ON THE NERVOUS SYSTEM.

THE nervous system consists of a central organ, the cerebro-spinal centre or axis, and of numerous rounded and flattened white cords,—the nerves, which are connected by one extremity with the cerebro-spinal centre, and by the other are distributed to all the textures of the body. The sympathetic system is an exception to this description; for in place of one it has many small centres, which are called ganglia, and which communicate very freely with the cerebro-spinal axis and with its nerves.

The cerebro-spinal axis consists of two portions, the brain; an organ of large size, situated within the skull, and the spinal cord, a lengthened portion of the nervous centre, continuous with the brain, and occupying the canal of the vertebral column.

The most superficial examination of the brain and spinal cord shows them to be composed of fibres, which in some situations are ranged side by side or collected into bundles of fasciculi, and in other situations are interlaced at various angles by cross fibres. The fibres are connected and held together by a delicate cellular web, which forms the bond of support to the entire organ. It is also observed that the cerebro-spinal axis presents two substances differing from each other in density and colour; a gray or cineritious or cortical substance, and a white or medullary substance. The *gray substance* forms a thin lamella over the entire surface of the convolutions of the cerebrum, and the laminæ of the cerebellum: hence it has been named cortical; but the gray substance is not confined to the surface of the brain, as this term would imply,—it is likewise situated in the centre of the spinal cord its entire length, and may be thence traced through the medulla oblongata, crura cerebri, thalami optici, and corpora striata; it enters also into the composition of the lobus perforatus, tuber cinereum, commissura mollis, pineal gland, and corpus rhomboideum.

The fibres of the cerebro-spinal axis are arranged into two classes, *diverging* and *converging*. The diverging fibres proceed from the medulla oblongata, and diverge to every part of the surface of the brain; while the converging commence upon the surface, and proceed inwards towards the centre so as to connect the diverging fibres of opposite sides. In certain parts of their course the diverging fibres are separated by the gray substance, and increase in number so as to form a body of considerable size, which is called a ganglion. The position and mutual relations of these fibres and ganglia may

be best explained by reference to the mode of developement of the cerebro-spinal axis in animals and in man.

The centre of the nervous system in the lowest animals possessed of a lengthened axis, presents itself in the form of a double cord. A step higher in the animal scale, and knots or *ganglia* are developed upon one extremity of this cord; such is the most rudimentary condition of the brain in the lowest forms of vertebrata. In the lowest fishes the anterior extremity of the double cord displays a succession of five pairs of ganglia. The higher fishes and amphibia appear to have a different disposition of these primitive ganglia. The first two have become fused into a single ganglion, and then follow only three pairs of symmetrical ganglia. But if the larger pair be unfolded after being hardened in alcohol, it will then be seen that the whole number of ganglia exists, but that four have become concealed by a thin covering that has spread across them. This condition of the brain carries us upwards in the animal scale even to Mammalia; *e. g.*, in the dog or cat we find, first a single ganglion, the cerebellum, then three pairs following each other in succession; and if we unfold the middle pair, we shall be at once convinced that it is indeed composed of two pairs of primitive ganglia concealed by an additional developement. Again it will be observed, that the primitive ganglia of opposite sides, at first separate and disjointed, become connected by means of transverse fibres of communication (*commissures, commissura, a joining*). The office of these commissures is the association in function of the two symmetrical portions. Hence we arrive at the general and important conclusion, that the brain among the lower animals consists of *primitive cords, primitive ganglia* upon those cords, and *commissures* which connect the substances of the adjoining ganglia, and associate their functions.

In the developement of the cerebro-spinal axis in man, the earliest indication of the spinal cord is presented under the form of a pair of minute longitudinal filaments placed side by side. Upon these, towards the anterior extremity, five pairs of minute swellings are observed, not disposed in a straight line as in fishes, but curved upon each other so as to correspond with the direction of the future cranium. The posterior pair soon becomes cemented upon the middle line, forming a single ganglion; the second pair also unite with each other; the third and fourth pairs, at first distinct, are speedily veiled by a lateral developement, which arches backwards and conceals them; the anterior pairs, at first very small, decrease in size and become almost lost in the increased developement of the preceding pairs.

We see here a chain of resemblances corresponding with the progressive developement observed in the lower animals; the human brain is passing through the phases of improving developement, which distinguish the higher from the lower creatures: and we are naturally led to the same conclusion with regard to the architecture of the human brain, that we were led to establish as the principle of developement in the inferior creature—that it is composed of

primitive cords, *primitive ganglia* upon those cords, *commissures* to connect those ganglia, and *developements* from those ganglia.

In the adult, the *primitive longitudinal cords* have become cemented together, to form the *spinal cord*. But, at the upper extremity, they separate from each other under the name of *crura cerebri*. The *first pair of ganglia* developed from the primitive cords, have grown into the *cerebellum*; the *second pair* (the optic lobes of animals) have become the *corpora quadrigemina* of man. The *third pair*, the *optic thalami*, and the *fourth*, the *corpora striati*, are the *basis of the hemispheres*, which, the merest lamina in the fish, has become the largest portion of the brain in man. And the *fifth pair* (olfactory lobes), so large in the lowest forms, have dwindled into the *olfactory bulbs* of man.

The white substance of the brain and spinal cord when examined with the microscope, is found to consist of fibres varying in diameter, according to Krause, from the $\frac{1}{370}$ to the $\frac{1}{134}$ of a line. These fibres are composed of a thin and transparent neurilemma, enclosing a soft homogeneous nervous substance, and they possess a remarkable tendency, when compressed, to assume a varicose appearance. The nervous fibres of the olfactory, optic, and auditory nerves have the same disposition to become varicose on pressure. The neurilemma of the primitive fibre, according to Fontana, consists of two layers, of which the internal is thin and transparent, and the external cellular and less transparent.

The gray substance of the brain, according to Valentin, is composed of spherical globules of considerable size, having a central nucleus, and near the margin of the latter another smaller nucleus, and frequently upon the surface of the globule, patches of pigment. Numerous minute fibres have been observed by Remak to proceed from the surface of these globules, and are supposed to maintain a communication with surrounding globules. The various shades of gray observed in different parts of the brain depend upon the greater or smaller number of globules existing in those parts. Two kinds of gray substance are described by Rolanda as existing in the spinal cord; the one (*substantia cinerea spongiosa vasculosa*) is the ordinary gray matter of the cord, and the other (*substantia cinerea gelatinosa*) forms part of the posterior cornua. The former resembles the gray matter of the brain, consisting of globules, while the latter is composed of small bodies resembling the blood corpuscles of the frog.

The nerves are divisible into two great classes,—those which proceed directly from the cerebro-spinal axis, the cranial and spinal nerves, and constitute the system of animal life; and those which originate from a system of nervous centres, independent of the cerebro-spinal axis, but closely associated with that centre by numerous communications, the sympathetic system, or system of organic life.

The division of nerves into cranial and spinal is purely arbitrary, and depends upon the circumstance of the former passing through

the foramina of the cranium, and the latter through those of the vertebral column. With respect to origin,—all the cranial nerves, with the exception of the first,—olfactory, proceed from the spinal cord, or from its immediate continuation into the brain. The spinal nerves arise by two roots; *anterior*, which proceeds from the anterior segment of the spinal cord, and possesses a motor function; and *posterior*, which is connected with the posterior segment, and bestows the faculty of sensation. The motor nerves of the cranium are shown by dissection to be continuous with the motor portion of the cord, and form one system with the motor roots of the spinal cord; while the nerves of sensation, always excepting the olfactory, are in like manner traced to the posterior segment of the cord, and form part of the system of sensation. To these two systems a third has been added by Sir Charles Bell,—the respiratory system,—which consists of nerves associated in the function of respiration, and arising from the side of the upper part of the spinal cord in one continuous line, which was thence named, by that distinguished physiologist, the respiratory tract. The microscope has succeeded in making no structural distinction between the anterior and posterior roots of the spinal nerves; but the latter are remarkable from possessing a ganglion near to their attachment with the cord. This ganglion is observed upon the posterior roots of all the spinal nerves, and also upon the corresponding root of the fifth cranial nerve, which is thence considered a spinal cranial nerve. Upon others of the cranial nerves a ganglion is found, which associates them in their function with the nerves of sensation, and establishes an analogy with the spinal nerves.

The recent researches of Mr. Grainger have made an important addition to our knowledge of the mode of connexion of the nerves with the spinal cord; he has shown that both roots of the spinal nerves, as well as most of the cerebral, divide into two sets of filaments upon entering the cord, one set being connected to the gray substance, while the other is continuous with the white or fibrous part of the cord. The former he considers to be the agents of the excito-motory system of Dr. Marshall Hall; and the latter, the communication with the brain and the medium for the transmission of sensation and volition. He has not been able to trace the fibres which enter the gray substance to their termination; but he thinks it probable that the ultimate filaments of the posterior root join those of the anterior root; or in the words of Dr. Marshall Hall's system, that the incident fibres (sensitive) are continuous with the reflex (motor).

The connexion of a nerve with the cerebro-spinal axis is called, for convenience of description, its *origin*: this term must not, however, be received literally; for each nerve is developed in the precise situation which it occupies in the body, and with the same relations that it possesses in after life. Indeed, we not unfrequently meet with instances in anencephalous fœtuses, where the nerves are beautifully and completely formed, while the brain and spinal cord

are wholly wanting. The word origin must, therefore, be considered as a relic of the darkness of preceding ages, when the cerebro-spinal axis was looked upon as the tree from which the nerves pushed forth as branches. In their *distribution* the spinal nerves for the most part follow the course of the arteries, particularly in the limbs, where they lie almost constantly to the outer side and superficially to the vessels, as if for the purpose of receiving the first intimation of danger, and of communicating it to the muscles, that they may instantly remove the arteries from impending injury.

The microscopic examination of a cerebro-spinal nerve shows it to be composed of minute fibres, resembling those of the brain, and consisting of a neurilemma enclosing a soft, homogeneous nervous substance. The chief difference between the fibres of the nerves and the cerebral fibres is a somewhat greater opacity and more granular appearance of the contents of the minute cylinders of the former; a greater thickness of their neurilemma, and an indisposition to the formation of varicose enlargements upon compression. The neurilemma presents the same two layers which exist in the cerebral fibres. The *primitive fibres*, or *filaments*, are assembled into small bundles and enclosed in a distinct sheath, constituting a *funiculus*; the funiculi are collected into larger bundles or *fasciculi*, and a single fasciculus or a number of fasciculi connected by cellular tissue, and invested by a membranous sheath, constitute a nerve. The funiculi, when freshly exposed, present a peculiar zig-zag line across their cylinder, which is most probably produced by the arrangement of the primitive fibres, or possibly by some condition of the neurilemma. This appearance is destroyed by making extension upon the nerve.

Communications between nerves take place either by means of the funiculi composing a single nerve, or of the fasciculi in a nervous plexus. In these communications there is no fusion of nervous substance, the cord formed by any two funiculi is constantly enlarged, and corresponds accurately with their combined bulk. Microscopic examination substantiates this observation, and shows that the primitive fibre passes unchanged from one funiculus to the other, so that the primitive fibre is single and uninterrupted from its connexion with the cerebro-spinal axis to its terminal distribution. A nervous plexus consists in a communication between the fasciculi and funiculi composing the nerves, which are associated in their supply of a limb or of a certain region of the body. During this communication there is an interchange of funiculi, and with the funiculi an interchange of fibres.

The *Sympathetic system* consists of numerous ganglia, of communicating branches passing between the ganglia, of others passing between the ganglia and the cerebro-spinal axis, and of branches of distribution which are remarkable for their frequent and plexiform communications. The sympathetic nerves also differ from other nerves in their colour, which is of a grayish pearly tint. Examined

with the microscope the sympathetic nerves are seen to be composed of an admixture of gray and white fibres; the white fibres belong to the cerebro-spinal system: the gray are much smaller than the white, less transparent, and the neurilemma is less easily distinguishable from its contents: some of the nerves are composed of gray fibres only without any admixture of white. The sympathetic ganglia contain the globules observed in the gray substance of the brain; they are firmer in structure and enclosed in a strong investing capsule. The fasciculi of fibres entering the ganglion become divided and form a plexus around the globules; they then converge to constitute another fasciculus, by which they quit the ganglion.

The nervous system may be divided for convenience of description into 1. The brain. 2. The spinal cord. 3. The cranial nerves. 4. The spinal nerves. 5. The sympathetic system.

THE BRAIN.

The brain is a collective term, which signifies those parts of the nervous system, exclusive of the nerves themselves, which are contained within the cranium; they are the cerebrum, cerebellum, and medulla oblongata. These are invested and protected by the membranes of the brain, and the whole together constitute the encephalon (ἔν, κεφαλή, within the head.)

MEMBRANES OF THE ENCEPHALON.

Dissection.—To examine the encephalon with its membranes, the upper part of the skull must be removed by sawing through the external table, and breaking the internal table with the chisel and hammer. After the calvarium has been loosened all round, it will require a considerable degree of force to tear the bone away from the dura mater. This adhesion is particularly firm at the sutures, where the dura mater is continuous with a membranous layer interposed between the edges of the bones; in other situations, the connexion results from numerous vessels which permeate the inner table of the skull. The adhesion subsisting between the dura mater and bone is greater in the young subject than in the adult.

Upon being torn away, the internal table will present the deeply grooved and ramified channels, corresponding with the branches of the arteria meningeae magna. Along the middle line will be seen a groove corresponding with the superior longitudinal sinus, and on either side may be frequently observed some depressed fossæ, corresponding with the Pacchionian bodies.

The membranes of the encephalon are the *dura mater*, *arachnoid membrane*, and *pia mater*.

The *Dura mater** is the firm, bluish, fibrous membrane, which is

* So named from a supposition that it was the source of all the fibrous membranes of the body.

exposed on the removal of the calvarium. It lines the anterior of the skull and spinal column, and sends processes inwards for the support and protection of the different parts of the brain. It also sends processes externally, which form sheaths for the nerves as they quit the skull and spinal column. Its external surface is rough and fibrous, and corresponds with the internal table of the skull. The internal surface is smooth, and lined by the thin varnish-like lamella of the arachnoid membrane. The latter is a serous membrane. Hence the dura mater becomes a *fibro-serous* membrane, being composed of its own proper fibrous structure, and the serous layer derived from the arachnoid. There are two other instances of fibro-serous membrane in the body, formed in the same way—the pericardium and tunica albuginea of the testicle.

On either side of the dura mater the branches of the middle meningeal artery may be seen ramifying; and in the middle line is a depressed groove, formed by the subsidence of the upper wall of the superior longitudinal sinus. If the sinus be opened along its course, it will be found to be a triangular channel, crossed at its lower angle by numerous white bands, called chordæ Willisii;* granular bodies are also occasionally seen in its interior; these are glandulæ Pacchioni.

The *Glandulæ Pacchioni*† are small, round, whitish granulations, collected into clusters of variable size. They are found in three situations. 1. On the inner surface of the dura mater near to the superior longitudinal sinus; when of large size they produce absorption of the dura mater, and considerable indentations on the inner wall of the skull. 2. In the superior longitudinal sinus. 3. On the arachnoid membrane investing the pia mater near to the margin of the hemispheres.

If the student cut through one side of the dura mater, along the line of his incision through the skull, and turn it upwards towards the middle line, he will observe the smooth internal surface of the dura mater. He will perceive also the large cerebral veins filled with dark blood, passing from behind forwards to open into the superior longitudinal sinus, and the firm connexions, by means of these veins and the Pacchionian bodies, between the opposed surfaces of the arachnoid membrane.

If he separate these with his scalpel, he will see a vertical layer of dura mater descending between the hemispheres, and if he draw one side of the brain a little outwards, he will distinctly perceive its extent; this is the falx cerebri.

The processes of dura mater which are sent inwards towards the

* Willis lived in the seventeenth century; he was a great defender of the opinions of Harvey.

† These bodies have no analogy whatsoever with glands. Their nature and use are but imperfectly known. They are not found in infancy. They are described as conglobate glands by Pacchioni, in an epistolary dissertation. "De Glandulis conglobatis Duræ Meningis indeque ortis Lymphaticis ad Piam Matrem productis," published in Rome, in 1705.

interior of the skull, are the *falx cerebri*, *tentorium cerebelli*, and *falx cerebelli*.

The *Falx cerebri* (falx, a sickle), so named from its sickle-like appearance, narrow in front, broad behind, and forming a sharp curved edge below, is attached in front to the crista galli process of the ethmoid bone, and behind to the tentorium cerebelli.

The *Tentorium cerebelli* (tentorium, a tent) is a roof of dura mater, thrown across the cerebellum, and attached at each side to the margin of the petrous portion of the temporal bone, behind to the transverse ridge of the occipital bone, which lodges the lateral sinuses, and to the clinoid processes in front. It supports the posterior lobes of the cerebrum and prevents their pressure* on the cerebellum, leaving only a small opening anteriorly, for the transmission of the crura cerebri.

The *Falx cerebelli* is a small process, generally double, attached to the vertical ridge of the occipital bone beneath the lateral sinus, and to the tentorium. It is received into the indentation between the two lateral lobes of the cerebellum.

The layers of the dura mater separate in several situations, so as to form irregular channels which receive the venous blood. These are the *sinuses* of the dura mater; they are described at page 356, in the Chapter on the Veins.

The student cannot see the tentorium and falx cerebelli until the brain is removed; but he should consider the attachments of the tentorium upon the dried skull, for he will have to divide it in the removal of the brain. He should now proceed to that operation, for which purpose the dura mater is to be incised all round, on a level with the section through the skull, and the scissors are to be carried deeply between the hemispheres of the brain in front, to cut through the anterior part of the falx; then draw the dura mater backwards, and leave it hanging by its attachment to the tentorium. Raise the anterior lobes of the brain carefully with the hand, and lift the olfactory bulbs from the cribriform fossæ with the handle of the scalpel. Then cut across the two optic nerves and internal carotid arteries. Next divide the infundibulum and third nerve, and carry the knife along the margin of the petrous bone at each side, so as to divide the tentorium near its attachment. Cut across the fourth, fifth, sixth, seventh, and eighth nerves in succession with a sharp knife, and pass the scalpel as far down as possible into the vertebral canal, to sever the spinal cord, cutting first to one side and then to the other, in order to divide the vertebral arteries and first cervical nerves. Then let him press the cerebellum gently forwards with the fingers of the right hand, the hemispheres being supported with the left, and the brain will roll into his hand.

The *Arteries* of the dura mater are the *anterior meningeal* from the internal carotid. The *middle meningeal* and *meningeal parva*

* In leaping animals, as the feline and canine genera, the tentorium forms a bony tent.

from the internal maxillary. The *inferior meningeal* from the ascending pharyngeal and occipital arteries; and the *posterior meningeal* from the vertebral.

The *Nerves* are derived from the nervi molles and vertebral plexus of the sympathetic, from the Casserian ganglion, the ophthalmic nerve, and sometimes from the fourth. The branches from the two last are given off while the nerves are situated by the side of the sella turcica; they are recurrent, and pass backwards between the layers of the tentorium, to the lining membrane of the lateral sinus.

Arachnoid Membrane.

The *Arachnoid* (ἀράχνη, εἶδος, like a spider's web), so named from its extreme tenuity, is the serous membrane of the cerebro-spinal centre, and like other serous membranes, a shut sac. It envelops the brain and spinal cord, and is reflected upon the inner surface of the dura mater, giving to that membrane its serous investment.

The arachnoid is thin and transparent on the upper surface of the brain, as may be demonstrated by inserting a blowpipe, and injecting beneath it a stream of air. In other situations, as at the base of the brain and between the cerebellum and medulla oblongata, it is semi-transparent and dense in structure, and is rendered very evident by passing across from one convexity to another, and leaving a considerable space between it and the brain. The space which is thus formed between the arachnoid membrane and the interval of the base of the brain between the two middle lobes of the hemispheres, has been called by Cruveilhier the *anterior sub-arachnoidean space*; and that intervening between the posterior and under part of the cerebellum and the medulla oblongata, the *posterior sub-arachnoidean space*. Both these spaces communicate with each other across the crura cerebelli. In inflammation of the meninges, this membrane is often thickened and opaque.

The arachnoid is attached to the pia mater of the brain by a loose cellular tissue, the sub-arachnoidean. This tissue is filamentous at the base of the brain, and between the hemispheres. Around the spinal cord the arachnoid is disposed very loosely so as to leave a considerable space between it and the spinal cord. The *spinal sub-arachnoidean space* is divided by a partial longitudinal septum which serves to connect the arachnoid with the posterior surface of the spinal cord.

The *Sub-arachnoidean cellular tissue* and the *sub-arachnoidean spaces* are the seat of an abundant serous secretion, the *sub-arachnoidean fluid*, which fills all the vacuities existing between the arachnoid and pia mater, and distends the arachnoid of the spinal cord so completely, as to enable it to occupy the whole of the space included in the sheath of dura mater.

The arachnoid also secretes a serous fluid from its inner surface, which is small in quantity compared with the sub-arachnoidean liquid.

The arachnoid does not enter into the ventricles of the brain, as imagined by Bichât, but is reflected inwards upon the venæ Galeni for a short distance only, and returns upon those vessels to the dura mater of the tentorium. It surrounds the nerves as they originate from the brain, and forms a sheath around them to their point of exit from the skull. It is then reflected back upon the inner surface of the dura mater.

There are no vessels in the arachnoid, and no nerves have been traced into it.

Pia Mater.

The *Pia mater* is a vascular membrane composed of innumerable vessels held together by a thin cellular layer. It invests the whole surface of the brain, dipping into its convolutions, and forming a fold in its interior called *velum interpositum*. It also forms folds in other situations, as in the fourth ventricle, and in the longitudinal grooves of the spinal cord.

This membrane differs very strikingly in its structure in different parts of the cerebro-spinal axis. Thus, on the surface of the cerebrum, in contact with the soft gray matter of the brain, it is excessively vascular, forming remarkable loops of anastomoses between the convolutions, and distributing multitudes of minute straight vessels to the gray substance. In the *substantia perforata*, again, and *locus perforatus*, it gives off tufts of small arteries, which pierce the white matter to reach the gray substance in the interior. But, upon the *crura cerebri*, *pons Varolii*, and spinal cord, its vascular character seems almost lost. It has become a *dense fibrous membrane*, difficult to tear off, and forming the proper sheath of the spinal cord.

The *pia mater* is the nutrient membrane of the brain, and derives its blood from the internal carotid and vertebral arteries.

Its *Nerves* are the minute filaments of the sympathetic, which accompany the branches of the arteries.

CEREBRUM.

The *Cerebrum* is divided into two hemispheres by the great longitudinal fissure, which lodges the *falx cerebri*, and marks the original development of the brain by two symmetrical halves.

Each hemisphere, upon its under surface, admits of a division into three lobes, anterior, middle, and posterior. The *anterior lobe*, rests upon the roof of the orbit, and is separated from the middle by the fissure of Sylvius.* The *middle lobe*, is received into the middle fossa, in the base of the skull, and is separated from the posterior by

* James Dubois, a celebrated professor of anatomy in Paris, where he succeeded Vidius in 1550, although known much earlier by his own works and discoveries, but particularly by his violence in the defence of Galen. His name was Latinised to *Jacobus Sylvius*.

a slight impression produced by the ridge of the petrous bone. The *posterior lobe* is supported by the tentorium.

If the upper part of one hemisphere be removed with a scalpel, a centre of white surface will be observed, surrounded by a narrow border of gray, which follows the depressions of the convolutions, and presents a zigzag outline. This appearance is called *centrum ovale minus*. The divided surface will be seen to be studded with numerous small red points (*puncta vasculosa*) which are produced by the escape of blood from the divided ends of minute arteries and veins.

Now separate carefully the two hemispheres of the cerebrum, and a broad band of white substance will be seen to connect them. Remove the upper part of each hemisphere, with a knife, to a level with this white layer. The appearance resulting from this section is the *centrum ovale majus*.

The *Centrum ovale majus* is the large centre of white substance presented to view on the removal of the upper part of both hemispheres; it is surrounded by a thin stratum of gray substance, which follows in a zigzag line all the convolutions and the fissures between them. In the middle of the *centrum ovale majus* is the broad band which connects the two hemispheres to each other, the *corpus callosum*.

The *Corpus callosum* (*callosus*, hard) is a dense layer of transverse fibres connecting the two hemispheres and constituting their *great commissure*. It is situated nearer to the anterior than to the posterior part of the brain, and terminates anteriorly in a rounded border which may be traced downwards to the base of the brain, in front of the commissure of the optic nerves. Posteriorly it forms a thick rounded fold which is continuous with the fornix.

Beneath the posterior rounded border of the *corpus callosum* is the *transverse fissure* of the cerebrum, which extends between the hemispheres and *crura cerebri* from the fissure of Sylvius on one side, to that on the opposite side of the brain. It is through this fissure that the *pia mater* communicates with the *velum interpositum*. And it was here that Bichât conceived the arachnoid to enter the ventricles; hence it is also named the *fissure of Bichât*.

Along the middle line of the *corpus callosum* is the *raphé*, a linear depression between two slightly elevated longitudinal bands; and, on either side of the *raphé*, may be seen the *lineæ transversæ*, which mark the direction of the fibres of which the *corpus callosum* is composed.

If an incision be made through the *corpus callosum* on either side of the *raphé*, two irregular cavities will be opened, which extend from one extremity of the hemispheres to the other: these are the *lateral ventricles*. To expose them completely the upper boundary should be removed with the scissors.

Each *lateral ventricle* is divided into a *central cavity*, and three smaller cavities called *cornua*. The *anterior cornu* curves forwards and outwards in the anterior lobe: the *middle cornu* descends into

the middle lobe; and the *posterior cornu* passes backwards in the posterior lobe, converging towards its fellow of the opposite side. The central cavity is triangular in its form, being bounded above (*roof*) by the corpus callosum; internally by the septum lucidum, which separates it from the opposite ventricle; and below (*floor*) by the following parts, taken in their order of position from before backwards:

Corpus striatum,
Tenia semicircularis,
Thalamus opticus,
Choroid plexus,
Corpus fimbriatum,
Fornix.

Fig. 140.

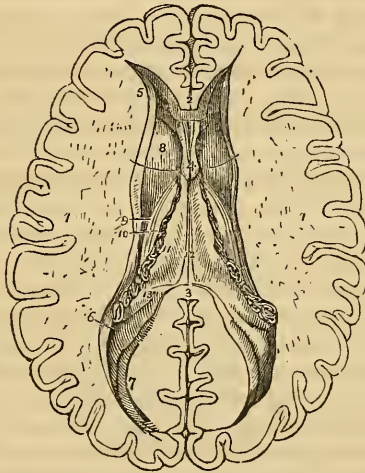


Fig. 140. The lateral ventricles of the cerebrum. 1, 1. The two hemispheres cut down to a level with the corpus callosum so as to constitute the centrum ovale majus. The surface is seen to be studded with the small vascular points—*puncta vasculosa*; and surrounded by a narrow margin which represents the gray substance. 2. A small portion of the anterior extremity of the corpus callosum. 3. Its posterior boundary; the intermediate portion forming the roof of the lateral ventricles has been removed so as to completely expose those cavities. 4. A part of the septum lucidum, showing an interspace between its layers—the fifth ventricle. 5. The anterior cornu of one side. 6. The commencement of the middle cornu. 7. The posterior cornu. 8. The corpus striatum of one ventricle. 9. The tenia semicircularis covered by the vena corporis striata and tenia Tarini. 10. A small part of the thalamus opticus. 11. The dark fringe-like body to the left of the figure is the choroid plexus. This plexus communicates with that of the opposite ventricle through the foramen of Munro; a bristle is passed through this opening, and its extremities are seen resting on the corpus striatum at each side. The figure 11 rests upon the edge of the fornix, upon that part of it which is called the corpus fimbriatum. 12. The fornix. 13. The commencement of the hippocampus major descending into the middle cornu. The rounded oblong body in the posterior cornu of the lateral ventricle, directly behind the figure 13, is the hippocampus minor.

The *Corpus striatum* is named from the striated lines of white and gray matter which are seen upon cutting into its substance. It is gray on the exterior, and of a pyriform shape. The broad end, directed forwards, rests against the corpus striatum of the opposite side: the small end, backwards, is separated from its fellow by the interposition of the thalami optici. The corpora striata are the superior ganglia of the cerebrum.

The *Tenia semicircularis* (tenia, a fillet) is a narrow band of medullary substance, extending along the posterior border of the corpus striatum, and serving as a bond of connexion between that body and the thalamus opticus. The tenia is partly concealed by a large vein (*vena corporis striati*) formed by small vessels from the corpus striatum and thalamus opticus, and terminating in the venæ Galeni. The vein is overlaid by a yellowish band, a thickening of the lining membrane of the ventricle.* This was first noticed and described by Tarinus, under the name of the *horny band*. We may, therefore, term it *tenia Turini*.*

The *Thalamus opticus* (thalamus, a bed) is an oblong body, having a thin coating of white substance on its surface; it has received its name from giving origin to one root of the optic nerve. It is the inferior ganglion of the cerebrum. The border only of the thalamus is seen in the floor of the lateral ventricle. We must, therefore, defer its further description until we can examine it in its entire extent.

The *Choroid plexus* (χόριον, εἶδος, resembling the chorion†) is a vascular fringe extending obliquely across the floor of the lateral ventricle, and sinking into the middle cornu. Anteriorly, it is small and tapering, and communicates with the choroid plexus of the opposite ventricle, through a large oval opening, the *foramen of Munro*. This foramen may be distinctly seen by pulling slightly on the plexus, and pressing aside the septum lucidum with the handle of the knife. It is situated between the under surface of the fornix, and the anterior extremities of the thalami optici, and forms a transverse communication between the lateral ventricles, and below with the third ventricle.

The choroid plexus is variable in its appearance, and sometimes presents groups and clusters of small serous cysts, which have been mistaken for hydatids.

The *Corpus fimbriatum* is a narrow white band, which is situated immediately behind the choroid plexus, and extends with it into the descending cornu of the lateral ventricle. It is the lateral thin edge of the fornix.

The *Fornix* is a white layer of medullary substance, of which a portion only is seen in this view of the ventricle.

The *Anterior cornu* is triangular in its form, sweeping outwards

* Peter Tarin, a French anatomist: his work, entitled "Adversaria Anatomica," was published in 1750.

† See the note appended to the description of the choroid coat of the eyeball.

and terminating by a point in the anterior lobe of the brain, at a short distance only from its surface.

The *Posterior cornu* or *digital cavity* curves inwards, as it extends into the posterior lobe of the brain, and likewise terminates near to the surface. An elevation corresponding with a deep sulcus between two convolutions projects into the area of this cornu, and is called the *hippocampus minor*.

The *Middle* or *descending cornu*, in descending into the middle lobe of the brain, forms a very considerable curve, and alters its direction several times as it proceeds. Hence it is described as passing backwards and outwards and downwards, and then turning forwards and inwards. This complex expression of a very simple curve has given birth to a symbol formed by the primary letters of these various terms; and by means of this the student recollects with ease the course of the cornu, BODFI. It is the largest of the three cornua.

The middle cornu should now be laid open, by inserting the little finger into its cavity, and making it serve as a director for the scalpel in cutting away the side of the hemisphere, so as to expose it completely.

Its *Superior boundary* is formed by the under surface of the thalamus opticus, upon which are the two projections called corpus geniculatum internum and externum; and the *inferior wall* by the various parts which are often spoken of as the contents of the middle cornu: these are the—

Hippocampus major,
 Pes hippocampi,
 Pes accessorius,
 Corpus fimbriatum,
 Choroid plexus,
 Fascia dentata,
 Transverse fissure.

The *Hippocampus major* or *cornu Ammonis*, so called from its resemblance to a ram's horn, the famous crest of Jupiter Ammon, is a considerable projection from the inferior wall, and extends the whole length of the middle cornu. Its extremity is likened to the club-foot of some animal, from its presenting a number of knuckle-like elevations upon the surface: hence it is named *pes hippocampi*. The hippocampus major is the termination of the lateral edge of the hemisphere, which in this situation is very much attenuated and rolled upon itself. If it be cut across, the section will be seen to resemble the extremity of a convoluted scroll, consisting of alternate layers of white and gray substance. The hippocampus major is continuous superiorly with the fornix and corpus callosum.

The *Pes accessorius* is a swelling somewhat resembling the hippocampus major, but smaller in size; it is situated on the outer wall of the cornu, and is frequently absent.

The *Corpus fimbriatum* is the narrow white band which is pro-

longed from the central cavity of the ventricle, and is attached along the inner border of the hippocampus major to its termination.

Fascia dentata:—If the corpus fimbriatum be carefully raised, a narrow serrated band of gray substance will be seen beneath it; this is the fascia dentata.

Beneath the corpus fimbriatum will be likewise seen the *transverse fissure* of the brain, which has been before described as extending from the fissure of Sylvius on one side, across to the same fissure on the opposite side of the brain. It is through this fissure that the pia mater communicates with the *choroid plexus*, and the latter obtains its supply of blood. The fissure is bounded on one side by the corpus fimbriatum, and on the other by the under surface of the thalamus opticus.

The internal boundary of the lateral ventricle is the *septum lucidum*. This septum is thin and semi-transparent, and consists of two laminæ of cerebral substance attached above to the under surface of the corpus callosum at its anterior part, and below to the fornix. Between the two layers is a narrow space, the *fifth ventricle*, which is lined by a proper membrane. The *fifth ventricle* may be shown, by snipping through the septum lucidum transversely with the scissors.

The corpus callosum should now be cut across towards its anterior extremity, and the two ends carefully dissected away. The anterior portion will be retained only by the septum lucidum, but the posterior will be found incorporated with the white layer beneath, which is the fornix.

The *fornix* (arch) is a triangular lamina of white substance, broad behind, and extending into each lateral ventricle: narrow in front, where it terminates in two crura, which arch downwards to the base of the brain. The two crura descend through the foramen commune anterius of the third ventricle, and terminate in the *corpora albicantia*. Opening transversely beneath these two crura, just as they are about to arch downwards, is the *foramen of Munro*, through which the two lateral ventricles communicate, and the choroid plexuses are connected anteriorly.

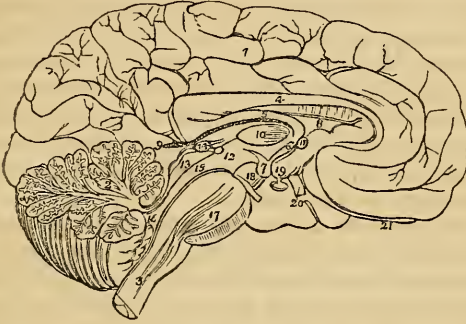
The lateral thin edges of the fornix are continuous *posteriorly* with the concave border of the hippocampus major at each side, and form the narrow white band called *corpus fimbriatum*. In the middle line the fornix is continuous with the corpus callosum, and at each side with the hippocampus major and minor. Upon the under surface of the fornix towards its posterior part, some transverse lines are seen passing between the diverging lateral fasciculi: this appearance is termed the *lyra*, from a fancied resemblance to the strings of a harp.

The fornix may now be removed by dividing it across anteriorly, and turning it backwards, at the same time separating its lateral connexions with the hippocampi. If the student examine its under surface, he will perceive the lyra above described.

Beneath the fornix is the *velum interpositum*, a reflection of pia

matter introduced into the interior of the brain, through the transverse fissure. The velum is connected at each side with the choroid plexus, and contains within its two layers, in the middle line, two large veins, the *venæ Galeni*, which receive the blood from the ventricles, and terminate posteriorly in the straight sinus. Upon the under surface of the velum interpositum are two fringe-like bodies which project into the third ventricle. These are the *choroid plexuses* of the *third ventricle*.

Fig. 141.



If the velum interpositum be raised and turned back, an operation which must be conducted with care, particularly at its posterior part, where it invests the pineal gland, the thalami optici and the cavity of the third ventricle will be brought into view.

The *thalami optici* are two rounded oblong bodies, of a white colour superficially, inserted between the two diverging portions of the corpora striata. In the middle line a fissure exists between them, which is called the *third ventricle*. Posteriorly and inferiorly, they form the superior wall of the descending cornu, and present

Fig. 141. The mesial surface of a longitudinal section of the brain. The incision has been carried along the middle line; between the two hemispheres of the cerebrum, and through the middle of the cerebellum and medulla oblongata. 1. The inner surface of the left hemisphere. 9. The divided surface of the cerebellum, showing the arbor vitæ. 3. The medulla oblongata. 4. The corpus callosum, rounded before to terminate in the base of the brain; and behind, to become continuous with 5, the fornix. 6. One of the crura of the fornix descending to 7, one of the corpora albicantia. 8. The septum lucidum. 9. The velum interpositum, communicating with the pia mater of the convolutions through the fissure of Bichat. 10. Section of the middle commissure situated in the third ventricle. 11. Section of the anterior commissure. 12. Section of the posterior commissure; the commissure is somewhat above and to the left of the number. The interspace between 10 and 11 is the foramen commune anterius, in which the crus of the fornix (6) is situated. The interspace between 10 and 12 is the foramen commune posterius. 13. The corpora quadrigemina, upon which is seen resting the pineal gland, 14. 15. The iter e tertio ad quartum ventriculum. 16. The fourth ventricle. 17. The pons Varolii, through which are seen passing the diverging fibres of the corpora pyramidalia. 18. The crus cerebri of the left side, with the third nerve arising from it. 19. The tuber cinereum, from which projects the infundibulum having the pituitary gland appended to its extremity. 20. One of the optic nerves. 21. The left olfactory nerve terminating anteriorly in a rounded bulb.

two rounded elevations called *corpus geniculatum externum* and *internum*. The *corpus geniculatum externum* is the larger of the two, and of a grayish colour; it is the principal origin of the optic nerve. Inferiorly, the thalami are connected with the corpora albicantia by means of two white bands, which appear to originate in the white substance uniting the thalami to the corpora striata. In their interior the thalami are composed of white fibres mixed with gray substance. They are essentially the *inferior ganglia of the cerebrum*.

The *Third ventricle* is the fissure between the two thalami optici. It is bounded above by the under surface of the velum interpositum, from which are suspended the choroid plexuses of the third ventricle. Its *floor* is formed by the anterior termination of the corpus callosum, the tuber cinereum, corpora albicantia, and locus perforatus. *Laterally* it is bounded by the thalami optici and part of the corpora striata; *anteriorly* by the anterior commissure and crura of the fornix; and *posteriorly* by the posterior commissure and the iter e tertio ad quartum ventriculum.

The third ventricle is crossed by three commissures, the anterior, middle, and posterior; and between these are two spaces, called foramen commune anterius and foramen commune posterius.

The *Anterior commissure* is a rounded white cord, which enters the corpus striatum at either side; the *middle*, or *soft commissure* consists of gray matter, and is very easily broken down; it connects the adjacent sides of the thalami optici: and the *posterior commissure* is a flattened white cord, connecting the two thalami optici posteriorly.

Between the anterior and middle commissure is the space called *foramen commune anterius*, which, from leading downwards into the infundibulum, is also designated *iter ad infundibulum*. The crura of the fornix descend through this space, surrounded by gray matter to the corpora albicantia. Between the middle and posterior commissure is the *foramen commune posterius*, from which a canal leads backwards to the fourth ventricle, the *iter e tertio ad quartum ventriculum*.

Behind the third ventricle is placed the quadrifid ganglion called optic lobes in the inferior animals, and *corpora quadrigemina* in man. The two anterior of these bodies are the larger, and are named *nates*; the two posterior, *testes*. Their base is perforated from before backwards by a tubular canal, which serves to communicate the third and fourth ventricles, and is thence named the iter e tertio ad quartum ventriculum, or aqueduct of Sylvius. Resting upon the corpora quadrigemina and surrounded by a sheath of pia mater, obtained from the velum interpositum, with which it is liable to be torn off unless very great care be used, is the *pineal gland*.

The *Pineal gland* consists of soft gray substance, and is of a conical form; hence one of its synonymes, *conarium*. It contains in its interior several brownish granules, which are composed of

phosphate and carbonate of lime. It is connected to the thalami optici by two small rounded cords, called *peduncles*, and is very improperly called a gland.

Behind the corpora quadrigemina is the cerebellum, and beneath the cerebellum the fourth ventricle. The student must therefore divide the cerebellum down to the fourth ventricle, and turn its lobes aside to examine that cavity.

The *Fourth ventricle* is the ventricle of the medulla oblongata, upon the posterior surface of which it is placed. It is an oblong quadrilateral cavity, *bounded on each side* by a thick cord passing between the cerebellum and corpora quadrigemina, called the *processus e cerebello ad testes*, and by the *corpus restiforme*. It is covered in *behind* by the arch of the cerebellum, which forms three remarkable projections into its cavity, named, from their resemblance, *uvula* and *tonsils*: and by a thin lamella of white substance, stretched between the two processus e cerebello ad testes, termed the *valve of Vieussens*.* This layer is easily broken down, and requires that care be used in its demonstration. In *front* the fourth ventricle is bounded by the posterior surface of the medulla oblongata; *above* by the corpora quadrigemina, and the termination of the iter e tertio ad quartum ventriculum; and *below* by a layer of pia mater and one of arachnoid, passing between the under surface of the cerebellum and the medulla oblongata, called the *valve of the arachnoid*.

We observe within the fourth ventricle the *choroid plexuses*, the *calamus scriptorius*, and the *lineæ transversæ*.

The *Choroid plexuses* resemble in miniature those of the lateral ventricles: they are formed by the pia mater, and lie against that part of the cerebellum called *uvula* and *tonsils*.

The anterior wall, or floor, of the fourth ventricle is formed of gray substance, which is continuous with that contained within the spinal cord. This gray substance is separated into two bands by a median fissure, which is continuous with the *calamus scriptorius*. The two bands are considered by Mr. Solly as the two *posterior pyramids*; and he has observed in their structure such an arrangement of fibres as induces him to name them the "*posterior ganglia of the medulla oblongata*," in opposition to the corpora olivaria, which he describes as the "*anterior ganglia of the medulla*."

The *Calamus scriptorius* is a groove upon the anterior wall, or floor, of the fourth ventricle. Its pen-like appearance is produced by the divergence of the posterior median columns, the feather by the *lineæ transversæ*. At the point of the pen is a small cavity lined with gray substance, and called the *ventricle of Arantius*.

The *Lineæ transversæ* are irregular transverse lines upon the anterior wall of the ventricle, which in some degree resemble the plume of the pen. They are the filaments of origin of the auditory nerve.

* Raymond Vieussens, a great discoverer in the anatomy of the brain and nervous system. His "*Neurographia Universalis*" was published at Lyons, in 1685.

The existence of a communication between the fourth ventricle and the subarachnoidean space, as imagined by Magendie, is very questionable.

LINING MEMBRANE OF THE VENTRICLES.

The lining membrane of the ventricles is a serous layer, quite distinct from the arachnoid, and having no communication with it. This membrane lines the whole of the interior of the lateral ventricles, and is connected above and below to the attached border of the choroid plexus, so as to exclude completely all communication between the ventricles and the exterior of the brain. It is reflected through the foramen of Munro, on each side, into the third ventricle, which it invests throughout. From the third it is conducted into the fourth ventricle, through the *iter e tertio ad quartum ventriculum*, and lines its interior, together with the layer of pia mater which forms its inferior boundary. In this manner a perfect communication is established between all the ventricles. It is this membrane which gives them their polished surface, and transudes the secretion which moistens their interior. When the fluid accumulates to an unnatural degree, it may then break down this layer and the layer of pia mater at the bottom of the fourth ventricle, and thus make its way into the subarachnoidean cellular tissue; but in the normal condition it is doubted whether a communication exists between the interior of the ventricles and the cavity of the subarachnoidean space.

CEREBELLUM.

The *Cerebellum*, according to Cruveilhier, is seven times smaller than the cerebrum. Like that organ it is composed of white and gray substance, whereof the gray is larger in proportion than the white. Its surface is formed by parallel *lamellæ*, separated by fissures; and at intervals deeper fissures exist, which divide it into larger segments termed *lobules*. The cerebellum is divided into two lateral hemispheres or lobes, two minor lobes called superior and inferior vermiform processes, and some small lobules.

The *Lateral lobes* are separated from each other posteriorly by a depression which lodges the *falx cerebelli*, and above and below by the projection of the vermiform processes.

The *Superior vermiform process*, a slightly elevated ridge along the middle of the upper surface of the cerebellum, is all that exists of that organ in birds, and it constitutes the largest proportion of the cerebellum in many mammalia. It is situated along the middle line, and serves to connect the lateral lobes superiorly.

The *Inferior vermiform process*, forms a projection inferiorly, and is the means of connexion between the lateral lobes below.

The principal lobules are the pneumogastric, the tonsils, uvula, and *linguetta laminosa*.

The *Pneumogastric lobule* (*flocculus*) is situated on the anterior border of the cerebellum, near to the origin of the eighth pair of

nerves, and is hence called pneumogastric. It is not unlike a convoluted shell in its form.

The *Tonsils* and *uvula* resemble those organs in a swollen state very strikingly; they project from the under surface of the cerebellum into the fourth ventricle.

The *Linguetta laminosa* is a thin tonguelet of gray substance, marked by transverse furrows, which extend forwards upon the valve of Vieussens from the gray substance of the cerebellum.

When cut into vertically, the cerebellum presents the appearance termed *arbor vitæ*. If the incision be made through the outer third of the organ, a gray body, surrounded by a yellow zigzag line of horny structure, will be seen in the centre of the white substance: this is the *corpus rhomboideum*, or ganglion of the cerebellum.

The cerebellum is associated with the spinal cord and cerebrum by three pairs of peduncles; the

Corpora restiformia,
Processus e cerebello ad testes,
Crura cerebelli.

The *Corpora restiformia*, or *inferior peduncles*, diverge at the upper extremity of the medulla oblongata, and enter the cerebellum, forming, by their divergence, part of the lateral boundaries of the fourth ventricle. Their fibres surround the corpus rhomboideum, and are expanded into the lamellæ of the cerebellum.

The *Processus e cerebello ad testes* are the *superior peduncles*: they ascend from the corpus rhomboideum, on each side, to the testis, and also form a part of the lateral boundaries of the fourth ventricle. The valve of Vieussens, by connecting the two processus e cerebello ad testes from side to side, and the cerebellum and testes from behind forwards, also contributes to the antero-posterior communication of the cerebellum.

The *Crura cerebelli* are the terminations of the transverse fibres of the pons Varolii, or great commissure of the cerebellum, which serves to establish a transverse communication between the lateral lobes.

BASE OF THE BRAIN.

The student should now prepare to study the base of the brain: for this purpose the organ should be turned upon its incised surface; and if the dissection have hitherto been conducted with care, he will find the base perfectly uninjured. The arachnoid membrane, some parts of the pia mater, and the circle of Willis, must be carefully cleared away in order to expose all the structures. These he will find arranged in the following order from before backwards:—

Longitudinal fissure,
Olfactory nerves,
Fissure of Sylvius,
Substantia perforata,

Commencement of the transverse fissure,
 Optic commissure,
 Tuber cinereum,
 Infundibulum,
 Corpora albicantia,
 Locus perforatus,
 Crura cerebri,
 Pons Varolii,
 Crura cerebelli,
 Medulla oblongata.

The *Longitudinal fissure* is the space separating the two hemispheres: it is continued downwards to the base of the brain, and divides the two anterior lobes. In this fissure the anterior cerebral arteries ascend towards the corpus callosum; and, if the two lobes be slightly drawn asunder, the anterior extremity of the corpus callosum will be seen descending to the base of the brain.

On each side of the longitudinal fissure, upon the under surface of each anterior lobe, is the *olfactory nerve*, with its bulb.

The *Fissure of Sylvius* bounds the anterior lobe posteriorly, and separates it from the middle lobe; it lodges the middle cerebral artery. If this fissure be followed outwards, a small isolated cluster of convolutions will be observed; these constitute the *island of Reil*.

The *Substantia perforata* is a triangular plane of white substance, situated at the inner extremity of the fissure of Sylvius. It is named *perforata*, from being pierced by a number of openings for small arteries, which enter the brain in this situation to supply the gray substance of the corpus striatum.

Passing backwards on each side beneath the edge of the middle lobe, is the commencement of the *great transverse fissure*, which extends beneath the hemisphere of one side to the same point on the opposite side.

The *Optic commissure* is situated on the middle line; it is the point of communication between the two optic nerves.

The *Tuber cinereum* is an eminence of gray substance immediately behind the optic commissure, and connected with its posterior border. It forms part of the floor of the third ventricle.

The *Infundibulum* is a tubular process of gray substance, opening from the centre of the tuber cinereum, and attached below to the *pituitary gland*, which is lodged in the sella turcica. This gland is retained within the sella turcica by the dura mater and arachnoid, and is with great difficulty removed with the brain. It is, therefore, better left in its place, where it is intended to study afterwards the base of the skull; for any attempt at removal would injure the cavernous sinuses. It consists of two lobes, but presents nothing glandular, either in structure or function.

The *Corpora albicantia* are two rounded white bodies, placed side by side, of about the size of peas; hence their synonyme *pisiformia*. They are the anterior extremities of the crura of the fornix, and are

connected with the thalami optici by two white cords, which may be easily traced.

The *Locus perforatus* is a layer of whitish gray substance, connected in front with the corpora albicantia, and on each side with the crura cerebri, between which it is situated. It is perforated by several thick tufts of arteries, which are distributed to the thalami optici and third ventricle, of which it assists in forming the floor. It is sometimes called the pons Tarini.

The *Crura cerebri* are two thick white cords which issue from beneath the pons Varolii, and diverge to each side to enter the thalami optici. The third nerve will be observed to arise from the inner side of each, and the fourth nerves wind around them from above. If the crus cerebri be cut across, it will be seen to present, in the centre of the section, the locus niger.

The *Pons Varolii** (protuberantia annularis) is the broad transverse band of white fibres, which arches like a bridge across the upper part of the medulla oblongata; and, contracting on each side into a thick rounded cord, enters the substance of the cerebellum under the name of crus cerebelli. There is a groove along its middle which lodges the basilar artery. The pons Varolii is the commissure of the cerebellum, and associates the two lateral lobes in their common function. Resting upon the pons, near its posterior border, is the sixth pair of nerves. On the anterior border of the crus cerebelli, at each side, is the thick bundle of filaments belonging to the fifth nerve, and, lying on its posterior border the seventh pair of nerves.

The *Medulla oblongata* is the upper enlarged portion of the spinal cord. Upon its anterior surface are seen two narrow projecting columns, the *corpora pyramidalia*. These bodies are broad above, and narrow below; and, at the point where they enter the pons Varolii, they become considerably constricted. They are connected to each other in the middle fissure, at about an inch below the pons, by a *decussation* of their fibres, which form small interlacing bands crossing from side to side.

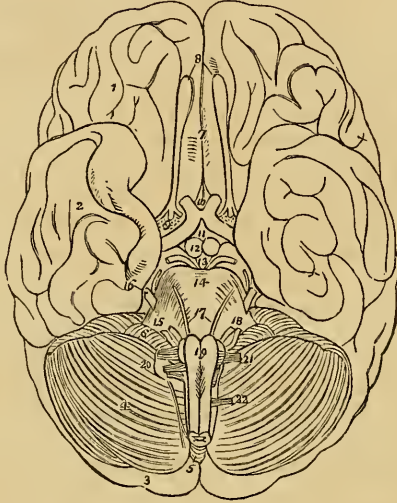
Externally to the corpora pyramidalia are two oblong and rounded bodies supposed to resemble olives in their form, and hence called *corpora olivaria*. If these bodies be divided by a longitudinal section, a gray zigzag outline, resembling the corpus rhomboideum of the cerebellum, will be seen in the interior of each. This is the ganglion of the corpus olivare.

Behind the corpus olivare is a narrow white band, which descends along the side of the medulla oblongata at the bottom of the lateral sulcus. This is the situation of the *respiratory tract* of Sir Charles Bell.

* Constant Varolius, Professor of Anatomy in Bologna; died in 1578. He dissected the brain in the course of its fibres, beginning from the medulla oblongata: a plan which has since been perfected by Vieussens, and by Gall and Spurzheim. The work containing his mode of dissection, "De Resolutione Corporis Humani," was published after his death, in 1591.

The *Corpora restiformia* (restis, a rope) are the remaining columns, of the medulla oblongata; they form its posterior segment, and diverge superiorly to enter the cerebellum. Between the two corpora restiformia posteriorly are two other white bands, which diverge at the point of the calamus scriptorius, and join the corpora restiformia: these are the *posterior median fasciculi* of the medulla oblongata.

Fig. 142.

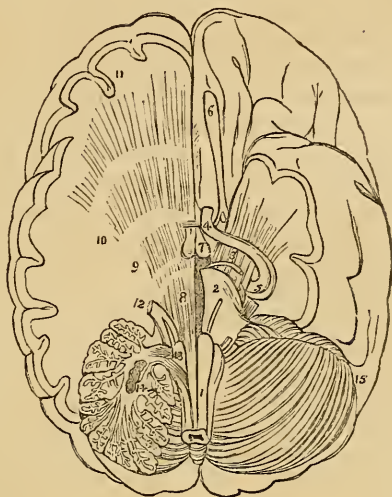


If a thin layer of the pons Varolii be carefully raised, or if a longitudinal incision be made across it, it may easily be seen that the corpus pyramidale passes through the pons into the crus cerebri. If the crus cerebri be traced forwards, it will be found to enter the thalamus opticus, and leaving it by the opposite border to plunge

Fig. 142. The under surface or base of the brain. 1. The anterior lobe of one hemisphere of the cerebrum. 2. The middle lobe. 3. The posterior lobe almost concealed by (4) the lateral lobe of the cerebellum. 5. The inferior vermiform process of the cerebellum. 6. The pneumogastric lobule. 7. The longitudinal fissure. 8. The olfactory nerves, with their bulbous expansions. 9. The substantia perforata at the inner termination of the fissure of Sylvius; the three roots of the olfactory nerve are seen upon the substantia perforata. The commencement of the transverse fissure on each side is concealed by the inner border of the middle lobe. 10. The commissure of the optic nerves. 11. The tuberculum cinereum, from which the infundibulum is seen projecting. 12. The corpora albicantia. 13. The locus perforatus bounded on each side by the crura cerebri, and by the third nerve. 14. The pons Varolii. 15. The crus cerebelli of one side. 16. The fifth nerve emerging from the anterior border of the crus cerebelli; the small nerve by its side is the fourth. 17. The sixth pair of nerves. 18. The seventh pair of nerves consisting of the auditory and facial. 19. The corpora pyramidalia of the medulla oblongata; the corpus olivare and part of the corpus restiforme are seen at each side. Just below the number is the decussation of the fibres of the corpora pyramidalia. 20. The eighth pair of nerves. 21. The ninth or hypoglossal nerve. 22. The anterior root of the first cervical spinal nerve.

into the corpus striatum, and pass from thence onwards to the convolutions of the hemispheres.

Fig. 143.



From pursuing this remarkable course, and spreading out as they advance, these fibres have been called by Gall the *diverging fibres*. While situated within the pons it is found that the fibres of the *corpus pyramidale* separate and spread out, and have gray substance interposed between them; and that they quit the pons much increased in number and bulk, so as to form the *crus cerebri*. The fibres of the *crus cerebri* again are separated in the thalamus opticus, and are intermingled with gray matter, and they also quit that body greatly increased in number and bulk. Precisely the same change takes place in the corpus striatum, and the fibres are now so extraordinarily multiplied as to be capable of forming a

Fig. 143. The base of the brain, upon which several sections have been made, showing the distribution of the diverging fibres. 1. The medulla oblongata. 2. One half of the pons Varolii. 3. The crus cerebri crossed by the optic nerve (4) and spreading out into the substance of the middle lobe. 5. The two roots of the optic nerve; the nerves about the crus cerebri and cerebelli are the same as in the preceding figure. 6. The olfactory nerve. 7. The corpora albicantia. On the right side a portion of the brain has been removed to show the distribution of the diverging fibres. 8. The fibres of the corpus pyramidale passing through the substance of the pons Varolii. 9. The fibres passing through the thalamus opticus. 10. The fibres passing through the corpus striatum. 11. Their distribution to the hemispheres. 12. The fifth nerve; its two roots may be traced, the one forwards to the fibres of the corpus pyramidale, the other backwards to the corpus restiforme. 13. The fibres of the corpus pyramidale which pass outwards with the corpus restiforme into the substance of the cerebellum; these are the arciform fibres of Solly. The number rests upon the upper part of the corpus olivare; the rest of that body having been cut away, the arciform fibres are below the number. 14. A section through one of the lateral lobes of the cerebellum, showing the corpus rhomboideum in the centre of its white substance; the arbor vite is also beautifully seen. 15. The opposite lobe of the cerebellum.

large proportion of the hemispheres, viz., the whole of the lower part of the anterior and middle lobes.

From observing this remarkable increase in the white fibres, apparently from the admixture of gray substance, Gall and Spurzheim considered the latter as the material increase of formative substance to the white fibres, and they are borne out in this conclusion by several collateral facts, among the most prominent of which is the great vascularity of the gray substance; and the larger proportion of the nutrient fluid circulating through it, is fully capable of affecting the increased growth and nutrition of the structures by which it is surrounded. For a like reason the bodies in which this gray substance occurs, are called by the same physiologists "*ganglia of increase*," and by other authors simply ganglia. Thus the thalami optici and corpora striata are the ganglia of the cerebrum; or, in other words, the *formative ganglia* of the hemispheres.

Mr. Solly, in a recent work upon "the human brain," has designated the diverging fibres of the corpus pyramidale that pursue the course above described, "*the cerebral fibres*;" to distinguish them from another set of fibres discovered by that gentleman, which also proceed from the corpus pyramidale, and pass outward beneath the corpus olivare to the cerebellum. These he names the "*arciform fibres*," and divides them into two layers, the *superficial cerebellar* and *deep cerebellar fibres*. They join the corpus restiforme, forming one-fourth of its whole diameter, and spread out in the structure of the cerebellum.

The *Copora olivaria* owe their convex olive-shaped form to a "ganglion of increase" (the anterior ganglia of the medulla oblongata of Solly), situated in the interior of each.

The white fibres surrounding these ganglia form a fasciculus at each side, which is continued into the pons Varolii along with the corpora pyramidalia. Here its fibres are mixed with gray matter, and pass into the crus cerebri, forming its superior and inner segment. From the crus cerebri they traverse successively the thalamus opticus and corpus striatum, and become developed into the convolutions of the upper part of the hemispheres and posterior lobe.

The *Corpora restiformia* diverge as they approach the cerebellum, and leaving between them the cavity of the fourth ventricle enter the substance of the cerebellum, under the form of two rounded cords. These cords envelope the corpora rhomboidea, or ganglia of increase, and then expand on all sides so as to constitute the cerebellum.

In addition to the diverging fibres which are thus shown to constitute both the cerebrum and cerebellum, by their increase and development, another set of fibres are found to exist, which have for their office the association of the symmetrical halves, and distant parts of the same hemispheres.

These are called from their direction *converging fibres*, and from their office *commissures*. The commissures of the cerebrum and cerebellum are the—

Corpus callosum,
 Fornix,
 Septum lucidum,
 Anterior commissure,
 Middle commissure,
 Posterior commissure,
 Peduncles of the pineal gland,
 Processus e cerebello ad testes,
 Valve of Vieussens,
 Pons Varolii.

The *Corpus callosum* is the commissure of the hemispheres. It is therefore of moderate thickness in the middle, where its fibres pass directly from one hemisphere to the other; thicker in front, where the anterior lobes are connected; and thickest behind, where the fibres from the posterior lobes are assembled.

The *Fornix* is an antero-posterior commissure, and serves to connect a number of parts. Below, it is associated with the thalami optici; on each side, by means of the corpora fimbriata, with the middle lobes of the brain; and, above, with the corpus callosum, and consequently with the hemispheres.

The *Septum lucidum* is a perpendicular commissure between the fornix and corpus callosum.

The *Anterior commissure* traverses the corpus striatum, and connects the anterior and middle lobes of opposite hemispheres.

The *Middle commissure* is a layer of gray substance, uniting the thalami optici.

The *Posterior commissure* is a white flattened cord, connecting the thalami optici.

The *Peduncles of the pineal gland* must also be regarded as commissures, assisted in their function by the gray substance of the gland.

The *Processus e cerebello ad testes* are the means of communication between the white substance of the cerebellum and cerebrum; and the linguetta laminosa and valve of Vieussens perform the same office to the gray substance.

The *Pons Varolii* is the commissure to the two lobes of the cerebellum. It consists of transverse fibres, which are split into two layers by the passage of the fasciculi of the corpora pyramidalia and olivaria. These two layers, the superior and inferior, are collected together on each side, in the formation of the crura cerebelli.

SPINAL CORD.

The dissection of the spinal cord requires that the spinal column should be opened throughout its entire length by sawing through the laminæ of the vertebræ, close to the roots of the transverse processes, and raising the arches with a chisel, after the muscles of the back have been removed.

The *Spinal column* contains the *spinal cord*, or medulla spinalis;

the roots of the *spinal nerves*; and the membranes of the cord, viz., *dura mater*, *arachnoid*, *pia mater*, and *membrana dentata*.

The *Dura mater* (*theca vertebralis*) is continuous with the *dura mater* of the skull: it is closely attached around the border of the occipital foramen, particularly in front, where it is connected with the posterior common ligament. In the vertebral canal it is connected only by loose cellular tissue, containing an oily fluid, somewhat analogous to the marrow of long bones. On either side and below, it forms a sheath, for each of the spinal nerves, to which it is closely adherent. Upon its inner surface it is smooth, being lined by the *arachnoid*; and on the sides may be seen the double openings for the two roots of each of the spinal nerves.

The *Arachnoid* is a continuation of the serous membrane of the brain. It encloses the cord very loosely, being connected to it only by long slender cellular filaments, and by a longitudinal lamella which is attached to the posterior aspect of the cord. It passes off on either side with the spinal nerves, to which it forms a sheath; and is then reflected upon the *dura mater*, to constitute its serous surface. A connexion exists in several situations between the *arachnoid* of the cord and that of the *dura mater*.

The space between the *arachnoid* and the spinal cord is identical with that already described as existing between the same parts in the brain, the *subarachnoidean space*. It is occupied in both by a serous fluid, sufficient in quantity to expand the *arachnoid*, and fill completely the cavity of the *theca vertebralis*. The *subarachnoidean fluid* keeps up a constant and gentle pressure upon the entire surface of the brain and spinal cord, and yields with the greatest facility to the various movements of the cord, giving to those delicate structures the advantage of the principles so usefully applied by Dr. Arnott in the hydrostatic bed. According to Magendie this fluid communicates with the secretion contained in the lateral ventricles, by means of an opening which exists in the fibrous layer of the inferior boundary of the fourth ventricle.

The *Pia mater* is the immediate investment of the cord; and, like the other membranes, is continuous with that of the brain. It is not, however, like the *pia mater cerebri*, a vascular membrane; but is dense and fibrous in its structure, and contains very few vessels. It invests the cord closely, and sends a duplicate into the *sulcus longitudinalis anterior*, and another, extremely delicate, into the *sulcus longitudinalis posterior*. It forms a sheath for each of the filaments of the nerves, and for the nerves themselves; and, inferiorly, at the conical termination of the cord, is prolonged downwards as a slender ligament, which descends through the centre of the *cauda equina*, and is attached to the *dura mater* lining the canal of the *coccyx*. This attachment is a rudiment of the original extension of the spinal cord into the canal of the *sacrum* and *coccyx*.

The *Membrana dentata* is a process of the *pia mater* sent off from each side of the cord throughout its entire length, and separating the anterior from the posterior roots of the spinal nerves. Between

each of the nerves it forms a serration, which is attached to the dura mater, and unites the two layers of the arachnoid membrane at that point. The processes are about twenty in number at each side. Their use is to maintain the position of the spinal cord in the midst of the fluid by which it is surrounded.

The *Spinal cord* of the adult extends from the pons Varolii to opposite the first or second lumbar vertebra, where it terminates in a rounded point; in the child, at birth, it reaches to the middle of the third lumbar vertebra, and in the embryo is prolonged as far as the coccyx. It presents a difference of diameter in different parts of its extent, and exhibits three enlargements. The uppermost of these is the *medulla oblongata*; the next corresponds with the origin of the nerves destined to the upper extremities; and the lower enlargement is situated near to its termination, and corresponds with the attachment of the nerves which are intended for the supply of the lower limbs.

In form, the spinal cord is a flattened cylinder, and presents on its anterior surface a groove, which extends into the cord to the depth of one third of its diameter. This is the *sulcus longitudinalis anterior*. If the sides of the groove be gently separated, they will be seen to be connected at the bottom by a layer of medullary substance, the anterior commissure.

On the posterior surface another fissure exists, which is so narrow as to be hardly perceptible without careful examination. This is the *sulcus longitudinalis posterior*. It extends much more deeply into the cord than the anterior sulcus, and terminates in the gray substance of the interior. These two fissures divide the medulla spinalis into two lateral cords, which are connected to each other merely by the white commissure which forms the bottom of the anterior longitudinal sulcus.

On either side of the *sulcus longitudinalis posterior* is a slight line, which bounds on each side the posterior median columns. These columns are most apparent at the upper part of the cord, near to the fourth ventricle, where they are separated by the point of the calamus scriptorius, and where they form a bulbous enlargement at each side, called the *processus clavatus*.

Two other lines are observed on the medulla, the anterior and posterior lateral sulci, corresponding with the attachment of the anterior and posterior roots of the spinal nerves. The *anterior lateral sulcus* is a mere trace, marked only by the attachment of the filaments of the anterior roots. The *posterior lateral sulcus* is more evident, and is formed by a narrow grayish fasciculus derived from the gray substance of the interior.

These sulci divide the medulla into four fasciculi or cords, viz.—

Anterior columns,
Lateral columns,
Posterior columns,
Median posterior columns.

The *Anterior* are the *motor columns*, and give origin to the motor roots of the spinal nerves. They are continued upward into the medulla oblongata, under the form of *corpora pyramidalia*.

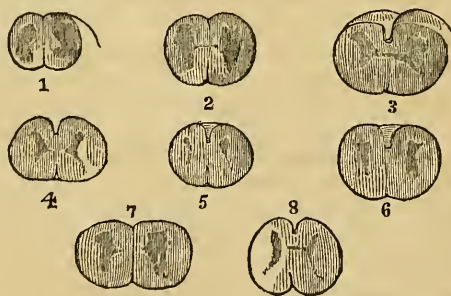
The *Lateral columns* are divided in their function between motion and sensation, and contain the fasciculus described by Sir Charles Bell as the respiratory tract. Some anatomists consider the anterior and lateral column on each side as a single column, under the name of *antero-lateral*.

The *Posterior* are the *columns of sensation*, and give origin to the sensitive roots of the spinal nerves. Their superior terminations are named *corpora restiformia*.

The *Median posterior columns* have no function at present assigned to them.

If a transverse section of the spinal cord be made, its internal structure may be seen and examined. It would then appear to be composed of two hollow cylinders of white matter, placed side by side, and connected by a narrow white commissure. Each cylinder is filled with gray substance, which is connected by a commissure of the same matter. The form of the gray substance, as observed in the section, is that of two half moons placed back to back, and joined by a transverse band. The horns of the moons correspond to the sulci of origin of the anterior and posterior roots of the nerves. The anterior horns do not quite reach this surface; but the posterior appear upon the surface, and form a narrow gray line.

Fig. 144.



The white substance of the spinal cord is composed of parallel fibres, which are collected into longitudinal laminæ and extend throughout the entire length of the cord. These laminæ are various in breadth, and are arranged in a radiated manner; one border being

Fig. 144. Sections of the spinal marrow in different portions of its length. 1. Opposite the 11th dorsal vertebra. 2. Opposite the 10th dorsal. 3. Opposite the 8th dorsal. 4. Opposite the 5th dorsal. 5. Opposite the 7th cervical. 6. Opposite the 4th cervical. 7. Opposite the 3d cervical. 8. Section of medulla oblongata through the *corpora olivaria*.

thick and corresponding with the surface of the cord, while the other is thin and lies in contact with the gray substance of the interior. According to Rolando the white substance constitutes a simple nervous membrane which is folded into longitudinal plaits, having the radiated disposition above described. The anterior commissure, according to his description, is merely the continuation of this nervous membrane from one lateral cord across the middle line to the other. Moreover, Rolando considers that a thin lamina of pia mater is received between each of the folds from the exterior, while a layer of the gray substance is prolonged between them from within. Cruveilhier is of opinion that each lamella is completely independent of its neighbours, and he believes this statement to be confirmed by pathology, which shows that a single lamella may be injured or atrophied, and at the same time be surrounded by others perfectly sound.

CRANIAL NERVES.

There are *nine pairs* of cranial nerves. Taken in their order from before, backwards, they are—

- 1st. Olfactory.
- 2d. Optic.
- 3d. Motores oculorum.
- 4th. Pathetici (trochleares).
- 5th. Trifacial (trigemini).
- 6th. Abducentes.
- 7th. { Facial (portio dura),
Auditory (portio mollis),
- 8th. { Glosso-pharyngeal,
Pneumogastric (vagus, par vagum).
Spinal accessory.
- 9th. Hypoglossal (lingual).

Functionally or physiologically they are divided into four groups, and in this order we shall examine them.

Nerves of

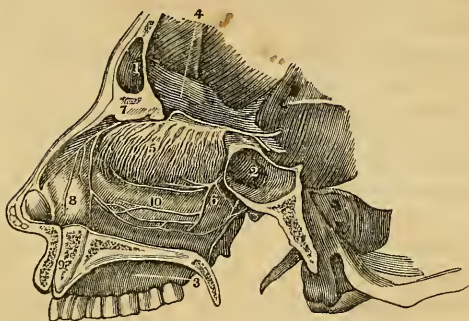
- | | | |
|--|------|--|
| 1. <i>Special sense</i> | { | 1st. Olfactory,
2d. Optic,
7th. Auditory. |
| 2. <i>Motion</i> | { | 3d. Motores oculorum,
6th. Abducentes,
9th. Hypoglossal. |
| 3. <i>Respiration (Bell)</i> | { | 4th. Patheticus,
7th. Facial,
8th. Glosso-pharyngeal.
Pneumogastric,
Spinal accessory. |
| 4. <i>Spinal</i> | 5th. | Trifacial. |

NERVES OF SPECIAL SENSE.

1st pair, OLFACTORY.—This nerve rests against the under surface of the anterior lobe of the brain, being lodged in the narrow interval between two convolutions, and retained in its place by the arachnoid membrane.

It arises by three roots, 1. *Internal*, from the substantia perforata. 2. *Middle*, from a papilla of gray matter embedded in the anterior

Fig. 145.



lobe. 3. *External*, from a long fasciculus which is traced for a considerable distance along the fissure of Sylvius, into the middle lobe. The union of these roots forms a grayish white nerve, prismoid in form and soft in structure, which expands into a *bulb* (*bulbus olfactorius*), and rests upon the cribriform plate. Its branches

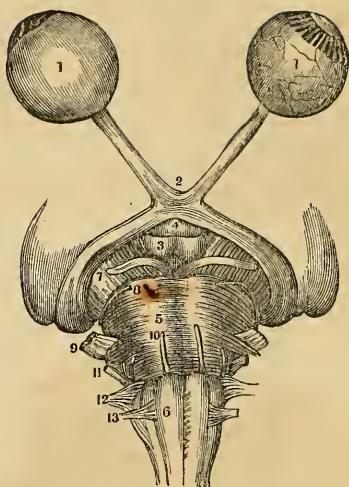
are transmitted through the numerous foramina in the cribriform plate, to be distributed to the mucous membrane of the nose. The innermost are reddish in colour and soft, and spread out upon the septum narium; the external branches are whiter and more firm, they pass through bony canals in the outer wall of the nose, and communicate freely with each other previously to their distribution in the mucous membrane of the superior and middle turbinated bones.

2d pair, OPTIC.—The optic nerve arises by two roots; *one* from the *corpus geniculatum externum*, the *other* from the anterior pair (nates) of the *corpora quadrigemina* or *optic lobes*. It winds around the crus cerebri as a flattened band, and unites with its fellow of the opposite side, to form the *commissure*. The two nerves then diverge from each other, to enter the orbit through the optic foramen, pierce the sclerotic and choroid coat of the eyeball, and expand in the retina. The optic commissure rests upon the processus olivaris of the sphenoid bone, and its posterior border is closely connected with the tuber cinereum, from which it receives fibres;

Fig. 145. A view of the 1st pair or olfactory, with the nasal branches of the 5th. 1. Frontal sinus. 2. Sphenoidal sinus. 3. Hard palate. 4. Bulb of the olfactory nerve. 5. Branches of the olfactory on the superior and middle turbinated bones. 6. Spheno-palatine nerves from the 2d of the 5th. 7. Internal nasal nerve from the 1st of the 5th. 8. Branches of 7, to Schneiderian membrane. 9. Ganglion of Cloquet in the *foramen incisivum*. 10. Anastomosis on the inferior turbinated bone of the branches of the 5th pair.

in its interior the innermost fibres of the two nerves cross each other, while the external proceed directly onwards in their course. On entering the orbit the nerve obtains a firm sheath from the dura mater, which is continuous with the sclerotic coat of the eyeball. This sheath is formed by the splitting of the dura mater at the foramen opticum into two layers, the one surrounding the optic nerve, while the other is continuous with the periosteum of the orbit. Near to the globe of the eyeball the optic nerve is pierced by the *arteria centralis retinæ*, which runs forwards in the centre of the nerve, and reaching the retina distributes branches upon its internal surface, forming its vascular layer.

Fig. 146.



7th pair, AUDITORY (*portio mollis*).—This nerve arises from the anterior wall or floor of the fourth ventricle, by means of the white fibres, *lineæ transversæ*, of the *calamus scriptorius*. It winds around the *corpus restiforme*, from which it receives fibres, and emerges upon the posterior border of the *crus cerebelli* ; it then enters the *meatus auditorius internus*, together with the facial nerve, which lies in a groove on its superior and anterior surface, and at the bottom of the *meatus* divides into two

Fig. 147.

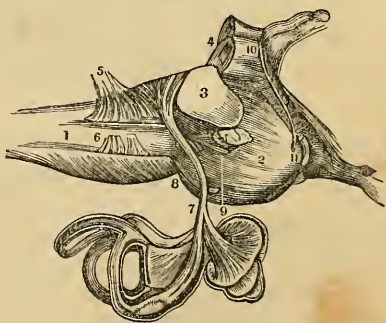


Fig. 146. A view of the 2d pair or optic, and the origins of seven other pairs. 1, 1. Globe of the eye, the one on the left hand is perfect, but that on the right has the sclerotic and choroid removed to show the retina. 2. The chiasm of the optic nerves. 3. The *corpora albicantia*. 4. The *infundibulum*. 5. The *pons Varolii*. 6. The *medulla oblongata*. The figure is on the right *corpus pyramidale*. 7. The 3d pair, *motores oculi*. 8. 4th pair, *pathetici*. 9. 5th pair, *trigemini*. 10. 6th pair, *abducentes*. 11. 7th pair, auditory and facial. 12. 8th pair, pneumogastric, spinal accessory, and glosso-pharyngeal. 13. 9th pair, hypoglossal.

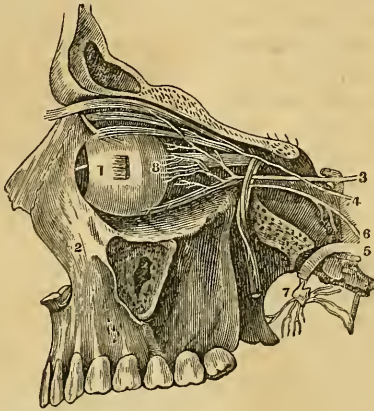
Fig. 147. A view of the origin and distribution of the *portio mollis* of the 7th pair or auditory nerve. 1. The *medulla oblongata*. 2. The *pons Varolii*. 3, and 4. The *crura cerebelli* of the right side. 5. 8th pair. 6. 9th pair. 7. The auditory nerve distributed to the cochlea and labyrinth. 8. The 6th pair. 9. The *portio dura* of the 7th pair. 10. The 4th pair. 11. The 3d pair.

branches, *cochlear* and *vestibular*, which are distributed to the internal ear. It is soft and pulpy in texture, and whilst situated in the meatus auditorius sends several filaments to the facial nerve.

NERVES OF MOTION.

We have already seen that the corpora pyramidalia are the continuations upwards of the anterior columns of the spinal cord, or motor tract, and that these fasciculi are prolonged onwards through the pons Varolii and crura cerebri into the ganglia of the hemispheres. Now, the three motor nerves arise from the cerebral portion of the motor tract at different points of its course.

Fig. 148.



3d pair, **MOTORES OCULORUM.**—The motor oculi nerve arises from the inner side of the crus cerebri, near to the pons Varolii, and passes forward between the posterior cerebral and superior cerebellar artery. It pierces the dura mater immediately in front of the posterior clinoid process; descends obliquely along the external wall of the cavernous sinus; and divides into two branches, which enter the orbit between the two heads of the external rectus muscle. The *superior* branch ascends, and supplies the superior rectus and levator palpebræ. The *inferior* sends a branch beneath the optic nerve to the internal rectus, another to the inferior rectus, and a long branch to the inferior oblique muscle. From the latter a short

Fig. 148. A view of the 3d, 4th, and 6th pairs of nerves. 1. Ball of the eye, the rectus externus muscle being cut and hanging down from its origin. 2. The superior maxilla. 3. The 3d pair or *motor oculi* distributed to all the muscles of the eye except the superior oblique and external rectus. 4. The 4th pair or *patheticus* going to the superior oblique muscle. 5. One of the branches of the 5th. 6. The 6th pair or *motor externus* distributed to the external rectus muscle. 7. Spheno-palatine ganglion and branches. 8. Ciliary nerves from the lenticular ganglion, the short root of which is seen to connect it with the 3d pair.

thick branch is given off to the ciliary ganglion, forming its inferior root.

The fibres of origin of this nerve may be traced into the gray substance of the crus cerebri,* into the motor tract† and as far as the superior fibres of the crus cerebri.‡ In the cavernous sinus it receives one or two filaments from the cavernous plexus, and one from the ophthalmic nerve.

6th pair, ABDUCENTES.—The abducens nerve arises from the upper part of the *corpus pyramidale*, close to the pons Varolii, several of its filaments of origin passing between the fasciculi of the pons. It pierces the dura mater upon the basilar process of the sphenoid bone, and ascends to the cavernous sinus. It then runs forward along the inner wall of the sinus, below the other nerves; and, resting against the internal carotid artery, passes beneath the two heads of the external rectus, and is distributed to that muscle. As it enters the orbit it lies upon the ophthalmic vein, from which it is separated by a lamina of dura mater. In the cavernous sinus it is joined by two filaments from the carotid plexus, and by one from the ophthalmic nerve. Mr. Mayo has traced the origin of this nerve between the fasciculi of the corpora pyramidalia to the posterior part of the medulla oblon-

Fig. 149.

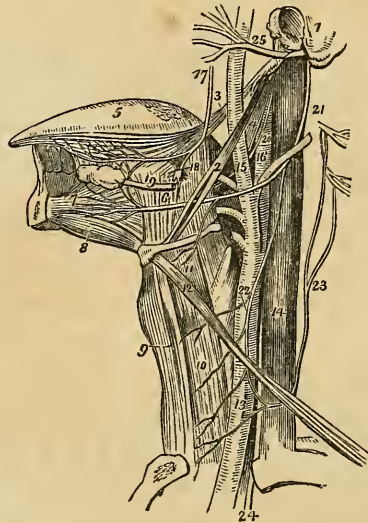


Fig. 149. The anatomy of the side of the neck, showing the nerves of the tongue. 1. A fragment of the temporal bone containing the meatus auditorius externus, mastoid, and styloid process. 2. The stylo-hyoid muscle. 3. The stylo-glossus. 4. The stylo-pharyngeus. 5. The tongue. 6. The hyo-glossus muscle; its two portions. 7. The genio-hyo-glossus muscle. 8. The genio-hyoideus; they both arise from the inner surface of the symphysis of the lower jaw. 9. The sterno-hyoid muscle. 10. The sterno-thyroid. 11. The thyro-hyoid, upon which the hyoid branch of the lingual nerve is seen ramifying. 12. The omohyoid crossing the common carotid artery (13), and internal jugular vein (14). 15. The external carotid giving off its branches. 16. The internal carotid. 17. The gustatory nerve giving off a branch to the submaxillary ganglion (18), and communicating a little further on with the hypoglossal nerve. 19. The submaxillary, or Wharton's duct, passing forwards to the sublingual gland. 20. The glosso-pharyngeal nerve. 21. The hypoglossal nerve curving around the occipital artery. 22. The descendens noni nerve, forming a loop with (23) the communicans noni, which is seen to be arising by filaments from the upper cervical nerves. 24. The pneumogastric nerve, emerging from between the internal jugular vein and common carotid artery, and entering the chest. 25. The facial nerve, emerging from the stylo-mastoid foramen, and crossing the external carotid artery.

* Mayo.

† Sully.

‡ Grainger.

gata; and Mr. Grainger has pointed out its connexion with the gray substance of the spinal cord.

9th pair, HYPGLOSSAL (lingual). The ninth nerve, the true motor nerve of the tongue, arises by eight or ten filaments from the side of the corpus pyramidale of the medulla oblongata. These filaments are disposed in two fasciculi which unite into a single nerve at the posterior condyloid foramen. The lingual nerve then passes forward between the internal carotid artery and internal jugular vein, and descends along the anterior and inner side of the vein to a point parallel with the angle of the lower jaw. It next curves inwards around the occipital artery, with which it forms a loop, and crosses the lower part of the hyo-glossus muscle to the genio-hyo-glossus, in which it terminates by sending filaments onwards with the anterior fibres of this muscle as far as the tip of the tongue. It is distributed to the muscles of the tongue, and principally to the genio-hyo-glossus. While resting on the hyo-glossus muscle it has a flattened appearance, and communicates beneath the mylo-hyoideus of the gustatory nerve.

The *Branches* of the hypoglossal nerve are:

Communicating branches with the Pneumogastric,
Spinal accessory,
First and second cervical
nerves,
Sympathetic.

Descendens noni,
Hyoidean branch,

Communicating filaments with the gustatory nerve.

The *Communications* with the pneumogastric and spinal accessory take place through the medium of a plexiform interlacement of branches at the base of the skull, behind the internal jugular vein. The communications with the sympathetic nerve are derived from the superior cervical ganglion.

The *Descendens noni* is a long slender twig, which quits the hypoglossal just as that nerve is about to form its arch around the occipital artery, and descends upon the sheath of the carotid vessels. Just below the middle of the neck it forms a loop with a long branch (*communicans noni*) from the second and third cervical nerves. From the convexity of this loop branches are sent to the depressor muscles of the larynx. If the descendens noni be traced to its connexion with the hypoglossal nerve, and examined with care, it will be found to be formed by two filaments, one from the lingual, the other, of larger size, from the first and second cervical nerves.

The *Hyoidean branch* is a small twig distributed to the insertions of the depressor muscles of the larynx, particularly to the thyrohyoid.

The *Communicating filaments* with the gustatory nerve are two or three small branches which ascend upon the anterior part of the

hyo-glossus muscle, and join corresponding branches sent downwards by the gustatory.

RESPIRATORY NERVES.

Under this head are grouped, by Sir Charles Bell, certain nerves which are associated in the movements of respiration. They all arise in the course of a distinct tract, situated between the corpus olivare and corpus restiforme on each side of the medulla oblongata, and which may be traced upwards to the corpora quadrigemina; hence this portion of the brain has been named the respiratory tract.

4th pair, PATHETICI (trochlearis).—The fourth is the smallest cerebral nerve; it arises from the valve of Vieussens and testis, and winds around the crus cerebri to the extremity of the petrous portion of the temporal bone, where it pierces the dura mater near to the oval opening for the fifth nerve, and passes along the outer wall of the cavernous sinus to the sphenoidal fissure. In its course through the sinus it is situated at first below the motor oculi, but afterwards ascends and becomes the highest of the nerves which enter the orbit through the sphenoidal fissure.

After reaching the orbit it crosses the levator palpebræ muscle near to its origin, and is distributed upon the orbital surface of the superior oblique or trochlearis muscle; hence its synonyme *trochlearis*.

Branches.—While in the cavernous sinus the fourth nerve gives off a recurrent branch; some filaments of communication to the ophthalmic nerve; and a branch to assist in forming the lachrymal nerve. The *recurrent branch* passes backwards between the layers of the tentorium and divides into two or three filaments, which are distributed to the lining membrane of the lateral sinus. In a preparation before me this branch is very distinct; but I have not always succeeded in finding it.

7th pair, FACIAL (*portio dura*.) The *Facial nerve* arises from the respiratory tract, at the upper part of the medulla oblongata close to the lower border of the pons Varolii, from which point its fibres may be traced deeply into the corpus restiforme. It enters the meatus auditorius internus in front of and superiorly to the auditory nerve (*portio mollis*), and at the bottom of the meatus passes into the canal which is expressly intended for it, the aqueductus Fallopii. In this canal it directs its course at first forwards towards the hiatus Fallopii, where it forms a gangliform swelling, and receives the petrosal branch of the Vidian nerve. It then curves backwards towards the tympanum, and descends along its inner wall to the stylo-mastoid foramen. Emerging at the stylo-mastoid foramen it passes forwards within the parotid gland, and crosses the external jugular vein and external carotid artery to the ramus of the jaw. While situated within the gland it is joined by a branch from the auricular nerve, and divides into two trunks—the *temporo-facial*

and *cervico-facial*—which communicate with each other and give off the numerous branches which constitute the *pes anserinus*, and are distributed over the whole of the side of the face, supplying the muscles.

The *Branches* of the *facial nerve* are—

<i>Within the aqueductus Fallopii,</i>	{ Tympanic, (Chorda tympani).*
<i>After emerging at the stylo-mastoid foramen,</i>	{ Communicating, Posterior auricular, Digastric, Stylo-hyoid.
<i>On the face,</i>	{ Temporo-facial, Cervico-facial.†

The *Tympanic* branches are two small filaments, which are distributed to the stapedius and tensor tympani muscle.

The *Chorda tympani* quits the facial just before that nerve emerges from the stylo-mastoid foramen. Entering the tympanum at its posterior and superior angle; it crosses its cavity between the handle of the malleus and long process of the incus, to its anterior inferior angle. It then escapes through a distinct opening in the fissura Glaseri, and joins the gustatory nerve at an acute angle between the two pterygoid muscles. Enclosed in the sheath of the gustatory nerve, it descends to the submaxillary gland, where it unites with the submaxillary ganglion.

The *Communicating branches* are filaments which it receives from the glosso-pharyngeal and pneumogastric nerves.

The *Posterior auricular* nerve ascends behind the ear, and crosses the mastoid process to the occipito-frontalis muscle; it gives branches also to the attollens and retrahens muscles of the pinna.

The *Digastric* branch supplies the posterior belly of the digastricus muscle.

The *Stylo-hyoid* branch is distributed to the stylo-hyoid muscle.

The *Temporo-facial* gives off a number of branches which are distributed over the temple and upper half of the face, supplying the muscles of this region, and communicating with the branches of the auricular, the temporo-malar, and the supra-orbital nerve. The inferior branches, which accompany Stenon's duct, form a plexus with the terminal branches of the infra-orbital nerve.

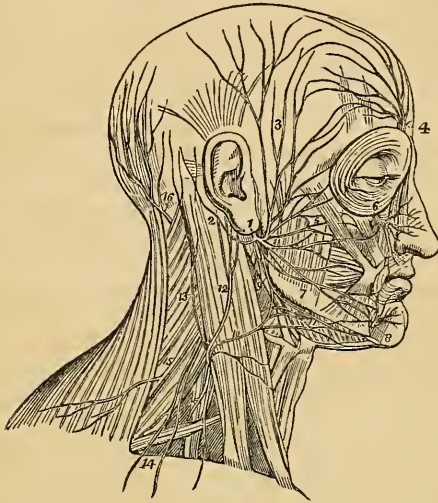
The *Cervico-facial* divides into a number of branches that are distributed to the muscles on the lower half of the face, and upper

* The chorda tympani is not considered as a branch of the facial; but being in close connexion with it, and being given off from it like a branch, I have inserted it here lest it should be overlooked.

† A third series of branches is usually described, which are included by Wilson in his temporo-facial branches. They are called buccal, from supplying the neighbourhood of the buccinator muscle.—G.

part of the neck. The cervical branches form a plexus with the superficialis colli nerve over the submaxillary gland.

Fig. 150.



The facial nerve has been named *sympatheticus minor*, on account of the number of communications which it maintains with other nerves. These will be best seen in a tabular arrangement:

In the petrous bone it communicates with { Auditory nerve,
Petrosal branch of Vidian,
Otic ganglion.

At its exit from the stylo-mastoid foramen, with { Glosso-pharyngeal,
Pneumogastric.

Fig. 150. The distribution of the facial nerve and the branches of the cervical plexus. 1. The facial nerve, escaping from the stylo-mastoid foramen, and crossing the ramus of the lower jaw; the parotid gland has been removed in order to see the nerve more distinctly. 2. The posterior auricular branch; the digastric and stylo-mastoid filaments are seen near the origin of this branch. 3. Temporal branches, communicating with (4) the branches of the frontal nerve. 5. Facial branches, communicating with (6) the infra-orbital nerve. 7. Facial branches, communicating with (8) the mental nerve. 9. Cervico-facial branches communicating with (10) the superficialis colli nerve, and forming a plexus (11) over the submaxillary gland. The distribution of the branches of the facial in a radiated direction over the side of the face constitutes the pes anserinus. 12. The auricularis magnus nerve, one of the ascending branches of the cervical plexus. 13. The occipitalis minor, ascending along the posterior border of the sterno-mastoid muscle. 14. The superficial and deep descending branches of the cervical plexus. 15. The spinal accessory nerve, giving off a branch to the external surface of the trapezius muscle. 16. The occipitalis major nerve, the posterior branch of the second cervical nerve.

In the parotid gland, with	}	Anterior auricular, Auricularis magnus, Occipitalis minor.
On the face and neck, with	}	Supra-orbital, Intra-orbital, Temporo-malar, Buccal, Mental, Superficialis colli.

8th pair.—This pair consists of three nerves, the *glosso-pharyngeal*, *pneumogastric*, and *spinal accessory*.

The GLOSSO-PHARYNGEAL NERVE arises by several filaments from the respiratory tract, between the corpus olivare and restiforme, and escapes from the skull at the innermost extremity of the jugular foramen through a distinct opening in the dura mater, lying anteriorly to the sheath of the pneumogastric and spinal accessory nerves, and internally to the jugular vein. It then passes forwards between the jugular vein and internal carotid artery to the stylo-pharyngeus muscle, and descends along its inferior border to the hyo-glossus, beneath which it passes to be distributed to the mucous membrane of the base of the tongue and fauces, to the mucous glands of the mouth, and to the tonsils. While situated in the jugular fossa, the nerve presents two gangliform swellings, one *superior* (ganglion jugulare of Müller) of small size, and involving only the posterior fibres of the nerve, the other *inferior*, nearly half an inch below the preceding, of larger size and occupying the whole diameter of the nerve, the ganglion of Andersch* (ganglion petrosum).

The fibres of origin of this nerve may be traced through the fasciculi of the corpus restiforme to the gray substance in the floor of the fourth ventricle.

The *Branches* of the glosso-pharyngeal nerve are—

Communicating branches with the Facial,
Pneumogastric,
Spinal accessory,
Sympathetic.

Tympanic,
Muscular,
Pharyngeal,
Lingual,
Tonsillitic.

The *Branches of communication* proceed from the ganglion and from the upper part of the trunk of the nerve, and are common to

* Charles Samuel Andersch. "Tractatus Anatomico-Physiologicus de Nervis Corporis Humani Aliquibus, 1797."

the facial, eighth pair, and sympathetic; they form a complicated plexus at the base of the skull.

The *Tympanic* branch (Jacobson's nerve) enters a small bony canal in the petrous portion of the temporal bone, and divides into six branches, which are distributed upon the inner wall of the tympanum, and establish important communications with the sympathetic and fifth pair of nerves. The *branches* of distribution supply the fenestra rotunda, fenestra ovalis, and Eustachian tube: those of communication join the carotid plexus, the petrosal branch of the Vidian nerve, and the otic ganglion.

The *Muscular* branch divides into filaments, which are distributed to the stylo-pharyngeus and to the posterior belly of the digastricus and stylo-hyoideus muscle.

The *Pharyngeal* branches are two or three filaments which are distributed to the pharynx and unite with the pharyngeal branches of the pneumogastric and of the sympathetic nerve to form the pharyngeal plexus.

The *Lingual* branches enter the substance of the tongue beneath the hyo-glossus and stylo-glossus muscle, and are distributed to the mucous membrane of the side and base of the tongue, and to the fauces.

The *Tonsillitic* branches proceed from the glosso-pharyngeal nerve near to its termination; they form a plexus (circulus tonsillaris) around the base of the tonsil, from which numerous filaments are given off to the mucous membrane of the fauces and soft palate, communicating with the posterior palatine branches of Meckel's ganglion.

The PNEUMOGASTRIC NERVE (vagus) arises by numerous filaments from the respiratory tract immediately below the glosso-pharyngeal, and passes out of the skull through the inner extremity of the jugular foramen in a distinct canal of the dura mater. While situated in this canal it presents a small rounded ganglion; and having escaped from the skull, a gangliform swelling, nearly an inch in length, and surrounded by an irregular plexus of white nerves, which communicate with each other, with the other divisions of the eighth pair, and with the trunk of the pneumogastric below the ganglion. This second, or *plexiform ganglion* (ganglion of the superior laryngeal branch, of Sir Astley Cooper), is situated, at first, behind the internal carotid artery, and then between that vessel and the internal jugular vein. The pneumogastric nerve then descends the neck within the sheath of the carotid vessels, lying behind and between the artery and vein, to the root of the neck. Here the course of the nerve at opposite sides becomes different.

The *Right* passes between the subclavian artery and vein to the posterior mediastinum, then behind the root of the lung to the œsophagus, which it accompanies to the stomach, lying on its posterior aspect.

The *Left* enters the chest parallel with the left subclavian artery, crosses the arch of the aorta, and descends behind the root of the

lung, and along the anterior surface of the œsophagus, to the stomach.

The fibres of origin of the pneumogastric nerve, like those of the glosso-pharyngeal, may be traced through the fasciculi of the corpus restiforme into the gray substance of the floor of the fourth ventricle.

The *Branches* of the pneumogastric nerve are the following :

Communicating branches with the Pharyngeal, Superior laryngeal, Cardiac, Inferior or recurrent laryngeal, Pulmonary anterior, Pulmonary posterior, Œsophageal, Gastric.	Facial, Glosso-pharyngeal, Spinal accessory, Hypo-glossal, Sympathetic.
---	---

The *Branches of communication* form part of the complicated plexus at the base of the skull. The branches to the ganglion of Andersch, and that to the facial nerve, are given off by the superior ganglion in the jugular fossa ; the latter passes through a minute canal in the petrous bone, to the lower part of the aqueductus Fallopii.

The *Pharyngeal* nerve arises from the pneumogastric, immediately above the plexiform ganglion, and descends behind the internal carotid artery to the upper border of the middle constrictor, upon which it forms the *pharyngeal plexus* assisted by branches from the glosso-pharyngeal, superior laryngeal, and sympathetic. The pharyngeal plexus is distributed to the muscles and mucous membrane of the pharynx.

The *Superior laryngeal* nerve arises from the inferior ganglion of the pneumogastric, of which it appears to be almost a continuation ; hence the ganglion has been named by Sir Astley Cooper, the "*ganglion of the superior laryngeal branch.*" The nerve descends behind the internal carotid artery to the opening in the thyro-hyoidean membrane, through which it passes with the superior laryngeal artery, and is distributed to the mucous membrane of the larynx, communicating on the arytenoid muscle, and behind the cricoid cartilage, with the recurrent laryngeal nerve. Behind the internal carotid it gives off the *external laryngeal branch*, which sends a branch to the pharyngeal plexus, and then descends to supply the inferior constrictor and crico-thyroid muscles and thyroid gland, and communicates by two or three branches with the recurrent laryngeal and sympathetic nerve.

Mr. John Hilton, demonstrator of anatomy in Guy's Hospital, who has made some able dissections of the nerves of the larynx, of which we refer the student to a masterly description in the 2d vol. of the Guy's Hospital Reports, concludes that the superior laryngeal nerve is the *nerve of sensation* to the larynx, being distributed solely (with the exception of its external laryngeal branch) to the mucous membrane, cellular tissue, and glands. If this fact be taken in connexion with the observations of Sir Astley Cooper, and the dissections of the origin of the nerve by Mr. Edward Cock, we shall perceive that, both in the ganglionic origin of the nerve and in its distribution, we have striking evidence of its sensitive function. The recurrent, or inferior laryngeal nerve, is the proper motor nerve, and is distributed to the muscles of the larynx.

The *Cardiac* branches, two or three in number, arise from the pneumogastric in the lower part of the neck, and cross the lower part of the common carotid, to communicate with the cardiac branches of the sympathetic, and with the great cardiac plexus.

The *Recurrent laryngeal*, or inferior laryngeal nerve, curves around the subclavian artery on the right, and the arch of the aorta on the left side. It ascends in the groove between the trachea and œsophagus, and piercing the lower fibres of the inferior constrictor muscle enters the larynx close to the articulation of the inferior cornu of the thyroid with the cricoid cartilage. It is distributed to all the muscles of the larynx, with the exception of the crico-thyroid, and communicates with the superior laryngeal nerve. As it curves

Fig. 151.

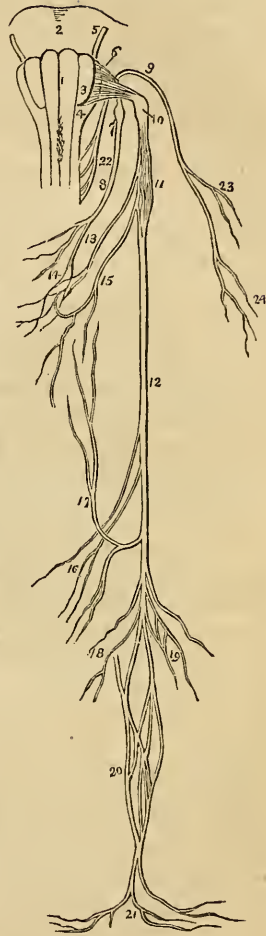

Fig. 151. Origin and distribution of the eighth pair of nerves. 1, 3, 4. The medulla oblongata. 1. Is the corpus pyramidale of one side. 3. The corpus olivare. 4. The corpus restiforme. 2. The pons Varolii. 5. The facial nerve. 6. The origin of the glosso-pharyngeal nerve. 7. The ganglion of Andersch. 8. The trunk of the nerve. 9. The spinal accessory nerve. 10. The ganglion of the pneumogastric nerve. 11. Its plexiform ganglion. 12. Its trunk. 13. Its pharyngeal branch forming the pharyngeal plexus (14), assisted by a branch from the glosso-pharyngeal (8), and one from the superior laryngeal nerve (15). 16. Cardiac branches. 17. Recurrent laryngeal branch. 18. Anterior pulmonary branches. 19. Posterior pulmonary branches. 20. Œsophageal plexus. 21. Gastric branches. 22. Origin of the spinal accessory nerve. 23. Its branches distributed to the sterno-mastoid muscle. 24. Its branches to the trapezius muscle.

around the subclavian artery and aorta it gives branches to the heart and root of the lungs; and as it ascends the neck it distributes filaments to the œsophagus and trachea, and communicates with the external laryngeal nerve and sympathetic.

The *Anterior pulmonary* branches are distributed upon the anterior aspect of the root of the lungs, forming, with branches from the great cardiac plexus, the *anterior pulmonary plexus*.

The *Posterior pulmonary* branches, more numerous than the anterior, are distributed upon the posterior aspect of the root of the lungs, and are joined by branches from the great cardiac plexus, forming the *posterior pulmonary plexus*.

Upon the œsophagus the two nerves divide into numerous branches which communicate with each other and constitute the *œsophageal plexus*, which completely surrounds the cylinder of the œsophagus, and accompanies it to the cardiac orifice of the stomach.

The *Gastric* branches are the terminal filaments of the two pneumogastric nerves; they are spread out upon the anterior and posterior surfaces of the stomach, and are likewise distributed to the omentum, spleen, pancreas, liver, and gall-bladder, and communicate, particularly the right nerve, with the solar plexus.

The SPINAL ACCESSORY NERVE arises by several filaments from the respiratory tract, as low down as the fourth or fifth cervical nerve, and ascends behind the ligamentum denticulatum, and between the anterior and posterior roots of the spinal nerves, to the foramen lacerum posterius. It communicates in its course with the posterior root of the first cervical nerve, and soon becomes applied against the ganglion of the pneumogastric, and enclosed in the same canal of dura mater. In the jugular fossa it divides into two branches; the smaller joins the pneumogastric immediately below the superior ganglion, and contributes to the formation of the pharyngeal nerve; while the larger or true continuation of the nerve passes backwards behind the internal jugular vein, and descends obliquely to the upper part of the sterno-mastoid muscle. It then pierces the sterno-mastoid and passes obliquely across the neck, communicating with the cervical nerves, and is distributed to the trapezius. The spinal accessory sends numerous branches to the sterno-mastoid in its passage through that muscle; its branches to the trapezius may be traced to the lower border of that muscle.

The pneumogastric and spinal accessory nerves together resemble a spinal nerve, the former representing the posterior root with its ganglion, and the latter an anterior root.

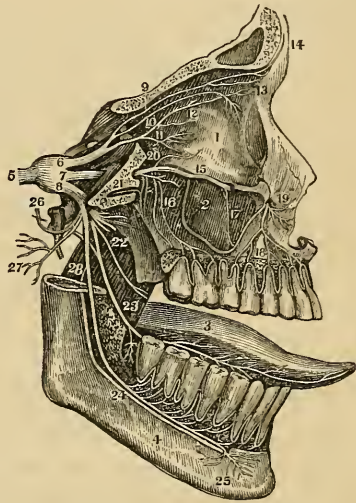
5th pair, TRIFACIAL (trigeminus).—This nerve is analogous to the spinal nerves in its origin by two roots, from the anterior and posterior columns of the spinal cord, and in the existence of a ganglion on the posterior root. Hence it ranges with the spinal nerves, and is considered as the cranial spinal nerve.

It arises* by two roots from a tract of yellowish white matter

* I have adopted the origin of this nerve, given by Dr. Alcock, of Dublin, as the result of his dissections, in the *Cyclopædia of Anatomy and Physiology*. Mr. Mayo also traces the anterior root of the nerve to a similar origin.

situated in front of the floor of the fourth ventricle and the origin of the auditory nerve, and behind the crus cerebelli. This tract divides inferiorly into two fasciculi which may be traced downwards into the spinal cord, one being continuous with the fibres of the anterior column, the other with the posterior column. Proceeding from this origin the two roots of the nerve pass forward, and issue from the brain upon the anterior part of the crus cerebelli, where they are separated by a slight interval. The anterior is much smaller than the posterior, and the two together constitute the fifth nerve, which in this situation consists of seventy to a hundred filaments held together by pia mater. The nerve then passes through an oval opening in the border of the tentorium, near to the extremity of the petrous bone, and spreads out into a large semilunar ganglion—the Casserian. If the ganglion be turned over, it will be seen that the anterior root lies against its under surface without having any connexion with it, and may be followed onwards to the inferior maxillary nerve. The Casserian ganglion divides into three branches, the ophthalmic, superior maxillary, and inferior maxillary.

Fig. 152.



The OPTHALMIC NERVE is a short trunk, being not more than three quarters of an inch in length; it arises from the upper angle of the Casserian ganglion, beneath the dura mater, and passes forwards through the outer wall of the cavernous sinus, lying externally to the other nerves: it divides into three branches. Previously to its division it receives several filaments from the carotid plexus, and gives off a small *recurrent*

Fig. 152. A view of the distribution of the trifacial or 5th pair.—1. Orbit. 2. Antrum of Highmore. 3. Tongue. 4. Lower maxilla. 5. Root of 5th pair forming the ganglion of Casser. 6. 1st branch, *Ophthalmic*. 7. 2d branch, *Superior maxillary*. 8. 3d branch, *Inferior maxillary*. 9. Frontal branch, dividing into external and internal frontal at 14. 10. Lachrymal branch; dividing before entering the lachrymal gland. 11. Nasal branch. Just under the figure is the long root of the lenticular or ciliary ganglion, and a few of the ciliary nerves. 12. Internal nasal, disappearing through the anterior ethmoidal foramen. 13. External nasal. 14. External and internal frontal. 15. Infra-orbitary nerve. 16. Posterior dental branches. 17. Middle dental branch. 18. Anterior dental nerve. 19. Terminating branches of infra-orbital, called labial and palpebral. 20. *Subcutaneus malæ* or orbital branch. 21. Pterygoid or recurrent, from Meckel's ganglion. 22. Five anterior branches of 3d of 5th, being nerves of motion, and called masseter, temporal, pterygoid and buccal. 23. Lingual branch joined at an acute angle by the *chorda tympani*. 24. Inferior dental nerve terminating in, 25. Mental branches. 26. Superficial temporal nerve. 27. Auricular branches. 28. Mylo-hyoid branch.

nerve, that passes backwards with the recurrent branch of the fourth nerve between the two layers of the tentorium to the lining membrane of the lateral sinus.

The *Branches* of the ophthalmic nerve are, the—

Frontal,
Lachrymal,
Nasal.

The *Frontal* nerve mounts above the levator palpebræ, and runs forward, resting upon that muscle, to the supra-orbital foramen, through which it escapes upon the forehead, and supplies the muscles and integument of that region.

It gives off one small branch, the *supra-trochlear*, which passes inwards above the pulley of the superior oblique muscle, and ascends along the middle line of the forehead, distributing filaments to the muscles and integument at the inner angle of the eye and root of the nose.

The *Lachrymal* nerve, the smallest of the three branches of the ophthalmic, receives a filament from the fourth nerve in the cavernous sinus, and passes outwards along the upper border of the external rectus muscle to the lachrymal gland, where it divides into two branches. The superior branch passes over the gland and through a foramen in the malar bone, and is distributed upon the temple and cheek, communicating with the temporo-malar and facial nerves. The inferior branch supplies the lower surface of the gland, and terminates in the integument of the upper lid, communicating with the facial nerve.

The *Nasal* nerve passes forwards between the two heads of the external rectus muscle, crosses the optic nerve in company with the ophthalmic artery, and enters the anterior ethmoidal foramen immediately above the internal rectus. It then traverses the upper part of the ethmoid bone to the cribriform plate, and passes downwards through the slit-like opening by the side of the crista galli into the nose, where it divides into two branches—an *internal branch* supplying the mucous membrane, near the anterior openings of the nares; and an *external branch* which passes between the fibro-cartilages, and is distributed to the integument at the extremity of the nose.

The *Branches* of the nasal nerve within the orbit are, the ganglionic, ciliary, and infra-trochlear; in the nose it gives off one or two filaments to the anterior ethmoidal cells and frontal sinus. The *ganglionic branch* passes obliquely forwards to the superior angle of the ciliary ganglion, forming its superior or long root. The *ciliary branches* are two or three filaments which are given off by the nasal as it crosses the optic nerve. They pierce the posterior part of the sclerotic, and pass between that tunic and the choroid to be distributed to the iris. The *infra-trochlear* is given off just as the nerve is about to enter the anterior ethmoidal foramen. It passes along the superior border of the internal rectus to the inner angle of the eye, where it communicates with the supra-trochlear nerve, and

supplies the lachrymal sac, caruncula lachrymalis, conjunctiva, and inner angle of the orbit.

The SUPERIOR MAXILLARY NERVE proceeds from the middle of the Casserian ganglion; it passes forwards through the foramen rotundum, crosses the speno-maxillary fossa, and enters the canal in the floor of the orbit, along which it runs to the infra-orbital foramen. Emerging on the face, beneath the levator labii superioris muscle, it divides into a leash of branches, which are distributed to the muscles and integument of the cheek, forming a plexus with the facial nerve.

The *Branches* of the superior maxillary nerve are divisible into three groups:—1. Those which are given off in the speno-maxillary fossa. 2. Those in the infra-orbital canal; and 3. Those on the face. They may be thus arranged:

<i>Spheno-maxillary fossa,</i>	{	Orbital, Two from Meckel's ganglion,* Posterior dental.
<i>Infra-orbital canal,</i>	{	Middle dental, Anterior dental.
<i>On the face,</i>	{	Muscular, Cutaneous.

The *Orbital* branch† enters the orbit through the speno-maxillary fissure, and divides into two branches: *lachrymal*,‡ which ascends along the outer wall of the orbit to the lachrymal gland, and communicates with the lachrymal nerve: *temporo-malar*,§ which passes forwards and divides into two branches: one piercing the malar bone, is distributed to the integument of the cheek, communicating with the facial nerve; the other escaping through the outer wall of the orbit supplies the temporal muscle and integument in the temporal region, and communicates with the temporal, anterior auricular, and facial nerve.

The *Two branches* from Meckel's ganglion ascend from that body to join the nerve, as it crosses the speno-maxillary fossa.

The *Posterior dental* branches pass through small foramina, in the posterior surface of the superior maxillary bone, and supply the posterior teeth.

The *Middle* and *anterior dental* branches descend to the teeth; the former beneath the lining membrane of the antrum, the latter through distinct canals in the walls of the bone.

The *Muscular* and *cutaneous branches* are the terminating fila-

* We now encounter a different mode of describing the nerves from that which has been so long in use; for where it was customary to describe these branches as branches of the fifth pair running *down* to form Meckel's ganglion, we now find them described as running *up* to join the fifth pair. This arises from the belief now general that these ganglia form a part of the great sympathetic, and the student will find their description under that head.—G.

† *Nervus subcutaneus malæ* of other anatomists.—G.

‡ The malar branch.—G.

§ The temporal branch.—G.

ments of the nerve; they supply the muscles and integument of the cheek, and form an intricate plexus with branches of the facial nerve.

The **INFERIOR MAXILLARY NERVE** proceeds from the inferior angle of the Casserian ganglion: it is the largest of the three divisions of the fifth nerve, and is augmented in size by the anterior or motor root, which passes behind the ganglion, and unites with the inferior maxillary as it escapes through the foramen ovale. Emerging at the foramen ovale the nerve divides into two trunks, external and internal, which are separated from each other by the external pterygoid muscle.

The *External trunk*, into which may be traced the whole of the motor root, immediately divides into five branches, which are distributed to the muscles of the temporo-maxillary region; they are—

The *Masseteric*, which crosses the sigmoid notch with the masseteric artery to the masseter muscle. It sends a small branch to the temporal muscle, and a filament to the temporo-maxillary articulation.

Temporal; two branches passing between the upper border of the external pterygoid muscle and the temporal bone to the temporal muscle. Two or three filaments from these nerves pierce the temporal fascia, and communicate with the lachrymal, temporo-malar, auricular, and facial nerve.

Buccal;* a large branch which pierces the fibres of the external pterygoid, to reach the buccinator muscle. This nerve sends filaments to the temporal and external pterygoid muscle, to the mucous membrane and integument of the cheek, and communicates with the facial nerve.

Internal pterygoid; a long and slender branch, which passes inwards to the internal pterygoid muscle. This nerve is remarkable from its connexion with the otic ganglion, to which it is closely attached.

The *Internal trunk* divides into three branches—

Gustatory,
Inferior dental,
Anterior auricular.

The **GUSTATORY NERVE** descends between the two pterygoid muscles to the side of the tongue, where it becomes flattened, and divides into numerous filaments, which are distributed to the papillæ and mucous membrane.

Relations.—It lies at first between the external pterygoid muscle and the pharynx, next between the two pterygoid muscles, then between the internal pterygoid and ramus of the jaw, and between the stylo-glossus muscle and the submaxillary gland; lastly, it runs

* The name buccal is usually applied to the central branches from the *pes anserinus* of the facial nerve.—G.

along the side of the tongue, resting upon the hyo-glossus muscle, and covered in by the mylo-hyoideus and mucous membrane.

The gustatory nerve, while between the two pterygoid muscles, receives a branch from the inferior dental; lower down it is joined at an acute angle by the chorda tympani, which passes downwards in the sheath of the gustatory to the submaxillary gland, where it unites with the submaxillary ganglion. On the hyo-glossus muscle some branches of communication are sent to the hypoglossal, and in the course of the nerve several small branches to the mucous membrane of the fauces, and to the tonsils, and numerous filaments to the submaxillary gland.

The INFERIOR DENTAL NERVE passes downwards with the inferior dental artery, at first between the two pterygoid muscles, and then between the internal lateral ligament and the ramus of the lower jaw, to the dental foramen. It then runs along the canal in the inferior maxillary bone, distributing branches to the teeth, and divides into two branches, incisive and mental. The *incisive* branch passes forwards to supply the incisive teeth: and the *mental* branch escapes through the mental foramen, to be distributed to the muscles and integument of the chin, and to communicate with the facial nerve.

It gives off but one branch, the *mylo-hyoidean*, which leaves the nerve just as it is about to enter the dental foramen. This branch pierces the insertion of the internal lateral ligament, and descends along a groove in the bone to the superior surface of the mylo-hyoid muscle, to which it is distributed.

The ANTERIOR AURICULAR NERVE passes directly backwards behind the articulation of the lower jaw, against which it rests. In this situation it divides into two branches, which reunite, and form a kind of plexus. From the plexus two branches are given off—ascending and descending. The *ascending* or *temporal branch** sends a considerable branch of communication to the facial nerve, and then ascends in front of the ear to the temporal region, upon which it is distributed in company with the branches of the temporal artery. In its course it sends filaments to the temporo-maxillary articulation, to the pinna and meatus of the ear, and to the integument in the temporal region. It communicates on the temple with branches of the facial, supra-orbital, lachrymal, and temporo-malar nerve. The *descending branch* enters the parotid gland, to which it sends numerous branches; it communicates with the inferior dental and auricularis magnus nerve, and supplies the external ear and the temporo-maxillary articulation.

SPINAL NERVES.

There are thirty-one pairs of spinal nerves, each arising by two roots, an anterior or motor root, and a posterior or sensitive root.

The anterior roots arise from a narrow white line upon the ante-

* This is usually called the superficial temporal nerve.—G.

rior columns of the spinal cord, and gradually approach towards the anterior longitudinal sulcus as they descend.

The posterior roots, more regular than the anterior, arise from a narrow gray band formed by the internal gray substance of the cord. They are larger, and the filaments of the origin more numerous than those of the anterior roots. A ganglion is found upon each of the posterior roots in the intervertebral foramina. The first cervical nerve forms an exception to these characters. Its posterior root is smaller than the anterior; there is frequently no ganglion upon it, and it often joins in the whole or in part with the spinal accessory nerve.

After the formation of the ganglion the two roots unite, and constitute a spinal nerve, which escapes through the intervertebral foramen, and divides into an anterior branch, for the supply of the front half of the body, and a posterior branch, for the posterior half.

The anterior branches, with the exception of the two first cervical nerves, are larger than the posterior; an arrangement which is proportioned to the larger extent of surface they are required to supply.

The *Spinal nerves* are divided into—

Cervical	8 pairs
Dorsal	12
Lumbar	5
Sacral	6

The *Cervical nerves* pass off transversely from the spinal cord; the *dorsal* are oblique in their direction; and the *lumbar* vertical, and form the large assemblage of nerves at the termination of the cord called *cauda equina*.

The CERVICAL NERVES increase in size from above downwards; the first (sub-occipital) passes out of the spinal canal between the occipital bone and the atlas; and the last, between the last cervical and first dorsal vertebra. Each nerve, at its escape from the intervertebral foramen, divides into an anterior and a posterior branch. The anterior branches of the four upper cervical nerves form the *cervical plexus*; the posterior branches, the *posterior cervical plexus*.

The anterior branches of the four inferior cervical together with the first dorsal form the brachial plexus.

Anterior cervical nerves.—The *Anterior branch* of the *first cervical nerve* escapes from the vertebral canal through the groove upon the posterior arch of the atlas which supports the vertebral artery, beneath which it lies. It then descends in front of the transverse process of the atlas, and forms a loop by communicating with an ascending branch of the second nerve.

The *Anterior branch* of the *second cervical nerve* divides into three branches at its exit from the intervertebral foramen between the atlas and axis, viz., an ascending branch, which completes the

arch of communication with the first nerve; and two descending branches, which communicate with the third nerve.

The *Anterior branch* of the *third cervical nerve*, double the size of the preceding, divides at its exit from the intervertebral foramen into numerous branches, some of which communicate and form loops and anastomoses with the second, and others with the fourth nerve.

The *Anterior branch* of the *fourth cervical nerve*, of the same size with the preceding, communicates by anastomoses with the third, and sends a small branch downwards to the fifth nerve. Its principal branches pass downwards and outwards across the posterior triangle of the neck, towards the clavicle and acromion.

The CERVICAL PLEXUS is constituted by the loops of communication, and by the anastomosis which take place between the anterior branches of the four first cervical nerves. The plexus rests upon the levator anguli scapulæ, posterior scalenus, and splenius muscle, and is covered in by the sterno-mastoid and platysma.

The branches of the cervical plexus may be arranged into three groups, superficial ascending, superficial descending; and deep—

Superficial	{	<i>Ascending.</i> <i>Descending.</i>	{	Superficialis colli, Auricularis magnus, Occipitalis minor. Acromiales, Claviculares.
Deep.	{	Communicating branches, Muscular, Communicans noni, Phrenic.		

The *Superficialis colli* is formed by communicating branches from the second and third cervical nerves; it curves around the posterior border of the sterno-mastoid, and crosses obliquely behind the external jugular vein to the anterior border of that muscle, where it divides into an ascending and a descending branch; the *descending branch* is distributed to the integument on the side and front of the neck; the *ascending branch* passes upwards to the submaxillary region, and divides into four or five filaments, some of which pierce the platysma myoides and supply the integument as high up as the chin and the lower part of the face, while others form a plexus with the descending branches of the facial nerve beneath the platysma. One or two filaments from this nerve accompany the external jugular vein.

The *Auricularis magnus* also proceeds from the second and third cervical nerves; it curves around the posterior border of the sterno-mastoid, and ascends upon that muscle, lying parallel with the external jugular vein, to the parotid gland, where it divides into a superficial and deep branch. The *superficial branch* is distributed to the integument over the parotid gland, and to the anterior surface

of the external ear. The *deep branch* pierces the parotid gland and crosses the mastoid process, where it divides into branches which supply the posterior part of the pinna and the integument of the side of the head. Previously to its division the auricularis magnus nerve sends off several facial branches, which are distributed to the cheek. The terminal branches of this nerve communicate with branches of the anterior auricular, the facial, and the occipitalis major nerve.

The *Occipitalis minor* arises from the second cervical nerve; it curves around the posterior border of the sterno-mastoid above the preceding and ascends upon that muscle, parallel with its posterior border, to the lateral and posterior side of the head. It is distributed to the integument in this region.

The *Acromiales* and *Claviculares* are two or three large nerves which descend from the plexus and divide into numerous branches which pass downwards over the clavicle, and are distributed to the integument of the upper and anterior part of the chest from the sternum to the shoulder.

The *Communicating branches* are filaments which arise from the loop between the first and second cervical nerve, and pass inwards to communicate with the sympathetic, the pneumogastric, and the lingual nerve. The three first cervical nerves send branches to the first cervical ganglion; the fourth sends a branch to the trunk of the sympathetic, or to the middle cervical ganglion. From the second cervical nerve a large branch is given off, which goes to join the spinal accessory nerve.

The *Muscular branches* proceed from the third and fourth cervical nerves; they are distributed to the trapezius, levator anguli scapulæ, and rhomboidei muscles. From the second cervical nerve a small muscular branch is sent to the rectus anticus major.

The *Communicans noni* is a long slender branch formed by filaments from the first, second, and third cervical nerves; it descends upon the outer side of the internal jugular vein, and forms a loop with the descendens noni over the sheath of the carotid vessels.

The *Phrenic nerve* is formed by filaments from the third, fourth, and fifth cervical nerves, receiving also a branch from the sympathetic. It descends to the root of the neck, resting upon the scalenus anticus muscle, then crosses the first portion of the subclavian artery, and enters the chest between it and the subclavian vein. Within the chest it passes through the middle mediastinum, between the pleura and pericardium to the diaphragm, to which it is distributed, and communicates in the abdomen with the phrenic and solar plexus, and on the right side with the hepatic plexus. The left phrenic nerve is rather longer than the right, from the inclination of the heart to the left side.

Posterior cervical nerves.—The posterior division of the *first cervical nerve* (sub-occipital), larger than the anterior, escapes from the vertebral canal through the opening for the vertebral artery, lying posteriorly to that vessel, and emerges into the triangular

space formed by the rectus posticus major, obliquus superior, and obliquus inferior. It is distributed to the recti and obliqui muscles, and sends one or two filaments downwards to communicate with the second cervical nerve. The posterior branch of the *second cervical nerve* is three or four times greater than the anterior branch, and is larger than the other posterior cervical nerves. The posterior branch of the *third cervical nerve* is smaller than the preceding, but larger than the fourth; and the other posterior cervical nerves go on progressively decreasing to the seventh.

POSTERIOR CERVICAL PLEXUS.—This plexus is constituted by the succession of anastomosing loops and communications which pass between the posterior branches of the first, second, and third cervical nerves. It is situated between the complexus and semispinalis colli, and its branches are the—

Musculo-cutaneous,
Occipitalis major.

The *Musculo-cutaneous* branches pass inwards between the complexus and semispinalis colli to the ligamentum nuchæ, distributing muscular filaments in their course. They then pierce the aponeurosis of the trapezius and become subcutaneous, sending branches outwards to supply the integument of the posterior aspect of the neck, and upwards to the posterior region of the scalp.

The *Occipitalis major* is the direct continuation of the second cervical nerve; it ascends obliquely inwards, between the obliquus inferior and complexus, pierces the complexus and trapezius, after passing for a short distance between them, and ascends upon the posterior aspect of the head between the integument and occipitofrontalis, in company with the occipital artery. The occipitalis major sends numerous branches to the muscles of the neck, and is distributed to the integument of the scalp, as far forwards as the middle of the vertex of the head.

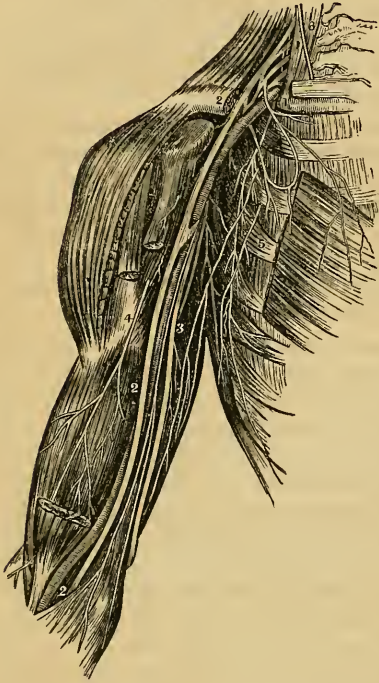The *Posterior branches* of the fourth, fifth, sixth, seventh, and eighth nerves pass inwards between the muscles of the back in the cervical and upper part of the dorsal region, and reaching the surface near to the middle line are reflected outwards to be distributed to the integument. The fourth and fifth are nearly transverse in their course, and lie between the semispinalis colli and complexus. The sixth, seventh, and eighth are directed nearly vertically downwards; they pierce the aponeurosis of origin of the splenius and trapezius.

BRACHIAL PLEXUS.

The *Brachial* or *axillary plexus* of nerves is formed by communications between the anterior branches of the four last cervical and first dorsal nerve. These nerves are all similar in size, and their mode of disposition in the formation of the plexus is the following:

the fifth and sixth nerves unite to form a common trunk, which soon divides into two branches; the last cervical and first dorsal also unite immediately upon their exit from the intervertebral foramina, and the common trunk resulting from their union after a short course also divides into two branches; the seventh nerve passes outwards between the common trunks of the two preceding, and opposite the clavicle divides into a superior branch which unites with the inferior division of the superior trunk, and an inferior branch which communicates with the superior division of the inferior trunk; from these divisions and communications the brachial plexus results. The brachial plexus communicates with the cervical plexus by means of a branch sent from the fourth to the fifth nerve, and by the inferior branch of origin of the phrenic nerve. The plexus is broad in the neck, narrow as it descends into the axilla, and again enlarges at its lower part

Fig. 153.



where it divides into its six terminal branches.

Relations.—The brachial plexus is in relation in the neck with the two scaleni muscles, between which its nerves issue; lower down it is placed between the clavicle and subclavius muscle above, and the first rib and first serration of the serratus magnus muscle below. In the axilla, it is situated at first to the outer side and then behind the axillary artery, resting by its outer border against the tendon of the subscapularis muscle. At this point it completely surrounds the artery by means of the two cords which are sent off to form the median nerve.

Its *Branches* may be arranged into two groups, humeral and descending,—

Fig. 153. A view of the brachial plexus of nerves and branches of arm. 1, 1. The scalenus anticus muscle, in front of which are the roots of the plexus. 2, 2. The median nerve. 3. The ulnar nerve. 4. The branch to the biceps muscle. 5. The nerves of *Wrisberg*. 6. The phrenic nerve from the 3d and 4th cervical.

Humeral Branches.

Superior muscular,
 Short thoracic,
 Long thoracic,
 Supra-scapular,
 Subscapular,
 Inferior muscular.

Descending Branches.

External cutaneous,
 Internal cutaneous,
 Lesser internal cutaneous,
 Median,
 Ulnar,
 Musculo-spiral,
 Circumflex.

The superior *Muscular nerves* are several large branches which are given off by the fifth cervical nerve above the clavicle; they are—a *subclavian branch* to the subclavius muscle, which usually sends a communicating filament to the phrenic nerve;—a *rhomboid branch* to the rhomboidei muscles; and frequently an *angular branch* to the levator anguli scapulæ.

The *Short thoracic nerves* are two in number; they arise from the brachial plexus at a point parallel with the clavicle, and are divisible into an anterior and a posterior branch. The *anterior branch* passes forwards between the subclavius muscle and the subclavian vein, and is distributed to the pectoralis major muscle, entering it by its costal surface. In its course it gives off a branch which forms a loop of communication with the posterior branch. The *posterior branch* passes forward beneath the axillary artery and unites with the communicating branch of the preceding to form a loop, from which numerous branches are given off to the pectoralis major and pectoralis minor.

The *Long thoracic nerve* (external respiratory of Bell) is a long and remarkable branch arising from the fourth and fifth cervical nerves, immediately after their escape from the intervertebral foramina. It passes down behind the plexus and axillary vessels, resting on the scalenus posticus muscle; it then descends along the side of the chest upon the serratus magnus muscle to its lowest serration. It sends numerous filaments to this muscle in its course.

The *Supra-scapular nerve* arises above the clavicle from the fifth cervical nerve and descends obliquely outwards to the supra-scapular notch; it then passes through the notch, crosses the supra-spinous fossa beneath the supra-spinatus muscle, and passing in front of the concave margin of the spine of the scapula, enters the infra-spinous fossa. It is distributed to the supra-spinatus and infra-spinatus muscle.

The *Subscapular nerves* are three or four in number; of which one arises from the brachial plexus above the clavicle, and the others in the axilla. They are distributed to the subscapularis muscle.

The terminal branches of the plexus are arranged in the following order: the external cutaneous, and one head of the median to the outer side of the artery; the other head of the median, internal cutaneous, and ulnar, upon its inner side; and the circumflex and musculo-spiral behind.

The **EXTERNAL CUTANEOUS NERVE** (musculo-cutaneous, perforans Casserii) arises from the brachial plexus in common with the external head of the median; it pierces the coraco-brachialis muscle, and passes between the biceps and brachialis anticus, to the outer side of the bend of the elbow, where it perforates the fascia, and divides into an *external* and *internal* branch.

These branches pass behind the median cephalic vein, and are distributed to the integument upon the outer side of the fore-arm as far as the wrist, communicating with the internal cutaneous and radial nerves. From the internal division at the lower third of the fore-arm a branch is given off which accompanies the radial artery to the wrist and supplies several filaments to the synovial membranes of the wrist, both on its anterior and posterior aspect.

The *Branches* of the external cutaneous nerve in the upper arm are distributed to the coraco-brachialis, biceps, and brachialis anti-muscle.

The **INTERNAL CUTANEOUS NERVE** is one of the internal and smallest of the branches of the axillary plexus; it arises from the plexus in common with the ulnar and internal head of the median, and passes down the inner side of the arm in company with the basilic vein. At about the middle of the arm it pierces the deep fascia by the side of the basilic vein and divides into two branches, anterior and posterior. Each of these branches subdivides into several filaments, which are distributed to the integument upon the anterior and posterior aspect of the ulnar border of the fore-arm as far as the wrist. At the bend of the elbow the filaments of the anterior branch pass in front of the median basilic vein, and sometimes behind that vessel. On the fore-arm the nervous filaments communicate with the external cutaneous and with the ulnar nerve.

The **LESSER INTERNAL CUTANEOUS NERVE** or *nerve of Wrisberg* is very irregular, in point of origin. It is a long and slender nerve, and usually arises from the common trunk of the last cervical and first dorsal nerve. Passing downwards into the axillary space it communicates with the external branch of the first intercosto-humeral nerve, and descends upon the inner side of the internal cutaneous nerve, to the middle of the posterior aspect of the upper arm, where it pierces the fascia and is distributed to the integument of the elbow, communicating with the filaments of the internal cutaneous and spiral cutaneous. In its course it gives off two or three cutaneous filaments to the integument of the inner and anterior aspect of the upper arm.

The **MEDIAN NERVE** has received its name from taking a course along the middle of the arm to the palm of the hand; it is, therefore, intermediate in position, between the radial and ulnar nerves. It commences by two heads, which embrace the axillary artery; lies at first to the outer side of the brachial artery, which it crosses at its middle; and descends on its inner side to the bend of the elbow. It then passes between the two heads of the pronator radii teres and flexor sublimis digitorum muscles, and runs down the fore-

arm between the flexor sublimis and profundus, and beneath the annular ligament into the palm of the hand.

The *branches* of the median nerve are,—

Muscular,	Superficial palmar,
Anterior interosseous,	Digital.

The *Muscular branches* are given off by the nerve at the bend of the elbow; they are distributed to all the muscles on the anterior aspect of the fore-arm, with the exception of the flexor carpi ulnaris, and to the periosteum. The branch to the pronator radii teres sends off reflected branches to the elbow-joint.

The *Anterior interosseous* is a large branch accompanying the anterior interosseous artery, and supplying the deep layer of muscles in the fore-arm. It passes beneath the pronator quadratus muscle, and pierces the interosseous membrane near to the wrist. On reaching the posterior aspect of the wrist it joins a large and remarkable ganglion, which gives off a number of branches for the supply of the joint.

The *Superficial palmar branch* arises from the median nerve at about the lower fourth of the fore-arm; it crosses the annular ligament, and is distributed to the integument over the ball of the thumb and in the palm of the hand.

The median nerve at its termination in the palm of the hand is very considerably spread out and flattened, and it divides into six branches, one muscular and five digital. The *muscular branch* is distributed to the muscles of the ball of the thumb. The *digital branches* are thus arranged:—two pass outwards to the thumb; one to the radial side of the index finger; one subdivides for the supply of the adjoining sides of the index and middle fingers; and the remaining one, for the supply of the adjoining sides of the middle and ring fingers. The digital nerves in their course along the fingers are situated to the inner side of the digital arteries. Opposite the base of the first phalanx each nerve gives off a *dorsal branch* which runs along the border of the dorsum of the finger. Near the extremity of the finger the digital nerve divides into a *palmar* and a

Fig. 154.

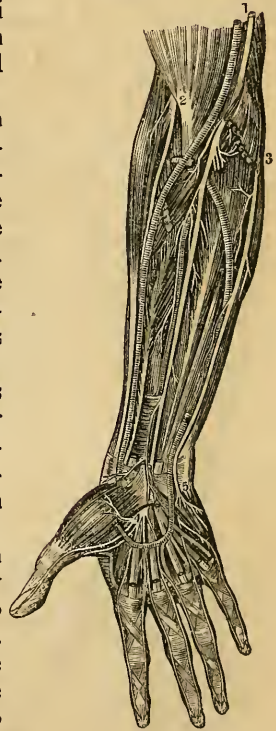

Fig. 154. Nerves of front of fore-arm. 1. Median nerve. 2. Anterior branch of musculo-spiral or radial nerve. 3. Ulnar nerve. 4. Division of median nerve in the palm to the thumb, 1st, 2d, and radial side of 3d finger. 5. Division of ulnar nerve to ulnar side of 3d and both sides of 4th finger.

dorsal branch; the former supplying the sentient extremity of the finger, and the latter the structures around and beneath the nail. The digital nerve maintains no communication with its fellow of the opposite side.

The ULNAR NERVE is somewhat smaller than the median, behind which it lies, gradually diverging from it in its course. It arises from the brachial plexus in common with the internal head of the median and the internal cutaneous nerve, and runs down the inner side of the arm, to the groove between the internal condyle and olecranon, resting upon the internal head of the triceps, and accompanied by

the inferior profunda artery. At the elbow it is superficial, and supported by the inner condyle, against which it is easily compressed, giving rise to the thrilling sensation along the inner side of the fore-arm and little finger, ascribed to striking the "funny bone." It then passes between the two heads of the flexor carpi ulnaris and descends along the inner side of the fore-arm, crosses the annular ligament, and divides into two branches, superficial and deep palmar. At the commencement of the middle third of the fore-arm, it becomes applied against the artery, and lies to its ulnar side, as far as the hand.

The *Branches* of the ulnar nerve are,—

Muscular in the upper arm,
Articular,
Muscular in the fore-arm,
Anastomotic,
Dorsal branch,
Superficial palmar,
Deep palmar.

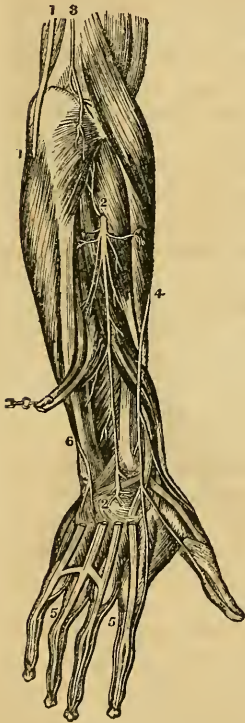The *Muscular branches* in the upper arm are a few filaments distributed to the triceps.

The *Articular branches* are several filaments to the elbow-joint, which are given off from the nerve as it lies in the groove between the inner condyle and the olecranon.

The *Muscular branches* in the fore-arm are distributed to the flexor carpi ulnaris and flexor profundus digitorum muscle.

The *Anastomotic branch* is a small nerve which arises from the ulnar at about the middle of the fore-arm, and divides into a deep and a superficial branch; the former accompanies the ulnar artery,

Fig. 155. A view of the nerves on the dorsal aspect of the fore-arm and hand. 1, 1. The ulnar nerve. 2, 2. The posterior interosseous nerve. 3. Termination of the *nervus cutaneus humeri*. 4. The *dorsalis carpi*, a branch of the radial nerve. 5, 5. A back view of the digital nerves. 6. Dorsal branch of the ulnar nerve.



and the latter pierces the deep fascia and communicates with the internal cutaneous nerve.

The *Dorsal branch* passes beneath the tendon of the flexor carpi ulnaris, at the lower third of the fore-arm, and divides into branches which supply the integument and two fingers and a half on the posterior aspect of the hand, and communicate with the radial nerve.

The *Superficial palmar branch* divides into three filaments, which are distributed,—*one* to the ulnar side of the little finger, *one* to the adjoining borders of the little and ring fingers, and a communicating branch to join the median nerve.

The *Deep palmar branch* passes between the abductor and flexor minimi digiti, to the deep palmar arch, supplying the muscles of the little finger, and the lumbricales and interossei in the palm of the hand.

The MUSCULO-SPIRAL NERVE, the largest branch of the brachial plexus, arises from the posterior part of the plexus by a common trunk with the circumflex nerve. It passes downwards from its origin in front of the tendons of the latissimus dorsi and teres major muscle, and winds around the humerus in the spiral groove, accompanied by the superior profunda artery, to the space between the brachialis anticus and supinator longus muscle, and thence onwards to the bend of the elbow, where it divides into two branches, the posterior interosseous and radial nerve.

The *Branches* of the musculo-spiral nerve are,—

Muscular,
Spiral cutaneous,
Radial,
Posterior interosseous.

The *Muscular branches* are distributed to the triceps, to the supinator longus, and to the extensor carpi radialis longior.

The *Spiral cutaneous nerve* pierces the deep fascia immediately below the insertion of the deltoid muscle, and passes down the outer side of the fore-arm as far as the wrist. It is distributed to the integument.

The *Radial nerve* runs along the radial side of the fore-arm to the commencement of its lower third; it then passes beneath the tendon of the supinator longus, and at about two inches above the wrist-joint divides into an external and an internal branch. The *external branch*, the smaller of the two, is distributed to the outer border of the hand and of the thumb. The *internal branch* crosses the direction of the extensor tendons of the thumb and divides into several filaments for the supply of the ulnar border of the thumb, the radial border of the index finger, and the adjoining borders of the index and middle fingers. It communicates on the back of the hand with the dorsal branch of the ulnar nerve.

In the upper third of the fore-arm the radial nerve lies beneath the border of the supinator longus muscle. In the middle third it is in relation with the radial artery lying to its outer side. It then

quits the artery, and passes beneath the tendon of the supinator longus, to reach the back of the hand.

The *Posterior interosseous nerve* separates from the radial at the bend of the elbow, pierces the supinator brevis muscle, and emerges from its lower border on the posterior aspect of the fore-arm, where it divides into branches which supply the whole of the muscles on the posterior aspect of the fore-arm. One branch, longer than the rest, descends to the posterior part of the wrist, and forms a large gangliform swelling (the common character of nerves which supply joints), from which numerous branches are distributed to the wrist-joint.

The *CIRCUMFLEX NERVE* arises from the posterior part of the brachial plexus by a common trunk with the musculo-spiral nerve. It passes downwards over the border of the subscapularis muscle, winds around the neck of the humerus, with the posterior circumflex artery, and terminates by dividing into numerous branches which supply the deltoid muscle.

The *Branches* of the circumflex nerve are muscular and cutaneous. The *Muscular* branches are distributed to the subscapularis, teres minor, teres major, latissimus dorsi, and deltoid. The *cutaneous* branches pierce the deltoid muscle and are distributed to the integument of the shoulder. One of these cutaneous branches, larger than the rest, winds around the posterior border of the deltoid, and divides into filaments which pass in a radiating direction across the shoulder and are distributed to the integument.

DORSAL NERVES.

The dorsal nerves are twelve in number on each side; the first appears between the first and second dorsal vertebra, and the last between the twelfth dorsal and first lumbar. Each nerve, as soon as it has escaped from the intervertebral foramen, divides into two branches; a dorsal branch and the true intercostal nerve.

The *Dorsal branches* pass directly backwards between the transverse processes of the vertebræ, lying internally to the anterior costo-transverse ligament, where each nerve divides into a muscular and a musculo-cutaneous branch. The *muscular branch* enters the substance of the muscles in the direction of a line corresponding with the interval of separation between the longissimus dorsi and sacro-lumbalis, and is distributed to the muscles of the back. The *musculo-cutaneous* branch passes inwards, crossing the semispinalis dorsi to the spinous processes of the dorsal vertebræ; it then pierces the aponeurosis of origin of the trapezius and latissimus dorsi, and divides into branches which are inclined outwards beneath the integument to which they are distributed. The posterior branch of the *first dorsal nerve* resembles in its mode of distribution the posterior branches of the last cervical. The posterior branches of the *four last dorsal nerves* pass obliquely downwards and outwards into the substance of the erector spinæ in the situation of the interspace between the sacro-lumbalis and longissimus dorsi. After supplying

the erector spinæ and communicating freely with each other they approach the surface along the outer border of the sacro-lumbalis, where they pierce the aponeuroses of the transversalis, internal oblique, serratus posticus inferior, and latissimus dorsi muscle, and divide into *internal branches* which supply the integument upon the middle line in the lumbar region, and *external branches* which are distributed to the integument upon the side of the lumbar and in the gluteal region.

The *Intercostal nerves* receive one or two filaments from the adjoining ganglia of the sympathetic, and pass forwards in the intercostal space with the intercostal vessels, lying below the veins and artery. At the termination of the intercostal spaces near to the sternum, the nerves pierce the intercostal and pectoral muscles, and incline downwards and outwards to be distributed to the integument of the mamma and front of the chest. Those which are situated between the false ribs pass behind the costal cartilages, and between the transversalis and obliquus internus muscles; and supply the rectus and the integument on the front of the abdomen. The first and last dorsal nerves are exceptions to this distribution. The anterior branch of the first dorsal nerve divides into two branches; a smaller, which takes its course along the under surface of the first rib to the sternal extremity of the first intercostal space; and a larger, which crosses obliquely the neck of the first rib, to join the brachial plexus. The last dorsal nerve, next in size to the first, sends a branch of communication to the first lumbar nerve, to assist in forming the lumbar plexus.

The *Branches* of each intercostal nerve are a *muscular* twig to the intercostal and neighbouring muscles, and a *cutaneous* branch which is given off at about the middle of the arch of the rib. The first dorsal nerve has no cutaneous branch. The cutaneous branches of the second and third intercostal nerves are named, from their origin and distribution, *intercosto-humeral*.

The *First intercosto-humeral nerve* is of large size; it pierces the external intercostal muscle of the second intercostal space, and divides into an internal and an external branch. The *internal branch* is distributed to the integument of the inner side of the arm. The *external branch* communicates with the nerve of Wrisberg, and divides into filaments which supply the integument upon the inner and posterior aspect of the arm as far as the elbow. This nerve sometimes takes the place of the nerve of Wrisberg.

The *Second Intercosto-humeral nerve* is much smaller than the preceding; it emerges from the external intercostal muscle of the third intercostal space between the serrations of the serratus magnus muscle, and divides into filaments which are distributed to the integument of the shoulder. One of these filaments may be traced inwards to the integument of the mamma.

The cutaneous branches of the *fourth* and *fifth* intercostal nerve send twigs to the integument of the mammary gland. The *cutaneous branches* of the remaining intercostal nerves reach the surface

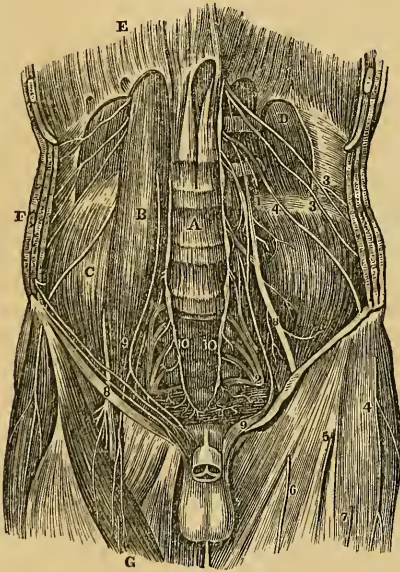
between the serrations of the serratus magnus muscle above and the external oblique below, and each nerve divides into an *anterior* and a *posterior* branch; the former being distributed to the integument of the antero-lateral, and the latter to that of the lateral part of the trunk.

The cutaneous branch of the *last dorsal nerve* is remarkably large; it pierces the internal and external oblique muscles, crosses the crest of the ilium, and is distributed to the integument of the gluteal region.

LUMBAR NERVES.

There are five pairs of lumbar nerves, of which the first makes its appearance between the first and second lumbar vertebra, and the last between the fifth lumbar and the base of the sacrum. The *anterior*

Fig. 156.



branches increase in size from above downwards, and form the lumbar plexus. The *posterior* branches diminish in size from above downwards; they form loops of communication with each other, and are distributed to the muscles of the lumbar region, and to the integument over the sacrum in the same manner with the posterior branches of the lower dorsal nerves.

The *lumbar plexus* is formed by the communications and anastomoses which take place between the anterior branch of the last dorsal and of the five lumbar nerves.

It is narrow above and increases in breadth inferiorly, is situated between the transverse processes of the lumbar vertebræ and the psoas magnus muscle, and receives filaments of communication from the lumbar ganglia of the sympathetic.

Fig. 156. A view of the lumbar and ischiatic plexus and the branches of the former. A. The bodies of the lumbar vertebræ. B. The psoas magnus muscle. C. The iliacus internus muscle. D. The quadratus lumborum muscle. E. The diaphragm. F. The three broad muscles of the abdomen. G. The sartorius. 1. The lumbar plexus. 2. The ischiatic plexus. 3, 3. Abdomino-erural nerves. 4. External cutaneous nerve (inguino-cutaneous). 5, 6, 7. Cutaneous branches from (8). The anterior erural nerve. 9. The genito-erural nerve or *spermaticus externus*. 10, 10. The lower termination of the great sympathetic.

The *Branches of the lumbar plexus* are the

Musculo-cutaneous,
 External-cutaneous,
 Genito-crural,
 Crural,
 Obturator,
 Lumbo-sacral.

The *Musculo-cutaneous nerves*, two in number, superior and inferior, proceed from the first lumbar nerve. The *superior musculo-cutaneous nerve* (ilio-scrotal) passes outwards between the posterior fibres of the psoas magnus, and crosses obliquely the quadratus lumborum muscle to the crest of the ilium. It then pierces the transversalis muscle, winds along the crest of the ilium between the transversalis and internal oblique, and divides into two branches, abdominal and scrotal. The *abdominal branch* is continued forwards parallel with the last intercostal muscle to the rectus muscle, to which it is distributed, sending a branch forwards to the integument of the abdomen. The *scrotal branch* opposite the anterior superior spinous process of the ilium, communicates with the inferior musculo-cutaneous nerve, and escapes at the external abdominal ring, with the spermatic cord in the male, and with the round ligament in the female. It is distributed to the integument of the front of the os pubis and of the groin, to the scrotum in the male and to the greater labium in the female. The *inferior musculo-cutaneous nerve* also arises from the first lumbar nerve. It is much smaller than the preceding, crosses the quadratus lumborum below it, and takes the same course along the crest of the ilium. It terminates, either by communicating with the superior nerve, or by escaping with it through the external abdominal ring and following the same distribution.

The *External cutaneous nerve* (inguino-cutaneous) proceeds from the second lumbar nerve. It pierces the posterior fibres of the psoas muscle; and crossing the iliacus obliquely, lying beneath the iliac fascia to the anterior superior spinous process of the ilium, passes into the thigh beneath Poupart's ligament. It then pierces the fascia lata at about two inches below the anterior superior spine of the ilium, and divides into two branches, anterior and posterior. The *posterior branch* crosses the tensor vaginæ femoris muscle to the outer and posterior side of the thigh, and supplies the integument in that region. The *anterior nerve* divides into two branches which are distributed to the integument upon the outer border of the thigh, and to the articulation of the knee.

The *Genito-crural* proceeds also from the second lumbar nerve. It traverses the psoas magnus from behind forwards, and runs down on the anterior surface of that muscle and beneath its fascia to near Poupart's ligament, where it divides into a genital and a crural branch. The *genital branch* crosses the external iliac artery to the internal abdominal ring, and descends along the spermatic

canal, lying behind the cord to the scrotum, where it divides into branches which supply the spermatic cord and cremaster in the male, and the round ligament in the female. At the internal abdominal ring this nerve sends some filaments to the lower border of the internal oblique and transversalis muscle. The *crural branch* enters the sheath of the femoral vessels in front of the femoral artery. It pierces the sheath below Poupart's ligament, and is distributed to the integument of the anterior aspect of the thigh as far as its middle. This nerve often communicates with a cutaneous branch of the crural nerve in the thigh.

The CRURAL, or FEMORAL NERVE, is the largest of the divisions of the lumbar plexus; it is formed by the union of the branches from the second, third, and fourth lumbar nerves, and, emerging from beneath the psoas muscle, passes downwards in the groove between it and the iliacus, and beneath Poupart's ligament into the thigh, where it spreads out and divides into numerous branches. At Poupart's ligament it is separated from the femoral artery by the breadth of the psoas muscle, which at this point is scarcely more than half an inch in diameter, and by the iliac fascia, beneath which it lies.

Fig. 157.



Branches.—While situated within the pelvis the crural nerve gives off several muscular branches to the iliacus and psoas. On emerging from beneath Poupart's ligament the nerve becomes flattened and divides into numerous branches, which may be arranged into,—

Cutaneous,
Muscular,
Branch to the femoral sheath,
Short saphenous nerve,
Long saphenous nerve.

The *Cutaneous branches* are four or five in number; they pierce the fascia lata at irregular distances below Poupart's ligament, and are distributed to the integument on the front and inner side of the thigh, constituting the middle and internal cutaneous nerves. Two of these nerves pass through the sartorius muscle before becoming cutaneous.

Fig. 157. A view of the anterior crural nerve and branches. 1. Place of emergence of the nerve under Poupart's ligament. 2. Division of the nerve into branches. 3. Femoral artery. 4. Femoral vein. 5. Branches of obturator nerve. 6. *Nervus saphenus*.

The *Muscular branches* are several large twigs which are distributed to the muscles on the anterior aspect of the thigh. Two or three of these branches are sent to the sartorius; one to the tensor vaginæ femoris, one to the rectus, one to the vastus externus, and one of very large size to the vastus internus and cruræus. The latter sends off a cutaneous branch and several filaments to the periosteum of the lower part of the femur, and to the articulation of the knee.

The *Branch to the femoral sheath* is a small nerve which passes inwards to the sheath of the femoral vessels at the upper part of the thigh, and divides into several filaments which surround the femoral and profunda vessels. Two of these filaments, one from the front, and the other from the posterior part of the sheath, unite to form a small nerve which escapes from the saphenous opening and passes downwards with the saphenous vein. Other filaments are distributed to the adductor muscles, and communicate with the internal saphenous nerve.

The *Short saphenous nerve* inclines inwards to the sheath of the femoral vessels, and divides into a superficial and a deep branch. The *superficial branch* passes downwards along the inner border of the sartorius muscle to the lower third of the thigh, it then joins the internal saphenous vein and accompanies that vessel to the knee-joint, where it terminates by communicating with the long saphenous nerve. The *deep branch* descends upon the outer side of the sheath of the femoral vessels, and crosses the sheath at its lower part to a point opposite to the termination of the femoral artery, where it divides into several filaments, which constitute a *plexus* by their communication with other nerves. One of these filaments communicates with the descending branch of the obturator nerve, another with the long saphenous nerve, and two or three are distributed to the integument upon the internal and posterior aspect of the thigh.

The *Long saphenous nerve* inclines inwards to the sheath of the femoral vessels, and entering the sheath accompanies the femoral artery to the tendinous canal formed by the adductor longus and vastus internus muscles. It then quits the artery, and, passing between the tendons of the sartorius and gracilis, descends along the inner side of the leg with the internal saphenous vein, crosses in front of the inner ankle, and is distributed to the integument on the inner side of the foot as far as the great toe.

The internal saphenous nerve receives at its upper part a large branch of communication from the obturator nerve, and another at the inner side of the knee-joint. In its course it gives off an *articular branch* for the supply of the synovial membrane of the knee-joint, and several cutaneous nerves; one to the integument of the thigh; one, of large size, which pierces the lower part of the sartorius and distributes filaments to the integument of the knee, and some to the integument of the leg, of the inner ankle, and of the inner side of the foot.

The *Obturator nerve* is formed by a branch from the third, and

another from the fourth lumbar nerve. It passes downwards in the fibres of the psoas muscle through the angle of bifurcation of the common iliac vessels, and along the inner border of the brim of the pelvis, to the obturator foramen, where it joins the obturator artery. Having escaped from the pelvis it gives off two small branches to the obturator externus muscle, and divides into four branches,—*three anterior*, which pass in front of the adductor brevis, supplying that muscle, the pectineus, the adductor longus, and the gracilis; and a *posterior* branch, which passes downwards behind the adductor brevis, and ramifies in the adductor magnus.

From the branch which supplies the adductor brevis, a *communicating filament* passes outwards through the angle of bifurcation of the femoral vessels to unite with the long saphenous nerve. From the branch to the adductor longus a long *cutaneous nerve* proceeds, which issues from beneath the inferior border of that muscle, sends filaments of communication to the plexus of the short saphenous nerve, and descends to the inner side of the knee, where it pierces the fascia and communicates with the long saphenous nerve. It is distributed to the integument upon the inner side of the leg. From the posterior branch an *articular branch* is given off, which pierces the adductor magnus muscle, accompanies the popliteal artery, and is distributed to the synovial membrane of the knee-joint on its posterior aspect.

The *Lumbo-sacral nerve*.—The anterior division of the fifth lumbar nerve, conjoined with a branch from the fourth, constitutes the lumbo-sacral nerve, which descends over the base of the sacrum into the pelvis, and assists in forming the sacral plexus.

SACRAL NERVES.

There are six pairs of sacral nerves; the first escapes from the vertebral canal through the first sacral foramina, and the two last between the sacrum and coccyx. The *posterior sacral nerves* are very small and diminish in size from above downwards; they communicate with each other immediately after their escape from the posterior sacral foramina, and divide into branches which are distributed to the muscles and integument in the sacral and gluteal region. The *anterior sacral nerves* diminish in size from above downwards; the *first* is of large size and unites with the lumbo-sacral nerve; the *second*, of equal size, unites with the preceding; the *third*, which is scarcely one-fourth the size of the second, also joins with the preceding nerves in the formation of the sacral plexus; the *fourth* is about one-third the size of the preceding sacral nerve; it divides into several branches, one of which is sent to the sacral plexus, a second to join the fifth sacral nerve, a third to the viscera of the pelvis, communicating with the hypogastric plexus, and a fourth to the coccygeus muscle, and to the integument around the anus. The *fifth* anterior sacral nerve presents about half the size of the fourth; it divides into two branches, one of which communicates

with the fourth, the other with the sixth. The *sixth* sacral nerve is exceedingly small; it gives off an ascending filament which is continuous with the communicating branch of the fifth; and a descending filament which passes downwards by the side of the coccyx and traverses the fibres of the great sacro-ischiatic ligament to be distributed to the gluteus maximus and to the integument. All the anterior sacral nerves receive branches from the sacral ganglia of the sympathetic at their emergence from the sacral foramina.

The *Sacral plexus* is formed by the lumbosacral, and by the anterior branches of the four upper sacral nerves. The plexus is triangular in form, the base corresponding with the whole length of the sacrum, and the apex with the lower part of the great ischiatic foramen. It is in relation behind with the pyriformis muscle, and in front with the pelvic fascia, which separates it from the branches of the internal iliac artery, and from the viscera of the pelvis.

The *Branches* of the sacral plexus are divisible into the *internal* and the *external*; they may be thus arranged :

Internal.
Visceral,
Muscular.

External.
Muscular,
Gluteal,
Internal pudic,
Lesser ischiatic,
Greater ischiatic.

The *Visceral nerves* are three or four large branches which are derived from the fourth and fifth sacral nerves: they ascend upon the side of the rectum and bladder; in the female upon the side of the rectum, the vagina and the bladder; and interlace with the branches of the hypogastric plexus, sending in their course numerous filaments to those viscera.

The *Muscular branches* given off within the pelvis are one or two twigs to the levator ani; an obturator branch which curves around the spine of the ischium to reach the internal surface of the obturator internus muscle; and an hæmorrhoidal nerve, which descends to

Fig. 158.

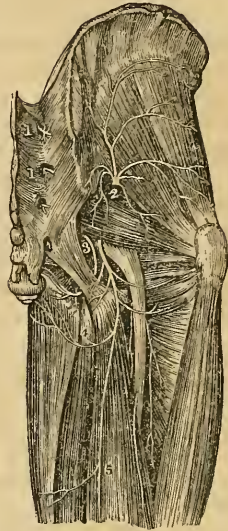

Fig. 158. A view of the branches of the ischiatic plexus to the hip and back of the thigh. 1, 1. Posterior sacral nerves. 2. *Nervi glutei*. 3. The internal pudic nerve, (*nervus pudendalis longus superior*). 4. The lesser ischiatic nerve, giving off the perineal cutaneous (*pudendalis longus inferior*,) and 5. The *ramus femoralis cutaneus posterior*. The reference to the great ischiatic has been omitted. It is seen to the right of 3.

the termination of the rectum, to supply the sphincter and the integument.

The *Muscular branches* supplied by the sacral plexus externally to the pelvis are, a branch to the pyramidalis; a branch to the gemellus superior; and a branch of moderate size which descends between the gemelli muscles and the ischium, and is distributed to the gemellus inferior, the quadratus femoris, and to the capsule of the hip-joint.

The *Gluteal nerve* is a branch of the lumbo-sacral; it passes out of the pelvis with the gluteal artery, through the great sacro-ischiatic foramen, and divides into a superior and an inferior branch. The *superior* branch follows the direction of the superior curved line of the ilium, accompanying the deep superior branch of the gluteal artery, and sending filaments to the gluteus medius and minimus. The *inferior* passes obliquely downwards and forwards between the gluteus medius and minimus, distributing numerous filaments to both, and terminates in the tensor vaginæ femoris muscle.

The *Internal pudic nerve* arises from the lower part of the sacral plexus, passes out of the pelvis through the great sacro-ischiatic foramen below the pyriformis muscle, and takes the course of the internal pudic artery. While situated beneath the obturator fascia it lies below that vessel and divides into a superior and an inferior branch. The *superior nerve* ascends upon the posterior surface of the ramus of the ischium, pierces the deep perineal fascia and accompanies the arteria dorsalis penis to the glans to which it is distributed. At the root of the penis this nerve gives off a cutaneous branch which runs along the side of the organ, and with its fellow of the opposite side supplies the integument of the upper two-thirds of the penis and of the prepuce. The *inferior* or *perineal nerve* pursues the course of the internal pudic artery in the perineum and sends off three principal branches,—1, an external perineal nerve which ascends upon the outer side of the crus penis, and supplies the scrotum; 2, a superficial perineal nerve which accompanies the artery of that name and distributes filaments to the scrotum, to the integument of the under part of the penis and to the prepuce; 3, the nerve of the bulb, which sends twigs to the sphincter ani, to the transversus perinei, and accelerator urinæ, and terminates by ramifying in the corpus spongiosum.

In the female, the internal pudic nerve is distributed to the parts analogous to those of the male. The *superior branch* supplies the clitoris; and the *inferior* the parts in the perineum and the vulva.

The *Lesser ischiatic nerve* passes out of the pelvis through the great sacro-ischiatic foramen below the pyriformis muscle, and divides into muscular and cutaneous branches. The muscular branches—*inferior gluteal*—are distributed to the gluteus maximus: some ascending in the substance of that muscle to its upper border, and others descending. The cutaneous branches are two in number,—the perineal cutaneous and the middle posterior cutaneous. The *perineal cutaneous nerve* (pudendalis longus inferior; Soem.)

curves around the tuberosity of the ischium and ascends in a direction parallel to the ramus of the ischium and os pubis to the scrotum, where it communicates with the superficial perineal nerve, and divides into an internal and an external branch. The internal branch passing down upon the inner side of the testis to the scrotum; the external branch to its outer side, and both terminating in the integument of the under border of the penis. The *middle posterior cutaneous nerve* crosses the tuberosity of the ischium, and pierces the deep fascia at the lower border of the gluteus maximus. It then passes downwards along the middle of the posterior aspect of the thigh, and of the popliteal region, and is distributed to the integument as far as the middle of the calf of the leg. In its course the nerve gives off several cutaneous branches to the integument upon the inner and outer side of the thigh, and in the popliteal region a communicating branch which pierces the fascia of the leg and unites with the external saphenous nerve.

The GREAT ISCHIATIC NERVE is the largest nervous cord in the body; it is formed by the sacral plexus, or rather it is a prolongation of the plexus, and at its exit from the great sacro-ischiatic foramen beneath the pyriformis muscle measures three quarters of an inch in breadth. It descends through the middle of the space between the trochanter major and tuberosity of the ischium, and along the posterior part of the thigh to about its lower third, where it divides into two large terminal branches, popliteal and peroneal. This division sometimes takes place at the plexus, and the two nerves descend together side by side; occasionally they are separated at their commencement by a part or the whole of the pyriformis muscle. The nerve in its course down the thigh rests upon the gemellus superior, tendon of the obturator internus, gemellus inferior, quadratus femoris, and adductor magnus muscle, and is covered in by the gluteus maximus, and by the biceps and semitendinosus muscle.

The *Branches* of the great ischiatic nerve, previously to its division, are muscular and articular. The *muscular* branches are given off from the upper part of the nerve, and supply the biceps, the semi-tendinosus, the semi-membranosus, and the adductor magnus. The *articular* branch descends to the upper part of the external condyle of the femur, and divides into filaments which are distributed to the fibrous capsule and to the synovial membrane of the knee-joint.

The POPLITEAL NERVE passes through the middle of the popliteal space, from the division of the great ischiatic nerve to the lower border of the popliteus muscle, where it passes with the artery beneath the arch of the soleus, and becomes the posterior tibial nerve. It is superficial in the whole of its course, and lies externally to the vein and artery.

The *Branches* of the popliteal nerve are muscular or sural and articular, and a cutaneous branch, the communicans poplitei.

The *Muscular branches*, of considerable size, and four or five in

number, are distributed to the two heads of the gastrocnemius, to the soleus, to the plantaris, and to the popliteus.

Fig. 159.

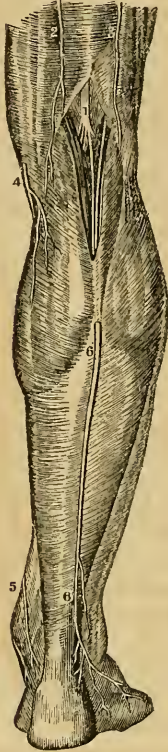


Fig. 160.



The *Articular nerve* pierces the ligamentum posticum Winslowi, and supplies the interior of the knee-joint. It usually sends a twig to the popliteus muscle.

The *Communicans poplitei* is a large nerve which arises from the popliteal at about the middle of its course, and descends between the two heads of the gastrocnemius, and along the groove formed by the two bellies of that muscle; at a variable distance below the articulation of the knee it receives a large branch, the *communicans peronei*, from the peroneal nerve, and the two together constitute the external saphenous nerve.

The *External saphenous nerve* pierces the deep fascia below the

Fig. 159. A view of some of the branches of the popliteal nerve. 1. The popliteal nerve. 2, 3. The terminations of the *ramus femoralis cutaneus posterior*. 4, 5. The saphenous nerve. 6, 6. The external saphenous or *communicans tibiæ*.

Fig. 160. A view of the posterior tibial nerve in the back of the leg. 1 and 2, indicate its course, the upper part of the peroneal nerve being seen to the right.

fleshy part of the gastrocnemius muscle, and continues its course down the leg, lying along the outer border of the tendo Achillis and by the side of the external saphenous vein, which it accompanies to the foot. At the lower part of the leg it winds around the outer malleolus, and is distributed to the outer side of the foot and of the little toe, communicating with the external peroneal cutaneous nerve, and sending numerous filaments to the integument of the heel and of the sole of the foot.

The POSTERIOR TIBIAL NERVE is continued along the posterior aspect of the leg from the lower border of the popliteus muscle to the posterior part of the inner ankle, where it divides into the internal and external plantar nerve. In the upper part of its course it lies to the outer side of the posterior tibial artery; it then becomes placed superficially to that vessel, and at the ankle is again situated to its outer side; in the lower third of the leg it lies parallel with the inner border of the tendo Achillis.

The *Branches* of the posterior tibial nerve are three or four *muscular* twigs to the deep muscles of the posterior aspect of the leg; the branch to the flexor longus pollicis accompanies the fibular artery; one or two filaments which entwine around the artery and then terminate in the integument;* and some cutaneous branches which pass downwards upon the inner side of the os calcis and are distributed to the integument of the heel.

The *Internal plantar nerve*, larger than the external, crosses the posterior tibial vessels to enter the sole of the foot, where it lies in the interspace between the abductor pollicis and flexor brevis digitorum; it then enters the sheath of the latter muscle, and divides opposite the bases of the metatarsal bones into three digital branches; *one* to supply the adjoining sides of the great and second toe; the *second* to the adjoining sides of the second and third toe; and the *third* to the third and fourth toes. The distribution is precisely similar to that of the digital branches of the median nerve.

In its course the internal plantar nerve gives off *cutaneous branches* to the integument of the inner side and sole of the foot; *muscular*

Fig. 161.

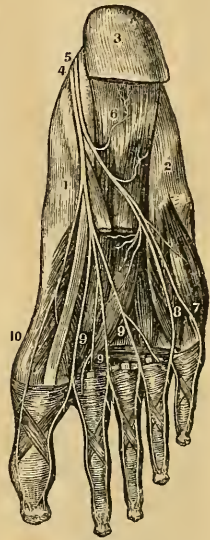


Fig. 161. A view of the termination of the posterior tibial nerve in the sole of the foot. 1. Inside of the foot. 2. Outer side. 3. Heel. 4. Internal plantar nerve. 5. External plantar nerve. 6. Branch to flexor brevis. 7. Branch to outside of little toe. 8. Branch to space between 4th and 5th toes. 9, 9, 9. Digital branches to remaining spaces. 10. Branch to internal side of great toe.

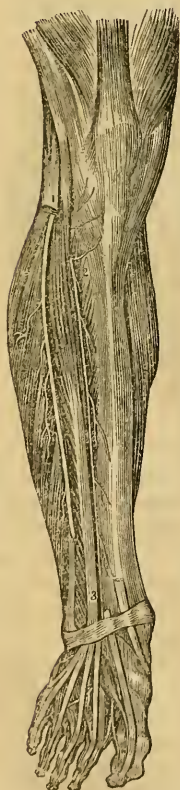* It is extremely interesting in a physiological point of view, to observe the mode of distribution of these filaments. I have traced them in relation with several, and I have no doubt that they exist in connexion with all the superficial arteries. They seem to be the direct *monitors* to the artery of the presence or approach of danger.

branches to the muscles forming the inner and middle group of the sole; a *digital* branch, to the inner border of the great toe; and *articular* branches to the articulations of the tarsal and metatarsal bones.

The *External plantar nerve*, the smaller of the two, follows the course of the external plantar artery to the outer border of the *musculus accessorius*, beneath which it sends several large muscular branches to supply the abductor pollicis and the articulations of the tarsal and metatarsal bones. It then gives branches to the integument of the outer border and sole of the foot, and sends forward two digital branches to supply the little toe and one half the next.

The PERONEAL NERVE is one half smaller than the popliteal; it passes downwards by the side of the tendon of the biceps, crossing the inner head of the *gastrocnemius* and the origin of the soleus, to the neck of the fibula, where it pierces the origin of the *peroneus longus* muscle, and divides into two branches, the anterior tibial and musculo-cutaneous.

Fig. 162.



The *Branches* of the peroneal nerve previously to its division are, the *communicans peronei*, cutaneous, and muscular. The *communicans peronei*, much smaller than the *communicans poplitei*, crosses the external head of the *gastrocnemius* to the middle of the leg. It there sends a large branch to join the *communicans poplitei* and constitute the external saphenous nerve, and descends very much reduced in size by the side of the external saphenous vein to the side of the external ankle, to which and to the integument of the heel it distributes filaments. The *cutaneous* branch descends in the integument upon the outer side of the leg, in which it ramifies. The *muscular* branches proceed from near the termination of the peroneal nerve; they are distributed to the upper part of the *tibialis anticus*.

The *Anterior tibial nerve* commences at the bifurcation of the peroneal, upon the head of the fibula, and passes beneath the upper part of the *extensor longus digitorum*, to reach the outer side of the anterior tibial artery, just as that vessel has emerged through the opening in the interosseous membrane. It descends the anterior aspect of the leg with the artery; lying at first to its outer side, and then

Fig. 162. A view of the anterior tibial nerve. 1. The peroneal nerve. 2, 3. The anterior tibial nerve accompanying the artery of the same name.

in front of it, and near the ankle becomes again placed to its outer side. Reaching the ankle it passes beneath the annular ligament; it accompanies the dorsalis pedis artery, supplies the adjoining sides of the great and second toes, and communicates with the internal peroneal cutaneous nerve.

The *Branches* given off by the anterior tibial nerve are, *muscular* to the muscles in its course, and on the foot a *tarsal* branch, which passes beneath the extensor brevis digitorum, and distributes filaments to the interossei muscles and to the articulations of the tarsus and metatarsus.

The *Musculo-cutaneous* nerve passes downwards in the direction of the fibula, in the substance of the peroneus longus; it then passes forwards to get between the peroneus longus and brevis, and at the lower third of the leg pierces the deep fascia, and divides into two peroneal cutaneous branches. In its course it gives off several branches to the peronei muscles.

The *Peroneal cutaneous* nerves pass in front of the ankle-joint, and are distributed to the integument of the foot and of the toes; the external supplying three toes and a half, and the internal one and a half. They communicate with the saphenous and anterior tibial nerve. The external saphenous nerve frequently supplies the fifth toe and the adjoining side of the fourth.

SYMPATHETIC SYSTEM.

The *Sympathetic system* consists of a series of ganglia, extending along each side of the vertebral column from the head to the coccyx, communicating with all the other nerves of the body, and distributing branches to all the internal organs and viscera.

It communicates with the other nerves immediately at their exit from the cranium and vertebral canal. The fourth and sixth nerves, however, form an exception to this rule; for with these it unites in the cavernous sinus; and with the olfactory, optic, and auditory, at their ultimate expansions.

The branches of distribution accompany the arteries which supply the different organs, and form communications around them, which are called *plexuses*, and take the name of the artery with which they are associated: thus we have the mesenteric plexus, hepatic plexus, splenic plexus, &c. All the *internal organs* of the head, neck, and trunk are supplied with branches from the sympathetic, and some of them exclusively; hence it is considered a nerve of *organic life*.

It is called the *ganglionic nerve* from the circumstance of being formed by a number of *ganglia*; and from the constant disposition which it evinces in its distribution, to communicate and form small knots or ganglia.

There are *six* sympathetic ganglia in the head: viz., the *ganglion of Ribes*; the *ciliary* or lenticular; the *naso-palatine*, or Cloquet's; the *spheno-palatine*, or Meckel's; the *submaxillary*; and the *otic*, or Arnold's: *three* in the *neck*; *superior*, *middle*, and *inferior*: *twelve*

in the *dorsal region*; *four* in the *lumbar region*; and *four or five* in the *sacral region*.

Each ganglion may be considered as a *distinct centre*, giving off branches in four different directions, viz., *superior* or *ascending*, to communicate with the ganglion above; *inferior* or *descending*, to communicate with the ganglion below; *external*, to communicate with the spinal nerves; and *internal*, to communicate with the sympathetic filaments of the opposite side, and to be distributed to the viscera.

CRANIAL GANGLIA.

Ganglion of Ribes,
Ciliary, or lenticular ganglion,
Naso-palatine, or Cloquet's ganglion,
Spheno-palatine, or Meckel's ganglion,
Submaxillary ganglion,
Otic, or Arnold's ganglion.

Fig. 163.

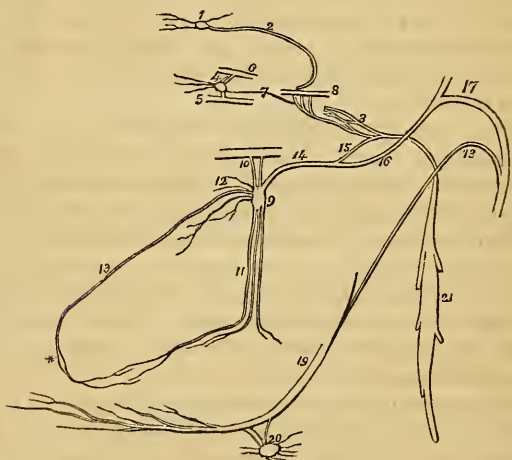


Fig. 163. The cranial ganglia of the sympathetic nerve. 1. The ganglion of Ribes. 2. The filament by which it communicates with the carotid plexus (3). 4. The ciliary or lenticular ganglion, giving off ciliary branches for the supply of the globe of the eye. 5. Part of the inferior division of the third nerve, receiving a short thick branch from the ganglion. 6. Part of the nasal nerve, receiving a longer branch from the ganglion. 7. A slender filament sent directly backwards from the ganglion to the sympathetic branches in the cavernous sinus. 8. Part of the sixth nerve in the cavernous sinus, receiving two branches from the carotid plexus. 9. Meckel's ganglion (spheno-palatine). 10. Its ascending branches, communicating with the superior maxillary nerve. 11. Its descending branches, the posterior palatine. 12. Its anterior branches, spheno-palatine or nasal. 13. The naso-palatine branch, one of the nasal branches. * The swelling which Cloquet imagines to be a ganglion. 14. The posterior branch of the ganglion, the Vidian nerve. 15. Its carotid branch communicating with the carotid plexus. 16. Its petrosal branches, joining the angular bend of the facial nerve. 17. The facial nerve. 18. The chorda tympani nerve, which descends to join the gustatory nerve. 19. The gustatory nerve. 20. The submaxillary ganglion, receiving the chorda tympani nerve from the gustatory. 21. The superior cervical ganglion of the sympathetic.

1. THE GANGLION OF RIBES is a small ganglion situated upon the anterior communicating artery, and formed by the union of the sympathetic filaments, which accompany the ramifications of the two anterior cerebral arteries. These filaments are derived from the carotid plexus at each side; and through their intervention, the ganglion of Ribes is brought into connexion with the carotid plexus, and with the other ganglia of the sympathetic. This ganglion, though of very small size, is interesting, as being the superior point of union between the sympathetic chains of opposite sides of the body.

2. The CILIARY GANGLION (*lenticular*) is a small quadrangular and flattened ganglion situated within the orbit, between the optic nerve and the external rectus muscle; it is in close contact with the optic nerve, and is surrounded by a quantity of fat, which renders its dissection somewhat difficult.

Its *branches of distribution* are the *ciliary*, which arise from its anterior angle by two groups: the upper group, consisting of about four filaments, and the lower, of five or six. They accompany the ciliary arteries in a waving course, and divide into a number of branches which pierce the sclerotic around the optic nerve, and supply the tunics of the eyeball. A small filament is said, by Tiedemann, to accompany the arteria centralis retinæ into the centre of the globe of the eye.

Its *branches of communication* are three:—1. From the posterior superior angle of the *nasal* branch of the ophthalmic nerve. 2. A short thick branch from the posterior inferior angle to the inferior division of the *third nerve*. 3. A long filament, which passes backwards to the cavernous sinus, and communicates with the *carotid plexus*.

3. The NASO-PALATINE GANGLION (Cloquet's), is a small lengthened body, situated in the naso-palatine canal. There is no difficulty in finding it in that situation. But it is still a question whether it be actually a ganglion. Arnold refuses to admit it in his plates of the cranial nerves, and denies its existence; Cruveilhier agrees with him in opinion. Mr. Charles Guthrie, demonstrator of anatomy in the Charing-Cross School of Medicine, has recently satisfied himself of its existence and of its ganglionic nature.*

Its *branches of distribution* are, two or three small filaments to the anterior part of the palate,—*anterior palatine nerves*.

Its *branches of communication* are two long delicate filaments, which ascend upon the septum narium, beneath the mucous membrane, and pass across the posterior part of the roof of the nares, and through the spleno-palatine foramina, to terminate in the spleno-palatine ganglion at each side.

4. The SPHENO-PALATINE GANGLION (Meckel's) the largest of the cranial ganglia of the sympathetic, is very variable in its dimensions. It is situated in the spheno-maxillary fossa.

* I have several times dissected for this ganglion, and have as yet *never* failed to find it.—G.

Its branches are divisible into four groups: *ascending*, *descending*, *anterior* or *internal*, and *posterior*.

The *branches of distribution* are, the *internal* or *nasal*, four or five in number, which enter the nose through the sphenopalatine foramen, and supply the mucous membrane of the nares; and the *descending* or *posterior palatine* branches, three in number, which pass downwards through the posterior palatine canal, and are distributed to the mucous membrane of the nose and antrum maxillare, to the velum palati and to the palate.

The *branches of communication* are the *ascending*,* two small branches which pass upwards to join the superior maxillary nerve; and the *posterior branch* or *Vidian nerve*.

The *Vidian*† *nerve* passes directly backwards from the sphenopalatine ganglion, through the pterygoid or Vidian canal, to the foramen lacerum basis cranii, where it divides into two branches, the *carotid* and *petrosal*.‡ The *carotid branch* enters the carotid canal, and joins the carotid plexus. The *petrosal branch* enters the cranium through the foramen lacerum basis cranii, and passes backwards beneath the Casserian ganglion, and beneath the dura mater, lying in a groove upon the anterior surface of the petrous bone, to the hiatus Fallopii. Entering the hiatus Fallopii it immediately joins the facial nerve, just as that cord is making its angular bend, previously to winding back along the inner wall of the tympanum.§ The petrosal branch accompanies the facial nerve, along the aquæductus Fallopii, enclosed in its sheath to within a few lines of the stylo-mastoid foramen. It then quits the facial nerve, returning upon itself at an acute angle, and enters the tympanum near the base of the pyramid. It now takes the name of *chorda tympani* and crosses the tympanum enveloped in mucous membrane, between the handle of the malleus and long process of the incus to the fissura Glaseri; passing through a particular opening in this fissure it descends upon the inner side of the condyle of the lower jaw, and internally to the auricular and inferior dental nerves to the gustatory nerve, which it joins at an acute angle.|| Accompanying the

* Arnold figures, in his beautiful plates of the cranial nerves, two small ascending filaments which enter the orbit and join the optic nerve.

† Guido Guidi, latinized into Vidus Vidius, was professor of anatomy and medicine in the College of France in 1542. His work is posthumous, and was published in 1611.

‡ Or the deep and superficial petrous.—G.

§ Here two rival opinions clash; one set of anatomists, and with them Swan and Arnold, believe that the petrosal branch unites with the substance of the facial nerve; the two latter writers even go so far as to describe a ganglionic enlargement upon the facial nerve at this point, and Arnold would seem to intimate that the nerve is actually a branch of this ganglion; while another set maintain that the petrosal branch merely accompanies the facial nerve, being enclosed in its neurilemma. As the question is yet litigated, and as I am prepared with no positive proof to decide for either party, I shall at present adopt the latter view as the more convenient for description, and for explaining the connexions between the different cranial ganglia. The latter opinion has for its supporters, Cloquet, Ribes, and Hirzel.

|| Here again, the question of fusion of nervous substance, or mere contact, has been warmly agitated, but with no positive and unquestionable results.

gustatory, enclosed in its sheath, to the submaxillary gland, it quits that nerve and communicates with the submaxillary ganglion.

The petrosal branch of the Vidian nerve receives a branch from the tympanic nerve while in the hiatus Fallopii.

The Vidian nerve thus becomes the medium of communication between the speno-palatine ganglion and submaxillary ganglion; and between both of these ganglia and the carotid plexus; and through the tympanic nerve with the glosso-pharyngeal and pneumogastric nerves: and if the fusion of nervous substance be admitted between the whole of these and the facial, the auditory, and the gustatory nerves.

5. The SUBMAXILLARY GANGLION is of small size, but very distinct, and is situated in the submaxillary gland.

Its *branches of distribution* are numerous, and ramify upon the ducts of the gland, and upon Wharton's duct.

Its *branches of communication* are,—1, one or two small branches which join the gustatory nerve; and 2, several minute branches which communicate with the sympathetic filaments ramifying upon the facial artery. It is associated with the carotid plexus, and the other cranial ganglia, by means of the petrosal branch of the Vidian.

6. The OTIC GANGLION (Arnold's)* is a small red body, resting against the inner surface of the inferior maxillary nerve, immediately below the foramen ovale; it is in *relation externally* with the trunk of the inferior maxillary nerve, just at the point of union of the motor root; *internally* it rests against the cartilage of the Eustachian tube and tensor palati muscle; and *posteriorly* it is in contact with the arteria meningea magna. It is closely adherent to the internal pterygoid nerve, and appears like a swelling upon that branch.

The branches of the otic ganglion are seven in number; two of distribution, and five of communication.

The *branches of distribution* are,—1, a small filament to the tensor tympani muscle; and, 2, one to the tensor palati muscle.

The *branches of communication* are,—1, two or three small branches to the motor root of the inferior maxillary nerve; 2, two branches to the auricular nerve; 3, a filament to the facial nerve; 4, a long filament, the *nervus petrosus superficialis minor*, to communicate with the tympanic nerve (Jacobson's) in the tympanum; and, 5, one or two small branches which join the sympathetic filaments of the arteria meningea media artery.

CAROTID PLEXUS.—The ascending branch of the superior cervical ganglion enters the carotid canal with the internal carotid artery, and divides into two branches, which form several loops of communication with each other around the artery. This constitutes the *carotid plexus*. They also form frequently a small gangliform

* Frederick Arnold, "Dissertatio Inauguralis de Parte Cephalica Nervi Sympathetici." Heidelberg, 1826; and "Ueber den Ohrknoten," 1828.

swelling upon the under part of the artery, which is called the *carotid ganglion*. The latter, however, is not constant; and, as it performs no special function, we do not include it amongst the cranial ganglia of the sympathetic. The continuation of the carotid plexus onwards with the artery by the side of the sella turcica, is called the *cavernous plexus*.

The carotid plexus is the centre of communication between all the cranial ganglia; and being derived from the superior cervical ganglion, between the cranial ganglia and those of the trunk, it also communicates with the greater part of the cerebral nerves, and distributes filaments with each of the branches of the internal carotid, which accompany those branches in all their ramifications.

Thus, the *Ganglion of Ribes* is formed by the union of the filaments which accompany the anterior cerebral arteries, and which meet on the anterior communicating artery. The *ciliary ganglion* communicates with the plexus by means of the long branch which is sent back to join it in the cavernous sinus. The *spheno-palatine*, and with it the *naso-palatine ganglion*, joins the plexus by means of the carotid branch of the Vidian. The *submaxillary ganglion* is also connected with it through the Vidian. And the *otic ganglion* is brought in relation with it by means of the tympanic nerve and by the Vidian.

It communicates with the third nerve in the cavernous sinus, and through the ciliary ganglion; with the Casserian ganglion; with the *ophthalmic* division of the fifth in the cavernous sinus, and by means of the ciliary ganglion; with the superior maxillary, through the spheno-palatine ganglion; and with the inferior maxillary, through the chorda tympani and Vidian. It sends two branches directly to the sixth nerve, which unite* with it as it crosses the cavernous sinus; it communicates with the facial and auditory nerves, through the medium of the petrosal branch of the Vidian; and with the glosso-pharyngeal and pneumogastric nerves, through the *nervus petrosus superficialis minor*, a branch from the otic ganglion to the tympanic nerve.

CERVICAL GANGLIA.

The *Superior cervical ganglion* is long and fusiform, of a grayish colour, smooth, and of considerable thickness, extending from within an inch of the carotid foramen in the petrous bone to opposite the lower border of the third cervical vertebra. It is in relation in front with the sheath of the internal carotid artery and internal jugular vein; and behind with the rectus anticus major muscle.

Its *branches*, like those of all the sympathetic ganglia in the trunk, are divisible into *superior*, *inferior*, *external*, and *internal*; to which may added, as proper to this ganglion, *anterior*.

* Panizza, in his "Experimental Researches on the Nerves," denies this communication, and states very vaguely that "they are merely lost and entwined around it."—*Edinburgh Medical and Surgical Journal*, January, 1836.

The *superior* is a single branch which ascends by the side of the internal carotid, and divides into two branches; one lying to the outer side, the other to the inner side of that vessel. The two branches enter the carotid canal, and communicate by means of several filaments sent from one to the other, to constitute the *carotid plexus*.

The *inferior* or descending branch, sometimes two, is the cord of communication with the middle cervical ganglion.

The *external branches* are numerous, and may be divided into two sets: 1, Those which communicate with the glosso-pharyngeal, pneumogastric, and hypoglossal nerves; and, 2, those which communicate with the three first cervical nerves.

The *internal branches* are three in number: 1. *Pharyngeal*, to assist in forming the pharyngeal plexus; 2. *Laryngeal*, to join the superior laryngeal nerve and its branches; and, 3. The *superior cardiac nerve*, or *nervus superficialis cordis*.

The *anterior branches*

Fig. 164.

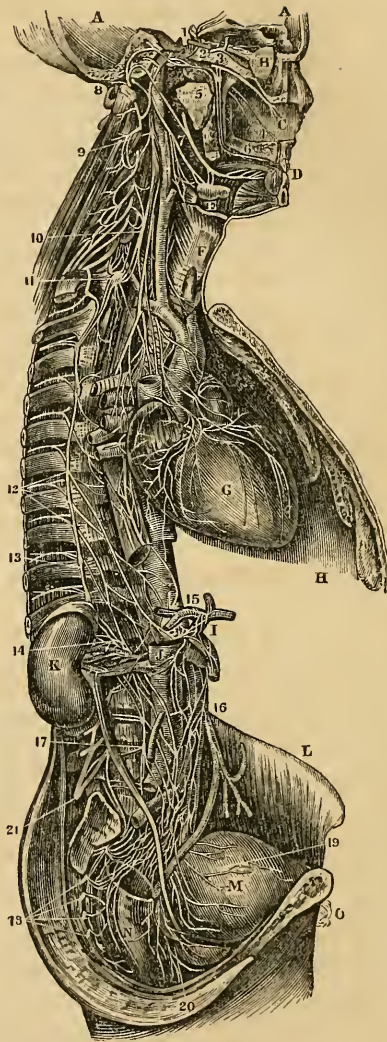


Fig. 164. A view of the great sympathetic nerve. A. The cavity of the cranium. B. The globe of the eye. C. The septum of the nose. D. The incisor teeth. E. The submaxillary gland. F. The larynx. G. The heart. H. The left lung. I. The cæliac axis. J. The ascending vena cava. K. The kidney. L. The crista of the ilium. M. The bladder. N. The rectum. O. The pubes. 1. Plexus on the carotid artery in the carotid foramen. 2. Sixth nerve, (motor externus). 3. 1st of the fifth or ophthalmic nerve. 4. Branch on the septum narium, connecting Meckel's ganglion with Cloquet's in the incisive foramen. 5. Immediately above the figure is the recurrent branch or Vidian nerve, dividing into the carotid and petrosal branches. 6. Posterior palatine branches. 7. Lingual nerve joined by the chorda tympani. 8. The portio dura of the seventh pair or facial nerve. 9. The superior cervical ganglion. 10. The middle cervical ganglion. 11. The inferior cervical ganglion. 12. The roots of the great splanchnic nerve, arising from the dorsal ganglia. 13. The lesser splanchnic nerve. 14. The renal plexus. 15. The solar plexus. 16. The mesenteric plexus. 17. The lumbar ganglia. 18. The sacral ganglia. 19. The vesical plexus. 20. The rectal plexus. 21. The lumbar plexus, (cerebro-spinal.)

accompany the carotid artery with its branches, around which they form intricate plexuses; they are called, from the softness of their texture, *nervi molles*.

The *Middle cervical ganglion* (thyroid ganglion) is of small size, and sometimes altogether wanting. It is situated opposite the fifth cervical vertebra, and rests upon the inferior thyroid artery. This relation is so constant, as to have induced Haller to name it the "thyroid ganglion."

Its *superior branch*, or branches, ascend to communicate with the superior cervical ganglion.

Its *inferior branches* descend to join the inferior cervical ganglion.

Its *external branches* communicate with the third, fourth, and fifth cervical nerves.

Its *internal branch* is the *middle cardiac nerve*, *nervus cardiacus magnus*.

The *Inferior cervical ganglion* (vertebral ganglion) is much larger than the preceding, and is constant in its existence. It is of a semilunar form, and is situated upon the base of the transverse process of the seventh cervical vertebra, immediately behind the vertebral artery: hence its title to the designation "*vertebral ganglion*."

Its *superior branches* communicate with the middle cervical ganglion.

The *inferior branches* pass some before and some behind the subclavian artery, to join the first thoracic ganglion.

The *external branches* consist of two sets; one which communicates with the sixth, seventh, and eighth cervical nerves; and one which accompanies the vertebral artery along the vertebral canal, forming the *vertebral plexus*. This plexus sends filaments to all the branches given off by the artery, and communicates in the skull with the filaments of the carotid plexus accompanying the branches of the internal carotid artery.

The *internal branch* is the *inferior cardiac nerve*, *nervus cardiacus minor*.

CARDIAC NERVES.*—The *superior cardiac nerve* (*nervus superficialis cordis*) arises from the lower part of the superior cervical ganglion; it then descends the neck behind the common carotid artery, and, parallel with the trachea, crosses the inferior thyroid artery, and accompanying the recurrent laryngeal nerve for a short distance, passes behind the *arteria innominata* to the concavity of the arch of the aorta, where it joins the *cardiac ganglion*.

In its course it receives branches from the pneumogastric nerve, and sends filaments to the thyroid gland and trachea.

The *Middle cardiac nerve* (*nervus cardiacus magnus*) proceeds from the middle cervical ganglion, or, in its absence, from the cord

* There is no constancy with regard to the origin and course of these nerves; therefore the student must not be disappointed in finding the description in discord with his dissection.

of communication between the superior and inferior. It is the largest of the three nerves, and lies nearly parallel with the recurrent laryngeal. At the root of the neck it divides into several branches, which pass some before and some behind the subclavian artery; it communicates with the superior and inferior cardiac, and with the pneumogastric and recurrent nerves, and descends to the bifurcation of the trachea, to the *great cardiac plexus*.

The *Inferior cardiac nerve* (*nervus cardiacus minor*) arises from the inferior cervical ganglion, communicates freely with the recurrent laryngeal and middle cardiac nerves, and descends to the front of the bifurcation of the trachea, to join the *great cardiac plexus*.

The *Cardiac ganglion* is a ganglionic enlargement of variable size, situated beneath the arch of the aorta, to the right side of the ligament of the ductus arteriosus. It receives the superior cardiac nerves of opposite sides of the neck, and a branch from the pneumogastric nerve, and gives off numerous branches to the cardiac plexuses.

The *Great cardiac plexus* is situated upon the bifurcation of the trachea, above the right pulmonary artery, and behind the arch of the aorta. It is formed by the convergence of the middle and inferior cardiac nerves, and by branches from the pneumogastric nerve.

The *Anterior cardiac plexus* is situated in front of the ascending aorta, near to its origin. It is formed by the communications of filaments that proceed from three different sources. 1st, from the superior cardiac nerves, crossing the arch of the aorta; 2dly, from the cardiac ganglion beneath the arch; and 3dly, from the great cardiac plexus,—passing between the ascending aorta and the right auricle. The anterior cardiac plexus supplies the anterior aspect of the heart, distributing numerous filaments with the left coronary artery, which form the *anterior coronary plexus*.

The *Posterior cardiac plexus* is formed by numerous branches from the great cardiac plexus, and is situated upon the posterior part of the ascending aorta, near to its origin. It divides into two sets of branches: one set accompanying the right coronary artery in the auriculo-ventricular sulcus; the other set joining the artery upon the posterior aspect of the heart. They both together constitute the *posterior coronary plexus*.

The great cardiac plexus likewise gives branches to the *ricueals* of the heart, and others, to assist in forming the *anterior* and *posterior pulmonary plexuses*.

THORACIC GANGLIA.

The *Thoracic ganglia* are twelve in number on each side. They are flattened and triangular, or irregular in form, and present the peculiar gray colour and pearly lustre of the other sympathetic ganglia; they rest upon the heads of the ribs, and are covered in by the pleura costalis. The two first and the last ganglia are usually the largest.

Their *branches* are superior, inferior, external and internal.

The *superior* and *inferior* are prolongations of the substance of the ganglia rather than branches; the *former* to communicate with the ganglion above, the *latter* with that below.

The *external branches*, two or three in number, communicate with each of the spinal nerves.

The *internal branches* of the five upper ganglia are *aortic*, and follow the course of the intercostal arteries to that trunk: the branches of the lower ganglia unite to form the two *splanchnic nerves*.

The *Great splanchnic nerve* arises from the sixth dorsal ganglion, and receives branches from the seventh, eighth, ninth and tenth, which increase it to a nerve of considerable size. It descends in front of the vertebral column, within the posterior mediastinum, pierces the diaphragm immediately to the outer side of each crus, and terminates in the *semilunar ganglion*.

The *Lesser splanchnic nerve (renal)* is formed by filaments from the tenth, eleventh, and sometimes from the twelfth dorsal ganglion. It pierces the diaphragm, and descends to join the *renal plexus*.

The *Semilunar ganglion* is a large, irregular, gangliform body, pierced by numerous openings, and appearing like the aggregation of a number of smaller ganglia, having spaces between them. It is situated by the side of the celiac axis, and communicates with the ganglion of the opposite side, both above and below that trunk, so as to form a gangliform circle, from which branches pass off in all directions, like rays from a centre. Hence the entire circle has been named the *solar plexus*.

The *Solar plexus* receives the great splanchnic nerves; part of the lesser splanchnic nerves; the termination of the right pneumogastric nerve; some branches from the right phrenic nerve; and sometimes one or two filaments from the left. It gives off numerous filaments, which accompany, under the name of *plexuses*, all the branches given off by the abdominal aorta. Thus, we have derived from the solar plexus the—

Phrenic plexuses,
Gastric plexus,
Hepatic plexus,
Splenic plexus,
Supra-renal plexuses,
Renal plexuses,
Superior mesenteric plexus,
Spermatic plexuses,
Inferior mesenteric plexus.

The *Renal plexus* is formed chiefly by the lesser splanchnic nerve, but receives many filaments from the solar plexus.

The *Spermatic plexus* is formed principally by the renal plexus.

The *Inferior mesenteric plexus* receives filaments from the aortic plexus.

LUMBAR GANGLIA.

The *Lumbar ganglia* are four in number on each side, of the peculiar pearly gray colour, fusiform, and situated upon the anterior part of the bodies of the lumbar vertebræ.

The *superior* and *inferior branches* of the lumbar ganglia are branches of communication with the ganglion above and below, as in the dorsal region.

The *external branches*, two or three in number, communicate with the lumbar nerves.

The *internal branches* consist of two sets; of which the upper pass inwards in front of the abdominal aorta, and form around that trunk a plexiform interlacement, which constitutes the *aortic plexus*; the lower branches cross the common iliac arteries, and unite over the promontory of the sacrum, to form the hypogastric plexus.

The *Aortic plexus* is formed by branches from the lumbar ganglia, and receives filaments from the solar and superior mesenteric plexuses. It sends filaments to the inferior mesenteric plexus, and terminates in the hypogastric plexus.

The *Hypogastric plexus* is formed by the termination of the aortic plexus, and by the union of branches from the lower lumbar ganglia. It is situated over the promontory of the sacrum, between the two common iliac arteries, and bifurcates inferiorly into two lateral portions, which communicate with branches from the fourth and fifth sacral nerves. It distributes branches to all the viscera of the pelvis, and to the branches of the internal iliac artery.

SACRAL GANGLIA.

The *Sacral ganglia* are four or five in number on each side. They are situated upon the sacrum, close to the anterior sacral foramina, and resemble the lumbar ganglia in form and mode of connexion, although they are much smaller in size.

The *superior* and *inferior branches* communicate with the ganglia above and below.

The *external branches* communicate with the sacral and coccygeal nerves.

The *internal branches* communicate very freely with the lateral divisions of the hypogastric plexus, and are distributed to the pelvic viscera. The last sacral ganglia of the opposite sides give off branches which join a small ganglion, situated on the first bone of the coccyx, called the *ganglion impar* or *azygos*. This ganglion resembles in its position and function the ganglion of Ribes, serving to connect the inferior extremity of the sympathetic system, as does the former ganglion its upper extremity. It gives off a few small branches to the coccyx and rectum.

CHAPTER IX.

ORGANS OF SENSE.

THE organs of sense, the instruments by which the animal frame is brought into relation with surrounding nature, are five in number. Four of these organs are situated within the head, viz. the apparatus of smell, sight, hearing, and taste, and the remaining organ, of touch, is resident in the skin, and is distributed over the entire surface of the body.

THE NOSE AND NASAL FOSSEÆ.

The organ of smell consists essentially of two parts: one external, *the nose*; the other internal, the *nasal fossæ*.

The nose is the triangular pyramid projecting from the centre of the face, immediately above the upper lip. Superiorly, it is connected with the forehead, by means of a narrow bridge; inferiorly, it presents two openings, the *nostrils*, which overhang the mouth, and are so constructed that the odour of all substances must be received by the nose before they can be introduced within the lips. The septum between the openings of the nostrils is called the *columna*. Their entrance is guarded by a number of stiff hairs (*vibrissæ*), which project across the openings, and act as a filter in preventing the introduction of foreign substances, such as dust or insects, with the current of air intended for respiration.

The anatomical elements of which the nose is composed are,—1. Integument. 2. Muscles. 3. Bones. 4. Fibro-cartilages. 5. Mucous membrane. 6. Vessels and nerves.

1. The *Integument* forming the tip (*lobulus*) and wings (*alæ*) of the nose is extremely thick and dense, so as to be with difficulty separated from the fibro-cartilage. It is furnished with a number of *sebaceous follicles*, which by their oily secretion, protect the extremity of the nose in excessive alternations of temperature. The sebaceous matter of these follicles, becomes of a dark colour upon the surface, from the attraction of the carbonaceous matter floating in the atmosphere: hence the spotted appearance which the tip of the nose presents in large cities. When the integument is firmly compressed, the inspissated sebaceous secretion is squeezed out from the follicles, and taking the cylindrical form of their excretory ducts, has the appearance of small white maggots with black heads.

2. The *Muscles* are brought into view by reflecting the integument: they are the pyramidalis nasi, compressor nasi, levator labii superioris alæque nasi, and depressor labii superioris alæque nasi. They have been already described with the muscles of the face.

3. The *Bones* of the nose are the nasal, and nasal processes of the superior maxillary.

4. The *Fibro-cartilages* give form and stability to the outwork of the nose, providing at the same time, by their elasticity, against injuries. They are five in number, the

- Fibro-cartilage of the septum,
- Two lateral fibro-cartilages,
- Two alar fibro-cartilages.

The *Fibro-cartilage of the septum*, somewhat triangular in form, divides the nose into its two nostrils. It is connected above with the nasal bones and lateral fibro-cartilages; behind, with the ethmoidal septum and vomer; and below, with the palate processes of the superior maxillary bones. The alar fibro-cartilages and columna move freely upon the fibro-cartilage of the septum, being but loosely connected with it by perichondrium.

The *Lateral fibro-cartilages* are also triangular: they are connected, *in front*, with the fibro-cartilage of the septum; *above* with the nasal bones; *behind* with the nasal processes of the superior maxillary bones; and *below* with the alar fibro-cartilages.

Alar fibro-cartilages.—Each of these cartilages is curved in such a manner as to correspond with the opening of the nostril, to which it forms a kind of rim. The inner portion is loosely connected with the same part of the opposite cartilage, so as to form the *columna*. It is expanded and thickened at the point of the nose to constitute the *lobe*; and upon the side forms a curve corresponding with the form of the ala. This curve is prolonged downwards and forwards in the direction of the posterior border of the ala by three or four small fibro-cartilaginous plates, which are appendages to the alar fibro-cartilage.

The whole of these fibro-cartilages are connected with each other, and to the bones, by perichondrium, which, from its membranous structure, permits of the freedom of motion existing between them.

5. The *Mucous membrane*, lining the interior of the nose, is con-

Fig. 165.

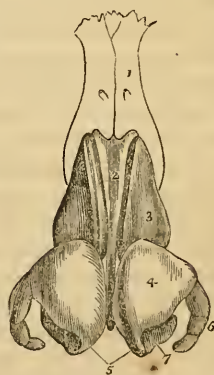


Fig. 165. The fibro-cartilages of the nose. 1. The nasal bones. 2. The fibro-cartilage of the septum. 3. The lateral fibro-cartilages. 4. The alar fibro-cartilages. 5. The central portions of the alar fibro-cartilages which constitute the columna. 6. The appendix of the alar fibro-cartilage. 7. The nostrils.

tinuous with the skin externally, and with the pituitary membrane of the nasal fossæ within. Around the entrance of the nostrils it is provided with numerous *vibrissæ*.

6. *Vessels and Nerves*.—The *Arteries* of the nose are the *lateralis nasi* from the facial, and the *nasalis septi* from the superior coronary.

Its *Nerves* are the facial, infra-orbital, and nasal branch of the ophthalmic.

NASAL FOSSÆ.

To obtain a good view of the *nasal fossæ*, the face must be divided through the nose by a vertical incision, a little to one side of the middle line.

The *Nasal fossæ* are two irregular, compressed cavities, extending backwards from the nose to the pharynx. They are bounded *superiorly* by the sphenoid and ethmoid bones. *Inferiorly* by the hard palate; and in the *middle* line they are separated from each other by a bony and fibro-cartilaginous septum. A plan of the boundaries of the nasal fossæ will be found at page 68.

Upon the outer wall of each fossa, in the dried skull, are three projecting processes, termed spongy bones. The two superior belong to the ethmoid, the inferior is a separate bone. In the fresh fossæ these are covered with mucous membrane, and serve to increase its surface by their projection and by their convoluted form. The space intervening between the superior and middle spongy bones is the *superior meatus*; the space between the middle and inferior bones is the *middle meatus*; and that between the inferior and the floor of the fossa is the *inferior meatus*.

These *meatuses* are passages which extend from before backwards, and it is in rushing through and amongst these that the atmosphere deposits its odorant particles upon the mucous membrane. There are several *openings* into the nasal fossæ: thus, in the *superior meatus* are the openings of the sphenoidal and posterior ethmoidal cells, in the *middle* the anterior ethmoidal cells, the frontal sinuses, and the antrum maxillare; and, in the inferior meatus, the termination of the nasal duct. In the dried bone there are two additional openings, the sphenopalatine and the anterior palatine foramen; the former being situated in the superior, and the latter in the inferior meatus.

The *Mucous membrane* of the nasal fossæ is called *pituitary*, or *Schneiderian*.* The former name being derived from its secretion, the latter from Schneider, who was the first to show that the secretion of the nose proceeded from the mucous membrane, and not from the brain, as was formerly imagined. It is continuous with the general gastro-pulmonary mucous membrane, and may be traced through the openings in the meatuses, into the sphenoidal and eth-

* Conrad Victor Schneider, Professor of Medicine at Wittenberg. His work, entitled *De Catarrhis*, &c., was published in 1661.

moidal cells; into the antrum maxillare; through the nasal duct to the surface of the eye, where it is continuous with the conjunctiva; along the Eustachian tubes into the tympanum and mastoid cells, to which it forms the lining membrane; and through the posterior nares into the pharynx and mouth, and thence through the lungs and alimentary canal.

The surface of this membranè is furnished with a columnar epithelium supporting innumerable vibratile cilia.

Vessels and Nerves.—The *Arteries* of the nasal fossæ are the anterior and posterior ethmoidal, from the ophthalmic artery; and sphenopalatine and pterygo-palatine from the internal maxillary.

The *Nerves* are, the olfactory, the sphenopalatine branches from Meckel's ganglion, and the nasal branch of the ophthalmic. The ultimate filaments of the olfactory nerve terminate in minute papillæ.

THE EYE, WITH ITS APPENDAGES.

The form of the eyeball is that of a sphere, of about one inch in diameter, having the segment of a smaller sphere ingrafted upon its anterior surface, which increases its antero-posterior diameter. The axes of the two eyeballs are parallel with each other, but do not correspond with the axes of the orbits, which are directed outwards. The optic nerves follow the direction of the orbits, and therefore enter the eyeballs to their nasal side.

The *Globe of the Eye* is composed of *tunics* and of refracting media called *humours*. The *tunics* are three in number, the

1. Sclerotic and Cornea,
2. Choroid, Iris, and Ciliary processes,
3. Retina and Zonula ciliaris.

The *humours* are also three—

- Aqueous,
- Crystalline (lens),
- Vitreous.

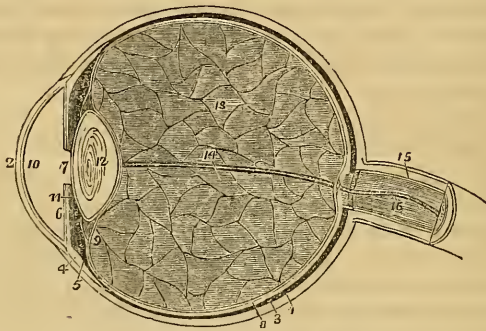
1. The *Sclerotic* and *Cornea* form the external tunic of the eyeball, and give to it its peculiar form. Four fifths of the globe are invested by the sclerotic, the remaining fifth by the cornea.

The *Sclerotic* ($\sigma\kappa\lambda\eta\rho\acute{\iota}\varsigma$, hard) is a dense fibrous membrane, thicker behind than in front. It is continuous, posteriorly, with the sheath of the optic nerve, which is derived from the dura matèr, and it is pierced by that nerve as well as by the ciliary nerves and arteries. Anteriorly it presents a *bevelled edge* which receives the cornea in the same way that a watch-glass is received by the groove in its case. Its anterior surface is covered by a thin tendinous layer, the *tunica albuginea*, derived from the expansion of the tendons of the four recti muscles. By its posterior surface it gives attachment to the two oblique muscles. The *tunica albuginea* is covered, for a

part of its extent, by the mucous membrane of the front of the eye, the conjunctiva; and, by reason of the brilliancy of its whiteness, gives occasion to the common expression, "the white of the eye."

At the entrance of the optic nerve the sclerotic forms a thin *cribriform lamella* (*lamina cribrosa*), which is pierced by a number of minute openings for the passage of the nervous filaments. One of these openings, larger than the rest, and situated in the centre of the lamella, is the *porus opticus*, through which the *arteria centralis retinae* enters the eye.

Fig. 166.



The *Cornea* (*corneus*, horny) is the transparent projecting layer that forms the anterior fifth of the globe of the eye. In its form it is circular, concavo-convex, and resembles a watch-glass. It is received by its edge, which is sharp and thin, within the bevelled border of the sclerotic, to which it is very firmly attached, and it is somewhat thicker than the anterior portion of that tunic. When examined from the exterior, its vertical diameter is seen to be about one-sixteenth shorter than the transverse, in consequence of the overlapping above and below, of the margin of the sclerotica; on the interior, however, its outline is perfectly circular.

The cornea is composed of four layers, 1, of the conjunctiva; 2, of the cornea proper, which consists of several thin lamellæ con-

Fig. 166. A longitudinal section of the globe of the eye. 1. The sclerotic, thicker behind than in front. 2. The cornea, received within the anterior margin of the sclerotic, and connected with it by means of a bevelled edge. 3. The choroid, connected anteriorly with (4) the ciliary ligament, and (5) the ciliary processes. 6. The iris. 7. The pupil. 8. The third layer of the eye, the retina, terminating anteriorly by an abrupt border at the commencement of the ciliary processes. 9. The canal of Petit, which encircles the lens (12); the thin layer in front of this canal is the zonula ciliaris, a prolongation of the vascular layer of the retina to the lens. 10. The anterior chamber of the eye containing the aqueous humour; the lining membrane by which the humour is secreted is represented in the diagram. 11. The posterior chamber. 12. The lens, more convex behind than before, and enclosed in its proper capsule. 13. The vitreous humour enclosed in the hyaloid membrane, and in cells formed in its interior by that membrane. 14. A tubular sheath of the hyaloid membrane, which serves for the passage of the artery of the capsule of the lens. 15. The neurilemma of the optic nerve. 16. The *arteria centralis retinae*, embedded in its centre.

nected together by an extremely fine cellular tissue; 3, of the cornea elastica, a "fine, elastic, and exquisitely transparent membrane, exactly applied to the inner surface of the cornea proper;" and 4, of the lining membrane of the anterior chamber of the eyeball. The cornea elastica is remarkable for its perfect transparency, even when submitted for many days to the action of water or alcohol; while the cornea proper is rendered perfectly opaque by the same immersion. To expose this membrane, Dr. Jacob suggests that the eye should be placed in water for six or eight days, and then that all the opaque cornea should be removed layer after layer. Another character of the cornea elastica is its great elasticity, which causes it to roll up when divided or torn, in the same manner with the capsule of the lens. The use of this layer, according to Dr. Jacob, is to "preserve the requisite permanent correct curvature of the flaccid cornea proper."

The opacity of the cornea, produced by pressure on the globe, results from the infiltration of fluid into the cellular tissue connecting its layers. This appearance cannot be produced in a sound living eye.

Dissection.—The sclerotic and cornea are now to be dissected away from the second tunic; this, with care, may be easily performed, the only connexions subsisting between them being at the circumference of the iris, the entrance of the optic nerve, and the perforation of the ciliary nerves and arteries. Pinch up a fold of the sclerotic near its anterior circumference, and make a small opening into it, then raise the edge of the tunic, and with a pair of fine scissors, having a probe point, divide the entire circumference of the sclerotic, and cut it away bit by bit. Then separate it from its attachment around the circumference of the iris by a gentle pressure with the edge of the knife. The dissection of the eye must be conducted under water.

In the course of this dissection the *ciliary nerves* and *long ciliary arteries* will be seen passing forwards between the sclerotic and choroid, to be distributed to the iris.

2. *Second tunic.*—The second tunic of the eyeball is formed by the *choroid*, *ciliary ligament* and *iris*, the *ciliary processes* being an appendage developed from its inner surface.

The *choroid** is a vascular membrane of a rich chocolate-brown colour upon its external surface, and of a deep black colour within. It is connected with the sclerotic, externally, by an extremely fine cellular tissue, and by the passage of nerves and vessels. Internally

* The word *choroid* has been very much abused in anatomical language; it was originally applied to the membrane of the fœtus called chorion from the Greek word *χοριον*, domicilium, that membrane being, as it were, the abode or receptacle of the fœtus. *Χοριον* comes from *χαρῖνω*, to take or receive. Now it so happens that the chorion in the ovum is a vascular membrane of a peculiar structure. Hence the term choroid, *χοριον ειδος*, like the chorion, has been used indiscriminately to signify vascular structures, as in the choroid membrane of the eye, the choroid plexus, &c. and we find Cruveilhier in his admirable work on *Anatomy*, vol. iii. p. 463, saying in a note, "Choroïde est synonyme de vasculaire."

it is in simple contact with the third tunic of the eye, the retina. It is pierced posteriorly for the passage of the optic nerve, and is connected anteriorly with the iris, ciliary processes, and with the line of junction of the cornea and sclerotic, by a dense white structure, the *ciliary ligament*, which surrounds the circumference of the iris like a ring.

The choroid membrane is composed of three layers:—1. An *external* or *venous*, which consists principally of veins arranged in a peculiar manner: hence they have been named *venæ vorticosaë*. The marking upon the surface of the membrane produced by these veins, resembles so many centres, to which a number of curved lines converge. It is this layer which is connected with the ciliary ligament. 2. The *middle* or *arterial layer* (*tunica Ruyschiana*)* is formed principally by the ramifications of minute arteries, and secretes upon its surface the pigmentum nigrum. It is reflected inwards at its junction with the ciliary ligament, so as to form the ciliary processes. 3. The *internal layer* is a delicate membrane (*membrana pigmenti*) which presents a beautiful appearance beneath the microscope; it is composed of several laminae of nucleated hexagonal cells, which contain the granules of pigmentum nigrum, and are arranged so as to resemble a tessellated pavement.

In animals the pigmentum nigrum, upon the posterior wall of the eyeball, is replaced by a layer of considerable extent, and of metallic brilliancy, called the tapetum.

The *ciliary ligament*, or circle, is the bond of union between the external and middle tunics of the eye, and serves to connect the cornea and sclerotic at their line of junction with the iris and external layer of the choroid. It is also the point to which the ciliary nerves and vessels proceed previously to their distribution, and it receives the anterior ciliary arteries through the anterior margin of the sclerotic. A minute vascular canal is situated within the ciliary ligament, called the ciliary canal, or the canal of Fontana, † from its discoverer.

The *Iris* (iris, a rainbow) is so named from its variety of colour in different individuals: it forms a septum between the anterior and posterior chambers of the eye, and is pierced somewhat to the nasal side of its centre by a circular opening, which is called the pupil. By its periphery it is connected with the ciliary ligament, and by its inner circumference forms the margin of the pupil: its anterior surface looks towards the cornea, and the posterior towards the ciliary processes and lens.


It is composed of two layers, an *anterior* or *muscular*, consisting of *radiating* fibres which converge from the circumference towards

* Ruysch was born at the Hague in 1638, and was appointed professor of Anatomy at Amsterdam in 1665. His whole life was employed in making injected preparations, for which he is justly celebrated. He came to the conclusion that the body was entirely made up of vessels. He died at the advanced age of ninety-three years.

† Felix Fontana, an anatomist of Tuscany. His "Description of a New Canal in the Eye," was published in 1778, in a letter to the Professor of Anatomy in Upsal.

the centre, and have the power of dilating the pupil; and *circular*, which surround the pupil like a sphincter, and by their action produce contraction of its area. The posterior layer is of a deep purple tint, and is thence named *uvea*, from its resemblance in colour to a ripe grape.

Fig. 167.



The *Ciliary processes* may be seen in two ways, either by removing the iris from its attachment to the ciliary ligament, when a front view of the processes will be obtained, or by making a transverse section through the globe of the eye, when they may be examined from behind, as in fig. 167.

The ciliary processes consist of a number of triangular folds, formed apparently by the plaiting of the internal layer of the choroid. They are, according to Zinn, about sixty in number, and may be divided into large and small, the latter being situated in the spaces between the former. The periphery is connected with the ciliary ligament, and is continuous with the internal layer of the choroid. The central border is free, and rests against the circumference of the lens. The anterior surface corresponds with the uvea; the posterior receives the folds of the zonula ciliaris between its processes, and thus establishes a connexion between the choroid and the third tunic of the eye. The ciliary processes are covered with a thick layer of pigmentum nigrum, which is more abundant upon them, and upon the anterior part of the choroid, than upon the posterior. When the pigment is washed off, the processes are of a whitish colour.

3. *Third tunic.*—The third tunic of the eye is the *retina*, which is prolonged forwards to the lens by the *zonula ciliaris*.

Dissection.—If after the preceding dissection the choroid membrane be carefully raised and removed, the eye being kept under water, the retina may be seen very distinctly.

The *Retina* is composed of three layers:

- External* or Jacob's membrane,
- Middle*, Nervous membrane,
- Internal*, Vascular membrane.

Jacob's membrane is extremely thin, and is seen as a flocculent film when the eye is suspended in water. Examined by the micro-

* Fig. 167. The anterior segment of a transverse section of the globe of the eye, seen from within. 1. The divided edge of the three tunics; sclerotic, choroid (the dark layer,) and retina. 2. The pupil. 3. The iris, the surface presented to view in this section being the uvea. 4. The ciliary processes. 5. The scalloped anterior border of the retina.

scope, it is seen to be composed of granules having a tessellated arrangement. Dr. Jacob considers it to be a serous membrane.

The *Nervous membrane* is the expansion of the optic nerve, and forms a thin semi-transparent bluish white layer, which envelops the vitreous humour, and extends forwards to the commencement of the ciliary processes, where it terminates in an abrupt scalloped margin.

This layer has been observed by Treviranus to be composed of cylindrical fibres, which proceed from the optic nerve and bend abruptly inwards, near their termination, to form the internal papillary layer, which lies in contact with the hyaloid membrane; each fibre constituting by its extremity a distinct papilla.

The *Vascular membrane* consists of the ramifications of a minute artery, the *arteria centralis retinae*, and its accompanying vein; the

Fig. 168.



artery pierces the optic nerve, and enters the globe of the eye through the porus opticus in the centre of the lamina cribrosa. This artery may be seen very distinctly by making a transverse section of the eyeball. Its branches are continuous anteriorly with the zonula ciliaris.

This vascular layer forms distinct sheaths for the nervous papillæ, which constitute the inner surface of the retina.

In the centre of the posterior part of the globe of the eye the retina presents a circular spot, which is called the *foramen of Soemmering*;* it is surrounded by a yellow halo, the *limbus luteus*, and is frequently obscured by an elliptical fold of the retina, which, from its constancy of appearance, has been regarded as a normal condition of the membrane. The term foramen is misapplied to this spot, for the vascular layer and the *membrani Jacobi* are continued across it; the nervous substance alone appearing to be deficient. It exists only in animals having the axis of the eyeballs parallel with each other, as man, quadrumana, and some saurian reptiles, and is said to give passage to a small lymphatic vessel.

Fig. 168. The posterior segment of the transverse section of the globe of the eye, seen from within. 1. The divided edge of the three tunics. The membrane covering the whole internal surface is the retina. 2. The entrance of the optic nerve with the *arteria centralis retinae* piercing its centre. 3, 3. The ramifications of the *arteria centralis*. 4. The foramen of Soemmering, in the centre of the axis of the eye; the shade from the sides of the section obscures the *limbus luteus* which surrounds it. 5. A fold of the retina, which generally obscures the foramen of Soemmering after the eye has been opened.

* Samuel Thomas Soemmering is celebrated for the beautiful and accurate plates which accompany his works. The account "De Foramine Centrali Retinae Humanæ, Limbo Luteo cincto," was published in 1779, in the *Commentationes Soc. Reg. Scient. Göttingensis*.

The *zonula ciliaris* (zonula of Zinn)* is a thin vascular layer which connects the anterior margin of the retina with the anterior surface of the lens near to its circumference. It presents upon its surface a number of small folds corresponding with the ciliary processes, between which they are received. These processes are arranged in the form of rays around the lens, and the spaces between them are stained by the pigmentum nigrum of the ciliary processes. They derive their vessels from the vascular layer of the retina. The under surface of the zonula is in contact with the hyaloid membrane, and around the lens forms the anterior fluted wall of the *canal of Petit*.

The connexion between these folds and the ciliary processes may be very easily demonstrated by dividing an eye transversely into two portions, then raising the anterior half, and allowing the vitreous humour to separate from its attachment by its own weight. The folds of the zonula will then be seen to be drawn out from between the folds of the ciliary processes.

HUMOURS.—The *Aqueous humour* is situated in the anterior and posterior chambers of the eye; it is a weakly albuminous fluid, having an alkaline reaction, and a specific gravity very little greater than distilled water. According to Petit, it scarcely exceeds four or five grains in weight.

The *anterior chamber* is the space intervening between the cornea in front and the iris and pupil behind.

The *posterior chamber* is the narrow space, less than half a line in depth,† bounded by the posterior surface of the iris and pupil in front, and by the ciliary processes, zonula ciliaris, and lens behind.

The two chambers are lined by a thin layer, the *secreting membrane of the aqueous humour*.

The *Vitreous humour* forms the principal bulk of the globe of the eye. It is an albuminous fluid resembling the aqueous humour enclosed in a delicate membrane, the *hyaloid*, which sends processes into its interior, forming cells in which the humour is retained. A small artery may sometimes be traced through the centre of the vitreous humour to the capsule of the lens; it is surrounded by a tubular sheath of the hyaloid membrane. This vessel is easily injected in the fœtus.

The *Crystalline humour* or *lens* is situated immediately behind the pupil, and is surrounded by the ciliary processes, which slightly overlap its margin. It is more convex on the posterior than on the anterior surface, and is embedded in the anterior part of the vitreous humour, from which it is separated by the hyaloid membrane. It is invested by a peculiarly transparent and elastic membrane, the

* John Gottfried Zinn, Professor of Anatomy in Göttingen; his "Descriptio Anatomica Oculi Humani," was published in 1755; with excellent plates. It was republished by Wrisberg in 1780.

† Winslow and Lieutaud thought the iris to be in contact with the lens; it frequently adheres to the capsule of the latter in iritis. The depth of the posterior chamber is greater in old than in young persons.

capsule of the lens, which contains a small quantity of fluid called *liquor Morgagni*,* and is retained in its place by the attachment of the zonula ciliaris. Dr. Jacob is of opinion that the lens is connected to its capsule by means of cellular tissue, and that the liquor Morgagni is the result of a cadaveric change.

The *Lens* consists of concentric layers, of which the external are soft, the next firmer, and the central form a hardened nucleus. These layers are best demonstrated by boiling, or by immersion in alcohol, when they separate easily from each other. Another division of the lens takes place at the same time: it splits into three triangular segments, which have the sharp edge directed towards the centre, and the base towards the circumference. The concentric lamellæ are composed of minute parallel fibres, which are united with each other by means of scalloped borders; the convexity on the one border fitting accurately the concave scallop upon the other.

Immediately around the circumference of the lens is a triangular canal, the *canal of Petit*,† about a line and a half in breadth. It is bounded in front by the flutings of the zonula ciliaris; behind by the hyaloid membrane; and within by the border of the lens.

The *Vessels* of the globe of the eye are the long, and short, and anterior ciliary arteries, and the arteria centralis retinæ. The *long ciliary arteries*, two in number, pierce the posterior part of the sclerotic, and pass forward on each side, between that membrane and the choroid, to the ciliary ligament, where they divide into two branches, which are distributed to the iris. The *short ciliary arteries* pierce the posterior part of the sclerotic coat, and are distributed to the internal layer of the choroid membrane. The *anterior ciliary* are branches of the muscular arteries. They enter the eye through the anterior part of the sclerotic, and are distributed to the iris. It is the increased number of these arteries in iritis that forms the peculiar red zone around the circumference of the cornea.

The *arteria centralis retinæ* enters the optic nerve at about half an inch from the globe of the eye, and passing through the porus opticus is distributed upon the inner surface of the retina, forming its vascular layer; one branch pierces the centre of the vitreous humour, and supplies the capsule of the lens.

The *Nerves* of the eyeball are the optic, two ciliary nerves from the nasal branch of the ophthalmic, and the ciliary nerves from the ciliary ganglion.

Observations.—The sclerotic is a tunic of protection, and the cornea a medium for the transmission of light. The choroid supports the vessels destined for the nourishment of the eye, and by its pigmentum nigrum absorbs all loose and scattered rays that might confuse the image impressed upon the retina. The iris, by means

* John Baptist Morgagni was born in 1682. He was appointed Professor of Medicine in Bologna, and published the first part of his "Adversaria Anatomica," in 1706. He died in 1771.

† John Louis Petit, a celebrated French surgeon: he published several surgical and anatomical Essays, in the early part of the 18th century. He died in 1750.

of its powers of expansion and contraction, regulates the quantity of light admitted through the pupil. If the iris be thin, and the rays of light pass through its substance, they are immediately absorbed by the uvea; and if that layer be insufficient, they are taken up by the black pigment of the ciliary processes.

In Albinos, where there is an absence of pigmentum nigrum, the rays of light traverse the iris and even the sclerotic, and so overwhelm the eye with light, that sight is destroyed, except in the dimness of evening or at night.

In the manufacture of optical instruments care is taken to colour their interior black, with the same object, the absorption of scattered rays.

The transparent lamellated cornea and the humours of the eye have for their office the refraction of the rays in such proportion as to direct the image in the most favourable manner upon the retina. Where the refracting medium is too great, as in over convexity of the cornea and lens, the image falls short of the retina (myopia, near-sightedness); and where it is too little the image is thrown beyond the nervous membrane (presbyopia, far-sightedness.)

These conditions are rectified by the use of spectacles, which provide a differently refracting medium externally to the eye, and thereby correct the transmission of light.

APPENDAGES OF THE EYE.

The *Appendages of the eye (tutamina oculi)* are the eyebrows, eyelids, eyelashes, conjunctiva, caruncula lachrymalis, and the lachrymal apparatus.

The *Eyebrows (supercilia)* are two projecting arches of integument covered with short thick hairs, which form the upper boundary of the orbits. They are connected beneath with the orbiculares, occipito-frontales, and corrugatores superciliarum muscles; their use is to shade the eyes from a too vivid light, or protect them from particles of dust and moisture floating over the forehead.

The *Eyelids (palpebræ)* are two valvular layers placed in front of the eye, serving to defend it from injury by their closure. When drawn open they leave between them an elliptical space, the angles of which are called *canthi*. The outer canthus is formed by the meeting of the two lids at an acute angle. The inner canthus is prolonged for a short distance inwards towards the nose, and a triangular space is left between the lids in this situation, which is called the *lacus lachrymalis*. At the commencement of the lacus lachrymalis upon each of the two lids is a small angular projection, the *lachrymal papilla* or *tubercle*; and at the apex of each papilla is a small orifice (punctum lachrymale), the commencement of the lachrymal canal.

The eyelids have, entering into their structure, *integument, orbicularis muscle, tarsal cartilages, Meibomian glands, and conjunctiva*.

The tegumentary cellular tissue of the eyelids is remarkable for its looseness and for the entire absence of adipose substance. It is

particularly liable to serous infiltration. The fibres of the orbicularis muscle covering the eyelids, are extremely thin and pale.

The *Tarsal cartilages* are two thin lamellæ of fibro-cartilage about an inch in length, which give form and support to the eyelids. The *superior* is of a semilunar form, about one-third of an inch in breadth at its middle, and tapering to each extremity. Its lower border is broad and flat, its upper is thin, and gives attachment to the levator palpebræ and to the fibrous membrane of the lids.

The *Inferior fibro-cartilage* is an elliptical band, narrower than the superior, and situated in the substance of the lower lid. Its upper border is flat, and corresponds with the flat edge of the upper cartilage. The lower is held in its place by the fibrous membrane. At the inner canthus the tarsal cartilages terminate at the commencement of the lachrymalis, and are attached to the margin of the orbit by the tendo oculi. At their outer extremity they terminate at a short distance from the angle of the canthus, and are retained in their position by means of a decussation of the fibrous structure of the broad tarsal ligament, called the *external palpebral ligament*.

The *Fibrous membrane* of the lids is firmly attached to the periosteum, around the margin of the orbit, by its circumference, and to the tarsal cartilages by its central margin. It is thick and dense on the outer half of the orbit, but becomes thin to its inner side. Its use is to retain the tarsal cartilages in their place, and give support to the lids; hence it has been named the *broad tarsal ligament*.

The *Meibomian glands** are embedded in the internal surface of the cartilages, and are very distinctly seen on examining the inner surface of the lids. They have the appearance of parallel strings of pearls, about thirty in number in the upper cartilage, and somewhat fewer in the lower; they open by minute foramina upon the edges of the lids. They correspond in length with the breadth of the cartilage, and are consequently longer in the upper than in the lower lid.

Each gland consists of a single lengthened follicle or tube, into which a number of small clustered follicles open; the latter are so numerous as almost to conceal the tube by which the secretion is poured out upon the margin of the lids. They are figured, after a very careful examination, in Dr. Quain's "Elements of Anatomy." Occasionally an arch is formed between two of them, as is seen in that figure, and produces a very graceful appearance.

The edges of the eyelids are furnished with a triple row of long thick hairs, which curve upwards from the upper lid, and downwards from the lower, so that they may not interlace with each other in the closure of the eyelids, and prove an impediment to the opening of the eyes. These are the *eyelashes (cilia)*, important organs of defence to the sensitive surface of so delicate an organ as the eye.

* Henry Meibomius, "de Vasis Palpebrarum Novis," 1666.

The *Conjunctiva* is the mucous membrane of the eye. It covers the whole of its anterior surface, and is then reflected upon the lids so as to form their internal layer. The duplicatures formed between the globe of the eye and the lids are called the *superior* and *inferior palpebral sinuses*, of which the former is much deeper than the inferior. Where it covers the cornea the conjunctiva is very thin and closely adherent, and no vessels can be traced into it. Upon the sclerotica it is thicker and less adherent, and to the inner surface of the lids is very closely connected, and is exceedingly vascular. It is continuous with the general gastro-pulmonary mucous membrane, and sympathizes in its affections, as may be observed in various diseases. From the surface of the eye it may be traced through the lachrymal gland; along the edges of the lids it is continuous with the mucous lining of the Meibomian glands, and at the inner angle of the eye may be followed through the lachrymal canals into the lachrymal sac, and thence downwards through the nasal duct into the inferior meatus of the nose.

This membrane is coated with a lamellated epithelium composed of vesicles and flattened scales, with central nuclei.

The *Caruncula lachrymalis* is the small reddish body which occupies the lacus lachrymalis at the inner canthus of the eye. In health it presents a bright pink tint; in sickness it loses its colour and becomes pale. It consists of an assemblage of follicles similar to the Meibomian glands, embedded in a fibro-cartilaginous tissue, and is the source of the whitish secretion which so constantly forms at the inner angle of the eye. It is covered with minute hairs which are sometimes so long as to be distinctly visible to the naked eye.

Immediately to the outer side of the caruncula is a slight duplicature of the conjunctiva, called *plica semilunaris*, which contains a minute plate of cartilage, and is the rudiment of the third lid of animals, the *membrana nictitans* of birds.

Vessels and nerves.—The palpebræ are supplied internally with *arteries* from the ophthalmic, and externally from the facial and transverse facial. Their *nerves* are branches of the fifth and of the facial.

LACHRYMAL APPARATUS.

The *Lachrymal apparatus* consists of the lachrymal gland with its excretory ducts; the puncta lachrymalia, and lachrymal canals; the lachrymal sac and nasal duct.

The *Lachrymal gland* is situated at the upper and outer angle of the orbit, and consists of two portions, orbital and palpebral. The *orbital portion*, about three quarters of an inch in length, is flattened and oval in shape, and occupies the lachrymal fossa in the orbital plate of the frontal bone; being in contact with the periosteum, to which it is closely connected by its upper and convex surface; being in relation with the globe of the eye, and with the superior and external rectus by its inferior or concave surface; and with the broad

tarsal ligament by its anterior border. By its posterior border it receives its vessels and nerves. The *palpebral portion*, smaller than the preceding, is situated in the upper eyelid, extending downwards to the superior margin of the tarsal cartilage. It is continuous with the orbital portion above, and is enclosed in an investment of dense fibrous membrane. The secretion of the lachrymal gland is conveyed away by ten or twelve small ducts which run for a short distance beneath the conjunctiva, and open upon its surface by a series of pores about one-twentieth of an inch apart, situated in a curved line a little above the upper border of the tarsal cartilage.

Lachrymal canals.—The lachrymal canals commence at the minute openings, *puncta lachrymalia*, seen upon the lachrymal papillæ of the lids at the outer extremity of the lacus lachrymalis, and proceed inwards to the lachrymal sac, where they terminate beneath a valvular semilunar fold of the lining membrane of the sac. The *superior* duct at first ascends, and then turns suddenly inwards towards the sac, forming an abrupt angle. The inferior duct forms the same kind of angle, by descending at first, and then turning abruptly inwards. They are dense and elastic in structure, and remain constantly open, so that they act like capillary tubes in absorbing the tears from the surface of the eye. The two fasciculi of the tensor tarsi muscle are inserted into these ducts, and serve to draw them inwards.

The *Lachrymal sac* is the upper extremity of the nasal duct, and is scarcely more dilated than the rest of the canal. It is lodged in the groove of the lachrymal bone, and is often distinguished internally from the nasal duct by a semilunar or circular valve. It consists of mucous membrane, but is covered in and retained in its place by a fibrous expansion, derived from the tendon of the orbicularis, which is inserted into the ridge on the lachrymal bone: it is also covered by the tensor tarsi muscle, which arises from the same ridge, and in its action upon the lachrymal canals may serve to compress the lachrymal sac.

The *Nasal duct* is a short canal about three quarters of an inch in length, directed downwards, backwards, and a little outwards to the inferior meatus of the nose, where it terminates by an expanded orifice. It is lined by mucous membrane, which is continuous with the conjunctiva above, and with the pituitary membrane of the nose below. Obstruction from inflammation and suppuration of this duct constitutes the disease called *fistula lachrymalis*.

Vessels and nerves.—The lachrymal gland is supplied with blood by the lachrymal branch of the ophthalmic artery, and with nerves by the lachrymal branch of the ophthalmic and orbital branch of the superior maxillary.

THE ORGAN OF HEARING.

The *Ear* is composed of three parts. 1. *External ear*. 2. *Middle ear*, or *tympanum*. 3. *Internal ear*, or *labyrinth*.

The **EXTERNAL EAR** consists of two portions, the *pinna* and

meatus; the former representing a kind of funnel which collects the vibrations of the atmosphere, called sounds, and the latter a tube which conveys the vibrations to the tympanum.

The *Pinna* presents a number of folds and hollows upon its surface, which have different names assigned to them. Thus the external folded margin is called the *helix* (ἑλιξ, a fold). The elevation parallel to and in front of the helix is called *antihelix* (ἀντι, opposite.) The pointed process, projecting like a valve over the opening of the ear from the face, is called the *tragus* (τράγος, a goat), probably from being sometimes covered with bristly hair like that of a goat; and a tubercle opposite to this is the *antitragus*. The lower dependent and fleshy portion of the pinna is the *lobulus*. The space between the helix and antihelix is named the *fossa innominata*.

Another depression is observed at the upper extremity of the antihelix, which bifurcates and leaves a triangular space between its branches called the *scaphoid fossa*; and the large central space to which all the channels converge is the *concha*, which opens directly into the *meatus*.

The pinna is composed of *integument*, *fibro-cartilage*, *ligaments*, and *muscles*.

The *Integument* is thin, and closely connected with the fibro-cartilage.

The *Fibro-cartilage*, gives form to the pinna, and is folded so as to produce the various convexities and grooves which have been described upon its surface. The *helix* commences in the concha, and partially divides that cavity into two parts; on its anterior border is a tubercle for the attachment of the *atrahens aurem* muscle, and a little above this a small vertical fissure, the *fissure of the helix*. The termination of the helix and antihelix forms a lengthened process, the *processus caudatus*, which is separated from the concha by an extensive fissure. Upon the anterior surface of the *tragus* is another fissure, the *fissure of the tragus*, and in the *lobulus* the fibro-cartilage is wholly deficient. The fibro-cartilage of the *meatus*, at the upper and anterior part of the cylinder, is divided from the concha by a fissure which is closed in the entire ear by ligamentous fibres; it is firmly attached at its termination to the *processus auditorius*.

The *Ligaments* of the external ear are those which attach the pinna to the side of the head, viz. the anterior, posterior, and ligament of the *tragus*; and those of the fibro-cartilage, which serve to preserve its folds and connect the opposite margins of the fissures. The latter are two in number,—the ligament between the concha and the *processus caudatus*, and the broad ligament which extends from the upper margin of the fibro-cartilage of the *tragus* to the helix, and completes the *meatus*.

The proper *Muscles* of the *Pinna* are the—

Major heliçis,
 Minor heliçis,
 Tragicus,
 Antitragicus,
 Transversus auriculæ.

The *Major heliçis* is a narrow band of muscular fibres situated upon the anterior border of the helix, just above the tragus.

The *Minor heliçis* is placed upon the posterior border of the helix, at its commencement in the fossa of the concha.

The *Tragicus* is a thin quadrilateral layer of muscular fibres, situated upon the tragus.

The *Antitragicus* arises from the antitragus, and is inserted into the posterior extremity, or processus caudatus of the helix.

The *Transversus auriculæ*, partly tendinous and partly muscular, extends transversely from the convexity of the concha to that of the helix, on the posterior surface of the pinna.

These muscles are rudimentary in the human ear, and deserve only the title of muscles in the ears of animals. Two other muscles are described by Mr. Tod,* the *obliquus auris* and *contractor meatûs*, or *trago-heliçis*.

The *Meatus auditorius* is a canal, partly cartilaginous and partly osseous, about an inch in length, which extends inwards and a little forwards from the concha to the tympanum. It is narrower in the middle than at each extremity, forms an oval cylinder, the long diameter being vertical, and is slightly curved upon itself, the concavity looking downwards.

It is lined by an extremely thin pouch of cuticle, which, when withdrawn after maceration, preserves the form of the meatus. Some stiff short hairs are also found in its interior, which stretch across the tube, and prevent the ingress of insects and dust. Beneath the cuticle are a number of small *ceruminous follicles*, which secrete the wax of the ear.

Vessels and Nerves.—The pinna is plentifully supplied with *arteries*; by the anterior auricular from the temporal, and by the posterior auricular from the external carotid.

Its *Nerves* are derived from the auricular branch of the fifth, and from the auricularis magnus of the cervical plexus.

TYMPANUM.—The tympanum is an irregular bony cavity, compressed from without inwards, and situated within the petrous bone. It is bounded *externally* by the meatus and membrana tympani; *internally* by its inner wall; and in its *circumference* by the petrous bone and mastoid cells.

The *Membrana tympani* is a thin and semi-transparent membrane of an oval shape, the longer diameter being nearly vertical. It is inserted into a groove around the circumference of the meatus near to its termination, and is placed obliquely across the area of that tube, the direction of the obliquity being downwards and inwards.

* "The Anatomy and Physiology of the Organ of Hearing," by David Tod, 1832.

It is concave towards the meatus, and convex towards the tympanum, and is composed of *three layers*, an *external cuticular*, *middle fibrous and muscular*, and *internal mucous*, derived from the mucous lining of the tympanum.

The tympanum contains three small bones, *ossicula auditûs*, viz. the—

Malleus,
Incus,
Stapes.

The *Malleus* (*hammer*) consists of a head, neck, handle (*manubrium*), and two processes, *long* (*processus gracilis*), and *short* (*processus brevis*). The manubrium is connected to the membrana tympani by its whole length extending to below the central point of that membrane. It lies beneath its mucous layer, and serves as a point of attachment to which the radiating fibres of the fibrous layer converge. The long process descends to a groove near to the fissura Glaseri, and gives attachment to the laxator tympani muscle. Into the short process is inserted the tendon of the tensor tympani, and the head of the bone articulates with the incus.

The *incus* (*anvil*) is named from an imagined resemblance to an anvil. It has also been likened to a bicuspid tooth, having one root longer, and widely separated from the other. It consists of two processes, which unite nearly at right angles, and at their junction form a flattened body, to articulate with the head of the malleus. The short process is attached to the margin of the opening of the mastoid cells by means of a short ligament; the long process descends nearly parallel with the handle of the malleus, and curves inwards, near to its termination. At its extremity is a small globular projection, the *os orbiculare*, which is a distinct bone in the fœtus, but becomes ankylosed to the long process of the incus in the adult; this process articulates with the head of the stapes.

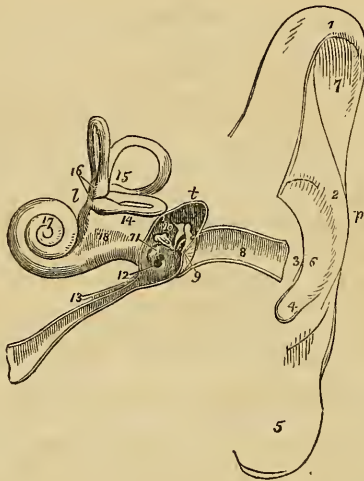
The *Stapes* is shaped like a stirrup, to which it bears a close resemblance. Its head articulates with the os orbiculare, and the two branches are connected by their extremities with a flat oval-shaped plate, representing the foot of the stirrup. The foot of the stirrup is received into the fenestra ovalis, to the margin of which it is connected by means of a circular ligament; it is in contact, by its surface, with the membrana vestibuli, and is covered in by the mucous lining of the tympanum. The neck of the stapes gives attachment to the stapedius muscle.

The ossicula auditûs are retained in their position and moved upon themselves by means of ligaments and muscles.

The *Ligaments* are three in number: the ligament of the head of the malleus, which is attached superiorly to the upper wall of the tympanum; the ligament of the incus, a short and thick band, which serves to attach the extremity of the short process of that bone to the margin of the opening of the mastoid cells; and the circular ligament, which connects the margin of the foot of the

stapes with the circumference of the fenestra ovalis. These ligaments have been described as muscles, by Mr. Tod, under the names of superior capitis mallei, obliquus incudis externus posterior, and musculus, vel structura stapedius inferior.

Fig. 169.



The *Muscles* of the *tympanum* are four in number, the—

Tensor tympani,
Laxator tympani,
Laxator tympani minor,
Stapedius.

The *Tensor tympani* (*musculus internus mallei*) arises from the spinous process of the sphenoid, from the petrous portion of the temporal bone, and from the Eustachian tube, and passes forwards in a distinct canal, separated from the tube by the *processus cochleariformis*, to be *inserted* into the handle of the malleus, immediately below the commencement of the *processus gracilis*.

Fig. 169. A diagram of the ear. *p.* The pinna. *t.* The tympanum. *l.* The labyrinth. 1. The upper part of the helix. 2. The antihelix. 3. The tragus. 4. The antitragus. 5. The lobulus. 6. The concha. 7. The upper part of the fossa innominata. 8. The meatus. 9. The membrana tympani, divided by the section. 10. The three little bones, crossing the area of the tympanum, malleus, incus, and stapes; the foot of the stapes blocks up the fenestra ovalis upon the inner wall of the tympanum. 11. The promontory. 12. The fenestra rotunda; the dark opening above the ossicula leads into the mastoid cells. 13. The Eustachian tube; the little canal upon this tube contains the tensor tympani muscle in its passage to the tympanum. 14. The vestibule. 15. The three semicircular canals, horizontal, perpendicular, and oblique. 16. The ampullæ upon the perpendicular and horizontal canals. 17. The cochlea. 18. A depression between the convexities of the two tubuli which communicate with the tympanum and vestibule; the one is the *scala tympani*, terminating at 12; the other is the *scala vestibuli*.

The *Laxator tympani* (musculus externus mallei) arises from the spinous process of the sphenoid bone, and passes through an opening in the fissura Glaseri, to be inserted into the long process of the malleus.

The *Laxator tympani minor* arises from the upper margin of the meatus, and is inserted into the handle of the malleus, near to the processus brevis. This is regarded as a ligament by some anatomists.

The *Stapedius* arises from the interior of the pyramid, and escapes from its summit to be inserted into the neck of the stapes.

The openings in the tympanum are ten in number, *five large* and *five small*; they are—

Large Openings.

Meatus auditorius,
Fenestra ovalis,
Fenestra rotunda,
Mastoid cells,
Eustachian tube.

Small Openings.

Entrance of the chorda tympani,
Exit of the chorda tympani,
For the laxator tympani,
For the tensor tympani,
For the stapedius.

The opening of the *meatus auditorius* has been previously described.

The *Fenestra ovalis* (fenestra vestibuli), is a reniform opening, situated at the bottom of a small oval fossa (the pelvis ovalis), in the upper part of the inner wall of the tympanum, directly opposite the meatus. The long diameter of the fenestra is directed horizontally, and its convex borders upwards. It is the opening of communication between the tympanum and the vestibule, and is closed by the foot of the stapes and by the lining membranes of both cavities.

The *Fenestra rotunda* (fenestra cochleæ) is somewhat triangular in its form, and situated in the inner wall of the tympanum, below and rather posteriorly to the fenestra ovalis, from which it is separated by a bony elevation, called the *promontory*. It serves to establish a communication between the tympanum and the cochlea. In the fresh subject it is closed by a proper membrane, as well as by the lining of both cavities.

The *Mastoid cells* are very numerous, and occupy the whole of the interior of the mastoid process, and part of the petrous bone. They communicate by a large irregular opening with the upper and posterior circumference of the tympanum.

The *Eustachian tube* is a canal of communication extending obliquely between the pharynx and the anterior circumference of the tympanum. In structure it is partly fibro-cartilaginous and partly osseous, is broad and expanded at its pharyngeal extremity, and narrow and compressed at the tympanum.

The *smaller openings* serve for the transmission of the chorda tympani nerve, and three of the muscles of the tympanum.

The *opening* by which the *chorda tympani* enters the tympanum,

is near the root of the pyramid, at about the middle of the *posterior wall*.

The *opening of exit* for the *chorda tympani* is at the fissura Glaseri in the *anterior wall* of the tympanum.

The *opening for the laxator tympani muscle* is also situated in the fissura Glaseri, in the *anterior wall* of the tympanum.

The *opening for the tensor tympani muscle* is in the *inner wall*, immediately above the opening of the Eustachian tube.

The *opening for the stapedius muscle* is at the apex of a conical bony eminence, called the pyramid, which is situated on the *posterior wall* of the tympanum, immediately behind the fenestra ovalis.

Directly *above* the fenestra ovalis is a *rounded ridge* formed by the projection of the *aquæductus Fallopii*.

Beneath the fenestra ovalis and separating it from the fenestra rotunda is the *promontory*, a rounded prominence formed by the projection of the first turn of the cochlea. It is channeled upon its surface by three small grooves, which lodge the three tympanic branches of Jacobson's nerve.

The *Foramina* and *processes of the tympanum* may be arranged, according to their situation, into four groups.

1. In the *External wall* is the *meatus auditorius*, closed by the *membrani tympani*.

2. In the *Inner wall*, from above downwards, are the—

Opening for the tensor tympani,
Ridge of the aquæductus Fallopii,
Fenestra ovalis,
Promontory,
Grooves for Jacobson's nerve,
Fenestra rotunda.

3. In the *Posterior wall* are the—

Opening of the mastoid cells,
Pyramid,
Opening for the stapedius,
Apertura chordæ (entrance).

4. In the *Anterior wall* are the—

Eustachian tube,
Fissura Glaseri,
Opening for the laxator tympani,
Apertura chordæ (exit).

The tympanum is lined by a *vascular mucous membrane*, which invests the ossicula and chorda tympani, and forms the internal layer of the *membrani tympani*. From the tympanum it is reflected into the mastoid cells, which it lines throughout, and passes through the Eustachian tube to become continuous with the mucous membrane of the pharynx.

Vessels and Nerves.—The *Arteries* of the tympanum are derived from the internal maxillary, internal carotid, and posterior auricular.

Its *Nerves* are—1. Minute branches from the *facial*, which are distributed to the stapedius muscle. 2. The *chorda tympani*, which leaves the facial nerve near to the stylo-mastoid foramen, and arches upwards to enter the tympanum at the root of the pyramid; it then passes forwards between the handle of the malleus and long process of the incus, to its proper opening in the fissura Glaseri. 3. The *tympanic branches of Jacobson's nerve*, which are distributed to the membranes of the fenestra ovalis and fenestra rotunda, and to the Eustachian tube, and form a plexus by communicating with the carotid plexus and otic ganglion. 4. A filament from the otic ganglion to the tensor tympani muscle.

INTERNAL EAR.

The *Internal ear* is called *labyrinth*, from the complexity of its communications: it consists of a membranous and an osseous portion. The osseous labyrinth presents a series of cavities which are channeled through the substance of the petrous bone, and is situated between the cavity of the tympanum and the meatus auditorius internus. It is divisible into the—

Vestibule,
Semicircular canals,
Cochlea.

The VESTIBULE is a small three-cornered cavity, compressed from without inwards, and situated immediately within the inner wall of the tympanum. The three corners which are named ventricles or cornua are placed, one anteriorly, one superiorly, and one posteriorly.

The anterior ventricle receives the oval aperture of the scala vestibuli; the superior, the ampullary openings of the superior and horizontal semicircular canals; the posterior ventricle receives the ampullary opening of the oblique semicircular canal, the common aperture of the oblique and perpendicular canals, the termination of the horizontal canal, and the aperture of the aquæductus vestibuli. In the *anterior ventricle* is a small depression, which corresponds with the posterior segment of the cul de sac of the meatus auditorius internus; it is called the fovea hemispherica, and is pierced by a cluster of small openings, the macula cribrosa. In the *superior ventricle* of the vestibule is another small depression, the fovea elliptica, which is separated from the fovea hemispherica by a projecting crest, the eminentia pyramidalis. The latter is pierced by numerous minute openings for the passage of nervous filaments. The *posterior ventricle* presents a third small depression, the fovea sulciformis, which leads upwards to the ostium aquæductus vestibuli. The *internal wall* of the vestibule corresponds with the bottom of the cul de sac of the meatus auditorius internus; and is pierced by numerous small openings for the transmission of nervous filaments. In the *external or tympanic wall* is the reniform opening of the

fenestra ovalis (fenestra vestibuli), the margin of which presents a projecting rim towards the cavity of the vestibule.

The openings of the vestibule may be arranged, like those of the tympanum, into *large* and *small*.

The *Large openings* are seven in number, viz. the—

- Fenestra ovalis,
- Scala vestibuli,
- Five openings of the three semicircular canals.

The *Small openings* are the—

- Aquæductus vestibuli,
- Openings for small arteries,
- Openings for branches of the auditory nerve.

The *Fenestra ovalis* has already been described; it is the opening into the tympanum.

The opening of the *scala vestibuli* is the oval termination of the vestibular canal of the cochlea.

The *Aquæductus vestibuli* (canal of Cotunnus) is the commencement of the small canal which opens under the osseous scale upon the posterior surface of the petrous bone. It gives a passage to a process of membrane which is continuous internally with the lining membrane of the vestibule, and externally with the dura mater, and to a small vein.

The *Openings* for the *arteries* and *nerves* are situated in the internal wall of the vestibule, and correspond with the termination of the meatus auditorius internus.

The SEMICIRCULAR CANALS are three bony passages which communicate with the vestibule, into which they open by both extremities. Near one extremity of each of the canals is a remarkable dilatation of its cavity, which is called the ampulla (sinus ampullaceus). The *superior* or perpendicular canal (canalis semicircularis verticalis superior), is directed transversely across the petrous portion of the temporal bone, forming a projection upon the anterior face of the petrous bone. It commences by means of an ampulla in the superior ventricle of the vestibule, and terminates posteriorly by joining with the oblique, and forming a common canal, which opens into the upper part of the posterior ventricle. The *middle* or *oblique* canal (canalis semicircularis verticalis posterior), corresponds with the posterior part of the petrous portion of the temporal bone; it commences by an ampullary dilatation in the posterior ventricle, and curves nearly perpendicularly upwards to terminate in the common canal. In the ampulla of this canal are numerous minute openings for nervous filaments. The *inferior* or *horizontal* canal (canalis semicircularis horizontalis), is directed outwards towards the base of the petrous bone, and is shorter than the two preceding. It commences by an ampullary dilatation in the superior ventricle, and terminates in the posterior ventricle.

The COCHLEA (*snail shell*) forms the anterior portion of the labyrinth, corresponding by its apex with the anterior wall of the petrous bone, and by its base with the anterior depression at the bottom of the cul de sac of the meatus auditorius internus. It consists of an osseous and gradually tapering canal, about one inch and a half in length, which makes two turns and a half spirally around a central axis called the modiulus.

The central axis or *modiulus* is large near its base where it corresponds with the first turn of the cochlea, and diminishes in diameter towards its extremity. At its base it is pierced by numerous minute openings which transmit the filaments of the cochlear nerve. These openings are disposed in a spiral manner, hence they have received from Cotunnus* the name of tractus spiralis foraminulentus. The modiulus is every where traversed in the direction of its length by minute canals, which proceed from the tractus spiralis foraminulentus, and terminate upon the sides of the modiulus, by opening into the canal of the cochlea or upon the surface of its lamina spiralis. The central canal of the tractus spiralis foraminulentus is larger than the rest, and is named the tubulus centralis modioli; it is continued onwards to the extremity of the modiulus, and transmits a nerve and a small artery, the arteria centralis modioli.

The interior of the canal of the cochlea is partially divided into two passages (*scalæ*) by means of a thin and porous lamina of bone (*zonula ossea laminæ spiralis*), which is wound spirally around the modiulus in the direction of the canal. This bony septum extends for about two-thirds across the diameter of the canal, and in the fresh subject is prolonged to the opposite wall by means of a membranous layer, so as to constitute a complete partition—the lamina

Fig. 170.

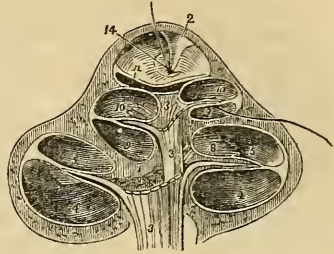


Fig. 170. The cochlea divided parallel with its axis, through the centre of the modiulus. After Breschet. 1. The modiulus. 2. The infundibulum in which the modiulus terminates. 3, 3. The cochlear nerve, sending its filaments through the centre of the modiulus. 4, 4. The scala tympani of the first turn of the cochlea. 5, 5. The scala vestibuli of the first turn. 6. Section of the lamina spiralis, its *zonula ossea*; one of the filaments of the cochlear nerve is seen passing between the two layers of the lamina spiralis to be distributed upon the membrane which invests the lamina. 7. The membranous portion of the lamina spiralis. 8. Loops formed by the filaments of the cochlear nerve. 9, 9. Scala tympani of the second turn of the cochlea. 10, 10. Scala vestibuli of the second turn; the septum between the two is the lamina spiralis. 11. The scala tympani of the remaining half turn. 12. The remaining half turn of the scala vestibuli; the dome placed over this half turn is the cupola. 13. The lamina of bone which forms the floor of the scala vestibuli curving spirally round to constitute the infundibulum (2). 14. The helicotrema through which a bristle is passed; its lower extremity issues from the scala tympani of the middle turn of the cochlea.

* Dominico Cotunnus, an Italian physician; his dissertation "*De Aquæductibus Auris Humanæ Internæ*," was published in Naples in 1761.

spiralis. The osseous lamina spiralis consists of two thin lamellæ of bone, between which, and through the perforations on their surfaces, the filaments of the cochlear nerve reach the membrane of the cochlea. At the apex of the cochlea the lamina spiralis terminates in a pointed, hook-shaped process, the hamulus laminæ spiralis.* The two scalæ of the cochlea which are completely separated throughout their length in the living ear, communicate superiorly over the hamulus laminæ spiralis by means of an opening common to both, which has been termed by Breschet *helico-trema* (ἑλιξ, ἐλίσσω volvere—τρήμα). Inferiorly, one of the two scalæ, the scala vestibuli, terminates by means of an oval aperture in the anterior ventricle of the vestibule; while the other, the scala tympani, becomes somewhat expanded, and opens into the tympanum through the fenestra rotunda (fenestra cochleæ). Near to the termination of the scala tympani is the small opening of the aquæductus cochleæ.

The internal surface of the osseous labyrinth is lined by a *fibro-serous membrane*, which is analogous to the dura mater in performing the office of a periosteum by its exterior, whilst it fulfils the purpose of a serous membrane by its internal layer, secreting a limpid fluid, the aqua labyrinthi (liquor Cotunnii), and sending a reflection inwards upon the nerves distributed to the membranous labyrinth. In the cochlea the membrane of the labyrinth invests the two surfaces of the bony lamina spiralis, and being continued from its border across the diameter of the canal to its outer wall, forms the membranous lamina spiralis and completes the separation between the scala tympani and scala vestibuli. The fenestra ovalis and fenestra rotunda are closed by an extension of this membrane across them, assisted by the membrane of the tympanum and a proper intermediate layer. Besides lining the interior of the osseous cavity the membrane of the labyrinth sends two delicate processes along the aqueducts of the vestibule and cochlea to the internal surface of the dura mater of the petrous portion of the temporal bone, with which they are continuous. These processes are the remains of a communication originally subsisting between the dura mater and the cavity of the labyrinth.*

The MEMBRANOUS LABYRINTH is smaller in size, but a perfect counterpart with respect to form, of the vestibule and semicircular canals. It consists of a small elongated sac, sacculus communis (utriculus communis); of three semicircular membranous canals, which correspond with the osseous canals, and communicate with the sacculus communis; and of a small round sac (sacculus proprius); which occupies the anterior ventricle of the vestibule, and

* Cotunnii regarded these processes as tubular canals, through which the superabundant aqua labyrinthi might be expelled into the cavity of the cranium. Mr. Wharton Jones, in the article "Organ of Hearing" in the *Cyclopædia of Anatomy and Physiology*, also describes them as tubular canals which terminate beneath the dura mater of the petrous bone in a small dilated pouch. In the ear of a man deaf and dumb from birth, he found the termination of the aqueduct of the vestibule of unusually large size in consequence of irregular development.

lies in close contact with the external surface of the sacculus communis.

The membranous semicircular canals are two-thirds smaller in diameter than the osseous canals. The membranous labyrinth is retained in its position by means of the numerous nervous filaments which are distributed to it from the openings in the inner wall of the vestibule, and is separated from the lining membrane of the labyrinth by the aqua labyrinthi.

The structure of the membranous labyrinth is composed of four layers: an external or serous layer, derived from the lining membrane of the labyrinth; a vascular layer, in which an abundance of minute vessels are distributed; a nervous layer formed by the expansion of the filaments of the vestibular nerve, and of an internal and serous membrane, by which the limpid fluid which fills the membranous labyrinth is secreted. Some small patches of pigment have been observed by Mr. Wharton Jones in the tissue of the membranous labyrinth of man. Among animals such spots are constant.

Fig. 171.

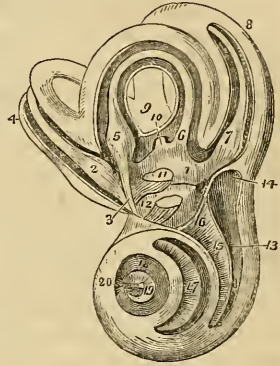


Fig. 171. The labyrinth of the left ear, laid open in order to show its cavities and the membranous labyrinth. After Breschet. 1. The cavity of the vestibule, opened from its anterior aspect in order to show the three-cornered form of its interior, and the membranous labyrinth which it contains. The figure rests upon the common sacculus of the membranous labyrinth,—the sacculus communis. 2. The ampulla of the superior or perpendicular semicircular canal, receiving a nervous fasciculus from the superior branch of the vestibular nerve. 3, 4. The superior or perpendicular canal with its contained membranous canal. 5. The ampulla of the inferior or horizontal semicircular canal, receiving a nervous fasciculus from the superior branch of the vestibular nerve. 6. The termination of the membranous canal of the horizontal semicircular canal in the sacculus communis. 7. The ampulla of the middle or oblique semicircular canal, receiving a nervous fasciculus from the inferior branch of the vestibular nerve. 8. The oblique semicircular canal with its membranous canal. 9. The common canal, resulting from the union of the perpendicular with the oblique semicircular canal. 10. The membranous common canal terminating in the sacculus communis. 11. The otoconite of the sacculus communis seen through the membranous parietes of that sac. A nervous fasciculus from the inferior branch of the vestibular nerve is seen to be distributed to the sacculus communis near to the otoconite. The extremity of the sacculus above the otoconite is lodged in the superior ventricle of the vestibule, and that below in the inferior ventricle. 12. The sacculus proprius situated in the anterior ventricle; its otoconite is seen through its membranous parietes, and a nervous fasciculus derived from the middle branch of the vestibular nerve is distributed to it. The spaces around the membranous labyrinth are occupied by the aqua labyrinthi. 13. The first turn of the cochlea; the figure is situated in the scala tympani. 14. The extremity of the scala tympani corresponding with the fenestra rotunda. 15. The lamina spiralis; the figure is situated in the scala vestibuli. 16. The opening of the scala vestibuli into the vestibule. 17. The second turn of the cochlea; the figure is placed upon the lamina spiralis, and therefore in the scala vestibuli, the scala tympani being beneath the lamina. 18. The remaining half turn of the cochlea; the figure is placed in the scala tympani. 19. The lamina spiralis terminating in a falciform extremity. The dark space included within the falciform curve of the extremity of the lamina spiralis is the helicotrema. 20. The infundibulum.

The membranous labyrinth is filled in the interior with a limpid fluid, first well described by Scarpa, and thence named liquor Scarpæ* (endolymph, vitreous humour of the ear,) and contains two small calcareous masses called otoconites. The otoconites (οὐζς, ὠτὸς κόνις, the ear-dust), consist of an assemblage of minute, crystalline particles of carbonate and phosphate of lime, held together by animal substance, and probably retained in form by a reflection of the lining membrane of the membranous labyrinth. They are found suspended in the liquor Scarpæ, one in the sacculus communis, and the other in the sacculus proprius, from that part of each sac with which the nerves are connected.

The AUDITORY NERVE divides into two branches at the bottom of the cul de sac of the meatus auditorius internus; a vestibular nerve, and a cochlear nerve. The *vestibular nerve*, the most posterior of the two, divides into three branches, superior, middle, and inferior. The superior vestibular branch gives off a number of filaments which pass through the minute openings of the eminentia pyramidalis, and of the superior ventricle of the vestibule, and are distributed to the sacculus communis, and to the ampullæ of the perpendicular and horizontal semicircular canals. The middle vestibular branch sends off numerous filaments which pass through the openings of the macula cribrosa in the anterior ventricle of the vestibule, and are distributed to the sacculus proprius. The inferior and smallest branch takes its course backwards to the posterior wall of the vestibule, and gives off filaments which pierce the wall of the ampullary dilatation of the oblique canal to be distributed upon its ampulla. According to Stiefensand there is in the situation of the point of entrance of the nervous filaments into the ampullæ a deep depression upon the exterior of the membrane, and upon the interior a corresponding projection, which forms a kind of transverse septum, partially dividing the cavity of the ampulla into two chambers.

Upon entering the structure of the sacculi and ampullæ, the nervous filaments radiate in all directions, anastomosing with each other, and forming interlacements and loops, and they terminate upon the inner surface of the membrane in minute papillæ, resembling those of the retina.

The *Cochlear nerve* divides into numerous filaments which enter the foramina of the tractus spiralis foraminulentus in the base of the cochlea, and passing upwards in the canals of the modiolus bend outwards at right angles, to be distributed in the tissue of the lamina spiralis. The central portion of the nerve passes through the tubulus centralis of the modiolus, and supplies the apical portion of the lamina spiralis. In the lamina spiralis the nervous filaments lying side by side on a smooth plane form numerous anasto-

* Antonio Scarpa is celebrated for several beautiful surgical and anatomical monographs; as, for example, his work on "Aneurism," "De Auditu et Olfactu," &c. An account of the aqua labyrinthi will be found in his anatomical observations "De Structurâ Fenestræ Rotundæ, et de Tympano Secundario."

mosing loops, and spread out ultimately into a nervous membrane. According to Treviranus and Gottsche the ultimate terminations of the filaments assume the form of papillæ.

The *Arteries* of the labyrinth are derived principally from the auditory branch of the superior cerebellar artery.

ORGAN OF TASTE.

The *Tongue* is composed of muscular fibres, which are distributed in layers arranged in various directions: thus, some are disposed *longitudinally*; others *transversely*; others, again, *obliquely* and *vertically*. Between the muscular fibres is a considerable quantity of adipose substance.

The tongue is *connected* posteriorly with the os hyoides by muscular attachment, and to the epiglottis by mucous membrane, forming the three folds which are called *fræna epiglottidis*. On either side it is held in connexion with the lower jaw by mucous membrane, and in front a fold of that membrane is formed beneath its under surface, which is named *frænum lingue*.

The surface of the tongue is covered by a dense layer analogous to the corium of the skin, which gives support to the papillæ. A *raphé* marks the middle line of the organ, and divides it into symmetrical halves.

The *Papillæ* of the *tongue* are the—

Papillæ circumvallatæ,
Papillæ conicæ,
Papillæ filiformes,
Papillæ fungiformes.

The *Papillæ circumvallatæ* are of large size, and from fifteen to twenty in number.* They are situated on the dorsum of the tongue, near to its root, and form a row upon each side, which meets its fellow at the middle line, like the two branches of the letter V. Each papillæ resembles a cone, attached by its apex to the bottom of a cup-shaped depression: hence they are also named *papillæ calyciformes*. This cup-shaped cavity forms a kind of fossa around the papilla, whence their name *circumvallatæ*.

At the meeting of the two rows of these papillæ upon the middle of the root of the tongue, is a deep mucous follicle called *foramen cæcum*.

The *Papillæ conicæ* and *filiformes* cover the whole surface of the tongue in front of the *circumvallatæ*, but are most abundant near its apex. They are conical and filiform in shape, and have their points directed backwards.

The *Papillæ fungiformes* are irregularly dispersed over the dorsum of the tongue, and are easily recognised amongst the other papillæ by their rounded heads and larger size. A number of these papillæ will generally be observed at the tip of the tongue.

* I think it rare to see more than nine, four on each side of the middle one, which is always the largest.—G.

Behind the papillæ circumvallatæ, at the root of the tongue, are a number of *mucous glands*, which open upon the surface. They have been improperly described as papillæ by some authors.

Vessels and Nerves.—The tongue is abundantly supplied with blood by the lingual arteries.

The *Nerves* are three in number, and of large size:—1. The *gustatory* branch of the fifth, which is distributed to the papillæ, and is the nerve of common sensation and of taste. 2. The *glosso-pharyngeal*, which is distributed to the mucous membrane, follicles, and glands of the tongue, is a nerve of sensation and motion; it also serves to associate the tongue with the pharynx and larynx. Panizza's experiments, tending to prove that this is the true nerve of taste, are rendered questionable by recent experiments. 3. The *lingual*, which is the motor nerve of the tongue, and is distributed to the muscles.

The *Mucous membrane* which invests the tongue, is continuous with the cutis along the margins of the lips. On either side of the frænum linguæ it may be traced through the sublingual ducts into the sublingual glands, and along Wharton's* ducts into the sub-maxillary glands; from the sides of the cheeks it passes through the openings of Stenon's† ducts to the parotid gland; in the fauces, it forms the assemblage of follicles called tonsils, and may be thence traced downwards into the larynx and pharynx, where it is continuous with the general gastro-pulmonary mucous membrane.

Beneath the mucous membrane of the mouth are a number of small *glandular granules*, which pour forth their secretion upon the surface. A considerable number of them are situated within the lips, in the palate, and in the floor of the mouth. They are named from the position which they may chance to occupy, *labial, palatine glands*, &c.‡

ORGAN OF TOUCH.

The *Skin* is composed of three layers, viz. the

Cutis,
Rete mucosum,
Cuticle.

The *Cutis* (dermis), or true skin, covers the entire surface of the body, and is continuous with the mucous membrane which lines its cavities. It consists of two layers, a deep one called *corium*, and a superficial or *papillary layer*.

The *Corium* is the base of support to the skin, and owes its density of structure to an interlacement of fibrous bands which form a

* Thomas Wharton, an English physician, devoted considerable attention to the anatomy of the various glands: his work, entitled "Adenographia," &c., was published in 1656.

† Nicholas Stenon, a Danish anatomist: he was made professor in Copenhagen in 1672.

‡ These glands are *salivary*, having the same structure as the parotid and secreting the same fluid.—G.

firm and elastic web. By its under surface it is connected with the common superficial fascia of the body, and presents a number of areolæ, in which are lodged small masses of adipose tissue.

On the upper surface the fibres are more closely aggregated, and form a smooth plane for the support of the papillary layer.

The corium differs very much in thickness in different parts of the body; thus, on the lips, eyelids, and scrotum it is extremely thin. On the head, back, soles of the feet, and palms of the hand it is very thick; and on the more exposed parts of the body it is much thicker than on those which are protected.

The *Papillary layer* is soft, and formed by minute papillæ which cover every part of its surface. On the body generally, the papillæ are very small and irregular in their distribution; they are best seen in the palm of the hand or sole of the foot, where they are disposed in linear ridges, as indicated by the markings on the cuticle. The ridges of papillæ in these situations are separated from each other by longitudinal furrows, and are divided by transverse furrows into small quadrilateral rounded masses. These quadrilateral masses are each composed of a considerable number of minute papillæ, which are conical in form and variable in length, one or two of the papillæ in each mass being generally longer than the rest. In the middle of the transverse furrow, between the papillæ, is the opening for the perspiratory duct.

The papillæ beneath the nail have a peculiar form and arrangement. At the root of the nail they are numerous, but small and very vascular; opposite to the part of the nail called *lunula*, they are scarcely raised above the surface, and less vascular; but beyond this point they form lengthened vascular plicæ, which afford a large surface of secretion. These lengthened papillæ deposit the horny

Fig. 172.

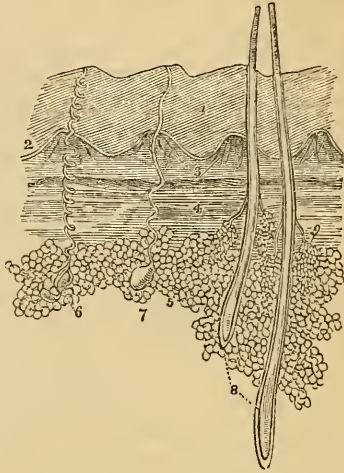
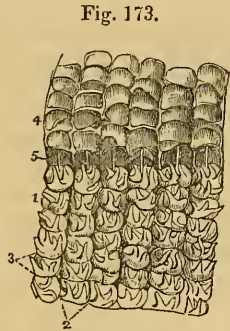


Fig. 172. The anatomy of the skin. 1. The cuticle, showing the oblique laminæ of which it is composed and the imbricated disposition of the ridges upon its surface. 2. The rete mucosum. 3. Two of the quadrilateral papillary masses, such as are seen in the palm of the hand or sole of the foot; they are composed of minute conical papillæ. 4. The deeper layer of the cutis, the corium. 5. Adipose vesicles; showing their appearance beneath the microscope. 6. A perspiratory gland with its spiral duct, such as is seen in the palm of the hand or sole of the foot. 7. Another perspiratory gland with a straighter duct, such as is seen in the scalp. 8. Two hairs on the scalp, enclosed in their follicles; their relative depth in the skin is preserved. 9. A pair of sebaceous glands, opening by short ducts into the follicle of the hair.

secretion in longitudinal lamellæ, which give to the nail the ribbed appearance which it presents upon its surface.

Vessels and Nerves.—The papillæ are abundantly supplied with vessels and nerves; the former to enable them to perform the office of secretion in the production of the cuticle, the latter to give them the sensibility necessary to an organ of touch.

The *Rete mucosum* is the soft medium which is situated between the papillary surface of the cutis and cuticle; after a careful maceration it may be separated as a distinct layer, particularly in the negro, where it is firmer than in the European, and contains the colouring matter of the skin.



The name *rete mucosum*, given to it by Malpighi, conveys a very inaccurate notion of its structure; for it is neither a network, nor is it mucous. It is thin upon the general surface of the body; but is thicker in the palm of the hand and sole of the foot, and presents a close correspondence with the thickness of the cuticle. Examined with the microscope, it is seen to be moulded accurately upon the papillæ, being thick in the spaces between these, and thin over their convexities; hence arises the appearance of a network. In the *rete mucosum* from the hand, these depressions are arranged in a linear series, as are the papillæ; in other situations they are more irregular, but correspond always with the distribution of the papillæ.

The *rete mucosum* is the freshly secreted layer of cuticle, and gradually hardens as it approaches the surface. It has been shown by Henle to be composed of minute oval vesicular cells, which become converted in the hardened cuticle into flattened scales, each containing a central nucleus. The dark pigment of the negro exists in the form of small granules of colouring matter.

The *cuticle* (epidermis, scarf-skin) is the horny unorganized lamella which covers and protects the entire surface of the more delicate layers of the skin. In situations exposed to pressure, as

Fig. 173. Anatomy of a portion of skin taken from the palm of the hand. 1, 1. The papillary layer, in which the longitudinal furrows (2) marking the arrangements of the papillæ into ridges is shown. Each ridge is moreover divided by transverse furrows (3) into small quadrangular masses. The quadrangular masses consist of a tuft of minute conical papillæ, of which one or two are frequently longer and larger than the rest. In this figure the long papillæ are alone seen, the rest being too numerous to introduce into a wood-engraving. 4, 4. The *rete mucosum* raised from the papillary layer and turned back; the under surface of this stratum presents an accurate impression of the papillary layer; on which are seen longitudinal ridges corresponding with the longitudinal furrows, transverse ridges corresponding with the transverse furrows, and quadrangular depressions corresponding with the quadrangular masses of papillæ. Moreover, wherever one of the long papillæ exists, a distinct conical sheath will be found in the *rete mucosum*. 5, 5. Perspiratory ducts drawn out straight by the separation of the *rete mucosum* from the papillary layer; the point at which each perspiratory duct issues from the papillary layer, and pierces the *rete mucosum*, is the middle of the transverse furrow between the quadrangular masses.

the palm of the hand and sole of the foot, it is very thick; on other parts it forms only a thin layer. The cuticle is marked on the surface by a network of lines: these are more numerous and larger near to joints, where they form deep wrinkles on account of the inelastic nature of its structure. Their appearance differs in different regions of the body; but every where depends upon the same cause, the inelasticity of the cuticle. At the entrance to the cavities of the body it is continuous with the epithelium or cuticular covering of the mucous membrane.

The cuticle, in minute structure, consists of several successions of laminæ which are secreted by the cutis; the last secreted layer being the rete mucosum. The rete mucosum is composed of small round masses or nuclei, connected together by a glutinous fluid containing a number of pigment granules. Each nucleus contains in its interior a minute central point, the nucleus-corporuscle, and around the exterior of the nucleus a vesicle is by degrees produced. The middle laminæ of the cuticle are composed of these nucleated vesicles, which are more and more compressed and flattened as they are observed nearer to the surface. In the superficial laminæ the vesicles are converted into thin scales, in the centre of which the nucleus with the nucleus-corporuscle is still apparent. The laminæ of the cuticle are disposed on the same plane with the surface of the skin in many situations, in others they are placed obliquely, so as to project by their free extremities upon the surface; in the palm of the hand and sole of the foot these layers correspond with the elevations of the papillæ, and present an imbricated linear surface. This is particularly seen on the points of the fingers where the rows of papillæ have a circular arrangement. The superficial laminæ of the cuticle are being continually thrown off by exfoliation or removed by abrasion, to give place to the deep and more newly formed layers.

Upon the inner surface of the cuticle a number of depressions and linear furrows are seen, corresponding with the projections of the papillæ. A number of conical processes are also observed on this surface, which correspond with the passage of hairs through the cuticle, and with the openings of the perspiratory ducts.

The *Openings in the cuticle* are the *pores* or openings for the perspiratory ducts, the openings for the passage of the hairs, and those of the sebaceous follicles.

APPENDAGES TO THE SKIN.

The appendages to the skin are the nails, hairs, sebaceous glands, and perspiratory glands and ducts.

The *Nails* are parts of the cuticle secreted in the same manner, composed of the same material, but disposed in a peculiar way to serve an especial purpose—the protection of the tactile extremities of the fingers. They are inserted by their root into a deep groove (matrix) of the skin, and are firmly attached to the papillary surface by the close connexion of the papillæ with the longitudinal laminæ.

The white semilunar segment near the root of the nail is called the *lunula*. The cuticle is closely connected with it all round, and in maceration the nail comes off with that layer.

The *Hairs* have a very different structure and arrangement from that of the nails: they are inserted for a considerable depth within the integument, and terminate in conical or somewhat bulbous roots. Each hair is enclosed beneath the surface by a vascular secretory follicle, which regulates its form during growth.

Hairs are very rarely completely cylindrical; they are generally more or less compressed, and somewhat prismoid in form. The transverse section is reniform; in texture it is dense and homogeneous towards the circumference, and porous and cellular in the centre like the pith of a plant.

The *Sebaceous glands* are abundant in some parts of the skin, as in the armpits, the nose, &c., and vary in complexity of structure from a simple pouch-like follicle to a lobulated gland. At the extremity of the nose they have several lobes; and in the scalp they are lobulated like a bunch of grapes, and terminate in the follicles of the hairs near to the surface of the skin. They secrete an oily fluid which is poured out upon the surface of the skin, and tends to preserve the flexibility of the cuticle.

The *Perspiratory ducts* are minute spiral tubes which commence in small lobulated glands, situated deeply in the integument beneath the corium and among the adipose vesicles. They are easily seen by examining a thin perpendicular section of the skin from the palm of the hand, with a lens of moderate power. Proceeding from the glands, the ducts ascend through the transverse furrow, between the quadrilateral masses of papillæ and through the rete mucosum to terminate by open pores upon the surface of the cuticle. That portion of the tube which is situated in the cuticle, is pretty equally spiral; but that below the level of the papillary surface is very irregularly twisted, and is often nearly straight. In the scalp the tubes are serpentine, or but slightly curved.

A good view of the perspiratory ducts passing between the cutis and cuticle, may be obtained by peeling off the cuticle from the palm of the hand in a decomposing limb; or by scalding a small portion of integument and then separating the cuticle.

The *Pores* are best observed during perspiration, when the fluid is seen oozing through their minute openings. In the hand and sole of the foot they are easily seen by the naked eye without this assistance. They are disposed at regular distances along the ridges of the cuticle, and give rise to the appearance of lines cutting the ridges transversely.

CHAPTER X.

OF THE VISCERA.

THAT part of the science of anatomy which treats of the viscera is named splanchnology, from the Greek words *σπλάγχνον*, viscus, and *λόγος*. The viscera of the human body are situated in the three great internal cavities,—the cranio-vertebral, thorax, and abdomen. The viscera of the cranio-vertebral cavity—the brain and spinal cord, with the principal organs of sense have been already described, in conjunction with the nervous system. The viscera of the chest are—the central organ of circulation, the heart; the organs of respiration, the lungs; and the thymus gland. The abdominal viscera admit of a subdivision into those which properly belong to that cavity, viz. the alimentary canal, liver, pancreas, spleen, kidneys, and supra-renal capsules, and those of the pelvis—the bladder and internal organs of generation.

THORAX.

The thorax is the conical cavity, situated at the upper part of the trunk of the body; it is narrow above and broad below, and is bounded *in front* by the sternum, six superior costal cartilages, ribs, and intercostal muscles; *laterally*, by the ribs and intercostal muscles; and, *behind*, by the same structures, and by the vertebral column, as low down as the upper border of the last rib and the first lumbar vertebra; *superiorly*, by the thoracic fascia and first ribs; and, *inferiorly*, by the diaphragm. It is much deeper on the posterior than on the anterior wall, in consequence of the obliquity of the diaphragm, and contains the heart, enclosed in its pericardium, with the great vessels; the lungs, with their serous coverings, the pleuræ; the œsophagus; some important nerves; and, in the fœtus, the thymus gland.

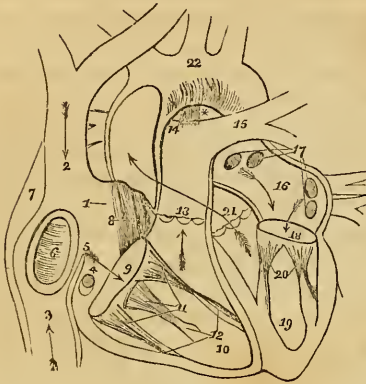
THE HEART.

The central organ of circulation, the heart, is situated between the two layers of pleura, which constitute the mediastinum, and is enclosed in a proper membrane, the pericardium.

Pericardium.—The pericardium is a fibro-serous membrane like the dura mater, and resembles that membrane in deriving its serous layer from the reflected serous membrane of the viscus which it encloses. It consists, therefore, of two layers, an external fibrous and an internal serous. The *fibrous* layer is attached above, to the great vessels at the root of the heart, where it is continuous with

the thoracic fascia; and below to the tendinous portion of the diaphragm. The serous membrane invests the heart with the commencement of its great vessels, and is then reflected upon the internal surface of the fibrous layer.

Fig. 174.



by the left. Surmounting the ventricles are the corresponding auricles, whose auricular appendages are directed forwards, and slightly overlap the root of the pulmonary artery. The pulmonary artery is the large anterior vessel at the root of the heart; it crosses obliquely the commencement of the aorta. The heart consists of two auricles and two ventricles, which are respectively named, from their position, right and left. The right is the venous side of the heart; it receives into its auricle venous blood from every part of the body, by the superior and inferior cava and coronary vein. From the auricle the

Fig. 174. The anatomy of the heart. 1. The right auricle. 2. The entrance of the superior vena cava. 3. The entrance of the inferior cava. 4. The opening of the coronary vein, half closed by the coronary valve. 5. The Eustachian valve. 6. The fossa ovalis, surrounded by the annulus ovalis. 7. The tuberculum Loweri. 8. The musculi pectinati in the appendix auriculæ. 9. The auriculo-ventricular opening. 10. The cavity of the right ventricle. 11. The tricuspid valve, attached by the chordæ tendineæ to the carnæ columnæ (12). 13. The pulmonary artery, guarded at its commencement by three semilunar valves. 14. The right pulmonary artery, passing beneath the arch and behind the ascending aorta. 15. The left pulmonary artery, crossing in front of the descending aorta. * The remains of the ductus arteriosus, acting as a ligament between the pulmonary artery and arch of the aorta. The arrows mark the course of the venous blood through the right side of the heart. Entering the auricle by the superior and inferior cavæ, it passes through the auriculo-ventricular opening into the ventricle, and thence through the pulmonary artery to the lungs. 16. The left auricle. 17. The openings of the four pulmonary veins. 18. The auriculo-ventricular opening. 19. The left ventricle. 20. The mitral valve, attached by its chordæ tendineæ to two large columnæ carnæ, which project from the walls of the ventricle. 21. The commencement and course of the ascending aorta behind the pulmonary artery, marked by an arrow. The entrance of the vessel is guarded by three semilunar valves. 22. The arch of the aorta. The comparative thickness of the two ventricles is shown in the diagram. The course of the pure blood through the left side of the heart is marked by arrows. The blood is brought from the lungs by the four pulmonary veins into the left auricle, and passes through the auriculo-ventricular opening into the left ventricle, whence it is conveyed by the aorta to every part of the body.

blood passes into the ventricle, and from the ventricle through the pulmonary artery, to the capillaries of the lungs. From these it is returned as arterial blood to the left auricle; from the left auricle it passes into the left ventricle; and from the left ventricle is carried through the aorta, to be distributed to every part of the body, and again returned to the heart by the veins. This constitutes the course of the *adult circulation*.

The heart is best studied *in situ*. If, however, it be removed from the body, it should be placed in the position indicated in the above description of its situation. A transverse incision should then be made along the ventricular margin of the right auricle, from the appendix to its right border, and crossed by a perpendicular incision, carried from the side of the superior to the inferior cava. The blood must then be removed. Some fine specimens of white fibrin are frequently found with the coagula; occasionally they are yellow and gelatinous. This appearance deceived the older anatomists, who called these substances "polypus of the heart;" they are also frequently found in the right ventricle, and sometimes in the left cavities.

The **RIGHT AURICLE** is larger than the left, and is divided into a principal cavity or sinus, and an appendix auriculæ. The interior of the sinus presents for examination five openings; two valves; two relics of fœtal structure; and two peculiarities in the proper structure of the auricle. They may be thus arranged:

Openings	{	Superior cava, Inferior cava, Coronary vein, Foramina Thebesii, Auriculo-ventricular opening.
Valves	{	Eustachian valve, Coronary valve.
Relics of fœtal structure .	{	Annulus ovalis, Fossa ovalis.
Structure of the Auricle .	{	Tuberculum Loweri, Musculi pectinati.

The *Superior cava* returns the blood from the upper half of the body, and opens into the upper and front part of the auricle.

The *Inferior cava* returns the blood from the lower half of the body, and opens into the lower and posterior wall, close to the partition between the auricles (septum auriculorum). The direction of these two vessels is such, that a stream forced through the superior cava would be directed towards the auriculo-ventricular opening. In like manner, a stream rushing upwards by the inferior cava would force its current against the septum auriculorum; this is the proper direction of the two currents during fœtal life.

The *Coronary vein* returns the venous blood from the substance

of the heart; it opens into the auricle between the inferior cava and the auriculo-ventricular opening, under cover of the coronary valve.

The *Foramina Thebesii** are minute pore-like openings, by which the venous blood exhales directly from the muscular structure of the heart into the auricle, without entering the venous current. These openings are also found in the left auricle, and in the right and left ventricles.

The *Auriculo-ventricular opening* is the large opening of communication between the auricle and ventricle.

The *Eustachian† valve* is a part of the apparatus of fetal circulation, and serves to direct the placental blood from the inferior cava, through the foramen ovale into the left auricle. In the adult it is a mere vestige and imperfect, though sometimes it remains of large size. It is formed by a fold of the lining membrane of the auricle, containing some muscular fibres, is situated between the opening of the inferior cava and the auriculo-ventricular opening, and is generally connected with the coronary valve.

The *Coronary valve* is a semilunar fold of the lining membrane, stretching across the mouth of the coronary vein, and preventing the reflux of the blood in the vein during the contraction of the auricle.

The *Annulus ovalis* is situated on the septum auriculorum, opposite the termination of the inferior cava. It is the rounded margin of the septum, which occupies the place of the foramen ovale of the fœtus.

The *Fossa ovalis* is an oval depression corresponding with the foramen ovale in the fœtus. This opening is closed at birth by a thin valvular layer, which is continuous with the left margin of the annulus and is frequently imperfect at its upper part. The depression or fossa in the right auricle results from this arrangement. There is no fossa ovalis in the left auricle.

The *Tuberculum Loweri‡* is the portion of auricle intervening between the openings of the superior and inferior cava. Being thicker than the walls of the veins it forms a projection, which was supposed by Lower to direct the blood from the superior cava into the auriculo-ventricular opening.

The *Musculi pectinati* are small muscular columns situated in the appendix auriculæ. They are very numerous, and are arranged parallel with each other; hence their cognomen, "*pectinati*," like the teeth of a comb.

THE RIGHT VENTRICLE is triangular and three-sided in its form.

* Adam Christian Thebesius. His discovery of the openings now known by his name, is contained in his "Dissertatio Medica de Circulo Sanguinis in Corde," 1708.

† Bartholomew Eustachius, born at San Severino, in Naples, was Professor of Medicine in Rome, where he died in 1570. He was one of the founders of modern anatomy, and the first who illustrated his works with good engravings on copper.

‡ Richard Lower, M.D. "Tractatus de Cõrde; item de Motu et Colore Sanguinis," 1669. His dissections were made upon quadrupeds, and his observations relate rather to animals than to man.

Its anterior side is convex, and forms the larger proportion of the front of the heart. The inferior side is flat, and rests upon the diaphragm: and the inner side corresponds with the partition between the two ventricles, septum ventriculorum.

The right ventricle is to be laid open by making an incision parallel with, and a little to the right of, the middle line, from the pulmonary artery in front, to the apex of the heart, and thence by the side of the middle line behind, to the auriculo-ventricular opening.

It contains, to be examined, two openings, the auriculo-ventricular and that of the pulmonary artery; two apparatus of valves, the tricuspid and semilunar; and a muscular and tendinous apparatus belonging to the tricuspid valves. They may be thus arranged:

Auriculo-ventricular opening,
Opening of the pulmonary artery.
Tricuspid valves,
Semilunar valves.
Chordæ tendineæ,
Carneæ columnæ.

The *Auriculo-ventricular opening* is surrounded by a fibrous ring, covered by the lining membrane of the heart. It is the opening of communication between the right auricle and ventricle.

The *Opening of the pulmonary artery* is situated close to the septum ventriculorum, on the left side of the right ventricle, and upon the anterior aspect of the heart.

The *Tricuspid valves* are three triangular folds of the lining membrane, strengthened by a thin layer of fibrous tissue. They are connected by their base around the auriculo-ventricular opening; and by their sides and apices, which are thickened, they give attachment to a number of slender tendinous cords, called chordæ tendineæ. The *chordæ tendineæ* are the tendons of the thick muscular columns (*columnæ carneæ*) which stand out from the walls of the ventricle, and serve as muscles to the valves. A number of these tendinous cords converge to a single muscular attachment. The tricuspid valves prevent the regurgitation of blood into the auricle during the contraction of the ventricle, and they are prevented from being themselves driven back, by the chordæ tendineæ and their muscular attachments.

This connexion of the muscular columns of the heart to the valves has caused their division into active and passive. The *active* valves are the tricuspid and mitral; the *passive* the mere folds of lining membrane, viz. the semilunar, Eustachian, and coronary.

Mr. T. W. King, of Guy's Hospital, has made the tricuspid valves a subject of special investigation, and has recorded his observations in a very interesting paper* in the Guy's Hospital Reports. The valves consist, according to Mr. King, of *curtains, cords*, and

* "Essay on the Safety Valve Function in the Right Ventricle of the Human Heart," by T. W. King. Guy's Hospital Reports, vol. ii.

columns. The *anterior valve* or *curtain* is the largest, and is so placed as to prevent the filling of the pulmonary artery during the distension of the ventricle. The *right valve* or *curtain* is of smaller size, and is situated upon the right side of the auriculo-ventricular opening. The third valve, or "*fixed curtain*" is connected by its cords to the septum ventriculorum. The *cords* (chordæ tendineæ) of the anterior curtain are attached, principally, to a long *column* (columna carnea), which is connected with the "right or thin and yielding wall of the ventricle." From the lower part of this column a transverse muscular band, the "*long moderator band*" is stretched to the septum ventriculorum or "*solid wall*" of the ventricle. The right curtain is connected, by means of its *cords*, partly with the long column, and partly with its own proper column, the *second column*, which is also attached to the "*yielding wall*" of the ventricle. A third and smaller column is generally connected with the right curtain. The "*fixed curtain*" is named from its attachment to the "*solid wall*" of the ventricle, by means of cords only, without fleshy columns.

From this remarkable arrangement of the valves it follows, that if the right ventricle be over distended, the thin or "*yielding wall*" will give way, and carry with it the columns of the anterior and right valves. The cords connected with these columns will draw down the edges of the corresponding valves, and produce an opening between the curtains, through which the superabundant blood may escape into the auricle, and the ventricle be relieved from over-pressure. This beautiful mechanism is therefore adapted, to fulfil the "function of a *safety valve*."

The *Columnæ carneæ* (fleshy columns) is a name expressive of the appearance of the internal walls of the ventricles, which seem formed of muscular columns interlacing in almost every direction. They are divided into three sets, according to the manner of their connexion. 1. The greater number are attached by the whole of one side, and merely form convexities into the cavity of the ventricle. 2. Others are connected by both extremities, being free in the middle. 3. A few (*columnæ papillares*) are attached by one extremity to the walls of the heart, and by the other give insertion to the chordæ tendineæ.

The *Semilunar valves*, three in number, are situated around the commencement of the pulmonary artery, being formed by a folding of its lining membrane, strengthened by a thin layer of fibrous tissue. They are attached by their convex borders, and free by the concave, which are directed upwards in the course of the vessel, so that, during the current of the blood along the artery they are pressed against the sides of the cylinder; but if any attempt at regurgitation ensue they are immediately expanded, and effectually close the entrance of the tube. The margins of the valves are thicker than the rest of their extent, and each valve presents in the centre of this

margin a small fibro-cartilaginous tubercle, called *corpus Arantii*,* which locks in with the two others during the closure of the valves, and secures the triangular space that would otherwise be left by the approximation of three semilunar folds.

Between the semilunar valves and the cylinder of the artery are three pouches, called the *pulmonary sinuses*. Similar sinuses are situated behind the valves at the commencement of the aorta, and are much larger and more capacious than those of the pulmonary artery.

The *Pulmonary artery* commences by a scalloped border, corresponding with the three valves which are attached along its edge. It is connected to the ventricle by muscular fibres, and by the lining membrane of the heart.

The LEFT AURICLE is somewhat smaller than the right; of a cuboid form, and situated more posteriorly. The *appendix auriculæ* is constricted at its junction with the auricle, and has an arborescent appearance; it is directed forwards towards the root of the pulmonary artery, to which the auriculæ of both sides appear to converge.

The left auricle is to be laid open by a \perp shaped incision, the horizontal section being made along the border which is attached to the base of the ventricle.

It presents for examination five openings, and the muscular structure of the appendix; these are,—

Four pulmonary veins,
Auriculo-ventricular opening,
Musculi pectinati.

The *Pulmonary veins*, two from the right and two from the left lung, open into the corresponding sides of the auricle. The two left pulmonary veins terminate frequently by a common opening.

The *Auriculo-ventricular opening* is the aperture of communication between the auricle and ventricle.

The *Musculi pectinati* are fewer in number than in the right auricle, and are situated only in the appendix auriculæ.

LEFT VENTRICLE.—The left ventricle is to be opened, by making an incision a little to the left of the septum ventriculorum, and continuing it around the apex of the heart, to the auriculo-ventricular opening behind.

The left ventricle is conical, both in external figure and in the form of its internal cavity. It forms the apex of the heart, by projecting beyond the right ventricle, while the latter has the advantage in length towards the base. Its walls are about seven lines in thickness, those of the right ventricle being about two lines and a half.

It presents for examination, in its interior, two openings, two

* Julius Cæsar Arantius, Professor of Medicine in Bologna. He was a disciple of Vesalius, one of the founders of modern anatomy. His treatise "De Humani Fætus," was published at Rome, in 1564.

valves, and the tendinous cords and muscular columns; they may be thus arranged:

Auriculo-ventricular opening,
Aortic opening.
Mitral valves,
Semilunar valves.
Chordæ tendineæ,
Columnæ carneæ.

The *Auriculo-ventricular opening* is a dense fibrous ring, covered by the lining membrane of the heart, but smaller in size than that of the right side.

The *Mitral valves* are attached around the auriculo-ventricular opening, as are the tricuspid in the right ventricle. They are thicker than the tricuspid, and consist of only two segments, of which the larger is placed between the auriculo-ventricular opening and the commencement of the aorta, and acts the part of a valve to that foramen, during the filling of the ventricle. The difference in size of the two valves, both being triangular, and the space between them, has given rise to the idea of a "*bishop's mitre*," after which they are named. These valves, like the tricuspid, are furnished with an apparatus of tendinous cords, *chordæ tendineæ*, which are attached to two very large *columnæ carneæ*.

The *Columnæ carneæ* admit of the same arrangement into three kinds, as on the right side. Those which are free by one extremity, the *columnæ papillares*, are only two in number, and much larger than those on the opposite side.

The *Semilunar valves* are placed around the commencement of the aorta, like those of the pulmonary artery; they are similar in structure, and are attached to the scalloped border by which the aorta is connected with the ventricle. The tubercle in the centre of each fold is larger than those in the pulmonary valves, and it was these that Arantius particularly described; but the term "*corpora Arantii*" is now applied indiscriminately to both. The fossæ between the semilunar valves and the cylinder of the artery are much larger than those of the pulmonary artery; they are called the "*sinus aortici*."

STRUCTURE OF THE HEART.

The arrangement of the fibres of the heart has been made the subject of careful and accurate investigation by Mr. Searle, to whose excellent article, "*Fibres of the Heart*," in the *Cyclopædia of Anatomy and Physiology*, I am indebted for the following summary of their distribution:

For the sake of clearness of description the fibres of the ventricles have been divided into three layers,—superficial, middle, and internal—all of which are disposed in a spiral direction around the cavities of the ventricles. The mode of formation of these three

layers will be best understood by adopting the plan pursued by Mr. Searle in tracing the course of the fibres from the centre of the heart towards its periphery.

The left surface of the septum ventriculorum is formed by a broad and thick layer of fibres, which proceed backwards in a spiral direction around the posterior aspect of the left ventricle, and become augmented on the left side of that ventricle, by other fibres derived from the bases of the two columnæ papillares. The broad and thick band formed by the fibres from these two sources, curves around the apex and lower third of the left ventricle, to the anterior border of the septum, where it divides into two bands,—a short or apical band, and a long or basal band.

The *Short or apical band* is increased in thickness at this point by receiving a layer of fibres (derived from the root of the aorta and carnæ columnæ) upon its internal surface, from the right surface of the septum ventriculorum; it is then continued onwards in a spiral direction from left to right, around the lower third of the anterior surface, and the middle third of the posterior surface of the right ventricle to the posterior border of the septum. From the latter point the short band is prolonged around the posterior and outer border of the left ventricle to the anterior surface of the base of that ventricle, and is inserted into the anterior border of the left auriculo-ventricular ring, and the anterior part of the root of the aorta and pulmonary artery.

The *Long or basal band*, at the anterior border of the septum, passes directly backwards through the septum, forming its middle layer, to the posterior ventricular groove, where it becomes joined by fibres derived from the root of the pulmonary artery. It then winds spirally around the middle and upper third of the left ventricle to the anterior border of the septum, where it is connected by means of its internal surface with the superior fibres derived from the aorta, which form part of the right wall of the septum. From this point it is continued around the upper third of the anterior and posterior surface of the right ventricle to the posterior border of the septum, where it is connected with the fibres constituting the right surface of the septum ventriculorum. At the latter point the fibres of this band begin to be twisted upon themselves, like the strands of a rope, the direction of the twist being from below upwards. This arrangement of fibres is called, by Mr. Searle, "the rope;" it is continued spirally upwards, forming the brim of the left ventricle, to the anterior surface of the base of that ventricle, where the twisting of the fibres ceases. The long band then curves inwards towards the septum, and spreads out upon the left surface of the septum into the broad and thick layer of fibres with which this description commenced.

The most inferior of the fibres of the left surface of the septum ventriculorum, after winding spirally around the internal surface of the apex of the left ventricle, so as to close its extremity, form a small fasciculus, which is excluded from the interior of the ventricle,

and expands in a radiated manner over the surface of the heart, constituting its superficial layer of fibres. The direction of these fibres is, for the most part, oblique, passing from left to right on the anterior, and from right to left on the posterior surface of the heart, becoming more longitudinal near its base, and terminating by being inserted into the fibrous rings of the auriculo-ventricular openings, and of the pulmonary artery and aorta. Over the right ventricle the superficial fibres are increased in number by the addition of accessory fibres from the right surface of the septum, which pierce the middle layer, and take the same direction with the superficial fibres from the apex of the left ventricle, and of other accessory fibres from the surface of both ventricles.

From this description it will be perceived, that the *superficial layer* of fibres is very scanty, and is pretty equally distributed over the surface of both ventricles. The *middle layer* of both ventricles is formed by the two bands, short and long. But the *internal layer* of the two ventricles is very differently constituted: that of the left is formed by the spiral expansion of the fibres of the rope, and of the two columnæ papillares; that of the right remains to be described. The septum ventriculorum also consists of three layers, a *left layer*, the radiated expansion of the rope and carneæ columnæ; a *middle layer*, the long band; and a *right layer*, belonging to the proper wall of the right ventricle, and continuous both in front and behind with the long band, and in front also with the short band, and with the superficial layer of the right ventricle.

The *Internal layer* of the *right ventricle* is formed by fasciculi of fibres which arise from the right segment of the root of the aorta, from the entire circumference of the root of the pulmonary artery, and from the bases of the columnæ papillares. The fibres from the root of the aorta, associated with some from the carneæ columnæ, constitute a layer which passes obliquely forwards upon the right side of the septum. The superior fibres coming directly from the aorta join the internal surface of the long band at the anterior border of the septum, while the lower two-thirds of the layer are continuous with the internal surface of the short band, some of its fibres piercing that band to augment the number of superficial fibres. The fibres derived from the root of the pulmonary artery, conjoined with those from the base of one of the columnæ papillares, curve forwards from their origin, and wind obliquely downwards and backwards around the internal surface of the wall of the ventricle to the posterior border of the septum, where they become continuous with the long band, directly that it has passed backwards through the septum.

Fibres of the Auricles.—The fibres of the auricles are disposed in two layers, external and internal. The *internal layer* is formed of fasciculi which arise from the fibrous rings of the auriculo-ventricular openings, and proceed upwards to enlase with each other, and constitute the appendices auriculorum. These fasciculi are parallel in their arrangement, and in the appendices form projec-

tions and give rise to the appearance which is denominated *musculi pectinati*. In their course they give off branches which connect adjoining fasciculi, and form a columnar interlacement between them.

External Layer.—The fibres of the right auricle having completed the appendix, wind from left to right around the right border of this auricle, and along its anterior aspect, beneath the appendix, to the anterior surface of the septum. From the septum they are continued to the anterior surface of the left auricle, where they separate into three bands,—superior, anterior, and posterior. The *superior band* proceeds onwards to the appendix, and encircles the apex of the auricle. The *anterior band* passes to the left, beneath the appendix, and winds a broad layer completely around the base of the auricle, and through the septum to the root of the aorta, to which it is partly attached, and from this point is continued onwards to the appendix, where its fibres terminate by interlacing with the *musculi pectinati*. The *posterior band* crosses the left auricle obliquely to its posterior part, and winds from left to right around its base, encircling the openings of the pulmonary veins; some of its fibres are lost upon the surface of the auricle, others are continued onwards to the base of the aorta; and a third set, forming a small band, is prolonged along the anterior edge of the appendix to its apex, where it is continuous with the *superior band*. The *septum auriculorum* has four sets of fibres entering into its formation; 1. The fibres arising from the auriculo-ventricular rings at each side; 2. Fibres arising from the root of the aorta, which pass upwards to the transverse band, and to the root of the superior cava; 3. Those fibres of the anterior band that pass through the lower part of the septum in their course around the left auricle; and 4. A slender fasciculus, which crosses through the septum from the posterior part of the right auriculo-ventricular ring to the left auricle.

It will be remarked from this description, that the left auricle is considerably thicker and more muscular than the right.

Vessels and Nerves.—The *Arteries* supplying the heart are the anterior and posterior coronary.

The *Veins* accompany the arteries, and empty themselves by the common coronary vein into the right auricle. The *lymphatics* terminate in the glands about the root of the heart. The *nerves* of the heart are derived from the cardiac plexuses, which are formed by communicating filaments from the sympathetic and pneumogastric.

ORGANS OF RESPIRATION AND VOICE.

The organs of respiration are the two lungs, with their air-tube, the trachea, to the upper part of which is adapted an apparatus of cartilages, constituting the organ of voice, or larynx.

THE LARYNX.

The *Larynx* is situated at the forepart of the neck, between the trachea, and at the base of the tongue. It is composed of *cartilages*, *ligaments*, *muscles*, *vessels*, and *nerves*, and *mucous membrane*.

The *Cartilages* are the—

Thyroid,
Cricoid,
Two Arytenoid,
Epiglottis.

The *Thyroid* (θυρεός—εἶδος, like a shield) is the largest cartilage of the larynx: it consists of two lateral portions, or *alæ*, which meet at an acute angle in front, and form the projection which is known by the name of *pomum Adami*. Where the pomum Adami is prominent, a bursa mucosa is often found between it and the skin.

Each ala is quadrilateral, and forms a rounded border posteriorly, which terminates above, in the *superior cornu*, and below, in the *inferior cornu*. Upon the side of the ala is an *oblique line*, into which the sterno-thyroid muscle is inserted, and from which the thyro-hyoid takes its origin. Behind this is a *vertical line*, which gives origin to the inferior constrictor muscle. In the *receding angle*, formed by the meeting of the two alæ upon the inner side of the cartilage, and near to its lower border, are attached the epiglottis, the chordæ vocales, the thyro-arytenoid, and thyro-epiglottidean muscles.

The *Cricoid* (κρίκος—εἶδος, like a ring) is a ring of cartilage, narrow in front and broad behind, where it is surmounted by *two rounded surfaces*, which articulate with the arytenoid cartilages. Upon the middle line, posteriorly, is a *vertical ridge*, which gives attachment to the œsophagus, and on each side of the ridge are the depressions which lodge the crico-arytenoidei postici muscles. On either side of the ring is a *glenoid cavity*, which articulates with the inferior cornu of the thyroid cartilage.

The *Arytenoid cartilages* (ἀρυταινα, a pitcher,)* two in number, are triangular in form. They are broad below, where they articulate with the upper border of the cricoid, and give attachment to the crico-arytenoidei postici, crico-arytenoidei laterales, and thyro-arytenoidei muscles, and chordæ vocales; and pointed above, where they articulate with two little curved cartilages, called *cornicula laryngis* (capitula laryngis). On the posterior surface they are concave, and lodge the arytenoideus muscle.

* This derivation has reference to the appearance of both cartilages taken together and covered by mucous membrane. In animals, which were the principal subjects of dissection among the ancients, the opening of the larynx with the arytenoid cartilages bears a striking resemblance to the mouth of a pitcher having a large spout.

The *Epiglottis* (ἐπιγλωττίς, upon the tongue) is a fibro-cartilage of a yellowish colour, studded with a number of small mucous glands, which are lodged in shallow pits upon its surface. It is shaped like a cordate leaf, and is placed immediately in front of the opening of the larynx, which it closes completely when the larynx is drawn up beneath the base of the tongue. It is attached by its point to the *receding angle*, between the two alæ of the thyroid cartilage.

Two small cartilaginous tubercles (cuneiform) are often found in the folds of the mucous membrane which bound the opening of the larynx laterally.

Ligaments.—The *Ligaments* of the larynx are numerous, and may be arranged into four groups: 1. Those which articulate the thyroid with the os hyoides. 2. Those which connect it with the cricoid. 3. Ligaments of the arytenoid cartilages. 4. Ligaments of the epiglottis.

1. The ligaments which connect the thyroid cartilage with the os hyoides are three in number:

The two *Thyro-hyoidean ligaments* pass between the superior cornua of the thyroid and the extremities of the greater cornua of the os hyoides: a sesamoid bone is found in each.

The *Thyro-hyoidean membrane* is a broad membranous layer, occupying the entire space between the thyroid cartilage and os hyoides. It is pierced by the superior laryngeal nerve and artery.

2. The ligaments connecting the thyroid to the cricoid cartilage are also three in number:—

Two *Capsular ligaments*, with their synovial membranes, which form the articulation between the inferior cornua of the thyroid and the sides of the cricoid, and the *crico-thyroidean membrane*, through which the operation of laryngotomy is performed. The latter is generally crossed by a small artery, the inferior laryngeal.

3. The ligaments of the arytenoid cartilages are four in number:

Two *Capsular ligaments*, and synovial membranes, which articulate the arytenoid cartilages with the cricoid; and the *thyro-arytenoid ligaments*, or *chordæ vocales*, which pass backwards from the receding angle of the thyroid cartilage, near to its lower border, to be inserted into the bases of the arytenoid cartilages. The space between these two ligaments is the glottis, or rima glottidis.

4. The ligaments of the epiglottis are five in number:—

1. Three folds of mucous membrane, one at the middle, and one at each side, called *fræna epiglottidis*, which hold the epiglottis back to the tongue. 2. *Epiglottis-hyoidean ligament*, which connects the epiglottis to the posterior surface of the os hyoides. 3. The ligament which attaches the epiglottis to the receding angle of the thyroid cartilage.

The *Muscles* of the larynx are eight in number: the five larger are the muscles of the chordæ vocales and rima glottidis; the three smaller are muscles of the epiglottis.

The five muscles of the chordæ vocales and rima glottidis are the—

Crico-thyroid,
Crico-arytenoideus posticus,
Crico-arytenoideus lateralis,
Thyro-arytenoideus,
Arytenoideus.

Fig. 175.

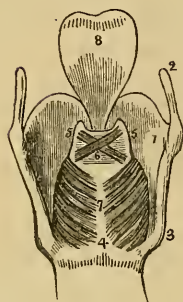
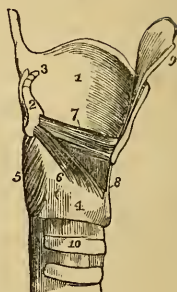


Fig. 176.



The *Crico-thyroid* muscle arises from the anterior surface of the cricoid cartilage, and is inserted into the lower and inner border of the thyroid.

The *Crico-arytenoideus posticus* arises from the depression on the posterior surface of the cricoid cartilage, and is inserted into the outer angle of the base of the arytenoid.

The *Crico-arytenoideus lateralis* arises from the upper border of the side of the cricoid, and is inserted into the outer angle of the base of the arytenoid cartilage.

The *Thyro-arytenoideus* arises from the receding angle of the thyroid cartilage, close to the outer side of the chorda vocalis, and passes backwards parallel with the chord, to be inserted into the base of the arytenoid cartilage.

The *Arytenoideus* muscle occupies the posterior concave surface of the arytenoid cartilages, between which it is stretched. It consists of three planes of transverse and oblique fibres; hence it was formerly considered as several muscles, under the names of *transversi* and *obliqui*.

The three muscles of the epiglottis are the—

Thyro-epiglottideus,
Aryteno-epiglottideus superior,
Aryteno-epiglottideus inferior (Hilton's muscle).

Fig. 175. A posterior view of the larynx. 1. The thyroid cartilage. 2. One of its ascending cornua. 3. One of the descending cornua. 4, 7. The cricoid cartilage. 5, 5. The arytenoid cartilages. 6. The arytenoideus muscle, consisting of oblique and transverse fasciculi. 7. The crico-arytenoidei postici muscles. 8. The epiglottis.

Fig. 176. A side view of the larynx, one ala of the thyroid cartilage has been removed. 1. The remaining ala of the thyroid cartilage. 2. One of the arytenoid cartilages. 3. One of the cornicula laryngis. 4. The cricoid cartilage. 5. The crico-arytenoideus posticus muscle. 6. The crico-arytenoideus lateralis. 7. The thyro-arytenoideus. 8. The crico-thyroid membrane. 9. One half of the epiglottis. 10. The upper part of the trachea.

The *Thyro-epiglottideus* appears to be formed by the upper fibres of the thyro-arytenoideus muscle; they spread out upon the external surface of the sacculus laryngis, on which they are lost; a few of the anterior fibres being continued onwards to the side of the epiglottis.

The *Aryteno-epiglottideus superior* consists of a few scattered fibres, which pass forwards in the fold of mucous membrane forming the lateral boundary of the entrance into the larynx, from the apex of the arytenoid cartilage to the side of the epiglottis.

The *Aryteno-epiglottideus inferior*.—This muscle was discovered by Mr. Hilton, and is very important in relation to the sacculus laryngis, with which it is closely connected. It may be found by raising the mucous membrane immediately above the ventricle of the larynx. It *arises* by a narrow and fibrous origin from the arytenoid cartilage, just above the attachment of the chorda vocalis; and passing forwards, and a little upwards, expands over the upper half, or two-thirds of the sacculus laryngis, and is *inserted* by a broad attachment into the side of the epiglottis.

Actions.—The crico-thyroid and arytenoid muscles are *contractors* of the rima glottidis; the crico-arytenoideus posticus and lateralis, and the thyro-arytenoideus, are *dilators*.

The crico-thyroid muscles elongate, and thereby bring together the chordæ vocales, by drawing the thyroid cartilage downwards and forwards; their posterior attachment at the arytenoid cartilages being fixed. The arytenoid muscle approximates the arytenoid cartilages, and consequently the chordæ vocales directly. The crico-thyroidei postici being attached to the outer angles of the bases of the arytenoid cartilages, draw them from each other, and stretch the chordæ vocales. The crico-arytenoidei laterales draw the arytenoid cartilages from each other, but relax the chordæ vocales; and the thyro-arytenoidei increase the width of the glottis, by directly relaxing the chordæ vocales.

The thyro-epiglottideus acts principally by compressing the glands of the sacculus laryngis and the sac itself: by its attachment to the epiglottis it would act feebly upon that valve. The aryteno-epiglottideus superior serves to keep the mucous membrane of the sides of the opening of the glottis tense, when the larynx is drawn upwards, and the opening closed by the epiglottis. Of the aryteno-epiglottideus, the "functions appear to be," writes Mr. Hilton, "to compress the subjacent glands which open into the pouch; to diminish the capacity of that cavity, and change its form; and to approximate the epiglottis and the arytenoid cartilage."

Mucous Membrane.—The larynx is lined by the mucous membrane, which is continued from the mouth and pharynx, and prolonged onwards through the trachea and bronchi to the bronchial cells. The chordæ vocales form two horizontal projections of the mucous membrane, and constitute the lateral boundaries of the *glottis*, or *rima glottidis*. Immediately above the horizontal projection of the chorda vocalis, at each side, is a depressed fossa, the

ventricle of the larynx. The superior boundary of the ventricle is an arched border of mucous membrane, which is very incorrectly termed the *superior chorda vocalis*. If the rounded extremity of a probe be introduced into the ventricle of the larynx, and then directed upwards, it will enter a considerable pouch, which has been recently described by Mr. Hilton as the *sacculus laryngis*.* From the ventricle of the larynx the sacculus is continued upwards, nearly as high as the upper border of the thyroid cartilage, and sometimes beyond it. When dissected from the interior of the larynx it is found covered by the aryteno-epiglottideus muscle and a fibrous membrane, which is attached to the superior chorda vocalis below; to the epiglottis in front; and to the upper border of the thyroid cartilage above. If examined from the exterior of the larynx, it will be seen to be covered by the thyro-epiglottideus muscle. On the surface of its mucous membrane are the openings of sixty or seventy small follicular glands, which are situated in the sub-mucous tissue, and give to its external surface a rough and ill-dissected appearance. This mucous secretion is intended for the lubrication of the chordæ vocales, and is directed upon them by two small valvular folds of mucous membrane, which are situated at the entrance of the sacculus.

The *Entrance of the larynx* is formed by two folds of mucous membrane, stretched between the apices of the arytenoid cartilages and the sides of the epiglottis. The arytenoid glands and superior aryteno-epiglottidean muscles are situated within these folds.

The *Glands* of the larynx are, 1. The *epiglottic*—most improperly named—for it consists merely of a mass of fat, situated between the convexity of the epiglottis and the thyro-hyoid membrane. 2. The *arytenoid* glands, some small granules found in the folds of mucous membrane near the apex of the arytenoid cartilage.

Vessels and Nerves.—The *Arteries* of the larynx are derived from the superior and inferior thyroid. The *nerves* are the superior laryngeal and recurrent laryngeal; both branches of the pneumogastric. The two nerves communicate with each other freely; but

* This sac was discovered and described by Mr. Hilton before he was aware that it had already been pointed out by the older anatomists. I myself made a dissection, which I still possess, of the same sac in an enlarged state during the month of August, 1837, without any knowledge either of Mr. Hilton's labours, or Morgagni's account. The sac projected considerably above the upper border of the thyroid cartilage, and the extremity had been snipped off on one side in the removal of the muscles. The larynx was presented to me by Dr. George Moore of Camberwell; he had obtained it from a child who died of bronchial disease; and he conceived that this peculiar disposition of the mucous membrane might possibly explain some of the symptoms by which the case was accompanied. Cruveilhier made the same discovery in equal ignorance of Morgagni's description, for we read in a note at page 677, vol. ii. of his *Anatomie Descriptive*,—"J'ai vu pour la première fois cette arrière cavité chez un individu affecté de phthisie laryngée, où elle était très-développée. Je fis des recherches sur le larynx d'autres individus, et je trouvai que cette disposition était constante. Je ne savais pas alors que Morgagni avait indiqué et fait représenter la même disposition." Cruveilhier compares its form very aptly to a "*Phrygian casque*," and Morgagni's figure, *Advers.* 1, *Epist. Anat.* 3, plate 2, fig. 4, has the same appearance. But neither of these anatomists notice the follicular glands described by Mr. Hilton.

the superior laryngeal is distributed principally to the mucous membrane at the entrance of the larynx; the recurrent, to the muscles.

In children, and in the female, the larynx is less developed than in the adult male; the thyroid cartilage forms a more obtuse angle, and is less firm: in the male the angle is acute, and the cartilages often converted into bone.

THE TRACHEA.

The TRACHEA extends from opposite the fifth cervical vertebra to opposite the third dorsal, where it divides into the two bronchi. The *right bronchus*, larger than the left, passes off nearly at *right angles* to the upper part of the corresponding lung. The *left* descends *obliquely*, and passes beneath the arch of the aorta, to reach the left lung.

The *Trachea* is composed of—

Fibro-cartilaginous rings,
Fibrous membrane,
Mucous membrane,
Longitudinal elastic fibres,
Muscular fibres,
Glands.

The *Fibro-cartilaginous rings* are from fifteen to twenty in number, and extend for two-thirds around the cylinder of the trachea. They are deficient at the posterior part, where the tube is completed by fibrous membrane. The last ring has usually a triangular form in front. The rings are connected to each other by a membrane of *yellow elastic fibrous tissue*, which in the space between the extremities of the cartilages, posteriorly, forms a distinct layer.

The *Longitudinal elastic fibres* are situated immediately beneath the mucous membrane on the posterior part of the trachea, and enclose the entire cylinder of the bronchial tubes to their ultimate terminations.

The *Muscular fibres* form a thin layer, extending transversely between the extremities of the cartilages.* On the posterior surface they are covered in by a cellulo-fibrous lamella, in which are lodged the *tracheal glands*. These are small flattened ovoid bodies, situated in great number between the fibrous and muscular layers of the membranous portion of the trachea, and also between the two layers of elastic fibrous tissue connecting the rings. They pour their secretion upon the mucous membrane.

Thyroid Gland.

The thyroid gland is one of those organs which it is found extremely difficult to classify from the absence of any positive knowledge with regard to its function. It is situated upon the trachea,

* I have several times seen a layer of longitudinal muscular fibres superadded to the transverse.—G.

and in an anatomical arrangement should therefore be considered in this place, although bearing no part in the function of respiration.

This gland consists of two lobes, which are placed one on each side of the trachea, and are connected with each other by means of an *isthmus*, which crosses its upper rings. There is considerable variety in the situation and breadth of this isthmus; which should be recollected in the performance of operations upon the trachea. In structure it appears to be composed of a dense cellular parenchyma, enclosing a great number of vessels. The gland is larger in young subjects and in females, than in the adult and males. It is the seat of an enlargement called bronchocele, goître, or the Derbyshire neck.

A muscle is occasionally found connected with its upper border or with its isthmus; and attached, superiorly, to the body of the os hyoides, or to the thyroid cartilage. It was named by Soemmering the "*levator glandulæ thyroideæ*."

Vessels and Nerves.—It is abundantly supplied with blood by the superior and inferior thyroid arteries. Sometimes an additional artery is derived from the arteria innominata, and ascends upon the front of the trachea to be distributed to the gland. The wounding of this vessel, in tracheotomy, might be fatal to the patient. The *nerves* are derived from the superior laryngeal and sympathetic.

THE LUNGS.

The lungs are two conical organs, situated one on each side of the chest, embracing the heart, and separated from each other by a membranous partition, the mediastinum. On the external or thoracic side they are convex, and correspond with the form of the cavity of the chest; internally they are concave, to receive the convexity of the heart. Superiorly they terminate in a tapering cone which extends above the level of the first rib, and inferiorly they are broad and concave, and rest upon the convex surface of the diaphragm. Their posterior border is rounded and broad, the anterior sharp and marked by one or two deep fissures, and the inferior which surrounds the base is also sharp.

The colour of the lungs is pinkish gray, mottled, and variously marked with black. The surface is figured with irregularly polygonal outlines which represent the lobules of the organ, and the area of each of these polygonal spaces is crossed by lighter lines.

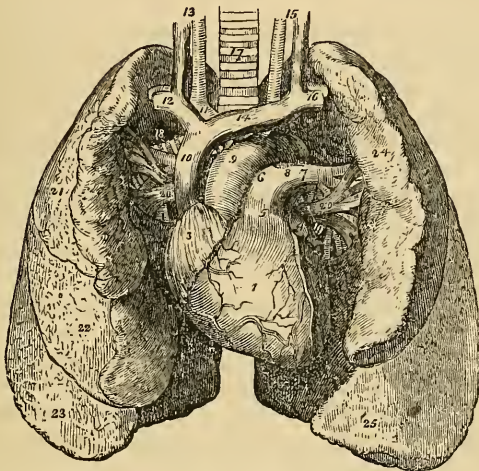
Each lung is divided into two lobes by a long and deep fissure, which extends from the posterior surface of the upper part of the organ, downwards and forwards to near the anterior angle of its base.

In the right lung the upper lobe is subdivided by a second fissure, which extends obliquely forwards from the middle of the preceding the anterior border of the organ, and marks off a small triangular lobe.

The *Right lung* is larger than the left, in consequence of the in-

clination of the heart to the left side. It is also shorter, from the great convexity of the liver, which presses the diaphragm upwards upon the right side of the chest considerably above the level of the left. It has three lobes.

Fig. 177.



The left lung is smaller, has but two lobes, but is longer than the right.

Each lung is retained in its place by its *root*, which is formed by the pulmonary artery, pulmonary veins and bronchial tubes, together with the bronchial vessels and pulmonary plexuses of nerves. The large vessels of the root of each lung are arranged in a similar order from before, backwards, on both sides, viz.

Pulmonary veins,
Pulmonary artery,
Bronchus.

From above, downwards, on the *right* side this order is exactly reversed; but on the *left* side the bronchus has to stoop beneath the

Fig. 177. Anatomy of the heart and lungs. 1. The right ventricle; the vessels to the right of the figure are the middle coronary artery and veins; and those to its left, the anterior coronary artery and veins. 2. The left ventricle. 3. The right auricle. 4. The left auricle. 5. The pulmonary artery. 6, 6. The right pulmonary artery. 7. The left pulmonary artery. 8. The remains of the ductus arteriosus. 9. The arch of the aorta. 10. The superior vena cava. 11. The right vena innominata, and the arteria innominata. 12. The right subclavian artery and vein. 13. The right common carotid artery and vein. 14. The left vena innominata. 15. The left carotid artery and vein. 16. The left subclavian artery and vein. 17. The trachea. 18. The right bronchus. 19. The left bronchus. 20, 20. The pulmonary veins; 18, 6, 20, form the root of the right lung; and 7, 19, 20, the root of the left. 21. The superior lobe of the right lung. 22. Its middle lobe. 23. Its inferior lobe. 24. The superior lobe of the left lung. 25. Its inferior lobe.

arch of the aorta, which alters its position to the vessels. They are thus disposed on the two sides:

<i>Right.</i>	<i>Left.</i>
Bronchus,	Artery,
Artery,	Bronchus,
Veins.	Veins.

Structure.—The lungs are composed of the ramifications of the bronchial tubes which terminate in bronchial cells (air cells), of the ramifications of the pulmonary artery and veins, bronchial arteries and veins, lymphatics and nerves; the whole of these structures being held together by cellular tissue, which constitutes the *parenchyma*. The parenchyma of the lungs, when examined on the surface or by means of a section, is seen to consist of small polygonal divisions, or lobules, which are connected to each other by an interlobular cellular tissue. These lobules again consist of smaller lobules, and the latter are formed by a cluster of air cells, in the parietes of which the capillaries of the pulmonary artery and pulmonary veins are distributed.*

Bronchial tubes.—The two bronchi proceed from the bifurcation of the trachea to their corresponding lungs. The right takes its course nearly at right angles with the trachea, and enters the upper part of the right lung, while the left, longer and smaller than the right, passes obliquely beneath the arch of the aorta, and enters the lung at about the middle of its root. Upon entering the lungs they divide into two branches, and each of these divides and subdivides dichotomously to their ultimate termination in small dilated sacs, the bronchial or pulmonary cells.

The fibro-cartilaginous rings which are observed in the trachea become incomplete and irregular in shape in the bronchi, and in the smaller bronchial tubes are lost altogether. At the termination of these tubes the fibrous and muscular coats become extremely thin, and are probably continued upon the lining mucous membrane of the air cells.

The *Pulmonary artery*, conveying the dark and impure venous blood to the lungs, terminates in capillary vessels, which form a minute network upon the parietes of the bronchial cells, and then converge to form the pulmonary veins, by which the arterial blood, purified in its passage through the capillaries, is returned to the left auricle of the heart.

The *Bronchial arteries*, branches of the thoracic aorta, ramify upon the bronchial tubes and in the tissue of the lungs, and supply them with nutrition, while the venous blood is returned by the bronchial veins to the vena azygos.

The *Lymphatics*, commencing upon the surface and in the sub-

* The walls of the air cells are so imperfect that all the cells of any lobule communicate freely with each other, whilst the contiguous lobules are separated by the parenchyma. Dr. Horner's dissections exhibit this in a beautiful manner. See Horner's *Special Anatomy*, 3d edition.—G.

stance of the lungs, terminate in the bronchial glands. These glands, very numerous and often of large size, are placed at the roots of the lungs, around the bronchi, and at the bifurcation of the trachea. In early life they resemble lymphatic glands in other situations; but in old age, and often in the adult, they are quite black, and filled with carbonaceous matter, and occasionally with calcareous deposits.

The *Nerves* are derived from the pneumogastric and sympathetic. They form two plexuses,—*anterior pulmonary plexus*, situated upon the front of the root of the lungs, and composed chiefly of filaments from the great cardiac plexus; and *posterior pulmonary plexus* on the posterior aspect of the root of the lungs, composed principally of branches from the pneumogastric. The branches from these plexuses follow the course of the bronchial tubes, and are distributed to the bronchial cells.

PLEURÆ.

Each lung is enclosed, and its structure maintained, by a serous membrane—the pleura, which invests it as far as the root, and is thence reflected upon the parietes of the chest. That portion of the membrane which is in relation with the lung is called *pleura pulmonalis*, and that in contact with the parietes, *pleura costalis*. The reflected portion, besides forming the internal lining to the ribs and intercostal muscles, also covers the diaphragm and the thoracic surface of the vessels at the root of the neck.

The pleura must be dissected from off the root of the lung, to see the vessels by which it is formed and the pulmonary plexuses.

MEDIASTINUM.

The approximation of the two reflected pleuræ in the middle line of the thorax forms a septum which divides the chest into the two pulmonary cavities. This is the mediastinum. The two pleuræ are not, however, in contact with each other at the middle line in the formation of the mediastinum, but leave a space between them which contains all the viscera of the chest with the exception of the lungs. The mediastinum is divided into the *anterior*, *middle*, and *posterior*.

The *Anterior mediastinum* is a triangular space, bounded in front by the sternum, and on each side by the pleura. It contains a quantity of loose cellular tissue, in which are found some lymphatic glands and vessels passing upwards from the liver; the remains of the thymus gland, the origins of the sterno-hyoid, sterno-thyroid, and triangularis sterni muscles, and the internal mammary vessels of the left side.

The *Middle mediastinum* contains the heart enclosed in its pericardium; the ascending aorta; the superior vena cava; the bifurcation of the trachea; the pulmonary arteries and veins; and the phrenic nerves.

The *Posterior mediastinum* is bounded behind by the vertebral

column, in front by the pericardium, and on each side by the pleura. It contains the descending aorta; the greater and lesser azygos veins, and superior intercostal vein; the thoracic duct; the œsophagus and pneumogastric nerves; and the great splanchnic nerves.

ABDOMEN.

The abdomen is the inferior cavity of the trunk of the body; it is *bounded in front* and *at the sides* by the lower ribs and abdominal muscles; *behind*, by the vertebral column and abdominal muscles; *above*, by the diaphragm; and, *below*, by the pelvis: and contains the alimentary canal, the organs subservient to digestion, viz. the liver, pancreas, and spleen, and the organs of excretion, the kidneys, with the supra-renal capsules.

Regions.—For convenience of description of the viscera, and for reference to the morbid affections of this cavity, the abdomen is divided into certain districts or regions. Thus, if two transverse lines be carried around the body, the one parallel with the convexities of the ribs, the other with the highest points of the crests of the ilia, the abdomen will be divided into three zones. Again, if a perpendicular line be drawn at each side, from the cartilage of the eighth rib to the middle of Poupart's ligament, the three primary zones will each be subdivided into three compartments or regions, a middle and two lateral.

The middle region of the upper zone being immediately over the small end of the stomach, is called *epigastric* (ἐπί—γαστήρ, over the stomach). The two lateral regions being under the cartilages of the ribs are called *hypochondriac* (ὑπὸ—χόνδροι, under the cartilages). The middle region of the middle zone is the *umbilical*; the two lateral, the *lumbar*. The middle region of the inferior zone is the *hypogastric* (ὑπὸ—γαστήρ, below the stomach); and the two lateral, the *iliac*. In addition to these divisions, we constantly use the term *inguinal region*, in reference to the vicinity of Poupart's ligament.

Position of the Viscera.—In the *upper zone* will be seen the liver, extending across from the right to the left side; the stomach and spleen on the left, and the pancreas and duodenum behind. In the *middle zone* is the transverse portion of the colon, with the upper part of the ascending and descending colon, omentum, small intestines, mesentery, and, behind, the kidneys and supra-renal capsules. In the *inferior zone* is the lower part of the omentum and small intestines, the cæcum, ascending and descending colon with the sigmoid flexure, and ureters.

The smooth and polished surface which the viscera and parietes of the abdomen present, is due to the peritoneum which should in the next place be studied.

PERITONEUM.

The *Peritoneum* (περιτρίβειν to extend around) is a serous membrane, and therefore a shut sac: a single exception exists in the

human subject to this character, viz. in the female, where the peritoneum is perforated by the open extremities of the Fallopiian tubes, and is continuous with their mucous lining.

The simplest idea that can be given of a serous membrane, which may apply equally to all, is, that it invests the viscus or viscera, and is then reflected upon the parietes of the containing cavity. If the cavity contain only a single viscus, the consideration of the serous membrane is extremely simple. But in the abdomen, where there are a number of viscera, the serous membrane passes from one to the other until it has invested the whole, before it is reflected on the parietes. Hence its reflections are a little more complicated.

In tracing the reflections of the peritoneum in the middle line, we commence with the diaphragm, which is lined by two layers, one from the parietes in front, *anterior*, and one from the parietes behind, *posterior*. These two layers of the same membrane, at the posterior part of the diaphragm, descend to the upper surface of the liver, forming the *coronary* and *lateral ligaments* of the liver. They then *surround* the liver, one going in front, the other behind that viscus, and, meeting at its under surface, pass to the stomach, forming the *lesser omentum*. They then, in the same manner, *surround* the stomach,

Fig. 178.

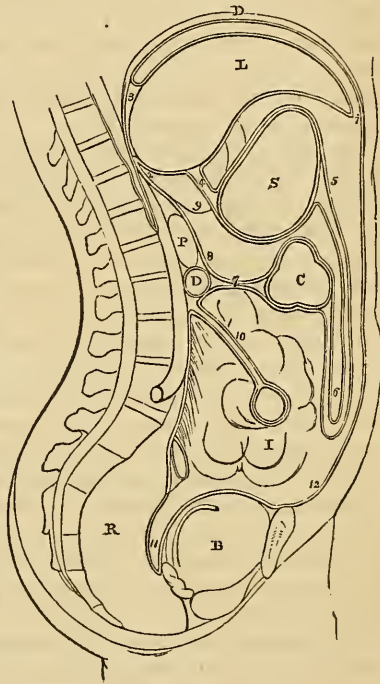


Fig. 178. The reflections of the peritoneum. D. The diaphragm. L. The liver. S. The stomach. C. The transverse colon. D. The transverse duodenum. P. The pancreas. I. The small intestine. R. The rectum. B. The urinary bladder. 1. The anterior layer of the peritoneum, lining the under surface of the diaphragm. 2. The posterior layer. 3. The two layers passing to the posterior border of the liver, and forming the coronary ligament. 4. The lesser omentum: the two layers passing from the under surface of the liver to the lesser curve of the stomach. 5. The two layers meeting at the greater curve, then passing downwards and returning upon themselves, forming (6) the greater omentum. 7. The transverse meso-colon. 8. The posterior layer traced upwards in front of D, the transverse duodenum, and P, the pancreas, to become continuous with the posterior layer (2). 9. The foramen of Winslow; the dotted line bounding this foramen inferiorly, marks the course of the hepatic artery forwards, to enter between the layers of the lesser omentum. 10. The mesentery encircling the small intestine. 11. The recto-vesical fold, formed by the descending anterior layer. 12. The anterior layer traced upwards upon the internal surface of the abdominal parietes to the layer (1), with which the examination commenced.

and meeting at its lower border descend for some distance in front of the intestines, and return to the transverse colon, forming the *great omentum*; they then *surround* the *transverse colon*, and pass directly backwards to the vertebral column, forming the *transverse meso-colon*. Here the two layers separate; the *posterior* ascends in front of the pancreas and aorta, and returns to the posterior part of the diaphragm, where it forms the posterior layer, with which we commenced. The *anterior* descends, *invests* all the *small intestines*, and returning to the vertebral column forms the *mesentery*. It then descends into the pelvis in front of the rectum, which it holds in its place by means of a fold called *meso-rectum*, forms a pouch, the *recto-vesical fold*, between it and the bladder, ascends upon the posterior surface of the bladder, forming its false ligaments, and returns upon the anterior parietes of the abdomen to the diaphragm, whence we first traced it.

In the female, after descending into the pelvis in front of the rectum, it is reflected upon the posterior surface of the vagina and uterus. It then descends on the anterior surface of the uterus, and forms at either side the broad ligaments of that organ. From the uterus it ascends upon the posterior surface of the bladder and anterior parietes of the abdomen, and is continued, as in the male, to the diaphragm.

In this way the continuity of the peritoneum, as a whole, is distinctly shown, and it matters not where the examination commence or where it terminate, still the same continuity of surface will be discernible throughout. If we trace it from side to side of the abdomen, we may commence at the umbilicus; we then follow it outwards lining the inner side of the parietes to the ascending colon; it surrounds that intestine; it then surrounds the small intestine, and returning on itself forms the mesentery. It then invests the descending colon, and reaches the parietes on the opposite side of the abdomen, whence it may be traced to the exact point from which we started.

The viscera, which are thus shown to be invested by the peritoneum in its course downwards, are the—

Liver,
Stomach,
Transverse colon,
Small intestines,
Pelvic viscera.

The folds, formed between these and between the diaphragm and the liver, are

(Diaphragm.)

Broad, coronary, and lateral ligaments.

(Liver.)

Lesser omentum.

(Stomach.)

Greater omentum.

(Transverse colon.)

Transverse meso-colon,
Mesentery,
Meso-rectum,
Recto-vesical fold,

False ligaments of the bladder.

And in the female, the

Broad ligaments of the uterus.

The ligaments of the liver will be examined with that organ.

The *Lesser omentum* is the duplicature passing between the liver and the upper border of the stomach. It is extremely thin, excepting at its right border, where it is free, and contains between its layers, the

Hepatic artery,
Ductus communis choledochus,
Portal vein,
Hepatic plexus of nerves,
Lymphatics.

These structures are enclosed in a loose cellular tissue, called *Glisson's capsule*.* The relative position of the three vessels is,—the artery to the left, the duct to the right, and the vein between and behind.

If the finger be introduced behind this right border of the lesser omentum, it will be situated in an opening called the *foramen of Winslow*.† In *front* of the finger will lie the right border of the lesser omentum; *behind* it the diaphragm, covered by the ascending or posterior layer of the peritoneum; *below*, the hepatic artery, curving forwards from the cœliac axis; and *above*, the lobus Spigelii. These, therefore, are the *boundaries of the foramen of Winslow*, which is nothing more than a constriction of the general cavity of the peritoneum at this point, arising out of the necessity for the hepatic and gastric arteries to pass forwards from the cœliac axis to reach their respective viscera.

If air be blown through the foramen of Winslow, it will descend behind the lesser omentum and stomach to the space between the descending and ascending pair of layers, forming the great omentum. This is sometimes called the lesser cavity of the peritoneum,

* Francis Glisson, Professor of Medicine in the University of Cambridge. His work, "De Anatomia Hepatis," was published in 1654.

† Jacob Benignus Winslow: his "Exposition Anatomique de la Structure du Corps Humain," was published in Paris in 1732.

and that external to the foramen the greater cavity; in which case the foramen is considered as the means of communication between the two. There is a great objection to this division, as it might lead the inexperienced to believe that there were really two cavities. There is but one only, the foramen of Winslow being merely a constriction of that one, to facilitate the communication between the nutrient arteries and the viscera of the upper part of the abdomen.

The *Great omentum* consists of *four layers of peritoneum*, the two which descend from the stomach, and the same two, returning upon themselves to the transverse colon. A quantity of adipose substance is deposited around the vessels which ramify through its structure. It would appear to perform a double function in the economy. 1st, Protecting the intestines from cold, and, 2dly, Facilitating the movement of the intestines upon each other during their vermicular action.

The *Transverse meso-colon* (μέσος, middle, being attached to the middle of the cylinder of the intestine) is the medium of connexion between the transverse colon and the posterior wall of the abdomen. It also affords to the nutrient arteries a passage to reach the intestine; and encloses between its layers, at the posterior part, the transverse portion of the duodenum.

The *Mesentery* (μέσον ἔντερον, being connected to the middle of the cylinder of the small intestine) is the medium of connexion between the small intestines and the posterior wall of the abdomen. It is oblique in its direction, being attached to the posterior wall, from the left side of the second lumbar vertebra to the right iliac fossa. It retains the small intestines in their places, and gives passage to the mesenteric arteries, veins, nerves, and lymphatics.

The *Meso-rectum*, in like manner, retains the rectum in connexion with the front of the sacrum. Besides this, there are some minor folds in the pelvis, as the *recto-vesical* fold, the *false ligaments of the bladder*, and *broad ligaments of the uterus*.

The *Appendices epiploicæ* are small irregular pouches of peritoneum, filled with fat, and situated like fringes upon the large intestine.

Three other duplicatures of peritoneum are situated in the sides of the abdomen; they are the *gastro-phrenic ligament*; the *gastro-splenic omentum*, the *ascending and descending meso-colon*. The *gastro-phrenic ligament* is a small duplicature of the peritoneum, which descends from the diaphragm to the extremity of the œsophagus, and to the lesser curve of the stomach. The *gastro-splenic omentum* is the duplicature which connects the spleen to the stomach. The *ascending meso-colon* is the fold which connects the upper part of the ascending colon with the posterior wall of the abdomen; and the *descending meso-colon*, that which retains the sigmoid flexure in connexion with the abdominal wall.

Structure of serous membrane.—Serous membrane consists of two layers, an external or cellular layer, and an internal layer or epithe-

lium. The *cellular layer* upon its outer surface is rough and vascular, and adherent to surrounding structures; but on its inner surface is dense and smooth, and wholly deficient of vessels carrying red blood. The smooth and brilliant surface of serous membrane is due to a distinct epithelium, which has been shown by the excellent researches of Henle, to be composed of laminæ of vesicles, and of flattened polygonal scales with central nuclei, like the epithelium of mucous membrane. Dr. Henle has observed this structure, which may be easily demonstrated with a good microscope upon the surface of all the serous membranes of the body, upon the surface of the lining membrane of arteries and veins, and upon synovial membranes.

The general characters of a serous membrane are its resemblance to a shut sac, and its secretion of a peculiar fluid, resembling the serum of the blood; but the former of these characters is not absolutely essential to the identity of a serous membrane; for, as we have shown above, the peritoneum in the female is perforated by the extremities of the Fallopian tubes; while in aquatic reptiles there is a direct communication between its cavity and the medium in which they live.

From the variable nature of the secretion of these membranes, they have been divided into two classes—the true serous membranes, viz. the arachnoid, pericardium, pleuræ, peritoneum, and tunicæ vaginales, which pour out a secretion containing but a small proportion of albumen; and the synovial membranes and bursæ which secrete a fluid containing a larger quantity of albumen.

ALIMENTARY CANAL.

The *Alimentary canal* is a musculo-membranous tube, extending from the mouth to the anus. It is variously named in the different parts of its course; hence it is divided into the

Mouth,	
Pharynx,	
Œsophagus,	
Stomach.	
Small intestine	{ Duodenum,
	{ Jejunum,
	{ Ileum.
Large intestine	{ Cæcum,
	{ Colon,
	{ Rectum.

The *Mouth* is the irregular cavity which contains the organs of taste and the principal instruments of mastication. It is bounded *in front* by the lips; on either *side* by the internal surface of the cheeks; *above* by the hard palate and teeth of the upper jaw; *below* by the tongue, by the mucous membrane stretched between the arch of the lower jaw and the under surface of the tongue, and by

the teeth of the inferior maxilla; and *behind* by the soft palate and fauces.

The *Lips* are two fleshy folds, formed externally by common integument, and internally by mucous membrane, and containing between these two layers the muscles of the lips, a quantity of fat, and numerous small labial glands. They are attached to the surface of the upper and lower jaw, and each lip is connected to the gum in the middle line by a fold of mucous membrane, the *frænum labii superioris* and *frænum labii inferioris*, the former being the larger.

The *Cheeks* (*buccæ*) are continuous on either hand with the lips, and form the sides of the face; they are composed of integument, a large quantity of fat, muscles, mucous membrane, and buccal glands.

The mucous membrane lining the cheeks is reflected above and below upon the sides of the jaws, and is attached posteriorly to the anterior margin of the ramus of the lower jaw. At about its middle, opposite to the second molar tooth of the upper jaw, is a papilla, upon which may be observed a small opening, the entrance of the duct of the parotid gland.

The *Hard palate* is a dense structure, composed of mucous membrane, palatal glands, fibrous tissue, vessels and nerves, and firmly connected to the palate processes of the superior maxillary and palate bones. It is bounded in front and on each side by the alveolar processes and gums, and is continuous behind with the soft palate. It is marked along the middle line by an elevated raphé, and presents upon each side of the raphé a number of transverse ridges and grooves. Near the anterior extremity, and immediately behind the middle incisor teeth, is a papilla which corresponds with the termination of the naso-palatine canal, and has been supposed to be endowed with a peculiar sensibility.

The *Gums* are composed of a thick and dense mucous membrane, which is closely adherent to the periosteum of the alveolar processes, and embraces the necks of the teeth. They are remarkable for their hardness and insensibility, and for their close contact, without adhesion to the surface of the tooth. From the neck of the tooth they are reflected into the alveolus, and become continuous with the periosteal membrane of that cavity.

The *Tongue* has been already described as an organ of sense; it is invested by mucous membrane, which is reflected from its under part upon the inner surface of the lower jaw, and constitutes, with the muscles beneath, the floor of the mouth. Upon the under surface of the tongue, near to its anterior part, the mucous membrane forms a considerable fold, which is called the *frænum linguæ*; and on each side of the *frænum* is a large papilla, the commencement of the duct of the submaxillary gland, and several smaller openings, the ducts of the sublingual gland.

The *Soft palate* (*velum pendulum palati*) is a fold of mucous membrane situated at the posterior part of the mouth. It is continuous,

superiorly with the hard palate, and is composed of mucous membrane, palatal glands, and muscles. Hanging from the middle of its inferior border is a small rounded process, the *uvula*; and passing outwards from the uvula on each side are two curved folds of the mucous membrane, the arches, or pillars of the palate. The *anterior pillar* is continued downwards to the side of the base of the tongue, and is formed by the projection of the palato-glossus muscle. The *posterior pillar* is prolonged downwards and backwards into the pharynx, and is formed by the convexity of the palato-pharyngeus muscle. These two pillars, closely united above, are separated below by a triangular interval or niche, in which the tonsil is lodged.

The *Tonsils* (*amygdalæ*) are two glandular organs, shaped like almonds, and situated between the anterior and posterior pillar of the soft palate, on each side of the fauces. They are cellular in texture, and composed of an assemblage of mucous follicles, which open upon the surface of the gland. Externally they are invested by the pharyngeal fascia, which separates them from the superior constrictor muscle and internal carotid artery, and prevents an abscess from opening in that direction. In relation to surrounding parts, they correspond with the angle of the lower jaw.

The space included between the soft palate and the root of the tongue is the *isthmus of the fauces*. It is bounded *above* by the soft palate; on each *side* by the pillars of the soft palate and tonsils; and *below* by the root of the tongue. It is the opening between the mouth and pharynx.

SALIVARY GLANDS.

Communicating with the mouth are the excretory ducts of three pairs of salivary glands, the parotid, submaxillary, and sublingual.

The *Parotid gland* (*παρά, near, ὄψις, ὠτός*, the ear), the largest of the three, is situated immediately in front of the external ear, and extends superficially for a short distance over the masseter muscle, and deeply behind the ramus of the lower jaw. It reaches inferiorly to below the level of the angle of the lower jaw, and posteriorly to the mastoid process, slightly overlapping the insertion of the sterno-mastoid muscle. Embedded in its substance are the external carotid artery, temporo-maxillary vein, and facial nerve; and, emerging from its anterior border, the transverse facial artery and branches of the pes anserinus; and above, the temporal artery.

The duct of the parotid gland (Stenon's* duct) commences at the papilla upon the internal surface of the cheek, opposite the second molar tooth of the upper jaw; and, piercing the buccinator muscle, crosses the masseter to the anterior border of the gland, where it divides into several branches, which subdivide and ramify through

* Nicholas Stenon, an anatomist of great research. He discovered the parotid duct while in Paris. He was appointed professor of medicine in Copenhagen in 1672. His work, "De Musculis et Glandulis Observationes," was published in 1664.

its structure, to terminate in the small cæcal pouches of which the gland is composed. A small branch is generally given off from the duct while crossing the masseter muscle, which forms, by its ramifications and terminal dilatations, a small glandular appendage, the *socia parotidis*. Stenon's duct is remarkably dense and of considerable thickness, while the area of its canal is extremely small.

The *Submaxillary gland* is situated in the posterior angle of the submaxillary triangle of the neck. It rests upon the hyo-glossus and mylo-hyoideus muscles, and is covered in by the body of the lower jaw and by the deep cervical fascia. It is separated from the parotid gland by the stylo-maxillary ligament, and from the sublingual by the mylo-hyoideus muscle. Embedded among its lobules is the facial artery and the submaxillary ganglion.

The *Excretory duct* (Wharton's) of the submaxillary gland commences upon the papilla, by the side of the frænum linguæ, and passes backwards beneath the mylo-hyoideus and resting upon the hyo-glossus muscle, to the middle of the gland, where it divides into numerous branches, which ramify through the structure of the gland to its cæcal terminations. It lies in its course against the mucous membrane forming the floor of the mouth, and causes a projecting ridge upon its surface.

The *Sublingual* is an elongated and flattened gland, situated beneath the mucous membrane of the floor of the mouth, on each side of the frænum linguæ. It is in relation *above* with the mucous membrane; *in front* with the depression by the side of the symphysis of the lower jaw; *externally* with the mylo-hyoideus muscle; and *internally* with the lingual nerve and genio-hyo-glossus muscle.

It pours its secretion into the mouth by seven or eight small ducts, which commence by small openings on each side of the frænum linguæ.

Structure.—The salivary are conglomerate glands, consisting of lobes, which are made up of angular lobules, and these of still smaller lobules.

The smallest lobule is apparently composed of granules, which are minute cæcal pouches, formed by the dilatation of the extreme ramifications of the ducts. These minute ducts unite to form lobular ducts, and the lobular ducts constitute by their union a single excretory duct.

The cæcal pouches are connected by cellular tissue, so as to form a minute lobule; the lobules are held together by a more condensed cellular layer; and the larger lobes are enveloped by a dense cellulo-fibrous capsule, which is firmly attached to the deep cervical fascia.

Vessels and Nerves.—The parotid gland is abundantly supplied with *arteries* by the external carotid; the submaxillary by the facial; and the sublingual by the sublingual branch of the lingual artery.

The *Nerves* of the parotid gland are derived from the auricular branch of the inferior maxillary nerve, from the auricularis mag-

nus, and from the *nervi molles* of the external carotid artery. The submaxillary gland is supplied by the branches of the submaxillary ganglion, and by filaments from the mylo-hyoidean nerve; and the sublingual by filaments from the submaxillary ganglion and gustatory nerve.

PHARYNX.

The pharynx (*φάρυγξ*, the throat) is a musculo-membranous sac, situated upon the cervical portion of the vertebral column, and extending from the base of the skull to a point corresponding with the cricoid cartilage in front, and the fifth cervical vertebra behind. It is composed of mucous membrane, muscles, vessels, and nerves, and is invested by a strong fascia, situated between the mucous membrane and muscles, which serves to connect it with the basilar process of the occipital bone and with the petrous portions of the temporal bones. Upon its anterior part it is incomplete, and has opening into it seven foramina, viz.

Posterior nares, two,
Eustachian tubes, two,
Mouth,
Larynx,
Œsophagus.

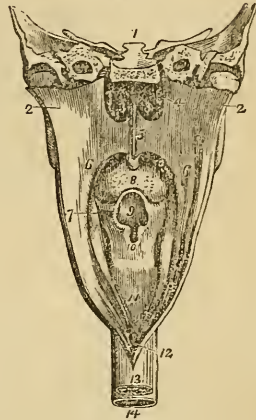
The *Posterior nares* are the two large openings at the upper and front part of the pharynx. On each side of these openings, and slightly above the posterior termination of the inferior turbinated bone, is the irregular depression in the mucous membrane, marking the entrance of the *Eustachian tube*. Beneath the posterior nares is the large opening into the *mouth*, partly veiled by the soft palate; and, beneath the root of the tongue, the opening of the larynx. The *œsophageal* opening is the lower constricted portion of the pharynx.

Œsophagus.—The œsophagus (*οἴσω*, to bear, *φαγεῖν*, to eat) is a slightly flexuous canal, inclining to the left in the neck, to the right in the upper part of the thorax,* and again to the left in its course

Fig. 179.° The pharynx laid open from behind. 1. A section carried transversely through the base of the skull. 2, 2. The walls of the pharynx drawn to each side. 3, 3. The posterior nares, separated by the vomer. 4. The extremity of the Eustachian tube of one side. 5. The soft palate. 6. The posterior pillar of the soft palate. 7. Its anterior pillar; the tonsil is seen situated in the niche between the two pillars. 8. The root of the tongue, partly concealed by the uvula. 9. The epiglottis, overhanging (10) the opening of the glottis. 11. The posterior part of the larynx. 12. The opening into the œsophagus. 13. The external surface of the œsophagus. 14. The trachea.

* Cruveilhier remarks that this inflexion explains the obstruction which a bougie sometimes meets with in its passage along the œsophagus opposite the first rib.

Fig. 179.



through the posterior mediastinum; it commences at the termination of the pharynx, opposite the lower border of the cricoid cartilage and fifth cervical vertebra, and descends the neck, behind and rather to the left of the trachea. It then passes behind the arch of the aorta, and along the posterior mediastinum, lying in front of the thoracic aorta, to the œsophageal opening in the diaphragm, where it enters the abdomen, and terminates at the cardiac orifice of the stomach at a point about opposite to the tenth dorsal vertebra. The œsophagus is flattened and narrow in the cervical region, and cylindrical in the rest of its course; its largest diameter is met with near to the lower part of its course.

THE STOMACH.

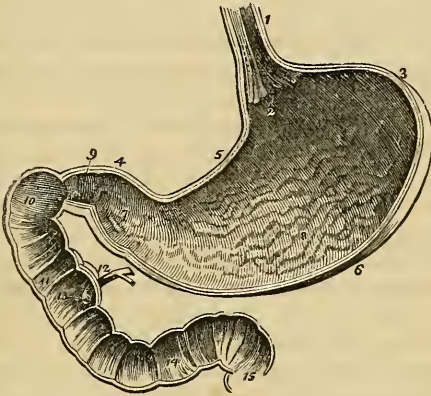
The stomach is an expansion of the alimentary canal, situated in the left hypochondriac, and extending into the epigastric region. It is directed somewhat obliquely from above downwards, from left to right and from before backwards; and in the female where the injurious system of tight-lacing has been pursued is longer than in the male. On account of the peculiarity of its form, it is divided into a *greater* or *splenic*, and a *lesser* or *pyloric*, end; a *lesser curvature* above, and a *greater curvature* below; an *anterior* and a *posterior surface*; a *cardiac orifice*, and a *pyloric orifice*. The great end is not only of large size, but expands beyond the point of entrance of the œsophagus, and is embraced by the concave surface of the spleen. The pylorus is the small and contracted extremity of the organ; near to its extremity is a small dilatation, which was called by Willis the antrum of the pylorus. The two curvatures give attachment to the peritoneum; the upper curve to the lesser omentum, and the lower to the greater omentum. The anterior surface looks upwards and forwards, and is in relation with the diaphragm, which separates it from the viscera of the thorax and from the six lower ribs, with the left lobe of the liver, and in the epigastric region, with the abdominal parietes. The posterior surface looks downwards and backwards, and is in relation with the diaphragm, the pancreas, the third portion of the duodenum, the transverse meso-colon, the right kidney, and suprarenal capsule; this surface forms the anterior boundary of that cul de sac of the peritoneum which is situated behind the lesser omentum and extends into the greater omentum.

Small Intestines.—The small intestine is about twenty-five feet in length, and is divisible into three portions, *duodenum*, *jejunum*, and *ileum*.

The *Duodenum* (called δωδεκαδάκτυλον by Herophilus) is somewhat larger than the rest of the small intestines, and has received its name from being about equal in length to the breadth of twelve fingers. Commencing at the pylorus, it ascends *obliquely* backwards to the under surface of the liver: it next descends *perpendicularly* in front of the right kidney, and then passes nearly *transversely* across the third lumbar vertebra; terminating in the jejunum

on the left side of the second lumbar vertebra, where it is crossed by the superior mesenteric artery and portal vein. The *first* or *oblique* portion of its course, between two and three inches, is completely enclosed by the peritoneum: it is in relation, *above* with the liver and neck of the gall-bladder; *in front* with the greater omentum and abdominal parietes; and *behind* with the right border of the lesser omentum and its vessels. The *second* or *perpendicular* portion is situated altogether behind the peritoneum; it is in relation

Fig. 180.



by its *anterior surface* with the commencement of the arch of the colon; by its *posterior surface* with the concave margin of the right kidney, the inferior vena cava, and the ductus communis choledochus; by its *right border* with the ascending colon; and by its *left border* with the pancreas. The ductus communis choledochus and pancreatic duct open into the internal and posterior side of the perpendicular portion, a little below its middle. The *third* or *transverse* portion of the duodenum lies between the diverging layers of the transverse meso-colon, with which and with the stomach it is in relation *in front*; *above* it is in contact with the lower border of

Fig. 180. A vertical and longitudinal section of the stomach and duodenum, made in such a direction as to include the two orifices of the stomach. 1. The œsophagus; upon its internal surface the plicated arrangement of the cuticular epithelium is shown. 2. The cardiac orifice of the stomach, around which the fringed border of the cuticular epithelium is seen. 3. The great end of the stomach. 4. Its lesser or pyloric end. 5. The lesser curve. 6. The greater curve. 7. The dilatation at the lesser end of the stomach which received from Willis the name of antrum of the pylorus. This may be regarded as the rudiment of a second stomach. 8. The rugæ of the stomach formed by the mucous membrane: their longitudinal direction is shown. 9. The pylorus. 10. The oblique portion of the duodenum. 11. The descending portion. 12. The pancreatic duct, and the ductus communis choledochus close to their termination. 13. The papilla upon which the ducts open. 14. The transverse portion of the duodenum. 15. The commencement of the jejunum. In the interior of the duodenum and jejunum, the valvulæ conniventes are seen.

the pancreas, the superior mesenteric artery and portal vein being interposed; and *behind* it rests upon the inferior vena cava and the aorta.

The *Jejunum* (jejunus, empty) is named from being generally found empty. It forms the upper two-fifths of the small intestine; commencing at the duodenum on the left side of the second lumbar vertebra, and terminating in the ileum. It is thicker to the touch than the rest of the intestine, and has a pinkish tinge from containing more mucous membrane than the ileum.

The *Ileum* (ἔϊλεϊν, to twist, to convolute) includes the remaining three-fifths of the small intestine. It is somewhat smaller in calibre, thinner in texture, and paler than the jejunum; but there is no mark by which to distinguish the termination of the one or the commencement of the other. It terminates in the right iliac fossa, by opening at an obtuse angle into the colon.

The jejunum and ileum are surrounded above and at the sides by the colon; in front they are in relation with the omentum and abdominal parietes; they are retained in their position by the mesentery, which connects them with the posterior wall of the abdomen; and below they descend into the cavity of the pelvis. At about the lower third of the ileum a pouch-like process or diverticulum of the intestine is occasionally seen. This is a remnant of embryonic structure, and is formed by the obliteration of the vitelline duct at a short distance from the cylinder of the intestine.

Large intestine.—The large intestine, about five feet in length, is sacculated in appearance, and is divided into the *cæcum*, *colon*, and *rectum*.

The *Cæcum* (cæcus, blind) is the blind pouch, or cul-de-sac, at the commencement of the large intestine. It is situated in the right iliac fossa, and is retained in its place by the peritoneum, which passes over its anterior surface; its posterior surface is connected by loose cellular tissue with the iliac fascia. Attached to its extremity is the appendix vermiformis, a long worm-shaped tube, the rudiment of the lengthened cæcum found in all mammiferous animals except man and the higher quadrumana. The appendix varies in length, from one to five or six inches; it is about equal in diameter to a goose-quill, and is connected with the posterior and left aspect of the cæcum near to the extremity of the ileum. It is usually more or less coiled upon itself, and retained in that coil by a falciform duplicature of peritoneum. Its canal is extremely small, and the orifice by which it opens into the cæcum not unfrequently provided with an incomplete valve. Occasionally the peritoneum invests the cæcum so completely as to constitute a meso-cæcum, which permits of an unusual degree of movement in this portion of the intestine, and serves to explain the occurrence of hernia of the cæcum upon the left side. The cæcum is the most dilated portion of the large intestine.

The *Colon* is divided into *ascending*, *transverse*, and *descending*. The *ascending colon* passes upwards from the right iliac fossa,

through the right lumbar region, to the under surface of the liver. It then bends inwards, and crosses the upper part of the umbilical region under the name of *transverse colon*, and on the left side descends (*descending colon*) through the left lumbar region to the left iliac fossa, where it makes a remarkable curve upon itself, which is called the *sigmoid flexure*.

The *ascending colon*, the most dilated portion of the large intestine, next to the cæcum, is retained in its position in the abdomen either by the peritoneum passing simply in front of it or by a narrow meso-colon. It is in relation *in front* with the small intestine and with the abdominal parietes; *behind* with the quadratus lumborum muscle and with the right kidney; *internally* with the small intestine and with the perpendicular portion of the duodenum; and by its *upper extremity* with the under surface of the liver and with the gall-bladder. The *transverse colon*, the longest portion of the large intestine, forms a curve across the cavity of the abdomen, the convexity of which looks forwards and sometimes downwards. It is in relation by its *upper surface* with the liver, the gall-bladder, the stomach, and with the lower extremity of the spleen; by its *lower surface* with the small intestine; by its *anterior surface* with the anterior layers of the great omentum and with the abdominal parietes; and by its *posterior surface* with the transverse meso-colon. The *descending colon* is smaller in calibre, and is situated more deeply than the ascending colon. Its relations are precisely similar. The *sigmoid flexure* is the narrowest part of the colon; it curves in the first place upwards and then downwards, and to one or the other side, and is retained in its place by a meso-colon. It is in relation *in front* with the small intestine and with the abdominal parietes; *behind* with the iliac fossa; and on either *side* with the small intestine.

The *Rectum* is the termination of the large intestine. It has received its name, not so much from the direction of its course, as from the straightness of its form in comparison with the colon. It descends from opposite the left sacro-iliac symphysis, in front of the sacrum, forming a gentle curve to the right side, and then returning to the middle line; near the extremity of the coccyx it curves backwards to terminate at the anus at about an inch in front of the apex of that bone. The rectum, therefore, forms a double flexure in its course, the one being directed from side to side, the other from before backwards. It is smaller in calibre at its upper part than the sigmoid flexure, but becomes gradually larger as it descends, and its lower extremity, previously to its termination at the anus, forms a dilatation of considerable but variable size.

With reference to its relations, the rectum is divided into three portions; the *first*, including half its length, extends to about the middle of the sacrum, is completely surrounded by peritoneum, and connected to the sacrum by means of the meso-rectum. It is in relation above with the left sacro-iliac symphysis and below with the branches of the internal iliac artery, and with the sacral plexus of

nerves; one or two convolutions of the small intestine are interposed between the front of the rectum and the bladder in the male; and between the rectum and the uterus with its appendages in the female. The *second portion*, about three inches in length, is closely attached to the surface of the sacrum, and covered by the peritoneum only in front; it is in relation by its lower part with the base of the bladder, vesiculæ seminales, and the prostate gland, and in the female with the vagina. The *third portion* curves backwards from opposite the prostate gland to terminate at the anus; it is embraced by the levatores ani, and is about one inch and a half in length. It is separated from the membranous portion of the urethra by a triangular space; in the female this space intervenes between the vagina and the rectum, and constitutes by its base the perineum.

The *Anus* is situated at a little more than an inch in front of the extremity of the coccyx. The integument around it is covered with hairs, and is drawn into numerous radiated plaits which are obliterated during the passage of fæces. The margin of the anus is provided with an abundance of sebaceous glands, and the cuticle may be seen terminating by a fringed and scalloped border, at a few lines above the extremity of the opening.

Structure of the Intestinal Canal.—The pharynx has three coats; a mucous coat, a fibrous coat derived from the pharyngeal fascia, and a muscular layer. The œsophagus has but two coats, the mucous and muscular. The stomach and intestines have three, *mucous* and *muscular*, and an external *serous* investment, derived from the peritoneum.

Mucous coat.—The mucous membrane of the mouth invests the whole internal surface of that cavity, and is reflected along the parotid, submaxillary, and sublingual ducts, into the corresponding glands. It terminates anteriorly upon the outer margin of the red border of the lips, and posteriorly is continuous with the mucous lining of the pharynx. The mucous membrane of the pharynx is continuous with the mucous lining of the Eustachian tubes, the nares, the mouth and the larynx. In the œsophagus it is thick, very loosely connected with the muscular coat, and is disposed in *longitudinal plicæ*. In the stomach the mucous membrane is thin and vascular at the great extremity, and becomes thicker and lighter in colour towards the pyloric extremity. It is formed into plaits or *rugæ*, which are disposed for the most part in a longitudinal direction. The rugæ are most numerous towards the lesser end of the stomach; while around the cardiac orifice they assume a radiated arrangement. At the pylorus the mucous membrane forms a circular or spiral fold which constitutes a part of the apparatus of the *pyloric valve*. In the lower half of the duodenum, the whole length of the jejunum, and in the upper part of the ileum, it forms valvular folds called *valvulæ conniventes*, which are several lines in breadth in the lower part of the duodenum and upper portion of the jejunum, and diminish gradually in size towards each extremity. These folds do not entirely surround the cylinder of the intestine, but ex-

tend for about one half or three-fourths of its circumference. In the lower half of the ileum the mucous lining is without folds; hence the thinness of the coats of this intestine as compared with the jejunum and duodenum. At the termination of the ileum in the cæcum, the mucous membrane forms two folds, which are strengthened by the muscular coat, and project into the cæcum. These are the *ilio-cæcal valve* (*Valvula Bauhini*). In the cæcum and colon the mucous membrane is raised into crescentic folds, which correspond with the sharp edges of the sacculi; and, in the rectum, it forms three valvular folds,* one of which is situated near the commencement of the intestine; the second, extending from the side of the tube, is placed opposite the middle of the sacrum; and the third, which is the largest and most constant, projects from the anterior wall of the intestine opposite the base of the bladder. Besides these folds, the membrane in the empty state of the intestine is thrown into longitudinal plaits, somewhat similar to those of the œsophagus; these have been named the *columns* of the rectum.†

Structure of Mucous Membrane.—This membrane is analogous to the cutaneous covering of the exterior of the body, and resembles that tissue very closely in its structure. It is composed of three layers, an *epithelium*, a *proper mucous*, and a *fibrous layer*.

The *Epithelium* is the cuticle of the mucous membrane. Throughout the pharynx and œsophagus it resembles the cuticle, both in appearance and character. It is continuous with the cuticle of the skin at the margin of the lips, and terminates by an irregular border at the cardiac orifice of the stomach. At the opposite extremity of the canal it terminates by a scalloped border just within the verge of the anus. In the mouth it is composed of several laminæ of oval vesicles and thin angular scales. Each vesicle and each scale possesses a central nucleus, and within the nucleus is a minute nucleus-corpuscle. According to Mr. Nasmuth‡ the deepest laminæ of the epithelium appears to consist of nuclei only, in the next the investing vesicle is developed; the vesicles by degrees enlarge and become flattened, and in the superficial laminæ are converted into thin scales. The nuclei, the vesicles, and the scales, are connected together by a glutinous fluid of the consistence of jelly, which contains an abundance of minute opaque granules. The scales of the superficial layer overlap each other by their margins. During the natural functions of the mucous membrane the superficial scales exfoliate continually and give place to the deeper layers. In the

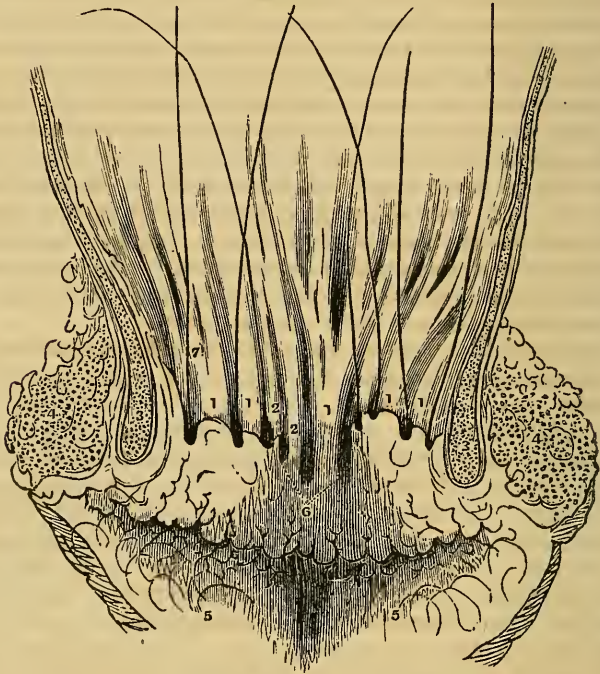
* Mr. Houston, "On the Mucous Membrane of the Rectum." Dublin Hospital Reports, vol. v.

† The spaces between the columns of the rectum become closed at the anus so as to form a series of pouches represented in the accompanying cut. These pouches are sometimes dilated and produce a disease first described by Dr. Physick. (See Gibson's Surgery.) The mucous membrane of the rectum is connected to the muscular coat by a very loose cellular tissue as in the œsophagus.—G.

‡ Investigations into the structure of the Epithelium, presented to the medical section of the British Medical Association, in 1839, published in a work entitled "Three Memoirs on the Development of the Teeth and Epithelium." 1841.

stomach and intestines these bodies are pyriform in shape, and have a columnar arrangement, the apices being applied to the papillary

Fig. 181.



surface of the membrane, and the bases forming by their approximation the free intestinal surface. Each column is provided with a central nucleus and nucleus-corpuscle, which gives to its middle a swollen appearance; and, from the transparency of its structure, the nucleus may be seen through the base of the column, when examined from the surface. Around the circular villi the columns, from being placed perpendicularly to the surface, have a radiated arrangement. The columnar epithelium is produced in the same manner with the laminated epithelium, in nuclei, vesicles, and columns, and the latter are continually thrown off to give place to successive layers.

The *Proper mucous*, or *Papillary layer*, is analogous to the papillary layer of the skin, and, like it, is the secreting structure by

Fig. 181. A vertical section of the anterior parietes of the anus, with the whole canal displayed so as to show the relations of the sacculi of the middle region, and their relations to the surrounding parts, their orifices being marked with bristles. 1, 1. Columns of the rectum. 2, 2. Rudiments of columns. 3. Internal sphincter. 4. External sphincter. 6. Rudimentary or imperfect sacculi. 5, 5. Radiated folds of the skin, terminating on the surface of the nates. 7. A bristle in one of the sacs.—G.

which the epithelium is produced. Its surface presents several varieties of appearance when examined in the different parts of its extent. In the stomach it forms polygonal cells, into the floor of which the gastric follicles open. In the small intestine it presents numerous minute, projecting papillæ, called villi. The villi are of two kinds, *cylindrical* and *laminated*, and so abundant as to give to the entire surface a beautiful velvety appearance. In the large intestine the surface is composed of a fine network of minute polygonal cells, more numerous than those of the stomach, but resembling them in receiving the secretion from numerous perpendicular follicles into their floors.*

The *Fibrous layer* (submucous, nervous) is the membrane of support to the mucous membrane, as is the corium to the papillary layer of the skin. It gives to the mucous membrane its strength and resistance, is but loosely connected with the mucous layer, but is firmly adherent to the muscular stratum, and is called, in the older works on anatomy, the "*nervous coat*."

In the loose cellular tissue connecting the mucous with the fibrous layer, are situated the glands and follicles belonging to the mucous membrane: these are the—

Pharyngeal glands,
 Œsophageal glands,
 Gastric follicles,
 Duodenal glands, (Brunner's).
 Glandulæ solitariæ,
 Glandulæ aggregatæ (Peyer's),
 Simple follicles (Lieberkühn's).

The *Pharyngeal glands* are situated in considerable numbers beneath the mucous membrane of the pharynx, particularly around the posterior nares. Two of these glands, of larger size than the rest, and lobulated in structure, occupy the margin of the opening of the Eustachian tube.

The *Œsophageal glands* are small lobulated bodies, situated in the submucous tissue, and opening upon the surface of the œsophagus by a long excretory duct, which passes obliquely through the mucous membrane.

The *Gastric follicles* are long tubular follicular glands, situated perpendicularly side by side in every part of the mucous membrane of the stomach. At their terminations they are dilated into small lateral pouches, which give them a clustered appearance. This character is more clearly exhibited at the pyloric than at the cardiac end of the stomach. They are intended, very probably, for the secretion of the gastric fluid.

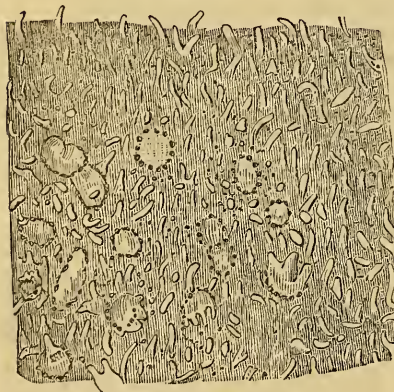
* The first notice of the true structure of mucous membrane appeared in the American Journal of Medical Sciences, and was from the pen of Professor Horner. The preparations which he made at the time are in the Wistar Museum, and illustrate the structure beautifully.—G.

The *Duodenal* or *Brunner's glands*,* are small flattened granular bodies, compared collectively by Von Brunn to a second pancreas. They resemble in structure the small salivary glands, so abundant beneath the mucous membrane of the mouth and lips; and, like them, they open upon the surface by minute excretory ducts. They are limited to the duodenum.

The *Solitary glands* are of two kinds, those of the small and those of the large intestine. The former are small circular patches, surrounded by a zone or wreath of simple follicles. When opened, they are seen to consist of a small flattened saccular cavity, containing a mucous secretion, but having no excretory duct. They are chiefly found in the lower part of the ileum. The solitary glands of the large intestine are most abundant in the cæcum and appendix cæci; they are small circular projections, flattened upon the surface, and perforated in the centre by a minute excretory opening.

The *Aggregate* or *Peyer's glands*,† are situated near to the lower end of the ileum, and occupy that portion of the intestine which is opposite the attachment of the mesentery. To the naked eye they present the appearance of oval disks, covered with small irregular fissures; but with the aid of the microscope they are seen to be composed of numerous small circular patches, surrounded by simple follicles, like the solitary glands of the small intestine. Each patch corresponds with a flattened and closed sac, situated beneath the membrane, but having no excretory opening, and the interspace between the patches is occupied by flattened villi.

Fig. 182.



The *Simple follicles*, or follicles of Lieberkühn, are small pouches of the mucous layer, dispersed in immense numbers over every part of the mucous membrane.

Muscular coat.—The muscular coat of the pharynx consists of five pairs of muscles, which have been already described. The muscular coat of the rest of the alimentary canal is composed of two planes of fibres, an external *longitudinal*, and an internal *circular*.

Fig. 182. Portion of one of the patches of Peyer's glands from the end of the ileum: highly magnified. The villi are also shown.—(Boehm.)

* John Conrad von Brunn; "Glandulæ Duodeni seu Pancreas Secundarium," 1715.

† John Conrad Peyer, an anatomist of Schaffhausen, in Switzerland. His essay, "De Glandulis Intestinalium," was published in 1677.

The *Œsophagus* is very muscular; its longitudinal fibres are continuous above with the pharynx, and are attached in front to the vertical ridge on the posterior surface of the cricoid cartilage; the uppermost circular fibres are also attached on each side to the cricoid cartilage. Below, both sets of fibres are continued upon the stomach. On the *stomach* the longitudinal fibres are most apparent along the lesser curve, and the circular at the smaller end. At the pylorus the latter are aggregated into a thick circular ring, which, with the spiral fold of mucous membrane, constitutes the *pyloric valve*. At the great end of the stomach a new order of fibres is introduced, having for their object to strengthen and compress that extremity of the organ. They are directed more or less horizontally from the great end towards the lesser end, and are generally lost upon the sides of the stomach at about its middle: these are the oblique fibres.

The *Small intestine* is provided with both layers, equally distributed over the entire surface. At the termination of the ileum the circular fibres are continued into the two folds of the ilio-cæcal valve, while the longitudinal fibres pass onwards to the large intestine. In the *large intestine* the longitudinal fibres commence at the appendix vermiformis and are collected into three bands, an anterior, broad; and two posterior and narrower bands. These bands are nearly one half shorter than the intestine, and give to it the sacculated appearance which is characteristic of the cæcum and colon. In the *descending colon* the posterior bands usually unite and form a single band. From this point the two bands are continued downwards upon the sigmoid flexure to the rectum, around which they spread out and form a thick and very muscular longitudinal layer. The circular fibres in the cæcum and colon are exceedingly thin; in the rectum they are thicker, and at its lower extremity they are aggregated into the thick muscular ring which is called the internal sphincter ani.*

SEROUS COAT.—The pharynx and œsophagus have no covering of serous membrane. The alimentary canal within the abdomen has a serous layer, derived from the peritoneum.

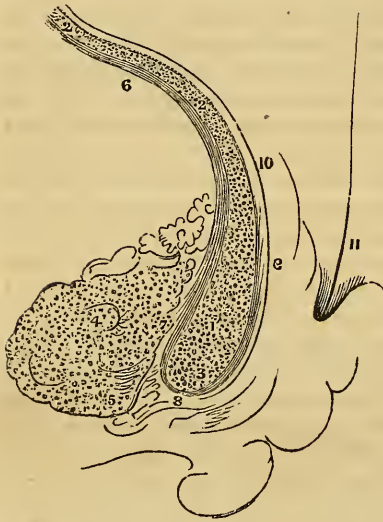
The *Stomach* is completely surrounded by the peritoneum excepting along the line of junction of the great and lesser omentum. The *first or oblique portion of the duodenum* is also completely in-

* Mr. Wilson does not seem to have paid the same close attention to the anatomy of the anus as to other parts of the body, and we here find a deficiency in the description which we shall endeavour to supply.

The *Muscular coat* of the rectum consists of much stronger fasciæ than that of the colon; the *transverse* fibres terminate at the anus by aggregating into a ring which is called the *internal sphincter* muscle, as in 1 fig. 183. The *longitudinal* fibres being outside of the transverse, when they reach the internal sphincter wind around it and are inserted into the submucous coat from one to four inches above the anus. They thus form a pulley-like arrangement which everts the mucous membrane in defecation and is the active agent in producing prolapsus ani. I have observed that when hæmorrhoids exist many of the fibres run to be inserted into them, hence their ready extrusion when the patient is directed to force them down. The following cut exhibits this arrangement. See Horner's Special Anatomy, 1836.—G.

cluded by the serous membrane with the exception of the points of attachment of the omenta. The *descending portion* has merely a partial covering on its anterior surface. The *transverse portion* is also behind the peritoneum, being situated between the two layers of the transverse meso-colon, and has but a partial covering. The rest of the *small intestine* is completely invested by it, excepting along the concave border to which the mesentery is attached. The

Fig. 183.



cæcum is more or less invested by the peritoneum, the more frequent disposition being that in which the intestine is surrounded for three-fourths only of its circumference. The *ascending* and the *descending colon* are covered by the serous membrane only in front. The *transverse colon* is invested completely, with the exception of the lines of attachment of the greater omentum and transverse meso-colon. And the *sigmoid flexure* is entirely surrounded, with the exception of the part corresponding with the junction of the left meso-colon. The upper third of the rectum is completely enclosed by the peritoneum; the middle third has an anterior covering only, and the inferior third none whatsoever.

Vessels and Nerves.—The *Arteries* of the alimentary canal, as they supply the tube from above downwards, are the pterygo-palatine, ascending pharyngeal, superior thyroid, and inferior thyroid in the neck; œsophageal in the thorax; gastric, hepatic, splenic, superior and inferior mesenteric in the abdomen; and inferior mesenteric, iliac, and internal pudic in the pelvis. The *veins* from the abdominal alimentary canal unite to form the vena portæ. The *lymphatics* and *lacteals* open into the thoracic duct.

The *Nerves* of the pharynx and œsophagus are derived from the

Fig. 183. A vertical section of the parietes of the anus, passing through the middle line of one of the columns of the rectum, and the neighbouring parts. 1. The internal sphincter, with its arched fibres transversely divided. 2, 2. The plane of arched fibres of the muscular coat, similarly divided. 3. The point of greatest contraction of the internal sphincter. 4. The external sphincter. 5. The point of greatest contraction of the same muscle. 6. The plane of longitudinal fibres of the muscular coat, longitudinally divided. 7. Some of these fibres terminating in the internal sphincter. 8. Others, terminating in the external sphincter. 9. The remaining longitudinal fibres, collected into a semitendinous fasciculus, passing over the lower margin of the internal sphincter, to be reverted upward within the duplicature of the column. 10. These reverted fibres again becoming muscular, and terminating in the mucous coat. 11. The mucous coat. 12. A bristle in one of the sacs.—G.

cord which passes through a fissure in its under surface, from the umbilicus to the inferior vena cava. They are the—

Longitudinal,
Two lateral,
Coronary,
Round.

The *Longitudinal ligament* (broad, ligamentum suspensorium hepatis) is an antero-posterior fold of peritoneum, extending from the notch on the anterior margin of the liver to its posterior border. Between its two layers in the anterior and free margin is the round ligament.

The two *Lateral ligaments* are formed by the two layers of peritoneum, which pass from the under surface of the diaphragm to the posterior border of the liver; they correspond with its lateral lobes.

The *Coronary ligament* is formed by the separation of the two layers forming the lateral ligaments near their point of convergence. The posterior layer is continued unbroken from one lateral ligament into the other; but the anterior quits the posterior at each side, and is continuous with the corresponding layer of the longitudinal ligament. In this way a large oval surface on the posterior border of the liver is left uncovered by peritoneum, and is connected to the diaphragm by a dense cellular tissue. This space is formed principally by the right lateral ligament, and is pierced near its left extremity by the inferior vena cava, previously to the passage of that vessel through the tendinous opening in the diaphragm.

The *Round ligament* is a fibrous cord resulting from the obliteration of the umbilical vein, and situated between the two layers of peritoneum in the anterior border of the longitudinal ligament. It may be traced from the umbilicus, along the longitudinal fissure upon the under surface of the liver to the inferior vena cava, to which it is connected.

The under surface of the liver is marked by five fissures which divide its surface into five compartments or lobes, two principal and three minor lobes; they are the—

Fissures.

Longitudinal fissure,
Fissure of the ductus venosus,
Transverse fissure,
Fissure for the gall-bladder,
Fissure for the vena cava.

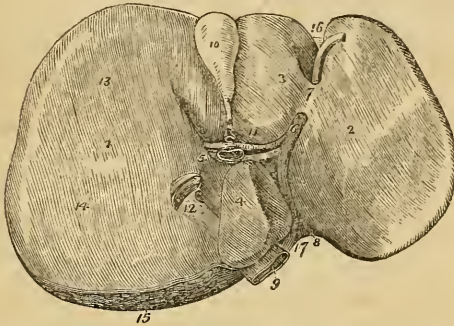
Lobes.

Right lobe,
Left lobe,
Lobus quadratus,
Lobus Spigelli,
Lobus caudatus.

The *Longitudinal fissure* is a deep groove running from the notch upon the anterior margin of the liver, to the posterior border of the organ. At about one-third from its posterior extremity it is joined by a short but deep fissure, the transverse, which meets it transversely from the under part of the right lobe.

The longitudinal fissure in front of this junction lodges the fibrous cord of the umbilical vein, and is generally crossed by a band of hepatic substance called the pons hepatis.

Fig. 185.



The *Fissure for the ductus venosus* is the shorter portion of the longitudinal fissure, extending from the junctional termination of the transverse fissure to the posterior border of the liver, and containing a small fibrous cord, the remains of the ductus venosus. This fissure is therefore but a part of the longitudinal fissure.

The *Transverse fissure* is the short and deep fissure, about two inches in length, through which the hepatic ducts, hepatic artery, and portal vein enter the liver. Hence this fissure was considered by the older anatomists as the gate (porta) of the liver; and the large vein entering the organ at this point, the portal vein. At their entrance into the transverse fissure the branches of the hepatic duct are the most anterior, next those of the artery, and most posteriorly the portal vein.

The *Fissure for the gall-bladder* is a shallow fossa extending forwards, parallel with the longitudinal fissure, from the right extremity of the transverse fissure to the free border of the liver, where it frequently forms a notch.

The *Fissure of the vena cava* is a deep and short fissure occasionally a rounded tunnel, which proceeds from a little behind the

Fig. 185. The under surface of the liver. 1. The right lobe. 2. The left lobe. 3. The lobus quadratus. 4. The lobus Spigelii. 5. The lobus caudatus. 6. The longitudinal fissure, in which is seen the rounded cord; the remains of the umbilical vein. 7. The pons hepatis. 8. The fissure for the ductus venosus; the obliterated cord of the ductus is seen passing backwards to be attached to the coats of the inferior vena cava 9. 10. The gall-bladder lodged in its fossa. 11. The transverse fissure, containing from before backwards, the hepatic duct, hepatic artery, and portal vein. 12. The vena cava. 13. A depression corresponding with the curve of the colon. 14. A double depression produced by the right kidney and its supra-renal capsule. 15. The rough surface on the posterior border of the liver left uncovered by peritoneum; the cut edge of peritoneum surrounding this surface forms part of the coronary ligament. 16. The notch on the anterior border, separating the two lobes. 17. The notch on the posterior border, corresponding with the vertebral column.

right extremity of the transverse fissure to the posterior border of the liver, and lodges the inferior vena cava.

These five fissures taken collectively resemble an inverted ∇ , the base corresponding with the free margin of the liver, and the apex with its posterior border. Viewing them in this way, the two anterior branches represent the longitudinal fissure on the left, and the fissure for the gall-bladder on the right side; the two posterior, the fissure for the ductus venosus on the left, and the fissure for the vena cava on the right side, and the connecting bar the transverse fissure.

Lobes.—The *Right lobe* is four or six times larger than the left, from which it is separated on the concave surface by the longitudinal fissure, and on the convex by the longitudinal ligament. It is marked upon its under surface by the transverse fissure, and by the fissures for the gall-bladder and vena cava, and presents three depressions, one in front for the curve of the ascending colon, and two behind for the right supra-renal capsule, and kidney.

The *Left lobe* is small and flattened, convex upon its upper surface, and concave below, where it lies in contact with the anterior surface of the stomach. It is sometimes in contact by its extremity with the upper end of the spleen, and is in relation by its posterior border with the cardiac orifice of the stomach, and left pneumogastric nerve.

The lobus quadratus is a quadrilateral lobe situated upon the under surface of the right lobe: it is bounded *in front* by the free border of the liver; *behind* by the transverse fissure; to the *right* by the gall-bladder; and to the *left* by the longitudinal fissure.

The *Lobus Spigelii** is a small triangular lobe, also situated upon the under surface of the right lobe: it is bounded *in front* by the transverse fissure; and *on the sides* by the fissures for the ductus venosus and vena cava.

The *Lobus caudatus* is a small tail-like appendage to the lobus Spigelii, from which it runs outwards like a crest into the right lobe, and serves to separate the right extremity of the transverse fissure from the commencement of the fissure for the vena cava. In some livers this lobe is extremely well-marked, in others it is small and ill-defined.

Reverting to the comparison of the fissures with an inverted ∇ , it will be observed that the quadrilateral interval, in front of the transverse bar, represents the lobus quadratus; the triangular space behind the bar, represents the Spigelii; and the apex of the letter, the point of union between the inferior vena cava, and the remains of the ductus venosus.

The *Vessels* entering into the structure of the liver are also *five* in number; they are, the

* Adrian Spigel, a Belgian physician, professor at Padua after Casserius in 1616. He assigned considerable importance to this little lobe, but it had been described by Sylvius full sixty years before his time.

Hepatic artery,
 Portal vein,
 Hepatic veins,
 Hepatic ducts,
 Lymphatics.

The *Hepatic artery, portal vein, and hepatic duct* enter the liver at the transverse fissure, and ramify through portal canals to every part of the organ; so that their general direction is from below upwards, and from the centre towards the circumference.

The *Hepatic veins* commence at the circumference and proceed from before backwards, to open into the vena cava, on the posterior border of the liver. Hence the branches of the two veins cross each other in their course.

The portal vein, hepatic artery, and duct are moreover enveloped in a loose cellular tissue, the capsule of Glisson, which permits them to contract upon themselves when emptied of their contents; the hepatic veins, on the contrary, are closely adherent by their parietes to the surface of the canals in which they run, and are unable to contract. By these characters the anatomist is enabled, in any section of the liver, to distinguish at once the most minute branch of the portal vein from the hepatic vein; the former will be found more or less collapsed, and always accompanied by an artery and duct, and the latter widely open and solitary.

The *Lymphatics* are described in the chapter dedicated to those vessels.

The *Nerves* of the liver are derived from the systems both of animal and of organic life; the former proceed from the right phrenic and pneumogastric nerves, and the latter from the hepatic plexus.

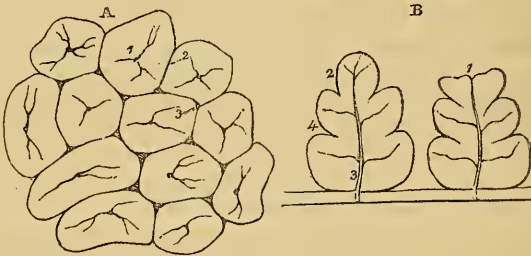
Structure and Minute Anatomy of the Liver, according to Mr. Kiernan.

The *Liver* is composed of *lobules*, of a connecting medium, called *Glisson's capsule*, of the ramifications of the *portal vein, hepatic duct, hepatic artery, hepatic veins, lymphatics, and nerves*, and is enclosed and retained in its proper situation by the peritoneum. I shall describe each of these structures singly, following rigidly the discoveries of Mr. Kiernan.

1. The *Lobules* are small granular bodies, of about the size of a millet seed, of an irregular form, and presenting a number of rounded projecting processes upon their surface. When divided longitudinally, they have a foliated appearance, and transversely, a polygonal outline, with sharp or rounded angles, according to the smaller or greater quantity of Glisson's capsule contained in the liver. Each lobule is divided upon its exterior into a base and a capsular surface. The *base* corresponds with one extremity of the lobule, is flattened, and rests upon an hepatic vein, which is thence named *sublobular*. The *capsular surface* includes the rest of the

periphery of the lobule, and has received its designation from being enclosed in a cellular capsule derived from the capsule of Glisson. In the centre of each lobule is a small vein, the *intralobular*, which is formed by the convergence of six or eight minute venules from the rounded processes situated upon the surface. The intralobular vein thus constituted takes its course through the centre of the longitudinal axis of the lobule, pierces the middle of its base, and opens into the sublobular vein. The circumference of the lobule, with the exception of its base, which is always closely attached to a sublobular vein, is connected by means of its cellular capsule with the capsular surface of surrounding lobules. The cellular interval between the lobules is the *interlobular fissure*, and the angular interstices formed by the apposition of several lobules are the *interlobular spaces*.

Fig. 186.



The lobules of the centre of the liver are angular, and somewhat smaller than those of the surface, from the greater compression to which they are submitted. The superficial lobules are incomplete, and give to the surface of the organ the appearance, and all the advantages resulting from an examination of a transverse section.

“Each lobule is *composed* of a plexus of biliary ducts, of a venous plexus formed by branches of the portal vein, of a branch (intra-lobular), of an hepatic vein, and of minute arteries; nerves and absorbents, it is to be presumed, also enter into their formation, but cannot be traced into them.” “Examined with the microscope, a lobule is apparently composed of numerous minute bodies of a yellowish colour, and of various forms, connected with each other by vessels. These minute bodies are the *acini* of Malpighi.” “If an uninjected lobule be examined and contrasted with an injected lobule, it will be found that the acini of Malpighi in the former

Fig. 186. The lobules of the liver. A. The lobules as they are seen upon the surface of the liver, or when divided transversely. 1. The intralobular vein in the centre of each lobule. 2. The interlobular fissure. 3. The interlobular space. B. A longitudinal section of two lobules. 1. A superficial lobule, terminating abruptly, and resembling a section at its extremity. 2. A deep lobule, showing the foliated appearance of its section. 3. The intralobular vein, with its converging venules; the vein terminates in a sublobular vein. 4. The external, or capsular surface of the lobule.

are identical with the injected lobular biliary plexus in the latter, and the blood-vessels in both will be easily distinguished from the ducts."

Glisson's capsule is the cellular tissue which envelops the hepatic artery, portal vein, and hepatic duct, during their passage through the right border of the lesser omentum, and which continues to surround them to their ultimate distribution in the substance of the lobules. It forms for each lobule a distinct capsule, which invests it on all sides with the exception of its base, connects all the lobules together, and constitutes the proper capsule of the entire organ. But "*Glisson's capsule*," observes Mr. Kiernan, "is not

mere cellular tissue; it is to the liver what the pia mater is to the brain; it is a cellulo-vascular membrane in which the vessels divide and subdivide to an extreme degree of minuteness; which lines the portal canals, forming sheaths for the larger vessels contained in them, and a web in which the smaller vessels ramify; which enters the interlobular fissures, and with the vessels forms the capsules of the lobules; and which finally enters the lobules, and with the blood-vessels expands itself over the secreting biliary ducts." Hence arises a natural division of the capsule into three portions, a *vaginal*, an *interlobular*, and a *lobular portion*.

The *vaginal portion* is that which invests the hepatic artery, hepatic duct, and portal vein, in the portal canals; in the larger canals it completely surrounds these vessels, but in the smaller is situated only on that side which is occupied by the artery and duct. The *interlobular portion* occupies the interlobular fissures and spaces, and the *lobular portion* forms the supporting tissue to the substance of the lobules.

The *Portal vein*, entering the liver at the transverse fissure, rami-

Fig. 187.

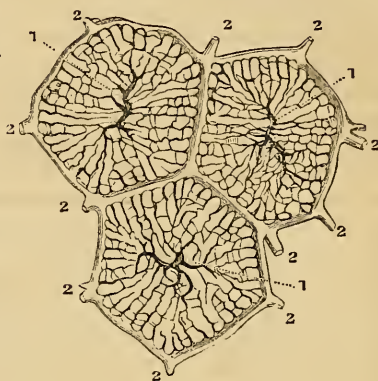


Fig. 188.

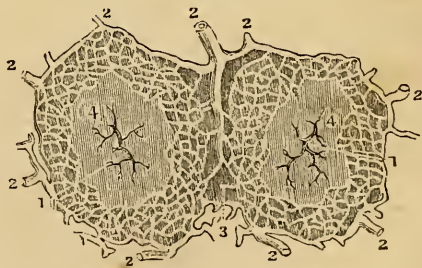


Fig. 187. Horizontal section of three superficial lobules, showing the two principal systems of bloodvessels.—(Kiernan.)

Fig. 188. Horizontal section of two superficial lobules, showing interlobular plexus of biliary ducts.—(Kiernan.)

fies through its structure in canals which resemble, by their surfaces, the external superficies of the liver, and are formed by the capsular surfaces of the lobules,—“all their canals being,” as it were, “tubular inflections inwards of the superficies of the liver.” These are the portal canals, and contain, besides the portal vein with its ramifications, the artery and duct with their branches.

In the larger canals, the vessels are separated from the parietes of the cavity by a web of Glisson’s capsule; but, in the smaller, the portal vein is in contact with the surface of the canal for about two-thirds of its cylinder, the opposite third being in relation with the artery and duct and their investing capsule. If, therefore, the portal vein were laid open by a longitudinal incision in one of these smaller canals, the coats being transparent, the outline of the lobules, bounded by their interlobular fissures, would be as distinctly seen as upon the external surface of the liver, and the smaller venous branches would be observed entering the interlobular spaces.

The branches of the portal vein are, the vaginal, interlobular, and lobular. The *vaginal branches* are those which, being given off in the portal canals, have to pass through the sheath (vagina) of Glisson’s capsule, previously to entering the interlobular spaces. In this course they form an intricate plexus, the *vaginal plexus*, which, depending for its existence on the capsule of Glisson, necessarily surrounds the vessels, as does that capsule in the larger canals, and occupies the capsular side only in the smaller canals. The *interlobular branches* are given off from the vaginal portal plexus where it exists, and directly from the portal veins, in that part of the smaller canals where the coats of the vein are in contact with the walls of the canal. They then enter the interlobular spaces and divide into branches, which cover with their ramifications every part of the surface of the lobules with the exception of their bases, and those extremities of the superficial lobules which appear upon the surfaces of the liver. The interlobular veins communicate freely with each other, and with the corresponding veins of adjoining fissures, and establish a general portal anastomosis throughout the entire liver. The *lobular branches* are derived from the interlobular veins; they form a plexus within each lobule, and converge from the circumference towards the centre, where they terminate in the minute radicles of the intralobular portal vein. This plexus, interposed between the interlobular portal veins and the intralobular hepatic vein, constitutes the venous part of the lobule, and may be called the *lobular venous plexus*. The irregular islets of the substance of the lobules, seen between the meshes of this plexus by means of the microscope, are the acini of Malpighi, and are shown by Mr. Kiernan to be portions of the lobular biliary plexus.

The portal vein returns the venous blood from the chylopoietic viscera, to be circulated through the lobules; it also receives the venous blood which results from the distribution of the hepatic artery.

The *Hepatic duct*, entering the liver at the transverse fissure,

divides into branches, which ramify through the portal canals, with the portal vein and hepatic artery, to terminate in the substance of the lobules. Its branches, like those of the portal vein, are vaginal, interlobular, and lobular.

The *Vaginal branches* ramify through the capsule of Glisson, and form a *vaginal biliary plexus*, which, like the vaginal portal plexus, surrounds the vessels in the large canals, but is deficient on that side of the smaller canals near which the duct is placed. The branches given off by the vaginal biliary plexus are interlobular and lobular. The *interlobular branches* proceed from the vaginal biliary plexus where it exists, and directly from the hepatic duct on that side of the smaller canals against which the duct is placed. They enter the interlobular spaces, and ramify upon the capsular surface of the lobules, in the interlobular fissures, where they communicate freely with each other. The *lobular ducts* are derived chiefly from the interlobular; but to those lobules forming the walls of the portal canals, they pass directly from the vaginal plexus. They enter the lobule and form a plexus in its interior, the *lobular biliary plexus*, which constitutes the principal part of the substance of the lobule. The ducts terminate either in loops or in cæcal extremities.

The coats of the ducts are very vascular, and supplied with a number of mucous follicles, which are distributed irregularly in the larger, but are arranged in two parallel longitudinal rows in the smaller ducts.

The *Hepatic artery* enters the liver with the portal vein and hepatic duct, and ramifies with those vessels through the portal canals. Its branches are the vaginal, interlobular, and lobular. The *vaginal branches*, like those of the portal vein and hepatic duct, form a *vaginal plexus*, which exists throughout the whole extent of the portal canals, with the exception of that side of the smaller canals which corresponds with the artery. The *interlobular branches*, arising from the vaginal plexus and from the parietal side of the artery in the smaller canals, ramify through the interlobular fissures, and are principally distributed to the coats of the interlobular ducts.

“From the superficial interlobular fissures small arteries emerge, and ramify in the *proper capsule*, on the convex and concave surface of the liver, and in the ligaments. These are the *capsular arteries*.” Where the capsule is well developed, “these vessels cover the surfaces of the liver with a beautiful plexus,” and “anastomose with branches of the phrenic, internal mammary, and supra-renal arteries,” and with the epigastric.

The *Lobular branches*, extremely minute and few in number, are the nutrient vessels of the lobules, and terminate in the lobular venous plexus.

All the venous blood resulting from the distribution of the hepatic artery, even that from the *vasa vasorum* of the hepatic veins, is returned into the portal vein.

The *Hepatic veins* commence in the substance of each lobule by

minute venules, which receive the blood from the lobular venous plexus, and converge to form the intralobular vein. The *intralobular vein* passes through the central axis of the lobule, and through the middle of its base, to terminate in a sublobular vein; and the union of the sublobular veins constitutes the hepatic trunks, which terminate in the inferior vena cava. The hepatic venous system consists, therefore, of three sets of vessels; intralobular veins, sublobular veins, and hepatic trunks.

The *Sublobular veins* are contained in canals formed solely by the bases of the lobules, with which, from the absence of Glisson's capsule, they are in immediate contact. Their coats are thin and transparent; and if they be laid open by a longitudinal incision, the bases of the lobules will be distinctly seen, separated by interlobular fissures, and perforated through the centre by the opening of the intralobular vein.

The *Hepatic trunks* are formed by the union of the sublobular veins; they are contained in canals (hepatic venous) similar in structure to the portal canals, and lined by a prolongation of the proper capsule. They proceed from before backwards, and terminate by two large openings, corresponding to the right and left lobe of the liver in the inferior vena cava.

It is to Kiernan that anatomical science is indebted for the clear, distinct, and intelligible idea of the structure of this most complicated organ, which has been furnished by the researches of that anatomist. To value this knowledge as it deserves, we have but to reflect upon the unsuccessful, though not fruitless, labours of those great discoverers in structural anatomy, Malpighi and Ruysch, upon the same subject, and the strange misconceptions of modern authors, among whom Müller and Cruveilhier occupy so conspicuous a place. It is not, however, in an anatomical, or even a physiological point of view merely, that we have to admire these discoveries; for in their practical application to the elucidation of pathological appearances, and the explanation of the phenomena of disease, they are still more interesting.

Summary.—The liver has been shown to be composed of *lobules*; the lobules (excepting at their bases) are invested and connected together, the vessels supported, and the whole organ enclosed by *Glisson's capsule*; and they are so arranged, that the base of every lobule in the liver is in contact with an hepatic vein (sublobular).

The *Portal vein* distributes its numberless branches through portal canals, which are channeled through every part of the organ; it brings the returning blood from the chylopoietic viscera; it collects also the venous blood from the ultimate ramifications of the hepatic artery in the liver itself. It gives off branches in the canals, which are called *vaginal*, and form a venous *vaginal plexus*; these give off *interlobular branches*, and the latter enter the lobules and form *lobular venous plexuses*, from the blood circulating in which the bile is secreted.

The *Bile* in the lobule is received by a network of minute ducts

the *lobular biliary plexus*; it is conveyed from the lobule into the *interlobular ducts*; it is thence poured into the biliary *vaginal plexus* of the portal canals, and thence into the excreting ducts, by which it is carried to the duodenum and gall-bladder, after being mingled in its course with the mucous secretion from the numberless muciparous follicles in the walls of the ducts.

The *Hepatic artery* distributes branches through every portal canal; gives off *vaginal branches* which form a vaginal hepatic plexus, from which the *interlobular branches* arise, and these latter terminate ultimately in the lobular venous plexuses of the portal vein. The artery ramifies abundantly in the coats of the hepatic ducts, enabling them to provide their mucous secretion; and supplies the *vasa vasorum* of the portal and hepatic veins, and the nutrient vessels of the entire organ.

The *Hepatic veins* commence in the centre of each lobule by minute radicles, which collect the impure blood from the lobular venous plexus and convey it into the *intra-lobular veins*; these open into the *sublobular veins*, and the sublobular veins unite to form the large hepatic trunks by which the blood is conveyed into the *vena cava*.

The physiological deduction arising out of this anatomical arrangement is, that the *bile is wholly secreted from venous blood*, and not from a mixed venous and arterial blood, as is believed by Müller; for although the portal vein receives its blood from two sources, viz. from the chylopoietic viscera and from the capillaries of the hepatic artery, yet the very fact of the blood of the latter vessel having passed through its capillaries into the portal vein, or in extremely small quantity into the capillary network of the lobular venous plexus, is sufficient to establish its venous character.*

The pathological deductions depend upon the following facts:— Each lobule is a perfect gland; of uniform structure, of uniform colour, and possessing the same degree of vascularity throughout. It is the seat of a double venous circulation, the vessels of the one (*hepatic*) being situated in the centre of the lobule, and those of the other (*portal*) in the circumference. Now the colour of the lobule, as of the entire liver, depends chiefly upon the proportion of blood contained within these two sets of vessels; and so long as the circulation is natural the colour will be uniform. But the instant that any cause is developed which shall interfere with the free circulation of either, there will be an immediate diversity in the colour of the lobule.

Thus, if there be any impediment to the free circulation of the venous blood through the heart or lungs, the circulation in the hepatic veins will be retarded, and the sublobular and the intra-lobular veins will become congested, giving rise to a more or less extensive redness in the centre of each of the lobules, while the marginal or non-congested portion presents a distinct border of a yel-

* For arguments upon this contested question, see the article "Liver," in the "Cyclopædia of Anatomy and Physiology," edited by Dr. Todd.

lowish white, yellow, or green colour, according to the quantity and quality of the bile it may contain. "This is '*passive congestion*' of the liver, the usual and natural state of the organ after death;" and, as it commences with the hepatic vein, it may be called the first stage of *hepatic-venous* congestion.

But if the causes which produced this state of congestion continue, or be from the beginning of a more active kind, the congestion will extend through the lobular venous plexuses "into those branches of the portal vein situated in the *interlobular fissures*, but not to those in the *spaces*, which, being larger, and giving origin to those in the fissures, are the last to be congested." In this second stage the liver has a mottled appearance, the non-congested substance is arranged in isolated, circular, and ramose patches, in the centres of which the spaces and part of the fissures are seen. This is an extended degree of *hepatic-venous congestion*; it is "*active congestion*" of the liver, and very commonly attends diseases of the heart and lungs.

There is another form of partial venous congestion which commences in the portal vein; this is, therefore, *portal venous congestion*. It is of very rare occurrence, and Mr. Kiernan has observed it in children only. "In this form the congested substance never assumes the deep red colour which characterizes hepatic venous congestion; the interlobular fissures and spaces, and the marginal portions of the lobules are of a deeper colour than usual; the congested substance is continuous and cortical, the non-congested substance being medullary, and occupying the centres of the lobules. The second stage of hepatic venous congestion, in which the congested substance appears, but is not cortical, may be easily confounded with portal venous congestion.

These are instances of *partial congestion*, but there is sometimes *general congestion* of the organ. "In general congestion the whole liver is of a red colour, but the central portions of the lobules are usually of a deeper hue than the marginal portions."

GALL-BLADDER.

The gall-bladder is the reservoir for the bile; it is a pyriform sac situated in a fossa, upon the under surface of the right lobe of the liver, and extending from the right extremity of the transverse fissure to its free margin. It is divided into a body, fundus, and neck; the fundus or broad extremity in the natural position of the liver is placed downwards, and frequently projects beyond the free margin of the liver, while the neck, small and constricted, is directed upwards. This sac is composed of three coats, serous, fibrous, and mucous. The *serous coat* is partial, is derived from the peritoneum, and covers that side only which is unattached to the liver. The *middle* or *fibrous coat* is a thin but strong cellulo-fibrous layer, intermingled with tendinous fibres. It is connected on one side to the liver, and on the other to the peritoneum. The *internal* or *mucous coat* is but loosely connected with the fibrous layer; it is every

where raised into minute rugæ which give it a beautifully reticulated appearance, and forms at the neck of the sac a spiral valve.

It is continuous through the hepatic duct with the mucous membrane lining all the ducts of the liver, and through the ductus communis choledochus, with the mucous membrane of the alimentary canal.

The *Biliary ducts* are,—the ductus communis choledochus, the cystic and the hepatic duct.

The *Ductus communis choledochus* (χολή bilis, δέχομαι recipio) is the common excretory duct of the liver and gall-bladder; it is about three inches in length, and commences upon the papilla, situated on the inner side of the cylinder of the perpendicular portion of the duodenum. Passing obliquely between the mucous and muscular coats, it ascends behind the duodenum, and through the right border of the lesser omentum; and divides into two branches, the cystic duct and the hepatic duct. It is constricted at its commencement in the duodenum, and becomes dilated in its progress upwards.

The *Cystic duct*, about an inch in length, passes outwards to the neck of the gall-bladder, with which it is continuous.

The *Hepatic duct* continues onwards to the transverse fissure of the liver, and divides into two branches, which ramify through the portal canals to every part of the liver.

The *coats* of the hepatic ducts are an external or fibrous, and an internal or mucous.

The *external coat* is composed of a contractile fibrous tissue, which is probably muscular; but its muscularity has not yet been demonstrated in the human subject. The *mucous coat* is continuous on the one hand with the lining membrane of the hepatic ducts and gall-bladder, and on the other with that of the duodenum.

Vessels and Nerves.—The gall-bladder is supplied with blood by the cystic artery, a branch of the hepatic. Its veins return their blood into the portal vein. The nerves are derived from the hepatic plexus.

THE PANCREAS.

The Pancreas is a long, flattened, conglomerate gland, analogous to the salivary glands. It is about six inches in length, and between three or four ounces in weight, and is situated transversely across the posterior wall of the abdomen, behind the stomach, and resting upon the aorta, vena portæ, inferior vena cava, the origin of the superior mesenteric artery, and the left kidney and supra-renal capsule; opposite to the first and second lumbar vertebræ. It is divided into a body, a greater, and a smaller extremity; the great end or head is placed towards the right, and is surrounded by the curve of the duodenum; the lesser end extends to the left as far as the spleen. The anterior surface of the body of the pancreas is covered by the ascending posterior layer of the peritoneum and is in relation with the stomach, the first portion of the duodenum and the commencement of the transverse arch of the colon. The pos-

terior surface is grooved for the splenic vein, and tunneled by a complete canal for the superior mesenteric and portal vein, and for the superior mesenteric artery. The upper border presents a deep groove, sometimes a canal for the splenic artery and vein, and is in relation with the oblique portion of the duodenum, the lobus Spigelii, and the cœliac axis. And the lower border is separated from the transverse portion of the duodenum by the superior mesenteric artery and vein. Upon the posterior part of the head of the pancreas is a lobular fold of the gland which completes the canal of the superior mesenteric vessels, and is called the *lesser pancreas*.

In structure it is composed of reddish-yellow angular lobules; these consist of smaller lobules, and the latter are made up of the arborescent ramifications of minute ducts, terminating in cæcal pouches.

The pancreatic duct commences at the papilla upon the inner and posterior surface of the perpendicular portion of the duodenum by a small dilatation which is common to it and to the ductus communis choledochus, and passing obliquely between the mucous and muscular coats runs from right to left through the middle of the gland, lying nearer to its anterior than to its posterior surface. At about the commencement of the apical third of its course it divides into two parallel terminal branches. It gives off numerous small branches, which are distributed through the lobules, and constitute with the latter the substances of the gland. The duct which receives the secretion from the lesser pancreas is called the *ductus pancreaticus minor*; it opens into the principal duct near to the duodenum, and sometimes passes separately into that intestine. As a variety, two pancreatic ducts are occasionally met with.

Vessels and Nerves.—The arteries of the pancreas are branches of the splenic, hepatic, and superior mesenteric; the *veins* open into the splenic vein; the *lymphatics* terminate in the lumbar glands. The *nerves* are filaments of the splenic plexus.

THE SPLEEN.

The spleen is an oblong flattened organ of a dark bluish-red colour, situated in the left hypochondriac region. It is very variable in size and weight, spongy and vascular in texture and exceedingly friable. The external surface is convex, the internal slightly concave, indented along the middle line, and pierced by several large and irregular openings for the entrance and exit of vessels; this is the *hilus lienis*. The upper extremity is somewhat larger than the lower, and rounded; the inferior is flattened; the posterior border is obtuse; the anterior is sharp and marked by several notches. The spleen is in relation by its external or convex surface with the diaphragm, which separates it from the ninth, tenth, and eleventh ribs; by its concave surface with the great end of the stomach, the extremity of the pancreas, the gastro-splenic omentum with its vessels, the left kidney and supra-renal capsule, and with the left crus

of the diaphragm; by its upper end with the diaphragm, and sometimes with the extremity of the left lobe of the liver, and by its lower end with the left extremity of the transverse arch of the colon. It is connected to the stomach by the gastro-splenic omentum and by the vessels contained in that duplicature. A second spleen (*lien succenturiatus*) is sometimes found appended to one of the branches of the splenic artery, near to the great end of the stomach; when it exists, it is round and of very small size, rarely larger than a hazelnut. I have seen two and even three of these bodies. The spleen is invested by the peritoneum and by a *tunica propria* of yellow elastic tissue, which enables it to yield to the greater or less distension of its vessels. The elastic tunic forms sheaths for the vessels in their ramifications through the organ, and from these sheaths small fibrous bands are given off in all directions, which become attached to the internal surface of the elastic tunic, and constitute the cellular framework of the spleen. The substance occupying the interspaces of this tissue is soft and granular, and of a bright red colour; in animals it is interspersed with small, white, soft corpuscles.

Vessels and Nerves.—The *Splenic artery* is of a very large size in proportion to the bulk of the spleen; it is a division of the cœliac axis. The branches which enter the spleen are distributed to distinct sections of the organ, and anastomose very sparingly with each other. The *veins* by their numerous dilatations constitute the principal part of the bulk of the spleen; they pour their blood into the splenic vein, which is one of the two great formative trunks of the portal vein. The *lymphatics* are remarkable for their number and large size, they terminate in the lumbar glands. The *nerves* are the splenic plexus, derived from the solar plexus.

THE SUPRA-RENAL CAPSULES.

The supra-renal capsules are two small yellowish and flattened bodies surmounting the kidneys, and inclining inwards towards the vertebral column. The right is somewhat three-cornered in shape, the left more semilunar; they are connected to the kidneys by the common investing cellular tissue, and each capsule is marked upon its anterior surface by a fissure which appears to divide it into two lobes. The right supra-renal capsule is closely adherent to the posterior and under surface of the liver, and the left lies in contact with the pancreas. Both capsules rest upon the crura of the diaphragm on a level with the tenth dorsal vertebra, while by their inner border they are in relation with the great splanchnic nerve, and with the semilunar ganglion. They are larger in the fœtus than in the adult, and appear to perform some office connected with embryonic life. The anatomy of these organs in the fœtus will be found in the succeeding chapter.

In structure they are composed of two substances, cortical and medullary. The cortical substance is of a yellowish colour, and consists of straight parallel fibres placed perpendicularly side by

side. The medullary substance is generally of a dark brown colour, double the quantity of the yellow substance, soft in texture, and contains within its centre the trunk of a large vein—the vena supra-renal. It is the large size of this vein that gives to the fresh supra-renal capsule the appearance of a central cavity; the dark-coloured pulpy or fluid contents of the capsule, at a certain period after death, are produced by softening of the medullary substance. Dr. Nagel* has shown, by his injections and microscopic examinations, that the appearance of straight fibres in the cortical substance is caused by the direction of a plexus of capillary vessels. Of the numerous minute arteries, supplying the supra-renal capsule, he says, the greater number enter the cortical substance at every point of its surface, and, after proceeding for scarcely half a line in its substance, divide into a plexus of straight capillary vessels. Some few of the small arteries pierce the cortical layer and give off several branches in the medullary substance, which proceed in different directions, and re-enter the cortical layer to divide into a capillary plexus in a similar manner with the preceding. From the capillary plexus, composing the cortical layer, the blood is received by numerous small veins which form a venous plexus in the medullary substance, and terminate at acute angles in the large central vein.

Vessels and Nerves.—The supra-renal arteries are derived from the aorta, from the renal, and from the phrenic arteries; they are remarkable for the innumerable minute arteries into which they divide previously to entering the capsule. The *supra-renal vein* collecting the blood from the medullary venous plexus and receiving the several branches which pierce the cortical layer, opens directly into the vena cava on the right side, and into the renal vein on the left.

The *Lymphatics* are large and very numerous; they terminate in the lumbar glands. The *nerves* are derived from the renal and from the phrenic plexus.

THE KIDNEYS.

The kidneys, the secreting organs of the urine, are situated in the lumbar regions behind the peritoneum, and on each side of the vertebral column, which they approach by their upper extremities. Each kidney is between four and five inches in length, about two inches and a half in breadth, and somewhat more than one inch in thickness; and weighs between three and five ounces. The kidneys are usually enclosed in a quantity of fat, they rest upon the diaphragm, upon the anterior lamella of the transversalis muscle, which separates them from the quadratus lumborum, and upon the psoas magnus. The *right kidney* is somewhat lower than the left, from the position of the liver; it is in relation by its anterior surface with the liver and descending portion of the duodenum, which rest upon it, and is covered in by the ascending colon and by its flexure. The

* Müller's Archiv. 1836.

left kidney, higher than the right, is covered in front by the great end of the stomach, by the spleen, descending colon with its flexure, and by a portion of the small intestines. The anterior surface of the kidney is convex, while the posterior is flat; the superior extremity is in relation with the supra-renal capsule; the convex border is turned outwards towards the parietes of the abdomen; and the concave border looks inwards towards the vertebral column, and is excavated by a deep fissure—the *hilus renalis*—in which are situated the vessels and nerves and pelvis of the kidney; the renal vein being the most anterior, next the renal artery, and lastly the pelvis.

The kidney is dense and fragile in texture, and is invested by a proper fibrous capsule, which is easily torn from its surface. When divided by a longitudinal incision carried from the convex to the concave border, it presents in its interior two structures, an external or vascular (cortical), and an internal or tubular (medullary) substance. The *tubular portion* is formed of pale reddish-coloured conical bodies corresponding by their bases with the vascular structure, and by their apices with the hilus of the organ; these bodies are named cones, and are from eight to fifteen in number. The *vascular portion* is composed of blood-vessels, and of the plexiform convolutions of uriniferous tubuli, and not only forms the surface of the kidney, but dips between the cones and surrounds them nearly to their apices. The tubuli uriniferi communicate frequently with each other in the vascular structure of the kidney, and terminate in anastomosing loops and cæcal extremities. They are each surrounded by a fine network of capillary vessels. When examined with a lens of low power, a multitude of small globular bodies, glomeruli (*corpora Malpighiana*) are seen to be interspersed through the vascular structure of the organ, and to be connected to the minute twigs of the arteries. They are about $\frac{1}{30}$ th of an inch in diameter, are composed of an aggregated plexus of capillary vessels, and enclose a small central cavity, the use of which is as yet unknown.

The *Cones* are composed of minute straight tubuli uriniferi of about the diameter of a fine hair; they divide into parallel branches in their course, and commence by minute openings upon the apex

Fig. 189.

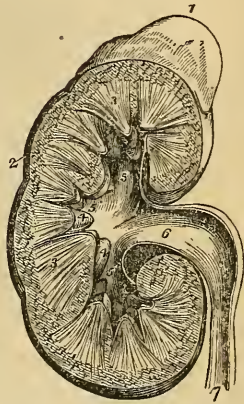


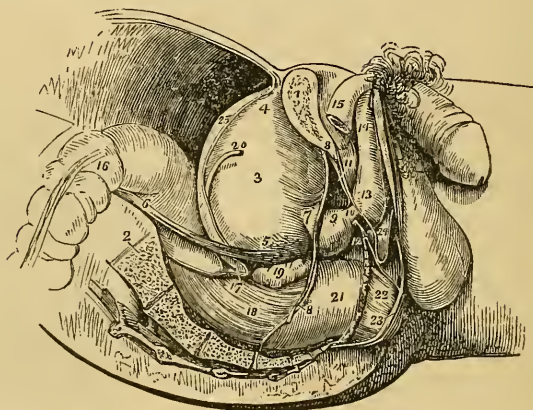
Fig. 189. A section of the kidney, surmounted by the supra-renal capsule; the swellings upon the surface mark the original constitution of the organ by distinct lobes. 1. The supra-renal capsule. 2. The vascular portion of the kidney. 3, 3. Its tubular portion, consisting of cones. 4, 4. Two of the papillæ projecting into thin corresponding calices. 5, 5, 5. The three infundibuli; the middle 5 is situated in the mouth of a calyx. 6. The pelvis. 7. The ureter.

or papilla of each cone. The papillæ are invested by mucous membrane, which is continuous with the lining membrane of the tubuli, and forms a cup-like pouch, the *calyx*, around each papilla.

The calices communicate with a common cavity of larger size, situated at each extremity, and in the middle of the organ; and these three cavities—the *infundibula*—constitute by their union the large membranous sac, which occupies the hilus renalis, the *pelvis* of the kidney.

The kidney in the embryo and fœtus consists of lobules. See the anatomy of the fœtus in the succeeding chapter.

Fig. 190.



The *Ureter* (οὐδρον, urine, τήρειν, to keep), the excretory duct of the kidney, is a membranous tube of about the diameter of a goose-quill, and nearly eighteen inches in length; it is continuous superiorly with the pelvis of the kidney, and is constricted inferiorly, where it lies in an oblique direction between the muscular and mucous coats

Fig. 190. A side view of the viscera of the male pelvis in situ. The right side of the pelvis has been removed by a vertical section made through the os pubis near to the symphysis; and another through the middle of the sacrum. 1. The divided surface of the os pubis. 2. The divided surface of the sacrum. 3. The body of the bladder. 4. Its fundus; from the apex is seen passing upwards the urachus. 5. The base of the bladder. 6. The ureter. 7. The neck of the bladder. 8, 8. The pelvic fascia; the fibres immediately above 7 are given off from the pelvic fascia and represent the anterior ligaments of the bladder. 9. The prostate gland. 10. The membranous portion of the urethra, between the two layers of the deep perineal fascia. 11. The deep perineal fascia formed of two layers. 12. One of Cowper's glands between the two layers of deep perineal fascia, and beneath the membranous portion of the urethra. 13. The bulb of the corpus spongiosum. 14. The body of the corpus spongiosum. 15. The right crus penis. 16. The upper part of the first portion of the rectum. 17. The rectovesical fold of peritoneum. 18. The second portion of the rectum. 19. The right vesicula seminalis. 20. The vas deferens. 21. The rectum covered with the descending layer of the pelvic fascia, just as it is making its bend backwards to constitute the third portion. 22. A part of the levator ani muscle investing the lower part of the rectum. 23. The external sphincter ani. 24. The interval between the deep and superficial perineal fascia; they are seen to be continuous beneath the figure.

of the base of the bladder, and opens upon its mucous surface. Lying along the posterior wall of the abdomen, it is situated behind the peritoneum and is crossed by the spermatic vessels; in its course downwards it rests upon the anterior surface of the psoas, and crosses the common iliac artery and vein, and then the external iliac vessels. Within the pelvis it crosses the umbilical artery and the vas deferens in the male, and the upper part of the vagina in the female. There are sometimes two ureters to one kidney.

The ureter, the pelvis, the infundibula, and the calices are composed of two coats, an external or fibrous coat, the tunica propria; and an internal mucous coat, which is continuous with the mucous membrane of the bladder inferiorly, and with the lining of the tubuli uriniferi above.

Vessels and Nerves.—The renal artery is derived from the aorta; it divides into several large branches before entering the hilus. There are frequently two renal arteries and sometimes three.

The *Veins* terminate in the vena cava by a single large trunk on each side; the left renal vein receiving the left spermatic vein. Injections thrown into the renal artery and returning by the vein, generally make their way into those vessels by rupture; and when the injection returns by the tubuli uriniferi, it always occurs from the bursting of the capillary vessels of the ducts into their cavities. The *lymphatic vessels* terminate in the lumbar glands.

The *Nerves* are derived from the renal plexus, which is formed partly by the solar plexus, and partly by the lesser splanchnic nerve. The renal plexus gives branches to the spermatic plexus, and branches which accompany the ureters: hence the morbid sympathies which exist between the kidney, the ureter, and the testicle; and by the communications with the solar plexus, with the stomach and diaphragm, and indeed with the whole system.

THE PELVIS.

The cavity of the pelvis is that portion of the great abdominal cavity which is included within the bones of the pelvis, below the level of the linea-ilio-pectinea and the promontory of the sacrum. It is bounded by the cavity of the abdomen above, and by the perineum below; its internal parietes are formed in front, below, and at the sides, by the peritoneum, pelvic fascia, levatores ani muscles, obturator fasciæ and muscles; and behind, by the sacrum, and sacral plexus of nerves.

The *Viscera of the pelvis* in the male are the urinary bladder, the prostate gland, vesiculæ seminales, and the rectum.

BLADDER.

The *Bladder* is an oblong membranous viscus of an ovoid shape, situated behind the os pubis and in front of the rectum. It is larger in its vertical diameter than from side to side; and its long axis is directed from above, obliquely downwards and backwards. It is divided into body, fundus, base, and neck. The *body* comprehends

the middle zone of the organ; the *fundus*, its upper segment; the *base*, the lower broad extremity, which rests upon the rectum; and the *neck*, the narrow constricted portion which is applied against the prostate gland.

This organ is retained in its place by ligaments which are divided into true and false; the true ligaments are seven in number, two anterior, two lateral, two umbilical, and the urachus; the false ligaments are folds of the peritoneum, and are four in number, two anterior and two posterior.

The *Anterior ligaments* are formed by the pelvic fascia, which passes from the inner surface of the os pubis, on each side of the symphysis, to the front of the bladder.

The *Lateral ligaments* are formed by the reflection of the pelvic fascia from the levatores ani muscles, upon the sides of the base of the bladder.

The *Umbilical ligaments* are the fibrous cords which result from the obliteration of the umbilical arteries of the fœtus; they pass forwards on each side of the fundus of the bladder, and ascend beneath the peritoneum to the umbilicus.

The *Urachus* is a small fibrous cord formed by the obliteration of a tubular canal existing in the embryo; it is attached to the apex of the bladder, and thence ascends to the umbilicus.

The *False ligaments* are folds of peritoneum, the two lateral correspond with the passage of the vasa deferentia, from the sides of the bladder to the internal abdominal rings, and the two posterior with the course of the umbilical arteries, to the fundus of the organ.

The bladder is composed of three coats, an external or serous coat, a muscular, and a mucous coat. The *serous coat* is partial, and derived from the peritoneum, which invests the posterior surface and sides of the bladder, from about opposite the point of termination of the two ureters to its summit, whence it is guided to the anterior wall of the abdomen by the umbilical ligaments and urachus. The *muscular coat* consists of two layers, an external layer composed of longitudinal fibres, the detrusor urinæ; and an internal layer of oblique and transverse fibres irregularly distributed. The anterior longitudinal fibres commence by four branches (the tendons of the bladder, or of the detrusor urinæ), two superior from the os pubis, and two inferior from the ramus of the ischium on each side, and spread out as they ascend upon the anterior surface of the bladder to its fundus; they then converge upon the posterior surface of the organ, and descend to its neck where they are inserted into the isthmus of the prostate gland, and into a ring of elastic tissue, which surrounds the commencement of the prostatic portion of the urethra. Some of the anterior fibres are also attached to this ring. The lateral fibres commence at the prostate gland and the elastic ring of the urethra on one side, and spread out as they ascend upon the side of the bladder to descend upon the opposite side, and be inserted into the prostate and opposite segment of the same ring. Two bands of oblique fibres are described by Sir Charles Bell, as ori-

ginating at the terminations of the ureters, and converging to the neck of the bladder; the existence of these muscles is not well established.

It has been well shown by Mr. Guthrie,* that there are no fibres at the neck of the bladder capable of forming a sphincter vesicæ. The fibres corresponding with the trigonum vesicæ are transverse.

Sir Astley Cooper has demonstrated around the neck of the bladder within the prostate gland, a ring of elastic tissue, which has for its object the mechanical closure of the urethra against the involuntary passage of the urine. It is into this elastic ring that the longitudinal fibres of the detrusor urinæ are inserted, so that this muscle taking a fixed point at the os pubis will not only compress the bladder, and thereby tend to force its contents along the urethra; but will at the same time, by means of its attachment to this ring dilate the entrance of the urethra, and afford a free egress to the contents of the bladder.†

* "On the Anatomy and Diseases of the Neck of the Bladder and of the Urethra."

† In Horner's Special Anatomy, vol. ii. p. 82, we find a different account of the sphincter apparatus at the neck of the bladder, which I subjoin because I have found it correct in every case which I have examined. On one point I beg leave to differ from Prof. Horner's description, viz.: in place of considering the transverse band connecting the two lobes of the prostate, and the triangular lamina underlying the vesical triangle as muscular, I believe them to belong to the proper elastic tissue such as forms the ligamentum nuchæ in the mammiferæ and the middle coat of the arterial system. I annex a cut to the description of Horner, taken by his permission from a drawing by Peale.—G.

"The internal orifice of the neck of the bladder resembles strongly that of a Florence flask, modified, however, by the projection of the uvula vesicæ, which makes it somewhat crescentic below. The neck of the bladder penetrates the prostate gland, but, at its commencement, is surrounded by loose cellular tissue containing a very large and abundant plexus of veins. The internal layer of muscular fibres is here transverse; and they cross and intermix with each other in different directions, forming a close compact tissue, which has the effect of a particular apparatus for retaining the urine, and is called *musculus sphincter vesicæ urinariæ*. Generally, anatomists have not considered this structure as distinct from the muscular coat at large; but Sir Charles Bell, now a professor in the University of Edinburgh, whose reputation as an anatomist is well established, gives the following account of it:

"Begin the dissection by taking off the inner membrane of the bladder from around the orifice of the urethra. A set of fibres will be discovered, on the lower half of the orifice, which, being carefully dis-

Fig. 191.

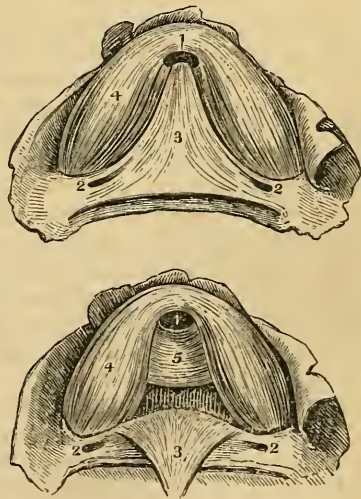


Fig. 191. Represents the neck of the bladder with the sphincter apparatus as described by Horner. 1, 1. Orifice of the neck of the bladder. 2, 2, 2. Orifices of the ureters. 3, 3. The triangular tissue, supposed to be muscular under the mucous membrane of the vesical triangle. 4, 4. Part of the *detrusor urinæ* muscle. 5. The elastic band which acts as a constant sphincter to the neck of the bladder.—G.

The *Mucous coat* is thin and smooth and exactly moulded upon the muscular coat, to which it is connected by a somewhat thick layer of submucous tissue, called by some anatomists, the nervous coat; its papillæ are very minute, and there is scarcely a trace of mucous follicles. This mucous membrane is continuous through the ureters with the lining membrane of the uriniferous ducts, and through the urethra with that of the prostatic ducts, tubuli seminiferi, and Cowper's glands.

Upon the internal surface of the base of the bladder is a triangular smooth plane of a paler colour than the rest of the mucous membrane; the trigonum vesicæ, or *trigone vesicale*. This is the most sensitive part of the bladder, and the pressure of calculi upon it gives rise to great suffering. It is bounded on each side by the raised ridge, corresponding with the muscles of the ureters, at each posterior angle by the openings of the ureters, and in front by a slight elevation of the mucous membrane at the entrance of the urethra, called the *uvula vesicæ*.

The external surface of the base of the bladder corresponding with the trigonum, is also triangular, and is separated from the rectum merely by a thin layer of fibrous membrane, the recto-vesical fascia. It is bounded behind by the recto-vesical fold of peritoneum; and on each side by the vas deferens, and vesicula seminalis, which converge almost to a point at the base of the prostate gland. It is through this space that the opening is made in the recto-vesical operation for puncture of the bladder.

PROSTATE GLAND.

The prostate gland (*πρόστυχium præponere*) is situated in front of the neck of the bladder behind the deep perineal fascia and upon the

sected, will be found to run in a semicircular form round the urethra. These fibres make a band of about half an inch in breadth, particularly strong on the lower part of the opening, and, having mounted a little above the orifice, on each side, they dispose of a portion of their fibres in the substance of the bladder. A smaller and somewhat weaker set of fibres will be seen to complete their course, surrounding the orifice on the upper part; to these sphincter fibres a bridle is joined, which comes from the union of the muscles of the ureters.

"After repeated observations on this point, I have come to the conclusion that Mr. Bell has indicated a real structure; but my own dissections have resulted as follows: The inferior semicircumference of the neck of the bladder is surrounded by a thick fasciculus of muscular fibre, half an inch wide, running in a transverse direction, and having its ends attached to the lateral lobes of the prostate gland, being above the third lobe of the latter. This fasciculus is perfectly distinct from the ordinary muscular fibre of the bladder, and resembles in its texture the musculo-fibrous coat of the arteries. The superior semicircumference is also surrounded by a thin layer of muscular fibres of an ordinary kind, forming a broad, thin band of a crescentic shape, the lower ends of which are insensibly lost in the adjacent muscular coat of the bladder by being spread out. And, lastly, beneath the mucous membrane of the vesical triangle there is a triangular muscle of the same size as the vesical triangle. Having elongated angles, the anterior angle may be traced to the posterior part of the caput gallinaginis, and the posterior angles to the orifices of the ureters and the adjacent part of the bladder. The texture of this muscle is also like that of the musculo-fibrous coat of the arteries. When a bladder is recent, this detail of structure is made out with difficulty: it requires to be previously hardened in spirits of wine. That a power exists in the neck of the bladder of retaining completely the urine, has been satisfactorily demonstrated to me in a case of fistula in perineo, which was presented to the notice of the late Dr. Physick and myself, a few years ago."

rectum, through which it may be distinctly felt. It surrounds the commencement of the urethra for a little more than an inch of its extent, and resembles a Spanish chestnut both in size and form; the base being directed backwards towards the neck of the bladder, the apex forwards, and the convex side towards the rectum. It is retained firmly in its position by the two superior and the two inferior tendons of the bladder, by the attachments of the pelvic fascia, and by a process of the internal layer of the deep perineal fascia, which forms a sheath around the membranous urethra, and is inserted into the apex of the gland. It consists of three lobes, two lateral and a middle lobe or isthmus; the lateral lobes are distinguished by an indentation upon the base of the gland, and by a slight furrow upon its upper and lower surface. The third lobe or isthmus is a small transverse band which passes between the two lateral lobes at the base of the organ. In structure the prostate gland is composed of ramified ducts, terminating in lobules of follicular pouches which are so closely compressed as to give to a thin section of the gland a cellular appearance beneath the microscope. It is pale in colour and hard in texture, splits easily in the course of its ducts, and is surrounded by a plexus of veins which are enclosed by the strong fibrous membrane with which it is invested. Its secretion is poured into the prostatic portion of the urethra by fifteen or twenty excretory ducts. The urethra in passing through the prostate lies one third nearer to its upper than to its lower surface.

VESICULÆ SEMINALES.

Upon the under surface of the base of the bladder, and converging towards the base of the prostate gland, are two lobulated and somewhat pyriform bodies, about two inches in length, the vesiculæ seminales. Their upper surface is in contact with the base of the bladder; the under side rests upon the rectum, separated only by the recto-vesical fascia; the larger extremities are directed backwards and outwards, and the smaller ends almost meet at the base of the prostate. They enclose between them a triangular space, which is bounded posteriorly by the recto-vesical fold of peritoneum, and which corresponds with the trigonum vesicæ on the interior of the bladder. Each vesicula is formed by the convolutions of a single tube, which gives off several irregular cæcal branches. It is

Fig. 192.

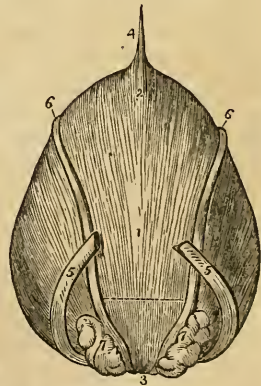


Fig. 192. The posterior aspect of the male bladder; the serous covering is removed in order to show the muscular coat. 1. The body of the bladder. 2. Its fundus. 3. Its inferior fundus or base. 4. The urachus. 5, 5. The ureters. 6, 6. The vas deferentia. 7, 7. The vesiculæ seminales. The triangular area, corresponding with the trigonum vesicæ, through which the bladder would be pierced in puncturing the bladder through the rectum. The dotted line forming the base of this triangular area, marks the extent of the recto-vesical fold of the peritoneum.

enclosed in a dense fibrous membrane, derived from the pelvic fascia, and is constricted beneath the isthmus of the prostate gland into a small excretory duct. The vas deferens, somewhat enlarged and convoluted, lies along the inner border of each vesicula, and is included in its fibrous investment. It communicates with the duct of the vesicula, beneath the isthmus of the prostate, and forms* the ejaculatory duct. The ejaculatory duct is about three quarters of an inch in length, and running forwards, first between the base of the prostate and the isthmus and then through the elastic tissue of the veru montanum, opens upon the mucous membrane of the urethra, near to its fellow of the opposite side, at the anterior extremity of that process.

MALE ORGANS OF GENERATION.

The organs of generation in the male are, the penis and the testes, with their appendages.

The *Penis* is divided into a body, root, and extremity. The *body* is surrounded by a thin integument, which is remarkable for the looseness of its cellular connexion with the deeper parts of the organ, and for containing no adipose tissue. The *root* is broad and firmly adherent to the rami of the os pubis and ischium by means of two strong processes, the crura, and is connected to the symphysis pubis by a fibrous membrane, the ligamentum suspensorium. The *extremity*, or *glans penis* resembles an obtuse cone, somewhat compressed from above downwards, and of a deeper red colour than the surrounding skin. At its apex is a small vertical slit, the meatus urinarius, which is bounded by two more or less protuberant labia; and, extending backwards from the meatus, is a depressed raphé, to which is attached a loose fold of mucous membrane, the frænum præputii. The base of the glans is marked by a projecting collar, the *corona glandis*, upon which are seen a number of small papillary elevations, formed by the aggregation of minute sebaceous glands, the glandulæ Tysoni (odoriferæ). Behind the corona is a deep fossa, bounded by a circular fold of integument, the *præputium*, which, in the quiescent state of the organ, may be drawn over the glans, but, in its distended state, is obliterated, and serves to facilitate its enlargement. The internal surface of the prepuce is lined by mucous membrane, covered by a thin cuticle; this membrane, upon reaching the base of the glans, is reflected over the glans penis, and, at the meatus urinarius, becomes continuous with the mucous lining of the urethra.

The penis is composed of the corpus cavernosum and corpus

* It has been customary hitherto, in works on anatomy, to describe the course of excretory ducts as proceeding from the gland, and passing thence to the point at which the secretion is poured out. In the description of the vas deferens, with its connexion with the duct of the vesicula seminalis, I have adopted this plan, that I might not too far depart from established habit. But as it is more correct and consistent with the present state of science to consider the gland as a development of the duct, I have pursued the latter principle in the description of most of the other glandular organs of the body.

spongiosum, and contains in its interior the longest portion of the urethra.

The *Corpus cavernosum* is distinguished into two lateral portions (corpora cavernosa), by an imperfect septum and by a superior and inferior groove, and is divided posteriorly into two crura. It is firmly adherent, by means of its crura, with the ramus of the os pubis and ischium. It forms, anteriorly, a single rounded extremity, which is received into a fossa in the base of the glans penis; the superior groove lodges the dorsal vessels of the organ, and the inferior receives the corpus spongiosum. Its fibrous tunic is thick, elastic, and extremely firm, and sends a number of fibrous bands and cords (trabeculæ) inwards from its inferior groove, which cross its interior in a radiating direction, and are inserted into the inner walls of the tunic. These trabeculæ are most abundant on the middle line, where they are ranged vertically, side by side, somewhat like the teeth of a comb, and constitute the imperfect partition of the corpus cavernosum, called the *septum pectiniforme*. This septum is more complete at its posterior than towards its anterior part.

The tunic of the corpus cavernosum consists of strong longitudinal fibrous fasciculi, closely interwoven with each other. Its internal structure is composed of erectile tissue.

The *Corpus spongiosum* is situated along the under surface of the corpus cavernosum, in its inferior groove. It commences by its posterior extremity between and beneath the crura penis, where it forms a considerable enlargement, the *bulb*, and terminates anteriorly by another expansion, the *glans penis*. Its middle portion, or body, is nearly cylindrical, and tapers gradually from its posterior towards its anterior extremity. The bulb is adherent to the deep perineal fascia by means of the tubular prolongation of the anterior layer, which surrounds the membranous portion of the urethra; in the rest of its extent the corpus spongiosum is attached to the corpus cavernosum by cellular tissue, and by veins which wind around that body to reach the dorsal vein. It is composed of erectile tissue, enclosed by a dense fibrous tissue, much thinner than that of the corpus cavernosum, and contains in its interior the spongy portion of the urethra, which lies nearer to its upper than to its lower wall.

Erectile tissue is a peculiar cellulo-vascular structure, entering in considerable proportion into the composition of the organs of generation. It consists essentially of a plexus of veins so closely convoluted and interwoven with each other, as to give rise to a cellular appearance when examined upon the surface of a section. The veins forming this plexus are smaller in the glans penis, corpus spongiosum, and circumference of the corpus cavernosum, than in the central part of the latter, where they are large and dilated. They have no other coat than the internal lining prolonged from the neighbouring veins; and the interstices of the plexus are occupied by a peculiar reddish fibrous substance. They receive their blood

from the capillaries of the arteries in the same manner with veins generally, and not by means of vessels having a peculiar form and distribution, as described by Müller. The helicine arteries of that physiologist have no existence.*

Vessels and Nerves.—The arteries of the penis are derived from the internal pudic; they are, the arteries of the bulb, arteries of the corpus cavernosum, and dorsalis penis. Its *veins* are superficial and deep. The deep veins run by the side of the deep arteries, and terminate in the internal pudic veins. The superficial veins emerge in considerable number from the base of the glans, and converge on the dorsum penis, to form a large dorsal vein, which receives other veins from the corpus cavernosum and spongiosum in its course, and passes backwards between two layers of the ligamentum suspensorium, and through the deep fascia beneath the arch of the os pubis, to terminate in the prostatic and vesical plexuses.

The *Lymphatics* terminate in the inguinal glands. The *nerves* are derived from the internal pudic nerve, from the sacral plexus, and, as shown by Professor Müller in his beautiful monograph, from the hypogastric plexus.

URETHRA.

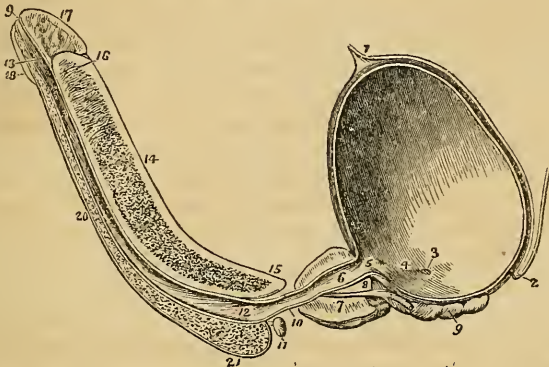
The urethra is the membranous canal extending from the neck of the bladder to the meatus urinarius. It is sigmoid in its course, and is composed of two layers, a mucous coat and an elastic fibrous coat. The mucous coat is thin and smooth; it is continuous, internally, with the mucous membrane of the bladder; externally, with the investing membrane of the glans; and, in certain points of its extent, with the lining membrane of the numerous ducts of mucous glands,—of those of Cowper's glands, the prostate gland, vasa deferentia, and vesiculæ seminales. The elastic fibrous coat varies in thickness in the different parts of the course of the urethra: it is thick in the prostate gland, forms a firm investment for the membranous portion of the canal, and is thin in the spongy portion, where it serves as a bond of connexion between the mucous membrane and the corpus spongiosum. The urethra is about nine inches in length, and is divided into a prostatic, membranous, and spongy portion.

The *Prostatic portion*, a little more than an inch in length, is situated in the prostate gland, about one-third nearer to its upper than to its lower surface, and extending from its base to its apex. Upon its lower circumference or floor is a longitudinal fold of mucous membrane—the *verumontanum*, or caput gallinaginis,—and on each side of the veru, a depressed fossa—the *prostatic sinus*—in which are seen the numerous openings of the prostatic ducts. At the anterior extremity of the verumontanum are the openings of the two ejaculatory ducts, and between them a third opening, which leads

* See my investigation upon this structure in the "Cyclopædia of Anatomy and Physiology." Article, "PENIS."

backwards into a small dilated sac—the sinus pocularis. The prostatic portion of the urethra, when distended, is the most dilated part of the canal; but, excepting during the passage of urine, is completely closed by means of a ring of elastic tissue which encircles the urethra as far as the anterior extremity of the verumontanum. In the contracted state of the urethra, the verumontanum acts as a valve, being pressed upwards against the upper wall of the canal;

Fig. 193.



but, during the action of the detrusor muscle of the bladder, the whole elastic ring is expanded by the muscular fibres which are inserted into it; and the veru is especially drawn downwards by two delicate tendons, which have been traced by Mr. Tyrrell, from the posterior fibres of the detrusor into the tissue of this process.

Fig. 193. A longitudinal section of the bladder, prostate gland, and penis, showing the urethra. 1. The urachus attached to the upper part of the fundus of the bladder. 2. The recto-vesical fold of peritoneum, at its point of reflection from the base of the bladder, upon the anterior surface of the rectum. 3. The opening of the right ureter. 4. A slight ridge, formed by the muscle of the ureter, and extending from the termination of the ureter to the commencement of the urethra. This ridge forms the lateral boundary of the trigonum vesicæ. 5. The commencement of the urethra; the elevation of mucous membrane immediately behind the figure is the uvula vesicæ. The constriction of the bladder at this point is the neck of the bladder. 6. The prostatic portion of the urethra. 7. The prostate gland; the difference of thickness of the gland, above and below the urethra, is shown. 8. The isthmus, or third lobe of the prostate; immediately beneath the ejaculatory duct is seen passing. 9. The right vesicula seminalis; the vas deferens is seen to be cut short off, close to its junction with the ejaculatory duct. 10. The membranous portion of the urethra. 11. Cowper's gland of the right side, with its duct. 12. The bulbous portion of the urethra; throughout the whole length of the urethra of the corpus spongiosum, numerous lacunæ are seen. 13. The fossa navicularis. 14. The corpus cavernosum, cut somewhat obliquely to the right side, near its lower part. The character of the venous cellular texture is well shown. 15. The right crus penis. 16. Near the upper part of the corpus cavernosum, the section has fallen a little to the left of the middle line; a portion of the septum pectiniforme is consequently seen. This figure also indicates the thickness of the fibrous investment of the corpus cavernosum, and its abrupt termination at the base of (17) the glans penis. 18. The lower segment of the glans. 19. The meatus urinarius. 20. The corpus spongiosum. 21. The bulb of the corpus spongiosum.

The discovery of this beautiful structure is due to our distinguished countryman, Sir Astley Cooper, and is one other instance of the marvellous indications of design evinced in the structure of the animal frame. Instead of a muscular apparatus, liable to fatigue, Nature has employed, for the purpose of retaining the urine, an elastic substance, which closes the urethra constantly by an unwearying physical property. Expulsion, on the contrary, occurring only at intervals, demands the exercise of muscular action, that action being immediately applied to the elastic agent and drawing it aside. It is by means of this interesting provision that the semen and the last drops of urine are expelled from the urethra without a chance of reflux into the bladder, and that the urine is enabled to pass freely along its canal without danger of entering the prostatic or ejaculatory ducts.

The *Membranous portion*, the narrowest part of the canal, is somewhat less than an inch in length. It is situated between the two layers of the deep perineal fascia, and is surrounded by the fan-like expansions of the upper and lower segments of the compressor urethræ muscle which meet at the *raphé* along its upper and lower surface. It is continuous posteriorly with the prostatic urethra, and anteriorly with the spongy portion of the canal. Its coverings are the mucous membrane, elastic fibrous layer, compressor urethræ muscle, and a partial sheath from the deep perineal fascia.

The *Spongy portion* forms the rest of the extent of the canal, and is lodged in the corpus spongiosum from its commencement at the deep perineal fascia to the meatus urinarius. It is narrowest in the body, and becomes dilated at either extremity, posteriorly in the bulb, where it is named the bulbous portion, and anteriorly in the glans penis, where it forms the fossa navicularis. The meatus urinarius is the most constricted part of the canal; so that a catheter, which will enter that opening, may be passed freely through the whole extent of a healthy urethra. Opening into the bulbous portion are two small excretory ducts about three quarters of an inch in length, which may be traced backwards, between the coats of the urethra and the bulb, to the interval between the two layers of the deep perineal fascia, where they ramify in two small lobulated and somewhat compressed glands of about the size of peas. These are Cowper's glands; they are situated immediately beneath the membranous portion of the urethra, and are enclosed by the lower segment of the compressor urethræ muscle so as to be subject to muscular compression. Upon the whole of the internal surface of the spongy portion of the urethra, particularly along its upper wall, are numerous small openings or lacunæ which are the entrances of mucous glands situated in the submucous cellular tissue. The openings of these lacunæ are directed forwards, and are liable occasionally to intercept the point of a small catheter in its passage into the bladder. At about an inch and a half from the opening of the meatus one of these lacunæ is generally found much larger than the

rest, and is named the *lacuna magna*. In a beautiful preparation of this lacuna, made by Sir Astley Cooper, the extremity of the canal presents several large primary ramifications.

TESTES.

The testes are two small glandular organs suspended from the abdomen by the spermatic cords, and enclosed in an external tegumentary covering, the scrotum.

The *Scrotum* is distinguished into two lateral halves or hemispheres by a *raphé*, which is continued anteriorly along the under surface of the penis, and posteriorly along the middle line of the perineum to the anus. Of these two lateral portions the left is somewhat longer than the right, and corresponds with the greater length of the spermatic cord on the left side.

The scrotum is composed of two layers, the integument and a proper covering, the dartos; the integument is extremely thin, transparent, and abundant, and beset by a number of hairs which issue obliquely from the skin, and have prominent roots. The dartos is a thin layer of a peculiar contractile fibrous tissue, intermediate in properties between muscular fibre and elastic tissue; it forms the proper tunic of the scrotum, and sends inwards a distinct septum (septum scroti) which divides it into two cavities for the two testes. The dartos is continuous around the base of the scrotum with the common superficial fascia of the abdomen and perineum.

The *Spermatic cord* is the medium of communication between the testes and the interior of the abdomen; it is composed of arteries, veins, lymphatics, nerves, the excretory duct of the testicle and its proper coverings. It commences at the internal abdominal ring, where the vessels of which it is composed converge, and passes obliquely along the spermatic canal; the cord then escapes at the external abdominal ring and descends through the scrotum to the posterior border of the testicle. The left cord is somewhat longer than the right, and permits the left testicle to reach a lower level than the right.

The *Arteries* of the spermatic cord are the spermatic artery from the aorta; the deferential artery, accompanying the vas deferens, from the superior vesical; and the cremasteric branch from the epigastric artery. The *spermatic veins* form a plexus which constitutes the chief bulk of the cord; they are provided with valves at short intervals, and the smaller veins have a peculiar tendril-like arrangement which has obtained for them the name of vasa pampiniformia. The *lymphatics* are of large size, and terminate in the lumbar glands. The *nerves* are the spermatic plexus, which is derived from the aortic and renal plexus, the genital branch of the genito-crural nerve, and the scrotal branch of the ilio-scrotal.

The *Vas deferens*, the excretory duct of the testicle, is situated along the posterior border of the cord, where it may be easily distinguished by the hard and cordy sensation which it communicates to the fingers. Its parietes are very thick and tough, and its canal

extremely small and lined by the mucous membrane continued from the urethra.

The *Coverings of the spermatic cord* are the spermatic fascia, cremaster muscle, and fascia propria. The spermatic fascia is a prolongation of the intercolumnar fascia, derived from the borders of the external abdominal ring during the descent of the testicle in the fœtus. The cremasteric covering (erythroid) is the thin muscular expansion formed by the spreading out of the fibres of the cremaster, which is likewise carried down by the testis during its descent. The fascia propria is a continuation of the infundibuliform process from the transversalis fascia which immediately invests the vessels of the cord, and is also obtained during the descent of the testis.

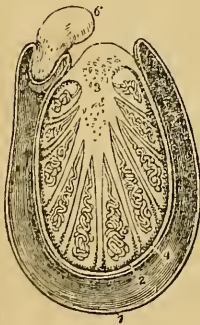
The *Testis* (testicle) is a small oblong and rounded gland, somewhat compressed upon the sides and behind, and suspended in the cavity of the scrotum by the spermatic cord.

Its position in the scrotum is oblique; so that the upper extremity is directed upwards and forwards, and a little outwards; the lower, downwards and backwards, and a little inwards; the convex surface looks forwards and downwards, and the flattened surface to which the cord is attached, backwards and upwards. Lying against its outer and posterior border is a flattened body which follows the course of the testicle, and extends from its upper to its lower extremity; this body is named, from its relation to the testis, *epididymis* (ἐπί upon, δίδυμος the testicle); it is divided into a central part or body, an upper extremity or globus major, and a lower extremity, globus minor (cauda) epididymis.

The globus major is situated upon the upper end of the testicle, to which it is closely adherent; the globus minor is placed at its lower end, is attached to the testis by cellular tissue, and curves upwards, to become continuous with the vas deferens. The testis is invested by three tunics—tunica vaginalis, tunica albuginea, and tunica vasculosa; and is connected to the inner surface of the dartos by a large quantity of extremely loose cellular tissue, in which fat is never deposited, but which is very susceptible of serous infiltration.

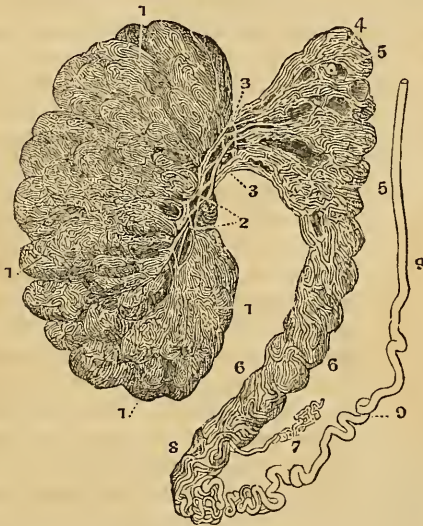
The *Tunica vaginalis* is a pouch of serous membrane derived

Fig. 194. A transverse section of the testicle. 1. The cavity of the tunica vaginalis; the most external layer is the tunica vaginalis reflexa; and that in contact with the organ, the tunica vaginalis propria. 2. The tunica albuginea. 3. The mediastinum testis, giving off numerous fibrous cords in a radiated direction to the internal surface of the tunica albuginea. The cut extremities of the vessels below the number belong to the rete testis; and those above to the arteries and veins of the organ. 4. The tunica vasculosa, or pia mater testis. 5. One of the lobules, consisting of the convolutions of the tubuli seminiferi, and terminating by a single duct—the vas rectum. Corresponding lobules are seen between the other fibrous cords of the mediastinum. 6. Section of the epididymis.



from the peritoneum in the descent of the testis, and afterwards obliterated from the abdomen to within a short distance of the gland. Like other serous coverings it is a shut sac, investing the organ and thence reflected so as to form a bag around its circumference; hence it is divided into the *tunica vaginalis propria*, and *tunica vaginalis reflexa*. The *tunica vaginalis propria* covers the surface of the *tunica albuginea*, and surrounds the epididymis, connecting it to the testis by means of a distinct duplicature. The *tunica vaginalis reflexa* is attached by its external surface, through the medium of a quantity of loose cellular tissue, to the inner surface of the *dartos*. Between the two layers is the smooth surface of the shut sac, moistened by its proper secretion.

Fig. 195.



The *Tunica albuginea* (*dura mater testis*) is a thick fibrous membrane of a bluish white colour, and the proper tunic of the testicle. It is adherent externally to the *tunica vaginalis propria*, and from the union of a serous with a fibrous membrane is considered a fibro-serous membrane, like the *dura mater* and *pericardium*. After surrounding the testicle, the *tunica albuginea* is reflected from its posterior border into the interior of the gland, and forms a projecting longitudinal ridge, which is called the *mediastinum testis* (*corpus Highmorianum**) from which numerous fibrous cords (*trabeculae*,

Fig. 195. Human testis injected with mercury. 1, 1. Lobules formed of seminiferous tubes. 2. Rete testis. 3. Vasa efferentia. 4. Plexuses of the efferent vessels passing into the head of the epididymis 5, 5. 6. Body of the epididymis. 7. Its appendix; its tail or cauda. 8. Vas deferens.—(Lauth.)

* Nathaniel Highmore, a physician of Oxford, in his "*Corporis Humani Disquisitio Anatomica*," published in 1651: he considers the *corpus Highmorianum* as a duct formed by the convergence of the fibrous cords, which he mistakes for smaller ducts.

septula) are given off, to be inserted into the inner surface of the tunic. The mediastinum serves to contain the vessels and ducts of the testicle in their passage into the substance of the organ, and the fibrous cords are admirably fitted, as has been shown by Sir Astley Cooper, to prevent compression of the gland. If a transverse section be made of the testis, and the surface of the mediastinum examined, it will be observed that the blood-vessels of the substance of the organ are situated near the posterior border of the mediastinum, while the divided ducts of the rete testis, occupy a place nearer to the free margin.

The *Tunica vasculosa* (pia mater testis) is the nutrient membrane of the testis; it is situated immediately within the tunica albuginea and encloses the substance of the gland, sending processes inwards between the lobules, in the same manner that the pia mater is reflected between the convolutions of the brain.

The substance of the testis consists of numerous conical flattened lobules (lobuli testis), the bases being directed towards the surface of the organ, and the apices towards the mediastinum. Krause found between four and five hundred of these lobules in a single testis. Each lobule is invested by a distinct sheath formed by two

layers, one being derived from the tunica vasculosa, the other from the tunica albuginea. The lobule is composed of one or several minute tubuli, *tubuli seminiferi*,* exceedingly convoluted, anastomosing frequently with each other near to their extremities, terminating in loops or in free cæcal ends, and of the same diameter ($\frac{1}{170}$ Lauth) throughout. The tubuli seminiferi are of a bright yellow colour; they become less convoluted in the apices of the lobules, and terminate by forming between twenty and thirty small straight ducts of about twice the diameter of the tubuli seminiferi,—the *vasa recta*. The vasa recta enter the substance of the mediastinum, and terminate in from seven to thirteen ducts, smaller in diameter than the vasa recta. These ducts pursue a waving course from below upwards through the fibrous tissue of the mediastinum; they communicate freely with each other, and constitute the *rete testis*. At the upper extremity of the

Fig. 196.

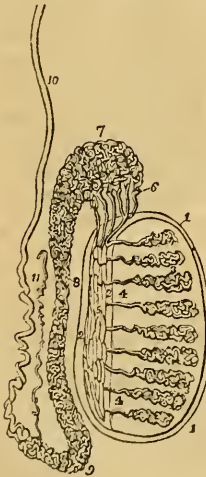


Fig. 196. Anatomy of the testis. 1, 1. The tunica albuginea. 2, 2. The mediastinum testis. 3, 3. The lobuli testis. 4, 4. The vasa recta. 5, 5. The rete testis. 6. The vasa efferentia, of which five only are represented in this diagram. 7. The coni vasculosi, constituting the globus major of the epididymis. 8. The body of the epididymis. 9. The globus minor of the epididymis. 10. The vas deferens. 11. The vasculum aberrans.

* Lauth estimates the whole number of tubuli seminiferi in each testis, at 840, and their average length at 2 feet 3 inches. According to this calculation, the whole length of the tubuli seminiferi would be 1890 feet.

mediastinum, the ducts of the rete testis terminate in from nine to thirty small ducts, the *vasa efferentia*,* which form by their convolutions a series of conical masses, the *coni vasculosi*; from the bases of these cones tubes of larger size proceed, which constitute by their complex convolutions the body of the epididymis. The tubes become gradually larger towards the lower end of the epididymis, and terminate in a single large and convoluted duct, the vas deferens.

The *Epididymis* is formed by the convolutions of the excretory seminal ducts, externally to the testis, previously to their termination in the vas deferens. The more numerous convolutions and the aggregation of the *coni vasculosi* at the upper end of the organ constitute the *globus major*; the continuation of the convolutions downwards is the body; and the smaller number of convolutions of the single tube at the lower extremity, the *globus minor*. The tubuli are connected together by a very delicate cellular tissue, and are enclosed by the *tunica vaginalis*.

A small convoluted duct, of variable length, is generally connected with the duct of the epididymis immediately before the commencement of the vas deferens. This is the *vasculum aberrans* of Haller; it is attached to the epididymis by the cellular tissue in which that body is enveloped. Sometimes it becomes dilated towards its extremity, but more frequently retains the same diameter throughout.

The *Vas deferens* may be traced upwards in the course of the seminal fluid, from the *globus minor* of the epididymis along the posterior part of the spermatic cord, and along the spermatic canal to the internal abdominal ring. From the ring it is reflected inwards to the side of the fundus of the bladder, and descends along its posterior surface, crossing the direction of the ureter, to the inner border of the *vesicula seminalis*. In this situation it becomes somewhat larger in size and convoluted, and terminates at the base of the prostate gland, by uniting with the duct of the *vesicula seminalis* and constituting the ejaculatory duct. The ejaculatory duct, which is thus formed by the junction of the duct of the *vesicula seminalis* with the vas deferens, passes forwards to the anterior extremity of the *verumontanum*, where it terminates by opening into the prostatic urethra.

FEMALE PELVIS.

The peculiarities of the form of the female pelvis have already been examined with the anatomy of the bones. Its lining boundaries are the same with those of the male. The contents are, the bladder, vagina, uterus with its appendages, and the rectum. Some portion of the small intestines also occupy the upper part of its cavity.

* Each vas deferens with its cone measures, according to Lauth, about 8 inches. The entire length of the tubes composing the epididymis, according to the same authority, is about 21 feet.

The *Bladder* is in relation with the os pubis in front, with the uterus behind, from which it is usually separated by a convolution of small intestine, and with the neck of the uterus, and with the vagina beneath. The form of the female bladder corresponds with that of the pelvis, being broad from side to side, and often bulging more on one side than on the other. This is particularly evident after frequent parturition. The *coats* of the bladder are the same as those of the male.

The *Urethra* is about an inch and a half in length, and is lodged in the upper wall of the vagina, in its course downwards and forwards, beneath the arch of the os pubis, to the meatus urinarius. It is lined by mucous membrane, which is disposed in longitudinal folds, and is continuous internally with that of the bladder, and externally with the vulva; the mucous membrane is surrounded by a proper coat of elastic tissue, to which the muscular fibres of the detrusor urinæ are attached. It is to this tissue that is due the remarkable dilatability of the female urethra, and its speedy return to its original diameter. The meatus is encircled by a ring of fibrous tissue, which prevents it from distending with the same facility as the rest of the canal; hence it is sometimes advantageous in performing this operation to divide its margin slightly with the knife.

Vagina.—The *Vagina* is a membranous canal, leading from the vulva to the uterus, and corresponding in direction with the axis of the outlet of the pelvis. It is constricted at its commencement, but near the uterus becomes considerably dilated; and is closed by the contact of the anterior with the posterior wall. Its length is very variable; but it is always longer upon the posterior than upon the anterior wall, the former being usually about five or six inches in length, and the latter four or five. It is inserted into the cervix of the uterus, which projects into the upper extremity of the canal.

In *Structure* the vagina is composed of a *mucous lining*, a layer of *erectile tissue*, and an external tunic of a *cellulo-fibrous* structure, resembling the dartos of the scrotum. The upper fourth of the posterior wall of the vagina is covered, on its pelvic surface, by the peritoneum; while in front the peritoneum is reflected from the upper part of the cervix of the uterus to the posterior surface of the bladder. On each side it gives attachment superiorly to the broad ligaments of the uterus; and inferiorly to the pelvic fascia, and to the levatores ani.

The *Mucous membrane* presents a number of *transverse papillæ* or *rugæ* upon its upper and lower surfaces, which extend outwards on each side from a middle *raphé*. The transverse papillæ and *raphé* are more apparent upon the upper than upon the lower surface, and the two *raphé* are called the *columns of the vagina*. The mucous membrane is covered by a thin cuticular epithelium, which is continued from the labia, and terminates by a fringed border at about the middle of the cervix uteri.

The *Middle* or *erectile layer* consists of erectile tissue enclosed

between two layers of fibrous membrane; this layer is thickest near the commencement of the vagina, and becomes gradually thinner as it approaches the uterus.

The *External*, or *dartoid layer* of the vagina, serves to connect it to the surrounding viscera. Thus, it is very closely adherent to the under surface of the bladder, and drags that organ down with it in prolapsus uteri. To the rectum it is less closely connected, and that intestine is therefore less frequently affected in prolapsus.

UTERUS.

The *Uterus* is a flattened organ of a pyriform shape, having the base directed upwards and forwards, and the apex downwards and backwards in the line of the axis of the inlet of the pelvis, and forming a considerable angle with the course of the vagina. It is

Fig. 197.

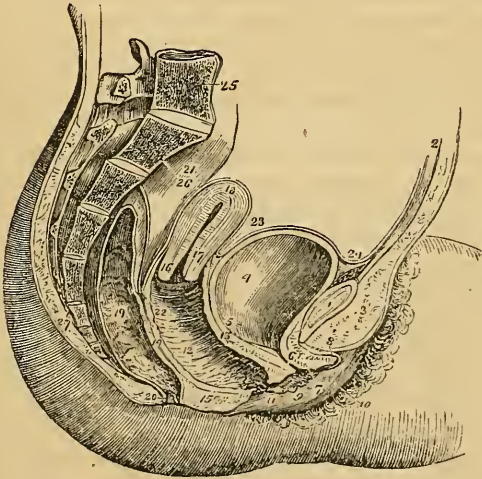


Fig. 197. A side view of the viscera of the female pelvis. 1. The symphysis pubis; to the upper part of which the tendon of the rectus muscle is attached. 2. The abdominal parietes. 3. The collection of fat, forming the projection of the mons Veneris. 4. The urinary bladder. 5. The entrance of the left ureter. 6. The canal of the urethra, converted into a mere fissure by the contraction of its walls. 7. The meatus urinarius. 8. The clitoris, with its præputium, divided through the middle. 9. The left nymphæ. 10. The left labium majus. 11. The meatus of the vagina, narrowed by the contraction of its sphincter. 12. The canal of the vagina, upon which the transverse rugæ are apparent. 13. The thick wall of separation between the base of the bladder and the vagina. 14. The wall of separation between the vagina and the rectum. 15. The perineum. 16. The os uteri. 17. Its cervix. 18. The fundus uteri. The *cavitas uteri* is seen along the centre of the organ. 19. The rectum, showing the disposition of its mucous membrane. 20. The anus. 21. The upper part of the rectum, invested by the peritoneum. 22. The recto-uterine fold of the peritoneum, just above the figure. 23. The utero-vesical fold. 24. The reflection of the peritoneum, from the apex of the bladder, upon the trachus to the internal surface of the abdominal parietes. 25. The last lumbar vertebra. 26. The sacrum. 27. The coccyx.

convex on its posterior surface, and somewhat flattened upon its anterior aspect. In the unimpregnated state it is about three inches in length, two in breadth across its broadest part, and one in thickness, and is divided into fundus, body, cervix, and os uteri. At the period of puberty the uterus weighs about one ounce and a half; after parturition from two to three ounces; and at the ninth month of utero-gestation from two to four pounds.

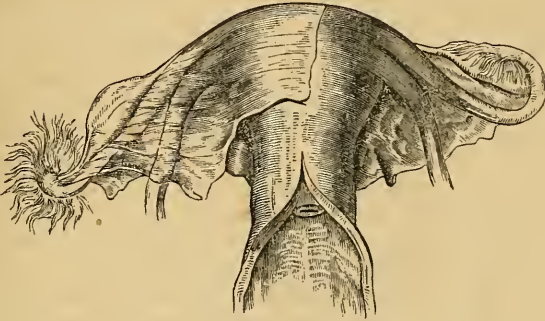
The *Fundus* and *body* are enclosed in a duplicature of peritoneum, which is connected with the two sides of the pelvis, and forms a transverse septum between the bladder and rectum. The folds formed by this duplicature of peritoneum on either side of the organ are the *broad ligaments* of the uterus. The *cervix* is the lower portion of the organ; it is distinguished from the body by a well-marked constriction; to its upper part is attached the upper extremity of the vagina, and at its extremity is an opening which is nearly round in the virgin, and transverse after parturition—the *os uteri*—bounded before and behind by two labia; the anterior labium being the most thick, and the posterior somewhat the longest. The opening of the os uteri is of considerable size, and is named the *orificium uteri externum*; the canal then becomes narrowed, and at the upper end of the cervix is constricted into a smaller opening—the *orificium internum*.* At this point the canal of the cervix expands into the shallow triangular cavity of the uterus, the inferior angle corresponding with the *orificium internum*, and the two superior angles, which are funnel-shaped and represent the original bicornute condition of the organ, with the commencement of the Fallopian tubes. In the canal of the cervix uteri are two or three longitudinal folds to which numerous oblique folds converge so as to give the idea of branches from the stem of a tree; hence this appearance has been denominated the *arbor vitæ uterina*. Between these folds, and around the os uteri, are numerous mucous follicles. It is the closure of the mouth of one of these follicles, and the subsequent distension of the follicle with its proper secretion, that occasions those vesicular appearances so often noticed within the mouth and cervix of the uterus, called the *ovula of Naboth*.

Structure.—The uterus is composed of three tunics; of an *external* or *serous coat* derived from the peritoneum, which constitutes the duplicatures on each side of the organ called the broad ligaments; of a *middle* or *muscular coat*, which gives thickness and bulk to the uterus; and of an *internal* or *mucous membrane*, which lines its interior, and is continuous on the one hand with the mucous lining of the Fallopian tubes, and on the other with that of the vagina. In the unimpregnated state the muscular coat is exceedingly condensed in texture, offers considerable resistance to section with the scalpel, and appears to be composed of white fibres inextricably interlaced and mingled with blood-vessels. In the impregnated uterus the

* The *orificium internum* is not unfrequently obliterated in old persons. Indeed this obliteration is so common, as to have induced Mayer to regard it as normal.

fibres are of large size and distinct, and are disposed in two layers, superficial and deep. The *superficial layer* consists of fibres which pursue a vertical direction, some being longitudinal and others oblique. The longitudinal fibres are found principally upon the

Fig. 198.



middle line, forming a thin plane upon the anterior and posterior face of the organ and upon its fundus. The oblique fibres occupy chiefly the sides and fundus. At

the angles of the uterus the fibres of the superficial layer are continued outwards upon the Fallopian tubes, and into the round ligaments and the ligaments of the ovaries. The *deep layer* consists of two hollow cones of circular fibres having their apex at the openings of the Fallopian tubes, and by their bases intermingling with each other on the body of the organ. These fibres are continuous with the deep muscular layer of the Fallopian tubes, and indicate the primitive formation of the uterus by the blending of these two canals. Around the cervix uteri the muscular fibres assume a circular form interlacing with and crossing each other at acute angles. The *mucous membrane* is provided with a columnar ciliated epithelium, which extends from the middle of the cervix uteri to the extremities of the Fallopian tubes.

Fig. 199.

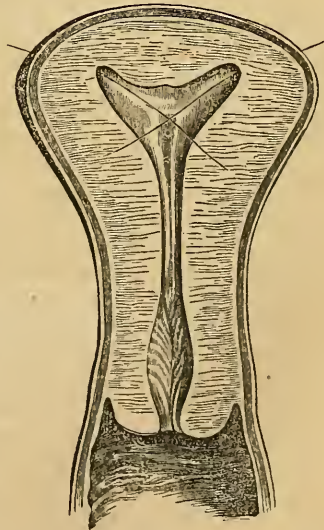


Fig. 198. Uterus. Round ligaments, Fallopian tubes, and peritoneal investment.

Fig. 199. Section of the uterus (transverse). The two bristles are introduced into the orifices of the Fallopian tubes.

Vessels and Nerves.—The *Arteries* of the uterus are the uterine from the internal iliac, and the spermatic from the aorta. The *veins* are very large and remarkable; in the impregnated uterus they are called sinuses, and consist of canals channeled through the substance of the organ, being merely lined by the internal membrane of the veins. They terminate on each side of the uterus in the uterine plexuses. The *lymphatics* terminate in the lumbar glands.

The *Nerves* are derived from the hypogastric and spermatic plexuses, and from the sacral plexus.

The *Appendages of the uterus* are enclosed by the lateral duplicatures of peritoneum, called the broad ligaments. They are the *Fallopian tubes* and *ovaries*.

FALLOPIAN TUBES.

The *Fallopian* tubes* or oviducts, the uterine trumpets of the French writers, are situated in the upper border of the broad ligaments, and are connected with the superior angles of the uterus. They are somewhat trumpet-shaped, being much smaller at the uterine than at the free extremity, and narrower in the middle than at either end. Each tube is about four or five inches in length, and more or less flexuous in its course. The canal of the Fallopian tube is exceedingly minute, its inner extremity opens by means of the *ostium uterinum* into the upper angle of the cavity of the uterus, and the opposite end into the cavity of the peritoneum. The free or expanded extremity of the Fallopian tube presents a double and sometimes a triple series of small processes or fringes which surround the margin of the trumpet or funnel-shaped opening, the *ostium abdominale*. This fringe-like appendage to the end of the tube has gained for it the appellation of the fimbriated extremity; and the remarkable manner in which this circular fringe applies itself to the surface of the ovary during sexual excitement, the additional title of *morsus diaboli*. One of these processes, longer than the rest, or, according to Cruveilhier, a distinct ligamentous cord, is attached to the distal end of the ovary, and serves to guide the tube in its seizure of that organ.

The Fallopian tube is composed of three tunics, an external and loose investment derived from the peritoneum; a middle or muscular coat consisting of circular [internal] and longitudinal [external] fibres, continuous with those of the uterus; and an internal or lining mucous membrane, which is continuous on the one hand with the mucous membrane of the uterus, and at the opposite extremity with the peritoneum. In the minute canal of the tube the mucous membrane is thrown into longitudinal folds or rugæ, which indicate the adaptation of the tube to dilatation.

* Gabriel Fallopius, a nobleman of Modena, was one of the founders of modern anatomy. He was Professor at Ferrara, then at Pisa, and afterwards succeeded Vesalius at Padua. His principal observations are collected in a work, "Observationes Anatomicæ," which he published in 1561.

OVARIES.

The *Ovaries* are two oblong flattened and oval bodies of a whitish colour, situated in the posterior layer of peritoneum of the broad ligaments. They are connected to the upper angles of the uterus at each side by means of a rounded cord, consisting chiefly of muscular fibres derived from the uterus,—the *ligament of the ovary*.

In *structure* the ovary is composed of a cellulo-fibrous parenchyma or stroma, traversed by blood-vessels, and enclosed in a capsule consisting of three layers; a vascular layer, which is situated most internally and sends processes inwards towards the interior of the organ; a middle or fibrous layer of considerable density, and an external investment of peritoneum. In the cells of the stroma of the ovary the small vesicles or ovisacs of the future ova, the Graafian vesicles, as they have been termed, are developed. There are usually about fifteen fully formed Graafian vesicles in each ovary; but Dr. Martin Barry has shown that countless numbers of microscopic ovisacs exist in the parenchyma of the organ, and that very few out of these are perfected so as to produce ova.

After conception a yellow spot, the *corpus luteum*, is found in one or both ovaries. The corpus luteum is a globular mass of yellow, spongy tissue, traversed by white cellular bands, and containing in its centre a small cavity, more or less obliterated, which was originally occupied by the ovum. The interior of the cavity is lined by a puckered membrane, the remains of the ovisac. In recent corpora lutea the opening by which the ovum escaped from the ovisac through the capsule of the ovary is distinctly visible; when closed, a small cicatrix may be seen upon the surface of the ovary in the situation of the opening. A similar appearance to the preceding, but of smaller size, and without a central cavity, is sometimes met with in the ovaries of the virgin,—this is a *false corpus luteum*.

Vessels and Nerves.—The *Arteries* of the ovaries are the spermatic. Its *nerves* are derived from the spermatic plexus.

The *Round ligaments* are two muscular and fibrous cords situated between the layers of the broad ligaments, and extending from the upper angles of the uterus, and along the spermatic canals to the labia majora, in which they are lost. They are accompanied by a small artery, by several filaments of the spermatic plexus of nerves, and by a plexus of veins. The latter occasionally become varicose, and form a small tumour at the external abdominal ring, which has been mistaken for inguinal hernia. The round ligaments serve to retain the uterus in its proper position in the pelvis, and during utero-gestation to draw the anterior surface of the organ against the abdominal parietes.

EXTERNAL ORGANS OF GENERATION.

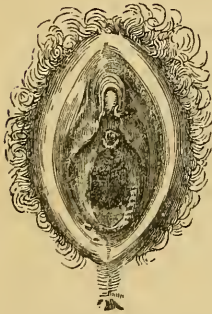The female organs of generation are divided into the internal and external; the internal are contained within the pelvis, and have been already described,—they are the vagina, uterus, ovaries, and Fallo-

pian tubes. The external organs are the mons Veneris, labia majora, labia minora, clitoris, meatus urinarius, and the opening of the vagina.

The *Mons Veneris* is the eminence of integument, situated upon the front of the os pubis. Its cellular tissue is loaded with adipose substance, and the surface covered with hairs:

The *Labia majora* are two large longitudinal folds of integument, consisting of fat and loose cellular tissue. They enclose an elliptical fissure, the common urino-sexual opening or *vulva*. The vulva receives the inferior opening of the urethra and vagina, and is bounded anteriorly by the commissura superior, and posteriorly by the commissura inferior. Stretching across the posterior commissure is a small transverse fold, the *frænulum labiorum* or fourchette, which is ruptured during parturition, and immediately within this fold is a

Fig. 200.



small cavity, the *fossa navicularis*. The breadth of the perineum, is measured from the posterior commissure to the margin of the anus, and is usually not more than an inch across. The external surface of the labia is covered with hairs; the inner surface is smooth, and lined by mucous membrane, which contains a number of sebaceous follicles, and is covered by a thin cuticular epithelium. The use of the labia majora is to favour the extension of the vulva during parturition; for in the passage of the head of the fœtus the labia are completely unfolded and effaced.

The *Labia minora*, or *nymphæ* are two smaller folds situated within the labia majora. Superiorly they are divided into two processes, which surround the glans clitoridis, the superior fold forming the præputium clitoridis, and the inferior its frænulum. Inferiorly, they diminish gradually in size, and are lost on the sides of the opening of the vagina. The nymphæ consist of mucous membrane, covered by a thin cuticular epithelium. They are provided with a number of sebaceous follicles, and contain, in their interior, a layer of erectile tissue.

The *Clitoris* is a small elongated organ situated in front of the os pubis, and supported by a suspensory ligament. It is formed by a small body, which is analogous to the corpus cavernosum of the penis, and, like it, arises from the ramus of the os pubis and ischium on each side, by two *crura*. The extremity of the clitoris is called its *glans*. It is composed of erectile tissue, enclosed in a dense layer of fibrous membrane, and is susceptible of erection. Like the penis, it is provided with two small muscles, the *erectores clitoridis*.

At about an inch beneath the clitoris is the *entrance of the vagina*, an elliptical opening, marked by a projecting margin. The entrance to the vagina is closed in the virgin by a membrane of a semilunar form, which is stretched across the opening; this is the *hymen*.

Sometimes the membrane forms a complete septum, and gives rise to great inconvenience by preventing the escape of the menstrual effusion. It is then called an *imperforate hymen*. The *hymen* must not be considered a necessary accompaniment to virginity, for its existence is very uncertain. When present it assumes a variety of appearances: it may be a membraneous fringe, with a round opening in the centre, or a semilunar fold, leaving an opening in front; or a transverse septum, having an opening both in front and behind; or a vertical band with an opening at either side.

The rupture of the hymen or its rudimentary existence, gives rise to the appearance of a fringe of papillæ around the opening of the vagina: these are called *carunculæ myrtiformes*.

The triangular smooth surface between the clitoris and the entrance of the vagina, which is bounded on each side by the upper portions of the nymphæ, is the *vestibule*.

At the upper angle of the vagina is an elevation formed by the projection of the upper wall of the canal, and analogous to the bulb of the urethra of the male: and immediately in front of this tubercle, and surrounded by it, is the opening of the urethra, the *meatus urinarius*.

MAMMARY GLANDS.

The *Mammæ* are situated in the pectoral region; and are separated from the pectoralis major muscle by a thin layer of superficial fascia. They exist in the male as well as in the female, but in a rudimentary state, unless excited into growth by some peculiar action, such as the loss or atrophy of the testes.

Their base is somewhat elliptical, the long diameter corresponding with the direction of the fibres of the pectoralis major muscle. The left mamma is generally a little larger than the right.

Near the centre of the convexity of each mamma is a small projection of the integument, called the *nipple*, which is surrounded by an areola having a coloured tint. In the female before impregnation, the colour of the areola is a delicate pink; after impregnation it assumes a brownish hue which deepens in colour as pregnancy advances; and after the birth of a child, the brownish tint continues through life.

The areola is furnished with a considerable number of *sebaceous follicles*, which secrete a peculiar fatty substance for the protection of the delicate integument around the nipple. During suckling these follicles are very much increased in size, and have the appearance of small pimples projecting from the skin. At this period they serve by their increased secretion to defend the nipple and areola from the excoriating action of the saliva of the infant.

In *Structure*, the mamma is a conglomerate gland, and consists of lobes, which are held together by a dense and firm cellular tissue; the lobes are composed of lobules; and the lobules, of minute cæcal vesicles, the ultimate terminations of the excretory ducts.

The excretory ducts (tubuli lactiferi), from ten to fifteen in

number, commence by small openings at the apex of the nipple, and pass inwards, parallel with each other, towards the central part of the gland, where they form dilatations (ampullæ) and give off numerous branches to ramify through the gland to their ultimate terminations in the minute lobules.

The ducts and cæcal vesicles are lined throughout by a mucous membrane, which is continuous at the apex of the nipple with the integument.

In the nipple the excretory ducts are surrounded by a tissue analogous to the dartos of the scrotum, to which the power of erectility of the nipple seems due. There is no appearance of any structure resembling erectile tissue.

Vessels and Nerves.—The mammæ are supplied with *arteries* from the thoracic branches of the axillary, from the intercostals, and from the internal mammary.

The *Lymphatics* follow the border of the pectoralis major to the axillary glands.

The *Nerves* are derived from the thoracic and intercostals.

CHAPTER XI.

ANATOMY OF THE FŒTUS.

THE medium weight of a child of the full period, at birth, is seven pounds; and its length nineteen inches. The head is of large size, and lengthened from before backwards; the face small. The upper extremities are greatly developed, and the thorax expanded and full. The upper part of the abdomen is large, from the great size of the liver; the lower part is small and conical. And the lower extremities are very small in proportion to the rest of the body. The external genital organs are very large, and fully developed.

OSSEOUS SYSTEM.—The development of the osseous system has been treated of in the first chapter. The ligamentous system presents no peculiarity deserving of remark.

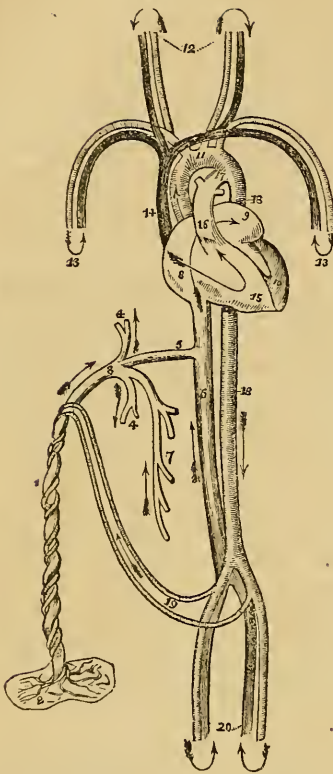
MUSCULAR SYSTEM.—The muscles of the fœtus at birth are large and fully formed. They are of a lighter colour than those of the adult, and of a softer texture. The transverse striæ upon the fibres of animal life are not distinguishable until the sixth month of fœtal life.

VASCULAR SYSTEM.—The circulating system presents several peculiarities; 1stly, In the heart; there is a communication between the two auricles by means of the *foramen ovale*. 2dly, In the arterial system; there is a communication between the pulmonary artery and descending aorta, by means of a large trunk—the *ductus arteriosus*. 3dly, Also in the arterial system; the internal iliac arteries, under the name of hypogastric and *umbilical*, are continued from the fœtus to the placenta, to which they return the blood which has circulated in the system of the fœtus. 4thly, In the venous system; there is a communication between the umbilical vein and the inferior cava, called the *ductus venosus*.

FŒTAL CIRCULATION.

The pure blood is brought from the placenta by the *umbilical vein*. The umbilical vein passes through the umbilicus and enters the liver, where it divides into several branches, which may be arranged under three heads:—1stly, two or three of which are distributed to the left lobe. 2dly, A single branch which communicates with the portal vein in the transverse fissure, and supplies the right lobe. 3dly, A large branch, the *ductus venosus*, which passes

Fig. 201.



directly backwards and joins the inferior cava. In the inferior cava the pure blood becomes mixed with that which is returning from the lower extremities, and is carried through the right auricle, guided by the Eustachian valve, and through the *foramen ovale* into the left auricle. From the left auricle it passes into the left ventricle, and from the left ventricle into the aorta, whence it is distributed, by means of the carotid and subclavian arteries, principally to the head and upper extremities. From the head and upper extremities, the impure blood is returned by the superior vena cava to the right auricle. From the right auricle, it is propelled into the right ventricle; and from the right ventricle into the pulmonary artery. In the adult, the blood would now be circulated through the lungs, and oxygenated; but in the fœtus the lungs are solid, and almost imperious. Only a small quantity of the blood passes therefore into the lungs; the greater part rushes through the *ductus arteriosus*, into the commencement of the descending aorta.

Fig. 201. The fœtal circulation. 1. The umbilical cord, consisting of the umbilical vein and two umbilical arteries; proceeding from the placenta (2). 3. The umbilical vein dividing into three branches; two (4, 4) to be distributed to the liver; and one (5), the ductus venosus, which enters the inferior vena cava (6). 7. The portal vein returning the blood from the intestines, and uniting with the right hepatic branch. 8. The right auricle; the course of the blood is denoted by the arrow, proceeding from 8 to 9, the left auricle. 10. The left ventricle; the blood following the arrow to the arch of the aorta (11), to be distributed through the branches given off by the arch to the head and upper extremities. The arrows 12 and 13, represent the return of the blood from the head and upper extremities through the jugular and subclavian veins, to the superior vena cava (14), to the right auricle (8), and in the course of the arrow through the right ventricle (15), to the pulmonary artery (16). 17. The ductus arteriosus, which appears to be a proper continuation of the pulmonary artery, the offsets at each side are the right and left pulmonary artery cut off; these are of extremely small size as compared with the ductus arteriosus. The ductus arteriosus joins the descending aorta (18, 18), which divides into the common iliacs, and these into the internal iliacs, which become the umbilical arteries (19), and return the blood along the umbilical cord to the placenta; while the other divisions, the external iliacs (20), are continued into the lower extremities. The arrows at the termination of these vessels mark the return of the venous blood by the veins to the inferior cava.

Passing along the aorta, a small quantity of the impure blood is distributed by the external iliac arteries to the lower extremities; the greater portion enters the internal iliacs, and is carried onwards by the side of the bladder, and upwards along the anterior wall of the abdomen, and through the umbilicus, under the name of *umbilical arteries*, to the placenta, to which they return the blood that has been circulated through the system of the fœtus.

From a careful consideration of this circulation, we shall perceive—1st. That the pure blood from the placenta is distributed in considerable quantity to the liver, before entering the general circulation. Hence arises the abundant nutrition of that organ, and its enormous size in comparison with the other viscera.

2dly. That the right auricle is the scene of meeting of a double current; the one coming from the inferior cava, the other from the superior, and that they must cross each other in their respective course. How this crossing is effected the theorist will wonder; not so the practical anatomist; for a cursory examination of the fœtal heart will show, 1. That the direction of entrance of the two vessels is so opposite, that they may discharge their currents through the same cavity without admixture. 2. That the inferior cava opens almost directly into the left auricle. 3. That by the aid of the Eustachian valve, the current in the inferior cava will be almost entirely excluded from the right ventricle.

3dly. That the blood which circulates through the arch of the aorta comes directly from the placenta; and, although mixed with impure blood of the inferior cava, yet is propelled in so great abundance to the head and upper extremities, as to provide for the increased nutrition of those important parts, and prepare them, by their greater size and development, for the functions which they are required to perform at the instant of birth.

4thly. That the blood circulating in the descending aorta is very impure, being obtained principally from the returning current in the superior cava; a small quantity only being derived from the left ventricle. Yet is it from this impure blood that the nutrition of the lower extremities is provided. Hence we are not surprised at their insignificant development at birth, while we admire the providence of nature, that directs the nutrient current in abundance to the organs of sense, of prehension, and of deglutition, so necessary even at the instant of birth to the safety and welfare of the creature.

After birth, the *foramen ovale* becomes gradually closed by a membranous layer, which is developed from the margins of the opening from below upwards, and completely separates the two auricles. The situation of the foramen is seen in the adult heart, upon the septum auriculorum, and is called the *fossa ovalis*; the projecting margin of the opening forms the *annulus ovalis*.

As soon as the lungs have become inflated by the first spasmodic act of inspiration, the blood of the pulmonary artery rushes through its right and left branches into the lungs, to be returned to the left

auricle by the pulmonary veins. Thus the pulmonary circulation is established. Then the *ductus arteriosus* contracts, and degenerates into an impervious fibrous cord, serving in after life merely as a bond of union between the left pulmonary artery and the concavity of the arch of the aorta.

The current through the umbilical cord being arrested, the *umbilical arteries* likewise contract and become impervious, and degenerate into the *umbilical ligaments* of the bladder.

The *Umbilical vein* and *ductus venosus*, also deprived of their circulating current, become reduced to fibrous cords, the former forming the *round ligament* of the liver, and the latter a fibrous band which may be traced along the fissure for the ductus venosus to the inferior vena cava.

NERVOUS SYSTEM.—The brain is very soft, almost pulpy, and has a reddish tint throughout: the difference between the white and gray substance is not well marked. The nerves are firm and well developed.

ORGANS OF SENSE.

Eye.—The eyeballs are of large size and well developed at birth. The pupil is closed by a vascular membrane called the *membrana pupillaris*, which disappears at about the seventh month. Sometimes it remains permanently, and produces blindness. It consists of two thin membranous layers, between which the ciliary arteries are prolonged from the edge of the iris, and form arches by returning to it again, without anastomosing with those of the opposite side.

The removal of the membrane takes place by the contraction of their loops towards the edge of the pupil. The capsule of the lens is extremely vascular.

Ear.—The ear is remarkable for its early development; the labyrinth and ossicula auditus are ossified at an early period, and the latter are completely formed before birth. The only parts remaining incomplete are the mastoid cells, and the meatus auditorius. The *membrana tympani* in the foetal head is very oblique, occupying almost the basilar surface of the skull; hence probably arises a deficient acuteness in the perception of sound. It is also extremely vascular.

Nose.—The sense of smell is very imperfect in the infant, as may be inferred from the small capacity of the nasal fossæ, and the non-development of the ethmoid, sphenoid, frontal, and maxillary sinuses.

THYROID GLAND.

The *Thyroid gland* is of a large size in the foetus, and is developed by two lateral halves, which approach and become connected at the middle line so as to constitute a single gland. It is doubtful whether it performs any especial function in foetal life.

THYMUS GLAND.

The *Thymus gland** consists "of a thoracic and a cervical portion on each side. The former is situated in the anterior mediastinum, and the latter is placed in the neck just above the first bone of the sternum, and behind the sterno-hyoidci and sterno-thyroidei muscles." It extends upwards from the fourth rib as high as the thyroid gland, resting upon the pericardium, and separated from the arch of the aorta and great vessels by the thoracic fascia in the chest, and lying on each side of the trachea in the neck.

Although described usually as a single gland, it consists actually of two lateral, almost symmetrical glands, connected with each other by cellular tissue only, and having no structural communication; they may therefore be "properly called a right and left thymus gland."

Between the second and third months of embryo existence, the thymus is so small as to be only "just perceptible;" and continues gradually increasing with the growth of the fœtus until the seventh. At the eighth month it is large; but, during the ninth, it undergoes a sudden change, assumes a greatly increased size, and at birth weighs 240 grains.

After birth it continues to enlarge until the expiration of the first year, when it ceases to grow, and gradually diminishes, until at puberty it has almost disappeared.

The thymus is a conglomerate gland, being composed of lobules disposed in a spiral form round a central cavity. The lobules are held together by a firm cellular tissue ("reticulated,") and the entire gland is enclosed in a coarse cellular capsule.

The *Lobules* are very numerous, and vary in size from that of the head of a pin to a moderate-sized pea. Each lobule contains in its interior a small cavity, or "*secretory cell*," and several of these

Fig. 202.

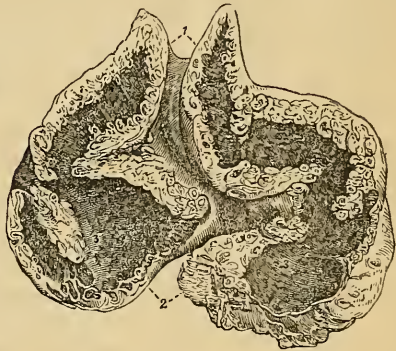

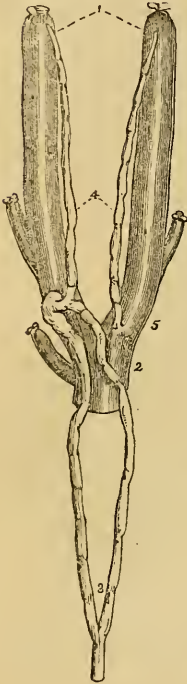
Fig. 202. A section of the thymus gland at the eighth month, showing its anatomy. This figure, and the succeeding, were drawn from two of Sir Astley Cooper's beautiful preparations, with the kind permission of their possessor. The references were made by Sir Astley's own hand. 1. The cervical portions of the gland; the independence of the two lateral glands is well marked. 2. Secretory cells seen upon the cut surface of the section; these are observed in all parts of the section. 3, 3. The pores or openings of the secretory cells and pouches, they are seen covering the whole internal surface of the great central cavity or reservoir. The continuity of the reservoir in the lower or thoracic portion of the gland, with the cervical portion, is seen in the figure.

* In the description of this gland I have adhered closely to the history of it given by our great authority on this subject, Sir Astley Cooper, in his beautiful monograph "On the Anatomy of the Thymus Gland," 1832.

cells open into a small “*pouch*” which is situated at their base, and leads to the central cavity, the “*reservoir of the thymus.*”

The *Reservoir* is lined in its interior by a vascular mucous membrane, which is raised into ridges by a layer of ligamentous bands situated beneath it. The ligamentous bands proceed in various directions, and encircle the open mouths (*pores*) of the secretory cells and pouches. This ligamentous layer serves to keep the lobules together, and prevent the injurious distension of the cavity.

Fig. 203.



When either gland is carefully unravelled by removing the cellular capsule and vessels, and dissecting away the reticulated cellular tissue, which retains the lobules in contact, the reservoir, from being folded in a serpentine manner upon itself, admits of being drawn out into a lengthened tubular *cord*,* around which the lobules are clustered in a spiral manner, and resemble knots upon a cord, or a string of beads.

The reservoir, pouches, and cells, contain a white fluid “like chyle,” or “like cream, but with a small admixture of red globules.”

In an examination of the thymic fluid which I lately made, with a Powell microscope magnifying 500 times linear measure, I observed that the corpuscles were very numerous, smaller than the blood corpuscles, globular and oval in form, irregular in outline, variable in size, and provided with a small central nucleus.

In the human fœtus this fluid has been found by Sir Astley in too small a proportion to be submitted to chemical analysis. But the thymic fluid of the fœtal calf, which exists in great abundance, gave the following analytical results:—one hundred parts of the fluid contained sixteen parts of solid matter, which consisted of,

Incipient fibrine,
Albumen,
Mucus, and muco-extractive matter,
Muriate and phosphate of potass,
Phosphate of soda,
Phosphoric acid, a trace.†

Fig. 203. The course and termination of the “absorbent ducts” of the thymus of the calf; from one of Sir Astley Cooper’s preparations. 1. The two internal jugular veins. 2. The superior vena cava. 3. The thoracic duct, dividing into two branches, which reunite previously to their termination in the root of the left jugular vein. 4. The two thymic ducts; that on the left side opens into the thoracic duct, and that on the right into the root of the right jugular vein.

* See the beautiful plates in Sir Astley Cooper’s work.

† This analysis was conducted by Dr. Dowler of Richmond.

The *Arteries* of the thymus gland are derived from the internal mammary, and from the superior and inferior thyroid.

The *Veins* terminate in the left vena innominata, and some small branches in the thyroid veins.

The *Nerves* are very minute, and are derived chiefly through the internal mammary plexus, from the superior thoracic ganglion of the sympathetic. Sir Astley Cooper has also seen a branch from the junction of the pneumogastric and sympathetic pass to the side of the gland.

The *Lymphatics* terminate in the general union of the lymphatic vessels at the junction of the internal jugular and subclavian veins. Sir Astley Cooper has injected them only once in the human fœtus, but in the calf he finds two large lymphatic ducts, which commence in the upper extremities of the glands, and pass downwards, to terminate at the junction of the jugular and subclavian vein at each side. These vessels he considers the "*absorbent ducts* of the glands; '*thymic ducts*;' they are the carriers of the fluid from the thymus into the veins."

Sir Astley Cooper concludes his anatomical description of this gland with the following interesting physiological observations:

"As the thymus secretes all the parts of the blood, viz. albumen, fibrine, and particles, is it not probable that the gland is designed to prepare a fluid well fitted for the fœtal growth and nourishment from the blood of the mother, before the birth of the fœtus, and, consequently, before chyle is formed from food?—and this process continues for a short time after birth, the quantity of fluid secreted from the thymus gradually declining as that of chylication becomes perfectly established."

FŒTAL LUNGS.

The *Lungs* previously to the act of inspiration, are dense and solid in structure, and of a deep red colour; their specific gravity greater than water, in which they sink to the bottom, whereas lung which has respired will float upon that fluid. The specific gravity is, however, no test of the real weight of the lung; the respired lung being actually heavier than the fœtal. Thus the weight of the fœtal lung, at about the middle period of uterine life, is to the weight of the body as 1 to 60.* But, after respiration, the relative weight of the lung to the entire body as 1 to 30.

FŒTAL HEART.

The *Heart* of the fœtus is large in proportion to the size of the body; it is also developed very early, representing at first a simple vessel, and undergoing various degrees of complication until it arrives at the compound character which it presents after birth. The two ventricles form, at one period, a single cavity, which is afterwards divided into two by the septum ventriculorum. The two

* Cruveilhier, Anatomie Descriptive, vol. ii. p. 621.

auricles communicate up to the moment of birth, the septum being incomplete, and leaving a large opening between them, the *foramen ovale* (foramen of Botal.)*

The *Ductus arteriosus* is another peculiarity of the fœtus connected with the heart; it is a communication between the pulmonary artery and the aorta. It degenerates into a fibrous cord after birth, from the double cause of a diversion in the current of the blood towards the lungs, and from the pressure of the left bronchus, caused by its distension with air.

VISCERA OF THE ABDOMEN.

At an early period of uterine life, and sometimes at the period of birth, as I have twice observed, in the imperfectly developed fœtus two minute fibrous threads may be seen, passing from the umbilicus to the mesentery. These are the remains of the omphalo-mesenteric vessels.

The *Omphalo-mesenteric* are the first developed vessels of the germ: they ramify upon the vesicula umbilicalis, or yolk-bag, and supply the newly formed alimentary canal of the embryo. From them, as from a centre, the general circulating system is produced. After the establishment of the placental circulation they cease to carry blood, and dwindle to the size of mere threads, which may be easily demonstrated in the early periods of uterine life; but are completely removed, except under peculiar circumstances, at a later period.

The *Stomach* is of small size, and the great extremity but little developed. It is also more vertical in direction the earlier it may be examined, a position that would seem due to the enormous magnitude of the liver, and particularly of its left lobe.

The *Appendix vermiformis cæci* is long and of large size, and is continued directly from the central part of the cul-de-sac of the cæcum, of which it appears to be a constricted continuation. This is the character of the appendix cæci in the higher quadrumana.

The large intestines are filled with a dark green viscous secretion called *meconium* (μῆκων, poppy), from its resemblance to the inspissated juice of the poppy.

The *Pancreas* is comparatively larger in the fœtus than in the adult.

The *Spleen* is comparatively smaller in the fœtus than in the adult.

FŒTAL LIVER.

The *Liver* is the first formed organ in the embryo. It is developed from the alimentary canal, and, at about the third week, fills the whole abdomen, and is one half the weight of the entire embryo.

* Leonard Botal, of Piedmont, was the first of the moderns who gave an account of this opening, in a work published in 1565. His description is very imperfect. The foramen was well known to Galen.

At the fourth month the liver is of immense size in proportion to the bulk of the fœtus. At birth it is of very large size and occupies the whole upper part of the abdomen. The left lobe is as large as the right, and the falciform ligament corresponds with the middle line of the body. The liver diminishes rapidly after birth, probably from the obliteration of the umbilical vein,

KIDNEYS AND SUPRA-RENAL CAPSULES.

The *Kidneys* present a lobulated appearance in the fœtus, which is the permanent type amongst some animals, as in the bear, the otter, and cetacea.

The *Supra-renal capsules* are organs which appear, from their early and considerable development, to belong especially to the economy of the fœtus. They are distinctly formed at the second month of embryonic life, and are greater in size and weight than the kidneys. At the fourth month they are equalled in bulk by the kidneys, and at birth they are about one-third less than those organs.

VISCERA OF THE PELVIS.

The *Bladder* in the fœtus is long and conical, and is situated altogether above the upper border of the os pubis, which is as yet small and undeveloped. It is, indeed, an abdominal viscus, and is connected superiorly with a fibrous cord, called the *urachus*, of which it appears to be an expansion.

The *Urachus* is continued upwards to the umbilicus, and becomes connected with the umbilical cord. In animals it is a pervious duct, and is continuous with one of the membranes of the embryo—the *allantois*. It has been found pervious in the human fœtus, and the urine has been passed through the umbilicus. Calculous concretions have also been found in its course.

The *Uterus*, in the early periods of embryonic existence, appears to be bifid, from the large size of the Fallopian tubes, and the small development of the body of the organ. At the end of the fourth month the body assumes a larger bulk, and the bifid appearance is lost. The cervix uteri in the fœtus is larger than the body of the organ.

The *Ovaries* are situated, like the testicles, in the lumbar region, near to the kidneys, and descend from thence gradually into the pelvis.

TESTES.

The *Testicles* in the embryo are situated in the lumbar regions, immediately in front of and somewhat below the kidneys. They have connected with them inferiorly a peculiar structure which assists in their descent, and is called the gubernaculum testis.

The *Gubernaculum* is a soft and conical cord composed of cellular tissue containing in its cells a gelatiniform fluid. In the abdomen it lies in front of the psoas muscle, and passes along the spermatic

canal which it serves to distend for the passage of the testis. It is attached by its superior and larger extremity to the lower end of the testis and epididymis, and by the inferior extremity to the bottom of the scrotum. The gubernaculum is surrounded by a thin layer of muscular fibres, the cremaster, which pass upwards upon this body to be attached to the testis. Inferiorly the muscular fibres divide into three processes which, according to Mr. Curling,* are thus attached:—"The external and broadest is connected to Poupart's ligament in the inguinal canal; the middle forms a lengthened band, which escapes at the external abdominal ring, and descends to the bottom of the scrotum, where it joins the dartos; the internal passes in the direction inwards, and has a firm attachment to the os pubis and sheath of the rectus muscle. Besides these a number of muscular fibres are reflected from the internal oblique on the front of the gubernaculum."

Fig. 204.

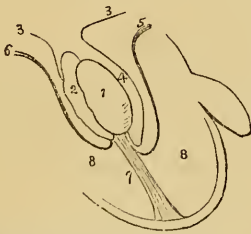
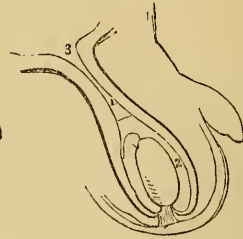


Fig. 205.



The *Descent of the testicle* is very gradual and progressive. Between the fifth and sixth month it has reached the lower part of the psoas muscle, and during the seventh it makes its way through the spermatic canal, and descends into the scrotum.

While situated in the lumbar region, the testis and gubernaculum are placed behind the peritoneum, by which they are invested upon their anterior surface and sides. As they descend, the investing peritoneum is carried downwards with the testis into the scrotum, forming a lengthened pouch which by its upper extremity opens

Fig. 204. A diagram illustrating the descent of the testis. 1. The testis. 2. The epididymis. 3, 3. The peritoneum. 4. The pouch formed around the testis by the peritoneum. 5. The pubic portion of the cremaster attached to the lower part of the testis. 6. The portion of the cremaster attached to Poupart's ligament. The mode of eversion of the cremaster is shown by these lines. 7. The gubernaculum, attached to the bottom of the scrotum, and becoming shortened by the contraction of the muscular fibres which surround it. 8, 8. The cavity of the scrotum. 9. The peritoneal cavity.

Fig. 205. In this figure the testis has completed its descent. The gubernaculum is shortened to its utmost, and the cremaster is completely everted. The pouch of peritoneum above the testis is compressed so as to form a tubular canal. 1. A dotted line marks the point at which the tunica vaginalis will terminate superiorly; and the figure 2 its cavity. 3. The peritoneal cavity.

* See an excellent paper "On the Structure of the Gubernaculum," &c. by Mr. Curling, Lecturer on Morbid Anatomy in the London Hospital, in the *Lancet*, vol. ii. 1840-41, p. 70.

into the cavity of the peritoneum. The upper part of this pouch being compressed by the spermatic canal is gradually obliterated, the obliteration extending downwards along the spermatic cord nearly to the testis. That portion of the peritoneum which immediately surrounds the testis is, by the above process, cut off from its continuity with the peritoneum, and is termed the tunica vaginalis; and as this membrane must be obviously a shut sac, one portion of it investing the testis, and the other being reflected so as to form a loose bag around it, its two portions have received the appellations of tunica vaginalis propria, and tunica vaginalis reflexa.

The descent of the testis is effected by means of the traction of the muscle of the gubernaculum (cremaster). "The fibres," writes Mr. Curling,* "proceeding from Poupart's ligament and the obliquus internus, tend to guide the gland into the inguinal canal; those attached to the os pubis, to draw it below the abdominal ring; and the process descending to the scrotum, to direct it to its final destination." During the descent "the muscle of the testis is gradually everted, until, when the transition is completed, it forms a muscular envelope external to the process of peritoneum, which surrounds the gland and the front of the cord." "The mass composing the central part of the gubernaculum, which is so soft, lax, and yielding as in every way to facilitate these changes, becomes gradually diffused, and, after the arrival of the testicle in the scrotum, contributes to form the loose cellular tissue which afterwards exists so abundantly in this part." The attachment of the gubernaculum to the bottom of the scrotum is indicated throughout life by distinct traces.

* Loc. cit.



INDEX.

A.

Abdomen, 518.
 Abdominal regions, 518.
 Abdominal ring, 211, 273.
 Abductor oculi, 172.
 Acetabulum, 108.
 Acini, 544.
 Adductor oculi, 172.
 Air-cells, 516.
 Albino, 475.
 Alcock, Dr., researches of, 424.
 Alimentary canal, 523.
 Allantois, 589.
 Amphi-arthritis, 122.
 Ampulla, 486.
 Amygdalæ, 525.
 Andersch, notice of, 420.
 Annulus ovalis, 500.
 Antihelix, 479.
 Antitragus, 479.
 Antrum of Highmore, 66.
 pylori, 528.
 Anus, 532, 538.
 Aorta, abdominal, 290.
 arch, 289.
 ascending, 288.
 thoracic, 290.
 Aortic sinuses, 287.
 Aponeurosis, 162.
 Apophysis, 41.
 Apparatus ligamentosus colli, 130.
 Appendices epiploicæ, 522.
 Appendix vermiformis, 530, 559.
 Aqua labyrinthi, 488.
 Aqueductus cochleæ, 488.
 vestibuli, 486.
 Aqueduct of Sylvius, 398.
 Aqueous humour, 473.
 Arachnoid membrane, 390, 408.
 Arantius, notice of, 503.
 Arbor vitæ, 401.
 uterina, 574.
 Arch, femoral, 282.
 palmar, superficial, 322.
 Arciform fibres, 406.
 Areola, 579.
 Arnold, Frederick, researches, 457.

ARTERIES.

General anatomy, 285.
 structure, 286.
 anastomotica femor, 342.
 magna, 317.
 aorta, 287.
 articulares genû, 343.
 auricula anterior, 299.
 posterior, 298.
 axillary, 313.
 basilar, 308.
 brachial, 316.
 bronchial, 322.
 bulbosi, 335.
 calcanean, 348.
 carotid common, 292.
 external, 293.
 internal, 302.
 carpal ulnar, 321.
 radial, 319.
 cavernosi, 335.
 centralis retinæ, 305, 474.
 cerebellar inferior, 309.
 superior, 309.
 cerebral, 305.
 cervicalis anterior, 311.
 posterior, 311.
 choroidean, 306.
 ciliary, 305.
 circumflex anterior, 315.
 external, 341.
 circumflex ilii, 337, 340.
 internal, 341.
 posterior, 315.
 coccygeal, 333.
 cœliac, 323.
 colic, 328.
 comes nervi ischiat., 334.
 comes phrenici, 312.
 communicans cerebri, 306.
 pedis, 347.
 coronaria dextra, 291.
 labii, 297.
 sinistra, 291.
 ventriculi, 323.
 corporis bulbosi, 335.
 cavernosi, 335.
 cremasteric, 337.

ARTERIES—*continued.*

- cystic, 325.
- dental, 302.
- digitales manus, 322.
 - pedis, 349.
- dorsales pollicis, 319.
- dorsalis linguæ, 296.
 - carpi, 319.
 - hallucis, 345.
 - nasi, 305.
 - pedis, 345.
 - penis, 335.
 - scapulæ, 310.
- emulgent, 330.
- epigastric, 337.
 - superficial, 340.
- ethmoidal, 305.
- facial, 296.
- femoral, 338.
- frontal, 305.
- gastric, 323.
- gastro-duodenalis, 325.
 - epiploica dextra, 325.
 - sinistra, 326.
- gluteal, 336.
 - inferior, 334.
- hæmorrhoidal ext., 333.
 - middle, 332.
 - superior, 330.
 - inferior, 334.
- hepatic, 324.
- ileo-colic, 328.
- iliac, common, 331
 - external, 337.
 - internal, 331.
- ilio-lumbar, 335.
- infra-orbital, 302.
- innominata, 291.
- intercostal, 322.
 - anterior, 312.
 - superior, 312.
- inter-osseous, 321.
- intestini tenuis, 328.
- ischiatric, 333.
- labial, 297.
- lachrymal, 304.
- laryngeal, 294.
- lateralis nasi, 297.
- lingual, 295.
- lumbar, 330.
- malleolar, 344.
- mammary internal, 312.
- masseteric, 297.
- mastoid, 297.
- maxillary internal, 299.
- mediastinal, 312.
- meningeæ anterior, 304.
 - inferior, 298.
 - media, 301.
 - parva, 301.
 - posterior, 309.
- mesenteric, 326.
 - inferior, 329.
- metacarpal, 319.

ARTERIES—*continued.*

- metatarsal, 345.
- musculo-phrenic, 312.
- nasal, 305.
- obturator, 335.
- occipital, 297.
- œsophageal, 322.
- ophthalmic, 304.
- orbital, 299.
- palatine inferior, 297.
 - posterior, 302.
- palpebral, 305.
- pancreatica magna, 326.
- pancreaticæ parvæ, 325.
- pancreatico-duoden., 325.
- parotidean, 298.
- perforantes, femoral, 341.
 - palmares, 320.
 - plantares, 349.
- pericardiac, 312.
- perineal superficial, 334.
- peroneal, 347.
- pharyngea ascendens, 298.
- phrenic, 323.
- plantar external, 349.
 - internal, 348.
- popliteal, 342.
- princeps cervicis, 298.
 - pollicis, 319.
- profunda cervicis, 311.
 - femoris, 340.
 - inferior, 317.
 - superior, 317.
- pterygoid, 297.
- pterygo-palatine, 302.
- pubic external, 340.
- pubic internal, 334.
- pulmonary, 350, 503.
- pyloric, 325.
- radial, 318.
- radialis indicis, 319.
- ranine, 295.
- recurrens inteross., 321.
 - radialis, 318.
 - tibialis, 344.
 - ulnaris, 321.
- renal, 330.
- sacra media, 330.
 - lateralis, 336.
- scapular posterior, 310.
- sigmoid, 330.
- spermatic, 328.
- spheno-palatine, 302.
- spinal, 309.
- splenic, 325.
- stylo-mastoid, 298.
- subclavian, 306.
- sublingual, 296.
- submaxillary, 297.
- submental, 297.
- subscapular, 314.
- superficialis cervicis, 311.
 - volæ, 318.
- supra-orbital, 304.

ARTERIES—*continued.*

- supra-renal, 330.
 - scapular, 310.
 - sural, 343.
 - tarsæ, 345.
 - temporal, 299.
 - temporales profundæ, 299.
 - thoracic, 314.
 - thyroidea inferior, 310.
 - superior, 294.
 - tibialis antica, 343.
 - postica, 347.
 - transversalis colli, 310.
 - faciei, 298.
 - humeri, 310.
 - perinei, 334.
 - tympanic, 301.
 - ulnar, 320.
 - umbilical, 332.
 - uterine, 335.
 - vaginal, 335.
 - vasa brevia, 326.
 - intestini tenuis, 328.
 - vertebral, 308.
 - vesical, 332.
 - Vidian, 302.
- Arthrodia, 123.
- Articulations, 126.
- Arytenoid cartilages, 508.
- Arytenoid glands, 512.
- Auricles of the heart, 499.
- Auriculo-ventricular openings, 500, 501.

B.

- Barry, Dr., researches of, 577.
- Base of the brain, 401.
- Bauhini, valvula, 533.
- Bell, Sir C., researches of, 385.
- Berzelius, analysis of bone, 337.
- Biliary ducts, 551.
- Bladder, 557.
- BONES, chemical composition, 37.
 - development, 41.
 - general anatomy, 37.
 - structure, 38.
- astragalus, 115.
 - atlas, 44.
 - axis, 45.
 - calcis, 116.
 - carpus, 100.
 - clavicula, 94.
 - coccyx, 50.
 - costæ, 92.
 - cuboides, 118.
 - cuneiforme carpi, 101.
 - externum tarsi, 117.
 - internum, 117.
 - medium, 117.
 - ethmoides, 64.
 - femur, 110.
 - fibula, 114.
 - frontale, 54.

BONES—*continued.*

- humerus, 96.
 - hyoides, 91.
 - ilium, 106.
 - innominatum, 106.
 - ischium, 107.
 - lachrymale, 68.
 - magnum, 103.
 - malare, 68.
 - maxillare superius, 65.
 - maxillare inferius, 71.
 - metacarpus, 104.
 - metatarsus, 118.
 - nasi, 65.
 - naviculare, 116.
 - occipitale, 50.
 - palati, 69.
 - parietale, 53.
 - patella, 113.
 - phalanges manus, 105.
 - pedis, 120.
 - pisiforme, 102.
 - pubis, 108.
 - radius, 99.
 - sacrum, 49.
 - scaphoides carpi, 100.
 - tarsi, 115.
 - scapula, 95.
 - semilunare, 101.
 - sesamoidea manus, 120.
 - pedis, 120.
 - sphenoides, 60.
 - sternum, 92.
 - tarsus, 115.
 - temporal, 56.
 - tibia, 113.
 - trapezoides, 102.
 - trapezium, 102.
 - triquetra, 74.
 - turbinatum inferius, 71.
 - superius, 64.
 - ulna, 98.
 - unciforme, 103.
 - unguis, 68.
 - vertebra prominens, 46.
 - vertebræ cervical, 44.
 - dorsal, 46.
 - lumbar, 47.
 - vomer, 71.
 - Wormiana, 74.
- Botal, foramen of, 588.
 - notice of, 588.
- Bowman, Mr. researches of, 164.
- Brain, 387.
- Bronchi, 513.
- Bronchial cells, 516.
 - tubes, 516.
- Bronchocele, 514.
- Brunn, Von, notice of, 536.
- Brunner's glands, 536.
- Bulb, corpus spongiosum, 563.
- Bulbous part of the urethra, 566.
- Bulbus olfactorius, 412.

Bursæ mucosæ, 125.

C.

Cæcum, 530.

Calamus scriptorius, 399.

Calyces, 556.

Camper's ligament, 278.

Canal of Fontana, 470.

Petit, 474.

Sylvius, 398.

Canals of Havers, 38.

Canthi, 475.

Capillaries, 286.

Capitula laryngis, 508.

Capsule of Glisson, 545.

Capsules supra-renal, 553.

Caput gallinaginis, 564.

Cardia, 628.

Carpus, 100.

Cartilage, 124.

CARTILAGES.

inter-articular of the clavicle, 141.

inter-articular of the jaw, 133.

inter-articular of the wrist, 146.

semilunar, 154.

Cartilagification, 41.

Caruncula lachrymalis, 477.

Carunculæ myrtiformes, 579.

Casserian ganglion, 425.

Cauda equina, 430.

Cementum, 86.

Centrum ovale majus, 392.

minus, 392.

Cerebellum, 400.

Cerebro-spinal axis, 382.

Cerebrum, 391.

Ceruminous follicles, 480.

Cervical ganglia, 458.

Chambers of the eye, 473.

Checks, 524.

Chordæ tendinæ, 501, 504.

vocales, 509.

Willisii, 388.

Choroid membrane, 464.

plexus, 394, 397, 399.

Cilia, 476.

Ciliary canal, 470.

ligament, 470.

processes, 471.

Circle of Willis, 310.

Circulation, adult, 499.

fœtal, 553.

Clitoris, 578.

Cochlea, 487.

Cock, Mr., researches of, 423.

Cœliac axis, 323.

Colon, 530.

Columnna nasi, 465.

Columnnæ carnæ, 502, 504.

papillares, 502.

Commissures, 398, 407.

great, 392.

Conarium, 398.

Concha, 479.

Congestion of the liver, 550.

Coni renales, 555.

vaseulosi, 571.

Conjunctiva, 477.

Cooper, Sir Astley, researches of, 585.

Corium, 492.

Cornea, 468.

Cornicula laryngis, 508.

Cornu Ammonis, 395.

Cornua of the ventricles, 392.

Corona glandis, 562.

Coronary valve, 500.

Corpora albicantia, 402.

Arantii, 504.

cavernosa, 563.

Malpighiana, 555.

olivaria, 406.

pisiformia, 402.

pyramidalia, 403.

quadrigenina, 398.

restiformia, 401, 404.

striata, 394.

Corpus callosum, 392, 407.

cavernosum, 563.

fimbriatum, 394.

genticulatum externum, 398.

internum, 398.

Highmorianum, 569.

luteum, 577.

rhomboideum, 401.

spongiosum, 563.

striatum, 394.

Costal cartilages, 94.

Cotunnus, notice of, 487.

Cowper's glands, 566.

Cranial nerves, 411.

Cribiform fascia, 281.

Cricoid cartilage, 508.

Crico-thyroid membrane, 509.

Crura cerebelli, 401.

cerebri, 403.

penis, 563.

Crural canal, 339.

ring, 282.

Crystalline lens, 473.

Cuneiform cartilages, 509.

Cupola, 487.

Curling, Mr. researches of, 590.

Cuticle, 494.

Cutis, 492.

Cystic duct, 551.

D.

Dartos, 567.

Davy, Dr., researches of, 308.

Derbyshire neck, 514.

Dermis, 492.

Detrusor urinæ, 559.

Deutch, researches of, 39.

Diaphragm, 215.

Diaphysis, 41.
 Diarthrosis, 123.
 Digital cavity, 395.
 Diverging fibres, 405.
 Dorsi-spinal veins, 368.
 Ductus ad nasum, 478.
 arteriosus, 588.
 comm. choledochus, 551.
 cysticus, 551.
 ejaculatorius, 564.
 hepaticus, 551.
 lymphaticus dexter, 381.
 pancreaticus, 552.
 prostaticus, 560.
 thoracicus, 379.
 venosus, 581.
 Duodenum, 528.
 Dura mater, 387, 408.

E.

Ear, 478.
 Ejaculatory duct, 564.
 Elastic tissue, 125.
 Enamel, 85.
 Enarthrosis, 123.
 Encephalon, 387.
 Endolymph, 490.
 Ensiform cartilage, 92.
 Epidermis, 494.
 Epididymis, 540.
 Epigastric region, 518.
 Epiglottic gland, 512.
 Epiglottis, 509.
 Epiglottico-hyoidean ligament, 509.
 Epiphysis, 41.
 Epithelium, 533.
 Erectile tissue, 563.
 Eustachian tube, 483.
 valve, 500.
 Eustachius, notice of, 500.
 Eye, 467.
 brows, 475.
 globe, 467.
 lashes, 476.
 lids, 475.

F.

Falciform process, 280.
 Fallopian tubes, 576.
 Fallopius, notice of, 547.
 Falx cerebelli, 389.
 cerebri, 389.

FASCIA.

 general anatomy of, 270.
 cervical, deep, 271.
 superficial, 271.
 cribriform, 281.
 dentata, 396.
 iliaca, 275.
 inter-columnar, 211.
 lata, 280.
 lumbar, 213.

FASCIA—continued.

 obturator, 277.
 palmar, 279.
 pelvica, 276.
 perineal, 277.
 plantar, 283.
 propria, 282.
 recto-vesical, 277.
 spermaticea, 211.
 temporal, 271.
 thoracic, 272.
 transversalis, 273.
 Fauces, 525.
 Femoral arch, 282.
 canal, 339.
 hernia, 282.
 ring, 282.
 Fenestra ovalis, 483.
 rotunda, 483.
 Fibres of the heart, 504, 506.
 Fibro-cartilage, 124.
 inter-articular of the clavicle, 141.
 jaw, 133.
 knee, 154.
 wrist, 146.
 Fimbriæ, Fallopiæ, 576.
 Fissure of Biehat, 392.
 Sylvius, 402.
 Fissures of the liver, 540.
 Flocculus, 400.
 Fœtal circulation, 582.
 Fœtus, anatomy of, 581.
 Follicles of Lieberkuhn, 536.
 Fontana, notice of, 470.
 Foramen cœcum, 491.
 commune anterius, 398.
 posterius, 398.
 Munro, of, 396.
 ovale, 581.
 saphenum, 280.
 Soemmering, of, 472.
 Winslow, of, 521.
 Foramina Thebesii, 500.
 Fornix, 394.
 Fossa innominata, 479.
 navicularis urethræ, 566.
 pudendi, 579.
 ovalis, 500.
 scaphoides, 479.
 Fourchette, 579.
 Fræna epiglottidis, 509.
 Frænum labii, 579.
 linguæ, 491.
 preputii, 562.

G.

Galea capitis, 168.
 Galen, 285.
 Gall-bladder, 551.
 Ganglia, cervical, 458.
 increase of, 406.
 lumbar, 463.
 sacral, 463.

- Ganglia semilunar, 462.
 structure of, 387.
 thoracic, 461.
- Ganglion of Andersch, 420.
 Arnold's, 457.
 azygos, 463.
 cardiac, 461.
 carotid, 458.
 Casserian, 425.
 ciliary, 455.
 Cloquet's, 455.
 impar, 463.
 jugular, 420.
 lenticular, 455.
 Meckel's, 455.
 naso-palatine, 455.
 otic, 457.
 petrous, 420.
 plexiforme, 421.
 Ribes, of, 455.
 spheno-palatine, 455.
 submaxillary, 457.
 thyroid, 460.
 vertebral, 460.
- Gimbernat's ligament, 211.
- Ginglymus, 123.
- Gland, epiglottic, 512.
 lachrymal, 477.
 parotid, 525.
 pineal, 398.
 pituitary, 402.
 prostate, 560.
 thymus, 585.
 thyroid, 513.
- Glands, aggregate, 536.
 arytenoid, 512.
 Brunner's, 536.
 Cowper's, 566.
 duodenal, 536.
 gastric, 535.
 inguinal, 375.
 Lieberkuhn's, 536.
 lymphatic, 371.
 mammary, 579.
 mesenteric, 378.
 Meibomian, 476.
 œsophageal, 535.
 Pacchionian, 388.
 Peyer's, 536.
 pharyngeal, 535.
 salivary, 525.
 solitary, 536.
 sublingual, 526.
 submaxillary, 526.
 tracheal, 513.
- Glandulæ odoriferae, 562.
 Pacchioni, 388.
 Tysoni, 562.
- Glans clitoridis, 549.
 penis, 534.
- Glisson, notice of, 521.
- Glisson's capsule, 545.
- Globus major epididymis, 568.
 minor epididymis, 568.
- Glomeruli, 557.
- Glottis, 511.
- Goodsir, Mr., researches of, 86.
- Goitre, 514.
- Gomphosis, 122.
- Graafian vesicles, 548.
- Grainger, Mr., researches of, 385.
- Gubernaculum testis, 591.
- Gums, 524.
- Guthrie, Mr., researches of, 559.
- Guthrie's muscle, 220.
- H.
- Hair, 496.
- Hall, Dr. Marshall, researches of, 335.
- Harmonia, 122.
- Haversian canals, 338.
- Heart, 497.
- Helicine arteries, 564.
- Helico-trema, 488.
- Helix, 479.
- Hepatic duct, 546.
- Hernia, congenital, 274.
 diaphragmatic, 216.
 direct, 274.
 encysted, 274.
 femoral, 282.
 inguinal, 274.
- Highmore, notice of, 569.
- Hilton's muscle, 511.
- Hilus lienis, 552.
 renalis, 555.
- Hippocampus major, 395.
 minor, 395.
- Horner's muscle, 170.
- Houston, Mr., researches of, 533.
- Humours of the eye, 473.
- Hyaloid membrane, 473.
- Hymen, 578.
- Hypochondriac regions, 518.
- Hypogastric region, 518.
- I.
- Ileo-cæcal valve, 533.
- Ileum, 530.
- Iliac regions, 518.
- Incus, 481.
- Infundibula, 556.
- Infundibulum, 402.
- Inguinal region, 518.
- Inter-articular cartilages of the clavicle,
 141.
 jaw, 133.
 wrist, 146.
- Inter-columnar fibres, 211.
- Inter-vertebral substance, 125.
- Intestinal canal, 530.
- Iris, 470.
- Isthmus of the fauces, 525.
- Ister ad infundibulum, 398.
 a tertio ad quartum ventriculum, 398.

J.

- Jacob's membrane, 471.
 Jejunum, 530.
 Joint, ankle, 157.
 elbow, 143.
 hip, 150.
 lower jaw, 132.
 knee, 151.
 shoulder, 142.
 wrist, 146.
 Jones, Mr., researches of, 488.

K.

- Kidneys, 526.
 Kiernan, Mr., researches of 516.
 King, Mr. T. W., researches of, 501.
 Krause, researches of, 222.

L.

- Labia majora, 549.
 minora, 549.
 Labyrinth, 485.
 Lachrymal canals, 478.
 gland, 477.
 papillæ, 475.
 puncta, 475.
 sac, 478.
 tubercles, 475.
 Lacteals, 379.
 Lacunæ, 539.
 Lacus lachrymalis, 475.
 Lamina cribrosa, 468.
 spiralis, 487.
 Laryngotomy, 509.
 Larynx, 508.
 Lateral ventricles, 392.
 Lauth, researches of, 569.
 Lens, 474.
 Lenticular ganglion, 455.
 Lieberkuhn's follicles, 536.
 Lien succenturiatus, 553.
 Ligament, 125.
 LIGAMENTS, 122.
 acromio-clavicular, 141.
 alar, 155.
 ankle, of the, 157.
 annular, of the ankle, 283.
 radius, 145.
 wrist, anterior, 147.
 posterior, 279.
 arcuatum externum, 215.
 internum, 215.
 atlo-axoid, 131.
 breve plantæ, 159.
 calcaneo-astragaloid, 160.
 cuboid, 159.
 scaphoid, 159.
 capsular of the hip, 150.
 jaw, 132.
 rib, 134.
 shoulder, 142.

LIGAMENTS—*continued.*

- capsular of the thumb, 149.
 carpal, 147.
 carpo-metacarpal, 148.
 common anterior, 126.
 posterior, 127.
 conoid, 141.
 coracoid, 142.
 coraco-acromial, 142.
 clavicular, 141.
 humeral, 142.
 coronary, 145.
 of the knee, 154.
 costo-clavicular, 140.
 sternal, 135.
 transverse, 134, 135.
 vertebral, 134.
 xyphoid, 136.
 cotyloid, 151.
 crico-thyroidean, 502.
 crucial, 153.
 cruciform, 131.
 deltoid, 158.
 elbow, of the, 143.
 epiglottio-hyoidean, 509.
 glenoid, 142.
 hip-joint, of the, 150.
 ilio-femoral, 150.
 inter-articular of ribs, 134.
 inter-clavicular, 140.
 inter-osseous,
 calcaneo-astragal, 159.
 peroneo-tibial, 156.
 radio-ulnar, 145.
 inter-spinous, 128.
 inter-transverse, 128.
 inter-vertebral, 127.
 knee, of the, 151.
 lateral of the ankle, 158.
 elbow, 143.
 jaw, 132.
 knee, 153.
 phalanges, foot, 161.
 phalanges, hand, 150.
 wrist, 147.
 liver, of the, 514.
 longum plantæ, 159.
 lumbo-iliac, 136.
 lumbo-sacral, 136.
 metacarpo-phalangeal, 149.
 metatarsal-phalangeal, 161.
 mucosum, 155.
 nuchæ, 196.
 oblique, 145.
 obturator, 139.
 occipito-atloid, 129.
 axoid, 130.
 odontoid, 130.
 orbicular, 145.
 palpebral, 476.
 patellæ, 152.
 peroneo-tibial, 156.
 phalanges of the foot, 161.
 of the hand, 149.

LIGAMENTS—*continued.*

- plantar, long, 159.
- plantar, short, 159.
- posticum Winslowii, 152.
- pterygo-maxillary, 132.
- pubic, 139.
- radio-ulnar, 145.
- rhomboid, 140.
- rotundum, hepatis, 540.
- sacro-coccygean, 138.
- sacro-iliac, 137.
- sacro-ischiatic anterior, 138.
- posterior, 138.
- stellate, 134.
- sterno-clavicular, 140.
- stylo-maxillary, 272.
- sub-flava, 127.
- sub-pubic, 139.
- supra-spinous, 128.
- suspensorium hepatis, 540.
- penis, 563.
- tarsal, 158.
- tarso-metatarsal, 160.
- teres, 151.
- thyro-arytenoid, 509.
- thyro-hyoidean, 509.
- tibio-fibular, 156.
- transverse, 158.
 - of the acetabulum, 151.
 - of the ankle, 157.
 - of the atlas, 131.
 - of the knee, 153.
 - of the metacarpus, 149.
 - of the metatarsus, 158.
 - of the scapula, 142.
 - of the semilunar cartilages, 153.
- trapezoid, 141.
- tympanum, of the, 481.
- wrist, of the, 146.
- Zinn, of, 171.
- Ligamentum nuchæ, 196.
- Limbus luteus, 472.
- Linea alba, 210.
- Linæ semi-lunares, 210.
 - transversæ, 210, 399.
- Linguetta laminosa, 401.
- Lips, 524.
- Liquor Cotunnii, 488.
 - Morgagni, 474.
 - Scarpa, of, 490.
- Liver, 539.
- Lobules of the liver, 544.
- Lobuli testis, 568.
- Lobules auris, 479.
 - pneumogastricus, 400.
- Lobus caudatus, 543.
- quadratus, 543.
- Spigeli, 544.
- Locus niger, 403.
 - perforatus, 403.
- Lower, notice of, 500.
- Lumbar fascia, 213.
 - regions, 518.
- Lungs, 514.
- Lunula, 495.
- Lymphatic glands and vessels, 371.
 - axillary, 374.
 - bronchial, 377.
 - cardiac, 378.
 - cervical, 373.
 - head and neck, 373.
 - heart, 378.
 - iliac, 377.
 - inguinal, 375.
 - intestines, 375.
 - kidney, 379.
 - lacteals, 379.
 - liver, 378.
 - lower extremity, 375.
 - lungs, 377.
 - mediastinal, 376.
 - mesenteric, 378.
 - pelvic viscera, 379.
 - popliteal, 375.
 - spleen, 378.
 - stomach, 378.
 - testicle, 379.
 - trunk, 376.
 - upper extremity, 374.
 - viscera, 377.
- Lyra, 396.

M.

- Malleus, 481.
- Mammæ, 579.
- Mammary gland, 579.
- Mastoid cells, 483.
- Matrix, 495.
- Maxillo pharyngeal space, 189.
- Mayo, Mr, re-searches of, 415.
- Meatus auditorius, 480.
 - urinarius, female, 579.
 - male, 562.
- Meatuses of the nares, 466.
- Meckel's ganglion, 455.
- Meconium, 559.
- Mediasinum, 517.
 - testis, 569.
- Medulla of bones, 41.
 - oblongata, 403.
- Meibomian glands, 476.
- Meibomius, notice of, 476.
- Membrana dentata, 408.
 - nictitans, 477.
 - pigmenti, 470.
- Membrana pupillaris, 468.
 - sacciformis, 146.
 - tympani, 480.
- Membrane, choroid, 469.
 - hyaloid, 473.
 - Jacob's, 471.
 - of the ventricles, 400.
- Membranous urethra, 565.
- Meniscus, 124.
- Mesenteric glands, 379.
- Me-entery, 522.
- Meso-colon, 522.

Meso-rectum, 522.
 Metacarpus, 104.
 Metatarsus, 118.
 Miescher, researches of, 39.
 Mitral valves, 504.
 Modiolus, 487.
 Mons Veneris, 578.
 Morgagni, notice of, 474.
 Morsus Diaboli, 576.
 Motor tract, 414.
 Mouth, 523.
 Mucous membrane, structure, 533.
 Müller, researches of, 39.
 MUSCLES.
 general anatomy of, 162.
 development of, 164.
 structure, 163.
 abductor min. digiti, 242.
 abduc. min. dig. pedis, 264.
 indicis, 243.
 pollicis, 240.
 pedis, 264.
 accelerator urinæ, 219.
 accessorius, 266.
 adductor brevis, 254.
 longus, 253.
 magnus, 254.
 min. digiti, 242.
 pollicis, 241.
 pedis, 267.
 anconeus, 238.
 anti-tragicus, 480.
 arytenoidens, 510.
 aryteno-epiglot. inf., 511.
 superior, 511.
 attollens aurem, 179.
 oculum, 171.
 atrahens aurem, 179.
 auricularus, 238.
 azygos uvulæ, 192.
 basio-glossus, 187.
 biceps flexor cruris, 255.
 cubiti, 229.
 biventer cervicis, 202.
 brachialis anticus, 230.
 buccinator, 177.
 cerato-glossus, 187.
 cervicalis ascendens, 201.
 circumflexus palati, 191.
 coccygeus, 222.
 complexus, 202.
 compressor nasi, 173.
 urethræ, 220.
 constrictor inferior, 189.
 isth. faucium, 188, 192.
 medius, 189.
 superior, 189.
 vaginæ, 222.
 coraco-brachialis, 229.
 corrugator supercillii, 169.
 cremaster, 212.
 crico-arytenoid lat., 510.
 posticus, 510.
 thyroideus, 510.

MUSCLES—continued.
 crureus, 251.
 cucullaris, 196.
 deltoid, 228.
 depressor ang. oris, 176.
 labii inferioris, 176.
 labii sup. alarque nasi, 175.
 depressor oculi, 172.
 detrusor urinæ, 559.
 diaphragm, 215.
 digastricus, 185.
 erector clitoridis, 222.
 penis, 219.
 spinæ, 200.
 extensor carpi rad. brev. 236.
 carpi rad. long., 236.
 carpi ulnaris, 238.
 digiti minimi, 238.
 digitor. brevis, 263.
 digitor. com. 236.
 digitor. longus, 257.
 indicis, 239.
 ossis metacarpi, 239.
 pollicis proprius, 257.
 primi internodii, 239.
 sec. internodii, 239.
 flexor accessorius, 266.
 brevis digiti minimi, 242.
 digiti minimi pedis, 267.
 carpi radialis, 232.
 ulnaris, 234.
 digitorum brevis, 265.
 profundus, 234.
 sublimis, 233.
 longus digit. pedis, 261.
 longus pollicis manus, 235.
 pedis, 260.
 ossis metacarpi, 240, 242.
 pollicis brevis, 241.
 pedis, 267.
 longus, 260.
 gastrocnemius, 253.
 gemellus inferior, 248.
 superior, 248.
 genio-hyo-glossus, 186.
 hyoideus, 186.
 glutens maximus, 246.
 medius, 247.
 minimus, 247.
 gracilis, 254.
 helicus major, 480.
 minor, 480.
 hyo-glossus, 187.
 iliacus, 252.
 indicator, 239.
 infra-spinatus, 227.
 inter-costales externi, 208.
 interni, 208.
 inter-ossei manus, 243.
 pedis, 263, 267.
 inter-spinales, 204.
 inter-transversales, 204.
 intra-costales, 209.
 larynx, of the, 510.

MUSCLES—*continued.*

latissimus dorsi, 196.
 laxator tympani, 483.
 levator anguli oris, 175.
 scapulæ, 197.
 ani, 221.
 glandulæ thyroid., 514.
 labii inferioris, 176.
 superioris, 174.
 sup. alæq. nasi, 174.
 menti, 176.
 palati, 191.
 palpebræ, 171.
 levatores costarum, 203.
 lingualis, 187.
 longissimus dorsi, 200.
 longus colli, 194.
 lumbricales manus, 242.
 pedis, 266.
 mallei externus, 483.
 internus, 482.
 masseter, 176.
 multifidus spinæ, 203.
 mylo-hyoideus, 185.
 myrtiformis, 175.
 obliquus abdom. ext. 210.
 abdom. int., 211.
 capitis inferior, 203.
 superior, 203.
 oculi inferior, 172.
 superior, 172.
 obturator externus, 249.
 internus, 248.
 occipito-frontalis, 167.
 omo-hyoideus, 184.
 opponens digit. min. 242.
 pollicis, 240.
 orbicularis oris, 174.
 palpebrarum, 169.
 palato-glossus, 188, 192.
 pharyngeus, 190, 192.
 palmaris brevis, 242.
 longus, 232.
 pectineus, 253.
 pectoralis major, 225.
 minor, 225.
 peroneus brevis, 263.
 longus, 262.
 tertius, 257.
 plantaris, 259.
 platysma-myoides, 181.
 popliteus, 260.
 pronator quadratus, 235.
 radii teres, 232.
 psoas magnus, 253.
 parvus, 215.
 pterygoideus ext., 178.
 int., 178.
 pyramidalis abdom., 214.
 nasi, 173.
 pyriformis, 247.
 quadratus femoris, 249.
 lumborum, 215.
 menti, 176.

MUSCLES—*continued.*

rectus abdominis, 214.
 capitis ant. maj., 193.
 min., 193.
 lateralis, 203.
 post. maj., 203.
 min. 203.
 femoris, 251.
 oculi externus, 172.
 inferior, 171.
 internus, 172.
 superior, 171.
 retrahens aurem, 179.
 rhomboideus major, 197.
 minor, 197.
 risorius Santorini, 181.
 sacro-lumbalis, 200.
 sartorius, 250.
 scalenus anticus, 193.
 posticus, 194.
 semi-spinalis colli, 202.
 dorsi, 202.
 semi-membranosus, 255.
 semi-tendinosus, 255.
 serratus magnus, 226.
 posticus inf., 199.
 sup., 199.
 soleus, 260.
 sphincter ani, 221.
 internus, 221.
 spinalis dorsi, 200.
 splenius capitis, 199.
 colli, 199.
 stapedius, 483.
 sterno-hyoideus, 183.
 mastoideus, 181.
 thyroideus, 183.
 stylo-glossus, 188.
 hyoideus, 185.
 pharyngens, 190.
 subclavius, 226.
 subcrureus, 251.
 subscapularis, 226.
 supinator brevis, 238.
 longus, 236.
 supra-spinales, 204.
 supra-spinatus, 227.
 temporal, 177.
 tensor palati, 191.
 tarsi, 170.
 tympani, 482.
 vaginæ fem. 250.
 teres major, 228.
 minor, 227.
 thyro-arytenoideus, 510.
 epiglottideus, 511.
 hyoideus, 183.
 tibialis anticus, 257.
 posticus, 261.
 trachelo-mastoideus, 202.
 tragicus, 480.
 transversalis abdom., 213.
 colli, 201.
 transversus auris, 480.

MUSCLES—*continued.*

- transversus pedis, 267.
 - perinci, 219, 222.
- trapezius, 196.
- triangularis oris, 176.
 - sterni, 210.
- triceps extens. cruris, 258.
 - cubiti, 230.
- ureters, of the, 556.
- vastus externus, 251.
 - internus, 251.
- zygomaticus major, 175.
 - minor, 175.

Muscular fibre, 164.

Musculi pectinati, 500.

Myolemma, 164.

Myopia, 475.

N.

Naboth, ovula of, 574.

Nagel, Mr., researches of, 576.

Nails, 495.

Narcs, 527.

Nasal duct, 478.

fossæ, 82, 466.

Nasmyth, Mr., researches of, 85.

Nates cerebri, 398.

NERVES.

general anatomy, 382.

abducentes, 415.

accessorius, 424.

acromiales, 432.

auditory, 413, 490.

auricularis anterior, 429.

magnus, 431.

posterior, 418.

buccal, 428.

cardiac, 423.

cardiacus inferior, 460.

magnus, 460.

medius, 460.

minor, 461.

superior, 460.

cervical, 430.

cervico-facial, 418.

chorda tympani, 418, 456.

ciliary, 426.

circumflex, 440.

claviculares, 432.

cochlear, 490.

communicans noni, 416, 432.

peronei, 452.

poplitei, 450.

cranial, 411.

crural, 444.

cutaneous ext. branch, 436.

ext. femoralis, 444.

int. brachialis, 436.

minor, 436.

post. femoralis, 449.

spiralis, 439.

dental anterior, 427.

inferior, 429.

posterior, 427.

NERVES—*continued.*

descendens noni, 416.

digastric, 418.

dorsal, 440.

eighth pair, 420.

facial, 417.

femoral, 444.

fifth pair, 424.

first pair, 412.

fourth pair, 417.

frontal, 426.

gastric, 424.

genito-crural, 443.

glosso-pharyngeal, 420.

gluteal, 448.

inferior, 448.

gustatory, 423.

hypo-glossal, 416.

ilio-scrotal, 443.

inferior maxillary, 428.

infra-trochlear, 426.

inguino-cutaneous, 443.

intercostal, 441.

intercosto-humeral, 441.

inter-osseous anterior, 437.

posterior, 440.

ischiatricus major, 449.

minor, 448.

Jacobson's, 421.

lachrymal, 426.

laryngeal inferior, 423.

super., 422, 459.

lingual, 416.

lumbar, 442.

lumbo-sacral, 446.

masseteric, 428.

maxillaris inferior, 428.

superior, 427.

median, 436.

molles, 460.

motores oculorum, 414.

musculo-cutan., arm, 436.

leg, 443.

musculo-spiral, 439.

mylo-hyoidean, 429.

nasal, 426.

obturator, 445.

occipitalis major, 433.

minor, 432.

olfactory, 412.

ophthalmic, 425.

optic, 412.

orbital, 427.

palatine anterior, 455.

posterior, 456.

palmar, deep, 439.

superficial, 437, 439.

pathetici, 417.

perforans Casserii, 436.

perineal, 448.

peroneo-cutaneous, 453.

peroneal, 452.

petrosus minor, 457.

pharyngeal, 422, 459.

phrenic, 432.

NERVES—*continued.*

- plantar external, 452.
- internal, 451.
- pneumogastric, 421.
- popliteal, 449.
- portio dura, 417.
- mollis, 413.
- pterygoid, 428.
- pudendalis, 448.
- pubic internal, 448.
- pulmonary, 424.
- radial, 439.
- recurrent, 423.
- respiratory external, 435.
- sacral, 416.
- saphenous external, 450.
- long, 445.
- short, 445.
- second pair, 412.
- sixth pair, 415.
- spinal, 429.
- spinal accessory, 424.
- splanchnicus major, 462.
- minor, 462.
- stylo hyoid, 418.
- sub-occipital, 432.
- subscapular, 435.
- superficialis colli, 431.
- cordis, 460.
- superior maxillary, 427.
- supra-orbital, 427.
- scapular, 435.
- trochlear, 426.
- sympatheticus major, 453.
- minor, 419.
- temporal, 428.
- temporo-facial, 418.
- malar, 427.
- third pair, 414.
- thoracic long, 435.
- short, 435.
- tibialis anticus, 452.
- posticus, 451.
- trifacial, 424.
- trigeminus, 424.
- trochlearis, 417.
- tympanic, 421.
- ulnar, 438.
- vagus, 421.
- vestibular, 490.
- Vidian, 456.
- Neurilemma, 386.
- Nipple, 579.
- Nose, 464.
- Nymphæ, 578.

O.

- Esophagus, 509, 527.
- Omentum, gastro-splenic, 522.
- great, 522.
- lesser, 521.
- Omphalo-mesenteric vessels, 574.
- Optic commissure, 402.

- Optic thalami, 394, 397.
- Orbiculare os, 481.
- Orbits, 81.
- Ossicula auditus, 481.
- Ossification, 41.
- Ostium abdominale, 432.
- uterinum, 575.
- Otoconites, 490.
- Ovaries, 577.
- Ovula Graafiana, 577.
- Naboth, of, 574.

P.

- Pacchionian glands, 388.
- Palate, 524.
- Palmar arch, 322.
- Palpebræ, 475.
- Palpebral ligaments, 476.
- sinuses, 477.
- Pancreas, 547.
- Panizza, researches of, 458.
- Papillæ of the natl, 495.
- of the skin, 493.
- of the tongue, 491.
- calyciformes, 491.
- circumvallatæ, 491.
- conicæ, 491.
- filiformes, 491.
- fungiformes, 491.
- Parotid gland, 525.
- Pelvis, 109.
- viscera of, 560.
- Penis, 563.
- Pericardium, 497.
- Perichondrium, 41.
- Pericranium, 41.
- Periosteum, 41.
- Peritoneum, 518.
- Perspiratory ducts, 496.
- Pes accessorius, 395.
- anserinus, 418.
- hippocampi, 395.
- Petit, notice of, 474.
- Peyer, notice of, 536.
- Peyer's glands, 536.
- Phalanges, 105.
- Pharynx, 527.
- Pia mater, 391, 408.
- Pigmentum nigrum, 470.
- Pillars of the palate, 525.
- Pineal gland, 338.
- Pinna, 479.
- Pituitary gland, 402.
- membrane, 466.
- Pleura, 517.
- Plexus, aortic, 463.
- axillary, 433.
- brachial, 433.
- cardiac, 461.
- carotid, 457.
- cavernous, 458.
- cervical anterior, 431.
- posterior, 433.

- Plexus, choroid, 394, 399.
 cæliac, 462.
 coronary, 461.
 gastric, 462.
 hepatic, 462.
 hypogastric, 463.
 lumbar, 442.
 mesenteric inferior, 462.
 superior, 462.
 œsophageal, 424.
 pharyngeal, 422.
 phrenic, 462.
 prostatic, 365.
 pterygoid, 354.
 pulmonary, 424, 461.
 renal, 462.
 sacral, 416.
 solar, 462.
 spermatic, 462.
 splenic, 462.
 submaxillary, 429.
 supra-renal, 462.
 uterine, 365.
 vertebral, 460.
 vesical, 365.
 Plica semilunaris, 477.
 Plicæ longitudinales, 573.
 Pneumogastric lobule, 400.
 Polypus of the heart, 499.
 Pomum Adami, 508.
 Pons Tarini, 403.
 Varolii, 403.
 Pores, 416.
 Portal vein, 369, 541.
 Portio dura, 417.
 mollis, 413.
 Forus opticus, 468.
 Poupart's ligament, 211.
 Prepuce, 563.
 Presbyopia, 475.
 Processus cerebelli ad testes, 401.
 clavatus, 409.
 vermiformes, 400.
 Promontory, 483.
 Prostate gland, 565.
 Prostatic urethra, 565.
 Protuberantia annularis, 403.
 Pulmonary artery, 540.
 plexuses, 540.
 sinuses, 503.
 veins, 370.
 Puncta lachrymalia, 475.
 vasculosa, 392.
 Pupil, 470.
 Purkinje, corpuscles of, 39.
 Pylorus, 528.
 Pyramid, 485.
 Pyramids, anterior, 403.
 posterior, 399.
 of Wistar, 65.
- R.
- Raphé, corporis callosi, 3.2.
 Receptaculum chyli, 379.
 Rectum, 531.
 Regions, abdominal, 518.
 Reil, island of, 402.
 Respiratory nerves, 417.
 tract, 417.
 Rete mucosum, 494.
 testis, 568.
 Retina, 471.
 Ribes, ganglion of, 455.
 Rima glottidis, 511.
 Ring, external abdominal, 211.
 femoral, 281.
 internal abdominal, 273.
 Rugæ, 567.
 Ruysch, notice of, 470.
- S.
- Sacculus laryngis, 512.
 proprius, 488.
 Salivary glands, 525.
 Saphenous opening, 280.
 veins, 363.
 Scala tympani, 487.
 vestibuli, 487.
 Scarf-skin, 494.
 Scarpa, notice of, 490.
 Schindylesis, 122.
 Schneider, notice of, 466.
 Schneiderian membrane, 466.
 Sclerotic coat, 467.
 Scrotum, 567.
 Searle, Mr., researches of, 504.
 Sebaceous glands, 496.
 Semicircular canals, 486.
 Semilunar fibro-cartilages, 154.
 valves, 502.
 Septum auricularum, 499.
 crurale, 282.
 lucidum, 396.
 pectiniforme, 563.
 scroti, 567.
 Serous membrane, structure, 522.
 Sesamoid bones, 120.
 Sheath of the rectus, 214.
 Sigmoid valves, 504.
 Sinuses, structure, 353.
 Sinus, aortic, 594.
 basilar, 359.
 cavernous, 353.
 circular, 359.
 fourth, 357.
 lateral, 358.
 longitudinal inferior, 357.
 superior, 356.
 occipital anterior, 357.
 posterior, 357.
 petrosal inferior, 359.
 superior, 359.
 pocularis, 555.
 prostatic, 566.
 pulmonary, 503.
 rectus or straight, 357.

- Sinus, transverse, 359.
 Skeleton, 42.
 Skin, 492.
 Skull, 50.
 Socia parotidis, 526.
 Soemmering, notice of, 472.
 Soft palate, 524.
 Spermatic canal, 274.
 cord, 567.
 Spheno-maxillary ganglion, 455.
 Spigel, notice of, 542.
 Spinal cord, 407.
 nerves, 429.
 veins, 368.
 Spleen, 552.
 Spongy part of the urethra, 566.
 Stapes, 481.
 Stenon, notice of, 492.
 Stenon's duct, 525.
 Stomach, 528.
 Striæ, muscular, 164.
 Sub-arachnoidean fluid, 390.
 space, 390.
 tissue, 390.
 Sublingual gland, 525.
 Submaxillary gland, 526.
 Substantia perforata, 402.
 Sulcus hepatis, 541.
 longitudinal chordæ spinal, 409.
 Supercilia, 475.
 Superficial fascia, 270.
 Supra-renal capsules, 553.
 Suspensory ligament, liver, 540.
 penis, 566.
 Sutures, 74.
 Sylvius, notice of, 391.
 Sympathetic nerve, 453.
 Symphysis, 122.
 Synarthrosis, 122.
 Synovia, 125.
 Synovial membrane, 125.
- T.
- Tapetum, 470.
 Tarin, Peter, notice of, 394.
 Tarsal cartilages, 476.
 Tarsus, 115.
 Teeth, 83.
 Tendo Achillis, 258.
 oculi, 169.
 Tendon, 162.
 Tenia semicircularis, 394.
 Tarini, 394.
 Tentorium cerebelli, 389.
 Testes cerebri, 398.
 Testicles, 568.
 descent, 588.
 Thalami optici, 394, 397.
 Thebesius, notice of, 500.
 Theca vertebralis, 408.
 Thoracic duct, 379.
 Thorax, 497.
 Thyimus gland, 586.
- Thyro-hyoid membrane, 509.
 Thyroid axis, 310.
 cartilage, 508.
 gland, 513.
 Tod, Mr., researches of, 480.
 Tongue, 491.
 Tonsils, 525.
 cerebelli, 401.
 Torcular Herophili, 357.
 Trachea, 513.
 Tractus motorius, 414.
 respiratorius, 417.
 Tragus, 479.
 Triangles of the neck, 184.
 Tricuspid valves, 501.
 Trigone vesicale, 567.
 Trochlearis, 172.
 Tuber cinereum, 402.
 Tubercula quadrigemina, 398.
 Tuberculum Loweri, 500.
 Tubuli lactiferi, 572.
 seminiferi, 567.
 uriniferi, 556.
 Tunica albuginea oculi, 467.
 testis, 569.
 erythroides, 570.
 nervea, 572.
 Ruyschiana, 471.
 vaginalis, 569.
 vasculosa testis, 568.
 Tympanum, 480.
 Tyrrell, Mr., researches of, 221.
 Tyson's glands, 562.
- U.
- Umbilical region, 518.
 Urachus, 558.
 Ureter, 552.
 Urethra, female, 573.
 male, 566.
 Uterus, 575.
 Utriculus communis, 488.
 Uvea, 471.
 Uvula cerebelli, 401.
 palati, 525.
 vesicæ, 558.
- V.
- Vagina, 578.
 Valve, arachnoid, 399.
 Baubini, 533.
 coronary, 500.
 Eustachian, 500.
 ileo-cæcal, 533.
 mitral, 504.
 pyloric, 532.
 rectum, of the, 538.
 semilunar, 502, 504.
 tricuspid, 501.
 Vicussens, of, 399.
 Valvulæ conniventes, 532.
 Varolius, notice of, 403.

Vasa efferentia, 569.
 lactea, 379.
 lymphatica, 379.
 pampiniformia, 570.
 recta, 568.
 vasorum, 287.

Vasculum, aberrans, 569.

Vas deferens, 569.

VEINS.
 structure, 353.
 angular, 354.
 auricular, 355.
 axillary, 362.
 azygos major, 367.
 minor, 367.
 basilic, 361.
 cardiac, 368.
 cava inferior, 365.
 superior, 364.
 cephalic, 361.
 cerebellar, 356.
 cerebral, 356.
 coronary, 368.
 corporis striata, 394.
 diploe, 355.
 dorsalis penis, 365.
 dorsi-spinal, 368.
 emulgent, 367.
 facial, 354.
 femoral, 363.
 frontal, 354.
 Galeni, 356.
 gastric, 369.
 hepatic, 367.
 iliac, 365, 366.
 innominata, 364.
 intercostal superior, 268.
 jugular, 359.
 lumbar, 366.
 mastoid, 355.
 maxillary internal, 354.
 median, 362.
 basilic, 362.
 cephalic, 362.
 medulli-spinal, 368.
 meningo-rachidian, 368.
 mesenteric inferior, 369.
 superior, 369.
 occipital, 355.
 ovarian, 366.
 parietal, 356.
 popliteal, 363.
 portal, 369.
 profunda femoris, 363.
 prostatic, 365.
 pulmonary, 370, 503.
 radial, 361.
 renal, 367.
 salvatella, 361.

VEINS—*continued.*
 saphenous external, 363.
 internal, 363.
 spermatic, 366.
 spinal, 363.
 splenic, 369.
 subclavian, 362.
 temporal, 355.
 temporo-maxillary, 355.
 Thebesii, 369.
 thyroid, 360.
 ulnar, 361.
 uterine, 365.
 vertebral, 360, 368.
 vesical, 365.

Velum interpositum, 391, 396.
 pendulum, palati, 402.

Venæ comites, 352.
 Galeni, 397.
 vorticosa, 470.

Ventricle of Arantius, 399.

Ventricles of the brain, 396.
 fifth, 396.
 fourth, 399.
 lateral, 392.
 third, 398.
 of the heart, 500, 503.
 of the larynx, 512.

Vermiform process, 400.

Vertebral aponeurosis, 199.
 column, 43.

Veru montanum, 565.

Vesiculæ seminales, 569.

Vestibule, 485.

Vestibulum vaginæ, 578.

Vibrissæ, 466.

Vidius Vidus, notice of, 456.

Vienssens, notice of, 399.

Villi, 507.

Vitreous humour, 473.


Vulva, 578.

W.

Wharton, notice of, 492.
 Wharton's duct, 526.
 Willis, notice of, 388.
 Wilson's muscles, 220.
 Winslow, notice of, 521.
 Wistar, pyramids of, 65.
 Wrisberg, nerve of, 436.

Z.

Zinn, notice of, 473.
 Zonula ciliaris, 473.
 of Zinn, 473.
 Zygoma, 56.



TO THE MEDICAL PROFESSION.

LEA AND BLANCHARD present a condensed list of Books published and preparing for publication by them, and would refer to the other pages of their catalogue for a more detailed account. The prices, and all other information in relation to them, will be given on application, free of postage. Being extensively engaged in the publication of Medical and Scientific works, it will be their effort to furnish them at prices lower than formerly, and as low as they can be afforded consistent with correct and well-executed editions. The latest editions will always be furnished; and, to their present extensive list, they will add, from time to time, such other good works as the wants of the profession may call for. Their publications may be found at all the principal Bookstores throughout the Union.

- Anatomical Atlas, by Smith and Horner, imperial 8vo., nearly 650 figures.
- Arnott's Elements of Physics, new edition, in 1 vol. 8vo., 484 closely printed pages.
- American Medical Journal, published quarterly at \$5 a year.
- Abercrombie on the Stomach, 1 vol. 8vo., 320 pages.
- Abercrombie on the Brain, a new edition, 1 vol. 8vo., 324 pages.
- Alison's Outlines of Pathology, in 1 vol. 8vo., 420 pages.
- Ashwell on the Diseases of Females, complete in one large vol. 8vo.
- Andral on the Blood, 120 pages, 8vo.
- Bird's Natural Philosophy, 1 vol. 8vo., preparing.
- Budd on the Liver, 1 vol. 8vo., preparing.
- Bell on the Teeth, with plates, 1 vol. 8vo., 351 pages.
- Buckland's Geology and Mineralogy, 2 vols. 8vo., with numerous plates and maps.
- Berzelius on the Kidneys and Urine, 1 vol. small 8vo., 179 pages.
- Bridgewater Treatises, with numerous illustrations, 7 vols. 8vo., 3257 pages.
- Bartlett on Fevers, &c., 1 vol. 8vo., 393 pages.
- Bartlett on the Philosophy of Medicine, 1 vol. 8vo., 312 pages.
- Brigham on Mental Excitement and Cultivation, 1 vol. 12mo., 204 pages.
- Billing's Principles of Medicine, 1 vol. 8vo., 304 pages.
- Brodie on Urinary Organs, 1 vol. 8vo., 214 pages.
- Brodie on the Joints, 1 vol. 8vo., 216 pages.
- Brodie's Surgical Lectures, 1 vol. 8vo., at press.
- Chapman on Thoracic and Abdominal Viscera, 1 vol. 8vo., 384 pages.
- Chapman on Fevers, Dropsy, Gout, &c., 1 vol. 8vo., 450 pages.
- Chitty's Medical Jurisprudence, 1 vol. 8vo., 509 large pages.
- Carpenter's Human Physiology, 1 vol. 8vo., 618 pages, with cuts.
- Carpenter's General and Comparative Physiology, 1 vol. 8vo., preparing.
- Carpenter's Vegetable Physiology, 1 vol. 12mo., with cuts, 300 pages.
- Carpenter's Animal Physiology, to be published hereafter.
- Cooper, Sir Astley, his work on Hernia, imperial 8vo., with plates, 428 pages.
- Copper on Dislocations and Fractures, 1 vol. 8vo., with cuts, 499 pages.
- Cooper on the Testis and Thymus Gland, 1 vol. imperial 8vo., many plates.
- Cooper on the Anatomy and Diseases of the Breast, 1 vol. 8vo., plates, at press.
- Condie on Diseases of Children, 1 vol. 8vo., 651 pages.
- Costello's Cyclopædia of Practical Surgery, to be published hereafter.
- Churchill on Females, 3d American edition, 1 vol. 8vo., 572 large pages.
- Churchill's Theory and Practice of Midwifery, 1 vol. 8vo., 519 pages, with cuts.
- Cyclopædia of Practical Medicine, by Forbes, &c. Edited by Dunglison, in 4 large super-royal vols.
- Carson's Medical Formulary, in preparation.
- Deweese's System of Midwifery, with plates, 10th edit., 660 pages.
- Deweese on Children, 8th edition, 548 pages.
- Deweese on Females, with plates, 8th edition, 532 pages.
- Dunglison's Physiology, 5th edition, 2 vols. 8vo., 1304 pages, with 300 cuts.
- Dunglison's Therapeutics and Materia Medica, a new work, 2 vols. 8vo., 1004 pages.
- Dunglison's Medical Dictionary, 4th edition, 1 vol. 8vo., 771 very large pages.
- Dunglison's New Remedies, 5th edition, 1843, 615 pages.
- Dunglison on Human Health, in 1 vol. 8vo., 464 pages.
- Dunglison's Practice of Medicine, 2d edition, 2 vols. 8vo., 1322 pages.
- Dunglison's Medical Student, a new edition, 1 vol. 12mo., 312 pages.
- Druitt's Modern Surgery, 1 vol. 8vo., 534 pages, 2d edition, many cuts.
- Ellis's Medical Formulary, 7th edition, 1 vol. 8vo., 262 pages.
- Elliotson's Mesmeric Cases, 8vo., 56 pages.
- Esquirol's Great Work on Insanity, translated by Hunt, 1 vol. 8vo., nearly ready.
- Fowues's Elementary Chemistry, preparing.
- Fergusson's Practical Surgery, 1 vol. 8vo., 629 pages.
- Graham's Chemistry, with cuts, 1 vol. 8vo., 750 pages.
- Goddard's Dissector's Companion, in preparation.
- Gregory's Chemistry, 1 vol. 8vo., preparing.
- Guthrie on the Bladder and Urethra, 1 vol. 8vo., at press.
- Hoblyn's Dictionary of Medical Terms, by Hays, 1 vol. 12mo., at press.
- Harris on the Maxillary Sinus, 1 vol. small 8vo., 165 pages.
- Hornor's Special Anatomy, 2 vols. 8vo., 6th edition, 1114 pages.
- Hodge on the Mechanism of Parturition, in 1 vol. 4to., with many plates, (preparing.)
- Hope on the Heart, 1 vol. 8vo., 572 pages.
- Harrison on the Nervous System, 1 vol. 8vo., 292 pages.
- Jones and Todd on the Ear, 1 vol., preparing.
- Kirby on Animals, many plates, 1 vol. 8vo., 519 pages.
- Lawrence on the Eye, 1 vol. 8vo., 778 pages.
- Lawrence on Ruptures, 1 vol. 8vo., 450 pages.
- Miller's Principles of Surgery, 1 vol. 8vo.
- Medical Botany, with numerous cuts, preparing.
- Maury's Dental Surgery, with plates, a new work, 1 vol. 8vo., 255 pages.
- Mütter's Surgery, 2 vols. 8vo., now in preparation, with cuts.
- Müller's Physiology, 1 vol. 8vo., 886 pages.
- Manual of Ophthalmic Medicine and Surgery, to be published hereafter.
- Medical News and Library, published monthly.
- Meigs's Translation of Colombat De L'Isere on the Diseases of Females, 1 vol. 8vo.
- Prout on the Stomach and Renal Diseases, 1 vol. 8vo., with coloured plates, 465 pages.
- Popular Medicine, by Coates, 1 vol. 8vo., 614 pages.
- Philip on Protracted Indigestion, 1 vol., 240 pages.
- Pereira's Materia Medica, 2 vols. 8vo., 1566 very large and closely printed pages.
- Rogee's Animal and Vegetable Physiology, with many cuts, 2 vols. 8vo., 871 pages.
- Rogee's Outlines of Physiology, 1 vol. 8vo., 516 pages.
- Rigby's System of Midwifery, 1 vol. 8vo., 491 pages.
- Ricord on Venereal, new edition, 1 vol. 8vo., 256 pages.
- Ramsbotham on Parturition, with numerous plates, 1 vol. imperial 8vo., 458 pages.
- Robertson on the Teeth, 1 vol. 8vo., 229 pages.
- Stanley on the Bones, 1 vol. 8vo., preparing.
- Squarey's Agricultural Chemistry, 12mo., 150 pages.
- Select Medical Essays by Chapman and others, 2 vols. 8vo., 1149 pages, double columns.
- Taylor's New Work on Medical Jurisprudence, by Griffith, 1 vol. 8vo., 540 pages.
- Tweedie's Library of Practical Medicine, 3 vols. 8vo., 2d edition, revised, 2016 large pages.
- Traill's Medical Jurisprudence, 1 vol. 8vo., 234 pages.
- Trimmer's Geology and Mineralogy, with many cuts, 1 vol. 8vo., 527 pages.
- Todd's Cyclopædia of Anatomy and Physiology, to be published hereafter.
- Walsh's Diagnosis of the Diseases of the Lungs, 1 vol. 12mo., 310 pages.
- Watson's Principles and Practice of Physic, 1 vol. 8vo., 920 very large pages.
- Wilson's Human Anatomy, with cuts, 1 vol. 8vo., a new and improved edition, 608 pages.
- Wilson's Dissector, or Practical and Surgical Anatomy, by Goddard, with cuts, 1 vol. 12mo., 444 pages.
- Wilson on the Skin, 1 vol. 8vo., 370 pages.
- Youatt on the Horse, by Skinner, with cuts, 448 pages, 1 vol. 8vo.
- Youatt and Clater's Cattle Doctor, 1 vol. 12mo., with cuts, 252 pages.
- Williams's Pathology, or Principles of Medicine, 1 vol. 8vo., 383 pages.
- Williams's Lectures on Stomach, Brain, &c., 1 vol. 8vo., preparing.
- Williams on Respiratory Organs, by Clymer, 1 vol. 8vo., 500 pages.

They have other works in preparation, not included in this list.

JUST ISSUED BY LEA & BLANCHARD.

**WILLIAMS AND CLYMER ON THE RESPIRATORY
ORGANS, ETC.**

**A TREATISE
ON THE
DISEASES OF THE RESPIRATORY ORGANS,**

INCLUDING

THE TRACHEA, LARYNX, LUNGS, AND PLEURA.

By **CHARLES J. B. WILLIAMS, M. D.,**

Consulting Physician to the Hospital for Consumption and Diseases of the Chest; Author of
"Principles of Medicine," &c. &c.

WITH NUMEROUS ADDITIONS AND NOTES.

By **MEREDITH CLYMER, M. D.,**

Physician to the Philadelphia Hospital.

In One neat Svo. Volume, with Cuts.

**NOW READY,
ANOTHER VOLUME OF THE SERIES OF SIR ASTLEY
COOPER'S WORKS.**

ON THE STRUCTURE AND DISEASES OF THE TESTIS.

ILLUSTRATED BY 120 FIGURES.

From the Second London Edition.

By **BRANSBY B. COOPER, Esq.**

"The republication of this splendid volume supplies a want that has been very severely felt from the exhaustion of the first edition of it. . . . The extraordinary merits of this treatise have been so long and so universally acknowledged, that it would be a work of supererogation to represent them in our pages. The practical surgeon who is not master of its contents, cannot be fully aware of the imperfection of his own knowledge on the subject of diseases of the testicle."—*British and Foreign Medical Review.*

AND

ON THE ANATOMY OF THE THYMUS GLAND.

ILLUSTRATED BY 57 FIGURES.

The two works together in one beautiful imperial octavo volume, illustrated in the best style of lithography, and printed and bound to match the author's great work on Hernia, lately published.

BRIGHAM ON MENTAL EXCITEMENT.

REMARKS ON THE INFLUENCE OF
MENTAL CULTIVATION AND MENTAL EXCITEMENT
UPON HEALTH.

Third Edition.

By **A. BRIGHAM, M. D.,**

Superintendent and Physician of the State Lunatic Asylum, Utica, N. Y.

In One Vol. 12mo.

This popular little work has been reprinted in London, Edinburgh and Glasgow. In this third American Edition the author has included all the improvements of the three British editors, and has also added new matter which brings it up to the day, and renders it still more worthy of the favour it has so long enjoyed.

NOW READY,
MEIGS'S TRANSLATION
OF
COLOMBAT DE L'ISÈRE ON THE DISEASES OF FEMALES.
A TREATISE ON THE DISEASES OF FEMALES,
AND ON
THE SPECIAL HYGIENE OF THEIR SEX.

WITH NUMEROUS WOOD-CUTS.

BY COLOMBAT DE L'ISÈRE, M. D.,

Chevalier of the Legion of Honour; late Surgeon to the Hospital of the Rue de Valois, devoted to the Diseases of Females. &c. &c.

TRANSLATED, WITH MANY NOTES AND ADDITIONS,

By C. D. MEIGS, M. D.,

Professor of Obstetrics and Diseases of Women and Children in the Jefferson Medical College, &c. &c.

In One Volume, 8vo.

The notes and addenda of Professor Meigs are very extensive and valuable, bringing the whole up to the day of publication, and giving whatever may be necessary with regard to American practice. It forms a large octavo volume of near 700 pages, with numerous wood-cuts.

LATELY PUBLISHED.

A NEW EDITION OF
WILSON'S HUMAN ANATOMY.
MUCH IMPROVED.

A SYSTEM OF HUMAN ANATOMY,
GENERAL AND SPECIAL.

By ERASMUS WILSON, M. D.,

SECOND AMERICAN EDITION.

EDITED BY

PAUL B. GODDARD, A. M., M. D.,

Lecturer on Anatomy, and Demonstrator in the University of Pennsylvania, &c.

WITH OVER TWO HUNDRED ILLUSTRATIONS,

Beautifully Printed from the Second London Edition.

From the Preface to the Second American Edition.

"The very rapid sale of the first edition of this work, is evidence of its appreciation by the profession, and is most gratifying to the author and American editor. In preparing the present edition no pains have been spared to render it as complete a manual of Anatomy for the medical student as possible. A chapter on Histology has therefore been prefixed, and a considerable number of new cuts added. Among the latter, are some very fine ones of the nerves which were almost wholly omitted from the original work. Great care has also been taken to have this edition correct, and the cuts carefully and beautifully worked, and it is confidently believed that it will give satisfaction, offering a farther inducement to its general use as a Text Book in the various Colleges."

LATELY PUBLISHED,

A NEW AND MUCH IMPROVED EDITION OF

DRUITT'S SURGERY.

THE PRINCIPLES AND PRACTICE OF MODERN SURGERY.

By ROBERT DRUITT, SURGEON.

FROM THE THIRD LONDON EDITION.

ILLUSTRATED BY ONE HUNDRED AND FIFTY-THREE WOOD ENGRAVINGS.

WITH NOTES AND COMMENTS

By JOSHUA B. FLINT, M. M. S. S.

In One Volume, 8vo.

"An unsurpassable compendium not only of surgical but of medical practice."—*London Medical Gazette.*

"It may be said with truth that the work of Mr. Drutt affords a complete, though brief and condensed view, of the entire field of modern surgery. We know of no work on the same subject, having the appearance of a manual, which includes so many topics of interest to the surgeon; and the terse manner in which each has been treated evinces a most enviable quality of mind on the part of the author, who seems to have an innate power of searching out and grasping the leading facts and features of the most elaborate productions of the pen. Notwithstanding various weeding and alterations, we find that there are nearly fifty pages of additional matter in the present volume, and evidently much has been done by both author and publishers to sustain the reputation already acquired. The wood-cuts have been greatly increased in number, and the pencil and graver of William Bagg have added brilliancy to this portion of the book. * * * It is a useful handbook for the practitioner, and we should deem a teacher of surgery unpardonable who did not recommend it to his pupils. In our own opinion, it is admirably adapted to the wants of the student; and with congratulations to the author and publishers—for the latter deserve much credit for the handsome appearance of the volume—on the success of their undertaking, we leave the present edition as a piquant proportion of the ample store of knowledge which it is the good fortune of the rising youth in the profession to be so cheaply provided with in the present day."—*Provincial Med Journal.*

NOW AT PRESS,

ESQUIROL'S GREAT WORK ON INSANITY.

MENTAL MALADIES,

CONSIDERED IN RELATION TO

MEDICINE, HYGIENE, AND MEDICAL JURISPRUDENCE.

By E. ESQUIROL.

Principal Physician of the "Maison Royale des Aliénés de Charenton," &c. &c.

TRANSLATED, WITH ADDITIONS,

By E. K. HUNT, M. D.,

In One Volume, Svo.

This great work has long been considered as the highest authority on the important points of which it treats. The notes and additions of the Translator, Dr. Hunt, will be numerous and valuable, bringing the scientific and medical parts of the treatise up to the day of publication, and embodying the results of the milder and improved American practice in the treatment of the insane.

NOW READY,

ASHWELL ON THE DISEASES OF FEMALES.

A PRACTICAL TREATISE

ON THE

DISEASES PECULIAR TO WOMEN,

ILLUSTRATED BY CASES

DERIVED FROM HOSPITAL AND PRIVATE PRACTICE.

By SAMUEL ASHWELL, M. D.,

Member of the Royal College of Physicians; Obstetric Physician and Lecturer to Guy's Hospital, &c.

WITH ADDITIONS,

By PAUL BECK GODDARD, M. D.

In One Vol. Svo.

CONTENTS.—PART I.—FUNCTIONAL DISEASES.

Introductory Remarks on the Functional Affections of the Female System.—Chlorosis, and Illustrative Cases.—Amenorrhœa, and Illustrative Cases.—Emmenagogues.—Dysmenorrhœa, and Illustrative Cases.—Formulæ of Remedies.—Profuse Menstruation.—Menorrhagia, and Illustrative Cases.—Leucorrhœa, and Illustrative Cases.—Inflammation of the Cervix Uteri, and Illustrative Cases.—Formulæ of Remedies.—Affections attendant on the decline of the Catamenial Function.—Hysteria.—Irritable Uterus or Hysteralgia, and Illustrative Cases.

PART II.—ORGANIC DISEASES.

Of the Organic Diseases of the Internal and External Female Genitals.—General Remarks on the History and Symptoms, Diagnosis, Pathology and Prognosis of the Organic Diseases of the Uterine System.—Of the Tumours of the Walls of the Uterus, characterized by Induration.—On Premature Labour in Pregnancy complicated with Organic Diseases, and Illustrative Cases.—Organic Diseases of the Os and Cervix Uteri.—Congestion of the Uterus.—Acute Metritis.—Chronic Metritis.—Cancer of the Uterus, and Illustrative Cases.—Simple Ulceration of the Cervix and Os Uteri.—Corroding Ulcer of the Uterus.—Cauliflower Excrescence of the Uterus.—Occlusion and Rigidity of the Cervix Uteri, and Illustrative Cases.

PART III.

Organic Diseases of the Mucous Membrane of the Cavity of the Uterus.—Polypus of the Uterus, and illustrative Cases.—Displacements of the Uterus.—Diseases of the Ovaries.—Of the Diseases of the External Organs of Generation in the Female.

APPENDIX.

On the Morbid consequences of undue Lactation, with Illustrative Cases.—Case of Pregnancy complicated with Abdominal Tumours.—Induction of Premature Labour, &c. &c.

A NEW EDITION OF

CHURCHILL ON FEMALES.

THE DISEASES OF FEMALES;

INCLUDING THOSE OF

PREGNANCY AND CHILDBED,

By FLEETWOOD CHURCHILL, M.D.,

Author of "Theory and Practice of Midwifery," &c. &c.

THIRD AMERICAN, FROM THE SECOND LONDON EDITION.

With Illustrations. Edited, with Notes,

By ROBERT M. HUSTON, M. D., &c. &c.

In One Volume, Svo.

"In complying with the demand of the profession in this country for a *third edition*, the Editor has much pleasure in the opportunity thus afforded of presenting the work in its more perfect form. All the additional references and illustrations contained in the English copy, are retained in this."

A MAGNIFICENT AND CHEAP WORK.

SMITH & HORNER'S ANATOMICAL ATLAS.

Just Published, Price Five Dollars in Parts.

AN

ANATOMICAL ATLAS

ILLUSTRATIVE OF THE STRUCTURE OF THE HUMAN BODY.

BY HENRY H. SMITH, M. D.,

Fellow of the College of Physicians, &c.

UNDER THE SUPERVISION OF

WILLIAM E. HORNER, M. D.,

Professor of Anatomy in the University of Pennsylvania.

In One large Volume, Imperial Octavo.

This work is but just completed, having been delayed over the time intended by the great difficulty in giving to the illustrations the desired finish and perfection. It consists of five parts, whose contents are as follows:

PART I. The Bones and Ligaments, with one hundred and thirty engravings.

PART II. The Muscular and Dermoid Systems, with ninety-one engravings.

PART III. The Organs of Digestion and Generation, with one hundred and ninety-one engravings.

PART IV. The Organs of Respiration and Circulation, with ninety-eight engravings.

PART V. The Nervous System and the Senses, with one hundred and twenty-six engravings.

Forming altogether a complete System of Anatomical Plates, of nearly

SIX HUNDRED AND FIFTY FIGURES,

executed in the best style of art, and making one large imperial octavo volume. Those who do not want it in parts can have the work bound in extra cloth or sheep at an extra cost.

This work possesses novelty both in the design and the execution. It is the first attempt to apply engraving on wood, on a large scale, to the illustration of human anatomy, and the beauty of the parts issued induces the publishers to flatter themselves with the hope of the perfect success of their undertaking. The plan of the work is at once novel and convenient. Each page is perfect in itself, the references being immediately under the figures, so that the eye takes in the whole at a glance, and obviates the necessity of continual reference backwards and forwards. The cuts are selected from the best and most accurate sources; and, where necessary, original drawings have been made from the admirable Anatomical Collection of the University of Pennsylvania. It embraces all the late beautiful discoveries arising from the use of the microscope in the investigation of the minute structure of the tissues.

In the getting up of this very complete work, the publishers have spared neither pains nor expense, and they now present it to the profession, with the full confidence that it will be deemed all that is wanted in a scientific and artistic point of view, while, at the same time, its very low price places it within the reach of all.

It is particularly adapted to supply the place of skeletons or subjects, as the profession will see by examining the list of plates now annexed.

"These figures are well selected, and present a complete and accurate representation of that wonderful fabric, the human body. The plan of this Atlas, which renders it so peculiarly convenient for the student, and its superb artistic execution, have been already pointed out. We must congratulate the student upon the completion of this atlas, as it is the most convenient work of the kind that has yet appeared; and, we must add, the very beautiful manner in which it is 'got up' is so creditable to the country as to be flattering to our national pride."—*American Medical Journal*.

"This is an exquisite volume, and a beautiful specimen of art. We have numerous Anatomical Atlases, but we will venture to say that none equal it in cheapness, and none surpass it in faithfulness and spirit. We strongly recommend to our friends, both urban and suburban, the purchase of this excellent work, for which both editor and publisher deserve the thanks of the profession."—*Medical Examiner*.

"We would strongly recommend it, not only to the student, but also to the working practitioner, who, although grown rusty in the toils of his harness, still has the desire, and often the necessity, of refreshing his knowledge in this fundamental part of the science of medicine."—*New York Journal of Medicine and Surg.*

"The plan of this Atlas is admirable, and its execution superior to any thing of the kind before published in this country. It is a real labour-saving affair, and we regard its publication as the greatest boon that could be conferred on the student of anatomy. It will be equally valuable to the practitioner, by affording him an easy means of recalling the details learned in the dissecting room, and which are soon forgotten."—*American Medical Journal*.

"It is a beautiful as well as particularly useful design, which should be extensively patronized by physicians, surgeons and medical students."—*Boston Med. and Surg. Journal*.

"It has been the aim of the author of the Atlas to comprise in it the valuable points of all previous works, to embrace the latest microscopical observations on the anatomy of the tissues, and by placing it at a moderate price to enable all to acquire it who may need its assistance in the dissecting or operating room, or other field of practice."—*Western Journal of Med. and Surgery*.

"These numbers complete the series of this beautiful work, which fully merits the praise bestowed upon the earlier numbers. We regard all the engravings as possessing an accuracy only equalled by their beauty, and cordially recommend the work to all engaged in the study of anatomy."—*New York Journal of Medicine and Surgery*.

"A more elegant work than the one before us could not easily be placed by a physician upon the table of his student."—*Western Journal of Medicine and Surgery*.

"We were much pleased with Part I, but the Second Part gratifies us still more, both as regards the attractive nature of the subject, (The Dermoid and Muscular Systems), and the beautiful artistic execution of the illustrations. We have here delineated the most accurate microscopic views of some of the tissues, as, for instance, the cellular and adipose tissues, the epidermis, rete mucosum and cutis vera, the sebaceous and perspiratory organs of the skin, the perspiratory glands and hairs of the skin, and the hair and nails. Then follows the general anatomy of the muscles, and, lastly, their separate delineations. We would recommend this Anatomical Atlas to our readers in the very strongest terms."—*New York Journal of Medicine and Surgery*.

LIST OF
THE ILLUSTRATIONS
EMBRACING
SIX HUNDRED AND THIRTY-SIX FIGURES
IN SMITH AND HORNER'S ATLAS.

~~~~~

A HIGHLY-FINISHED VIEW OF THE BONES OF THE HEAD, . . . . . facing the title-page.  
VIEW OF CUVIER'S ANATOMICAL THEATRE, . . . . . vignette.

~~~~~

PART I.—BONES AND LIGAMENTS.

- | | |
|--|---|
| <p>Fig.</p> <p>1 Front view of adult skeleton.
2 Back view of adult skeleton.
3 Fœtal skeleton.
4 Cellular structure of femur.
5 Cellular and compound structure of tibia.
6 Fibres of compact matter of bone.
7 Concentric lamellæ of bone.
8 Compact matter under the microscope.
9 Haversian canals and lacunæ of bone.
10 Vessels of compact matter.
11 Minute structure of bones.
12 Ossification in cartilage.
13 Ossification in the scapula.
14 Puncta ossificationis in femur.
15 Side view of the spinal column.
16 Epiphyses and diaphysis of bone.
17 External periosteum.
18 Punctum ossificationis in the head.
19 A cervical vertebra.
20 The atlas. 21 The dentata.
22 Side view of the cervical vertebræ.
23 Side view of the dorsal vertebræ.
24 A dorsal vertebra.
25 Side view of the lumbar vertebræ.
26 Side view of one of the lumbar vertebræ.
27 Perpendicular view of the lumbar vertebræ.
28 Anterior view of sacrum.
29 Posterior view of sacrum.
30 The bones of the coccyx.
31 Outside view of the innominatum.
32 Inside view of the innominatum.
33 Anterior view of the male pelvis.
34 Anterior view of the female pelvis.
35 Front of the thorax. 36 The first rib.
37 General characters of a rib.
38 Front view of the sternum.
39 Head of a Peruvian Indian.
40 Head of a Choctaw Indian.
41 Front view of the os frontis.
42 Under surface of the os frontis.
43 Internal surface of the os frontis.
44 External surface of the parietal bones.
45 Internal surface of the parietal bone.
46 External surface of the os occipitis.
47 Internal surface of the os occipitis.
48 External surface of the temporal bone.
49 Internal surface of the temporal bone.
50 Internal surface of the sphenoid bone.
51 Anterior surface of the sphenoid bone.
52 Posterior surface of the ethmoid bone.
53 Front view of the bones of the face.
54 Outside of the upper maxilla.
55 Inside of the upper maxilla.
56 Posterior surface of the palate bone.
57 The nasal bones.
58 The os unguis. 59 Inferior spongy bone.
60 Right malar bone. 61 The vomer.
62 Inferior maxillary bone.
63 Sutures of the vault of the cranium.</p> | <p>Fig.</p> <p>64 Sutures of the posterior of the cranium.
65 Diploe of the cranium.
66 Inside of the base of the cranium.
67 Outside of the base of the cranium.
68 The facial angle. 69 The fontanels.
70 The os hyoides.
71 Posterior of the scapula.
72 Axillary margin of the scapula.
73 The clavicle. 74 The humerus.
75 The ulna. 76 The radius.
77 The bones of the carpus.
78 The bones of the hand.
79 Articulation of the carpal bones.
80 Anterior view of the femur.
81 Posterior view of the femur.
82 The tibia. 83 The fibula.
84 Anterior view of the patella.
85 Posterior view of the patella.
86 The os calcis. 87 The astragalus.
88 The naviculare. 89 The cuboid bone.
90 The three cuneiform bones.
91 Top of the foot.
92 The sole of the foot. 93 Cells in cartilage.
94 Articular cartilage under the microscope.
95 Costal cartilage under the microscope.
96 Magnified section of cartilage.
97 Magnified view of fibro-cartilage.
98 White fibrous tissue.
99 Yellow fibrous tissue.
100 Ligaments of the jaw.
101 Internal view of the same.
102 Vertical section of the same.
103 Anterior vertebral ligaments.
104 Posterior vertebral ligaments.
105 Yellow ligaments.
106 Costo-vertebral ligaments.
107 Occipito-aldoidien ligaments.
108 Posterior view of the same.
109 Upper part of the same.
110 Moderator ligaments.
111 Anterior pelvic ligaments.
112 Posterior pelvic ligaments.
113 Sterno-clavicular ligaments.
114 Scapulo-humeral articulation.
115 External view of elbow joint.
116 Internal view of elbow joint.
117 Ligaments of the wrist.
118 Diagram of the carpal synovial membrane
119 Ligaments of the hip joint.
120 Anterior view of the knee joint.
121 Posterior view of the knee joint.
122 Section of the right knee joint.
123 Section of the left knee joint.
124 Internal side of the ankle joint.
125 External side of the ankle joint.
126 Posterior view of the ankle joint.
127 Ligaments of the sole of the foot.
128 Vertical section of the foot.</p> |
|--|---|

PART II.—DERMOID AND MUSCULAR SYSTEMS.

- | | |
|--|--|
| <p>129 Muscles on the front of the body, <i>full length</i>.
131 Muscles on the back of the body, <i>full length</i>.
130 The cellular tissue. 132 Fat vesicles.</p> | <p>133 Blood-vessels of fat.
134 Cell membrane of fat vesicles.
135 Magnified view of the epidermis.</p> |
|--|--|

Illustrations to Smith and Horner's Atlas, continued.

- Fig.
 136 Cellular tissue of the skin.
 137 Rete mucosum, &c., of foot.
 138 Epidermis and rete mucosum.
 139 Cutis vera, magnified.
 140 Cutaneous papillæ.
 141 Internal face of cutis vera.
 142 Integuments of foot under the microscope.
 143 Cutaneous glands. 144 Sudoriferous organs.
 145 Sebaceous glands and hairs.
 146 Perspiratory gland magnified.
 147 A hair under the microscope.
 148 A hair from the face under the microscope.
 149 Follicle of a hair. 150 Arteries of a hair.
 151 Skin of the beard magnified.
 152 External surface of the thumb nail.
 153 Internal surface of the thumb nail.
 154 Section of nail of fore finger.
 155 Same highly magnified.
 156 Development of muscular fibre.
 157 Another view of the same.
 158 Arrangement of fibres of muscle.
 159 Discs of muscular fibre.
 160 Muscular fibre broken transversely.
 161 Striped elementary fibres magnified.
 162 Striæ of fibres from the heart of an ox.
 163 Transverse section of biceps muscle.
 164 Fibres of the pectoralis major.
 165 Attachment of tendon to muscle.
 166 Nerve terminating in muscle.
 167 Superficial muscles of face and neck.
 168 Deep-seated muscles of face and neck.
 169 Lateral view of the same.
 170 Lateral view of superficial muscles of face.
 171 Lateral view of deep-seated muscles of face.
 172 Tensor tarsi or muscle of Horner.
 173 Pterygoid muscles. 174 Muscles of neck.
 175 Muscles of tongue.
 176 Fascia profunda colli.
 177 Superficial muscles of thorax.
 178 Deep-seated muscles of thorax.
 179 Front view of abdominal muscles.

- Fig.
 180 Side view of abdominal muscles.
 181 External parts concerned in hernia.
 182 Internal parts concerned in hernia.
 183 Deep-seated muscles of trunk.
 184 Inguinal and femoral rings.
 185 Deep-seated muscles of neck.
 186 Superficial muscles of back.
 187 Posterior parietes of chest and abdomen.
 188 Under side of diaphragm.
 189 Second layer of muscles of back.
 190 Muscles of vertebral gutter.
 191 Fourth layer of muscles of back.
 192 Muscles behind cervical vertebræ.
 193 Deltoid muscle.
 194 Anterior view of muscles of shoulder.
 195 Posterior view of muscles of shoulder.
 196 Another view of the same.
 197 Fascia brachialis.
 198 Fascia of the fore-arm.
 199 Muscles on the back of the hand.
 200 Muscles on the front of the arm.
 201 Muscles on the back of the arm.
 202 Pronators of the fore-arm.
 203 Flexor muscles of fore-arm.
 204 Muscles in palm of hand.
 205 Deep flexors of the fingers.
 206 Superficial extensors.
 207 Deep-seated extensors.
 208 Rotator muscles of the thigh.
 209 Muscles on the back of the hip.
 210 Deep muscles on the front of thigh.
 211 Superficial muscles on the front of thigh.
 212 Muscles on the back of the thigh.
 213 Muscles on front of leg.
 214 Muscles on back of leg.
 215 Deep-seated muscles on back of leg.
 216 Muscles on the sole of the foot.
 217 Another view of the same.
 218 Deep muscles on front of arm.
 219 Deep muscles on back of arm.

PART III.—ORGANS OF DIGESTION AND GENERATION.

- 220 Digestive organs in their whole length.
 221 Cavity of the mouth.
 222 Labial and buccal glands.
 223 Teeth in the upper and lower jaws.
 224 Upper jaw, with sockets for teeth.
 225 Lower jaw, with sockets for teeth.
 226 Under side of the teeth in the upper jaw.
 227 Upper side of the teeth in the lower jaw.
 228 to 235. Eight teeth, from the upper jaw.
 236 to 243. Eight teeth from the lower jaw.
 244 to 251. Side view of eight upper jaw teeth.
 252 to 259. Side view of eight lower jaw teeth.
 260 to 265. Sections of eight teeth.
 266 to 267. Enamel and structure of two of the teeth.
 268 Bicuspis tooth under the microscope.
 269 Position of enamel fibres.
 270 Hexagonal enamel fibres.
 271 Enamel fibres very highly magnified.
 272 A very highly magnified view of fig. 268.
 273 Internal portion of the dental tubes.
 274 External portion of the dental tubes.
 275 Section of the crown of a tooth.
 276 Tubes at the root of a bicuspis.
 277 Upper surface of the tongue.
 278 Under surface of the tongue.
 279 Periglottis turned off the tongue.
 280 Muscles of the tongue.
 281 Another view of the same.
 282 Section of the tongue.
 283 Styloid muscles, &c.
 284 Section of a gustatory papilla.
 285 View of another papilla.
 286 Root of the mouth and soft palate.
 287 Front view of the pharynx and muscles.
 288 Back view of the pharynx and muscles.
 289 Under side of the soft palate.
 290 A lobule of the parotid gland.
 291 Salivary glands.
 292 Internal surface of the pharynx.
 293 External surface of the pharynx.
 294 Vertical section of the pharynx.
 295 Muscular coat of the œsophagus.
 296 Longitudinal section of the œsophagus.
 297 Parietes of the abdomen.
 298 Reflexions of the peritoneum.
 299 Viscera of the chest and abdomen.
 300 Another view of the same.
 301 The intestines in situ.
 302 Stomach and œsophagus.
 303 Front view of the stomach.
 304 Interior of the stomach.
 305 The stomach and duodenum.
 306 Interior of the duodenum.
 307 Gastric glands.
 308 Mucous coat of the stomach.
 309 An intestinal villus. 310 Its vessels.
 311 Glands of the stomach magnified.
 312 Villus and lacteal.
 313 Muscular coat of the ileum.
 314 Jejunum distended and dried.
 315 Follicles of Lieberkuhn
 316 Glands of Brunner. 317 Intestinal glands.
 318 Valvule conniventes. 319 Ileo-colic valve.
 320 Villi and intestinal follicles.
 321 Veins of the ileum.
 322 Villi filled with chyle. 323 Peyer's glands
 324 Villi of the jejunum under the microscope.
 325 The cæcum. 326 The mesocolon and colon.
 327 Muscular coat of the colon.

- Fig.
 328 Muscular fibres of the rectum.
 329 Curvatures of the large intestine.
 350 Mucous follicles of the rectum.
 331 Rectal pouches.
 332 Follicles of the colon, highly magnified.
 333 Folds and follicles of the stomach.
 334 Follicles, &c. of the jejunum.
 335 Villi and follicles of the ileum.
 336 Muciparous glands of the stomach.
 337 Ileum inverted, &c.
 338 Glands of Peyer magnified.
 339 Peritoneum of the liver injected.
 340 Liver in situ.
 341 Under surface of the liver. 342 Hepatic vein.
 343 Parenchyma of the liver.
 344 Hepatic blood-vessels. 345 Biliary ducts.
 346 Angular lobules of the liver.
 347 Rounded hepatic lobules.
 348 Coats of the gall bladder.
 349 Gall bladder injected.
 350 Vena portarum.
 351 External face of the spleen.
 352 Internal face of the spleen.
 353 Splenic vein.
 354 Pancreas &c., injected. 355 Urinary organs.
 356 Right kidney and capsule.
 357 Left kidney and capsule.
 358 Kidney under the microscope.
 359 The ureter. 360 Section of right kidney.
 361 Section of the left kidney.
 362 Pyramids of Malpighi.
 363 Lobes of the kidney.
 364 Renal arteries, &c., injected.
 365 Section of the kidney highly magnified.
 366 Copora Malpighiana. 367 Same magnified.
 368 Tubuli uriniferi. 369 Corpora Wolffiana.
 370 The bladder and urethra, full length.
 371 Muscular coat of the bladder.
 372 Another view of the same.

- Fig.
 373 Sphincter apparatus of the bladder.
 374 Prostate and vesiculæ seminales.
 375 Side view of the pelvic viscera.
 376 The glans penis injected.
 377 The penis distended and dried.
 378 Section of the same.
 379 Vertical section of the male pelvis, &c.
 380 Septum pectiniforme.
 381 Arteries of the penis.
 382 Vertical section of the urethra.
 383 Vesiculæ seminales injected.
 384 Muscles of the male perineum.
 385 Interior of the pelvis, seen from above.
 386 Testis in the fœtus.
 387 Diagram of the descent of the testis.
 388 Tunica vaginalis testis.
 389 Transverse section of the testis.
 390 Relative position of the prostate.
 391 Vas deferens.
 392 Vertical section of the bladder.
 393 The testicle injected with mercury.
 394 Another view.
 395 Minute structure of the testis.
 396 Female generative organs.
 397 Another view of the same.
 398 External organs in the fœtus.
 399 Muscles of the female perineum.
 400 Side view of the female pelvis, &c.
 401 Relative position of the female organs.
 402 Section of the uterus, &c.
 403 Fallopian tubes, ovaries, &c.
 404 Front view of the mammary gland.
 405 The same after removal of the skin.
 406 Side view of the breast.
 407 Origin of lactiferous ducts.
 408 Lactiferous tubes during lactation.
 409 Minute termination of a tube.
 410 Ducts injected; after Sir Astley Cooper.

PART IV.—ORGANS OF RESPIRATION AND CIRCULATION.

- 411 Front view of the thyroid cartilage.
 412 Side view of the thyroid cartilage.
 413 Posterior of the arytenoid cartilage.
 414 Anterior of the arytenoid cartilage.
 415 Epiglottis cartilage. 416 Cricoid cartilage.
 417 Ligaments of the larynx.
 418 Side view of the same.
 419 The thyroid gland.
 420 Internal surface of the larynx.
 421 Crico-thyroid muscles.
 422 Crico-arytenoid muscles.
 423 Articulations of the larynx.
 424 Vertical section of the larynx.
 425 The vocal ligaments. 426 Thyms gland.
 427 Front view of the lungs.
 428 Back view of the lungs.
 429 The trachea and bronchia.
 430 Lungs, heart, &c.
 431 First appearance of the blood-vessels.
 432 Capillary vessels magnified.
 433 Another view of the same.
 434 Blood globules.
 435 Another view of the same.
 436 The mediastina.
 437 Parenchyma of the lung.
 438 The heart and pericardium.
 439 Anterior view of the heart.
 440 Posterior view of the heart.
 441 Anterior view of its muscular structure.
 442 Posterior view of the same.
 443 Interior of the right ventricle.
 444 Interior of the left ventricle.
 445 Mitral valve, the size of life.
 446 The auriculo-ventricular valves.
 447 Section of the ventricles.
 448 The arteries from the arch of the aorta.
 449 The arteries of the neck, the size of life.
 450 The external carotid artery.
 451 A front view of arteries of head and neck.
 452 The internal maxillary artery.
 453 Vertebral and carotid arteries with the aorta.
 454 Axillary and brachial arteries.
 455 The brachial artery.
 456 Its division at the elbow.
 457 One of the anomalies of the brachial artery.
 458 Radial and ulnar arteries.
 459 Another view of the same.
 460 The arcus sublimis and profundus.
 461 The aorta in its entire length.
 462 Arteries of the stomach and liver.
 463 Superior mesenteric artery.
 464 Inferior mesenteric artery.
 465 Abdominal aorta.
 466 Primitive iliac and femoral arteries.
 467 Perineal arteries of the male.
 468 Position of the arteries in the inguinal canal.
 469 Internal iliac artery. 470 Femoral artery.
 471 Gluteal and ischiatic arteries.
 472 Branches of the ischiatic artery.
 473 Popliteal artery.
 474 Anterior tibial artery.
 475 Posterior tibial artery.
 476 Superficial arteries on the top of the foot.
 477 Deep-seated arteries on the top of the foot.
 478 Posterior tibial artery at the ankle.
 479 The plantar arteries.
 480 Arteries and veins of the face and neck.
 481 Great vessels from the heart.
 482 External jugular vein.
 483 Lateral view of the vertebral sinuses.
 484 Posterior view of the vertebral sinuses.
 485 Anterior view of the vertebral sinuses.
 486 Superficial veins of the arm.
 487 The same at the elbow.

- Fig.
 488 The veins of the hand.
 489 The great veins of the trunk.
 490 Positions of the arteries and veins of the trunk.
 491 The venæ cavæ. 492 The vena portarum.
 493 Deep veins of the back of the leg.
 494 Positions of the veins to the arteries in the arm. 495 Superficial veins of the thigh.
 496 Saphena vein.
 497 Superficial veins of the leg.
 498 Lymphatics of the upper extremity.

- Fig.
 499 The lymphatics and glands of the axilla.
 500 The femoral and aortic lymphatics.
 501 The lymphatics of the small intestines.
 502 The thoracic duct.
 503 The lymphatics of the groin.
 504 Superficial lymphatics of the thigh.
 505 Lymphatics of the jejunum.
 506 Deep lymphatics of the thigh.
 507 Superficial lymphatics of the leg.
 508 Deep lymphatics of the leg.

PART V.—THE NERVOUS SYSTEM AND SENSES.

- 509 Dura mater cerebri and spinalis.
 510 Anterior view of brain and spinal marrow.
 511 Anterior view of the spinal marrow, &c.
 512 Lateral view of the spinal marrow, &c.
 513 Posterior view of the spinal marrow, &c.
 514 Decussation of Mitischelli.
 515 Origins of the spinal nerves.
 516 Anterior view of spinal marrow and nerves.
 517 Posterior view of spinal marrow and nerves.
 518 Anterior spinal commissure.
 519 Posterior spinal commissure.
 520 Transverse section of the spinal marrow.
 521 Dura mater and sinuses.
 522 Sinuses laid open.
 523 Sinuses at the base of the cranium.
 524 Pons Varolii, cerebellum, &c.
 525 Superior face of the cerebellum.
 526 Inferior face of the cerebellum.
 527 Another view of the cerebellum.
 528 View of the arbor vitæ, &c.
 529 Posterior view of the medulla oblongata.
 530 A vertical section of the cerebellum.
 531 Another section of the cerebellum.
 532 Convulsions of the cerebrum.
 533 The cerebrum entire.
 534 A section of its base.
 535 The corpus callosum entire.
 536 Diverging fibres of the cerebrum, &c.
 537 Vertical section of the head.
 538 Section of the corpus callosum.
 539 Longitudinal section of the brain.
 540 View of a dissection by Gall.
 541 The commissures of the brain.
 542 Lateral ventricles.
 543 Corpora striata-fornix, &c.
 544 Fifth ventricle and lyra.
 545 Another view of the lateral ventricles.
 546 Another view of the ventricles.
 547 Origins of the 4th and 5th pairs of nerves.
 548 The circle of Willis.
 549 A side view of the nose.
 550 The nasal cartilages.
 551 Bones and cartilages of the nose.
 552 Oval cartilages, &c.
 553 Schneiderian membrane.
 554 External parietes of the left nostril.
 555 Arteries of the nose.
 556 Pituitary membrane injected.
 557 Posterior nares. 558 Front view of the eye.
 559 Side view of the eye.
 560 Posterior view of the eyelids, &c.
 561 Glandulæ palpebrarum.
 562 Lachrymal canals.
 563 Muscles of the eyeball.
 564 Side view of the eyeball.
 565 Longitudinal section of the eyeball.
 566 Horizontal section of the eyeball.
 567 Anterior view of a transverse section.
 568 Posterior view of a transverse section.
 569 Choroid coat injected.
 570 Veins of the choroid coat.
 571 The iris. 572 The retina and lens.
 573 External view of the same.
 574 Vessels in the conjunctiva.
 575 Retina, injected and magnified.
 576 Iris, highly magnified.
 577 Vitreous humour and lens.
 578 Crystalline adult lens.
 579 Lens of the fœtus, magnified.
 580 Side view of the lens.
 581 Membrana pupillaris.
 582 Another view of the same.
 583 Posterior view of the same.
 584 A view of the left ear.
 585 Its sebaceous follicles.
 586 Cartilages of the ear.
 587 The same with its muscles.
 588 The cranial side of the ear.
 589 Meatus auditorius externus, &c.
 590 Labyrinth and bones of the ear.
 591 Full view of the malleus. 592 The incus.
 593 Another view of the malleus.
 594 A front view of the stapes.
 595 Magnified view of the stapes.
 596 Magnified view of the incus.
 597 Cellular structure of the malleus.
 598 Magnified view of the labyrinth.
 599 Natural size of the labyrinth.
 600 Labyrinth laid open and magnified.
 601 Labyrinth, natural size.
 602 Labyrinth of a fœtus.
 603 Another view of the same.
 604 Nerves of the labyrinth.
 605 A view of the vestibule, &c.
 606 Its soft parts, &c.
 607 An ampulla and nerve.
 608 Plan of the cochlea.
 609 Lamina spiralis, &c.
 610 The auditory nerve.
 611 Nerve on the lamina spiralis.
 612 Arrangement of the cochlea.
 613 Veins of the cochlea, highly magnified.
 614 Opening of the Eustachian tube in the throat.
 615 Portio mollis of the seventh pair of nerves.
 616 The olfactory nerves.
 617 The optic and seven other pairs of nerves.
 618 Third, fourth and sixth pairs of nerves.
 619 Distribution of the fifth pair.
 620 The facial nerve.
 621 The hypo-glossal nerves.
 622 A plan of the eighth pair of nerves.
 623 The distribution of the eighth pair.
 624 The great sympathetic nerve.
 625 The brachial plexus.
 626 Nerves of the front of the arm.
 627 Nerves of the back of the arm.
 628 Lumbar and ischiatic nerves.
 629 Posterior branches to the hip, &c.
 630 Anterior crural nerve.
 631 Anterior tibial nerve.
 632 Branches of the popliteal nerve.
 633 Posterior tibial nerve on the leg.
 634 Posterior tibial nerve on the foot.

NOW READY.
TAYLOR'S MEDICAL JURISPRUDENCE.

MEDICAL JURISPRUDENCE,

By ALFRED S. TAYLOR,

Lecturer on Medical Jurisprudence and Chemistry at Guy's Hospital, &c.

With numerous Notes and Additions, and references to American practice and law.

By R. E. GRIFFITH, M. D.

In One Volume, 8vo.

Contents.—POISONING—WOUNDS—INFANTICIDE—DROWNING—HANGING—STRANGULATION—SUFFOCATION—LIGHTNING—COLD—STARVATION—RAPE—PREGNANCY—DELIVERY—BIRTH—INHERITANCE—LEGITIMACY—INSANITY, &c. &c.

"The promise of the first parts was so full, and the ability displayed was so unquestionable, that all who felt jealous of the honour of our national medical literature hailed with delight the appearance of a comprehensive and original work of English growth, on one of the most important and difficult departments of our science. Everywhere, indeed, we find evidences of extensive reading and laborious research; the copious literature, both of France and Germany, on the subject of Medical Jurisprudence, is laid under frequent contribution, and we have the pleasure of meeting with the accumulated stores of science and experience on this branch of knowledge, it may be said of the whole world, condensed and made accessible in this admirable volume. It is, in fact, not only the fullest and most satisfactory book we have ever consulted on the subject of which it treats, but it is also one of the most masterly books we have ever perused. So much precise individual knowledge, under guidance of judgment and critical powers of so high an order, as meet us in every page of Mr. Taylor's work, we have rarely encountered."—*London Med. Gazette.*

"We recommend Mr. Taylor's work as the ablest, most comprehensive, and, above all, the most practically useful book which exists on the subject of legal medicine. Any man of sound judgment, who has mastered the contents of Taylor's 'Medical Jurisprudence,' may go into a court of law with the most perfect confidence of being able to acquit himself creditably."—*Medico-Chirurgical Review.*

"The work of Mr. Taylor may be regarded as a full systematic treatise on the subject of Medical Jurisprudence. It certainly presents a very excellent view, which may be named both full and condensed, of the present state of knowledge on Medical Jurisprudence. The author has illustrated many of the doubtful points of the science by good and interesting cases. He has, in general, shown much judgment in the examination of the difficult and ambiguous cases; but the whole treatise is so ably prepared that we have no hesitation in recommending it as a very useful guide to the student."—*Edinburgh Med. and Surg. Journal.*

"The most elaborate and complete work that has yet appeared. It contains an immense quantity of cases, lately tried, which entitles it to be considered now what Beck was in its day."—*Dublin Medical Journal.*

"Medical Jurisprudence ought to be a prominent branch of the studies of every lawyer: but what books shall they read? We have seen none so calculated to serve the purpose of a text-book as this manual. Mr. Taylor possesses the happy art of expressing himself on a scientific topic in intelligible language. Its size fits it to be a circuit companion."—*Law Times.*

ALSO, NOW READY,
MILLER'S PRINCIPLES OF SURGERY.

THE PRINCIPLES OF SURGERY.

By JAMES MILLER, F. R. S. E., F. R. C. S. E.,

Professor of Surgery in the University of Edinburgh, &c.

In One neat 8vo. Volume,

To match in size with Fergusson's Operative Surgery.

"No one can peruse this work without the conviction that he has been addressed by an accomplished surgeon, endowed with no mean literary skill or doubtful good sense, and who knows how to grace or illumine his subjects with the later lights of our rapidly advancing physiology. The book deserves a strong recommendation, and must secure itself a general perusal."—*Medical Times.*

BARTLETT'S PHILOSOPHY OF MEDICINE.

AN ESSAY ON
THE PHILOSOPHY OF MEDICAL SCIENCE.

IN TWO PARTS.

"I trust that I have got hold of my pitcher by the right handle."—*John Joachim Beecher.*

By ELISHA BARTLETT, M. D.,

Professor of the Theory and Practice of Medicine in the University of Maryland.

In One neat Octavo Volume.

"We have not room in the present number of our journal, for such a notice of this philosophical and elegant work, as its merits justly demand. It is evidently destined to create quite a sensation in the medical world; and we shall therefore give an extended analysis of its contents, accompanied by some comments in our January number. In the mean time, we advise all our readers to purchase and carefully read it."—*N. Y. Journal of Medicine.*

☞ Gentlemen who receive this Catalogue would much oblige the Publishers, if, after reading it, they would hand it, or the following eight pages, to their friends.

THE EXPLORING EXPEDITION.

LEA AND BLANCHARD,
PHILADELPHIA,

ARE PREPARING FOR PUBLICATION, AND WILL SHORTLY ISSUE,

THE NARRATIVE OF THE
UNITED STATES EXPLORING EXPEDITION
DURING THE YEARS

1838, 1839, 1840, 1841, AND 1842.

By CHARLES WILKES, U. S. N.,

COMMANDER OF THE EXPEDITION, ETC., ETC.

In Five Octavo Volumes, of about 2500 Pages; with over 300 Cuts,
and Maps.

As the history of the only Expedition yet commissioned by our Government to explore foreign countries, this work must present features of unusual interest to every American. Much curiosity has been excited respecting this enterprise, from the length of time during which it was in preparation, and from the various conflicting reports which were circulated during its protracted absence.

The Squadron—six vessels—sailed from Norfolk in August, 1838, and after making important observations on the voyage, via. Madeira, arrived at Rio, when their investigations were successfully prosecuted. Sailing thence for Cape Horn, they examined the commercial capabilities of Rio Negro. Arriving at Cape Horn, two of the vessels were dispatched to investigate Palmer's Land, and other Antarctic Regions; whence, after encountering great danger, they returned safely, and sailed with the whole Squadron for Valparaiso and Callao. After making important observations on the West Coast of South America, regarding the commerce, political history, &c., of that portion of America, they sailed for Sydney, cruising among the numerous groups of islands of the Pacific Archipelago, where the results were peculiarly important, as connected with the commerce and Whale Fishery of our country, as well as the aid they were able to bring to the various missionary establishments engaged in the introduction of Christianity and civilization. After remaining some time at Sydney, pursuing important investigations, they sailed for the Antarctic Regions, leaving behind them the corps of Naturalists to explore that singular country, the observations on which will be found of great interest. The Squadron then proceeding South, made the brilliant discovery of the ANTARCTIC CONTINENT, on the 19th January, 1840, in 160° east longitude, along which they coasted, in a westerly direction, to 95° east, a distance of 1500 miles. On the return of the vessels, they touched at New Zealand, when the Naturalists were again taken on board. They next proceeded to the Friendly Islands of Cook, the Feejee Group, and reached the Sandwich Islands late in the fall, which precluded them from going to the North-West Coast that season. The Paumotu, Samoan, and King's Mills group of islands were visited, and a particular examination made of the Island of Hawaii, its interesting craters and volcanic eruptions. In the spring, the Squadron proceeded to the Oregon Territory, now exciting so much interest in a political point of view; it was thoroughly examined in regard to its commercial and agricultural prospects, &c. Here the Peacock was lost on the dangerous bar of the Columbia river. After the Oregon, Upper California was examined. The Expedition now returned to the Sandwich Islands, and thence sailed for Manilla and Singapore, touching at the Philippine Islands, and passing through the Sooloo Sea, the channels of which being correctly ascertained, will greatly benefit the important navigation to China.

Touching at the Cape of Good Hope and Rio, this important and successful Exploring Expedition finally, on the 10th of June, 1842, arrived at New York, after an absence of three years and ten months.

During the whole Voyage, every opportunity was taken to procure information, investigate unknown or little frequented parts of those seas now reached by our commerce, and thoroughly to institute scientific investigations of all kinds. To illustrate these, a vast number of drawings and maps have been executed; but the chief objects in view were of a practical nature. Numerous regulations have been made with the rulers of various islands, to secure the safety of our commerce, now daily increasing in those seas. In short, every thing has been done which lay in the power of officers or men to make the Expedition redound to the interest and honour of the Country; and in the volumes to be issued will be found its history and embodiment.

EAST'S REPORTS.

LEA AND BLANCHARD, PHILADELPHIA,

HAVE IN PRESS, AND WILL SHORTLY PUBLISH,

REPORTS OF CASES

ADJUDGED AND DETERMINED

IN THE

COURT OF KING'S BENCH;

WITH

TABLES OF THE NAMES OF THE CASES, AND PRINCIPAL MATTERS.

By EDWARD HYDE EAST, Esq.,

OF THE INNER TEMPLE, BARRISTER AT LAW,

EDITED, WITH NOTES AND REFERENCES.

By G. M. WHARTON, ESQ.,

OF THE PHILADELPHIA BAR.

IN this new and improved Edition, the sixteen original will be comprised in eight large Royal Octavo volumes, printed with beautiful Long Primer type, on paper manufactured expressly for the purpose, and every care will be taken, in their passage through the press, to insure perfect accuracy.

The price of the work handsomely bound in Law Sheep, to those who subscribe before the day of publication, will be only Twenty-Five Dollars, being a great reduction from Seventy-Two Dollars, the publishing price of the former edition. The publishers trust that this moderate charge will insure a liberal subscription.

Twenty-seven years have elapsed since the publication of the last American Edition of East's Reports by Mr. Day, and the work has become exceedingly scarce. This is the more to be regretted, as the great value of these Reports, arising from the variety and importance of the subjects considered in them, and the fulness of the decisions on the subjects of Mercantile Law, renders them absolutely necessary to the American Lawyer. The judgments of Lord Kenyon and Lord Ellenborough, on all Practical and commercial points, are of the highest authority, and the volumes which contain them should form part of every well-selected law library.

These considerations have induced the publishers to prepare a new edition, in which nothing should be omitted. The editor, G. M. Wharton, Esq., proposes to add a brief annotation of the leading cases in the Reports, with references to the more important decisions upon similar points in the principal commercial States of the Union, while the Notes of Mr. Day will be retained, and, though the whole work will be compressed into eight volumes, the original Cases, as reported, will be preserved entire. At the head of each Report, a reference will be had to the paging of the English Edition, directly under the name of the case, and the original indexes will be incorporated together at the end of each volume of this Edition.

Subscriptions received by the publishers, Lea & Blanchard, Philadelphia, and the principal Booksellers throughout the Union.

LIBRARY OF STANDARD LITERATURE.

LEA & BLANCHARD are publishing, under the general title of The Library of Standard Literature, a number of valuable works on History, Biography, &c. &c., which merit a permanent place in every library. Among them are contained the following:

NIEBUHR'S HISTORY OF ROME.

Complete in Two large 8vo. Volumes, or Five Parts, Paper, at \$1 each.

THE HISTORY OF ROME,

BY B. G. NIEBUHR.

TRANSLATED BY

JULIUS CHARLES HARE, M. A.
CONNOP THIRLWALL, M. A.

WILLIAM SMITH, Ph. D. AND
LEONARD SCHMITZ, Ph. D.

WITH A MAP.

The last three parts of this valuable work have never before been published in this country, having only lately been printed in Germany, and translated in England. They complete the history, bringing it down to the time of Constantine.

"Here we close our remarks upon this memorable work; a work which, of all that have appeared in our age, is the best fitted to excite men of learning to intellectual activity; from which the most accomplished scholar may gather fresh stores of knowledge, to which the most experienced politician may resort for theoretical and practical instruction, and which no person can read as it ought to be read, without feeling the better and more generous sentiments of his common human nature enlivened and strengthened."—*Edinburgh Review*, Jan., 1833.

"The world has now in Niebuhr an imperishable model."—*Edinburgh Review*, Jan., 1844.

"At length the American reader can have easy access to the unrivaled History of Rome, by Niebuhr, a work which combines deep critical research with full political disquisition and comparison."—*Colonization Herald*.

"The History of Niebuhr has thrown new light on our knowledge of Roman affairs, to a degree of which those unacquainted with it can scarcely form an idea."—*Quarterly Review*.

"It is since I saw you that I have been devouring with the most intense admiration the third volume of Niebuhr. The clearness and comprehensiveness of all his military details is a new feature in that wonderful mind, and how inimitably beautiful is that brief account of Terni!"—*Dr. Arnold (Life, vol. 2)*.

This edition will comprise in the fourth and fifth volumes, the Lectures of Professor Niebuhr, on the latter part of Roman History, so long lost to the world. Concerning them the Eclectic Review says:

"It is an unexpected surprise and pleasure to the admirers of Niebuhr—that is to all earnest students of ancient history—to recover, as if from the grave, the lectures before us."

And the London Athenæum:

"We have dwelt at sufficient length on these volumes to show how highly we appreciate the benefit which the editor has conferred on historical literature by their publication."

HISTORY OF THE REFORMATION

IN GERMANY.

BY PROFESSOR LEOPOLD RANKE.

Parts First and Second. Price 25 Cents each.

TRANSLATED FROM THE SECOND EDITION,

BY SARAH AUSTEN.

To be completed in about Five Parts, each Part containing One Volume of the London Edition.

RANKE'S HISTORY OF THE POPES, THEIR CHURCH AND STATE,

DURING THE SIXTEENTH AND SEVENTEENTH CENTURIES.

A NEW TRANSLATION,

BY WALTER K. KELLY.

In One neat Octavo Volume, extra cloth; or Two Parts, Paper, at One Dollar each.

RANKE'S HISTORY OF THE OTTOMAN AND SPANISH EMPIRES.

TRANSLATED FROM THE GERMAN

By **WALTER K. KELLY, Esq.**

In One Part, Paper, at Seventy-five Cents.

This book completes the uniform series of Professor Ranké's Historical Works. When bound with the History of the Popes, this forms the "Sovereigns and Nations of Southern Europe, in the 16th and 17th Centuries."

POSTHUMOUS MEMOIRS OF HIS OWN TIMES;

BY SIR NICHOLAS W. WRAXALL.

In Two Parts, Paper, at 75 cents each, or One Volume Octavo, Cloth.

**NEW LETTERS TO SIR HORACE MANN,
FROM 1760 TO 1785.**

BY HORACE WALPOLE.

In Four Parts, Paper, at One Dollar each, or Two Volumes, Octavo, Extra Cloth.

These volumes comprise letters never before published, and which have but recently been brought to light.

**HISTORY OF THE CRUSADES,
FOR THE RECOVERY AND POSSESSION OF THE HOLY LAND,**

BY CHARLES MILLS.

In One Part, Paper, Price One Dollar.

**THE HISTORY OF CHIVALRY;
OR, KNIGHTHOOD AND ITS TIMES.**

BY CHARLES MILLS.

In One Part, Paper, Price One Dollar. The two works in One Volume, Octavo, Cloth.

L. & B. have also in preparation, for the Library, Horace Walpole's Memoirs of the Reign of George III., of which they have received an early copy—Wraxall's Historical Memoirs of his own Times—Browning's History of the Huguenots—Proctor's History of Italy, and many other valuable and standard works.

They have for sale a few copies of

WALPOLE'S EARLY LETTERS IN 4 Vols. Svo.

GRAHAME'S UNITED STATES.

LEA & BLANCHARD WILL SHORTLY PUBLISH

**THE HISTORY OF THE UNITED STATES
OF NORTH AMERICA,**

FROM THE PLANTATION OF THE BRITISH COLONIES TILL THEIR REVOLT
AND DECLARATION OF INDEPENDENCE.

By **JAMES GRAHAME, Esq.**

In Four beautiful Octavo Volumes.

This work cost the author twelve years of unremitting toil and labor, during which he examined thoroughly all the English and European Libraries which could throw light on his subject. It was published in 1836, and met with but little approbation from the English public on account of the strong feeling which it manifests in favour of the colonies. Mr. Grahame continued revising and emending it till his death in 1832, shortly after which all his MSS. and papers were sent by his son to Harvard College. President Quincy, Judge Story, Professor Jared Sparks, and other gentlemen connected with the University have accordingly undertaken the task of revising an edition of the work to be presented to the American public in a style as nearly as possible resembling that of the English edition.

TAYLOR'S MEDICAL JURISPRUDENCE may be had bound in Law Sheep for the legal profession. See Advertisement at page 12.

MISCELLANEOUS BOOKS.

LEA & BLANCHARD publish, and have for sale, the following valuable works in various departments of Literature and Science.

- American Ornithology; by Prince Charles Buonaparte. In 4 vols. folio, half-bound.
- Arnott's Elements of Physics, a new edition. In 1 vol. 8vo., sheep.
- Boz's Complete Works. In 7 vols. 8vo., extra cloth, with numerous plates.
- Same work, common edition, in paper.
- Benthamiana; Extracts from Bentham, with a Memoir and Essay on his Theories. In 1 vol.
- Browne's Religio Medici, and its sequel Christian Morals. In 1 vol. 8vo., extra cloth.
- Bulwer's Miscellanies, 2 vols. 12mo., cloth.
- Bolmar's French Series, consisting of—A Selection of One Hundred Perrin's Fables, with a Key to the Pronunciation; A Series of Colloquial Phrases; The First Eight Books of Fenelon's Telemachus; Key to the same; A Treatise on all the French Verbs, Regular and Irregular. The whole forming 5 small volumes, halfbound, to match.
- Butler's Atlas of Ancient Geography. In 1 vol. large 8vo., half-bound, coloured.
- Butler's Geographia Classica; new and revised edition, 1 vol. 8vo.
- Bridgewater Treatises; the whole complete in 7 vols. 8vo., various bindings: containing—Roget's Animal and Vegetable Physiology, in 2 vols., with many cuts; Kirby on the History, Habits and Instincts of Animals, 1 vol., with plates; Prout on Chemistry; Chalmers on the Moral Condition of Man; Whewell on Astronomy; Bell on the Hand; Kidd on the Physical Condition of Man; Buckland's Geology, 2 vols., with numerous plates and maps. Of these may be had separately—Kirby on Animals, 1 vol. 8vo.; Roget's Animal and Vegetable Physiology, 2 vols. 8vo.; Buckland's Geology, 2 vols. 8vo.
- Brougham on the French Revolution. In 1 vol. 12mo., cloth or paper.
- Brougham's Historical Sketches of Statesmen who flourished under George III. Complete in 3 vols. 12mo., extra cloth.
- Speeches, selected, with Historical Introductions by himself. In 2 large 8vo. vols., extra cloth or law sheep.
- Barnaby Rudge, by "Boz." fine edition, in 1 vol. 8vo., extra cloth, with plates and numerous cuts.
- Same work, common edition, in paper, with cuts. Price only 50 cents.
- Brewster's Treatise on Optics, with numerous cuts; Edited, with an appendix, by A. D. Bache, L.L.D. In 1 vol. 12mo., half-bound.
- Babbage's "Fragment," the 9th Bridgewater Treatise, 1 vol. 8vo.
- Complete Cook; edited by Sanderson. 1 vol. 12mo., sewed: price only 25 cents.
- Complete Confectioner; by Parkinson. 1 vol. 12mo., sewed: price only 25 cents.
- N.B.—These two useful little works may be had in one neat 12mo. volume, done up in cloth for 50 cents.
- Complete Florist; 1 vol. 12mo., paper: 25 cents.
- Complete Gardener, do. price 25 cents.
- Complete Gardener and Florist; 1 vol., cloth: 50 cents.
- Curiosity Shop; by Boz. In 1 vol. 8vo., extra cloth, with over 100 plates and cuts.
- Same work, cheap edition, paper, numerous cuts: price 50 cents.
- Campbell's Complete Poetical Works, with a Memoir, by Irving; and an Essay, by Jeffreys; with a portrait and numerous illustrations. In 1 vol. crown 8vo., beautifully done up in cloth gilt or extra white calf.
- Cooper's Naval History of the United States. In 2 vols. 8vo., with 2 maps, cloth, second edition.
- Switzerland, 2 vols. 12mo., paper.
- Novels and Tales. In 23 vols., sheep gilt, 12mo., or 47 vols., paper.
- Ned Myers, 1 vol., paper: 37½ cents.
- Wyandotté, 2 vols., paper: 50 cents.
- Wing-and-Wing, 2 vols., paper: 50 cts.
- The Spy, 2 vols., paper: 50 cents.
- The Pioneers; 2 vols. do. do.
- The Pilot, a Tale of the Sea; do. do. do.
- The Prairie; 2 vols. do. do.
- Lionel Lincoln, 2 vols. do. do.
- Last of the Mohicans; 2 vols., paper.
- The Red Rover; 2 vols. do. do.
- Wept of the Wish-ton-Wish; 2 vols.
- Water Witch, 2 vols. do. do.
- The Bravo, 2 vols., paper: do.
- The Travelling Bachelor, 2 vols. do.
- The Heidenmauer, 2 vols. do.
- Precaution; 2 vols. do. do.
- Homeward Bound, 2 vols. do.
- Home as Found; 2 vols. do. do.
- Headsmen, 2 vols. do. do.
- Monikins, 2 vols. do. do.
- The Pathfinder, 2 vols. do. do.
- Mercedes of Castile; 2 vols., paper: 50 cents.
- The Deerslayer, 2 vols. do. do.
- The Two Admirals; 2 vols. do. do.
- Sea Tales, including The Pilot, Red Rover, Water Witch, Homeward Bound, Two Admirals, and Wing and Wing. In 6 vols. 12mo., cloth.
- Leather Stocking Tales, including The Prairie, The Pioneers, Last of the Mohicans, Pathfinder, and Deerslayer. In 5 vols. 12mo., extra cloth.
- Carey's Essay on Wages. In 1 vol. 8vo., cloth.
- Carey on the Laws of Wealth; 3 vols. 8vo., cloth—on the Credit System.
- Calavar, by Dr. Birl; 2 vols. 12mo., cloth.
- Clater's Every Man his own Horse-Doctor, now at press; 1 vol. 12mo.; a cheap work.
- Davidson, Margaret, (Memoirs and Writings of,) by Irving. In 1 vol. 12mo., extra cloth, or paper, 50 cents.
- , Lucretia, Poetical Remains, by Miss Sedgwick. In 1 vol. 12mo., extra cloth, or in paper, 50 cents.
- , Mrs., Selections from the Writings of. In 1 vol. 12mo., extra cloth, or in paper, 50 cents.
- Destiny, or The Chief's Daughter, a Novel, by Miss Ferrier. In 1 vol. 12mo., paper; price 40 cents.
- Dick Turpin the Highwayman, or Rookwood, by William Harrison Ainsworth: 8vo., paper, with illustrations: price 25 cents.
- The ENCYCLOPEDIA OF GEOGRAPHY; comprising a complete description of the Earth, Physical, Statistical, Commercial and Political; exhibiting its relation to the Heavenly bodies,—its physical structure—the natural history of each country,—and the Industry, Commerce, Political Institutions, and Civil and Social State

- of all Nations. By Hugh Murray, F. R. S. E., &c., assisted by Professors Wallace, Jameson, Hooker and Swainson. Illustrated by 82 maps, and about 1100 wood cuts, together with a map of the United States, after Tanner's.— Edited, with additions, by T. G. Bradford. In 3 large 8vo. vols., done up in extra cloth, plain sheep, or sheep gilt.
- The *ENCYCLOPEDIA AMERICANA*; A Popular Dictionary of Arts, Sciences, Literature, History, Politics, and Biography, including a copious Collection of Original Articles on American Biography. On the basis of the seventh edition of the German "Conversation Lexicon." Edited by Francis Leiber, assisted by E. Wigglesworth and T. G. Bradford. In 13 octavo volumes, of about 600 pages each.— This valuable work is offered at a very low price, in various styles of binding.
- East's Reports; edited by G. M. Wharton. In 8 vols. large 8vo., law sheep: price \$25 to subscribers, (at press, see advertisement.)
- Education of Mothers, or the Civilization of Mankind by Woman. From the French of L. Aimé Martin. In 1 vol. 12mo., cloth or paper.
- Frederic the Great; edited by Campbell. 2 vols. 12mo., extra cloth.
- Fielding's Select Works, in one volume 8vo., cloth; or in four parts, paper: price \$1.25, viz., Tom Jones, 50 cents; Joseph Andrews, 25 cents; Amelia, 25 cents; Jonathan Wild, &c., 25 cents.
- Fairy Legends and Traditions of Ireland; by T. Crofton Croker, with many cuts; 1 vol. 12mo., fancy paper: price 50 cents.
- Grahame's History of the United States; edited by Quiney, Prescott, Sparks, and Story. In 4 vols. 8vo., (at press, see advertisement.)
- Gieseler's Text Book of Ecclesiastical History; 3 vols. 8vo., cloth.
- Herschell's Treatise on Astronomy; edited, with a series of Questions, by S. C. Walker: illustrated by numerous plates and wood cuts; 1 vol. 12mo., half-bound.
- Hemans' Complete Poetical Works, in 7 vols. 12mo., cloth; or fancy paper at 50 cents per volume. With a Memoir by her sister, and an Essay on her Genius, by Mrs. Sigourney.
- Memoirs, by her Sister, with an Essay by Mrs. Sigourney. In 1 vol. 12mo., cloth.
- Heber's (Bishop) Poetical Works, complete in one neat 18mo. volume, extra cloth or Turkey morocco.
- The Hunchback of Notre Dame, from the French of Victor Hugo. In 8vo. paper, with a plate: price 25 cents.
- Irving's Select Works, in 2 vols. super royal 8vo., library edition, with a portrait.
- Columbus; in 2 vols. 8vo., sheep.
- Crayon Miscellany—comprising Legend of the Conquest of Spain, Abbottsford and Newstead Abbey, A Tour on the Prairies. In 3 vols. 12mo., cloth.
- Beauties, in 1 vol. 18mo.
- History of Astoria; 2 vols. 8vo., cloth.
- Rocky Mountains; 2 vols. 12mo. do.
- Life of Margaret M. Davidson, 1 vol. 12mo., paper.
- Jesse's Memoirs of the Court of England, from 1688 to the Accession of George III. In 3 vols. 12mo., extra cloth.
- Keble's Christian Year, Thoughts in Verse for the Sundays and Holidays throughout the Year. A new and beautiful miniature edition, in 32mo., with an illuminated Title, extra cloth.
- The same work in 18mo., extra cloth, or Turkey morocco.
- Keble's Childs' Christian Year; 1 vol. 18mo., eloth.
- Life of Thomas Jefferson; by Judge Tucker. In 2 vols. 8vo., with a Portrait, cloth, or sheep gilt.
- Lights, Shadows and Reflections of Whigs and Tories. In 1 vol. 12mo., cloth.
- Language of Flowers; 1 vol. 18mo., embossed morocco, coloured plates.
- Lockhart's Life of Sir Walter Scott, in 7 vols. royal 12mo., cloth.
- Life of Richard Henry Lee; 8vo., boards.
- Loves of the Poets,—Biographical Sketches of Women celebrated in Ancient and Modern Poetry; by Mrs. Jamieson. In 1 vol. 12mo. paper.
- Moore's History of Ireland; in 1 vol. 8vo., cloth.
- Martin Chuzzlewit, by Boz; 1 vol. 8vo., extra cloth, with plates; or in paper, 50 cents.
- Millwright's and Miller's Guide; by Oliver Evans. In 1 vol. 8vo., sheep, many plates.
- Mills' History of the Crusades, in 1 vol. 8vo., paper: price, one dollar.
- History of Chivalry; 1 vol. 8vo.; price, one dollar.
- Or both works in 1 vol. cloth.
- Narrative of the United States' Exploring Expedition; by Captain Charles Wilkes. In 5 large imperial 8vo. volumes, and an Atlas, with illustrations. (See advertisement.)
- Niebuhr's History of Rome, complete in five parts, paper, at one dollar each, or two large octavo volumes, extra cloth—Vol. 2, containing the three last parts, has never before been published in this country, and may be had separately, completing the edition published here some years since.
- Nicholas Nickleby, by Boz; fine edition, with 39 plates, and a portrait of the Author. In 1 vol. large 8vo., extra cloth.
- The same work, cheap edition, paper covers, for 50 cents.
- Oliver Twist, by Boz; fine edition, with 24 plates, 1 vol. large 8vo., extra cloth.
- Same work, cheap edition, paper covers, for 25 cents.
- Picciola,—The Prisoner of Fenestrella; or, Captivity Captive. From the French of M. de Saintine; 1 vol. 12mo., paper: price 35 cents.
- Peregrine Bounce, a Novel, by Theodore Hook; 1 vol.; paper, 25 cents.
- Popular Vegetable Physiology, by Professor Carpenter. In 1 vol. 12mo., extra cloth, with numerous cuts.
- Pickwick Club, by Boz. Fine edition, in 1 vol. royal 8vo., extra cloth, with numerous illustrations.
- Same work, cheap edition, paper covers; price, 50 cents.
- Lives of the Queens of England from the Norman Conquest; by Agnes Strickland. In 7 vols. 12mo., fancy paper, \$4.10, or extra green cloth. Any volume sold separately. The 7th volume brings the history down to the time of Anne of Denmark, Queen of James I.
- Queen of Flowers, or Memoirs of the Rose. In 1 vol. 18mo., cloth gilt, with coloured plates.
- Ranke's History of the Popes of Rome. Translated by Mrs. Austin; in 2 vols. 8vo., cloth.
- The same work, translated by Walter Keating Kelly, in 1 volume, 8vo., cloth; or two parts, paper, at one dollar each.
- History of the Reformation in Germany. Translated by Mrs. Austin. To be finished in about five parts, at 25 cents each. Part I and 2, now ready. (See advertisement.)
- Ranke's History of the Ottoman and Spanish

- Empires. In 1 vol. 8vo., paper; to match the above.
- Rogers's Poems, a splendid edition, illustrated. In 1 vol. imperial 8vo., cloth gilt, or white calf extra.
- Roget's Outlines of Physiology, 1 vol. 8vo., plates.
- Scott's Complete Poetical Works. In 6 vols. 12mo., cloth, with Notes, &c.
- Select Works of Tobias Smollett, in five parts, paper, \$1.50,—containing Peregrine Pickle, 50 cents; Roderic Random, 25 cents; Humphrey Clinker, 25 cents; Ferdinand Count Fathom, 25 cents, and Sir Launcelot Greaves, 25 cents.
- Tynney Hall, a Novel, by Thomas Hood; 1 vol., paper, with a portrait: price 25 cents.
- Ugolino, a Tragedy, sewed.
- United Irishmen, their Lives and Times; by Dr. Madden. In 2 vols. 12mo., paper.
- Walpole's unrivalled Letters; in 4 large vols. royal 8vo., extra cloth, with a portrait.
- New Letters to Sir Horace Mann; in 2 vols. 8vo., extra cloth, or 4 parts, paper, at \$1 each.
- Walpole, Memoirs of George the Third; a new work now at press.
- White's Universal History, a new and improved work for Schools, Colleges, &c.: with Questions, by Professor Hart. In 1 volume, large 12mo., extra cloth, or half-bound.
- Whims and Oddities, by Thomas Hood; in 1 vol. 12mo., fancy paper, with nearly 90 cuts: price only 50 cents.
- Whimsicalities, by Thomas Hood; in 1 vol. 12mo., fancy paper, with numerous illustrations: price 50 cents.
- Wheaton on the Right of Search; in 1 vol. thin 8vo., cloth.
- Mrs. Washington Potts and Mr. Smith; Prize Tales, by Miss Leslie, paper, 25 cents.
- Wraxall's Posthumous Memoirs of his Own Time; in 1 vol. 8vo., cloth, or two parts, paper, at 75 cents each.
- Historical Memoirs in 1 vol. 8vo., at press.

THE HORSE.

BY WILLIAM YOUATT.

A NEW EDITION WITH ILLUSTRATIONS;

CONTAINING

A full account of the Diseases of the Horse, with their mode of treatment; his anatomy, and the usual operations performed on him; his breeding, breaking, and management; and hints on his soundness, and the purchase and sale. Together with a General History of the Horse; a dissertation on the American Trotting Horse, how trained and jockeyed, an account of his remarkable performances, and an Essay on the Ass and the Mule,

BY J. S. SKINNER,

Assistant Post-Master General and Editor of the Turf Register.
In One Volume. octavo.

YOUATT AND CLATER'S CATTLE AND SHEEP-DOCTOR.

NOW READY,

EVERY MAN HIS OWN CATTLE AND SHEEP-DOCTOR:

CONTAINING

THE CAUSES, SYMPTOMS, AND TREATMENT OF ALL THE DISEASES INCIDENT TO
OXEN, SHEEP, AND SWINE.

By FRANCIS CLATER.

EDITED, REVISED, AND ALMOST REWRITTEN,

By WILLIAM YOUATT, AUTHOR OF "THE HORSE," &c.

Together with numerous Additions, by the American Editor, J. S. Skinner.

AMONG WHICH ARE

AN ESSAY ON THE USE OF OXEN, WITH MODES OF BREAKING, FEEDING, GRAZING, ETC.
AND A TREATISE ON THE GROWTH, IMPROVEMENT AND BREEDING OF SHEEP,
AND THE SOILS ADAPTED TO THEIR RAISING.

With numerous Cuts and Illustrations. In one volume, 12mo.

Price Fifty Cents, in Cloth.

JUST PUBLISHED,

MARSTON;

OR, THE MEMOIRS OF A STATESMAN,

In two parts, at 25 Cents each.

DICKENS' NEW WORK.

THE CHIMES, A GOBLIN STORY

OF SOME BELLS THAT RUNG AN OLD YEAR OUT AND A NEW-YEAR IN.

A CHEAP EDITION, IN PAPER COVERS,

AND A FINE EDITION WITH PLATES.

See the List for a new edition of Campbell's Poetical Works, by Wash. Irving and Lord Jeffreys.

WATSON'S PRACTICE OF MEDICINE.

L. & B. HAVE LATELY PUBLISHED

LECTURES

ON THE PRINCIPLES AND PRACTICE OF PHYSIC.

DELIVERED AT KING'S COLLEGE, LONDON.

By THOMAS WATSON, M. D.,

Fellow of the Royal College of Physicians, Physician to the Middlesex Hospital, &c. &c.

In One large Octavo Volume, of over *nine hundred* unusually large pages, strongly bound in leather, containing *Ninety Lectures*. Offered to the public at a very low price.

This volume, although so short a time before the medical public of this country, has met with almost unprecedented approbation from all classes of the profession, teachers, practitioners and students, in every section of the country; and has been favourably noticed by all the medical journals.

The publishers submit the following notice of its approval from the Professor of the University of Pennsylvania, and from some of the journals, foreign and domestic, which have borne testimony to its excellence.

Phila., Sept. 27th, 1844.

Watson's Practice of Physic, in my opinion, is among the most comprehensive works on the subject extant, replete with curious and important matter, and written with great perspicuity and felicity of manner. As calculated to do much good, I cordially recommend it to that portion of the profession in this country who may be influenced by my judgment.

N. CHAPMAN, M. D.,

Professor of the Practice and Theory of Medicine in the University of Pennsylvania.

"We know of no other work better calculated for being placed in the hands of the student, and for a text book, and as such we are sure it will be very extensively adopted. On every important point, the author seems to have posted up his knowledge to the day."—*American Medical Journal*.

"In the Lectures of Dr. Watson, now republished here in a large and closely printed volume, in small type, of nearly a thousand pages, we have a body of doctrine and practice of medicine well calculated, by its intrinsic soundness and correctness of style, to instruct the student and younger practitioner, and improve members of the profession of every age."—*Bulletin of Medical Science*.

"We know not, indeed, of any work of the same size that contains a greater amount of useful and interesting matter. We are satisfied, indeed, that no physician, well read and observing as he may be, can rise from its perusal without having added largely to his stock of valuable information."—*Medical Examiner*.

"We regard these lectures as the best exposition of their subjects of any we remember to have read. The author is assuredly master of his art. His has been a life of observation and study, and in this work he has given us the matured results of these mental efforts."—*New Orleans Medical Journal*.

"Open this huge, well-furnished volume where we may, the eye immediately rests on something that carries value on its front. We are impressed at once with the strength and depth of the lecturer's views. He gains on our admiration in proportion to the extent of our acquaintance with his profound researches. Whoever owns this book, will have an acknowledged treasure if the combined wisdom of the highest authorities is appreciated."—*Boston Med. and Surg. Journal*.

"One of the most practically useful books that ever was presented to the student—indeed, a more admirable summary of general and special pathology, and of the

application of therapeutics to diseases, we are free to say has not appeared for very many years. The lecturer proceeds through the whole classification of human ills, *a capite ad calcem*, showing at every step an extensive knowledge of his subject, with the ability of communicating his precise ideas, in a style remarkable for its clearness and simplicity."—*N. Y. Journal of Medicine and Surgery*.

"The style is correct and pleasing, and the matter worth the attention of *all* practitioners, young and old."—*Western Lancet*.

"We are free to state that a careful examination of this volume has satisfied us that it merits all the commendation bestowed on it in this country and at home. It is a work adapted to the wants of young practitioners, combining, as it does, sound principles and substantial practice. It is not too much to say, that it is a representative of the actual state of medicine as taught and practised by the most eminent physicians of the present day, and as such we would advise every one about embarking in the practice of physic to provide himself with a copy of it."—*Western Journal of Med. and Surgery*.

"The medical literature of this country has been enriched by a work of standard excellence, which we can proudly hold up to our brethren of other countries as a representative of the natural state of British medicine, as professed and practised by our most enlightened physicians. And, for our own parts, we are not only willing that our characters as scientific physicians and skilful practitioners may be deduced from the doctrines contained in this book, but we hesitate not to declare our belief, that for sound, trustworthy principles, and substantial, good practice, it cannot be paralleled by any similar production in any other country. * * * * We would advise no one to set himself down in practice, unprovided with a copy."—*British and Foreign Medical Review*.

WORKS BY PROFESSOR DUNGLISON.

LEA & BLANCHARD publish and have for sale the following valuable Medical Works by Professor Robley Dunglison.

HUMAN PHYSIOLOGY,

WITH UPWARDS OF THREE HUNDRED ILLUSTRATIONS,

By ROBLEY DUNGLISON, M. D.,

PROFESSOR OF THE INSTITUTES OF MEDICINE, &c. IN JEFFERSON MEDICAL COLLEGE, PHILADA.;
ATTENDING PHYSICIAN AND LECTURER ON CLINICAL MEDICINE AT THE PHILADA. MEDICAL HOSPITAL;
SECRETARY TO THE AMERICAN PHILOSOPHICAL SOCIETY, &c. &c.

FIFTH EDITION, GREATLY MODIFIED AND IMPROVED.

IN TWO VOLUMES, OF 1304 LARGE OCTAVO PAGES.

In presenting this new and much improved edition of Professor Dunglison's standard work on Physiology, the Publishers beg to state, that "although only a short time has elapsed since the publication of the fourth edition of this work, the labours of Physiologists have been so numerous, diversified, and important, as to demand material modifications and additions in the present edition, and that no little time and industry have been bestowed by the author to introduce these, and to digest the various materials contained in the *ex professo* treatises, as well as the various Journals of this country and of Europe.

"To this edition nearly ninety wood-cuts have been added to elucidate either topics that had been already treated of in the previous editions, or such as are new in this; most of the old cuts have been retouched, and many replaced by others that are superior. Altogether, the author has endeavoured to make the work a just and impartial record of Physiolog'cal science, and to render it worthy a continuance of that favour which has been so liberally extended to it." The size of the volumes has been materially increased, by the addition of over eighty pages, and the illustrations are far superior to those of any former edition.

THE PRACTICE OF MEDICINE,

OR A TREATISE ON

SPECIAL PATHOLOGY AND THERAPEUTICS.

By ROBLEY DUNGLISON, M. D.,

CONTAINING

THE DISEASES OF THE ALIMENTARY CANAL, THE DISEASES OF THE CIRCULATORY APPARATUS, DISEASES OF THE GLANDULAR ORGANS, DISEASES OF THE ORGANS OF THE SENSES, DISEASES OF THE RESPIRATORY ORGANS, DISEASES OF THE GLANDIFORM GANGLIONS, DISEASES OF THE NERVOUS SYSTEM, DISEASES OF THE ORGANS OF REPRODUCTION, DISEASES INVOLVING VARIOUS ORGANS, &c. &c.

In Two Volumes, Octavo.

This work has been introduced as a text-book in many of the Medical colleges, and the general favour with which it has been received, is a guarantee of its value to the practitioner and student.

"In the volumes before us, Dr. Dunglison has proved that his acquaintance with the present facts and doctrines, wheresoever originating, is most extensive and intimate, and the judgment, skill, and impartiality with which the materials of the work have been collected, weighed, arranged, and exposed, are strikingly manifested in every chapter. Great care is everywhere taken to indicate the source of information, and under the head of treatment, formulæ of the most appropriate remedies are everywhere introduced. In conclusion, we congratulate the students and junior practitioners of America, on possessing in the present volumes, a work of standard merit, to which they may confidently refer in their doubts and difficulties."—*British and Foreign Medical Review for July, 1842.*

"Since the foregoing observations were written, we have received a second edition of Dunglison's work. A sufficient indication of the high character it has already attained in America, and justly attained."—*British and Foreign Medical Review for October, 1844.*

"We hail the appearance of this work, which has just been issued from the prolific press of Messrs. Lea & Blanchard, of Philadelphia, with no ordinary degree of pleasure. Comprised in two large and closely printed volumes, it exhibits a more full, accurate, and comprehensive digest of the existing state of medicine than any other treatise with which we are acquainted in the English language. It discusses many topics—some of them of great practical importance, which are entirely omitted in the writings of Eberle, Dewees, Hosack, Graves, Stokes, McIntosh, and Gregory; and it cannot fail, therefore, to be of great value, not only to the student, but to the practitioner, as it affords him ready access to information of which he stands in daily need in the exercise of his profession. It has been the desire of the author, well known as one of the most abundant writers of the age, to render his work strictly practical; and to this end he has been induced, whenever opportunity offered, to incorporate the results of his own experience with that of his scientific brethren in America and Europe. To the former, ample justice seems to have been done throughout. We believe this constitutes the seventh work which Professor Dunglison has published within the last ten years; and, when we reflect upon the large amount of labour and reflection which must have been necessary in their preparation, it is amazing how he could have accomplished so much in so short a time."—*Louisville Journal.*

NEW REMEDIES,

PHARMACEUTICALLY AND THERAPEUTICALLY CONSIDERED.

By ROBLEY DUNGLISON, M. D.,

In One Volume, Octavo—over 600 pages, the Fourth Edition.

A NEW EDITION OF
THE STANDARD MEDICAL DICTIONARY.

A DICTIONARY OF MEDICAL SCIENCE:

CONTAINING

A CONCISE ACCOUNT OF THE VARIOUS SUBJECTS AND TERMS, WITH THE FRENCH AND OTHER SYNONYMES, NOTICES OF CLIMATE AND OF CELEBRATED MINERAL WATERS, FORMULÆ FOR VARIOUS OFFICIAL AND EMPIRICAL PREPARATIONS, ETC.

Fourth Edition, Extensively Modified and Improved.

By **ROBLEY DUNGLISON, M. D.,**

In One Volume, Royal Octavo.

"The present undertaking was suggested by the frequent complaints made by the author's pupils, that they were unable to meet with information on numerous topics of professional inquiry—especially of recent introduction—in the medical dictionaries accessible to them.

"It may, indeed, be correctly affirmed, that we have no dictionary of medical subjects and terms which can be looked upon as adapted to the state of the science. In proof of this the author need but to remark, that the present edition will be found to contain at least two thousand subjects and terms not embraced in the last edition, and to have experienced numerous modifications.

"The author's object has not been to make the work a mere lexicon or dictionary of terms, but to afford, under each, a condensed view of its various medical relations, and thus to render the work an epitome of the existing condition of medical science.

"To execute such a work requires great erudition, unwearied industry, and extensive research; and we know no one who could bring to the task higher qualifications of this description than Professor Dunglison."—*American Medical Journal*.

THERAPEUTICS AND MATERIA MEDICA.

GENERAL THERAPEUTICS AND MATERIA MEDICA,

ADAPTED FOR A MEDICAL TEXT-BOOK.

By **ROBLEY DUNGLISON, M. D.,**

In Two Volumes, Octavo.

"The subject of Materia Medica has been handled by our author with more than usual judgment. The greater part of treatises on that subject are, in effect, expositions of the natural and chemical history of the substances used in medicine, with very brief notices at all of the indications they are capable of fulfilling, and the general principles of Therapeutics. Dr. Dunglison, very wisely, in our opinion, has reversed all this, and given his principal attention to the articles of the Materia Medica as *medicines*. . . . In conclusion, we strongly recommend these volumes to our readers. No medical student on either side of the Atlantic should be without them."—*Forbes' British and Foreign Medical Review*.

LATELY PUBLISHED,

DUNGLISON ON HUMAN HEALTH.

HUMAN HEALTH;

OR, THE INFLUENCE OF ATMOSPHERE AND LOCALITY, CHANGE OF AIR AND CLIMATE, SEASONS, FOOD, CLOTHING, BATHING AND MINERAL SPRINGS, EXERCISE, SLEEP, CORPOREAL AND INTELLECTUAL PURSUITS, &c. &c. ON HEALTHY MAN:

CONSTITUTING

ELEMENTS OF HYGIÈNE.

By **ROBLEY DUNGLISON, M. D.,**

A NEW EDITION WITH MANY MODIFICATIONS AND ADDITIONS.

In One Volume, 8vo.

"We have just received the new edition of this learned work on the 'Elements of Hygiene.' Dr. Dunglison is one of the most industrious and voluminous authors of the day. How he finds time to amass and arrange the immense amount of matter contained in his various works, is almost above the comprehension of men possessing but ordinary talents and industry. Such labour deserves immortality."—*St. Louis Med. and Surg. Journal*.

A NEW EDITION OF

THE MEDICAL STUDENT;
OR, AIDS TO THE STUDY OF MEDICINE.

A REVISED AND MODIFIED EDITION.

By **ROBLEY DUNGLISON, M. D.,**

In One neat 12mo. Volume.

"In effect, the author's aim is to teach the tyro what he ought to, and how he may study to the best advantage both before and after he has attained the dignity of a medical diploma; and while he gives him much good advice in an agreeable manner and enforced by happy illustrations, he endeavours to simplify his labours by presenting him with 'a glossary of the prefixes, suffixes and radicals of many of the terms legitimately compounded; of medical technology, a vocabulary of terms used in prescribing and other useful information.'"—*American Medical Journal*.

THE CYCLOPÆDIA OF PRACTICAL MEDICINE.

TO BE READY IN MARCH.

Forming Four magnificent super-royal Octavo Volumes of about 3200 unusually large double-columned pages, printed on beautiful white paper, with a new and clear type, done up in strong sheep binding, or neat extra cloth; or, in Twenty-four Parts, at Fifty Cents each.

LEA & BLANCHARD ARE NOW ISSUING

THE CYCLOPÆDIA OF PRACTICAL MEDICINE:

COMPRISING

TREATISES ON THE

NATURE AND TREATMENT OF DISEASES,

MATERIA MEDICA AND THERAPEUTICS,

DISEASES OF WOMEN AND CHILDREN,

MEDICAL JURISPRUDENCE, &c. &c.

EDITED BY

JOHN FORBES, M. D., F. R. S.,

ALEXANDER TWEEDIE, M. D., F. R. S.,

AND

JOHN CONOLLY, M. D.

REVISED, WITH ADDITIONS,

BY ROBLEY DUNGLISON, M. D.

This work is printed on good paper with a new and clear type, and forms
FOUR VERY LARGE SUPER-ROYAL OCTAVO VOLUMES,
with over three thousand unusually large pages, in double columns.

This work has now been in the course of publication for about ten months, and is nearly completed, twenty-two numbers having been issued, and the whole will be completed early in March.

The parts already published contain the following valuable articles by distinguished authors:

CONTENTS OF PART I.

Abdomen, Exploration of the, Dr. Forbes.
Abortion, Dr. Lee.
Abscess, Internal, Dr. Tweedie.
Abstinence, Dr. Marshall Hall.
Achor, Dr. Todd.
Aene, Dr. Todd.
Acro-dynia, Dr. Dunglison.
Acupuncture, Dr. Elliotson.
Age, Dr. Roget.
Air, Change of, Sir James Clarke.
Alopecia, Dr. Todd.
Alteratives, Dr. Conolly.
Amaurosis, Dr. Jacob.
Amenorrhœa, Dr. Looock.
Anæmia, Dr. Marshall Hall.
Anasarca, Dr. Darwall.
Angina Pectoris, Dr. Forbes.
Anodynes, Dr. Whiting.
Anthelmintics, Dr. A. T. Thomson.
Anthraxion, Dr. Dunglison.
Antiphlogistic Regimen, Dr. Barlow.
Antispasmodics, Dr. A. T. Thomson.
Aorta, Aneurism of, Dr. Hope.

CONTENTS OF PART II.

Apoplexy, Cerebral, Dr. Clatterbuck.
" Pulmonary, Dr. Townsend.
Arteritis, Dr. Hope.
Ascites, Dr. Darwall.
Artisans, Diseases of, Dr. Darwall.
Asphyxia, Dr. Roget.
" of the New Born, Dr. Dunglison.
Asthma, Dr. Forbes.
Astringents, Dr. A. T. Thomson.
Atrophy, Dr. Townsend.
Auscultation, Dr. Forbes.
Barbers, Dr. Scott.
Bathing, Dr. Forbes.

CONTENTS OF PART III.

Bathing (*continued*), Dr. Forbes.
Beriberi, Dr. Scott.
Blood, Determination of, Dr. Barlow.
" Morbid States of, Dr. Marshall Hall.
Blood-letting, Dr. Marshall Hall.
Brain, Inflammation of the,
Meningitis, Dr. Quain.
Cerebritis, Dr. Adair Crawford.
Bronchial Glands, Diseases of the, Dr. Dunglison.
Bronchitis, Acute and Chronic, Dr. Williams.
" Summer, Dr. Dunglison.
Bronchocele, Dr. And. Crawford.
Bullæ, Dr. Todd.
Cachexia, Dr. Dunglison.
Calculi, Dr. T. Thomson.
Calculous Diseases, Dr. Cumin.
Catalepsy, Dr. Joy.
Catarrh, Dr. Williams.
Cathartics, Dr. A. T. Thomson.
Chest, Exploration of the, Dr. Forbes.
Chicken Pox, Dr. Gregory.
Chlorosis, Dr. Marshall Hall.
Cholera, Common and Epidemic, Dr. Brown.

CONTENTS OF PART IV.

Cholera, Epidemic, (*continued*), Dr. Brown.
" Infantum, Dr. Dunglison.
Chorea, Dr. And. Crawford.
Cirrhosis of the Lung, Dr. Dunglison.
Climate, Dr. Clark.
Cold, Dr. Whiting.
Colic, Drs. Whiting and Tweedie.
Colica Pietonum, Dr. Whiting.
Colon, Torpor of the, Dr. Dunglison.
Coma, Dr. Adair Crawford.
Combustion, Spontaneous, Dr. Apjoha.
Congestion of Blood, Dr. Barlow.
Constipation, Drs. Hastings and Streeten.

Contents of Cyclopædia of Practical Medicine.

Contagion, Dr. Brown.
Convalescence, Dr. Tweedie.
Convulsions, Dr. Adair Crawford.
 " Infantile, Dr. Locoek.
 " Puerperal, Dr. Locoek.
Coryza, Dr. Williams.
Counter Irritation, Dr. Williams.
Croup, Dr. Cheyne.

CONTENTS OF PART V.

Croup, (*continued*), Dr. Cheyne.
Cyanosis, Dr. Crampton.
Cystitis, Dr. Cumin.
Dead, Persons found, Dr. Beatty.
Delirium, Dr. Pritchard.
 " Tremens, Drs. Carter and Dunglison.
Dengue, Dr. Dunglison.
Dentition, Disorders of, Dr. Joy.
Derivation, Dr. Stokes.
Diabetes, Dr. Bardsley.
Diagnosis, Dr. Marshall Hall.
Diaphoretics, Dr. A. T. Thomson.
Diarrhœa, Drs. Crampton and Forbes.
 " Adipous, Dr. Dunglison.
Dietetics, Dr. Paris.

CONTENTS OF PART VI.

Dietetics, (*continued*), Dr. Paris.
Disease, Dr. Conolly.
Disinfectants, Dr. Dunglison.
Disinfection, Dr. Brown.
Diuretics, Dr. A. T. Thomson.
 Dropsy, Dr. Darwall.
Dysentery, Dr. Brown.
Dysmenorrhœa, Dr. Locoek.
Dysphagia, Dr. Stokes.
Dyspnœa, Dr. Williams.
Dysuria, Dr. Cumin.
Ecthyma, Dr. Todd.
Eczema, Dr. Joy.
Education, Physical, Dr. Barlow.
Electricity, Dr. Apjohn.
Elephantiasis, Dr. Joy.
Emetics, Dr. A. T. Thomson.
Emmenagogues, Dr. A. T. Thomson.

CONTENTS OF PART VII.

Empysema, Dr. R. Townsend.
 " of the Lungs, Dr. R. Townsend.
Empyema, Dr. R. Townsend.
E endemic diseases, Dr. Hancock.
Enteritis, Drs. Stokes and Dunglison.
Ephelis, Dr. Todd.
Epidemics, Dr. Hancock.
Epilepsy, Dr. Cheyne.
Epistaxis, Dr. Kerr.
Erethismus Mercurialis, Dr. Burder.
Erysipelas, Dr. Tweedie.
Erythema, Dr. Joy.
Eutrophic, Dr. Dunglison.
Exanthemata, Dr. Tweedie.
Expectorants, Dr. A. T. Thomson.
Expectoration, Dr. Williams.
Favus, Dr. A. T. Thomson.
Feigned diseases, Drs. Scott, Forbes and Marshall.

CONTENTS OF PART VIII.

Feigned diseases, (*continued*), Drs. Scott, Forbes and Marshall.
Fever, general doctrine of, Dr. Tweedie.
 " Continued, and its modifications, Dr. Tweedie.
 " Typhus, Dr. Tweedie.
 " Epidemic Gastric, Dr. Cheyne.
 " Intermittent, Dr. Brown.
 " Remittent, Dr. Brown.
 " Malignant Remittent, Dr. Dunglison.
 " Infantile, Dr. Joy.
 " Hectic, Dr. Brown.
 " Puerperal, Dr. Lee.
 " Yellow, Dr. Gillkrest.

CONTENTS OF PART IX.

Fever, Yellow, (*continued*), Dr. Gillkrest.
Fungus Hæmatodes, Dr. Kerr.
Galvanism, Drs. Apjohn and Dunglison.
Gastritis, Dr. Stokes.
Gastrodynia, Dr. Barlow.
Gastro-Enteritis, Dr. Stokes.
Glanders, Dr. Dunglison.
Glossitis, Dr. Kerr.

Glottis, Spasm of the, Dr. Joy.
Gout, Dr. Barlow.
Hæmatemesis, Dr. Goldie.
Hæmoptysis, Dr. Law.
Headache, Dr. Burder.
Heart, Diseases of the, Dr. Hope.
 " Dilatation of the, Dr. Hope.
 " Displacement of the, Dr. Townsend.
 " Fatty and greasy degeneration of the, Dr. Hope.
 " Hypertrophy of the, Dr. Hope.

CONTENTS OF PART X.

Heart, Hypertrophy of the, (*continued*), Dr. Hope.
 " Malformations of the, Dr. Williams.
 " Polypus of the, Dr. Dunglison.
 " Rupture of the, Dr. Townsend.
 " Diseases of the Valves of the, Dr. Hope.
Hæmorrhage, Dr. Watson.
Hæmorrhoids, Dr. Burne.
Hereditary transmission of disease, Dr. Brown.
Herpes, Dr. A. T. Thomson.
Hiccup, Dr. Ash.
Hooping Cough, Dr. Johnson.
Hydatids, Dr. Kerr.
Hydrocephalus, Dr. Joy.
Hydropericardium, Dr. Darwall.
Hydrophobia, Dr. Bardsley.

CONTENTS OF PART XI.

Hydrophobia, (*continued*), Dr. Bardsley.
Hydrothorax, Dr. Darwall.
Hyperæsthesia, Dr. Dunglison.
Hypertrophy, Dr. Townsend.
Hypochondriasis, Dr. Pritchard.
Hysteria, Dr. Conolly.
Ichthyosis, Dr. Thomson.
Identity, Dr. Montgomery.
Impetigo, Dr. A. T. Thomson.
Impotence, Dr. Beatty.
Incubus, Dr. Williams.
Indigestion, Dr. Todd.

CONTENTS OF PART XII.

Indigestion, (*continued*), Dr. Todd.
Induration, Dr. Carswell.
Infanticide, Dr. Arrowsmith.
Infection, Dr. Brown.
Inflammation, Drs. Adair Crawford and Tweedie.

CONTENTS OF PART XIII.

Influenza, Dr. Hancock.
Insanity, Dr. Pritchard.
Intussusception, Dr. Dunglison.
Irritation, Dr. Williams.
Jaundice, Dr. Burder.
 " of the Infant, Dr. Dunglison.
Kidneys, diseases of, Dr. Carter.
Lactation, Dr. Locoek.
Laryngitis, Dr. Cheyne.
 " Chronic, Dr. Dunglison.
Latent diseases, Dr. Christison.
Lepra, Dr. Houghton.
Leucorrhœa, Dr. Locoek.
Lichen, Dr. Houghton.
Liver, Diseases of the, Dr. Stokes.

CONTENTS OF PART XIV.

Liver, Diseases of the, (*continued*), Dr. Venables.
 " Inflammation of the, Dr. Stokes.
Malaria and Miasma, Dr. Brown.
Medicine, History of, Dr. Postock.
 " American, before the Revolution, Dr. J. B. Beck.
 " State of in the 19th century, Dr. Alison.
 " Practical, Principles of, Dr. Conolly.

CONTENTS OF PART XV.

Medicine, Practical, Principles of, Dr. Conolly.
Melæna, Dr. Goldie.
Melanosis, Dr. Carswell.
Menorrhagia, Dr. Locoek.
Menstruation, Pathology of, Dr. Locoek.
Miliaria, Dr. Tweedie.
Milk Sickness, Dr. Dunglison.
Mind, Soundness and Unsoundness of, Drs. Pritchard and Dunglison.
Molluscum, Dr. Dunglison.
Mortification, Dr. Carswell.
Narcotics, Dr. A. T. Thomson.

Contents of Cyclopædia of Practical Medicine.

Nauseants, Dr. Dunglison.
Nephralgia and Nephritis, Dr. Carter.
Neuralgia, Dr. Elliottson.
Noli-Me-Tangere or Lupus, Dr. Houghton.
Nyctalopia, Dr. Grant.

CONTENTS OF PART XVI.

Nyctalopia, (*continued*.) Dr. Grant.
Obesity, Dr. Williams.
Oedema, Dr. Darwall.
Ophthalmia, Drs. Jacobs and Dunglison.
Otitis and Otitis, Dr. Burne.
Ovaria, Diseases of the, Dr. Lee.
Palpitation, Drs. Hope and Dunglison.
Pancreas, diseases of the, Dr. Carter.
Paralysis, Dr. Todd.
Parotitis, Dr. Kerr.
Parturients, Dr. Dunglison.
Pellagra, Dr. Kerr.
Pneumigus, Dr. Corrigan.
Perforation of the Hollow Viscera, Dr. Carswell.
Pericarditis, Dr. Hope.
Peritonitis, Drs. McAdam and Stokes.

CONTENTS OF PART XVII.

Peritonitis, (*continued*.) Dr. Stokes.
Phlegmasia Dolens, Dr. Lec.
Pityriasis, Dr. Cumin.
Plague, Dr. Brown.
Pleurora, Dr. Barlow.
Pleurisy, Dr. Law.
Plica Polonica, Dr. Corrigan.
Pneumonia, Dr. Williams.
Pneumothorax, Dr. Houghton.
Porriago, Dr. A. T. Thomson.

CONTENTS OF PART XVIII.

Porriago, (*continued*.) Dr. A. T. Thomson.
Pregnancy and Delivery, signs of, Dr. Montgomery.
Prognosis, Dr. Ash.
Prurigo, Dr. A. T. Thomson.
Pseudo-Morbid Appearances, Dr. Todd.
Psoriasis, Dr. Cumin.
Ptyalism, Dr. Dunglison.
Puerperal Diseases, Dr. Marshall Hall.
Pulse, Dr. Hestock.
Purpura, Dr. Goldie.
Pus, Dr. Tweedie.
Pyrosis, Dr. Kerr.
Rape, Dr. Beatty.

CONTENTS OF PART XIX.

Refrigerants, Dr. A. T. Thomson.

Rheumatism, Drs. Barlow and Dunglison.
Rickets, Dr. Cumin.
Roseola, Dr. Tweedie.
Rubecula, Dr. Montgomery.
Rupia, Dr. Corrigan.
Scabies, Dr. Houghton.
Scarlatina, Dr. Tweedie.
Scirrhus, Dr. Carswell.
Scorbutus, Dr. Kerr.
Scrofula, Dr. Cumin.

CONTENTS OF PART XX.

Scrofula, (*continued*.) Dr. Cumin.
Sedatives, Drs. A. T. Thomson and Dunglison.
Sex, Doubtful, Dr. Beatty.
Small Pox, Dr. Gregory.
Softening of Organs, Dr. Carswell.
Somnambulism and Animal Magnetism, Dr. Pritchard.
Spermatorrhœa, Dr. Dunglison.
Spinal Marrow, Diseases of the, Dr. Todd.
Spleen, Diseases of the, Drs. Bigsby and Dunglison.
Statistics, Medical, Drs. Hawkins and Dunglison.
Stethoscope, Dr. Williams.
Stimulants, Dr. A. T. Thomson.
Stomach, Organic Diseases of, Dr. Houghton.

CONTENTS OF PART XXI.

Stomach, Organic Diseases of, (*continued*.) Dr. Houghton and Dunglison.
Stomatitis, Dr. Dunglison.
Strophulus, Dr. Dunglison.
Succession of Inheritance, Legitimacy, Dr. Montgomery.
Suppuration, Dr. Todd.
Survivorship, Dr. Beatty.
Syccosis, Dr. Cumin.
Symptomatology, Dr. Marshall Hall.
Syncope, Dr. Ash.
Tabes Mesenterica, Dr. Joy.
Temperament, Dr. Pritchard.
Tetanus, Dr. Dunglison.
Tetanus, Dr. Symonds.
Throat, Diseases of the, Dr. Tweedie.
Tissue Adventitious.
Tonics, Dr. A. T. Thomson.

CONTENTS OF PART XXII.

Tonics, (*continued*.) Dr. A. T. Thomson.
Toothache, Dr. Dunglison.
Toxicology, Drs. Apjohn and Dunglison.
Transformations, Dr. Duesbury.
Transfusion, Dr. Kay.
Tubercle, Dr. Carswell.
Tubercular Phthisis, Dr. Clark.

"We rejoice that this work is to be placed within the reach of the profession in this country, it being unquestionably one of very great value to the practitioner. This estimate of it has not been formed from a hasty examination, but after an intimate acquaintance derived from frequent consultation of it during the past nine or ten years. The editors are practitioners of established reputation, and the list of contributors embraces many of the most eminent professors and teachers of London, Edinburgh, Dublin and Glasgow. It is, indeed, the great merit of this work that the principal articles have been furnished by practitioners who have not only devoted especial attention to the diseases about which they have written, but have also enjoyed opportunities for an extensive practical acquaintance with them,—and whose reputation carries the assurance of their competency justly to appreciate the opinions of others, while it stamps their own doctrines with high and just authority."—*American Medical Journal*.

"Do young physicians generally know what a treasure is offered to them in Dr. Dunglison's revised edition? Without wishing to be thought importunate, we cannot very well refrain from urging upon them the claims of this highly meritorious undertaking."—*Boston Medical and Surgical Journal*.

"It has been to us, both as learner and teacher, a work for ready and frequent reference, one in which modern English Medicine is exhibited in the most advantageous light, and with adaptations to various tastes and expectations. The Publishers can be safely relied on as both able and willing to carry this undertaking through with all possible expedition."—*Medical Examiner*.

"Such a work as this has long been wanting in this country. British medicine ought to have set itself forth in this way much sooner. We have often wondered that the medical profession and the enterprising publishers of Great Britain did not long ere this, enter upon such an undertaking as a Cyclopædia of Practical Medicine."—*London Medical Gazette*.

"The Cyclopædia of Practical Medicine, a work which does honour to our country, and to which one is proud to see the names of so many provincial physicians attached."—*Dr. Hastings' Address to Provincial Medical and Surgical Association*.

"Of the medical publications of the past year, one may be more particularly noticed, as partaking from its extent and the number of contributors, somewhat of the nature of a national undertaking, namely, the 'Cyclopædia of Practical Medicine.' It accomplishes what has been noticed as most desirable, by presenting, on several important topics of medical inquiry, full, comprehensive, and well-digested expositions, showing the present state of our knowledge on each. In this country, a work of this kind was much wanted: and that now supplied cannot but be deemed an important acquisition. The difficulties of the undertaking were not slight, and it required great energies to surmount them. These energies, however, were possessed by the able and distinguished editors, who, with diligence and labour such as few can know or appreciate, have succeeded in concentrating in a work of moderate size, a body of practical knowledge of great extent and usefulness."—*Dr. Barlow's Address to the Med. and Sur. Association*.

"This Cyclopædia is pronounced on all hands to be one of the most valuable medical publications of the day. It is meant to be a library of Practical Medicine. As a work of reference it is invaluable. Among the contributors to its pages many of the most experienced and learned physicians of the age, and as a whole it forms a compendium of medical science and practice from which practitioners and students may draw the richest instruction."—*Western Journ. of Med. and Surgery.*

"In our last number we noticed the publication of this splendid work by Lea and Blanchard. We have since received three additional parts, an examination of which has confirmed us in our first impression, that as a work of reference for the practitioner—as a cyclopædia of practical medicine—it is admirably adapted to the wants of the American profession. In fact, it might advantageously find a place in the library of any gentleman, who has leisure and taste for looking somewhat into the nature, causes, and cure of diseases."—*Western Journal of Med. and Surgery.*

"The favourable opinion which we expressed on former occasions from the specimens then before us, is in no degree lessened by a further acquaintance with its scope and execution."—*Medical Examiner.*

"In conversation with practising physicians, we have been gratified to find that this work comes fully up to the high expectations formed of it from the complimentary notices of the Journals, and that as a work of reference it is regarded as superior to any thing hitherto published on Practical Medicine."—*Western Journal of Med. and Surgery.*

* * * In reply to the numerous inquiries made to them respecting Tweedie's Library of Practical Medicine, the Publishers beg leave to state that its place is supplied, in a great measure, by the Cyclopædia of Practical Medicine, a work much more extended in its plan and execution. The works are entirely distinct and by different authors. The "Library" consists of essays on diseases, systematically arranged. The "Cyclopædia" embraces these subjects treated in a more extended manner, together with numerous interesting essays on all important points of Medical Jurisprudence, Materia Medica and Therapeutics, Obstetrics, History of Medicine, &c., &c. by the first physicians of England, the whole arranged alphabetically for easier reference.

JUST PUBLISHED,

CHAPMAN ON FEVERS, &c.

LECTURES ON THE MORE IMPORTANT
ERUPTIVE FEVERS, HÆMORRHAGES AND
DROPSIES, AND ON GOUT AND RHEUMATISM,
DELIVERED IN THE UNIVERSITY OF PENNSYLVANIA.

By N. CHAPMAN, M. D.,

Professor of the Theory and Practice of Medicine, &c. &c.

In one neat octavo volume.

This volume contains Lectures on the following subjects:

EXANTHEMATOUS FEVERS.

Variola, or Small Pox; Inoculated Small Pox; Varicella, or Chicken Pox; Variolæ Vaccinæ, or Vaccinia, or Cow-pock; Varioloid Disease; Rubeola, Morbilli, or Measles; Scarlatina vel Febris Rubra—Scarlet Fever.

HÆMORRHAGES.

Hæmoptysis, Spitting of Blood; Hæmorrhag'a Nasium, or Hæmorrhage from the Nose; Hæmatemesis, or Vomiting of Blood; Hæmaturia, or Voiding of Bloody Urine; Hæmorrhagia Uterina, or Uterine Hæmorrhage; Hæmorrhoids or Hæmorrhoids; Cutaneous Hæmorrhage; Purpura Hæmorrhagica.

DROPSIES.

Ascites; Encysted Dropsy; Hydrothorax; Hydrops Pericardii; Hydrocephalus Internus, acute, subacute, and chronic; Anasarca; with a Disquisition on the Management of the whole.

GOUT, RHEUMATISM &c &c.

THEY HAVE ALSO FOR SALE

LECTURES ON THE MORE IMPORTANT DISEASES
OF THE
THORACIC AND ABDOMINAL VISCERA,
DELIVERED IN THE UNIVERSITY OF PENNSYLVANIA.

By N. CHAPMAN, M. D.

Professor of the Theory and Practice of Medicine, &c.

In one volume, octavo.

LEA & BLANCHARD PUBLISH AND HAVE FOR SALE,
HORNER'S ANATOMY.

SPECIAL ANATOMY AND HISTOLOGY.

BY WILLIAM E. HORNER, M. D.,

Professor of Anatomy in the University of Pennsylvania, Member of the Imperial Medico-Chirurgical Academy of St. Petersburg, of the Am. Philosophical Society, &c. &c.

Sixth edition, in two volumes, 8vo.

"Another edition of this standard work of Professor Horner has made its appearance to which many additions have been made, and upon which much labour has been bestowed by the author. The additions are chiefly in the department of Histology, or Elementary Anatomy, and so important are they that the Professor has added the term to the title of his work. Every part of this edition seems to have undergone the most careful revision, and its readers may rest assured of having the science of Anatomy fully brought up to the present day."—*Am. Med. Journal.*

**GRAHAM'S CHEMISTRY,
THE ELEMENTS OF CHEMISTRY,**

Including the application of the Science to the Arts.

WITH NUMEROUS ILLUSTRATIONS.

BY THOMAS GRAHAM, F. R. S., L. and E. D.

Professor of Chemistry in University College, London, &c. &c.

WITH NOTES AND ADDITIONS

BY ROBERT BRIDGES, M. D., &c. &c.

In One Vol. Octavo.

The great advancement recently made in all branches of chemical investigation renders necessary a new text book which shall clearly elucidate the numerous discoveries, especially in the department connected with organic Chemistry and Physiology, in which such gigantic strides have been made during the last few years. The present treatise is considered by eminent judges to fulfil all these indications, and to be peculiarly adapted to the wants of the medical student and practitioner. In adapting it to the wants of the American profession, the editor has endeavoured to render his portion of the work worthy the exalted reputation of the first chemist of England. It is already introduced as a text book in many of the Colleges, and has universal approbation.

"Professor Graham's work is one of the best, if not the best, of all English text books, and is of such recent date as to embrace all the latest discoveries. The appearance of a correct and amended American Edition, under the care of Dr. Bridges, will prove an acceptable thing to both teachers and students of Chemistry in this country."—*Silliman's Journal.*

PEREIRA'S MATERIA MEDICA.

WITH NEAR THREE HUNDRED ENGRAVINGS ON WOOD.

**THE ELEMENTS OF
MATERIA MEDICA AND THERAPEUTICS.**

COMPREHENDING THE NATURAL HISTORY, PREPARATION, PROPERTIES,

COMPOSITION, EFFECTS, AND USES OF MEDICINES.

BY JONATHAN PEREIRA, M. D., F. R. S. and L. S.

From the Second London Edition, enlarged and improved.

WITH NOTES AND ADDITIONS

BY JOSEPH CARSON, M. D.

In Two Vols. Octavo.

The object of the author has been to supply the Medical Student with a Class Book on Materia Medica, containing a faithful outline of this Department of Medicine which should embrace a concise account of the most important discoveries in Natural History, Chemistry, Physiology and Therapeutics, in so far as they pertain to Pharmacology, and treat the subjects in the order of their natural historical relations.

This great *Library or Cyclopædia of Materia Medica* has been fully revised by DR. JOSEPH CARSON, professor of Materia Medica and Pharmacy in the "College of Pharmacy," and forms Two Volumes, octavo, of near 1600 large and closely-printed pages. It may be fully relied upon as a permanent and standard work for the country,—embodying, as it does, full references to the U. S. Pharmacopœia and an account of the Medical Plants indigenous to the United States.

FERGUSON'S PRACTICAL SURGERY.

A SYSTEM OF PRACTICAL SURGERY,

BY WILLIAM FERGUSON, F. R. S. E.,

Professor of Surgery in King's College, London; Surgeon to King's College Hospital, &c. &c.

WITH TWO HUNDRED AND FORTY-SIX ILLUSTRATIONS.

Engraved by Gilbert, after drawings by Bagg.

WITH NOTES AND ADDITIONAL ILLUSTRATIONS

BY GEORGE W. NORRIS, M. D.,

In one volume octavo.

The publishers commend this work to the attention of the Profession as combining *cheapness and elegance* with a clear, sound, and practical treatment of every subject in surgical science. No pains or expense have been spared to present it in a style equal, if not superior to the London edition, and to match the editions of "Wilson's Anatomy," "Churchill's System of Midwifery," and "Carpenter's Human Physiology." It is now extensively used as a text book.

LEA AND BLANCHARD ARE PREPARING FOR PUBLICATION

**A MANUAL OF ELEMENTARY CHEMISTRY,
THEORETICAL AND PRACTICAL.**

By GEORGE FOWNES, PH. D.

WITH NUMEROUS WOOD ENGRAVINGS,
And Notes and Additions by

ROBERT BRIDGES, M. D.,

Professor of Chemistry in the "Philadelphia Medical Association," &c. &c.

In one vol. royal 12mo.

HOBLYN'S DICTIONARY.

**A DICTIONARY OF TERMS USED IN MEDICINE
AND THE COLLATERAL SCIENCES,
FOR THE USE OF STUDENTS.**

BY RICHARD D. HOBLYN, M. D., &c.

From the Second London Edition, with numerous additions.

BY ISAAC HAYS, M. D., &c.

In One Volume, royal 12mo.

GUTHRIE ON THE ANATOMY OF THE BLADDER AND THE URETHRA,

AND THE

TREATMENT OF THE OBSTRUCTIONS TO WHICH THOSE PASSAGES ARE LIABLE.

From the Third London Edition,

In one volume, 8vo.

ALSO,

**ANOTHER VOLUME OF THE SPLENDID SERIES OF THE
WORKS OF SIR ASTLEY COOPER.**

COOPER ON THE ANATOMY AND DISEASES OF THE BREAST.

The whole to form one large and beautiful imperial octavo volume, with numerous plates in the best style of Lithography, and printed and bound to match the volumes on Hernia and the Testis already issued.

L. & B. HAVE LATELY PUBLISHED

CARPENTER'S PHYSIOLOGY.

PRINCIPLES OF HUMAN PHYSIOLOGY.

With their chief applications to Pathology, Hygiene, and Forensic Medicine. Especially designed for the use of Students.

With over One Hundred beautiful Illustrations on Wood.

BY WILLIAM B. CARPENTER, M. D.,

Lecturer on Physiology in the Bristol Medical School.

FIRST AMERICAN EDITION, WITH NOTES BY THE AUTHOR, AND NOTES AND ADDITIONS

BY MEREDITH CLYMER, M. D.,

In one volume, octavo.

☞ This edition of Carpenter's Physiology has been most carefully prepared by Dr. Clymer, at the request of Professor Jackson, for his lectures at the University of Pennsylvania.

ALISON'S PATHOLOGY.

A NEW WORK.

**OUTLINES OF PATHOLOGY AND
PRACTICE OF MEDICINE.**

BY WILLIAM PULTENEY ALISON, M. D.,

Professor of the Practice of Medicine in the University of Edinburgh, &c. &c.

In three Parts—Part I.—Preliminary Observations—Part II.—Inflammatory and Febrile Diseases, and

Part III., Chronic or Non-Febrile Diseases.

In one volume octavo.

**For numerous other works not detailed, see the Two following
Pages.**

WORKS
IN THE VARIOUS DEPARTMENTS
OF
MEDICINE AND SURGERY:

PUBLISHED
BY
LEA & BLANCHARD.

ANATOMY.

ANATOMICAL ATLAS, illustrative of the Structure of the Human Body; with over Six Hundred Illustrations; the most complete work of the kind ever issued,—beautifully executed, in One Volume Imperial Octavo; by H. H. Smith, M.D., under the supervision of Professor W. E. Horner.

HORNER'S Special Anatomy and His-

tology; 6th edition, much improved. 2 vols. 8vo., 1114 pages.

WILSON'S Human Anatomy; a new edition (the second) revised, with additions by Dr. Goddard: 207 beautiful cuts. 8vo., 608 pages.

WILSON'S Dissector, or Practical and Surgical Anatomy; with additions by Goddard—106 cuts. Royal 12mo., 444 pages.

PHYSIOLOGY.

CARPENTER'S Human Physiology; with notes and additions by Meredith Clymer, and over 100 cuts—in 8vo., 618 pages.

DUNGLISON'S Human Physiology; the fifth edition, with numerous additions and 300 cuts—in 2 vols. 8vo., 1304 pages.

HARRISON on the Nervous System; 8vo., 292 pages.

MÜLLER'S Elements of Physiology by Baly, arranged by Bell—8vo., 886 pages.

ROGET'S Outlines of Physiology—8vo., 516 pages.

PATHOLOGY.

ABERCROMBIE on the Brain. 3d edit. —on the Stomach. 4th edit.

ALISON'S Outlines of Pathology. 8vo., 424 pages.

ANDRAL on the Blood in Disease. 130 pages, 8vo.

BELL on the Teeth, with plates—8vo., 350 pages.

BERZELIUS on the Kidneys and Urine. 8vo., 178 pages.

BARTLETT on the Fevers of the United States—8vo., 394 pages.

BILLINGS' Principles of Medicine—8vo., 304 pages.

BRODIE on the Urinary Organs. 8vo., 214 pages.

BRODIE on the Diseases of the Joints. 8vo., 216 pages.

CHAPMAN on Thoracic and Abdominal Viscera. 8vo., 384 pages.

CHAPMAN on Eruptive Fevers, &c. 8vo., 448 pages.

HOPE'S Treatise on the Diseases of the

Heart and Great Vessels, with additions by Pennock. 8vo., 572 pages.

JONES and TODD on the Diseases of the Ear, edited by Dr. Hays; with numerous cuts. 8vo., pages—preparing.

LAWRENCE'S Treatise on the Diseases of the Eye, with additions by Hays, and numerous cuts. 8vo., 778 pages.

PROUTS' Treatise on Stomach and Renal Diseases, with coloured plates. 8vo., 466 pages.

PHILIP'S Treatise on Protracted Indigestion. 8vo., 240 pages.

RICORD'S Treatise on Venereal Diseases. 8vo., 256 pages.

WALSHE'S Diagnosis of the Diseases of the Lungs. 12mo., 310 pages.

WILSON on the Diseases of the Skin. 8vo., 370 pages.

WILLIAMS' Principles and Pathology, with additions by Clymer. 8vo., 384 pages.

WILLIAMS on the Respiratory Organs, edited by Clymer. 8vo., 508 pages.

PRACTICE OF MEDICINE.

ASHWELL on the Diseases of Females, by Goddard. 1 vol. 8vo., pages—nearly ready.

CONDIE'S Practical Treatise on the Diseases of Children. 1 vol. 8vo., 650 pages.

CHURCHILL on the Diseases of Females, including those of Pregnancy and Childbed; with additions by Huston. 8vo., 596 pages. 3d edition.

COATES' Popular Medicine. 8vo. 514 pp.

LEA AND BLANCHARD'S PUBLICATIONS.

- DEWEES on the Diseases of Children. 8th edition; 8vo., 548 pages.
 DEWEES on the Diseases of Females. 8vo., with plates, 532 pages.
 DUNGLISON'S Practice of Medicine. Second edition, in 2 volumes 8vo., 1322 pages.
- TWEEDIE'S Library of Practical Medicine. Second edition, revised; in 3 vols. large 8vo., 2016 pages.
 Any one of the five volumes of the first edition can be had separate.
 WATSON on the Principles and Practice of Physic. 8vo., 920 large pages.

SURGERY.

- COOPER'S (Sir Astley) Treatise on Hernia, with lithographic plates. Imperial 8vo., 428 pages.
 COOPER (Sir Astley) on the Testis and Thymus Gland, with lithographic plates. Imperial 8vo., 1 vol.
 COOPER (Sir Astley) on Dislocations and Fractures, with numerous cuts, and a Memoir and Portrait. 8vo., 500 pages.
 DRUITT'S Modern Surgery. Second edition, with 153 cuts; 8vo., 568 pages.
- FERGUSON'S System of Practical Surgery, edited by Norris, with 246 cuts. 8vo., 630 pages.
 HARRIS on the Maxillary Sinus. 8vo., 164 pages.
 LAWRENCE'S Treatise on Ruptures. 8vo., 480 pages.
 MAURY'S Dental Surgery, with numerous plates and cuts. 8vo., 286 pages.
 ROBERTSON on the Teeth. 8vo., 230 pages.

THERAPEUTICS AND MATERIA MEDICA.

- DUNGLISON'S Therapeutics and Materia Medica; a new work. 2 vols. 8vo., 1004 pages.
 DUNGLISON'S Treatise on New Remedies. Fifth edition, 8vo., 616 pages.
- ELLIS' Medical Formulary, by Morton. Seventh edition, 8vo., 262 pages.
 PEREIRA'S Elements of Materia Medica and Therapeutics; edited by Carson, with 280 cuts. 2 vols. 8vo., 1566 pages.

OBSTETRICS.

- CHURCHILL on the Theory and Practice of Midwifery, by Huston; 116 cuts. 8vo., 520 pages.
 DEWEES' System of Midwifery, with plates. Tenth edition, 8vo., 660 pages.
- RIGBY'S System of Midwifery, with cuts. 8vo., 492 pages.
 RAMSBOTHAM on Parturition, with figures in lithography. Imperial 8vo., 458 pages.

CHEMISTRY, MEDICAL PHYSICS AND HYGIENE.

- ARNOTT'S Elements of Physics, with numerous cuts. One volume 8vo., 520 pages.
 DUNGLISON on Human Health; a second edition revised, with additions. 8vo., 464 pages.
 GRAHAM'S Elements of Chemistry, by Bridges, with numerous cuts. 8vo., 750 pp.

MEDICAL JURISPRUDENCE AND MEDICAL EDUCATION.

- CHITTY'S Medical Jurisprudence.—8vo., 510 pages.
 DUNGLISON'S Medical Student; a new edition, large 12mo.
- TRAILL'S Medical Jurisprudence.—8vo., 234 pages.
 TAYLOR'S Medical Jurisprudence, by Griffith. 1 vol. 8vo., 540 very large pages.

DICTIONARIES AND JOURNALS.

- AMERICAN JOURNAL OF THE MEDICAL SCIENCES; edited by Dr. Isaac Hays, published Quarterly at Five Dollars a Year.
 CYCLOPEDIA OF PRACTICAL MEDICINE; comprising Treatises on the nature and treatment of Diseases, including those of *Women and Children, Materia Medica, Therapeutics, Medical Jurisprudence, &c., &c.* Edited by Forbes, Tweedie, Conolly and Dunglison. 4 large Super-Royal Octavo Volumes. About 3000 pages in double columns.
 DUNGLISON'S Medical Dictionary; 4th edition, containing over 40,000 words and synonymes; large 8vo., of 772 pages, double columns.
 MEDICAL NEWS AND LIBRARY. Published Monthly at One Dollar a Year.
 SELECT MEDICAL ESSAYS; by Drs. Dunglison, Chapman and others.—2 vols. 8vo., 1150 pages.

THE AMERICAN JOURNAL OF THE MEDICAL SCIENCES.

LEA & BLANCHARD are the Publishers of the American Journal of the Medical Sciences, Edited by ISAAC HAYS, M. D., Surgeon to Wills' Hospital, Physician to the Philadelphia Orphan Asylum, Member of the Am. Philos. Soc., &c. &c. &c., assisted by numerous collaborators in every section of the Union.

This Journal was commenced TWENTY-FIVE YEARS AGO, and it is therefore the oldest Medical Journal now existing in the United States, and its permanency may be considered as established.

It was originally edited by Dr. Chapman, who has been a constant contributor to its pages; and, for the last eighteen years, it has been under the editorial direction of Dr. Isaac Hays.

The pages of this Journal contain the records of the experience of the most distinguished members of the Profession in every part of the Union.

CONTENTS OF THE NO. FOR JANUARY, 1845.

MEMOIRS AND CASES.—ART. I. Cases of Strangulated Hernia, with some remarks principally intended to show the necessity of an early resort to the operation: By John C. Warren, M. D. II. On the Pathology of Remittent Fever. By John A. Swett, M. D. III. On the treatment of Yellow Fever. By F. Wurdemann, M. D. IV. On the Pulse of the Insane, by Pliny Earle, M. D. V. Temporary Protrusion of the Eyeball, with loss of Vision, from rheumatic inflammation. By Isaac G. Porter, M. D. VI. On Obstetrical Auscultation. By L. S. Joyne, M. D. VII. Tumour of the Neck, of extraordinary size, successfully removed. By P. C. Spencer, M. D. [With two wood cuts] VIII. Surgical Cases. By Edwin Hall, M. D. IX. Cases of Strangulated Hernia. By A. B. Shipman, M. D.

REVIEWS.—X. *Pouchet* on the Fecondation of the Mammiferæ. *Raciborski* on Puberty and the Critical Age in Women, and of the Periodical Discharge of Ova, &c. *Bischoff* on the Proof of the Periodical Ripening and Separation of the Ova of Mammalia and Man, independent of Cœtus. XI. *Chadwick* on Intermittent in Towns.

BIBLIOGRAPHICAL NOTICES.—XII. 1. The Twentieth Annual Report of the Officers of the Retreat for the Insane at Hartford. 2. Eighth Annual Report of the Physician and Superintendent of the Vermont Asylum for the Insane. 3. Report of the Superintendent of the Boston Lunatic Hospital, and Physician of the Public Institutions of South Boston.—XIII. 1. Reports of the state of the Kent County Lunatic Asylum. 2. Statements of the Visiting Committee of the County Lunatic Asylum, near Gloucester. 3. The Report of the Committee of Visitors of the Lunatic Asylum for the County of Leicester. 4. Thirty-third Annual Report of the General Lunatic Asylum, near Nottingham. 5. Reports of the Medical Officers of the Lunatic Asylum for the County of Lancaster. 6. Fifty-ninth, Sixty-fourth and Sixty-Eighth Reports of the Visiting Justices of the County Lunatic Asylum at Hanwell. XIV. *Zeis* on the Plastic Surgery of Celsus: on Organic Adhesions: and on inverted Toe-Nail. XV. *Wattman* on Means of Preventing the Rapid Occurrence of Fatal Symptoms in the Accidental Introduction of Air into the Veins. XVI. *Hennemann* on a New Series of Subcutaneous Operations. XVII. *Hufeland's* Eucheridion Medicum. XVIII. Summary of the Transactions of the College of Physicians of Philadelphia. March to October, 1844. XIX. *Chapman* on the more important Eruptive Fevers, Hæmorrhages and Dropsies, and on Gout and Rheumatism.

SUMMARY OF THE IMPROVEMENTS AND DISCOVERIES IN THE MEDICAL SCIENCES.

ANATOMY AND PHYSIOLOGY.—1. *Scherer* on the Coloration of the Blood. 2. *Jobert de Lamballe* on the Structure of the Uterus. 3. *Müller* on the products of the oxidation of Protein in the Animal Organism. 4. *Moreau* on the causes which determine the Sex in Generation. 5. *Magendie* on the Influence of Heat and of Stoves on Animal Life. 6. *Bernard* and *Barrès* on Alimentary Substances. 7. *Schvan* on the importance of Bile in the Living Animal Organism. 8. *Blaquiere* on Gunshot Wound of the Anterior Cerebral Lobes. 9. *Boudet* on the Chemical Composition of the Pulmonary Parenchyma and of Tubercles.

MATERIA MEDICA AND PHARMACY.—10. *Seiditz* on Cotton as a Dressing to Blisters. 11. *Devay* on the mode of preparing the Valerianate of Zinc. 12. *Bouchardat* on Croton Oil Plaster. 13. *Millot* on the Lithontriptric action of the Gastric Juice. 14. *Gumprecht* on Cortex Frangulae. 15. *Scheidemandel* on the mode of preparing some Narcotic Extracts in small quantities. 16. *Burton* on a new method of making Medicated Tinctures. 17. *Hoffman* on Caroub of Judea in Asthmatic Affections.

MEDICAL PATHOLOGY AND THERAPEUTICS AND PRACTICAL MEDICINE.—18. *Lossette* on Small-pox in persons who had been Vaccinated. 19. *Bertini* and *Bellingiere* on Nitrate of Silver in Chronic Diarrhea. 20. *Bellingiere* on Balsam of Copaiba in Chronic Bronchitis. 21. *Druitt* on the uses of Pure Tannin. 22. *Foucault* on the causes of Albuminuria. 23. *Meyer's* Researches on Albuminuria. 24. *Rees* on the Pathology and Treatment of the Morbus Brightii, and various forms of Anæmia. 25. *Gregory* on Deaths from Small-pox after Vaccination, in London. 26. *Devay* on Valerianate of Zinc in Nervous Affections. 27. *Perini* on a singular case of Encephalitis. 28. *Salvagnoli* on Analysis of the Blood of Persons Exposed to Malaria. 29. *Esterlen* on the Passage of Metallic Mercury into the Blood and Solid Tissues. 30. *Lamothe* on Epilepsy caused by a Foreign Body in the Ear, and cured by its removal. 31. Symptoms of Acute Pleurisy, caused by Intestinal Worms. 32. *J. and J. H. Smith* on Sulphate of Iron combined with an Alkaline Carbonate, an Antidote for Prussic Acid. 33. *Mac Donnel* on the Diagnosis of Empyema. 34. *Mondiere* on a Tænia evacuated through an opening in the Abdominal Parietes. 35. *Trousseau* on the Signs of Auscultation in Young Children.

SURGICAL PATHOLOGY AND THERAPEUTICS AND OPERATIVE SURGERY.—36. *Syme* on treatment of Obstinate Stricture of the Urethra. 37. *Reybard* on Suture of the Intestine. 38. *Bodinier* on the Nature and Source of the Liquid which flows from the Ear producing Œdema of the Scalp. 39. *Danville* on Gunshot Wound, where the charge passed from the Navel to the Back without fatal consequences. 40. *Sandham* on mode of Reducing Partial Displacement of the Semi-lunar Cartilages of the Knee-joint. 41. *Porter* on Operation for the Radical Cure of Hydrocele. 42. Two cases of Luxation of the Iliac Bone upon the Sacrum. 43. Singular cause of Error in Diagnosis of Affections of the Knee. 44. *Daniell* on Wart-like Excrescences near the Verge of the Anus. 45. *Daniell* on Enormous Steatoma removed from the Shoulder. 46. *Jeaffreson* on Operations for Removal of Ovarian Tumours. 47. *Bird* on Removal of a Diseased Ovary. 48. *Wiesel* on Ununited Fracture Successfully Treated by Acupuncture. 49. *Monin* on Luxation of the Forearm forwards without fracture of the Olecranon. 50. *Segalas* on Influence of Traumatic Lesions of the Spinal Cord on Diseases of the Urinary Passages. 51. *Wilbrand* on the Treatment of Syphilis by Tartar-emetie. 52. *Barbier's* case of Recovery from Wound with Hernia of the Lung. 53. *Syme* on Popliteal Aneurism in a Child. 54. *Rognetta* on Epidemic Erysipelas. 55. *Inman* on Mortality attending the operation of Tying the Large Arteries. 56. *Vanzetti* on Fibrous Tumour of the Parotid. 57. *Vidal* on New Operation for Varicocele. 58. *Inman* on Mortality attending the Operation for Hernia. 59. *Laugier* on Immovable Bandages of Starched Paper for the Treatment of Fractures of the Limbs. 60. *Cox* on Gunshot Wound of the Chest—evacuation of the ball per anum. 61. *Wilde* on Discharges from the Ears. 62. *Syme* on Bursal Swelling of the Wrist and Palm of the Hand.

OPHTHALMOLOGY.—63. *Morant* on Epidemic Ophthalmia. 64. *Bernard's* Method of Curing Lachrymal Fistulae and Chronic Lachrymations reputed incurable. 65. *Dalrymple* on Cyst attached to the Anterior Surface of the Iris.

MIDWIFERY.—66. *Prael* on Cæsarian operation performed with success both for the mother and child; rupture of the uterus and of the abdominal parietes thirteen months subsequently, during a second pregnancy; delivery of the fetus through this spontaneous opening; complete recovery of the mother. 67. *Fischer's* case of Gravid Uterus passing into the Sac of an old Inguinal Hernia.—Cæsarian Section. 68. *Aubinais* on Polypus of the Uterus adherent to the Placenta Successfully Removed. 69. *Ginestet* on the Juice of the Urtica Urens in Uterine Hemorrhage. 70. *Darby* on Prolapsed Uterus—Pregnancy. 71. *Lee* on Dropsy of the Amnion. 72. *Lee* on the Causes and Treatment of Uterine Hemorrhage, in the latter months of pregnancy. 73. *Lee* on Retained Placenta. 74. *Lisfranc* on Diagnosis of Inverted Uterus and Polypus. 75. *Murphy's* Statistics of Obstetric Practice.

MEDICAL JURISPRUDENCE AND TOXICOLOGY.—76. *Olivier* on Arsenic in the Earth of Cemeteries. 77. *Ramsay* on Aconitum Napellus. 78. *Jacob* on Poisoning by Euphorbia Lathyris. 79. Rupture of the Omentum. 80. *Lisfranc's* opinion on some Disputed Points in Obstetrical Medical Jurisprudence. 81. Hereditary Insanity, how far, in cases of alleged unsoundness of mind, it may be pleaded. 82. *Simpson* on Relative Weight and Size of the Male and Female at Birth. 83. Copper Tanks at St. Helena. 84. Trial for Murder. 85. Case of Suicide. 86. Recent English Law Cases. 87. Obituary of *Dr. Abercrombie*.

AMERICAN INTELLIGENCE.—Original Communications.—*Horne* on the Preservation of the Human Body for Anatomical Purposes. Proceedings of the Association of Medical Superintendents of American Institutions for the Insane. *Perkins's* Cases of Congestive Fever.

DOMESTIC SUMMARY.—*Fougeand* on Mortality among Children in St. Louis. *Le Conte* on Extraordinary Effects of a Stroke of Lightning. *Bowles* on Removal of a Diseased Ovary. *Herrick* on Rupture of the Spleen. *Mathews* on Fracture during Pregnancy. *Buck and Watson* on Opium a Hazardous Remedy in Strangulated Hernia. Yellow Fever at Woodville, Miss. *Davis* on Colon Strangulated by the Meso-colon. *Clark* on Discharge of a Lumbrius from the Male Urethra. *M'Dowell's* cases of Extirpation of Diseased Ovaria New Works. Death of *Dr. Forry*.

AMERICAN MEDICAL JOURNAL.

PUBLISHERS' NOTICE.

IN presenting the first number for the year of THE AMERICAN JOURNAL OF THE MEDICAL SCIENCES, the Publishers must offer their thanks to the profession for the increased favour extended to this long-established periodical, now the oldest Medical Journal in the Union. As an evidence of this patronage it may be stated, that notwithstanding an enlarged edition was printed for last year, at the present time not a single copy of the January or October numbers can be supplied.

It is intended to continue the work as heretofore, with about 264 large pages, quarterly, with such cuts and plates as are essential to illustrate the different papers; and *particular attention* is invited to that portion embracing

THE RETROSPECT FOR THE QUARTER,

Presenting, as it does, the most copious Summary of the Improvements and Discoveries in Medicine and Surgery, from all the various Journals published abroad and at home.

With a view of extending the circulation of the Journal, the publishers are now furnishing, with it—

A MONTHLY PERIODICAL, FREE OF CHARGE,
to such subscribers as remit Five Dollars in advance.

Attention is solicited to the following terms:—

Those persons who remit Five Dollars by the first of March, will receive not only The Medical Journal for 1845, but the Medical News and Library for 1845, free from any further charge.

For Ten Dollars they will furnish the Journal for 1845 and 1846, and the News for 1844, 1845 and 1846 free from any further charge.

Subscribers who have not yet paid for the year 1844, are particularly requested to remit at once, and are informed that if Ten Dollars are remitted at once it will be placed to their credit for the Journal for 1844 and 1845, and the News for the same years sent free of charge.

No such terms can be made except to subscribers who remit *in advance, free of postage, and direct to the Publishers.*

Agents can furnish the News *gratis* to be sent by mail, only in cases where the subscription, Five Dollars, for the Journal, is *paid in advance*; under no other circumstances will they send The News gratis.

Early orders are solicited, as very few more copies of the Journal will be printed than are actually subscribed for, and subscribers may be disappointed in obtaining the early Numbers of the year, as was the case in the last volume.

The *Medical News and Library* for 1845 will contain, in addition to the News of the month,


THE SURGICAL LECTURES OF SIR BENJAMIN BRODIE;

Thus following Watson's Practice of Physic, (which occupied the Library portion of the News for 1843 and 1844,) with a work on Surgery of great practical value, and by one of the first and most authoritative surgeons of the day. The pages of the Lectures will be so arranged that, when complete, they can be bound in a volume.

The News and Library will be issued monthly, and contain 32 pages, and go by mail as a newspaper. Price One Dollar a year, payable in advance, and in current funds, free of postage.

Postmasters are at liberty to frank remittances in payment for subscriptions.

The Publishers beg to present the Contents of the Journal for January 1845, which will be found on the preceding page.

 This paper may be delivered to any physician if declined by the person to whom it is addressed or if they have removed—and Postmasters and others will particularly oblige the publishers by furnishing a list of the Physicians and Lawyers of their county or neighbourhood. In addition to the business it may bring to the office, a copy of "The Complete Florist," or such other volume, will be sent by mail gratis for any ten or more names furnished free of cost.

Philadelphia, January, 1845.



