

COLUMBIA LIBRARIES OFFSITE
HEALTH SCIENCES STANDARD



HX00063568

RECAP


RD101


1907 St5

Columbia University
in the City of New York
College of Physicians and Surgeons



Reference Library





Digitized by the Internet Archive
in 2010 with funding from
Open Knowledge Commons

A PRACTICAL TREATISE

ON

FRACTURES AND DISLOCATIONS.

BY

LEWIS A. STIMSON, B. A., M. D., LL. D. (YALEN),

PROFESSOR OF SURGERY IN CORNELL UNIVERSITY MEDICAL COLLEGE, NEW YORK; SURGEON TO THE NEW YORK AND HUDSON ST. HOSPITALS; CONSULTING SURGEON TO BELLEVUE, ST. JOHNS, AND CHRIST HOSPITALS; CORRESPONDING MEMBER OF THE SOCIÉTÉ DE CHIRURGIE OF PARIS.

FIFTH EDITION, REVISED AND ENLARGED.

WITH 352 ILLUSTRATIONS AND 52 PLATES IN MONOTINT.



LEA BROTHERS & CO.,
NEW YORK AND PHILADELPHIA.

RD101

\$45

1907

Entered according to Act of Congress in the year 1907, by
LEA BROTHERS & CO.,
in the Office of the Librarian of Congress, at Washington. All rights reserved.

PREFACE TO THE FIFTH EDITION.

THE two volumes in which this work originally appeared were so extensively rewritten for the edition in one volume, published in 1899, that it was then practically a new book. The author gratefully acknowledges the favor which exhausted that edition in about a year, and which has continued and strengthened, as shown by the demand for three larger editions since. On each occasion he has endeavored to respond by revising it to date. The volume continues to embody the experience gained in the House of Relief (Hudson Street Hospital), where traumatic cases are so numerous as to include all the ordinary forms of injury, and most of those which are rare. So wide indeed is this clinical field that a number of lesions were first observed there and described in this work. These facts gave the opportunity for and seemed to justify in the successive editions a more personal form for the book, with a reduction in the number of quotations of histories and of opinions based upon single cases. This enabled the author not only to introduce such additions as were made to our knowledge of the subject in the intervals, but also to adapt the work more specifically to the needs of the practitioner, especially in regard to diagnosis and treatment, while the requirements of the student of special subjects were heeded in the bibliographical references, which were largely augmented.

Notable increase in our knowledge of details has come through the accumulation of data obtained by the use of the *x*-ray in recent and old cases, especially in fractures involving joints and the small bones. The results constituted a prominent feature of the fourth edition and have again led to important additions in the present one, where they appear largely among the observations and studies of injuries of the bones of the wrist and foot, and of fractures and dislocations of the ends of the large bones. For example, important additions have

been made to the sections covering fractures of the carpal and scaphoid bones, of the upper end of the radius and the tarsal bones, and dislocations of the semilunar, most of which have been the theme of many recent papers and the subject of many observations and experiments. The reports of rarer forms of injury have increased so greatly that it has become impossible as well as unnecessary to mention or quote them all, and I again thank the many friends who have so kindly sent them to me. They have made it possible in several cases to substitute general descriptions for the quotation of one or two examples.

The illustrations have been freshened by the addition or substitution of about thirty new cuts and twelve new skiagrams in the plates.

LEWIS A. STIMSON.

277 LEXINGTON AVENUE, NEW YORK,
1907.

CONTENTS.

FRACTURES.

CHAPTER I.

INTRODUCTION.

	PAGE
Definitions, statistics, influences of sex, age, and season	19

CHAPTER II.

PATHOLOGY.

A. The bone ; varieties of fracture	22
1. Incomplete fractures	23
(a) Fissures	23
(b) True incomplete, green-stick ; infraction	24
(c) Depressions	24
(d) Separation of a splinter or apophysis	24
2. Complete fractures ; subdivided according to	25
(a) Direction and character of the line of fracture	25
(b) The seat of fracture	29
Separation of epiphysis	29
(c) Intra-articular	31
3. Multiple fractures	31
4. Compound fractures	31
5. Gunshot fractures	33
Displacements	35
B. The soft parts	37

CHAPTER III.

ETIOLOGY.

Predisposing causes	39
External, normal, interstitial atrophy	39
Inherited liability	40
Determining causes	40
External violence, direct or indirect	40
Muscular action	41
Spontaneous and pathological fractures	44
General diseases	44
Diseases of nerve centres	46
Rachitis, syphilis, rheumatism	46
Cancer and sarcoma	47
Cysts, osteomyelitis	48
Intra-uterine, and during delivery	48

CHAPTER IV.

EARLY SYMPTOMS AND DIAGNOSIS.

Objective signs	50
Deformity (normal asymmetry)	50
Abnormal mobility	51
Crepitus	52
Subjective or rational symptoms	53
Loss of function ; pain	53
History	54

CHAPTER V.

REPAIR OF FRACTURES AND CLINICAL COURSE.

	PAGE
Anatomo-pathological processes	57
The callus	57
In compound fracture	61
In short and flat bones	62
At the epiphyseal line	63
Clinical course	64

CHAPTER VI.

COMPLICATIONS AND REMOTE CONSEQUENCES.

Early local complications	67
Skin. Bloodvessels	67, 68
Gangrene. Degeneration of muscles	69
Suppuration	70
Early general complications	70
Septicæmia	70
Fat embolism	71
Delirium tremens, tetanus, pneumonia	72
Late local complications	73
Excessive or painful callus	73
Development of a tumor	74
Injury of a nerve	74
Weakness of callus	75
Arrest or exaggeration of growth	76
Stiffness of the joints	76
Atrophy. Thrombosis and embolism	77
Arteries	78

CHAPTER VII.

TREATMENT.

Reduction	80
Retention	85
Temporary and removable dressings	87
Wooden and metal splints	88
Volkman's splint	89
Anterior suspended splints	90
Moulded splints	91
Permanent or final dressings	93
Encasement in plaster	94
Traction, Buck's extension	96
Hodgen's splint, long side splint	97
Vertical suspension. Double inclined plane	98
Direct fixation	99
Massage	101
Ambulatory treatment	102
Management of the joints	104
Compound fractures	106
By indirect violence	106
By direct violence	107
Gunshot fractures	108
Amputation	109
Compound articular fractures	110
General treatment	111

CHAPTER VIII.

DELAYED UNION, FAILURE OF UNION, FAULTY UNION.

Delayed union ; failure of union	112
Pathology	112
Etiology	113

	PAGE
Delayed union: symptoms	115
Treatment	115
Faulty or vicious union	117
Treatment	118

CHAPTER IX.

GENERAL PROGNOSIS	120
-----------------------------	-----

CHAPTER X.

FRACTURES OF THE SKULL.

Mechanism and pathology	124
Exceptional forms	129
Internal table	130
Injuries of brain	131
Pathological and reparative processes	132
Symptoms, diagnosis, and treatment	133
Circumscribed fractures of the vault	134
Fissured fractures with generalized brain injury	136
Internal table	138
Rupture of the middle meningeal artery	139
Perforating fractures of the base	140
Summary	141

CHAPTER XI.

FRACTURES OF THE VERTEBRÆ.

Pathology	143
Hæmatomyelia	146
Etiology	146
Symptoms and diagnosis	147
Atlas and axis	148
Lower five cervical and first two dorsal	150
Lower dorsal and first two lumbar	152
Lower three lumbar	153
Course and termination	153
Treatment	156

CHAPTER XII.

FRACTURES OF THE BONES OF THE FACE.

1. Nose	160
2. Malar bone and zygoma	162
3. Superior maxilla	164
4. Inferior maxilla	166

CHAPTER XIII.

FRACTURES OF THE HYOID BONE	173
---------------------------------------	-----

CHAPTER XIV.

FRACTURES OF THE LARYNX AND TRACHEA	175
---	-----

CHAPTER XV.

FRACTURES OF THE STERNUM	177
------------------------------------	-----

CHAPTER XVI.

FRACTURES OF THE RIBS AND THEIR CARTILAGES	183
--	-----

The ribs	183
The costal cartilages	188

CHAPTER XVII.

FRACTURES OF THE CLAVICLE.

	PAGE
Pathology	192
1. Middle third	193
2. Outer third	194
3. Inner third	195
Multiple fractures. Complications	196
Etiology	198
Symptoms and course	199
Simultaneous fractures of both clavicles	201
Treatment	202

CHAPTER XVIII.

FRACTURES OF THE SCAPULA.

1. Of the body of the scapula	208
2. Of the inferior angle	210
3. Of the upper angle	211
4. Of the spine	211
5. Of the acromion	211
6. Of the coracoid process	213
7. Of the neck	214
8. Of the glenoid cavity	216

CHAPTER XIX.

FRACTURES OF THE HUMERUS.

1. Fractures of the upper end of the humerus	217
A. Fractures of the head	218
B. Fractures of the anatomical neck and fracture through the tuberosities	218
C. Fractures of the tuberosities	222
D. Separation of the epiphysis	225
E. Fracture of the surgical neck	229
Symptoms	232
Diagnosis	233
Prognosis, treatment	234
2. Fractures of the shaft of the humerus	238
3. Fractures of the lower end of the humerus	242
A. Fractures above the condyles—supracondyloid	244
B. Fractures of the internal epicondyle	249
C. Fractures of the external epicondyle	251
D. Fractures of the internal condyle	251
E. Fractures of the external condyle	253
F. Intercondyloid, T-shaped or Y-shaped fractures	256
G. Separation of the epiphysis	258
H. Fractures of the articular process	259
Of the capitellum	259
Of the trochlea	261
Diagnosis	261
Treatment	262

CHAPTER XX.

FRACTURES OF THE BONES OF THE FOREARM.

1. In the vicinity of the elbow-joint	263
A. Olecranon	263
B. Coronoid process	270
C. Of the head of the radius	272
D. Of the neck of the radius	275
2. Fractures of the shaft	276
A. Fractures of the shafts of both bones	276
B. Of the shaft of the ulna	282
C. Of the shaft of the radius	284
3. Fractures in the vicinity of the wrist	285

	PAGE
A. Fractures of the radius. Colles's fracture	285
Cause	289
Symptoms	290
Treatment	292
B. Fractures at the wrist other than Colles's	294

CHAPTER XXI.

FRACTURES OF THE CARPUS AND HAND.

1. Fractures of the carpal bones	297
2. Fractures of the metacarpal bones	299
3. Fractures of the phalanges	301

CHAPTER XXII.

FRACTURES OF THE PELVIS.

1. Fractures of the ring of the pelvis	303
Separation of the symphysis pubis	304
Separation in front and behind	305
Separation of the sacro-iliac synchondrosis	305
Separation of all three joints	305
Fracture of the pubic portion of the pelvic ring	306
Fracture of the lateral portion	306
Course, diagnosis, treatment	309
2. Transverse fracture of the sacrum	310
3. Fracture of the coccyx	311
4. Fracture of the ilium	312
5. Fracture of the ischium	313
6. Fracture of the pubis	313
7. Fracture of the rim of the acetabulum	314

CHAPTER XXIII.

FRACTURES OF THE FEMUR.

1. Fractures at the upper end of the femur	315
A. Fractures of the head of the femur	316
B. Fracture of the neck of the femur	316
Causes	319
Pathology	320
(a) Fractures through the neck	320
(b) Separation of the epiphysis	321
(c) Fractures at the base of the neck	323
Repair	328
Symptoms	332
Diagnosis	336
Prognosis	338
Treatment	340
C. Fractures through the trochanter and neck	344
D. Fracture of the great trochanter	345
E. Fracture of the trochanter minor	346
2. Fractures of the shaft of the femur	347
3. Fractures of the lower end of the femur	356
A. Intercondyloid fractures	356
B. Separation of the epiphysis	358
C. Fracture of either condyle	361

CHAPTER XXIV.

FRACTURES OF THE PATELLA.

Cause	363
Pathology	364
Symptoms	366

	PAGE
Treatment	369
Non-operative	370
Operative	374
For relief of disability	377
For refracture	378

CHAPTER XXV.

FRACTURES OF THE BONES OF THE LEG.

1. Fractures of the upper end	379
Separation of the epiphysis	381
Avulsion of the spine of the tibia	381
Avulsion of the tubercle of the tibia	382
2. Fractures of the shaft	383
3. Fractures at the lower end of the leg	386
A. Comminuted fracture of the tibia	387
B. Supramalleolar fracture	387
C. Separation of the epiphysis of the tibia	388
D. Fractures by eversion and abduction, Pott's	389
E. Fractures of the malleoli by inversion	397
F. Of the posterior portion of articular surface	398
G. Of the anterior portion of the articular surface	399
4. Fractures of the fibula	400
A. Of the upper end	400
B. Of the shaft	400
C. Separation of lower epiphysis	401

CHAPTER XXVI.

FRACTURES OF THE BONES OF THE FOOT.

1. Of the astragalus	402
Of processus posticus	403
2. Of the calcaneum	403
Of the sustentaculum	404
By muscular action	405
3. Of the scaphoid	406
4. Of the cuboid	406
5. Fractures of the metatarsal bones	406
6. Fractures of the phalanges	407

DISLOCATIONS.

CHAPTER XXVII.

GENERALITIES.

Definitions	411
Statistics	413

CHAPTER XXVIII.

ETIOLOGY AND MECHANISM.

A. Predisposing causes	416
B. Immediate or determining causes	417
Recurrent or habitual dislocations	418

CHAPTER XXIX.

PATHOLOGICAL ANATOMY IN RECENT DISLOCATIONS; COMPLICATIONS; PROCESS OF REPAIR AFTER REDUCTION.		PAGE
Pathological anatomy		420
Complications		421
Bones		421
Bloodvessels		422
Nerves		424
Viscera		427
Soft parts and integument		427
Repair		428

CHAPTER XXX.

PATHOLOGY OF UNREDUCED (ANCIENT) DISLOCATIONS	431
---	-----

CHAPTER XXXI.

SYMPTOMS AND DIAGNOSIS.

Objective signs	436
Deformity	436
Loss of mobility	438
Crepitus	439
Subjective symptoms	439
Pain	439
Loss of function; history	439

CHAPTER XXXII.

COURSE AND PROGNOSIS.	441
-------------------------------	-----

CHAPTER XXXIII.

TREATMENT.

Spontaneous reduction	443
Obstacles to reduction	443
Anæsthesia	445
Methods of reduction	446
Old dislocations	451
After-treatment	453
Habitual dislocation	454

CHAPTER XXXIV.

ACCIDENTS THAT MAY BE CAUSED BY ATTEMPTS TO REDUCE A DISLOCATION	455
Integument	456
Emphysema of the cellular tissue	456
Rupture of the muscles	457
Avulsion of a portion of a limb	457
Injuries of the main bloodvessels	457
Injuries to nerves	463
Fracture	465
Inflammation, suppuration, gangrene	466
Persistent œdema	467
Syncope and sudden or early death; fat embolism	468

CHAPTER XXXV.

CONGENITAL DISLOCATIONS.

Statistics	469
Etiology	470
Pathology (hip)	474

	PAGE
Symptoms and diagnosis	477
Prognosis	479
Treatment	479

CHAPTER XXXVI.

SPONTANEOUS DISLOCATIONS 481

By distention	482
Paralytic	483
Voluntary	483
By destruction; by deformity	483

CHAPTER XXXVII.

DISLOCATIONS OF THE LOWER JAW.

Backward with fracture	485
Upward	485
Outward	486
Forward	486
Pathology	487
Symptoms	489
Prognosis	489
Treatment	489
Pathological	491
Congenital	491

CHAPTER XXXVIII.

DISLOCATIONS OF THE VERTEBRÆ AND OF THE OCCIPUT FROM THE ATLAS.

Classification and pathology	493
Secondary changes	498
Etiology	499
Symptoms and diagnosis	499
Prognosis	501
Treatment	502
Dislocations of the occiput	503
Dislocations of the atlas	505
Dislocations of the lower six cervical vertebræ	508
Dislocations of the dorsal vertebræ	514
Dislocations of the lumbar vertebræ	516

CHAPTER XXXIX.

DISLOCATIONS OF THE STERNUM.

Of the body from the manubrium	518
Of the ensiform process	522

CHAPTER XL.

DISLOCATIONS OF THE RIBS AND COSTAL CARTILAGES.

Of the head of the rib	523
Of the ribs from the costal cartilages	524
Of the costal cartilages from the sternum	525
Of one cartilage from another	527

CHAPTER XLI.

DISLOCATIONS OF THE CLAVICLE.

1. Of the sternal end	528
Forward	529
Backward	532
Upward	534

	PAGE
2. Of the acromial end	536
Supra-acromial	537
Subacromial	542
Subcoracoid	545
3. Simultaneous of both ends	545

CHAPTER XLII.

DISLOCATIONS OF THE SHOULDER.

Anatomy	547
Statistics	551
Classification	552
Anterior (and downward) dislocations	557
1. Subcoracoid	558
Pathology	560
Symptoms and diagnosis	563
2. Intracoracoid	565
Treatment of anterior dislocations	567
Direct reposition; traction downward and outward	569
Traction upward	570
Traction with leverage	572
Heel in the axilla	572
Forcible traction	572
Manipulation	573
After-treatment	577

CHAPTER XLIII.

DISLOCATIONS OF THE SHOULDER—*Continued.*

Downward dislocations	579
1. Subglenoid	579
Symptoms; treatment	582
2. Luxatio erecta	582
3. Subtricipital dislocation	583
Posterior dislocations (subacromial, subspinous)	584
Symptoms	588
Diagnosis and treatment	589
Upward dislocations (supraglenoid, supracoracoid)	590

CHAPTER XLIV.

DISLOCATIONS OF THE SHOULDER—*Continued.*

Associated injuries and complications	595
Laceration of muscles	595
Fractures	596
Nerves	599
Vessels. Chest. Compound	600
Simultaneous of both shoulders	601
Prognosis and after-treatment	602
Habitual dislocation	603
Treatment of old dislocations	607
Subcutaneous section	608
Arthrotoomy	608
Excision of the head of the humerus	609
Fracture of the surgical neck	609
Congenital dislocations	610
Pathological dislocations and subluxations	614
Dislocations due to paralysis	616

CHAPTER XLV.

DISLOCATIONS OF THE ELBOW.

Anatomy	617
Frequency. Classification	619

	PAGE
Frequency. Dislocations of the forearm backward	620
Mechanism	620
Pathology	622
Complications	623
Symptoms	624
Diagnosis	625
Prognosis	626
Treatment	627
Lateral dislocations	630
Incomplete lateral	631
A. Inward	632
B. Outward	633
Complete outward	637
Forward dislocations	641
Divergent dislocations of the radius and ulna	645
A. Antero-posterior	646
B. Transverse	648

CHAPTER XLVI.

DISLOCATIONS OF THE ELBOW—*Continued.*

Dislocation of the ulna alone	649
1. Backward	650
2. Inward	653
3. Forward	653
Dislocation of the radius alone	653
1. Backward	654
2. Outward	657
3. Forward	660
4. By elongation, or subluxation in children	663
Dislocation of the head of the radius with fracture of the ulna	668

CHAPTER XLVII.

DISLOCATIONS OF THE ELBOW—*Continued.*

Treatment of old dislocations	670
Congenital and pathological dislocations	675

CHAPTER XLVIII.

DISLOCATIONS AT THE WRIST.

Dislocations of the lower radio-ulnar joint	679
Backward	679
Forward	680
Inward and downward	681
Dislocations of the radio-carpal joint	681
Backward	683
Forward	685
Outward	687
Pathological ; subluxation forward	687
Congenital	691
Dislocations of the carpal bones	692
Medio-carpal	692
Isolated dislocations of the carpal bones	694
Scaphoid	694
Semilunar	695
Unciform ; pisiform	696
Os magnum	697
Trapezoid ; trapezium ; os magnum and trapezoid	698
Carpometacarpal dislocations	699

CHAPTER XLIX.

DISLOCATIONS OF THE THUMB AND FINGERS.		PAGE
Proximal phalanx of thumb		704
Anatomy		704
Backward		705
Forward		708
Lateral		709
Metacarpo-phalangeal of the fingers		710
Backward		710
Forward		711
Dislocations of the middle phalanges		711
Backward		711
Forward		712
Lateral		712
Dislocations of the distal phalanges		712
Backward		713
Forward		713
Lateral		713

CHAPTER L.

DISLOCATIONS OF THE PELVIS AND OF THE COCCYX.

Dislocations of the pelvis	715
Dislocations of the coccyx	715
Forward	716
Backward	717
Lateral	717

CHAPTER LI.

DISLOCATIONS OF THE HIP.

Anatomy	718
Statistics	721
Simultaneous dislocation of both hips	722
Compound dislocations	722
Classification	724
Backward dislocations	728
1. Dorsal dislocations	729
Causes	729
Pathology	730
Symptoms	733
Diagnosis	736
2. Everted dorsal dislocations	736
Pathology	738
Anterior oblique	739
Symptoms	739
Treatment of backward dislocations	740

CHAPTER LII.

DISLOCATIONS OF THE HIP—*Continued.*

Dislocations downward and inward	745
Obturator or thyroid dislocations	745
Cause	745
Pathology	746
Symptoms	747
Treatment	748
Perineal dislocations	750
Dislocations upward and forward, and inward and forward (suprapubic)	751
Iliopectineal; pubic; intrapelvic	751

	PAGE
Dislocations, iliopectineal. Pathology	752
Symptoms	754
Treatment	755
Dislocations directly upward (subspinous; supracotyloid)	756
Dislocations directly downward (infracotyloid)	760

CHAPTER LIII.

DISLOCATIONS OF THE HIP—*Continued.*

Complications	763
Muscles. Bloodvessels	763
Nerves. Fractures	764
Simultaneous dislocation of both hips	766
Accidents caused by attempts to reduce	767
Prognosis and after-treatment	768
Habitual dislocations	768
Treatment of old unreduced dislocations	770
Congenital dislocations	772
Spontaneous or pathological dislocations	772

CHAPTER LIV.

DISLOCATIONS OF THE KNEE.

Anatomy	775
Statistics	776
Dislocations forward	777
Dislocations backward	781
Lateral dislocations	783
1. Outward dislocations	783
2. Inward dislocations	785
Antero-lateral dislocations	786
Dislocations by rotation	786
Outward	786
Inward	787
Dislocation of the semilunar cartilages	787
Congenital dislocations	792
Spontaneous or pathological dislocations	794

CHAPTER LV.

DISLOCATIONS OF THE PATELLA.

General considerations	796
Outward dislocations	799
1. Complete	799
2. Incomplete	802
3. Outward edgewise, or vertical	803
Inward dislocations	804
Inward edgewise, or vertical	805
Complete reversal	805
Downward with rotation	806
Congenital dislocations	807
Habitual or pathological dislocations	808

CHAPTER LVI.

DISLOCATIONS OF THE FIBULA.

Dislocations of the upper end	810
1. Forward	810
2. Backward	811
3. Upward	811

	PAGE
Dislocations of the lower end	812
Spontaneous or pathological dislocations	812

CHAPTER LVII.

DISLOCATIONS AT OR NEAR THE ANKLE.

Anatomy	811
Dislocations of the foot. Tibio-tarsal dislocations	815
1. Dislocations backward	815
2. Dislocations forward	817
3. Dislocations inward	818
4. Dislocations outward	819
5. Dislocations upward	820
6. Compound and complicated dislocations	820
Subastragaloid dislocations	821
1. Dislocations inward or inward and backward	821
2. Dislocations outward	823
3. Dislocations backward	824
4. Dislocations forward	825
With fracture of astragalus	826
Diagnosis	826
Treatment	827
Total dislocations of the astragalus	828
1. Forward	829
2. Outward and forward	829
3. Inward and forward	829
4. Inward	830
5. Backward	830
6. By rotation	831
Treatment	834
Medio-tarsal dislocation	836
Congenital dislocations of the ankle-joint	837

CHAPTER LVIII.

DISLOCATIONS OF THE TARSAL AND METATARSAL BONES AND OF THE TOES.

Calcaneum	838
Scaphoid	838
Cuboid	838
Cuneiform bones	839
Of the metatarsal bones from the tarsus and from one another	839
Subluxation of the head of a metatarsal bone	841
Dislocations of the toes	841
1. Metatarso-phalangeal dislocations	841
Of the great toe	841
Of the other toes	842
2. Dislocations of the phalanges	842

LIST OF PLATES.

PLATE	PAGE
I.—Recent gunshot fracture of carpus and radius.....	34
II.—Same as Plate I., after repair.....	34
III.—Fig. 1. Periosteal bridge; fracture of forearm. Fig. 2. Periosteal bridge; humerus; two years after injury.....	37
IV.—Same as Plate III., fig. 2; injury recent.....	37
V.—Fracture of surgical neck of humerus in a child.....	230
VI.—Fig. 1. Skiagram of normal elbow at age of 5 years. Fig. 2. Skiagram of normal elbow at age of 8 years.....	246
VII.—Figs. 1 and 2. Cubitus varus; front and rear views. Fig. 3. Frontal sections of same.....	246
VIII.—Figs. 1 and 2. Supra-condyloid fracture.....	246
IX.—Fig. 1. Old supra-condyloid fracture of humerus; eubitus varus. Fig. 2. Cubitus varus, three years after a low partial supra- condyloid fracture.....	246
X.—Fracture of internal condyle of humerus, in an adult.....	251
XI.—Fracture of external condyle, 18 years.....	253
XII.—Fig. 1. Same case as Plate XI., Angular displacement by flexion. Fig. 2. Supra-condyloid fracture.....	261
XIII.—Fig. 1. Fracture of olecranon; dislocation forward of radius and ulna. Fig. 2. Fracture of forearm; angular displacement.....	265
XIV.—Fig. 1. Fracture of head of radius. Fig. 2. Fracture of neck...	275
XV.—Fig. 1. Fracture of humerus by small bullet. Fig. 2. Fracture of forearm.....	275
XVI.—Fig. 1. Fracture of radius; marked angular displacement. Fig. 2. Recent Colles's fracture in a boy 12 years old.....	277
XVII.—Fig. 1. Recent Colles's fracture; male, 22 years old (Plate XXI., fig. 1). Fig. 2. Old Colles's fracture.....	288
XVIII.—Fig. 1. Recent Colles's fracture, comminuted; male, 45 years old. Fig. 2. Recent Colles's fracture, comminuted; male, 40 years old (Plate XXI., fig. 2).....	288
XIX.—Fig. 1. Recent Colles's fracture; male, 26 years old. Fig. 2. Same as Fig. 1, side view.....	288
XX.—Fig. 1. Same as Plate XIX., after reduction. Fig. 2. Recent Colles's fracture; male, 56 years old.....	288
XXI.—Fig. 1. Recent Colles's fracture; male, 22 years old (Plate XVII., fig. 1). Fig. 2. Recent Colles's fracture; male, 40 years old (Plate XVIII., fig. 2).....	288
XXII.—Colles's fracture.....	288

PLATE	PAGE
XXIII.—Fig. 1. Colles's fracture at 12 years; arrest of growth. Fig. 2. Separation of radial epiphysis; boy, 15 years old.....	288
XXIV.—Fig. 1. Normal wrist; adult male. Fig. 2. Normal wrist; adult female, fracture of third metacarpal.....	288
XXV.—Fracture of scaphoid, and possibly of radius.....	296
XXVI.—Fracture of scaphoid, with dislocation of proximal fragment.....	296
XXVII.—After removal of fragment of scaphoid.....	296
XXVIII.—Fig. 1. Fracture of carpal scaphoid. Fig. 2. Separation of lower epiphysis of femur.....	296
XXIX.—Fig. 1. Fracture of patella, three months later; non-operative treatment. Fig. 2. Fracture of patella, two months after mediate suture.....	365
XXX.—Fig. 1. Fracture of patella, three years after periosteal suture. Fig. 2. Fracture of patella, three months after periosteal suture.....	367
XXXI.—Fracture of patella. Ossification of ligamentum patellæ.....	368
XXXII.—Fracture of upper end of tibia.....	379
XXXIII.—Separation of lower tibial epiphysis.....	389
XXXIV.—Fig. 1. Pott's fracture by eversion in a youth. Fig. 2. Fracture of the posterior portion of the lower end of tibia.....	390
XXXV.—Fig. 1. Pott's fracture by abduction. Fig. 2. Pott's fracture, two months old; backward displacement.....	390
XXXVI.—Fig. 1. Pott's fracture by abduction. Fig. 2. Bimalleolar fracture by inversion.....	397
XXXVII.—Fracture by eversion with interposition of astragalus.....	397
XXXVIII.—Longitudinal fracture of lower end of tibia by a fall upon and inversion of the foot.....	397
XXXIX.—Fig. 1. Bimalleolar fracture by inversion in youth. Fig. 2. Fracture of femur remaining ununited a year after wiring.....	397
XL.—Fig. 1. Fracture of cuboid. Fig. 2. Long oblique fracture of tibia and external malleolus.....	400
XLI.—Figs. 1 and 2. Fracture of calcaneum. (CABOT.).....	406
XLII.—Fig. 1. Fracture of calcaneum. (CABOT.) Fig. 2. Fracture of upper posterior angle of os calcis.....	406
XLIII.—Fig. 1. Congenital dislocation of the hip. Fig. 2. Dislocation of semilunar bone.....	477
XLIV.—Congenital dislocation of hip.....	477
XLV.—Old dislocation of shoulder.....	560
XLVI.—Congenital dislocation of the shoulder.....	612
XLVII.—Dislocation backward of elbow.....	650
XLVIII.—Figs. 1 and 2. Dislocation of semilunar.....	697
XLIX.—Fig. 1. Old dislocation backward of os magnum, side view. Fig. 2. Old dislocation backward of os magnum, antero-posterior.....	697
L.—Fresh dorsal dislocation of the thumb.....	706
LI.—Fig. 1. Anterior dislocation of the knee. Fig. 2. Posterior dislocation of the knee.....	776
LII.—Subastragaloid dislocation.....	821

FRACTURES.

A TREATISE

ON

FRACTURES AND DISLOCATIONS.

CHAPTER I.

INTRODUCTION.

By *Fracture*, in the surgical sense of the term, is meant the breaking of a bone or cartilage.

The liability to fracture of the different bones of the body varies greatly, in consequence of their differences in size, shape, and degree of exposure to external violence or extreme muscular action. Hospital records covering periods varying in length from five to eighty-seven years have been tabulated by different writers, with the object of determining the relative degree of this liability; but it is evident that such statistics cannot contain all the needed facts, for the reason that patients with fractures which do not necessitate confinement to the bed do not so generally seek hospital care as those with fractures which do. Combined hospital and dispensary statistics are more nearly correct, but even they differ considerably from one another in their percentages, possibly because of differences in the occupations and mode of life of the communities which furnished them. I have compiled the following table from the records of the House of Relief ("Hudson Street Hospital"), of which I am the attending surgeon, including both the In- and the Out-patient services. The hospital is the only one in New York City below Canal Street, a region largely given over to trade, transportation, and manufacturing, with frequent construction of large buildings, and in which there is only a laboring resident population.

HUDSON STREET HOSPITAL, NEW YORK: STATISTICS OF FRACTURES TREATED
IN HOSPITAL AND DISPENSARY, 1894-1905.

	Cases.	Cases.	Per cent.
Cranium	772		
Malar bone	29		
Nasal bones	672		
Superior maxilla	46		
Inferior maxilla	502		
Zygoma	29		
Hyoid	3		
	772	1281	5.50
			8.79

	Cases.	Cases.	Per cent.				
Spine	66	Trunk	1832	12.57			
Pelvis	75						
Coccyx	3						
Sternum	13						
Ribs	1675						
“Upper extremity”	132						
Clavicle	662						
Scapula	66						
Humerus, shaft and neck	411						
lower end	209						
internal epicondyle	6	Upper extremity	6818	46.80			
Radius and ulna	283						
Radius, shaft	363						
Colles's	1212						
Ulna, shaft	318						
olecranon	118						
Carpus	15						
Metacarpus	1063						
Phalanges	1990						
Femur	540						
Patella	183						
Tibia, or tibia and fibula	943						
Abduction and adduction fractures at ankle	1089						
Fibula	233				Lower extremity	3863	26.54
External malleolus	33						
Internal malleolus	31						
Tarsus	151						
Metatarsus	326						
Toes	334						
Total	14,566						

During the same period 1527 dislocations were treated.

Sex. Fractures are more numerous in men than in women, in the proportion of about three to one, because of the greater exposure of men to the accidents which cause them. Mainly, for the same reason, the proportion varies greatly at different ages; in infancy the difference is slight; in middle life fractures are ten times as frequent in men as in women; between the ages of fifty and seventy years the difference again becomes slight, and after the age of seventy years fractures are more common in women than in men, a reversal of conditions due to a disproportionate increase in the number of fractures of the neck of the femur.

Age. Gurlt¹ tabulated 1383 cases (hospital and dispensary) with reference to the ages of the patients, and found in the first decade, 265; in the second, 193; in the third, 274; in the fourth, 224; in the fifth, 154; in the sixth, 155; in the seventh, 72; in the eighth, 38, and in the ninth, 8. Combining these with statistics showing the relative number of people living at the different ages, he found the highest proportion of fractures in the period above the age of sixty years. Malgaigne² made a similar tabulation, using only hospital cases, and grouping in periods of five years he found that the periods between fifty-five and eighty were practically equal to one another, and gave the highest proportion according to population.

¹ Gurlt: Handbuch der Lehre von den Knochenbrüchen, 1862.
² Malgaigne: Traité des Fractures et des Luxations, 1847.

Season affects the frequency of fracture only by increasing or diminishing the exposure to the accidents which occasion them. Falls due to ice and snow in winter are more than offset as a cause by the more varied and active occupations of the milder months, and fractures are, therefore, less frequent in winter than in summer. This is shown by the following tabulation of the fractures treated in the Hudson Street Hospital, according to months :

HUDSON STREET HOSPITAL: FRACTURES IN 1896, WARDS AND DISPENSARY.

January,	77	March,	130	June,	82	September,	105
February,	88	April,	103	July,	148	October,	107
December,	119	May,	97	August,	150	November,	116
	<hr/>		<hr/>		<hr/>		<hr/>
	284		330		380		328
Omitting hand and toes, }	57		84		104		92
	<hr/>		<hr/>		<hr/>		<hr/>
	227		246		276		236

The maximum is found in the summer months, the minimum in the winter. It is only in fractures of the leg that the winter season heads the list, and yet even in these, as the following table shows, a decided monthly maximum is found in March, a month in which there is but little snow and ice in New York :

FRACTURES OF THE LEG, OF EITHER BONE, AND POTT'S FRACTURE.

January,	19	March,	29	June,	9	September,	8
February,	20	April,	9	July,	11	October,	6
December,	21	May,	12	August,	25	November,	20
	<hr/>		<hr/>		<hr/>		<hr/>
	60		50		45		34

Fractures of the femur (shaft and neck) give the following totals: Winter 16, spring 17, summer 8, autumn 12; those of the upper extremity (clavicle, humerus, and either or both bones of the forearm) give: Winter 67, spring 63, summer 107, autumn 72.

NOTE.—For other statistics see Malgaigne, Gurlt, and the first edition of this work; also Wallace, *American Journal of the Medical Sciences*, 1839; Norris, *Ibid.*, 1841; Lente, *New York Medical Journal*, 1851; Lonsdale, *Fractures*, 1838, and Scannell, *Boston Medical and Surgical Journal*, Nov. 15, 1906.

CHAPTER II.

PATHOLOGY.

The Bone—Varieties: Incomplete, Complete, Multiple, Compound, Gunshot. Displacements. The soft parts.

(A) THE BONE—VARIETIES OF FRACTURE.

THE varieties of fracture are numerous and are constituted by differences in the extent of the injury to the bone or to the surrounding soft parts, in the seat, shape, and direction of the fracture, in the relation of the fragments to each other, and in the number of bones involved. These varieties may be grouped in five divisions, marked by important clinical differences and containing many subdivisions, as follows:

1. Incomplete fractures.

(a) Fissures.

(b) True incomplete, "green-stick;" bent bone.

(c) Depressions.

(d) Separation of a splinter or of an apophysis.

2. Complete fractures, subdivided, according to

(a) Direction and character of the line of fracture, into transverse, oblique, longitudinal, spiral, toothed or dentate, V-, Y-, or T-shaped, and comminuted;

(b) Seat of the fracture, into fracture of the shaft, of the neck, of the upper, middle, or lower third, intercondyloid, separation of epiphysis; and

(c) If extending into a joint, intra-articular.

3. Multiple fractures, comprising fractures of two or more non-adjacent bones and two or more fractures of the same bone.

4. Compound (or open) fractures.

5. Gunshot fractures.

The term *simple* (or *closed*) fracture is commonly used, in contradistinction to the term *compound*, to indicate that there is no associated wound of the soft parts which establishes communication between the fracture and the exterior.¹ Some writers make also a class of *complicated fractures* to include cases in which some important injury coexists; and there are still other terms in use to indicate peculiarities which do not lend themselves easily to the above classification. Such are: *Spontaneous fracture*, one produced by the minimum of violence; *pathological fracture*, one favored by weakening or partial destruction of the bone by disease; *direct fracture*, one occurring at the point where the causative

¹ Of late an effort has been made to substitute the use of the term *open* for *compound*, and *closed* for *simple*, but it does not appear to have gained much momentum or that there is urgent need of the change. The significance of *compound* is freely and widely understood, without, as well as within, the profession; that of *simple* is perhaps not so well understood and is occasionally liable to misinterpretation.

external violence is received; *indirect fracture*, one occurring at a distance from that point; *recent and old*, or *unwited, fracture*. Another grouping is according to the mechanism of production: fractures by bending, by torsion, by crushing, by avulsion, by gunshot; with subsidiary terms: fractures by *flexion* or *extension*, by *abduction* or *adduction*, by *eversion* or *inversion*.

1. Incomplete Fractures.

Under this head will be considered fractures in which the continuity of the bone has not been completely lost or a fragment has not been completely detached.

(a) **Fissures.** This variety is characterized by the existence of a split or crack in the bone, one which does not entirely circumscribe a fragment and separate it from the rest of the bone. It is of common occurrence in the bones of the cranium, and very rare in the long bones except when associated with other varieties. It is almost unknown in the short or spongy bones.

The examples of isolated fissure of long bones are very rare. Fig. 1, copied by Gurlt from Froriep, represents one extending from the greater tuberosity of the humerus to the lower fourth of the shaft, produced in a boy by a fall upon the elbow. Fissures connected with complete fracture are common; are sometimes very long, and may extend into a neighboring joint. A very long fissure is sometimes termed a longitudinal fracture.

The mechanism by which a long isolated fissure is produced in a long bone is probably the forcible bending of the bone. This is plainly indicated in a case reported by Debrou in 1843, and quoted by Gurlt as a case of *infraction*. The patient, a man sixty-two years old, fell while walking, and injured his thigh. Erysipelas set in and caused his death. At the autopsy a fissure was found under the untorn periosteum, extending six inches downward from the trochanter minor, and this fissure could be made to widen by pressure upon the ends of the bone.

The diagnosis cannot be made with certainty, except when the bone is exposed to direct examination; but it can be inferred with much probability in some forms of fracture with which it is usually associated, such as V-shaped fractures of the tibia. Giese,¹ reporting a case involving the tibia, calls attention to the discrepancy between the slight objective signs and the extreme sensitiveness and interference with function.

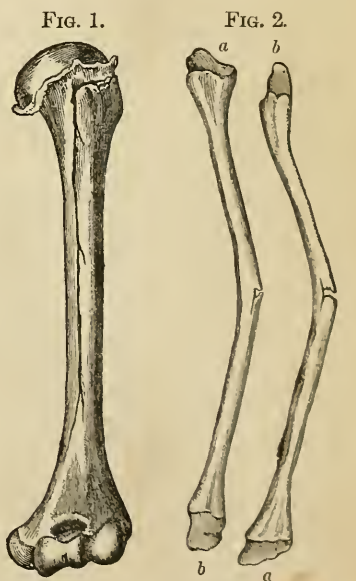


FIG. 1.
Fissure of the humerus. (GURLT.)

FIG. 2.
Partial fracture of the fibula. a, the head; b, the malleolus.

¹Giese: Münchener med. Wochenschrift, 1906, No. 9.

Except when it extends into a joint the importance of a fissure is probably slight, and is dominated by that of the associated lesions. In some cases the injury has been promptly or tardily followed by suppuration beneath the periosteum or within the bone.

(b) **True Incomplete, "Green-stick Fracture"; Infraction; Bent Bone, or Curvature Without Fracture.** This variety is characterized by a fracture involving only a portion of the thickness of a long bone, and combined with a bending of the bone at the seat of fracture. In its consideration is included also that of the rare cases of curvature without recognizable fracture, a variety which has only an academical interest, for it cannot be recognized clinically. Its possibility has been demonstrated experimentally upon young animals and by a single specimen belonging to Prof. Uhde, the ulna of an adult much bent by a machinery accident, and showing no trace of fracture.

The injury appears ordinarily as a short transverse fracture, continuous with one or more longitudinal ones of variable length; sometimes there is no transverse line, but only oblique ones running from the angle upward or downward. The appearance can be closely imitated by over-bending a green or tough stick, a fact that has given this form of fracture a name by which it is very commonly known.

This fracture is seen most frequently in the bones of the forearm, then in the clavicle, and very rarely in the bones of the arm, leg, and thigh. The great majority of cases occur in those under the age of fifteen years. In the forearm it may be found in only one bone, the other being completely broken. The usual cause is a fall, but I have seen several cases in which the cause was the forcible bending of the forearm over a rigid body, as when the limb is caught between a shaft and its belting.

The chief symptoms are deformity, consisting in an angular deviation of a portion of the limb or bone, and localized pain on pressure at the angle. The deviation can be more or less completely corrected by the use of force, and the correction may be accompanied by crepitus and followed by abnormal mobility, the fracture having been made complete.

The prognosis is favorable as regards correction of the deformity and repair. Ordinarily, the limb can be straightened by the surgeon's hands alone, aided, perhaps, by the pressure of his knee against the angle; and the surgeon should not be deterred, by the fear of making the fracture complete, from using all the force that is necessary.

(c) **Depressions.** I limit the use of this term to those cases in which a portion of the outer layer of a flat bone or the spongy portion of a long bone is driven inward by direct violence, usually a blow with a pointed instrument. The injury is most frequently seen in the vault of the skull, and is there generally termed a fracture of the outer table. It is occasionally seen in the limbs in connection with complete fracture.

(d) **Separation of a Splinter or of an Apophysis.** In this variety are included two classes of fractures which differ widely in their mode of production, but have this in common: that the fragment does not comprise the entire breadth or thickness of the bone, and that consequently the continuity of the latter is not destroyed. In the first class a

splinter or fragment of bone is broken off by direct violence, as by a cutting instrument; in the second class a bony prominence is torn off by the violent contraction of the muscle attached to it or by traction through a ligament.

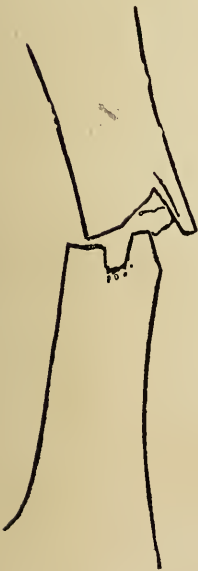The separation of a splinter or scale of bone by a sword-cut or bullet is not uncommon in the spongy bones or the spongy extremities of long bones, and has also been known to occur in the shaft of the tibia. It is an injury which should be classed rather among wounds of bones than among fractures. The separation of a splinter by direct violence, unaccompanied by a wound of the soft parts, occurs in the bones of the face, at the crest of the ilium, and at exposed points upon the extremities of the long bones.

Avulsion of an apophysis, or of a scale of bone, by muscular action is a far more common accident than the one just described. The lesion consists in the fracture of an apophysis at its base or in the tearing off of a portion of bone to which a muscle or tendon is attached.

2. Complete Fractures.

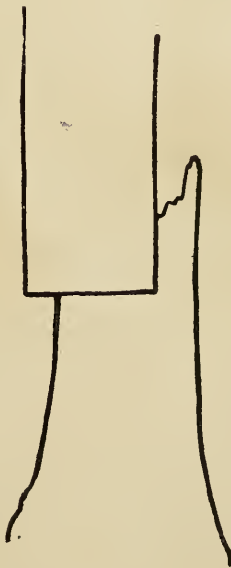
The term *complete*, when applied to a fracture of a long bone, indicates that the bone is divided by a line of fracture crossing from side to side or obliquely across the end.

FIG. 3.



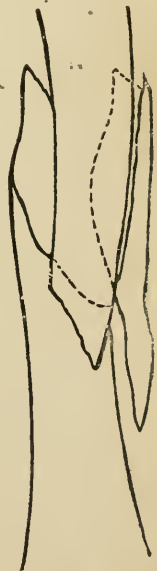Humerus.

FIG. 4.



Femur.
(Tracings from skiagrams.)

FIG. 5.



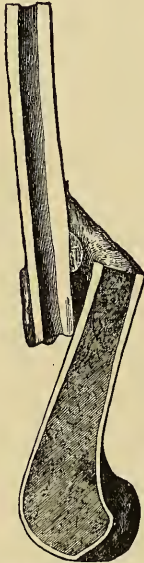Femur.

(a) **Subdivision According to the Direction of the Line of Fracture.** Such terms in use are *transverse*, *oblique*, *splintered*, *spiral*, *V-shaped*

T- or Y-shaped, dentate, longitudinal, and comminuted. Apparently as a result of physical conditions, fractures by direct or indirect violence which bend a long bone are either practically transverse or markedly oblique, with or without splintering.

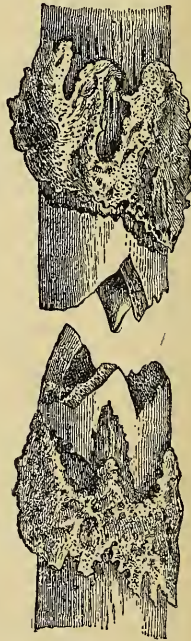
The line of a *transverse* fracture does not deviate more than about 15 or 20 degrees from that of the transverse axis; that of an *oblique* fracture lies near an angle of 50 degrees. A transverse fracture may be, but rarely is, exactly transverse and smooth (Fig. 6); clinically such details cannot be recognized unless the fracture is compound, and the diagnosis of the variety is made on the fact that the end of the fragment can be felt through the overlying soft parts to be approximately square and smooth. In the *oblique* variety the line of fracture may be single (Fig. 9) or multiple (Fig. 8), circumscribing in the latter case

FIG. 6.



Transverse fracture of the femur. (GURLT.)

FIG. 7.



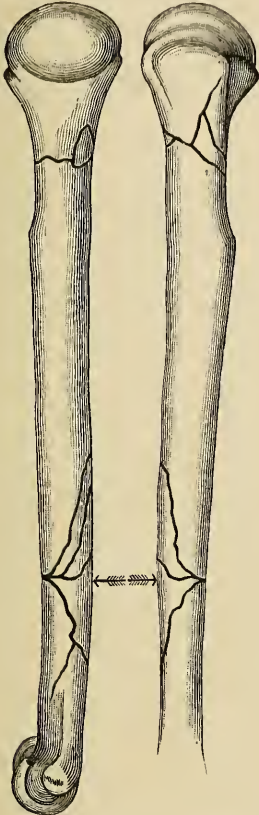Fracture of humerus. (V. BRUNS.)

one or more detached fragments which apparently are formed on the side of the concavity created by the bending of the bone (*splintered*). This is characteristic of the fractures produced by bending. The line of fracture in either form may be markedly irregular on either or both fragments. When this irregularity is found on both fragments the term *toothed* or *dentate* is applied; when it is found only on one side the absence of a corresponding line on the other is due to the crushing of the bone or to the splitting off of one or more large fragments.

Spiral fractures, which are rare, are produced by torsion of the bone,

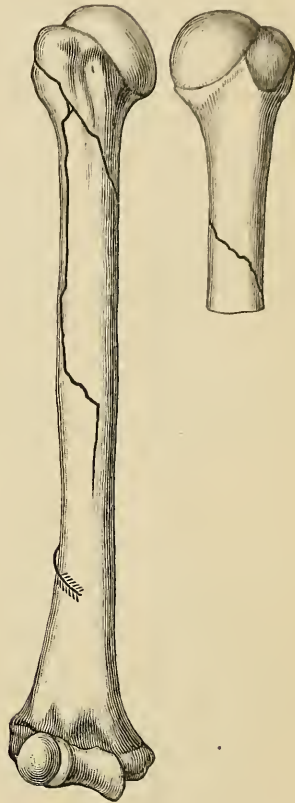
and are found in the femur, humerus, and tibia. In the latter they are better known as *V-shaped* (Fig. 10), and can be readily recognized

FIG. 8.



Oblique fracture by direct pressure.
(KOCHER.)

FIG. 9.



Spiral fracture by outward rotation of
lower end. (KOCHER.)

by the sharp point of the upper fragment, which can be felt midway between the crest and the internal border of the bone. From the re-entrant angle corresponding to this point a fissure runs down to the ankle-joint.

Under the term *longitudinal* are included very oblique fractures running from one side of the bone to the other, fractures running from one end of the bone to or nearly to the other, and fractures which split lengthwise a long fragment intermediate between two transverse fractures. The last-named form is produced only by great crushing violence, and the prognosis is very bad. In the other forms the violence is indirect, apparently a bend or twist of the bone or a blow received at one end; the ill results which have so commonly followed appear to be due in some to the implication of one or both joints or to a failure to recognize the injury and maintain immobility. The most marked cases are one reported by Krönlein,¹ a fracture of the humerus

¹ Krönlein: Deutsche Zeitsch. f. Chir., 1873, p. 132.

from the shoulder to the elbow-joint, in a man twenty-seven years old, by an attempt to raise a heavy ladder, and one by Cloquet, in 1831, a fracture of the femur from the intercondyloid notch to a point just below the trochanter minor, by a fall from a roof.

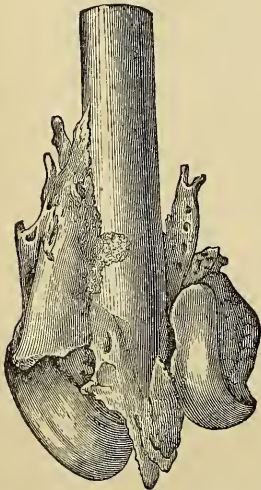
A *comminuted fracture* of the shaft of a long bone is one in which, in addition to the complete division of the bone into two fragments, there is also extensive splintering of the portion of bone adjoining the fracture or of one of the fragments (Figs. 11 and 12). In a comminuted fracture of a flat bone the bone or a portion thereof is broken into several rather large fragments, with or without additional small ones; in this use of the term fractures showing only two or three fragments, and those rather small, are excluded, the line of distinction being of necessity vague and arbitrary. In the short bones and the spongy ends of the long bones comminution is frequently associated with crushing of the spongy tissue, or the end of the diaphyseal fragment may be driven into the expanded, spongy end, crushing it or splitting it; if the two main fragments are rather firmly held together in their new relations the condition is termed *impaction* or *impacted fracture* (Fig. 13). If the crushing of the spongy tissue has taken place without much splintering of the cortical layer the term *fracture with crushing* is used (Fig. 14). This crushing of spongy tissue is effected by breaking down the innumerable fine lamellæ of bone and forcing out the fat within the meshes, as a handful of snow or a wet sponge is compressed, and the result is

FIG. 10.



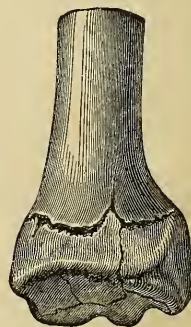V-shaped fracture.

FIG. 11.



Comminuted fracture of the femur, with splitting of the condyles.

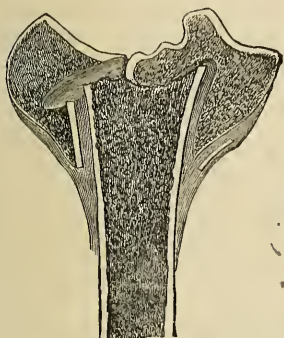
FIG. 12.



Comminuted fracture of the lower end of the radius. Palmar aspect.

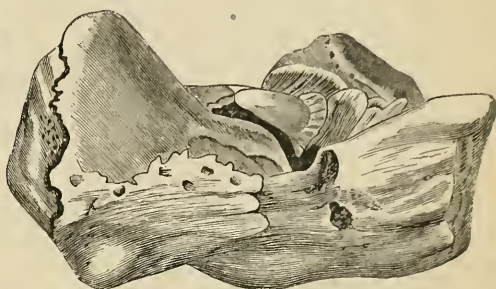equivalent to an actual loss of tissue; that is, if the main fragments are replaced in their original positions a gap is left between them corresponding to the position and extent of the crushing. This gap is often too large to be filled by new bone formed during repair; consequently, a full correction of the displacement is inadvisable, even when possible, lest failure of union should result, and the surgeon must be content to obtain union with some deformity.

FIG. 13.



Intra-articular fracture of the head of the tibia, with impaction and separation of the upper fragments.

FIG. 14.



Fracture of the calcaneum, with crushing.

(b) **Varieties Dependent Upon the Seat of the Fracture.**—A fracture may occupy any portion of the bone and be known by its name; for example, fracture of the neck of the femur, of the lower third of the tibia, of the head, of the shaft, of the inner condyle, of the acromion; intercondyloid fracture, when it passes across the shaft and also downward between the condyles; separation of the epiphysis.

*Separation of the Epiphysis.*¹ This term is limited to separation of epiphyses which have not yet become united by bone with the shaft. This union takes place in the different bones at different ages, but is usually complete in all in the female at the age of twenty-two years, and in the male at twenty-five years. Bruns² collected 81 cases, with 101 separations, in which direct examination of the seat of injury was possible; the points of greatest frequency were the lower end of the femur 28, lower end of the radius 25, and upper end of the humerus 11. Of the 52 cases in which the age was given, 44 were between ten and nineteen years old, 8 between one and nine years. Of 61 in which the line was exactly described, the line in 23 ran exactly along the face of the conjugal cartilage, in 5 it ran through the cartilage, and in 33 partly along the cartilage and partly through the adjoining "chondroid" tissue on its diaphyseal side. An important feature is the fact that the periosteum of the adjoining portion of the shaft is

¹ The first work upon this subject is by G. C. Reichel, "De Epiphysium ab Ossium Diaphysi Diductione," published at Leipsic in 1794. Manquat's thesis, in 1877, and Bruns' article, in 1878, were the first in which any considerable number of cases was collected. Later articles will be referred to in connection with the different epiphyses. Quite recently, 1898, a large work upon the subject has been published by John Poland.

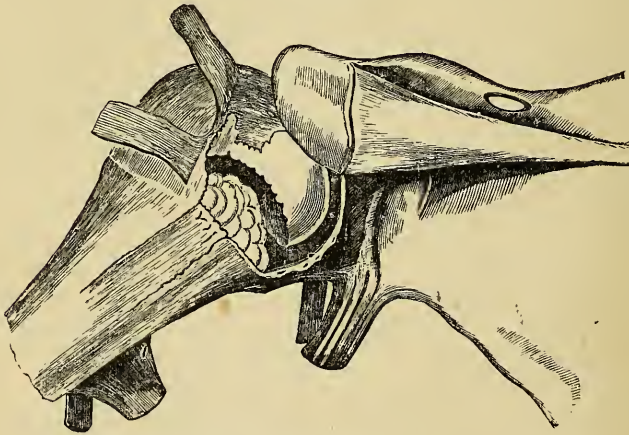
² Bruns: Arch. f. klin. Chir., 1878, vol. xxii. p. 343.

freely stripped off, preserving its continuity to a large extent with the epiphysis. It has lately been recognized that a partial or complete separation of the epiphysis of the lower end of the humerus is frequent. (See Plates VIII. to XII.)

The mode of production appears usually to be by cross-strain, the limb being bent beyond the limit of normal motion in the corresponding joint or in a direction in which there is normally no motion; for example, lateral bending at the knee.

The displacement may be very slight or so great as wholly to separate the fractured surfaces from each other. Colles's fracture at the lower end of the radius in the young is occasionally a separation of the epiphysis with slight displacement (see Plate XXIII., Fig. 2); at the upper end of the humerus the displacement is usually equal to

FIG. 15.



Separation of the epiphysis. Periosteum partly intact. (THUDICUM.)

about half the thickness of the bone; at the elbow it may be complete backward or inward, but is usually incomplete inward.

The diagnosis is made in the cases of slight displacement on the history of the injury and tenderness on pressure limited to the line of junction of the epiphysis and shaft; in the others by recognition of the deformity and of the size and shape of the fragment. When the displacement is great reduction may be seriously opposed by the interposition of the loosened periosteum.

The prognosis is affected by the possibility of arrest of growth due to an uncorrected displacement or to premature ossification of the conjugal cartilage. A few such cases have been reported. This deficiency of growth is, of course, most marked in those who receive their injury at an early age, and secondly in those cases in which the affected epiphysis normally takes the larger part in the growth of the bone in length, namely, the upper end of the humerus and tibia and the lower end of the femur and radius. I have seen two cases in which this injury at the lower end of the radius at the age of fourteen years produced a late deformity exactly resembling that of a very bad Colles's fracture. (See Plate XXIII., Fig. 1.)

(c) **Intra-articular or articular fractures** are those in which the main line of fracture, or a subsidiary one, extends into a joint. Common examples are fractures of either condyle of the femur or humerus, intercondyloid fractures of the same bones, fractures of the patella and olecranon. The special importance of the variety arises partly from the implication of the joint in the inflammatory reaction following the trauma, but mainly from the change in the mechanical conditions produced by the displacement of the fragment, the callus, and the implication of the capsule and periarticular tissues. Thus, the result after a fracture of the patella in which the permanent displacement is slight is usually very good, while that following a fracture of a condyle of the humerus or of the head of the tibia may be great limitation of the motions of the joint. In the young excessive formation of bone outside of, but near to, the joint as the result of the traumatic irritation of the periosteum may also mechanically limit the motions of the joint. An important factor in producing the bad result is found in the difficulty or impossibility of properly reducing the displacement or maintaining the reduction because of the small size of the fragment and the lack of efficient means of acting upon it.

3. Multiple Fractures.

This term is applied to the simultaneous fracture of two or more non-adjacent bones and two or more fractures of the same bone whose lines are not continuous with one another. The term *double* is also used when there are only two fractures. This definition is intended to exclude simultaneous fracture of both bones of the leg or forearm and fractures which involve two or more adjacent bones of the skull or pelvis. The term is frequently applied to fracture of two or more adjacent ribs, and sometimes to cases of extensive splintering of the flat bones.

Multiple fractures of a single bone are caused by violence, usually great, acting in part directly against the shaft, as the fall of a heavy weight or, as in one of my own cases, by the striking of the thigh against a tree when the patient was thrown from a carriage. The condition may be serious as to life, because of the shock of the injury, and in respect of restoration of form and function, because of the difficulty of controlling the position of the intermediate fragment. There is also the chance of overlooking one of the fractures.

Multiple fractures of different bones are also usually caused by great violence; the prognosis is affected much more by the associated injuries and shock than by the multiplicity of the fractures. If the patient survives the primary effects of the accident the fractures heal in the ordinary manner.

4. Compound (or Open) Fractures.

A compound fracture is one in which communication between the fracture and the external air is established through a wound of the soft parts. The importance of this communication arises through the possibility of infection of the wound from without, with all the risks

involved in the consequent suppuration of the bone and the lacerated soft parts. In addition, a large proportion of compound fractures are caused by direct violence, and the consequent laceration of the overlying soft parts is such as to be a serious addition to the fact of fracture. In other cases the external wound may be merely a puncture made by the broken end of the bone, which, under suitable treatment, heals in a few days, making the fracture thenceforth a simple (closed) one.

A fracture that is simple at first may be made compound by the sloughing of the overlying skin in consequence of its injury by the primary violence or of pressure upon it by a displaced fragment, or by the later forcing of the sharp end of a fragment through the skin in the agitation of delirium or in an attempt to use the limb while in ignorance of the character of the injury that has been received.

In determining the compound character of a fracture it is sufficient to establish the fact that the wound of the soft parts extends through the enveloping fascia and to the immediate neighborhood of the seat of fracture, for even if the gross lesion should not extend to the broken surface of the bone, yet the minuter lacerations and the extravasated blood create a path for the spread of infection that brings the condition fully within the definition and the special dangers.

The prognosis varies so greatly with the extent and character of the injury to the soft parts that statistics which take no account of these variations have but little value. A fracture produced by indirect violence and made compound by a puncture of the skin by the end of a subcutaneous bone, such as the ulna or tibia, may be confidently expected to heal under appropriate treatment as kindly and promptly as a simple fracture; while one produced by direct violence and accompanied by destruction of the skin and muscles can heal only by granulation, and will probably suppurate, notwithstanding all the care that may be given it; or, the associated damage to the soft parts may be such that the limb would be useless even if the wound should heal. The most virulent and rapidly progressive infections appear with exceptional frequency in compound fractures accompanied by much bruising or laceration of the muscles; their production is presumably favored by the local reduction of vitality.

The shock of the injury is usually much greater than that of simple fracture, and may cause death in a few hours, and the probability of the existence of serious associated lesions is also greater because of the usually greater violence that has produced the fracture. This is shown by the following statistics: During two years, February, 1895, to February, 1897, there were received at the Hudson Street Hospital 70 compound fractures of the limbs, exclusive of those of the hand. Eleven of these patients died within twenty-four hours after the accident, 3 of the 11 having also a fracture of the base of the skull; 4 more died within three days after the accident, making in all 15 deaths (or 12, if the fractures of the skull are excluded) directly due to the shock of the injury, a mortality of 21 per cent. This is largely in excess of that following simple fractures, although they, too, may be accompanied by other grave lesions or by severe shock, or may lead to a fatal pneumonia or attack of delirium tremens. I cannot give the final result in the remaining 55 cases of my list, because

many of them were transferred to their homes or to other hospitals after they had recovered from the primary effects of their injuries. At least three of them underwent amputation.

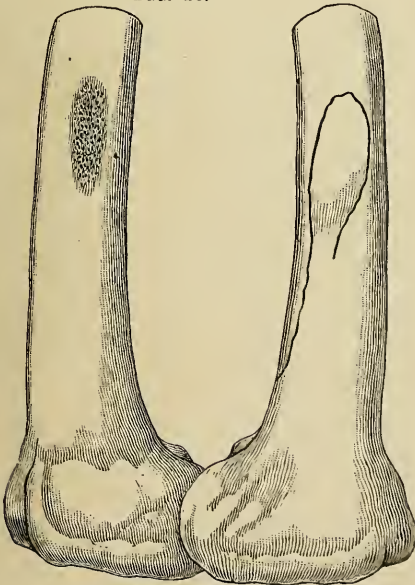
Mumford,¹ collating 300 cases (excluding those that died within the first twelve hours and those treated by primary amputation) received at the Massachusetts General Hospital during the preceding eight years, found a mortality of 30, or 10 per cent., the causes of death being sepsis, 10; shock, 7; delirium tremens, 6; fat embolism, 3; gangrene, 3; nephritis, 1. The highest mortality was in fractures of the femur—25 cases with 7 deaths, 28 per cent.

The principles of treatment are to transform the fracture into a simple one as promptly as possible, to minimize suppuration and keep it superficial when it is inevitable, and to protect against other infection while the wound is open, meanwhile immobilizing the fragments by suitable splints. Under the protection of strict asepsis (including in that rigid disinfection of the crushed soft parts in fractures by direct violence) the question of the need of amputation may often be postponed until after the progress of the case shall have clearly shown whether or not the limb can be saved.

5. Gunshot Fractures.

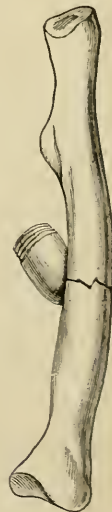The call for separate consideration of this variety of compound fractures comes through peculiarities of the lesions and dangers consequent

FIG. 16.



Contusion of side of femur by pistol-ball; "symmetrical" fissure of the opposite side. (POULET and BOUSQUET.)

FIG. 17.



Transverse fracture of the clavicle by a spent ball. (RICARD.)

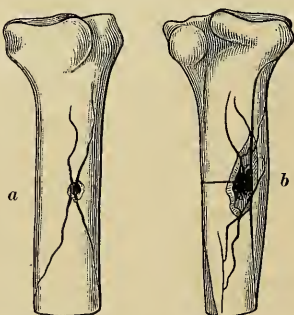
upon the small size and the velocity of the projectile. The subject,

¹ Mumford: Boston Medical and Surgical Journal, May 10, 1894.

consequently, is rather more limited than its title might suggest, and does not include fractures by large balls or pieces of shell, in which the extensive laceration of the soft parts is even more important than the fracture.

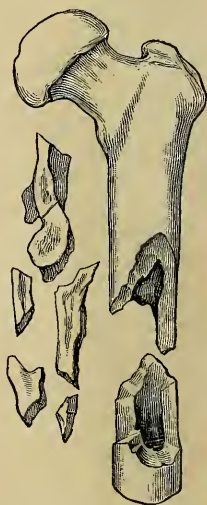
The special features are the usually extensive splintering and fissuring of the bone and the bruising of the tissues along the track of the bullet which may prevent prompt healing of the wound. These features are found in varying degrees, corresponding to the velocity of the ball and to its size. A ball whose force is nearly spent may, on striking the shaft of a long bone, do no injury at the point of impact, but may yet cause a curved fissure nearly circumscribing a cortical fragment on the opposite side (Delorme, Fig. 16); if its speed is slightly greater, and especially if it strikes the spongy end of the bone, it causes a depression of the surface only; if the ball is large and its velocity low, and the point struck is near the centre of the shaft, a transverse fracture (Fig. 17) or an oblique one (Plate XV.) may be produced. At higher velocities the bone is perforated, with more or less splintering and fissuring (Fig. 18), or the entire cylinder for a length of one or two inches is split into small fragments which are driven far into the surrounding tissues (Fig. 19). See also Plate I. With the latter

FIG. 18.



Perforating shot-wound of tibia. *a*, entrance; *b*, exit.
(RICARD.)

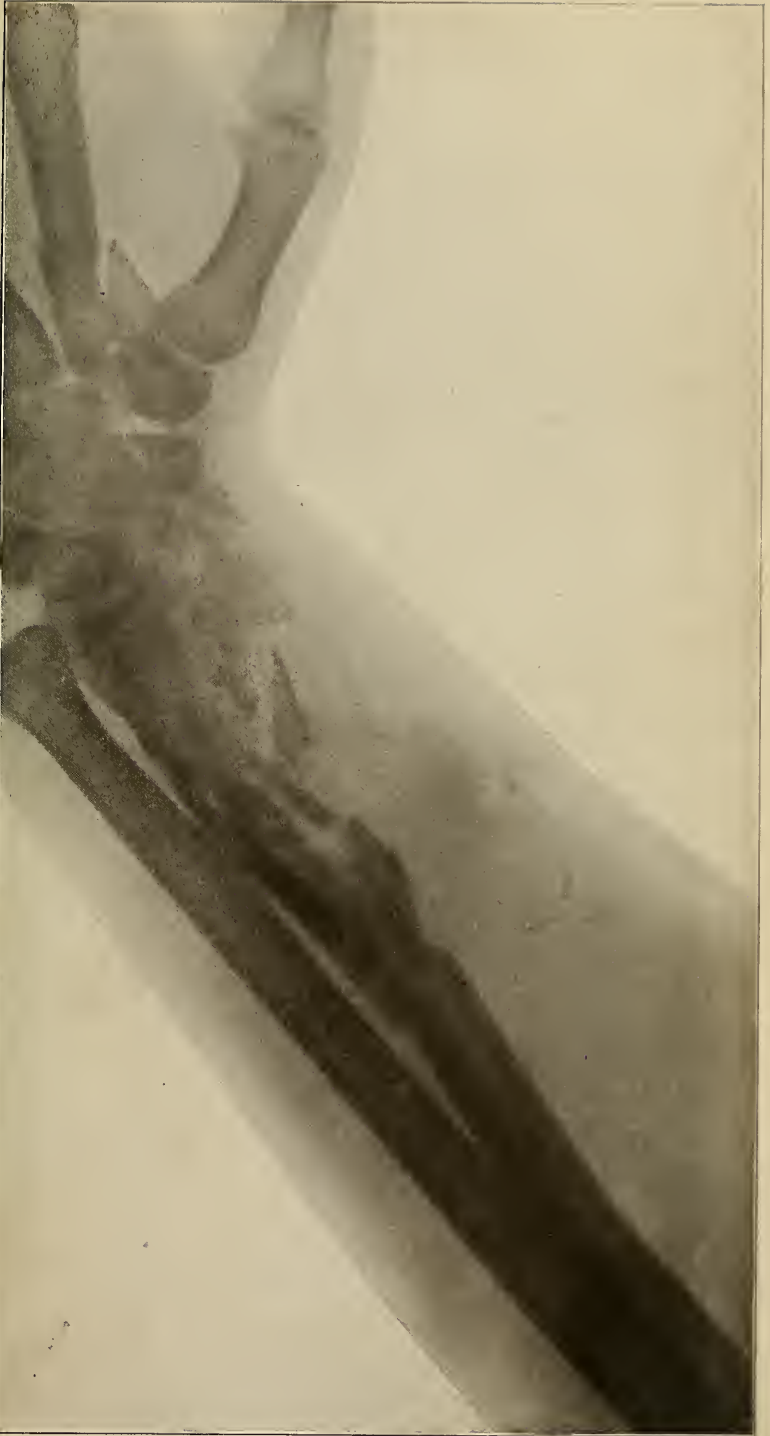FIG. 19.



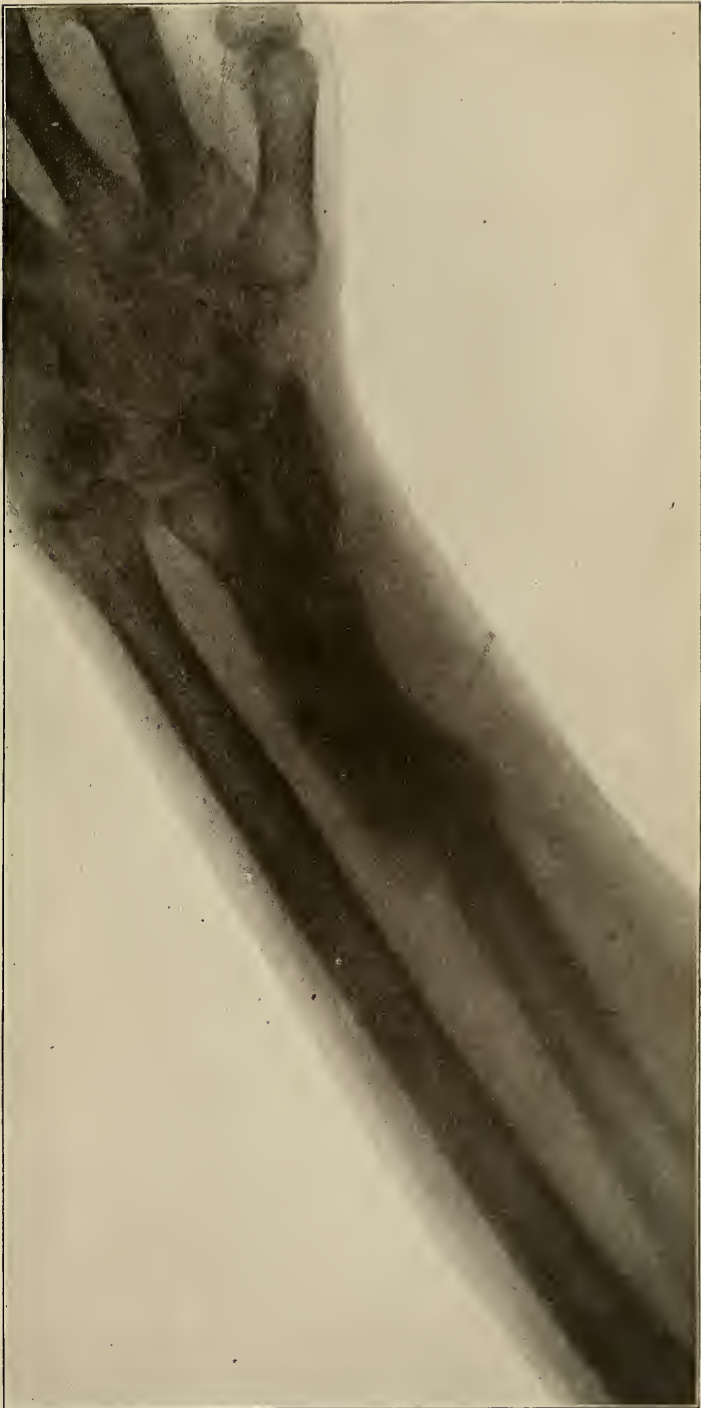Fracture of femur by ball from a Lobel rifle; small calibre; high velocity. (CHAUVEL and NIMIER.)

may be associated extensive laceration of the soft parts on the distal side. In other cases the bone is fissured or split into large fragments on each side. Occasionally the bone may be simply perforated or notched, and then broken by the subsequent use of the limb. I have seen two such cases; in one the patient was shot by a policeman, and as he ran away the femur broke at the point where it had been perforated; he died of tetanus. In the other, fracture of the leg, the same sequence was observed, but the patient survived, and the exact character of the injury caused by the bullet remained unknown.

In the case shown in Plate I., in which the ball entered between the fingers and emerged above the elbow after extensively splintering the



Fracture of Radius by Small Bullet of High Velocity entering
at the Hand and emerging at the Elbow.



Same Case as Plate I., after Repair.

lower half of the radius, the skin of the forearm was torn longitudinally in several places, apparently by the distending effect of the ball.

In fractures by a charge of small shot at close range the laceration of the soft parts is the predominant feature. In those of the cranium, chest, and pelvis the associated visceral injuries are the most important; thus, one of my patients died from the injury done to his brain by a single bird shot, size No. 7, which entered through a very thin part of the frontal bone just below the inner end of the eyebrow. The removal of the bullet, even from the brain, is not essential to recovery, and a search for it may easily be harmful.

The great mortality which formerly characterized these injuries has been greatly reduced by antiseptic treatment. In military surgery the gain in saving life and limb has also been increased by the reduction in the size of the bullet and possibly also by its higher velocity. In civil practice, which deals mainly with pistol-shot wounds, the results now obtained are good. A pistol-shot wound is usually surgically clean, and if not officiously treated may be confidently expected to heal kindly; a piece of the clothing is rarely carried in by the bullet, and in most cases all that is necessary is to clean the surface and the orifice of the wound and apply a dressing. The bullet may be left to heal in unless the wound is large and ragged. Late hemorrhages, due to the sloughing of bruised vessels, sometimes occur.

Displacements.

The relations of the two principal fragments produced by fracture of a bone may be altered in various ways, which Malgaigne classified under six heads. The classification has been generally adopted, with the understanding, however, that a fracture usually presents a combination of two or more of them, and that there is an additional group of cases in which the peculiarities of the displacement defy classification.

The six classes group displacements according to

1. The transverse axis of the bone, *transverse* or *lateral* displacement.
2. The long axis of the bone, *angular* displacement.
3. The circumference of the bone, *rotatory* displacement.
4. The length of the bone, *overriding*.
5. Penetration of one fragment by the other, *impaction* or *crushing*.
6. *Direct longitudinal separation*.

1. **Transverse or lateral displacement** may take place forward, backward, or toward either side, and may be partial or complete. Pure transverse displacement is rare; it is usually associated with overriding or angular displacement, or both (Plate III., fig. 1).


2. **Angular displacement** may vary in degree from a slight deviation to a right angle, or even more, and may be associated with so complete and distant separation of the broken surfaces that the fragments form a T (Fig. 20). It may be produced by the fracturing violence, the action of gravity, or the contraction of the muscles.

3. In **rotatory displacement** one fragment, usually the lower, turns about its long axis, while the other fragment remains in position.

4. **Overriding** is most common after oblique fracture of the shaft,

and is produced by various causes, such as a continuation for a moment after the fracture of the force that has produced it, the tonicity of the muscles, or the swelling of the limb due to inflammatory reaction and extravasation of blood beneath the deep fascia, which, by increasing the transverse diameters, shortens the longitudinal one.

FIG. 20.



Fracture of the clavicle.

5. Displacement by penetration or crushing has been already mentioned as the *impacted* variety of fracture. Penetration rarely takes place without a change in the direction of the axes of the fragments, because of differences in the resistance or of the direction of the fracture.

FIG. 21.



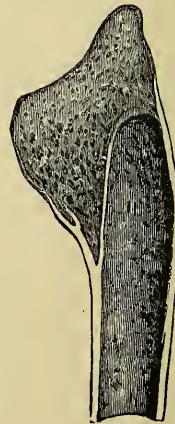Rotatory displacement after fracture of the neck of the femur.

FIG. 22.



Fracture of both bones of the leg, with overriding.

FIG. 23.



Fracture of the lower end of the radius. Angular displacement of the lower fragment backward. (R. W. SMITH.)

The callus found after consolidation of the fracture may give the appearance of a much deeper penetration than has actually taken place; thus, in Fig. 23 the triangular mass of spongy tissue on the side is

PLATE III.

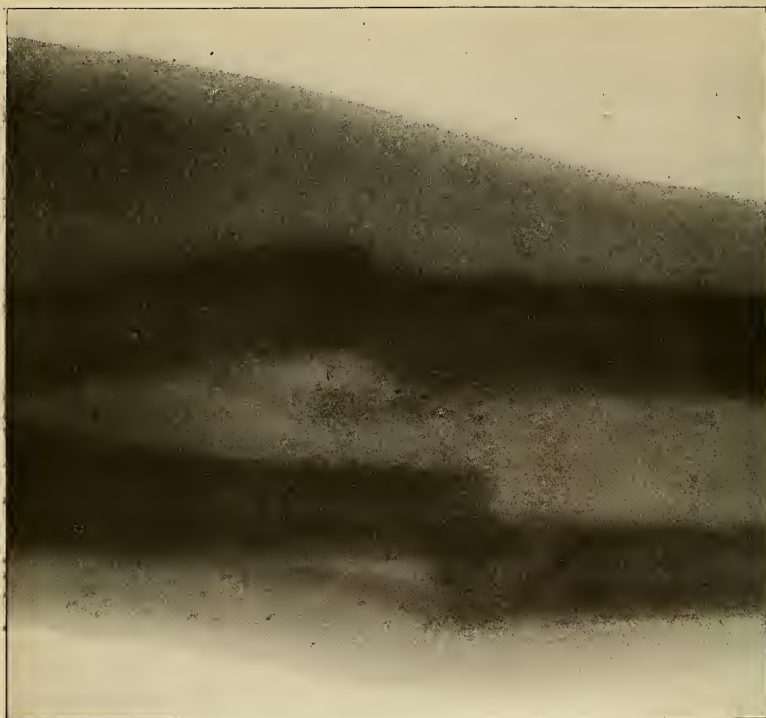


Fig. 1.—Fracture of Forearm, Six Weeks Old, showing Ossification along Periosteal Bridge.

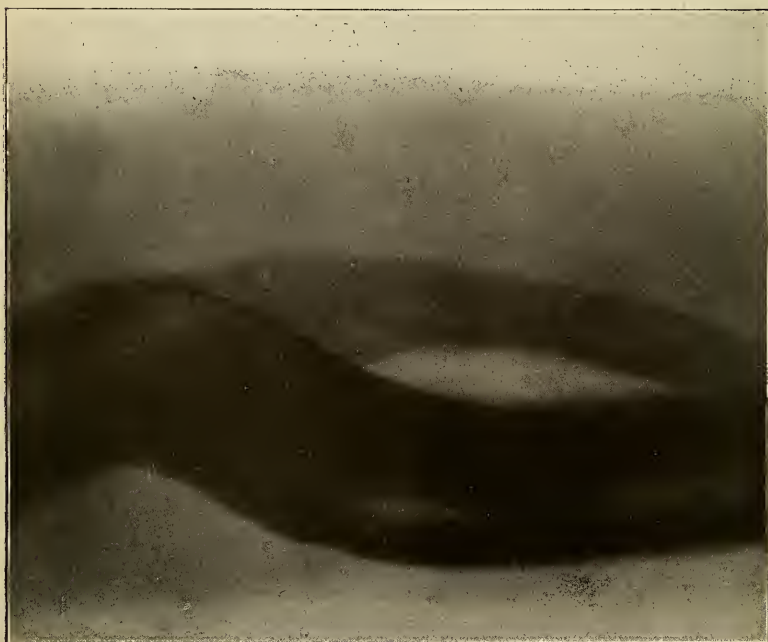
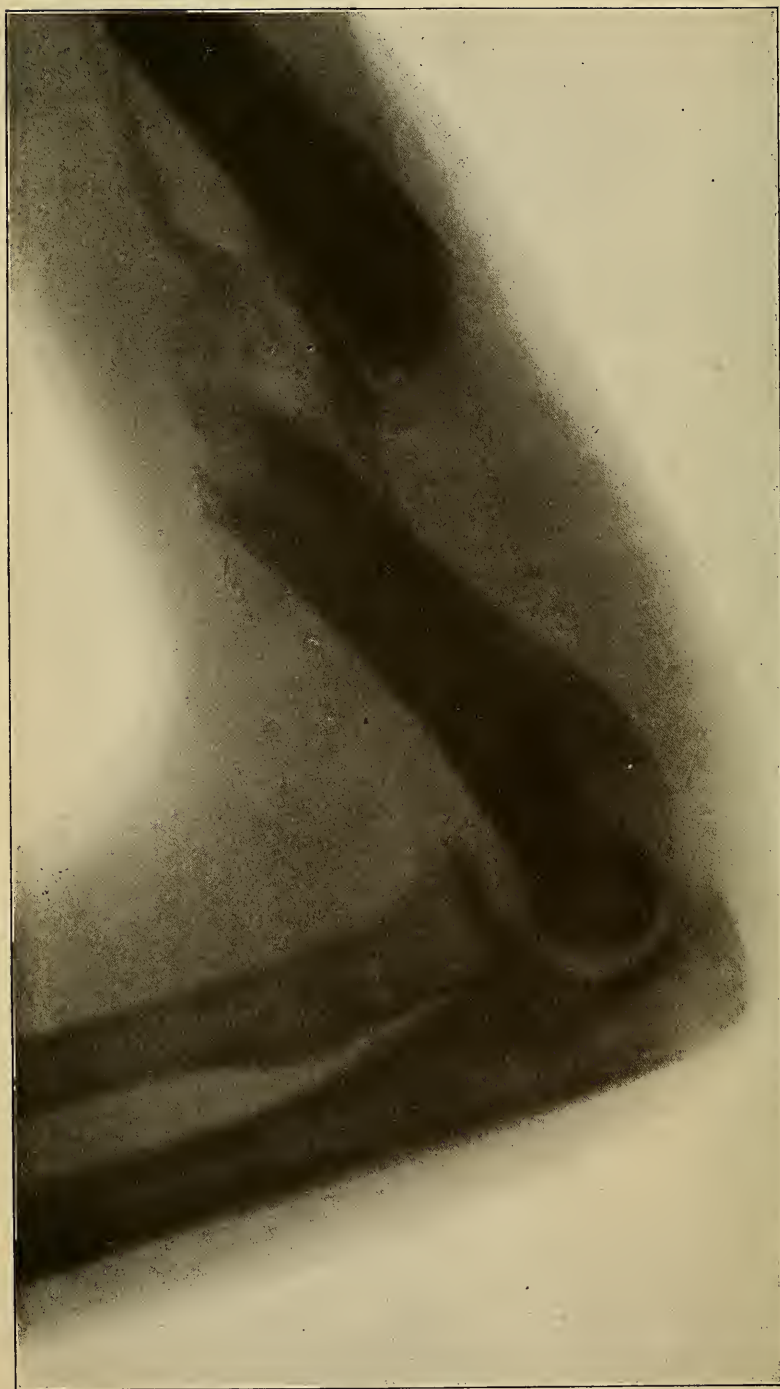
Fig. 2.—Humerus, Two Years after Fracture. Growth of Bone along Periosteal Bridge.

PLATE IV.



Same as Plate III., Fig. 2. Injury recent.

not the penetrated epiphysis, but is mainly composed of callus formed by the stripped-up periosteum.

6. **Direct longitudinal separation** is seen most frequently after fracture of the patella, and is then due partly to the retraction of the quadriceps and partly to the distention of the joint by blood and exudate.

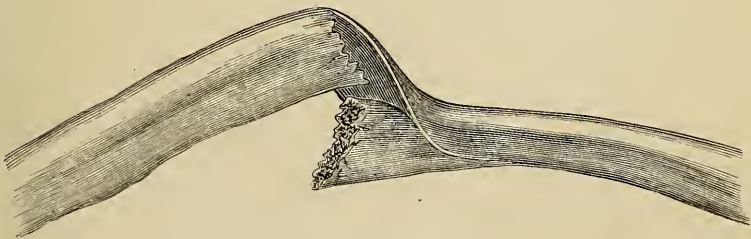
Among the *irregular* displacements, those which do not fall entirely within the above-classification, may be mentioned rotation of one fragment about its transverse axis, as in some fractures of the neck of the humerus, crossing of the fragments in the form of an X, and the interposition of a bone between two fractured ones, or of the end of the shaft between its separated condyles.

(B) THE SOFT PARTS.

The **periosteum** may be simply loosened from the surface of bone adjoining the fracture, or it may be torn across throughout the whole or only a portion of its extent at or near the line of fracture. The first form (excluding fractures of the flat bones) is found only in fractures with slight displacement, and especially in the young, in whom the periosteum is thick and resistant. Such fractures are known as *subperiosteal*. They may be recognized or inferred from the youth of the patient and the slight displacement and mobility of the fragments. Their prognosis is exceptionally good.

Complete rupture of the periosteum all around the bone is probably infrequent and to be found only in fractures with great displacement. Examination of fresh specimens and of the position and shape of the callus in those that have united indicates that in most cases the continuity of the periosteum is preserved on one side, the continuous portion being stripped off one of the fragments for some distance and forming a "periosteal bridge" (Ollier), which unites the two fragments and takes an important part in the subsequent repair. (Plate III. and IV.)

FIG. 24.



"Periosteal bridge," diagrammatic.

The **muscles** may escape injury or may be extensively torn. The neighboring **connective tissue** is torn and infiltrated with blood from its own **vessels** or from those of the broken bone. Injury to important **vessels** and **nerves** is rare; it will be described under **Complications**, Chapter VI.

The **skin** may be torn by the original violence or by the sharp end of a fragment, or it may be so bruised by the original violence or so pressed upon by a displaced fragment that it subsequently sloughs. These lesions of the skin may communicate with the seat of fracture (compound fracture), or may be at a distance therefrom and without influence upon its course, except so far as they may interfere with the application of splints. Discoloration of the skin due to extravasated blood beneath almost invariably appears after a day or two, and may be widespread. Large blebs filled with dark, blood-stained serum frequently appear upon the limb near the fracture by the second or third day.

CHAPTER III.

ETIOLOGY.

Predisposing Causes—Determining Causes—Spontaneous and Pathological Fractures—Intra-uterine Fractures and Fractures During Delivery.

THE causes of fracture may be grouped under two heads: A. *The predisposing causes*; B. *The immediate or determining causes*.

The Predisposing Causes

are of three kinds: (1) the external, (2) the normal or physiological, and (3) the pathological. Most of the latter, which consist in a local or, more rarely, a general diminution of the strength or an actual destruction of the bone by a local or general disease, will be considered under the head of Spontaneous or Pathological Fractures.

The external predisposing causes are those incidental to various occupations and modes of life which involve greater exposure to determining causes; they account for the great excess of fractures in males over those in females between youth and old age, and for their rarity in young children.

The normal or physiological causes are those which have their origin in the position and functions of the different bones. The bones of the skull and chest are broken when the violence against which they are designed to protect the enclosed viscera is too great for their power of resistance; the use of the arms in many occupations exposes them to fracturing violence, and they and the lower limbs are broken in falls all the more easily because of the contraction of the muscles by which they are stiffened to protect the body against the shock. In like manner the normal curves in single or associated bones—*e. g.*, the clavicle and spinal column—which supply an elasticity that is protective of the viscera increase their liability to fracture.

Interstitial atrophy of the bones, which is so common a senile change, is undoubtedly the cause of the greater relative frequency of fractures in the old; and its agency becomes all the more apparent when the usual withdrawal of the aged from the occupations which most expose to fracture is taken into account. This atrophy consists in thinning of the cortex of the shafts and of the trabeculae of the spongy portions and of the short bones, not in a relative increase of the lime salts in the bone tissue itself, as was long supposed. It is an actual diminution of the bone substance and a corresponding increase of the fat and other soft parts contained in it. In the old, and when not extreme, it may be classed as a normal predisposition to fracture, but when it appears prematurely or reaches an extreme degree it must be deemed pathological and classed with other similar atrophies whose nature and causes are not well understood.

The *inherited or early developed liability* to fracture which has been observed in certain individuals and families who were in other respects normal is probably the result of a similar scantiness of the bone tissue. Of this inherited liability Gurlt gives three examples, extending in one over four generations, in the others over three. One of the patients suffered fourteen fractures, and another thirteen, before either reached the age of thirteen years. All united promptly. He gives also three cases of a congenital but not inherited liability to fracture in families. One girl suffered thirty-one fractures of the thigh, leg, and arm between the ages of three and fourteen years; her sister had nine before she was six years old. Not infrequently individuals have developed in early or middle life a noticeable fragility of the bones without any other change that would indicate a general deterioration or disease. Thus, Biggs¹ reports a case of twenty-two fractures, all but one of the arm or thigh, between the ages of twenty and thirty years in a man who had suffered none before or after.

Immediate or Determining Causes of Fractures.

These are of two kinds: (1) External violence, and (2) muscular action, the latter exerted by muscles connected more or less directly with the bone that is broken.

1. **Fractures by External Violence.** The division of these into two classes, of which one is called fractures by *direct*, the other fractures by *indirect*, violence is based upon clinical differences often of extreme importance, and not simply upon mechanical differences in the mode of transmission and in the effect of the applied force. This relieves us, therefore, from the necessity of examining the latter questions with their many obscure factors and complex relations, and makes the definitions simple. A fracture by *direct violence* is one in which the bone is broken immediately under the point upon the surface where the fracturing force is exerted; and a fracture by *indirect violence* is one in which the fracture takes place at a distance from that point. The most important clinical difference between the two varieties depends upon the injury to the overlying soft parts in the one case and the absence of such injury in the other.

The skin is not always broken in fractures by direct violence, even when the vulnerant force has been great and the injury to the soft parts under the skin extensive, but it may have been so injured, even if it shows no marks of violence, that it will slough. On the other hand, the blow may break the skin at the point where it is received and produce fracture indirectly at a greater or less distance, the bone yielding at its point of least resistance and not at that where the force is directly exerted.

The fracturing force may be applied *directly* or *indirectly* to the bone, to crush or break it, or obliquely to its long axis, or as torsion, or as avulsion. Examples of the first are furnished by falls upon the feet with fracture of the calcaneum, gunshot wounds, and crushing of the lower end of the radius in a fall upon the hand; of the second by most

¹ Biggs: Univ. of Penn. Bulletin, 1903, No. 12.

fractures of the shafts of long bones; of the third by some fractures of the leg when the foot is fixed and the body turned forcibly about it; and of the fourth by some fractures of the lower end of the humerus by forced abduction of the forearm, by some of the internal malleolus in eversion of the foot, and by some of the patella in forced flexion of the knee when its normal range of motion has been limited by previous injury.

Indirect fractures are by far more common in long bones than in the short spongy ones, because of their proportions and functions. The principle of their production is that of the transmission of a force along a bone or set of bones made rigid by ligamentary attachments or muscular contraction in such manner that it is resolved into forces acting in two or more directions, one of which crosses the long axis of the bone and acts as if it had been applied directly at the point of least resistance in a transverse direction. The effect is greatly modified by the anatomical structure and form of the bone, the attitude of the limb, the contraction of the muscles, and the direction of the blow. Thus, a fall upon the hand may break the bones of the forearm, the humerus, or the clavicle; a fall upon the foot may fracture the calcaneum by direct violence, or the bones of the leg, the thigh, or even the vertebral column or skull by indirect violence.

The best example of the fracture of short bones by indirect violence is furnished by the spinal column, the bones of which, considered as a group, constitute a long bone with several curves, the forcible exaggeration of which produces fracture.

2. Fractures by Muscular Action. Under this head are included only those fractures in which the rupturing force is exerted by the muscles alone, without the aid of any external violence. It is, of course, evident that, if an individual breaks his skull or a limb by running or striking against a solid object, the force that causes the fracture is developed by the action of his muscles; but the mechanism is the same as if he had fallen from a height, or as if his body was at rest and the object with which he has come into contact was in motion. Only those cases are considered to be fractures by muscular action in which the action is exerted directly by the muscles upon the bones to which they are attached (mediately or immediately), either as direct traction, as in fracture of the patella or of the olecranon, or obliquely, or in torsion against resistance, or by sudden muscular arrest of the rapidly moving limb, as in throwing, or in striking or kicking at an object and missing it.

Some authors have expressed the opinion that no bone can be broken by simple muscular contraction unless it has previously undergone some change that has diminished its strength; but this opinion must be looked upon as an attempt to explain away by an unfounded, or at least an unproved, assumption a difficulty which does not really exist. It is no more logical to claim that such a change has preceded every fracture by muscular action than it would be to make the same claim for fractures by external violence; it can rest only upon the assumption that the power of resistance of a normal bone is superior to any force that a muscle or group of muscles can exert upon it, even under extreme and unusual circumstances; whereas, on the contrary, nature's precautions and adaptations are calculated upon the basis of the prob-

able, not of the exceptional. Such a position may be taken with propriety concerning all fractures produced by slight causes in the old, the diseased, the cachectic, or in those who have suffered pain at the point of fracture for some time previous to the accident; but it is entirely unsupported by proof in the rarer, but still sufficiently numerous, cases of the fracture of the shaft of a long bone produced by a violent effort in a healthy athletic man, and in the common ones of fracture of the patella.

The effect of muscular action is manifested in all the degrees of varying importance between its relatively unimportant additions to the effects of external violence and those cases in which it is the sole agent of the fracture of a healthy bone. The intermediate degrees are presented by those fractures, usually of weakened bones, in which moderate muscular action has acted either alone or combined with slight external violence. In the first case, when the power of the muscle is exerted in the same direction as the external violence, it increases the fracturing force by just so much; and, by prolonging its effect after the fracture has been made, it also increases the displacement of the fragments and the laceration of the soft parts. The principal interest of the intermediate cases is connected with the cause of the exceptional fragility of the bone, and is considered in the following section—Spontaneous and Pathological Fractures.

The commonest examples of fracture by muscular action alone are furnished by the patella; other apophyses and tuberosities to which powerful muscles are attached—the olecranon, greater tuberosity of the humerus, coracoid, acromion—furnish them much more rarely.

Of the long bones the humerus is the one most frequently broken in this manner; out of 85 cases of fracture of the limbs by muscular action collected by Gurlt,¹ 57 were fractures of the humerus, 15 of the thigh, 8 of the leg, and 5 of the forearm. Ashurst² collected 81 cases of fracture of the humerus: 24 by torsion, 57 by a blow. The mechanism seems in most cases to be the same as in indirect fracture; in some the fracture takes place at the insertion of the muscle, and in others the elements are too complex and too conjectural to be explained theoretically. In a comparatively small number of cases the fracture has been caused by reflex spasms in limbs that had long been paralyzed or by the convulsions of epilepsy or tetanus, but usually the cause is a violent voluntary muscular effort to avoid a fall, to throw a stone, or to lift a heavy object. The following cases taken from Gurlt illustrate the different forms and the methods by which they may be produced. It must be remembered that fractures produced during convulsions need to be closely examined in order not to overlook the possible addition of external violence by a fall from the bed or by a blow.

In a negro boy, twelve or thirteen years of age, affected with tetanus, both thigh bones were broken "at the neck," possibly just below the trochanter, by the contraction of the muscles, and the fragments forced through the skin on the outer side of the limb.

An athletic man, thirty-four years old, accustomed to lift heavy weights, broke his humerus with an audible snap, just below the insertion of the deltoid, by the effort made, on a wager, to throw a stone

¹ Gurlt: *Loc. cit.*, vol. i. p. 232. ² Ashurst: *Univ. of Penn. Med. Bull.*, Feb., 1906.

weighing about two ounces the distance of a hundred yards. Recovery in six weeks.

Gurlt gives also 11 cases (Ashurst, loc. cit., 24) in which the humerus was broken during that trial of strength in which two men place their elbows upon a table, clasp hands with the forearms parallel and vertical, and strive to force each other's hand backward.

Fractures of the femur may occur at any point of the shaft, and in the recorded cases have been the result of an attempt to kick, to avoid a fall, or to rise from the ground on one foot, or of cramps, excited in one case by drawing on a tight boot and in another by turning in bed.

A man, thirty-six to thirty-eight years old, of middle size and great muscular power, broke his thigh at the junction of its upper and middle thirds by kicking at and missing his servant.

Van Oven described before the Royal Medical and Surgical Society a fracture of the thigh sustained by himself. He was fifty-six years old, healthy and strong, and free from taint of cancer, scrofula, syphilis, etc. He was awakened by a sharp, cramp-like pain above the knee, and as he felt the part with his hand, and noticed that the muscle was tense, he heard a snap, followed by relaxation of the muscle, crepitus, and diminution of the pain. Examination showed a transverse fracture of the femur three inches above the knee. Complete recovery in four months.

A cavalryman, twenty-nine years old, while trying to rise from a sitting posture on the ground without the aid of his hands, broke his right thigh at its middle.

Gurlt's eight cases of fracture of the leg comprise four of both bones, one of the tibia, and three of the fibula alone, the latter being fractures at the upper end of the bone by the contraction of the biceps.

A small, rather corpulent woman, forty-five years old, slipped on the left foot while descending some steps, made a violent effort with the right leg to avoid a fall, felt at once a severe pain in the latter, and fell in a sitting posture. An immediate examination showed a fracture of both bones at the middle of the leg.

A woman, fifty-two years old, mistook a door leading into the cellar for one opening into a closet, and, recognizing the mistake as she put her right foot forward, drew herself instinctively backward, and felt at the same moment something snap in her left leg, upon which the weight of her body rested. She fell and rolled down the steps. A fracture of the left fibula just below its head was found.

Fracture of either or both bones of the forearm has been caused by the wringing of wet clothes and in shovelling. A healthy girl, eighteen years old, while wringing clothes, felt a sudden sharp pain on the inner side of the forearm above the wrist. Three days afterward a fracture of the ulna, two and one-half inches above the wrist, was recognized.

A woman, thirty years old, broke the radius in its lower third with severe pain while wringing two heavy towels.

Fractures of the clavicle have been caused by the effort of raising a heavy object, shovelling, and striking backward or with a whip.

Fractures of one or more ribs are not infrequently caused by violent

coughing, especially in the consumptive. The sternum has been broken in four recorded cases by the violent straining and bending backward of the body during the expulsive efforts of parturition, and there are several cases of fracture of the cervical vertebræ by muscular action alone, and of the scapula.

Hilton reports the case of a man who had broken a rib by muscular action while trying to mount a spirited horse.

A primipara, twenty-four years old, taken in labor, sought to hasten delivery by forcible expulsive efforts, bending backward and resting on her elbows and heels; she felt a sudden sharp pain and a snap in the middle of the breast, and said at once that something had broken there. She died of peritonitis, and at the autopsy a transverse fracture of the sternum was found, one and one-half lines above the junction of its body and the manubrium.

A soldier dived into a river, and, not reappearing, was sought for and brought out. His body showed no trace of external violence, but there was paralysis of all the limbs, loss of sensation, pain at the posterior and lower parts of the neck, priapism, frequent desire to urinate. He said that as he dived he saw the water was too shallow, and in the effort to avoid striking against the bottom he jerked his head sharply backward and at once lost consciousness. He died the same night, and the autopsy showed a transverse fracture of the body of the fifth cervical vertebra a little below its centre. A number of similar cases have been reported.

A servant engaged in preparing a lamp raised his arm quickly to arrest the action of an escaping spring and felt something give way in it. The arm fell powerless by his side, and the greater portion of the acromion was found to have been broken off.

I have seen two fractures of the coracoid process by forcible contraction of the muscles of the arm.

Spontaneous and Pathological Fractures.

The term *spontaneous* is used to indicate that the violence, external or muscular, which has produced the fracture is much less than that commonly observed in that form; and the term *pathological* to indicate a preceding abnormal change in the fractured bone by which its strength has been diminished. It has become common to use the terms interchangeably, because the slight violence indicated by the first is efficient to fracture only when the change indicated by the second is present.

It is noteworthy that the pain accompanying or following the fracture is often very slight; fractures of ribs, and even some of the limbs, have passed unrecognized until the autopsy. The pathological condition known as general atrophy or rarefaction of the bone, or osteoporosis, and which has been referred to as senile atrophy, may appear prematurely or may have its origin in other causes than senility, such as paralysis, locomotor ataxia, diabetes, pregnancy, and osteomalacia. It is worthy of note that in not a small proportion of cases union takes place promptly. In most of the cases which furnish autopsies the bones

are found softened and reduced to a shell by absorption from within, and in some of the cases suppuration has taken place at the fracture.

It has been noted by Bonchard and by Verneuil and Verchère that spontaneous fracture occasionally happens in the diabetic, and that the urine shows the presence not only of sugar but also of phosphoric acid in quantities that suggest its origin in a decalcification of the bones. These observations have been confirmed by Isch-Wall (quoted by Ricard), who also found the phosphoric acid present in some patients affected with cancer. In nine cases of spontaneous fracture in the diabetic reported by Verchère union was greatly delayed.

The following cases represent different varieties :

A woman, seventy-two years old, had both thighs broken by kneeling in church, and the humerus by the efforts of bystanders to lift her up. Another broke her clavicle by putting her arm about the nurse's neck and trying to turn herself in bed (Gurtl).

A woman, forty-five years old, the mother of two children, suffered a great deal of pain in her bones after the birth of her second child, and became so helpless that she could not get into or out of bed without aid. She broke each thigh below the trochanter by stumbling against the bedpost in one case and by turning in bed in the other. Both united with marked angular displacement, and at the autopsy the bones of the thigh and pelvis were found to be so light that they floated in water and could be crushed by pressure with the finger. The cortical layer of the femur was as thin as an egg-shell, the medullary canal enlarged, traversed here and there by delicate plates of bone, and filled with a grumous, semifluid mixture of blood and marrow (Gurtl).

A man, sixty years old, broke his femur in the middle third by stumbling, without falling. He died a fortnight later, and I found an enormous calculus in each kidney.

Saviard saw in 1690 a woman, about thirty years old, who had suffered for four months with severe pains throughout the body, increased by movements, and without fever. Three months later she had become bedridden, and her bones had become so friable that most of them were broken, and she could not be moved without causing a new fracture. She lived ten months in this condition, and the autopsy showed fractures of almost every bone in her body. The structure of the bones was so delicate that they could not be pressed between the fingers without breaking into small pieces; the marrow was red, the muscles pale, the joints and cartilages unchanged.

In a case under my care the tibia appeared to have been weakened by an osteitis set up by a blow and a wound of the soft parts. The wound healed in three weeks; a fortnight later the patient returned with a compound fracture of the leg at the scar, caused by stepping down a distance of two feet. The bone could be plainly seen and was rarefied. Prompt recovery.

A similar friability is also found in some cases of old unreduced dislocation, due, it is supposed, to lack of use. The condition was shown by direct examination in a case of subcoracoid dislocation of six weeks' standing, in which Guérin¹ tore off the forearm in an attempt

¹ Guérin: Bull. de la Soc. de Chir., 1864, vol. v. pp. 121 and 131.

to reduce. The ends of the bones were rarefied and soft, and the muscles softened and brown. The autopsy showed no change in the other portions of the body.

It seems probable, however, that in most cases in which fracture has occurred during an attempt to reduce a dislocation, and in which unusual fragility has been alleged in explanation, the force exerted upon the bone has been greater than the surgeon supposed, because of the leverage employed, especially in rotation of the limb.

Disease of the Nerve-centres. In 1842 Davey called attention to the facility with which fracture sometimes occurred in lunatics, especially in those who were also paralytic, and the observation has been abundantly confirmed, Bruns having collected more than sixty reported cases. Weir Mitchell¹ was the first to call attention to the frequency of fracture in those affected with locomotor ataxia, and suggested that the cause might lie in an impairment of the nutrition, and consequently of the strength, of the bone dependent upon the disease of the cord. Shortly afterward Charcot² published a remarkable case of multiple fractures and dislocations in an ataxic woman, and Bruns³ followed with a paper upon the subject, based upon thirty cases reported within a few years. He finds that the fractures are usually multiple, from two to six in number, and are most common in the lower limb, especially in the femur; the frequency is equal in the different bones of the upper extremity—clavicle, humerus, and forearm. Repair takes place in the usual time.

The accident seems to occur more frequently in the earlier than in the later stages of the nervous disease, and the predisposing condition is a rarefaction of the bone marked by great absorption of the compact tissue, increase of fat, and loss of inorganic matter. A very remarkable instance of the earliness of this change is given by Tillmann⁴ in the report of three cases of spiral fracture of the shaft of the femur caused by the effort made in drawing off a shoe. The patients showed nothing abnormal at the time, but when examined three and half, five, and eight years later, respectively, locomotor ataxia existed.

Rachitis. Friability due to rachitis is found only in childhood, for the disease is one which involves the bones only during their period of growth, and consists essentially in the prolongation and exaggeration of the embryonal or developmental condition of the shaft, in consequence of which its strength and the firmness of its union with the epiphyses are diminished.

Union after fracture takes place rather more slowly than in normal bone, and sometimes fails entirely. The callus is usually large, but, as it is composed of the same soft embryonal tissue whose excess is the pathological feature of the disease, it is lacking in firmness.

Syphilis, Mercurialism, and Rheumatism. Syphilis affects the organism in so many and so varied forms, and causes such serious bone lesions in its later stages, that it is not strange that both physicians and patients have been inclined to attribute to it fractures produced by slight causes whenever the patient was or had been affected by it.

¹ Weir Mitchell: *American Journal of the Medical Sciences*, July, 1873, p. 113.

² Charcot: *Arch. de Phys.*, 1874, p. 166.

³ Bruns: *Berlin. klin. Wochenschrift*, 1882, p. 164.

⁴ Tillmann: *Berlin. klin. Wochenschrift*, 1896, No. 35.

And in like manner those who saw in mercury the cause of the bone lesions of syphilis attributed the fractures to the use of that drug.

When we remember what multitudes of people have contracted syphilis, how numerous those in whom it has caused grave lesions of the bones, and on the other hand how few are the cases, excluding separation of the epiphyses in the new-born, in which it can even be suspected as a predisposing cause of fracture, it is evident that it can have but little influence in this direction; and an examination of the alleged cases shows very frequently a coexisting constitutional weakness or a cachexia not always to be attributed to the specific disease which creates a close resemblance between these cases and those in which the friability of the bone is due to a premature or exaggerated senile atrophy. Yet it seems strange that the development of a gumma in the shaft of a long bone, with the consequent destruction of tissue, does not more often lead to fracture.

Gurlt's fifteen syphilitic cases include five in which the fracture was preceded by severe pain, more or less prolonged, in the broken bone, and these might be deemed demonstrative of the influence of syphilis did we not possess other similar cases in which the syphilitic complication does not exist. Malgaigne,¹ indeed, speaks of local inflammation of the bone as a frequent and too much neglected predisposing cause of fracture, adding: "I give this name, conjecturally, to an affection which manifests itself by dull pains attributed by the patient to some contusion or to rheumatism, rarely sufficient to cause a general reaction, and attracting but little attention until some slight cause produces fracture at the point it occupies." There is a striking similarity between the cases he cites and Gurlt's syphilitic cases.

There seems to be no reason to suppose that mercury has any direct action upon the bones rendering them more liable to fracture, and the most that can be claimed is that its excessive, unskilful use will cause a deterioration of the health, which may result in an atrophy of the bones similar to that found in old age.

Cancer and Sarcoma. There are two ways, apparently, in which the development of a malignant tumor may lead to fracture: either the tumor may occupy the bone itself, primarily or secondarily, and destroy it to such an extent that the slightest force is sufficient to fracture it, or the presence of the tumor elsewhere may induce a cachexia which results in atrophy of the bones. The following cases are quoted in illustration:

Louis² was called to see a nun, sixty years old, whose arm had been broken by the efforts of a coachman to help her into a carriage. Union did not take place, and six months later, while seated in a chair, she broke her femur by letting her hand fall upon it. Louis, seeking the cause of this fragility, then learned that the patient had an ulcerated cancer of the breast.

A woman,³ forty years old, who had a cancer of the breast for some time, with well-marked cachexia, broke her right femur in the lower third by rising from a chair. She was taken to the hospital, and there

¹ Malgaigne: *Loc. cit.*, p. 22.

² Malgaigne: *Loc. cit.*, vol. i. p. 14.

³ Cruveilhier: *Anat. Path.*, Livraison xx, Pl. 1, Fig. 4.

the other femur was broken by the interne as he was preparing to apply a bandage to the first. She died the same night, and at the autopsy cancerous masses were found in the spongy tissue and in the medullary canal at the points of fracture and elsewhere, also in the vertebræ and cranial bones.

I have now under treatment a woman thirty-one years old who broke her left femur in the upper third by stumbling, without falling. For two years she has had a carcinoma of the left breast, unulcerated but involving the skin. Two months later there was a large mass at the seat of fracture, and on moving the limb crackling (apparently the breaking of small pieces of bone) could be plainly felt. Now, a month later, there seems to be fairly firm union.

In thirty-two cases collected by Gurlt in which the position of the primary tumor is noted, it occupied the mammary gland twenty-six times (once in a man); and of the entire thirty-eight cases thirty-five were women. As a rule, too, the affection was of long standing; in many of the cases the tumor had returned after removal, and in nine it had ulcerated. The humerus and femur were almost exclusively affected, but very unequally—twenty-six fractures of the femur and seven of the humerus. Severe localized pain in the bone preceded the fracture in a number of cases.

Reunion took place in one-fourth of the cases, and in at least three of these there was cancerous degeneration of the bone at the seat of fracture. In most of the remaining twenty-eight cases death, due to the progress of the disease, followed so soon after the fracture that the bones had not time to unite, even if they were capable of doing so.

Hydatid and Other Cysts. There are a few instances on record in which the unsuspected development of a hydatid cyst within a bone has resulted in its fracture by slight violence at the point occupied by the cyst; and others in which a similar result has been produced by the occurrence of a cystic degeneration of unspecified character within the bone. These causes act by direct absorption of the cortical layer of the bone, and their action is purely local.

Osteomyelitis favors fracture by partial destruction of the bone, but as this effect is accompanied by a rapid and often very bulky new-formation which makes good the loss, fractures are but infrequently observed except in the course of operations undertaken for the cure of the disease which require much cutting away of the new bone. I have seen several such; their importance is slight, for there is usually but little displacement, and repair takes place within the usual time.

Intra-uterine Fractures and Fractures During Delivery.

Fracture of a limb of the child during its delivery through the natural passages of the mother is not very infrequent and is usually the result of manual or instrumental interference. Such fractures belong to the class of fractures by external violence, and present no features of special interest; but there are others in which the fracture is caused by the expulsive efforts of the mother alone. An arm or a leg is engaged between the body of the child and the rigid parts of the

mother, and the humerus or the femur is broken, sometimes with an audible snap, as the child is forced through the passage.

Fractures within the uterus have been caused in a few cases by a bullet or sharp instrument that has at the same time perforated the abdominal wall of the mother.

The possibility of the occurrence of fracture within the uterus as the result of external violence without perforation of the abdomen of the mother, or, in some cases, of unknown causes, has been proved by the birth of children presenting fractures of different bones in various stages of repair. It is not always easy to say, when a child is born with a fracture, whether it was caused during delivery or at an earlier period, or whether it was due to external violence or to the contractions of the uterus. And, further, it is not always possible to say whether an apparent fracture is actually one or only a malformation, a defect of ossification or of development, or a separation of the epiphysis due to syphilis. Gurlt collected eight cases in which the causal relation between an injury received by the mother during pregnancy and the fracture observed in the child seemed to him to be clearly demonstrated, and twenty-five others in which more or less doubt existed as to the cause of the fracture or the character of the lesion. The injury in the first eight cases was either a fall from a height or a violent blow upon the abdomen; and the bones broken were those of the thigh, leg, arm, and forearm, and the clavicle.

The other group includes some in which an undoubted fracture existed, but with no history of external violence, and some in which the coexistence of malformations threw some doubt upon the character of the supposed fracture, and others in which the fractures were so numerous and so symmetrical that they must have depended upon some general cause, syphilis or rachitis, acting possibly upon the epiphyseal cartilages.

CHAPTER IV.

EARLY SYMPTOMS AND DIAGNOSIS.

THE symptoms produced by a fracture are divided into two groups : the *objective* or *positive*, those which can be directly observed by the surgeon, and the *subjective* or *rational*, those for his knowledge of which he has to depend more or less completely upon the statements of the patient. The former include *deformity* of the limb or part, *abnormal mobility* at the point of fracture, and *crepitus*. The second group includes *loss of function*, *pain*, and *history* of the case and of the patient.

Objective Signs.

Deformity. This term is here employed in its widest sense, to include changes in the relations of the fragments of the bones to each other and the modifications in the appearance of the limb or part of the body produced by those changes, by the effusion of blood, and by the later inflammatory processes.

The changes in the relations of the fragments to each other have been described in detail under *Displacements*. Many of them are so marked that they are recognizable by simple inspection of the part, while others are brought to light only by careful palpation and by measurements compared with those of the opposite limb. These measurements are used in practice only to recognize displacements by which a limb is shortened or the diameters of an articular extremity modified. In a few places practically normal relations exist which may take the place of comparison with the opposite limb : such are those of the great trochanter of the femur to a line drawn from the tuberosity of the ischium to the anterior superior spine of the ilium, and those of the styloid process of the radius to that of the ulna, both of which may be used with confidence in cases of fracture of the neck of the femur or of the lower extremity of the radius respectively.

The chief difficulty in employing mensuration is that of finding well-defined points upon the skeleton between which the measurements can be made. Those employed in fractures are bony prominences or edges sufficiently near the surface to be clearly felt, but as they are all more or less rounded, absolute accuracy in measuring the distance is impossible.

Another cause of uncertainty or of error lies in the *normal asymmetry*, the difference not due to traumatism or disease, which has been found occasionally to exist, and which sometimes is very notable, as much as an inch and a half in the lower limbs.

Other sources of difficulty and error are found in the swelling of the soft parts, which may prevent the tape from being drawn straight, and in the varying angles between the axis of the limb and the line of measurement. The first is not likely to be great or to be overlooked; but the latter is a frequent source of error. It is rare that the two fixed points between which the measurement is made are both upon the limb or the bone whose length is in question; one of them is usually upon the trunk, and lies at a certain distance from the centre of motion of the limb. Consequently, any change in the position of the limb changes the distance between the two points that have been chosen. For example, in measuring the length of the lower limb the points taken are the anterior superior spine of the ilium and the tip of the malleolus; the former lies several inches away from the centre of the hip-joint, and when the limb is in abduction the distance between the chosen points is less than when the limb is parallel to the long axis of the body. If a comparison is to be made between the two limbs, it is essential that their position with reference to the pelvis should be the same, and, therefore, care must be taken that the ankles are equidistant from a line drawn between them at right angles to and from the centre of another connecting the two anterior iliac spines.

Similar difficulties and uncertainties exist in transverse and peripheral measurements. The swelling of the soft parts not only increases the bulk of the limb, but it also obscures the bony prominences and places them at a greater distance below the surface, so that an accurate measurement of the distance between points on the opposite sides of a bone is practically impossible. For this and for rotatory and angular displacements the trained eye, aided by careful and minute consideration and palpation of the anatomical landmarks and comparison with the opposite limb, is the best guide.

The appearance of the limb will be still further modified by swelling due to extravasated blood and inflammatory exudate, and sometimes to the shortening of the limb, which increases its transverse diameters.

Ecchymosis is a symptom that is rarely absent, although its appearance may be delayed for several days. It is most marked and most extensive in the old. The blood which escapes from the broken bone and the adjoining parts makes its way along the muscular planes, and first appears under the surface at some distance from the fracture. Its appearance at certain points creates a strong presumption of fracture—*e. g.*, beneath the malleoli in Pott's fracture—and the same interference is measurably justified whenever an ecchymosis appears upon a limb that has not been directly contused.

Large blebs, the serum of which is often dark, frequently appear upon the leg a day or two after its fracture; less frequently upon other limbs. The cause of their production is not known.

In fractures communicating with joints a characteristic deformity is caused by the filling of the cavity of the joint with blood or an inflammatory effusion, the situation of which is shown by its limitation within the boundaries of the articular capsule.

Abnormal Mobility. Mobility appearing after injury at a point in a

bone where it did not previously exist, and permitting the bone to be bent at an angle, or a portion of it to be moved while the other portion remains at rest, is pathognomonic of fracture, but it is not always present or recognizable, for the fracture may be incomplete or too near a joint, or one of the fragments may be too small or too deeply placed to be grasped. In fracture of the ribs, sternum, or fibula the elasticity of the bone may deceive if not taken into consideration, or raise a doubt if it is.

The manipulations employed for the detection of abnormal mobility vary with the seat of fracture and the kind of mobility which is sought to be produced. In fracture of the shaft of a long bone the surgeon seeks first to produce an angular displacement by passing his hand under the limb at the supposed seat of fracture and gently raising it, or by grasping the two extremities of the bone firmly and moving the lower one slightly from side to side while the upper one is held stationary. Or he may grasp the limb with both hands close to the fracture, and produce transverse displacement by moving the fragments bodily in opposite directions. In fracture of the shaft of the fibula, radius, or ulna lateral mobility may be detected by grasping the limb with both hands above and below the fracture, and then making pressure alternately against the bone.

In fracture of the upper portion of the shaft of the femur or of the neck of the humerus or of the upper end of the tibia, where a lateral or angular mobility cannot be easily recognized, recourse may be had to slight rotatory movements of the lower portions of the limb, while the upper portion is so held that its bony prominences can be distinctly felt by the fingers. Abnormal mobility is then recognized by the failure of the manipulation to transmit the rotatory movements to the upper fragment. It is essential that the communicated movements should be slight, for otherwise the attachments of the soft parts or the interlocking of the fragments may prevent the success of the manœuvre, which, moreover, for obvious reasons, must fail in partial or impacted fractures.

In fracture of either condyle of the femur or humerus, or in fracture of an apophysis, the surgeon must try to grasp the fragment firmly and move it in the direction of the plane of fracture.

It is sometimes possible to give a fragment a tipping or see-saw motion; thus, by pressing the tip of the external malleolus inward, when the fibula has been broken just above the ankle, the upper end of the lower fragment may sometimes be felt to move outward. In this manipulation the sliding of the skin is liable to be mistaken for movement of the bone, and should be guarded against by pressing the fingers toward each other so as to relax the skin between them.

Crepitus. This is the sound produced, or the sensation communicated to the hand of the surgeon, by the friction of the fragments of a broken bone against each other. It is as pathognomonic of fracture as is abnormal mobility, and these two signs usually coexist. The sensation is not the same in all cases; it may be the sharp click of two hard points or edges, or a dull, muffled contact, or the crackling and grating of multiple fragments and broad surfaces. Some of its forms

are practically identical with the friction sounds obtained by the movement of joints whose surfaces are altered by disease, and although it is usual to speak of a recognizable difference in the quality of these sensations, the one being called *hard* or *rough*, the other *soft* or *smooth*, the diagnosis in cases of doubt must depend upon circumstances other than this difference.

Crepitus is perceived through the hand rather than the ear, although sometimes it is audible to bystanders not in contact with the patient. It is to be sought by the same methods as abnormal mobility, and also in the ribs and flat bones by placing the palm of the hand over the supposed seat of fracture and pressing gently in various directions. Direct auscultation is sometimes employed, especially in fracture of the ribs or sternum.

Crepitus cannot always be produced when there is a fracture, for its production is conditioned upon the contact and, in a measure, the character, of the broken surfaces. If the fragments are completely separated, if a piece of muscle or fascia is interposed between them, or if they have become covered with granulations, their movements may not cause crepitus, and it is a common experience that the manipulation which produces it at one moment fails to produce it at the next.

Auscultatory percussion, the stethoscope being moved from one fragment to the other while percussion is made upon the first, will sometimes give a marked change in the sound as the line of fracture is crossed; but it is rarely significant, except in cases in which the diagnosis can be made by other means.

Conditions giving rise to sensations that may be mistaken for crepitus are: Roughness of neighboring joints, inflammation of the sheaths of tendons or of bursae, and the crackling of coagulated blood.

By the use of the *x*-rays, aided by the fluoroscope or photography, many fractures can be recognized in detail. Thus far, in my experience, the rays have rarely given practically important information in fractures which could not be obtained without their aid, but they often disclose interesting details and sometimes are of great value.

Subjective or Rational Symptoms.

Loss of function of the limb or part involved is a common result of fracture, and is due either to mechanical causes, such as the breaking of the lever through which the muscles act, or to the inhibitory effect of pain or the fear of pain. As pain due to other causes may have the same effect, and as the loss after some fractures, even of the main bone of a limb, may be at first slight, the presence or the absence of the symptom is only suggestive, not indicative, of the presence or absence of fracture. In most cases of fracture of a long bone the limb is practically helpless, but from time to time we meet with patients who can move it with some freedom or who can walk with a broken ankle, leg, or even thigh.

Pain, spontaneous or on pressure upon, or movement of, the broken bone, is a constant accompaniment of fracture. Spontaneous pain

when the part is at rest is usually slight, not distinctly limited to the seat of injury, and not significant; but localized pain on pressure, on movement of the bone, and on pressing the fragments together is a valuable symptom, and in some cases the most positive one that can be obtained, and sufficient in itself for a diagnosis. It is to be sought for by pressure with the tip of the finger along the line of the bone, by pressing one end of the bone toward the other, or, more rarely, by gentle lateral or rotatory movements communicated to the lower portion of the limb while the upper is fixed, or by making the patient contract a muscle attached to the bone while its movement is opposed, as in fracture of the calcaneum or olecranon. It is of great diagnostic importance in absence of the positive signs, and is therefore specially valuable in many fractures near the end of a bone and in those of the metacarpals and metatarsals and ribs, and its absence is often a positive means of excluding fracture.

The absence of pain on handling an important fracture, such as one of the leg or thigh, deserves attention as possibly indicative of central nervous disease or of commencing delirium tremens.

The history, with reference to diagnosis, includes earlier injuries which may have modified the form of the limb, the nature of the accident, and the manner in which the force was applied, the interference with function, and occasionally the snap heard at the time and the distortion of the limb observed. A knowledge of the manner in which the violence was applied is sometimes of value in determining obscure points, and, in the absence of positive information, indications may be gathered from the position of contusions or of stains made by contact with the ground. The account given by the patient must always be received with distrust, because of his preoccupation by other circumstances at the moment of the accident and of the tendency to substitute inference for observation.

Such are the facts upon which the diagnosis is made. They are not all present in every case, and it is never necessary to seek for them all; deformity, abnormal mobility, and crepitus are alone absolutely pathognomonic, but in not a few fractures none of these can be recognized by manipulations that are not unduly severe, and the diagnosis must be made upon the history and localized pain. It is important that this should be borne in mind, for many a fracture has been overlooked because crepitus could not be got. The character of the injury is sometimes so apparent that it can be recognized at a glance; in others so obscure that even the most careful and experienced observer may remain in doubt. In most cases the examination should be made systematically and thoroughly, beginning with the history and following with an investigation of the interference with function, the pain, the deformity, and the abnormal mobility and crepitus in that order.

The clothing should be removed from the injured part, and in doubtful cases also from the opposite limb. After having noted such changes in appearance as are easily recognizable, the surgeon makes gentle pressure with his fingers along the limb in search of the point of maximum tenderness and of irregularity of outline if the bone is subcutaneous, and when that has been found he seeks evidence of abnormal mobility

at that point by one of the manipulations above mentioned. If the search is successful the diagnosis is made. If not, or if the injury is at a point where abnormal mobility is not recognizable, the surgeon seeks for such deformity as is likely to exist after such a fracture as is suspected, first inquiring whether the region has been previously injured, in order that he may not mistake an old deformity for a fresh one, and the pain of a sprain for that of a fracture.

If neither abnormal mobility nor deformity can be recognized he tests for local pain by pressure in the long axis of the bone or by the action of attached muscles, and accepts pain thus aroused as indicative of the presence of a variety of fracture which may not give the signs that are lacking.

If doubt still remains as to the existence of a fracture, and if the search for signs is hampered by the pain that the necessary manipulations cause, or if, a fracture having been proved, it is necessary to determine its details, he employs an anæsthetic after having made his preparations to utilize the anæsthesia for the reduction of displacements and the application of a dressing.

The compound character of a fracture is easily determined. In fractures by indirect violence the wound in the skin, close to the seat of fracture, is usually small and bleeds much more freely than a simple wound of the skin would; in fractures by direct violence the tegumentary wound is usually large and ragged, and the broken ends of the bones can be seen or felt through it. It is not necessary positively to determine the existence of direct communication between the fracture and the external wound; the coexistence of the two is sufficient to make imperative the employment of every precaution against infection that would be called for if such communication were known to exist. If the wound is explored at all, it should be done only as a part of the treatment, and with strict asepsis, not merely as a diagnostic measure.

Roentgen Rays.—In obscure cases, in fractures of the small bones, and to determine details in those in the neighborhood of or directly involving joints, the *x*-rays may be of use and sometimes of great value. Errors of interpretation are, however, frequent. It must be borne in mind that the skiagram is the reproduction only of a shadow, and that the apparent modeling of the surface of the bone shown in it is the result of differences of opacity and is often misleading. The elements of the shadow are distorted by differences in the relative distances of the various parts from the plate and in the angle of the rays, and because of the absence of perspective these distances are not indicated. There are many elements of error in a skiagram, many possibilities of misinterpretation, which must be controlled by experience in the use of the rays and by digital examination of the part. I have recently seen a case clinically diagnosed as fracture of the upper third of the femur, but the skiagram of which was thought by all to show a fracture at the base of the neck. The autopsy proved the correctness of the clinical opinion. The skiagraphic error was due to tilting of the upper fragment. An additional difficulty is caused in children by the permeability of cartilage to the rays, in consequence of which large gaps

corresponding to the cartilaginous epiphysis appear at the joints. Except for well-defined changes in outline of a single bone a skiagram cannot safely be taken as proof of all it seems to show, but needs to be interpreted by the aid of clinical findings and of considerable experience in its use. Particularly, I think, do we need to be upon our guard against assuming that dark lines across spongy bone always indicate lines of fracture. Stereoscopic views are, of course, more trustworthy than single ones, but they are not often available.

CHAPTER V.

THE REPAIR OF FRACTURES AND THE CLINICAL COURSE.

Anatomo-pathological Processes.

The Callus. Bone is one of those tissues whose cicatrices are composed of a substance closely resembling, or identical with, the original tissue. The process of repair after fracture is fundamentally the same as that after other forms of injury, and its histological phenomena, like those of repair of other tissues, are those of normal growth and exaggerated nutrition. It begins with the enlargement and multiplication of the cells of the periosteum, marrow, Haversian canals, and lacunæ; this multiplication produces a mass of granulations which fill the gap between the fragments and are transformed into bone, sometimes directly, sometimes after having passed through a cartilaginous stage. This mass of new bone, at first spongy in its structure—that is, composed of irregular lamellæ or plates circumscribing relatively large lacunæ filled with bloodvessels and medullary elements—becomes firmer and more compact in some portions by increase in thickness of the lamellæ and consequent reduction in size of the lacunæ—the process known as “condensing osteitis,” and observed constantly in the fetus as well as in many pathological conditions—and becomes thinner and weaker in other portions until it finally disappears by the converse process, diminution of the lamellæ through their absorption by the medullary elements of the lacunæ, “rarefying osteitis,” another stage of productive or simple osteitis and also found in the normal development of bone and in pathological conditions. The variations depend upon differences in the degree of the injury or in the position of the fragments, which require disproportionate amounts of work to be done by the different parts. The details of the process will appear upon examination of the manner in which it is carried on after simple fracture of the shaft of a long bone, an example which has the advantage of illustrating the behavior of all the different elements and of being both more complete and more open to experimental study than fractures of short bones or of the spongy extremities of long ones.

When a fracture takes place the cylindrical shell is broken along an irregular line and probably always with the production of splinters of greater or less size. The periosteum is usually torn, but the extent of its rupture has probably been largely overestimated even when there is much displacement of the fragments. Ollier¹ was the first to call especial attention to the preservation of its continuity at some part of the periphery of the bone and to the fact that when a lateral or longitudinal displacement has occurred the membrane is stripped partly

¹ Ollier: *Traité de la Régénération des Os.*

off one fragment, but without having its continuity broken, and thus forms a band uniting the two fragments. To this band he gave the name of "periosteal bridge." Other portions, also, which do not preserve their continuity with the rest, are doubtless stripped off the fragments, as can be seen in compound fractures, and as they are structurally continuous with the overlying soft parts they probably come quite accurately into place when the displacement is corrected, and thus form a fairly complete tubular sheath connecting the ends of the fragments and all splinters except those which are entirely loose, guiding and limiting the formation of the new tissue that is to establish the ultimate union. When this sheath is not complete, because of persisting displacement, the existence of the periosteal bridge is of extreme importance, because it maintains the connection between the fragments by means of a tissue whose activity in the production of bone is marked. The position and form of the callus in specimens of union with displacement indicate clearly the position and agency of the bridge, and Plate III. shows the ossification on the inner surface of the bridge, but not complete throughout the interval between it and the surface of the bone.

At the same time blood is poured out from the torn vessels of the bone into the gap between the fragments and from the vessels of the soft parts into the interstices among the muscles. This blood is gradually absorbed during the first few days following the receipt of the injury, and at the same time the effects of the traumatism are manifested in the inflammatory oedema of the limb and the infiltration of a thick viscid liquid into the soft tissues immediately adjoining the seat of the fracture, the beginning of the firm ovoid mass which can always be felt at this point. The periosteum becomes much thicker, softer, and more vascular; a thin layer of gelatinous or viscid liquid is found between it and the bone for a distance of a few lines from the edge of the fracture or from the point to which the membrane has been stripped up, and at the more distant limit of this layer the surface of the bone promptly become roughened by the formation of patches of new bone. The portions of the periosteum which have been stripped off, those which form complete or incomplete bridges, and the lacerated tissues which form the wall of the cavity in which the ends of the bone lie, granulate and pour out an exudate to mingle with the remaining blood.

The marrow shares in this production of granulations, and the cells of the connective tissue external to the periosteum share for a greater or less distance in the irritation, and by their proliferation bind together all the adjoining parts in one firm, compact mass. The compact layer of bone, the cylindrical shell of the shaft, feels the same influence and reacts in the same manner, but much more slowly in consequence of the scantiness of its cellular elements. Its outer and broken surfaces soon show pink points which enlarge and send out granulations to join those already produced by the periosteum and marrow, and thus there is formed between the separated fragments a bond of union which is actually continuous, almost from the beginning, with all their constituent parts. The size and character of this bond vary

with the degree of displacement; if the fragments remain nearly in their original relations to each other, the bond is short and symmetrical, the granulations springing from the marrow meet and unite in the centre of the gap, while the thickened periosteum passes from one fragment directly to the other, remaining adherent to them or separated only by a layer of effused blood. If lateral displacement occurs and persists, the bond passes obliquely from the outer surface of one fragment to that of the other, and is much more complete at some points of the periphery than at others. Thus, in Fig. 25, which represents the condition on the seventh day, the firmest union is by the cartilaginous band crossing the angle at *b* and formed apparently by the thickening of a periosteal bridge. On the opposite side of the lower fragment the beginning of an incomplete band of similar structure is seen.

The formative action thus begun is rapidly carried on, and principally by the periosteum and marrow. When the fragments are kept end to end an ovoid mass of tissue, having the consistency of jelly and a pearly white appearance, and continuous above and below with the periosteum, envelops them, the so-called "provisional" or "ensheathing" callus. This mass is formed not solely by granulations springing from the under side of the periosteum, but also by the thickening of that membrane and of the connective tissue on the outer side, including that which surrounds the adjoining muscular bundles, and according to Cornil and Coudray,¹ even the cells of the sarcolemma. Composed at first of embryonal elements, it soon becomes cartilaginous in the portions formed by the periosteum; then lime salts are deposited at different points within it, and finally it is transformed into bone.

The granulations that spring from the marrow ossify without passing through the cartilaginous stage, and the process here apparently begins at the fine lamellæ which lie upon the inner side of the compact shell. The new lamellæ extend across the canal, soon occluding it entirely, and also out into the interval to meet those coming from the other fragment. Thus is formed the internal or medullary plug.

The granulations occupying the annular interval between the cortical layers of the two fragments (when the reduction is complete) apparently come mainly from the periosteum and pass through a cartilaginous stage before becoming bone, as do the others that have the same origin. They unite promptly with those of the medullary plug and ultimately (sometimes after a long delay) with the cortical layer. It was to this part of the callus that Dupuytren gave the name of "definitive callus." The cause of the delay in union with the cortical layer lies in the slowness with which the latter forms the granulations necessary to unite with the others, and doubtless to the occasional long persistence of a

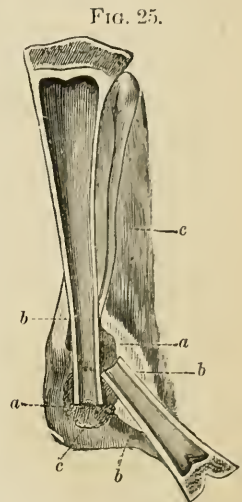


FIG. 25.
Tibia of rabbit. Seventh day: *a*, blood; *b*, cartilaginous callus; *c*, muscles. (GURLT.)

¹ Cornil and Coudray, *Revue de Chir.*, 24th year, No. 7.

necrotic scale of bone on its broken surface, which has to be slowly penetrated and absorbed by the granulations. The cellular elements of the cortex, which have to do the work of enlarging the Haversian canals and forming the granulations, are scanty, and those immediately adjoining the broken surface cannot share in the work because their blood-supply is cut off by the clotting of the blood in the torn capillaries. The cells situated a little more deeply have to carry on the work and slowly break through the intermediate necrotic scale before they can meet and unite with the other granulations that have spread into the interval from without and within. This process in the compact tissue is the usual rarefying osteitis, characterized by an enlargement of the Haversian canals and a corresponding loss of the bone tissue, a change, in short, which transforms the cortex for a certain distance into spongy tissue like that of the ossifying callus. Ultimately the rarefaction ceases and a "productive" or "condensing" osteitis follows, by which the lamellæ are thickened and the intermediate spaces and canals contracted until the former proportions between them are measurably restored. Occasionally the ossification spreads into ligaments and tendons attached to the bone close by the fracture.

While the callus is thus forming and ossifying, the irritation in the adjoining soft parts subsides, and they regain their original condition and functions more or less completely. Occasionally the associated injuries of muscles or tendons or the sheaths of the latter lead to permanent disabling adhesions.

After the ossification of the callus has been completed the excess on its exterior and even projecting portions of fragments slowly disappear, and in cases in which the reduction of the displacements has been exact this disappearance of the exterior callus may go so far as to leave little or no trace on the surface of its previous existence. In like manner the central plug diminishes and the medullary canal may be restored.

Fragments of the cortical layer broken off at the time of the injury may remain attached to the periosteum, preserve their vitality, share in the same processes, and form a part, often an important one, of the callus. There is reason to believe also that even after they have been entirely detached they may form new connections with the soft parts and granulations, and preserve (or renew) their life. Such fragments have been found embedded so deeply in a callus that no other explanation than that of complete detachment can well be accepted. Howship describes and figures one, and Gurlt another and remarkable one (Fig. 26). The possibility of this preservation has also been established by experiment upon animals. Portions of the shaft have been chiselled off, separated entirely from the soft parts, and replaced in contact with the bone; examination after the lapse of some weeks showed re-establishment of vascular connection.

It is also known that fragments may long remain without vascular connection embedded in a callus as well-tolerated foreign bodies. After the lapse of months, or even years, and from unknown causes, they may cause irritation; an abscess forms, the bone softens about them, and either they are cast out spontaneously or they remain, provoking an interminable suppuration, until removed.

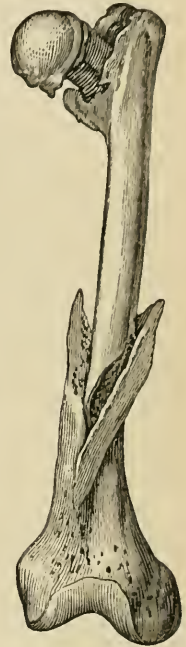It occasionally happens that the callus does not ossify, and in some very exceptional cases the bone is entirely absorbed for a considerable distance on each side of the seat of fracture. The causes are not fully understood. The difference in the process consists in an entire or partial absence of productive osteitis and in an excess of the rarefying osteitis. The latter, I am convinced, is favored by the presence of a metallic suture in the bone.

When the fracture is **compound**, and remains so, the details of the reparative process are different to this extent: that the callus does not pass through the preliminary cartilaginous stage at any point where suppuration has occurred. The formation of the medullary plug is not affected, the granulations there being transformed directly into bone as they are in simple fractures; the difference is in the external or ensheathing callus. The reason of this difference, as shown by experiment,¹ lies in the destruction of the periosteum by the suppurative process, in the destruction, that is, of the only tissue whose granulations pass through the cartilaginous stage in forming the callus.

The process is slower than after a simple fracture because the suppuration of the wound delays or prevents the formation of much of the external callus and throws most of the labor upon the bone itself, which, as has been shown, is the least able to do it. It is easy to watch the process. The ends of the bone are seen lying bare and white in the wound; a mass of pink granulations forms at the limit of the denudation and advances slowly across the bared surface; the broken surface remains for a time quiescent, then granulations spring from it, beginning at the points nearest the medullary canal and spreading slowly toward the outer edge; the wound gradually fills up with these granulations, the bone is covered in, and cicatrization follows.

In less fortunate cases a portion of the bared bone dies and is cast off by the formation of a line of demarcation which can sometimes be seen at the edge of the granulations, but which more commonly is hidden by them. It must not be thought that all the bare white bone seen in such a wound is dead; even after it has remained unchanged in appearance for several weeks. Its surface may, indeed, be dead, but the interior is often alive and able to cast off the dead superficial scale without aid. The granulations which form between the living and the dead parts seem

FIG. 26.



Fracture of the neck of the femur and of the shaft. A splinter 5 inches long and nearly 1 inch wide, composed of the cortical layer, has been turned completely about its long axis and become united, with its original periosteal surface in contact with the other fragments. (Figured by GURLT from the Museum of the Royal College of Surgeons, England, No. 454.)

¹ Rigal and Vignal: *Comptes-Rendus de l'Académie des Sciences*, 1880, vol. xc. p. 1218.

sometimes to dissolve and absorb the latter if they are small and thin, or, if not, slowly to bear them to the surface and cast them out.

The callus thus formed is larger and more irregular than after simple fracture; it remains tender and sensitive for a long time, and is covered by an adherent scar at the seat of the wound. Fragments formed at the time of the accident and remaining attached to the periosteum usually preserve their vitality; if not, they become detached after a time and are found loose in the wound, or become shut in by the callus and prolong the suppuration indefinitely. In this latter case the constant irritation due to the presence of the foreign body, the existence of sinuses, and the burrowing of the pus interfere with the evolution of the callus. Instead of undergoing a gradual and uniform diminution and condensation, it becomes eburnated at some points and entirely absorbed at others, irregular prominences appear on its surface or follow the lines of attached tendons and fasciæ, and its interior is occupied by cavities of various sizes usually suppurating and in communication with the exterior.

In the **spongy bones** and the spongy ends of the long bones less of the work of repair is done by the periosteum and more by the bone itself, for the periosteum is so interrupted by attached tendons and ligaments that it is less freely stripped up, and the bone surfaces are broadly in contact and, being spongy, are ready at once to form granulations without preliminary rarefaction.

In fractures involving **joint-surfaces** the absence of periosteum and other soft tissues on the articular surface prevents the formation of an external callus on that side, and union takes place by granulations arising directly from the fractured surfaces and by an external callus at the extra-articular parts of the fracture. The line of the fracture on the articular surface is marked by the absence of cartilage over it, and usually by a groove. The fracture of the cartilage does not heal by the formation of new cartilage; usually the callus is covered at this point by a firm white layer of fibrous tissue, but sometimes the bone is bare. In exceptional cases the callus is exuberant and grows out beyond the level of the cartilage, forming an irregular mass in place of the usual groove.

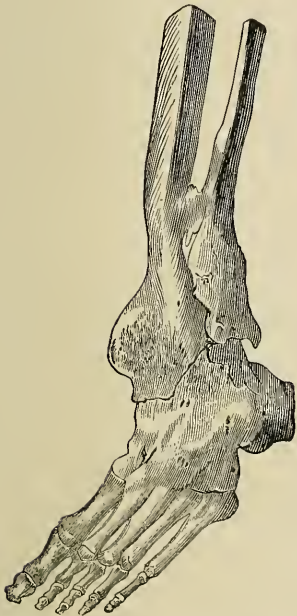
Fracture of **cartilage** (costal cartilage, larynx, etc.) is repaired partly by a fibrous, rarely a cartilaginous, band between the fragments, and partly by a bony peripheral callus. (See Chapter XVI.)

Exuberance of the callus, both external and intermediate, is a frequent cause of diminution of the functions of the joint by destroying the normal relations of the articular surfaces, by filling up normal depressions, and by creating abnormal prominences. These results are usually beyond the control of the surgeon, and the latter are most common in the young, whose power of producing bone is greatest. Occasionally the productive process excited by the fracture extends far beyond the limits of the latter, and not only may the joint itself be obliterated by fusion of the bones which constitute it, but the process may also spread to and produce the same result in neighboring joints as in the case represented in Fig. 27.

Bones which lie parallel and close to each other, as those of the fore-

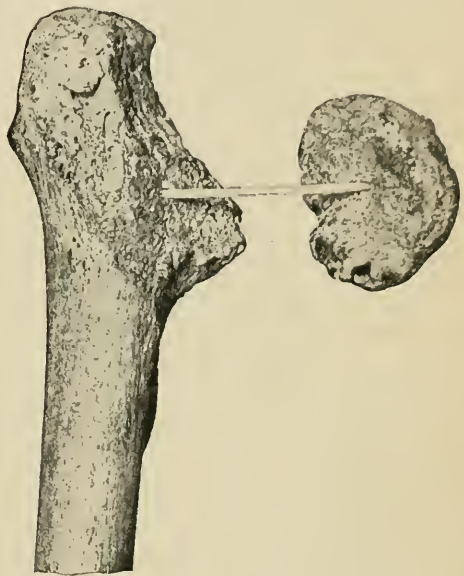
arm and leg and the ribs, may become united by an exuberant callus when either one or both are broken. This consolidation is most likely to occur when both bones are broken at the same level, and when displacement of one or more of the fragments diminishes the normal interval between them. The mass of granulations developed about one fracture becomes continuous with that developed about the other, and ossification follows. The presence of an interosseous membrane favors this result, for this tissue has the same tendency to ossify that is shown

FIG. 27.



Bony ankylosis of the foot and ankle after fracture of the leg. (GURLT.)

FIG. 28.



Absorption of the neck of the femur after fracture.

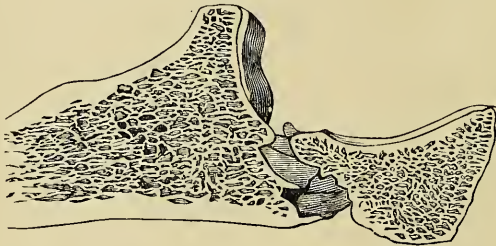
by other white fibrous tissue in the presence of a productive osteitis. The effect of this consolidation is, of course, to prevent independent motion of the two bones, and while of no importance in the leg and of little, if any, in the ribs, it produces a very serious disability in the forearm by abolishing pronation and supination. It occasionally happens, when two bones are broken at the same level, that the calluses grow into contact with each other but do not unite. Their adjoining surfaces are smooth and together form a sort of lateral joint which may allow movement of one upon the other.

When the line of fracture follows that of a still existing epiphyseal cartilage, either wholly or in part, and the fragments are not displaced, union apparently takes place as readily as after simple fracture, but nothing positive is known of the details of the process. The injury does not necessarily interfere with the subsequent growth of the bone; the layer of cartilage may remain unossified and perform its functions

as before ; but it is known from the results of experiments upon animals, and from cases of inflammatory disease and from some of traumatic separation without displacement, that the effect of irritation of the epiphyseal cartilage is sometimes to hasten its ossification, and thus arrest the growth of the limb. This last result must certainly be produced when the epiphysis is dislocated by the fracture and is not restored to its place.

Finally, failure of union after fracture may be due to arrest of the reparative process in the granulation stage, ossification not taking place and the bond between the fragments remaining fibrous, or to the wide separation of the fragments, or to the interposition of a bundle of muscular tissue, or to the insufficiency of the blood-supply of one of the fragments. This condition, especially as seen after fracture of

FIG. 29.



Fracture of the olecranon : fibrous union. (MALGAIGNE.)

the shaft of a long bone, is considered in detail in Chapter VIII., Pseudarthrosis. Examples at other points than the shaft are furnished especially by the patella and olecranon (direct longitudinal separation), and by some fractures of the neck of the femur where the cause lies in an excess of the rarefying process, by which the neck is destroyed, or in the cutting off of the blood-supply by complete rupture of the periosteum of the neck which carries vessels to the head.

Clinical Course.

This varies with the position and character of the fracture and especially with the complications arising from the peculiarities of the fracture and the health and age of the patient. Ordinarily, in simple cases, after the primary reaction of the injury has subsided and an appropriate treatment has been established, the patient goes on to recovery without pain, fever, or other disturbance of his general health, and incommodes only by the disability of the limb and the confinement to which he is subjected. But in the alcoholic this tranquil course may be promptly interrupted by the onset of a pneumonia or an attack of delirium tremens; and in the old, confined to bed by a broken thigh or leg, the primary shock may be sufficient to cause death in the first few days, or the general health may begin to suffer about the third week, and death follow after a short interval marked by symptoms of hypostatic pneumonia or mild delirium and gradual failing of the strength. And very, very rarely, even in simple cases

and without the slightest warning, death may come suddenly in the first few days by fat embolism of the lungs, or at a later period by a cardiac pulmonary embolus detached from a thrombus in some large vein.

For the first day or two the patient may suffer pain at and near the fracture, augmented by muscular twitchings, and considerable discomfort from the weight and tension of the swollen limb; and if the bone is a large one (thigh, leg, arm) and the fright and emotion at the time of the accident extreme, the symptoms of shock may be well marked.

The temperature usually shows a rise of from one to two degrees Fahrenheit, "aseptic" fever, which promptly diminishes, and disappears within a few days. At the same time the urine may contain a small amount of albumin and free fat and hyaline casts enclosing brown granules. The fat, which is sometimes sufficient to form a distinct layer on the surface after standing, is thought to come from the crushed marrow of the bone, and the variations in its quality and the time of appearance to depend upon its temporary arrest in the pulmonary capillaries (fat embolism, *q. v.*). The brown casts are sometimes very numerous, but more often are wholly lacking.

The limb swells, partly because of extravasated blood and shortening, but mainly by œdema; the swelling reaches its maximum on the second or third day and then slowly subsides. The skin of the involved region shows a yellowish tinge, the result of staining with the coloring matter of the extravasated blood, and ecchymoses appear at points below and sometimes above the fracture. Larger or smaller blebs appear, especially on the legs, by the second or third day, and may interfere with the early application of a fixed dressing.

As the swelling subsides a firm ovoid mass becomes recognizable, extending above and below the fracture, and the sensitiveness on pressure diminishes; this mass diminishes in size and increases in firmness as time passes, the abnormal mobility diminishes, and finally, after a length of time which varies greatly in different cases, ceases, and union is then effected, although not so firm as it will ultimately become after ossification shall have been completed. A small, hard mass can still be felt at the seat of fracture which will slowly diminish for months, perhaps for years.

Other things being equal, and bone for bone, less time is required to complete repair in children than in adults; and fractures heal as rapidly in one sex as in the other, and in the old as rapidly as in the middle-aged. As a general rule, too, the larger the bone the longer the time required, and fractures of the shaft require more time than those of the spongy ends, and those with uncorrected displacement more than those in which the normal relations have been maintained or restored. The average for fractures of the shaft of the long bones in adults varies from four weeks for the clavicle or forearm to eight or nine weeks for the thigh.

But with the union of the fracture the recovery of the patient, especially after fractures of the limbs, is not yet complete. The circulation of the part, the skin, the muscles, and the neighboring joints have yet to recover from the disabilities imposed upon them by the primary injury or by the prolonged disuse of the limb. The skin is harsh and dry; the limb swells and shows venous congestion when used, and

especially when dependent, presumably because of plugging of the veins and possibly because of rupture of lymphatic channels; the joints are swollen, stiff, and sensitive. As a rule, all these features disappear under use, and more rapidly in the young than in the old, but occasionally some of them persist for a long time.

The course of the case, as thus sketched, may be greatly modified by exceptional severity of the injury, by associated lesions, or by a wound or contusion which makes the fracture compound either immediately or after the lapse of a few days. In the severe cases, with more splintering of the bone and laceration of the soft parts, the pain, swelling, and general and local reaction are greater and more prolonged, but very rarely end in suppuration.

The direct implication of a joint in a fracture, or the spread to it of the neighboring reaction, or the presence of a concomitant sprain, as is so often seen at the knee in fractures of the thigh, adds an arthritis which increases the pain and discomfort, and may delay recovery or diminish its completeness.

In compound fractures with a small, clean wound it has seemed to me that the local and general reaction is even less than in simple fracture, presumably because the extravasated blood escapes through the wound, with consequently less tension and less absorption of fibrin-ferments to cause fever. Under appropriate treatment such a wound heals in a few days, and the course is thenceforth that of a simple fracture.

In compound fractures with bruising of the skin that prevents primary union of the wound, and in those made compound by the sloughing of the bruised skin, the course may be very different. It is that of a deep, lacerated wound, from whose walls sloughs must be cast off, and in which suppuration is inevitable and serious infection possible. In the milder forms the suppuration is slight and limited to the superficial portions of the wound, and the course is practically that of a simple fracture with only the delay due to tardier union of the bone and cicatrization of the wound. But in the severer forms all the local and general symptoms are more marked, the swelling is greater, the fever higher and persistent. If treatment fails to overcome the infection the pus burrows amid the muscles, neighboring abscesses form, with chills and exacerbation of the fever, and amputation may be indicated to save the imperiled life. Or, by counter-openings, drainage, and the free use of antiseptics, the suppuration may be brought under control, and then the patient pursues his weary course toward convalescence through the pains and perils of the slow casting off of necrotic fragments of the bone and the tardy formation and ossification of the granulations that must take their place. Such cases are often despairingly slow in reaching solid union and closure of the sinuses, and still longer in regaining use of the limb. The callus is large, the cicatrix adherent and sensitive, the adjoining muscles hampered by adhesions. The condensation of the callus is liable to become extreme in portions, because of the prolongation of the irritation, and thereby to cause partial necroses which prolong or renew the suppuration in the efforts to cast them out, so that the sinuses may persist intermittently for years with longer or shorter interruptions.

CHAPTER VI.

COMPLICATIONS AND REMOTE CONSEQUENCES.

Early Local Complications: Skin, bloodvessels, gangrene, degeneration of muscles, suppuration. **Early General Complications:** Septicæmia, fat embolism, delirium tremens, tetanus, pneumonia. **Late Local Complications:** Excessive painful callus, tumor, injury of nerve, weak callus, arrest or exaggeration of growth, stiffness of joints, atrophy, thrombosis, and embolism.

THESE may be local or general, and the complications may be the direct and immediate result of the primary violence or the later result of the primary lesions, of infection, or of constitutional conditions. Some are peculiar to fractures, others may arise also in connection with other forms of injury.

Early Local Complications.

Skin. The sharp point of the upper main fragment may be forced through the overlying muscles and fascia and perforate the skin or become engaged in its deeper layers in such a way that its reduction is difficult, or it may make such pressure upon the unbroken skin that the latter will slough at the point of pressure in the course of a few days. The first condition may sometimes be corrected by traction upon the lower segment of the limb, but usually an incision will be necessary to effect a complete reduction of the displacement. If perforation has taken place the opening should be at once enlarged, for this does not add to the chance of infection, and greatly simplifies reduction.

Pressure upon the unbroken skin must be relieved by reduction, or at least by diminution of the displacement; and if this is not possible the bone should be exposed by incision and the projecting portion cut away, for such a wound can be so protected that it will heal promptly, while one made by sloughing will surely suppurate, and even if dangerous infection thereby of the seat of fracture is avoided, yet the wound will be slow to heal, and will leave an adherent and possibly sensitive scar.

The sloughing of the skin contused by the primary violence is rare except in connection with compound fracture—that is, violence which is sufficient to kill the skin generally breaks it. Theoretically, it would be well immediately to remove all skin and other tissues that have been thus killed, in order more surely to avoid infection; but the limits of such destruction cannot be determined with sufficient accuracy. A fairly accurate estimate of the probability of sloughing and its extent can be made by applying a rubber bandage tightly to the limb for a few minutes, as in producing artificial ischæmia for opera-

tion, and noting the areas which do not share in the blush following its removal. This test is fairly accurate except for areas of skin on the distal side of long transverse wounds; such generally remain pale, even if viable. The failure of blood to flow on minute puncture of the skin is also a fairly accurate indication of its death.

Bloodvessels. Rupture or serious bruising of the main vessels of a limb is a serious but infrequent complication. Among the more important vessels that have been thus injured in simple fracture are the middle meningeal and carotid arteries in fractures of the skull, the subclavian vein and artery, and the acromial branch of the acromio-thoracic artery in fractures of the clavicle, the brachial and axillary artery in fractures of the humerus, the popliteal artery and vein in those of the lower end of the femur, and the anterior tibial in those of the leg. In compound fractures the same vessels and also those lying at a greater distance from the bone may be injured.

The rupture of an artery in a simple fracture may lead to fatal hemorrhage, even if the vessel is a small one, in case the blood can escape into a large natural cavity, as in a unique case of fatal hemorrhage following rupture of a small branch of an intercostal artery after fracture of a rib;¹ but in a limb it leads either to the formation of a traumatic aneurism or to gangrene. The rupture may be immediate or it may occur after a few days by sloughing of the bruised vessel.

The symptoms are a rapidly increasing local swelling, which pulsates after it has ceased to increase, and (in the case of the main artery) absence of the pulse in its distal branches. Gangrene is more directly due to interference with the venous flow by the pressure of the swelling than to loss of arterial supply, and consequently appears in the "moist" form, characterized by swelling, duskiness, and coolness of the limb.

The object of early treatment is to check the hemorrhage and favor the venous flow by elevation of the limb, possibly combined with digital pressure upon the main trunk or with snug bandaging from the lower end of the limb to a point well above the injury. If a well-defined aneurism forms it may be treated, after union of the fracture has taken place or is well advanced, by proximal or local ligation of the artery. Possibly, if gangrene threatened, the limb might be saved by a free incision through which the escaped blood could be turned out, thus relieving the pressure on the veins, and by tying the artery.

In compound fractures the diagnosis is made by the profuseness and arterial character of the bleeding; and the treatment is to tie the artery at the point of injury.

Rupture of a large vein cannot be certainly recognized in a simple fracture, and its treatment is controlled by that of the gangrene which it may cause. In compound fractures the vessels may sometimes be seen and tied, but probably the associated lesions will be such that amputation will be indicated.

Thrombosis of an artery, and doubtless also of a vein, may be caused by the direct violence which causes a fracture. I have seen examples in the arteries of the arm and leg broken by the passage of a wheel, the condition being found on examination of the limb after amputation

¹ London Medical Times and Gazette, 1860, ii., p. 607.

because of gangrene, and others have been reported. Thrombosis of a vein may be caused by the pressure of a displaced fragment. A case involving the femoral vein and ending in gangrene and amputation is reported in the *Deutsche med. Wochenschrift*, June 8, 1892, p. 549.

Gangrene may be local or general: the former the result of crushing of the skin and other soft parts in direct fracture, the latter the result of injury to or compression of the vessels or of tight bandaging.

Local gangrene is manifested by the darkening and hardening of an area of skin surrounded by an inflammatory zone; the swelling and fever are more marked and persistent, and when the dry patch is split or cut away an abundant thin, pink or dark, and offensive exudate escapes from beneath it and from the adjoining subcutaneous and inter-muscular planes. The infection must be combatted by free removal of the dead and dying tissues, irrigation, and drainage. The danger of general infection is great, and amputation is often required to save life.

Gangrene of the limbs is usually of the moist form and begins with coolness and discoloration of the toes or fingers, the latter beginning as a deep-red color, and soon changing to purple and grayish-black. Dark blebs may appear on the surface, or the epidermis may be extensively but slightly raised by a thin, dark serum. If taken in time, and if the cause can be removed, as in tight bandaging, the life of the part may be preserved, and I have thought that keeping the limb in hot water (100° to 102° F.) was helpful; but the vitality of the skin is greater than that of the muscles, so that even if the circulation returns in the former the muscles may yet disintegrate and the limb be lost. I saw this result in a case of fracture of the olecranon which had been treated by the immediate application of a plaster-of-Paris dressing. The patient entered the hospital on the fifth day, with the uncovered hand black and swollen; the dressing was removed, and the limb placed in a hot bath. Two days later circulation was re-established in the skin of the hand and forearm, but a week later incisions had to be made in the forearm, through which the muscles appeared wholly disorganized and diffuent.

It must be borne in mind that even a narrow circular constriction, as by a band of adhesive plaster, is sufficient to produce this disastrous result, and is, perhaps, even more likely to do so than an equally tight bandage covering the limb. Consequently the longitudinal strips of plaster used in making traction should not be reinforced by the circular strips which are sometimes applied with the idea of keeping the former more securely in place.

Degeneration and contraction of the muscles, the result of arrested blood-supply by bandaging or injury to the arteries, is occasionally seen; it is a lower grade of the change mentioned in the preceding section. Volkmann, who first described it, gave it the name of "ischæmic contraction." It is most frequently seen in the forearm after fracture of the radius and ulna or supracondylar fracture of the humerus and is marked by atrophy and shortening of the muscles, the fingers being permanently flexed. This change is brought about by rapid degeneration of the muscular fibres and subsequent reactive increase and contraction of the connective tissue. It is to be distinguished from similar

contractures due to nerve injury or disease by its prompt appearance. In the less severe cases something may be gained by massage, electricity, and persistent efforts to straighten the fingers. Hildebrand,¹ who had noticed signs of involvement of the nerves, obtained partial relief in 3 cases by removing the nerve trunks from among the shrunken muscles and lodging them between the fascia and the skin. Kleinschmidt and Hoffa² got good results by excising about an inch of the radius and ulna, thus giving the flexor muscles adequate length.

Suppuration in simple fractures is very rare, and when it occurs it appears to be due to auto-infection, by germs carried by the blood and possibly brought from some suppurating focus in a distant portion of the body, as a furuncle; rough handling of the broken limb and neglect of proper care apparently favor its occurrence. It promptly makes the fracture compound by spontaneous or surgical opening, and the course and prognosis are then those of an open infected fracture.

Suppuration in compound fractures can generally be prevented or restricted to the superficial layers when the wound is small and its edges not contused, as is ordinarily the case in fractures by indirect violence. The later its appearance, the less likely is it to spread widely among the muscles and endanger life.

In compound fracture with bruising and extensive laceration, suppuration may remain as a local complication, the pus escaping freely to the exterior and the infection not spreading; the graver cases will be considered in the following section.

Early General Complications.

Septicæmia. This grave complication occurs in compound fractures and in simple ones followed by gangrene of the limb or suppuration at the seat of fracture. The most prompt, rapid, and fatal forms are seen in compound fractures accompanied by much bruising and laceration of the soft parts and in those patients whose vitality has been lowered by alcoholism, disease, or age.

A dusky-brown tinge discolors the skin about the wound and spreads rapidly upward, especially on the sides and back of the limb; the torn muscles become gray and less moist, an offensive odor appears and grows rapidly more marked, and a thin offensive discharge escapes at the surface of the wound and can be pressed out from its recesses. The limb swells far above the fracture, the temperature rises, the patient becomes apathetic and slightly delirious. Occasionally pressure with the fingers upon the discolored skin provokes the slight crackle of emphysema, evidence of decomposition with production of gas, and, if well marked, strongly suggestive of the presence of one of the most rapidly fatal infections known, that of the "vibrion septique" of Pasteur, or the bacillus capsulatus aërogenes (Welch), the germ of acute gangrenous septicæmia.

Amputation alone, with vigorous disinfection of the stump and of the subcutaneous tissue throughout the discolored area, can save life, and that only in so small a proportion of the cases that no one can be blamed for declining to resort to it. The peroxide of hydrogen appears to be a valuable antiseptic in these cases; it can be forced under the

¹ Hildebrand: *Sammlung klin. Vorträge*, 1906. Chir. No. 122.

² Kleinschmidt and Hoffa: *Zentralblatt für Chir.*, 1907, p. 81.

skin with a syringe or through incisions which will serve also for drainage. I have known only two in which the septic vibrio was present to recover; in a few cases in which the early symptoms indicated its presence I have changed the diagnosis because the patient did not fail so rapidly as I anticipated, and in every such case culture tests have shown its absence. Air which occasionally makes its way through the wound into the adjoining cellular tissue must not be mistaken for the gas of this decomposition.

In the less acute cases septic infection follows the establishment of suppuration and is less marked locally and generally. The limb swells and becomes discolored, but the color is a dusky red and its area is limited; the swelling is more like the common inflammatory bogginess, and incisions into it give exit to pus or inflammatory serum which has not the odor of decomposition. Such processes may be arrested by free incisions, drainage, and antiseptics; but complete recovery is long delayed by necrosis of the ends of the fragments.

Fat Embolism. As has been stated in Chapter III., free fat can frequently be found in the urine during the first two or three days after fracture. It is reasonable to suppose that it comes from the lacerated marrow, entering the circulation either directly through the torn and gaping veins of the bone or through the lymphatics. When thus taken up in considerable quantities it may be arrested in the pulmonary capillaries or, after having passed through those, in the capillaries of the systemic circulation, and occasion serious symptoms or even death. Although the subject has been studied by several, by observation and experiment, since Von Recklinghausen first noted it in 1884 as a cause of death by plugging the pulmonary capillaries, its symptomatology is not at all clear, presumably because it is masked by the functional disturbances created by its interference with the circulation in various organs, notably the brain. There is even reason to think that it has something, perhaps much, to do in some cases with the phenomena classed as shock, with delirium tremens, which is so much more common after fractures than after other injuries, and with the pulmonary œdema and early pneumonias of the alcoholic and aged.

The pathological conditions revealed on autopsy are œdema of the lungs and extensive plugging of the pulmonary capillaries, and sometimes even of the arterioles, with free fat, similar but less extensive plugging of the systemic capillaries, often marked by small hemorrhages, and sometimes extensive filling of the renal glomeruli. The local reaction is that of the beginning of infarction, and probably in the cases which survive it is arrested by the prompt forcing of the fat through the capillaries and the re-establishment of the circulation. Since the emboli are not septic the element of infection does not enter into the case, and death is due to the mechanical interference with the nutrition and functions of the parts involved.

The symptoms in well-defined cases confirmed by autopsy have begun within twenty-four hours after the injury, rarely after two or three days, and usually with quickening of the respiration that sometimes became marked dyspnœa; undiminished resonance of the chest

and abundant, coarse râles ; little or no fever ; face at first pale, then cyanotic ; unconsciousness followed, and death within a few hours. In other cases the central nervous symptoms have been the most prominent: unconsciousness, noisy and slow breathing, muscular twitching, and even convulsions, and sometimes paralyses. Most tragical are those cases, fortunately very rare, in which the complication proves rapidly fatal in a young and healthy patient after a simple, comparatively unimportant fracture, such as a Pott's at the ankle, with which the idea of danger to life is not associated.

Treatment is apparently almost powerless to help ; the indications are to prevent further crushing of the marrow by immobilization of the limb, to stimulate the heart, and to aid the respiration by inhalations of oxygen when dyspnoea is present.

Delirium tremens is a not infrequent complication of fracture in hospital cases. The course is less severe and the prognosis better than in cases not excited by traumatism. Its occurrence appears to be favored not only by the traumatism, but also by the withdrawal of the customary stimulant which usually follows admission to a hospital, and I have found it advisable, therefore, as routine practice to give alcohol in moderate quantities during the first week to those injured who are habitual, even if not excessive, drinkers. The attack begins with restlessness and sleeplessness, and when fully developed presents the usual symptoms. In addition to alcohol, sedatives are indicated, together with cathartics and a light, nutritious diet. Usually the attack subsides after one good night's rest has been obtained.

Tetanus is a rare complication, almost unknown in simple fractures and much more frequent in compound fractures of the hand and fingers than in those of other bones. Excluding those of the hand and fingers, I have seen it only in one fracture of the femur (gunshot) and in two of the forearm (compound). Although the microbic nature of the disease has been established, it is noteworthy that many of the attacks are preceded by a sudden fall in the temperature of the air. One of my cases developed after such a fall, and on the same day two cases occurred in two other hospitals in the city.

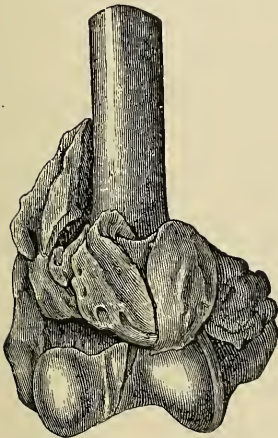
Pneumonia, developing on the second or third day, is a rather frequent and dangerous complication. Reference has been made to its possible origin in fat embolism of the lungs. It begins more frequently without a chill than with one, and, in our hospital cases at least, is likely to run a rapid, severe course, with high fever and delirium, often terminating fatally in three or four days.

Pneumonia appears also as a late complication in the old and feeble, beginning insidiously, and pursuing an asthenic course, with moderate fever and mild delirium, and ending usually in unconsciousness and death. Prolonged recumbency is thought to favor its occurrence by promoting venous congestion of the lungs, but it appears to me to be rather a relatively unimportant incident in a general failing of the strength which is usually manifest a few days before the signs of consolidation appear, and to which the death appears to be due quite as much as to the pneumonia. I have learned to look for this change especially in fractures of the neck of the femur in the old and feeble.

Late Local Complications.

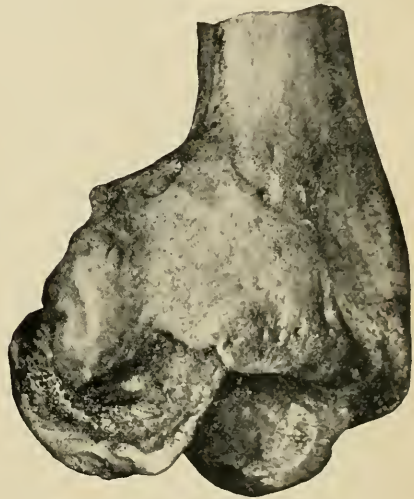The callus may be *excessive*, *painful*, or *weak*, or may become the seat of a sarcoma. A callus may be unusually large, "exuberant," either because the fragments remain widely displaced during repair, or because ossification extends far beyond the usual limits, or because the presence of a necrotic fragment maintains irritation and delays the termination of the productive process. The first variety is not properly to be termed a complication, for the size of the callus is necessary to firm union. The second is seen especially in the neighborhood of joints, as the result of the persistent displacement of a fragment, or of ossification of muscular attachments, ligaments, or capsule in the old, or of exaggerated productive activity of the periosteum in the young. The third is rather common after compound fractures that have suppurated.

FIG. 30.



Intra-articular fracture of the lower end of the humerus, with exuberant callus, especially in front.

FIG. 31.



Exuberant callus; fracture of lower end of humerus.

Enlargement near a joint may mechanically restrict its range of motion, and at other points it may, in like manner, interfere with the action of a muscle or make disabling pressure upon a nerve or interfere with the venous circulation in the limb.

An exuberant callus may, and usually does, diminish in size, but not sufficiently to remove marked obstacles to function. Such removal can be effected only by surgical measures, the cutting away of the exuberant mass; local applications made to the surface with the object of promoting its absorption are useless. The same pressure-effects can be produced by persistent displacement of the fragments, and it is not always possible to determine, previous to operation, whether the offending mass is a fragment or the callus.

Painfulness of the callus may begin early in the course of repair and persist long after union has become complete, or it may begin after an interval, sometimes a very long one. Many patients complain of dull pain in the limb for months, even for years, after the injury, especially after prolonged use and in connection with changes in the weather, but the cases in which the pain is limited to the callus are rare. The late form, that in which the pain begins after an interval, is clearly inflammatory, the inflammation being generally a recurrence in an old suppurative focus, manifesting itself by fever, swelling, and tenderness, and relieved by spontaneous or surgical evacuation of the pus.

The early continuous form is not inflammatory, but the causes are not always clear. The pain has been attributed to pressure upon a nerve either without or within the callus, to a neuritis set up by injury of a nerve at the time of the accident, as is seen also after wounds involving only the soft parts, and to a supposed persistent osteitis or an osteo-neuralgia (Gosselin) the cause of which is equally conjectural. The pain may be continuous or intermittent, and exacerbated at night or by change in the weather. It must be distinguished from pain due to injury of, or pressure upon, a nerve.

Counter-irritation on the surface has given relief, and I should think that in the rebellious cases it might be advisable to incise the periosteum or to cut into or chisel away the bone.

The development of a tumor, sarcoma, at the site of a healed fracture, within a few weeks or after an interval of several years, has been occasionally observed, and apparently belongs in the same etiological group as that of sarcomata following other injuries of bone or soft tissues. Still rarer is the development of carcinoma after fracture in those who have or have had a carcinoma at another point. Pearce Gould (*Lancet*, April 25, 1896) refers to one such case, fracture of the humerus in a lady whose breast had been removed for carcinoma five years previously; he explored very carefully by operation, without finding any sign of tumor; "two months later an extensive growth had appeared at the seat of fracture."

Associated Injury of a Nerve. A nerve may be bruised or completely ruptured at the time of the accident, or it may become stretched over the edge of a fragment or by the growing callus, or compressed within a more or less complete canal formed about it by the callus or by cicatricial tissue developed in the soft parts. Primary rupture of a motor nerve is liable to be overlooked at first, because of the withdrawal of the limb from use in consequence of the fracture, but it is not probable that the resultant delay diminishes the chance of successfully uniting the divided portions by operation, and on some accounts the operation is more free from risk if not undertaken until after the fracture has become united. The diagnosis of rupture cannot always be safely made on immediate paralysis of the muscles supplied by the nerve. I once operated upon a case of supposed rupture of the musculo-spiral nerve in connection with fracture of the shaft of the humerus, and found the nerve untorn and apparently uninjured for some distance above and below the fracture. It must also not be hastily assumed that an operation to reunite the nerve has failed; in

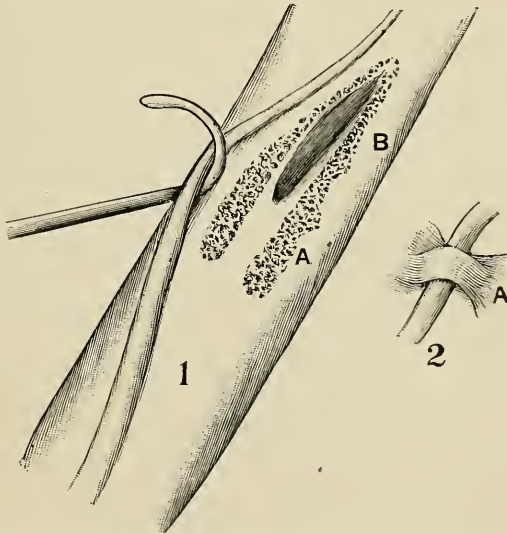
two cases (musculo-spiral nerve) I have seen function return after nearly a year had elapsed since the operation.

The compression of a nerve by a displaced fragment may abolish its functions or may excite a neuritis manifested by modifications of sensibility and sometimes by great pain; similar effects may be produced by a coincident contusion of the nerve. The most frequent examples are in fractures above the elbow and above and below the knee; occasionally it is seen in fractures of the clavicle, upper end of the humerus, and pelvis.

Similar compression may be made by the callus upon a nerve which crosses or passes through it. Of late years a number of such cases have been operated upon, and various gross changes noted in the nerve, which is usually reduced in size for a greater or less distance below and shows a notable enlargement just above the point of pressure.

The treatment consists in the removal of the corresponding portion of the bone or callus, and this should be done freely. I have thought it advisable in some cases to interpose a strip of periosteum or other soft tissue between the nerve and the cut surface of the bone in order

FIG. 32.



Inclusion and compression of the musculo-spiral nerve in a callus. A in 2 shows a bony bridge crossing the nerve, and in 1 shows the surface left by its removal. The dotted area shows the surface left after the cutting away of the sides of the bony gutter.

to diminish the probability of the nerve becoming included in a firm adherent and possibly compressing cicatrix.

Weakness of the callus, which should not be confounded with delay in consolidation, is manifested in two ways: by its yielding under use of the limb after union, as judged by the usual tests, has appeared to be complete, and by a later loss of its strength under the influence of intercurrent local or general causes; the latter is also termed *softening* or *absorption* of the callus, and in either case, if fracture occurs, it

is termed *secondary* fracture. The weakness may be due to insufficiency in the amount of the callus, as when a gap has been created between the principal fragments by their displacement or by loss of bone, or in the ossification of the bond uniting the fragments. In either case the bony bridge uniting the fragments is not strong enough to bear the strain of use, and it either breaks completely or yields enough to permit an angular displacement.

Softening of the callus under the influence of a general disease—*e. g.*, scurvy, typhoid fever, erysipelas—has been observed in a few cases, sometimes after the lapse of many months. Clarke, quoted in the *Traité de Chirurgie*, reported a case in which the softening appeared to be the result of overwork in school. The callus has been felt to diminish in size, and abnormal mobility to reappear without the intervention of any violence.

Secondary, or “iterative,” fracture without apparent defect or change in the callus is a not infrequent accident due to premature use of the limb or to slight external violence. Gosselin tells of a man twenty-five years old who broke his femur six times in twenty months; the fractures occurred in the second week after he began to walk and in consequence of a slight effort, as in dancing, running, and trying to avoid a fall; each time the patient had left his bed on the forty-fifth day. The symptoms are those of primary fracture, but usually less marked.

Arrest of growth of the bone is occasionally observed in the young after fracture at or near the epiphyseal cartilage. (See Separation of the Epiphyses, Chapter II.)

Exaggeration of growth of the bone after fracture has been observed in a very few cases, in consequence either of stimulation of the epiphyseal cartilage to greater activity or of exaggerated production of bone at the fracture. Cases have been reported in which a considerable shortening noted immediately after recovery has disappeared in the course of a year or two. There is usually room in such cases for some doubt of the accuracy of the observation. Enlargement of the patella after close reunion by operation has been observed in a number of cases, both in breadth and length.

Stiffness of the joints of the injured limb is habitually seen after fracture, and involves not only those of which the broken bone forms part but also those at a distance from it, especially on the distal side. It is most marked in the old and rheumatic and in joints directly involved in the fracture or coincidentally sprained. It appears promptly after the accident, is most marked when the splints are removed (unless measures have meanwhile been taken to relieve it), and in most cases disappears slowly under use of the limb. If a joint is involved in the fracture, or otherwise injured at the moment of the accident, a traumatic arthritis may follow and the resultant stiffness may be permanent; and in the old and rheumatic more or less limitation of motion may remain even when the joint has not been directly injured.

The causes of the stiffness, exclusive of direct injury of the joint, are to be found in injury of the muscles, œdema, and shortening and loss of elasticity in the peri-articular tissues, sometimes because of

their implication in the irritative reaction following the injury, and sometimes because of the enforced quiet. Stiffness of the knee and ankle after fracture of the thigh, of the elbow after fracture of the arm, and of the wrist and fingers after fracture of the forearm is constant and often very persistent. It is relieved by measures which diminish the œdema and improve the circulation, and these may sometimes be employed before consolidation of the fracture is complete: such are massage, passive motion, and position. The fingers stiffen, and sometimes very rebelliously, under immobilization, and especially when kept fully extended. The rule should therefore be, in all injuries of the upper extremities, to leave them free of the dressings whenever that is possible and to instruct the patient to move them frequently; when they must be confined the position of flexion for the fingers and abduction for the thumb is to be preferred.

Persistent active and passive motion of the joints within their existing range, massage and hot and cold douching will usually increase the range and freedom rapidly; in the young and young adults little time will be lost by simply trusting to the natural use of the limb to restore its functions. Patients should be encouraged to disregard pain following use which does not leave the joint tender the next day. Limitation of motion due to displaced fragments or overgrowth of callus can be relieved, if at all, only by operation.

Atrophy of the Muscles. A limb that has long been withdrawn from use because of fracture appears smaller above the seat of the injury, and also below it if the œdema has disappeared. Advantage has been taken of the death of a few patients at this period to weigh their muscles, and they have been found distinctly, and in some cases notably, smaller than those of the opposite limb, the loss involving all and not merely those of some group supplied by a nerve that might have been injured. In the young and in young adults the loss is soon made good, but in others and in cases of long duration the atrophy may persist for months or even be permanent. Various explanations have been offered, such as lack of use, occlusion in fixed dressings, diversion of nutritive materials to form the callus, and reflex trophic disturbances from injured nerve branches, but none is free from serious objections. Massage, electricity, and systematic exercise are the measures employed to hasten or effect recovery.

Thrombosis of the Veins and Embolism. Thrombosis of some of the larger veins in the neighborhood of a fracture is thought to be rather common and to be the cause of the œdema and venous congestion which are so constant and troublesome after fracture of the lower limb when the patient begins to walk. Occasionally, but very rarely, the process occupies or extends into a vein sufficiently large to furnish an embolus which is carried to the heart or, more commonly, through it into the pulmonary artery, and causes death. Virchow published in 1846 such a case following fracture of the neck of the femur, and Durodié¹ collected eight other cases in which the deaths occurred between the sixteenth and fifty-seventh days. One fracture was of the

¹ Durodié: *Etude sur les Thromboses et l'Embolie veineuses dans les Contusions et les Fractures*, Thèse de Paris, 1874, No. 326.

femur, the others of the leg. Wilde¹ reported two cases and collected five others; and Smirnow² reported one and collected thirty-seven reported cases.

The symptoms are the usual ones of pulmonary embolism: sudden onset, with lividity or pallor, dyspnoea, præcordial distress, and death in a few minutes.

Arteries. Traumatic aneurysm is a rare complication. H. Meyer³ collected sixty reported cases and added one of an intercostal artery after fracture of a rib. Thrombosis of an artery, because of coincident bruising, is more common.

¹ Wilde: *Centralb. für Chir.*, 1902, p. 1349.

² Smirnow: *Ibid.*, 1903, p. 825.

³ Meyer: *Inaug. Dissert.*, Kiel, 1903; *Centralb. für Chir.*, 1903, p. 819.

CHAPTER VII.

TREATMENT.

Reduction. Retention: Removable Dressings, Permanent Dressings, Direct Fixation. Massage. Ambulatory Treatment. Management of Joints. Compound Fractures. Amputation. Compound Articular Fractures. General Treatment.

GENERALLY speaking, the treatment of a fracture should begin when the patient is first seen, but by this it is not meant that every indication should at once be met by appropriate measures; even the correction of the displacement, the "setting" of the fracture, and the immobilization of the fragments may have to be left undone or incomplete because of conflicting and dominating conditions, such as extreme swelling, muscular spasm, or associated lesions. A delay of even several days is usually, in respect of these indications, of small importance, for the preparatory work in the bone and soft parts goes on notwithstanding it, and when finally the adjustment is made the condition differs but little from that which would have existed had it been made at the first.

A much more important indication in most cases is to prevent additional injury while the patient is being taken home or to hospital. The danger at this time is that by incautious handling, disordered movements, or injudicious attempts to use an injured limb a simple fracture may be made compound or additional laceration caused. This risk exists especially after fracture of the leg because a large extent of the surface of the tibia lies immediately beneath the skin and the end of a fragment can easily be forced through it. The surgeon therefore will protect the limb by a temporary splint, when such protection is needed, and the judicious layman will leave the patient undisturbed or will transport him recumbent.

If the fracture is one which necessitates confinement to the bed, the bed should be narrow and high, and the mattress firm. A long, broad board may be placed beneath the latter if the spring mattress is soft. Specially constructed "fracture-beds," some of which are very ingeniously arranged, are convenient, but not at all essential. A water-bed or air-bed is of the greatest value in the treatment of fractures of the spine in minimizing the formation and duration of bed-sores.

The points to be considered and the indications to be followed by the surgeon called to treat a fracture vary greatly in different cases according to the bone or portion of bone involved, the complications that exist or are to be feared, and the age, the health, the habits, and even the social status of the patient. At one end of the long and varied series of problems which present themselves he has only to

provide the simplest means to protect the patient from additional injury or pain during the few days or weeks that are needed for repair; at the other the highest resources of his art are required to save life or limb or to preserve function. On the one hand, the fracture may be the sole thing to be considered, his attention must be unremittingly given to the position of the fragments and their maintenance in proper relations, and his skill and care will determine the character of the result; on the other, his best endeavor may be powerless to affect the position of the fragments or modify the result, or the fracture, as in many of the base of the skull, may be a wholly unimportant and negligible incident beside the associated lesion.

The indications for treatment arise, therefore, in varying degrees from the fracture itself, the associated lesions, and the immediate or late local or general effects upon the patient. Occasionally they conflict, and the surgeon must then temporarily disregard some or he must even be content with a defective local result because an attempt to secure a better one would involve risks disproportionate to the advantage sought. Those directly concerned with the fracture are to correct displacement of the fragments, if such displacement exists and if its correction is possible and advisable, and to oppose by appropriate means the action of those forces which might reproduce it, such as muscular action, swelling, and gravity. This correction of the displacement is termed the "reduction" or "setting" of the fracture.

Reduction.

Not every fresh fracture is accompanied by a displacement that needs to be corrected; and of those in which such displacement exists, in not every one is reduction possible or advisable; and sometimes when reduction is both possible and advisable circumstances require that it should be delayed.

Fractures without a displacement that needs to be corrected are many and varied, such as most simple fractures of the cranium, of the scapula, of the ribs, the ilium, the shaft of the fibula or ulna alone, and many of the metacarpal and metatarsal bones.

Reduction is said to be impossible (although in most cases the better term would be inadvisable) when the opposing conditions are such that they cannot be overcome by the methods ordinarily in use, and when more efficient ones would involve overbalancing disadvantages or risks. The causes of this condition are varied; among them may be mentioned the interlocking of the irregular ends of the main fragments, the interposition of soft parts or small fragments, and the small size and inaccessible position of a fragment, as in some articular fractures. When the fracture is of the shaft or subcutaneous end of a long bone the existence and character of the displacement are usually recognizable, but when one of the principal fragments is a part of the articular end of a long bone and is thickly covered by muscle or masked by swelling, not only the character but even the existence of the displacement may be in doubt and remain so until after repair is far advanced. In such cases an exact diagnosis can be made and

reduction can generally be effected by the aid of an incision which exposes the seat of fracture, but although the probability that such an operation in experienced hands and under proper precautions would be followed by disaster is small, yet the evils of such a result, if it should follow, are usually so in excess of those resulting from the persistence of the displacement that the operation is rarely undertaken while the injury is recent, and then only because of the presence of some controlling condition or danger, such as pressure upon the skin or a main vessel or nerve that cannot otherwise be removed. In cases not thus complicated the worst that can follow after fracture of the shaft is failure of union or union with a disabling deformity, and both of these conditions may be relieved by a late operation. Nevertheless, displacements unrelievable by manipulation and likely to involve serious loss of function if not corrected, can occasionally be recognized, and in such cases reduction by open operation is called for. They are generally cases in which the limb has been greatly distorted at the time of the accident, so that the sharp end of a fragment has been driven into an adjoining muscle or through the enveloping fascia, or an obliquely broken fragment has been forced around to the opposite side of the other from which it has been broken. The first form is not uncommon in fractures of the lower end of the femur or in the neighborhood of thinly covered joints. From the admitted propriety of operative interference in such cases it is a long step to similar interference in all, as has been urged; and such generalization, if accepted, would, in my judgment, lead to disasters far more serious and numerous than the disadvantages that would follow failure to reduce the displacements. Ranzi¹ reports 4 severe infections in 50 operations and protests against the generalization of reduction by operation. See also Fritz König² for a thoughtful study of the conditions justifying or forbidding operation.

In articular fractures the conditions are different: the displacement if uncorrected may seriously compromise the usefulness of the joint, and but little if any relief is to be expected from a late operation. If anything is to be done it must be while the injury is still recent. I have taken this course in a considerable number of cases, and without ill result in any, but I am convinced it should be resorted to only after thorough study of the conditions and careful weighing of the probabilities. The risk of such primary interference by operation is, I think, less the more promptly it follows upon the receipt of the injury: if it is done within the first twenty-four hours the condition is practically that of an operation upon previously uninjured tissues, and the same confidence may be felt that primary union will be obtained, but if the third or fourth day has been reached and the tissues are swollen and infiltrated with extravasated blood the same confidence cannot be felt, and it is, I think, better to wait for the subsidence of the swelling and the absorption of the blood. It has been observed that some compound fractures which heal primarily, and simple fractures which have been exposed by early incision, run their course

¹ Ranzi: Arch. für klin. Chir., vol. 80, pp. 567 and 843.

² König: Ibid., vol. 76, p. 725.

with less swelling and possibly with less general reaction than simple fractures treated solely by immobilization; their course is essentially that of an ordinary osteotomy for deformity; but nevertheless the difference, in my opinion, is too slight to justify routine resort to operation, as has been suggested, in order to obtain it, even with the added advantage of an accurate adjustment of the fragments. The difference is apparently due to the prompt removal of the extravasated blood and the drainage of the primary serous exudate; and the advantage, except in a few selected cases, is limited to some diminution of the discomfort of the first few days, and does not extend either to the character of the final result or to the time within which it is obtained.

Other conditions which make exact and immediate reduction inadvisable are crushing of the spongy tissue of the bone, extreme subfascial swelling of the broken limb, muscular spasm, and coincident injuries or other conditions which prevent the application of a dressing efficient to maintain the reduction when effected. Crushing of the spongy tissue is seen mainly in the old, at the upper end of the femur and humerus, at the lower end of the radius, and in the bodies of the vertebræ. The effect of this crushing is the same as the removal of a piece of the bone; if the fragments are restored to their original positions a gap corresponding to the amount of the crushing is created between them, which, if the position is maintained, must be filled by the production of new bone, a task that may be beyond the power of the organism, and failure in which would lead to failure of union, a result much more disabling than the persistence of the deformity.

Extreme subfascial swelling of an injured limb shortens it and increases its transverse diameter, because the capacity of the fascial sheath is greater the more nearly it approaches the globular form; consequently forcible elongation of the limb with the object of correcting the shortening diminishes the capacity of the fascial sheath and increases its tension and the pressure upon its contents; this resistance may be sufficient to maintain the shortening against any reasonable effort to overcome it, or to endanger the vitality of the limb by interference with the circulation. It is therefore necessary to await the subsidence of the swelling.

Muscular spasm, excited by the trauma or by pain or the fear of pain, acts powerfully at first to fix the fragments in their faulty positions and especially to produce and maintain shortening of the limb. It usually disappears within a day or two, and can be temporarily annulled by anæsthesia or a full dose of opium or even, as was pointed out by Broca, by compression of the main artery of the limb.

Associated injuries or conditions which prevent or delay reduction may be general or local, such as profound shock due to the fracture or to other injuries, damage to the main vessels of the limb threatening gangrene, and extensive wounds of the skin which would prevent the use of dressings to maintain reduction.

In the absence of any of these contraindications the sooner the fracture is "set," the sooner the fragments are brought to and fixed

in the positions they are expected to keep during repair, the better; for although the preparatory changes in the bone itself require several days, and in places even weeks, for their completion, yet the accessory processes in the soft parts begin immediately, and it is desirable that they should not be interrupted or undone by changes of place and relations. The thickening and infiltration of the parts adjoining the bone which appear so promptly give a steadily increasing fixity to the position of the fragments, and it is desirable that that position should as early as possible be made the permanent and final one, for although it can be changed without much difficulty and to a considerable extent in many fractures even two or three weeks after the receipt of the injury, yet the shift is necessarily accompanied by some loss of security and time.

The actual reduction or setting of the fracture is in many cases a procedure guided only by general ideas, not by an exact and detailed knowledge of the peculiarities of the displacement to be overcome or even of the lines of fracture, and the extent to which the effort has been successful can only be surmised, not positively known. Such is notably the case in fracture of the shaft of a long bone thickly covered with muscle, as the femur. By eye, touch, and measurements the surgeon can recognize shortening, angular, rotatory, and perhaps even lateral displacement, and by traction and pressure he can straighten and lengthen the limb, but he cannot know whether or not the adjustment of the fragments is accurate and close. The same is measurably true even of many fractures of bones that are more or less subcutaneous and palpable; or if palpation shows some remaining irregularity of outline the best effort may be unavailing to correct it. This, however, does not make the result so much a matter of chance as the statement may seem to indicate; the main factors of displacement at the different points are known, and the surgeon is safely guided by this knowledge in his choice and use of methods to make and maintain reduction and of the attitude and support given to the limb while the fracture is healing, and is justified in awaiting the outcome with a confidence that is limited only by knowledge of the fact that in a certain proportion of cases, fortunately small, unknown and unknowable factors may defeat efforts wisely conceived and faithfully executed. The ideal is the complete restoration of form and function, but he must often be content to obtain, or even to seek, much less. These more or less necessary limitations will be mentioned in connection with the results of the individual varieties of fracture.

Since the principal causes of displacement after fracture of the shaft of a long bone are the tonic contraction of the attached muscles and the unsupported weight of the lower segment of the limb, reduction is commonly effected by bringing this lower segment into line with the upper one and making steady traction upon it in the direction of its long axis, the different joints being usually held in partial flexion in order that the attached muscles on either side may be correspondingly relaxed. Note must be taken, in fractures at certain points, of the known tendency of the upper segment to assume a certain attitude

because of the unopposed action of the muscles attached to it, an attitude which is often but faintly indicated by the form of the limb if the fragment is short and thickly covered by muscle. Common examples are furnished by fractures of the upper third of the femur and of the surgical neck of the humerus, in both of which the upper fragment may be markedly abducted, flexed, and rotated outward. The surgeon confidently places the lower segment in the corresponding attitude, even if he cannot detect the deviation of the upper one, for he knows that even if it does not exist the upper fragment will follow the movement he gives to the lower one, and the two pieces will be in line when he makes the traction designed to give the limb its proper length.

While traction (and, if necessary, rotation of the lower segment) is made the surgeon makes lateral pressure to correct such lateral displacement as may remain, and seeks to discover and take advantage of such peculiarities of the line of fracture as may aid him to maintain the position he gives the fragments. Thus, in a transverse fracture or in one with marked irregularities of outline the opposing ends may be so engaged with each other that the lower fragment will be held in place and kept from overriding, notwithstanding the pull of the muscles. If there is only an angular displacement, as in partial, subperiosteal, and some transverse fractures, traction is not needed, and the surgeon has only to correct the deviation by lateral pressure. In the partial fractures of adolescence this sometimes requires considerable force; the knee must be placed against the projecting angle and the ends drawn into line; but usually it can be accomplished by the hands alone, the thumbs being placed against the angle while the fingers grasp the limb above and below it.

A serious obstacle to reduction occasionally arises from the penetration of the overlying muscle and fascia by the sharp end of one of the fragments, usually the upper one. This occurs most frequently in oblique fracture of the lower third of the femur, and can there be treated most effectively by flexing the hip and the knee to a right angle, thus drawing the relaxed quadriceps (which is the muscle commonly penetrated) downward past the engaged end of the upper fragment, and, if necessary, completing the act by traction at the knee. This exemplifies the principles of treatment in all cases: relaxation of the muscle, if it crosses the proximal joint, and also the fascia by moving the limb toward the corresponding side; drawing the muscle downward by bending the distal joint in the opposite direction; and then lifting the lower segment of the limb bodily away from the upper fragment. If this or other appropriate manipulations fail, the fragment must be exposed by an incision and freed by direct means. If the fragment has perforated the skin also the opening should be at once enlarged and reduction guided and aided through it; as the external wound exists, nothing is lost and much may be gained by freely using it for reduction, cleaning, and drainage.

Whenever an anæsthetic is given it is prudent to protect the broken limb during its administration by temporary splints or the hands of

an assistant in order that the lacerations may not be increased by the unconscious struggles of the patient.

In some cases in which the fragments are firmly interlocked or impacted, notably in some Colles's fractures at the lower end of the radius, it is advisable to increase the angular displacement as a first step, and forcibly to move the lower fragment backward and forward in order to break up the impaction and thus facilitate reduction.

When the line of fracture runs through or close above the articular end of a bone it is at most points impracticable to control the position of the small articular fragment by manipulation, because it is too small or too deeply covered to be grasped; under such circumstances it can sometimes be brought into place by so changing the attitude at the corresponding joint as to make tense a portion of the capsule which is attached to it and then by continuing the movement to correct the displacement, or by making direct traction upon it through its ligaments. In some injuries—*e. g.*, separation of the upper epiphysis of the humerus and Pott's fracture at the ankle—the character of the displacement is so constant that a formula of treatment is based upon these facts; similar formulæ have been made for injuries at other points, as the elbow and knee, but the lesions and displacements are there too varied to make routine treatment safe. At the shoulder the separated epiphysis is in anterior flexion and abduction although the arm hangs by the side; on raising and abducting the elbow the movement of the already flexed and abducted epiphysis is promptly arrested at the normal limit by the posterior portion of the capsule, and then the lower portion of the humerus is brought into line with it by continuing its movement in the same direction, and thus the angular displacement is corrected. At the elbow, after fracture of the internal condyle, the small fragment can be drawn down into place by full extension of the joint and abduction of the forearm; and after supra-condyloid fracture of the humerus full flexion of the elbow, by making tense the posterior portion of the capsule, enables the surgeon to correct an angular displacement of the lower fragment in which the apex of the angle is directed forward.

Retention.

The objects of retention are to prevent displacement of the fragments by the various agents that are competent to produce it, notably gravity and muscular contraction, to protect the limb from external violence during the progress of repair, and to prevent the pain that would be caused by movement of the fragments. The relative importance or urgency of these needs varies greatly in different cases, and this, together with the mechanical conditions, measurably determines the choice of the method of treatment. Thus, in the fracture of a single long bone, such as the femur, where the weight of the limb and the action of the muscles are efficient and always ready to produce displacement, support equivalent to that destroyed by the injury must be supplied by apparatus; while in fractures of only one

of two or more parallel bones, as of the fibula or of a rib, or in those of the flat or small spongy bones, or of an apophysis or condyle, only such a dressing is required as will moderate or prevent voluntary or involuntary contraction of attached muscles.

The swelling of a limb which so promptly follows its fracture is an element of much importance because its variations affect the adjustment and fit of most dressings and because its appearance after the application of a dressing that envelops a limb may so interfere with the circulation as to cause gangrene of the limb or ischæmic degeneration and contracture of the muscles. For these reasons it is frequently advisable to delay the application of an enveloping permanent dressing until after the swelling shall have notably subsided, and it should be the rule to make frequent examination of the fingers and toes during the first two or three days after the application of such a dressing, and to leave them uncovered by the dressing for the purpose of such examination.

The possibility of dangerous constriction is specially to be borne in mind in dressings which completely and closely encircle a limb and which are inelastic, such as plaster-of-Paris encasement or even a muslin roller-bandage applied directly to the surface without an intervening layer of cotton. Such a dressing snugly applied while the injury is recent will almost always become too tight and will have to be removed in a few hours either because of the pain which it causes or of the threatening strangulation of the tissues. This is true even when the injury is a comparatively slight one. I have seen gangrene of the hand and forearm follow the application of a gypsum dressing for fracture of the olecranon. A roller-bandage may be placed directly upon the limb *below* the fracture to restrain its swelling, but should not be carried as high as the fracture beneath the splints, except very loosely; and when splints are used they should be broad enough to prevent circular constriction by the bandage which binds them in place. If plaster of Paris is used it should preferably be in the form of moulded splints, not complete encasement, or at least in a form which will permit the dressing to be loosened.

It is a good rule also to remove a permanent dressing after ten or twelve days in order to detect and correct any displacement that may have taken place under it and to tighten or renew it to meet the shrinking of the limb.

It is specially important that the possibility of constriction by the dressing should be guarded against whenever the injury is such that it may itself cause gangrene of the limb. A limb whose vitality has thus been put in doubt by the injury should be treated for the first few days with the primary object of favoring the impaired circulation and especially of avoiding the creation of any additional obstacle to the venous flow, and this not only for the advantage of the patient, but also for the protection of the surgeon against the suspicion or the charge that his dressings may have caused the gangrene. This disastrous result of injury is a fruitful source of suits for malpractice, and the defence that it was due to the injury and not to the treatment

is usually viewed with so much suspicion that the surgeon should be watchful from the beginning of the case that the real cause should be clear. It must be remembered that in the great majority of cases the gangrene is of the moist form and due to interference with the venous flow, and that this interference may easily and rapidly be raised to a dangerous degree by circular constriction at even a single point.

Cases differ far too widely in severity and local conditions to permit of a general rule of practice applicable to all. Many, in which the tendency to displacement is slight or easily controlled, may be treated in a permanent dressing from the beginning, one which gives the necessary support without danger of constriction, and can be left in place (or removed temporarily for inspection) for one, two, or three weeks. Others, more severe, such as most fractures of the femur, also receive a permanent dressing at the beginning because this dressing is mainly applied below the seat of fracture and does not expose to constriction by swelling. Others, such as most fractures of the leg, should rest in a temporary dressing, such as a Volkman splint, for from five to ten days, unless permanent moulded splints that can be loosened are used.

So, too, when the surface of the limb has been so torn or bruised that the wounds cannot be properly treated through an opening made for the purpose in a permanent dressing, and when damage to the deeper parts forbids the use of any constriction or pressure. Under such circumstances the surgeon must be content to make such dressings as the associated injuries require and to leave the limb simply supported upon the bed by pads or in splints loosely applied over the other dressings. Although the use of these temporary dressings may be necessarily prolonged for several weeks, it will be convenient and proper to describe them under that title.

The presence of large blebs is sometimes an additional reason for delay, although they usually heal promptly under a protective dressing after puncture. If it is desired to leave the limb as undisturbed as possible, it is advisable thoroughly to clean and disinfect the adjoining skin, cut away all the raised epidermis, cover the exposed surface with sterile rubber tissue or silver foil, and apply a gauze dressing.

Temporary and Removable Dressings.


The object of a temporary dressing is mainly to protect the patient against pain and additional injury by movement of the fragments during transport to his home or hospital, or to prevent displacement by the unsupported weight of the lower segment of the limb; it is rarely efficient to prevent displacement by the action of the muscles when the character of the fracture is such that such displacement is possible.

Side Splints. These are usually made of wood, but in case of need many other materials are available, such as card-board, stiff leather, iron, zinc, tin, even bundles of tightly-rolled straw.

The **wooden splint** in its simplest form is a piece of soft wood of a length and breadth corresponding to those of the injured limb and thick enough not to bend under firm pressure. A thick layer of cotton or other soft material should be bound along the side which is to rest against the limb, and should be reinforced at needed points in order to fill depressions of the surface of the limb. Projecting points of bone should be protected by cotton placed *around* them, not *upon* them. While an assistant makes traction upon the lower segment of the limb the surgeon places the splints, one on each side, and binds them on with a roller-bandage, taking care that the turns support the limb throughout its entire length, but do not make circular compression. The splints should be long enough to support the hand and foot respectively. A form in common hospital use is the thin bass-wood splint, the necessary rigidity being obtained by binding several together,

Gooch's flexible wooden splint, which is made of narrow strips pasted together upon cloth on one side, is designed to adapt itself to the curve of the limb and thus give a more uniform support. It is rarely used.

FIG. 33.



Wire splint.

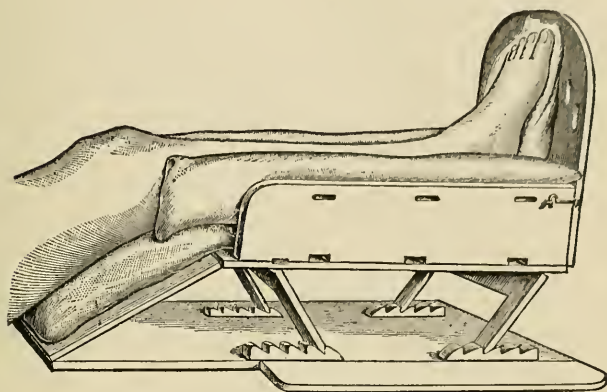
The carved splints sold in packages of assorted sizes have few if any points of superiority over those improvised for the occasion, for they also need to be fitted and padded. If it is desired to have a splint that more nearly follows the contour of the limb an excellent one can be made with plaster of Paris (see below) or card-board or leather softened in water, and similar ones can also be used with advantage over the dressings that are needed for associated wounds of the skin or compound fractures.

Splints of wire (Fig. 33) that can be measurably modelled to the limb are convenient; they can be had from the instrument makers.

The **fracture-box** (Fig. 34) is a form of wooden splint once much used in fractures of the leg, but now almost wholly discarded for the following:

Volkman's splint (Fig. 35) is a shallow gutter and foot-piece, made in several lengths, and fitted with a movable support, by which the

FIG. 34.



Petit's fracture-box.

foot can be raised from the bed. For use it is thickly padded with cotton, and the leg is bound in it with a roller-bandage. Care must be taken that undue pressure is not made on the skin covering the front of the tibia by the bandage or on the heel or the tendo Achillis;

FIG. 35.



Volkman's splint for leg.

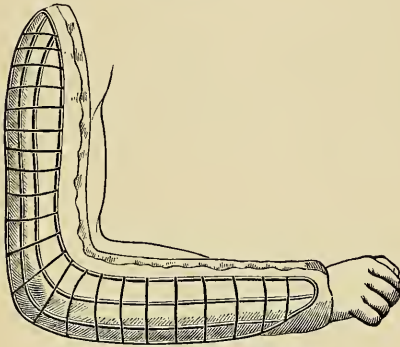
the latter pressure is best avoided by slinging the foot by means of a broad strip of adhesive plaster extending from the middle of the calf, under the heel and along the sole, to the top of the foot-piece, where

it is made fast by a reversed piece attached to it and then to the lower surface of the metal.

Gutters of galvanized wire or tin (Fig. 36) are much used for fractures of the humerus: they give more protection than short splints because they include the forearm. They can be readily made from sheets of wire gauze by taking a strip of suitable size and cutting it partly through at the angle, and tying together the meshes which overlap where it is bent.

When it is desired to cover the limb with dressings because of the presence of a wound of the skin or to make moderate uniform compression, or while waiting to

FIG. 36.



Wire gutter for the arm and forearm.

learn the effect of the injury upon the vitality of the skin or the limb, a convenient method of applying them so that they can be readily and painlessly removed for adjustment or inspection is in the form of the *Scultetus bandage*, a dressing which was formerly in wide use for retention. The dressings are cut in thick strips one-half longer than the circumference of the limb and three or four inches wide, and then arranged upon a piece of muslin a little longer than the part to be

dressed in such a way that each overlaps its adjoining upper one by about an inch. The limb is then placed along the centre of the bandages and each end of each of the latter, beginning with the lowest, turned over the front of the limb until it is entirely enveloped; lateral support is given by splints rolled into the sides of the underlying strip of muslin and bound fast, or by other splints, or by placing the limb in a Volkmann splint or a gutter. The front and sides of the limb can then be readily exposed by turning back the ends of the pieces of dressing.

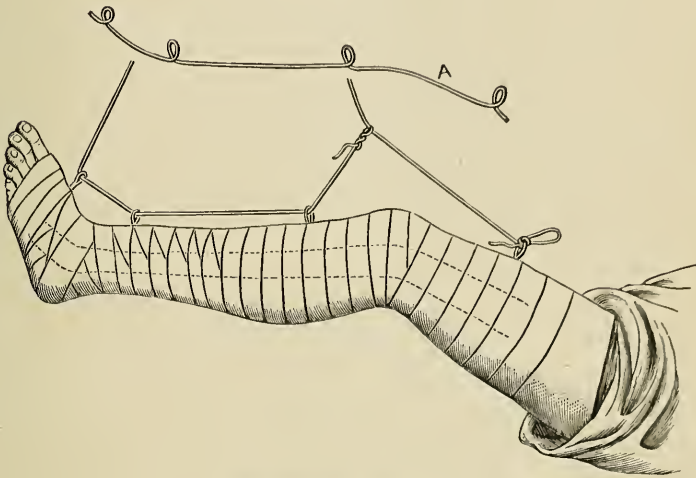
Instead of lateral, *anterior* or *posterior* splints may be used, either that they may be combined with suspension or that portions of the limb may be more conveniently exposed and dressed. Because of the importance of equally distributing the pressure, a posterior splint to be used with suspension should be accurately fitted to the limb; consequently the moulded splints (plaster of Paris, gutta-percha, etc., see below) are to be preferred. When they are sufficiently rigid the limb can be suspended by two or three bandages passed beneath and attached above to a suitable support.

Late in the treatment of fracture of the femur one of the forms of hip-splints may be conveniently used.

Anterior suspended splints may also be of the moulded kind, with included metal rings or loops for the attachment of the supporting cords, or some modification of Nathan R. Smith's anterior splint specially designed for the treatment of fractures of the femur. This

splint (Fig. 38) is made of two parallel iron rods, joined at the ends, and by two or three intermediate rods, bent slightly at the knee and sharply upward at each end to fit the foot and pelvis. It is placed along the anterior surface of the limb, which is attached to it by a roller or by straps, and is suspended by cords. Hodgen's splint has

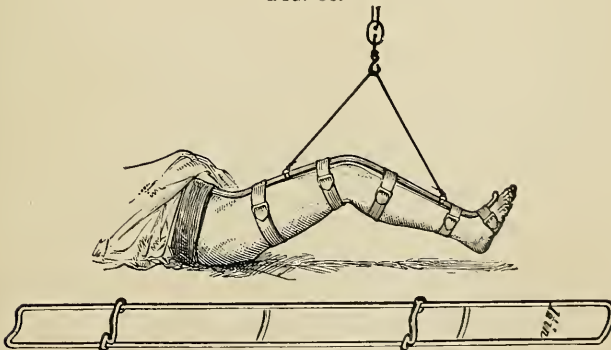
FIG. 37.



Suspended moulded splint.

taken its place for fractures of the thigh because of the additional traction which it supplies, but Smith's is useful in those and, in suitably modified forms, in others when suspension alone is desired.

FIG. 38.



Nathan R. Smith's anterior splint.

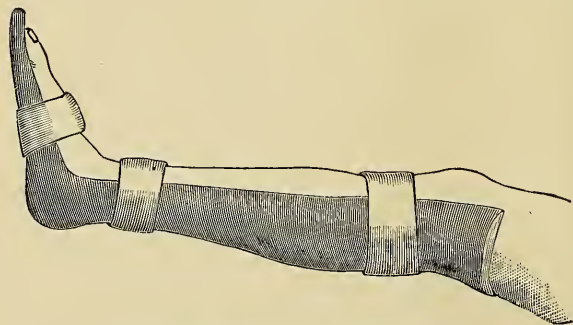
Moulded splints are constructed of any material that can be made temporarily soft enough accurately to take the shape of the part to which it is fitted and which then becomes hard enough to retain the shape thus given to it. The materials most frequently used are plaster of Paris, pasteboard, leather, felt, and gutta-percha.

Pasteboard is used by softening one or two strips of suitable size by immersion in hot water, and then moulding them to the limb by binding them on snugly with a roller-bandage. Temporary support must usually be given by other splints until the pasteboard has become hard by drying. When it is necessary to bend the pasteboard at a sharp angle cuts should be made in it in suitable directions and places and the overlapping portions stitched together.

Leather and felt are prepared in the same manner. A material is made for this purpose of woven tissue soaked in shellac which can be softened by dry heat and hardens more rapidly than the others. Gutta-percha is used in strips one-sixteenth to one-eighth inch thick and is softened by immersion in hot water. The stickiness of the surface can be mitigated by covering it with muslin.

Plaster-of-Paris, or gypsum, splints can be made of the prepared bandages or of some loose-meshed material soaked in plaster cream. If the prepared bandages are used they should be thoroughly wet in the usual way, squeezed out, and then rapidly unrolled back and forth to make a splint of the desired dimensions. From eight to fifteen layers are required to give the needed solidity. Plaster cream is prepared by sifting the dry plaster into water and then spreading the plaster thus moistened upon the selected material previously cut to suitable shape and wrung out in water. The number of layers needed will depend upon the thickness of the material, and care must be taken thoroughly to work the plaster into them. The use of hot water or the addition of salt or zinc oxide to the water will hasten the setting. If the plaster has been long exposed to the air before

FIG. 39.



Posterior gypsum splint or gutter.

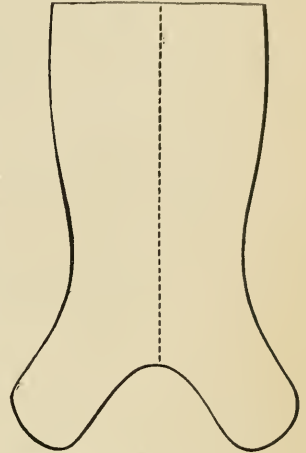
use it should be dried in an oven; otherwise the setting may be long delayed or even fail. Splints thus prepared can be made impervious to water by varnishing them or by pouring melted paraffin upon them. A strip of rubber tissue or oiled-silk carefully packed in at the exposed point will protect satisfactorily for several days from the discharge of a wound. Weight can be reduced, while preserving the strength, by inserting thin strips of metal or wood at places where the splint will not require much modelling to fit the limb. Splints of

this kind are specially useful in fractures at the ankle, wrist, elbow, and arm, and not infrequently, such a temporary splint will remain efficient for two or three weeks. For fractures of the leg one of the splints should be posterior and broad enough to cover nearly half of the circumference of the limb; a narrower anterior one may be used with it, or a lateral one the lower end of which encircles the instep, or a bilateral one crossing below the instep like a stirrup. The posterior splint should pass along the sole and project about an inch beyond the toes so as to take the weight of the bed-clothing. They must be snugly moulded to the limb with a roller bandage, and the desired position of the fragments maintained by the hands or a suitable support until the plaster shall have set.

If for any reason a posterior splint cannot be used, a strong broad anterior one may be substituted, and if suspension is desired the inclusion within it of a stout wire bent into loops at several points will facilitate it (Fig. 37).

A form of bilateral moulded splint which I have found convenient in fractures of the leg as a substitute for the Volkmann splint during the first week, and, because of the ease with which it can be removed, even for the complete encasement in plaster of Paris which usually follows, is the following: Two pieces of muslin are cut to the shape shown in Fig. 40, and of a size to fit the limb, and stitched together along the median line. Then twelve or fifteen pieces of crinoline, or three or four of canton-flannel, each a little smaller than a lateral half of the first, are soaked in plaster cream and laid in each half of the first between its two layers, and the whole then bound smoothly to the limb with a roller-bandage. Swelling of the limb is met by loosening the bandage, and inspection is easy by turning down either lateral half, the line of stitching acting as a hinge. The additional trouble entailed in its preparation, as compared with the Volkmann splint and later encasement in plaster, is offset by the greater security and ease with which the patient can be moved during the first week, and the ease with which the dressing can be removed and the seat of fracture inspected so long as intercurrent displacement is possible and corrigible.

FIG. 40.



Stocking or bivalve plaster splint.

Permanent or Final Dressings.

The dressings included under this title are those designed to maintain the fragments in the relative positions given them until union is complete or, at least, far advanced. They are expected to give the protection and quiet of the temporary dressings, and in addition to oppose, with as much efficiency as possible, shortening of the limb or angular displacement by muscular contraction or gravity. As has been said,

the temporary dressings may sometimes be used equally well for the same purpose, and some of the permanent dressings, especially those making continuous traction, may be used from the beginning. A rule of practice which will save the surgeon an occasional and very disagreeable surprise and disappointment should be to examine about the end of the second week, and again later if the fragments are still movable, every fracture that has been covered by the dressing in order to detect and correct such displacement as may have occurred beneath it. This applies especially to fractures of the shaft of the long bones and to some articular fractures in which displacement is easy.

FIG. 41.



Encasement of leg in plaster of Paris.

Complete encasement in plaster of Paris (Fig. 41), occasionally advisable, if carefully watched, even as a primary dressing, is most useful and efficient when applied after the swelling has subsided, and at still later stages in cases in which continuous traction has been used until union has become well advanced. Its mode of application is as follows: The limb is raised by one or two assistants who make steady traction upon it in order to keep it straight and of full length; the surgeon wraps it in a thin layer of cotton batting, preferably prepared in three-inch rollers, and then applies the plaster roller-bandages, thoroughly wetted and wrung out in hot water, from below upward. The turns of the first layer should be drawn just tight enough to keep their place, and the subsequent turns simply rolled over the first without increasing the pressure, taking care to model the dressings accurately to the prominences and depressions of the limb. When the dressing is complete the limb is lowered to rest, and proper support given it until the plaster is hardened. The dressing should extend far enough above and below the fracture to rest against such prominences of the skeleton or muscles as may be present and will act, after the plaster shall have set, to prevent movement of the limb within its case. When such fixed points do not exist, as at the shoulder and hip, other means to prevent shortening must be used, usually some form of traction. The upper and lower ends should be so placed that their edges will not make irritating pressure directly against a diverging surface: thus, for the forearm it should stop well short of the flexure of the elbow or should pass a short distance up the arm; at the ankle it should stop short of or pass well forward on the dorsum of the foot; on the inner side of the thigh it should not reach the perineum.

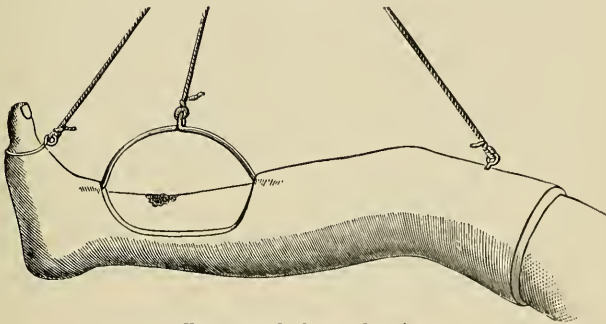
The finger or toes should always be left uncovered and should be repeatedly inspected during the first two or three days in order to detect any interference with the circulation.

In the lack of plaster rollers the dressing can be made of any coarse material cut in suitable strips and soaked in plaster cream.

If it is desired to have a small portion of the limb exposed, as for the dressing of a wound, a fenestra can be cut, and its edges protected with adhesive plaster, rubber tissue, or oiled silk. If a larger opening is required the splint must be reinforced by one or two curved iron bands incorporated in the dressing or, better, fastened to it by additional turns of a plaster roller after the main portion of the dressing has hardened. These are termed "fenestrated" or, if the opening includes the entire circumference, "interrupted" splints (Fig. 42).

Ochsner recommends very highly a means devised by Croux for the protection of the splint against the discharges in compound fractures.

FIG. 42.



Fenestrated plaster dressing.

It consists of a thick solution of India-rubber in chloroform mixed with small pieces of lambs' wool; this is poured in between the splint and the limb around the opening.

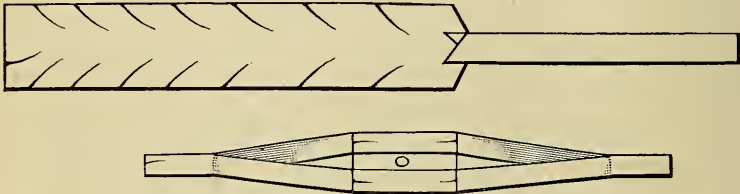
Similar dressings can be made with silicate of soda or potash, starch, dextrin, or glue. The silicate and dextrin are used by thoroughly saturating roller-bandages with the material and applying them in the same manner as plaster bandages. They do not dry so rapidly as plaster, but are lighter and cleaner and not so liable to crumble at the edges. Silicate is frequently used for dressings of the hand and forearm. The edges of both silicate and plaster dressings can be advantageously protected against crumbling by covering them with adhesive plaster.

The removal of one of these dressings is a tedious and troublesome task; it can best be done by cutting lengthwise with a short, stout-bladed knife, aided in the case of plaster by moistening the dressing along the line of the division. The diminished resistance to the knife gives warning of the proximity of the skin, and the deepest layer and the underlying cotton should be cut with strong bandage scissors. The principal difficulty is in turning re-entrant angles, as at the front of the ankle or elbow. After the division has been completed the sides can be forcibly drawn back and the limb lifted out.

In cases in which the absence of firm points of support makes a fixed dressing inefficient effectually to oppose the contraction of the muscles, as in most fractures of the thigh and many of the humerus, permanent moderate traction is employed to tire the muscles and obtain and maintain the desired length of the limb. For this purpose the partially unsupported weight of one segment of the limb may be utilized or a weight attached to the lower segment.

Traction by Weight and Pulley, or Elastic Traction. This method is employed almost exclusively in the treatment of fractures of the thigh. Methods of treatment by continuous traction have long been in use, but the efficiency and comfort which now make the method so

FIG. 43.



Adhesive plaster and "spreader" for Buck's extension.

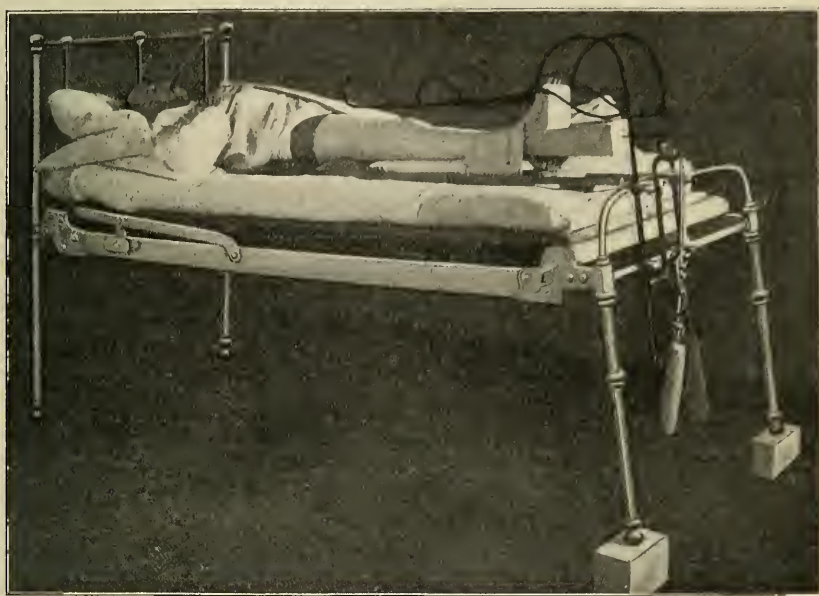
popular date from the introduction about the year 1850 by the American surgeons Sargent, Josiah Crosby, and Gordon Buck of the use of adhesive plaster to attach the weight or screw to the limb. Previously the attachment was by bandages about the foot and ankle, and the pain and damage to the skin occasioned thereby were such that efficient traction could not be maintained.

"Buck's Extension." (As for a fracture of the thigh.) Two strips of stout adhesive plaster, each four inches wide and long enough to reach from well above the knee to a little beyond the sole, are notched on each side at the junction of the lower and middle thirds for one-third their width, and the sides turned in, as shown in Fig. 43, so as completely to cover the adhesive surface of that portion. The sides of the remaining portion are obliquely notched at several points. A piece of wood, 5×3 inches, with a central hole, is then covered with adhesive plaster folded beyond the ends, as shown in Fig. 43.

A third piece of adhesive plaster a yard long and 2 inches wide is cut in two and the halves fastened together end to end by facing their terminal four or five inches; it is attached to the back of the calf, and brought along and well beyond the sole of the foot; a roller-bandage is applied to the foot and lower third of the leg, the first two strips of plaster placed one on each side above it so that their folded portions extend below the ankle, and the roller carried over them. Unless the fracture is too low the roller and strips of plaster should be carried well above the knee. The ends of the plaster on the wooden "spreader" are then attached by pins or clamps to the free ends of the lateral plasters so that the "spreader" lies squarely across the sole a few inches below it. A cord is then passed through the hole in the "spreader" and secured by a knot.

A Volkmann's sliding-rest (Fig. 44) is then placed under the leg, the foot lightly swung from it by carrying the free end of the third

FIG. 44.



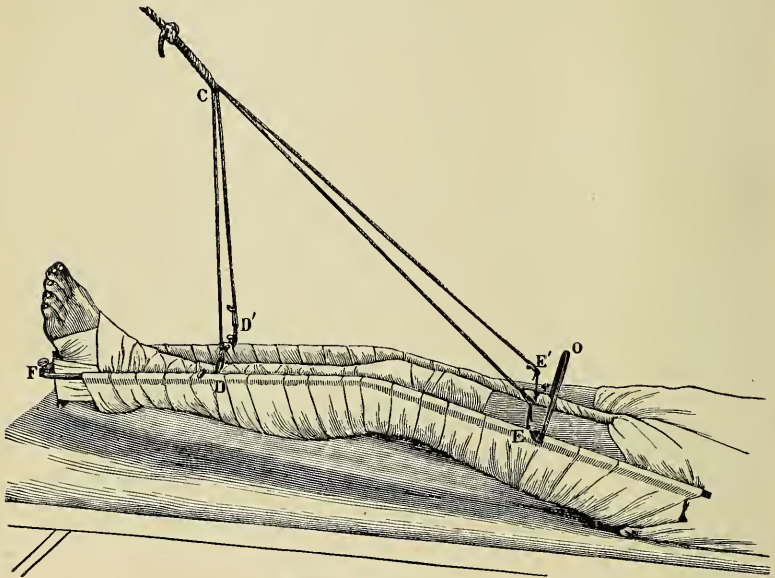
Volkmann's sliding-rest for fractures of the thigh.

strip of plaster over its top and sticking it to its lower surface, and the leg secured to it by a roller. This cord is then carried over a pulley at the foot of the bed, and a weight of from ten to twenty pounds attached. Counter-extension is made by raising the foot of the bed about four inches. Coaptation splints about a foot long are bound about the thigh to give lateral support.

Hodgen's suspended splint (Fig. 45) is a modification which gives more freedom of motion and consequently more comfort to the patient. It consists of two parallel iron bars, slightly bent at the point corresponding to the knee and connected at the lower end by a straight bar and at the upper end by a curved one. The leg and thigh are placed between these bars and suspended from them by half a dozen bands, and the ends of the lateral pieces of plaster are attached to the lower cross-bar, care being taken that they do not press against the malleoli, or by the cord of the spreader of Buck's extension. Then the limb is raised from the bed by a cord, as shown in the figure, which should be attached to a support at least four feet (better more) above the bed and so placed that the cord is inclined fifteen to thirty degrees from the vertical, and shall thus tend constantly to draw the leg downward; this furnishes the traction, and by moving the point of support to the outer side the position of abduction of the thigh, which is usually desirable, can be readily obtained.

The same method of traction is sometimes used in fractures of the thigh in connection with a *long side splint*, either with a weight and pulley or with an elastic cord on the side of the splint (Fig. 46), and also with one of the forms of hip-splints. A splint devised by Dr. Weed (Fig. 47) uses a steel spring to make traction, and contains many

FIG. 45.

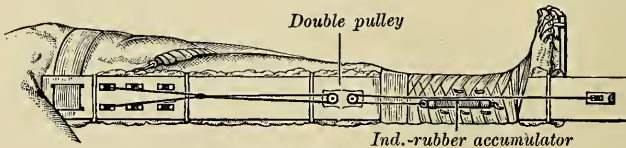


Hodgen's suspended splint.

ingenious devices to modify the amount of traction and to adapt the splint to limbs of different sizes. But in all such the pressure of the perineal band is likely to prevent efficient use.

Vertical suspension, for fractures of the thigh in infants and for some fractures of the arm, can be obtained in like manner by the use of the

FIG. 46.

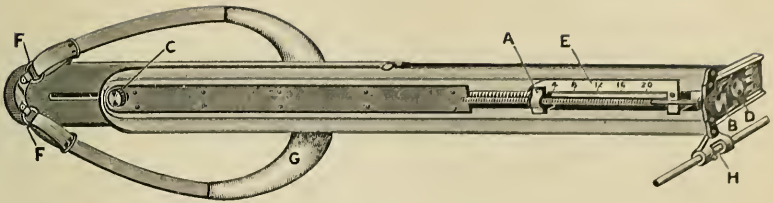


Long side splint with traction.

plaster strips and a cord carried to a point of support directly above the bed. (See Fig. 198.)

In the **double inclined plane** (Fig. 48) traction is made by the weight of the upper segment of the thigh and pelvis. It consists of two posterior splints, for the leg and thigh respectively, hinged at the knee and

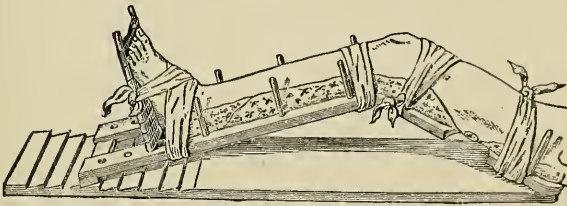
FIG. 47.



Weed's splint.

kept at the desired angle by a plank upon which they rest and to which the upper end of the short femoral splint is hinged. As shown in the figure the femoral splint is too long; it must be so short that the upper part of the thigh is wholly unsupported by it, and the mattress must

FIG. 48.



Esmarch's double inclined plane.

be so soft that the pelvis can sink into it, for it is by this sinking of the pelvis that the upper fragment of the broken thigh is drawn away from the lower one. It cannot be depended upon to give a good result in respect of shortening, but it is very convenient in some compound fractures.

Direct Fixation of the Fragments.

This can be effected in a variety of ways, the types being the suture, ligature, pin, and central or external brace. Even the plan of baring the ends and engaging them in a ferrule of bone has been employed in a few cases. It is rarely resorted to except in compound fractures, some special ones such as fractures of the patella, and in operations after failure of union.

In determining the advisability of resort to it in any case or in making choice of a method, consideration should be given to the following facts: The cases of fracture of the shaft of a long bone in which sufficient reduction cannot be maintained by a suitable external dressing are very rare. The cases are more frequent in which it cannot be completely made, or in which it cannot be certainly maintained during the application of the dressing. To make complete reduction exposure of the seat of fracture may be necessary, and in some fractures thus exposed and in some compound ones temporary direct fixation of the fragments may be advisable. In fractures of articular extremities the difficulty is in making reduction (or in being certain that it has been made) rather than in maintaining it, the exceptions being cases of

extensive splintering. In fracture of apophyses to which powerful muscles are attached, such as the olecranon, the coracoid process, the greater tuberosity of the humerus, the tuberosity of the os calcis, it may be impracticable to maintain a position of the limb in which the muscle is so fully relaxed that it will not renew the displacement even if it can be corrected, and in such the proper relations of the fragments can be secured only by direct fixation; but in most of such cases the continuity is maintained by periosteal or fascial attachments which ensure a union, bony or fibrous, sufficient for satisfactory function.

Another fact, to which I think far too little attention has been given, but of which I have been convinced by many observations, is that the presence of a foreign body, even if sterile and unconnected with supuration, in bone at or near the line of fracture notably exaggerates and prolongs the preliminary rarefaction of the bone. I believe this influence may even cause failure of union by transformation of a considerable portion of the bone into fibrous tissue, for in several cases in which I have operated for failure of union several weeks or months after a wire suture has been applied to the fracture I have found the suture lying free, and the ends of the fragments thinned and pointed and separated by a considerable intermediate mass of fibrous tissue. That the holes pierced for such sutures enlarge, and that the bone included in the loop wholly disappears is a common observation, and I believe the same change is promoted for a considerable distance round about, and although this ill effect is not to be expected always to follow, yet its possibility should be seriously considered.¹

In my judgment, direct fixation by suture or pins should therefore be only temporary, with the view merely of holding the fragments together during the application of a dressing and for a few days thereafter, and that the loop of a suture should include only a small portion of the cortical layer. Possibly silk and silkworm-gut are less injurious than wire, although I have known both wholly to free themselves in the same manner as wire, and I am not willing to advise against their use as absolutely as I do against that of wire, but I believe that with care in handling strong catgut will give all we ought to seek to obtain from a suture. I devised and have used in two cases a simple means of freeing a silk suture which also serves as a drain: a metal cylinder one-eighth inch in diameter and one or two inches long according to circumstances, with a broad, flat, transversely notched head. After the suture has been drawn through the holes drilled in the bone its ends are passed through the cylinder, which is then pressed down to the bone, and are tied tight about its head. After untying or cutting the thread all can be easily withdrawn. That the loop cannot be so tightly drawn as by a knot is no objection, for it should always be rather loose so as to diminish the chance of breaking by a bend or twist of the limb.

¹ Mumford (Boston Medical and Surgical Journal, May 10, 1894), in a report on 300 cases of compound fracture, noted that in twenty-seven primary wiring of the fragment was done, and that in seven of these necrosis followed.

v. Brunn (Beilage zum Zülblatt für Chir., 1906, p. 123) examined 12 cases of fracture of the patella treated by wiring. There was bony union in only 3; one silver loop was still in place, one had been freed by absorption of the enclosed bone, all the others had broken into two or more pieces, and in 3 cases pieces of the wire were found free in the cavity of the joint, causing constant discomfort.

Temporary fastening by nails or pins is applicable mainly to spongy portions of bone; it has been suggested for fractures of the shaft in the form of a long pin passed through the pieces, which are further secured by a thread thrown several times over the point and the shaft; by withdrawing the pin the thread is freed. In Parkhill's clamp one or two pins are passed through the skin into each fragment near the fracture and held together by a plate. An objection to pins reaching to the exterior is the difficulty of keeping their track aseptic; the objection is, of course, greater when the pin passes to the fracture.

The extent to which sublime confidence in the innocuousness of the knife may lead is indicated in the proposal of Niehans¹ to treat supra-condyloid fracture of the lower end of the humerus by sawing through the olecranon, stripping off all the extensor muscles, and nailing the fragments together.

A ligature thrown circularly, or better obliquely in notches, about the bone has been employed.

Fixation by a bone pin inserted lengthwise into the medullary canal, by an external metal plate screwed to the two fragments, or by pinning or screwing the notched and fitted fragments together has been practised, but mainly, I think, in operations after failure of union.

In fracture of the patella, in which a special indication for fixation exists, it has been my practice for several years to use a silk suture passed through the tendon of the quadriceps and the ligamentum patellæ and crossing the front of the bone, or simply two or three points of catgut suture in the fibro-periosteum at the edge of the fracture and in the capsule close to the bone. In fracture of the olecranon I have once or twice used a suture similarly passed through the tendon of the triceps and the firm fibrous layers overlying the ulna or through a hole drilled transversely in the ulna a short distance below the fracture.

To sum it up, direct fixation is very rarely necessary; when it is made convenient by an existing wound it should be temporary, by the use either of an absorbable suture or of one that can be easily removed after a few days. Pins reaching to the exterior are also objectionable because of the difficulty of keeping their track aseptic; the infection may spread to the fracture.

Massage.

Massage has shown itself after fracture, as after other injuries, so efficient to overcome the early and later swellings, stiffness of contiguous joints, and dryness and coldness of the surface, the conditions which delay convalescence and apparently prolong the period of repair, that a somewhat exaggerated impression of its value has found expression in some quarters, and it has even been proposed as a sole method of treatment to the exclusion of all retentive dressings. To these excessive claims has succeeded a calmer and more judicial appreciation of its merits and limitations, largely through the experience and writings

¹ Niehans: Arch. für klin. Chir., vol. lxxiii., part i.

of Lucas-Championnière.¹ It appears to be beyond question that by its systematic and skilful use in suitable cases the primary swelling is lessened and disappears more promptly, the circulation and skin more rapidly regain their normal condition, the atrophy of the muscles is less and more promptly disappears, and the joints more quickly lose their sensitiveness and regain the range of motion which is possible under the changed skeletal conditions; possibly that range after fracture at or near a joint may be increased by massage over what it would be without it, but if so the fact can hardly be demonstrable.

The claim that repair of the fracture takes place more promptly has not, I think, been substantiated and seems to me, moreover, possibly inconsistent with certain observations which indicate that repair may be delayed by insufficiency of reaction.

Whether these gains, which amount to a little more than a shortening of the period of after-effects, are worth the trouble and expense of obtaining them is an economic rather than a surgical question, and it is clear that they should be sought for only when there is no danger of making greater losses thereby—that is, in cases in which the tendency to displacement is slight and can be satisfactorily guarded against. This is the case with many fractures at the ankle, wrist and elbow, and of the fibula alone; and in some of the leg, forearm, and arm protected by moulded splints one splint will give sufficient protection while massage is made after removal of the other.

Massage is made by light rubbing toward the trunk with the fingers and then the whole hand, first beside the fracture and then, as tolerance is established, over it. The sittings should last for twenty or thirty minutes and be repeated daily. It has seemed to me that the repeated application of the elastic bandage was equally advantageous.

Ambulatory Treatment.²

The suggestions made a few years ago by an instrument maker in Germany that in fractures of the lower extremity splints should be used which would enable the patient to walk during treatment has led to considerable experimentation, the ultimate result of which seems likely to be of some benefit to the patient, although far less than is claimed by some who have sought to generalize the method. In estimating the value of the suggestion and determining the extent to which the previous use of the method can be broadened, we must discriminate sharply between the different forms of fracture. A man with a fracture of the fibula, of the external malleolus, even with a Pott's fracture, can often walk with comparative ease and security under the protection of a plaster-of-Paris dressing which limits the motion of the ankle-joint and prevents lateral strain upon it. And so too with fracture of the patella. To that extent there is nothing new in the idea, so far at least as the freedom from confinement is concerned. The claim now is that the method can be extended to fracture of both bones of the

¹ Lucas-Championnière: *Du massage dans le traitement des fractures*, Paris, 1895.

² For a thorough presentation of the history and claims of the method, see Guitard. *De la méthode ambulatoire dans les traumatismes osseux du membre inférieur*, Paris, 1903.

leg and even of the femur, that the loss of time and earning capacity is thereby lessened, that union takes place more rapidly, and that the joints more promptly regain their freedom of motion and the whole limb its normal condition. The comparison in respect of the last three points is one that is notoriously difficult to make with accuracy, and it has not been helped by the statistics that have been published, for they have included a large proportion of the slighter cases, and I think it must still be held that the claim has not been substantiated. As for the pecuniary value of ambulation on the splint, the advantage seems to me to be illusory; the splint is in that respect no better than a crutch, and although it may perhaps be at times more convenient it is at others less so.

On the other hand, the method exposes to risks of displacement and of healing with deformity which, in my judgment, outweigh even the claimed advantages, and the statistics show that the risk is a real one and that damage results in a considerable proportion of cases.

The principle of construction of an ambulatory splint for a fracture of the leg is to make it of plaster of Paris in a way to combine retention in the ordinary manner with a support on each side which extends well below the sole and takes the weight of the body through its attachment to the splint well above the fracture, the lower segment of the limb hanging between these supports and receiving none of the weight. For a fracture of the thigh the dressing is a combination of a fixed dressing and a hip-splint which receives the weight of the body at the pelvis.

It is admitted, I think, by all supporters of the method that it should not be employed until after the primary swelling has subsided and the early hardening of the soft parts about the fracture has appeared, say after a fortnight in a fracture of both bones of the leg. The limb is then covered with a plaster dressing applied directly over the skin except along the sole, where it is separated from it by a layer of cotton about two inches thick. Along the sole and on the sides of the limb the dressing is made very thick and strong and is sometimes reinforced by lateral strips of wood or metal. The other foot must be correspondingly raised by a thick sole. It is beyond question that if the method is employed the patient should be kept under observation and the same precautions as regards removal for inspection should be taken as have been shown to be necessary with other splints.

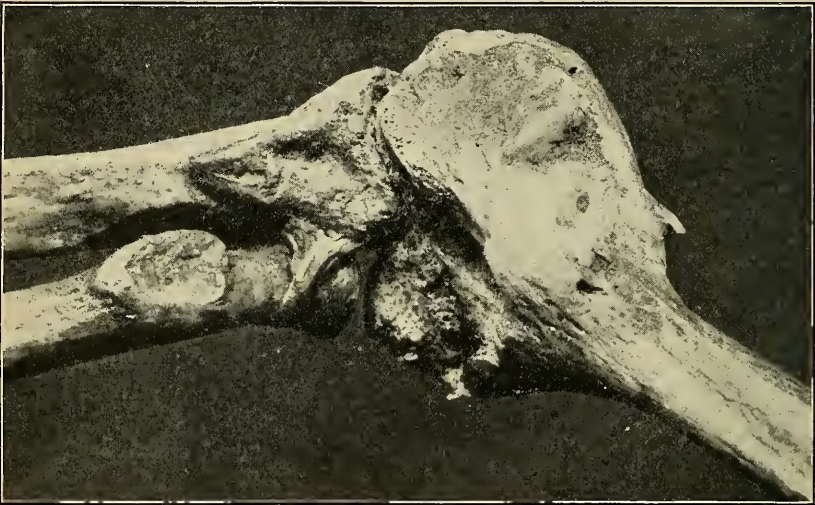
A safer plan, if it is essential that the patient should walk, is to use an ordinary hip-splint for ambulation, the broken leg being separately encased in plaster. The same plan can be employed in the later stages of fracture of the femur.

I have found that patients can sometimes walk about with the aid of two lateral strips of wood placed outside of an ordinary plaster dressing after it has hardened and supported by a shoulder or collar of plaster at its upper part, or by a light apparatus of two iron side-pieces fastened over a plaster dressing with straps and buckles.

Management of the Joints.

The joints in the formation of which the broken bone takes part, and often more distant ones, become stiff and sensitive during the period of repair and remain so for a longer or shorter time thereafter. This disability is specially marked and may become permanent in the old and rheumatic when the fracture has involved the joint or when the joint has been coincidentally sprained, and in the joints of the hand even when the fracture is of the arm or forearm. The causes are varied and numerous, usually unavoidable, and sometimes irremovable. The more

FIG. 49.



Bony ankylosis after supracondyloid fracture.

important and permanent are those arising from change in the shape of the articular end of the bone by uncorrected displacement of a fragment or by excessive formation of callus, or by ankylosis, and, in less degree, from thickening and retraction of the periarticular tissues and the formation of adhesions within the joint following its sprain or its share in the fracture. These are all the result of the primary injury and of the inflammatory reaction, overgrowth of callus being most common in the young because of the activity of the periosteum in bone formation at that period. Anything which diminishes that reaction and shortens its duration will, therefore, tend to diminish these hampering consequences; anything which augments it will add to them. This gives us a standard by which to measure the value and appropriateness of any method of treatment. Rest, massage, elastic compression have long since proved their value to reduce inflammation in joints and to remove exudates from within them and from the periarticular tissues; and moderate use, active or passive, to increase the range of motion after the inflammatory reaction has ceased. The

importance, and especially the respective timeliness, of these two opposing methods need to be fully grasped. The surgeon's dread of ankylosis, his ankylophobia, as it has been termed, too often leads him to move and even to force a joint while such motion will still be painful and will be followed by an increase in the reaction and a reduction of the range of motion, and, on the other hand, if he has well grasped the corresponding principle he is in danger of unduly prolonging confinement and thereby postponing and perhaps restricting the restoration of function. The criterion is a plain one: so long as the joint is swollen and hot, so long as its use is followed by an increase of swelling and heat and by persistent pain, so long must it be kept at rest and so long must active treatment be limited to massage or elastic compression; and, as a rule, this attitude of non-interference may be maintained without harm until after union of the fracture has become complete. Then he may resort to passive motion or may encourage the patient to gradually increasing use of the limb, and he will see the stiff joint rapidly regain its functions.

Forcible passive motion, with or without anæsthesia, is always harmful before the second month, and even after that time it is far more likely to do harm than good. About the only condition in which it can really help is that of isolated cord-like adhesions within the joint which can thus be broken without the probability of their reunion. Such a condition we have every reason to believe to be very rare. When the method is employed to increase a range of motion that has been restricted by the common causes, such as broad adhesions, retraction of the capsule with periarticular thickening, and bony irregularities, it accomplishes its object only by creating lacerations which necessitate immediate immobilization in order to check inflammatory reaction and which in healing re-create the original or similar conditions and even increase them. The procedure should, I think, be almost wholly abandoned, and in its place we should resort to massage, constant use within existing limits, and possibly to the recently introduced method of prolonged exposure to high dry temperatures, and these failing, I should prefer to expose the joint by incision in order to remove such intra-articular obstacles as might exist and be removable rather than blindly to seek to break and tear them without knowing what and where they are. Yet it must be added that occasionally joints at a distance from the injury may become so stiff and sensitive that the patient can make no progress in freeing them by use of the limb, but if once moved freely under anæsthesia they retain the mobility and lose the sensitiveness. At the ankle particularly such forcible correction of the position of the foot will enable the patient to stand upon it and thus begin the gentle use which is needed.

This general rule of immobilization needs one important addition with respect to the fingers. In the treatment of all fractures of the arm and forearm the fingers and thumb should be left free and the patient should be enjoined constantly to move them; in addition, if the dressing must include a portion of the hand it should be so arranged that the wrist will be in slight dorsal flexion, the fingers flexed but free to be extended, and the thumb abducted, because these attitudes tend

to retard and diminish the ill effects of confinement and lack of use. If the fingers must be confined it should be in flexion.

COMPOUND FRACTURES.

The points here to be considered are those connected with the management of the wound of the soft parts and the modifications imposed by its presence and character upon the details of reduction and retention of the fracture.

A very important difference is that between fractures by direct and fractures by indirect violence, because in the former the wound is usually large and so contused that its prompt uncomplicated healing cannot be expected, while in the latter it is usually made from within outward by the sharp end of a fragment, is small and clean, and may confidently be expected to heal within a few days under proper care, thus transforming the fracture into a simple one and putting an end to the special dangers which make the injury so redoubtable. Moreover, in the former, especially when the muscles as well as the skin are lacerated, the more virulent streptococcus and even the *B. aërogenes* infections develop with exceptional frequency. I have long noted this fact, the frequent development of these redoubtable infections amid bruised, torn muscles, when slighter contemporaneous wounds received under similar personal conditions and apparently exposed to the same contaminations ran an uneventful course. It is unreasonable to assume that contamination is limited to the severe cases; it must occur also in some, perhaps in many, of the others. The reason of its development in one and not in another must then be sought in the differing conditions, and I think it may be found in the lowered vitality of the bruised muscles, in the products of their changed metabolism, or in their lowered power of resistance.

These two varieties differ so greatly in prognosis and treatment that I shall seek to emphasize the distinction between them by a separate description, although it must be admitted that the special difficulties and dangers which characterize those by direct violence may also exist in those by indirect violence in consequence of unusual associated conditions more or less independent of the mode of production. The essential difference is in the condition of the wounded tissue: in the one, a lacerated contused wound, some of the skin about which, even if apparently uninjured, is almost certain to slough; in the other, a small clean wound almost as fit to heal as if it had been made on the operating table.

Compound Fracture by Indirect Violence, or with a Small, Clean Wound.

The patient is anesthetized and the skin about the wound is cleaned as for an operation. If the point of a fragment projects through the skin and is rather tightly grasped by it the wound must be freely enlarged, and it and the bone irrigated with an antiseptic solution,

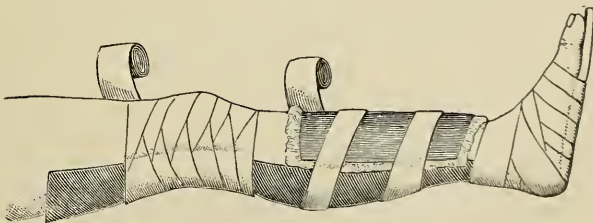
such as the 1-1000 bichloride; reduction is then made, the limb pressed to force out the escaped blood, the wound closed with interrupted sutures at half-inch intervals, and a sterile or antiseptic dressing applied, with temporary splints. Exceptionally it may be advisable to insert a drain of gauze or rubber, or to explore the wound to aid the reduction or to remove fragments, or to secure a torn vessel, but the less the wound is handled the better, because of the risk of contamination by the fingers.

About a week later the dressing is removed and if all has gone well the fracture is thenceforth treated as a simple one; but if infection has occurred the measures described in the next section must be employed.

Compound Fracture by Direct Violence, or with a Contused or Infected Wound.

The patient is anæsthetized, the skin cleaned, and the wound thoroughly washed out with an antiseptic solution; loose fragments are removed, the ends of the bones regularized if necessary, and the deeper layers of muscle and fascia fastened together by sutures so as to give support to the fragments; if deemed necessary a catgut or temporary suture may be placed in the bone to hold the fragments together. Then the enveloping fascia is sutured at a few points, not too closely, and the skin sutured so far as its condition permits. Drains of rubber or gauze are inserted, and a dressing placed over all. The limb is then placed in splints that will permit a change of dressing with the least disturbance of the fragments; for the leg Volkmann's splint is convenient, or the plaster stocking (page 93), or moulded anterior and posterior splints, one of which is placed if possible next the skin and protected by rubber tissue or Croux's paste (p. 95) from soaking by the discharge (Fig. 50). Later in the course, if the case does well, an interrupted or fenestrated splint may be used, but the dressing occu-

FIG. 50.



Compound fracture. Dressing and plaster splint.

pying the fenestra or interval must be bound on very snugly or the tissues under it will become œdematous and project through the opening. Suspension adds to the comfort of the patient and often to the convenience of the surgeon.

For the thigh Hodgen's splint is usually the most convenient, but the double inclined plane is sometimes better. For the arm, especially in fractures near the elbow, I like vertical suspension; it seems to

keep down the reaction very efficiently, but moulded splints are very convenient, as they also are for the forearm.

The condition of the skin about the wound in these fractures demands close inspection, for it is usually much more seriously and extensively affected than its appearance indicates. It is almost invariably stripped up from the underlying parts for a considerable distance and certain to slough, often over a large area, although it may show no sign of the injury received. (See page 68.)

I have experimented somewhat on the possible advisability of cutting away at once all skin that is clearly certain to slough in order to diminish infection and favor drainage from beneath it, but have not been able to satisfy myself that it is best to do so. If the infection is slight the skin mummifies and but little exudate forms under it, and it serves, by the sutures placed in it, to prevent retraction of the adjoining portions; it can be cut away later, in the second or third week. If, on the other hand, the case does less well the dying or dead skin can be removed at the second or third dressing with, I think, no serious loss from the attempt to utilize and save it. Extensively crushed and lacerated subcutaneous tissue can be satisfactorily treated with balsam of Peru.

Lacerated and divided muscles should be adjusted as nearly as possible in their normal relations and may be secured there by a few catgut sutures, but the main reliance upon their proper reunion is in the closing of the enveloping fascia over them, with intervals for drainage. Divided nerves and tendons are, of course, to be sutured, and torn vessels tied.

The proper management of fragments of bone is often a matter of anxious doubt and the surgeon must be guided somewhat by the probability of avoiding extensive suppuration, for fragments may safely be left in wounds that are to heal kindly which must certainly be removed sooner or later if suppuration takes place about them. It has been abundantly demonstrated that even wholly detached fragments can maintain or regain their vitality and be an important aid in establishing union between the main fragments if infection is avoided. If the loss of bone is considerable it is advisable to square the ends of the main fragments and bring them close together; in the leg this loss is usually at the expense of the tibia, and the fibula must then be correspondingly shortened.

If the laceration of the muscles is great, and persistent infection probable, abundant provision for drainage and irrigation should be made. Long fenestrated rubber tubes should be run through the limb, by counter-openings, and should project through the dressings so that an antiseptic solution can be frequently injected during the first few days or until the infection is under control. If suppuration becomes fully established it must be treated according to general principles, or amputation must be done.

Gunshot Fractures.

Gunshot fractures, when the missile is small, can generally be successfully treated by a single irrigation of the wound and an antiseptic dressing without removal of the bullet. It is very rare for a piece of the clothing to be carried in beyond the skin. When the missile

is a large rifle ball or a charge of shot at close range the destruction of the soft parts is such that prompt closure of the wound cannot be expected, and the case must be treated as one of the second class just described. I have recently, 1898, seen two cases of fracture of the upper end of the femur, one of the carpus and radius, and one of the humerus, by Mauser balls, which healed without supuration.

Amputation.

There is a class of cases, fortunately not a large one, in which primary amputation is clearly indicated, cases in which the fracture is only one, and sometimes not the most important, of the injuries received. The extensive destruction of the soft parts, sometimes also of the bone, makes it evident that the limb cannot be saved or that if saved it would be useless. The only question is as to the time and place of amputation. I am confident that in some of these cases a formal amputation well above the injury should be rejected in favor of division of the remaining soft parts at the upper limit of the laceration and the removal of only so much of the upper fragment as can be conveniently reached from the surface of section. These are the cases in which the soft parts have not been torn and bruised above the line of their division, and in which it is important to save as much as possible of the length of the limb, or in which a formal amputation would sacrifice a contiguous joint, especially the knee or elbow. Recovery of course would be slower, but under the protection of asepsis the stump would be more serviceable than those which were formerly obtained after supuration and whose defects led to the rule of practice which now, I think, needs revision. Such limited experience as I have gained in the matter encourages me to invite consideration of it.

Doubt as to the advisability of amputation and anxiety as to the result if amputation is not done arise in those cases in which the injury is not clearly destructive of the limb or its usefulness, but in which the attempt to save it will imperil life by the progress of an infection already present or certain to result from the sloughing of the bruised tissues. It is a peculiarly anxious question for the surgeon, for it involves his reputation for sound judgment as well as the welfare of the patient. Weighing the probabilities he may wisely decide that the chance of saving the limb or of its usefulness if saved is not such as to justify the taking of the risks involved in the attempt to save it, and yet if the patient refuses amputation and happily saves both life and limb the advice to amputate is likely often to be recalled as a reproach or an error of judgment. In some cases it is probable that under the protection of antiseptics the decision can be delayed until time shall have shown the full extent of the injury and the ability or inability to control the infection, with a reasonable expectation that a later amputation, if necessary, will still be in time to save life; but in other cases, particularly in the middle-aged and alcoholic and in those with diseased organs and tissues, the infection is so superior to the organism's power of resistance that if it is allowed to become fairly established death is inevitable. In the first set of cases the surgeon may fairly place the responsibility of delay, of taking the chances, upon the

patient or his friends ; in the latter he must throw the whole weight of his opinion unreservedly in favor of immediate amputation unless he is forced to believe that even that will be unavailing. An infection in a middle-aged patient which in a few hours has produced a condition of apathy or subdelirium, with brownish discoloration of the skin extending rapidly upward and a dark offensive discharge from the wound, cannot be arrested by amputation, except perhaps when it has not got above the knee or elbow ; but one which is marked rather by abundant suppuration, even with high fever, by less implication of the sensorium, and by a slower, reddish, boggy œdema of the parts about and above the wound can often be saved by amputation.

An interesting analysis of one hundred and thirty-seven cases of compound fractures of long bones has been made by Klauber.¹ Ninety were by direct, forty-seven by indirect violence. Twenty-four are classed as traumatic amputations, primarily operated upon to regularize the stump—one death ; fourteen were treated by primary amputation—two deaths ; fifteen treated conservatively—three deaths, and two successful secondary amputations ; average length of treatment one hundred and three days.

Compound Articular Fracture.

In these cases also conservative treatment has gained much additional ground ; the outlook and details vary, as in fracture of the shaft, with the character and extent of the injury to the soft parts. In addition to the principles governing the treatment of similar fractures of the shaft the surgeon has also to consider the conditions arising from the implication of the joint, especially the probability of the extension of suppuration to it and the effect upon its functions of such suppuration or of the injury itself. If the wound is small and clean its communication with the joint may be disregarded, or, at the most, drainage of the joint made and maintained for twenty-four to forty-eight hours. The principle in any case of moderate or extensive laceration and contusion of the soft part, in which the attempt is made to preserve all the articular portions of the bone and the functions of the joint, is to protect the joint by drainage against the consequences of primary infection and against later infection from the wound itself by assuring the early escape of the exudates of the latter. In the more severe cases—laceration, splintering of the articular end, free communication between the wound and joint—drainage may be made directly through the wound and even partial excision of the joint may be done to insure its thoroughness.

The probable effect of the injury to destroy the functions of the joint raises the question of resection with a view to restrict the loss. The answer varies with the joint and to some extent with the vocation of the patient, for at some joints and in some occupations solidity is more useful than mobility with insufficient control. Thus, at the knee anchylosis is preferable, at the ankle the removal of the astragalus may leave a useful limb, but anchylosis is better than removal of the lower portion

¹ Klauber : Beiträge zur klin. Chir., vol. xliii. p. 319.

of the tibia, at the elbow a stiff joint in a good position is more useful than one that is very loose for a man who has to do heavy work, while for one who does light work, using mainly his fingers and wrist, even a loose elbow would be better than a stiff one. We have learned too that partial resections under the protection of the antiseptic method give much better results in respect of mobility than they formerly did; thus, removal of the lower end of the humerus with conservation of the olecranon gives usually a more useful joint than total resection does.

GENERAL TREATMENT.

The vital indications in simple fracture of the limbs rarely arise except in the aged and the alcoholic. In the former the shock of the injury, frequently a fracture of the neck of the femur, occasionally proves fatal within a day or two, or the strength gradually fails and the patient dies about the third week, often with symptoms of localized pneumonia at the end. Against this there is little that can be done, except to avoid dressings which give pain and increase discomfort. I do not believe that the recumbent posture increases the latter danger or can be safely discarded during the first three weeks. At a still later period it may sometimes be advisable, because of the general condition, to take the patient out of bed even at the risk of failure of union.

In the alcoholic, it is important to maintain nutrition and secure sleep during the first week, and to give alcohol regularly in moderate quantities; it is claimed that the chance of an alcoholic outbreak—delirium tremens—is less if the patient is not kept in bed, and for that reason an early application of a fixed dressing is advised.

No medication, except tonics, appears to have any value in hastening or assuring union of the fracture except when some specific poisoning is present, such as syphilis or paludism, when mercurials and quinine are respectively indicated.

CHAPTER VIII.

DELAYED UNION, FAILURE OF UNION, PSEUDARTHROSIS, FAULTY UNION.¹

Delayed Union ; Failure of Union.

IN the use of the terms *delayed union*, *fibrous union*, and *failure of union* or *pseudarthrosis*, a certain vagueness of differentiation is inevitable because of the frequent lack of knowledge of the exact anatomical conditions and because the time requisite for the complete repair of a fracture varies so much in different cases that it may not be possible to say whether in a given case the process has come to a standstill or is still slowly but surely continuing. This vagueness, moreover, is not simply clinical but extends also to the anatomical condition, for in most cases this represents a stage through which the process of repair commonly passes, that of union of the fragments by a bond of fibrous tissue, and the abnormality consists in the delay or failure of that bond to ossify. Furthermore, as this final step, ossification, is often still possible after a delay of many months, a case which fully deserves, clinically, to be termed "failure of union," one in which special measures are required to excite ossification, is yet identical, anatomically, with another in which ossification will follow without other aid than the prolongation of the usual immobilization. The term pseudarthrosis, literally false joint, is not restricted to those rare cases in which some of the characteristic anatomical elements of a joint are present, but is used as a synonym of failure of union. In cases in which bony union is from the first unlooked for, or has been deemed unlikely, as in most fractures of the patella without operative treatment, the term "fibrous union" is habitually used instead of "failure of union."

While delay in union is not infrequent, failure of union is rare. The published statistics of failure differ so widely that it is evident the same basis of classification has not been followed, and probably those which give the large proportions include cases of delayed union and possibly even fractures of apophyses which are habitually so displaced by attached muscles that only fibrous union is probable. Failure is more frequent, actually and relatively, in the shaft of the humerus than in that of any other bone (except perhaps the radius and ulna), and in the prime of life than at any other age. It must be remembered that these statements and most of what follows relate only to the shafts of the long bones, and do not include fractures of the short bones, of apophyses, or even of the neck of the femur.

Pathology. Although the anatomical conditions differ greatly in

¹ For statistics see Norris: *American Journal of the Medical Sciences*, 1842, vol. xxix. Agnew's *Surgery*, vol. i. Gurlt: *die Knochenbrüche*. Bérenger-Féraud: *Traité des fractures non-consolidées ou pseudarthroses*, 1871. For experimental study: Cornil and Courday, *Revue de Chir.*, 24th year, No. 7.

detail they may be conveniently classified in two groups, one, containing most of the cases, in which the fragments are united end to end or laterally and more or less closely by fibrous tissue, and another, very rare, in which a distinct joint has formed between them. The varieties of the first form are very numerous, the variations depending upon the relative positions of the fragments, the extent of the preliminary rarefaction, the amount of fibrous tissue, and the presence or absence of a productive osteitis or partial ossification of the bond. In short, the process of repair in any of the widely different forms imposed upon it by the character of the fracture and the displacement may be arrested at any period or may be continued unevenly but still incompletely at different points. Thus, the fragments may be in close apposition and united by a short firm bond with only slight motion between them, or they may overlap in such a way that the surfaces of fracture are not apposed and the union is only by the thickened interposed connective tissue; or the displaced end may be enlarged, with osteophytes extending into the fibrous bond and separate nodules of bone developed within it, needing only a slight additional ossification for complete bony union; or the effect of the preliminary rarefaction of one or both fragments may not have been corrected by subsequent ossification, and they remain soft and spongy, or atrophied and pointed, and even this process of rarefaction may be so exaggerated as to create as distinct a gap between the fragments as if a piece had been removed or even to transform the entire shaft of the bone into a fibrous cord, or, as in a case of fracture at the lower end of the humerus reported by Machol,¹ to cause the disappearance of the epiphysis.

Of the second form, the creation of a joint between the fragments, only a few examples have been recorded. They show, in more or less complete and distorted forms, joints with a fibrous capsule embedding cartilaginous or bony nodules, a cavity containing a synovia-like liquid, and the ends of the fragments rounded, eburnated, usually enlarged, sometimes smooth and polished and sometimes covered with a fibrous or even a cartilaginous lining.

Etiology. Certain general conditions have been deemed a cause of delay or failure of union either through a specific poison, as in syphilis, or through a deterioration of the health or a lowering of the vitality induced by them, as pregnancy, lactation, defective nourishment, and acute diseases; but it is beyond question that the causes are usually local and that the most common one is a faulty relation of the fragments to each other, including therein the interposition between them of muscular tissue. Others are defective innervation, disease of the bone, inflammation on the surface, and defective treatment. But it is also true that delay and even failure may occur when no local or general cause can be found, when the fragments are in exact apposition, and when the general condition is good. We know that the less the primary displacement, the more exact the reposition, and the more complete the immobilization, the less is the local reaction and the smaller the callus. It is possible, therefore, that the reaction—the hyperemia and the exaggeration of the local nutritive processes—may be too slight or too brief to complete repair, but this only throws the

¹ Machol: *Centralb. für Chir.*, 1904, p. 1399.

question further back, and we have yet to learn why the reaction is insufficient in one case and sufficient in others which are apparently identical. In the leg and in the forearm a condition occasionally exists which is not found where there is only a single bone. For example, the fibula unites, but the rarefactive process in the tibia is exaggerated and leaves the fragments separated by quite an interval occupied by granulations, and the ossification which follows is not active enough to extend entirely across it. If the bone were single it seems not unreasonable to suppose that the fragments would be brought nearer together and the intermediate granulations stimulated by the pressure caused by the contraction of the muscles, but here the fibula holds the fragments apart. This exaggerated rarefaction can sometimes be directly observed in compound fractures, especially in the spongy tissue near the epiphyses. The delay commonly observed after resection for the relief of pseudarthrosis I attribute to the absence of a periosteal bridge.

The defective relations of the fragments consist mainly in a displacement by which the fractured surfaces are more or less widely separated and which is maintained perhaps by the interposition of muscle. This interposition, which has occasionally been demonstrated by operation, is thought by some to be by far the most common cause of failure of union, but in the present lack of observations the opinion must be deemed too exclusive. It is probable that when interposition occurs it is by penetration of the sharp point of one fragment into the overlying muscle. Another form of defective relations is constituted by the interposition of a fragment wholly or partially detached or by the loss, in a compound fracture, of one or more fragments and the consequent creation of a considerable gap.

Failure by defective innervation, as shown by Bognaud,¹ occurs when the trophic nerves or nerve centers of the limb are injured. Motor or sensory paralysis without injury of the trophic apparatus does not delay union. Bognaud collected six cases of failure of union of fracture of the leg with paraplegia due to injury of the spinal cord at or below the last dorsal vertebra, while in others in which the paralysis was incomplete or the spine was injured at a higher point union took place.

Local diseases, syphilis, cancer, etc., which by destroying or softening the bone lead to "spontaneous" or "pathological" fracture, act in like manner to prevent repair; and deep suppuration in compound fracture, which is usually associated with necrosis, is a frequent cause of delay or failure.

The presence of an open wound exposing a fracture, even when suppuration is slight and superficial, I have observed in several cases to be accompanied by marked hyperæmia and softening of the bone and by great delay in union of the fracture even when the fragments were in exact apposition.

Defective treatment includes the failure to correct the displacements which make union difficult and which might be corrected, to secure immobility and maintain it for a sufficient length of time, and possibly

¹ Bognaud: Sur l'influence de quelques lésions du système nerveux sur la formation du cal, Thèse de Paris, 1878.

certain errors of commission, such as the excessive use of cold upon the limb. Of these, frequent movement of the fragments upon each other has long been recognized as a potent factor in delaying union. It may be due to insufficient retention by the splints or to the indolence of the patient or to the manipulation of the surgeon in making early passive motion of a neighboring joint.

The return of mobility after union has become apparently complete, and even after the patient has used the limb for some time, is occasionally observed. In most of the cases probably the union has only been fibrous, although close and firm, and has slowly yielded under use; but in others, in which there is no reason to doubt the solidity of the union, the cause has been a local inflammation, such as erysipelas, or an ulcer, an acute febrile disease, or scurvy.

Symptoms. The persistence of abnormal mobility after a lapse of a period that is usually largely sufficient for union constitutes "delayed" union; the merger into "failure of union" is a matter of opinion rather than of exact definition. If the position of the fragments is good and the mobility slight the condition should be deemed merely one of delay for a much longer period than when the local relations are less favorable, and the usual treatment of a fracture should be continued; the instances are numerous in which union has finally become complete after the lapse of several months and without exceptional measures. On the other hand, failure may be predicated even before the usual time has passed if the position of the fragments is very unfavorable and the mobility still great.

The persistence of abnormal mobility is the pathognomonic sign, but it is occasionally difficult or even impossible of recognition either because it is very slight or because the fracture is so close to the articular end of the bone that the mobility is masked by the movements at the joint; under such circumstances the functional disturbance and pain may be the only symptoms. The abnormal mobility may be slight or very free, and is usually painless until its limits are approached or reached.

Functional disturbances vary with the extent of mobility, the limb, and the amount of the associated muscular degeneration; it ranges from complete disability to interference so slight as scarcely to be noticeable; in one of my own cases, a compound fracture, the patient preferred amputation of the leg to longer delay, and others have sought in amputation relief from the pain of the mobility. Others, again, are able to use the limb with the aid of a brace, and some even without it. In the shaft of the femur the disability is usually the greatest and is practically complete, but when at its neck the limb may be still quite useful; I have seen several such cases.

Treatment. When delay has occurred and the local conditions are such that union may reasonably be hoped for, the surgeon's first duty is to seek for and combat any general condition that may be at fault, such as syphilitic or malarial poisoning or defective nourishment, using the respective remedies and tonics, and perhaps giving preference among the latter to phosphorus or phosphate of lime.¹ Then he continues the immobilization, aiding it then or a little later by massage; this still

failing, he has choice of a number of mild measures to hasten the process, such as the application for a few hours, once or twice repeated, of a bandage about the limb above the fracture tight enough to cause venous congestion and swelling (Bier), the painting of the skin with iodine, or the injection of a few drops of tincture of iodine or of a 10 per cent. solution of the chloride of zinc into the periosteum and the fibrous bond at the fracture; or, in the case of the leg, if the mobility is slight and the fragment in good position, he applies a splint or brace by the aid of which the limb can be used in walking without too much risk of causing displacement, in the hope that the irritation thereby produced at the fracture may stimulate the process. Bier (*Medizinische Klinik*, 1905, No. 1) recommends the hypodermic injection about the fracture of 30 c.cm. of blood drawn from a vein of the patient.

If these also fail or if the condition calls for more pronounced measures, he seeks to produce a sharp reaction by forcibly and widely bending the limb at the fracture, under an anæsthetic, so as to tear the bond and measurably produce the conditions of a fresh fracture, or he passes a drill down to the bone, with or without incision, and perforates the ends of the fragments at several points. Bone and ivory pegs have been inserted into holes thus made and withdrawn after a few days or weeks, but apparently with no advantage over simple drilling.

Electrolysis has also been used with advantage, the needle being passed into the bond between the fragments.

Finally, the surgeon may freely expose the fracture by incision, resect the ends of the fragments, bring them into close and exact apposition, and secure them there by external dressing with or without the aid of a suture or other fastening applied directly to the bone. In the preceding chapter, I have given reasons for thinking that the presence of a permanent metallic suture or pin interferes with the processes by which alone union can be accomplished, and I must repeat my belief that sufficient security can be given by an external dressing, and that the usefulness of a suture is limited to keeping the fragments in position during the application of that dressing. No suture that can properly be used is strong enough to relieve the surgeon from the necessity of great care in handling the limb during the application of the dressing, not because the fragments have a great tendency to slip apart laterally, but because the angular deviations which are certain to take place bring a great breaking strain upon the suture. For this reason I believe that if any suture is used it should be of catgut or silk, and tied loosely so as to permit angular deviation within a moderate range. The best security, I believe, lies in making the ends of the bone square and then having an assistant press the lower segment of the limb forcibly against the upper one until the dressing has been completed. I have successfully operated upon at least six cases of failure of union of the femur in this way and without suture. I may add that I have seen as many cases of pseudarthrosis of the leg that

¹ Gauthier: *Lyon Médical*, June and July, 1897, reports the successful use in two cases of the thyroid extract to cause consolidation after delay of about three months; the remedy was used for between three and four weeks and union was then established. I have employed it in two cases without recognizable benefit.

had been unsuccessfully sutured with silver wire, and in all of them I have found at the second operation the wire lying loose and sometimes broken. (See also Plate XXXIX., fig. 2.)

If on resection the end of the bone is found thickened and dense I drill it in several places in order to promote its rarefaction by increasing the area of irritation, and under such circumstances the use for two or three weeks of a silk or other removable suture might further the same aim and thereby be advantageous. In the humerus and in the bones of the forearm I have used both absorbable and temporary silk ligatures.

A pin of bone or the thigh bone of a fowl has sometimes been inserted into the medullary canal to hold the fragments together; if a sepsis is preserved it may heal in, but it usually needs to be removed.

When failure of union has been due to loss of bone the gap has sometimes been filled and union obtained by pieces of fresh or decalcified bone over which the soft parts are closed by primary healing. Absolute a sepsis is necessary to success. Apparently the pieces act only mechanically by furnishing a framework within and around which the granulations grow and by filling the space which if left to be filled by the slowly forming granulations would collect the exudates and thus favor the spread of chance infection. It has also been proposed to fill the gap with powdered calcined bone on the theory that it would equally well fill the space and serve as a framework, and would also supply the lime salts needed for the formation of bone. The plan commends itself by its simplicity and cleanliness, for the powder can be perfectly sterilized by fire, and I have thought it might also be useful in delayed compound and even simple fractures, the powder being poured in among the granulations or introduced through a hypodermic needle mixed with water.

When loss of substance has occurred in one of two parallel bones, as in the leg or forearm, it is usually advisable, if the gap is not too large, to excise a corresponding piece from the other bone so that the fragments of the first can be brought into contact. When the gap has been larger in the tibia a solid limb has been obtained by dividing the fibula and uniting its lower segment with the upper segment of the tibia. In time the bone enlarges sufficiently to make the limb strong and useful.

Faulty or Vicious Union; Union with Deformity.

The use of these terms is restricted to cases in which the deformity or persistent displacement differs notably from the result usually obtained after that form of fracture; the term is not applied when the irregularity is slight or common. Thus it is not applied to moderate shortening by overriding in oblique fractures, to the shortening and outward rotation commonly seen after fracture of the neck of the femur, or to the deformity of the wrist so frequently seen after Colles's fracture. In short, its use implies a condition that might and should have been avoided.

Any of the possible displacements after fracture may remain uncorrected and produce this condition, but the most common are marked

angular displacement or rotation after fracture of the shaft and transverse displacement with overriding. Excessive size of the callus is sometimes included in this group and so is the inclusion in the callus of muscle, tendon, or nerve. The ill results are not limited to the change in the appearance of the limb, which is often marked and offensive, but include also an interference with function, which may amount to complete disability by shortening of the limb, by the deviation of its lower segment, or by restricting the movements of a neighboring joint either directly or indirectly by implication of its muscles. Thus angular displacement, with or without overriding, after fracture of the thigh near the middle may produce a shortening of several inches; angular displacement after fracture of the leg may so raise the heel or toes or invert or evert the foot as to make it difficult or impossible to place the sole squarely on the ground in walking; transverse displacement backward or forward close above the elbow may limit flexion or extension respectively, more, I think, by cicatricial implication of the muscle than by contact with the bones of the forearm.

Treatment. The method of treatment varies with the solidity of union, and therefore to some extent with the length of time that has elapsed. As persistent displacement is often a cause of delay of union and of early weakness of the callus, it is possible to correct the position by the hands alone at a much later period than under better conditions; that is, an angular displacement can thus be corrected by forcibly straightening the limb with the hands or with the knee pressed against the projecting angle. But little improvement in overriding is to be expected from such means because the cicatricial condition of the soft parts which maintains it cannot often thus be modified. A few cases have been reported in which continuous traction has been quite efficient. Gradual straightening has occasionally been effected by a lateral brace with transverse elastic pressure at the angle.

Refracture by specially devised osteoclasis has been much employed in the past for the correction of angular deformity, but has largely given place of late to open operation. Some of the instruments are very powerful and accurate in the application of the force. Union after early refracture may be confidently expected to require less time than after primary fracture. A serious obstacle to success may exist in the permanent retraction of the soft parts on the concave side when the deformity has long existed. The condition then resembles that of a bent bow, and as the length of the soft parts determines that of the limb the latter cannot be increased, and the bone can be straightened after breaking it only by forcing the ends of the fragments past each other, overriding.

Osteotomy meets the indications in the same manner as osteoclasis, but more widely and precisely, for it not only insures division at the chosen point, but it also permits the correction of lateral displacement and the removal of a V-shaped or longer piece if the condition is that mentioned at the close of the preceding paragraph. With strict attention to asepsis recovery is likely to be as uneventful as after osteoclasis, but it will be notably slower if bone is excised. Unless anatomical reasons to the contrary exist the incision should be made

longitudinally at or near the most projecting part of the bone, and should be long enough to permit free exposure and easy access to it; the management of the bone will be determined by the relations of the fragments and by the end in view, but in case of excision every effort should be made to maintain the continuity of the periosteum on one side and to restore it by suture on the other at the end of the operation.

In articular fracture with displacement, such as Pott's fracture above mentioned, the bone can sometimes be restored to place by open operation with considerable improvement in function. I have improved the condition in a number of Pott's fractures in this way; and in one of accidental refracture of the outer condyle of the humerus in which the primary fracture (two years previous) had resulted in considerable limitation of motion, I exposed the fracture by incision because of non-reducible displacement of the fragment, and was able so to place it that the range of motion was subsequently increased. Possibly a like advantage could be gained by a deliberate osteotomy and shifting of the fragments.

An excessive portion of callus or a projecting fragment which causes pain or ulceration of the skin by pressure can be removed by the chisel or rongeur.

CHAPTER IX.

GENERAL PROGNOSIS.

THE prognosis after fracture involves consideration of the effects of the injury in respect of the prolongation of life, the preservation of the limb, its usefulness if preserved, and the time required for recovery. The factors in the prognosis have been considered in detail in the preceding chapters and will only be grouped here for a more convenient general review.

The prognosis varies with the age and condition of the patient, the position and character of the fracture, and the complications present or possible.

The Patient. *Sex* does not affect the prognosis. *Age* has a considerable influence; the younger the patient the better the prognosis, because in the young fractures unite more easily and promptly than in the adult, and advancing years increase the probability of diminished vitality and of the presence of constitutional dyscrasiæ. In the old the prognosis is worse in respect of life, because of their diminished ability to withstand the shock and to bear prolonged confinement to bed and pain, and worst in respect of function because of the greater difficulty with which the affected soft parts and joints regain their original conditions. The reduction of vitality by degeneration or disease of various organs may have a similar effect. Chronic alcoholism exposes to an outbreak of delirium tremens and, as does also advanced age, to the so-called hypostatic pneumonias.

Sudden death by *fat* or *pulmonary embolism* is possible, but very rare, at any age and with almost any form of fracture.

The Fracture. In compound fracture the prognosis is worse in every respect than in simple fracture, and worse when by direct violence than by indirect violence because of the usually greater extent and severity of the associated lesions of the soft parts.

The fracture of the shaft of a long bone generally heals with some shortening, the chief exceptions being the incomplete and subperiosteal fractures of the young and transverse fractures in which lateral and angular displacements can be reduced or prevented.

Fractures of the short or spongy bones heal promptly, but the displacement, with or without crushing, cannot usually be fully corrected. Fracture of the spongy end of a long bone usually heals more quickly than fracture of the shaft, but occasionally delay, or even failure of union, is occasioned by exaggeration of the preliminary rarefactive process. Fracture of a flat bone is rather frequently followed by exaggerated formation of callus.

Fracture of one of two parallel and connected bones (leg, forearm) is more easily managed and has a better prognosis than fracture of both

or of a single bone, because the unbroken one acts as a splint; an exception to this is found when the fracture is accompanied by a loss of substance which creates a gap between the fragments.

Articular fractures and fractures near the joints are especially liable to be followed by limitation of motion in the joint; at the knee and elbow, and to a less extent the shoulder and hip, this is the rule.

No general statement of value can be made as to the time required to reach the final result after fracture or as to the completeness of restoration of function, and the statistics that have been collected are practically valueless because they do not completely discriminate between the different forms and ages of the patients. Each fracture or at least each class of fracture must be judged by itself, and in many a given case there can be no great certainty that it will not vary widely from the average. As I write this paragraph, I have just visited a patient who broke the outer portion of the head of the tibia seven months ago; I predicted great loss of motion and was gratified when at the end of about four months a range of 45° had been obtained, and yet within the last two months that range has been increased to 90° under natural use of the limb. I think it can properly be said that an uncomplicated fracture of the shaft of the long bone of the arm, forearm, or leg will, in the great majority of cases, heal without any diminution of the earning capacity of the patient after six months, and that almost all the remainder will have reached the same condition in a year. In fractures of the shaft of the femur more time is required, and the number of those who will remain more or less disabled is greater. As middle life is passed, the ability of the patient to adapt himself to changed conditions is less, the joints are more likely to be stiffened, and pain in the limb after fatigue or when the weather is cold and damp is more common. The latest statistics I have seen are those of Loew¹ and Ramsperger,² collected from the records of Aid Societies. Loew's were of 167 simple fractures of the leg; only one was permanently disabled, the others regained their earning capacity in an average of 101 days, 70 per cent. in 91 days each.

Ramsperger's, of 145 fractures of the leg, given in more detail, show complete earning capacity, after simple fracture of the shaft of both bones healed without deformity, restored in most during the first six months, in a few not until the third or fourth year; in those that healed with deformity (36 per cent.) the restoration was complete in 29 per cent., in the remainder the loss was generally less than 25 per cent. Of the compound fractures of the shaft complete restoration followed in 32 per cent., the loss in the remainder was usually less than 25 per cent.

Of the simple fractures of the malleoli there was recovery without deformity in 61 per cent., with deformity in 39 per cent.; of the former, restoration was complete in 75 per cent., of the latter, in 23 per cent. Two-thirds of all resumed work during the first six months, one-third during the second six months. After compound fracture there was always some loss.

¹ Loew: Deutsche, Zeitschrift f. Chir. vol. xlv. Abstr. in Centralb. f. Chir., 1897, p. 855.

² Ramsperger: Korresp. des Würtemb. ärzt. Landesvereins. Abstr. in Centralb., 1897, p. 735. See also Morian: Arch. klin. Chir., vol. 81, ii. p. 98.

After fracture of the fibula restoration was always complete, but sometimes much delayed.

Sauer¹ in 111 cases of fracture of one or both bones of the leg or of one or both malleoli (Pott's), found complete restoration of earning capacity in 75 per cent. after 16.4 months. The percentage varied from nearly 100 in patients under twenty years of age to about 33 per cent. in those over fifty years.

The more unfavorable estimates of results in respect of earning capacity, notably those of Lane, are entirely out of accord with my own experience and observation. I recently sent letters to all the patients who had been treated in the New York Hospital for fracture of the lower limb during the previous year and received answers from twenty-six as follows: Neck of femur, 3; limb nearly useless. Shaft of the femur, 4; limb as useful as before the injury. Leg, 10; in 7 as good as ever, in 3 good, but with some pain. Pott's fracture, 9; in 6 as good as ever, in 2 fairly good, in 1 bad.

¹Sauer: Beiträge zur klin. Chir., vol. 46, p. 184.

CHAPTER X.

FRACTURES OF THE SKULL.

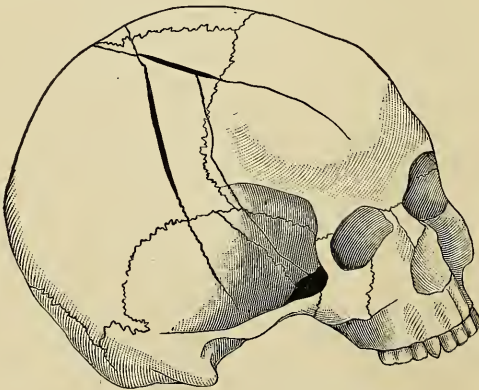
THE function of the cranium is so largely limited to mechanical protection of the brain and its annexa from external violence, its fracture in a great majority of cases involves after recovery so slight an interference with this function, and treatment can do so little to diminish this interference, that the importance of the injury lies almost wholly in the associated injury of the brain and in the later inflammatory or degenerative processes therein to which that injury or that of the overlying soft parts may give rise, and its consideration falls in the majority of cases rather under the rubric of injury of the brain than under that of fractures. It is unfortunate that these injuries should be so universally classed as fractures, for this leads to an undue fixing of the attention upon the lesion of the bone to the exclusion or minimizing of that of the brain and to undeserved reproach for occasional failure to recognize the presence of fracture. It should be remembered that the violence which causes fatal injury of the brain together with fracture of the skull may, under slightly changed conditions, cause the former without the latter, and that in a large proportion of fatal cases the fracture is merely an incident without any direct relation to the fatal result or only with that of having made the causative lesion possible. On the other hand, there is a class of fractures in which the lesions are entirely local and limited to the bone and the overlying soft parts, or in which, if the contents of the cranium are at all injured, the injury is limited to the immediate neighborhood of the fracture. In these the fracture is the essential lesion, and the treatment is almost wholly directed to it. Between these two forms—generalized contusion of the brain and its envelopes, with or without fracture, and circumscribed fracture with or without localized injury of the brain or meninges—there are others in which the character of the fracture and its mode of production are exaggerations of those of the second group, and the effect upon the contents of the cranium those of the first group. In the first group the fracture is usually fissured and almost always occupies or extends to the base of the skull, and hemorrhages covering a large area though limited in amount of extravasated blood are found upon the surface of the brain and sometimes within it and the medulla, indicating contusion; in the second the type is a compound circumscribed depressed fracture, possibly with a rent in the underlying dura; in the intermediate class there are the comminution of the second (but more extensive and associated with fissure) and the hemorrhages and the contusion of the first. In the production of the first the causative violence acts broadly upon the skull, modifying its shape through its elasticity and perhaps splitting it by exceeding the limits of that elas-

ticity, and bruising its contents by that modification of the shape and by the jar, as in a fall ; in the second, as in a blow of a hammer, the force is consumed in breaking the bone at the point of impact, there is no general change in the shape of the skull, no diffused effect upon the brain as a whole. Because of the mode of production fractures of the second group are usually compound. In the intermediate group the violence is greater than in the others, it breaks a larger area of bone and is not exhausted in producing the fracture. This difference in the mode of production and in the effects of the violence dominates the whole subject and determines the treatment and the prognosis. All this appears plainly in study of the mechanism, pathology, and cause of the injury in the various forms.

Mechanism and Pathology.

In studying the mechanism of fracture certain anatomical features of the cranium must be borne in mind. Of the vault and base of which it is composed in unequal parts, the former is globular, thick, and elastic ; the latter is flattened, irregular, thick in places, thin in others, and perforated at many points for the passage of nerves and vessels. From the occipital condyles, by which it rests upon the spinal column, pass outward, backward, and forward various thick portions or ridges constituting a strong framework to connect them with the vault ; the basilar process and body of the sphenoid, the occipital crest, and the petrous portions of the temporal bones ; further forward are the thicker portions of the greater and lesser wings of the sphenoid and the frontal crest. To a certain extent these ridges direct lines of fracture of the base to the thinner intermediate segments, but

FIG. 51.



Sword cut ; fissured fracture. (KÖNIG.)

all can be crossed by them. The vault, which varies greatly in thickness at different points and in different individuals, has a thick outer and a thin inner table of dense bone separated by the spongy diploë. The physical characteristic of the vault which most concerns us is its

elasticity, which is sufficient to permit a considerable change of shape without fracture—that is, a diameter of the skull can be shortened and those at right angles to it lengthened by compressing it in a vise, or a portion of its surface can be momentarily flattened by a blow.

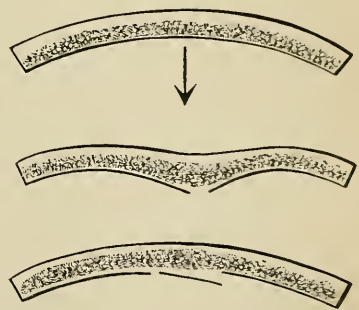
The effect of violence acting upon the skull varies with its character and the size and shape of the vulnerant body, and appears in all the gradations between a slight crush or cut of the outer table or of the entire thickness of the bone, through circumscribed depressed areas to single or multiple fissures running completely around. A cutting instrument, as a chisel or sword, cuts partly or entirely through the bone and by its wedge-action may produce long fissures running from each end of the cut if the weapon is heavy and the blow powerful (Fig. 51), or, if the instrument changes its direction, it may break off a piece of the bone and raise it above the level.

A moderate blow with a pointed or edged weapon may simply break the outer table, where the bone is thick, and depress it by crushing the underlying diploë, or, if the bone is thin, it may make a small rounded hole in it without splintering or fissuring of the side. If the instrument is not sharp or edged the bone is bent inward and the effect varies with the force of the blow and the prolongation of its action. In the slightest form the elasticity of the skull takes up and distributes the force without recognizable injury to the bone. If the force is a little greater the inner table, which is overbent in the movement, splits away from the diploë and is broken (fracture of the inner table alone), the unbroken portion springing back to its original position and leaving the fragment more or less removed and changed in position. The same effect has been produced in the outer table by a blow from within, as by a bullet that has traversed the skull from the opposite side.

If the force is still greater the bone is broken entirely through to an extent and in directions that vary widely, and the circumscribed portion remains more or less depressed.

If the lines of fracture do not entirely circumscribe the affected area the elasticity of the unbroken portion brings back the depressed piece toward or to its place (Fig. 53), sometimes imprisoning in the fissure a few hairs or a portion of the head covering. If the circle of fracture is complete the enclosed portion remains depressed, either bodily or, more commonly, with sloping sides (Fig. 54). From the edge of the opening, small fissures or circumscribed lines of fracture frequently run. The inner table is always more extensively broken than the outer one, and the two are largely separated from each other by planes of fractures through the diploë (Fig. 55). These fractures are almost always compound because of the character of the causative violence, the skin yielding

FIG. 52.

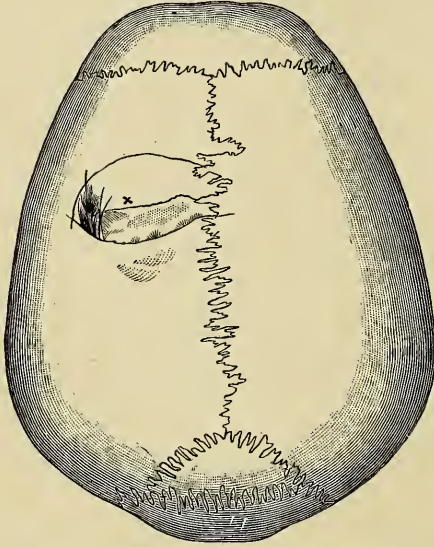


Mechanism of fracture of the internal table by bending of the bone.

under it as the bone does. They are part of the so-called "compound comminuted depressed fractures of the skull."

All of the injuries thus far described belong in what are termed the second group in the opening paragraph of this chapter, those in which

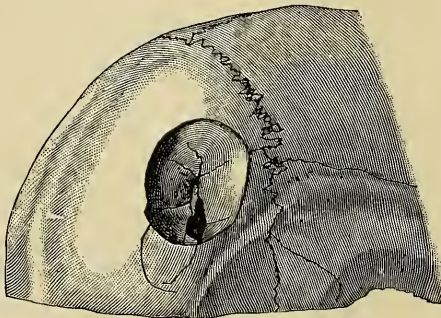
FIG. 53.



Circumscribed fracture with inclusion of hair. (KÖNIG.)

the dominant feature is the fracture and in which injury to the brain is usually absent or strictly localized. This feature is of so great practical importance that I wish it might be indicated in the classifying

FIG. 54.



Circumscribed depressed fracture. (KÖNIG.)

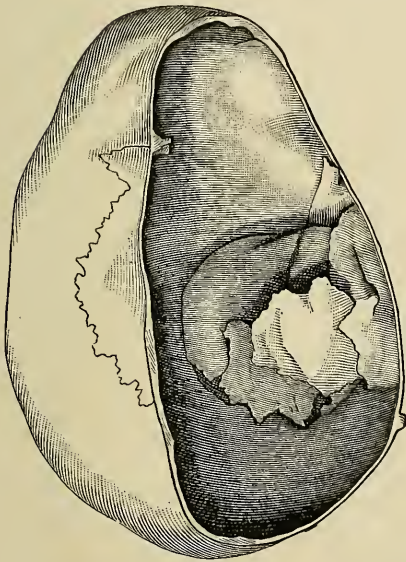
nomenclature, to the exclusion, or at least the great subordination, of "depression," which has long held the attention of the surgeon, to the hopeless confounding of radically different cases and the useless or

harmful generalization of therapeutic measures the value of which is strictly limited. I have long sought such a name that would be distinctive and short; possibly "circumscribed fracture of the vault" would serve the purpose, although it is far from meeting all the indications.

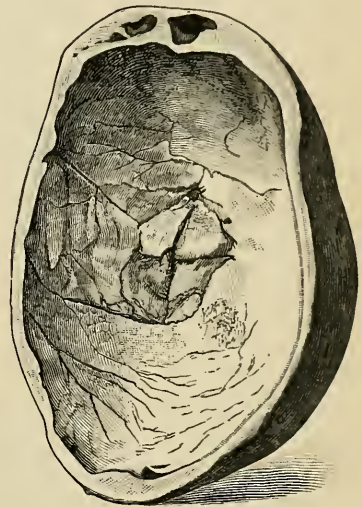
The vast majority of fractures of this class involve the vault, but they occasionally occur at the base, the vulnerant body reaching it through the mouth or orbit, and in a very few cases even the condyle of the lower jaw has been driven through the roof of its socket, or the ethmoid driven in by a blow on the nose. The prognosis is worse in these basal cases because important parts of the brain are usually injured, efficient treatment is impracticable, and infection is more likely to occur.

FIG. 55.

FIG. 56.



Circumscribed depressed fracture, inner side ;
healed. (KÖNIG.)



Fracture of internal table.
(BERGMANN.)

The other group of fractures, those produced by a force acting broadly upon the cranium to modify its shape as a whole, include almost all fractures of the base, and all so-called "indirect fractures" and "fractures by contrecoup" which have had so large a part in the discussion of this subject. In these, I repeat, the important lesion is that produced in the brain; the fracture is an incident, it usually has no influence upon the progress of the case and gives rise to no therapeutic indications. Similar brain lesions can be produced without fracture, and these cases belong among injuries of the brain rather than among fractures. This makes a detailed account of the many forms, their relative frequency, and their more or less hypothetical

relations to different forms of violence unnecessary in a work of the scope of this one.

The mode of production of these fractures has been the subject of close observation, experiment, and study by many, among whom I shall mention only Aran, Félizet, Messemmer, and Von Wahl. Another, Duret,¹ deserves to be remembered, perhaps above all others, for his remarkable investigations and his theory of mechanism by which the changes of shape of the cranium produce the often distant lesions of the brain and meninges, a theory which, even if carried in its details somewhat further than it can readily be followed, and possibly even incorrect, has yet been most valuable in fixing the attention upon the intracranial lesions and clearing away a large amount of nebulous theories concerning distant effects and their hypothetical causes.

The theory of these fractures as now apprehended is based in part upon the shortening of the diameter in the direction of the violence and the consequent lengthening of those at right angles to it, and in part upon the overbending of the bone under a like strain. In a globular body of uniform elasticity the shortening of one diameter under pressure is necessarily accompanied by the enlargement of the mass in the line of the equator and in the corresponding separation of the meridians. If the limit of cohesion is passed, separation (fracture) necessarily takes place between two or more meridians, and the line of fracture runs approximately from pole to pole—that is, from the point struck to one diametrically opposite—along a meridian. To these Messemmer gave the name of “bursting fracture.” Thus, in the skull, a blow received in the centre of the frontal bone and directed backward would shorten the antero-posterior diameter and enlarge the skull in the central transverse plane at right angles to the line of force, and, if strong enough, produce one or more fissured fractures running from before backward along the summit or side of the cranium. If the blow were received upon the side the lines of fracture would be transverse through the vault or base or both.

Under other circumstances not fully understood, but probably dependent upon lack of uniformity in or differing degrees of elasticity, the yielding along the line of impact is not so fully or so promptly met by expansion in the other plane, and the bone breaks at the point of maximum curvature at the periphery of the depressed area and along what may be termed a parallel of latitude, at right angles to the line of force, producing what Von Wahl names a “bending fracture.” Thus, a force acting from before backward upon the centre of the frontal bone would produce this form of fracture along a line crossing the cranium from side to side.

The lines of fracture produced in these two ways are modified by lack of uniformity in the shape and structure of the cranium and by the degree of the fracturing force; the majority of those involving the base and limited to a single zone occupy the middle fossa, and in those not limited to a single zone the violence appears to have been greater, and the portion of the vault which has received the blow shows ex-

¹Duret: *Etudes Expérimentales et Cliniques sur les Traumatismes Cérébraux*, Paris, 1878.

tensive splintering (Von Bergmann). The direction of fissures limited to the middle fossa is in the great majority of cases transverse, following one of two paths, either in the anterior part of the petrous portion of the temporal bone, parallel to its long axis and opening into the middle ear, or further forward in the great wing of the sphenoid. The cause is a blow upon the vertex or the side of the skull, and the fracture ends in the foramen lacerum anterius or in the sphenoidal fissure. If the force is greater the fracture may extend across the sella turcica into the opposite middle fossa, or obliquely through the sphenoid into the opposite anterior fossa, or into the anterior fossa of the same side. Fractures of the posterior fossa, caused by a blow on the occiput, are rarely limited to it, but cross the petrous portion to the middle fossa, but never cross the occipital ridge; and those of the anterior fossa usually pass through the upper margin of the orbit and run back to the optic or sphenoidal foramen, extending sometimes across the middle into the posterior fossa, sometimes also across the cribriform plate to the other orbit (König). In crushing fracture of the bones of the face longitudinal fracture of the base along the body of the sphenoid appears to be frequent.

That most of the fractures produced in this manner occupy the base with but little or no extension to the vault is to be explained by the less resistance of the base due to its relative thinness and its irregularity of shape and also, possibly, in part to the impinging force or the resistance of the body exerted upon the base by the spinal column through the occipital condyles. When the vault is more extensively involved the line of fracture may cross it completely in any direction either as a long fissure with little change of place or with a separation so free that the two halves of the skull can be freely moved upon each other. The internal table shows no splintering. The short isolated fissures distant from the point struck, which are seen not infrequently in the base and occasionally, but very rarely, in the vault, are produced in a variety of ways and will be considered in the following paragraph among the exceptional forms. Most of the extensive fissures of the vault belong in what was spoken of in the opening paragraph of this chapter as the group of fractures intermediate between the two main groups, those in which the causative violence is great and produces extensive crushing fracture at the point struck, with radiating fissures and generalized lesion of the brain. They are sometimes, but not always, compound.

Exceptional forms of fracture, the mode of production of some of which is very obscure, are found at many points. The small isolated fissures at a distance from, or even directly opposite, the point struck, to which the name "fracture by contrecoup" was given, belong almost all among the "bursting" or "bending" fractures, those of the base (when the blow has been received upon the vertex) being due to the resistance of the spinal column acting through the occipital condyles. The cases in which the fracture is directly opposite the point struck are so few and so doubtful that their existence has been denied, yet Perrin produced experimentally a fracture of the frontal bone by throwing a skull upon its occiput, and therefore the possibility must

be admitted. Inclusion in this group of fractures at such a point produced by a second blow directly upon it, as when a fracture of the occiput is caused by a fall upon the back of the head following a blow upon the forehead, is, of course, unjustifiable. A special group of nine cases collected by Von Bergmann¹ in which the orbital plate was broken is of great interest. In four cases the primary violence was by a glancing bullet, in the others a bullet penetrating the temporal (3), the occipital (1), and the parietal (1). In some only one orbital plate was broken, in others both; the fracture was either a straight fissure or circular; in President Lincoln's case² (perforation of the occipital by a bullet) both plates were broken and the fragments "pushed up toward the brain;" in two the fragments were depressed a few millimetres into the orbit. In an allied case a perforating bullet wound of the right parietal was accompanied by a fissure extending from the sella turcica through the great wing of the sphenoid. The explanation offered by Longmore³ and Von Bergmann is by momentary excessive intracranial pressure produced by the penetration of the ball or the bending inward of the vault.

Fracture of the posterior clinoid processes is occasionally observed, evidently produced by traction upon them by the attached tentorium during elongation of the antero-posterior diameter of the skull.

The so-called "ring fractures" about the foramen magnum caused by a fall upon the feet or buttocks are due to the impact of the skull, through the occipital condyles, upon the upper end of the spinal column, just as, to use Félizet's comparison, the head of a hammer is driven firmly down upon its handle by striking the other end of the latter against the ground.

Exceptional isolated fractures of the base by direct violence have been referred to, such as those produced by the passage of a bullet, a stick, or a knife through the orbit or the mouth, fracture of the ethmoid by a blow upon the nose, or fracture of the temporal by the pressure of the condyle of the inferior maxilla in a blow upon the chin. Fracture of the anterior wall of the auditory canal by the same cause deserves mention because of the bleeding from the ear which it occasions and which may be mistaken for that following fracture of the petrous portion of the temporal bone. These fractures owe their importance to the associated injuries of the contents of the cranium, especially of the carotid artery and cavernous sinus in wounds through the orbit, and to the possibility of the spread of infection from the outside to the interior.

Fractures of the Internal Table. These are apparently extremely rare. In the *Medical and Surgical History of the War of the Rebellion* twenty cases observed during the war are recorded and brief notes are given of twenty-nine cases reported during the preceding two hundred years. Von Bergmann describes three additional specimens. In the great majority of the reported cases the cause was a blow by a glancing bullet which exposed the bone but left the outer table uninjured or only grooved or contused; among the other causes are blows with small

¹ Von Bergmann: *Deutsche Chirurgie*, Lief. 30, p. 211.

² *Surg. Hist. War of the Rebellion*, vol. i. p. 305. ³ *Lancet*, 1865, vol. ii. p. 649.

round objects, such as a hammer, a cricket-ball, a beer glass; in only one case was the cause a fall upon the head. The alleged greater brittleness of the internal table appears to be entirely foreign to this limitation of the effect of the blow, the cause of which is the overhending of the table as described above.

The fracture may be a simple fissure, one side of which is slightly depressed, or circumscribing and detaching a scale of bone, or, more commonly, a comminuted one with a marked central depression (Fig. 56). The dura may be torn or the small fragment may be forced entirely through it. In one case the middle meningeal artery was torn. In some of the cases close examination after death has shown a slight fissure of the outer table and diploë. As almost all the reported cases have ended fatally, usually in consequence of suppuration of the superficial wound and extension of the infection to the interior of the cranium, it is possible that many other cases not thus complicated have ended in recovery and passed unrecognized; the inference then would be that the danger to life lay not in the fracture or in the displacement of a fragment but in the coexisting wound and the spread of infection from it.

The coincident injuries of the contents of the cranium are rupture of the dura and pia, laceration and contusion of the brain, rupture of arteries, venous sinuses, and cranial nerves, and multiple extravasations of blood from the smaller vessels on the surface of the brain and ventricles and less frequently in its substance.

The dura is rarely torn except when the fragments are notably driven inward, and then only to a moderate extent. Direct contusion and laceration of the brain, recognizable macroscopically, is found only under the same circumstances, but there is reason to believe that even in the slighter cases it receives a contusion which makes it peculiarly liable to be secondarily affected by infection proceeding from suppuration of the adjoining scalp; that is, central abscesses and cysts which are probably not the remains of hemorrhages are occasionally observed, the former after suppuration of the scalp, the latter after even simple fracture.

The hemorrhages from the vessels of the pia which are constant in the "bursting" and "bending" fractures are attributed by Duret to rupture of the smaller vessels by the sudden forced shifting of the cerebro-spinal liquid under the influence of the blow and the change in the shape of the skull thereby produced, by which certain portions of the space in which it is contained are sharply distended and the connected vessels torn. The effects are seen not only on the surface of the brain or in the subarachnoid space but also within the cortex and in the ventricles, especially the fourth, and it is to these that many of the cerebral symptoms are to be attributed. This also is the explanation of the presence of the hemorrhages found at points distant from the one struck.

Rupture of the middle meningeal artery is followed by increasing extravasation of blood, usually between the dura and the skull, with quite characteristic symptoms and the possibility of relief by operation.

Rupture of the cavernous sinus, and more rarely of the carotid artery

where it lies within it, is seen in some fractures of the base and especially in those due to the entrance of the vulnerant body through the orbit. Occasionally an arterio-venous aneurysm results. The other sinuses may also be torn when the line of fracture crosses them, but the complication seems rarely to be important.

Laceration of a cranial nerve is rare; the facial most frequently. But interference with function by hemorrhage into the sheath of a nerve is more common.

Pathological and Reparative Processes following Fracture.

These differ radically according as infection is present or absent, and while this difference does not exactly coincide with that of simple and compound fractures, yet the existence of an open wound in communication with or even near the fracture creates dangers which are almost wholly absent from simple fractures.

Repair of the fracture is effected largely by the diploë, and although the pericranium and dura can each produce bone they usually do so to only a slight extent, and consequently an overgrown callus is rare. Moreover, the osteogenetic action is rarely sufficient to close even a small gap in the bone, so that gaps created by the removal of fragments or trephining are habitually closed only by fibrous tissue with at the most a small margin of new bone along the edge of the opening. And yet in a case in which I removed fully two square inches from the frontal bone, broken by a blow with a hammer, I found twenty-five years afterward firm, apparently bony, resistance over the entire area. Depressed fragments heal in the position in which they are left, and large broad depressions in infants will often be diminished by intracranial pressure.

Persistent depression in the motor area may maintain a corresponding paralysis by its local pressure upon the cortex, but the weight of surgical opinion at the present time is opposed to the belief that it has any marked influence in producing irritation or other functional disturbances, such as epilepsy.¹ It has been abundantly shown clinically and by experiment that the brain readily accommodates itself to a marked diminution of the cranial capacity, and that even a sudden diminution must amount to about two cubic inches in the adult skull before it can of itself produce permanent symptoms of general compression. In very few fractures is the depression as great as that, and the symptoms which accompany it rarely differ from those of other fractures with little or no depression. That cerebral symptoms have been promptly relieved by the removal of a depressed portion of bone does not prove that the depression was their cause, for similar relief has often been given by the removal of portions that were not depressed or in any way altered, and even by operations on distant parts of the body. The clinical grounds for the belief that the scar following removal of a portion of the skull is able to cause functional disorders are as good as those that a persistent depression can do so. It seems

¹ See Von Bergmann, König, Hutchinson, in *London Hospital Reports*, vol. vi.; Echeverria, *Arch. Gén. de Méd.*, 1878.

probable that if the dura is torn, and intrameningeal adhesions thereby produced, the chances of chronic irritation and functional derangement are greater than if such adhesions do not exist.

Contusion of the brain and laceration of its vessels and of those of the pia, in uncomplicated cases in which the patient survives the primary injury, heal kindly, and the cases in which they give rise to a meningitis of any extent or importance are very exceptional. The extravasated blood is absorbed; or occasionally remains as a cyst. Occasionally, but very rarely, suppuration takes place beneath a simple fracture, just as it does in closed injuries in other parts of the body.

Generalized contusion of the brain, as seen in the "bursting" and "bending" fractures and in those of the intermediary group, is generally fatal, but not through meningitis. The lesions are more extensive than those of most apoplexies and apparently they kill in like manner. Even in fractures of the base with rupture into the middle ear the cases in which an intracranial infection has originated through this communication with the exterior are, in my experience, very rare. It is the cerebral lesion that kills, not the fracture or any secondary result of the fracture.

In compound fractures when infection is avoided repair goes on in the same manner; but if the wound suppurates the infection may spread not only to the bone but also, as in cases of phlegmon without fracture, to the interior of the cranium by lymph channels, connective tissue, and thrombi in the veins, and thus give rise to suppurative meningitis and pyæmia. In short, the progress of a case is determined mainly by the character and extent of the intracranial lesions and the presence or absence of infection, and the fracture, as such, usually has but little influence upon it.

Symptoms, Diagnosis, and Treatment.

The distinction which has been made between those cases in which the fracture is an important, perhaps the principal, lesion and those in which it is only a comparatively unimportant accompaniment of grave lesions of the brain and its annexa must here be kept constantly in mind. Fortunately, in the former, in which the recognition of the fracture is important because of the therapeutic indications which arise from it, the diagnosis is usually easy; and in the latter, in which the fracture seldom demands or can receive any direct treatment or affects in any way the prognosis, and in which the practical interest is limited to the intracranial injuries, the fact that the existence of a fracture can only be inferred, and not be demonstrated, does not leave us less able to do all that can be done for the patient. Instead, therefore, of following the usual division of the subject—fractures of the vault and fractures of the base—I shall use that of *circumscribed fractures of the vault and fissured fractures with generalized brain injury*, with separate consideration of the rarer forms which lie outside of this grouping. Furthermore, as diagnostic and therapeutic measures in many cases run closely together or even coincide, I shall at the same time consider the treatment.

Circumscribed Fractures of the Vault.

As these fractures are produced by a blow from a relatively small body or from one having an edge or corner, the fracture is often compound and the diagnosis is made by direct inspection and palpation of the bone. In most cases there is no difficulty; the fragments can be seen and felt at the bottom of the wound, and it remains only to determine the extent of the fracture and apply the appropriate treatment. In the doubtful cases the bone has to be carefully examined in search of a fissure, or its condition and the character of the violence considered as bearing upon the probability of a fracture of the internal table.

In respect of a **fissure** the edge of the torn periosteum can easily be mistaken for one by touch, or a cranial suture by the eye. The error in the first case is so easily made, even when one is on his guard against it, that the finger should not be trusted; in the second the fissure can generally be recognized by its bleeding, when fresh or when rubbed. The importance of its recognition comes from its possible indication of more extensive fracture beneath and from the frequent advisability of enlarging it for thorough disinfection.

When the bone is distinctly **broken and depressed**, even when the area is small, the depressed portion should be raised. If it proves to be only a fracture and depression of the outer table the operation needs to be carried no further; the wound is washed and closed. If the entire thickness of the bone is broken the deeper as well as the superficial fragments must be removed. It is rarely necessary to use a trephine for this purpose, for the corner of a chisel or elevator can be engaged under the edge of a fragment and thus raise it, and after one piece has been removed the removal of the deeper ones is easy, for they can be grasped with forceps and withdrawn by careful traction; the amount of internal table removed is usually greater than that of the outer table. If the dura is torn, and there is no bleeding from the pia, the opening in the dura should be closed with catgut sutures; if there is free bleeding from the pia the wound should be packed with gauze for a few hours, after which the opening in the dura may be closed. The overlying soft parts, including the pericranium as far as possible, should be closed with sutures, a small gauze drain being inserted and maintained for a day or two. The scalp should be shaved for some distance about the wound and thoroughly disinfected by scrubbing and washing with bichloride before anything is done to the bone.

When the gap left by the removal of bone is large and the wound is clean a thin sheet of aluminum, celluloid, rubber tissue, or foil cut to fit it may be inserted in it. The softer materials seem to answer as well as the firmer ones by leading to the formation of a thick and tough cicatrix. Gold foil or rubber tissue has sometimes been placed beneath the torn dura to prevent meningeal adhesions, but either is liable to induce exaggerated cicatricial formation. Freeman has lately recommended the use of the lining membrane of an egg.

Brewitt¹ has recently (1906) published a series of remarkable results obtained by replacing the fragments and closing the wound over them.

¹ Brewitt: Arch. für klin. Chir., vol. 79, p. 47.

Of 38 cases 2 died ; in all the others primary healing took place, and in 28 of them the fragments united solidly on a level with the adjoining bone ; in the others there was some depression of the surface. He also claims, with statistics in support, that patients thus treated are also more free from late ill effects.

In **small perforations**, as by a nail or even by the end of a small stick (the handle of a paint-brush in one of my own cases), the opening must be enlarged by the chisel or trephine for the better cleaning of the deeper parts of the wound ; and in pistol-shot fractures this is also necessary, but only for the same purpose and for the removal of the ball, if it is within easy reach, and of small fragments. Bullets can heal in, and without giving rise to late consequences ; and I think the risks of attempts to remove a bullet are greater than those of leaving it in place if the orifice of entry is the only communication with the exterior and can be thoroughly cleaned. If the bullet in its passage has opened the ethmoid cells or the frontal sinus infection from that side is probable and the bullet should be removed if possible, but whether it is removable or not the prognosis is thoroughly bad.

In any of these cases there may be free hemorrhage from within the cranium and escape of brain tissue, or, very rarely, a flow of cerebrospinal liquid coming from the subarachnoid space or even from the lateral ventricle. Bleeding from a wounded sinus can be arrested by lateral ligation or suture or by packing.

Circumscribed depression without wound of the soft parts may be recognized by the finger, which when carried firmly along from the adjoining bone appreciates the change in level, but a very similar sensation is given by the swollen circular margin of a deep contusion ; that is, the finger passes over a firm rim to a soft central area which suggests depression. Error can be avoided by making firm pressure on the hard margin and then passing slowly toward the centre ; the margin yields under the pressure and the finger recognizes the level resistance of the bone throughout.

In these cases, as in the preceding, general symptoms—cerebral shock or contusion—may be slight, transient, or absent ; the stunning, the partial or complete unconsciousness passes and is perhaps followed by nausea and headache ; if they are more than this they indicate generalized lesions that bring the case into the intermediate group, to be subsequently considered. If the depression is immediately over a portion of the motor area or a special centre there may be a corresponding paralysis or abolition of function. Very rarely a fluctuating tumor may form under the skin which on puncture proves to contain cerebrospinal liquid that has escaped through the torn dura. This has been observed only in young children.

In the treatment of these simple circumscribed fractures with depression there are two things to be considered : the effect upon the brain and meninges if the depression persists, and the risks involved in relieving it. The reasons have been given above for the belief that persistent depression is not often responsible for the late functional disturbances that have been attributed to it, and that consequently it does not, in the absence of special indications, imperatively require relief. But,

on the other hand, although it is properly urged that the unbroken skin is a safer protection against infection than the strictest asepsis (König), yet the danger incurred in making an opening in the vault of the cranium, especially if the dura is not wounded, is so slight that I cannot criticise those who act upon the conviction that it is less than those of persistent displacement even when the disadvantages of the resultant gap are taken into account. This applies only to small areas of depression and the removal of only a small portion of bone. The special indications referred to, which call for operation, are found in the evidences of localized pressure or of hemorrhage from a branch of the middle meningeal artery. (See below.) The value of a localized symptom (monoplegia, etc.) is much greater in a fresh injury than when it occurs after the lapse of a few days, for in the latter case it may be due to the spread of inflammation from a primary focus at some little distance from the centre which corresponds to the paralysis.

Fissured Fractures with Generalized Brain Injury.

These, let me repeat, are the "bending" and "bursting" fractures produced by violence acting broadly upon the skull, changing its shape temporarily beyond the limits of its elasticity, and causing contusion of the brain with larger or smaller hemorrhages especially upon its surface. In the great majority the fracture occupies or extends to the base of the skull, and the injury is hence generally spoken of as *fracture of the base*. The principal injury is the lesion of the brain, and the associated fracture is mainly of importance as indicating that the injury to the brain is probably extensive and grave. The opinion long held that fractures of the base were necessarily fatal has been shown to be exaggerated,¹ but yet the percentage of mortality is high, and similarly produced fractures of the vault have a like gravity. In ten years—1895–1904—319 cases of fracture of the base were treated at the Hudson Street Hospital, with 206 deaths. The chief symptom of the brain injury is unconsciousness, more or less complete, with the history of a blow, irregularity of the pupils, and a moderate rise of temperature. The high temperatures which have been spoken of as constant, 105° to 107° F. (Phelps), I have seen only in the few hours before death. Paralytic symptoms and symptoms connected with the circulation and respiration depend upon the portions of the brain and medulla involved in the injury.

The differentiation is with other forms of coma, especially the alcoholic, and is often extremely difficult or even impossible, as when alcoholism coincides with trauma. The points of difference (with many exceptions) are that in alcoholic coma the temperature is not raised, the unconsciousness is less deep, the pupils are equal and responsive. It must always be remembered that the two conditions may coexist.

¹ Graf (Deutsche Zeitschrift für Chir., vol. lxxviii, p. 464) gives statistics of 90 cases of fracture of the base treated at the Charité in Berlin between 1896 and 1902, including the condition after recovery in 48 of them. There were 34 deaths. The most common late result was diminution of the hearing in 27 of 39 cases examined. In 2 there was persistent facial paralysis.

During the past year I have withdrawn by lumbar puncture a few drops of the cerebrospinal liquid in many cases of unconsciousness due to various causes, in the hope of finding that the presence or absence of blood in it would aid in the differential diagnosis. Blood was almost invariably present in fracture of the skull, and also in many apoplexies. The diagnostic value of its presence is considerably diminished by the fact that it is caused not infrequently by the puncture itself, presumably by wounding a meningeal vein.

The symptoms belonging to the fracture itself are hemorrhages, ecchymoses, occasionally a watery discharge from the ear or nose, and deafness of the ear of the affected side.

Hemorrhage from the ear, nose, or mouth is frequent, that from the ear being almost pathognomonic of a fracture through the petrous portion of the temporal bone; it is usually slight but may be profuse. König refers to a case in which the flow from the middle ear through the Eustachian tube into the mouth was so abundant that he felt obliged to do tracheotomy to prevent suffocation. Bleeding from the ear which may be mistaken for that of a fracture of the base may be due to rupture of the membrana tympani or to injury of the external auditory canal by a blow upon the chin which has forced the condyle of the jaw backward, or even to a fissure of the vault extending to the mastoid process.

Ecchymosis at certain points, not due to direct contusion, is significant of fracture. The most common is that beneath the ocular conjunctiva, spreading to that of the lids and then to the skin of the latter; it is most constant and marked in fractures of the orbital plate and sphenoid. A slight ecchymosis behind the ear is often found after a day or two.

A **watery discharge** from the ear after fracture of the base is not infrequent and is sometimes very profuse (in one case 63 ounces in four and one-half days). Four varieties differing in the amount and character of the discharge have been observed: (1) The flow is abundant and prolonged, the liquid contains a large proportion of chloride of sodium and but little albumin, and is then doubtless the cerebro-spinal liquid of the subarachnoid space and sinuses escaping through fracture of the internal auditory canal and rupture of the tympanum. (2) The flow is similar, but the liquid is highly albuminous and without chloride of sodium; autopsy in some cases has shown a fracture through the middle and internal ear but not through the internal auditory canal; the liquid is probably lymph coming from the large arachnoid lymph-space which normally communicates with that occupied by the perilymph of the labyrinth or liquid Cotunnii. (3) The flow is abundant and albuminous, becoming scanty and purulent; probably an inflammatory discharge from the surface of the cavity of the tympanum. (4) The flow is scanty, appears late, is albuminous and reddish, and is probably the serum of extravasated blood.¹

Deafness of the ear of the affected side is due to injury of the middle or internal ear or of the acoustic nerve in its passage through the bone.

¹ For interesting details of these symptoms the reader is referred to Hewett, in Holmes's System, vol. i.; Von Bergmann, in Deutsche Chirurgie, Lief. 30, and Roswell Park.

Paralysis of other cranial nerves is occasionally observed, the result of direct injury of the nerve or of pressure upon it by extravasated blood; the facial is the one most frequently affected, then the abducens. Paralysis of the limbs is caused by intracranial hemorrhage. Slowing of the pulse and irregularity of the respiration indicate hemorrhage in the medulla.

Fissured fractures of the vault are sometimes recognizable by a difference in the level of the two sides and even in rare cases by the independent mobility of the two parts of the cranium. Auscultatory percussion has been alleged to be a means of recognition of a fissure, but I have found it wholly untrustworthy. The general symptoms are the same as when the fracture occupies the base and are dependent upon similar lesions of the brain.

Emphysema of the scalp is a rare symptom and is due to the escape of air into it after fracture opening the mastoid, frontal, or ethmoid sinuses.

The **treatment** of these fractures is medicinal and expectant: absolute quiet, light diet, laxatives, and cold to the head if indicated by restlessness, headache, or other symptoms of cerebral irritation. In fractures of the base with bleeding from the ear a light plug of iodoform gauze may be placed in the external meatus, but more active measures to disinfect this region seem to me wholly uncalled for in view of the fact that a route for infection from the mouth through the Eustachian tube remains and cannot be protected.

When the fracture involves the vault and is compound the wound should be thoroughly cleansed, and to this end it is proper to chisel away the sides of the fissure, but I do not think it judicious to enlarge the wound in the scalp in order to follow up the fissure and treat it thus throughout its entire length. The interference is solely for disinfection, and in fresh cases we may be confident that infection has not passed much beyond the limits of the external wound. Depression of one side of a fissure of the vault is not a justification for making an incision through the unbroken skin.

The same principles apply to the treatment of the intermediary group—extensive comminuted fractures with marked general cerebral symptoms. The important lesion is that of the brain, and it is not probable that good can be got by removal of fragments or relief of depression that will compensate for the risk incurred in dividing the unbroken scalp. Possibly the relief of tension by draining away the exudate through an incision may be an important advantage, but this has not been demonstrated. If the fracture is compound the wound must be cleaned and protected, and advantage may be taken of it to do whatever the condition of the bone requires, but this cannot be expected to have any important influence upon the progress and outcome of the injury.

Certain exceptional forms of injury require separate description.

Possible Fracture of the Internal Table.

When the skull has been contused (compound) by a blow of the kind known sometimes to produce fracture of the internal table, such as a glancing bullet or a sharp blow by some small object, there can be

no serious objection to trephining in order to insure cleanliness and determine the condition of the internal table, if care is taken not to open the dura; and even when the skin is not broken, if well-marked symptoms of localized cerebral injury are present, a similar interference would, I think, be justifiable as an attempt to relieve a *local* and *limited* injury. But, I repeat, the known instances of fracture of the internal table alone are very few, and almost all of them compound and fatal by infection through the scalp wound. If it is claimed that there are many simple (not compound) ones which pass unrecognized because the patient recovers, it must be added that that then is proof that an operation is not always necessary. The diagnosis of probable fracture of the internal table has been not infrequently made for no better reason than that no other could be positively made. Such mistakes would be less frequent and officious treatment would be rarer if the fact was fully appreciated that early general cerebral symptoms mean generalized cerebral lesions, and that such cannot be relieved by local measures. For the latter there must be local indications.

Rupture of the Middle Meningeal Artery.

Rupture of the middle meningeal artery or of one of its branches by a fracture crossing its course, or even without fracture, is a not infrequent injury of great importance and requiring immediate operative relief. As the vessel lies in a groove on the inner surface of the bone and is covered by the dura, the hemorrhage commonly takes place between the dura and the bone, stripping up the former sometimes for a considerable distance and causing symptoms of local and sometimes of general compression. Usually there is an interval, half an hour to three hours (occasionally very much longer, even eight days in one of König's cases and four days in one of mine), between the blow and the development of the symptoms, an interval during which the patient may seem entirely well, but which in other cases may be masked by the symptoms of cerebral injury occasioned by the primary violence; the recognition in the latter case must then come through the steady increase in the symptoms and frequently the limited paralyses caused by pressure upon portions of the motor area. The pulse becomes slow (pulse of pressure), and the pupils unequal, that on the side of the injury being usually dilated. The paralyses, of course, are on the opposite side of the body; if limited they indicate a hemorrhage between the dura and the bone; if diffuse, a hemorrhage into the arachnoid space.

Left to itself the injury terminates fatally in the great majority of cases. Relief must be given by removal of the extravasated blood and arrest of the bleeding. The difficulty may be to determine the point at which the trephine is to be applied to meet the indications; the guides thereto are furnished by external evidences of injury, the seat of the fracture, the situation of the centres corresponding to the paralyses, the anatomical relations of the artery, and the relative frequency of hemorrhage at different points. The artery runs from the foramen spinosum across the middle fossa and upward along the greater wing

of the sphenoid and there divides into two branches. The most frequent seat of rupture and hemorrhage corresponds to the lower anterior portion of the parietal bone (anterior branch of the artery); the next, but much less frequent, corresponds to the lower posterior portion of the parietal and the adjoining portion of the occipital (posterior branch).

The size of the extravasation varies greatly; I have seen one of less than an ounce directly above the ear in which the symptoms—stupor and limited paralysis—were well marked and which was cured by operation.

If the exact position of the extravasation cannot be determined and if no indication is furnished by a line of fracture or paralysis, an opening made near the point where the frontal, parietal, and temporal bones meet, say two finger-breadths above the zygoma and an inch behind the external angular process of the frontal, will expose the most frequent seat and also the anterior branches of the artery. An opening about three inches directly behind this will expose the posterior region.

The opening should be made with the trephine or by removing a broken fragment, and if the extravasation is not at once encountered the dura should be carefully separated from the bone in different directions in search of it. When found the blood should be picked or washed out if clotted, and bleeding points should be secured if possible, or, failing that, the wound should be packed in their neighborhood. The artery is often difficult to secure, especially when its point of rupture is not within the opening made by the trephine. Temporary pressure with the finger, an artery clamp, or even a pad of gauze has been successfully employed. In all my own cases the bleeding has stopped spontaneously before the removal of the clot.

Perforating Fractures of the Base through the Orbit.

Perforating fractures of the base through the orbit are extremely grave and rarely accessible to treatment, the important lesion being usually that of the brain. In the extent of these lesions and their consequences the variations are very great. I have seen the breech-piece of a shot gun, about six inches long, driven into the brain through the nose and orbit and carried there, unrecognized, for more than two months, the patient recovering sufficiently to take a railway trip to the city in order to have the deformity of his face relieved; and in another a single birdshot which entered just above the tendo oculi and passed through the lower part of the frontal lobe directly back nearly to the Sylvian fissure caused death in a week without any evidence of inflammation and with only a minute intracranial hemorrhage. Sometimes an important feature is the wounding of the cavernous sinus or of a large artery. Another, and frequent one, is the infection of the deeper portion of the wound by the vulnerant body even if the superficial portion of the wound is small and heals kindly. The common cause is the passage of a small body—a bullet, cane, pencil—through or even between the eyelids. I have seen two cases in which a slender stick (the end of an umbrella in one) had thus penetrated and had broken off; both patients died, one after removal to another hospital and opera-

tion there by the large omega-flap to expose the base of the brain, profuse venous bleeding which could not be arrested was encountered and the patient died shortly after removal from the table.

Similar wounds through the nose and mouth are even more exposed to infection.

Summary.

The principles of treatment may be thus summarized: Danger to life and function comes mainly from generalized contusion of the brain, large or small intracranial hemorrhages, and intracranial infection through an open wound; the fracture itself, as such, even when associated with depression, is rarely a factor in the fatal result.

Against generalized cerebral injury the only treatment is medical—rest, sedatives, laxatives, cold to the head. Against infection we have prevention and disinfection; after it is fairly established disinfection and drainage have a restricted availability. Consequently, fractures of the base and fissured fractures of the vault not compound do not require operation. When compound, the wound may be enlarged sufficiently to permit disinfection of the area already exposed to infection; and for the purpose of this disinfection a fissure may be enlarged, but this enlargement should not be carried much beyond the limits of the original wound.

Depression of a portion of the skull below its normal level is not a condition which always needs to be corrected. The associated conditions which *indicate* its correction are limited paralyses due to pressure of the depressed portion upon the underlying portion of the brain. Conditions which *justify* its correction are an associated wound of the scalp and, in simple fractures with a well-defined small area of depression, the absence of symptoms of generalized injury of the brain and consequently of fissures radiating from the depressed area which would favor the extension of infection if it should occur in the wound made for the relief of the depression.

Epidural or subdural hemorrhage (rupture of the middle meningeal artery) requires operation for the removal of the extravasated blood and the arrest of hemorrhage.

A monoplegia promptly following a blow upon the head is an indication for the application of the trephine over the corresponding cortical centre, with the expectation of thereby removing a clot or a fragment which is making pressure on that portion of the brain.

Late functional cerebral disturbances (epilepsy, etc.) appear to be so much more closely connected with injury of the brain and meninges which cannot be corrected by a primary operation than with traumatic irregularities on the inner surface of the skull which can be thus corrected, that an early operation for their prevention is not indicated.

Severe meningeal or cortical inflammation, not connected with an external wound, is so rare that operation for its prevention is not indicated, and is, indeed, more likely to produce it than to prevent it.

CHAPTER XI.

FRACTURES OF THE VERTEBRÆ.

FRACTURES of the vertebræ have this in common with fractures of the skull, that most of their importance depends upon the associated injury of the nerve-centres and trunks contained within their canal, but they have in addition the importance due to the function of the spine as a support for the head and trunk. Upon the integrity of this support depend not only the power of locomotion, but also grace of carriage and dexterity in the use of the limbs.

The spinal cord, occupying the centre of the vertebral column, is efficiently protected against any external violence that is not sufficient to break the bones that constitute the latter, or the ligaments and muscles that bind those bones together; and the column itself is constituted in a manner that combines elasticity and mobility with the necessary firmness and rigidity. The bodies of the vertebræ, increasing in size from above downward in correspondence with the variations in the weight and strain which the different ones are called upon to bear, are composed of spongy tissue and separated from each other by the elastic intervertebral cartilages, and prevented from changing their positions by the interlocking of the articular processes upon the sides. The general form of the column is that of a long slender cone with a double antero-posterior curve, and its component parts are strongly bound together by ligaments and muscles allowing a range of motion which, while small between each pair of vertebræ, is in the aggregate considerable. Mechanically, therefore, the spine is exposed to fracture by direct violence, like other bones, and by indirect violence through exaggeration or straightening of its normal curves.

In the displacements following fracture the corresponding joints may be dislocated, and as in dislocation there may be associated fracture, and as the symptoms in the two forms of injury are in many respects the same, they are sometimes grouped as "fracture-dislocations" of the spine.

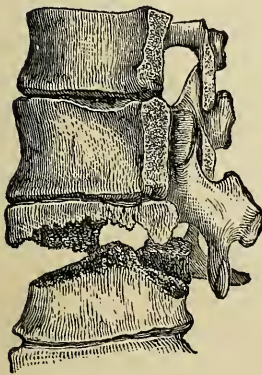
Fractures of the vertebræ are relatively rare, 0.5 per cent. in my statistics (Chapter I.). Gurlt collected 270 cases, with 444 fractures, and found that fractures of the cervical and dorsal vertebræ are about equally frequent, 178 and 184 respectively, while those of the lumbar vertebræ, 82, are much less common; that the fatal cases of fracture of the cervical vertebræ are, however, considerably more numerous, actually and relatively, than those of the two other regions; that the fifth and sixth cervical, the last dorsal, and the first lumbar are more frequently broken than any of the others; and that it is common in fractures of the cervical and dorsal regions for more than one vertebra to be broken at the same time. They are extremely rare in childhood and old age, and relatively infrequent in women.

The part most frequently fractured is the body of the vertebrae—that is, in about two-thirds of all cases, or in more than half of the fractures of the cervical vertebrae, in about seven-eighths of those of the dorsal vertebrae, and in about all those of the lumbar vertebrae. Or, in general terms, fractures of the bodies of the vertebrae begin at about the middle of the cervical region and increase in frequency downward. Simultaneous fracture of two or more vertebrae is common in the cervical and upper dorsal regions, less common in the lower dorsal, and rare in the lumbar region. Fracture of one or more of the vertebral processes either of the same or of adjoining vertebrae is common.

Pathology.

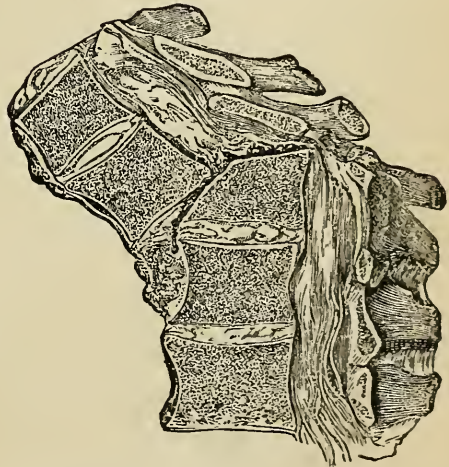The fracture of the **body of a vertebra** may be complete or incomplete; the line of fracture may extend only partly through it or entirely across it, or it may be broken into several fragments, or compressed, or impacted. The line of fracture, if single, may be vertical, horizontal, or oblique in any direction; the first being found almost exclusively in the cervical and upper dorsal regions, the two latter and multiple fractures occurring everywhere. The transverse and oblique fractures lie, as a rule, nearer the upper than the lower

FIG. 57.



Transverse fracture of vertebra.

FIG. 58.



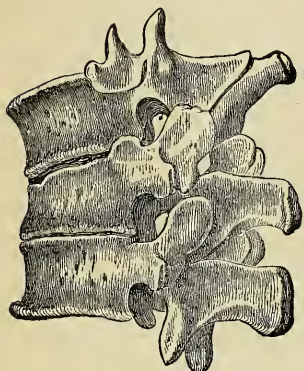
Displacement of the vertebrae causing compression of the spinal cord.

border of the bone, and may pass from the upper to the anterior surface, leaving the posterior and lower surfaces unbroken, and in these cases the upper fragment preserves its relations to the overlying vertebra and is displaced with it forward and downward, producing a change in the long axis of the spine characterized by an angle having its apex directed backward at the seat of fracture. This displacement narrows the antero-posterior diameter of the spinal canal and lacerates

or compresses the spinal cord within it. If the line of fracture is oblique, and if fracture or dislocation of the articular processes is associated with it, the displacement is inclined to the corresponding side either directly or by rotation.

Compression of the body of a vertebra is found either in combination with comminuted fracture or alone, and involving one or several vertebræ. It is apparently caused by forcible forward flexion, in which either the posterior portions of the vertebræ must separate from each other or the anterior portions must approximate by condensation of the intervertebral disks or of the bone.

FIG. 59.



Compression of the last dorsal vertebra.

The compression may be so extreme that the intervertebral disks above and below the affected vertebra are brought into contact with each other in front, the substance of the bone being partly compressed and partly forced out upon the sides or behind into the spinal canal (Figs. 60 and 61), compressing the cord. With this compression may be associated fracture or fissure of the body, and especially fracture of the processes of the same or the adjoining vertebra. The same shortening of the anterior portion of the body may be produced by splintering of part of the bone or by impaction of one fragment into another lying above

FIG. 60.

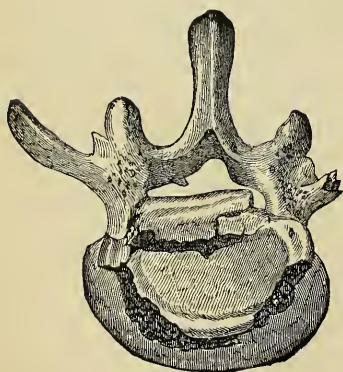
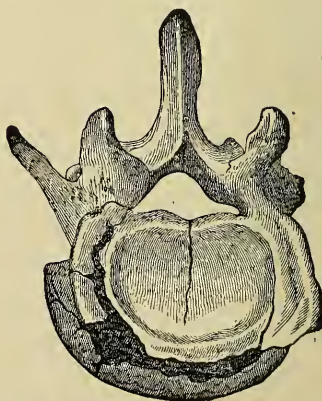


FIG. 61.



Fracture with compression of the third and fourth lumbar vertebræ.

or below it. The intervertebral disk may be partly squeezed out, bringing with it a scale of bone from either or both vertebræ.

Fracture of the vertebral arches, according to Gurlt, is found in about half the cases of fracture of the cervical vertebræ, and only in one-

seventh of those of the dorsal, and one-eighth of those of the lumbar.¹ He attributes the frequency of this form of fracture in the cervical spine to the comparatively greater breadth and less height of the arch and to the absence of that protection which is furnished in the dorsal and lumbar regions by the larger and stronger spinous, transverse, and oblique processes. When the arch is broken on each side the intermediate portion bearing the spinous process may be driven into the spinal canal and cause fatal laceration or compression of the cord. Gurlt's statistics contain six such cases, affecting the fifth, sixth, and seventh cervical vertebrae.

The **spinous processes** are broken most frequently at those points where they are longest and thinnest, nearly one-fourth of the cases occurring in the cervical spine, more than half in the dorsal, and about one-eighth in the lumbar; and often several adjoining ones are broken at the same time. In the dorsal region this fracture is usually found only in combination with fracture of the body of one of the vertebrae above or below it. Isolated fracture of a spinous process may occur as the result of direct violence, or of muscular action, and the displacement is either directly downward or to one side.

Fracture of the **transverse or articular processes** occurs in combination with other fractures in about one-sixth of all cases, but is rare except in such combination. In the few instances in which it has occurred alone it was the result of gunshot injury. As a complication of other fractures the proportion of its occurrence for the transverse process is greatest in the cervical and next in the lumbar and dorsal regions; for the articular processes it is greatest in the cervical and smallest in the lumbar. Fracture of a transverse process of a dorsal vertebra may lead to fracture of the rib which articulates with it, and fracture of the transverse process of a cervical vertebra may seriously injure the vessels contained in the vertebral canal. Fracture of an articular process exposes to dislocation of the vertebra with all its accompanying dangers.

The **ligaments** which bind the different vertebrae together are torn in fracture to an extent which varies with the severity of the injury and the degree of the displacement, and the intervertebral disks may be torn, displaced, or compressed. In rare cases the injury may be confined to the ligaments and disks—real dislocation or diastasis without fracture—although the distinction cannot be made during life.

The **spinal cord**, the diameter of which is considerably less than that of the canal in which it lies, is suspended within the dura mater, which is itself loosely connected with the bones and separated from direct contact with them in most places by a rich venous plexus. The medullary portion of the cord ends at the first or second lumbar vertebra, and its lower portion is enveloped by the numerous nerve trunks which pass downward to form the cauda equina and the lumbar and sacral plexuses. The cord is injured directly only when the lumen of the canal is considerably encroached upon by the displacement of a frag-

¹ For cases of doubtful character in the lumbar vertebrae, see section on Course and Terminations.

ment or of a vertebra, but it can be compressed by extravasated blood or by inflammatory exudations, or torn by elongation. I have seen it so injured in fracture of both laminae of the sixth cervical without displacement, by anterior flexion of the neck, as to cause immediate paraplegia and death in a week. Occasionally the cord is penetrated by a sharp fragment, but usually the dura mater is untorn and the cord is crushed between the anterior portion of one fragment or vertebra, usually the lower, and the posterior portion of another, usually the upper. This crushing presents all degrees, from a slight flattening to complete disorganization, and apparently the medullary portion is more easily and permanently injured and destroyed than the nerve-fibres in the columns beside it.

Hemorrhage, Hæmatomyelia. Hemorrhage, without division of the cord, may be extra- or intra-dural, or within the substance of the cord (hæmatomyelia). Hemorrhage outside the cord spreads upward and downward within the canal and produces changes and symptoms by pressure upon the cord.

Hæmatomyelia is apparently caused by forcible elongation of the cord in hyperflexion or extension of the column, with or without recognizable lesion of the ligaments or bones; it is seen almost exclusively in the lower cervical and upper dorsal region, but sometimes near the junction of the lower dorsal and lumbar regions. The condition, first pointed out by Thorburn and Minor, of Moscow, about 1890, has been recently studied in detail by Bailey¹ and Bolton.² The hemorrhage takes place in the gray matter of the cord and may be very closely limited to it, spreading upward and downward in it through two, three, or even more segments. If the lesion is more severe the hemorrhage may extend into the white columns as a clot, or appear there as punctate extravasations. If the patient survives the blood is absorbed, leaving cavities within the cord which contain a viscid liquid and tend toward obliteration by formation of connective tissue. The elements of the gray matter, cells and fibres, which are injured by the hemorrhage appear to be incapable of repair with restoration of function, but pressure-effects upon adjoining parts may be, and apparently frequently are, recovered from. Consequently, the recognition of the condition is of great importance in prognosis and in deterring from active surgical interference. Apparently most of the cases of injury to the neck which recover after having presented symptoms of severe injury to the cord are cases of hæmatomyelia. In a notable number of them the injury has been caused by diving into shallow water, the head being thrown forcibly back to avoid contact with the bottom.

Etiology.

The *immediate causes* are muscular action and external violence. The former is very rare and acts either by a direct pull of the muscle upon the process to which it is attached or by the momentum given by the head in sudden dorsal flexion of the neck or rotation of the head. The most frequent examples of the latter (producing either

¹ Bailey: Med. Record, Nov. 19, 1898.

² Bolton: Annals of Surg., Aug., 1899.

fracture or dislocation of the cervical spine) have been in cases in which the patient has dived into shallow water and has thrown his head backward to escape contact with the bottom.

The commonest cause is the forcible bending of the spine in a fall or, less frequently, by the weight of a falling object or by the compression of the body in a narrow space, as in driving under an archway (indirect fracture). The relative frequency of the injury at the lower part of the cervical spine and at the junction of the dorsal and lumbar segment seems to be associated with the fact that at these points the more flexible and the more rigid portions of the column meet, such meeting points being specially liable to break in all combinations of flexible and rigid bodies.

Fractures by direct violence are infrequent and are usually found in the posterior portion of the vertebra.

Symptoms and Diagnosis.

(See also Dislocations of the Vertebrae.)

The symptoms of fracture of the spine vary with the position and the portion of the vertebra involved, and therefore need a separate and detailed consideration in connection with the different groups of fractures. But there are certain general symptoms common to most which may first be mentioned. After the first shock of the injury, which usually passes off without permanent impairment of the intelligence, the patient complains of a localized pain at the seat of fracture increased by manipulation or movements. There is usually a recognizable deformity consisting of a change in the direction of the spine, a more or less marked angular projection backward with or without swelling of the surrounding soft parts; crepitus can sometimes be made out by the surgeon, but more commonly it is appreciable, if at all, only by the patient himself when his body is moved. The most important and constant symptom is paralysis, motor and sensory, more or less complete, of the limbs and the portion of the body lying below the fracture. If complete its upper limit is usually sharply defined by a line crossing the trunk and corresponding to the adjoining limits of the regions supplied by the nerves that leave the column immediately above and below the point at which the cord has been injured. The consequences of this paralysis, if it involves the abdominal muscles, bladder, and rectum, are retention of urine and feces, followed by incontinence of one or both, by alkaline fermentation of the former, and cystitis. Respiratory difficulties, sometimes severe enough to cause death, appear when the fracture involves the upper portion of the spine, the result of the paralysis either of the abdominal muscles or of the diaphragm, or of vasomotor injury. There is also a great tendency to sloughing at all points of pressure within the paralyzed region, especially over the sacrum and trochanters and along the back. The sloughs appear promptly, sometimes within two or three days, are usually symmetrical, and often hasten death even if they are not its immediate cause.

Paralysis is, of course, only a symptom of injury to the cord and

may follow violence that has caused neither fracture or dislocation. Thus, a diastasis of two vertebræ, followed by immediate return to their normal relations, may cause hemorrhage into the canal or may even injure the cord by elongation and thus cause paralysis. A paralysis appearing shortly after an injury, and increasing, generally indicates hemorrhage into the canal, but I have seen it caused by displacement, with pressure, occurring during the transfer of the patient to hospital, the condition being shown by autopsy.

Extension of paralysis indicates hemorrhage or an ascending myelitis.

In *hæmatomyelia* there is immediate motor paralysis (usually paraplegia, but occasionally hemiplegia, when only one gray column is affected) which is transient except for those muscles whose spinal nuclei in the gray matter have been destroyed by the hemorrhage. Thus, when the lesion is situated in the lower cervical region the paralysis of the lower limbs and the sphincters promptly disappears, but that of the muscles of the forearm and hand remains in part. The interference with sensation is constant and characteristic: there is loss of sensibility to heat and cold (thermo-anæsthesia) and usually insensibility to pain (analgesia) also, but tactile sensibility is not affected. Bailey says the distribution of these disturbances is the same as that of the anæsthesia of a corresponding transverse lesion of the cord, but that it may present the Brown-Séquard type, namely, motor paralysis of one arm and leg with loss of pain-sense and temperature-sense in the arm and leg of the opposite side. The tendency is toward improvement, and sometimes recovery is complete. The reflexes are at first lost, then slowly regained.

In *complete transverse* injury there is permanent complete paraplegia and loss of all kinds of sensation and of the reflexes.

In *incomplete transverse* injury there is irregular paraplegia, the sensibility to pain, touch, and temperature may persist or be regained in limited areas below the lesion, and the reflexes return and become exaggerated.

Priapism, more or less complete, was observed, according to Gurlt, in 31 of 96 cases of fracture of the cervical and two upper dorsal vertebræ, 16 times in 133 cases of fracture between the third dorsal and second lumbar vertebræ, and never in fracture below the latter. It appears promptly, usually on the first or second day, and seldom lasts longer than a fortnight. Notwithstanding the insensitiveness of the penis it may be caused or increased by the use of the catheter. On the other hand, in one case the erect organ became relaxed as soon as the catheter had passed over half the length of the urethra. Ejaculations are very exceptional, there being only four instances in Gurlt's collection, all of them in cases of fracture of the cervical spine.

Fracture of Atlas and Axis.

The intimate relations existing between these two bones and the medulla oblongata, and their position above the roots of the phrenic nerve as well as above those of the other nerves supplying other

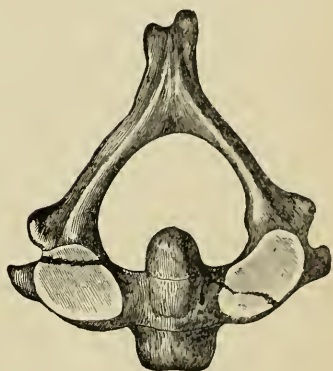
muscles which aid in respiration, make their injury especially dangerous, and have probably led to the generally received opinion that their fracture is, as a rule, immediately fatal. Gurlt's cases show, however, that this opinion is not correct, for in the eleven in which the nature of the injury was demonstrated by the autopsy, death occurred immediately in only two, and in only two others within an hour after the injury was received. In the other cases the patients survived for a considerable length of time, thirteen days in one, although some of them at the last died suddenly, apparently by displacement of the vertebræ due to incautious movements. The fractures were all caused by external violence, sometimes slight, as a fall from the bed while trying to reach down to the floor.

The parts broken in ten of these eleven cases were: the odontoid process alone once; the odontoid process and posterior arch of the atlas three times; the posterior arches of the atlas and axis three times; the posterior arch of the axis alone once; the spinous process of the axis twice: In six of the cases there was associated fracture of other cervical or dorsal vertebræ, and in no case was the transverse ligament torn. Figure 62, taken from a specimen in the museum at Braunschweig, shows a fracture of the superior articular surface of the axis. The patient was twenty-four years old, and died in a few hours after falling out of a wagon upon his head.

The symptoms of this fracture are so variable and so indefinite and have so much in common with simple dislocation of one bone upon the other, or of the atlas upon the skull, that the diagnosis is extremely difficult. On the one hand, the patient may die instantly; on the other, he may survive a longer or shorter time, either completely paralyzed or presenting no important symptoms, and then die suddenly by displacement of the fragments or gradually by extension of the symptoms, or in consequence of other injuries, or, if the diagnosis in some such cases may be accepted, may even get well. The symptoms of local pain and stiffness of the neck are too indefinite to be of any service, and paralytic symptoms may be entirely absent, as in Gurlt's second case, where the patient walked for two hours after the accident to reach home and developed no paralysis until the following day. Death took place suddenly on the eighth day, and the autopsy showed fracture of both arches of the atlas and of the odontoid process.

The symptoms in those of Gurlt's eleven cases which survived long enough to present any, or in which any are recorded, were complete paralysis of all the parts below the fracture in some, partial paralysis in others, only a slight diminution of sensibility in the left arm in one, pain in the neck or occiput in six, rigidity of the neck in most, absence

FIG. 62.



Fracture through the superior articular surfaces of the axis. (GURLT.)

of recognizable deformity in all, distinct crepitus in one, and falling forward of the head upon the breast in one. All of these symptoms—pain, rigidity, paralysis, sudden death—may be the result of dislocation as well as of fracture, and, as dislocation has in addition no general or local characteristic symptoms which serve to distinguish it, the differential diagnosis must usually remain in doubt.

Fractures of the Lower Five Cervical and First Two Dorsal Vertebrae.

The special characteristics of fractures of this region are due to the inclusion within it of the roots of the phrenic nerve and brachial plexus. The former passes out through the intervertebral foramen between the third and fourth cervical vertebrae, either coming from the fourth cervical pair alone, or receiving branches also from the third and fifth pairs. The brachial plexus is formed by the four lower cervical and the first dorsal pairs. Consequently, if the fracture is accompanied by displacement of the fragments and injury to the spinal cord, paralysis of the upper limbs also is caused, and if the fracture is high enough in the region to involve the phrenic nerve directly or by extension death follows promptly, preceded by the respiratory symptoms peculiar to lesion of this nerve.

Here, too, as after fracture of the atlas and axis, are found cases in which the patients present only symptoms of paralysis for a longer or shorter time, and then die suddenly of asphyxia in consequence of some accidental or intentional movement of the head, which probably causes compression of the phrenic nerves by displacement of the fragments.

The paralysis in fractures of the portion of this region below the fourth cervical vertebra shows many variations. From the relations of this part to the brachial plexus it might be expected that paralysis of the upper limbs would be a constant symptom, excluding those cases in which there is no displacement, but Gurlt's tables show this paralysis to have been present in less than one-fourth of the cases, that in the majority complete paralysis of the lower portion of the body extended upward at first only to the middle of the breast, the second rib, rarely to the neck, clavicle, or shoulders, and sometimes not even to the umbilicus, although it often advanced to a higher point later in the progress of the case. Paralytic symptoms appeared in the arms, as a rule, either later on the day of the accident or on the following day. The paralysis may be complete in one arm and partial or absent in the other; it may be complete of motion and incomplete of sensation, or the reverse; it may be limited to the arm or to the forearm; or the injury to the nerves may be evidenced by abnormal sensations, such as numbness or prickling in the limb. Probably incompleteness of paralysis is due in most cases to the conservation of some of the nerve fibres, although the medullary position of the cord is completely destroyed by crushing. Hyperæsthesia affecting the whole or part of the limb is occasionally observed, and is sometimes associated with sharp, lancinating, continuous or intermittent pain, which may be spontaneous or may be excited or increased by the slightest touch of the surface. Tonic or clonic spasms are seen somewhat more

frequently than hyperæsthesia, sometimes limited to the arms alone, sometimes involving other muscles also.

An important consequence of the paralysis is the change in the respiratory act due to the withdrawal of the aid of the accessory muscles when the phrenic nerve is uninjured. As a consequence of the paralysis of the intercostal and abdominal muscles, inspiration is effected by the diaphragm alone, and expiration by the weight of the abdominal walls and viscera which sink back to the positions from which they have been displaced by the contraction of the diaphragm. As the expiration is thus purely passive the patient cannot sneeze or cough strongly, and as he is thus prevented from clearing his lungs of the mucus which collects in them it gives rise to plentiful moist râles. If the phrenic nerve shares in the injury the diaphragm acts very slowly, perhaps not oftener than twice or thrice in the minute, the breathing is noisy or sighing, and the shoulders may be slightly raised at each inspiration. Sometimes a change in the position increases or diminishes the difficulty by modifying the pressure upon the cord. A noticeable slowing of the pulse accompanies this defective respiration.

The local symptoms are usually few and obscure, often nothing more than the pain that is felt at the seat of fracture and is increased by pressure or motion. Sometimes there are positive objective signs: an abnormal projection or depression of one or more spinous processes, an irregularity on the posterior wall of the pharynx produced by the displaced body of a vertebra, lateral displacement of one or more spinous processes, irregularity in the line of the transverse processes, and possibly erepitis or abnormal mobility.

The position and mobility of the head vary greatly in different cases. In some cases they show nothing abnormal, in others the head can be moved freely to either side, but not forward or backward, and in others it is held firmly fixed in some one position and any attempt to change that position causes pain. This rigidity is due not to change in the relations of the articular surfaces, but to the involuntary spasmodic contraction of the muscles which is nature's method of preventing the infliction of pain by movement of the parts.

It is to be borne in mind that, as stated above, this is the region in which traumatic hæmatomyelia almost exclusively occurs, and that examination of the sensibility to heat, cold, and pain should be made whenever, in connection with more or less motor paralysis, there is preservation of the touch-sense.

It is apparent that the diagnosis of fracture of this region may be difficult or impossible. The most that can be done in many cases is to recognize approximately the seat of the injury. Thus, paralysis or symptoms of irritation in the arms, even if they first appear after some delay, indicate a lesion above the second dorsal vertebra, although in a few exceptional cases this symptom has existed when the injury was lower on the spine, and was then due probably to an associated brain lesion or a large collection of blood within the spinal canal. If all local and functional signs are absent the diagnosis is, of course, impossible, and the real nature of the injury may be entirely over-

looked until the progress of the inflammation or a chance displacement of the fragments brings it to light.

The prognosis is extremely unfavorable. Gurlt's tables contain 96 fatal cases, and only 8 which ended in recovery, and in one of these the symptoms reappeared after a fall and the patient died in consequence. In one-third of the cases death took place within the first four days; in 20 between the fifth and twelfth; in 11 between the thirteenth and thirty-sixth; and in one case the patient survived five months. I have known two cases in which life was prolonged more than a year, without change in the paralysis. In hæmatomyelia the prognosis is much more favorable.

Fractures of the Lower Ten Dorsal and First Two Lumbar Vertebrae.

This region includes another point at which fractures are very common, the lower dorsal and the first lumbar vertebrae. Its position below the origin of the brachial plexus prevents the involvement of the arms in the paralysis except in rare cases where this unusual extension is due apparently to the spread of inflammatory softening of the cord or to the pressure of extravasated blood. Paralysis of the lower limbs, the bladder, and rectum, which is one of the common results of fracture in this division as well as in the higher ones, may be entirely absent at the beginning, especially after fracture of the second lumbar vertebra, or, more frequently, may be incomplete, the motor paralysis being, as a rule, more marked than the paralysis of sensation. The latter may extend as high as the lower part of the breast, or may stop at the groin, and sometimes even does not reach above the lower part of the thigh. A common result of the paralysis is the immediate retention of urine and feces, followed, as before mentioned, by incontinence and by alkaline decomposition of the urine and cystitis. This incontinence persists until death takes place or improvement begins. The disturbance in the function of the bowels aided by the flaccidity of the abdominal muscles produces tympanites, which makes its appearance usually within a day or two and may be sufficiently marked to interfere with respiration by crowding the diaphragm upward and opposing its contraction. In other cases, even of apparently severe injury to the body of a vertebra, there may be an entire absence of paralytic symptoms and even of those of meningeal irritation.

The diagnosis is aided by objective symptoms, which are more marked and distinctive than those found after fractures of the upper portion of the column, because as the fracture in the great majority of the cases involves the body of the vertebra, and is comminuted or accompanied by displacement, there is usually a recognizable deformity consisting in an angular change in the long axis of the spine, with projection of the spinous process of the broken vertebra or of the one immediately above it. This change in the position of the spinous process is sometimes so marked that the finger can be pressed deeply in between it and the next lower one.

The possibility of traumatic hæmatomyelia in the lower part of this region must not be overlooked.

The prognosis, as regards both life and recovery of function, is more favorable than after fracture at a higher point.

Fractures of the Lower Three Lumbar Vertebæ.

Fractures of this portion of the spine appear to be exceedingly rare.¹ The absence of paralytic symptoms and recognizable displacement would make the diagnosis during life practically impossible.

As this portion of the spinal canal contains only nerve trunks, which are better fitted by their texture and comparative independence of each other to resist or escape damaging pressure by displaced fragments than the spinal cord itself is, paralysis may be absent even when the displacement is marked; in some cases it has been complete, both of motion and sensation, over the limbs and abdomen. The patient may, however, be unable to walk in consequence of the loss of support occasioned by the fracture, or he may walk only feebly and in a bent posture. But if union takes place, even if the deformity persists, he may be as strong and capable as before. In short, the prognosis is favorable as regards both life and function.

Course and Terminations.

The course and terminations of fracture of the spine, with their many variations as regards both the life and principal functions of the patient, have been indicated in the preceding section; we have now to consider the changes effected in the broken bone by the process of repair, and to describe some of the later symptoms with more detail.

Repair takes place by a callus which may remain fibrous, but is usually bony and possesses ample solidity notwithstanding the common persistence of displacement. In fractures that have been healed for a long time is found the same absorption of projecting angles and surfaces which has been noticed in connection with other fractures, and this absorption is especially marked in the bodies of the vertebæ. If several adjoining vertebæ are broken at the same time the intervertebral disks disappear in part by absorption, and the remaining portions undergo partial or complete ossification, uniting structurally with the vertebæ, and thus forming a more or less extensive, rigid, bony mass. The length of time required for consolidation appears to be greater than for that of other spongy bones.

A number of instances of complete pseudarthrosis have been recorded and their origin differently interpreted. Gurll collected 21 such cases: 1 of the odontoid process, 4 of the spinous processes of the cervical, dorsal, and lumbar vertebæ, and of the sacrum, 3 of the transverse processes of lumbar vertebæ, 11 of the arches of lumbar vertebæ, and 2 of the side of the upper false vertebra of the sacrum. Meckel considered the 11 cases involving the arches of lumbar ver-

¹ If the specimens of supposed ununited fracture of the arch of these bones, which have been found upon the dissecting-table, in museums, and in old Indian graves, are accepted as such, they raise the question whether similar fractures are not more common than has been supposed, and whether they may not be present, without displacement, in some of the severe, so-called strains of this region.

tebræ as instances of arrest of development, comparing them with the vertebræ of some reptiles, which consist normally of a separate body and arch, and in which many of the processes also remain ununited. Otto opposed this view, because the position of the false joint does not correspond to that of the line between the diaphysis and epiphysis, and Wyman,¹ who reported eleven additional cases and did not know of these earlier ones, held the same opinion for the same reason. Gurlt accepted Meckel's opinion concerning the arches of the lumbar vertebræ, and claims that it is probably true also of the other cases. His reasons are that there is no trace of injury to other parts, and that it is known that fracture limited to a vertebral arch, a spinous, or a transverse process is exceedingly rare; that most of the cases relate to the lowest lumbar vertebræ, fractures of which, of any kind, are rare, and in the case of the fifth unknown; and that the identity of the position of the joint in all corresponding cases, and its perfect structure, point strongly to an arrest of development, and are incompatible with a fracture by external violence. Shepherd² reports another of the fifth lumbar vertebræ found in the dissecting-room.

Suppuration at the seat of fracture, which is very rare in other bones, seems to be more common after simple fracture of the spine, and is attributed by Gurlt to the greater complexity of the anatomical conditions and to the less perfect immobility maintained during the progress of the case. His statistics contain eight cases in which, excluding instances of suppurative meningitis, more or less pus was found after death at the seat of fracture.

As to the recovery of the cord after injury, with restoration of function, nothing definite is known beyond the fact that a number of autopsies made at various periods after injury have shown the cord more or less completely divided, or reduced to pulp at the compressed part, or replaced by fibrous tissue. There is nothing to prove that a disintegrated portion can be restored, or that divided cords can be reunited, and it is not easy to see how proof of such a fact could be furnished except by experiment. In those cases in which paralysis has disappeared after a time, it is impossible to know exactly what was the nature of the lesion of the cord that caused it, but probably most of them are cases of moderate hæmatomyelia.

In one or two cases recently published, in which a partial division of the cord has been demonstrated by operation, partial recovery of function has followed. I doubt if this can be held to prove more than that nerve-fibres of the cord can reunite, with re-establishment of conduction. That destruction of the gray matter can be made good must still be deemed unproved, and unfortunately that destruction is the common lesion in fracture.

The troubles created by paralysis of the bladder are very serious, and often hasten a fatal termination. They begin, usually promptly, with retention, which if not looked for by the surgeon may pass unnoticed, since it gives the patient no pain, until the distention of the bladder has become so great that the urine begins to dribble away

¹ Wyman: Boston Medical and Surgical Journal, August 14, 1869.

² Shepherd: Montreal Medical Journal, June, 1892.

through the urethra. The symptoms and usual consequences of the consequent cystitis are such as are commonly observed when the same affection is excited by other causes, and do not require a detailed description here; but in addition to these common ones there are occasionally observed others of great gravity, such as sloughing of the wall of the bladder, and pericystitis with formation of abscesses.

Every effort should be made to delay the appearance of this complication and to diminish its severity, and with this object the water must be regularly drawn as soon as the first signs of retention appear. It is usually sufficient to use the catheter twice a day; it must be sterilized and passed with even more than the usual precautions and gentleness because the patient's insensitiveness creates an additional risk of doing damage unwittingly to the urethral wall. After cystitis has appeared and the urine has become turbid, the bladder should be washed once or twice a day. Permanent drainage of the bladder through a perineal or suprapubic incision has been employed with advantage.

Bed-sores appear promptly after any fracture that has caused paraplegia by a complete transverse lesion of the cord, but are absent in hæmatomyelia. The skin at first becomes white, then mottled, and then sloughs, and the slough spreads peripherally and in depth. The commonest seat is the skin covering the convexity of the sacrum, then other prominent points upon the back and legs. The cause of this early sloughing has been thought to lie in injury to nerves or nerve centres presiding over the nutrition of the parts; but Mr. Shaw¹ explains it by the pressure which is continued for a length of time and with an absence of interruption unknown except in connection with paralysis. Not only is the patient unable to move, but he is insensitive to the prolonged pressure, and does not seek to change his position or to have it changed. He lies absolutely motionless in one settled position; the pressure interrupts the circulation at certain points, and, if this interruption continues unrelieved, the part dies. The presence of urine or liquid feces may prove an additional source of irritation, as may also creases or irregularities in the bed-clothing, and lack of attention and scrupulous cleanliness. The rapid improvement which sometimes takes place in these sloughs, even when the paralysis remains complete, as soon as the consolidation of the fracture is sufficiently advanced to allow the patient to be readily moved, is corroboration of the opinion. Some cases which have recovered with permanent paraplegia have shown, on the other hand, a very marked tendency to the formation of sloughs on slight provocation, and in one case² the tarsal bones of both feet became necrotic.

In those cases in which the patients survive the injury and its more immediate consequences, it is sometimes found that the paralysis gradually diminishes and may even disappear entirely. The beginning of the improvement is sometimes marked by the appearance of sharp darting pains in the limbs and of muscular twitchings excited by slight causes, such as pinching or touching the skin; then the power of vol-

¹ Shaw: *Holmes's System of Surgery*. Am. ed., vol. i. p. 810.

² *Courier Médical*, November 11, 1882.

untary motion returns, first in one muscle, then in another. Sensation returns usually before motion; the bladder is found to be again able to retain a certain quantity of urine and to expel it with some force; and a similar improvement is presented by the rectum, although, as a rule, even in the best cases, the functions of the rectum and bladder remain partially and permanently disabled. The improvement in the paralysis may be very slight, or it may go on to complete restoration of function, or it may be arrested at any intermediate stage. Cases have been referred to in which a permanent deformity existed, but the functions of the body and limbs were in no manner disturbed by it. Finally, after a short period of apparent recovery, symptoms of progressive degeneration of the cord or of pachymeningitis may appear.

Treatment.

The indications, as in other fractures, are to reduce displacement and to immobilize until repair shall have taken place, but the limitations which exist in so many other fractures exist here to an even greater extent because of the uncertainty as to the character of the displacement, the difficulty in modifying it as desired, and the frequent association of dominant lesions of the cord which cannot possibly be remedied. The condition of the cord, as indicated by the symptoms, should usually determine the measure of benefit to be expected from treatment, but unfortunately we cannot distinguish with certainty between a complete division or crush of the cord which cannot be repaired and compression by bone or extravasated blood which will be recovered from if the pressure is relieved. We know that in the great majority of cases, a majority which is greater the higher the injury is situated in the vertebral column, the condition of the cord is hopeless or at the most can only be mitigated.

In the first care of the patient—transport, undressing, examination—he must be handled with constant watchfulness to avoid producing or increasing displacement. Then, if the fracture is of a spinous process alone or of the column without recognizable displacement and without symptoms of injury of the cord, confinement to the bed, preferably aided by a plaster-of-Paris corset, is all that is required.

If there is recognizable displacement—gibbosity of the spine—without cord symptoms immobilization in the plaster corset is indicated, with or without an attempt to correct the displacement.

If symptoms of pressure on or injury of the cord coexist an attempt should be made to relieve the condition by correcting the displacement.

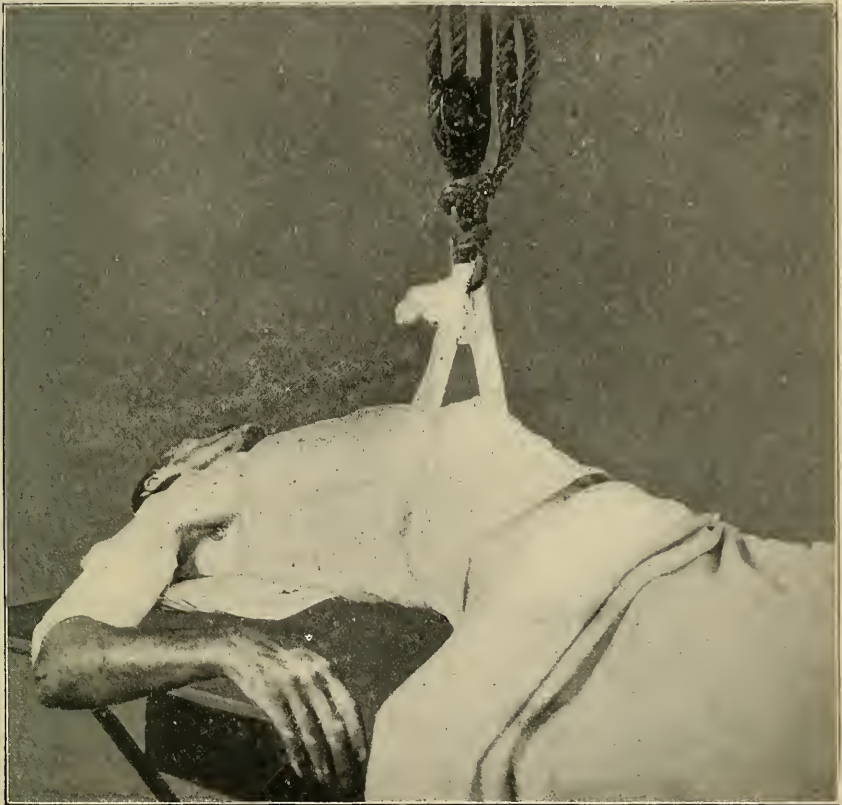
The means of accomplishing this are traction upon the trunk to straighten it by elongation, direct pressure forward upon the projecting angle, and open operation.

When the injury is in the cervical or upper dorsal region traction can be made by turning the patient upon his side and pulling by the chin and occiput; and by gradually changing the direction of the traction by moving the head backward while pressure is made against the spine below the fracture the angular displacement can sometimes be completely corrected. But when the injury is at a lower point, and

especially if the patient is large and heavy, traction thus made is not sufficient even with the aid of anæsthesia; and even pressure with the knee or hand against the angle (the patient being on his side) while the hips and shoulders are pressed backward may fail to make any change in the condition.

Suspension by the apparatus used in disease of the spine has been employed by some with advantage, but I have not ventured to try it.

FIG. 63.



Fracture of spine. Correction of the displacement by suspension and plaster jacket.

Instead, I have used a long plank, placing the patient upon it, securing his shoulders to one end, and then gradually raising that end so that the lower limbs would make the desired traction by their weight. While the patient is thus supported pressure forward upon the angle can be made by a bandage or stick passed between it and the plank. If the materials for a plaster corset have been previously prepared, in the form of broad strips of muslin or canton-flannel soaked in plaster cream, and placed at the proper point upon the plank before the patient has been laid upon it, the dressing can be easily and rapidly

completed while the patient remains suspended by bringing forward the ends of the strips around the body on each side.

Dandridge recommends horizontal suspension on a narrow strip of stout muslin, like a hammock, which is then included in the plaster jacket. The method is praised by those who have employed it in Pott's disease of the spine. Or partial suspension can be made by a bandage resting against the angle of the gibbosity (Fig. 63).

In a few cases an existing paraplegia has immediately disappeared during suspension, and although in others the symptoms have been temporarily aggravated I think we are justified in deeming the method safe and probably efficient to correct an angular displacement due to fracture or crushing of the body of a vertebra or of the pedicles or articular processes and also, though less certainly, a forward displacement of one segment. It cannot correct the much less common displacement forward into the canal of the posterior portion of the vertebral arch, the spinous process with one or both laminae, or probably a fracture-dislocation in which one or both inferior articular processes of an upper vertebra have lodged in front of the corresponding superior processes of the next lower one.

In reduction by open operation a longitudinal incision is made along the median line with its centre at the apex of the angle of the fracture, and the soft parts separated on each side from the spinous process and laminae of the vertebra forming the upper part of the angle, cutting through both laminae, if unbroken, and removing them with the spinous process. If indicated the opening in the spinal canal is enlarged upward or downward by removal of the adjoining spinous process and laminae, and the displacement of the body of the vertebra is corrected by manipulation guided by the eye and perhaps aided by traction with a blunt hook passed into the spinal canal. Hemorrhage beneath the dura is relieved by evacuation through an incision.

A large number of cases have been thus operated upon during the last few years, and apparently with marked benefit in some, but it is still too early to formulate a rule of practice. It is admitted by all that the operation can do good in only a small proportion of cases, and it is probable even that that proportion is less than is indicated by the statistics because it is not clear that the improvement which has sometimes followed was the result of the operation; similar improvement has been noted in apparently identical cases not operated upon, some of them probably cases of hæmatomyelia. It must also be admitted, I think, that the operation is not likely to do harm and that occasionally it discloses an important condition which could not otherwise be recognized and corrected. My own inclination is strongly toward reliance upon traction and the plaster jacket, systematic use of which might show a gain as great as that which Burrell¹ found in the Boston City Hospital: 33 per cent. of recoveries as against 22 per cent. under expectant treatment. I believe, for reasons above given, that in the common form of injury with angular displacement—gibbosity—reduction can almost always be accomplished as well in this way as by operation, and that the latter may find its special indica-

¹ Burrell: *Annals of Surgery*, February, 1895.

tions in cases of intraspinal hemorrhage and those rare ones in which the posterior portion of the arch is driven into the canal and presses upon the cord. Thorburn,¹ after a personal experience of seven cases of operation and study of about 200 published cases, says he has found no clear evidence of benefit from it. Nevertheless, he deems laminectomy justifiable “(1) in compound fracture; (2) in injuries of the laminae and spinous processes with lesion of the cord when the crush is probably incomplete; (3) when the symptoms are mainly or entirely due to thecal or perithecal hemorrhage; (4) in pachymeningitis or peripachymeningitis, which may follow an injury after a very long period; and (5) in cases of compression of the cauda equina.”

Of the great value of the plaster jacket, applied during suspension, in aiding consolidation of the fracture in cases in which the disability is due to the fracture rather than to injury of the cord, there can be no question.²

The general treatment, when paraplegia is present, is to place the patient upon a water-bed, carefully prevent irritation of the skin by moisture or creases in the sheets, and regularly empty the bladder and bowels. Later in the case electricity may render some service.

¹Thorburn: *Lancet*, August 11, 1894.

²See Papail, *De l'emploi du corset plâtré dans les lésions de la colonne vertébrale*, Paris, 1887.

CHAPTER XII.

FRACTURES OF THE BONES OF THE FACE.

1. Fractures of the Nose.

UNDER this term we include not only the two nasal bones, but also those upon which they rest, the septum, the nasal process of the superior maxillary, and the nasal spine of the frontal. The fracture may involve one or both nasal bones or adjoining processes ; it may be simple or compound, multiple or comminuted ; and it may be associated with other fractures of neighboring bones, the most important of which is fracture of the cribriform plate of the ethmoid. In the great majority of cases the fracture is a more or less comminuted one, occupying the lower half of the nasal bones, the main line of fracture running transversely or obliquely, and the fragments are displaced backward or backward and to one side, according to the direction of the force that has produced the injury. In rare cases the fracture involves only one nasal bone, or there may be dislocation of one or both bones. The cartilages which form the alæ may be broken or torn from their attachments to the bone, and that which forms the septum is frequently broken in connection with fractures of the bones themselves, or separated from the vomer.

The symptoms by which fracture may be recognized are deformity, mobility, and crepitus. If the nose is grasped by the thumb and finger lateral mobility with crepitus can usually be recognized, and displacements may at the same time be appreciated. The separation or fracture of the septum is recognized by exploration within the nostrils. The swelling of the soft parts, which appears promptly, will mask any but an extreme displacement.

Other symptoms which may be present, but which are by no means pathognomonic, are free bleeding from the nose, and occasionally emphysema of the eyelids and face. Bleeding is often severe and sometimes recurrent and difficult to arrest, but rarely endangers life. Emphysema generally has its origin in an effort of the patient to blow his nose ; the air is forced into the subcutaneous cellular tissue through a rent in the mucous membrane and spreads promptly to the eyelids and sometimes over the rest of the face.

An occasional symptom, when the fracture has extended into the adjoining portion of the superior maxillary bone, is obstruction to the flow through the lachrymal duct in consequence of its inclusion in the line of fracture. Another and more common one is the difficulty or impossibility of breathing through the nose, the result of inflammatory swelling of the mucous membrane ; and, finally, in the comminuted fractures that are or have become compound, suppuration may be

maintained for weeks or months until all the necrosed fragments have worked their way out or have been removed. It occasionally happens, too, that a tendency is manifested toward inflammatory complications in the neighborhood, abscesses form in and about the nose, portions of bone or cartilage become necrosed and are exfoliated, and a constant purulent discharge from the nostrils is maintained.

It is so important that displacement should be corrected that an anæsthetic should be used if a thorough exploration cannot be made without its aid, and the surgeon should spare no pains to satisfy himself as to the condition and position of the bones. The examination cannot prudently be long postponed, for the bones of the face unite promptly, and more than once it has been found impossible to correct a displacement after eight or ten days had elapsed; firm union may be expected within a fortnight or three weeks.

The prognosis as regards life is favorable, except in those cases in which the skull is at the same time broken, and in those few others in which recurrent hemorrhages, of which no satisfactory explanation is given, show themselves. But as regards the avoidance of deformity the outlook is not so favorable, because it is not always easy to recognize or correct a displacement through the swollen tissues and the persistence of even a slight one is likely to be a noticeable blemish.

The treatment consists mainly in the reduction of the displacement, for it is seldom possible to apply any apparatus or dressing that will prevent a recurrence of the displacement if there is any tendency toward it. The reduction when there is depression is accomplished by pressure made from within the nostril, upon the septum, if broken or displaced, as well as upon the bones, aided by manipulation or modelling of the fragments on the outside. The interval between the septum and the side of the nose at the part of the nostril corresponding to the nasal bone is so small that a strong flat instrument, such as a periosteum elevator, must be used, one that is small enough to work within the narrow space next the nasal bone, and strong enough to transmit considerable pressure. The fingers of the left hand placed upon the nose serve to guide the instrument and to recognize the degree of reduction that has been obtained. Cocaine may be used to diminish the sensitiveness of the mucosa. Ordinarily there is but little tendency to recurrence of the displacement, except when the fracture is comminuted and the septum badly broken; the only forces that tend to change the position of the fragments are the swelling of the external soft parts and the pressure of the air when the patient seeks to clear his nose by snuffing or blowing.

The idea of supporting the fragments by pressure from within the nostrils suggests itself so readily that it is not surprising to find recorded many instances and several varieties in the methods of its use. The simplest one consists of packing the lower, and perhaps the middle, meatus on the side toward which the septum is displaced with strips of iodoform ganze for a few days, so as to hold the septum in place and thus support the nasal bones. This is the method which we have used for several years at the Hudson Street Hospital. The more elaborate ones are arrangements of rods supported by straps crossing the upper

lip, and capable of adjustment in length and direction within the nostril so as to hold the fragments in place; they are said to have been efficient in some difficult cases.

The use of plaster or gutta-percha splints moulded upon the outside seems to me to be entirely illusory; if swelling takes place under them it will tend to reproduce the displacement by pressure, if it is present when the mould is applied its subsidence soon creates a gap between the splint and the skin. The best plan appears to be repetition of the reduction as often as the displacement recurs. Occasionally the bridge has been held up by transfixion with a pin which rests upon the solid bone on each side. Recurrence of a lateral displacement may be opposed by a pad of gauze secured against the side of the nose by a strip of adhesive plaster crossing both cheeks.

Separation of the cartilaginous septum from the vomer can be treated with a pair of forceps, one branch of which is passed into each nostril, lapping and grasping the bone and cartilage so as to hold them in line. The depression of the bridge, the "saddle nose," which so often is seen after this fracture, constitutes so marked a disfigurement that many attempts have been made to correct it. Operations upon the bone, designed to detach and raise the bridge, have, as a rule, failed so completely that I was led to try to meet the indication by introducing a suitably shaped foreign body between the skin and the bone. It proved entirely successful in restoring the profile, and the pieces of aluminum and gutta-percha have remained in place for several years without causing irritation. (*Annals of Surgery*, June, 1896.) Of late, subcutaneous injection of warm paraffin has proved very satisfactory.

2. Fractures of the Malar Bone and Zygoma.

Isolated fractures of this bone are rare, and, so far as can be inferred from the small number of cases in which a direct examination has been possible, single fractures are rarer than multiple ones, and the rarest is that which is almost a simple diastasis, a separation at the sutures with some splintering. Partial fractures involving the lower and outer portion of the bone or the margin of the orbit have been observed, and also single fractures of the frontal and zygomatic processes, extending possibly into the bones with which they articulate. In most cases there is depression of the entire bone with fracture of the malar process of the superior maxilla and crushing of the anterior wall of the antrum, the malar bone being displaced inward toward the antrum or sometimes backward into the zygomatic fossa. The force and direction of the violence may be such that adjoining portions of the cranium will be broken, with possible laceration of the brain.

Fractures of the zygomatic arch alone have been caused by external violence acting from without inward, and in two cases from within outward, the patient having fallen forward upon a stick held in the mouth. In some of those I have seen a portion of the arch has been separated by two lines of fracture and depressed; in one of them one of the lines of fracture extended into the temporo-maxillary joint. The displacement follows the direction of the fracturing force.

The symptoms upon which the diagnosis must be made are deformity, mobility, and crepitus. Unless there is much inflammatory swelling the deformity, which consists usually in a depression or flattening of the cheek just below the outer half of the eye, can be recognized by sight and touch, and the irregularity of the line of fracture can be readily felt on the margin of the orbit, or, if it extends to the malar process of the superior maxillary bone, on the under and anterior surface of this process by the finger within the mouth. Mobility and crepitus are perceived more rarely; the latter can be sometimes produced by the movement of the jaw.

Anæsthesia or a sense of formication in the cheek, nose, upper lip, and gum of the corresponding side is sometimes observed, and is due to an extension of the fracture to the infra-orbital canal and tearing or bruising of the superior maxillary nerve. This symptom may be associated with the extravasation of blood in the posterior part of the orbit sufficient to force the eye forward and showing itself also under the conjunctiva and in the eyelids. Bleeding from the mouth or nose is occasionally seen as the result of the extension of the fracture through the mucous membrane of the mouth or antrum.

When the fracture involves the zygomatic arch, and the fragments, as is usually the case, are driven inward, movement of the jaw may be difficult or impossible, either because the masseter has been injured, or because the depressed fragments of the arch are forced against the coronoid process of the inferior maxilla, or into the tendon of the temporal muscle. In one case the tip of the coronoid process was broken off by the same blow that fractured the arch. The same interference can be produced by the displacement backward of the main portion of the bone. Swelling, discoloration, and pain are the natural and constant results of the fracture and the bruising of the soft parts.

The natural course of these fractures is toward rapid repair without excessive callus, and with gradual disappearance of any difficulty that may exist at first in the movement of the jaws. It is seldom possible to reduce the displacement completely, because, as has been said, it is generally inward, and there is no way of acting very efficiently upon the bone, except through a wound of the skin. The attempt must be made to move the bone in the desired direction by engaging the end of the thumb or finger under it in the zygomatic fossa, introducing it through the mouth if the cheek is swollen. It has been proposed, and occasionally practised, to cut down upon the bone opposite the zygomatic process, divide the fascia overlying the masseter muscle, pass a stout hook under the process, and raise the bone by drawing upon it, or to make a smaller incision over the body of the bone and screw an elevator into it, by which it could then be raised.

Inward displacement of the zygomatic arch cannot be directly acted upon except by a hook introduced through the skin or an incision. In only one of the recorded cases has the displacement interfered seriously and for any length of time with the movement of the jaws; in this one the difficulty increased steadily for some time until the patient could barely separate the teeth, and then one morning while yawning he felt something snap, and the motion of the jaw at once became and remained free.

3. Fractures of the Superior Maxilla.

While the body of this bone, protected as it is by outlying processes and other bones, is rarely fractured, its own processes are not infrequently broken or involved in the fractures of those bones with which they are continuous. Thus, a blow upon the nose breaks not only the nasal bones but also the nasal process of the superior maxilla, and a blow upon the malar bone may force in the anterior wall of the antrum on which it rests. The fractures are always produced by direct violence, and present, consequently, considerable variety in their extent and the parts involved, but a fissure may extend to this bone from a fracture of the cranium. The alveolar process may be broken off in part or entirely by a blow received on it or on the teeth. A blow received in front, at or below the level of the nostrils, may produce a horizontal line of fracture separating the alveolar and palatal processes from the body of the bone, and including also the pterygoid plates. Falls from a height have caused a vertical line of fracture or diastasis between the two bones along the median line of the mouth, extending even through the soft palate, and associated with fracture of the malar or nasal bones. In a very few cases a line of fracture on each side at the canine tooth has separated the intermediate portion, with marked displacement and mobility. Fractures of the alveolar process, even with much displacement and mobility, present but little gravity, for they heal rapidly and without necrosis except of small pieces of the sockets of teeth displaced at the same time.

It occasionally happens that one or both bones are driven in with multiple and comminuted fracturing of them and of the adjoining ones. The earliest known case of the kind was reported by Wiseman, and has been extensively quoted. The upper jaw was driven in so far that the finger could not be introduced between the palate and the posterior wall of the pharynx. Wiseman inserted a blunt hook through the mouth and easily drew the bone forward into place; as, however, the displacement recurred very easily, he left the hook behind the palate and had it drawn upon constantly by the patient or his friends until consolidation had taken place. Quite a number of similar cases (Gurlt collected upward of twenty) have been reported, all the result of great violence, either by falls from a height or the passage across the face of a heavy wagon, or a violent blow. In one of my own, a blow by a descending elevator upon an upturned face, the nasal bones were separated from the frontal along the suture line, the right malar and zygoma broken, and both superior maxillæ displaced downward and backward and separated from each other along the median line of the hard palate. In one case the bones of the face were so movable that they moved up and down when the patient swallowed, as if they were restrained only by the skin. In most of them the patients recovered, and it is worthy of remark that, notwithstanding the degree of the violence and the extent of the injury, it seldom happens that the fracture involves the cranium. The reason lies apparently in the direction in which the fracturing force is applied, a direction outside of and more or less parallel to the surface of the cranium and not in the line of one

of its diameters. The bones of the face are, as it were, torn off the cranium rather than driven back upon it.

Very extensive mutilation of the face has been caused by gunshot wounds, especially in attempts at suicide when the muzzle of the gun has been placed within the mouth, but it is rare for ordinary violence to lead to much loss of tissue. Malgaigne speaks of the following case as unique in this respect in his experience: A boy was kicked in the face by a horse; the superior maxillary, nasal, and palatal bones were extensively comminuted, and the skin torn and bruised. Recovery took place, but with much deformity. The nasal bones, the anterior portion of the alveolar arch, and the greater part, if not all, of the hard palate had disappeared. There was no longer either nose or mouth; the lips were united by a firm cicatrix, and the mouth and nostrils were represented by an oval opening between the nasal processes of the superior maxillæ. Through this opening the patient breathed, spoke, drank, and ate.

The diagnosis of fracture is ordinarily made without any difficulty, since large portions of the bone are open to direct examination with the finger through the mouth and on the cheek. Irregularity of outline, mobility, displacements, and crepitus can be readily recognized. In some few cases where there was no displacement the diagnosis has been in doubt, and Guérin¹ has pointed out a symptom which might be useful under such circumstances. It has been said that the pterygoid apophysis is always broken when the line of fracture crosses the jaw horizontally between the alveolar process and the malar bone, and Guérin found that pressure with the finger upon the inner plate of this process caused pain and sometimes showed mobility when there was no other sign of fracture. Ecchymosis of the hard or soft palate indicates fracture.

Repair in cases of average severity takes place in from thirty to forty days with a scanty formation of callus, and not infrequently in less time. The vitality of the bone is exceptionally great, hence the rule laid down by Malgaigne and some of his predecessors, and repeated by all subsequent writers, to leave every fragment that is not absolutely and entirely detached. Although the rule is a sound one, it occasionally happens that fragments become necrosed and have to be removed. This is thought to happen more frequently with fragments of the alveolar border than with any others.

Displacement is seldom noticeable after repair is completed, except in the nose, but it usually exists to a greater or less degree, and the ingenuity and the patience of the surgeon are often severely taxed to overcome the constant tendency to the recurrence of the displacement. Salivation is often profuse, and the discharge offensive. Division of the lachrymal canal by the fracture may lead to its obliteration.

Displacement of the entire bone may be treated as in Wiseman's case, or the retention may be aided by securing the lower jaw against the upper one, with or without the intervention of interdental splints or moulds of gutta-percha or metal shaped to fit the teeth and alveolar arch. Lateral pressure cannot well be made upon the cheeks to over-

¹ Guérin: *Archives Générales de Médecine*, July, 1866, vol. ii. p. 5.

come separation along the median line of the palate, but fortunately it is not always necessary. In Simonin's case, quoted by Malgaigne, the

gap began to contract spontaneously by the tenth day, and was completely closed by the thirty-third, with no other displacement than a slight difference in level between the two halves. In another case, quoted by Hamilton, the gap was large enough to admit the little finger, and was still open six weeks after the receipt of the injury.

After fracture of the alveolar process the fragment should be carefully readjusted and fixed by wiring the teeth to the adjoining ones, or by a splint of gutta-percha or metal. Agnew says he has used for this purpose with great advantage a piece of cork with grooves cut in its upper and lower surfaces to receive the teeth of both jaws. The reduction is made, the cork inserted, and the jaws firmly bound together.

No attempt should be made to remove the corresponding teeth, for not only are the chances in favor of their becoming firm again in their sockets, but the attempt to draw them, even if they are loose, may bring away an important piece of the bone.

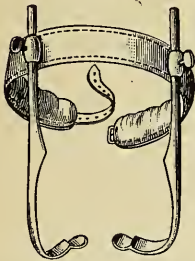
The gutta-percha or metal mould may be held in place by binding the lower jaw against it after it has been fitted to the upper one, or by an apparatus similar to one devised by Graefe for the purpose, and shown in Fig. 64. If the splint is to be supported by the lower jaw it should be so constructed that an interval will be left, through which food can be given and the mouth cleansed. The cavity of the mouth should be repeatedly cleansed.

4. Fractures of the Inferior Maxilla.

Fracture of the inferior maxilla occurs more frequently than that of any other of the bones of the face. It is rare in childhood and old age, most frequent between the ages of twenty and thirty, and is apparently more than ten times as common in males as in females.

Gurlt collected 143 published cases in which the character and position of the fracture were described with sufficient accuracy to allow of their use as statistics: of these 80 were single, 49 double, and in 14 there were three or more lines of fracture. Of 75 single ones (excluding 5 in which the fracture was limited to the alveolar process) the fracture occupied the median line in 25, the region of the incisor teeth in 22, that of the back teeth in 15, behind the teeth in 8, and the condyloid process in 5. In 35 double fractures both halves of the bone were broken 20 times, and at points on the two halves corresponding closely with each other; one side alone 8 times, and the median line by one of the fractures 7 times. One or both of the condyloid processes were broken in several of the multiple fractures. These figures show that, exclusive of partial fractures of the alveolar border, which are very common, and often caused by the drawing of a tooth, the most frequent seat of fracture is at or near the median line, and that single fracture of the ramus, or of the alveolar or condyloid process is com-

FIG. 64.



Intra-buccal splint for fracture of the upper jaw.

paratively rare. They differ materially from the estimates made by various writers, but as the latter differ quite as much among themselves, and appear to have spoken in most cases from general impressions rather than from figures, the preference should be given, I think, to Gurlt.

Double fractures of the lower jaw are relatively more common than those of other bones, while comminuted ones are rare. Compound fractures are common, both because the gum overlying the fracture is frequently torn and because the lip and skin are often involved in the direct injury that has caused the fracture. The fracture is complete or incomplete, the latter rarely except when the alveolar border alone is involved. A portion of the lower border of the bone may be broken off by a blow.

The line of fracture in the body of the bone is usually vertical or nearly vertical; at the angle or in the ramus it is oblique or rarely transverse. At the median line there is but little displacement, if any; but, when present, it may be in either of three directions: a difference in the horizontal level of the edge of the teeth, a displacement forward and backward of the fragments upon each other, or a lateral separation of the two. In the fractures between the median line and the canine tooth the line is still much more frequently vertical than oblique; but displacement is the rule, although no one form of it seems to be more common than the others. Between the canine tooth and the angle of the jaw it is either vertical or inclined backward and downward, and usually, instead of crossing the bone from without inward at a right angle to the surface, it is inclined backward and inward, so that the anterior fragment is lengthened on the inner side and the posterior fragment on the outer side. The inferior dental nerve is crossed by this fracture, and is sometimes torn or bruised.

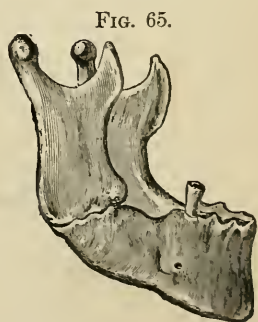Fracture behind the teeth is comparatively rare, only eighteen cases being contained in Gurlt's statistics, and it is frequently double or multiple or associated with other fractures.

When the fracture lies at the junction of the body of the jaw and the ascending ramus, it is usually oblique, running from behind the last tooth backward and downward toward the angle of the jaw; but it may be vertical. Displacement is usually slight or lacking, the parts being kept well together by the masseter and internal pterygoid muscles (Fig. 65).

Fracture of the condyloid process is usually accompanied by other fractures of the same or other bones of the face, and may be produced by a blow either upon the chin or upon the side of the jaw near the joint. The line of fracture passes through the neck, and the few specimens furnished by autopsies and museums do not show a greater frequency at any point or in any direction than at any other.

Fracture of the coronoid process is exceedingly rare and has been seen only in association with other fractures of the same or adjoining bones.

A portion of the alveolar process with the teeth in place is some-



Fracture of lower jaw behind the teeth.

times broken off. The size of the piece varies within wide limits, and the displacement is habitually inward. In one or two entirely exceptional cases a similar piece, including a portion of the body of the bone, has been broken off.

Comminuted fractures, except as the result of gunshot wounds, are comparatively rare; double and treble fractures are less so; and one case is on record in which there were five distinct and separate lines of fracture.

The most frequent cause of fracture, exclusive of partial fractures produced by attempts to draw a tooth, is violence received upon the chin; fracture by pressure upon the sides is much less common, the other occurring thrice as frequently. Fracture of the condyloid process may be produced in either of the same two ways—a blow upon the chin or upon the cheek.

The objective symptoms of fracture of the lower jaw are the same as those of other fractures: abnormal mobility, crepitus, displacement, pain. The bone is so accessible to the touch both within and without the mouth that irregularities in the outline of its body can be easily recognized by the fingers and sometimes by sight. The teeth show differences in level, vertically or antero-posteriorly; those which adjoin the fracture are usually loosened and may be entirely dislodged. Mobility and crepitus are detected by manipulation. When the fracture is situated at or above the angle of the jaw its recognition is by no means so easy; by passing the finger within the mouth along the inner and outer surfaces of the ramus irregularities of outline and localized points of pain may be recognized, and pain at a fixed point is caused by biting.

The degree and direction of the displacement vary much. As a rule, when the fracture is single and lateral, the anterior fragment tends toward the inside of the mouth. In double fractures, the intermediate piece is almost invariably drawn downward and backward by the unopposed action of the muscles of the neck which are attached to it.

Fracture of the condyloid process was first studied by Desault and Bichat, and but little if anything has been added to our knowledge of the subject since their time. The symptoms are pain, increased by motion, diminished mobility of the jaw, often crepitus on manipulation, irregularities in the region of the condyle, the ease with which the condyle can be pushed forward into the zygomatic fossa, its failure to share in the movements of the jaw, and its almost constant displacement forward by the contraction of the external pterygoid. Ribes pointed out an additional symptom which is sometimes present, deviation of the chin toward the affected side. This is effected by the displacement of the ramus upward and backward on the outer side of the condyle and neck, and the more easily if the fracture is a double or multiple one. Gurlt quotes the description of a specimen of this kind from a work by Bonn, published in 1785. The condyle was united by a bony callus to the ramus just above the orifice of the dental canal.

Swelling of the gums, face, and glands follows promptly upon the injury, and is often increased by the direct bruising of the soft parts themselves; the secretions of the mouth, increased in quantity by the irritation, mingle with the pus that comes from the fracture if com-

pound or from the ulcers produced by the stomatitis, decompose, and cause an offensive odor that can scarcely be kept under control even by the most careful attention. Abscesses may form and open within the mouth or upon the sides of the jaw or the neck below it; they are almost invariably associated with the presence of detached splinters or the exfoliation of portions of the jaw, which require, of course, to be removed before a permanent cure can be obtained. Small fragments may long escape recognition, and the only indication of their presence may be a sinus; larger fragments force themselves promptly upon the surgeon's attention by the profuseness of the discharge and the amount of local reaction. A few cases of extensive necrosis have been reported.

Simple fractures unite in from thirty to forty days, and, even when there has been a considerable loss of bone by splintering or necrosis, the final result may be a very good one, in this sense, that the jaw is strong enough to support artificial teeth in the place of those that have been lost by the accident, is sufficiently regular in form to avoid deformity, and is free in its movements.

Failure of union, pseudarthrosis, is rare. Gurlt's statistics contain only two cases which can be properly considered as such, and they were both cured by operation. It is more common after fracture with much loss of substance by elimination of splinters, and may interfere with mastication.

The prognosis is a relatively favorable one; the probabilities are that union will take place promptly, that no serious complications will arise, and that no important deformity or disability will remain. Danger to life may come from two quarters: the proximity of the bone to the cranium carries with it the possibility of associated injury to the brain or to its case; retention of pus in a compound fracture in communication with the cavity of the mouth exposes to the grave danger of absorption of the decomposed secretions and, though rarely, to the burrowing of the decomposed pus along the deeper planes of the neck into the anterior mediastinum.

Treatment. Displacement following fracture of the body of the jaw can usually be readily overcome by the pressure of the thumb and fingers upon the teeth and the lower border of the bone; in some cases the interlocking or wedging of the smaller pieces or of displaced teeth may render the reduction impossible until after they shall have been removed.

In simple cases where the tendency to displacement is slight it is sufficient to immobilize the lower jaw by binding it against the upper one with a four-tailed bandage, the centre of which is at the chin, as shown in Fig. 66.

Splints are applied either to the front and under surface of the jaw outside the mouth, or to the teeth, or the inner surface of the jaw, and two kinds are sometimes used in combination. Outside splints are available only in cases in which there is not much tendency to displacement and in which the lateral pressure of a simple bandage would cause the fragments to override in one direction or another. They may be made of leather, pasteboard, gutta-percha, or plaster of Paris, and consist essentially of a cup-shaped piece embracing the chin and extending nearly to the angle of the jaw on each side, and to the fold of the neck below.


Interdental splints are made of metal, gutta-percha, or vulcanized rubber; they are fitted to the crowns of the teeth of both fragments after reduction of the displacement, and are held in place either by binding the jaws together with an outside bandage, or by braces connecting the splint with a pad under the jaw, or by a special arrangement of lateral braces as in Kingsley's apparatus (Fig. 67), or by fastening them to the teeth with wires. Some are fitted only to the broken jaw and are intended only to immobilize the fragments on each other; others are fitted to both jaws and enable the upper one to be used as a splint for the lower. Ackland¹ describes one capable of ready adjustment to almost any fracture of the body: a metal gutter partly filled with softened gutta-percha, pressed down upon the teeth, and secured to a plate beneath the chin by two adjustable clamps.

FIG. 66.



Four-tailed bandage for fracture of the lower jaw.

FIG. 67.



Kingsley's splint applied.

In one difficult case I used a carpenter's small wooden vise, one end of which lay on the edge of the teeth, the other under the chin; after a few days's use the displacement ceased to recur.

Gutta-percha splints may be made either of thin strips or of thick lumps or wedges. The former have a length of three or four inches, and a breadth sufficient to overlap the crowns of the teeth from gum to gum; they are softened by immersion in hot water, moulded to the teeth, cooled as rapidly as possible, taken off, and trimmed suitably. Then the splint is reapplied and the jaws bound together. If the tendency to displacement is slight the bandage may be loosened during the day to allow the introduction of liquid food, or a wedge may be kept between the jaws so as to create an interval to be used for this purpose, or advantage may be taken of the absence of teeth, especially from the upper jaw. In a case quoted by Gurlt² two fragments of the alveolar

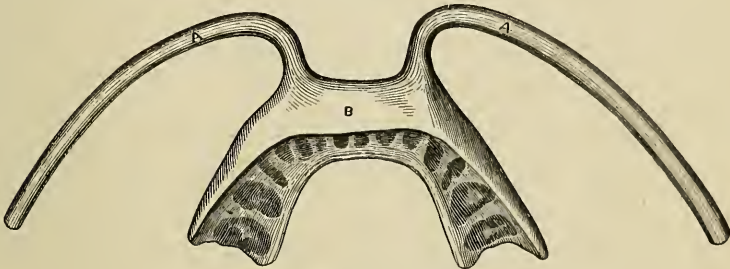
¹ Ackland: *British Medical Journal*, April 1, 1893.

² Gurlt: *Loc. cit.*, vol. ii. p. 393.

border carrying eight teeth were secured by a splint of sheet lead moulded to the teeth and fastened down by silver wire, the ends of which were brought out under the chin by means of a needle and tied over a roll of plaster. The wire caused no irritation and was left in place forty-seven days.

Gutta-percha wedges were introduced by Dr. Hamilton to meet a double indication, that of fixing the fragments securely and of allowing the easy introduction of food. Two pieces of gutta-percha of suitable size are softened and formed into wedges and introduced between the jaws, the edge of the wedge directed backward. The jaws are closed upon them, the fragments pressed up until the line of the teeth is straight, and the wedges moulded to the sides of the teeth above and below. As soon as the gutta-percha has hardened it is removed, trimmed suitably, and reapplied, and the jaws are bound together with a bandage.

FIG. 68.



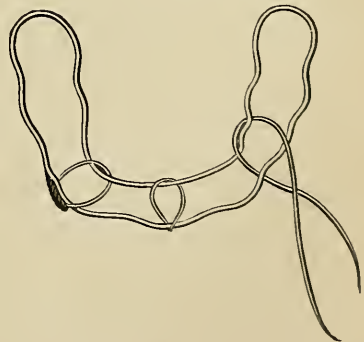
Kingsley's interdental splint.

Vulcanized rubber is a valuable substitute for gutta-percha in some difficult cases, but its employment requires special skill and experience which are found usually only among the dentists. Casts of one or both jaws are first taken in wax; from these plaster models are made, and upon these latter the splint. Figs. 67 and 68 show the splint as made by Dr. Kingsley, of New York, with attached bars by which the splint and jaw can be bound firmly together, the bandage passing from one bar to the other underneath the chin.

Another method, which dates back to Hippocrates, is to fasten together the teeth on opposite sides of the fracture by thread. In some cases I have found this to answer perfectly, in most to fail entirely. The ligature should be attached to the second or third tooth from the fracture on each side, and should be drawn very tight.

A wire loop exactly moulded to the sides of the teeth and secured to them at several points by en-

FIG. 69.



Hammond's wire splint for fracture of the jaw.

circling loops (Fig. 69) has been found efficient; also Angle's¹ "anchor splint," in which the wire is attached to the teeth by metal collars cemented on. In a few cases it has been found effectual to bind the jaws together by ligatures applied to opposing teeth.

Direct suture of the fragments by stout wire passed through holes drilled well below the alveolar border is said by König to be the method which he has employed exclusively for several years. Others have passed the suture through holes drilled in the lower border of the bone through an incision beneath the chin.

Repair takes place so rapidly that, except in compound fracture with much suppuration, there is rarely any tendency to displacement after the tenth day, and, therefore, the discomforts incidental to the continuous closure of the jaws do not need to be borne for any great length of time. If the importance of the case warrants it, if the displacement can be prevented only by keeping the jaws constantly in contact with each other, the patient can be fed through a tube passed behind the last molar tooth, or through the nose, or by the rectum.

Cleansing and disinfecting washes containing chlorate of potash, borax, or alum will be found to add much to the comfort of the patient whenever they can be used.

After fracture of the neck of the condyle the tendency is to the displacement of the condyle forward by the traction of the external pterygoid muscle, and as the fragment is too small to be acted upon directly by any dressing this tendency, if manifested, cannot well be overcome. The treatment, therefore, is to reduce the displacement if it exists, and then to immobilize the jaw after having pressed it upward to interlock the fragments. Ribes reduced the displacement by passing his forefinger into the mouth and along the inner side of the ascending ramus until he reached the condyle and was able to press it back into place. Fountain obtained a good result by drawing the jaw well forward and wiring the teeth together, so as to maintain the position.

Fracture of the coronoid process is not open to any treatment except immobilization.

Fractures of the alveolar border are best treated, like fractures of the body, by immobilization after careful reduction of the displacement, and it is advisable not to make haste to remove loose or semi-detached teeth. They may become firmly adherent again, or, if this should fail, they may be removed subsequently without having caused any serious trouble or delay.

Delayed union and pseudarthrosis are to be treated by the removal of the cause, if any definite local one exist, or by operative interference, freshening of the surfaces of fracture, and wiring of the fragments.

When a gap has been created by loss of bone, every effort should be made to keep the fragments in proper position, for it will usually be maintained spontaneously after the lapse of two or three weeks.

¹ Angle: Medical Record, August, 1890.

CHAPTER XIII.

FRACTURES OF THE HYOID BONE.

THIS comparatively rare lesion has received the attention of writers only within the present century. Malgaigne collected 8 cases, Hamilton added 2, and Gibb 3; in 1864 Gurlt collected 27 cases, 21 being of the bone alone, while in 6 there was associated fracture of the thyroid or cricoid cartilage or of the trachea. I have seen 3 of the greater cornu and 2 others were received at the Hudson Street Hospital in 1902 and 1903, which I did not see. In 3 of Malgaigne's cases and in 5 additional of Gurlt's the fracture was caused by hanging, judicial or suicidal, one of the latter surviving; in 6 of these one of the greater cornua was broken, in the remaining 2 the body. In the other cases of the list the cause was violent grasping of the neck, or a blow, or fall, and in 2 cases apparently muscular action, general muscular contraction during a fall. Valsalva reports a case of "dislocation of one of the greater horns from the body," caused by the effort to swallow a large piece of food.

In the great majority of the cases the fracture was of one of the greater cornua, and usually at or near its junction with the body. In only three cases was the body of the bone broken, and in none the lesser horn.

Symptoms. The symptoms of fracture of one of the larger cornua, without accompanying injury to the larynx or trachea, are, according to the records, quite well defined and characteristic: sharp pain at the seat of fracture increased by pressure, speaking, or swallowing; swelling in the same region appearing soon after the accident and due in part to extravasated blood; recognizable displacement or mobility of the fragment; crepitus; and sometimes free bleeding into the mouth, the result of perforation of the mucous membrane of the pharynx by the bone. Exploration of the pharynx will enable the surgeon to recognize displacement of the horn inward and perforation of the mucous membrane if they exist. The patient is seldom able to move the tongue freely or without pain, and in some cases attempts to depress it or put it out have caused paroxysms of suffocation. In all the cases it has been difficult to swallow, even a drop of water sometimes causing the patient to cough and choke, and in many of them it was necessary to give food through an œsophageal tube, in one case for twenty days. In my own cases there was localized pain on pressure, and the mobility of the cornu could be recognized by grasping the bone with the thumb and finger on either side of the neck. The subjective symptoms were not urgent except when fracture of the larynx was associated; one such died by suffocation while tracheotomy was being done.

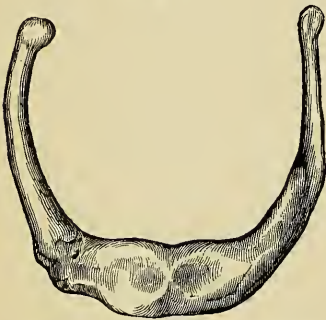
In the single case in which a fracture of the body of the hyoid bone

was observed during life the symptoms were severe paroxysms of coughing, dyspnoea, lividity of the face, and abundant bloody sputa, and were relieved by the reduction of the displacement.

The local and general reaction after the injury has been quite marked and although the bone appears to have united promptly convalescence has been delayed by the persistence of the dysphagia and of the change in the voice. In two cases an abscess formed at the seat of fracture, and three months afterward the necrosed posterior fragment was cast out. In an unreported case of which I have heard a sluggish abscess without necrosis formed, and the diagnosis was made when the pus was evacuated.

The possibility of repair by a bony callus is shown by three specimens: one, taken from the body of an adult man without a history and presented to the London Pathological Society by Gibb, showing a fracture of the right greater horn which had united with overriding to the extent of one-quarter of an inch, and displacement inward; another (Fig. 66) in the pathological collection of the college at Brunswick, showing a fracture of the right greater horn united with some shortening and displacement downward; the third,¹ found in the dissecting-room, a fracture at the junction of the left cornu and body, united with angular displacement.

FIG. 70.



United fracture of the hyoid bone.
(GURLT.)

Prognosis. The prognosis, so far as life is endangered by the injury to the bone, is favorable, but the associated injuries in the recorded cases have often been such as to cause death. Among these associated injuries fracture of the larynx is prominent.

Treatment. The treatment requires the reduction of displacement, if possible; and this might be facilitated by the introduction of the finger into the pharynx. It is unlikely that a bandage would be of any service in opposing a tendency to the recurrence of displacement. Immobilization of the head and neck by a stiff collar has been suggested.

The dysphagia may render nourishment through an œsophageal tube necessary, and associated injury of the larynx may require tracheotomy.

¹ Scriber: Medical Age, Detroit, January, 1892.

CHAPTER XIV.

FRACTURES OF THE CARTILAGES OF THE LARYNX AND TRACHEA.

THIS injury, although actually rare, is more frequent and much more dangerous than fracture of the hyoid bone and has received more attention from writers. Gurlt's collection published in 1864 contained 47 cases, Dr. Hunt¹ collected and analyzed 27 cases but did not give the details, and Henoque² collected 52 cases, to which Mr. Durham³ added 10, making 62 in all, or including 4 of Gurlt's in which the trachea alone was injured, 66. Platt⁴ reports one terminating fatally by broncho-pneumonia in three days, and Stephens⁵ one combined with fracture of the hyoid, followed by death in a few minutes.

The following table shows the relative frequency with which the different parts are affected :

Cartilage broken.	Cases.	Deaths.	Recoveries.
Thyroid alone	24	18	6
Cricoid alone	11	11	
Thyroid and hyoid bone	5	3	2
" " cricoid	9	9	
" " " and hyoid bone	2	2	
" " " " trachea	2	2	
Cricoid and trachea	2	2	
" " " and hyoid bone	1	1	
"Larynx"	7	3	4
Trachea alone	4	3	1
	—	—	—
	67	54	13

The causes are blows, falls, hanging, and the grasp of the hand in a fight, or in an attempt to strangle. The injury is seen more frequently in males than in females, and in middle life than at any other period, but youth and old age are not exempt. The mechanism of the fracture of the thyroid or cricoid is usually either lateral compression on both sides or pressure backward against the vertebral column; the first causes commonly longitudinal fracture of the thyroid cartilage near its middle, together with flattening or depression of its sides, and either a double lateral fracture of the cricoid cartilage or a single fracture in the anterior median line; the second causes irregular and multiple lines of fracture. The mucous membrane of the larynx is frequently torn, and extravasations of blood take place under the skin and mucous membrane or among the muscles.

¹ Hunt: American Journal of the Medical Sciences, April, 1866, p. 378.

² Henoque: Gazette Hebdomadaire, Sept. 26 and Oct. 2, 1868.

³ Holmes's System of Surgery, American edition, vol. i. p. 697.

⁴ Platt: Med. Chronicle, Dec., 1899.

⁵ Stephens: Guy's Hospital Reports, vol. liv., 1900.

Symptoms.—The symptoms of fracture of the larynx are frothy bloody expectoration with convulsive coughing and usually much dyspnoea and its attendant symptoms. The voice is affected or lost, and swallowing often difficult and painful, although not so much so as after fracture of the hyoid bone; and in all severe cases, when there is laceration of the mucous membrane, emphysema appears promptly and spreads steadily over the neck, face, trunk, the extremities, and mediastinum, being sometimes more marked in the intermuscular than in the subcutaneous connective tissue and sometimes causing pneumothorax without wound of the lung.

The additional objective symptoms are deformity of the region and abnormal mobility of parts of the larynx upon each other, but both these signs may be unrecognizable on account of the swelling. I have seen one case in which the only symptom was the mobility with crepitus of a small fragment at the upper posterior angle of the larynx; there was also slight hoarseness.

In some cases there have been no marked symptoms beyond a change in the voice, although the character of the injury was made clear by careful examination, and the difference seems to be due to the absence in these cases of any obstruction or narrowing of the air-passages by displacement or swelling.

The course in the severe cases is toward prompt death by suffocation, either by gradual increase of the dyspnoea or by the sudden intercurrent of œdema of the glottis. Occasionally the dyspnoea does not make its appearance until some days after the injury. In the mild cases the symptoms gradually subside, and recovery follows.

It seems probable that repair is by a bony, or at least by a calcified, callus.

Treatment. The treatment in the milder cases consists of local antiphlogistics and quiet; in the severer ones, of tracheotomy whenever the dyspnoea is great or increasing. It is not safe to wait until it has become extreme, for its increase at the last is often so rapid and sudden that death takes place before relief can be given. It is, therefore, the part of prudence to interfere early and before the interference is made actually necessary by the defective breathing. Advantage should be taken of the opportunity afforded by the operation to reduce any displacement that may exist and that can be overcome by manipulation through the wound.

Trachea. The symptoms of fracture of the trachea are similar to those of fracture of the larynx, except the local ones due to the displacements; the diagnosis is difficult because of the lack of symptoms distinctive of the seat and character of the lesion. The prognosis is unfavorable, and the treatment has usually been insufficient to avert the fatal termination or relieve the suffering, because in the few recorded cases the seat of injury has been beyond reach by operation. The indication for treatment is to insert a tube into the trachea past the point of fracture so as to insure free breathing.

CHAPTER XV.

FRACTURES OF THE STERNUM.

THE sternum, formed originally of several pieces, has an irregular and uncertain development, only one feature of which needs here to be mentioned. The upper portion, the manubrium, may unite by ossification with the central portion, the body, at some time during adult life, and in such case a traumatic separation of the two portions is a fracture, not a dislocation.

Fracture is rare, almost unknown, before the age of twenty years, and is frequently associated with other fractures, especially of the ribs and vertebræ. The fracture may be incomplete, multiple, transverse, oblique, or longitudinal. Of the first form there are but two recorded instances; in both the infraction occupied the posterior surface of the bone at or near the junction of the lower and middle thirds and was accompanied by an abundant extravasation of blood into the anterior mediastinum.

Of compound fractures, except such as were gunshot or stab wounds, there is but one example, reported by Duverney in 1751. A quarryman, while at work lying upon his side, was caught under a heavy stone about five feet long which compressed his chest laterally with such force as to separate the middle portion of the sternum from the upper portion and force it through the skin. Death was immediate, by rupture of the heart and lungs.

Of pure longitudinal fracture there is but one certain example, but there are two other cases in one of which there was a longitudinal fracture of the manubrium, and in the other of the body of the sternum associated with a transverse fracture at its upper end. The first case was that of a man who was overthrown and crushed by a falling wall; in addition to numerous contusions, the sternum was broken longitudinally through its entire length, the right half being depressed from eight to ten lines below the level of the left half. There was profuse bloody expectoration and difficult breathing. Reduction was accomplished by drawing the right arm back and making forcible pressure upon the middle of the sternal ribs of the right side and gentle pressure upon the left side. The patient recovered in six weeks.

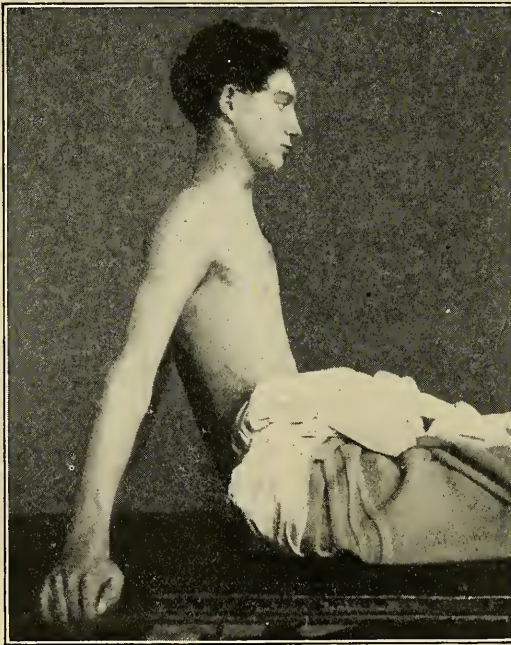
Cases of congenital fissure of the sternum have been mistaken for longitudinal fracture.

Simple transverse fractures form the great majority of fractures of the sternum, and occupy most frequently the junction between the manubrium and the body of the bone or its immediate neighborhood—that is, the region of the second intercostal space; next in frequency are fractures at or near the middle of the bone, corresponding to the

third rib and the third intercostal space; they are rarely high in the manubrium and below the middle of the body, and very uncommon as separations of the ensiform appendix from the body.

Fractures of the **manubrium** occur most commonly a short distance, two or three lines, above its lower border; the periosteum sometimes remains untoru upon either the anterior or the posterior surface; in some cases there has been no displacement, in others either the upper or the lower fragment has been displaced forward, and in one case there was angular displacement, the apex of the angle being directed backward. In several of the cases the fracture was produced by muscular action, by straining during childbirth, or by the effort to raise a heavy weight with the teeth, the back being bent far back. In a large proportion of cases in which the lesion was produced by external violence there was also fracture of the ribs, clavicle, or vertebræ.

FIG. 71.



Fracture of the sternum.

Fractures of the border have been observed in three instances, once in connection with fracture of the ribs, a scale of bone corresponding to the articulation with the first rib being broken off; a second time in connection with dislocation of the sternal end of the clavicle, the portion to which the sterno-cleido-mastoid was attached being torn off and drawn upward nearly half an inch; and in a third case in connection with a transverse fracture lower down,

Transverse fracture at or near the junction of the manubrium and body of the bone, and diastasis at this point, which is not always to be distinguished from fracture, are the commonest forms of injury. In the great majority of cases the lower fragment is displaced so as to lie in front of the upper one, and sometimes to override; it is exceptional for displacement to be absent or for the upper fragment to lie in front of the lower one.

There is reason to think that the periosteum is almost invariably torn upon the anterior surface, but that it sometimes remains unrent behind, a fact which derives considerable importance from its bearing upon the escape of blood into the anterior mediastinum. One or both of the second pair of ribs usually remain attached to the manubrium.

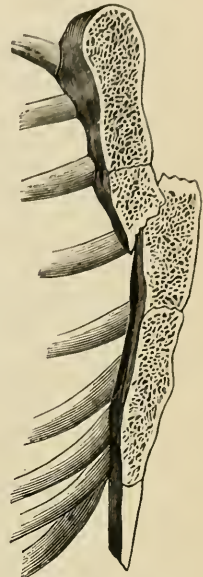Out of a total of 105 cases of fracture of the sternum collected by Gurlt, 27 are described as partial or complete diastasis at the junction of the first and second portions, the character of the lesion having been determined by post-mortem examination in fourteen of them.

Fractures of the **body** of the sternum (Fig. 72) occur most frequently between the second and fourth costal cartilages, are usually transverse, but sometimes oblique laterally or from before backward. The displacements are the same as after fracture at the junction of the manubrium and sternum, and there is the same relative frequency of the projection of the lower fragment.

Comminuted fracture of the body of the sternum has been rarely seen except in connection with gunshot and punctured wounds. Of triple fractures Gurlt found only two cases, and of double fractures only six, all of them associated with fracture of other bones, usually the ribs or vertebræ.

Of fracture or diastasis of the **ensiform appendix**, Gurlt collected only four examples, and the list does not appear to have been increased by subsequent writers; one was a fracture, the other three diastases. The fracture was produced in a man sixty years old by a fall upon the sharp edge of a grain measure, and, when last examined, nine months after the accident, was still ununited, and crepitated on pressure, but caused no inconvenience. In the other three cases the prominent symptom was persistent vomiting, which in one lasted for two years, recurring every five or six days, and then ceased spontaneously; in another it was cured by grasping the process between two fingers and bending it back into place; and in the third, after it had lasted a month and death by exhaustion seemed imminent, it was instantly relieved by the reduction of the displacement, which was accomplished by inserting a blunt hook into the abdominal cavity through an incision, and drawing the process forward. The patients were aged respectively twenty-eight, eighteen, and nineteen years.

FIG. 72.



Transverse fracture of the body of the sternum.

The effusion of blood, which is observed after all fractures, may attain an especial importance after fracture of the sternum, by the pressure which it may exert upon the underlying heart. The blood, coming from the torn vessels of the bone and periosteum, makes its way forward into a region where it can do no harm if the periosteum on the posterior surface remains untornd; but if this membrane shares in the injury, and especially if one of the internal mammary veins or arteries is ruptured, the blood makes its way into the anterior mediastinum, and sometimes in sufficient amount to cause death promptly.

Rupture of the pericardium, or of the heart, has been observed in a few cases; as has also probable laceration of the lung, evidenced by the appearance of subcutaneous emphysema or pneumothorax.

Etiology. Fracture of the sternum may be produced either by muscular action or by external violence.

There are four recorded cases in which the bone has been broken by straining during labor, and three in which the fracture has occurred during an effort to lift a heavy object.

External violence acts either directly by a blow upon the breast, or indirectly by forcibly bending the body forward or backward, or possibly by a combination of the two forms in the fall upon the body of a heavy object, or the passage across it of a loaded wagon, or, according to Lane, by depression of the shoulder acting through the clavicle and the upper ribs. It is not necessary that the force which acts directly should be very great to produce fracture; it is sufficient for it to act upon a limited area, as in a fall upon a stone, or stick, or the edge or corner of a box.

The violence which produces indirect fracture is, in most cases, a fall either upon the shoulders or buttocks, or with the back or breast across some fixed object, so that the trunk is bent sharply forward or backward; in the one case the bone is broken by being bent forward, in the other by traction exerted through the muscular attachments at either end.

Diagnosis. The diagnosis is readily made by the objective symptoms—the displacement, mobility, and crepitus—and by the localized area of pain excited by pressure, change of position, and the more forcible respiratory acts. I have seen a few cases in which the only symptom was pain on pressure, with late ecchymosis. The examination of the bone must be made carefully in order, on the one hand, to avoid mistaking some irregularity of development for a traumatic displacement, and, on the other, not to overlook a second or third fracture, or even a single one in case there should be no displacement. In cases of supposed injury to the ensiform appendix the frequent irregularities in the shape, position, and mobility of that part must be borne in mind.

The importance of the injury is by no means so great as the mortality of the recorded cases would indicate, for this mortality is largely due to associated lesions. Gurlt tabulated 98 cases with reference to this point, among others, and found that of 54 simple cases 46 recovered and 8 died, while of 44 complicated cases, cases, that is, in which there was some severe associated injury, only 1 recovered and 43 died. Of 20 cases in which the fracture was certainly caused by direct vio-

lence, 15 recovered and 5 died, 3 of the latter being complicated cases.

Course. The course in the uncomplicated cases is uneventful; if pain and oppression are marked at first they soon diminish and disappear, as do also expectoration of blood, dyspnoea, and orthopnoea. The principal danger is from pulmonary complications, especially in the old and alcoholic. In exceptional cases the local reaction may be great and may lead even to the formation of an abscess about the fracture. The pus may make its way to the surface between the fragments or on the sides, and if it collects upon the posterior surface and is discharged imperfectly through a small opening, the sinus may persist indefinitely, or the unnatural conditions may lead to extensive caries of the bone. Both conditions require treatment by active operative interference.

Usually repair takes place in from four to eight weeks, and by a bony callus. The persistence of a certain degree of displacement is not uncommon, and in some cases the deformity has been extreme.

Failure of bony union has been observed in a few cases, but does not appear to have caused any disability beyond a temporary difficulty in abduction and adduction of the arms.

Gunshot fractures may be penetrating or non-penetrating. A number of illustrative cases of each kind are given in the *Surgical History of the War of the Rebellion*. The latter do not differ materially from compound fractures due to any other cause, but in the former the prognosis is rendered very grave by the associated lesions.

Treatment. The first indication is to reduce such displacement as may exist. This is not always possible; the most intelligently directed and persistently conducted efforts have sometimes failed. The usual method is direct pressure upon the projecting fragment, aided, especially when there is overriding, by traction upon the two pieces. The traction must be made, in part at least, through the muscles attached to the ends of the bone, and is accomplished sometimes by resting the back upon some rather firm object, as a cushion or box, and bending the head and shoulders forcibly backward. At the same time the patient may be directed to take a full inspiration, and the surgeon presses downward against the upper edge of the lower fragment if that one, as is usual, projects, or he draws this fragment downward by taking hold of the projecting ribs that are attached to it. Various modifications of the plan have been employed, but all have the same fundamental idea, that of traction in opposite directions upon the fragments by forcible bending of the body backward. In one case reduction was gradually effected in three days by keeping the patient recumbent, with the head and shoulders thrown back.

A number of operative methods have been proposed for use in those cases in which the displacement cannot be reduced by manipulation, such as to raise the depressed fragment by a sort of gimlet screwed into it, or by an elevator or blunt hook passed under it through an incision, or to cut away the projecting portion, or to press it back with a rod carried directly down to it through an incision. Most of these remain as suggestions that have not been put to the test. One case

has been already mentioned in which the ensiform appendix was drawn forward successfully by means of a blunt hook passed into the peritoneal cavity; in another, of fracture at the upper part of the sternum with depression of the lower fragment, an incision was made with the intention of introducing a hook, but the pleural cavity was opened and the surgeon felt it necessary to close the wound immediately. In another the upper fragment was raised to the proper level by screwing a sort of gimlet into it and drawing it forward, but it afterward sank partly back again, and a second attempt to raise it was defeated by the tearing of the screw.

Unless the displacement is actually causing dangerous or distressing symptoms these methods of removing it by operation are hardly justifiable, because they carry with them risks that should not be lightly run.

The subsequent treatment consists in immobilization of the chest, and, if necessary, in the use of measures to allay local inflammation and to prevent coughing. A convenient dressing is a broad flannel bandage pinned tightly about the chest after forced expiration, or bands of adhesive plaster extending from side to side across the front of the chest and covering the entire length of the sternum.

If the formation of pus behind the bone is recognized or suspected it should be promptly sought for and evacuated by cutting through the bone at the seat of fracture.

CHAPTER XVI.

FRACTURES OF THE RIBS AND THEIR CARTILAGES.

Fractures of the Ribs.

THESE are among the commonest of all fractures, more common in men than in women, and almost unknown (or unrecognized) in infancy and childhood; probably many cases pass unrecognized, and the frequency is even greater than the statistics show.

Pathology. The fracture may be partial or complete, simple or compound, single or multiple. Partial fractures may be constituted either by a fissure involving only one of the borders of the rib and, perhaps, separating entirely a longer or shorter fragment of that border, or by an infraction. The former is very uncommon.

Complete fractures may be transverse, oblique, irregular, or multiple, and may be limited to a single rib, or may involve all the true ones on one side, and in some cases even many on both sides. The central ribs are the ones most frequently broken. Fracture of the twelfth is very rare; Gurlt could find only two recorded cases, the causes being a fall against the edge of a step and a table respectively. I saw one at the Hudson Street Hospital in 1896, in a man, fifty years old, who had been caught about the waist in the loop of a hawser. He died a few days later of coincident rupture of the large intestine; the twelfth rib was broken obliquely at its centre. For another case, see Chapter XL, Dislocation of Head or Rib. In 1905 I saw another, a sailor carried by a wave against the corner of a hatch.

Fracture of the first rib was formerly thought to be almost equally rare, but the observations of Lane¹ and Marsh² indicate that fracture of it or its cartilage may be rather common. Lane found four specimens in a series of 200 bodies in the dissecting-room, and Marsh saw four cases in six months' hospital service. According to Lane this rib is easily broken by forcible depression of the shoulder acting by direct pressure of the clavicle. The symptom is said to be pain behind the upper part of the sternum on lifting with the corresponding hand.

The fracture of a rib may occupy any part of it, but is most frequent on the side and anterior half. The periosteum may remain untorso, and the fragments preserve their relations to each other, or they may form a re-entrant or a salient angle, or override each other. If several ribs are broken at the same time and forced inward the depression may remain both broad and deep. Overriding of the fragments is impossible unless several ribs are broken at the same time, for the muscular and fibrous attachments of the adjoining ones hold the fragments in place, and the ribs above and below act as splints to pre-

¹ Lane: *British Medical Journal*, 1887, vol. ii. p. 119, and *Guy's Hospital Reports*, 1886, p. 429.

² Marsh: *Lancet*, June 30, 1888.

vent shortening. In double or multiple fracture of one or several ribs the intermediate piece or pieces may be so loosened that they move in and out with every inspiration.

In compound fractures the wound of the soft parts is rarely, if ever, caused by the projection of the broken end of the rib, but always by the object which produced the fracture.

The complications include injuries to the muscles, which are rarely important, to the intercostal arteries, and to the thoracic and abdominal viscera. The intercostal arteries are rarely seriously injured, although moderate hæmothorax is not uncommon after fracture of the middle third, especially of the sixth to the ninth ribs. Fatal hemorrhage into the pleural cavity has occurred in a few cases, even after fracture of a single rib and by slight violence, and a case of traumatic aneurysm has been reported (see p. 76).

A wound of the pleura and of the lungs is a rather common complication, and is generally caused by the sharp end of a fragment, but in some cases fatal injury of the lung has been caused by the crushing effect of the external violence acting through the, perhaps unbroken, ribs; the thorax is compressed by the force, and the lung is put upon the stretch in such a manner that it is actually torn, not perforated by the bone. The consequences of the wound vary with its size and with the relations existing between the lung and the thoracic wall. If these latter are normal—that is, if the lung is not adherent at the wounded part—air and blood escape more or less freely into the pleural cavity, and the lung collapses; if, on the other hand, the lung is adherent, the escaping air makes its way into the meshes of the connective tissue, and may spread through the mediastinum, under the pericardium and pleura, and into the interlobular tissue of the lung itself and the subcutaneous tissue on the surface of the body. Emphysema of the surface may be produced also when the lung is not adherent; the air which has escaped into and filled the pleural cavity is forced by the contraction of the chest during expiration out through the opening at the fracture, and its place is supplied at the next inspiration by fresh air drawn in through the wound of the lung, and thus a small quantity is pumped into the outer cellular tissue at each respiration, and this will continue until one or the other opening is closed by a clot or exudate or a change in the relations of its walls.

Wounds of the heart are much rarer, and even more dangerous. Gurlt collected six cases, in only four of which the wound of the heart appears to have been caused by the broken rib; in the other two it appears to have been caused by the compression of the heart between the anterior chest-wall and the vertebral column, for the pericardium was untorn.

Etiology, Fractures of the ribs may be caused by muscular action or by external violence. Of muscular action the most common form by far is coughing; others are sneezing, lifting a heavy object, even turning in bed. The lower ribs, especially the eleventh, are the ones most frequently broken in this way, but it has happened to the second, fourth, fifth, and sixth. It is much more common on the left than on the right side. (See forty cases collected by Tunis in *University Med-*

ical Magazine, November, 1890, and thirteen personal cases by Chelmonski in *Centralbl. f. Chir.*, 1901, p. 1188.) The so-called spontaneous fractures are observed almost exclusively in the insane, whose bones are frequently very soft.

By far the most common cause of fracture is external violence, by a blow, fall, or excessive pressure. The fracture may be direct or indirect, but it is not often easy to distinguish between these two varieties. In indirect fractures caused by pressure upon or near the sternal ends of the ribs the fracture is found most frequently in either the anterior or the posterior third, and the point of greatest frequency seems to be very near that at which the force is received, an inch or two on the outer side of the sternal end of the bone. Double or triple fractures of one or more adjoining ribs may apparently be caused in either of two ways: Extreme violence acting at one point breaks the rib at that point by direct pressure, and then depressing the broken ends breaks the bone again at a distance indirectly on one or both sides; or, the force acting more broadly, breaks the bone simultaneously at a point on each side.

Symptoms. The symptoms of fracture of a rib in the less severe cases are likely to be obscure. The breathing is shallow and sometimes catching through pain or fear of pain, and occasionally there is very troublesome reflex cough. Pain is provoked by pressure, inspiration, coughing, sneezing, and certain movements of the body; its diagnostic value comes from its limitation to one point under the different causes and especially when pressure is made on the affected rib at a distance.

Abnormal mobility is sometimes present, but the elasticity and mobility of the ribs make its recognition uncertain. It may sometimes be made out by placing a finger on each side of the suspected fracture, and pressing alternately with one and the other. The same manipulation may produce crepitus, but usually this is more readily recognized by placing the hand flat upon the chest, and pressing slightly at different points, or asking the patient to cough or draw a long breath. It may also be heard sometimes on auscultation of the chest in the usual manner, and may be accompanied after a day or two by a pleuritic friction sound, the result of a pleurisy excited by the traumatism, and usually limited in area to its immediate neighborhood. It is not uncommon for the patient himself to recognize the crepitus. Emphysema is, in itself, a very positive sign of injury to the lung and of fracture of a rib if there is no penetrating wound to account for it otherwise. Pneumothorax, or hemorrhage into the pleural cavity from a lacerated lung or an intercostal artery may be present in any of the severer cases; and bloody expectoration, which also points toward fracture, is often present even in slight cases, and is not infrequently absent in grave ones.

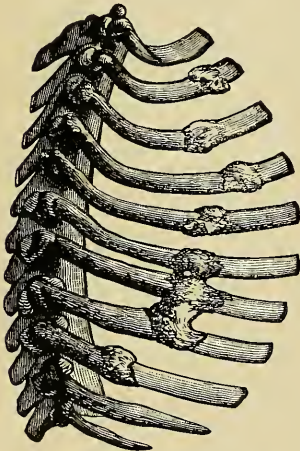
The symptoms of partial fracture or infraction are seldom definite enough to permit a positive diagnosis.

The course of a simple uncomplicated fracture is usually quite uneventful; the patient remains quiet, sometimes keeping his bed, and breathes carefully and superficially to avoid pain; after two or three weeks he finds these precautions unnecessary, and the surgeon finds on examination that the local tenderness has disappeared, and that crep-

itus and mobility can no longer be detected. Union by a bony callus takes place almost invariably, notwithstanding the defective immobilization of the parts, but, as a consequence of the latter, the callus is likely to be large, and, when two or more ribs have been broken, to unite the adjoining ones by a bridge of new formation. Solidity is given at first by an ensheathing callus, and the union between the fractured surfaces, even when they are in apposition, may remain fibrous for several months. Failure of union is rare.

Displacement upward or downward of a fragment may lead to its union with the adjoining rib, or to the formation of a lateral joint between them, as in the next following case; or, if adjoining ribs are displaced in opposite directions, a gap may be left between them which may lead to hernia of the lung, as in a case which is recorded in the *Gazette Médicale de Paris*, 1832, p. 465, and pictured in Cruveilhier's *Atlas d'Anatomie Pathologique*, a gap in the right side in front between the first and fourth ribs, four inches long and two inches wide. The patient had survived the accident about forty years.

FIG. 73.



Fracture of ribs, with excessive callus. (V. BERGMANN.)

The course and symptoms in the severer cases vary with the degree and character of the complications which give them their gravity. Emphysema may be slight and transitory, or it may continue for days and spread over a large portion of the surface of the body. If the air escapes into the cavity of the chest, or if the fracture is compound with a penetrating wound, the resultant dyspnoea and oppression may be extreme, and the physical signs of pneumothorax will be found upon examination. If, in addition to the escape of air, there is also free hemorrhage into the chest from the torn lung or an intercostal artery, the physical signs will be correspondingly modified. Extreme dyspnoea, due to congestion of the lung following promptly upon the injury, is not un-

common, and pneumonia occasionally results and leads to a fatal termination in the old and feeble.

I have observed in half a dozen cases of severe compression of the chest with fracture or dislocation of ribs or, more commonly, costal cartilages, a peculiar dusky discoloration of the skin of the face, neck, and upper part of the chest, together with marked subconjunctival bulbar ecchymosis nearly limited to the interpalpebral space. The discoloration does not disappear on pressure and is apparently due to the coloring-matter of the blood, possibly through innumerable minute capillary extravasations. It appears immediately, is evidently due to the compression of the chest, and disappears slowly.¹

Legros Clark² claims that serious functional derangement, without

¹ New York Medical Journal, March 1, 1890.

² Clark: Diagnosis of Visceral Lesions, p. 213.

organic lesion of the lung, may result from contusion or concussion of the chest, that it may be transient or may be followed by inflammation, local or general, of the affected lung, and that it is sometimes observed in the lung on the side opposite that which has sustained the injury.

Prognosis. The prognosis depends largely upon the complications. Simple fractures without important complications do well, as a rule; the exceptions are found mainly in the old and feeble, whose lives may be endangered by congestion of the lungs, pneumonia, or pleurisy. Cases complicated by wound of the heart or pericardium are usually promptly fatal. Wounds of the lungs are serious, but there are many instances of recovery even in cases where the laceration of the lung was probably extensive and accompanied a fracture that was in itself severe.

Treatment. The indications for treatment are to reduce any displacement that threatens to produce a complication or that causes pain, to immobilize the chest-wall, and to relieve or prevent pulmonary inflammation or congestion.

Outward angular displacement may be corrected by pressure upon the projecting angle, and inward angular displacement may sometimes be corrected, when the broken surfaces are still in contact and the fracture is situated near the middle of the rib, by pressing the sternum backward and thus springing the bone out. If the fragments have overridden this manœuvre is worse than useless, for it can only increase the displacement. Relief may also be obtained by making the patient strain or draw full deep breaths. Ravaton relieved the pain and corrected the displacement in one case by suspending the patient upon two rods passed under his axillæ.

When the displacement was greater and one of the fragments was pressed inward Malgaigne ingeniously made use of the other to elevate it, pressing it in until the ends met and became locked together by the irregularities of their broken surfaces so that the elasticity of the second should serve to raise the first.

For the elevation or removal of a depressed fragment by operation a number of methods have been proposed, but very few instances are known of the use of any of them. If such elevation should seem necessary, and if approach through an incision were deemed inadvisable because of the risk of the admission of air to the pleural cavity, the old suggestion of raising the bone by means of a hook passed through the skin and behind the upper border of the bone might be used.

Immobilization of the chest is best effected by surrounding it with a broad, snugly drawn piece of adhesive plaster, or with two or three narrower strips. The guide to the amount of pressure is the comfort of the patient. Malgaigne preferred a bandage three or four inches wide and long enough to pass once and a half around the chest, and he did not place it lower than the ensiform appendix, believing it to be sufficient, whichever ribs might be broken, to restrain the movements of the middle ones. When a circular bandage cannot be borne he recommends that a long narrow strip of plaster should be carried from the anterior end of the seventh rib on the right side, for example, across the front of the chest, under the left arm and across the back to

and over the right shoulder, thence again across the chest in front and around the left side and back to end at the crest of the right ilium. This immobilizes the left side of the chest very effectually and leaves the right side free. He suggests that in addition the arm should be fixed to the side.

The pressure of a bandage is useful also to prevent the spread of emphysema. This complication seldom requires any more active treatment, although scarifications have been made or the air drawn off through a trocar. If either method is used the instrument should be applied at a distance from the fracture. The more dangerous variety of emphysema, that in which the air makes its way into the mediastinum and the interlobular tissue of the lung, is not amenable to operative treatment.

In pneumothorax it may be desirable to draw off the air through an aspirating needle or a canula in order to relieve the pressure, and if blood accumulates within the pleural cavity in quantities sufficiently large to endanger life by interference with the action of the heart and either or both lungs, it may become necessary to remove it by aspiration or incision, but the indications should be very plain before the surgeon decides to interfere in this manner, since the removal of the blood and the relief of pressure may only lead to a return of the bleeding. Persistent internal hemorrhage can be treated only by indirect measures, because its source cannot be recognized, and, if recognized, probably could not be reached. It has been found useful to constrict the thighs circularly at the groin with rubber tubing or a roller-bandage just sufficiently to arrest the venous current; this withdraws a considerable amount of blood temporarily from circulation and acts as a venesection. It sometimes arrests bleeding instantly.

When life is threatened by pulmonary engorgement with extreme dyspnoea, blood should be taken from the arm immediately and freely, and the bleeding should be repeated if the symptoms reappear. The older records are full of cases showing the benefit of this practice, and, among modern surgeons, Mr. Bryant recommends it unhesitatingly and forcibly. He says: "Bleed with no sparing hand. . . . When relief has been obtained arrest the flow immediately, as syncope can only do harm," then follow with antimony.

Fractures of the Costal Cartilages.

The first mention made of this lesion appears to have been by Zwinger in 1698, and it is not again referred to in medical literature until 1805, when Lobstein, at Strasburg, and in 1806 Magendie, at Paris, each described it with cases. Additional observations were made by Delpech, Sir Astley Cooper, and Velpeau, and in 1841 Malgaigne¹ published a paper upon the subject which, six years afterward, he reproduced in part in his book on fractures. Since then but little work has been done upon the subject, most writers contenting themselves with reproducing in substance Malgaigne's chapter. Gurlt collected more than thirty cases for the chapter upon it in his book on

¹ Malgaigne: *Bulletins de Thérapeutique*, 1841, p. 227.

fractures, and Paulet,¹ who appears not to have known of Gurlt's work, gives fourteen cases which he obtained by a partial search through French periodical literature, only four of which are mentioned by Gurlt. Bourneville² (1880) and Pozzi³ (1888) raised the list to seventy-nine cases. I have seen two or three.

Fractures occur much more frequently at or near the junction of the cartilage and rib than at any other point, and more frequently in the seventh and eighth ribs than in any other. The fracture may be double, and may involve several cartilages on one side or on both. All the recorded fractures have been complete with the exception of one case; they have been perpendicular to the long axis of the cartilage, or very slightly oblique, and the surface has always been smooth, without serrations or splinters.

It is probable that persons advanced in life are more liable to this fracture than the young, because of the calcification or ossification of the cartilages, but it has occurred in young men (seventeen years) and even in a child seven years old.

Displacement has been absent in a very few cases; in most it takes place in the antero-posterior direction, and in some the fragments have overridden in the direction of the long axis of the rib. This latter form, probably, is possible only in the longer and more curved ribs, or when several adjoining ones are broken. The separation in either of these two directions may amount to as much as an inch, but is rarely so great. Either fragment may lie in front of the other, although the costal fragment projects more frequently than the sternal one; the displacement, however, appears to depend entirely upon the direction of the fracturing force and upon the position occupied by the patient.

No instance of a compound fracture of a costal cartilage is on record, and the complications are less frequent and, as a rule, less serious than those accompanying fractures of the ribs. In some cases where the violence has been extreme and many cartilages have been broken fatal injury has been done at the same time to the heart or great vessels, but not by the penetration of one of the fragments; the viscera are crushed or torn by the continued action of the force after the wall of the chest has yielded under it.

Hernia of the lung has been observed in three cases, one after fracture of the third and fourth cartilages and rupture of the intercostal muscles by the fall of a heavy weight, the second, a double one, after fracture or diastasis due to paroxysms of coughing, and the third, observed by Legros Clark⁴ after a blow received from the shaft of some vehicle. In this one the cartilage of the second rib was driven in, creating a gap through which a tumor as large as the fist appeared at each inspiration and disappeared at each expiration, leaving a depression capable of containing at least two ounces of liquid. Recovery in three weeks, the gap persisting but "evidently occupied by some plastic deposit."

¹ Paulet: *Dict. Encyclopédique*, First Series, vol. xxi., art. Côtes, 1878.

² Bourneville: *Progrès Méd.*, 1880.

³ Pozzi: *Ibid.*, October 20, 1888.

⁴ Legros Clark: *Loc. cit.*, p. 206.

In seven cases the fracture has been produced by muscular action, either an excessive effort, as to avoid a fall or to throw a heavy object, or coughing or sneezing. Thus Broca¹ reported the case of a porter at the market who having placed a sack of peas upon his shoulder asked a comrade to add another to it. The latter threw the second sac heavily upon him, and in the effort to avoid a fall under the weight he fractured the cartilages of the sixth, seventh, and eighth ribs on the right side at points seven or eight centimetres from the median line.

Fractures by external violence may be direct or indirect. Gurlt, thinks the indirect fractures take place at or near the costo-chondral junction, the force acting upon the rib itself in such manner as to spring its anterior end outward, while in the direct fractures the force is exerted upon a restricted area of the cartilage itself, as in a fall upon the edge of a tub or step, the blow of a fist, the kick of a horse.

The symptoms are local pain and deformity. Crepitus and abnormal mobility are not often recognizable, but if displacement is present it can usually be made out by following the outline of the rib and cartilage with the finger and by observing that it can be increased or diminished by pressure upon one or the other fragment. It may not be easy in some cases to say whether the fracture involves the rib or the cartilage and in others whether it is a fracture of the cartilage or a dislocation of its sternal or costal end, but the question has no practical importance.

The prognosis, independent of complications, is favorable, and the fracture may be expected to unite in three or four weeks. Our knowledge of the mode of repair has been obtained partly by experimentation and partly by examination of specimens. When the fragments remain end to end and the fractured surfaces are more or less completely in contact, a fibrous band unites them, and the union is strengthened by an external ring of spongy bone. In a specimen obtained by Basserau² and examined microscopically by Malassez, and in one reported by Pozzi,³ it was found that the central band was partly cartilaginous, and it is asserted that in other specimens points of ossification have been found.

FIG. 74.

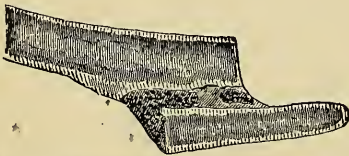
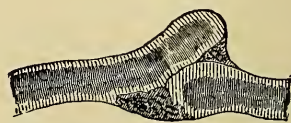


FIG. 75.



Repair of fracture of a costal cartilage. (GURLT.) Repair of fracture of a costal cartilage.

When the fragments override, they take, so far at least as the broken ends are concerned, little or no part in the repair. Union is accomplished by an intermediate band which is at first fibrous or cartilaginous and may become bony (Fig. 74), or if the fragments are in contact

¹ Broca: Quoted by Paulet, loc. cit., p. 83.

² Basserau: Paulet, loc. cit., p. 68.

³ Pozzi: Loc. cit.

the new bone forms on the sides and the ends (Fig. 75), and in both cases it envelopes the pieces more or less completely like a ring. This ring originates apparently in the perichondrium, and its ossification is the final result of the formative irritation created by the traumatism, and is analogous to the ossification seen so constantly not only in cartilage which would normally be transformed into bone, but also in others, such as that of the larynx, whose normal evolution does not include that change.

Treatment. The treatment is similar to that of fracture of the ribs : reduction of a displacement if necessary and possible, and immobilization. The former must be accomplished, if at all, by placing the patient upon the opposite side or upon his back, by drawing the shoulders back, or by deep inspirations ; the latter by a body bandage, strips of adhesive plaster, or, following Malgaigne's example, by a hernial truss so placed as to restrain the fragment that tends to project.

CHAPTER XVII.

FRACTURES OF THE CLAVICLE.

FRACTURE of the clavicle is a common injury and is especially frequent in childhood, taking the place at that age, as was pointed out by Krönlein, of dislocation of the shoulder by direct violence later in life. That is, a fall upon the shoulder breaks the clavicle of a child but dislocates the shoulder of an adult.

Pathology.

It has been found convenient by most modern authors for the purposes of study and description to divide the fractures into three groups, according as they occupy the inner, middle, or outer third of the bone. The average length of the clavicle is six inches, and this division into thirds of about two inches each corresponds to anatomical differences of considerable clinical importance. To the flattened outer third are attached the trapezius and deltoid muscles and the strong coraco-clavicular ligament binding it to the coracoid process, the inner fasciculus of which, known as the coracoid ligament, marks the inner limit of this portion, and can sometimes be readily felt upon the living body. The dividing line between the inner and middle thirds is not so definitely marked anatomically, it corresponds approximately to the point where the clavicle crosses the lower or outer edge of the first rib. The inner third is attached to the sternum by the sterno-clavicular ligaments, and to the cartilage of the first rib by the costo-clavicular or rhomboid ligament. To its upper border is attached the sterno-cleido-mastoid muscle, to its lower the pectoralis major.

Since the outer third is broadly attached by ligaments to the scapula it is apparent that after fracture of the bone in the inner or middle third the outer fragment will not be able to change its relations to the scapula materially, and that its displacement, therefore, will be governed by the change of position of the latter, by its sinking inward and forward to the side of the chest in consequence of the loss of its anterior support.

The outer portion of the middle third is by far the most common seat of fractures observed clinically, but Lane's¹ observations in the dissecting-room and his experiments indicate that fractures of the outer third may be very frequent and usually unrecognized.

The fracture may be partial or complete, single or multiple, simple or compound; the most frequent form is simple complete fracture. Compound fracture is so rare that Gurlt says he could find only four examples of it, and Hamilton, who gives the same four cases, says he had never met with an example. I have seen one: A laborer was

¹ Lane: Guy's Hospital Reports, 1886, vol. xliii.

struck by a falling stone upon the shoulder and sustained a fracture of the right clavicle at a point nearly two inches from the sternal end of the bone. The line of fracture was oblique from above downward and inward. A large ragged wound extended backward across the clavicle and shoulder, in which some of the divided fibres of the trapezius could be seen. The outer end of the inner fragment was directed sharply upward, the outer fragment lying below and a little distance from it. The wound healed almost entirely in about six weeks, but when last seen there was still a sinus over the end of the inner fragment through which a probe could be passed to the bone.

Incomplete or partial fracture is, according to Hamilton, who gave much attention to this variety, very common. He thinks that 34 of the 157 fractures of the clavicle recorded by him¹ were partial fractures, and says that at least eleven of these were immediately and spontaneously restored to their natural axes. The symptoms accepted for this diagnosis are the history of a fall upon the shoulder, or at least indirect violence, the youth of the patient, a swelling upon the upper surface and front or rear border of the middle third of the bone appearing within two or three days after the accident, possibly a change in the axis of the bone, and possibly ability to straighten it with slight crepitus.

1. Complete fracture of the middle third may be oblique or transverse, the former variety being found most commonly in adults, the latter in children. The line of an oblique fracture usually runs inward and downward or backward, but may take any other direction and may be nearly transverse, or extremely oblique (Fig. 76), or practically longi-

FIG. 76.



Oblique fracture of the clavicle.

tudinal, as in a case observed by Chassaignac and mentioned by Polailon,² in which the fracture ran from the centre of the acromial end to a point just external to the sterno-clavicular articulation, dividing the bone into two longitudinal halves. Multiple and comminuted fractures are rare. When the fracture is multiple or double, the intermediate fragment is likely to occupy a very irregular position.

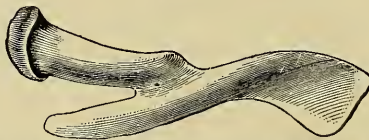The most common displacements are produced by the falling forward, downward, and inward of the shoulder, the consequence of the loss of support normally furnished by the clavicle, and depend somewhat upon the direction of the line of fracture. The commonest form is that in which the sternal fragment is drawn upward by the sterno-cleido-mastoid muscle or pushed upward by the outer fragment, which

¹ Hamilton : Fractures and Dislocations, 6th ed., p. 90.

² Polailon : Dict. Encyclopédique, art. Clavicule, p. 682.


is displaced inward along the under or anterior surface of the other and has at the same time changed its direction somewhat by the sinking of its acromial end. The shortening may be very notable, nearly one-third of the entire length of the bone in a specimen mentioned by Malgaigne. Another form is found where the line of fracture is such that the fragments do not readily leave each other, and the broken ends are displaced together upward and backward by the falling in of the shoulders so that the bone forms an angle at the seat of fracture. In some exceptional cases the outer fragment has lain upon the upper or posterior surface of the inner fragment. Malgaigne¹ says this variety was mentioned by Hippocrates, and that he himself saw one, but only one, example of it. Under these circumstances the sternal fragment is held down instead of being pushed up by the other one, and the displacement is mainly in the direction of the latter, the inner end of which is turned upward, forming a projection at the seat of fracture.

FIG. 77.



Fracture of the clavicle. Union with extreme displacement.

FIG. 78.



Fracture of the clavicle.

In transverse fractures the broken surfaces seldom leave each other, and the only displacements possible are in thickness and direction, the lateral and angular. The latter is the one usually seen, the angle being directed, for reasons that have been already stated, upward and backward.

The most common and persistent cause of these displacements is undoubtedly the tendency of the scapula and shoulder to fall forward and inward upon the chest, but it is aided largely in the first place by the fracturing force which continues to act after the bone has yielded to it. Thus, in a fall upon the shoulder or the outstretched hand, the clavicle breaks by the exaggeration of its normal curves, and as the direction of the line of fracture is usually downward and inward the outer fragment is forced inward on the under side of the other and necessarily turns the outer end of the latter upward.

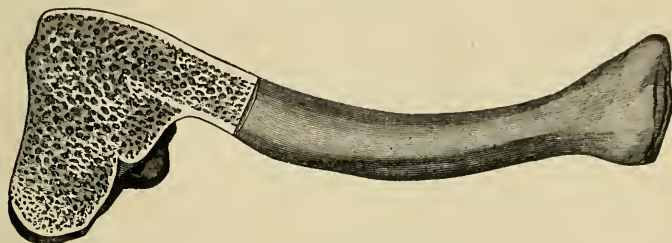
2. Fracture of the Outer Third. This variety is next in frequency to the preceding, and may be produced by direct or indirect violence. The direction of the line of fracture is more commonly transverse than

¹ Malgaigne: *Loc. cit.*, p. 468.

oblique. The degree of displacement varies greatly in different cases, being very notable in some and slight or entirely absent in others.

When displacement exists it is usually an angular one, the apex of the angle being directed backward. In some specimens¹ bony union has taken place between the clavicle and the scapula, presumably by ossification of the coraco-clavicular ligament. It is in the form of a prop extending from the under side of the clavicle to the base of the coracoid process, and sometimes to the notch of the scapula, and usually convex posteriorly.

FIG. 79.



Fracture of the clavicle, outer third. Extreme angular displacement. (R. W. SMITH.)

When the fracture is external to the trapezoid ligament—that is, when it lies within the outer inch of the bone—angular displacement is the rule, the outer fragment turning forward and inward until its axis is at right angles with that of the inner fragment; sometimes its broken surface lies against the anterior border of the inner one, and sometimes the outer fragment lies under the inner one. Malgaigne describes a case in which, after fracture within half an inch of the articular surface, the inner fragment was elevated an inch above the other, and there was shortening of nearly half an inch; the appearance, in short, was that of a dislocation upward of the acromial end of the clavicle.

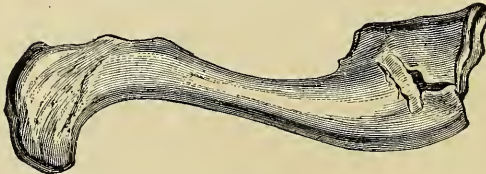
3. **Fracture of the Inner Third.** The older division, which was into fractures of the body and fractures of the outer end, took no special notice of this variety which received its first separate description from Malgaigne. It is the least common of the three; Delens,² who wrote the first formal article upon the subject, collected twenty-eight cases, to which Polaillon two years later added three. I have seen one caused by a direct blow with a baseball. The fracture may occupy any point in the division, and is more often oblique than transverse. It was asserted at first that the displacement did not occur if the fracture was within the region of the attachment of the costo-clavicular ligament, but the contrary has since been proved; displacement may take place in any direction, but the commonest one is downward and forward of the inner end of the outer fragment, or of the adjoining ends of both fragments if they do not separate from each other. Polaillon attributes the principal part in the production of this displacement to the action

¹ Smith: Dublin Journ. Med. Sci., 1842, p. 478, and Fractures in the Vicinity of Joints, p. 212.

² Delens: Archives Générales de Méd., 1873, vol. i. p. 529.

of the pectoral and deltoid muscles upon the outer fragment, and finds support for his opinion in the fact that this displacement has always been observed after fracture by muscular action; and as in this variety the fracture is usually near the inner articular surface, in a region, that is, where displacement after fracture by other causes is slight or absent, the argument is not without weight, although the obliquity of the line of fracture in such cases as that represented in Fig. 80 cannot be entirely foreign to the direction and degree of the displacement. When the fracture is transverse the lateral displacement may be slight or entirely absent and the periosteum may remain untornd. Longitudinal fracture with comminution was seen in one case, and Hamilton reports another in which the line ran from the articulation upward and outward for one and a half inches. The fragments overlapped three-fourths of an inch and were firmly united. In two cases the end of the outer fragment lay underneath the inner one and both were directed upward and backward. The outer end of the inner fragment is acted upon more strongly by the sterno-cleido-mastoid muscle than by any other, the effect of which is to draw it upward, and this effect is increased by the pressure of the outer fragment when that is forced in front of and below the other, so that whenever the two fractured surfaces leave each other the inner fragment is likely to incline upward.

FIG. 80.



Fracture of the clavicle, inner third. (GURLT.)

Multiple Fractures. But few cases are recorded in which the bone has been broken in two or more places; in some the fracture was by direct, in others by indirect, violence. Both fractures have been found in the middle third, but more commonly they occupy different thirds. When one fracture has been in the acromial, and the other in the inner or middle third, the intermediate piece has not shown much displacement, and each fracture has followed the usual course of a single one; but when the fractures have been within or close to the limits of the middle third, the displacement has been very notable.

Complications. Complications of fracture of the clavicle consist in injuries to the vessels, nerves, and lungs, and are exceedingly rare, excluding gunshot wounds in which the complications are produced by the ball and not by the fractured bone. Taylor¹ reports a case of aneurism of the subclavian artery and quotes another seen by Heath. Gallois and Piollet² report a case of arterio-venous aneurism (subclavian artery) and collected three others. Dupuytren speaks in a

¹ Taylor: *Annals of Surg.*, 1903, p. 638.

² Gallois and Piollet: *Rev. de Chir.*, 1901.

lecture of having seen two or three cases of aneurism following fracture of the clavicle, and Jacquemier gives a case observed by Blandin, of an aneurism of the acromial branch of the acromio-thoracic artery following fracture by direct violence. Taylor¹ reports a case of aneurism of the subclavian caused by a splinter from the fractured clavicle and quotes 3 others by Heath,² Boulby,³ and Twyman.⁴ Taylor's recovered after operation. Meinhold⁵ reports a case of gradual interruption of the current in the subclavian artery, becoming complete three and a half months after fracture in the middle by direct violence, healing with angular displacement; relieved by resection of the angle. In a case reported by Fisk⁶ of rupture of the subclavian and of four of the roots of the brachial plexus, with a subperiosteal fracture of the clavicle without displacement, by the fall of a heavy piece of iron upon the patient's shoulder, the fracture seems to have been an unimportant, non-causative incident, and the artery and nerves to have been torn by extreme depression of the shoulder. (Cf. similar rupture of the nerves in Flaubert's case quoted in Chapter XXXIV., *Emphysema of Cellular Tissue*.)

A few cases are reported of injury to the subclavian or internal jugular vein, in some of which the diagnosis was verified by autopsy. (See First Edition and Taylor, above quoted.)

In the museum of St. George's Hospital is a specimen in which the fractured end of the bone was driven through the internal jugular vein. A man⁷ fifty-nine years old broke the right clavicle in the middle third by a fall upon the shoulder. The fracture was very oblique from without inward and backward, and the vein was torn completely across by the outer fragment. The artery and nerves were not injured.

Fifteen cases⁸ have been reported in which symptoms indicating injury to the brachial plexus have appeared immediately or after an interval. In most of those in which they appeared promptly the causative violence was great and the displacement of the fragments marked, but in mine there was no displacement. In one (Velpeau) extensive subcutaneous emphysema showed injury to the lung, and fracture of no rib could be detected. In two (Earle, Stimson) there was paralysis of the scapular muscles supplied by the supra-scapular nerve which leaves the plexus above the clavicle. In two (Davis, Mauclaire) the displacement was corrected by operation with relief of symptoms, and in one (Poirier) the arm was amputated because of the pain. In six cases (Hassler, Sieur, Delens, Polaillon, Lequyer, McCosh) the symptoms appeared late; they were due to excessive callus in the first-named five and to a cicatrix involving the plexus in the last; all were relieved by operation; but Lequyer's only slightly.

¹Taylor: *Trans. Royal Acad. of Med. in Ireland*, 1903, p. 225.

²Heath: *Med. Chir. Soc.*, vol. 63.

³Boulby: *Path. Soc.*, London, vol. 42, p. 79.

⁴Twyman: *Lancet*, 1890, vol. i, p. 1352.

⁵Meinhold: *Münch. Med. Woch.*, 1904, No. 17.

⁶Fisk: *Annals of Surgery*, 1904, p. 1011.

⁷*Prog. Méd.*, 1882, No. 16.

⁸Desault, Velpeau, Earle, Gibson, quoted by Grull, *loc. cit.*, ii, pp. 601, 604, 606; Polaillon, *loc. cit.*, p. 696; Mercier, *Des Complications des Fractures de la Clavicule*, 1881; Delens, *Arch. de Méd.*, Aug., 1881, p. 170; Stimson, *N. Y. Med. Journ.*, June 11, 1887; Poirier, *La Semaine Méd.*, Sept. 2, 1891; Mauclaire, *Ibid.*, Oct. 17, 1894; Hassler, *Lyon Méd.*, January 12, 1896; Sieur, *Bull. de la Soc. de Chir.*, vol. 25, p. 503; Davis, *Annals of Surg.*, Feb., 1895; McCosh, *Annals of Surg.*, 1902, vol. 35, p. 110; Lequyer, *Gaz. méd. de Nantes*, 1906, No. 15, *abst. in Zülblatt für Chir.*, 1906, p. 1016.

Injury to the lung, as evidenced by emphysema, has been recorded in five cases where this symptom seemed to be demonstrative, and in two others in which it is much more likely that the emphysema was due to the introduction of air through a wound of the soft parts.

The first five cases are those of Vigarous, Velpeau, Huguier, Rühle, and Mercier. All except the fourth are described with all the details obtainable in a thesis by Mercier.¹ (See First Edition.)

The anatomical demonstration of the immediate agency is lacking in all these cases, but the notes in all but one show that the surgeons were mindful of the possibility that a fracture of a rib might coexist and might have been the cause of the wound in the lung, and that they were unable to detect such a complication. In most of them, too, mention is made of the depression of the outer fragment, and as the relations of the clavicle to the upper portion of the thoracic cavity are such that it is not difficult to admit the possibility of a wound of the apex of the lung by the broken bone, I think the clinical evidence may be accepted as sufficient.

Etiology.

The clavicle may be broken by muscular action, by direct violence, or by indirect violence.

Gurlt² and Delens³ collected and analyzed a number of reported cases of fracture by muscular action. The efforts by which the fractures were caused were various: lifting a heavy weight; striking with the hand, a whip, or racket; making a vigorous effort that involved the contraction of many muscles, as in Legros Clark's case of a lad who, while swinging by the feet from a trapeze, tried to raise himself so as to seize the bar with his hands: the clavicle broke in its inner third during the effort. It is probable that the clavicular fibres of the deltoid and pectoralis major are the most efficient agents in producing this fracture, since their contraction tends to draw the unsupported central portion of the clavicle downward and outward toward the humerus when the arm is fixed.

Closely allied to these cases are those in which the fracture has been produced by a blow or other force acting at the hand; thus, an old woman broke her clavicle by closing the door of a wardrobe forcibly, and a lunatic at Bicêtre broke his by striking violently with a heavy stick against some iron bars.

In a very few of the cases the fracture has been produced by two efforts, or a blow and an effort, separated by a longer or shorter interval; the patient feels pain at some point in the clavicle after a fall or a blow or an effort, which persists, perhaps, but is not severe and does not interfere with the use of the arm; and then in a few days, after another violence or effort, the bone breaks. If the second violence were sufficient in itself to account for the fracture, the first one might be regarded as a mere coincidence, but it has generally been less than the first.

¹ Mercier: *Des Complications des Fractures de la Clavicule*, Thèse de Paris, 1881.

² Gurlt: *Loc. cit.*

³ Delens: *Loc. cit.*, and *Arch. Gén.*, 1875, vol. i. p. 257.

Direct fractures are produced by varied causes, and may occur at any part of the bone, but most frequently in the middle and outer thirds. The commonest form of violence is a blow falling upon the centre of the bone in a direction that is backward and downward.

Indirect fractures, which constitute the great majority, are most frequently produced by a fall upon the shoulder or upon the hand or elbow, the arm being extended and the muscles rigid. In a few cases the fracture has been caused apparently by the sudden depression of the shoulder, by which the clavicle was bent over the first rib. Malgaigne¹ reports one: an incomplete fracture at the middle of the bone due to the slipping of a burden from the shoulder to the arm; and Polaillon² another: a man who held the end of a lever which was to receive part of the weight of a heavy stone, the stone slipped suddenly upon the lever and drew the arm which held it downward. The man heard a snap and felt pain in the shoulder; the clavicle was broken in its middle third.

The clavicle has been broken in a number of cases during intra-uterine life by external violence, and occasionally by the midwife or obstetrician during parturition.

Symptoms and Course.

The rational and physical signs common to most fractures are found in those of the clavicle. These are the deformity, mobility, and crepitus, the localized pain, and the diminution of function. Besides the deformity due to the displacement of the fragments, there is also that which is produced by the falling inward of the shoulder and which is most apparent when viewed from behind, and with it goes a very noticeable projection of the posterior border and inferior angle of the scapula.

In fractures of the middle third there is usually displacement of such a character and extent that there is no difficulty in recognizing it and its cause; the fragments can be separately grasped and moved upon each other. Crepitus, however, is not always produced by this manœuvre, for the broken surfaces may not be in contact, and in order to get this symptom it may be necessary to have the shoulder drawn backward and outward, so as to reduce the displacement.

Localized pain on direct pressure or when the shoulder is pressed inward is a valuable sign in partial fractures and in fractures without displacement, and it may be the only one that is present immediately after the injury; the appearance within a week of a firm oval mass at the point where pain was felt confirms the diagnosis of fracture.

The interference with function seems to be largely the consequence of the pain which makes the patient unwilling to move the arm, rather than of any mechanical defect produced by the fracture. The patient can usually move the arm quite freely backward and forward, but cannot raise it or adduct it without pain, and if asked to put his hand

¹ Malgaigne: *Loc. cit.*, p. 463.

² Polaillon: *Loc. cit.*, p. 679.

on his head, will usually flex the forearm, incline the body, and bend down his head to accomplish it. The fracture and displacement are not entirely without influence in this limitation of the movements, but they are not wholly responsible for it. Hurel,¹ who profited by his internat at the hospital for convalescents at Paris, to examine the later condition of patients with this fracture, found the movement of circumduction of the arm the last to be regained, and that a shortening of half an inch or more delayed complete recovery considerably beyond the time that was sufficient for it when the shortening was less or absent.

The patient's appearance is often quite characteristic; he sits with his body and head inclined toward the injured side and supports the elbow with the other hand. The only cases in which the diagnosis can well remain in doubt after even a brief examination are those of incomplete fracture, and some of fracture close to either end of the bone which may be mistaken for dislocation. On the other hand, the crepitus which is so frequently present in dislocation of the acromial end of the clavicle, because of the chipping of the edge of the joint, may lead to a diagnosis of fracture. Either error may be avoided if the outline of the bone can be accurately traced.

The progress of the fracture is simple and is rarely disturbed by complications or dangers. Union is usually firm by the end of the fourth week, sometimes much earlier, and failure of union is rare. Displacement and shortening, however, are the rule; only those cases, apparently, are exempt in which the line of fracture is transverse and there is no displacement at first. The amount of the shortening may vary from a fraction of an inch to one and even two inches, and it may be produced by angular displacement, or by overriding, or by both.

The complications that may occur in the course of the repair are the ordinary inflammatory ones that may arise at the seat of fracture in consequence of the bruising of the surrounding parts, or of the failure to immobilize the fragments, or special ones due to the pressure of the fragments or callus upon the vessels and nerves. (See above, *Complications*.) Delens's² case is very satisfactory. The patient was brought to the hospital January 1, 1881, with fracture of the left clavicle and two ribs. The arm was placed in a Mayor's sling, and union was complete by the end of the month. The patient returned on March 19th, complaining of great loss of power in the left arm; examination showed marked overriding of the fragments, the outer lying in front of the inner one, with a hard, firm callus two inches thick, atrophy of all the muscles of the left arm, and passive congestion of the skin of the hand; the pulsations of the left radial artery were much weaker than those of the right. The posterior and lower portion of the callus was removed by operation, the pulsations of the radial artery and the appearance of the hand at once became normal,

¹ Hurel: *Les Fractures de la Clavicule*, Thèse de Paris, 1867.

² Delens: *De la résection d'un cal de la Clavicule comprimant les vaisseaux et les nerfs sous-claviers*, in *Archives de Médecine*, August, 1881, p. 170.

and the patient gradually recovered the use of the limb. McCosh¹ briefly reports a case relieved by dissecting the plexus out of a mass of cicatricial tissue apparently caused by fracture.

In another case Gosselin removed a portion of callus which had caused persistent ulceration of the soft parts covering it. A prompt cure followed.

Ossification of the coraco-clavicular ligament has been observed in several cases after fracture in the outer third. No description is given of the modifications, if any, of the functions of the part produced by this ankylosis.

Failure of union is rare, and in the few cases which have been recorded it does not appear to have resulted in any diminution of function; in one case carefully examined by Hamilton where there was ligamentous union and overriding to the extent of half an inch the arm on the affected side was in every way as strong and as fit for use as the other.

Simultaneous fracture of both clavicles is a relatively rare accident. Writing in 1881, I found twenty-eight cases collected by five authors. but a year seldom passes now without the report of one or more cases. In position, symptoms, and mode of production these double fractures do not differ materially from single ones. Sometimes they are produced simultaneously by lateral pressure upon the shoulders, sometimes successively by two different blows, and once simultaneously by a kick by a horse, each hoof breaking a clavicle.

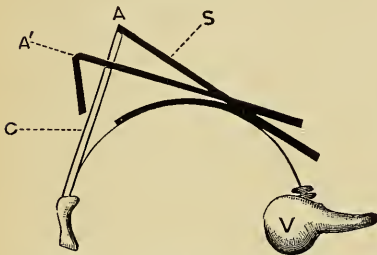
In three of the six cases collected by Malgaigne, union failed in both bones, and he has left a very complete account of the resultant disability in one of them which was under his own care. In the others there was apparently but little permanent interference with the functions of the arms. In none of the recently reported cases has failure of union been noted. In recent cases there is sometimes considerable dyspnoea, which Hurel thinks is due to the weight of the arms and shoulders upon the thorax, aided perhaps by the loss of power of the accessory muscles of respiration, those which pass from the neck or thorax to the clavicle and scapula. This dyspnoea is relieved by the dorsal decubitus if the shoulders rest upon a firm support. The condition of Malgaigne's patient on examination three years after the accident was as follows: the shoulders appeared to be below, in front of, and on the inner side of their normal positions, the shoulder-blades stood out posteriorly three or four inches from the chest-wall and were inclined forward and outward, and the upper part of the chest seemed much contracted. The clavicles were broken at the centre, and the outer fragments were below and behind the inner ones. The shoulders could be drawn back slightly, but not enough to overcome the displacement forward, and they could be drawn forward so far that they were separated by an interval of only three inches, measuring across the chest. The arms could be raised to the horizontal line in front and on the side, but not behind.

¹ McCosh: *Annals of Surgery*, 1902, vol. xxxv. p. 110.

Treatment.

The indications for treatment are to reduce the displacement and to prevent its recurrence. The means by which they are to be met do not differ materially in the different fractures, but in describing them I shall have mainly in mind fractures of the middle third.

FIG. 81.



Mechanism of displacement after fracture of the clavicle: A, acromion; C, clavicle; S, scapula; A', position of the acromion after the fracture.

As has been already said, the shoulder and outer fragment are usually displaced inward, forward, and downward, and the outer end of the inner fragment is displaced upward. The force which produces the first displacement is the weight of the shoulder. It must be remembered that the shoulder hangs out from the chest as a sign hangs out from the side of a house; the scapula and clavicle are two lateral supports, and the trapezius muscle is a suspensory one. A glance at Fig. 81 shows how the fracture of the clavicle removes one lateral support, and how the weight of the shoulder, being no longer supported upon that side, swings forward and inward until a new equilibrium is found. This movement of rotation carries the posterior portion of the scapula away from the back at the same time that it brings the anterior portion nearer the front, and as the upper part of the chest is dome-like and not simply cylindrical, and as the movement, the change of position, takes place therefore in a vertical as well as in a horizontal plane, the shoulder drops and the inferior angle of the scapula rises, by comparison at least, if not actually. Reduction, therefore, is to be accomplished by carrying the shoulder back to its former position, and retention by supplying the support previously given by the clavicle. These indications have been clearly understood since the time of the earliest writers, but it has been found very difficult to embody them in practice, because there is no means of acting in the desired manner upon the shoulder that does not involve an amount of discomfort that patients will not ordinarily submit to. Moreover, in some cases surgeons have lost sight of the fact that the position of the arm is a secondary one, its importance being due solely to its use as a means of acting upon the outer end of the scapula, and that it is useless to press the elbow upward unless the scapula is left free to be raised by that pressure. It is entirely useless to bind the elbow to the shoulder on the same side; such dressings do not raise the scapula.

One of the methods of reduction employed by Hippocrates resembles in principle very closely the dressing suggested by Velpeau and employed with much success by him and others. He placed the hand of the affected side upon the opposite shoulder and then pressed the elbow forcibly upward and outward. As the arm lies thus across the chest its long axis is exactly in the direction in which pressure should be

made to overcome the usual displacement. Another method employed by Hippocrates was to place the patient upon his back with a small, hard cushion between his shoulders, and then to press backward upon the acromion or the head of the humerus while the elbow was pushed up by an assistant. Paulus Ægineta made extension by drawing the arm upward and outward, and counter-extension by the neck or other arm, and he also recommended the axillary pad with the elbow brought close to the side. Guy de Chauliac placed his knee between the patient's shoulders and drew them backward. These methods are the types of all that have since been used or that are now in use.

Reduction, in short, is to be sought by carrying the shoulder upward, outward, and backward, acting either directly upon it or indirectly through the elbow, or using the arm as a lever. Polaillon recommends strongly a method based upon the latter principle; standing behind the patient he passes the hand or forearm into the axilla, and draws upward and backward with it, while with the other hand he presses the elbow against the side and thus forces the shoulder outward.

In some cases it is necessary to have these efforts made by an assistant in order that the surgeon himself may be at liberty to make such movements of coaptation as may be needed to overcome the obstacles offered by points or irregularities upon the surface when the line of fracture is transverse or nearly so. In transverse fractures with only angular displacement upward and forward it is sometimes sufficient to make pressure upon the angle.

The physical obstacles that need to be overcome in the treatment are so great and the success that has attended the different methods has often been so moderate that the number of plans that have been proposed and employed is very great, and the history of the treatment shows mainly a recurrence of periods marked at first by elaboration and multiplication of details and precautions and then by the abandonment of them all and the substitution of something very simple. The results obtained by the simple scarf or sling are often as good as those furnished by the most elaborate bandaging, and the discomfort to the patient during treatment is much less.


The differences in the methods depend in great part upon the indication which each surgeon has had more particularly in mind, upon the displacement which he sought to prevent. Thus, in some, the special object of the dressing is to maintain the shoulder elevated, in others to hold it back, and in others again to draw it outward. The type of the first class is a band passing under the elbow and forearm and around the neck, the forearm lying across the chest. That of the second is a posterior transverse splint to the ends of which the shoulders are made fast, or an anterior transverse splint pressing the shoulder back. That of the third is the axillary pad used as a fulcrum to force the shoulder out by pressing the elbow in.

When the patient is sufficiently desirous to avoid any visible irregularity in the outline of the clavicle to bear the discomforts of a prolonged rest in bed without change of position, and when the displacement can be reduced, treatment in the recumbent position holds out the best prospect of recovery without deformity. The patient should

be placed upon his back (or rather upon *her* back, for it is not probable that any one but a lady whose social position requires her neck to be left at times uncovered will submit to this confinement), upon a firm mattress with the neck bent so as to relax the sterno-cleido-mastoid upon the injured side, and the elbow fastened to the side or chest or raised upon a cushion so that the weight of the arm may tend somewhat to force the shoulder upward and backward, anatomically speaking. It has been recommended also that a firm narrow cushion be placed along the spine between the shoulder-blades, and Robert preferred to have the patient lie not entirely flat upon the back, but inclined slightly toward the uninjured side. In one case digital pressure was made upon the fragments throughout the treatment to insure accurate coaptation. The position must be kept practically unchanged for at least two, and probably for three, weeks.

MAYOR'S SCARF or SLING (Fig. 82) is made of a square of muslin, the diagonal of which is long enough to extend easily around the body.

FIG. 82.



Fracture of the clavicle. Mayor's scarf.

FIG. 83.



Velpeau's dressing for fracture of the clavicle.

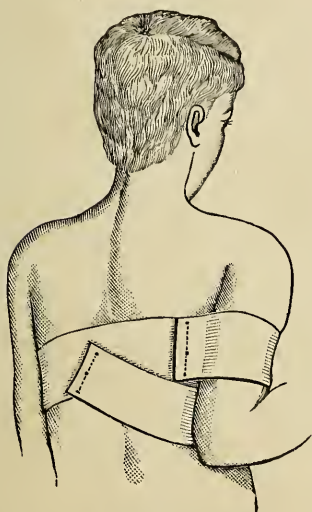The forearm is flexed at a right angle and laid across the breast; the cloth, folded diagonally, is laid over it and tied around the body so that its folded border runs horizontally around an inch or two above the forearm, in front of which the cloth hangs down. The free point of the triangle is then brought up between the forearm and the body, and the two folds of which it is composed are secured, one on either side of the neck, by bands attached to the scarf behind and brought forward over the shoulder; or the forearm is placed between the folds of the triangle, the folded diagonal of which thus forms the lowest part of the dressing, while its ends are tied around the body as before. The folds that form the third point are tied together about the neck.

This method is suitable for fractures without much displacement, especially for those in children with untorn periosteum.

VELPEAU'S DRESSING (Fig. 83) is more secure. It is made with a long roller-bandage. The elbow is brought well in front of the chest and the hand placed on the opposite shoulder, and the limb is drawn snugly up toward the neck by successive turns of the roller which, beginning at the opposite axilla, pass obliquely across the back, over the shoulder, in front of the arm, under the elbow, and back to the axilla; after three or four such turns have been placed the bandage is carried circularly around the body covering in the arm from below upward. The turns should be secured by stitching or by soaking in dextrine or plaster.

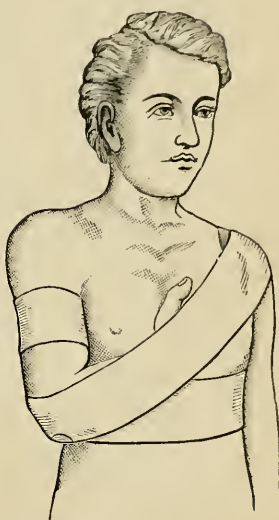SAYRE'S DRESSING (Figs. 84 and 85). A very convenient and popular dressing is the one introduced by Prof. Sayre. It is made of

FIG. 84.



Sayre's adhesive plaster dressing for fracture of the clavicle. First piece.

FIG. 85.



The same. Second piece.

two strips of stout adhesive plaster, each about three inches wide and long enough to go once and a half around the body; one end of the first strip is stitched closely about the arm just below the axilla, and the other carried around the chest from behind forward, as shown in Fig. 84. The second strip is then carried from the top of the shoulder on the uninjured side across the back, under the elbow, and along the forearm to the shoulder again (Fig. 85). The elbow should be drawn back while the first strip is applied, and well forward while the second is. The object of the first strip is to fix the upper middle portion of the arm, so that when the elbow is brought forward by the second one the shoulder shall be forced backward and upward. It is a convenience to the patient to have the plaster carried past the ulnar side of the hand so as to leave the latter uncovered. The action of the dressing is simply to press the shoulder upward and backward, and its principal

advantage lies in the solidity which the use of the adhesive plaster gives. A thin pad of absorbent cotton may be placed in the axilla to absorb perspiration.

THE AXILLARY PAD, designed especially to prevent shortening by forcing the shoulder outward, has been in use for many centuries, and reached its highest development at the hands of Desault, of whose complicated dressing it forms the essential part. I believe that whenever it is large and firm enough to accomplish its object it is dangerous, and whenever small enough to be free from danger it is useless.

The dressings which are intended mainly to draw the shoulder backward are modifications of the figure-of-eight bandage and the posterior and anterior splints. The simple figure-of-eight carried across the back from one shoulder to the other, either in muslin or plaster of Paris, I have found to interfere too much with the circulation in the arms if efficiently applied. In two cases of marked displacement which could be reduced by drawing the shoulders back, but which recurred under the usual dressings, I obtained a satisfactory result by the use of a breast-plate made of crinoline soaked in plaster cream and covering the front of the chest and shoulders. The shoulders were held back and reduction maintained until the plaster had set, and then the position was maintained by a figure-of-eight bandage. The heavy ends of the breast-plate in front of the shoulder prevented compression of the axillary vessels by the bandage, and the dressing was worn with comfort for three or four weeks.

Mayer and Cordua¹ recommend that the forearm should be fixed behind the back and the shoulder held back by a strip of adhesive plaster passing across its front to the back. Mayer had used it only in a case of fracture of the outer third, but Cordua appears to have generalized its use. He says that patients soon adapt themselves to it.

A modification of the figure-of-eight suggested by Récamier amounts almost to a posterior splint. He placed a large, hard square cushion between the shoulders behind and carried a bandage from each upper corner over the shoulder and under the axilla back to the lower corner.

POSTERIOR SPLINTS have been made in the form of a cross, against the arms of which the shoulders were drawn back, and as iron, wooden, and pasteboard splints crossing the back and extending usually beyond the shoulders, so that the traction of the bandages by which the shoulders were made fast should be exerted in an outward direction as well as backward.

A fixed support shaped like the upper end of a crutch and fastened to the side of the chest by adhesive plaster has been occasionally suggested and even used. Like the axillary pad it is probably intolerable or dangerous if applied efficiently.

It is apparent that while many different dressings may give good results in certain cases, none can be depended upon to do so in all, and that the displacement, the shortening, which is the rule in the adult, is the result in some cases of forces which cannot be effectually controlled, of the obliquity of the fracture, and not infrequently of the indocility of the patient, who, finding himself incommoded by the dressing, shifts

¹ Mayer and Cordua : *Zentralblatt für Chir.*, 1906, pp. 1004 and 1200.

it slightly, but often, until he obtains ease at the sacrifice of the object it was applied to secure.

If the fracture is without displacement, especially the subperiosteal fracture of children, or if the displacement shows but little tendency to recur after reduction, the simple scarf or sling or Sayre's dressing will answer every purpose.

If, on the other hand, the tendency to displacement is great, the choice of a method of treatment will depend largely upon the character and wishes of the patient. If he is indifferent to the deformity or intolerant of restraint, it is useless to attempt more than a simple dressing; but if he is willing to submit to the confinement, the fracture may be treated by dorsal decubitus and digital pressure with a fair prospect of success, or by the plaster-of-Paris breast-plate and figure-of-eight bandage. Fortunately, persistence of displacement does not necessarily cause loss of function.

In simultaneous fracture of the two clavicles, the dorsal position is strongly to be recommended.

It is well to place in the axilla a pad of cotton wrapped in a compress to absorb the moisture and keep the opposing surfaces from contact with each other; and for the same reason a compress should be placed between the arm and the body, wherever the two would otherwise be in contact.

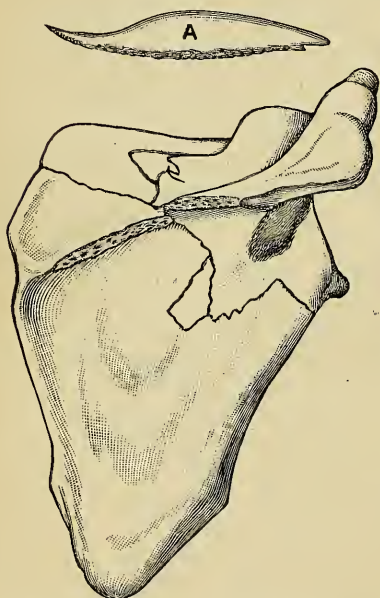
The dressing should be worn for from fifteen to twenty days by children, and twenty to thirty days by adults.

CHAPTER XVIII.

FRACTURES OF THE SCAPULA.

FRACTURES of the scapula clinically recognized are comparatively rare, about 1 per cent. of all fractures according to the best statistics at

FIG. 86.



Fracture across body of the scapula, with separation of a long piece of the spine, A.

our command, but Lane's¹ observations in the dissecting-room indicate that fractures of the acromion are very common and must, therefore, usually pass unrecognized. They are six times as common in men as in women, and in the great majority of cases the patients have been between twenty and fifty years of age.

The size and shape of the bone, and the presence of three irregular and prominent apophyses permit a diversity of fractures differing so greatly in their mode of production and symptoms that it becomes necessary to consider them separately. Most writers in the last hundred years have made from six to eight groups as follows: 1st, fractures of the body; 2d, fractures of the inferior angle; 3d, fractures of the upper angle and supra-spinous fossa; 4th, fractures of the spine; 5th, fractures of the acromion; 6th, fractures of the coracoid process; 7th, fractures through the surgical

neck; 8th, fractures of the glenoid cavity. Of these varieties the 1st, 4th, and 5th are by far the most common; the others are extremely rare.

1. Fractures of the Body of the Scapula.

Fractures of the body of the scapula are single or multiple. The former are confined to the subspinous fossa, and the direction of the line of fracture is transverse or oblique. The fragments may preserve their normal relations to each other or there may be displacement, the lower fragment shifting to either side of the upper one and overriding for a greater or less distance. This overriding is most marked on the axillary side and is due apparently to contraction of the teres major

¹ Lane: Guy's Hospital Reports, 1886, vol. xliii. p. 418.

and serratus, while the lateral displacement is the result of the continued action of the fracturing force. In some cases the fragments have united after transverse or oblique fracture in such a position that they touch or override at one side and are separated at the other.

In multiple fractures the lesion is extremely variable, the fracture may be "starred," or comminuted, some of the lines may be incomplete, and the main one may be longitudinal; the only condition, apparently, under which longitudinal fracture is met with (Fig. 87).

The fracture may be partial, in the form of a fissure running from one border, or circumscribed, a central piece being broken out.

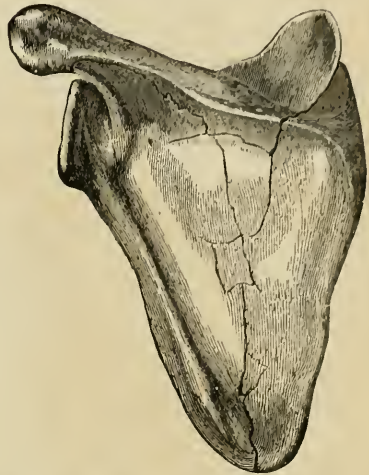
The cause of the fracture has almost always been direct violence, usually a blow or a fall upon some angular object, but in three reported cases it appears to have been caused by muscular action, as in similar fractures of the inferior angle (q. v.), the line of fracture being somewhat higher than in the latter. The cases are those of Dobson,¹ Leidy,² and Hoover.³

The objective symptoms which may be met with are irregularity in outline, abnormal mobility, crepitus, and ecchymosis. The posterior border and inferior angle of the bone can be made prominent by carrying the elbow forward and inward, and then if the finger is passed along it a transverse or oblique fracture with displacement will be certainly recognized. Abnormal mobility and crepitus can be recognized by grasping the inferior angle and moving it while the upper portion is steadied by the other hand. In multiple or partial fractures with depression the adjoining edge of bone may be felt if the patient is not too fat or muscular. The precaution should always be taken to make a comparison with the other scapula, and the normal ridges along the borders and at the base of the spine should be borne in mind. Ecchymosis, unless due to the action of the violence upon the soft parts, seldom appears until after the lapse of a few days.

Localized pain on pressure and on movement of the arm is a constant symptom, and may make it impossible for the patient to extend his arm horizontally and directly forward because it is so much increased by the contraction of the muscles concerned in this movement.

The course in the simpler cases ends in recovery in four or five weeks, usually with preservation of function even if union has taken place

FIG. 87.



Multiple (longitudinal) fracture of the scapula.

¹ Dobson : Lancet, November 27, 1886.

² Leidy : University Medical Magazine, March, 1891.

³ Hoover : Medical and Surgical Reporter, 1893, p. 848.

with some unreduced displacement. Multiple fractures are more dangerous because of the greater probability of suppuration at or in the neighborhood of the fracture, and of course if the fracture is a compound one the danger is still greater. In a very few instances there has been much disability due to failure of union or to union with displacement and exuberant callus. Gurlt quotes an example of the former in which the patient was unable to raise his hand to the back of his neck, and one of the latter in which the disability was almost complete and all communicated movements of the arm and shoulder were painful.

Treatment. In simple fracture without displacement no other treatment is needed than immobilization of the arm and shoulder during the length of time necessary for consolidation. If displacement exist it must be corrected, if possible, by placing the arm and shoulder in various positions and pressing upon the fragments with the hands in the directions indicated by the displacement. When the latter is reduced as far as possible the arm and shoulder must be immobilized by binding the arm to the side or merely supporting it in a sling, and a broad strip of adhesive plaster may be laid across the scapula to aid its immobilization.

In comminuted fractures the principal indication is to prevent the severe inflammatory reaction which is so likely to follow the bruising and laceration produced at the same time by the extreme violence that has caused the fracture. If the fracture is compound it must be explored through the wound and treated in accordance with the principles elsewhere laid down, and it is prudent in such cases to remove partly adherent fragments which could be safely left after fracture of other bones, whenever by such removal a free outlet that would otherwise be lacking is supplied to matter that may accumulate on the under (costal) surface of the bone. In a few cases of simple fracture pus has formed and caused much trouble by burrowing down the side of the body, confirming the experience furnished by some simple fractures of other bones, in which pus has formed apparently in consequence of imperfect immobilization.

2. Fractures of the Inferior Angle.

These are included by some writers in the group of fractures of the body of the scapula, from which they differ merely by the proximity of the line of fracture to the lowest part of the bone, but as they present a more constant and well-defined displacement which cannot be readily overcome or prevented they deserve separate mention. The recorded instances of separate fracture are not very numerous. Gensoul reported one produced by muscular action; the patient saved himself from falling to the ground while descending a sharp incline, either by catching hold of some support or by falling backward upon his outstretched hand; the abstracts of the report are not clear upon this point. A triangular piece corresponding to the inferior angle was detached from the scapula and displaced forward and upward, and could be moved independently and with crepitus. Gensoul attributed the

fracture to the sharp contraction of the *teres major*. Guinard¹ reports a second case and quotes a third,² the only one he could find. He adds a detailed study of fractures of the body and inferior angle by muscular action and quotes the reports of all the known cases. The histories of these cases and of those of fracture of the body suggest the possibility, even the probability, that muscular contraction was the cause in many others in which the history of a fall upon the back led to the easy assumption of fracture by direct violence.

Symptoms. The symptoms are clear and unmistakable: displacement of the fragment forward and upward by the combined action of the *serratus magnus* and *teres major*; abnormal mobility recognized by grasping the fragment with one hand and moving it, or by fixing it with one hand and moving the scapula with the other; and crepitus. In one case³ the displacement was said to have been downward.

The displacement is difficult to maintain reduced, because the smallness of the fragment prevents efficient control of it, and the tonicity of the muscles tends constantly to draw it away; but while this ensures some deformity it is slight and does not add seriousness to the prognosis.

3. Fractures of the Upper Angle.

These are very rare. Gurlt gives a figure of a specimen preserved in Dresden, and Hamilton of one in Philadelphia. In the latter a fissure extends well into the subspinous fossa. In both repair has taken place without much displacement. Gurlt records two cases observed during life; in each the injury was the result of a fall upon the back; in one there was no displacement, in the other the fragment was drawn upward and inward by the *levator anguli scapulæ*. Texier⁴ reports a case; the cause was direct violence; prompt recovery.

Treatment. The treatment is to immobilize the arm and shoulder in the position that is most comfortable, securing the scapula with a body bandage or strips of adhesive plaster, and the arm by binding it to the body with the forearm flexed across the chest.

4. Fractures of the Spine of the Scapula.

There are no known specimens of isolated fracture of the spine of the scapula, and our only knowledge of them is clinical. In those I have seen the diagnosis was readily made by recognition of the abnormal mobility, with crepitus, of the fragment, and sometimes of an irregularity in the outline of the spine.

Treatment. The treatment is as before; immobilization of the arm in a suitable position, and local antiphlogistic remedies if required.

5. Fracture of the Acromion.

The alleged frequency of this fracture has been called in question by those who deem most of the museum specimens examples either of

¹ Guinard: *Archives générales de Méd.*, April, 1896.

² Sabatier: *Union Médicale*, 1857, p. 397.

³ Denucé: *Journ. de Méd. de Bordeaux*, 1892, vol. i. p. 571.

⁴ Texier: *Journ. de Méd. de Bordeaux*, April 5, 1896.

a traumatic separation of the epiphysis or of non-ossification. The former would still belong under the head of fractures, and, even if we exclude the others, there are still clinical instances in sufficient number to make the lesion one of the most common.

The acromion is exposed to fracture by blows received directly upon it, and also through the humerus, as in a fall upon the elbow, and occasionally by muscular action. The line of fracture is usually perpendicular to the axis of the apophysis, but is sometimes oblique. It lies most frequently either in front of the acromio-clavicular joint or at the root of the acromion, rarely at an intermediate point.

The symptoms are those of fracture, and of the contusion if the agency has been direct violence; and as the latter are prominent and may obscure the former, the fracture may be overlooked. The signs common to both are ecchymosis, local or extending down the arm, swelling, and pain. The additional signs of fracture are increase of the local pain on pressure and on moving the arm, usually complete inability to abduct the arm, abnormal mobility, and crepitus, and possibly displacement.

The displacement varies with the position and extent of the fracture. If the latter involves only the outer end of the apophysis, the displacement is slight and downward by the contraction of the attached fibres of the deltoid, the shoulder loses a little of its roundness in consequence, but the head of the humerus retains its place. If the fracture is near the base of the apophysis, the weight of the arm tends to draw the fragment downward and inward, turning it upon the outer end of the clavicle as a centre, and the shoulder is flattened. The finger passed along the spine recognizes an irregularity in the outline, usually a depression of the outer fragment, but sometimes an elevation or a transverse groove or gap in which the end of the finger can rest.

Crepitus can often be got by lifting the elbow directly upward, so as to push up the acromion, or by abducting the arm; and abnormal mobility must be sought by varied manipulations of the apophysis and by moving the arm.

The commonest functional disturbance is the inability to raise the arm, although this is not a constant symptom, while the power of rotation is preserved unaltered, even if somewhat painful.

Bony union appears to be the exception, the fragments uniting by a fibrous bond of greater or less length and solidity; the rupture or the preservation of the periosteum must be of almost controlling importance in determining the character of the union. Apparently, bony union takes place only when the fragments remain in close contact. In one case the distal fragment became necrosed and was cast out.

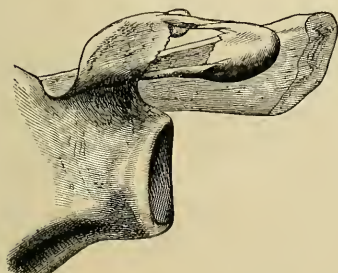
Treatment. The treatment consists in reduction of the displacement by pressing the head of the humerus upward against the acromion, and in securing it in this position by a bandage passing about the body and the arm. The dressing should be worn for about three weeks.

6. Fracture of the Coracoid Process.

This may be caused by muscular action or by direct or indirect violence; in the former the causative effort is sometimes comparatively slight—wringing wet clothes in one case—but more often is a powerful effort made with the arm. In fractures by direct violence other bones—ribs, arm, clavicle—are usually coincidentally broken; those by indirect violence appear, according to the observations of Lane,¹ to be most commonly produced by pressure of the tip of the process against the clavicle in forced flexion of the shoulder; other instances are those in which the fracture is produced by the impact of the dislocated head of the humerus.

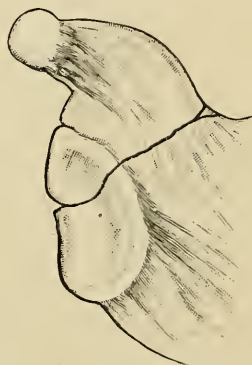The line of fracture is usually about an inch behind the apex of the process, but sometimes is further back, passing close to the upper edge of the glenoid cavity in a line that corresponds so nearly to the position of the epiphyseal cartilage that some observers consider some specimens to be examples of separation of the epiphysis, or even simply of delay in ossification. Normally this conjugal cartilage ossifies at about the fourteenth year. Bennett² published a case of separation of the epiphysis, verified by autopsy, in a child six years old. In one of Mal-

FIG. 88.



Fracture of the coracoid process.

FIG. 89.



Fracture at base of coracoid.

gaigne's and in two of Gurlt's cases the end of the process was also split longitudinally into two pieces, one remaining attached to the tendon of the biceps, the other to that of the pectoralis minor.

A unique case of fracture across the base of the coracoid and the upper part of the glenoid fossa is reported by Braun³ and represented in Fig. 89. The patient had been struck by a locomotive.

The displacement is seldom great, because the fragment is prevented from yielding to the action of the attached muscles by the coraco-clavicular ligament; still, in one of the last-mentioned cases the fragments were displaced more than half an inch downward. Petty⁴ gives a skiagraph of a case of fracture by muscular action showing fracture at the middle with tilting downward and inward of the distal portion.

¹ Lane: *British Medical Journal*, May 19, 1888.

² Bennett: *Dublin Journ. Med. Sciences*, August, 1888.

³ Braun: *Arch. für klin. Chir.*, vol. 42, p. 110.

⁴ Petty: *Annals of Surg.*, March, 1907.

Symptoms. The symptoms are abnormal mobility and crepitus, but are not easily recognized, especially if the soft parts be much bruised and swollen; the depth at which the process is placed, and the thickness of the overlying muscles, make it difficult to grasp the process between the fingers or to appreciate its independent mobility. I have also noticed localized pain on forcible voluntary adduction of the arm and flexion of the forearm.

The fracture in itself involves no danger to life, and no probable disability, although the union is seldom bony. Of six specimens examined by Gurlt bony union was found in only one; in four cases mentioned by him of which our knowledge is only clinical, mobility persisted in two. This failure of union does not seem to cause any loss of function. In Hulme's case the union was firm but the fragment somewhat displaced downward.

Treatment. The treatment must be directed to immobilizing the arm in a position which will relax, as well as may be, the muscles attached to the process. Theoretically, the best position is that in which the forearm is flexed and the elbow carried across the front of the chest, but this cannot be carried out thoroughly without causing more discomfort than the benefit to be obtained by it will warrant; and it is best, therefore, simply to fix the arm against the side with the forearm comfortably flexed.

7. Fractures of the Neck of the Scapula.

Under this term, following Gurlt, I include not only fractures which pass from the suprascapular notch to the axillary border of the scapula in a direction parallel to the surface of the glenoid cavity, but also those which begin in front of the base of the coracoid process (sometimes even within the articular border) and pass obliquely downward and backward to the axillary border. There is no known example of fracture running close behind and parallel to the glenoid fossa along what is sometimes termed the anatomical neck.

The small anterior fragment always carries with it the attachment of the triceps and usually the entire coracoid process; but the ligaments which bind the coracoid process to the clavicle and acromion remain untornd, as does also a ligament extending from the under surface of the spine of the scapula to the edge of the glenoid cavity, and they limit the displacement.

The cases in which this fracture has been verified by dissection are six in number: the cases of Duverney, Neill, and Spence, a specimen in the museum of Guy's Hospital and another in that of the Royal College of Surgeons at London, and one found by Lane.¹ Gurlt describes the first three, and Flower² mentions the next two. The exact character of Neill's³ case is uncertain; in Spence's⁴ (Fig. 90) the fracture passed in front of the coracoid process; in the others it appears to have passed through the suprascapular notch.

¹ Lane: *Loc. cit.*, p. 415.

² Flower: *Holmes's System of Surgery*, Am. ed., vol. i. p. 851.

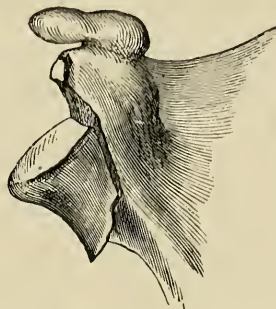
³ Neill: *American Journ. Med. Sciences*, new ser., 1858, vol. xxxvi. p. 105.

⁴ Spence: *Edinburgh Medical Journal*, June, 1863, p. 1082.

Cause. The cause has been a fall or blow upon the shoulder; May¹ reported a case caused in a girl by the effort of placing a handkerchief about her neck, but it seems more probable from the description that the injury was a fracture of the coracoid.

Farabeuf found that if the anterior portion of the capsule was made tense by outward rotation of the arm the neck could be broken

FIG. 90.



Fracture of the neck of the scapula. Spence's case. (GURLT.)

by a blow on the back of the head of the humerus or by one upon the elbow if the arm was also directed backward.

Symptoms. The symptoms of the fracture are the flattening of the shoulder, the prominence of the acromion, the absence of the head of the humerus from the axilla (where it would be found if the injury were a dislocation), the easy reduction of the displacement by raising the elbow, its immediate return when the support is withdrawn from the elbow, and the crepitus which accompanies these movements. In two of Gurlt's cases the fragment could be felt in the axilla. The power of voluntary motion of the arm is lost, but passive movements are free, and, within certain limits, painless. On the other hand, manipulations which reduce the displacement or bring out crepitus cause much pain. Sometimes the lower edge of the fragment can be felt in the posterior and outer part of the axilla as a hard movable body which can be pushed upward, with pain and crepitus, but falls back as soon as the pressure is removed. In a case reported by Ashhurst,² crepitus was obtained by grasping the parts between the fingers on the shoulder and the thumb deep in the axilla and rotating the arm. There was very slight displacement. In a personal case a point of pain on pressure could be found by passing the finger high up along the axillary border of the scapula.

The most characteristic symptom is the easy reduction and the immediate return of the displacement, and it is this which distinguishes it most sharply from dislocation of the humerus, the prominent symptoms of which are so similar.

Prognosis. According to Gurlt, bony union is the rule, fibrous union the exception, but in both cases with slight displacement of the frag-

¹ May: London Medical Gazette, 1842-43, p. 49.

² Ashhurst: Trans. Coll. of Physicians, Phila., 1875, 3d ser., vol. i. p. 69.

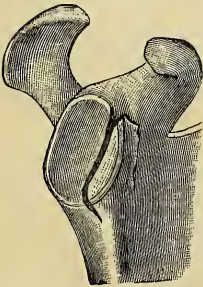
ment forward and downward. His collection contains only two cases of fibrous union; in one the patient had fair use of the arm, in the other the limb was entirely useless. In the cases where bony union was secured, repair was complete in from four to seven weeks; in some there was slight diminution of the usefulness of the limb, but in the majority its use was fully regained.

Treatment. It is doubtful if the parts can be supported by any dressing so perfectly that union without any displacement can be secured. The indications of treatment are to oppose the constant displacement downward and forward or inward by supporting the elbow; probably the dressing which I have found so efficient in dislocation of the acromial end of the clavicle (q. v.) would answer the purpose if the ends of the plaster strip were carried further inward on the shoulder.

8. Fracture of the Glenoid Cavity.

In almost all the instances that are on record this fracture has been discovered *post mortem* or during operation after dislocation of the shoulder. It is thought to be not uncommon, but as the diagnosis is very difficult its frequency cannot be determined. Usually the fracture is of the inner border of the articular surface, but sometimes the outer or lower border has been broken off; and Flower says that fractures have been found running across the glenoid fossa and even splitting it into several portions. Poland¹ showed a specimen of stellate fracture of the fossa with three lines radiating thence to the body; there was also fracture of the acromion, but no dislocation. Agnew gives a similar figure, but does not state the source from which it was derived.

FIG. 91.



Fracture of edge of glenoid fossa. (V. BRUNS.)

Symptoms. The symptoms cannot be described because no case appears to have been recognized during life; and it seems unlikely that a diagnosis could be made with any positiveness. The fragment is small and not accessible to direct manipulation, so that the only symptoms would be those of a dislocation together with crepitus on reduction, and perhaps a ready recurrence of the dislocation

—signs that may be present under a variety of circumstances.

Treatment. Treatment must be limited to reduction and immobilization, and the latter should be more complete and better guarded than after a simple dislocation, because of the greater ease with which the head of the humerus can escape from the glenoid cavity when the rim of the latter is broken.

¹ Poland: British Medical Journal, January 23, 1892.

CHAPTER XIX.

FRACTURES OF THE HUMERUS.

THE tables in Chapter I. show that, while fractures of the upper extremity (including the clavicle) constitute nearly half of all fractures, those of the humerus are only 4 per cent. of all, and this bone is less frequently broken than either the clavicle, radius, or ulna. Different tables of statistics show great variations in the relative frequency of the fractures of the different portions of the bone, some giving the greatest number to the shaft, others to the lower end, but all agree in giving the greatest frequency to the first twenty years of life.

The different varieties of fracture may be most conveniently studied by arranging them in three groups: fractures of the upper end, fractures of the shaft, and fractures of the lower end, although the first and third groups severally contain varieties which differ materially from one another.

For a remarkable case of longitudinal fracture extending the entire length of the bone which cannot be placed in any one of these groups, the reader is referred to page 27.

1. FRACTURES OF THE UPPER END OF THE HUMERUS.

The fractures of this region include fissures and chippings of the articular head, fractures of the tuberosities, of the anatomical neck, and along the epiphyseal line, and a group comprising the great majority of fractures in this region in which the line of fracture crosses the bone in a variety of ways between the anatomical neck and the lower border of the surgical neck, which is commonly drawn at the insertions of the *teres major* and *pectoralis*, and which includes fractures produced by compression, so-called, cross-strain, and torsion. Above, this group unites with or closely approaches fractures of the anatomical neck, and below with oblique and comminuted fractures of the adjoining portions of the shaft. Its upper limit may be placed at those fractures which pass along or very close to the lower (inner and posterior) portion of the anatomical neck and then reach the outer side through the greater tuberosity; the lower limit may, for clinical reasons, be conveniently placed low enough to include even quite oblique fractures in which one end of the line rises to the surgical neck. Between those at the upper limit and fractures of the anatomical neck are some in which the line is doubled on the outer side—a fracture of the anatomical neck with a second line passing through the tuberosities from about the middle of the first. As these, like pure fractures of the anatomical

neck, are frequently associated with anterior dislocation of the shoulder, and as they lack the clinical characteristics of the lower fractures, I shall describe them in the same section with fractures of the anatomical neck, but under a separate title—*fractures through the tuberosities*; their lower line is the same as that of the highest of the main group (fractures of the surgical neck), the distinction lying in the addition of a line along the anatomical neck detaching the head. The lower main group is characterized clinically by the fact that the upper fragment is peculiarly subject to the unopposed action of the scapular muscles; a separate class is made of separation of the epiphysis in the young, but fractures in the adult which follow in the main the former line of the conjugal cartilage are not separated from the main group.

In this section, then, will be considered fractures of the head, of the anatomical neck, through the tuberosities, of the tuberosities, and of the surgical neck, and separation of the epiphysis.

A. Fractures of the Head.

Simple fissures or partial fractures of the head of the humerus without associated fracture of the tuberosities or surgical neck are very rare. To the two instances which Gurlt quotes from Gosselin and Gross¹ may be added, I think, three others, one described by Malgaigne,² the other two by Houel.

Houel's first case is a specimen in the Musée Dupuytren; about one-third of the head of the humerus has been broken off and has reunited.

His second case, also in the same museum, is a specimen of fracture through the head separating a thin fragment entirely covered with articular cartilage. The fragment was turned completely over and not united. The patient was an old woman and died seven or eight months after the receipt of the injury.

The cases are much more numerous in which the articular surface is fractured in connection with fracture of adjoining parts; and in anterior dislocation of the shoulder (q. v.) deep indentation or bruising of the surface of the head by the edge of the glenoid fossa is apparently not infrequent.

B. Fracture of the Anatomical Neck, and Fracture Through the Tuberosities.³

Fracture of the anatomical neck, without an additional line of fracture through the tuberosities, is apparently a very rare, and also a very obscure, injury, except in association with anterior dislocation of the shoulder. Although it is described, and the means of diagnosis given, in all systematic works upon the subject, it must be admitted, I think, that our knowledge of it is extremely scanty and uncertain, being limited to a few specimens and to a few cases clinically observed in which the diagnosis remains more or less doubtful. The reported specimens of fresh fracture, without dislocation or additional fracture

¹ Gross' Surgery, fifth ed., vol. i. p. 985.

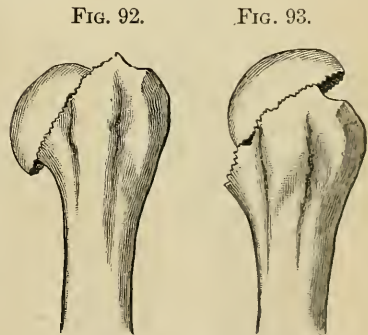
² Malgaigne's Atlas, Plate iv. Fig. 2.

³ It is to be noted that some writers include both forms under the title "Fracture of the Anatomical Neck."

through the tuberosities, are those of Boyer¹ and Spence;² both patients were aged, and in each the injury was caused by a fall upon the shoulder. The reported specimens from cases in which the fracture was associated with dislocation are more numerous, but in so many of such cases associated fracture of the tuberosities, generally without displacement, is mentioned that it seems probable it may have been overlooked or passed without comment in many of the others. These specimens have been obtained in the course of operations undertaken for the removal of the dislocated head or for the reduction of the dislocation. Usually the head remains attached to the shaft by a strip of periosteum or capsule, and in two cases (McBurney, Stimson) the line of fracture diverged from the neck and split off a thin piece of the shaft adjoining the lowest portion of the head.

The clinical cases are obscure, even uncertain. A number of supposed cases have recently been reported in which the diagnosis rested upon skiagraphic showings, but the skiagrams, as published, leave in my mind much doubt of the accuracy of this diagnosis; it seems probable that the line in fracture runs in part, at least, through the tuberosities. Koehler³ reports three cases in which he thought this diagnosis could be made. The first was a man seventy-nine years old who fell from a height upon his side; the shoulder was swollen; no deviation of the axis of the arm; shortening half a centimetre; active motion lost, passive motion gave distinct crepitus. The head projected in front below the acromion and could be drawn downward away from it, so that the finger could be passed in beneath the acromion and could there feel behind the fulness of the head in the region of the anatomical neck the edge of the lower fragment directed backward. In the second case, also a fall upon the side, the patient was nineteen years old, and the edge could be similarly felt; movements were very painful. The third patient was a woman sixty-one years old; the cause a fall upon the front of the shoulder. Slight swelling, pain, loss of function, crepitus on rotation of the arm; displacement of the upper fragment upward could be felt. Figs. 92 and 93 represent his conception of the fracture and the displacements.

I have seen only one case in which the diagnosis seemed probable. The patient, whom I presented to the New York Surgical Society,⁴ was a man about thirty-five years old, who had fallen on his back in front of a horse-car in such a way that, as the car passed over him, the



Supposed displacement and line of fracture of anatomical neck of the humerus. (KOCHER.)

¹ Boyer: *Traité des Maladies Chirurgicales*, 1831, vol. iii. p. 199.

² Spence: *Edinburgh Medical Journal*, 1830, vol. v. p. 1140.

³ Koehler: *Praktisch wichtiger Frakturformen*, 1896.

⁴ Stimson: *New York Medical Journal*, March 19, 1891, p. 310.

edge of the front platform caught against his right elbow and pressed the humerus with great force against the scapula. Swelling and pain at the shoulder, complete loss of function; the tuberosities rotated with the shaft; the acromion, coracoid, and neck of the scapula were uninjured; pressing the arm upward against the acromion gave pain and was accompanied by crepitus. He was treated in the recumbent position with moderate continuous traction for five weeks, and made a complete recovery.

On another occasion I had an opportunity to examine an undoubted case. The patient had suffered the fracture with dislocation, and I was able clearly to recognize the small, movable upper fragment in the axilla. Under anæsthesia I was, fortunately, able to reduce the dislocation, and then, being in presence of a fracture of the anatomical neck without dislocation, I examined it carefully in order to ascertain, if possible, a means of diagnosis; but I could detect nothing abnormal, no deformity, no crepitus; after the anæsthesia had ended, pressure upward at the elbow or backward at the front of the shoulder caused pain.

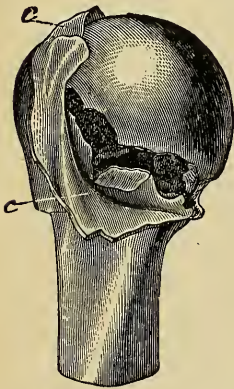
This shows that the fracture can exist without other symptoms than pain on pressing the fragments together, and that crepitus on moderate movements of the limb may be absent; which, indeed, is not surprising when it is remembered how easily the head can move in its socket and, consequently, how likely it is to share in the movement of the lower fragment if it is at all closely connected with it by irregularities of the line of fracture. Probably the most that can be said in any case is that there is a fracture above the surgical neck, but whether it is purely of the anatomical neck or combined with fracture through the tuberosities or even partly of the neck and partly through the tuberosities is likely to remain uncertain, because the determining fact—the relations of the upper part of the greater tuberosity with the shaft, its movement with it or its independence of it—may easily be beyond exact determination.

Of *fracture through the tuberosities* the examples are much more numerous. To a fracture of the anatomical neck may be added one or more lines of fracture passing from the first through the tuberosities, or the line may pass along the lower (posterior and internal) portion of the neck and then diverge through the tuberosities. The fresh specimens have almost all been obtained from cases of combined fracture and dislocation, and our periodical literature

now contains almost every year one or more instances. I have had two such, fracture of the anatomical neck with fissuring of the greater tuberosity, in which I removed the head, and have seen two others under the care of colleagues.

The distinction between this variety and the higher form of fractures

FIG. 94.

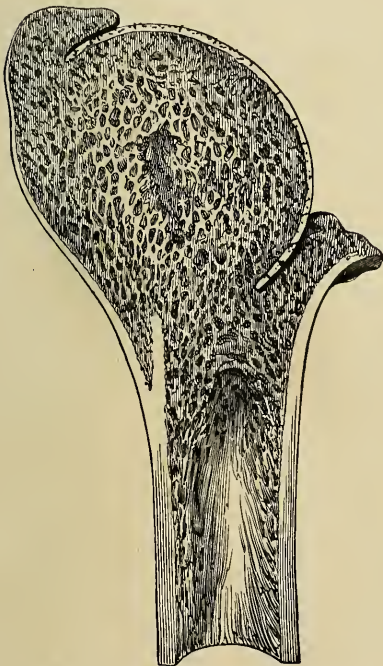

Fracture of the anatomical neck of the humerus, with slight splintering and fracture of both tuberosities. (GURLT.)

of the surgical neck (as I have here defined the latter) is arbitrarily drawn and I doubt, for the reasons given, if it can often be recognized clinically. Because of its mode of production—violence acting directly against the upper end of the bone from the outer side or in front—it is, I think, much more frequently associated with dislocation of the upper fragment than are fractures at a somewhat lower level which seem more commonly to be caused by cross-strain. Independent mobility of only the upper part of the tuberosity would at least show that the fracture was high.

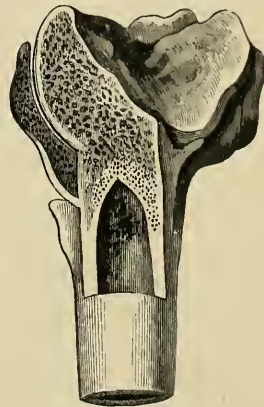
Two specimens described and pictured by R. W. Smith¹ (Figs. 95 and 96) show healing with marked impaction in one case and with complete reversal of the head in the other. In the one shown in Fig. 96, examined five years after the accident, “the head of the humerus was found to have been drawn into the cancellated tissue of the shaft between the tuberosities so deeply as to be below the summit of the

FIG. 95.



Impaction of the head of the humerus into the shaft, with splitting off of the tuberosities. (R. W. SMITH.)

FIG. 96.



Fracture through the tuberosities of the humerus. Reversal of the head. (R. W. SMITH.)

greater tubercle; this process had been split off and displaced outward; it formed an obtuse angle with the outer surface of the shaft of the bone.”

The specimen illustrated in Fig. 96 is described by the same author as “impacted fracture of the neck of the humerus, accompanied by fracture of both tubercles.” “The head of the bone was found to have been separated from the shaft by a fracture which traversed the anatomical neck of the humerus. It was reversed in the articulation, so that the fractured surface was directed upward toward the glenoid cavity, and the cartilaginous articulating surface thrown downward

¹ R. W. Smith: Fractures in the Vicinity of Joints, 1854, p. 192.

toward the shaft, and having assumed this position it was driven to a considerable distance into the cancellated structure between the tubercles. From this violent impaction of the head of the bone into the lower fragment a second fracture resulted which split off the lesser tubercle along with about two-thirds of the greater, and a small portion of the shaft of the humerus, corresponding to the upper part of the bicipital groove."

The outer part of the cartilaginous surface of the head was buried to a depth of nearly an inch, but the inner part was free; the cartilage remained perfect, and was not united to the cancellated tissue of the tubercles; the rest of the fragment was firmly united with the tissue of the tubercles, and their union also was complete. A similar case is reported by Krönlein¹ and one by Körte.² (See also Gurlt, vol. ii. p. 693.)

Doubtless, also, the upper fragment may undergo that displacement inward and downward by the rising of the shaft under the action of the deltoid which was pointed out by Jonathan Hutchinson as occurring in those cases which I here classify as high fractures of the surgical neck, and which at a later period may easily be mistaken for unreduced dislocation.

Repair is largely carried on by the distal portion of the bone, and is marked by an exuberant production of callus and osteophytic growths on the surface and sometimes by ossification of the adjoining portion of the capsule.

Of the fate of the small upper fragment after fracture of the anatomical neck we have little positive knowledge. Boyer's statement that in his case the fragment had been diminished by absorption has been extensively quoted, but as the patient died only seven days after the injury was received the accuracy of the observation is doubtful. Kocher does not state the result in his cases, but in McBurney's in which the fragment was restored to its place by operation, and in mine in which a presumably similar fragment was restored to its place by manipulation, and in my other in which the fragment was not dislocated and the diagnosis is not certain, recovery with good function followed. Probably the head in most cases retains some vital connection through untorn portions of the capsule, and experience at other joints shows that similar fragments can reunite or can remain as unirritating loose bodies in the joint.

Treatment. Treatment is clearly limited to immobilization of the joint, possibly aided by some traction to oppose the tendency of the muscles to draw the shaft upward and thus displace the head.

C. Fractures of the Tuberosities.

Isolated fracture of either tuberosity is so rare an accident, except in connection with dislocation of the shoulder, that very few cases are on record, and none that have been verified by direct examination while

¹ Krönlein: *Deutsche Zeitschrift f. Chirurgie*, 1874, p. 1.

² Körte: *Langenbeck's Archives*, 1882, vol. xxvii. p. 749.

fresh. Partial fracture of the **greater tuberosity**, that is, the fracture of a larger or smaller portion comprising some or all of the facets to which the supraspinatus, infraspinatus, and teres minor muscles are attached, is a not infrequent accompaniment of anterior dislocation of the humerus,¹ and has also been seen by Malgaigne² in a case of dislocation backward under the acromion. (See Anterior Dislocations of the Shoulder.) Fracture of the lesser tuberosity is much more rare.

A number of cases have been reported of fracture of the greater tuberosity with symptoms so closely resembling those of dislocation that the diagnosis of the latter lesion was at first made in each case, and a study of the reports makes it seem probable that this diagnosis was correct, the dislocation having then been unwittingly reduced during the manipulations; most of the specimens found at autopsies probably belong in the same class.

Gurlt quotes a case of supposed fracture of the tuberosity by muscular action, in which the symptoms were extreme passive mobility at the shoulder, complete loss of voluntary outward rotation, and partial loss of voluntary elevation of the arm. If the arm was rotated vigorously and the ear laid upon the patient's shoulder, crepitus could be heard. Four weeks later the corresponding muscles were still powerless and atrophied. The patient was a muscular youth of twenty years, and the lesion was produced by an effort to throw a snow-ball with force; something was heard to crack and the arm fell powerless. The only mention of displacement in the case is that the patient's brother, a physician, thought the arm was dislocated and "made a sort of reduction."

In 1881 I saw at the Presbyterian Hospital a youth of nineteen years who had been injured the preceding day. He said that while holding the bridle of a horse in his right hand the animal reared, and as he came down his breast struck against the patient's left forearm which was held before his face in protection, and threw him to the ground. The left shoulder was somewhat swollen; there was an ecchymosis at the lower border of the tendon of the pectoralis major; voluntary abduction possible; voluntary external rotation impossible; firm pressure upward at the elbow painless. The lesser tuberosity moved with the shaft on rotation; crepitus observed high up in the shoulder when the head of the bone was grasped between the thumb and fingers and they were moved; pain on pressure upon the greater tuberosity. I inserted an insect-pin in front at the bicipital groove and passed it backward its full length, evidently between two bony surfaces, and by pressing its point against the inner one and rotating the arm the continuity of this surface with the shaft was shown. My diagnosis was fracture of the greater tuberosity by muscular action, by outward rotation of the arm in the effort to ward off the descending body of the horse.

I have seen a few cases of pain at the greater tuberosity on pressure and on voluntary outward rotation, but without crepitus or abnormal

¹ For a review of a number of cases, see Wohlgenuth, *Deutsche Gesellschaft für Chir.*, 1900, ii, p. 375.

² Malgaigne: *Atlas*, Plate xxii. Figs. 5 and 6.

mobility, which I have regarded as minor effects of similar muscular action, the partial rupture or detachment of the tendon or possibly the avulsion of a small piece of the bone; in one of them the *x*-ray showed fracture of the upper portion of the tuberosity.

Graessner¹ and Jacob,² with the aid of the *x*-rays, have found it frequently after falls upon the shoulder, and think it a frequent cause of the stiffness which follows such blows. Graessner saw 23 examples in three years; 20 were due to direct violence, 3 to a fall upon the outstretched hand.

The line of fracture usually runs along the sulcus marking the anatomical neck at the part where it adjoins the tuberosity and down the bicipital groove, sometimes liberating the long tendon of the biceps from its sheath and allowing it to slip in between the fractured surfaces. If the separation is complete the fragment is drawn upward and backward; if incomplete, that is, if the periosteum remains untor on the side of the fragment adjoining the shaft, new bone fills up the lower part of the gap, and the upper part of the fragment stands out from the surface from which it has been torn, as in Fig. 97. When union takes place it is almost always bony.

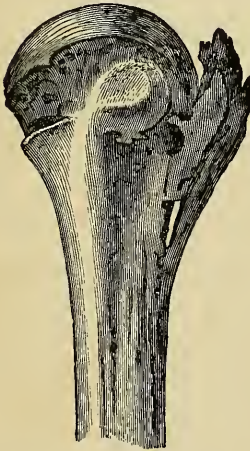


FIG. 97.

Fracture of the greater tuberosity of the humerus united.

I believe that in all cases in which the fracture is not an incident of a dislocation the cause is the direct action of the attached muscles. Some writers ascribe it almost without exception to direct external violence, but I know of no cases to support the opinion. The diagnosis must be made by localized pain on pressure and on attempted voluntary outward rotation of the arm, and by the abnormal mobility of the fragment, possibly with crepitus.

Treatment. The treatment is immobilization with as much outward rotation of the arm as is practicable in order to diminish the pull of the attached muscles. Any tendency to inward displacement, such as was noted by Smith, should be opposed by a pad in or below the axilla. Keen in 1907 (personal communication) exposed the fragment and sutured it as nearly in place as he could bring it; and Niehaus³ says he has done it several times. Wohlgemuth says Schuler in two cases relieved the limitation of abduction caused by contact of the fragment with the acromion by chiselling away a portion of the tuberosity.

Fractures of the **lesser tuberosity** are extremely rare. Gurlt collected only three cases, two of them accompanying dislocation of the shoulder, the third a specimen in the museum at Giessen. In each of the first two a small hard lump could be felt on the inner side of the head

¹ Graessner: Veröff. aus dem Gebiete Militär-Sanitats., Hft. 35, p. 180.

² Jacob: Gaz. des Hop., 1903, pp. 109, 123.

³ Niehaus: Arch. klin Chir., 1904, vol. 73, p. 71.

of the humerus, not moving with it. A very few other cases, certainly or probably associated with dislocation, have been reported, among them two by Bardenheuer.¹ The only case not so associated and which seems beyond question is that of Lorenz,² whose paper may be profitably consulted for an analysis of reported cases. His patient was a man forty-five years old, whose arm was forced into outward rotation, with an audible crack. He was treated for a contusion. When seen, three months later, by Lorenz active inward rotation was almost lost, outward rotation increased 40°, and a bony irregularity tender in pressure could be felt at the site of the lesser tuberosity. A slightly movable piece of bone could be indistinctly felt below the coracoid. The outlines of the shoulder were normal.

Jossel³ reports two cases accompanying backward dislocation of the shoulder (q. v.); in both the tuberosity remained attached to the subscapularis, and in one it was broken into two pieces. Engel⁴ reports one.

Treatment. The treatment would be immobilization in inward rotation, possibly aided by pressure on the outer aspect of the shoulder to oppose a tendency to outward displacement.

D. Separation of the Epiphysis.

The upper epiphysis of the humerus comprises the head and the tuberosities. The epiphyseal line runs upward and outward along the lower and inner half of the anatomical neck and then transversely under or through the tuberosities to the outer edge, its level rising as the individual grows older, and passing above part of the insertion of the teres minor. Its centre is higher than its edge, so that the shaft terminates in a low cone or wedge, with a corresponding hollow on the under surface of the epiphysis. This cone is very low in early life and its height increases as the individual grows older, until ossification of the conjugal cartilage takes place, usually by the twentieth year, but sometimes as late as the twenty-fifth.

This lesion has been observed at all ages between the moment of birth and the age of nineteen years. Jetter,⁵ in an account of sixteen cases operated upon by Bruns, mentions two cases aged twenty-three and twenty-four years, but no mention is made of the presence of the conjugal cartilage in either, and in one the line of fracture followed that of the epiphyseal junction for only half an inch. Both, I think, belong in the class of fractures after ossification of the cartilage, and are examples of the rather common high fractures of the surgical neck in which the line of fracture frequently follows the former epiphyseal lines quite closely. In 66 cases collected by J. Hutchinson, Jr.,⁶ 6 occurred at birth, 4 during the first year, and 17 at or above the age of fifteen years. In a considerable number of the recorded cases it was

¹ Bardenheuer: *Deutsche Chirurgie*, Lief 63 a. p. 168.

² Lorenz: *Deutsche Zeitschrift für Chir.*, 1900-01, vol. lviii. p. 593.

³ Jossel: *Deutsche Zeitschrift für Chir.*, 1874, vol. iv. p. 125.

⁴ Engel: *Arch. für klin. Chir.*, 1897, vol. 55. p. 603.

⁵ Jetter: *Beiträge zur klin. Chir.*, 1892, vol. ix. p. 361.

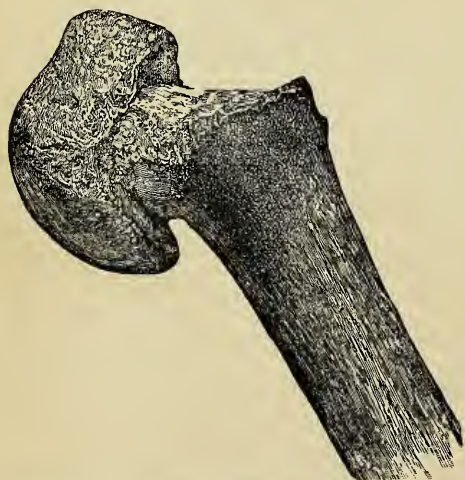
⁶ J. Hutchinson, Jr., *British Medical Journal*, July 8, 1893.

produced by the efforts of the midwife or physician to hasten delivery by drawing upon the presenting arm, or with the finger hooked into the axilla, or to bring down the arm from the side of the head when the legs and body were already delivered. In others it has been caused by falls, by forcibly drawing the arm upward and outward, and by a fall upon the elbow when it was held behind the axillary line. See also a paper by Linser.³

Considering how easily the epiphyses can be separated by the cross-strain produced in forcibly carrying the limb beyond the normal limit of motion in the corresponding joint established by the capsule, ligaments, and muscles attached to it, it seems probable that this is the mechanism in most cases, and in this may probably be included forced rotation of the arm.

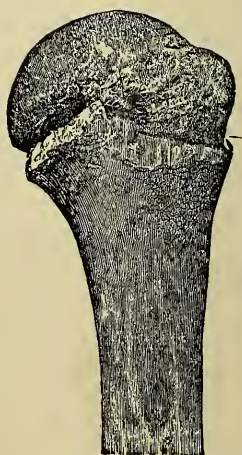
The opportunities for direct examination of the seat of injury have been largely increased of late by operations undertaken for the correction of the displacement, often while recent. They show that the line of fracture almost always follows the epiphyseal line closely and that the periosteum remains untornt to a considerable extent, especially posteriorly, and that where torn its separation often takes place at some

FIG. 98.



Separation of the upper epiphysis of the humerus; displacement forward of the lower fragment. (MOORE.)

FIG. 99.



Upper epiphysis of the humerus at 10 years; separated by maceration. Outer side. (MOORE.)

distance below the line of fracture, the portion between the rent and the line of fracture being stripped from the shaft and remaining attached to the epiphysis as an irregular sleeve. The younger the patient the more marked apparently is this sleeve formation.

The displacement is habitually of the shaft forward, and sometimes to the outer or to the inner side, the posterior portion of the end of the shaft usually lodging in the saucer-shaped lower surface of the epiphysis, the latter being flexed and abducted (Fig. 98). Excep-

¹ Linser: Beiträge zur klin. Chir., 1900-01, v. l. xxix. p. 350.

FIG. 100.

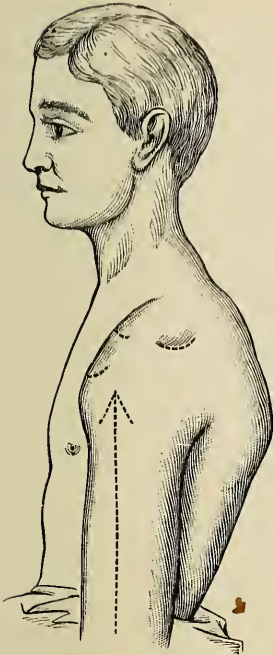
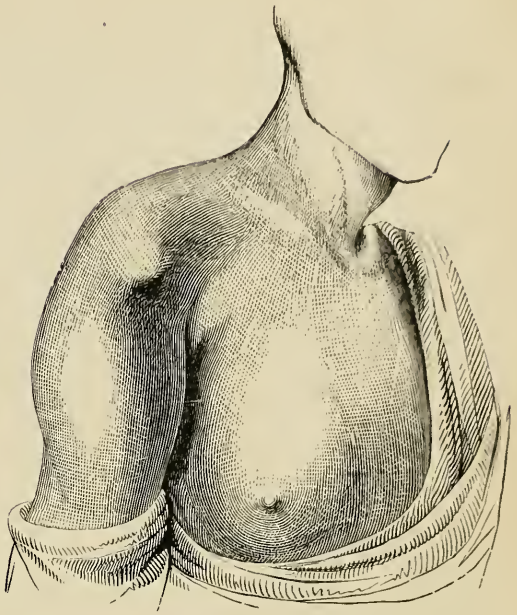
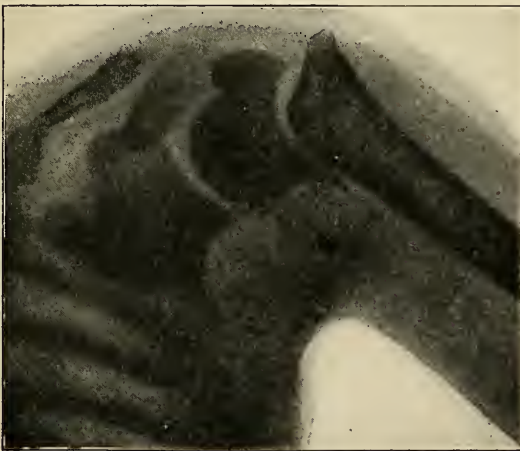

FIG. 101.



Separation of upper epiphysis of humerus.

FIG. 102.



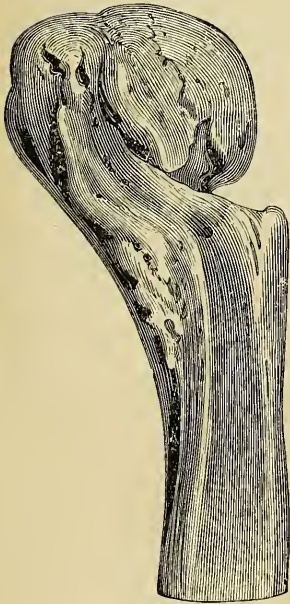Separation of the epiphysis, with an oblique fragment from shaft. Outward displacement of shaft. (V. BRUNS.)

tionally the displacement inward of the upper end of the shaft may be such as completely to separate the fractured surfaces and lodge the

end of the shaft beneath the coracoid process. There is reason to think that in some cases there is no displacement. The upper fragment may be rotated outward.

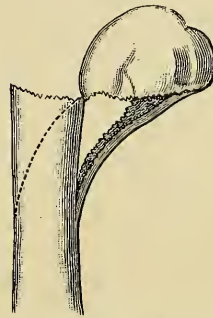
Symptoms. The symptoms are so characteristic that it is difficult to understand why the mistake of supposing the injury to be a dislocation should have been made so frequently. The anterior edge of the upper end of the shaft can be distinctly felt at the front of the shoulder an inch or more below the acromion, and often so raises the skin that its presence can be seen as well as felt. The arm usually hangs straight with the elbow directed a little backward, or it may be abducted, but the suggestion of a dislocation which the latter attitude gives is at once removed by palpation of the shoulder which shows the head of the humerus to be in its place, and if the head is grasped between the thumb and fingers and the arm gently rotated the independent mobility of the two will be recognized, perhaps with crepitus. The anterior displacement of the upper end of the shaft is well shown in Fig. 99.

FIG. 103.



Union after separation of the upper epiphysis of the humerus with displacement. (R. W. SMITH.)

FIG. 104.



Separation of upper epiphysis of humerus. Excision of projecting end of shaft. (KOCHER.)

In cases without displacement the diagnosis could be made only by the localized pain on pressure, on pressing the elbow upward, and on attempting to use the limb.

If displacement is absent or has been corrected repair takes place habitually without incident, although occasionally the trauma has led to premature ossification of the conjugal cartilage and consequent arrest of growth, a matter of special importance here because the greater part of the growth of the humerus in length takes place at its upper end.

When the displacement persists various results are possible: union may take place (Fig. 103), and the subsequent range of motion be restricted by the deformity; as the epiphysis is already flexed and

abducted motion of the arm in those directions is restricted, and motion in other directions may be interfered with either by the faulty position in some respects (*e. g.*, inward rotation) of the lower fragment or by the contact of projecting portions with adjoining apophyses. Or suppuration may follow; in the reported cases it is not entirely clear that the suppuration was not provoked by injudicious attempts to reduce a supposed dislocation, or that it may not have been a spontaneous osteomyelitis preceding the separation of the epiphysis, the latter being the result, not the cause, of the suppuration. Or, very rarely, reunion may fail.

In respect of treatment the first effort must be to correct the displacement; this can sometimes be effected by traction upon the arm aided by direct pressure upon the projecting fragment, but in other cases it is advisable to use the plan suggested by Dr. E. M. Moore, that of forcibly raising the elbow beside the head so as to bring the shaft into a position corresponding with that taken by the epiphysis; as the latter is prevented by the posterior portion of the capsule from moving further in this direction, the forced movement of the arm throws the upper end of the shaft backward into place. Interposition of the torn and loosened periosteal sleeve may create so serious an obstacle that reduction cannot be effected without the aid of an incision exposing the seat of fracture. In the older cases ossification of the untorn periosteum rapidly produces a bony bridge between the fragments which prevents reduction. In two such cases Koehler cut away the projecting portion of the shaft (Fig. 104) and increased the range thereby; others have resected the callus and a portion of the diaphysis and then made reduction.

After reduction immobilization of the limb for three or four weeks is necessary. It is only in cases in which reduction is incomplete that measures are required to oppose a tendency to recurrence of the displacement.

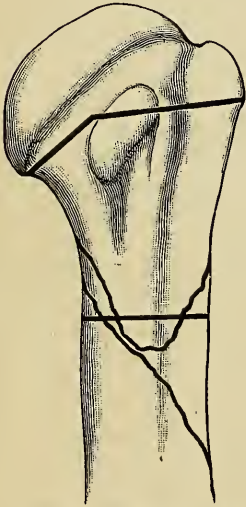
E. Fracture of the Surgical Neck.

Under this rubric are here included fractures of the portion of the bone lying between the site of the epiphyseal cartilage and the insertion of the pectoralis and teres major, the great majority of all fractures of the upper end of the bone. The line of fracture in separation of the epiphysis in the young marks the upper limit of this group in adults; its lower limit is an arbitrary and ill-defined one and, moreover, is not infrequently crossed by fractures which lie partly above and partly below it. The higher fractures of the group are separately described by some as fracture through the tuberosities, *fractura pertubercularis*, but the distinction does not seem worth preserving.

The common cause is external violence, a fall or a blow upon the arm, but occasionally is muscular action. The mode of action is rarely clear in the history of a given case, but experiment has thrown light upon it. The higher fractures may be caused by a blow or fall upon the upper part of the arm or upon the elbow, presumably aided by the resistance of the glenoid fossa or the acromion, the so-called "compression" fractures, but much more frequently, I think, by a cross-

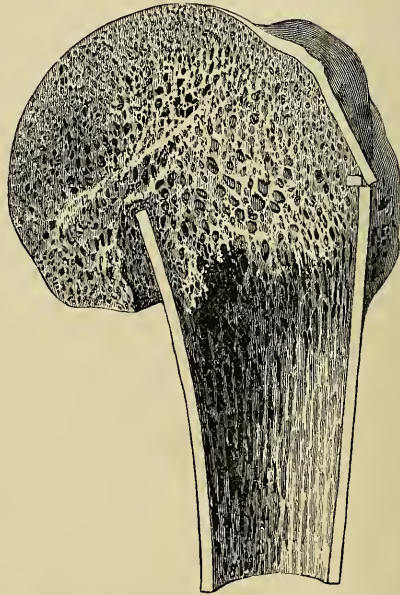strain in which the upper end is fixed by the resistance of the capsule and ligaments and possibly the muscles, and either the elbow is forced outward or forward or is fixed in abduction while the blow is received on the outer part of the shoulder, "abduction fractures;" "adduction fractures," by violence acting in the opposite direction, are much rarer. The lower fractures may be caused by violence acting on the side of the shaft at or below the point of fracture, or by cross-strain in a fall on the elbow or hand, or by torsion of the limb.

FIG. 105.



Upper and lower limits of fracture of the surgical neck of the humerus, with spiral fracture of shaft extending into the area.

FIG. 106.

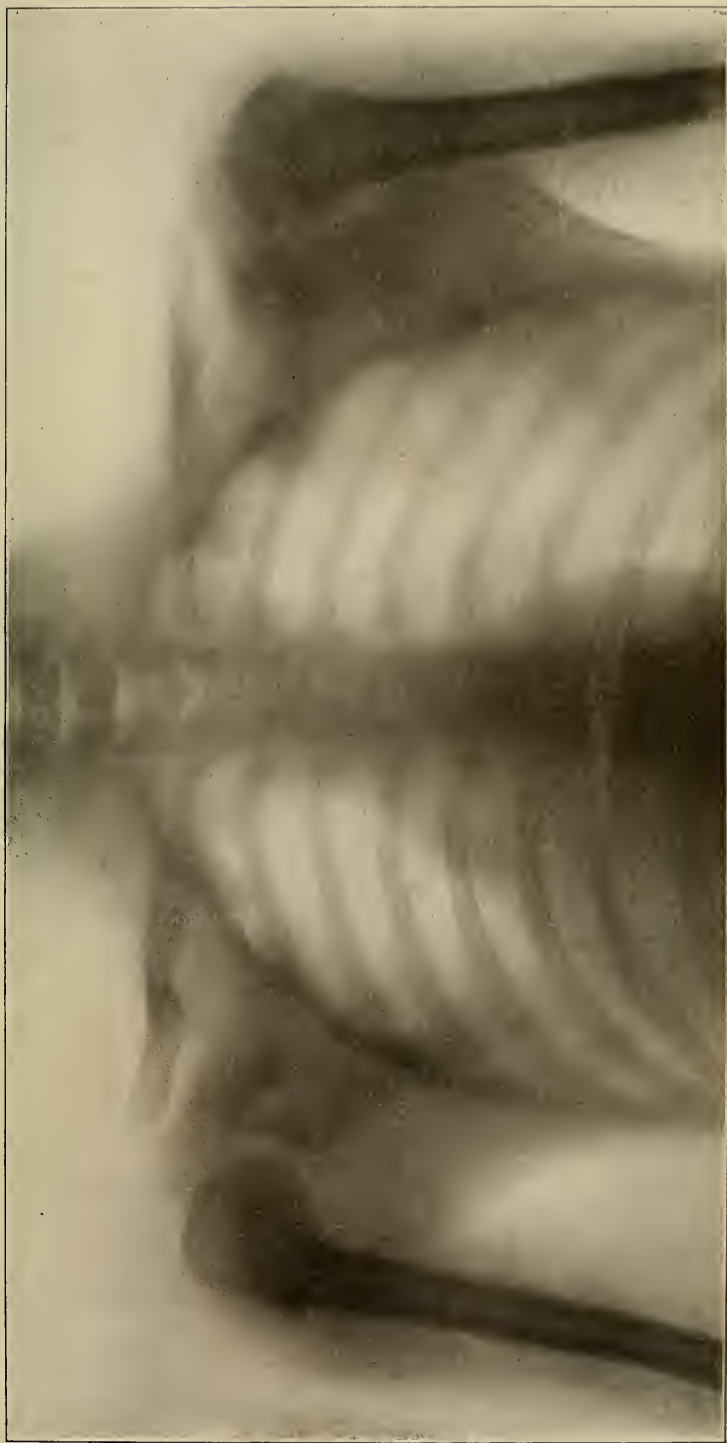

Impacted fracture of the surgical neck of the humerus. (R. W. SMITH.)

In the higher and some of the lower fractures the line is essentially transverse, usually with splintering or even comminution, sometimes with fissures extending through the head and sometimes with notable impaction. Many of the lower fractures are oblique, often markedly so.

The upper fragment, since opposition to the action of the muscles attached to it is diminished or annulled by the fracture, often takes the attitude of flexion, abduction, and outward rotation, being sometimes aided therein by the impaction into it of the lower fragment (Plate V.); the latter is usually displaced inward, partly by the momentary continuation of the fracturing force in some cases and partly by the action of the pectoralis and teres major. Exceptionally the displacement is equal to the thickness of the shaft, and may be outward or posterior, as shown in some of the figures; but in the great majority of cases the displacement is too slight to be clinically recognizable.

PLATE V.



Fracture of Surgical Neck of Humerus, in a Child.

An important form of impaction is that in which the shaft passes to the front and outer side of the head and the latter is thereby brought to a lower point on its inner side (Fig. 106). It is claimed by Hutchinson that the rising of the shaft under the pull of the deltoid may press the head so far inward and downward that the final position may resemble that of a dislocation below the coracoid.

FIG. 107.

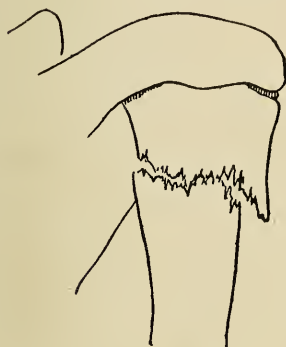

FIG. 108.

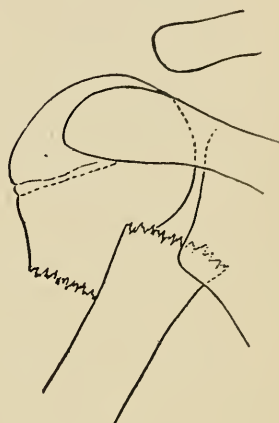


FIG. 109.

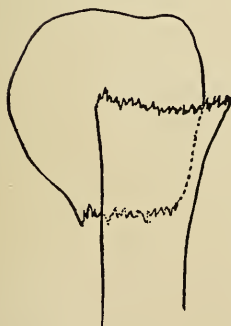
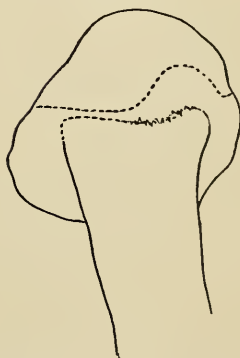


FIG. 110.



FIGS. 107-110. Forms of fracture at the upper end of the humerus. x-ray tracings.

The tendon of the long head of the biceps may be torn in these extreme displacements. Injury of the axillary vessels and nerves is extremely rare; thrombosis of the artery in consequence of bruising has been seen, the axillary vein has been torn in a compound fracture, and the musculo-spiral nerve has been so compressed as to cause paralysis of motion and sensation in its area of distribution.

In an oblique fracture the sharp end of the lower fragment may approach or become engaged in or even perforate the skin, usually on the inner side, and even in the higher fractures this has been observed in front close below the acromion.

FIG. 111.

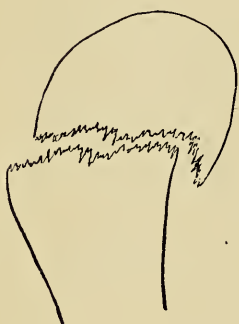


FIG. 112.

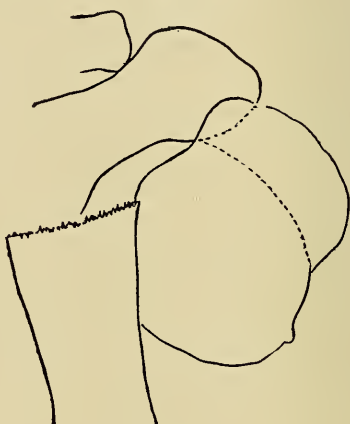


FIG. 113.

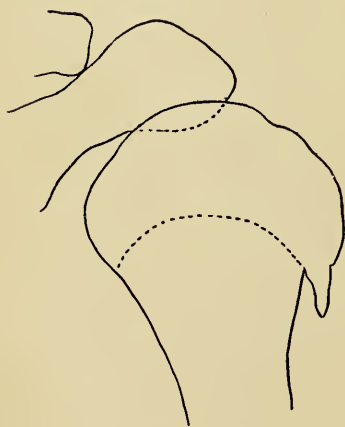
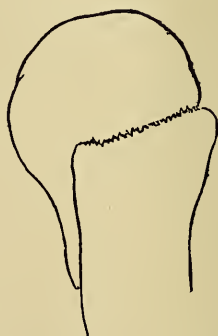


FIG. 114.



FIGS. 111-114. Forms of fracture at the upper end of the humerus. x-ray tracings.

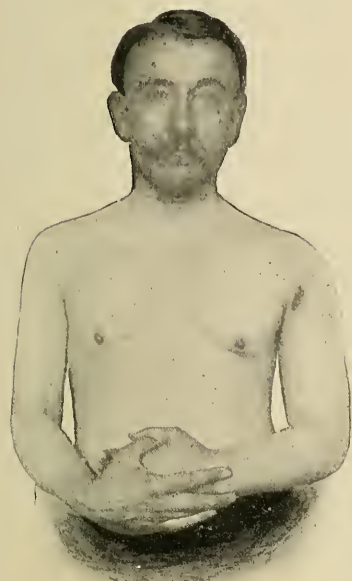For the combination of fracture with dislocation see Dislocation of the Shoulder, Chapter XLIV.

Symptoms. The symptoms vary with the form of fracture and the displacement; usually the arm hangs by the side or the elbow is slightly

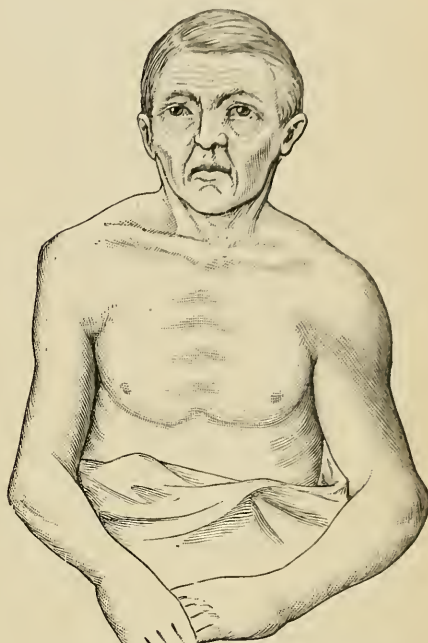abducted, but if the displacement inward of the upper end of the shaft is marked the abduction of the arm resembles that of an anterior dislocation (Fig. 116); the distinction is easily made by recognition of the presence of the head in the glenoid fossa, maintaining the fulness

FIG. 115.

FIG. 116.



Fracture of the surgical neck of the humerus. The dark spot is an ecchymosis.



Fracture of the surgical neck; displacement inward of the lower fragment, resembling dislocation.

of the shoulder. Loss of function is usually complete, swelling marked, and ecchymoses very extensive, especially in the old, often spreading to the elbow and across the front of the chest.

If the elbow is pressed upward pain is felt at the fracture, and distinctly localized pain can often be caused by pressure with the finger along the line of fracture.

Then if the upper fragment is grasped between the thumb and fingers in such a way that the notch between the tuberosities at the bicipital groove can be felt, and the elbow is gently rotated, the failure of the former to share in the movement will be recognized and usually crepitus will be perceived. In the cases with more marked displacement the relations of the fragments can be determined by palpation if the patient is not too fat or the region too swollen, or by noting the direction of the axis of the shaft.

Diagnosis. In the great majority of cases the diagnosis is made upon the localized pain, especially on pressing the elbow upward, and on the

failure of the tuberosities to share in slight rotatory movements communicated to the elbow, for the displacement is usually too slight to be recognized through the swollen tissues. When marked displacement exists the position of the upper end of the lower fragment is indicated by the direction of the axis of the shaft, generally upward and inward, and is demonstrated by abnormal resistance to pressure and pain at the indicated point, usually corresponding to the groove between the pectoralis and deltoid near the coracoid. Dislocation of the shoulder is excluded by recognition of the head in its place. The lower end of the upper fragment can be traced only in those oblique fractures where the line of fracture descends upon the shaft.

Prognosis. When no important displacement persists and no complications are present, the course is uneventful and the result good; union takes place in from thirty to forty days, and the restoration of function is complete after a few more weeks. Exceptionally, function may be diminished by an associated arthritis, especially in the old, or by excessive formation of callus in the higher forms. Failure of union has been noted in only a very few cases with uncorrected displacement; and once or twice the displaced end of the shaft has become firmly adherent to the coracoid process.

Treatment. Reduction of the displacement is made by traction upon the arm aided by appropriate pressure on the end of the lower fragment. In most cases, because of the usual abduction of the upper fragment, it is necessary to make traction with the arm widely abducted so as to bring the shaft into line with the attitude of the upper fragment, and after the displacement has thus been reduced the arm is lowered to the side and there maintained by suitable dressings unless this position too greatly favors recurrence of the displacement, in which case the abducted position must be maintained for a week or two. Exceptionally, another attitude may be made necessary by another form of displacement.

The chief disturbing influence which the retentive dressing has to oppose is the action of the muscles, which tends to draw the lower fragment upward and inward and to flex, abduct, and sometimes outwardly rotate the upper fragment, and the great difficulties in the preparation of an always effective dressing are to find a fixed support for its upper end which will furnish the counter-extension for traction upon the lower segment and to oppose the tendency to displacement inward without making undue pressure upon the vessels and nerves of the axilla and inner aspect of the arm. The upper fragment is too small to be acted upon directly by any splint, and its position and movements can be controlled only through its interlocking with the lower fragment; in default of such control the lower fragment must be brought into line with the upper in the position given to the latter by its attached muscles. Counter-extension against the folds of the axilla is ineffective both because they are yielding and because they rest upon muscles, the pectoralis and latissimus dorsi, which are attached to the humerus below the seat of fracture, so that the force is applied to the two ends of the lower segment and is, therefore, ineffectual to control its rela-

tions to the upper one. The desired fixation can be got by a heavy plaster-of-Paris dressing enveloping the chest and shoulder, but this is too irksome to be used except in cases of extreme need. I have used it with advantage in some compound fractures. Fortunately the tendency to displacement can usually be controlled by simple measures which are sufficiently effective in practice even if not in theory, but when it is great continuous traction must be used, either by weight and pulley with the patient in bed, or by a weight attached to the dependent arm when the patient is seated or standing.

Lateral displacement inward of the upper end of the shaft can be effectively opposed when the patient is in bed by moderate traction outward applied by a band about the upper part of the arm. No fixed dressing or splint can alone do it, when the tendency is marked, because of the presence of the main vessels and nerves on the inner side of the arm where they might be dangerously compressed between the bone and the upper part of the splint. Fixed dressings consist essentially of a stiff piece on the outer side of the limb, resting against the shoulder and elbow, to which the arm is made fast by a bandage; this measurably controls inward displacement but not shortening. If the latter threatens it must be opposed by traction, although that supplied by the weight of the limb is usually sufficient. Occasionally the fixed dressing is a simple support between the arm and the body, by which the limb is immobilized in abduction; and not infrequently it is sufficient simply to bind the arm to the side of the body.

Continuous traction by weight and pulley is made through a cord attached to the arm above the elbow by two strips of adhesive plaster bound to it by a roller bandage as in the similar treatment of fractures of the thigh (page 96). The hand and forearm should be bandaged to prevent swelling. The patient should be in bed, the arm somewhat abducted and resting on pillows or a sliding support; weight about five pounds. It is rarely necessary to maintain it for more than two weeks.

Traction with the patient out of bed can be made by a weight similarly attached to the arm or hanging from a plaster-of-Paris dressing as described below; the elbow is flexed at a right angle, and the forearm supported *at the wrist* by a sling.

The common shoulder-cap of leather or cardboard, capping the shoulder and covering the outer aspect of the arm, or even extending to the elbow, is wholly inefficient against inward displacement or overriding and serves only to give support and to protect against chance violence. It must be combined with an internal lateral splint to give it more control over the lower fragment and with traction to prevent over-riding.

A similar dressing of plaster of Paris enveloping the arm and forearm and overlapping the shoulder has the same defects, although they are diminished by the better control of the limb and by the weight of the dressings which makes efficient traction when the patient is erect. It can safely be used when the tendency to displacement is slight, especially after the second week. It can be readily made as shown in Fig. 122 or with the usual plaster roller-bandage, applied

lightly over the forearm and more thickly on the arm as high as the axilla, and combined with a cap over the shoulder made by carrying the bandage up and down over it from the outer side of the arm. Overriding taking place under it can be detected by noticing that the cap rises above the shoulder, admitting the finger, or even two, beneath it; this must be met by attaching a weight to the elbow, and in all cases the forearm should be supported across the chest, *only at the wrist*, in order that the weight of the arm may constantly draw the lower fragment down when the patient is erect. A triangular cushion extending from the axilla to the elbow between the arm and the chest secures slight abduction if needed and may add to the comfort (Fig. 124).

FIG. 117.

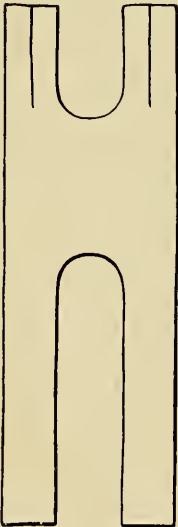


FIG. 118.



Hennequin's plaster splint for fracture of the humerus.

A convenient method of making a similar plaster dressing is that devised by Hennequin:¹ a dozen thicknesses of erinoline, or three or four of muslin or canton-flannel, cut as shown in Fig. 117, the width being equal to the circumference of the arm, and the length of the central portion equal to the distance from the fold of the axilla to the elbow, are soaked in plaster cream and applied as shown in Fig. 118, the limb having previously been bandaged from the wrist to the elbow to prevent swelling. If overriding is present or anticipated traction must be made while the plaster is hardening, either by the hands or by a weight made fast at the elbow by a bandage under the splint. Hennequin makes temporary counter-extension by a bandage under the axilla, but I doubt its value or safety; it seems liable to lead to making

¹ Hennequin: *Revue de Chirurgie*, 1887.

the splint too high on the inner side and thus chafing the axillary folds.

For cases in which the attitude and fixation of the upper fragment are such that the limb must be kept abducted so as to be in line with it, and in which confinement to bed must be avoided, a support braced against the body may be used. Middeldorpf's triangle (Fig. 119) is a type of such dressing; the objection to it is in the internal rotation which it gives to the arm and which may not coincide with the position of the upper fragment. A lighter pattern is made of a bent rod or piece of stout leather strapped to the arm and trunk.

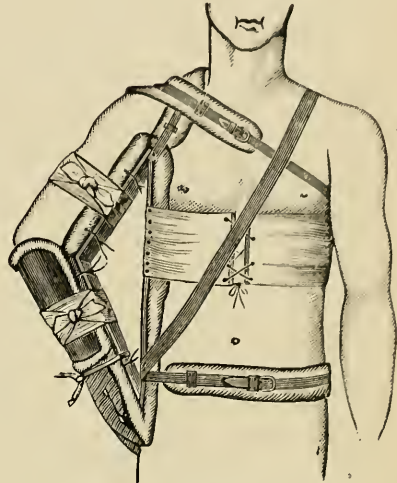
The choice of these different methods in varying cases may be summarized as follows: In the high fractures with little displacement or tendency thereto moderate immobilization, support, and protection are sufficient, and these may often be got by binding the arm to the side, especially if the patient is fat.

If the patient is robust, and especially if the fracture is oblique, so that shortening by the traction of the muscles is probable, a plaster-of-Paris dressing with traction by a weight at the elbow is required. If the upper fragment is abducted and its position cannot be controlled by interlocking of the broken surfaces, the abducted position of the arm is necessary, and the patient should be treated in bed with traction in that position for a fortnight, when the upper fragment will generally be found to accompany the lower one when it is adducted, or out of bed with a dressing like the Middeldorpf triangle. Cases with marked tendency to displacement inward of the upper end of the lower fragment should be treated in bed with traction in abduction aided by moderate outward traction upon the upper part of the lower fragment.

Compound fractures which suppurate need a strong fixed support which can be maintained during the changes of dressing, such as a plaster-of-Paris jacket with iron braces extending across to a plaster case enveloping the lower two-thirds of the arm or with a strong broad plaster bridge uniting the two over the top and outer aspect of the shoulder. In compound fractures with splintering of the upper fragment and implication of the joint, usually gunshot, excision of the head favors repair and the subsequent usefulness of the limb.

In all cases the patient should be directed to move his wrist and fingers freely; and fixed dressings should be removed as early as pos-

FIG. 119.



Middeldorpf's triangle for fracture of the humerus.

sible, and the limb supported only in a sling and protected by a removable shoulder-cap extending to the elbow, in order that massage may be used to hasten the restoration of function.

For the treatment of fracture combined with dislocation see Dislocation of the Shoulder.

Fig. 120.



Longitudinal fracture of the humerus. (GURLT.)

2. FRACTURES OF THE SHAFT OF THE HUMERUS.

The region is that included between the insertion of the pectoralis major and the upper portion of the supracondyloid ridges.

All the varieties of fracture which may occur in long bones are contained among those of the shaft of the humerus. A remarkable and unique example of longitudinal fracture extending the entire length of the bone is quoted in Chapter II. (p. 27), and Gurlt gives two of exceptionally long fissures, beginning in the one case at the condyles and ending at the insertion of the deltoid, and extending in the other from the upper border of the greater tuberosity to the lower fourth of the shaft. Incomplete or partial fractures are extremely rare.

All the forms of displacement common to fractures of the long bones are also found here, and no one deserves mention as of exceptional frequency and importance. The character of the primary displacement depends largely upon the fracturing force; that of later displacement upon the unsupported weight of the limb and upon muscular action.

Double fractures of the same bone are very rare. Simultaneous fracture of both humeri has been caused by epileptic convulsions and by external violence.

Among the injuries which may be associated with the fracture are dislocation of the shoulder, laceration of the soft parts, and contusion or rupture of bloodvessels or nerves. The latter deserve special attention because of the gangrene of the limb or the paralysis which may result and may be attributed to negligence in the treatment. The brachial artery or vein may be so crushed or bruised by direct violence that a thrombus forms within it and arrests the circulation; or, more rarely, it may be torn by the sharp edge of a displaced fragment, or the vessel may be stretched across the fragment in such a way as to be occluded by pressure. Occasionally the injury to the artery has resulted in the formation of an aneurism. The musculo-spiral nerve is particularly exposed to injury because of its close relations to the bone throughout so large a part of its course. (See p. 74.)

Causes. The causes of fracture are external violence and muscular action; the latter causes fracture in the humerus more frequently than in any other bone, and the causative effort has not always been very

great. The two most common efforts which have caused it are throwing a stone and that trial of strength in which two men clasp hands with elbows resting on a table and strive each to force the other's hand aside; the latter produces a spiral fracture. *Also snapping & whist.*

Compound fractures have no anatomical peculiarities that require mention. Gurlt collected five cases of almost complete severance of the arm by a blow with an axe or sabre, all of which recovered with preservation of the limb; in all the wound was on the outer and anterior aspect of the limb.

Symptoms. The symptoms are the usual ones: abnormal mobility, crepitus, loss of function, pain, and more or less deformity. Important complications, such as dislocation of the shoulder or injury of the artery or a nerve, have their special symptoms; the principal danger is that they may be overlooked because the attention is concentrated on the fracture. Injury to the artery is indicated by absence or weakness of the radial pulse, either immediately or after the lapse of a few hours; sometimes the symptoms have appeared gradually, the pulse becoming weak, and finally disappearing, the hand numb and cold, the surface bluish, and after death or amputation a clot, sometimes firm, pale, and adherent, sometimes dark and soft, has been found in the artery. Injury of a nerve, usually the musculo-spiral, is shown by paralysis and loss of sensation or hyperæsthesia in the region supplied by it; paralysis or loss of sensation indicates division or destruction of the nerve; hyperæsthesia indicates irritation, usually by pressure. Paralysis of motion is often overlooked at first.

A simple fracture in an adult, running its course without complications, will be solidly united in from four to six weeks, and in three or four weeks in children. The possible complications are inflammation and delayed union; the former is sometimes quite marked, and the latter is of more frequent occurrence in the humerus than in any other bone. The general and local causes which lead to delay in or failure of union have been discussed in Chapter VIII. It has been thought that the special cause in the case of the humerus is defective immobilization of the fragments, for when the elbow is kept at a right angle any vertical movement of the hand or forearm is likely to cause horizontal movement of the lower fragment on the upper one, and lateral splints cannot be fitted accurately or snugly enough to prevent it. It has been proposed, therefore, to treat the fracture with the elbow in full extension, but this position is very irksome and equal immobilization can be obtained by the use of a posterior splint the upper end of which overlaps and is secured to the shoulder. The supposed interposition of muscle which has been so frequently alleged as the cause has existed in none of the cases upon which I have operated because of failure of union.

Treatment. Reduction is made by traction upon the condyles or the flexed forearm. The treatment in fractures of the upper third is essentially the same as in fractures of the surgical neck; rest in bed, with continuous traction and the limb supported upon cushions, may be required at first. For the lower fractures abduction of the limb is not so often needed. The plaster-of-Paris bandage is in common use, is

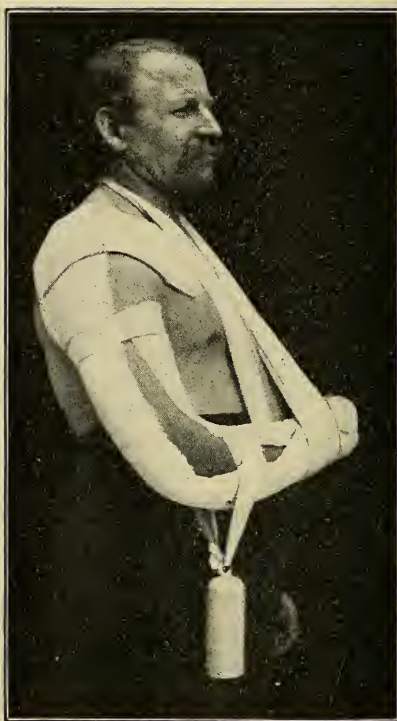more secure than lateral splints, and gives good results, but it needs careful watching at first, both to detect displacement and to prevent

FIG. 121.



Fracture of lower portion of shaft; angular displacement; cubitus varus.

FIG. 122.



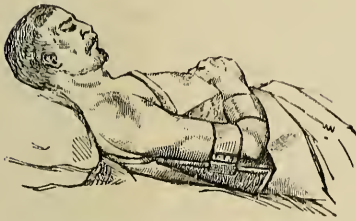
Plaster-of-Paris splints for fracture of the shaft of the humerus.

strangulation of the limb. It should be carried from the wrist to the shoulder, and may include a few spica turns over the shoulder and about the chest to aid immobilization and oppose overriding. The forearm should be flexed and supported by a sling at the wrist. Snug support under the elbow in low fractures can produce an angular deviation inward of the lower fragment (Fig. 121), which greatly disfigures the limb, especially when the forearm is extended; this deformity is considered in detail in the subsequent section on Supra-condyloid Fractures. A posterior moulded plaster or wire splint, extending under the forearm and over the back of the shoulder (Fig. 122), is convenient and efficient. A weight attached to the elbow is sometimes useful to prevent shortening or to overcome that which is already present; it will lengthen a limb even after the lapse of two or three weeks.

I have found it advantageous in cases of fracture by direct violence, especially in women and the alcoholic, to keep the patient in bed for about a week, or until the danger of acute inflammatory complications

had passed. Stromeyer's cushion, designed particularly for the treatment of compound fractures, is useful as a support. It has the form

FIG. 123.



Stromeyer's cushion applied.

of a triangular pyramid (Fig. 123), the long lines of which are twelve or fifteen inches long. It should be firm enough to keep its shape under pressure, and its upper end should be blunter than shown in the figure. It is secured in place by tying the upper pair of straps about the opposite shoulder and the lower pair about the waist. A similar but smaller cushion (Fig. 124) is sometimes used in connection with an ambulatory dressing like the preceding.

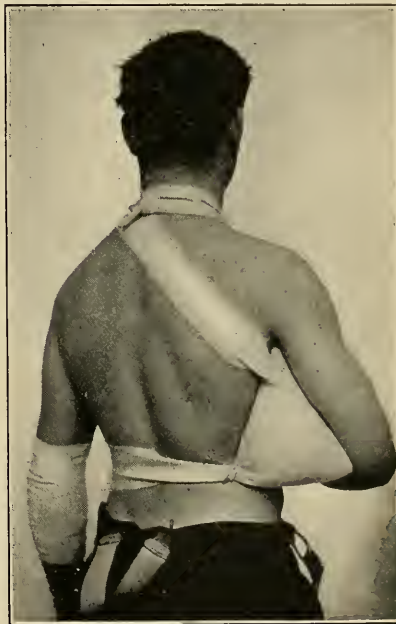In the treatment of compound fractures the general principles laid down in Chapter VII. are to be followed. I habitually treat them in

bed for the first fortnight with the limb on a pillow, trusting to the position and the support of a bulky dressing of the wound for the desired immobilization. If prompt union of the wound is not obtained moulded splints can be applied outside the dressing. Resection of the ends of the fragments or their direct suturing is rarely indicated.

When there is reason to fear serious injury to bloodvessels or nerves fixed dressings and bandages should be avoided until after the extent of the injury shall have become apparent. Reduction should be made as completely as possible and the limb supported upon cushions.

If there is reason to believe that the musculo-spiral nerve has been ruptured, it should be sought in the groove between the supinator and brachialis anticus and traced to the point of injury, and sutured. Or the operation may be delayed two or three weeks in order that repair may be well advanced and the dangers of infection thereby lessened. If the paralysis appears only after the lapse of a few weeks it is probably due to inclusion of this nerve in callus or cicatricial tissue, which must then be relieved by open operation. (See Chapter VI., p. 75.)

FIG. 124.



Small Stromeyer cushion for ambulatory treatment.

3. FRACTURES OF THE LOWER END OF THE HUMERUS.

This group, like that of fractures at the upper end of the humerus, includes a number of varieties differing materially in character and importance, and having in common only their position near the elbow, and the frequent necessity and difficulty of making a differential diagnosis between each and the others and dislocation. A certain lack of agreement among writers, as to the sense in which some of the distinguishing terms are used, makes it desirable to define those that are to be here employed at the same time that the limits of the divisions of the main group are traced. These divisions are :

A. Fractures Above the Condyles ; Supracondyloid. The line of fracture crosses the expanded part of the bone above the articular surface transversely or obliquely, and may or may not open the articulation.

B. Fractures of the Internal Epicondyle or Epitrochlea. The line of fracture is entirely extra-articular, and the piece broken off consists of the whole or part of the epicondyle. And by the internal epicondyle or epitrochlea is meant the whole of the projecting tuberosity that lies above and on the inner side of the trochlea, and part of which is developed about a separate centre of ossification.

C. Fractures of the External Epicondyle. The line of fracture is probably extra-articular ; the fragment is very small, consisting of the epicondyle proper, either alone or with some of the adjoining bone.

D. Fractures of the Internal Condyle. In these the line of fracture passes from a point on the inner border of the bone above the tip of the epicondyle obliquely downward and outward to the articular surface.

E. Fractures of the External Condyle. Similar to the preceding variety, except that the line of fracture begins upon the outer side and passes downward and inward.

F. Intercondyloid or T-shaped Fractures. These are a combination of the first, fourth, and fifth, the extremity being separated from the shaft and split into two or more pieces.

G. Separation of the Epiphysis. The fracture follows the line of the conjugal cartilage.

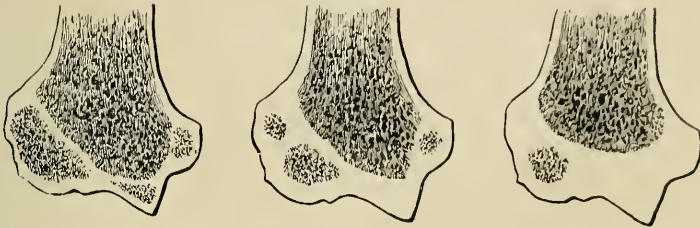
H. Fracture of the Articular Process. In this more or less of the portion of bone covered by articular cartilage is broken off ; the most common form is fracture of the capitellum.

These fractures are much more common than those of either the upper end or shaft. The relative frequency of the varieties mentioned in the preceding list has not been satisfactorily determined ; published statistics differ quite widely, and the differential diagnosis is often so difficult (partly because of the extreme youth of many of the patients) that doubt must sometimes remain whether a case has been properly assigned to its class. In the Out-patient Department of the House of Relief in about six years, ending in 1904, 97 of these fractures, excluding the epicondyle, were received, as follows : External condyle 45, supracondyloid 26, intercondyloid 9, internal condyle 15, separation of epiphysis 1, edge of trochlea 1.¹

¹ Examination of the record suggests that some of those classed as fractures of the internal condyle were supracondyloid. Sixty-two of the patients were under eleven years of age, and 18 others were less than twenty years old ; 15 were more than twenty years old. For other statistics, see Stolle, *Deutsche Zeitschrift für Chirurg.*, vol. lxxiv. p. 65.

The great relative frequency of these fractures in children makes necessary a brief account of the somewhat complex development of this end of the bone. According to Henle, the epiphysis at birth is wholly cartilaginous below a transverse line passing through the lower part of the olecranon fossa; in a month or two this line descends centrally to the lower edge of the fossa, becoming convex, and during the first

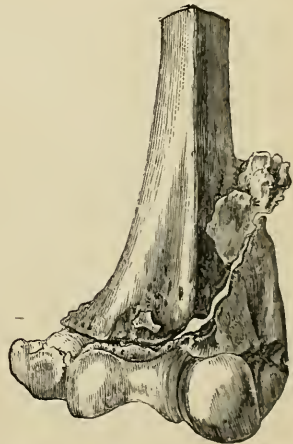FIG. 125.



Twelfth to fifteenth year. Eighth to twelfth year. First to second year.
Ossification of the lower epiphysis of the humerus.

or second year a centre of ossification appears in the capitellum. Between the eighth and twelfth years this nodule enlarges, nearly or quite reaching the trochlear groove, a nodule appears in each epicondyle, and the diaphysis sends a prolongation down into the inner portion of the trochlea. Between the twelfth and fifteenth years the nodule of the capitellum unites with that of its epicondyle, and after that the final point of ossification, that of the trochlea, appears; it is a thin concave cap or shell, closely applied to the downward projection of the corresponding portion of the diaphysis, and unites with the nodule of the capitellum about the fifteenth year; soon afterward the nodule formed by the union of the trochlea, capitellum, and external epicondyle unites with the diaphysis, and subsequently the nodule of the internal epicondyle unites. Kocher's statement, following Farabeuf, that the trochlear nodule is the first to unite with the diaphysis seems to be an error due to misinterpretation of the peculiar descent of the diaphysis into the trochlea, probably through ignorance of the late appearance of the trochlear nodule. It thus appears that the epiphysis after about the fifth year is an irregular strip of cartilage containing one, or two, bony nodules in its thicker outer portion, and none in its thin saucer-like trochlear portion, which latter is continuous by a sort of neck with the cartilaginous and bony internal epicondyle. My own specimens and skiagrams indicate that the end of the diaphysis after the sixth year is much more directly transverse, descends lower on the outer side, than is shown in Fig. 125. Possibly the difference in ap-

FIG. 126.



Supracondyloid fracture of the humerus.

pearance depends upon the direction of the line of section, Henle carrying it further forward on the outer side so as to include more of the projecting capitellum.

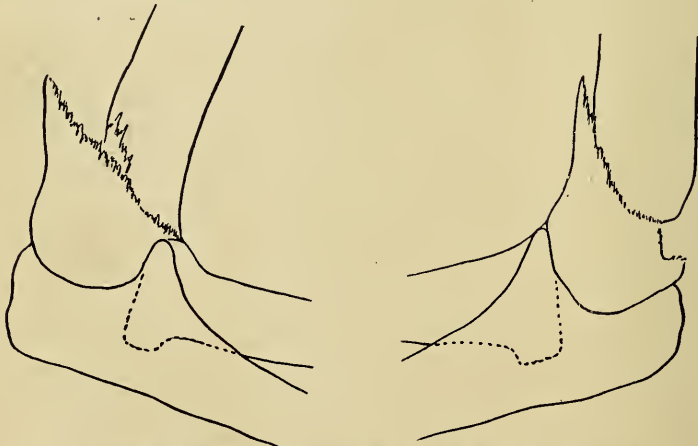A. Fractures Above the Condyles—Supracondyloid.

The line of fracture may be transverse or oblique, and oblique either from side to side or from before backward, and it may open the joint by crossing the olecranon or coronoid fossa or by the extension into it of a fissure between the condyles. It may lie above both epicondyles, or above one and below the other, and, at least at an early age, may coincide in whole or in part with the epiphyseal line.

The cause is violence acting upon the front or back of the lower end of the bone, usually through the bones of the forearm, as in a fall upon the outstretched hand, or, as indicated by Kocher's experiments, by torsion. The commonest cause appears to be a fall upon the hand in which the end of the humerus is pressed backward ("extension fracture") either directly by the partly flexed forearm or possibly by hyperextension of the joint. In this case the line of fracture is oblique from behind downward and forward, the lower end of the upper fragment often ending in a sharp point on its anterior aspect.

FIG. 127.

FIG. 128.



"Extension" and "flexion" fractures of lower end of the humerus.

When the force acts in the opposite direction, against the back of the elbow, a much more rare occurrence, and the lower end of the humerus is forced forward ("flexion fracture"), the line of fracture runs from in front downward and backward, and the sharp point is found at the upper end of the lower fragment in front (Figs. 127 and 128). Figs. 129 and 130 represent a specimen of this kind which I obtained from a patient who died of delirium tremens shortly after the accident. While carrying a flagstone he fell upon the elbow, flexed at a right angle, with the edge of the stone resting in the flexure of the joint; the fracture was almost exactly in the frontal plane, as if the condyles had been cut off by an axe descending along the anterior surface of

the humerus. In both forms the higher the fracture the less, apparently, is the obliquity. An adduction fracture in the young may be

FIG. 129.

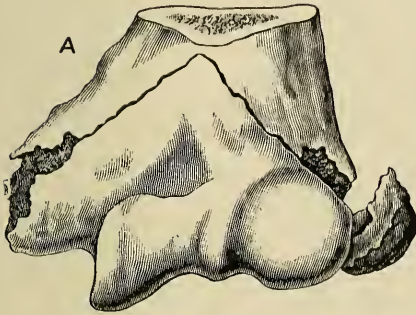
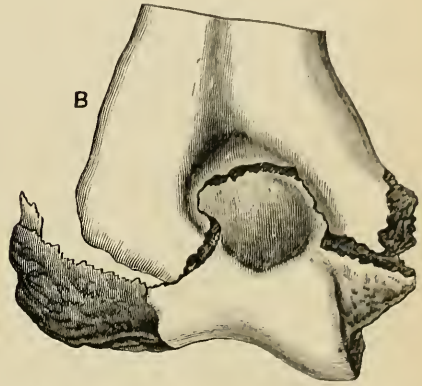


FIG. 130.

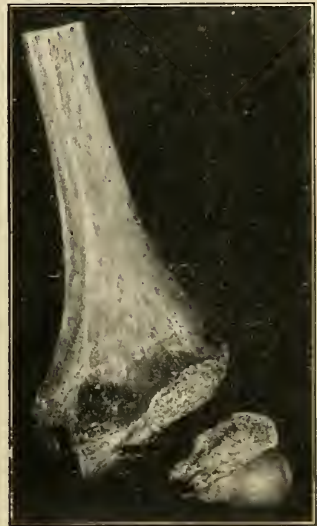

Supracondyloid fracture. A. Front. B. Rear view.

classed as a low form of this; the fracture starts close above the external epicondyle and runs along or close above the epiphysal line toward or to the epitrochlea or diverges downward through the trochlea into the joint (Fig. 131); the displacement is angular, pivoting on the inner side, and if it remains uncorrected or recurs, marked cubitus varus results.

The character and extent of displacement vary with the direction of the line of fracture; as the latter is so often oblique downward and forward, the lower fragment is commonly displaced backward and upward, and not infrequently the sharp end of the upper fragment is forced through the overlying muscles and even the skin on the antero-internal aspect. In one case, seen six months after the accident, I found on operation the musculospiral nerve ruptured at the edge of the upper fragment. To this displacement backward may be added, or for it may be substituted, an angular displacement, the apex directed forward, which accentuates the prominence of the back of the elbow. In the less common cases in which the obliquity is downward and backward the displacement of the fragment is forward and upward, but is much less marked than in the other form, although occasionally the upper fragment has been forced through the triceps and the skin. If displacement persists the range of motion in

FIG. 131.




Experimental adduction fracture in a child.

the elbow may be restricted by direct bony contact or by fibrous bands attaching the torn and bruised muscles to the bone.


In the low fractures in children, where the line apparently often coincides more or less with the epiphyseal junction, the lower fragment may be displaced inward, or less frequently outward, and with the inward displacement usually coexists an angular displacement by which the outer portion of the lower fragment is lowered, and sometimes a backward displacement of its outer portion. The result of this displacement, if uncorrected, is the angular lateral deviation of the lower fragment with the apex directly outward, which is shown in

FIG. 132.



Supracondyloid fracture with angular displacement; marked cubitus varus.

FIG. 133.



Supracondyloid fracture with angular displacement; marked cubitus varus. Front view.

Figs. 132 and 133 and in Plates VI. to IX. The deformity of the elbow, cubitus varus, which results is very noticeable in extension and has usually been attributed solely to the ascent of the internal condyle after its fracture; but the almost total absence of such specimens, the possession of others showing descent of the external condyle, and the findings in several operations undertaken to correct the deformity have convinced me¹ that, when marked, it is habitually the result of a

¹ Stimson: Cubitus varus, *Annals of Surg.*, Sept., 1900.

PLATE VI.

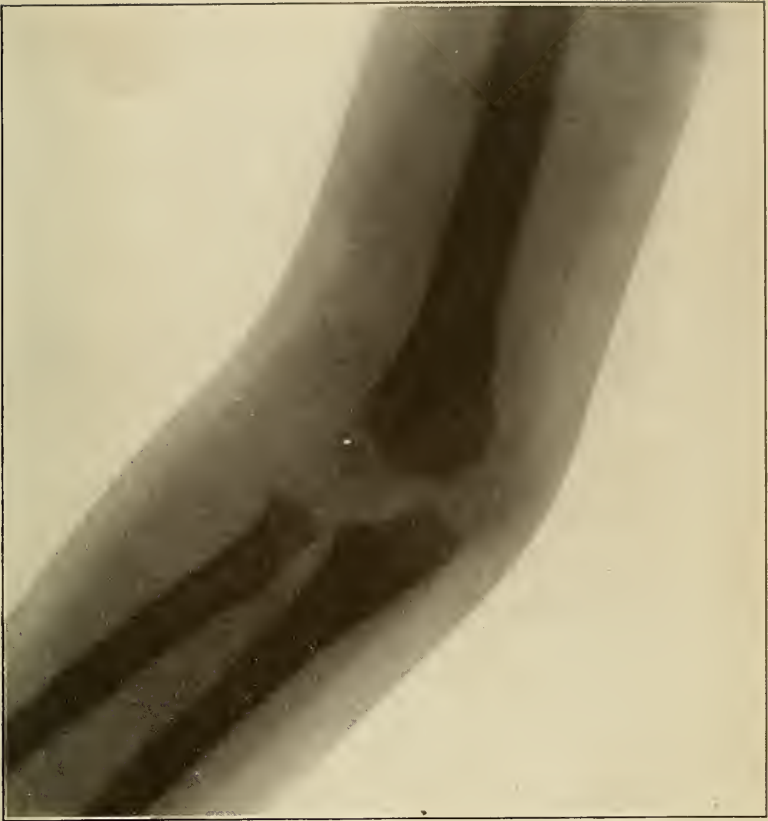

Fig. 1.—Skiagram of Normal Elbow at age of Five Years.



Fig. 2.—Normal Epiphysis of Humerus at age of Eight Years.

FIG. 1.

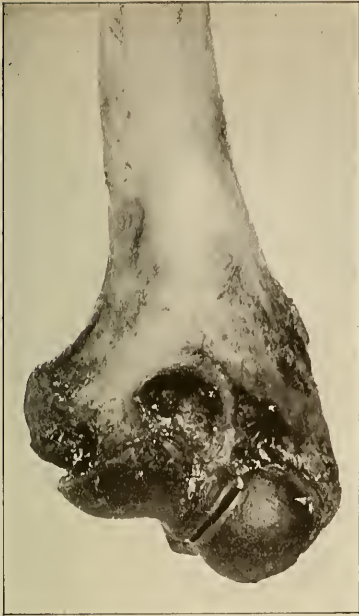

FIG. 2.

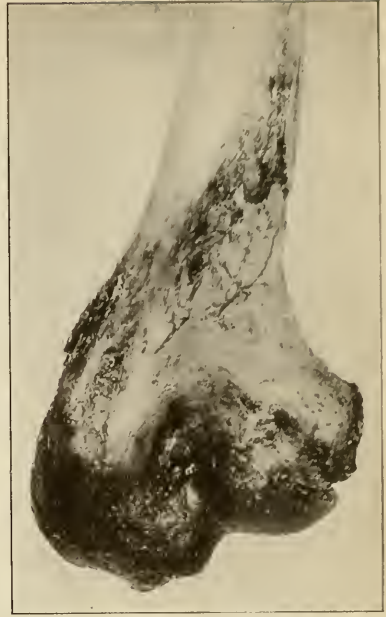
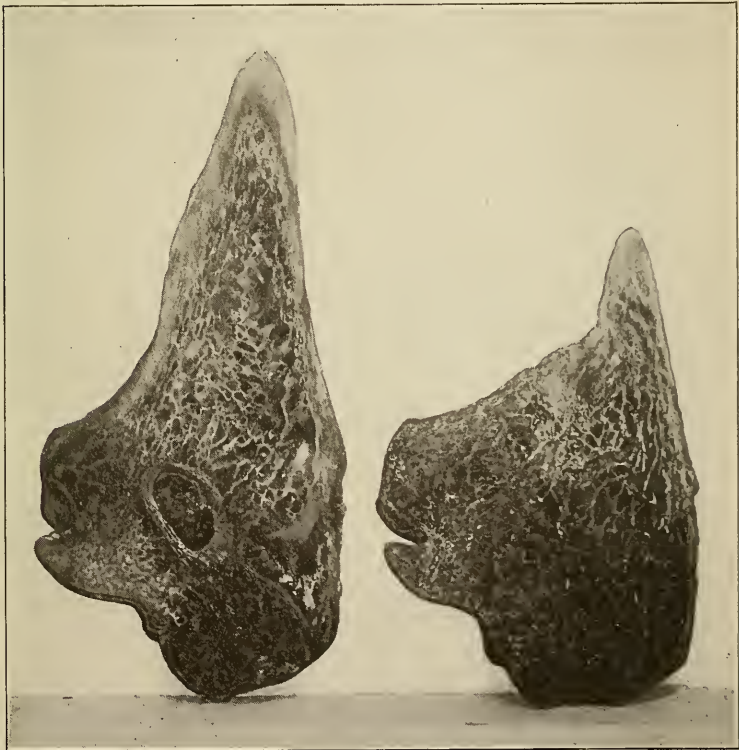
FIG. 3.

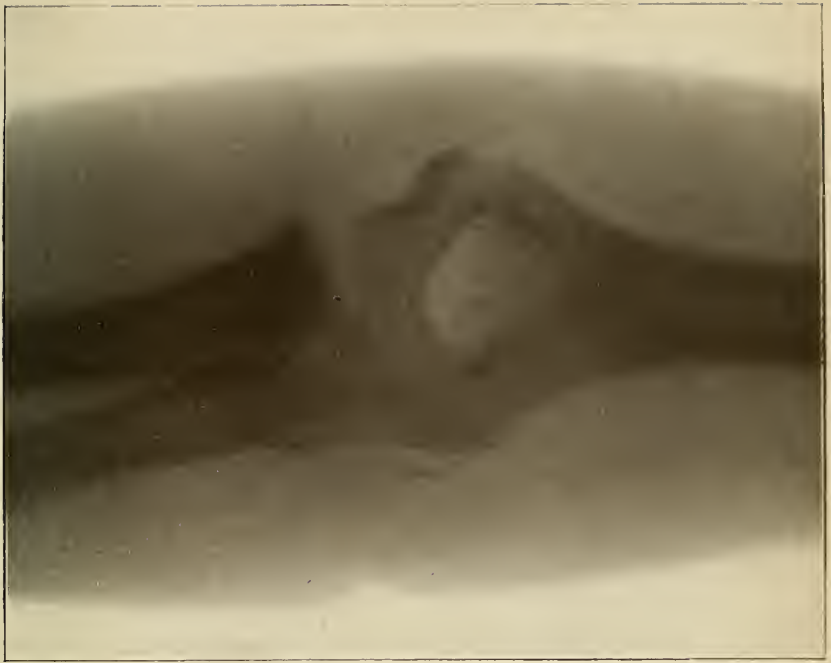

Cubitus Varus after Low Partial Supracondyloid Fracture in Youth,
or Separation of Epiphysis.

Fig. 1, front. Fig. 2, rear. Fig. 3, sections, ending above on posterior surface.

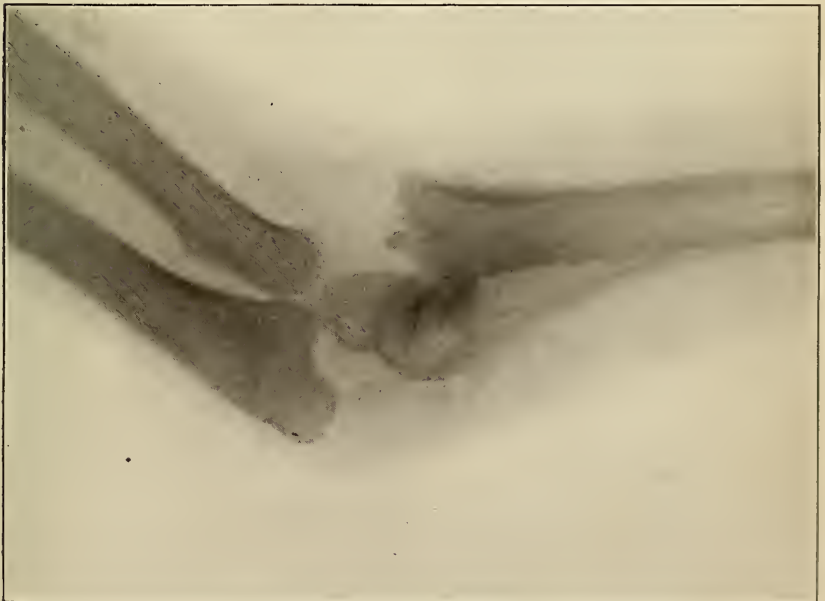PLATE VIII.

FIG. 1.



Supracondyloid Fracture at Eleven Years. No displacement.

FIG. 2.



Supracondyloid Fracture at Eight Years.

PLATE IX.



Fig. 1 - Old supracondyloid fracture of the humerus. Cubitus Varus.

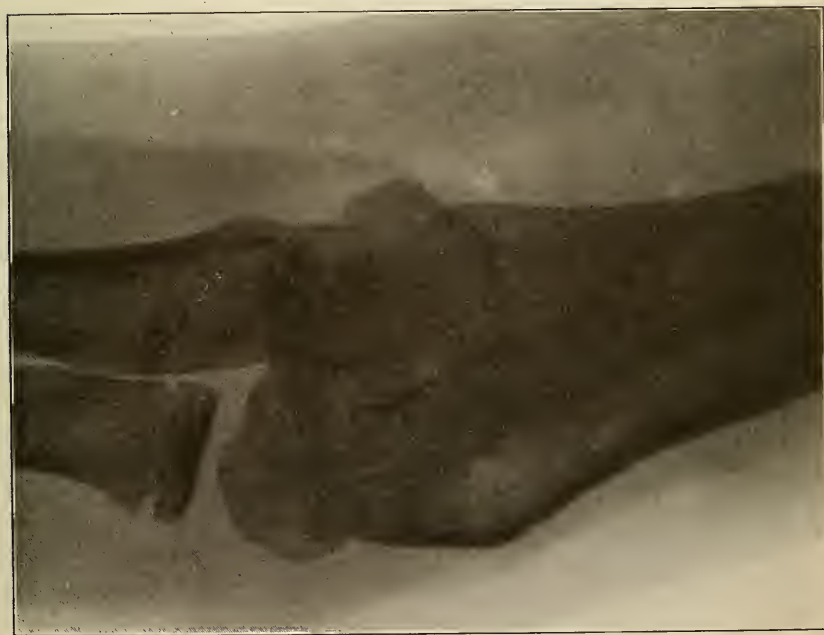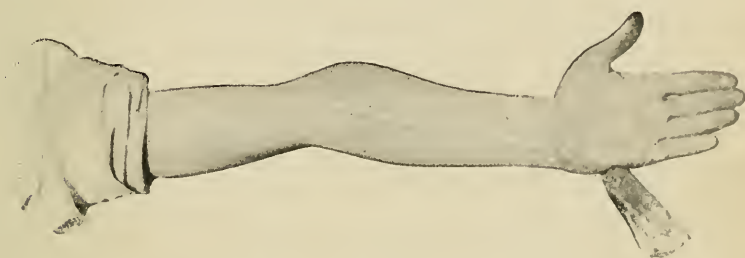


Fig. 2.--Cubitus Varus; Three Years after a Low supracondyloid Fracture. The lower part of the Supinator Ridge has been cut away.

complete or partial supracondyloid fracture followed by this angular displacement, and that this is practically the only form of fracture after which it is at all likely to occur to any extent. A number of specimens have been described and I possess three (Figs. 121, 132 and 133, and Plate VII.); those represented in Fig. 133 and Plate VII. correspond almost exactly with the condition of the bones shown in the skiagram (Plate IX., fig. 1) of the limb shown in Fig. 134.

Two frontal sections of the specimens shown in Plate VII. show no trace of fracture, no change in the cortex of the juxta-epiphysary region, and the outline of the inner supracondyloid ridge is unbroken, but more sharply curved. The appearance is that of elongation on the outer side, not of shortening on the inner, and suggests a frac-

FIG. 134.



Supracondyloid fracture; cubitus varus.

ture along or close above the epiphysary line, incomplete on the inner side, with angular displacement upon the inner portion of the internal condyle as a centre. Presumably the mass between the outer condyle and the shaft is new bone formed by the untorn periosteum. Experiment on the cadaver shows that the posterior part of the periosteum may remain untorn even when the displacement downward of the outer part of the fragment is considerable, and its preservation is even greater when the fracture is along or close to the epiphysal line.

The artery or the median or musculo-spiral nerve may be torn or compressed, but this injury is much less frequent than might be anticipated from the extent and direction of the displacement. In one case six months old I found the musculospiral nerve ruptured at the diaphyseal edge of the fracture, and sutured it. The ultimate result is not known.

In two cases of inward displacement of the low form in the young I have seen late sloughing of the skin by pressure against the outer angle of the upper fragment. Savariaud¹ reports four cases of apparent injury to the median and ulnar nerves; one recovered spontaneously, one after operation, and in two operation failed to relieve.

Symptoms. The symptoms are deformity, loss of function, abnormal mobility, and pain. The deformity may be marked or slight, the former especially when the line of fracture is oblique from behind downward and forward and the lower fragment is displaced and tilted backward; this causes a prominence of the back of the elbow which

¹Savariaud: Arch. gén. de med., 1903, No. 2.

in some stages resembles that of a dislocation, but is readily distinguished from it by noting that the relations of the olecranon and epicondyles are normal and that the head of the radius is in place. In the young, when the line of fracture passes below the internal epicondyle and the lower fragment is displaced inward, the appearance on the inner side is that of an internal lateral dislocation, and the true nature of the injury must be determined by the relations of the head of the radius and the capitellum. The easy reduction of the backward displacement by drawing the flexed forearm forward, and its easy reproduction by pressing the forearm backward has led even experienced surgeons into error, and emphasizes the necessity of accurately determining the relations of the head of the radius and the capitellum.

The determination of these relations is the first step to be taken in the examination of most injuries of the elbow; it is conveniently done by placing the tips of the thumb and middle finger on the two epicondyles respectively and that of the index-finger upon the point of the olecranon, and noting their correspondence or lack of correspondence with the normal in the positions of extension and of flexion at a right angle, ordinarily using the other elbow in comparison. The head of the radius can be felt from one-half to three-fourths of an inch distant from the external epicondyle in the direction of the wrist.

Swelling is marked and uniform; ecchymosis is usually present after a few hours; voluntary motion is inhibited by pain, passive motion restricted. Abnormal lateral mobility—adduction and abduction of the forearm—exists and is most surely recognized if the test is made while the elbow is extended. If the condyles are firmly grasped with one hand and the shaft with the other, free mobility of one upon the other, usually with crepitus, is found. Pressure upward with the hand under the flexed elbow causes pain. Pressing the condyles together does not cause pain unless the line of fracture also runs between them (T-fracture), nor can the condyles be moved independently of each other. Pressure with the tip of the finger along the supracondyloid ridges may detect irregularity and cause pain at the point of fracture if the displacement is slight; if it is marked the lower end of the upper fragment can be readily recognized, usually in front, at or close above the flexure of the elbow. Kocher, analyzing five personal cases of what he terms *fractura diacondylica*, which corresponds to that described here as the low form in the young, speaks of pain on pressing the extended or flexed forearm against the arm.

Treatment. In view of the proximity of the joint the important indication is to secure repair without displacement; and the displacements which threaten are the primary overriding in the higher fractures in adults and the late lateral angular deviation in the low ones in children (Fig. 132). The overriding can be corrected by traction, preferably with the elbow at a right angle, and its recurrence effectively opposed by anterior and posterior moulded splints, or a plaster encasement, aided sometimes by a weight attached to the forearm close by the elbow, with the wrist supported by a sling.

In the low form in children, which is, I believe, practically the only form of fracture at the elbow in which the dreaded deformity,

cubitus varus, is liable to ensue, the principal factor in its production, after reduction of the primary displacement, is, I think, the action of gravity when the forearm is supported across the front of the body. In experiments upon the cadaver and in operations to correct the deformity I have repeatedly seen the displacement appear when the limb was placed in this position, and I have seen one patient in whom it seemed probable that it took place within a plaster encasement, although it is not certain that reduction was made and maintained during the application of the dressing. Recumbency, with the elbow at a right angle and the forearm vertical, has always, in my experience, prevented it, with the aid of a thick enveloping dressing of gauze rollers. The confinement to bed need not last more than a week.

Full flexion of the elbow, which of late has been urged in a somewhat exaggerated and uncritical way as the proper treatment for all fractures at the elbow, undoubtedly holds the fragments, in this form of fracture, more firmly together, apparently by the tension of the triceps thus produced, but it can itself produce an angular displacement (apex backward), as shown in Plate XII., and of course it is valueless unless antecedent reduction is made.

In compound fractures I always use vertical suspension of the limb for about a fortnight, unless the wound heals sooner. It is of great value in controlling reaction as well as preventing gross displacements; minor adjustments can still be made after the wound has healed or has become unimportant.

In several cases of low fracture in the young, after the lapse of from four weeks to six months, I have exposed the region through an external lateral incision, cut away all new bone, freed the lower fragment, and brought it back into place with full restoration of form and function. Occasionally a second incision on the inner side is needed. In some old cases the deformity has been relieved by excision of a wedge-shaped piece from the outer side of the humerus just above the epicondyle, thus bringing the lower fragment into line with the shaft. The same could be done in case of angular displacement, apex forward, and thereby the hand would be brought nearer the shoulder in full flexion of the joint.

B. Fractures of the Internal Epicondyle (Epitrochlea).

By the epitrochlea is meant the projecting spur of bone on the side of the trochlea; its lower limit is sharply defined, but above it is continuous with the condyloid ridge.

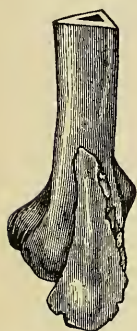The first author who called attention to this fracture was Granger,¹ in 1818. It is more common in children than in adults; of ten cases, not associated with dislocation of the elbow, treated in the House of Relief in two and a half years, the ages were one, five, ten, ten, fourteen, seventeen, twenty-eight, thirty-four, and forty-three years. The fracture frequently accompanies dislocation of the elbow, being produced, I think, by the pull of the flexor muscles of the forearm which are attached to it and which are put upon the stretch by the forcible

¹ Granger: *Edinburgh Medical and Surgical Journal*. vol. xiv. p. 196.

abduction of the form which is so common a first step in the production of a backward or outward dislocation. In cases not thus complicated the cause appears commonly to be external violence acting directly upon the back of the epitrochlea.

Symptoms. The symptoms vary somewhat with the size of the fragment, for when the latter is small it is held in place by the untorn portion of the muscular attachments upon it and the adjoining bone, but when it is large enough to include the greater part of the attachment displacement takes place downward and forward in the direction of the muscles. If the swelling is not too great the fragment can be seized

FIG. 135.



Fracture of the internal epicondyle of the humerus (epitrochlea). (GURLT.)

between the thumb and finger and moved, usually with crepitus. Ecchymosis is common, and the functions of the joint may be diminished by pain or the fear of it.

In a few cases the ulnar nerve has been injured by the original violence or irritated by pressure of the displaced fragment or a portion of callus. In three of Granger's cases there was partial paralysis of motion and sensation in the region supplied by the ulnar nerve, and repeated crops of vesicles formed upon the corresponding part of the hand during the two or three months following the injury. All the symptoms disappeared after a time. Richet¹ observed a case of fracture of the epitrochlea with dislocation of the elbow inward due to a fall upon the ice. After reduction of the dislocation the ulnar nerve was found to be completely paralyzed. A month later the little finger was so insensitive that the patient amused himself and amazed his play-fellows by holding it more than a

minute in the flame of a candle. The deep burn which was the result took several weeks to heal; afterward sensibility returned gradually and became complete.

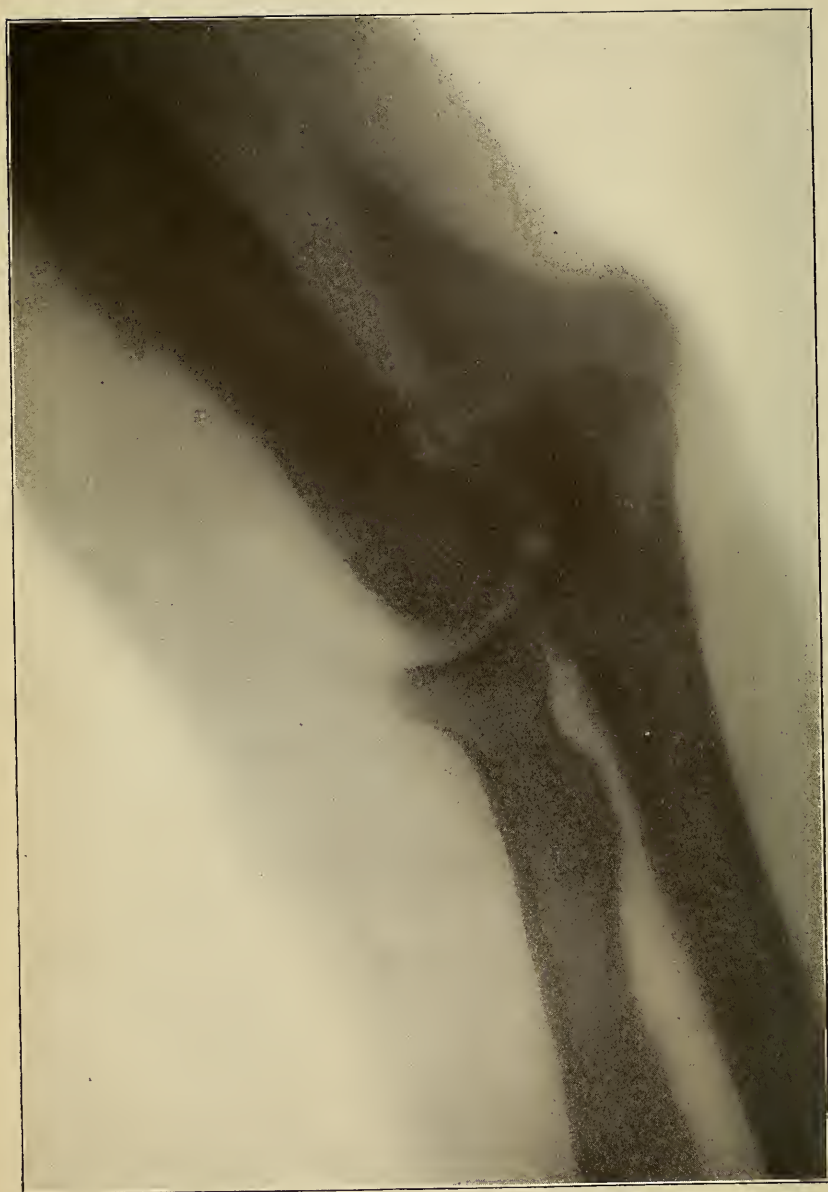Denucé² was consulted by a man suffering with an intense neuralgia of the ulnar nerve following a fall upon the elbow three months before. He recognized deformity of the epitrochlea, made an incision, and found the nerve hypertrophied and resting upon a bony prominence formed by the epitrochlea displaced and united in its false position. The projecting part of the bone was excised, and the neuralgia ceased.

Treatment. The treatment is simple: immobilization of the elbow in the flexed position so as to relax the muscles that arise from the epitrochlea and thus diminish the force that tends to draw it forward and downward. It is futile to attempt to keep the fragment in place by pressure upon it from the outside. Even if it remains displaced downward and forward the deformity is slight and entails no loss of function. Immobilization should be maintained until consolidation has taken place, the length of time necessary for which varies with the age of the patient and the extent of the unreduced displacement. In children, and without displacement, union is sufficiently firm at the end of ten days or a fortnight to allow splints to be laid aside and the arm to be

¹ Richet : Anatomie Medico-Chirurgicale, 4th ed., p. 672, note.

² Denucé : Dict. de Méd. et Chir. Pratiques, art. Coude, p. 721.

PLATE X.



Fracture of Internal Condyle of the Humerus;
in an Adult.

carried in a sling, and in three weeks the arm may be left unsupported and free.

In a few cases the fragment has been excised because of pain or fear lest it should interfere with function; it has also been proposed to secure it in place by transfixion with a pin or by incision and suture, but the measure seems wholly unnecessary.

C. Fractures of the External Epicondyle.

This is a much rarer accident than the preceding, and as the fragment that is broken off is small, and as the cause appears to be always direct violence, which is usually accompanied by bruising and swelling, the exact nature of the injury may easily pass unrecognized. An anatomical demonstration of the fracture has never been made, except in connection with more extensive fractures of the elbow.

In the sense in which the term is here used the epicondyle is the small prominence above and on the outer side of the capitellum, composed in part of bone formed about a separate centre of ossification, and in part of the projecting portion of the shaft or condyle itself. To it are attached the external lateral ligament of the joint and part of the extensor muscles of the forearm.

Most surgeons deny the possibility of an extra-articular fracture of this part, and group all fractures of the region as of the external condyle. Anatomically speaking it is certainly possible for such a fracture to occur; the epicondyle, though small, is still large enough to be broken in such a way that the line of fracture may lie entirely outside the joint.

Gurlt describes as extra-articular fractures of the external epicondyle two specimens preserved, the one at Giessen, the other at Berlin. In each the fracture has united with considerable displacement downward of the fragment, which appears in the description and figure (Fig. 136) too large to have been entirely extra-articular. Still, his personal examination of the specimens was more likely to lead to a correct opinion of them than a verbal description or a figure is.

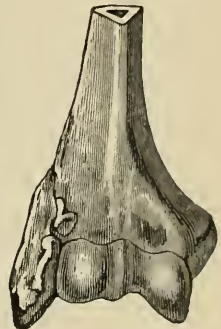There is little to be added. The cause must be direct violence, or possibly forcible adduction of the forearm acting through the lateral ligament; the displacement must be slight and unimportant; the treatment, rest.

D. Fractures of the Internal Condyle.

The line of fracture runs from a point on the inner border of the epitrochlea or of the ridge above it downward and outward, ending on the outer half of the lower part of the trochlea or at, or even a little beyond, its junction with the capitellum (Fig. 137).

The common cause appears to be violence acting from below upward upon the trochlea, as in a fall upon the flexed elbow or by forced adduc-

FIG. 136.

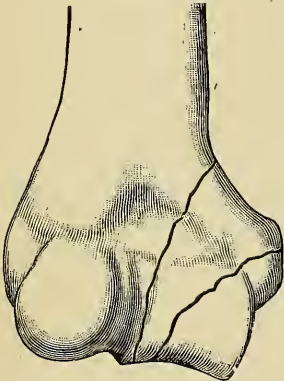


Fracture of the external epicondyle of the humerus. (GURLT.)

tion or abduction of the forearm, turning upon the head of the radius as a centre, and breaking off the condyle by forcing it upward or backward or drawing it downward or forward.

The fragment may be displaced in any of these directions, and may also be rotated. As the ulna remains attached to the fragment and is itself held in place by its attachments to the radius, the displacement of the fragment cannot be great unless there is associated dislocation of the radius from the capitellum, as occasionally observed. A late displacement, similar in effect to that observed after supracondyloid fracture, may occur here also; pressure upward against the flexed elbow, as by a snug sling, is transmitted through the olecranon to the fragment and raises it above its proper place,

FIG. 137.



Upper and lower limits of fracture
of the internal condyle.

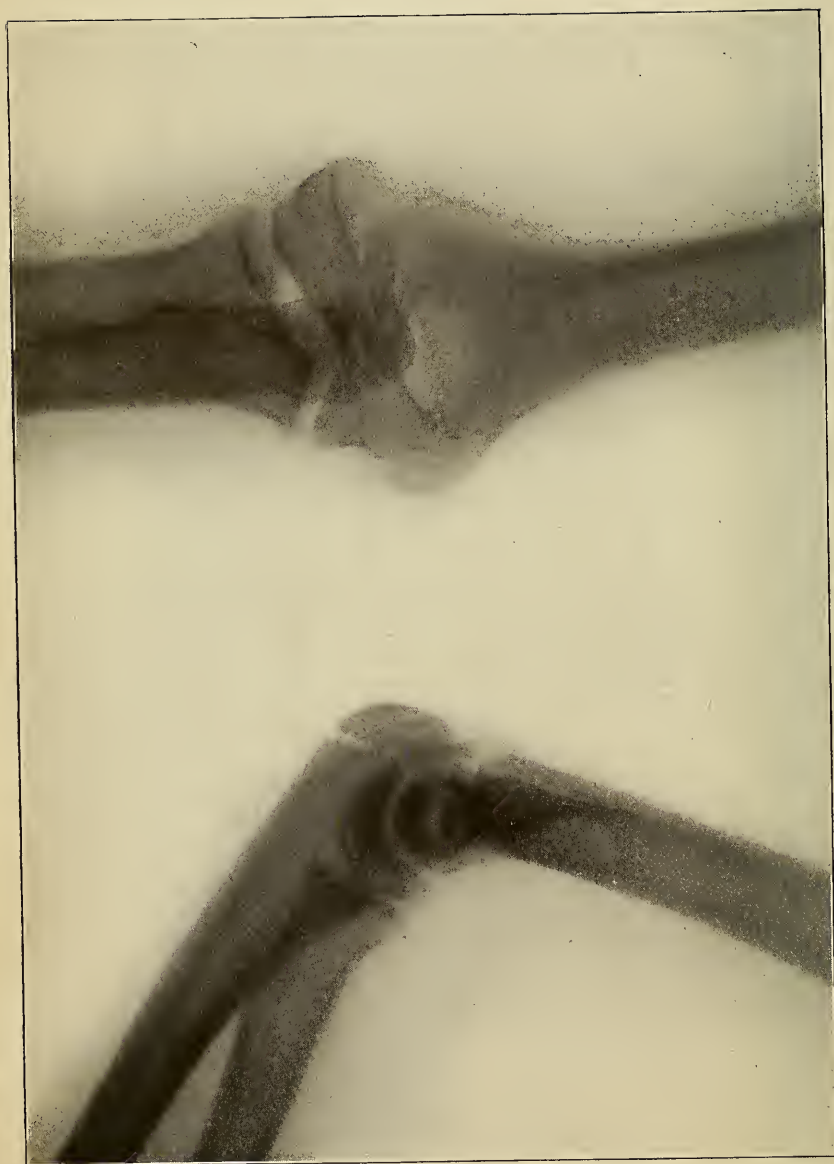thus changing the direction of the transverse axis of the joint and substituting adduction of the forearm—cubitus varus—for the slight normal abduction. Possibly the contraction of the triceps and brachialis anticus may aid in producing this result. I believe, however, this is a much less frequent cause of the deformity than displacement after supracondyloid fracture.

The swelling, as in most of these fractures at the elbow, is uniform, rarely more marked on the side of the injury except at first; loss of function is marked, the arm generally being held at an angle of about 125 degrees, and the range even of passive motion without anæsthesia is restricted.

The characteristic symptoms are independent mobility of the condyle, usually with crepitus, pain on pressing the condyles together and on pressure with the tip of the finger at the point where the line of fracture crosses the supracondyloid ridge, and sometimes an irregularity in the line of the ridge at that point. The independent mobility is recognized by grasping the fragment between the thumb and fingers and moving it slightly backward and forward while the other condyle and the shaft are held with the other hand. Pain can also be caused by pressure upward against the olecranon or backward through the forearm while the elbow is partly flexed. If the limb can be fully extended abnormal lateral mobility of the forearm—adduction and abduction—is found, especially abduction. The same mobility exists when the joint is more or less flexed, but the observation cannot be safely made, at least in the young, because of the difficulty of distinguishing between it and rotation of the humerus; full extension is necessary for the test, and this can rarely be had except with the aid of general anæsthesia. The relations of the epitrochlea and tip of the olecranon are preserved, and their elevation or displacement backward with reference to the external epicondyle is generally too slight to be recognized through the swelling.

Associated dislocation of the radius from the capitellum is recognized by the presence of its head below and behind the outer condyle and by

PLATE XI.



Fracture of External Condyle; Patient Eighteen Years Old.

the marked displacement backward of the internal condyle and olecranon which leaves the outer condyle and lower end of the shaft as an easily recognizable prominence in the flexure of the joint.

The main point to be considered in the treatment is the correction or prevention of such displacement as would seriously interfere with the functions of the joint or the appearance of the limb, notably the ascent of the condyle by which the axis of the forearm would be directed inward (adduction). The fragment is too small to be acted upon directly by any dressing, and its position must, therefore, be controlled through the ulna to which it is attached. Ordinarily this can be satisfactorily done by a fixed dressing with the elbow at a right angle, either a tin posterior splint or, preferably, a moulded one or a plaster encasement. The essential points are that the fragment should be kept well down in place while the dressing is hardening, if a moulded one is used, and that it should not be pressed upward during repair by the bandage which supports the forearm; this should lie near the wrist, not under the elbow. Full flexion and full extension of the joint, which measurably control the position of the fragment by the tension of the posterior and anterior portions of the capsule respectively, have been recommended; in each position tilting of the fragment sometimes occurs. Full flexion is a much more convenient attitude than full extension, unless the patient is kept in bed; but it is no more convenient than rectangular flexion and, I think, gives no more security against displacement. It is usually desirable in fracture complicated by dislocation of the radius, in order to oppose recurrence.

If the fragment is rotated or tilted and cannot otherwise be brought into place it should be exposed by an incision; advantage may be taken of this to fix the fragment in place by periosteal sutures or even by transfixion with a pin.

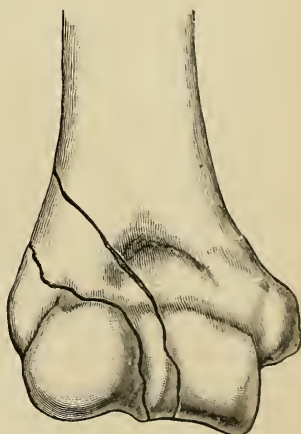Immobilization is required for about three weeks, a sling for another week, and then the limb abandoned to natural use without forced passive motion; the latter, for reasons given in Chapter VII., is more likely to do harm than good, for it may increase the irritation which provokes overgrowth of callus. Even with satisfactory reduction the range of motion may be diminished by callus obstructing the olecranon or coronoid fossa.

E. Fractures of the External Condyle.

These are much more common than fractures of the internal condyle, and much more frequent in the young than in adults.

The cause is a fall upon the hand while the elbow is flexed or upon the inner and posterior portion of the flexed elbow, or forcible adduction of forearm; in the first the force is transmitted through the radius to the

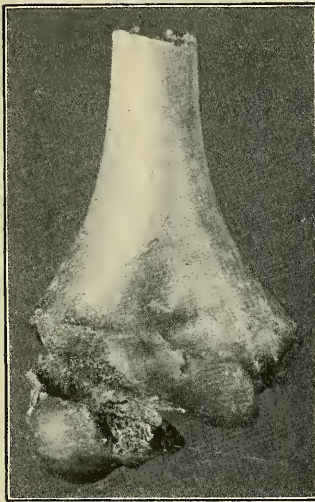FIG. 138.



Lines of fracture of external condyle.

capitellum in a backward or backward and upward direction, in the second through the olecranon upward and outward against the outer slope of the trochlea, and in the third it

FIG. 139.



Experimental fracture of external condyle by a blow on the palm of the hand, elbow flexed at right angle.

acts by avulsion through the external lateral ligament and the muscles attached to the condyle. I have found it easy to produce the fracture by adduction of the extended forearm in bodies of the young, or by a blow upon the palm with the elbow flexed at a right angle (Fig. 122). In one or two cases I have thought the cause was a blow upon the back of the condyle.

The line of fracture runs obliquely from the outer ridge of the humerus above the epicondyle downward and inward into the joint, ending usually in the groove of the trochlea, coinciding in part at least with the epiphyseal line so that the fragment comprises the capitellum, the outer portion of the trochlea, and perhaps the epicondyle. In the adult the line seems usually to extend somewhat higher. As the fragment remains attached to the radius and ulna by the lateral ligament and capsule, the

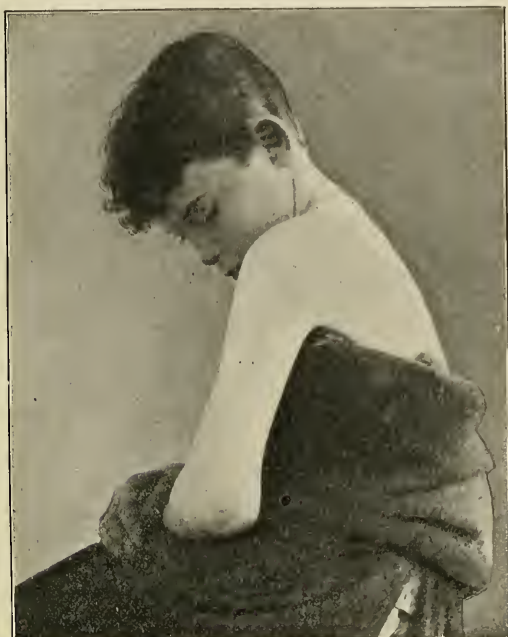displacement is usually slight when the forearm is in its proper position, but there is tendency to tilting (flexion) of the fragment, and sometimes it is markedly rotated about one or another axis, so far in one of Kocher's cases and one of mine that the fractured surface looked outward, and in two of mine upward. If the forearm is abducted the fragment is displaced backward or upward and outward; if adducted, forward or downward. If the elbow is simultaneously dislocated backward or outward the fragment accompanies the radius.

A late condition, sometimes found, such as that shown in Fig. 141, and usually attributed to a primary displacement left uncorrected, appears to me to be due more probably to arrest of development at the base of the capitellum. This condition leads to marked abduction of the forearm—cubitus valgus.

Swelling appears first on the outer side and then becomes uniform; ecchymosis appears below the condyle, or on the inner side if the patient has remained in bed with the arm abducted. Loss of function is not so marked as in fracture of the internal condyle; pain is felt on pressing the broken condyle against the shaft, inward, upward, or forward; also on pressure with the tip of the finger on the ridge close above the epicondyle. Abnormal mobility appears as adduction of the forearm (also painful), with less or no abduction, and can sometimes be recognized by grasping the fragment between the thumb and finger and moving it backward and forward while the shaft is firmly held; crepitus may be perceived at the same time. If the fragment is notably

displaced the irregularity may be recognized by palpation; and if the ulna is at the same time dislocated backward from the trochlea the condition is recognized by noting the common signs of dislocation on the inner side—backward projection of the olecranon, prominence of the trochlea in the flexure of the elbow—and the position of the fragment

FIG. 140.



Old fracture of external condyle of humerus with displacement downward and inward and incomplete dislocation inward of ulna.

in close relations with the head of the radius behind and above its proper position. The much rarer dislocation outward could be recognized in like manner.

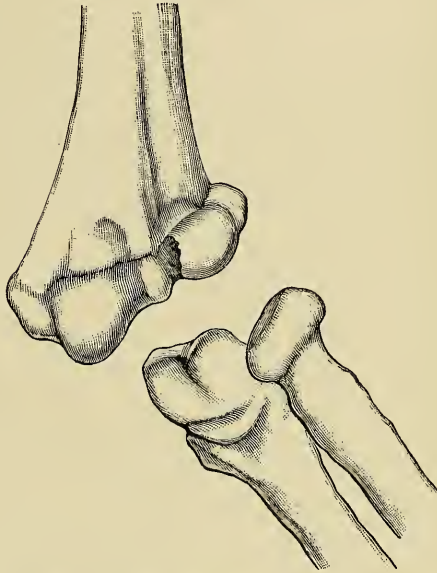
The difficulty in treatment lies more in the reduction of displacement, if it is marked, than in the maintenance of the proper position if that is secured. In most cases, those without much displacement, immobilization for three weeks at a right angle by a posterior moulded splint is sufficient, although, of course, pains must be taken to make reduction as complete as possible.

When the fragment has suffered one of the rarer displacements by rotation it is generally impossible to restore it to place without an operation. In three such cases I opened the joint by an incision on the outer side and, with considerable difficulty in two, turned the fragment back into place and obtained a good result. Kocher twice excised the fragment under such circumstances, and reports a satisfactory result; both were old cases, and one of mine was two months old.

In two old cases, one of them with displacement of the fragment

downward and inward and partial dislocation of the ulna inward, the other with displacement upward and backward, I detached the frag-

FIG. 141.



Fracture of external condyle; late result. Cubitus valgus. (HELPERICH.)

ment with a chisel and brought it back into place. Primary union; considerable improvement in function.

F. Intercondyloid, T-shaped, or Y-shaped Fractures.

These fractures are commonly caused by great violence, and consequently are often compound, either by the direct action of the violence upon the skin or from within outward by the sharp end of one of the fragments.

In many the main line of fracture is the same as in supracondyloid fracture, with an additional line passing down into the joint between the condyles; in the others the variations in the form and extent of the fracture and the degree of displacement are very great, the essential features being the separation of both condyles from the shaft and from each other, the variations appearing in the number and position of the fragments and lines of fracture. When the fracture between the condyles is a mere fissure the condyles remain together, and the displacements are those of supracondyloid fracture; in the other cases the displacements are too varied and irregular for classification and the condyles may be widely separated from each other, the olecranon passing up between them.

Occasionally the nerves or vessels crossing the front of the joint are torn or compressed.

Symptoms. The symptoms in many cases are those of supracondy-

loid fracture with, in addition, independent mobility of the condyles upon each other and pain when they are pressed together. In cases with the more varied displacements the deformity is great and the independent mobility of the condyles upon each other and the shaft is readily recognized if they can be grasped through the swollen tissues.

FIG. 142.

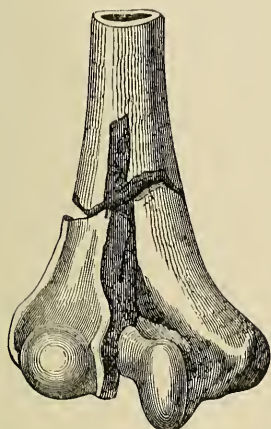
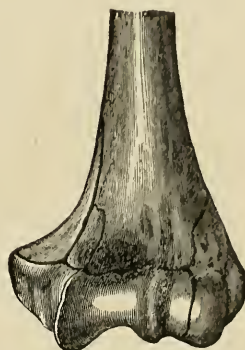
Intercondyloid fracture of the humerus.
(GURLT.)

FIG. 143.

Intercondyloid fracture of the humerus.
Front view. (GURLT.)

In respect of treatment much that has been said of that of supracondyloid fracture can be repeated. Cases with comminution and much displacement are quite certain to result in marked limitation of motion in the joint. Reduction by manipulation through the unbroken skin is largely problematical, and the limb should, therefore, be kept in the attitude which will be most useful if stiffness results. In maintaining reduction I have been best satisfied with plaster splints, anterior and posterior, held snugly at and above the condyles while they were hardening. Vertical suspension occasionally does well, especially in compound fractures, but I have never continued its use for more than about ten days, resorting then to moulded splints with the elbow flexed, and with fresh reduction if necessary. There is of late a distinct tendency toward operation in such cases with the object of suturing or pinning the fragments in place, but it must be remembered that an ideal restoration is far from always producing a similar restoration of function.

In compound fractures it may sometimes be advisable to remove some of the smaller fragments or cut off sharp ends; and in one case in which the fragments could not otherwise be held together I transfixed them with a long drill which was left in place for a fortnight. Kocher recommends the removal of the external condyle, on the ground that it facilitates drainage and ensures a greater range of motion without seriously diminishing the stability of the joint. Occasionally it has seemed advisable to remove both condyles; the resulting joint is likely to be troublesomely loose, although not so much so as when the olecranon also has been removed.

G. Separation of the Epiphysis.

To the account of the development of the epiphysis previously given (p. 243) must be added that the views of others differ therefrom in some important details, and that some of the appearances shown on section can be explained only on the supposition that the development (especially of the trochlea) differs widely in individuals, or (which seems to me more probable) that the sections have been made in different planes. The accounts which seem most trustworthy represent the trochlear portion of the epiphysis as remaining wholly cartilaginous much longer than the other portions, and as having a concave upper surface which steadily deepens so that before its union with the diaphysis it has become a relatively thin saucer-like scale capping a projecting portion of the shaft, and is connected with the capitellum on one side and with the epitrochlea on the other only by a thin neck. This seems to make the separation of the entire epiphysis, with or without the epitrochlea, in one piece from the shaft very improbable except at an early age; that it has thus been separated is demonstrated by a few specimens, but the diagnosis in the great majority of supposed cases rests only upon doubtful clinical evidence. Moreover, some writers and reporters of cases describe under this title fractures in which the line diverges widely into the shaft on the inner side, and I believe that all the cases are essentially the same as those described above as low supracondyloid fractures in the young.

Among the specimens described are Lange's,¹ two of Bardenheuer's,² and two figured and described by Poland³ from the museums of St. Mary's and St. Thomas's hospitals; in Lange's the patient was ten years old, the separation (compound) was wholly through cartilage, and the epicondyles were separated from the fragment and also from the shaft; the fragment was widely displaced from the shaft and the bones of the forearm, but was still attached to the shaft by the loosened periosteum. In one of Bardenheuer's the separation appears to have been below both epicondyles, and the fragment was displaced backward and inward with the forearm; in the second the fragment, which is not described in detail, was displaced backward, also preserving its relations with the bones of the forearm. In both of Poland's the separation was wholly along cartilage, the epicondyles remaining attached to the trochlea and capitellum. A specimen apparently of pure cartilaginous separation was in the Bellevue Hospital Museum, but has now been lost.

The cause appears usually to have been a fall upon the elbow or the outstretched hand; in Lange's the elbow was caught between an elevator and a beam, and in one of Poland's it was "jammed in a gate."

The displacement in all the certain cases has been great, and in all but Bardenheuer's the injury was compound. In the alleged cases diagnosed without direct examination of the fragment the displace-

¹ Lange: Medical Record, July, 1880, p. 48.

² Bardenheuer: Deutsche Chirurgie, Lief. 63a, p. 736.

³ Poland: "Traumatic Separation of the Epiphyses," London, 1898.

ment has been sometimes marked, sometimes slight, the diagnosis in the former being made by palpation of the fragment, in the others upon the abnormal lateral and antero-posterior mobility of the upper end of the forearm with fine crepitus and on the exclusion of other forms of fracture. Schüller and Bruns think the injury more frequent than the paucity of reported cases indicates, an opinion which must be correct if the low supracondyloid fractures in the young are included.

The symptoms and diagnosis are essentially those of low supracondyloid fracture in the young. The line of separation may pass above or below the epicondyles; the essential diagnostic feature (from dislocation) is the maintenance of the relations of the small lower fragment with the radius and ulna; and the position of the line of separation along the epiphyseal junction may be indicated by cartilaginous crepitus on manipulation.

The treatment is reduction of the displacement and immobilization, with special precautions against displacement inward, as in low supracondyloid fracture (*q. v.*).

H. Fractures of the Articular Process, in Whole or in Part.

These include fractures of the whole or part of the capitellum, of the inner portion of the trochlea, and of the capitellum and trochlea together.

A few specimens of fracture in adults passing wholly or mainly below the epicondyles are known, and Kocher, who includes them with separation of the epiphysis under the title "fractura diacondylica," found that the lesion could be produced experimentally by a blow upon the lower surface of the bone in the direction of its long axis.

The direction and character of the violence apparently concerned in the production of these fractures suggest a well-marked displacement of the fragment forward and upward in combination with the radius and ulna which probably could be recognized by palpation and the abnormal mobility. The indications for treatment would be to press the fragment downward and backward into place and keep it there by pressure or traction upon the upper part of the forearm. The prognosis, in respect of the preservation of function, seems bad because of the intra-articular position of the line of fracture.

Fracture of the capitellum alone, in whole or in part, has been observed in a number of cases. Hahn¹ reports an old specimen in which the capitellum had united with the front of the humerus after displacement upward and rotation. Kocher figures four specimens representing larger or smaller portions of the capitellum removed by operation in fresh cases; Figs. 145 and 146 represent the largest and smallest. Steinthal² reports a case similar to Hahn's. The capitellum was removed by operation, with improvement of function.

In two of Kocher's cases the cause was violence exerted through the radius, the elbow being flexed, once in a fall upon the palm of the hand, and once by pressure against the palm while the back of the elbow rested against a wall; in the other two the injury was received

¹ Hahn: Quoted by Gurlt, loc. cit., p. 801.

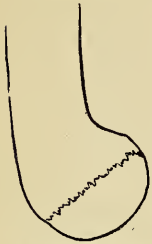² Steinthal: Centralb. f. Chir., 1898, p. 17.

in an effort to raise or hold a heavy object, apparently with the elbow partly flexed. The mechanism in the latter cases seems to me to be pressure by the head of the radius upward against the lower anterior portion of the capitellum under the pull of the biceps.

In a personal case the capitellum was broken off and the upper posterior angle of the olecranon broken (extra-articular) by the fall of a heavy stone. The injury was compound and the skin so contused that it sloughed; the ensuing suppuration led to later excision of the end of the humerus. Recovery with preservation of rotation of the forearm. In another the lower two-thirds of the capitellum was broken off, but remained attached posteriorly (Fig. 144). The arm had been caught between a tugboat and a float. There was a large hematoma and a small wound of the skin. I exposed the fracture and fastened the fragment in place with periosteal sutures. Good result.

The local reaction, as evidenced by pain, swelling, and loss of function, is comparatively slight or tardy in appearing; in three of six reported cases the fragment was displaced upward within the capsule of the joint, in the other three

FIG. 144.

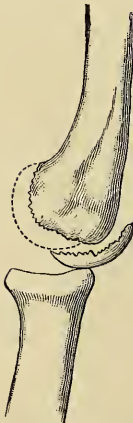

Fracture of the capitellum.

FIG. 145.

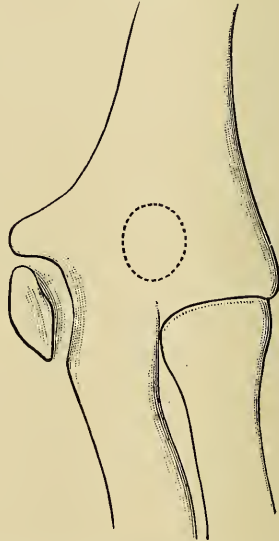


FIG. 146.



Fracture of capitellum.

FIG. 147.




Fracture of inner rim of trochlea. (Tracing from an imperfect skiagram.)

(all Kocher's) backward, lying between the head of the radius and the olecranon, where it could be easily felt. Kocher removed the fragment

PLATE XII.

FIG. 1.



Angular Displacement Produced by Flexion. Same case as Plate XI.

FIG. 2.



Supracondylar Fracture, Three Weeks Old.
Reduced by operation.

in all his cases and secured a good result. Lorenz¹ reports 2 cases successfully treated by excision of the fragment, and quotes 2 others (Hahn, Steintal) in which the fragment was displaced upward beyond the head of the radius.

Fracture of the trochlea alone is very rare. Langier first called attention to it in 1853 in a report of a case in which the diagnosis rested only on scanty clinical evidence. I have had a case in which a fragment of the lower part of the inner rim of the trochlea, about three-fourths of an inch long, had been broken off and could be easily felt beneath the epitrochlea. The displacement was slight, so I did not excise the fragment, but simply immobilized the joint. The result was good. In another case, Fig. 147, with a larger fragment, the same plan was followed with a similar result.

Diagnosis.

There is so much in common in these injuries of the lower end of the humerus that it is well to summarize the methods of examination and the principles of treatment.

In most cases of injury the diagnosis at first sight rests between fracture, dislocation, and sprain; the first two have positive signs by which they can be affirmatively recognized, the latter has its own signs, but its diagnosis must be confirmed by exclusion of the other injuries.

If the case is seen early the absence of swelling greatly facilitates examination; if excessive swelling is present it may be diminished by vertical suspension of the limb or by the use of the elastic bandage, and the fluoroscope or the skiagram may give information that cannot be got at the time by palpation. The region in which swelling begins, or to which it remains limited, is the one which specially requires close examination.

After the history of the accident has been obtained—usually too vague or uncertain to be of much value—and in the absence of indications pointing clearly to one or another portion of the bone or one or another kind of injury, the surgeon seeks to place the ends of his thumb, index-, and middle finger on the two epicondyles and the tip of the olecranon in order to determine their relative positions and to note if their relations are normal in such attitudes as he can give to the joint. This examination, if it can be satisfactorily made, should at once determine the presence or absence of a dislocation of the ulna, and of the radius if the head of that bone is next found.

If dislocation has thus been excluded and if the patient is not too young, he next seeks the indications given by pain, grasping the elbow with one hand and the shaft of the humerus with the other and pressing the two together and then sideways, with thumb and fingers on the epicondyles, determining also by the latter movement the presence or absence of abnormal mobility of the lower end upon the shaft; if the results suggest supracondylar fracture confirmation is sought by exploration of the condyloid ridge for points of pain and irregularity of outline, and the shaft is traced downward to determine its relations

¹ Lorenz: *Deutsche Zeitschrift für Chir.*, vol. 78, p. 531.

to the condyles. The condyles are also pressed together to note the pain of a fissure running down between them, or each is grasped between the thumb and fingers and the effort made to move them on each other.

The positive sign of fracture of either condyle is its independent mobility, recognized by grasping it between the thumb and fingers and moving it backward and forward. Corroborative evidence, or evidence that may be deemed sufficient in absence of independent mobility, is pain on point pressure on the condyloid ridge and abnormal abduction or adduction of the forearm, adduction in fracture of the external, adduction in that of the internal condyle, and pain, especially on movement in the opposite direction.

Fracture of the internal epicondyle is shown by its abnormal mobility.

The positive evidence in every case is the independent mobility of the fragment, usually with crepitus, and only when that is unrecognizable because of the impossibility of properly grasping the fragment should the surgeon rest his diagnosis upon other symptoms. If this rule and that of always determining the relative positions of the ends of the bone constituting the joint were followed, the disastrous confounding of fractures and dislocations would be much less frequent. Anæsthesia is indispensable in many cases for a complete examination.

Treatment.

The tendency to displacement except by the unsupported or improperly supported weight of the limb is so slight that if reduction can be made a satisfactory result should be obtained in most cases, the exceptions being those in which the functions of the joint are diminished by obstructive callus or by peri-articular thickening. Consequently every effort should be made to effect complete reduction, especially when the fracture extends into the joint, even, if necessary, by exposure through an incision, and then to prevent its recurrence by so supporting the limb that this cause of displacement may not become operative. In the great majority of cases efficient immobilization and protection are afforded by moulded anterior and posterior plaster splints, the elbow being flexed at a right angle and the limb supported *at the wrist* by a sling. But in the low supracondylar fractures in children this attitude exposes to lateral displacement by gravity and consequent marked cubitus varus, and should be guarded against as above described. If the sling is broader and so placed as snugly to support the limb at the elbow, it may easily produce a slighter form of cubitus varus in fracture of the internal condyle or in the higher supracondyloid fractures, by pressing the internal condyle or the inner portion of the lower fragment respectively upward.

The stiffness which is found when the splints are removed will ordinarily disappear promptly under natural use. The period can be shortened by systematic daily massage, begun at about the end of the second week. Bony ankylosis is extremely rare.

For the details of special cases which cannot well be summarized the reader is referred to the preceding sections, and for fracture of the adjoining portions of the radius and ulna, to the following chapter.

CHAPTER XX.

FRACTURES OF THE BONES OF THE FOREARM.

In the Vicinity of the Elbow-joint: Olecranon, coronoid process, head and neck of radius—Fractures of the Shaft: Both bones, ulna, radius—In the Vicinity of the Wrist: Of the radius, Colles's, other than Colles's.

1. IN THE VICINITY OF THE ELBOW-JOINT.

A. Fractures of the Olecranon.

THE frequency of fractures of the olecranon has been very differently estimated by different writers, Malgaigne placing it among the rarest, only nine cases in a total of more than 2300 fractures treated during eleven years at the Hôtel-Dieu. The table in Chapter I. gives 118 cases in a total of 14,566 (0.8 per cent.).

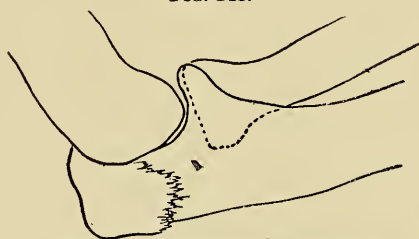The line of fracture may lie at any point above the base of the coronoid process, crossing the bone transversely or obliquely or along a V-shaped line corresponding somewhat to the borders of the triangular subcutaneous surface of the olecranon. In rare cases it is comminuted, and sometimes is compound. In a very few cases the epiphysis has been broken off along the line of the conjugal cartilage.

The commonest cause by far—36 out of 45 cases collected by one writer—is thought to be a fall upon the elbow. The mechanism, however, is apparently not simply that of fracture, by direct violence, the bone is not broken solely by a force acting directly upon the end of the apophysis, but the contraction of the triceps must play an important part in it. Among the reasons for this belief are the usual absence of the signs of direct violence upon the surface of the region sufficient to have caused the fracture, and the impossibility of producing similar fractures upon the cadaver by this means. When the fracture is produced experimentally by direct violence, by a blow with a blunt object, the bone is not broken cleanly and transversely at its narrowest part, as is the case in most fractures observed clinically, but it is crushed and split into several pieces. The explanation that seems most plausible is that a sudden change is effected in the position of the forearm by the fall when the muscles are all tense. The man falls with his elbow partly bent, and all his muscles rigid with the effort to save himself; his outstretched hand or the back of his forearm encounters some solid object, and the flexion of the limb is suddenly and violently increased, while the olecranon is held immovable by the triceps. The consequence is that the ulna is bent about the elbow, and breaks at the weakest part of the olecranon if the violence is received near the elbow, or, perhaps, at some part of its much thinner shaft if the violence is received upon the hand.

Occasionally the olecranon has been broken in an attempt to reduce an old dislocation or to mobilize a stiff elbow; and it has been alleged that a blow upon the back of the ulna near the elbow can break or crack the olecranon from the articular surface outward.

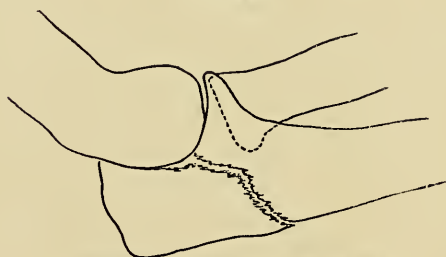
Muscular action, contraction of the triceps, appears to be an occasional cause, as in throwing a ball or vigorously pushing with the elbow partly flexed. In such fractures the fragment torn off is small, little more than the cortical layer of the summit of the process to which the triceps is principally attached; in other cases the line of fracture lies usually at the narrowest part of the process, directly under the centre of the sigmoid fossa, that which is called by some the centre, by others the base, of the olecranon.

FIG. 148.



Fracture of olecranon. x-ray tracing.

FIG. 149.



Fracture of olecranon. x-ray tracing.

Another variety of fracture, partial or complete, and produced from within outward, has been spoken of by different writers as theoretically possible, but has only recently been observed and described clinically. Pingaud¹ produced it experimentally in the effort to dislocate the ulna backward by over-extension (extension beyond the straight line) of the forearm. The end of the olecranon is pressed against the humerus, the lateral ligaments resist the movement, and the prolongation of the effort results in fracture of the olecranon or, much more commonly, of the thinner and weaker shaft of the ulna. Quintin² reports three cases of incomplete fracture of the olecranon; the surface articulating with the humerus was broken, the dorsal portion was unbroken; in all

¹ Pingaud: *Dict. Encyclopédique*, art. Coude, pp. 517 and 631.

² Quintin: *Beitrag zur Lehre von den Brüchen des Olekranon*, Bonn, 1881, Abstract in *Centralblatt für Chirurgie*, 1881, p. 763.

PLATE XIII.

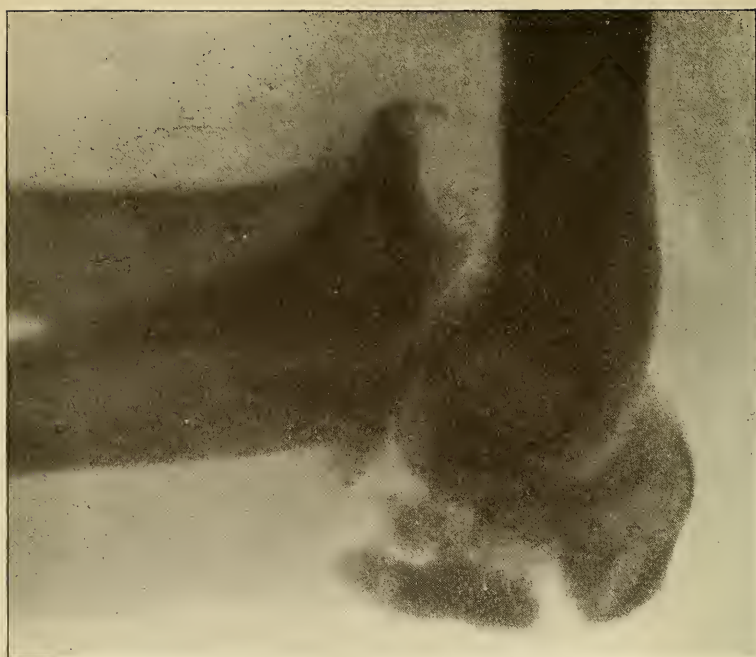

Fig. 1.—Fracture of Olecranon; Dislocation forward of Radius and Remainder of Ulna.

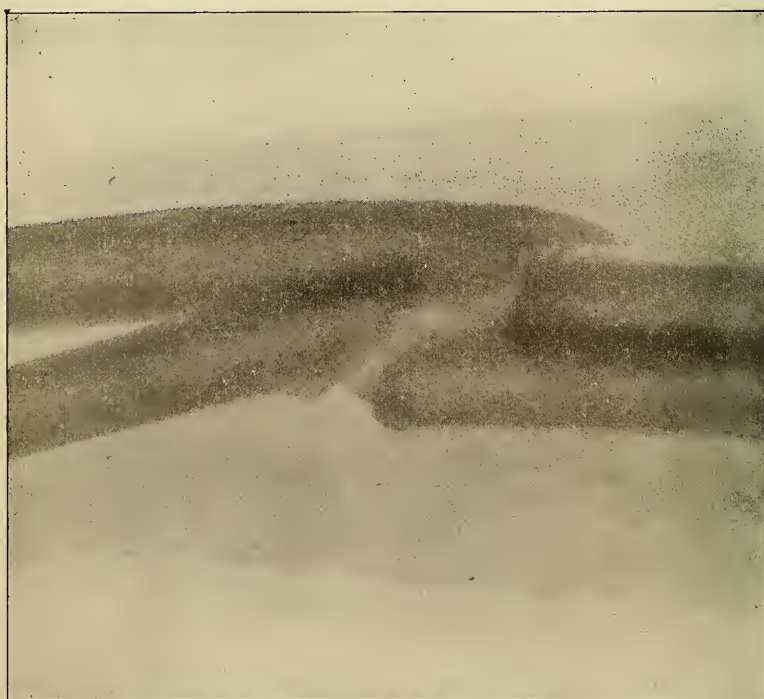


Fig. 1.—Fracture of Radius; marked Angular Displacement.

the swelling was moderate, the pain severe, flexion and extension complete but slow. In the first case, seen a week after the accident, a small prominence could be felt on the side of the olecranon, and behind it was a notch; the upper end could be sprung back a little. In the second case a short shallow groove could be felt on the outer side of the olecranon, at its base; and in the third the olecranon could also be sprung. Quintin thinks this fracture is frequently overlooked and treated as a simple contusion. The symptoms in the three cases described will, perhaps, hardly be considered entirely demonstrative, in the absence of corroborative testimony of direct examination, of a recent fracture; and, indeed, it is only by admitting that the injury is a common one and has heretofore always been overlooked that its occurrence three times during a short period in the experience of one observer can seem probable.

Symptoms. The symptoms of the fracture are pain, swelling, displacement, and mobility of the upper fragment, sometimes crepitus, and loss of power, especially of active extension.

As the result, apparently, of theoretical considerations, and of what has been observed in exceptional cases, the tendency to displacement upward of the fragment by the contraction of the triceps has been somewhat overstated. This action of the muscle is greatly restricted by the lateral aponeurotic attachments and ligaments, and by the extension of the insertion of the triceps along the lateral and posterior aspects of the olecranon, all of which must be ruptured before the fragments can be widely separated and the upper one drawn high up. In a discussion in the *Société de Chirurgie* which followed the presentation by Bardinet of a paper upon this subject, Robert, Richert, and Gosselin testified to the usual absence of separation in their experience, and similar testimony has since been furnished in abundance.

If the thick periosteum and tendinous attachments on the sides and back of the olecranon are torn, nothing remains to hold the fragments together, and separation may be effected either by the contraction of the triceps, drawing the upper fragment away from the shaft of the bone, or by flexion of the forearm, drawing the bone away from the fragment. In either case coaptation is effected by extending, straightening, the forearm upon the arm, because the triceps cannot draw the fragment above the position which it takes in complete extension unless the ligaments which bind it to the humerus are torn, and this is a complication which apparently happens very rarely.

In old ununited cases the gradual retraction of the triceps draws the fragment upward, but not even in such has it risen above the olecranon fossa.

Another displacement, one that is important because of the danger that the skin may be broken by the pressure to which it leads, is an angular one observed in a few cases when the line of fracture has been near the base of the coronoid process, and especially when its direction has been obliquely downward and backward and the upper fragment has ended in a sharp lower edge or point.

Coincident dislocation of the radius and ulna forward is occasionally seen. (See Chapter XLV., and Plate XIII.)

Mobility of the fragment is recognized by grasping it between the thumb and finger and moving it laterally, or by flexing the forearm gently while the finger is pressed against the groove or crack left by the separation when it is slight. If the fragments are brought together by extending the forearm or drawing the upper fragment down, crepitus can be felt.

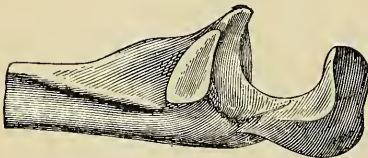
If the swelling is sufficient to prevent recognition of these objective signs, the fracture may be suspected from the history of the case and the loss or marked diminution of the power of active extension.

Repair. It is very important, with reference both to the treatment and prognosis, that the character and extent of the displacement should be known. As a rule, union takes place, but it is fibrous, not bony; and the restoration of function depends in a measure upon the length of the fibrous band. I say "in a measure," for experience has shown in not a few cases that there may be excellent control over the limb even with a long fibrous band between the two fragments. The disability sometimes observed under the opposing conditions, limitation of motion when the band is short, is due to adhesions between the fragment and the humerus, or to change in the flexibility and length of the capsular bands. The process of repair involves two dangers: defective union or failure of union between the fragments, and the formation of the intra-articular bands or changes in the articular and peri-articular tissues.

Instances of bony union do exist. Malgaigne figures and describes one in his *Atlas* (Plate XXIV., fig. 2), which, however, differs notably from the ordinary fracture, the line having run so obliquely as to bring away with the olecranon a lateral half of the coronoid process. Many instances of union with very slight separation, if any, and apparently bony, have been reported, but in only a few has the character of the union been established by autopsy. Gurlt¹ describes and pictures two: one, a fracture half an inch from the apex of the process, united with slight displacement of the fragment upward and only a small amount of callus on the outer side; the line of fracture

is partly visible upon the surface of section, and complete extension of the joint is prevented by an over-growth of bone at the apex. The other is an oblique fracture (Fig. 150), and has united so completely that the only sign of it is "a shallow groove on the under surface of the olecranon running obliquely backward from the radial to the

FIG. 150.



Fracture of olecranon; bony union. (GURLT.)

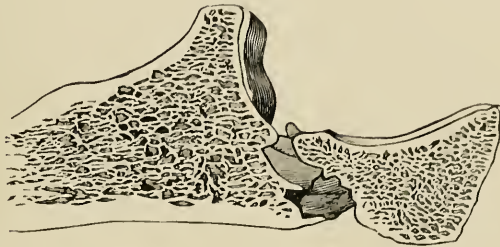
ulnar side. The articular cartilage is lacking in part, and the callus consequently visible." Apparently bony union is more probable when the fracture is oblique.

The length of the fibrous band varies within very wide limits. Fig. 151, taken from Malgaigne, represents a comparatively short band and one that presents another peculiarity in that it consists of two

¹ Gurlt: *Loc. cit.*, vol. i. p. 41, Fig. 9, and p. 310, Fig. 121.

lateral bands with a central interval or gap. This is by far the most common mode of reunion, and although several cases have been reported in which the patient appeared to have regained full use of the

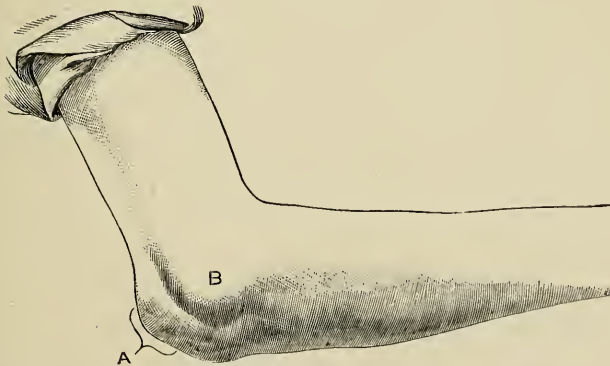
FIG. 151.



Fracture of the olecranon; fibrous union. (MALGAIGNE.)

arm, notwithstanding fibrous union with separation to the extent of half an inch more, yet actual deficiency in the power of active extension of the forearm is to be regarded as a frequent result of fibrous union, and its degree will vary directly with the length of the band. The disability may be unnoticed by others, and its consequences may be avoided or diminished by care in the use of the arm, by avoidance of positions and movements which require the especial action of the

FIG. 152.



Ununited fracture of the olecranon. A, the upper fragment; B, the external condyle.

triceps, but it exists and can be readily demonstrated. Malgaigne describes a case in which the fragment apparently had not reunited with the shaft, and yet the patient could use the limb actively, and even handle a sword or a foil. On examination it was found, however, that the vigor and strength of the arm depended largely upon its position, being greatest when the hand was supinated and the arm dependent, and disappearing almost entirely when the arm was raised above the horizontal line.

Failure of union, as in the case just mentioned, is not very uncommon; the upper fragment may remain freely movable, or it may become adherent to the humerus. In a case of the latter condition which came

under my observation thirty-five years after the accident (Fig. 152) the forearm could be completely flexed and could be extended to 135 degrees, the force of extension being very feeble.

In the majority of cases union takes place with but little separation and with full restoration of function, so far at least as power is concerned, although extension is often incomplete.

A still more unfortunate result, ankylosis of the joint, has followed in a small number of cases. Malgaigne quotes from Camper and Trioen an anatomical specimen of bony fusion, and although it is not specifically asserted that the union was between the ulna and the humerus, this seems probable from the context. Thierry, according to Pingaud, reported two cases of articular rigidity that had lasted, the one for six months, the other for a year, in spite of the most persistent efforts to overcome it. I have seen a case in which the joint was stiff in full extension after wiring of the fragments, although the operation-wound had healed without suppuration.

The course of the fracture is ordinarily very simple and uncomplicated; the swelling subsides promptly and union takes place in from three to four weeks.

Treatment. Discussion concerning the proper treatment of fracture of the olecranon has turned mainly upon the position to be given to the limb, some favoring the extended position in order to secure closer union of the ligaments, others recommending flexion, either because they did not fear separation of the fragments and sought the position that could be kept with the least discomfort, or because they feared ankylosis and wished to have the limb in the most favorable position if it should occur. It is evident from the facts that have been already stated that neither the first nor the third reason is sufficient to establish a rule of practice to be followed in all cases. The probability of the occurrence of ankylosis after simple fracture is very small, so small that it ought not to be weighed against that of non-union when the fragments are separated rather widely. On the other hand, the separation at first is so slight in many cases and the extended position so unnecessary to overcome it that if partial flexion is more comfortable to the patient, if it makes the restraint less irksome, it should not be denied him. Furthermore, there appears to be danger of two displacements in complete extension: if the fracture is at or near the base of the process the ulna can be readily dislocated forward; and secondly, effusion into the joint or swelling of the capsule may prevent the tip of the olecranon from sinking into the olecranon fossa to the usual depth, and under such circumstances complete extension of the forearm would cause a tilting, an angular displacement of this fragment. This latter point has been made by several writers upon theoretical grounds alone, but, although it seems plausible, no confirmatory observation has been made, so far as I know.

The aim of treatment should be to secure bony union if possible, and, failing that, close fibrous union, and this consideration will regulate the position to be given to the arm. If there is wide separation which increases as the elbow is flexed, if the fragments cannot be brought well together except by extending the forearm, that position must

be taken and kept until consolidation is well advanced. If, on the other hand, the separation is slight and the upper fragment follows the movements of the lower, if they can be easily brought together and kept so by moderate traction upon the upper one, the patient may be safely allowed the comfort of the partly flexed position.

Apparently it is not often necessary to take especial measures to draw the upper fragment down to the lower one, and even when there is considerable separation between them in the flexed position it is usually sufficient simply to extend the elbow. Some methods of treatment, however, have been designed with the especial intention of drawing the fragment down, and it has been sought to accomplish this by figure-of-eight bandages passing above and below the fragment and crossing in front of the elbow, or by circular bands about the arm drawn together by longitudinal ones. In others, strips of adhesive plaster have been applied to the skin above the olecranon, drawn down snugly, and fastened to the skin of the forearm or to the splints; sometimes the plaster is cut in the form of a U, the olecranon lying in the angle and the two sides passing along the forearm.

Metal hooks similar to those used in fracture of the patella have also been used here successfully, although not frequently. I do not know when or by whom they were first employed, but Busch recommended them in 1864, and Pingaud¹ speaks of the use of a similar method "a very long time ago" by Prof. Rigaud, of Strasburg. It is sufficient that the hook should have but a single point at the upper end, and at the other end should be made fast to a gypsum bandage covering the arm and forearm and provided with a large fenestra behind the elbow.

The best splint is an anterior one made fast to the limb by a roller bandage or a fenestrated gypsum bandage. It is not worth while, I think, to try to force the upper fragment down by turns of a roller bandage, because this can be done much more effectively when necessary by adhesive plaster or hooks. In short, the treatment to be recommended is as follows: If the separation is slight and is not increased by the flexed position it is only necessary to immobilize the limb with the forearm slightly flexed, about midway between complete extension and flexion at a right angle, and for this purpose an anterior splint of wood or of plaster of Paris is sufficient and convenient. If the fragment shows any tendency to be drawn up it should be secured with adhesive plaster. If, on the other hand, there is notable separation, and if the separation is increased by flexion of the forearm, the extension should be complete enough to bring the fragments together, and it should be aided by adhesive plaster or hooks. The fenestrated gypsum bandage seems to be the one best fitted for this purpose, and the fenestra should be large enough and so placed as to permit inspection of the seat of fracture. If Malgaigne's hooks are used in connection with it one hook or pair of hooks should be forced through the tendon of the triceps down to the bone, and the other pair fixed to the gypsum bandage below the fenestra. In one of three cases recorded by Quin-

¹ Pingaud: *Dict. Encyclopédique*, art. Coude, p. 639 (1878).

tin,¹ the hooks remained in place four weeks without causing any inflammatory symptoms.

If the patient is rheumatic, or if the reaction has been severe and prolonged and ankylosis is feared, it is well to change the degree of flexion slightly from time to time after the pain and inflammation have disappeared; and if the tendency to separation is slight this change of position may be begun quite early. It must be done very gently and cautiously, and the upper fragment must be supported by the finger in order that the adhesions may not be ruptured. In a case reported by Pingaud,² the callus was broken by this attempt at passive motion; and as the surgeon did not dare to immobilize the joint again for three or four weeks he applied a plaster bandage to the forearm, and used it as the support for a pair of Malgaigne's hooks by which he was enabled to keep the fragment perfectly in place, and at the same time to move the elbow as much as he wished.

Lauenstein³ used in one case a method of preliminary treatment recommended by Volkman in fracture of the patella: aspiration of the joint to remove the blood and synovia. There was separation to the extent of half an inch and the joint was distended; he removed 50 c.c. (about 1½ ounces), dressed the limb in the extended position upon an anterior splint, and drew down the fragment by means of longitudinal strips of adhesive plaster renewed about once a week. Recovery followed without displacement and with full use of the joint. Another case is reported in the *Centralblatt für Chirurgie*, 1885, p. 570.

In a few cases the fragments have been wired together; when resort to such a measure was deemed necessary I have preferred sutures through the fibro-periosteum adjoining the fracture, or a suture through the tendon of the triceps and a hole drilled transversely in the ulna below the fracture.

In a few cases of fibrous union with much separation and consequent disability operative measures, according to some of the various plans mentioned in Chapter VIII., have been undertaken to obtain closer union; and some surgeons have obtained good results by excising the fibrous band and wiring the fragments together.

B. Fractures of the Coronoid Process.⁴

This fracture, the frequency of which has been much disputed, is unquestionably very rare except as a complication of dislocation of the ulna backward.

So far as can be inferred from the few detailed descriptions of specimens the line of fracture crosses the process transversely or somewhat

¹ Quintin: *Centralblatt für Chirurgie*, 1881, p. 764.

² Pingaud: *Gazette Hebdomadaire*, May 21, 1875.

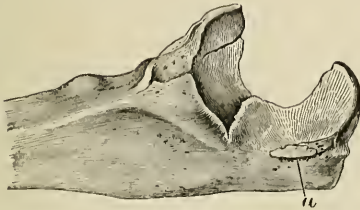
³ Lauenstein: *Centralblatt für Chirurgie*, 1881, p. 172.

⁴ The references to the specimens in the first edition are: Cooper, *Fractures and Dislocations*, p. 411; S. Cooper and Gibson, quoted by Hamilton; Velpeau, *Annales de la Chir.*, 1843, vol. ix. p. 98; Bérard, *Dict. de Méd.*, en 30 vols., art. Coude, p. 228; Gurlt, vol. i. p. 41; Bryant's *Surg.*, 3d Am. ed., vol. i. p. 837; two in Holmes's *System*, Am. ed., vol. i. pp. 859, 860; Annandale, *Medical Times and Gazette*, 1875, vol. i. p. 576, and *Edinburgh Medical Journal*, February, 1885, p. 681. For a personal case see the following section, *Fractures of the Head and Neck of the Radius*.

obliquely at about one-fourth of an inch below its apex, and may reunite with a close bony union or by a fibrous band. When the union is close and bony there may be a somewhat exuberant callus upon the anterior aspect of the process, due probably to the stripping up of the periosteum or tendon.

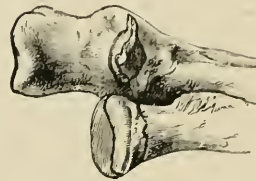The mechanism in the great majority of cases is by indirect violence exerted in such a way as to cause dislocation of the joint backward and to break off the point of the process as it is forced past the trochlea,

FIG. 153.



Fracture of the coronoid process of the right ulna. United with exuberant callus on the anterior surface, line of fracture still visible on the articular surface. *a*, a small fragment broken from the articular border of the olecranon and reunited. (GURLT.)

FIG. 154.



Fracture of the coronoid process and the head of the radius. (BRYANT.)

and in such cases there is also sometimes fracture of the anterior portion of the head of the radius. In one case mentioned by Lotzbeck¹ the process appeared to have been broken off by direct violence; a soldier was struck in the elbow by a piece of a shell which caused a severe contusion but no open wound. Two months afterward the coronoid process could be felt as a movable body, and by pressing it down it could be made to rub against the ulna with a creaking sound. Acupuncture proved the supposed fragment to be a hard solid body. In another case, that of a boy fourteen years old, the process was broken off by extreme flexion of the elbow. A somewhat similar personal experience may be mentioned as corroborative of this mechanism to a certain extent. I excised an elbow for suppurative disease of the joint, using Ollier's postero-lateral incision. In order to facilitate the cleaning of the external condyle, and before the olecranon had been touched, I asked the assistant to flex the elbow; he did so with some force, and felt something snap. About half an inch of the coronoid process was found to have been broken off. It seemed, however, to be unusually long and prominent, possibly by ossification of the attached capsule in consequence of the prolonged inflammation.

As regards experiment upon the cadaver we have the assertion of Malgaigne,² that in producing dislocations backward he broke off the end of the coronoid process quite frequently, and the more detailed results of Lotzbeck who fixed the elbow in a slightly flexed position by means of a gypsum bandage and then by striking upon the palm of the hand broke the coronoid process five times in ten attempts. Vary-

¹ Lotzbeck: Schmidt's Jahrbuch, 1866, vol. cxxix. p. 134.

² Malgaigne: Luxations, p. 634.

ing the experiment by extending the elbow completely he succeeded in producing the fracture only once.

The mechanism of this production and the anatomical relations of the process explain the union with slight displacement shown in some of the specimens and the difficulty of diagnosis during life. The tendon of the brachialis anticus is inserted not upon the top of the process but upon its anterior aspect and base, and the articular capsule is attached all along its edge. When it is broken off by being forced backward against the trochlea its connection with the ulna is preserved in front by the tough attachments of the tendon, and therefore instead of being displaced bodily along the anterior aspect of the bone it is probably only tilted forward. Its vitality is assured in any case by its connection with the capsule, and when the dislocation is reduced the fragment is held exactly in place by the tendon of the brachialis anticus in front and the humerus behind.

The symptoms and the means of diagnosis, in view of the uncertainty of the diagnosis in the supposed cases, cannot be positively described; those which have been deemed sufficient are: dislocation backward, easy reduction, great tendency to recurrence, possibly crepitus, and the presence of a hard movable body in front of the elbow in the line of the tendon of the brachialis anticus. In a personal case the supposed fragment could be readily grasped between the thumb and finger and moved freely to and fro.

Treatment. The treatment consists in immobilization of the joint flexed to a right angle or beyond. The degree of flexion and the completeness of the immobilization may vary with the tendency to displacement. If the latter is great, experience has shown that it is best opposed by increasing the flexion; and, of course, complete immobilization gives additional security. The immobilization should be maintained as long as the tendency to dislocation exists; when that ceases the splint becomes unnecessary, and the only indication then is to maintain sufficient flexion to favor prompt and close union.

C. Fractures of the Head of the Radius.

Our knowledge of this variety of fracture is drawn from about a score of specimens, old or recent, and a constantly increasing number of clinical cases supported by skiagrams. It has recently been studied by Thomas¹ in a paper admirable alike for its thoroughness of research and its soberness of judgment. Apparently the injury occurs quite frequently; Thomas collected 48 cases and found evidence of 55 others in skiagrams taken in Philadelphia. The line of fracture may separate a small portion of the head, about one-third, or a much larger portion passing down through the neck, or may split the head into two or more pieces and separate all of them from the shaft. Usually the fragments retain connection with the periosteum of the neck.

Cause. The cause may be a blow upon the head of the bone (Stimson, Cheyne, Delorme), or a wrench of the forearm, probably forced abduction (Stimson), or a fall on the palm, or the injury may occur as

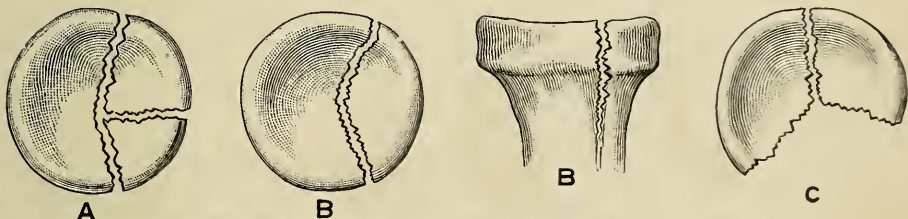
¹ Thomas: Univ. of Penn. Med. Bull., vol. 18, p. 184.

an incident of a backward dislocation of both bones of the forearm or of the head of the radius. The form of the fracture varies with the cause: fracture of a small portion of the head is the form seen in dislocation and in fracture by direct violence; the more extensive fractures—splitting of the head and complete separation from the shaft—are seen when the limb has been violently wrenched. I have seen five of the former—four in dislocation and one by direct violence—and three of the latter verified by arthrotomy and four probable cases observed clinically.

In the cases accompanying dislocation a small piece, comprising about one-third of the periphery, is broken off, probably the portion that is anterior when the head is forced past the capitellum. I have found it lying, after reduction of the dislocation, beneath the external epicondyle between the radius and the olecranon, and the portion of the head of the radius accessible to palpation did not comprise the gap left by the fracture. In one case the fragment had been displaced downward along the neck and had become attached, limiting rotation; I cut it away and covered the raw surfaces with silver foil, getting a good functional result.

In a case of fracture by direct violence (kick by a horse) Cheyne found the fragment in the same place and removed it, as he did also in another supposed to be by direct violence; in another Delorme recognized abnormal mobility of the undisplaced fragment and treated it by immobilization, obtaining complete restoration of function. In mine the patient did not come under observation until after suppuration of the joint had occurred; resection was done.

FIG. 155.



Fracture of head and neck of radius. A, first case: B, second case: C, third case; the portion corresponding to the gap was crushed.

My three certain cases of fracture by violence acting through the forearm resemble one another closely. In each the cause was a fall from a height, the arm being caught under the body. I imagine that the immediate cause was violent abduction of the forearm. Fig. 155 shows the lines of fracture. In the first, one of the two smaller fragments was displaced outward and backward, and a primary excision of the head and neck was done, with a good functional result. It was thought that the coronoid process also was broken. In the second there was no recognizable displacement at first, and I was not entirely certain of the character of the injury; after immobilization for four weeks the functional result seemed so likely to be bad that I opened the joint and removed the head and neck, finding the larger fragment

displaced angularly outward and backward and reunited with the shaft. In the third case there were two large pieces and a crush of the intermediate portion, also fracture of the coronoid process and slight displacement backward of the ulna. I saw the patient a month after the accident and removed the head of the radius. The cases are reported in detail in the references given above. In one case observed clinically (details in first edition) reunion followed, with a good functional result, notwithstanding a notable enlargement of the upper end of the radius; in the other rotation of the forearm was lost. I have also had a case in which the head of the radius was broken by a pistol-bullet entering from the outer side and above. I excised the head, and the functional result was good.

Two of Mutter's specimens and Helferich's show a small portion of the head broken off and reunited with displacement. In Pinner's the small fragment was eburnated but not reunited, and in Delorme's the fragment reunited with conservation of function.

These cases show that union is possible, even probable, after fracture of the neck or of the head; in my case in which suppuration followed the patient was a delicate strumous lad in whom any serious joint lesion would have been likely to have that result.

Diagnosis. The diagnosis after fracture of a small portion accompanying a dislocation or by direct violence is easy if the fragment is displaced to the position beside the olecranon which it has occupied in most of the reported cases, for it can then be readily palpated. Its removal is easy, and its loss appears to entail no disability. The loss of rotation observed in one case after removal was probably due to adhesions between the surface of fracture and the capsule.

In the cases of more extensive breaking the diagnosis is easy if there is enough displacement of the head to be recognized by palpation and if its separation from the shaft is shown by its failure to share in rotatory movements of the forearm. In my second case the head rotated with the shaft, and the only sign pointing to its fracture was an occasional click perceived during rotation of the forearm; there was also marked abnormal lateral mobility, especially adduction of the forearm, and sharp pain on abduction. If it cannot be felt, the diagnosis must be made by local tenderness on pressure, but probably the *x*-rays are needed for a positive recognition.

The proper treatment of this condition is not so clear; one of my cases regained good use of the joint without operation; another did the same after a primary excision; the others had all lost more or less rotation when first seen some weeks after the accident, and some of them much of flexion and extension; the removal of the fragment or of the entire head improved the condition. The results recently obtained by massage and immobilization in cases in which an early diagnosis was made are encouraging, but I doubt if small completely detached portions of the head should be left in; their reunion is not to be expected and their presence is always a danger. Of 18 cases of Thomas's collection in which the result is known there was good union without deformity in 3, with deformity in 5, non-union in 8, 1 bony and 1 fibrous ankylosis, and 2 with greatly impaired function.

PLATE XIV.



Fig. 1.—Fracture of the Head of the Radius.




Fig. 2.—Fracture of the Neck of the Radius.

PLATE XV.

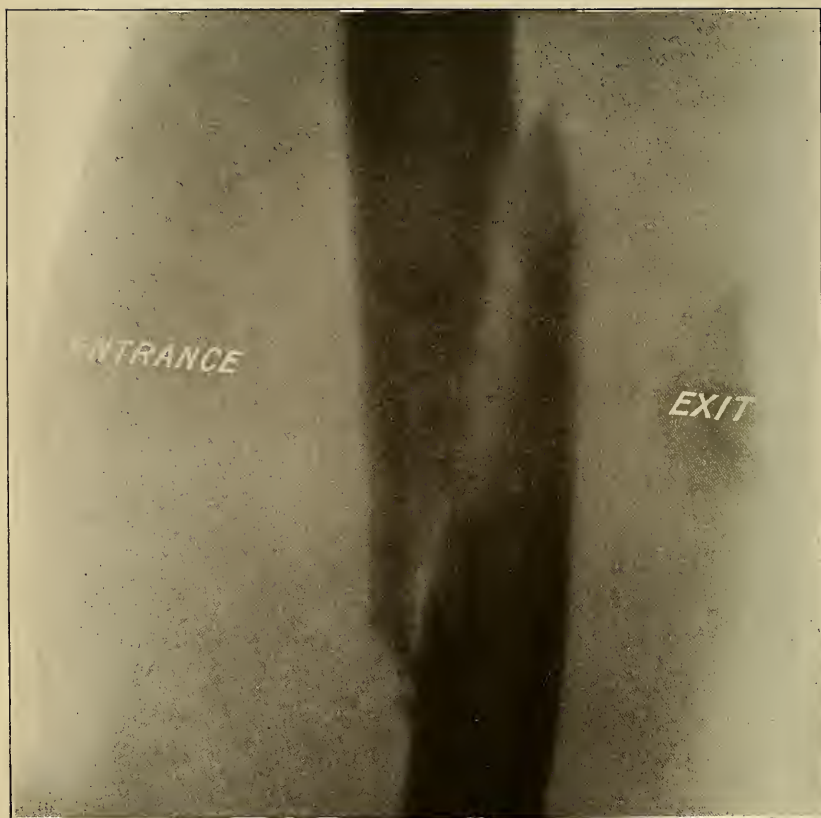

Fig. 1.—Fracture of Humerus by Small Bullet.



Fig. 2—Fracture of Forearm

D. Fractures of the Neck of the Radius.

This injury appears to be much less frequent than fracture of the head, although Mouchet¹ saw 11 cases in the course of two or three years, all in children under thirteen years of age. The known specimens are one of Mutter's, united with displacement, one each removed by Annandale, Douglas, Mouchet, and myself, and one found by Moullin on amputation. Moullin's² was a separation of the epiphysis. In several other cases the line of fracture has been shown by the *x*-rays (Plate XIV.). Mouchet's is shown in Fig. 156.

Mutter's specimen of fracture of the neck alone is without history of the cause or symptoms; in Annandale's the patient, a man forty years old, received a severe jar of the elbow by striking his wrist against his knee while shovelling. He did not seek treatment until six weeks later. After a month's immobilization the joint was opened; the head was found loose and the neck atrophied.

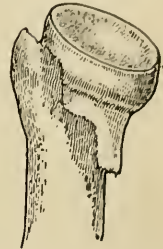
Dr. Richard Douglas, of Nashville, reported to me a case of fracture of the neck by a blow on the inner side of the forearm, verified by a late arthrotomy. A prominent feature was marked flattening of the inner side of the elbow, with extensive ecchymosis, which I attributed to avulsion of the flexor muscles in forced abduction of the forearm.

In November, 1902, I saw at the Hudson Street Hospital a man whose right elbow had been dislocated (and reduced) two days previously. The flexed forearm could be moved slightly backward and forward upon the arm, there was a gap below the capitellum, and the head of the radius could be plainly felt in the flexure of the joint. I exposed the joint by an external incision and removed the head of the radius, which had been broken off by a fracture through the neck. The coronoid was broken at its base.

The line is transverse or somewhat oblique, and the proximal fragment usually has an angular displacement, the angle opening outward and backward. The mode of production has varied greatly—a fall on the hand, a blow on either side of the forearm, a wrench of the forearm, a crush of the elbow in a machine. Definite diagnostic features are not known beyond pain at the site of fracture and especially on attempting supination (Mouchet). Here, too, the *x*-rays will probably be the final arbiter in doubtful cases.

Mouchet's 9 fresh cases recovered with good function after treatment by massage and mobilization. Adults have not done so well, and late excision may be required to improve function.

FIG. 156.



Fracture of neck of radius. (MOUCHET.)

¹ Mouchet: *Revue de Chir.*, vol. 21, p. 596.

² Moullin: *Trans. Path. Soc. London*, vol. 39, p. 242.

2. FRACTURES OF THE SHAFT.

A. Fractures of the Shafts of Both Bones.

The relative frequency of fracture of both bones may be seen by reference to the table in Chapter I. It occurs rarely in the upper third and with about equal frequency in the middle and lower thirds. Usually the radius is broken nearer the elbow than the ulna.

Cause. The cause may be direct or indirect violence or muscular action, a fall upon the hand, or the bending of the forearm across some object, or by a transverse blow.

Only a few instances of fracture by muscular action have been recorded, and even in those there was a contributing external force, such as shovelling or rising upon the hand in bed.

Partial or incomplete fractures—"green-stick fractures"—are, according to Malgaigne, more common in the forearm than elsewhere, and are usually due to a fall upon the hand.

Displacements. The displacements are of the usual kinds: overriding in oblique fractures, lateral with or without overriding in the transverse fractures, and angular displacement of one or both bones in both forms. Rotatory displacement of the radius alone, especially when it is broken above the insertion of the pronator teres, was first pointed out apparently by Lonsdale. He suggested that the upper fragment might be strongly supinated by the biceps, while the lower fragment was kept in the usual semi-prone position, and he thought this might be a cause of the inability to supinate the hand completely sometimes observed after fracture. Flower and Hulke¹ say they have found proof of the correctness of this conjecture in the examination of numerous specimens of united fracture of the radius, "in a great number of which the lower fragment was much less supinated than the upper," and Agnew says there are similar specimens in the collections of the College of Physicians and the University of Pennsylvania. Mr. Callender² examined eighteen specimens of united fracture of the shaft of the radius in the London museums, and found in fifteen of them rotatory displacement averaging 36 degrees, the extremes being 6 degrees and 64 degrees. The displacement in every case was that pointed out by Lonsdale, supination of the upper fragment. The agency of this rotatory displacement—supination of the upper fragment—in preventing full supination of the lower segment after healing appears much more likely to be efficient in fractures below the insertion of the pronator radii teres, for that muscle is the main opponent of the exaggerated supination of the upper fragment which would then be necessary to the full supination of the lower.

In angular displacement one bone may be bent while the other remains nearly straight, possibly with overriding, or the fragments of both bones may be inclined in the same direction, forward, backward,

¹ Hulke: Holmes's System of Surgery, Am. ed., vol. i. p. 860.

² Callender: St. Bartholomew's Hospital Reports, vol. i., 1865, p. 297.

PLATE XVI.



Fig. 1—Fracture of Radius; marked Angular Displacement.

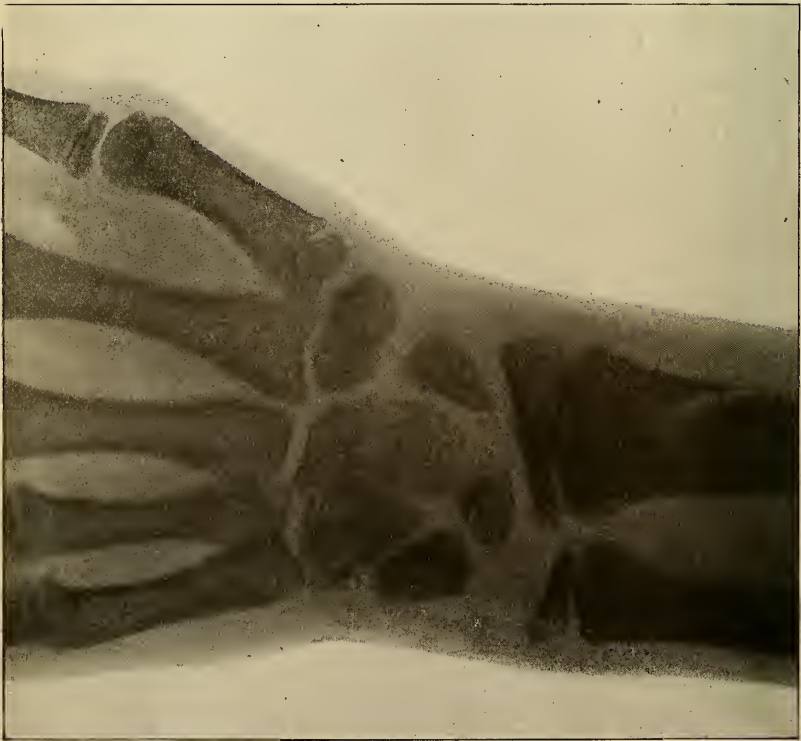

Fig 2 —Recent Colles's Fracture in a Boy Twelve Years Old, showing Epiphyses.

or to either side, or there may be lateral inclination in opposite directions, each bone being inclined toward the other; and if the fractures are at the same level the four ends may thus be brought into contact, and the possibility created of a union that will abolish the power of rotation of the limb. Such faulty union of the two bones is, however, very rare. Overriding of the fragments has been observed to a distance of more than three inches (eight centimetres).

Symptoms. The symptoms are the usual ones of fracture: pain, deformity, abnormal mobility, crepitus, and loss of power.

The *course* is usually simple and the *prognosis* favorable, but both may be gravely modified by laceration or bruising of the soft parts or by the occurrence of acute inflammatory reaction or of gangrene, and in addition the prognosis may be made unfavorable by an irreducible displacement or comminution or loss of substance of one of the bones. Displacement affects the prognosis when it increases the chances that union may take place between the two bones, and comminution or loss of substance by favoring the occurrence of pseudarthrosis.

In simple cases without marked displacement or complication complete union may be expected in a month, but in no other limb do inflammatory complications and gangrene occur so frequently, even under prudent treatment. The gangrene may be limited to points where the splints have made pressure or to portions of the hand and fingers, but it is very likely to involve the entire member if it is overlooked at the beginning or not effectively combated. Diffuse phlegmonous inflammation of the forearm may follow severe bruising of the soft parts or may even take its rise in the fracture. Its importance lies in the danger to the life and limb which follows the burrowing of the pus, the opening which it necessitates, and the matting together of the tendons and their sheaths.

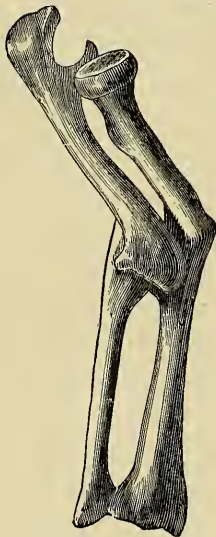
Ischæmic contraction of the muscles (p. 69) is of especial importance because of its marked interference with the usefulness of the hand.

The cause of gangrene in many cases and of ischæmic contraction has been pressure exerted by splints or bandages, and the necessity for caution and watchfulness to avoid this accident cannot be urged too strongly. The practice of applying a roller bandage to the limb under the splints is extremely dangerous, and so also is the use of splints of soft material, pasteboard and the like, which take the shape of the limb and are fastened to it with a roller bandage. There is the same compression, the same chance of strangulation in this case as when the roller is applied directly to the skin. It is not safe to depend upon the sensations of the patient, upon pain, to give warning of threatening strangulation; cases, in both old and young, have been reported in which total gangrene of the distal portion of the limb has occurred without attracting the attention of the patient or his attendants by any symptoms except the final change in the color of the exposed fingers.

The persistence of angular displacement of both bones, or, to a less degree, of the radius alone, affects the prognosis by its interference with rotation. In rotation only the radius moves, and its

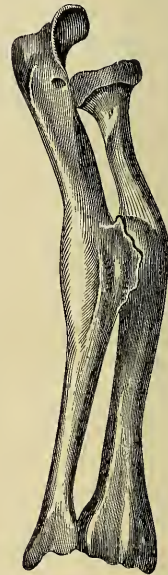movement is about an axis running from its upper end to the lower end of the ulna, so that in full pronation the radius crosses the ulna obliquely, and in supination is parallel to it and at its maximum distance from it at the centre. If now the bones are bent, say in the middle third, the radius of rotation of the radius at the apex of the angle is correspondingly increased, and this angle must, therefore, move to a greater distance from the ulna than normal in supination; such a movement is prevented by the interosseous membrane, and rotation is correspondingly diminished. This is the most frequent cause of diminution or loss of rotation after fracture. The marked dis-

FIG. 157.



Fracture of the forearm, angular displacement, and union between the bones.

FIG. 158.



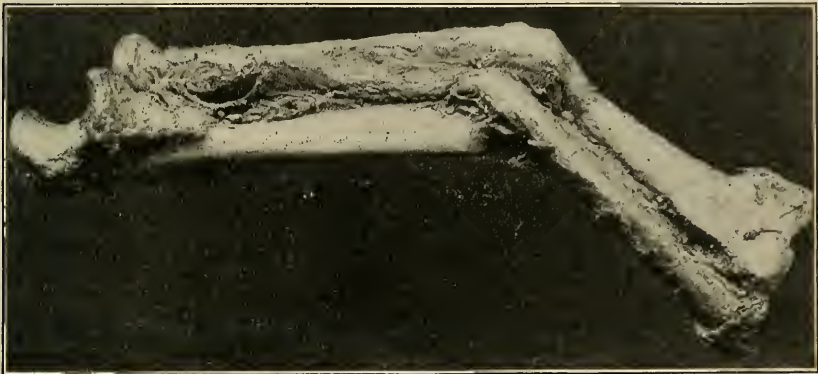
Fracture of the forearm, with formation of a lateral joint.

placement of the radius in the case represented in Plate XVI., fig. 1, caused the loss of only half of the rotation.

The possibility of union between the bones as well as the fragments, though rare, should also be borne in mind. Its occurrence is more likely when the natural interval between them is destroyed or diminished by displacement, but this approximation is not essential. Excessive formation of callus, in consequence of laceration of the intermediate tissues and irritation, especially of the interosseous membrane, is sufficient in itself to produce this result so destructive of the usefulness of the limb. The occurrence is favored also by correspondence in the position of the fractures, for the fragments are more likely to fall into abnormal contact with each other, and the granulations which form the callus about each fracture may easily unite if each spreads over only half the intermediate space (Fig. 157). It has occasionally happened

that the two calluses have come into contact and formed a lateral joint (Fig. 158), instead of uniting. Slight inclination of the hand to one side or the other is a not infrequent result and may be due to the position of the sling in which the arm is supported; thus, if the weight of the arm is borne upon the sling at or above the point of fracture the unsupported hand drops downward and the lower fragment deviates toward the ulnar side, as in the figures; while if the sling passes under the hand or wrist and leaves the forearm unsupported the latter sinks down between the wrist and elbow and the lower fragment deviates in the opposite direction toward the radial side.

FIG. 159.



Fracture of the forearm; union with angular displacement. No union between the two bones.

Delay or failure of union of either or both bones is not very uncommon, especially of the radius, and cases are reported in which the union of one of the bones has been delayed four or five months, and has then taken place without operative aid.

Treatment. Reduction must be effected, when necessary, by extension and counter-extension aided by cautious pressure upon the bones near the seat of fracture. The importance of reduction is exceptionally great, because of the special function of rotation of the forearm which may be so easily destroyed by displacement or failure of union. I have once or twice found it necessary to cut down upon the fracture because I could not otherwise correct the displacement, the fragments being so placed after oblique fracture that the surfaces of fracture were separated from each other by the entire thickness of the bone and the fragments were in contact only by surfaces covered with periosteum. Overriding is to be overcome by traction; the forearm and fingers are flexed, counter-extension is made by an assistant who grasps the arm close above the elbow, and traction by the surgeon himself or another assistant grasping the hand. If there is angular displacement the traction should be first made in the direction of the lower fragment, and when this is thought to be sufficient, and while it is still maintained, the lower segment of the limb is brought into line with the upper one, the latter being steadied by the hand of the surgeon or press-

ure being made upon the projecting angle with the thumbs. This pressure may be safely made if the angle is directed forward or backward, but it must be used with great caution when the angle is lateral, for there is danger that it may force the bone upon which it is made too near its fellow, and that when the manœuvre is completed the position of the fragments may resemble that of the arms of an X, each pair being displaced angularly toward the other. To avoid this result the hand should be supinated while the reduction is making, because in this position the interval between the bones at the centre of the limb is greatest and most accessible, and the surgeon should seek to force or keep the fragments apart by pressing his thumbs in between them in front and his fingers behind.

The position in which the forearm is usually kept during treatment is that which is midway between pronation and supination. It is the one which the limb naturally assumes when it is suspended beside the body with the elbow bent at a right angle and is the one which is borne with the least fatigue and discomfort. But while this position meets the indications sufficiently in the simple and, indeed, in most cases, it was long since recognized by some surgeons that the bones of the forearm are normally separated most widely from each other at the centre when the limb is supinated, and that consequently this position is the one in which the arm should be kept whenever there appears to be danger of the bones uniting with each other. According to Malgaigne, fractures of the forearm were treated in the supine position by the contemporaries of Hippocrates, but the practice was condemned by that writer; it was reinvented by Paré, and abandoned by him when he learned that Hippocrates had disapproved of it, a yielding to authority that seems to have been unusual with that vigorous-minded surgeon, and again reinvented by Malgaigne, who afterward learned that Lonsdale had preceded him by a few years. Lonsdale¹ recommended the position for a reason mentioned above, the difference between the degree of supination of the upper fragment of the radius and that of its lower fragment; Malgaigne recommended it because of the greater distance between the centres of the bones when they are in this position.

The difficulty which Lonsdale sought to avoid, supination of the upper fragment, appears not to have much importance when the fracture of the radius is above the insertion of the pronator radii teres and to be rare when it is below it; that which Malgaigne had in mind—possible union of the two bones—is rare even when the two bones are broken at the same level. The principal faults to be avoided are angular displacement and overriding, and so far as these are concerned the attitude of pronation or supination seems to be indifferent. The objection to the attitude of supination is its greater constraint and inconvenience; if the attitude is desirable the discomfort can be avoided by confinement to bed with the arm abducted and the elbow flexed at a right angle, in which position the forearm rests easily in full supination.

A common method of treatment is to fix the limb between two light

¹ Lonsdale: London Medical Gazette, 1832, vol. ix. p. 910.

wooden splints broad enough to overlap it slightly when applied to the palmar and dorsal surfaces. The palmar splint should extend from the fold of the elbow to the roots of the fingers, the dorsal one should be shorter and not reach beyond the wrist. Each splint should be padded with cotton, and patients usually find it agreeable to have the end corresponding to the palm of the hand very thickly padded, or a small

FIG. 160.



Moulded plaster splint for fracture of forearm.

roll of bandage fastened obliquely to it so that the fingers can close easily over it.

In simple cases uncomplicated by threatening displacement, the splints are applied to the semi-pronated limb and fastened by two strips of adhesive plaster wrapped about them, one near the elbow, the other at the wrist, the hand is made fast to the palmar splint by a few turns of a bandage, and the limb is placed in a sling that supports both the elbow and hand.

The limb should be frequently inspected at first in order to guard against excessive pressure either by bandages too tightly applied at first, or made too tight by the swelling of the parts, and the splints should be removed in the second week to detect and remedy any new displacement.

A roller bandage should not be applied to the limb under the splints; it exposes to displacement by pressing the bones toward each other, and to gangrene or ischæmic contraction by constriction. The complete plaster-of-Paris dressing is objectionable for the same reasons during the first few days, but it or moulded plaster splints including the lower portion of the arm may be used after the first week if care is taken not to make lateral pressure.

Anterior and posterior splints immobilize the limb sufficiently to meet every indication except that of opposing the tonicity of the muscles and the occurrence of overriding. When the lines of fracture are transverse or toothed the bones themselves afford sufficient protection, and in any case flexion of the elbow relaxes many of the muscles and diminishes the risk, which, moreover, is not a great one.

A moulded plaster-of-Paris splint dressing, much used at the Hudson Street Hospital, especially in the young, is shown in Fig. 160. As it extends above the elbow it efficiently opposes shortening if traction is maintained while the plaster hardens.

In compound fractures great caution should be used in removing fragments or excising portions of bone, lest failure of union should follow. If the extent and position of the wound are such that efficient splints cannot be used at first, the patient should be kept in bed with the arm abducted and the elbow flexed, and traction, elastic or by weight, made by means of adhesive plaster attached to the hand and wrist. Counter-extension can be made from the lower part of the arm by a broad bandage, the limb being meanwhile supported upon cushions or suspended, and preferably steadied by a splint placed outside the dressings of the wound.

B. Fracture of the Shaft of the Ulna.

Fractures of the shaft of the ulna alone are almost invariably the result of direct violence, of a blow received upon the arm while it is raised to protect the head, or of a fall upon the ulnar side of the forearm.

Displacement. Displacement may be entirely absent, and when present may be in any direction. Its extent and direction seem to depend almost entirely upon the fracturing force. Most recent writers, following the example of Pouteau,¹ have alleged that the broad articulation of the ulna with the humerus prevented lateral displacement of the upper fragment, and that the lower fragment was therefore the only one that could be displaced toward the radius. Even if the articulation was absolutely free from lateral mobility, the inference that has been thus drawn would not be correct, because the radius can be moved toward the ulna after fracture of the latter and thus the exact equivalent of the displacement of the ulna toward the radius produced. The only muscle which acts directly upon the lower fragment is the pronator quadratus, the tendency of which is to draw it toward the radius.

Symptoms. The symptoms may be limited to pain and swelling at the seat of fracture, and if their significance should be rendered obscure by the history and the effect upon the soft parts of the direct violence

¹ Pouteau : Œuvres posthumes, 1783, vol. ii. p. 258.

which has caused the fracture, the doubt can be removed by noting that pain at that point is aroused by the effort actively to extend the elbow against opposition. If the radius remains entire and is not dislocated at either end, there can be no shortening of the limb, no overriding of the fragments, and displacement, if present, must be recognized by following the outline of the bone with the finger. Crepitus and abnormal mobility may be obtained by grasping the limb above and below the fracture and making pressure alternately upon the fragments with the fingers, or by seizing the fragments between the thumb and fingers and moving them forward and backward upon each other.

An important and not infrequent complication is dislocation of the head of the radius forward; it should always be suspected when there is marked displacement of the fragments of the ulna or unusual swelling at the elbow.

FIG. 161.



Fracture of ulna, with dislocation of head of radius forward.

The prognosis is good as regards repair and preservation of function.

Reduction. Reduction can be made only by appropriate pressure upon the displaced fragments, traction being practically without value. The displacement which it is most important to overcome is the lateral one toward the radius, and that should be met in the same way as after fracture of both bones, that is, by pressing the thumb and fingers in between the bones.

As the radius acts as a splint to prevent overriding of the fragments the surgeon's chief care is to secure immobility and prevent lateral or angular displacement. This can be done by the anterior and posterior splints used in fracture of both bones, or by a rectangular splint fastened against the inner side of the arm and semi-pronated forearm, or by a moulded plaster splint. In some cases it may be necessary to keep the forearm supinated, and in others the bruising of the soft parts

may be so severe as to forbid the use of splints at first. The arm should be kept in a sling and the same precautions should be taken to avoid undue pressure by the sling upon the ulna as when both bones have been broken. A pasteboard, felt, or plaster gutter may be used to avoid this danger.

C. Fracture of the Shaft of the Radius.

As far as can be judged from general impressions and statistics that are somewhat scanty, isolated fracture of the shaft of the radius is less frequent than that of the ulna, and appears also to be generally caused by direct violence, sometimes by a fall upon the hand. In three cases reported by Falkson¹ fracture in the middle third with angular displacement forward was caused by pressure along its longitudinal axis, the palm of the hand in dorsal flexion and the back of the elbow having been caught between heavy objects which were approaching each other. Occasionally it has been broken by muscular action—forcible rotation.

Displacements. The displacements vary somewhat with the seat of fracture, the causes being the fracturing force and the action of the biceps and pronator muscles. The more common displacement appears to be an angular one, the apex of the angle directed forward and inward. Plate XVI. represents an extreme form.

The possible loss of supination in consequence of union with a rotatory displacement, the upper fragment being completely supinated by the biceps while the lower is kept partly pronated by the dressings, which was pointed out by Lonsdale, and has been spoken of in the section on fracture of both bones, is also to be borne in mind after fracture of the radius alone, especially if the seat of fracture is above the insertion of the pronator teres, and is to be met, if at all, in the same manner, that is, by keeping the forearm supinated, but it does not appear to interfere noticeably with function.

If the fracture is at or below the middle of the bone the tendency of the biceps and pronator teres is to draw the lower end of the upper fragment forward and inward, and that of the pronator quadratus and supinator longus is to draw the upper end of the lower fragment toward the ulna.

Overriding has been observed only when dislocation of the lower end of the ulna was associated with the fracture.

Diagnosis. The diagnosis is made by recognition of the displacement, if it exists, of crepitus and abnormal mobility obtained by grasping the fragments with either hand and moving them upon each other or by placing a thumb upon the head of the radius and rotating the wrist gently.

Treatment. The indications for treatment are the same as after fracture of both bones, except so far as the uninjured ulna may be utilized as a splint or as its dislocation may require more or less prolonged traction. If displacement exists the fragments should be pressed back into place as before described, and if the fracture is low down and the lower fragment is inclined toward the ulna it will perhaps be

¹ Falkson : Centralblatt für Chirurgie, 1885, p. 913.

found easier to bring it back into line by drawing the hand forcibly downward and toward the ulnar side than by pressing the fingers in between the bones. Traction at the wrist and elbow may be required to overcome dislocation of the lower fragment upward from the ulna.

The arm should be secured upon well-padded anterior and posterior wooden or moulded splints in the semi-pronated position. Dislocation at the lower radio-ulnar articulation or change in the direction of the lower articular surface of the radius may make it desirable to use a moulded splint that will include the hand and perhaps the lower part of the arm, or a long rectangular one for the purpose of extension and counter-extension, or to keep the hand inclined toward the ulnar side.

3. FRACTURES IN THE VICINITY OF THE WRIST.

A. Fractures of the Radius. Colles's Fracture.

Under this term are included fractures of the radius near the wrist, which, while differing from each other in many respects, have in common a characteristic deformity, and often a certain difficulty in making reduction.

Next after the ribs the lower end of the radius is the part of the skeleton most frequently broken. While the fracture occurs at all ages, it is most frequent in the elderly. It is very remarkable, and worthy of mention as a proof of the difficulty of diagnosis in fractures near a joint, as well as of the force of authority and tradition, that the real nature of this common injury which comes so frequently under the notice of all surgeons should not have been recognized, and that it should have been taken almost always for a dislocation of the wrist backward, until about one hundred years ago. The first mention of the injury as a fracture is generally attributed to J. L. Petit, but, I think, incorrectly, for I find no reference to it in his chapter on fractures, while the chapter on dislocation of the wrist contains a very good clinical description of it.

Pouteau¹ is the first author to describe it as a fracture and to point out the previous universal error in diagnosis. He describes its pathology, attributes its production to the violent contraction of the pronators, and gives its symptoms and treatment, adding that there is, perhaps, no fracture so easy to recognize at a glance. The fact that he includes in his description fractures of both bones does not, I think, diminish the credit due him for his recognition of the error of his predecessors and contemporaries. His view of the subject does not appear to have commended itself to his immediate successors, and, during the thirty years following its publication, only an occasional mention is made of even the possibility of such a lesion, and the common injury was still deemed a dislocation.

The next writer upon the subject failed in like manner to impress his opinion upon his immediate contemporaries, and although justice was ultimately done him, and the fracture is now known widely by his name, the recognition did not come until after his death. Mr. Colles

¹ Pouteau: Œuvres posthumes, 1783, vol. ii. p. 251.

published his brief but accurate account of the fracture in 1814,¹ but Dr. R. W. Smith, writing in 1847,² says: "Subsequent authors have repeated what Mr. Colles had said upward of thirty years since, but no writer (as far as I have been able to ascertain), not even the distinguished author of the *Surgical Dictionary*, has alluded to his account of the injury."

Sir Astley Cooper, in the second edition of his *Dislocations and Fractures of the Joints*, published in 1823, describes fracture of the lower end of the radius, and adds that he had seen this injury frequently, but did not understand its nature until taught by dissection; but he describes at the same time dislocation of the wrist, and evidently did not appreciate the full character and frequency of the fracture. In a subsequent edition he describes experiments made by himself upon the cadaver in 1833, in which he produced the fracture by hyperextension (extreme dorsal flexion) of the hand. The same failure to appreciate the character of the common injury which was coming so frequently under the care of every surgeon persisted, notwithstanding the publications of Pouteau and Colles, that of the former being entirely overlooked apparently, and that of the latter remembered only by the Dublin surgeons, who believed in the fracture and gave his name to it. But the misapprehension was not destined to last long; the great change which took place in the science of medicine at the beginning of the present century under the inspiration and guidance of the French physicians, the substitution of objective knowledge for dogma, of clinical and dead-house observation for pure speculation, made short work of this error. Dupuytren was the first to call attention to it and to impress it upon the profession; a post-mortem examination in 1820 showed him the real character of the injury, and his hospital service gave him the clinical opportunities that were needed for study and demonstration. A short period of doubt followed, and then, about 1830, the fact was universally accepted, and the second stage—that of discussion of details, which has lasted until the present time—was entered upon.

Mr. Colles, who had never had an opportunity to dissect a specimen of the fracture, speaks only of the symptoms and treatment. His only statement concerning the fracture itself is an incorrect one: "This fracture takes place at about an inch and a half above the carpal extremity of the radius." We now know that, while the line of fracture may lie at the point he mentioned, it is usually much lower, and is often associated with comminution of the lower fragment. "The average distance is differently estimated, possibly because some have measured from the articular edge of the bone and others from the styloid process; but the weight of testimony places it at from one-third to three-fourths of an inch above the articular border. In the young it sometimes follows the epiphyseal line. Its direction is usually transverse, but it may be oblique laterally or antero-posteriorly, and the lower fragment is often comminuted. The lower fragment is sometimes displaced bodily backward without crushing, as in Figs. 162 and

¹ Colles: *Edinburgh Med. and Surg. Journal*, April, 1814, vol. x. p. 182.

² R. W. Smith: "Fractures in the Vicinity of Joints," *Am. ed.*, p. 129.

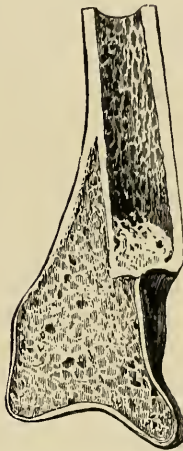163, but the displacement appears more often to be almost entirely angular, the lower fragment turning upon its anterior edge as upon a

FIG. 162.



Fracture of the lower end of the radius. Displacement backward. (R. W. SMITH.)

FIG. 163.



Fracture of the lower end of the radius. Displacement of lower fragment backward. (R. W. SMITH.)

FIG. 164.



Fracture of the lower end of the radius. Angular displacement of the lower fragment backward with impaction. (R. W. SMITH.)

hinge, crushing or penetration with impaction taking place posteriorly and outwardly, and the articulating surface looking downward and backward instead of downward and forward as it does normally; at the same time the styloid process rises to a higher level. An extreme example of this displacement, with union, is shown in Fig. 164. Sometimes the styloid process of the ulna is broken off, apparently by avulsion through the lateral ligament or possibly the fibro-cartilage. Some authors have noted this complication in more than half of their cases; it has appeared in less than 10 per cent. of my skiagrams.

Specimens of recent fracture are not very common, and many of those we possess are open to the objection that the fractures have been caused by violence far in excess of that which causes the great majority of the fractures met with clinically, the patients having falling from a considerable height, and having received other injuries that caused death within a short time thereafter. Others are obtained from elderly patients who have received the fracture in the usual manner, that is, by a fall upon the ground while walking, and have then died in a few days of an intercurrent affection, usually pneumonia.

The Röntgen rays have recently added to our knowledge of the details, showing that the surface of fracture is rarely flat and transverse, that comminution or splitting of the lower fragment is frequent even in early adult life, and that the displacement backward of the fragment is not commonly so marked as has been supposed from the appearance of the limb. They confirm the opinion that the radial side

of the bone is shortened and show that the carpus preserves its relations with the articular surface of the radius, passing slightly upward toward the radial side of the ulna and thus making the latter prominent. In marked backward displacement the ulna accompanies the fragment.

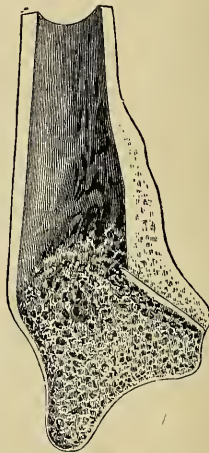The figures of Plates XVI.–XXII. show the different levels at which the fracture occurs, the frequency and character of the comminution, the differences in dorsal displacement, and the marked dorsal projection of the first row of the carpus in one. Plate XXIII., fig. 1, shows arrest of growth after fracture at the age of twelve years, the patient being nineteen years old when the picture was taken. Plate XXIV. shows the normal wrist in the adult male and female; the notably lower position of the articular surface of the radius as compared

FIG. 165.



United fracture of the radius. (R. W. SMITH.)

FIG. 166.



Recently united fracture of the lower end of the radius. (R. W. SMITH.)

with that of the ulna in the female was found in most of the female cases examined.

In specimens obtained after repair has taken place without reduction of the displacement the penetration of the posterior portion appears very marked (Fig. 165), often more so than it really is. The appearance is due in part to the formation of callus upon the posterior face of the upper fragment under the periosteum which is stripped up, the "periosteal bridge," which is so often found at one side of a fracture, and in part to condensation of the spongy tissues during repair.

Among the lesions that may be associated with the principal fracture are fracture of the ulna near its lower end, fracture of the styloid process of the ulna, rupture of the radio-ulnar and intra-articular ligaments, and perforation of the skin by the ulna. The first is rare, and all the others are the consequence of the momentary prolongation of the action or variation in the degree of the fracturing force. The Röntgen rays show the fracture only occasionally, and then only as the breaking off of the tip of the process, so that I think it probable that the more extensive injuries heretofore noted were in cases charac-

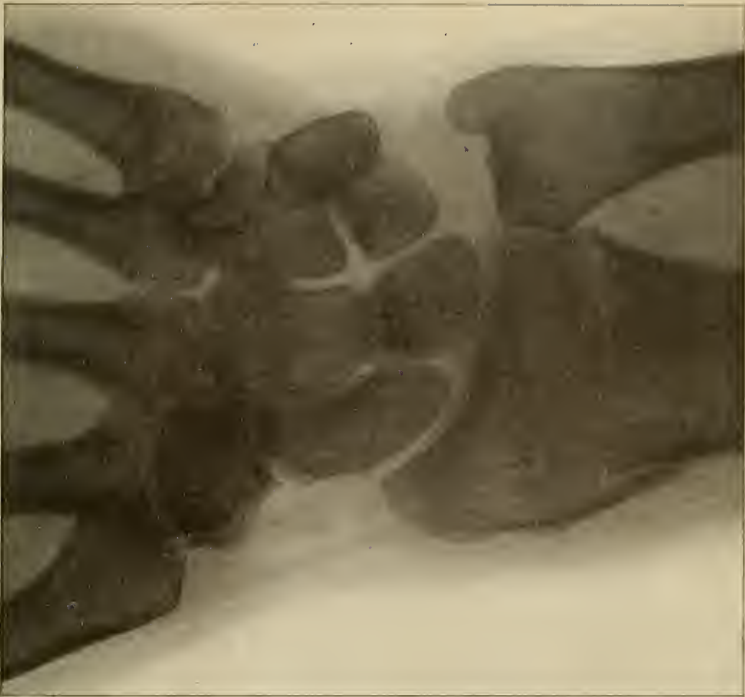

Fig. 1 —Recent Colles's Fracture ; Male, Twenty-two Years.
Same as Plate XXI., Fig. 1.

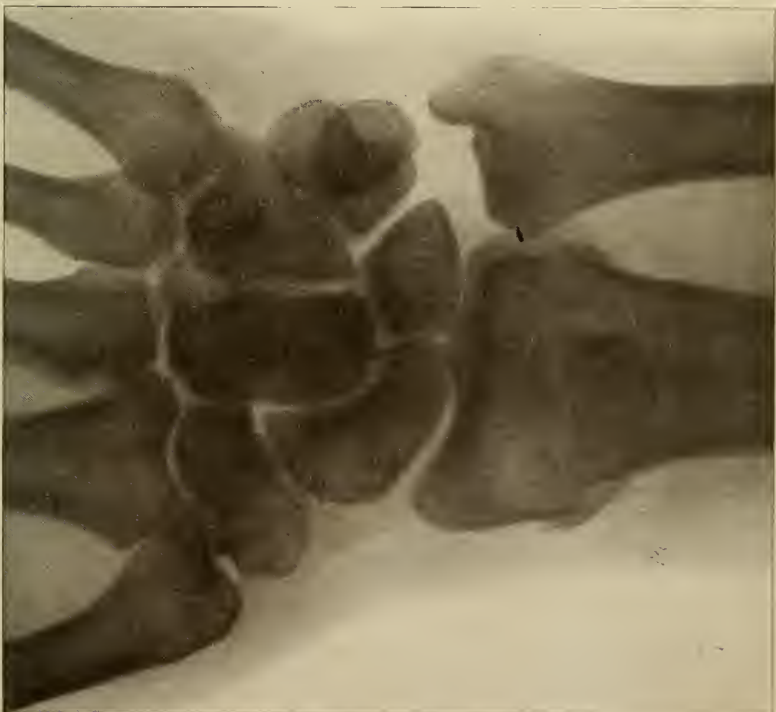

Fig. 2.—Old Colles's Fracture.

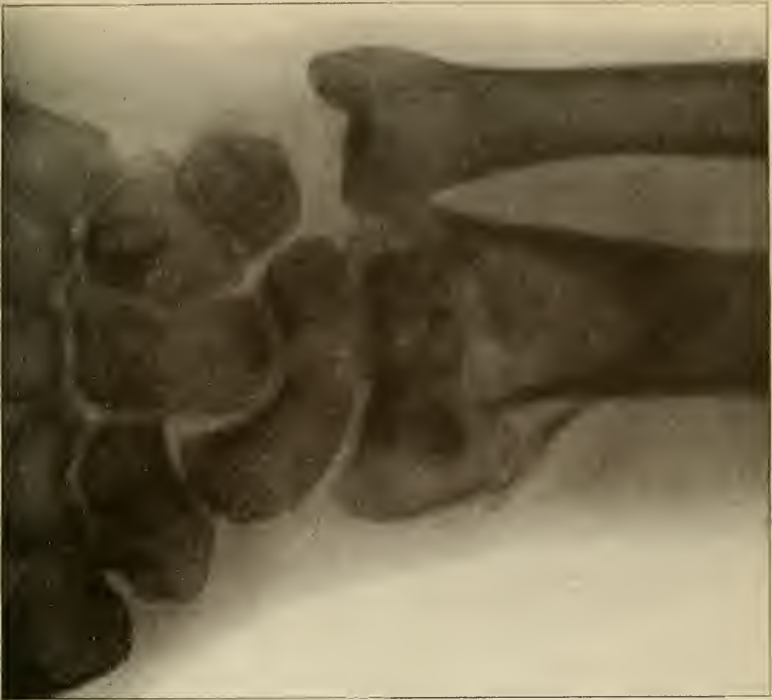

Fig. 1.—Recent Colles's Fracture; Comminution; Male, Forty-five Years.

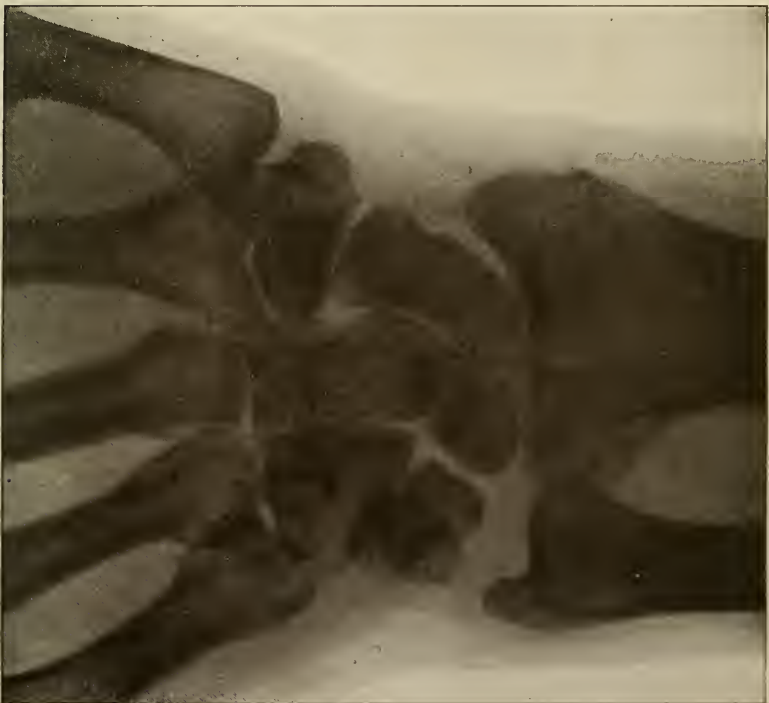

Fig. 2.—Recent Colles's Fracture; Comminution; Male, Forty Years.
See also Plate XXI., Fig. 2.

PLATE XIX.



Fig. 1.—Recent Colles's Fracture; Male, Twenty-six Years. Fall from a height of four feet.



Fig. 2.—Same as Fig. 1. Side view.



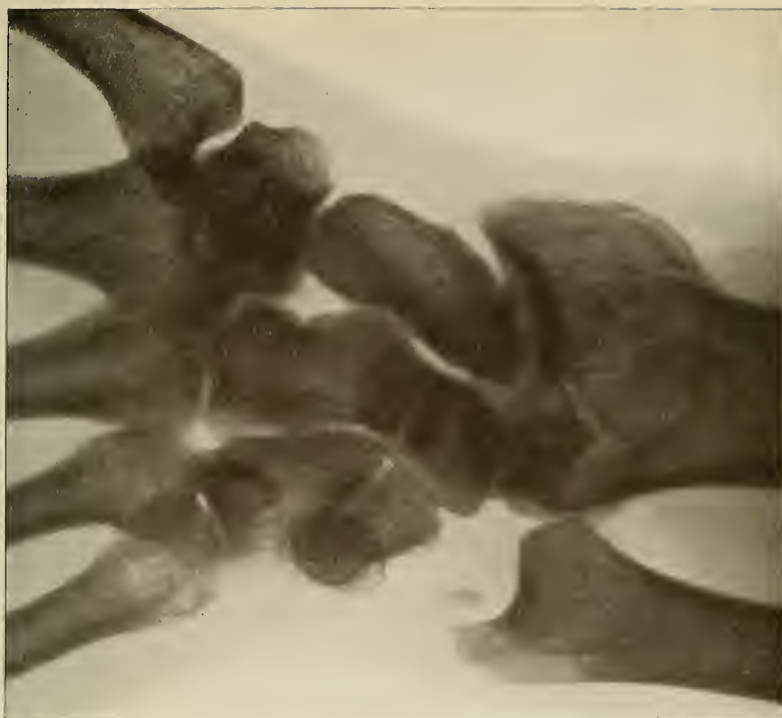

Fig 1. Same as Plate XIX. After reduction

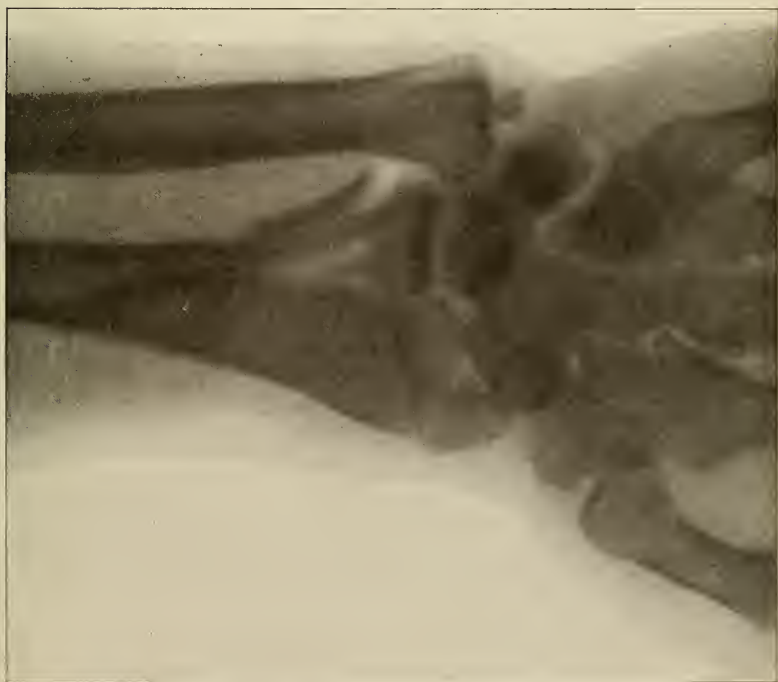

Fig. 2 - Recent Colles's Fracture; Male, Fifty-six Years.
Fall from a height.

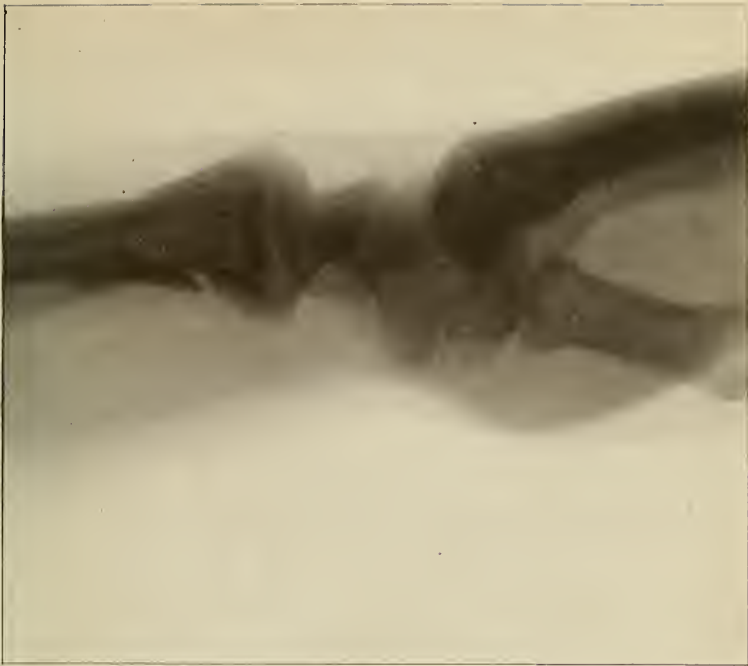
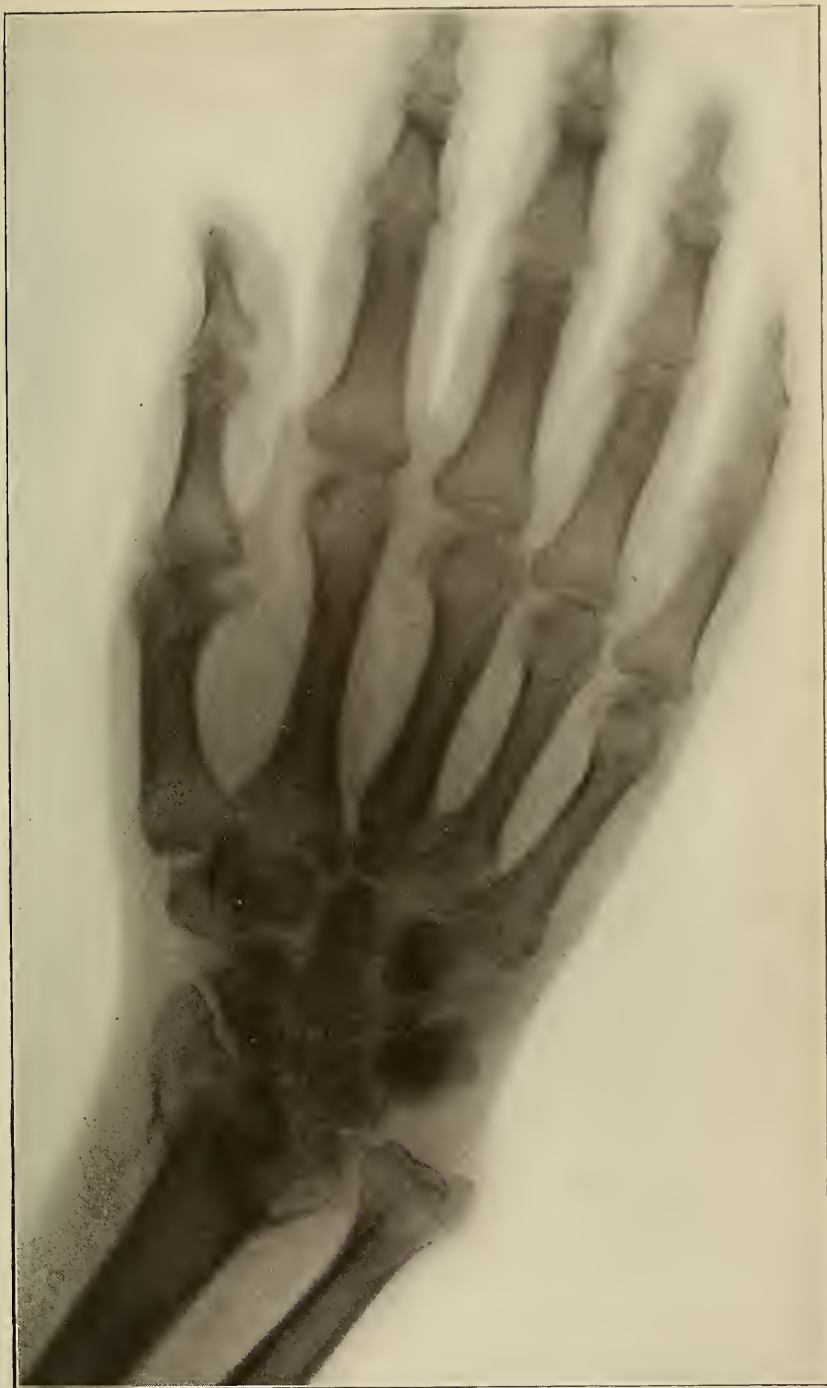
Fig. 1.—Recent Colles's Fracture; Male, Twenty-two Years.
Same as Plate XVII., Fig. 1.



Fig. 2.—Recent Colles's Fracture: Male, Forty Years.
Same as Plate XVIII., Fig. 2.



Comminuted Colles's Fracture.

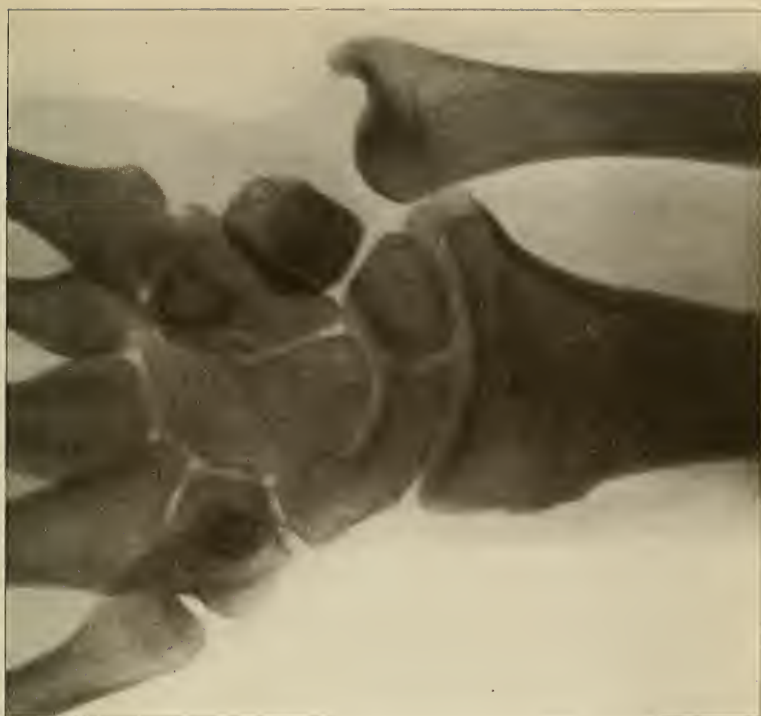

Fig. 1.—Arrest of Growth of Radius after Colles's Fracture at age of Twelve Years. Present age, nineteen years.

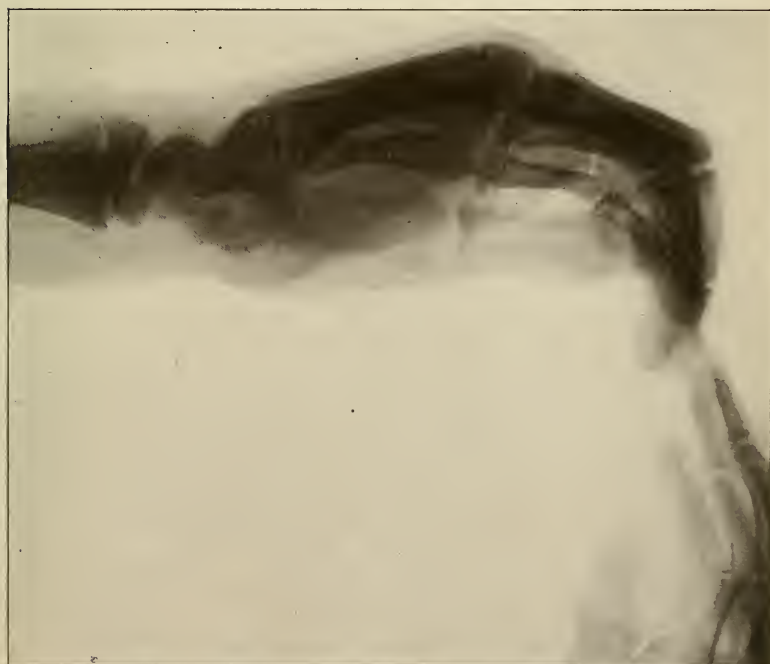

Fig 2.—Separation of Radial Epiphysis; Boy, Fifteen Years.

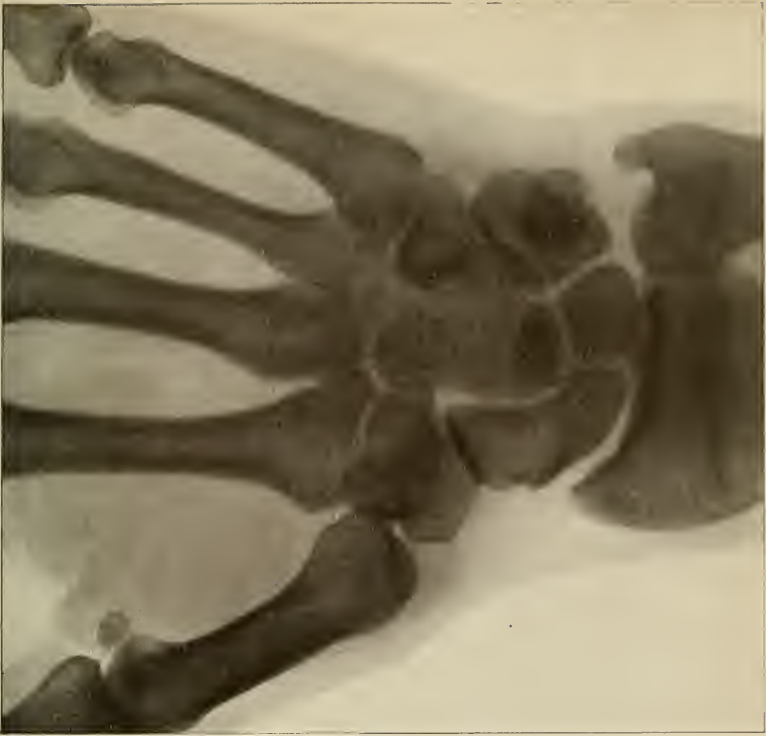

Fig. 1.—Normal Wrist; Adult Male.

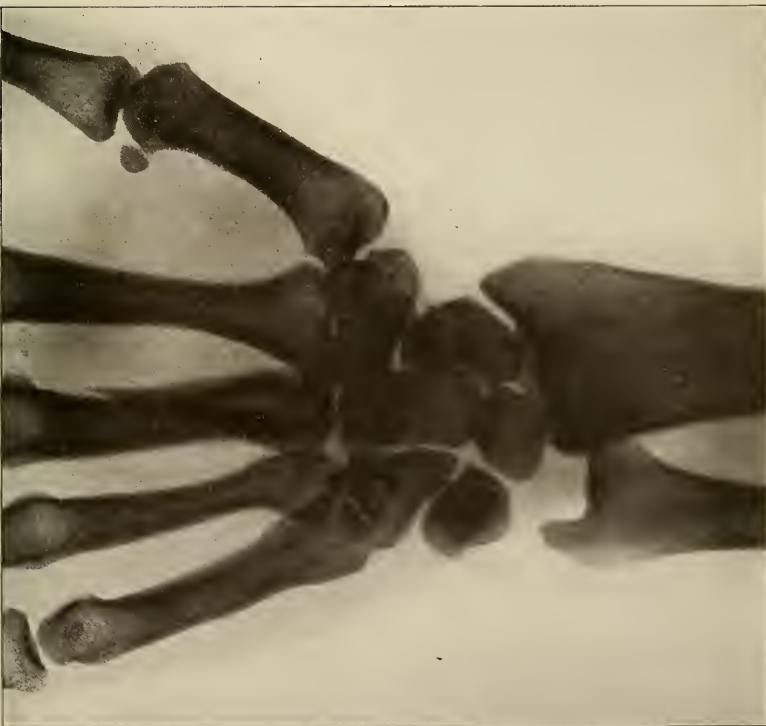

Fig 2.—Normal Wrist; Adult Female. Fracture of Third Metacarpal.

terized by greater causative violence and wider displacement. The mechanism appears to be avulsion through the cord-like lateral ligament which is attached to its tip.

Concerning the condition of the intra-articular fibro-cartilage I can find but little that is positive, since the only sources of information are the autopsies of recent fractures. The Röntgen rays give no direct information on this point, for the cartilage is transparent to them; its avulsion from the ulna or radius seems inevitable when the lower end of the radius is markedly displaced.

Although much stress has been laid by some upon the supposed rupture of the internal lateral ligament, fresh specimens and experiment upon the cadaver give no ground for the belief that it occurs except in cases with marked displacement. The fact that the end of the ulna is prominent and that the finger can be pressed in on the side below it much more deeply than in a normal joint can be explained by the ascent of the carpus, which would draw the ligament to a more transverse position.

I believe that in the severer cases the tendon of the extensor carpi ulnaris is torn out of its sheath and displaced outwardly from the ulna, for I have noted in such cases the absence of the resistance which the tendon normally offers to the finger close below the joint.

I have not met with the record of any case in which the radius projected through the skin, except after separation of the epiphysis, but I have seen fractures compound on the radial side.

Associated fracture of the scaphoid has been observed in a number of clinical and experimental cases, and that of the semilunar (Hunt) and dislocation of the semilunar (Cameron) have been reported. (See Fractures of the Carpus.)

Cause. The cause of Colles's fracture is usually a fall upon the palm of the hand, and in the great majority of cases the fall is only to the ground while walking. This is true of almost all cases in which the patients are somewhat advanced in life; in the younger ones the violence is usually greater, as a fall from a height.

The mechanism by which the fracture is produced has been the subject of much discussion. Three theories have been advanced: 1. Fracture by splitting or crushing; the cancellous tissue is crushed or comminuted between the carpus and the diaphysis. 2. Fracture as in other bones by decomposition of the force and yielding at the weakest point. 3. Fracture by cross-strain exerted through the anterior ligament in exaggerated and forced dorsal flexion (hyperextension) of the hand. I believe that almost all these fractures are produced according to one or the other of the first two ways, and that the third is rarely seen.

In the first the weight of the body is received upon the ball of the hand—the carpus—directly in the line of the long axis of the radius, and the inner end of the scaphoid or the semilunar splits the end of the radius like a wedge. This is shown by many specimens and appears to be especially frequent in the elderly.

In the second the line of the force is slightly inclined from the long axis of the radius, making an angle open anteriorly. The arm is out-

stretched and not directly in the line of the fall. The force is decomposed as usual, part being taken up by the resistance of the shaft in the long axis, and part acting transversely to break the bone. The backward displacement and tilting of the lower fragment indicate the direction of this component.

According to the third theory a cross-strain is exerted upon the end of the bone through the anterior ligament of the wrist; the force is thought to be received upon the palm of the extended hand at a point that lies posterior to the posterior border of the end of the radius, the hand is bent back, the ligament is put upon the stretch, and the bone is broken by avulsion. The theory seems to have originated in experiments upon the cadaver. The earliest recorded experiments in this direction were those already alluded to which were made by Sir Astley Cooper in 1833, but not published until several years afterward; the earliest publication appears to have been by Bouchet¹ in 1834. The experiment may produce a transverse fracture within a short distance of the articular surface of the radius, but quite as often it causes rupture of the anterior ligament and even dislocation or fracture of one or more of the carpal bones. There is no doubt, therefore, that the fracture can be produced in this way, and there are a few clinical cases in which this was apparently the mode of production. But, with the exception of these few cases, in which the mode of action of the violence was distinctly exceptional, there is nothing but the experiments to support the theory. In other clinical cases the same movement has produced dislocation of the semilunar or fracture of the scaphoid or semilunar. (See also Poulsen, *Arch. klin. Chir.*, vol. 80, p. 902, and Cartruccio, *Beiträge zur klin. Chir.*, vol. 53, p. 66.)

The violence in a fall is not usually received at a point on the palm of the hand posterior to the line of the radius so as to bend the hand backward; it is received at the base of the thumb, at a point corresponding to the trapezium, or along the carpus, and is transmitted directly to the radius as above described. Moreover, the theory fails to explain the comminution so frequently seen and fractures above the corjugal cartilage in the young.

Symptoms. The symptoms are marked and characteristic, but crepitus and abnormal mobility, so common in other fractures, are not always easily recognizable in this. The most striking features of the deformity are the prominence of the dorsum over the lower fragment and that of the end of the ulna. The former so changes the outline of the forearm and wrist that when viewed from the radial side its appearance is like that represented in Fig. 167, and was aptly compared by Velpeau to the outline of a silver fork, a comparison which has survived in the name "silver-fork fracture," by which it is sometimes known. The cause of this change in the outline, so far as it is due to the position of the fragments, is shown in some of the radiographs; swelling of the soft parts and even projection of the first row of the carpus accounts for some of it; that of the palmar aspect is due mainly to swelling of the soft parts.

¹ Bouchet: Thèse sur les Luxations du Poignet. Quoted by Malgaigne.

The radiographs show that the characteristic deformity is present even when the displacement of the fragment is slight, and that in

FIG. 167.



Deformity in Colles's fracture.

general this displacement is much less than has heretofore been supposed.

The prominence of the end of the ulna appears to be due to the displacement of the carpus and the fragment of the radius upward and somewhat to the radial side, aided sometimes by avulsion of the styloid process of the ulna, or, possibly, the equivalent rupture of the internal lateral ligament. That ascent of the end of the radius is sufficient to produce this prominence is shown by its gradual appearance in cases of arrest of growth at the lower end of that bone. (See Plate XXIII.)

If the surgeon marks the positions of the styloid processes by pressing the end of a finger into the side of the joint below and against the end of each, he will see that that of the radius has risen, so that instead of being about a quarter of an inch lower (nearer the hand) than that of the ulna, as it usually is, it has risen to the same level or even above it.

The swelling upon the anterior surface of the forearm is quite marked, and is sharply rounded off toward the wrist with deepening of the transverse creases.

Crepitus and abnormal mobility can sometimes be obtained by grasping the lower fragment between the thumb and fingers and moving it backward and forward while the forearm is steadied by the other hand.

Pressure along the line of fracture on the dorsum of the radius or of the hand upward against the forearm is painful.

Diagnosis. The diagnosis is made by recognition of the above signs and symptoms. In difficult cases, for people and children without displacement, it may be made upon the existence of a well-defined transverse line of tenderness on pressure on the dorsum of the radius, pain at the same point when the hand is pressed upward against the

radius, deepening of the transverse folds on the palmar aspect of the wrist, loss of power in the limb, and history of the case.

A sprain or contusion may be mistaken for a fracture if the limb has been broken previously and has united with deformity, for it will present some of the physical and functional signs. The question therefore should always be asked whether the wrist has suffered a previous injury.

Course and Prognosis. Firm union between the fragments may be expected within a month. The prognosis with reference to deformity depends, of course, upon the completeness of the reduction and retention. As a rule, permanent deformity after fracture in youth is slight or entirely absent; but in adults the case is different, either because the original displacement is greater, or because crushing and comminution make complete reduction and retention practically impossible.

The prognosis with reference to function is somewhat better, since the persistence of even marked displacement does not necessarily entail disability. The range of motion at the wrist may be somewhat restricted, and yet may be wide enough to answer all purposes, and a change in the direction of the articular surface is still compatible with free and painless motion. Rigidity of the wrist and fingers usually persists for some weeks, or even months, and in exceptional cases, in the old and rheumatic and in those where there has been much inflammation of the sheaths of the tendons and of the wrist-joint, it may persist for years. I have seen two cases in which the hand was practically useless a year or two after the receipt of the injury. There was much deformity in one of them. This rigidity of the fingers is due in part to their prolonged immobilization and in part possibly to inflammation within the sheaths of their tendons in the forearm.

The possible arrest of the growth of the bone after separation of the epiphysis in the young deserves mention, although it is an exceptional consequence of the injury. I have seen two such cases. (Plate XXIII.)

Treatment. Complete reduction of the displacement is, of course, essential to prevent permanent deformity. The ease with which it can be accomplished varies greatly in different cases. Traction upon the hand with direct pressure upon the fragment is sometimes sufficient to correct the dorsal displacement; in other cases forcible pressure must be made, the forearm is grasped with the fingers upon the palmar prominence and the thumbs upon the dorsal one, and the pieces pressed into line. Occasionally an anæsthetic must be given and the fragment mobilized by moving it forcibly backward and forward and then pressing it into place.

In order to meet the two indications—the prevention of posterior displacement of the lower fragment and of projection of the end of the ulna—a great variety of splints have been devised, most of them upon the theory that the position of the fragment can be controlled by the attitude given to the hand. Thus, palmar flexion of the wrist has been employed to prevent backward displacement of the fragment of the radius, and ulnar flexion to prevent the prominence of the ulna. The theory is wrong and the results have disappointed. If the dorsal displacement has been corrected it has little tendency to recur, and the

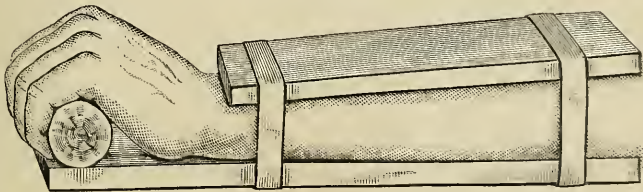
attitude of the hand is without influence upon it; the projection of the end of the ulna cannot be prevented by ulnar flexion of the wrist, for this movement does not bring back the carpus and the radial fragment to their normal positions.

The facts to be borne in mind are: 1. That dorsal prominence of the fragment is to be prevented by correction of the displacement before the application of a dressing, and its recurrence prevented by direct action upon the fragment, not by indirect action through the hand. 2. That some permanent shortening of the radius, especially on its outer side, if its cancellous tissue has been crushed, as is the rule in the old and frequent in others, is inevitable. 3. That the prominence of the ulna can be prevented only by bringing the fragment of the radius (and thus the carpus) fully back to its normal position—a practical impossibility in many cases. Direct lateral pressure upon the sides of the wrist may diminish the prominence in some cases. 4. That the fingers must be left free in order to avoid the stiffening caused by their confinement.

A suitable dressing, therefore, is one which immobilizes the fragment and the carpus in the position given to them and leaves the fingers free to be flexed and extended at will; and as the tendency to recurrence of the dorsal displacement is slight special precautions against it are rarely needed.

Such a dressing may be made of plaster-of-Paris or wooden splints. The most convenient attitude is that of partial pronation with the wrist in slight dorsal flexion and the fingers flexed. There should be two splints, palmar and dorsal, the former extending from a little below the elbow to the metacarpo-phalangeal joints, the latter from the same height to the carpo-metacarpal joints.

FIG. 168.



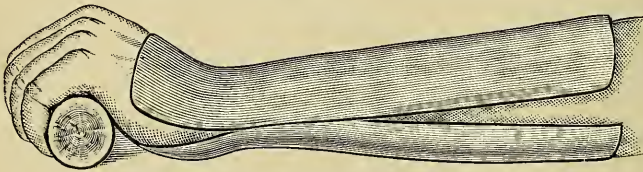
Wooden splints for Colles's fracture.

Wooden splints (Fig. 168) should be three inches broad and padded, the padding being a little thicker on the palmar splint at the point corresponding to the lower end of the upper fragment, and on the dorsal splint at the point corresponding to the lower fragment. A roller-bandage placed obliquely at the lower end of the palmar splint makes a convenient rest for the hand, maintains dorsal flexion of the wrist, and permits the fingers to be clasped over it. The splints are secured in place by two adhesive bands, one at each end, and by a roller-bandage.

Plaster-of-Paris splints (Fig. 169) should be wide enough to cover in the wrist, and the lower end of the palmar one may be conveniently

made into a roll to fill the palm of the hand. The dorsal one may extend upon the back of the hand. They should be secured in place by a roller-bandage, and while the plaster is setting it may be held snugly against the sides of the wrist so as to keep the ends of the radius and ulna close together. They are especially advantageous in permitting daily massage of the parts: the dorsal splint is removed and massage made on the uncovered portion from the beginning, and the palmar one can be removed for the same purpose (the dorsal one being kept in place) after the first week. The patient must be instructed to keep the fingers flexed when at rest, and to move them frequently. It is well also to keep the thumb abducted.

FIG. 169.



Plaster-of-Paris splints for Colles's fracture.

The question sometimes arises whether the deformity, persisting for some time after the injury and the result of an error in diagnosis or of failure of treatment, can be corrected. Among Dupuytren's earliest cases were three of this kind, and he succeeded in overcoming the deformity by steady forcible traction and pressure upon the fragments on the twentieth, twenty-ninth, and thirtieth days after the receipt of the injury, the patients being respectively sixty-nine, ten, and thirteen years old. A few cases have been treated by refracture or by incision and osteotomy. I doubt if anything more than an improvement in appearance can be gained thereby; the causes of loss of function cannot be thus removed.

B. Fractures at the Wrist Other than Colles's.

Dr. Rhea Barton,¹ of Philadelphia, described clinically a fracture which he said was very common, and which he supposed to be the detachment of the posterior border of the articular surface of the radius. It does not appear from his paper that he had ever had an opportunity to verify the diagnosis by examination. A few specimens of such a fracture, most of them, I believe, found in the dissecting-room and without history, are in existence, and the injury is known in America as Barton's fracture. Dr. Agnew² figures a specimen in which the fragment is much larger. It is perhaps hardly worth while to try now to change this name, but there are three good reasons why the injury should not be known as Barton's fracture: 1st, as a reference to the original article shows, the injury which Barton described clinically was not what he supposed it to be anatomically, but was the ordinary

¹ Barton: *Medical Examiner*, 1838, p. 365.

² Agnew: *Loc. cit.*, vol. i. p. 905.

Colles's fracture; 2d, the lesion as he supposed it to be, had been observed some years before his paper was published, and the specimen was presented by Lenoir¹ to one of the Paris societies; and, 3d, it deserves to be classed not as a variety of fracture, but as a complication of dislocation of the carpus backward. In Lenoir's case, which is described as a dislocation by Voillemier and Malgaigne, a narrow fragment of the posterior articular border had been broken off, remained attached to the capsule, and was displaced backward with the bones of the wrist. I have seen two such cases.

An analogous case, dislocation of the carpus forward with detachment of the *anterior* border of the articular end of the radius and fracture of the styloid process, was reported, with the specimen, to the Société Anatomique, by Letenneur.² The patient was brought to the Hôtel-Dieu May 7, 1838, having received this injury and also a fracture of the scaphoid bone of the other wrist, by falling into a ditch while intoxicated. Mr. Callender³ refers to a somewhat similar specimen, but one in which the fragment is much larger, in the following words: "The line of fracture is four-tenths of an inch from the end of the radius on the palmar surface, but on the dorsal passed into—along the edge of—the articular facets." A case demonstrated by the *x*-ray is reported by Shoemaker.⁴

Other infrequent fractures of the region may be conveniently mentioned here:

A condition in which, the line of fracture being the same as in Colles's fracture, the lower fragment is displaced toward the palmar side, and the crushing is also on that side. Mr. Callender⁵ reports such a case caused by forced flexion of the hand in a fall upon it; there was a well-marked prominence on the dorsum of the forearm about three-fourths of an inch above the wrist-joint, and opposite it on the palmar surface was a considerable depression. The lower fragment of the radius was inclined at an oblique angle to the palmar surface, and projected at the wrist. No crepitus. Reduction could not be effected. Ten months later the deformity persisted, with good rotation, exaggerated flexion, and inability to extend the hand beyond a straight line with the forearm.

Callender mentions also two specimens, one in the museum of Westminster Hospital, the other at St. Bartholomew's, which show the corresponding displacement with union. In one the styloid process of the ulna was broken and the lower fragment of the radius displaced forward and outward, especially in the latter direction, with penetration on the palmar surface, to the depth of more than three-tenths of an inch. In the other the line of fracture is rather more than an inch above the end of the bone; there is a prominent angle on the dorsal aspect in the line of the fracture and an elevation of new bone on the

¹ Lenoir: This fact is mentioned by Voillemier, in the *Archives Générales de Médecine*, 1839, vol. vi. p. 402, and by Malgaigne. The Society referred to is probably the Société Anatomique, but I have failed to find mention of the specimen in its Bulletin.

² Letenneur: *Bulletins*, vol. xiv. p. 162.

³ Callender: *Loc. cit.*, p. 291.

⁴ Shoemaker: *Annals of Surgery*, August, 1904, p. 284.

⁵ Callender: *Loc. cit.*, p. 289.

corresponding part of the palmar surface ; the triangular fibro-cartilage was almost completely separated from the radius.

R. W. Smith¹ describes and figures a similar case, in which also the fracture was caused by a fall upon the back of the hand, and I know of one seen by Dr. Keyes.

The diagnosis is made by attention to the position of the styloid process with reference to the carpus and the ulna and by recognition of the line of limited tenderness if mobility and crepitus cannot be obtained. The treatment should be the same as in Colles's fracture, except that the position of the pads should be changed to meet the different displacements. The subject has been treated in detail by Dr. J. B. Roberts in *Annals of Surgery*, January, 1897 ; see also *Idem.*, September, 1904, p. 423, for two cases seen by him and one by Stewart.

An oblique fracture running downward and inward and detaching the **styloid process** of the radius with more or less of the articular portion ; the larger the fragment the more closely will the symptoms resemble those of Colles's fracture. The injury is rare. In the few cases I have seen and in those reported the fragment has been quite large. Usually the displacement is slight, but in one case the fragment was drawn upward one and a half inches. Immobilization of the wrist appears to be all that is needed.

Longitudinal fracture or fissure of the end of the bone. Dr. Bigelow² reported one case and referred to a second. There was a star-shaped crack on the articular surface without displacement and slight corresponding cracks in the shaft for more than an inch above. At first there was only lameness at the wrist, but after several days there were swelling and tenderness, the persistence of which led Dr. Bigelow to make the diagnosis. He had had a similar case two years before, with the same symptoms, but less extensive injury to the bone. I have seen one, shown by skiagram. It is clearly an incomplete Colles's ; if the violence had been greater the fracture would have been the usual one.

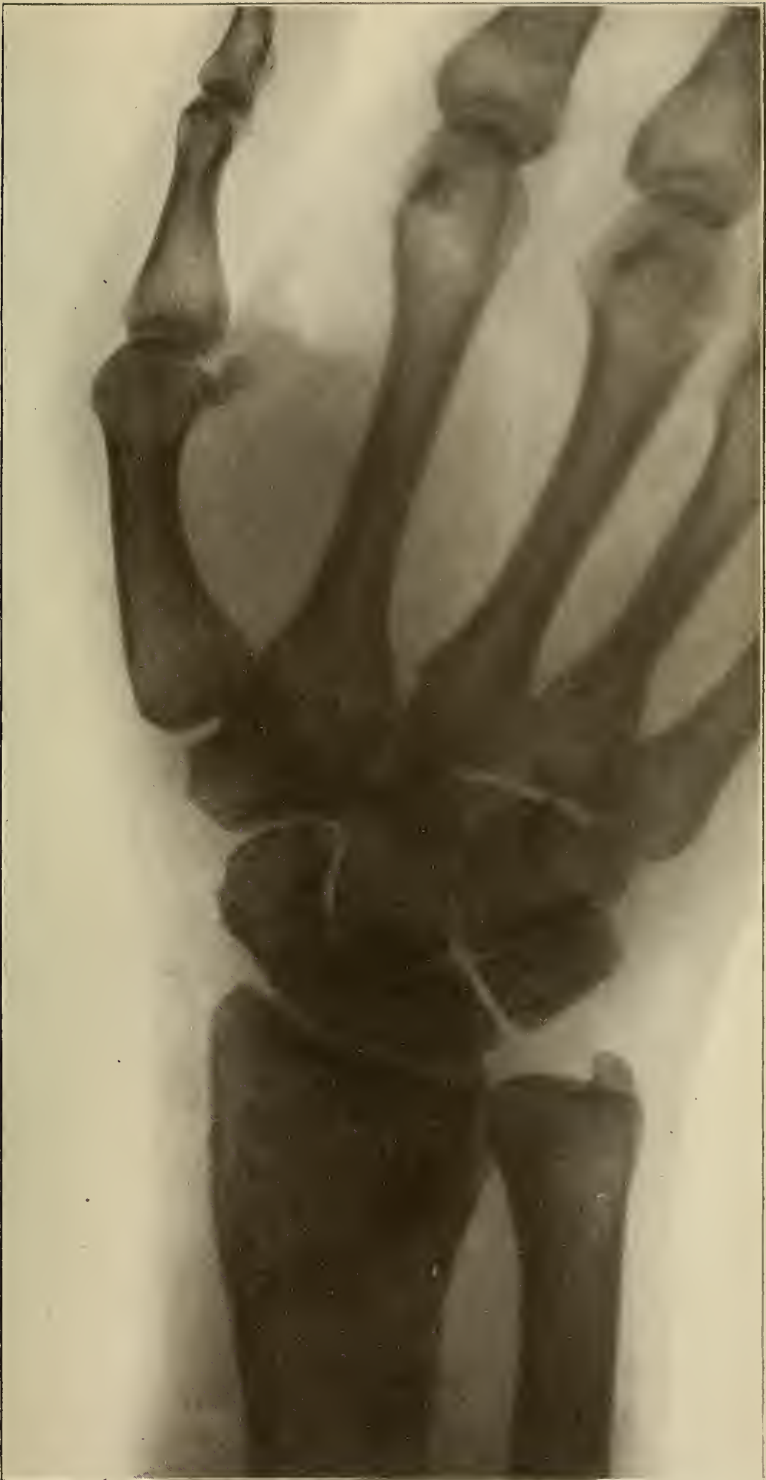Fracture of the styloid process of the ulna is sometimes observed separately as the result of direct violence. In addition to the usual symptoms of pain and swelling, mobility of the process could probably be recognized by direct manipulation or by abduction of the hand. Dr. Agnew says some deformity is likely to remain, and that in the only case he had seen the union was fibrous. He advises treatment upon an anterior splint with the hand inclined toward the ulnar side and in dorsal flexion, so as to relax the extensor carpi ulnaris.

Fracture of both bones near the wrist is occasionally seen. The diagnosis is made by recognition of the abnormal mobility of the fragments. Treatment as in Colles's fracture.

In *compound fractures* every effort should be made to avoid amputation. Good results have been obtained even by excision of the lower end of the ulna alone or of both bones.

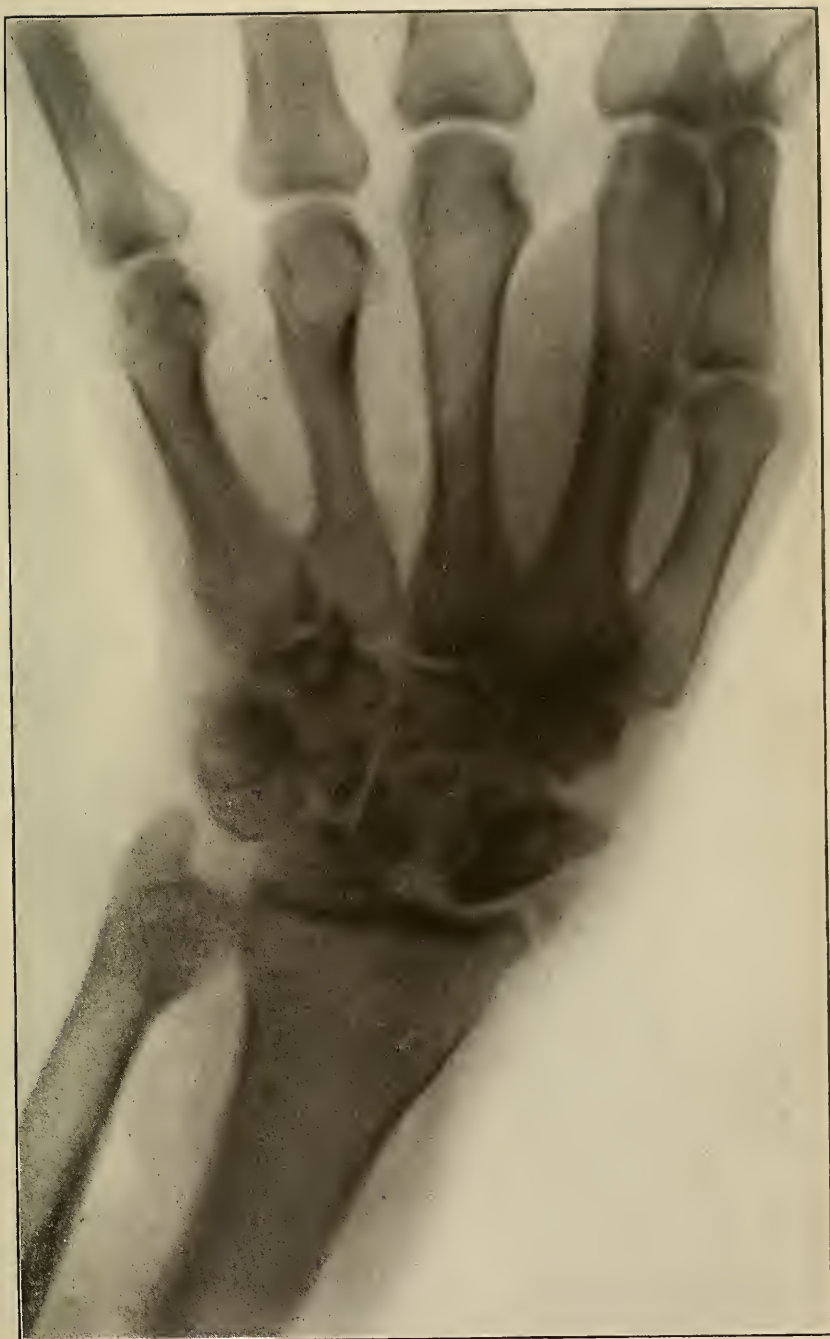¹ R. W. Smith : *Loc. cit.*, p. 162.

² Bigelow : *Boston Med. and Surg. Journal*, 1858, vol. lviii. p. 99.

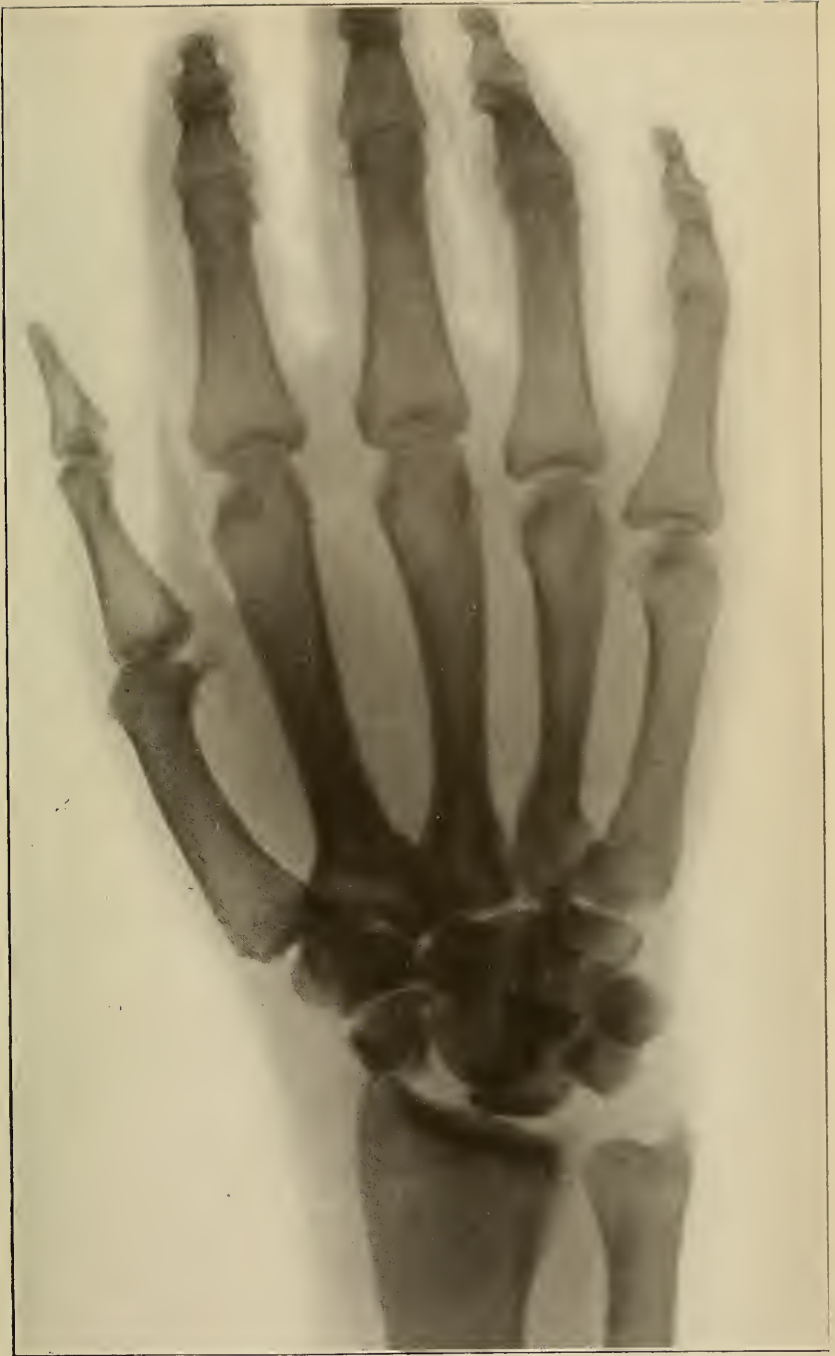

Fracture of Scaphoid and possibly of Radius.

PLATE XXVI.



Fracture of Scaphoid, with Dislocation of Proximal
Fragment.



After Removal of Proximal Fragment of Fractured Scaphoid.

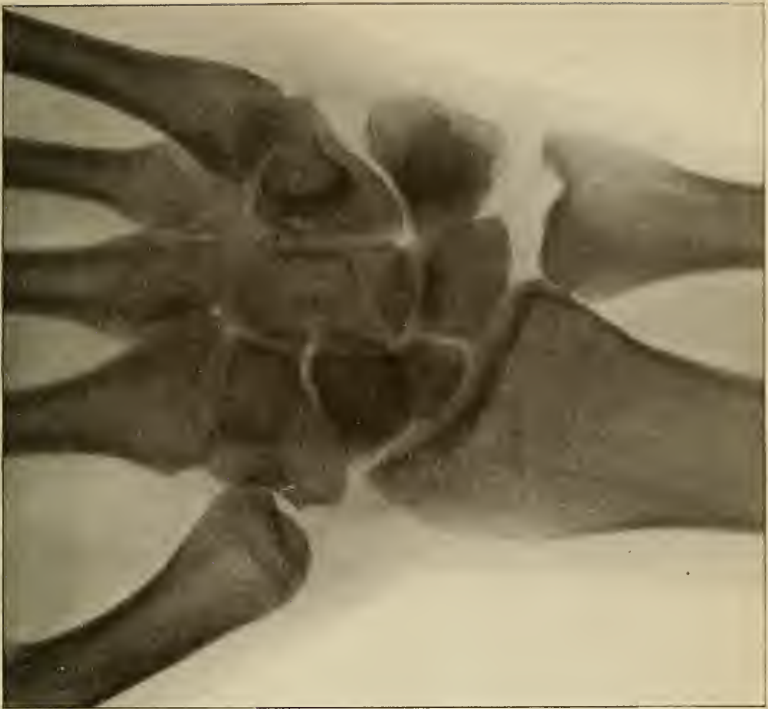

Fig. 1.—Fracture of Carpal Scaphoid.



Fig 2—Separation of Lower Epiphysis of Femur; Displacement forward with Rotation about the Transverse Axis.

CHAPTER XXI.

FRACTURES OF THE CARPUS AND HAND.

Fractures of the Carpus, of the Metacarpal Bones, of the Phalanges.

1. FRACTURES OF THE CARPAL BONES.

FRACTURE of any of the carpal bones has heretofore been thought to be a very rare injury, but the disclosures of the *x*-rays and the attention aroused thereby have resulted in the recognition of a number of fractures of the scaphoid so considerable as to warrant the opinion that the injury is not very infrequent.

Scaphoid.¹ The first reported case of which I have knowledge was observed by Letenneur, although two earlier cases of "fracture of the carpal bones" seen by Cloquet (*Dict. en 30 vols.*, art. *Main*), have been generally quoted as of the scaphoid. The second case is that of Guibout; it was caused by a fall from a height and was accompanied by fracture of the os magnum, cuneiform, and pisiform. A few specimens of old fracture have been preserved in museums; some of them in which union had failed were thought to be developmental vagaries and termed "naviculare bipartitum." Flower's incomplete fracture, Rutherford's, and mine, of 1891, were all due to great violence, and the diagnosis was made at autopsy or through an associated wound.

In the last few years, after the *x*-rays had demonstrated the existence of the injury and clinical recognition had become easier and more assured, a number of cases have been reported and the fracture has been the theme of several papers. There is, however, reason to suspect that some of the cases reported on skiagraphic evidence were misinterpretations of dark lines and irregularities of outline such as are seen in some uninjured bones. The probable frequency is indicated by the fact that Lilienfeld found 7 cases among 128 patients with fracture, who came for late treatment to the Zander-institut in Leipzig, Blau saw 15 cases in a year and a half, and Ehebald 23 in a year. I have seen 3 old cases and 6 fresh ones. Of the latter, the first three have been reported, two others are shown in Plates XXV. and XXVI., the sixth was seen

¹ BIBLIOGRAPHY.—Letenneur, *Bull. de la Soc. Anat.*, 1839, vol. xiv. p. 162; Guibout, *ibid.*, vol. xxii. p. 27; Flower, *Holmes's Syst. of Surg.*, Am. ed., vol. i. p. 867; Fortuinet, *Lyon Méd.*, July 1, 1888; Rutherford, *Glasgow Med. Jour.*, 1891, p. 312; Stimson, *N. Y. Med. Jour.*, May 21, 1892; Auvray, *Gaz. des Hôp.*, 1898, p. 377; Sir Wm. Stokes, *British Med. Jour.*, 1900, i. p. 1075; Hoffiger, *Corresp.-blatt für Schweiz. Aerzte*, 1901, p. 297; Kaufman, *Ibid.*, 1902, p. 257; Stimson, *Annals of Surg.*, May, 1902; Pagenstecher, *Münch. Med. Wochenschrift*, 1903, p. 1916; Wolff, *Deutsche Zeitschrift für Chir.*, 1903, vol. lxxix. p. 401; Blau, *Ibid.*, vol. lxxii. p. 445; Lilienfeld, *Arch. für klin. Chir.*, 1903, vol. lxxix. p. 1158; Vialle, *Arch. de Méd. and Phar. Med.*, Oct., 1904; Russ, *Annals of Surg.*, Feb., 1905; Codman and Chase, *Annals of Surg.*, March and June, 1905, an elaborate paper; Karrer, *Inaug. Diss.*, Kiel, 1905, abst. in *Zentralblatt für Chir.*, 1906, p. 811; Ehebald, *Arch. für Orthopædie, Mechanother. und Unfallchir.*, 1906, p. 276, with bibliography; Hirsh, *Ztblatt für Chir.*, 1906, p. 1289; Cartruccio, *Beiträge zur klin. Chir.*, Feb., 1907, p. 66.

with Dr. Kenyon. In two the proximal fragment was dislocated, and removed by operation, in one it was slightly displaced and not removed, the patient recovering with good use of the wrist. In Dr. Kenyon's the result was good. Of the other the result is not known. Since the above was written (1904) I have seen several cases each year. Fracture of the radius and dislocation of the semilunar are not infrequent accompaniments.

The mechanism of the injury is not clear; apparently it can be caused by violence which presses the scaphoid against the radius, but I am inclined to believe that it is commonly effected by cross-strain, "avulsion-fracture." The commonest cause is forced pressure of the wrist against the radius in dorsal flexion. In one of Hoflinger's and one of mine it was caused by palmar flexion. The line of fracture passes through, or close to, the middle third of the bone; according to Ehebald, commonly at the middle, but sometimes at the junction of the middle and one of the terminal thirds. Dislocation of the central fragment existed in four of my cases, and has been reported in several others; it is usually backward.

The symptoms are complete, or almost complete, stiffness of the wrist, especially in extension, pain on pressure over the scaphoid, especially in the depression between the extensor tendons of the thumb, the *tabatière*, and more or less marked radial abduction of the hand with shortening of the distance between the styloid process of the radius and the trapezium. Ehebald recommends for the recognition of the pain that the thumb be placed in the *tabatière* and the fingers on the volar aspect, and the bone compressed between them.

Apparently failure of union is frequent (4 out of Blau's 15 cases, all but one of Ehebald's), presumably because the proximal fragment is generally intra-articular and cut off by the fracture from its blood-supply. Some of the old specimens (Wolff) show smooth, even eburnated, surfaces of fracture. In Russ's case the small central fragment could be easily dislocated backward and replaced. Apparently failure of union does not necessarily cause much loss of function if there is no displacement, unless it should give rise to a chronic arthritis; but the persistence of any displacement is disabling.

The treatment is immobilization for four or five weeks and massage. When there is dislocation of one fragment it should be removed. Lilienfeld found considerable loss of motion in the old cases, and in one of mine ankylosis was almost complete. Hoflinger and Kaufmann recommend excision of the bone in old cases to restore function, and the latter recommends for this purpose an incision between the extensor tendons of the thumb. Ehebald urges removal in fresh cases if displacement exists, but Codman and Chase only after conservative treatment has been tried for two months without success. They recommend an incision on the dorsum of the wrist along the inner side of the tendon of the long radial extensor and deepened through the annular ligament between the radial extensor and the extensors of the fingers. In the intra-articular form Hirsh makes no attempt to obtain union and seeks only to get good function by massage and early movement.

The **semilunar**¹ has been reported broken in three cases, all by great violence and with associated injuries of the region. Peste's was double. Wittek² describes a case in which the bone appeared to have been flattened and broadened and quotes Pfitzner and Schmitz for 9 similar ones.

The **cuneiform** and **pisiform** were broken in Guibout's case (*vide supra*).

The **os magnum** has been reported broken at the neck in three cases observed clinically, and of course some doubt must remain of the accuracy of the diagnosis. The first case was that of Robert, quoted as doubtful in the *Traité de Chirurgie* of Le Dentu and Delbet from the *Ann. de Thérapeutique de Roquette*, 1845, p. 146. The others are those of Moty (*Gaz. des Hôp.*, 1890, p. 634), which seems accurate, and of Guermontprez, very briefly abstracted in the *Rev. de Chir.*, 1882, p. 81. I have seen one case in which the possibility of fracture was suggested by pain on pressure over the neck of the bone.

2. FRACTURES OF THE METACARPAL BONES.

While simple fracture of a metacarpal bone is not a very common accident, still it is not so rare as some authors have inferred from hospital statistics. Malgaigne found 16 cases in a total of 2377 fractures of all kinds treated at the Hôtel-Dieu, a percentage of 0.67; Polaillon, 64 cases in a total of 5517 fractures treated in the Paris hospitals during the years 1861-63, a percentage of 1.16. Of Polaillon's 64 cases, 57 were men, only two were old, and none were infants.

The third and fourth are most frequently broken, the first and fifth least. Simultaneous fracture of two or more is frequent when the injury is compound.

A very few cases of probable separation of the distal epiphysis have been recorded, one by Malgaigne, one by Hamilton, and one quoted by Polaillon from a thesis by Pichon, the ages being nine, eight, and twelve years respectively. There was failure of union in Malgaigne's case, but without disturbance of function when last seen, thirteen years after the injury. Bennett³ has described a variety of fracture of the base of the first metacarpal, an oblique fracture by which the palmar half of this end is separated and the remainder is displaced more or less backward, so that at first sight the injury appears to be a subluxation. He collected nine examples. The usual displacement is angular, the apex of the angle being directed backward or forward, and at the same time the fragments may override longitudinally. Miles and Struthers (*Edinb. Med. Journal*, April, 1904) observed ten cases in four years, and Russ (*Journ. Am. Med. Assoc.*, 1906, vol. 46, p. 1824) eight in one year.

Cause. The cause may be direct or indirect violence. When direct it is a blow upon the back or even the palm of the hand, a fall or blow upon its side, or a crushing force, the hand being caught between

¹ Peste: Bull. Soc. Anat., 1843, vol. xviii, p. 170; Hunt, Annals of Anat. and Surg., 1881, p. 110; Pfitzner, quoted by Wittek.

² Wittek: Beiträge zur klin. Chir., vol. 42, p. 578.

³ Bennett: British Medical Journal, July, 1886, p. 13.

two solid bodies. The first, second, and fifth metacarpals are the ones most frequently broken by direct violence.

The commonest indirect cause is violence received upon the distal end of the bone in the direction of its long axis, by which its normal curve is exaggerated and fracture produced, as in a fall upon the knuckles or a blow with the fist. Lonsdale reported a case in which fracture of the third metacarpal was caused by a fall upon the end of the outstretched middle finger. In a case reported by Dupuytren, the third metacarpal bone was broken by being bent backward in a trial of strength, the contestants trying to force each other's wrist back with their fingers interlocked. Velpeau saw the same bone broken by traction upon the index- and middle fingers with some twisting.

Symptoms. The symptoms are the deformity due to the displacement of the distal fragment, abnormal mobility, crepitus, pain, and inability to use the fingers. The deformity is usually slight and may be wholly masked by the swelling; abnormal mobility and crepitus may be found by flexing and extending the corresponding finger and at the same time making pressure upon the palm at the supposed seat of fracture, so as to make the fragments prominent behind. The pain can be suddenly and sharply increased by pressing the finger toward the carpus.

The course of the fracture is usually simple, and ends in consolidation in the course of three or four weeks. The complications which occurred in the eighty-one cases collected by Polaillon were inflammation of the carpo-metacarpal joint, union with marked displacement, fusion of adjoining bones when both were broken, and deviation of the extensor tendons by a voluminous callus in one each, and failure of union in three. In neglected cases of fracture at or near the knuckle suppuration is not infrequent and may so extend as to cause marked disability.

Treatment. The first indication is to prevent a too severe inflammatory reaction if it threatens, and with this object the hand should be kept at rest in an elevated position.

If there is no displacement or tendency thereto, a simple immobilizing dressing of cotton, bound on snugly with a roller-bandage, is sufficient, the fingers being left free to prevent their stiffening.

A method that has long found favor is to fill the palm with a mass of tightly packed cotton or some similar substance, or a ball, over which the fingers are closed and fastened down with a bandage or adhesive plaster. The flexion of the finger over the firm mass tends to draw the knuckle downward, and thus prevent shortening. The support furnished by the adjoining bones is an additional aid against displacement, and the back of the hand can be left partly uncovered for inspection.

In fracture of the third and fourth metacarpals the hand may be bound upon a dorsal or palmar longitudinal splint suitably padded and fastened with a roller, but this plan is unsuited to fractures of the second or fifth because the circular compression exerted by the bandage tends to cause lateral displacement.

If continuous traction seems necessary to overcome a tendency to

displacement the finger may be bound to the adjoining ones for a few days, but it is important that immobilization of the fingers, especially in the extended position, should be avoided or made as brief as possible.

In Bennett's fracture of the first metatarsal reduction is made by strong traction and pressure against the base of the bone; maintenance by splints and adhesive plaster or by plaster of Paris.

3. FRACTURES OF THE PHALANGES.

These fractures are usually due to direct violence, and in consequence are frequently compound or at least accompanied by laceration or bruising of the soft parts. A few cases have been reported of fracture by indirect violence, as in a fall or blow upon the end of the finger, or by having the finger caught and fixed while the hand continued to move.

The proximal phalanx is the one most frequently broken, the terminal phalanx most rarely.

The symptoms upon which the diagnosis is made in simple fractures are mobility and crepitus.

The progress of the case in simple fracture is toward prompt repair; in compound fractures the suppuration is apt to be prolonged, and necrosis of splinters and even of one of the principal fragments is not uncommon.

A well-established rule of treatment of injuries of the hand is to save everything that can be saved, but it needs limitation in compound fractures of the fingers. While it is desirable to save the thumb or any part of it, even at the price of ankylosis of both the joints, the same value does not attach to the fingers, and a rigid deformed finger that has been saved with much difficulty is often a source of so much inconvenience that the patient subsequently seeks relief in amputation. It is better that members so injured that rigidity will probably result should be removed at first, for the attempt to save them cannot be made without incurring certain risks, prolonged suppuration, phlegmon of the forearm, tetanus, which, although somewhat remote, should not be lost sight of.

In the treatment of simple fracture the usual indication to prevent displacement is habitually met by means of a moulded palmar splint made of pasteboard, felt, or gutta-percha to which the finger, slightly flexed, is made fast. This answers very well for the terminal and middle phalanges, but it does not support the proximal one sufficiently. Sometimes a straight splint is used, sometimes a plaster-of-Paris bandage.

A common displacement, important to be guarded against, is an angular one with the apex directed forward and caused, I think, by the action of the interosseous muscles. The persistence of this displacement constitutes a serious inconvenience, for it limits flexion of the metacarpo-phalangeal joint and creates a prominence upon the palmar aspect of the phalanx, the skin covering which may become so sensitive that a firm grasp cannot be taken of any hard object.

As a palmar splint does not entirely prevent this displacement I prefer to close the hand upon some firm cylindrical body, a roller-bandage for example, and fasten the fingers down with strips of adhesive plaster applied longitudinally along the back of the hand, the fingers, and the front of the forearm, and additionally secured with a few turns of a bandage. The roll must be large enough to give ample support, and by passing the finger along the dorsum of the phalanx the occurrence of displacement can be recognized. It will be remembered that the tendon of each extensor muscle is attached to the base of the proximal phalanx by a short band which limits the action of the muscle to that phalanx, and that the extension of the middle and distal phalanges is accomplished by the interossei, which also flex the metacarpophalangeal joint and are relaxed when the fingers are closed. The tendency to overriding is thus effectively opposed by this position, and the displacement which then most needs to be guarded against is the one also that is most readily detected, angular displacement with the angle directed backward.

Support that may be sufficient in some cases can be readily obtained by binding the broken finger to the adjoining ones and supporting both or all three upon a common splint.

In compound fractures prophylactic doses of tetanus antitoxin have been much used, and apparently with good results.

CHAPTER XXII.

FRACTURES OF THE PELVIS.

Fractures of the Ring of the Pelvis, Sacrum, Coccyx, Ilium, Ischium, Pubis, Rim of the Acetabulum.

FOLLOWING well-founded custom I group in one section all fractures which break the continuity of the ring of the pelvis and consider separately fractures of the individual bones which do not break the continuity of the ring.

1. FRACTURES OF THE RING OF THE PELVIS.

The most frequent cause of this lesion is the passage of the wheel of a heavily laden wagon across the thigh and hypogastrium; among the others are falls upon the feet or the buttocks, the caving in of an embankment, and crushing between the buffers of railway cars or other heavy moving objects. The position and the number of the fractures vary with the degree of the violence and the portion of the ring upon which it is received. When it falls upon the symphysis and is directed backward the arch yields at its weakest point, and the line of fracture passes through the horizontal and descending branches of the pubis, sometimes on one side alone, sometimes on both sides. If the force then continues to act it presses the sides apart, and either breaks the sacrum vertically (by avulsion) or ruptures the ligaments of the sacro-iliac synchondrosis, or breaks the ilium into the synchondrosis or into the sacro-sciatic notch; and it does this sometimes also on one side alone, and sometimes on both.

When the violence is received upon the side of the pelvis, or the great trochanter, or even upon the foot, it may cause what Malgaigne described as double vertical fracture of the pelvis, or fracture of the acetabulum to a variable extent, and in one case a fall upon the foot caused dislocation of the entire os innominatum, separating it cleanly at the symphysis pubis and sacro-iliac joint and forcing it upward. In double vertical fracture the anterior fracture occupies the same position as when the force has been received upon the symphysis, it crosses the pubis; the posterior one is usually entirely within the ilium and behind the acetabulum. In fracture of the acetabulum, which can be caused only by violence transmitted through the femur, the bone may be simply fissured, or the head of the femur may be driven entirely through into the cavity of the pelvis. In the slighter cases the continuity of the pelvic ring is not broken, but in the more extensive ones it is. In young people the lines of fracture may follow those of the developmental division of the bone into three.

The displacements are seldom great, but complications are numerous and serious. The most frequent is rupture of the urethra, usually in its membranous portion; among the others are rupture of the bladder and laceration of the iliac veins or the external iliac artery. Rupture of the bladder may be intra- or extra-peritoneal; in some cases it appears to have been caused by the direct pressure upon the bladder of the object which caused the fracture, in others by a splinter or the displaced fragment. The other two lesions mentioned are due to the displacements. The separation of the pubes tears the urethra across at or near the triangular ligament, and the projecting edge of the posterior line of fracture lacerates one of the iliac veins, or the edge of the anterior one tears the external iliac vein or artery.

In a case briefly referred to by Legros Clark¹ there were several fractures, and separation of the sacro-iliac synchondrosis on each side and of the pubic symphysis to the extent of four inches. The rectum was ruptured and feces were extravasated into the pelvis; the bladder was ruptured and the urethra torn completely from the prostate gland.

The varieties and the symptoms, which vary notably with them, require separate mention.

Separation of the symphysis pubis may be produced by external violence directly pressing the anterior superior spines or the ischia apart or through forced abduction of the thighs, or by the descent of the fœtus through the superior strait in parturition. Malgaigne collected seventeen cases of the latter, most of them occurring in primiparæ, and most by the unaided action of the patient's muscles; in a few cases the forceps was used. Usually the separation takes place with a distinct cracking sound, and the gap can be felt with the finger, and in one or two cases the fracture has been made compound by simultaneous laceration of the soft parts. The gap is the chief diagnostic symptom. The scanty information possessed upon the subject indicates that, in the traumatic cases at least, the separation takes place not through the cartilage, but between the cartilage and the bone.

The traumatic cases are no less numerous and more varied in their details, although in a large proportion of them the force seems to have been exerted through the adductor muscles of the thighs. In two cases quoted by Malgaigne, in a third reported by Weber,² and in a fourth by Earle,³ the patient was on horseback and received the injury either by being thrown forward upon the withers, or first to one side and then to the other, or by the muscular effort made to keep his seat. In one of Malgaigne's cases the results were an immediate hernia, rupture of the perineum with a separation at the symphysis that would admit the hand, and pain at each sacro-iliac synchondrosis. The patient recovered in three and a half months, the treatment consisting of a bandage drawn tightly about the pelvis, with the limbs resting upon a double inclined plane.

In Earle's case there were collapse, severe pain, flattening of the pubes, and free bleeding from the anus. An incision in the perineum

¹ Legros Clark: *Diagnosis of Visceral Lesions*, p. 339.

² Weber: *Gaz. Méd. de Strasbourg*, 1872.

³ Earle: *Med. Chir. Trans.*, 1835, vol. xix. p. 257.

gave exit to blood and urine. The patient survived for only forty hours, and the autopsy showed a separation of three inches at the symphysis, the left sacro-iliac synchondrosis gaping one inch, and the prostate torn completely away from the bladder and hanging down in a cavity filled with clot. The patient was between sixty and seventy years of age.

In another singular case quoted by Malgaigne the patient, a lad eighteen years old, was learning to be a dancer. His teacher made him lie upon his back on the floor with his thighs flexed, and then standing upon him with one foot on each knee, sought to force the thighs outward. It caused the bones to separate at the symphysis to the extent of half a finger-breadth.

Separation in Front and Behind. In one of Mr. Earle's¹ cases there was complete separation of the left os innominatum, both in front and behind; the bone was forced up to a considerable extent, and the common iliac vein torn across. The patient was a young man, and received the injury by jumping from a third story; he landed upon the left foot, causing also a compound comminuted fracture of the calcaneum and astragalus.

Similar cases were collected by Malgaigne, and two have been published by Salleron.² Creite³ reports one case and collects seven others. The injury has been caused by a fall upon one foot or upon the side of the pelvis, or by the pressure of a heavy weight upon the front of the pelvis. The characteristic symptom is the elevation of the corresponding half of the pelvis with absence of the crepitus which is usually present in double vertical fracture. Salleron was able to reduce the dislocation in his cases, and both recovered, but, as a rule, the prognosis is extremely grave.

Separation of the Sacro-iliac Synchondrosis. Simple separation of this joint is very rare. Malgaigne⁴ quotes one case of it, and four others in which there was in addition fracture of the ilium. I have seen one well-marked case. The lesion is said also to have been produced during labor.

The diagnosis is made by recognition of the displacement, which is backward and outward.

Separation of all Three Joints. A few cases have been reported as such, but in most there has been also fracture at one or more points, and the separation of one or both of the sacro-iliac synchondroses has been only the gaping of the joint due to the lateral separation of the two halves of the pelvis and not a real displacement. Malgaigne quotes briefly five cases, in four of which there were associated fractures of the pelvic bones. Dolbeau,⁵ Dubrueil,⁶ and Pollock⁷ have since reported others. Dubrueil's is the only one in which there seems to have been actual displacement at all three points, and even in it there was also a slight fracture. The patient was run over by a wagon. There was separation of two and a half inches at the symphysis pubis

¹ Earle: Loc. cit., p. 261, Case 5.

² Salleron: Archives Gén. de Méd., 1871, vol. ii. p. 34, Cases 1 and 2.

³ Creite: Deutsche Zeitschrift für Chir., vol. 83, p. 391.

⁴ Malgaigne: Loc. cit., vol. ii. p. 777.

⁵ Dolbeau: Gazette des Hôpitaux, 1868, p. 194.

⁶ Dubrueil: Ibid., 1871, p. 413.

⁷ Pollock: The Lancet, 1872, vol. ii. p. 409.

and gaping of both sacro-iliac synchondroses. The sacrum was displaced forward, projecting at the level of the superior strait two centimetres in front of the right ilium and one and a half in front of the left. There was a fracture at the junction of the right ischium and pubis, and partial fracture of the body of the right pubis.

In each case the injury was caused by extreme violence acting directly upon the pelvis, the passage of a heavy wagon, the fall of a heavy object. All terminated fatally.

Fracture of the pubic portion of the pelvic ring, which is the most common of all, passes usually through the horizontal ramus just in front of the ilio-pectineal eminence and through the descending ramus near its junction with the ischium. The fracture may be oblique or transverse, may be double (of one or both pubic bones), or may be associated with separation of the symphysis or with other fractures of the lateral or posterior portions of the pelvis. As has been already mentioned, rupture of the ligaments of one or both sacro-iliac synchondroses with gaping of the joint is a frequent accompaniment when the action of the fracturing force is momentarily prolonged.

The displacement is sometimes so marked that it can be easily recognized by the eye; in other cases the diagnosis can only be made after palpation of the outline of the bone, which is quite accessible to the touch.

Interference with the voiding of the urine, either by rupture of the urethra or by pressure upon it, is a frequent complication. Injury to the urethra takes place usually in the membranous portion. The bladder, too, has been sometimes torn by a fragment or ruptured by pressure.

The following are the more noteworthy complications and varieties that have been recorded. A man, twenty years old, was run over by a railway train and received a fracture of the crest of the right ilium, the ramus of the left pubis, and of the "right pubis close to its junction with the iliac portion of the bone, the sharp end of this fracture had entirely divided the external iliac artery."¹ A man, forty-three years old, was run over by a wagon, was brought to the hospital insensible, and died in three hours. There was fracture of the "ramus and body of the pubis on both sides, and separation of the sacrum from the left os innominatum. Fracture of the left ilium, the fracture extending across the pectineal line and causing laceration of the left external iliac vein."²

Fracture of the lateral portion of the ring occurs in two principal forms, one in connection with fracture of the pubic portion, the other a fracture radiating from the cavity of the acetabulum. The former is the one to which attention was first called by Malgaigne under the title of *double vertical fracture of the pelvis*, a variety of which has been described at much length by Voillemier³ as *vertical fracture of the sacrum*. The posterior line of fracture lies either in the ilium entirely behind the acetabulum, or in the sacrum, or partly in the ilium or sacrum and partly in the sacro-iliac synchondrosis, and sometimes the sacrum is crushed rather than fractured. The cause apparently may

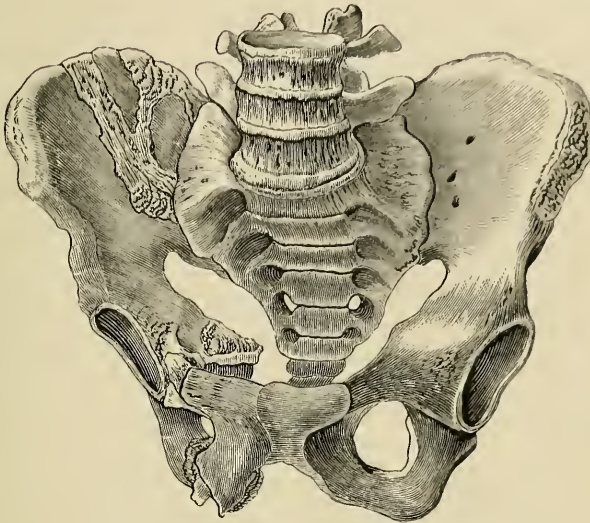
¹ Lancet, 1878, vol. i. p. 347, Case 2.

² Lancet, Idem., Case 3.

³ Voillemier: Clinique Chirurgicale, 1862, p. 77.

be a force acting in either the antero-posterior or transverse diameter of the pelvis or upward against the tuberosity of the ischium. The

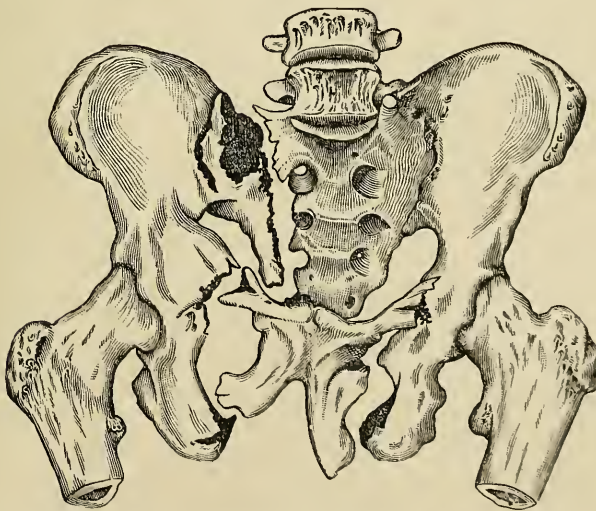
FIG. 170.



Double vertical fracture of the pelvis; united.

most prominent symptoms in these cases are in the position of the leg and in the extent to which it can be moved. The femur is attached

FIG. 171.



Double vertical fracture of the pelvis; vertical of sacrum, double of pelvis.

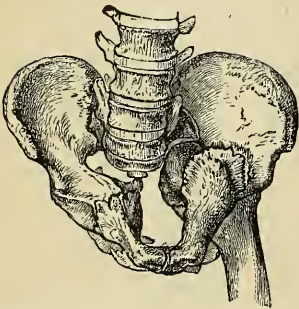
to the portion of bone which is intermediate between the two lines of fracture, and as this piece is usually displaced upward and inward

there is apparent shortening of the limb. At the same time the piece is commonly rotated about an antero-posterior axis so that the upper part of the pelvis is broadened and the lower part narrowed. The inability to move the limb is due in part to the lack of a solid support and the fear of pain, and in part perhaps to laceration of the muscles of the iliac fossa. Pain in the distribution of the obturator nerve is not uncommon. The prognosis is unfavorable (35 deaths in 106 cases, Dreschler) because of the probability of associated injuries. It may result in lameness or in a permanent change in the shape of the pelvis, which in a woman may have serious consequences if pregnancy should follow.

Walther¹ describes a variation in which the anterior fracture occupied the body and descending ramus of the pubis, and the second fracture ran below the anterior superior spine of the ilium to the sacro-sciatic notch; in addition the upper fragment of the ilium was split vertically, and the fifth sacral vertebra was broken. The fragment between the two principal lines of fracture was displaced inward and had reunited.

The second form of lateral fracture of the pelvis, *radiating fracture of the acetabulum*, is produced by violence acting through the femur, and is quite rare, although Dupuytren said he had met with it a number of times. The typical forms are: (1)

FIG. 172.



Head of the femur driven through the acetabulum.

(2) three or four fissures crossing the acetabulum and extending respectively through the ilium upward or backward into the sciatic notch and downward into the obturator foramen; (3) slight depression of the floor toward the abdominal cavity; and (4) the passage of the head of the femur into the pelvis through the broken floor. (See Guibé, *Revue de Chir.*, An. 24, No. I., and Thevenot, *ibid.*, No. II.) Dr. Agnew refers to a preparation in the collection of Dr. Neill in which the lines of fracture follow those of the embryonal division of the bone; the union is complete, and there is very little callus on the articular surface.

In the slighter forms the patients can sometimes walk, but usually the functions of the limb are much restricted. In the third form the symptoms have varied considerably in the different cases, and the diagnosis has not always been made during life. Sometimes there are outward rotation, fixation, and extreme pain on motion; in other cases the movements of the limb are quite free and painless within certain limits. Shortening is slight or absent, the trochanter is sunk, and there is absence of crepitus. Interesting fatal cases have been reported by Drs. Neill,² Sands,³ Lawson,⁴ and Holmes.⁵

A remarkable case, which will serve to illustrate the possibilities of

¹ Walther: *Soc. Anat.*, October, 1891.

² Neill: *Transactions of the College of Physicians, Philadelphia*, vol. ii. p. 267.

³ Sands: *New York Medical Record*, 1877, p. 93.

⁴ Lawson: *Lancet*, 1878, vol. i. p. 382.

⁵ Holmes: *British Medical Journal*, December 24, 1887.

repair, is one reported by Mr. Moore.¹ A man received a severe injury of the hip, thought to be fracture of the neck of the femur; he recovered and was able to walk with only a slight limp. At the autopsy several years afterward the injury was found to have been a fracture of the pubis, ilium, and acetabulum, which allowed the head of the femur to pass through into the pelvis, the trochanter resting against the acetabulum (Fig. 172).

Similar cases are reported by Lendrick and Morel-Lavellée.

Vertical fractures of the sacrum are not known except in connection with fractures of the pelvic ring at other points, as already mentioned. A few cases of very extensive injury have been recorded, extensive crushing and multiple fractures. All proved fatal.

Course and Prognosis. The course and prognosis in all these cases depend mainly upon the lesions associated with the fracture. The only additional point which requires mention is one referred to by Legros Clark, the tendency to suppuration in the loose connective tissue between the pubes and the bladder, especially after fracture of the pubis or separation of the epiphysis. The uncomplicated and simpler forms of fracture tend to easy repair, and even fractures that are very extensive are by no means necessarily fatal.

Diagnosis. The diagnosis is usually easy, but may be very obscure if the fracture is limited and without much displacement. The outline of the pubis should be carefully followed with the finger to detect irregularity or localized pain, and pressure should be made backward alternately with either hand upon the anterior portion of each ilium in the search for abnormal mobility and crepitus. In vertical fracture of the sacrum or in separation of the sacro-iliac synchondrosis displacement will change the position of the posterior spine of the ilium. In double vertical fracture the intermediate portion, which bears the anterior superior spine, is usually displaced upward, and the displacement is easy of recognition and can be diminished or perhaps reduced by traction upon the leg. Fissured fracture of the acetabulum would probably pass unrecognized, or at the most, be only suspected from the history of a fall upon the trochanter, knee, or foot with pain in the joint and the absence of dislocation or of fracture of the femur. Fracture of the acetabulum with displacement of the head of the femur into the cavity of the pelvis will probably be recognizable by palpation of the iliac fossa through the anterior abdominal wall or by digital or manual exploration through the rectum, and by the depression of the trochanter.

Treatment. In cases without much displacement rest in bed on the back is all that is required, aided in the multiple forms or in separation at or near the symphysis pubis by a stout girdle drawn snugly about the pelvis. Reduction of a fragment of the pubis may sometimes be made by digital pressure, and that of the intermediate fragment in double fracture by traction upon the limb aided by pressure with the finger from the vagina or rectum. In compound fractures loose fragments should be removed. Displacement of the head of the femur through the acetabulum may be corrected by traction upon the limb.

Treatment of the complications belongs more properly to the subject

¹ Moore: *Medico-Chirurgical Transactions*, vol. xxxiv. p. 107.

of general surgery, but the frequency of laceration of the urethra and the advantages of its early recognition and treatment are so great that it deserves mention. On the first indication of probable injury to the urethra the catheter should be introduced, and if its passage is prevented or even rendered difficult by injury to the urethra, an incision should be made through the perineum to the injured part cutting upon the end of the catheter as a guide. I have almost always found the membranous urethra not only torn across but also so freely separated by laceration of the soft parts amid which it lies that its recognition was difficult. It is so thin and collapsed and its torn end so shreddy that it can hardly be distinguished. For this reason it is desirable to make the incision with the aid only of local anæsthesia—cocaine or freezing—in order that the patient may aid the recognition by passing urine. If possible the two torn ends of the urethra should be united by one or two sutures along its roof so as to aid the permanent restoration of the continuity of the canal; and each torn end should be split for half an inch along the floor so as to avoid the cicatricial narrowing which follows circular division.

If the bladder has been ruptured, intra- or extra-peritoneally, suprapubic cystotomy may be needed to evacuate the escaped urine and close the opening or for drainage of the bladder. Permanent catheterization through the perineal opening may sometimes take the place of suprapubic drainage; it is not needed if the bladder is uninjured.

2. TRANSVERSE FRACTURE OF THE SACRUM.

This rare injury is produced by blows or falls upon the corresponding region, and appears in all cases to have occupied the lower half of the bone and to have been produced by the forcible bending inward of its apex. Its direction is practically transverse. Malgaigne has reported one case of oblique fracture; in it the violence was received upon the side of the bone, and there were also two incomplete transverse fractures.

The usual displacement is an angular one, the coccyx and lower fragment being drawn forward so that the apex of the angle is directed backward at the seat of fracture. The displacement is due in part to the fracturing force and in part to the action of the attached muscles. In a case that came under my observation at Bellevue Hospital there was extensive sloughing over the sacrum and denudation of the bone, apparently due to the direct violence that caused the fracture. The same complication is mentioned in two of the five cases collected by Malgaigne, both terminating fatally.

The symptoms are: pain at the seat of fracture, both spontaneous and provoked by pressure or movements of the trunk, or by the act of defecation, or perhaps by the act of coughing; the displacement if present; and abnormal mobility and crepitus recognized by grasping the lower fragment between the thumb and a finger introduced into the rectum.

Agnew¹ says "there will probably be present paralysis of the bladder and rectum, both of these organs receiving nerves from the sacral plexus," and Lossen² says that when there is complete displacement of

¹ Agnew: Surgery, p. 922.

² Lossen: Deutsche Chirurgie, Lief. 65, p. 7.

the fragment paralysis of the lower extremities, bladder, and rectum is never absent, but neither author quotes any cases in support of the statement. In the one case that has come under my own observation, there was almost complete paralysis of the lower limbs, bladder, and rectum, which nine months after the accident had been recovered from in great part.

In Bermond's case, quoted by Malgaigne, the fracture was near the coccyx, and the lower fragment was displaced so far forward that the finger could not be passed into the rectum until after a female catheter had been introduced as a guide. The pain was extreme, was relieved by the reduction of the displacement, and returned as soon as the finger was withdrawn.

Treatment. Unless there is marked displacement, no treatment is required beyond the use of pads or rings to relieve the lower fragment from pressure. In some cases the surgeons have sought to diminish the pressure by flexing the thighs and supporting them upon pillows piled up under the knees.

In two cases the surgeon has tried to make direct pressure upon the lower fragment by dressings introduced into the rectum. Judes, quoted by Malgaigne, used a cylinder of wood five inches long and one inch in diameter with graduated compresses outside and a T-bandage to support the whole. Bermond filled the rectum with a bag of lint, which soothed the patient's pain but had to be removed on the following day to allow the bowels to be emptied. He then used a shirted canula through which the gas and feces could be passed at will while the rectum was kept distended by the tampon. It was removed temporarily on the seventh day, and finally on the nineteenth, when abnormal mobility could no longer be detected.

3. FRACTURE OF THE COCCYX.

There is but little definite knowledge concerning this lesion. The first mention of it appears to be that of Cloquet in the statement that when in old people union has taken place between the different portions of the coccyx, and between it and the sacrum, the coccyx might be broken by a fall upon the buttocks or, as in a case which he had seen, by a kick upon the same part. He refers also to another case in which caries of the coccyx followed its fracture, but, as Malgaigne says, it does not appear that Cloquet verified the fracture. Within a few years several cases have been published, and it is furthermore possible that some of the cases described as dislocations of the coccyx or coccygodynia may have been fractures. None of the cases of fracture mentioned has been described with any details, and there is, therefore, nothing to be said except that the diagnosis must be made as after fracture of the sacrum, and that probably no treatment would be required except to reduce displacement. (See Dislocations of the Coccyx.)

Jolly¹ reported a unique case of escape of the lower segment of the coccyx through the anus ten days after delivery, the bone apparently having been broken at that time.

¹ Jolly : Medical Record, Dec. 17, 1887.

4. FRACTURE OF THE ILIUM.

Fractures of the expanded upper portion of the ilium are comparatively frequent and vary widely in their position and extent; the more extensive ones pass transversely or obliquely from before backward at some distance below the crest and are associated sometimes with vertical lines which divide the upper fragment into two or more portions. Malgaigne says that when the fracture lies near the crest it begins commonly at a triangular prominence on the crest near its middle, and runs thence backward or forward, or in both directions, following a curved line the concavity of which is directed upward. The fracture may be limited to a small portion of the rim of the bone, as the anterior superior spinous process or the outer lip of the crest. In a unique case observed by Hamilton, the posterior superior spinous process was broken off by a fall upon the back; and Riedinger and Linhart¹ have shown experimentally that the anterior inferior spinous process can be torn off by putting the Y-ligament of the hip-joint upon the stretch. In a case reported in the *Bulletins de la Société Anatomique*, 1867, p. 283, the anterior superior and inferior spinous processes were broken off while still in the condition of epiphyses by the passage of a wagon. The patient was fifteen years old.

The displacement is usually slightly outward, and forward when the line of fracture is below the anterior superior spine. Fragments of the crest alone may be markedly displaced upward, and after fracture of the anterior superior spine the fragment may be displaced downward.

Cause. The cause has heretofore been thought to be direct violence exclusively, but Hamilton reported a case of fracture by muscular action separating a piece of the crest three inches long and including the anterior superior spinous process. Nickerson² has reported another of the anterior superior spine with abstracts of four additional cases, and Whitelocke³ two others in lads eighteen and nineteen years old while running, and Albertin⁴ and Reverdin⁵ similar ones.

Symptoms. The usual signs of pain and swelling are increased by the associated bruising of the overlying soft parts; abnormal mobility and crepitus can be felt on manipulation at times, but their manifestation depends upon the position of the fragment, the posture of the patient, and the contraction or relaxation of the muscles. In a case under my care where a large fragment composed of the anterior half of the crest and the adjoining bone had been broken off by a fall, mobility and crepitus would at times disappear entirely, apparently in consequence of slight changes in the position of the fragment. In seeking for mobility and crepitus the abdominal muscles should be relaxed by bending the body forward and to one side, and the thighs should be flexed on the pelvis.

The patient is usually unable to walk, because of pain or of the sense of a lack of support.

¹ Linhart: Langenbeck's Archiv, vol. xx. p. 451.

² Nickerson: Deutsche med. Wochenschrift, March 6, 1890.

³ Whitelocke: Lancet, November 25, 1893.

⁴ Albertin: La Province Médicale, 1887, p. 741.

⁵ Reverdin: Centralblatt für Chirurgie, 1900, p. 352.

Course. The course is usually a simple one, and the patients are sometimes able to leave their beds in two or three weeks. In some very exceptional cases where the violence has been extreme fatal injury has been done to the viscera, such as perforation of the intestines by a splinter or laceration of the iliac veins; and suppuration has sometimes taken place.

Treatment. The treatment is simple, rest in bed in the position which gives most ease and is most favorable to the relaxation of the muscles which would be likely to cause displacement. The attempts that have been made in the few recorded cases of fracture of the spinous processes to keep them in place by pressure with pads and bandages have been entirely unsuccessful.

5. FRACTURE OF THE ISCHIUM.

This is one of the rarest of the fractures of the pelvis. Malgaigne collected only six cases, and the list has not been since increased by any reported in detail. In some of the cases almost the entire ischium was broken off, in others only the tuberosity. Experiment indicates that the fracture may pass into the cotyloid cavity. In three of Malgaigne's cases the cause was a fall upon the buttocks, the fourth was a gunshot fracture, the fifth was caused by an explosion, and the sixth was in a woman who had recovered from a double vertical fracture of the pelvic ring with a displacement that narrowed the inferior strait so much that two years afterward delivery could be effected only with the aid of forceps, and the ischium was broken in the effort. In two of the cases the fracture was comminuted, and in one of them also compound, in the other the scrotum was lacerated and the urethra torn, presumably by violence received at the same time upon the perineum and not by displacement of the bone. In the simple cases there was little or no displacement; in the gunshot fracture the fragment was displaced downward more than two inches by the contraction of the hamstring muscles. The displacement persisted, but does not appear to have interfered materially with the movements of the limb. All except the sixth recovered.

Mobility and crepitus can be recognized by manipulation of the bone, preferably with the finger in the rectum or vagina. The severity of the pain depends upon the violence and the associated injuries and makes it difficult for the patient to walk.

No treatment is required except rest in bed with pillows or air-cushions so arranged as to prevent pressure upon the broken bone. If the patient lies upon the side the knees may be kept flexed to relax the muscles which are attached to the ischium.

6. FRACTURE OF THE PUBIS.

In almost all cases of its fracture the pubis is so broken that the continuity of the pelvic ring is destroyed; the cases in which only one ramus has been broken or in which a lateral fragment has been broken off are extremely rare, and consequently there is but little to be added

to what has been already said in the first portion of this chapter. The only cases of this limited fracture of which I have any knowledge are one reported by Nivet and one by Cappelletti. In Nivet's¹ case, the account of which is not quite clear, there appears to have been a double fracture of the descending ramus, the intermediate piece was displaced forward and had torn the skin of the groin. In Cappelletti's² case a man jumped from a carriage, alighting upon his feet with one limb widely abducted. Six months afterward there was still some swelling at the anterior superior part of the right thigh, and a fragment of bone about two and a half inches long, and as large as the finger could be felt there. Cappelletti was convinced that this fragment was a portion of the descending branch of the pubis and the ascending branch of the ischium detached by muscular action. The pelvis appeared to be defective anteriorly at the point corresponding to the supposed original seat of the fragment, there was acute pain on pressure at the swelling and at the tuberosity of the ischium, the patient walked limping and with pain, and the pain was increased by abduction of the limb.

7. FRACTURE OF THE RIM OF THE ACETABULUM.

This is a lesion which sometimes accompanies partial or complete dislocation of the femur upon the pelvis.

The upper and posterior portion of the rim is the part most frequently broken, and the accompanying dislocation is commonly backward. In one of M'Tyer's cases³ there were two fragments, and in Maisonneuve's case three, but in this latter the fracture was much more extensive. In another case (M'Tyer) the fracture had united with but slight displacement, and the ligamentum teres was untorn.

The symptoms, when the case first comes under observation, are those of simple dislocation backward, and the complication of fracture is recognizable only by slight crepitus felt on manipulation or during reduction and by the easy recurrence of the dislocation after reduction. Sometimes the head of the bone slips out of its socket again as soon as the traction ceases, in other cases only after the lapse of a few hours or on movement of the limb or body.

Malgaigne calls attention to the necessity of making sure of the existence of a dislocation, and of not depending for the diagnosis solely upon crepitus and easy recurrence of the displacement, signs which may accompany fracture of the neck of the femur. The prominent distinction between dislocation backward and fracture of the neck of the femur is in the position of the limb, which is flexed upon the pelvis and rotated inward in the former, and usually straight and rotated outward in the latter, but this alone should not be depended upon, the position of the head of the bone should be made out.

The treatment should be directed to the prevention of a recurrence of the dislocation after its reduction. Continuous traction gave me a good result in one case, but theoretically abduction and extension of the limb should be maintained, as the attitude most opposed to recurrence.

¹ Nivet: Bull. de la Société Anatomique, 1837, p. 194.

² Cappelletti: Ranking's Abstract, 1848, vol. viii. p. 91.

³ M'Tyer: Glasgow Medical Journal, 1830.

CHAPTER XXIII.

FRACTURES OF THE FEMUR.

Fractures of the upper end: Head, neck, separation of epiphysis, through the trochanter and neck, great trochanter, trochanter minor. Of the shaft. Of the lower end: Intercondyloid, separation of epiphysis, either condyle.

THE table in Chapter I. shows 540 fractures of the femur in a total of 14,566 cases (3.7 per cent.). Those of the London Hospital for twenty-six years show 3243 in a total of 51,938, about 6 per cent. The Berlin and Halle records, quoted by Gurlt, show in totals of 232 and 97 fractures of the thigh, 76 and 21 of the neck of the bone respectively. The records of Bellevue Hospital for nine years, collated by Dr. F. E. Hyde,¹ contained 302 cases of fracture of the thigh, in which the position of the fracture was stated, divided as follows: neck 61, upper third (exclusive of neck) 34, middle third 169, lower third 31, of which 7 were of the condyles. Of 236 fractures of the thigh recorded by Hamilton, 84 were of the neck, 30 of the upper third, 86 of the middle third, and 36 of the lower third.

Malgaigne's analysis of 311 fractures (104 of the neck, 207 of the shaft) according to age and sex is as follows:

FRACTURES OF THE SHAFT.

Age.	Male.	Female.
2 to 20 years	35	12
20 " 40 "	47	6
40 " 60 "	43	15
60 " 80 "	20	29
	145	62 = 207

FRACTURES OF THE NECK.

Age.	Male.	Female.
4 to 50 years	9	5
50 " 60 "	9	10
Above 60 "	30	41
	48	56 = 104

1. FRACTURES AT THE UPPER END OF THE FEMUR.

In this class are included fractures of the head, of the neck of the femur, separation of the epiphysis, fractures of the great trochanter and separation of its epiphysis, fractures through the trochanter, and fracture of the trochanter minor.

¹ Hyde: New York Medical Record, 1875.

A. Fractures of the Head of the Femur.

The only reported instances of this very rare injury have been obtained in cases in which there was also dislocation backward of the head of the bone. Riedel (quoted by Hoffa) reported one, a boy fifteen years old who had been run over by a heavy wagon. The dislocated head was split by a line of fracture which also traversed the neck longitudinally, and the posterior portion of the rim of the acetabulum was crushed. The upper outer fragment and the trochanter were removed; the rest of the head was returned to the socket. Healing with ankylosis.

Braun¹ reported a similar case, the line of fracture running from the insertion of the ligamentum teres to the attachment of the capsule.

I showed to the New York Surgical Society² a specimen showing a crush of the anterior portion of the head one inch long, half an inch wide, and one-eighth inch deep, caused evidently by impact against an exostosis situated close behind the rim of the acetabulum; the injury closely resembled that occasionally produced in the head of the humerus in an anterior dislocation by impact against the edge of the glenoid fossa.

B. Fracture of the Neck of the Femur.

This is essentially a lesion of advanced middle life and old age, and, as the table given above shows, is more common in old women than in old men. Whitman³ has shown that it is more frequent in childhood than has heretofore been supposed, though still relatively rare, and Hoffa⁴ collected 78 cases; most of which were epiphyseal separations. It is often produced, too, by slight causes, such as a misstep, a stumble, a fall upon the knee or hip, and these two facts taken together indicate senile change in the bone as a markedly predisposing cause. Examination of the thigh bones of old people, those that have been broken and those that have not, bears out this indication, for it shows all the parts of the bone much rarefied, with thinning of the cortical shell and enlargement of the meshes of the spongy tissue.

Another reason for the greater frequency of these fractures in the old has been sought in a change alleged to take place in the angle at which the neck joins the shaft. It has been asserted that as the individual grows older this angle approaches a right angle, a position that would favor fracture, but examination has proved this not to be the rule. Rodet⁵ found the average angle in the child and adult 131 degrees, and in the old 128 degrees, a difference too small to deserve attention, especially since the limits between which the angle ranges normally are wide, 121 degrees and 144 degrees according to the same author. Similar findings have been published by others; on the other hand, Lauenstein found the angle changed.

Other points in the connection between the neck and the shaft require mention because of their influence in the production of the fracture and

¹ Braun: *Arch. für klin. Chir.*, July 15, 1892.

² Stimson: *New York Medical Journal*, August, 1889, p. 163.

³ Whitman: *Annals of Surgery*, June, 1897, and February, 1900.

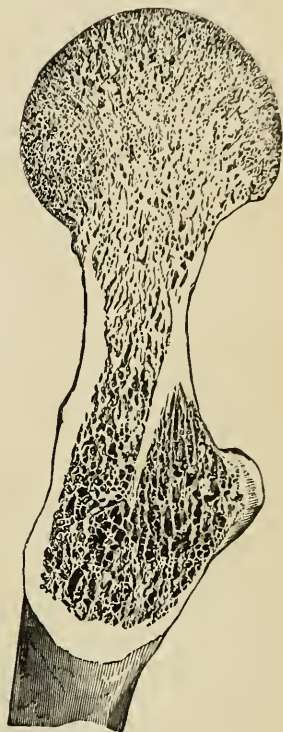⁴ Hoffa: *Zeitschrift für Orthopæd. Chir.*, vol. xi. part 3.

⁵ Rodet: *Thèse de Paris*, 1844, quoted by Tillaux and others.

in the character of the displacement. The antero-posterior diameter of the neck is much smaller than that of the shaft, and the two are so joined that a large part of the great trochanter lies behind the posterior wall of the neck, and, as shown by Prof. Bigelow,¹ it is traversed in part by a prolongation of the posterior wall of the neck (Fig. 173). This prolongation which Bigelow calls the true neck constitutes a vertical septum, "a thin dense plate of bone continuous with the back of the neck, and reinforcing it, plunging beneath the intertrochanteric ridge in an endeavor to reach the opposite and outer side of the shaft. At its lower extremity it curves a little forward so as to take its origin, when on a level with the lesser trochanter, from the centre instead of the back of the cylindrical cavity." The posterior part of the trochanter is therefore only an apophysis attached to the shaft for the insertion of the rotator muscles, and the mechanical function of the shaft and neck with reference to the resistance to strain is practically independent of it. The rarefying senile change affects this septum and may remove it so completely that it cannot be distinguished from the surrounding cancellous tissue.

The capsule is usually attached to the femur in front along the spiral line, above to the neck a little short of its junction with the trochanter, behind to the neck itself about half an inch from the intertrochanteric line, and below to the upper part of the lesser trochanter. In front and below, therefore, the neck lies entirely within the capsule, while above and behind, its outer third or fourth part is external to it. These limits vary somewhat in different individuals. The synovial membrane does not follow the capsule closely to its insertion, but is reflected early from it to the neck, leaving a strip of the latter between the points where it joins the capsule and the synovial membrane which although intracapsular is yet extra-articular. The periosteum is thick, and contains, especially in its upper portion, numerous bloodvessels which enter the head and neck by the large foramina found there. Of these vessels, one in particular, a branch of the internal circumflex artery, is of considerable size, runs along the upper portion of the neck and enters the head. Wilkinson King² long ago called attention to the fact that this portion of the periosteum is frequently left untorn in fracture of the narrow part of the neck, and suggested that this arterial branch might preserve the vitality of the head of the bone under

Fig. 173.



Neck of femur. (BIGELOW.)

¹ Bigelow: *The Hip*, p. 121.

² King: *Guy's Hospital Reports*, 1844, p. 347.

such circumstances. Later observations indicate that the vitality is preserved, and presumably by this agency, much more frequently than has long been supposed.

The division into *intracapsular* and *extracapsular* fractures, so long current and still so widely used, had its origin in important pathological differences, but it has proved unsatisfactory and misleading, partly because the two terms do not properly express these differences and, consequently, leave a large group—the “mixed” fractures, those in which the line of fracture lies partly within and partly without the capsule—to be classed sometimes with one and sometimes with the other, and partly because the associated theory that repair was impossible after intracapsular fracture, although subsequently abandoned by its author, Sir Astley Cooper, and many times disproved, has clung to it in many minds until the present time. The breaking away from this classification which has appeared in so many of the systematic writings of the last thirty years is largely due to the late Professor Bigelow who suggested the terms *fracture at the narrow part of the neck* and *fracture at the base of the neck*. These have the disadvantage of being rather cumbrous and of unduly limiting the seat of fracture in the former, for which, therefore, it seems to me advisable to substitute the term *fracture through the neck*. An alternative measure recommended by some (most recently Sir William Stokes¹), of *fracture of the neck* for the former and *at the base of the neck* for the latter, is open to the objection that the first is also habitually used for the injury as a whole and is, therefore, liable to be misunderstood when used as meaning either more or less than was intended. Kocher's² recently proposed *fractura subcapitalis* for the first finds some favor, but *fractura intertrochanterica* and *fractura pertrochanterica* for the latter do not seem likely to be acceptable.

The importance of the distinction in prognosis and treatment is certainly not so great as has been alleged, nor is the presence or absence of so-called impaction. The capital point in prognosis—the degree of vitality of the upper fragment—apparently depends not upon impaction nor upon the situation of the fracture, but upon the preservation of the vascular supply furnished by the vessels which approach the bone near the insertion of the capsule and run to the head in the thick periosteum of the neck. In fractures at the base of the neck these vessels are not much injured, and in fractures at the narrow part of the neck the continuity of the periosteum and the included vessels appears to be sufficiently preserved in many, perhaps most, cases to maintain the vitality of the fragment. The number of specimens of bony union after undoubted fracture at the narrow part of the neck is not only large enough amply to demonstrate the possibility of such repair, but also, in comparison with those of failure of union and in connection with clinical results, to indicate that such union is probably common under appropriate treatment and in the absence of injudicious movements at first which may destroy the connection left by the fracture. Moreover, it is clinically impossible positively to distinguish between

¹ Stokes: British Medical Journal, October 12, 1895.

² Kocher: Praktisch wichtiger Frakturformen, 1896.

many of these fractures at the narrow part of the neck and those at the base in which there is little or no injury to the adjoining part of the shaft and its periosteum.

It therefore seems to me unwise to make a sharp distinction between the two forms and to urge, as some do, that fractures of the narrow part of the neck, or intracapsular, should be deemed from the first incapable of union and treated accordingly. I think, on the contrary, that union should be sought in all cases and almost always by the same methods and that the diagnostic differentiation at the outset, therefore, is rarely of practical importance in treatment, although affecting prognosis. Although the distinction must be preserved in the description of the forms of fracture (I shall use the names *fracture through the neck*, or *subcapital*, and *fractures at the base of the neck*), the sections on symptoms and treatment will treat of them jointly.

Causes.

An important predisposing cause has been mentioned, the senile rarefaction which begins usually after the fiftieth year and is more marked in females than in males.

The common cause in the old is a fall to the ground while walking; occasionally a stumble or a misstep with an effort to avoid a fall, or the jar occasioned by stepping down to a slightly lower level than was anticipated.¹ In the young and young adults the cause is usually much greater violence, as in a fall from a height, but reports of cases are accumulating which indicate that a perhaps notable proportion of injuries caused by moderate violence and deemed sprains or contusions of the hip are fractures, incomplete or without separation.

It is probable that the strain exerted through the ligaments in extreme positions of the limb is a more frequent cause of fracture than is generally supposed, and that the fall is sometimes the consequence rather than the cause. A number of cases are on record in which the bone has been broken in this manner, and by efforts so slight in some of them that they might easily have been overlooked if a fall had been associated with them, and experiment upon the cadaver confirms the opinion. The efforts which have been made to explain different varieties of fracture by differences in the direction of the blow or in the point at which it has been received have not been satisfactory either as a demonstration or as an aid in diagnosis. Few patients are able to tell exactly how they have fallen, and even if they could do so there would still be enough uncertainty concerning the extent to which the position of the limb had intervened to vitiate the conclusions that might otherwise be drawn from the circumstances of the fall. On the cadaver the bone can be broken at the narrow part of the neck by a blow on its head, or on the knee when the limb is somewhat abducted, and at the base of the neck by a blow upon the trochanter, if the cadaver is that of an old person; and it is

¹ For illustrative cases of fracture by slight causes and of experimental fracture see previous editions and Cooper, loc. cit., pp. 155 and 157; Earle, Practical Obs. on Surg., 1822, p. 20; Malgaigne, loc. cit., vol. i. p. 666; Linhart, Deutsche Gesellschaft für Chir., 1875; Riedinger, Centralblatt für Chir., 1875, p. 817; Stetter, Idem, 1877, p. 561.

comparatively easy to break the bone in the old, either at the base or at the narrow part of the neck, by abduction, adduction, or rotation. In some of the fractures produced by strain through the ilio-femoral ligament (by hyperextension and abduction) the break takes place outside the attachment of the ligament along the spiral line and the ligament remains attached to the upper fragment. In others with apparently the same mode of production the fracture is through the narrow part of the neck.

Muscular action may be a cause by producing a forced position of the limb in which the capsule, and especially the Y-ligament, is put upon the stretch, the mechanism then being the same as when the corresponding position is given by an external force.

Pathology.

The line of fracture may lie at any point between the junction of the head and neck and the base of the neck, and in the latter case it may be associated with more or less splitting of the trochanter and adjoining shaft, or it may pass (rarely) from the lower part of the junction of the neck and shaft transversely to the outer side. Fractures at a somewhat lower level, below the trochanter minor, will be considered among fractures of the shaft. There are, therefore, to be considered here fractures through the neck, fractures at the base of the neck with or without splitting of the trochanter, separation of the epiphysis, and fracture through the trochanter.

(a) **Fractures Through the Neck.** (Intracapsular fracture, subcapital fracture.) The frequency of these fractures has been thought to increase with advancing age after sixty years, but the facts upon which the opinion rests are mainly clinical and, therefore, not entirely trustworthy.

The line of fracture may be transverse, oblique, or irregular; it may lie close to the head or at some distance from it, or may (rarely) pass slightly into the head itself. In a few old specimens the appearance suggests that the line of fracture was incomplete on one side, but as the head in such cases shows a well-marked angular displacement it is probable that the fracture was complete with bending but no other displacement at the apparently continuous portion and crushing elsewhere. The surface of fracture is frequently irregular, but sometimes uniform and sometimes smooth or irregular on the side of the head while the neck on the other side is crushed or comminuted (Fig. 174).

Angular deviation at the fracture is the rule, the apex of the angle being usually directed forward and upward, and is habitually effected by crushing of the bone or by penetration of one fragment into the other. This penetration or impaction is rarely more than a simple interlocking of the irregularities of the surface, although Bigelow¹ reported one in which considerable force was required to separate the fragments; possibly the fixation was due to incompleteness of the primary separation at some point on the periphery, as in the so-called "incomplete" fractures (Fig. 175).

¹ Bigelow: *Loc. cit.*, p. 131.

The periosteum of the neck appears usually to remain unbroken over a portion of the periphery, and may even be complete, as in cases reported by Mayor¹ and Stanley.² In one of my specimens the unbroken portion is nearly an inch wide and is situated at the lower and posterior portion of the neck; in another it was broadly preserved in three bands; in other reported cases it has been behind, behind and above, and above and in front. If the primary displacement is great, or if it is increased by an attempt to bear the weight upon the limb, the rupture may be or may become complete and the fragments may be widely separated, both of which circumstances would seriously affect the prognosis; under similar circumstances the capsule may be torn.

FIG. 174.

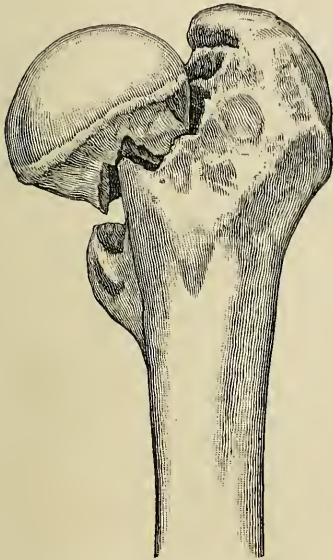
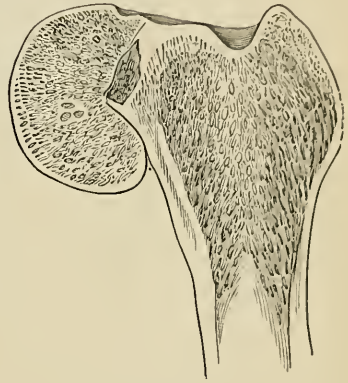
Fracture through the neck of the femur. (*F. sub-capitalis*.) (KOCHER.)

FIG. 175.



So-called "incomplete" fracture of the neck of the femur. (KÖNIG.)

(*b*) Separation of the epiphysis has been demonstrated by specimen in a few cases and suspected in a number in which fracture of the neck has occurred in the young, but there is reason to believe that it is rarer even than fracture at the corresponding age. The conjugal cartilage immediately adjoins the head, and bony union takes place between the seventeenth and twenty-first years. The first case verified by direct examination was reported by Bousseau.³ The patient was fifteen years old, and was run over by a wagon. The symptoms were shortening, eversion, and inability to move the limb. The patient died in a few hours. The separation was complete along the epiphyseal line, and the head was attached to the neck only by a strip of periosteum two

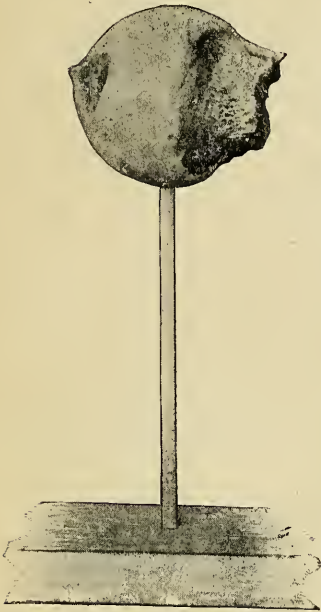¹ Mayor: Gazette Médicale, 1834, p. 612.

² Stanley: Medico-Chirurgical Transactions, 1825, vol. xiii, p. 511.

³ Bousseau: Bulletin de la Société Anatomique, 1867, p. 283.

millimetres wide. The periosteum was stripped up on the inner and lower part of the neck, and the capsule was torn at its inner portion.

FIG. 176.

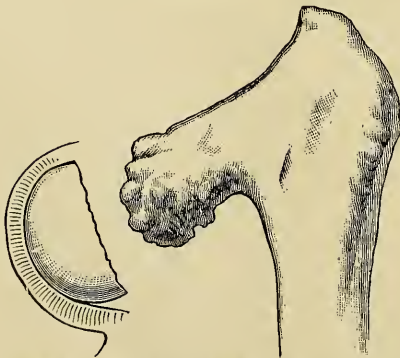


Fracture through the neck in a boy eight years old. (BOLTON.)

Kocher¹ reports two. The first is that of a girl sixteen years old, who fell while walking and struck upon her right trochanter. On the theory that if the injury, as supposed, was a fracture through the neck (or separation of the epiphysis) repair was impossible, an operation was done three weeks later for the removal of the upper fragment. A fracture, hidden by the untorn periosteum, was found along the epiphyseal line, with penetration of the posterior part of the neck into the head; the latter was removed; recovery with ankylosis.

The second case was that of a girl, who, when ten years old, fell from a height; she rose and walked a short distance, was then unable to use the limb because of pain, and was taken to a hospital. After apparent recovery she walked with a limp which increased as time passed. Four years after the accident Kocher found shortening of three centimetres, outward rotation, and marked diminution, active and passive, of motion in the hip-joint. The condition found at the operation is shown in Fig. 177; the head was so tightly fixed in the acetabulum that it was removed with difficulty; the neck was bent sharply downward with an irregular,

FIG. 177.



Separation of the epiphysis; old. (KOCHER.)

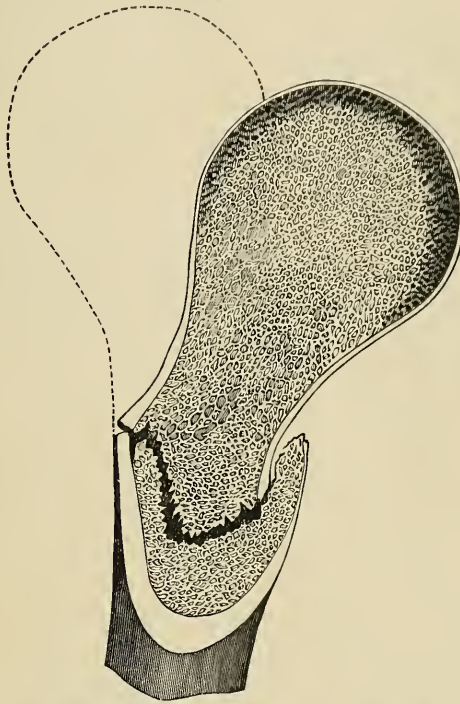
knobbed end covered with fibro-cartilage; the end was placed in the

¹ Kocher; *Praktisch wichtiger Frakturformen*, 1896, pp. 238 and 243.

acetabulum and the limb fixed in abduction and inward rotation. The history ends with the recovery from the operation.

Poland¹ reports a personal case verified by operation and quotes two others, and Whitman² reports one in which the injury was caused by forcible abduction of the thigh in a lad sixteen years old,

FIG. 178.



Impacted fracture at the base of the cervix femoris, with bending of the head backward. (BIGELOW.)

the diagnosis being confirmed by a skiagram taken three weeks after the accident. He thinks the separation is often only partial, the symptoms at first being a slight limp with some stiffness and pain, and later, after some slight violence, those of fracture. In two cases he corrected the displacement through an anterior incision. Ramstedt³ thinks that nearly all injuries of the neck of the femur in patients less than eighteen years old are separations of the epiphysis and that coxa vara is a frequent result.

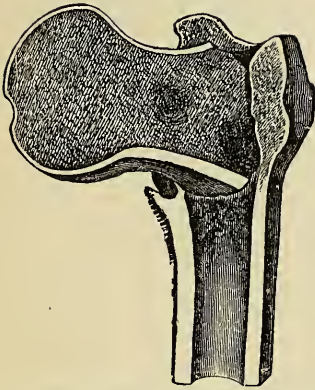
(c) **Fractures at the Base of the Neck.** (Extracapsular and "mixed" fractures.) The line of fracture follows ordinarily the junction of the neck and shaft quite closely—that is, it coincides with the spiral line in front and the intertrochanteric line behind as they pass between the great and lesser trochanters. It may extend downward and detach the

¹ Poland: "Traumatic Separation of the Epiphyses," p. 628.

² Whitman: *Annals of Surgery*, February, 1900, p. 151. See also *Med. News*, September 24, 1904.

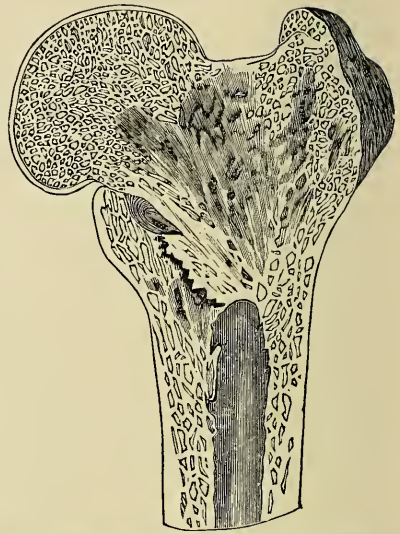
³ Ramstedt: *Arch. für klin. Chir.*, vol. lxi, part 3.

FIG. 179.



Impacted fracture of the neck of the femur without splintering. Vertical section.

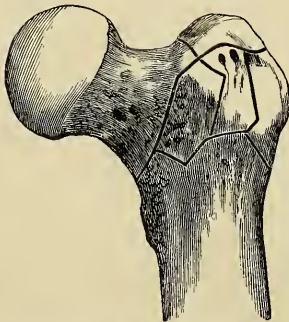
FIG. 180.



Repair after fracture of the neck of the femur. (LOSSEN.)

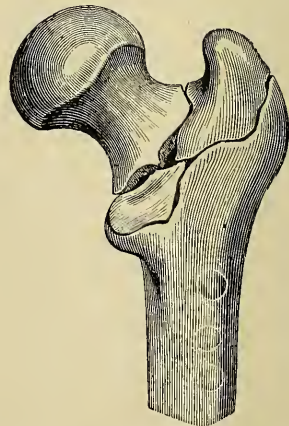
lesser trochanter from the shaft, leaving it attached to the neck, or go even lower and separate a part of the shaft. At its upper part it may

FIG. 181.



Comminuted fracture of the neck of the femur. Anterior aspect.

FIG. 182.



Fracture of the neck of the femur with splitting of the great trochanter.

deflect to either side, crossing the outer part of the neck or traversing the great trochanter, in the latter case passing quite beyond the limits of the neck.

In the majority of cases other lines of fracture traverse one or both trochanters, splitting off one or two pieces, usually from the posterior surface of the great trochanter, or comminuting it completely. Malgaigne thought that simple fracture, division into only two fragments, was exceedingly rare; the only case of which he knew, excluding two

FIG. 183.

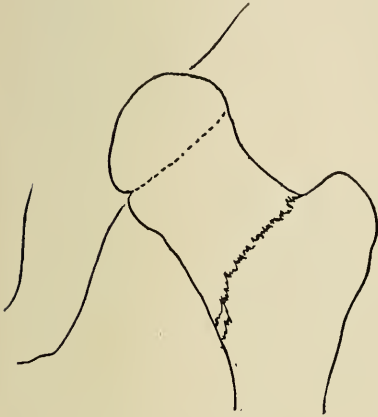


FIG. 184.

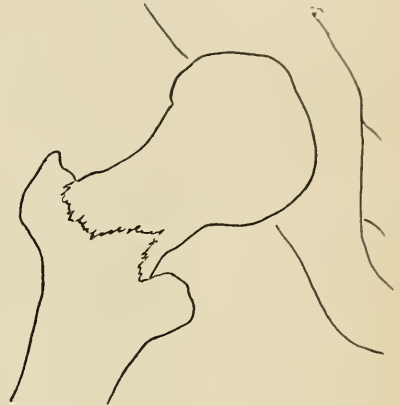

FIG. 185.

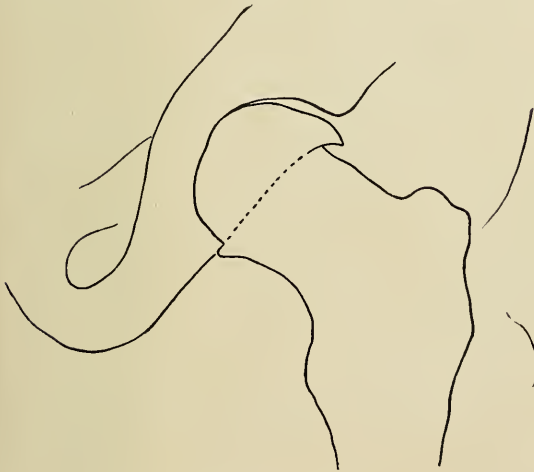
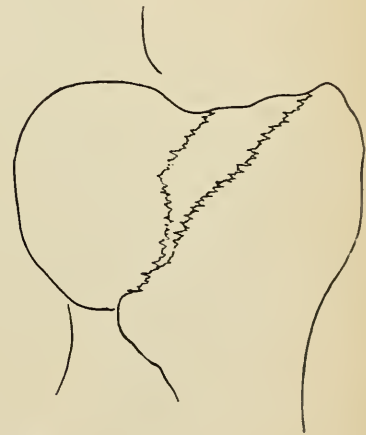


FIG. 186.



FIGS. 183-186.—x-ray tracings of fracture of the neck of the femur.

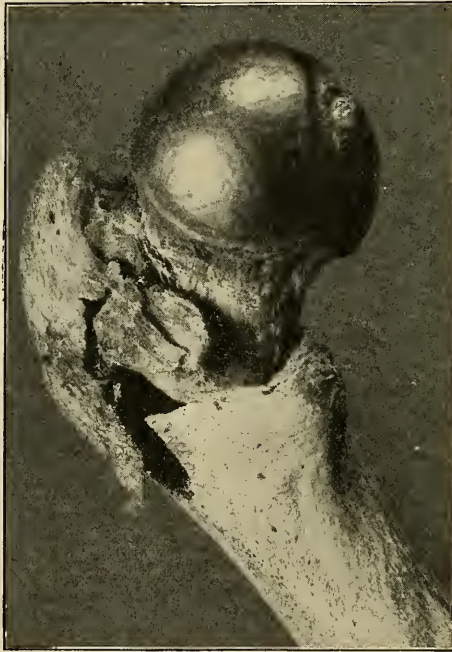in which the fracture crossed the trochanter horizontally, was one described by R. W. Smith,¹ and, as even in this two fragments are broken off the trochanter behind, it is evident that he believed considerable comminution to be the rule. Hamilton refers to two similar specimens, one in Dr. Mütter's, the other in Dr. Neill's collection; in one of my own specimens there was no splintering, and in another the

¹ R. W. Smith: *Loc. cit.*, Case 34.

fracture was almost identical with the one quoted by Malgaigne from Smith.

The common fracture is that in which the neck is bent backward with crushing of the posterior part or penetration of the neck into the trochanter. Prof. Bigelow¹ directed especial attention to this bending backward and impaction (Fig. 178) as the important features of the most common form of fracture in this region, the symptoms of which are pain and tenderness, disability, shortening and eversion, however slight, absence of crepitus, and rotation of the trochanter about the head of the bone as a centre, and he described the displacement as a rotation of the head and neck backward and downward upon the

FIG. 187.



Comminuted fracture at the base of the neck of the femur.

portion of the anterior wall corresponding to the spiral line uniting the trochanters as upon a hinge. This displacement accounts for the eversion and slight shortening.

A certain amount of misapprehension has resulted from the use of the word *impaction*. Impaction, in the sense of penetration and fixation, is, I think, uncommon; while crushing, with or without penetration or much splitting of the trochanter, is the rule. The penetration or crushing may be limited to the posterior part (this, as has been said, is the most common condition), or the neck may turn upon its upper portion, making that the hinge, and sink its anterior, posterior, and lower walls into the substance of the trochanter, or the neck may be

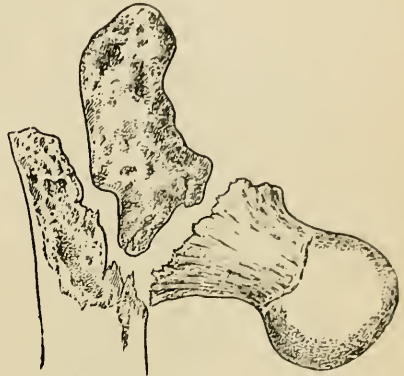
¹ Bigelow: *The Hip*, p. 118, and *Boston Medical and Surgical Journal*, 1875, vol. xcii. pp. 1, 29.

driven bodily into the trochanter without much change of direction, and may even penetrate to the opposite wall. In exceptional cases the lower fragment may penetrate the upper one.

The splitting of the trochanter may be limited to one or two pieces broken off its posterior border (Fig. 182), or it may be very general (Fig. 187). The extent of the splitting seems to be independent of the force that caused the fracture, extensive comminution being sometimes produced by a simple fall while walking, as in Fig. 181, which is drawn from one of my own specimens. Occasionally the unbroken trochanter may be wholly detached from both neck and shaft (Fig. 188).

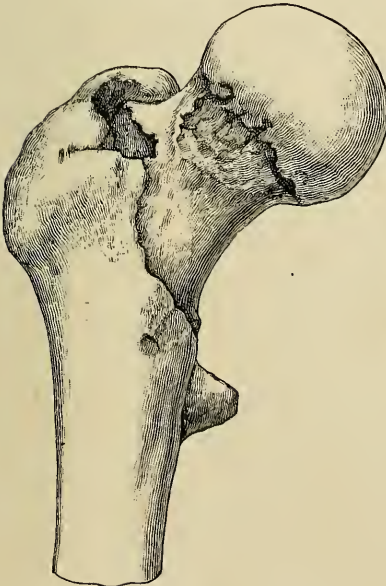
In a few cases the angular displacement of the neck has been in the opposite direction, so that the limb has been rotated inward instead of outward. R. W. Smith¹ describes one such specimen, and Bigelow²

FIG. 188.



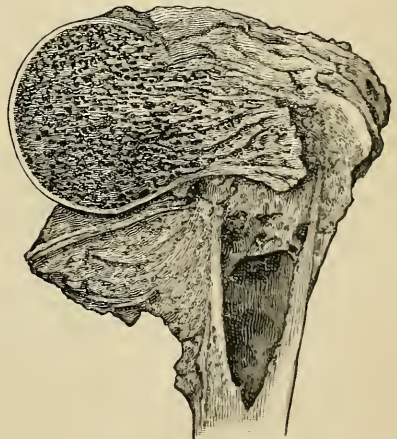Total separation of great trochanter. (FRANGENHEIM.)

FIG. 189.



Fracture of the neck of the femur in abduction. (KOCHER.)

FIG. 190.



Fracture of the neck of the femur in adduction. (KOCHER.)

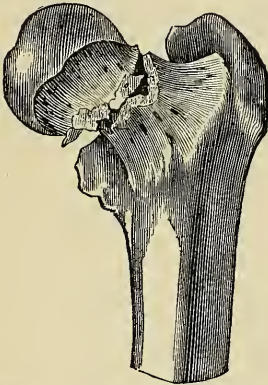
another. In a number of cases inversion has existed when the fragments were not interlocked.

¹ R. W. Smith: *Loc. cit.*, p. 128.

² Bigelow: *Loc. cit.*, p. 128.

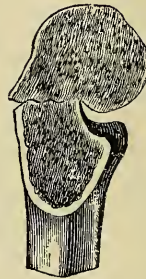The angular displacement of the neck and the form of the fracture appear to be connected with the mode of production of the fracture and the attitude of the limb at the moment of fracture; thus, if the limb is extended and rotated outward or abducted the anterior portion of the capsule is tense and the posterior portion of the neck is driven into the trochanter (Fig. 189); if the limb is strongly adducted the deep penetration is found especially at the inferior portion of the neck (Fig. 190).

FIG. 191.



Pure intracapsular fracture of the neck of the femur. Bony union. (GURLT.)

FIG. 192.



Oblique section of the specimen shown in Fig. 191. (GURLT.)

The capsule is sometimes torn so that the cavity of the joint is opened; the laceration of the periosteum and adjoining soft parts varies with the extent of the comminution and crushing.

Repair. ✓

The question of the extent to which repair is possible or probable after fracture through the neck is important because of its bearing upon treatment. If reunion is possible an effort to obtain it should be made, in the absence of controlling contraindications; if it is impossible or even improbable, treatment must be directed to obtaining the best functional result compatible with such failure.

That repair is possible is abundantly proved by specimens, even if we disregard those in which any question can be raised as to the character of the injury or the exact situation of the fracture. Such illustrative specimens are those of Stanley,¹ Swan,² Gurlt³ (Figs. 191 and 192), Brulatour,⁴ Cushing,⁵ Humphry,⁶ Raven,⁷ and Kocher⁸ (Fig. 193).⁹

¹ Stanley: *Medico-Chirurgical Transactions*, 1833, vol. xviii. p. 256.

² Swan: Quoted by R. W. Smith, *Fractures in the Vicinity of Joints*, p. 59.

³ Gurlt: *Knochenbrücheu*, vol. i. p. 308.

⁴ Brulatour: *Medico-Chirurgical Transactions*, 1825, vol. xiii. p. 513.

⁵ Cushing: Quoted by Bigelow, *The Hip*, p. 133. ⁶ Humphry: *Lancet*, August 2, 1890.

⁷ Raven: *Ibid.*, 1887.

⁸ Kocher: *Loc. cit.*, p. 206.

⁹ For other cases and details the reader is referred to the first edition and the bibliography in it, page 499.

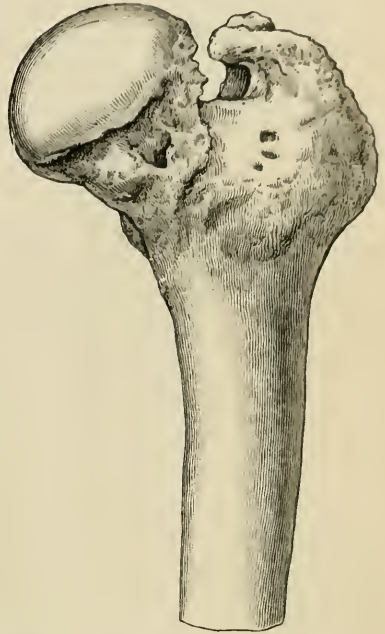
They include patients of ages varying from eighteen to eighty-one years.

Other specimens show close fibrous union (Figs. 194 and 195); and others in which no form of union had taken place show eburnation of the head and other changes which demonstrate the preservation of its vitality. After fibrous union or failure of union the capsule usually thickens and sometimes becomes closely adherent to the periosteum lining the neck, thus obliterating all the outer portion of the original cavity of the joint. This was the condition in two cases reported by Colles,¹ and there was actually a false joint between the fragments, the surface of the lower one being hollowed out to receive the upper. The process of repair has been minutely studied by Frangenheim.² He found that the periosteum of the neck forms little or no callus, so that union after subcapital fracture must be effected, if at all, by the spongy tissue. Fibrous union may be close and firm. Absorption of the neck may take place very promptly; he thought it occurred only after subcapital fracture. Occasionally the opposing surfaces of head and neck become eburnated and a nearthrosis is formed. He quotes with approval Gurlt's statement that fracture of the neck of the femur is the slowest of all fractures to heal, and gives a case of deeply impacted fracture at the base, in which union after eight and one-half months was still fibrous, although so firm that it was thought to be bony before the specimen had been sawn.

Some specimens of failure of union show entire disappearance of the neck, the head remaining in the acetabulum and presenting a smooth uniform surface; there is a similar smooth surface on the mesial aspect of the shaft at the place corresponding to the base of the neck (Fig. 196). The situation of the fracture in such cases cannot be positively known; the neck has disappeared by crushing and rarefaction, and this presumably can happen after either form of fracture.

Some specimens with union show an almost equal absence of the neck; in some, as shown in Fig. 180, the neck still exists, but has been driven into the trochanter; in others it has disappeared in great part, presumably by crushing and rarefactive osteitis, and it is difficult or impossible exactly to determine the primary position of the fracture.

Fig. 193.



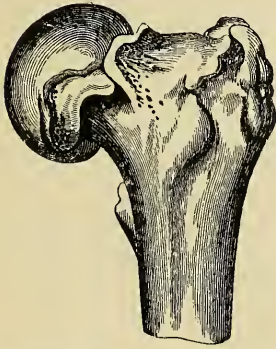
Bony union after fracture through the neck.
(*F. subcapitalis.*) (KOCHER.)

¹ Colles: Dublin Hospital Reports, vol. ii. p. 334.

² Frangenheim: Deutsche Zeitschrift für Chir., 1906, vol. 83, p. 401.

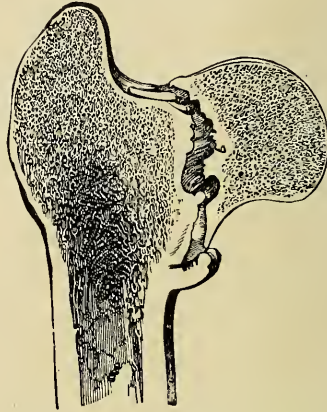These latter specimens are of special interest because they have been used to support the theory that interstitial absorption of the neck may

FIG. 194.



Fracture within the capsule; fibrous union.
(SMITH.)

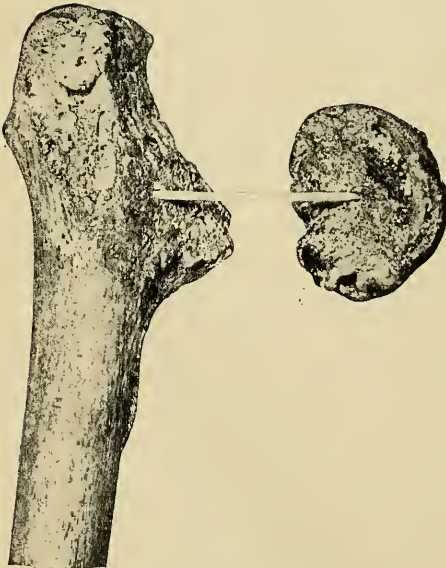
FIG. 195.



Fracture within the capsule. Close fibrous union.

be caused by a contusion, without fracture, and that thus may be gradually produced a deformity clinically identical with that following fracture. I have given elsewhere¹ reasons for

FIG. 196.



Fracture with absorption of the neck.

deeming this theory incorrect and for believing all such alleged cases to be those of unrecognized fracture.

Other specimens, and they are numerous, show an abundant production all about the trochanter and upper end of the shaft. In part this enlargement is due to splitting and displacement of the fragments, but the greater part of it is new bone produced subperiosteally, or, more probably, by ossification of the attached fibrous and tendinous tissues. This is especially common at the back, along the intertrochanteric line. Sometimes these masses so embrace the end of the

ununited upper fragment (neck) that the patient can walk well without the aid of cane or crutch (Fig. 197).

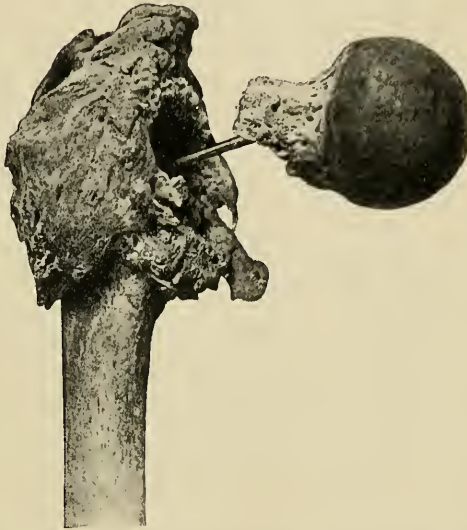
¹Stimson: "Doubtful Fractures of the Neck of the Femur and their Identity with an Alleged Form of Arthritis Deformans," *New York Medical Journal*, April 14, 1888.

The cavity of the joint is sometimes diminished by an adhesive synovitis which, aided by peri-articular thickening and retraction and by the above-mentioned osteophytic growths, greatly restricts its mobility.

Occasionally the limb, after either form of fracture, remains useless, and much pain is felt, especially if union has failed; and there are a few recorded cases in which suppuration has occurred within or without the joint.

The degree of probability of bony union after fracture *through the neck* could be determined only by the statistics of a series of continuous

FIG. 197.



Fracture of the base of the neck. Exuberant callus and interlocking of the fragments that permitted fair use of the limb, notwithstanding failure of union.

cases. The collation of reported cases is not sufficient because it is certain that the proportion of failures of union therein would be disproportionately large; the examination post mortem of the part is more likely to be made if the patient remains disabled until death than if he has regained use of the limb. Most of the specimens we possess of bony union have been obtained from patients who died from some intercurrent cause within a comparatively short time after the accident, while its memory was still fresh.

Clinical statistics are untrustworthy because of uncertainty as to the exact situation of the fracture and as to the extent and character of the repair. In respect of the latter it is to be borne in mind that some patients have been able to make fair use of the limb even when union had entirely failed, and that others (after fracture at the base of the neck) have been able to make even less use although bony union had taken place. Good union in the young seems, on clinical evidence, to have been frequent.

The facts in our possession are: (1) that bony or close fibrous union after fracture *through the neck* is possible; (2) that the preservation of

enough of the periosteum of the neck to make a vigorous vitality of the head probable is probably common; and (3) that the primary displacement usually does not separate the fractured surfaces, so that if it is not increased by early attempts to use the limb or, more rarely, by the action of the muscles in the absence of proper retention, the conditions for reunion are favorable. We also know that fair usefulness of the limb, even after union has failed, is possible; and it has not been proved that this usefulness is greater or more probable if the attempt to secure union has not been made.

Symptoms and Diagnosis.

The symptoms of the fracture and the signs upon which the diagnosis must be made include not only the usual objective and subjective symptoms of fracture but also the history of the case, the nature of the violence, and especially its slight degree, which so often characterizes this injury.

Interference with Function. As a rule the patient is unable to use the limb, and he is not merely unable to bear his weight upon it, but he cannot even move it in bed. Exceptions to this have been already mentioned, and it is not particularly uncommon to see patients who, while lying on the back, can slowly flex the thigh upon the pelvis either by its muscles alone or with the aid of the hands, but they cannot raise the foot from the bed, the knee bends at the same time and the foot is drawn up toward the body. Most authors have mentioned cases in which the patients have walked for longer or shorter distances immediately after the injury, and in which the existence of a fracture has subsequently become very clear. This is very exceptional, and it is sufficient to bear the possibility in mind to avoid the error of inferring that a fracture cannot be present because the patient is or has been able to use the limb. Frangenheim (*loc. cit.*, p. 449) reports one fifty-seven years old, who walked to the hospital fourteen days after the accident and complained only of slight pain in the hip. At her death, three weeks later, the fracture was found to be at the junction of head and neck with sharp angular displacement, apex forward. In the slighter cases in the young the patients have sometimes walked for several days before shortening and disability suddenly appeared. See Blecher (*Deutsche Zeitschrift für Chir.*, vol. 77, p. 302) for four such personal cases; the patients were twenty and twenty-two years old, and the fracture at the middle of the neck.

The opposite error, that of supposing a fracture to exist because the limb has been disabled by a fall, can be easily made, because a simple contusion may cause eversion of the limb as well as ecchymosis and swelling, and in some cases fracture causes no other symptoms than these. Observation of the case for a few days will make the diagnosis clear. Whitman (*loc. cit.*) claims that in the young the disability is usually much less than in the old, and that in many instances the patients are able to walk after a few days.

Pain is always present. It is usually slight, or even absent, when the patient is at rest, but is readily excited by even slight communicated or voluntary movements. It is referred sometimes to the region

of the trochanter, sometimes to the groin or inner and upper portion of the thigh. Sometimes pressure with the end of the finger detects a particularly sensitive point in the line of the neck in front just outside the great vessels, or at the corresponding point behind. Forceful pressure upward against the foot or inward against the trochanter frequently fails to cause pain.

The posture and appearance of the limb are so characteristic that it is sometimes almost safe to make the diagnosis by simple inspection. As the patient lies upon his back the affected limb appears shorter than the other, everted, and slightly flexed and abducted, and conveys an impression of helplessness that is often very striking. The upper portion of the thigh is swollen in front and on the outer side, and ecchymosis sometimes appears after a day or two. The greater the shortening the more marked is this swelling.

Eversion may be so marked that the foot rests entirely upon its outer border as the patient lies upon the back. In other cases it is so slight that, as Prof. Bigelow has pointed out, it is best recognized by comparing the extent to which the two feet can be *inverted*.

In exceptional cases the limb is *inverted*; it is either found so on the first examination or it becomes so after a day or two.

The cause of the eversion is probably almost always mechanical; it is largely the effect of gravity acting upon the limb under changed conditions of support. It is favored by angular displacement at the fracture. On the other hand, eversion has been observed in cases of simple contusion, and in others of fracture in which there was no displacement of the fragments, no rupture of the periosteum even, and consequently no loss of support. When one lies upon his back a distinct, although slight, effort is required to keep the toes upright; the natural tendency of the limb is toward eversion, particularly if the knee is slightly flexed, and this tendency which is increased by anything that diminishes the activity of the muscles must be taken into account in those obscure cases where the diagnosis lies between a contusion and a fracture.

The cause of inversion is not so clear. Smith attributes it to the position of the fragments relative to each other, and says that in all the cases of inversion which he was able to examine post mortem he found the lower fragment in front of the upper one. This, however, does not always explain the symptom when the fracture is of the narrow part of the neck, intracapsular, although it may do so in some, as in the case observed by Goyrand¹ where the neck had slipped behind the head and was fixed between it and the capsule.

The diagnostic value of the posture of the limb, as regards eversion or inversion, is not very great, for inversion is a symptom that needs, as it were, to be explained away, and eversion may be due to a simple contusion. In order to estimate the degree and persistence of the eversion the patient should be placed flat upon his back with the thigh and leg extended. A comparison with the other foot will then show the degree of the eversion, and gentle efforts to rotate the limb will show to what extent and in what manner the movements are restricted.

Shortening of the limb is produced either by alteration of the angle

¹ Goyrand : Dict. Encyclopédique, art. Cuisse, p. 239.

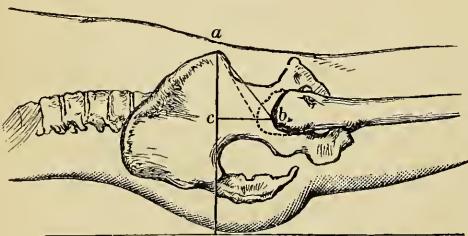
between the shaft and the neck or by overriding, and may vary in extent from a small fraction of an inch to two or three inches. It may be present at its maximum immediately after the accident, or it may be absent at first and appear gradually or suddenly after the lapse of a few hours or days, or may increase gradually or suddenly. It is usually held that when the fracture is of the narrow part of the neck (intracapsular) the shortening is absent or slight at first, increases more or less gradually, and never exceeds one and a quarter inches; and gradual increase in the amount of shortening is claimed by some to be pathognomonic of this variety of fracture. These statements are true only as an expression of the average condition; in exceptional intracapsular cases the shortening may exceed this amount, and in fractures at the base of the neck it may increase gradually in the same manner. Dietzer (*Deutsche Zeitschrift für Chir.*, vol. 64, p. 63) reports a unique case of lengthening, 2 cms.

In measuring the limbs care must be taken to have them form the same angle with the pelvis, that each is in the same position of extension and abduction. If the injured limb cannot be brought parallel to the median line of the body the other must be abducted to the same degree. To insure this symmetry it is well to stretch a cord downward at right angles to and from the centre of another cord stretched between the two anterior superior iliac spines, and then to place the ankles at equal distances from it and as near to it as is convenient. The measurements are usually made between the anterior superior spine of the ilium and a malleolus.

Another method of recognizing shortening and of measuring its extent is one recommended by Mr. Bryant, measuring to the trans-

verse vertical plane passing through the anterior superior spinous processes. Thus, in Fig. 198 *ac* represents the vertical plane passing through these processes, and *b* is the top of the great trochanter. In fracture of the neck with shortening *b* is brought nearer to *c*. The same care must be taken to have the limbs in symmetrical positions, and I have found it convenient to

FIG. 198.



Bryant's ilio-femoral triangle, for diagnosis of fracture of the neck of the femur.

mark the vertical plane by placing a small stick or pencil upright beside the pelvis and in line with the processes, and then to measure the distance between it and the trochanter. The same measurement can be made, roughly but usually with sufficient accuracy, by placing the thumbs on the superior iliac spinous processes and the tip of a finger on each trochanter, and thus estimating the comparative levels.

Another but less accurate method of recognizing the elevation of the trochanter is to find its position with reference to "Nélaton's line," the line taken by a cord stretched between the tuberosity of the ischium and the anterior superior spine of the ilium. Under normal conditions

this line crosses the top of the trochanter when the thigh is slightly flexed on the pelvis.

Attention has been called by Dr. Allis to an effect of this shortening which can be easily recognized; the relaxation of the fascia lata between the ilium and the trochanter and just above the knee on the outer side.

Another effect is the broadening and thickening of the upper portion of the thigh, a change in shape which the eye learns to recognize as almost pathognomonic.

The shortening can sometimes be overcome, entirely or in great part, by gentle traction upon the limb combined with enough rotation inward to correct such eversion as may exist. I think the dread of separating impacted fragments by traction has been exaggerated. The penetration is transverse, and longitudinal traction that is not violent enough to cause much pain cannot do more than change the angle at the junction of the neck and shaft, it does not separate the fragments from each other. Rotatory movements communicated to the limb are more likely to do harm, as is also such lack of support as will allow the eversion and shortening to be increased.

Crepitus is occasionally perceived during the manipulation of the limb while making either traction or rotation, in the latter especially if the limb is at the same time flexed; but it is far from being a constant sign, either because of impaction or of splintering that leaves the pieces too closely connected to produce it. The sign is one that should not be repeatedly sought for; in the cases that are really obscure it is highly improbable that it can be obtained, and in the others it is not needed. The failure to obtain it on examination has led to many costly errors in diagnosis.

Among other signs which may be present are enlargement of the great trochanter when it has been split or comminuted, or the appearance of its enlargement by the inflammatory thickening of the overlying soft parts, change in its distance from the median line of the body, change in the centre of rotation of the limb, and change in the depressibility of the outer portion of Scarpa's space.

The enlargement of the trochanter in consequence of its having been split by the outer end of the neck is sometimes very marked and easily recognized before the soft parts have become swollen by grasping it between the thumb and fingers. The similar enlargement due to infiltration of the adjoining soft parts is always present in fracture at the base of the neck after a day or two.

The distance between the outer face of the trochanter and the median line of the body may be increased or diminished, but the change is seldom very marked and is difficult of accurate determination. It is easier to prove that it ought to exist on theoretical grounds than to recognize it if actually present. If the neck is driven into the trochanter the distance of the trochanter from the cotyloid cavity is diminished by the amount of the penetration; if, on the other hand, there is no penetration or crushing and the displacement is an angular one in the frontal plane, the bone being pushed up until the angle at the junction of the neck and shaft becomes a right angle, the distance is increased because the neck then stands directly out from the body instead of being inclined downward; and thirdly, in combinations of

penetration and this angular displacement the two changes may neutralize each other in whole or in part.

Rotation of the trochanter upon a shorter radius than usual is another symptom found in the text-books but not often at the bedside. Theoretically, if the lever upon which rotation is made is broken a new centre is formed at the seat of fracture or the radius is shortened by impaction. Nothing could be simpler or more accurate in theory, but in practice it is beset with difficulties that make it worthless as a sign, for it is recognizable only in cases where the diagnosis cannot be in doubt.

It is practically impossible to tell by pressing the finger against the outer face of the trochanter whether it rotates upon a long or a short axis, for the range of permissible motion is too limited to make it possible to recognize the sharpness of its curve. In cases of fracture with crushing of the neck and when the shaft lies unconnected with the remainder of the neck and the head, rotation of the limb may take place about the longitudinal axis of the femur, and the centre of motion lie within the shaft, not outside of it in the cotyloid cavity, and this can sometimes be recognized by pressing the finger against the *posterior* face of the trochanter and rotating the limb gently. Instead of rising from the finger the bone may be felt to slide over it. Or pressure against the back of the trochanter may simply raise it, instead of inverting the foot.

The change in the depressibility of Scarpa's space signalized by Hennequin¹ is a valuable diagnostic symptom. Under normal conditions the fingers can be pressed deeply into the limb in the outer portion of Scarpa's space, but when the neck of the femur is broken this depressibility is reduced in varying degrees, apparently by the angular displacement (with the apex directed forward) which takes place so commonly at the junction of the neck and shaft or by infiltration of the soft parts. The same condition was described by Laugier² as a sort of bony tumor to be felt on the outer side of the great vessels an inch or two below Poupart's ligament, slight pressure upon which was painful.

Diagnosis.

In most cases the existence of a fracture of the neck of the femur can be readily determined and sometimes its variety can also be easily recognized, but in others the main character of the injury is very obscure, and in a large proportion of cases it is simply impossible to say whether the fracture is intracapsular or extracapsular, of the narrow part of the neck or of the base of the neck. This difficulty has found expression in many surgical works, and is now generally recognized by all practical surgeons.

When the symptoms described above are clearly marked, when there is the history of a fall followed by complete loss of power in the limb, with shortening, eversion, crepitus, pain at the hip, and elevation of the trochanter, there can, of course, be no doubt—the neck of the femur is broken. But when the limb is not entirely powerless, when the shortening and eversion are slight, perhaps even doubtful, when crepitus is not felt, when, in short, there is no single positive sign, the

¹ Hennequin: Des Fractures du Fémur, p. 700.

² Laugier: Dict. Encyclopédique, art. Cuisse, p. 507.

temptation to conclude that there is no fracture is great, and although the warning uttered by Hodgson nearly a century ago, that inability in an elderly patient to use the limb after a fall upon the hip should be deemed evidence of probable fracture of the neck of the femur, has been repeated many times since, it is still very often disregarded to the great damage of the patient and sometimes also of the surgeon. The rule should be firmly established in practice that every doubtful case, especially in the elderly, should be treated at first as a fracture, and all the more so if the violence has been comparatively slight, such as a stumble or a fall while walking. It has been said that the pain of a contusion or sprain is most marked on moving the limb, that of a fracture on trying to bear the weight of the body upon it; but even if the statement is accurate, which I doubt, it would be very injudicious to make the test, for if fracture is present the effort to bear the weight upon the limb would be likely to separate the fractured surfaces and increase the displacement and the chances of failure of union. If the injury is not a fracture the rest and even the confinement to bed can do no harm and are but a small price to pay for the avoidance of the grave risks involved in the neglect of the precaution so long as it is possible that the injury is a fracture.

The examination should be directed first to the history of the case, then to the functions of the limb and the pain, then to its attitude and length, the condition and height of the trochanter, and the depressibility of Scarpa's space. If any doubt then remains the limb may be gently rotated, in order to judge of the degree of eversion and of its mobility, and, if desired, to estimate the radius of rotation, and perhaps incidentally to elicit crepitus.

A possible source of error in the existence of a former fracture, or of a deforming or dry arthritis, to which a fresh contusion has just been superadded, must be borne in mind when the history of the case is inquired into.

Dislocation is eliminated in case of eversion by noting the absence of the head of the femur from the pubic region. The exclusion of dislocation backward upon the ilium in case of fracture with inversion of the limb may be more difficult. In dislocation the limb is more fixed, it is adducted and flexed, the trochanter is prominent, the head of the femur may perhaps be felt posteriorly, and its absence from the cotyloid cavity be recognized by palpation. In fracture the inversion may give place to eversion after traction upon the limb.

Fracture at a lower level is recognized by the seat of pain on direct pressure and usually by the failure of the trochanter to share in rotatory movements communicated to the lower portion of the limb.

Fracture of the acetabulum with penetration of the head of the femur into the pelvis has usually been mistaken for fracture of the neck of the femur. The means of diagnosis has been mentioned in the preceding chapter.

In regard to the differential diagnosis between fractures through the neck (intracapsular) and those at the base (extracapsular) it can only be said that some of the latter can be positively recognized, as when the trochanter is split or the infiltration of the soft parts adjoining the

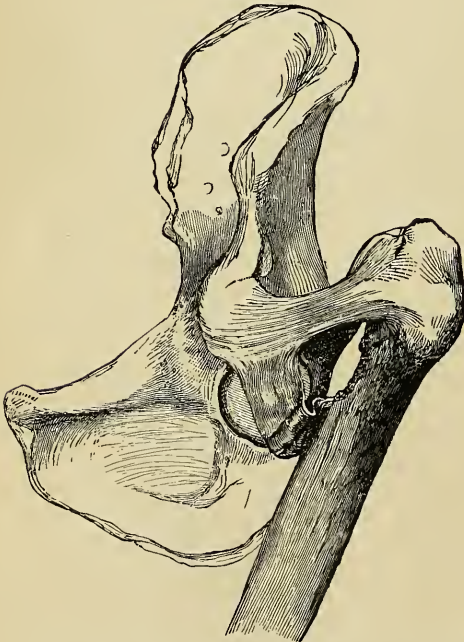
base of the neck is marked, and some of the former almost as positively by exclusion aided by the age of the patient, the slight violence, the absence of thickening and sensitiveness to pressure about the base of the neck, and the absence or the slight amount of the shortening, but in many cases the distinction cannot be made. Thickening about the trochanter and base may be a little delayed. Anæsthesia makes the recognition of some of the signs easier, but is likely to lead to unnecessary handling and to increase the displacement.

In the young, before shortening and disability have occurred, a positive diagnosis without the aid of the *x*-rays may be impossible.

Prognosis.

In this must be considered the immediate danger to the life of the patient created by the accident, and the remoter influence upon the functions of the limb. In five years during which the published records of the New York Hospital differentiate between fractures of

FIG. 199.



Ununited fracture of the neck of the femur, showing the hypertrophied outer fasciculus of the Y-ligament supporting the weight of the body in walking. (BIGELOW.)

the neck and of the shaft thirty-three cases of the former were received, with one death; but as the average stay was only thirty days, it is probable that fully half of them were transferred to other institutions within a day or two after their receipt, and the actual mortality was greater.

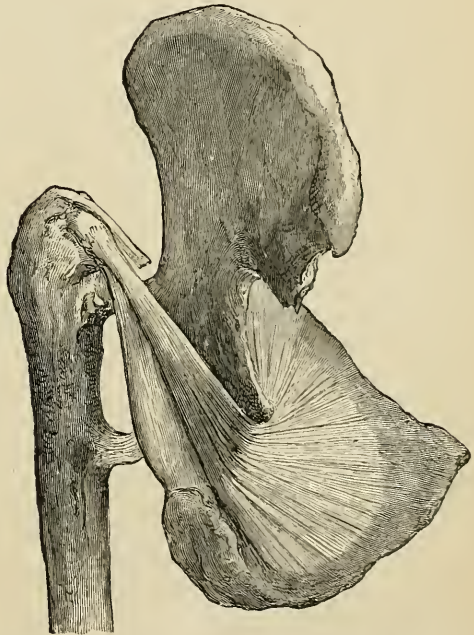The promptly fatal cases present three principal forms: in one the primary inflammatory reaction is sharp, fever sets in, the patient becomes delirious and dies within a few days, or pneumonia is developed soon after the accident and proves fatal. In another the patient, old and feeble, seems overwhelmed by the mental and physical shock and dies within two or three days. In the third form the patient's strength fails rapidly without much inflammatory reaction from

the injury, and he dies asthenic, with mild delirium, and usually with some pulmonary consolidation, about the third week. It is possible that fat embolism, especially of the lungs, may be an important factor in producing this result. The influence of age upon the prognosis is very well marked, the older the patient the greater the probability of a fatal termination within a few weeks.

The influence of the seat of the fracture upon the prognosis in respect of repair has been discussed above. Speaking generally, union may be confidently expected in fractures at the base of the neck, and I believe that it is much more common after fracture through the neck than has been supposed, and that this frequency can be increased by appropriate treatment. But, on the other hand, union takes place almost inevitably with some deformity and with some limitation of motion at the hip; the limb is shortened and everted, and abduction is diminished by the change in the angle of the neck with the shaft. This shortening may be slight, but it causes more of a limp than an equal amount in the line of the shaft does, because a compensatory abduction of the limb is not so easily made. The limitation of motion is seldom enough to cause much inconvenience, but the joint may be sensitive to fatigue and weather and may even be persistently painful. Very satisfactory usefulness is possible even in advanced age.

Failure of union—bony or fibrous—does not necessarily cause complete disability. There are a number of specimens of complete failure of union obtained from patients who have made considerable use of the limb for several years after the fracture; they show usually complete disappearance of the neck and smooth opposing surfaces on the head and side of the shaft. One of Bigelow's specimens shows a similar condition with marked displacement upward of the shaft, the weight of the body having apparently been borne upon it by suspension through the Y-ligament and the obturator and inferior gemellus. Among later specimens reported with interesting details are two by Reboul¹ and one by Bryce.² In such cases that have come under my observation the usefulness of the limb has been slight, although there were good motion and little or no pain; the patient walks with a marked limp, only with the aid of a cane or crutch, and usually bearing the weight only momentarily upon the limb. In the case represented in Fig. 197 the

FIG. 200.



The same, seen from behind, showing the tense obturator tendon and the hypertrophied inferior gemellus. (BIGELOW.)

¹ Reboul: Bull. de la Soc. Anat., May 25, 1888.

² Bryce: Glasgow Medical Journal, July, 1892.

patient walked without a cane. In other cases the pain has been so great and constant that excision of the upper fragment has been done for its relief.

Occasionally, especially in the old and rheumatic, the joint remains stiff and painful even after union has taken place, and sometimes the new formation of bone upon and about the trochanter is so great that it notably restricts motion in the joint.

Mr. Bryant's¹ statement that all his hospital cases for many years (forty-two cases, average age seventy) "went out with good and useful limbs" indicates results much better than any others I have knowledge of, even if his standard of "good and useful" is only that the patient can stand and walk a little with the aid of a cane.

Treatment.

The attainment of the ideal object of treatment—restoration of form and function—is rarely to be expected or even sought; the lack of control of the upper fragment and the destruction of tissue by crushing prevent the restoration of form, while the proximity or involvement of the joint, combined as it usually is with advanced age, insures limitation of function. In addition, the danger to life in weak and aged patients from measures which cause pain and insure rigid confinement is such as to forbid in such cases the use of means by which alone the displacements could be corrected and sometimes even of those by which union is to be sought. The first indication is to save life, the second to get union, the third to correct or diminish displacements.

The vital indication often forbids the use of an anæsthetic to complete the diagnosis or to correct the displacement, even if either should be deemed very desirable, and sometimes, as when pulmonary or heart disease is present, even prevents the recumbent position and consequently the use of means of retention which otherwise would be chosen.

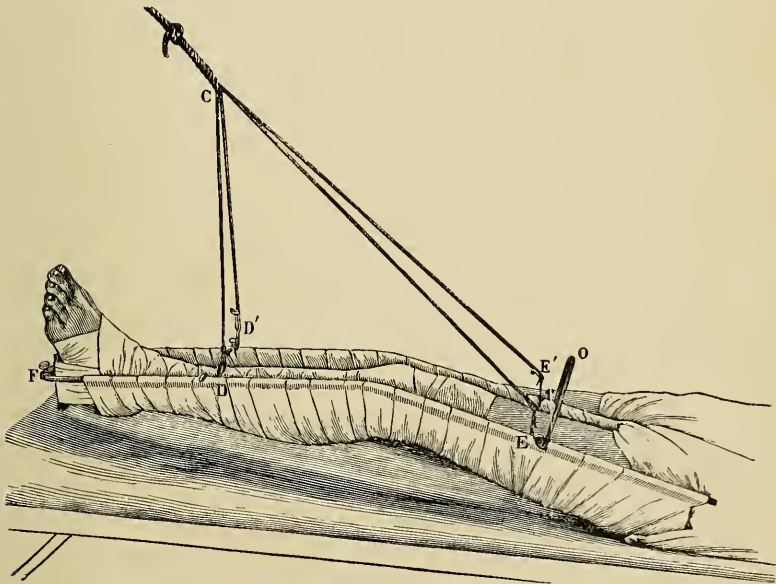
Reduction of the displacement, which is not only desirable and proper but also essential to repair in many fractures of the neck, may be disadvantageous in others, and especially in fractures at the base with crushing, because it would increase the difficulty of repair by creating a gap between the fragments. Thus, if the angle of the neck with the shaft has been diminished by crushing at the lower part of the neck (Fig. 190), or if the posterior portion has been similarly crushed (Fig. 178), the correction of the displacement (shortening in the first, eversion in the second) would separate the fractured surfaces so far as to endanger union. And the forcible breaking up of a tight impaction may also endanger repair by creating a mobility between the fragments which it may be difficult to control by apparatus. As the presence or absence of tight impaction or of crushing cannot often be recognized with certainty, and as the consequences of an uncorrected displacement are not serious, it has long been the rule of practice to make no attempt to correct eversion or slight shortening and to seek only to prevent their increase. In marked shortening and in most fractures through the

¹ Bryant: *Lancet*, 1880, vol. i. p. 160, and *British Medical Journal*, Oct. 12, 1895, p. 889.

neck the limb can usually be drawn down easily to or nearly to its full length, and this much at least is certainly permissible. Forceful correction under ether, recommended by Semm and recently again by Southam and Whitman, should be limited, in my opinion, to the relatively young and robust patients. Whitman's proposal to abduct the limb under anaesthesia until the trochanter rests against the ilium, and then to force the abduction, using the trochanter as a fulcrum, so as to reestablish the original angle between the neck and the shaft, does not commend itself to me. So far as I can analyze the mechanical conditions and foresee the effects, the promises seem to me illusory and the dangers, at least in the aged, serious.

Retention has for its object to maintain the position of the limb against the displacing action of the muscles and gravity, to keep the fractured surfaces in contact, and at the same time to permit a certain general freedom of motion to the patient which will facilitate the attentions necessary to meet his wants, preserve cleanliness, avoid bed-sores,

FIG. 201.



Hodgen's suspended splint.

and diminish the general ill effects of restraint. The means employed, in their order of frequency, are continuous traction, immobilization by splints with or without direct pressure upon the trochanter, and fixation of the fragments by nails or sutures.

It has long been noted that satisfactory functional results can sometimes be obtained by simple rest in bed for a few weeks with only such support for the limb as can be given by cushions or a long side-splint without traction or a double inclined plane, but it is always advisable and sometimes absolutely necessary to use means which will more surely give the necessary immobilization in the proper position.

Continuous traction can be made by weight and pulley (Buck's extension), or by Hodgen's suspended splint, or in combination with a long side-splint or hip-splint. The details of their application are given in Chapter VII. If Buck's extension is used the foot and leg should lie upon a Volkmann's sliding-rest (Fig. 44) to promote comfort and oppose eversion of the limb, and a small firm cushion should be placed behind the trochanter. Direct pressure upon the outer aspect of the trochanter to press the fragments together can be made by a padded band about the pelvis. The weight varies from five or ten pounds in the old to fifteen or twenty in the young adult. If Hodgen's splint (Fig. 201) is used, the traction can be made greater or less by changing the angle of the supporting cord; thus, in the old its upper attachment should usually be about a foot beyond the vertical (at a height of about five feet), and more if more traction is desired. The limb should swing just free of the bed, somewhat abducted. The Hodgen splint greatly promotes the patient's comfort and is generally to be preferred, I think, to the other methods of traction.

Hennequin¹ makes traction by a band crossing the front of the thigh close above the knee and passing across and behind the upper part of the partly flexed leg, the thigh being supported in a wire gutter. The leg and foot, thickly wrapped in cotton, rest on a chair beside the bed, or in a gap made by cutting out the lower part of the mattress on that side.

The combination of continuous traction and immobilization by a splint is effected in various ways. The older method was the long single or double side-splint with elastic traction, as shown in Fig. 48. Its objectionable feature is the general restraint and immobility which it imposes and which the aged do not bear well. Lighter and shorter splints with a perineal band for counter-extension, and with traction by screws and springs, such as that shown in Fig. 50, are freer from this objection.

The various metal splints designed for use in hip-joint disease have of late come into some use in the treatment of these fractures, and this use might, I think, be advantageously extended, certainly in the younger cases. Such an apparatus can be used simply for immobilization, as in the Thomas splint, or combined with traction in the usual manner. With its aid, especially if supplemented by a pelvic band or a pad to press upon the trochanter, the patient, if not too old and feeble, can leave the bed by the fourth or fifth week, sometimes even earlier, and go about on crutches. Shaffer² has reported two very interesting and suggestive cases in which by the aid of such a splint with traction and trochanteric pressure he obtained good union, although treatment was begun in one three months, in the other nine months, after the receipt of the injury. In his first case the trochanteric pressure was made by a pelvic band, in the second by a tourniquet; it could be increased and diminished at will and was borne without discomfort. In both cases the fracture was thought to be through the neck (intra-capsular), and the patients were young men. They mark an important

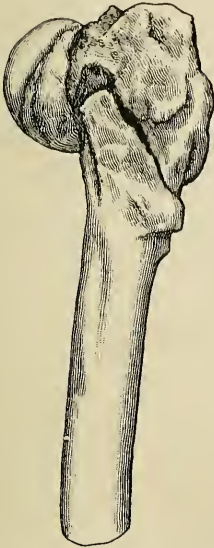
¹ Hennequin: *Fractures des os longs*, 1904.

² Shaffer: *New York Medical Journal*, October 23, 1897, p. 557.

advance in the treatment of failure of union and suggest the more general use of trochanteric pressure, especially in fractures through the neck.

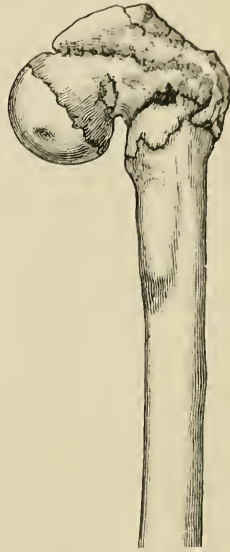
Encasement of the limb and pelvis in plaster of Paris is occasionally used, but the discomfort and inconvenience of the method are great and add to the danger to life in the aged. Senn applied the plaster to both limbs and the pelvis and made pressure by a steel pin passed through the soft parts to the outer aspect of the trochanter, but the plan has not met with favor and appears to be distinctly inferior to the long traction-splint and pressure by a girdle.

FIG. 202.



Pertrochanteric fracture. (KOCHER.)

FIG. 203.



Pertrochanteric fracture. (KOCHER.)

The apparent advantage of a dressing that permits the patient promptly to leave the bed is illusory in most cases, for the patients are too old and feeble to profit by it; those that may seem to need the change most are the least able to make it, in the others the gain does not seem to me to compensate for the risk. In fractures through the neck, and in others in which the transformation of the bond of union into bone is delayed such a dressing has great advantages, for it permits the patient to leave the bed, say in the second or third month, without interruption of the immobilization.

The attempt to secure union by operation,¹ in fresh as well as in old cases, has been made many times since Langenbeck's first and unsuccessful one. The first success was got by Franz König in 1875 by passing a metal pin through the trochanter, neck, and head, and most subsequent ones have been got in the same way.

¹ König, *Chirurgie*, 5th Ed., vol. 3, p. 282; Loretta, *Brit. Med. Journ.*, Aug. 25, 1888; Cheyne, *Ibid.*, March 7, 1892; Dollinger, *Centralblatt für Chir.*, June 6, 1892; Meyer, *Annals of Surg.*, July, 1893; Kocher, *Wichtiger Frakturformen*, p. 303; Freeman, *Annals of Surg.*, Oct., 1904, p. 561; Fritz König, *Arch. für klin. Chir.*, vol. 76, p. 725; Schlange, *Ibid.*, vol. 81, part 2, p. 26; Vaughan, *Am. Journ. Med. Sci.*, March, 1907, p. 385; Herz, *Ztblatt für Chir.*, 1906, p. 705.

The weight of opinion, to judge from the published papers and reports of discussions in various surgical societies, is strongly in favor of abstention in fractures at the base of the neck. The occasional successes obtained in old cases are matched by those obtained by splints.

In fracture through the narrow part of the neck the question is still an open one and presents itself in two forms: Shall the attempt be made in a fresh fracture? Shall it be made in an old fracture or shall excision of the head be preferred? Here, too, the weight of opinion has been decidedly against operation in fresh cases, and seems to be fully justified by the known pathology of the injury and the belief that the preservation of the blood supply of the head is essential to repair. Suturing the periosteum, if it has been torn, cannot be expected to restore this blood supply sufficiently soon and abundantly to do any good; and if the periosteum has not been torn, suturing of the bone is superfluous and correction of the angular displacement will only open a gap on the concave side which will diminish the breadth and consequently the strength of such union as may be obtained. Fritz König, after four attempts at late suture, got a good result in an early one and obtained the specimen a few months later. He found firm union (bony?) in front where he had sutured bone and periosteum, and a gap behind where he had placed no sutures, and on the strength of this he argues for operation at the end of the first week and for suturing all around, attributing the gap to the absence of sutures. It can, with greater plausibility, I think, be charged to correction of the displacement. Late attempts to get union have given few results that can be called even moderate successes, and König's opinion that if it is to be done at all it should be done early is doubtless correct.

Excision of the head¹ in old cases for the relief of pain and improvement of function has given a number of good results. For the attempt to get union and also for excision Fritz König recommends the anterior approach by an incision between the tensor vaginae femoris on one side and the rectus and sartorius on the other. Ito and Asahara, for excision, used the posterior route, the Langenbeck or Kocher incision.

C. Fractures Through the Great Trochanter and Neck.

(Fractura Pertrochanterica, Kocher.)

This class may be defined as composed of those cases in which the line of fracture begins at or near the lower part of the junction of the neck and shaft and passes through or close below the great trochanter, dividing the bone into two parts, of which the upper is formed by the head, neck, and upper part of the trochanter. The line of fracture may be oblique from within outward and upward, or from behind upward and forward. The line of division between these and the subtrochanteric fractures, the highest of the fractures of the shaft, is marked by the trochanter minor, which also establishes an important clinical difference depending upon the action of the psoas-iliacus which

¹ Howe, *Med. Record*, vol. 14, p. 394; Fritz König, *Chirurgie*, vol. 3, p. 252; Lejars, *Semaine méd.*, Oct. 17, 1894; Bolton, *Annals of Surg.*, Feb., 1900, p. 149; Ito and Asahara, *Deutsche Zeitschrift für klin. Chir.*, vol. 78, p. 121, 7 cases; Fritz König, *loc. cit.*

is attached thereto. Its action in fractures below that point is to flex the upper fragment.

The injury is not a common one, and the recorded specimens are few. To those described in the first edition may be added three from the museum of Trinity College, Dublin, shown by Bennett¹ to the British Medical Association, and five described and figured by Kocher. The illustrations of Bennett's are so indistinctly printed that the details are not recognizable; in two of them the fracture appears to have extended down the outer part of the shaft. Kocher's² specimens show marked angular deformity, apex forward, and some diminution of the angle of the neck, adduction of the shaft (Figs. 202 and 203).

The only one I have seen differed notably from the type form in that the line of fracture was very long and oblique, extending from the top of the trochanter downward and inward to a point which I thought was well below the lesser trochanter. Because of persistent displacement and some uncertainty of diagnosis I exposed the fracture by an anterior incision, but did not uncover its lower end. The patient was fifty years old, and recovered with little, if any, shortening.

The mechanism appears to be forcible extension (possibly abduction) of the limb, in which movement the neck and trochanter are arrested by the Y-ligament and the fracture takes place below or through its lower attachment.

The characteristic symptom appears to be the prominence of the angle in front, with pain on pressure at this point and possibly with immobility of the trochanter and crepitus when the limb is gently rotated. Shortening and eversion are present, the latter due to muscular relaxation and loss of control of the lower fragment. In my case the trochanter was prominent and eversion marked.

Treatment. The treatment is immobilization with traction, but preferably with more flexion of the hip than is usual in fracture of the neck.

D. Fracture of the Great Trochanter. Separation of the Apophysis.

Only a few specimens, not more than a dozen, of this injury, independent of associated fracture of the neck, have been reported. The cause appears commonly to be a blow upon the outer posterior portion of the trochanter; occasionally muscular action.

The fragment usually remains attached to the femur by tendinous and periosteal fibres, and is sometimes broken into two or more pieces; it is freely movable upon the shaft, but rarely is completely separated from it and displaced upward or backward by the attached muscles. Potherat³ reported a specimen, found in the dissecting-room, with displacement upward of four centimetres. Neck⁴ demonstrated by incision a flat fragment on the outer aspect.

The specimens of the separation of the apophysis are one in Guy's

¹ Bennett: British Medical Journal, October 12, 1895, p. 893.

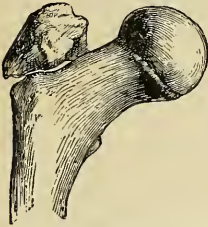
² Kocher: *Loc. cit.*, Figs. 140 and 151-157.

³ Potherat: Bull. de la Soc. Anat., February, 1888.

⁴ Neck: Centralblatt für Chirurgie, 1903, p. 1447.

Hospital museum, Key's case (Fig. 204), one in Steevens's Hospital,¹ Dublin, Hilton's,² Ashton's,³ Adami's,⁴ and Daniels's.⁵ The last four are quoted from Poland. Two of these (Adami's and Steevens Hosp.) were obtained in the dissecting-room without history. In the others death followed within a few weeks after the violence that was thought to have caused the separation, and was preceded by fever and suppuration about the upper part of the bone. In

FIG. 204.



Fracture or diastasis of the great trochanter. (BRYANT.)

all but one (Daniels) the separation was exactly along the epiphyseal line, and the fragment was not displaced; it seems to me highly probable that they were cases of osteomyelitis, possibly originating in the trauma.

McCarthy's case seems to me clearly to be osteomyelitis rather than fracture.

Symptoms. The symptoms are local pain on pressure, and mobility of the fragment recognizable if the swelling is not too great.

Most of the patients have been able to walk, though with pain; and rotation of the hip was painful.

Treatment. The treatment is immobilization, preferably with the limb abducted and rotated outward to diminish the displacing action of the attached muscles. Local pressure by a bandage about the hips has been used, but is probably unimportant.

E. Fracture of the Trochanter Minor.

Bennett⁶ reports a specimen of this fracture in the museum of Trinity College, Dublin, associated with a united intracapsular fracture of the neck. The accompanying illustration shows the trochanter detached with a small portion of the shaft. He adds that he has recognized the fracture in the living, but gives no details.

The only other specimens or cases that I know of are Fenwick's and Julliard's. Fenwick's is reported by J. Hutchinson, Jr.,⁷ a boy, seventeen years old, leaped upon a fence and fell backward, breaking off the lesser trochanter, apparently by the pull of the psoas-iliacus. This was verified by incision. He died of septicaemia on the seventeenth day. The specimen is in the museum of McGill College, Montreal.

Julliard's⁸ patient was a man eighty-two years old and was injured by falling as he rose from bed. Severe pain in the hip and marked eversion and disability which persisted until his death, a fortnight later. Diagnosis, fracture of the neck of the femur. The autopsy showed a large extravasation of blood in the muscles, the joint and neck of the femur intact, the lesser trochanter broken off and adherent only by a strip of periosteum. "The upper extremity of the femur shows a cavity as large as a small nut and presents a sarcomatous degeneration."

¹ Transactions Pathological Society of Dublin, vol. vii. n. s., quoted by Bennett.

² Hilton: Guy's Hospital Reports, 1865, p. 342.

³ Ashton: Lancet, Feb., 1875, p. 231.

⁴ Poland: Traumatic Separation of Epiphyses, p. 666.

⁵ Transactions London Pathological Society, vol. xlvii. p. 174.

⁶ Bennett: British Medical Journal, October 12, 1895, p. 893.

⁷ Hutchinson: British Medical Journal, December 30, 1893, p. 671.

⁸ Julliard: Progrès Méd., 1879, vii. p. 825.

2. FRACTURES OF THE SHAFT OF THE FEMUR.

The highest of the fractures considered in this section are the sub-trochanteric, the lowest the supracondyloid; intercondyloid or T-fractures will be described in the following section. Exceptional and irregular forms are occasionally seen, spiral and oblique fractures in which the main line or a fissure passes from the upper part of the shaft to the neck and the trochanter, and even in which the upper fragment has been split longitudinally through the trochanter.

Causes. The causes of fracture are direct and indirect violence and muscular action; see Chapter III.

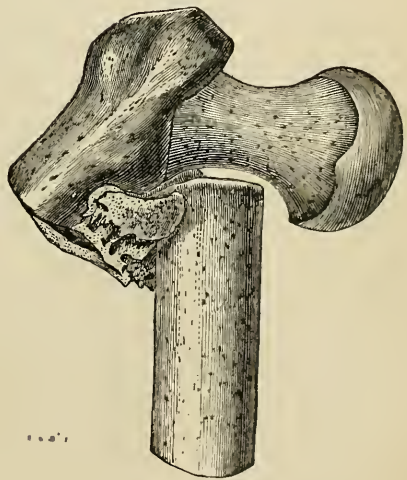
Pathology. All the varieties of fracture that may occur in long bones are met with in the femur, but in the great majority of cases the fracture is oblique and often extremely so, the obliquity usually corresponding to the normal curves of the bone; that is, in the middle part of the bone it runs from behind forward and downward, and in the upper third forward and outward. Transverse fracture is rare in adults, but more common in children.

FIG. 205.



Fracture of the upper third of the femur; union with great displacement. (A. COOPER.)

FIG. 206.

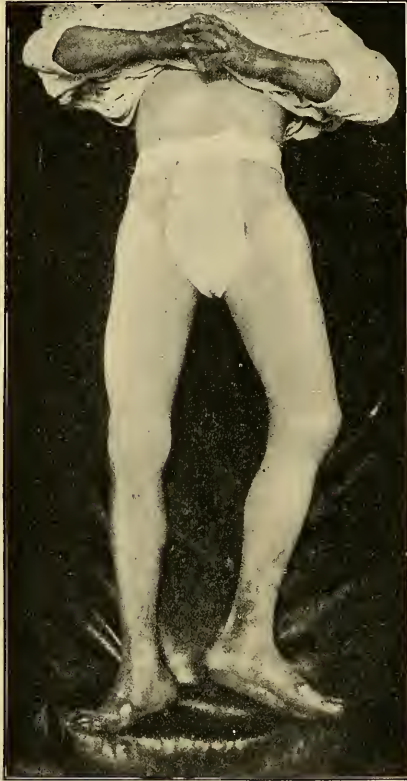


Transverse fracture of the femur. (GURLT.)

The displacement is marked, and is the effect of the fracturing cause, of the contraction of the powerful muscles of the thigh, and of the swelling of the limb beneath the fascia by which it is broadened and shortened. The lower fragment usually passes behind and to the inner side of the upper one and is sometimes rotated outwardly; in addition there is angular displacement, the angle usually being directed forward or forward and outward, but sometimes backward or inward.

Inclination forward and outward of the lower end of the upper fragment after fracture in the upper third is the rule and is mainly due to muscular action, the contraction of the gluteal muscles and the psoas upon the upper fragment and of the adductors and the flexors of the leg upon the lower one. The tendency of the former is to tilt the upper fragment forward, outward, or in both directions; that of the latter is to draw the lower fragment up against the upper one, and this

FIG. 207.



Fracture of left femur close below the trochanters.

will produce an angular displacement in any direction that is favored by the line of fracture. The fact that the displacement is sometimes backward or inward does not disprove the influence of the muscles attached to the upper fragment, as has been argued; the principal agency is the drawing upward of the lower fragment, and if the fragments are so related at the seat of fracture that the upper one is pushed in a different direction from that in which its muscles would draw it the latter must yield. In the extreme case shown in Fig. 205 it can be seen how great the angular displacement and at the same time the over-riding can be under these circumstances. The angular displacement necessarily produces shortening, and this shortening varies according

to the angle and, the angle being the same, according to the distance of the fracture below the neck of the bone. In the same specimen outer rotation of the lower fragment is also very marked. In transverse and toothed fractures the displacement may be lateral or angular or both, and if the lateral displacement is sufficient to free the fragments they may override.

Extreme obliquity of the fracture, which is not uncommon, leads occasionally to a complication which may be very troublesome and may transform a simple fracture into a compound one, the penetration of the muscle and sometimes of the skin by the sharp end of the upper fragment. This is specially likely to occur in fractures of the lower third, the sharp lower end of the upper fragment perforating the quadriceps or even the skin. The perforation of the muscle is directed downward as well as forward, probably because the knee is flexed at the moment when it occurs, and then when the joint is straightened the muscle retracts upward along the spike of bone; this makes it necessary to flex the knee again in order to free the bone, thus drawing the muscle down past its end. In these fractures of the lower third the lower fragment is sometimes tilted (presumably by the action of the gastrocnemius) so that its upper end is directed obliquely backward, and it is sometimes split by a line of fracture running between the condyles. See Intercondyloid Fractures.

Other complications are rare, the vessels and nerves not lying in sufficiently close relations with the bone to be often injured. Müller¹ reported a case of rupture of the inner and middle coats of the femoral artery in a fracture at the junction of the middle and lower thirds; gangrene threatening, amputation was done; death. And Selenkow² reported one of laceration of the femoral vein; death followed, apparently the result of officious treatment. The danger is greater in the lower third than elsewhere, and pressure upon the vessels when they are not torn may cause gangrene of the leg either by its continuance or by the formation of a thrombus in consequence of the bruising.

Fissures extending upward and downward from the seat of fracture are probably not infrequent, especially in gunshot fractures.

Double fractures have been observed, and, according to Malgaigne, there is a specimen of triple fracture in the Musée Dupuytren. Double fracture should always be looked for when the causative violence has been great. Comminuted or splintered fractures are not uncommon, especially among fractures by direct violence, and the splinters may be large.

The effusion into the knee-joint which is observed so frequently in the course of fractures of the thigh has received particular attention since 1870, when Rouge, of Lausanne, first wrote concerning it. Among those who have studied it most carefully are Gosselin,³ Berger,⁴ Marjolin, Alison,⁵ and Hennequin,⁶ the two former attribut-

¹ Müller: Deutsche med. Wochenschrift, October 11, 1858.

² Selenkow: St. Petersburg med. Woch., October 8, 1858.

³ Gosselin: Clinique de l'Hôpital de la Charité.

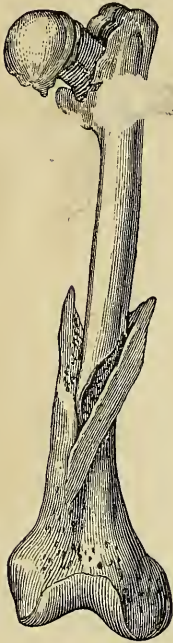⁴ Berger: Thèse de Paris, 1873.

⁵ Alison: Thèse de Paris.

⁶ Hennequin: Loc. cit., p. 78. (See also the discussions in the Bulletins de la Société de Chirurgie, 1873, pp. 6 and 336.)

ing it to the passage of extravasated blood into the joint, the third and fourth to interference with the return venous circulation, and the last, in common with Verneuil and others, to an associated sprain.

FIG. 208.



Fracture of the neck of the femur and of the shaft. A splinter, 5 inches long and nearly 1 inch wide, composed of the cortical layer, has been turned completely about its long axis and become united, with its original periosteal surface in contact with the other fragments. (Figured by GURLT from the Museum of the Royal College of Surgeons, England, No. 454.)

Others again have sought the cause of the effusions noted in the later periods of the case in the prolonged immobility and the extended position. An appreciable effusion makes its appearance in a majority of the cases within the first three days following the injury; it is most prompt in children and when the fracture is in the lower third, and is more common after fracture by indirect than after fracture by direct violence. It disappears promptly in children, more slowly in adults, and may persist for years.


Symptoms. The symptoms are pain, loss of function, abnormal mobility, deformity, and crepitus. As the bone is deeply placed under thick muscles, irregularity in its outline cannot be recognized by the touch; angular displacement can often be readily recognized in thin patients by the eye, but the method of examination which renders the best service in this respect is the comparative measurement of the two limbs. The fixed points commonly used for this purpose are the anterior superior spinous process of the ilium and the tip of the external malleolus; the rules for making these measurements and the precautions to be taken to guard against error have been given in Chapter IV. and in the preceding section of this chapter, page 329; the capital point is to make sure that the two limbs form the same angle with the pelvis, and the best method of doing this is to stretch a tape across the abdomen from one anterior superior iliac spine to the other, and a second one at right angles to the first from its centre downward, and then to place the ankles at equal distances from the second line. The

shortening may vary from a small fraction of an inch to several inches.

Abnormal mobility may be recognized by placing the hand under the thigh at the suspected seat of fracture and gently lifting it, or by holding the upper portion of the thigh down with one hand and gently lifting the leg or moving it from side to side with the other, or by observing whether the great trochanter moves with the leg when the latter is gently rotated. The examination for abnormal mobility and crepitus should be made very gently, and should not be prolonged if the latter is not promptly obtained.

Prognosis. Any fracture of the femur is a serious injury to this extent, that its proper treatment makes confinement to the bed for several weeks desirable, that it will make it difficult for a long time for the patient to get about even with crutches, and that it may lead to shortening of the limb, even if not to a persistent limp. It also

FIG. 209.



Fracture of the shaft of the femur.

exposes to the possibility of a fatal result, especially in the aged and alcoholic, and to that of gangrene of the limb by rupture or bruising of the main vessels or by pressure upon them.

A simple fracture without displacement, or suitably reduced, will usually consolidate in six or seven weeks sufficiently to allow the patient to get about on crutches, and he will be able to bear his weight safely upon the limb, and to discard the crutches in three or four weeks more. In exceptional cases the consolidation may be delayed, and it happens occasionally that a secondary fracture occurs soon after the patient first leaves his bed, usually in consequence of a fall.

Most authorities assert that an oblique fracture of the shaft of the femur cannot be cured without some permanent shortening. Since the time of Desault the possibility of a better result has been claimed by different surgeons, and for different dressings, but no method has yet won a general acceptance of its claim. While there is no reason to doubt the possibility of a union without shortening, and while I believe such union has been obtained in some cases, I do not believe there is any method of treatment which can be depended upon to secure it in any given case, for it can never be known in advance whether or not the patient will be able or tractable enough to support the traction and pressure necessary to success. Some surgeons have claimed an actual elongation of the limb by the use of continuous traction. Although a certain doubt is thrown over such assertions by the acknowledged difficulty of making accurate measurements, and by the possibility of a previously existing inequality in the length of the limbs, the occurrence is not impossible, however improbable it may be.

The persistence of some shortening, even an inch, does not necessarily cause the patient to limp, since it may be compensated for by an inclination of the pelvis. The rigidity in the knee is likely to persist for a length of time that is greater if the patient is older and of a rheumatic habit.

The prognosis in compound fractures is particularly grave when the

injury has been produced by direct violence; and in a fracture of both thighs, particularly if either is compound, the shock is usually so great as to put the patient's life in serious danger.

Treatment. The dressings now in use for the treatment of fracture of the shaft of the femur are Buck's extension, Hodgen's suspended splint, the long side-splint or the hip-splint, usually with traction, encasement in plaster of Paris, and the double inclined plane. All have been described in detail in Chapter VII. It remains only to note their special advantages and indications.

THE LONG SIDE-SPLINT WITHOUT TRACTION should be used only as a temporary dressing during transport or for a few days at first when the condition of the patient—delirium, shock, associated injuries—contraindicates one which would not be sufficiently restraining, or the application of which would be too exhausting.

THE LONG SIDE-SPLINT WITH TRACTION may be used temporarily later in the case if the patient is to be transported to a distance; it is cheaper than a hip-splint, can be readily improvised, and as it extends almost to the axilla it insures greater immobilization. Indeed, the immobilization of the trunk, and the consequent restraint, is the objection to its general use. In a somewhat shorter form (Fig. 46), extending only to the waist, it is widely used in England throughout the course of the case. Weed's splint (Fig. 47) represents a highly developed form, adjustable to limbs of different lengths and making traction by a spring.

"**BUCK'S EXTENSION**" (Fig. 44) is the method in general use in the United States and very largely in Europe. It is suitable for the great majority of cases, except the subtrochanteric, is easily borne, and, as it permits a certain freedom of motion, promotes the comfort and well-being of the patient. It also permits constant supervision of the fracture and easy recognition of shortening or angular displacement. An objection to it is that the patient tends to turn on the injured side and thus rotate the upper fragment outward while the lower one and the foot are kept upright. This can be measurably met by a small firm cushion behind the trochanter, as can also the occasional outward rotation of the upper fragment by gravity. In the higher fractures, too, it is not always easy to maintain as much abduction of the limb as may be desirable. Sagging of the fragments, with production of a backward or outward angular displacement, can be prevented by cushions or a long posterior plaster gutter.

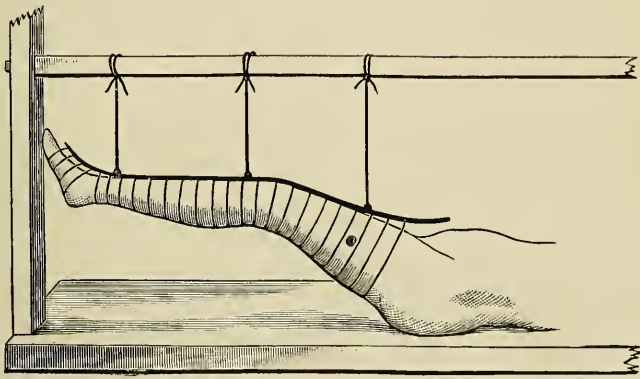
HODGEN'S SUSPENDED SPLINT (Fig. 201) gives even greater comfort and freedom, permits greater variety in the attitude given to the limb—abduction and flexion for the higher fractures—and allows the knee to be kept partly flexed, an easier position. It is specially advantageous in the older and feebler patients. I do not think it immobilizes the fractures quite so well as Buck's extension does, but I have found no serious inconvenience from this and I use the splint more and more in preference even to Buck's, and always in high fractures and in those of the lower third; in the latter because of the flexion of the knee.

ENCASEMENT IN PLASTER OF PARIS, including the pelvis, after

having been widely used as the preferred treatment for some years after 1870, has now largely given place to continuous traction during the first month or six weeks, but is still much used in the later stages when displacements are no longer to be much feared and the patient needs only to be protected against accident while he goes about on crutches and awaits complete consolidation. In cases of delayed union it may even permit the patient to bear part of his weight upon the limb and thus hasten ossification of the bond. It is still sometimes used from the beginning, and the patient allowed to go about on crutches, but marked displacement can occur under such circumstances and the chance, in my opinion, should not be taken. The absence of a fixed upper point of support makes it easy for overriding and angular displacement to occur.

THE HIP-SPLINT, in any of its various forms, meets the same indications more conveniently, though more expensively, and as it can be

FIG. 210.



Anterior suspended splint, without traction, in compound fracture.

combined with traction (as in hip-joint disease) it can be safely used at an earlier period in the case. It is especially convenient in cases of delayed union, for it relieves the patient from confinement to bed.

THE DOUBLE INCLINED PLANE (Fig. 48) is occasionally useful as a temporary dressing in very severe injuries when the swelling is great or the circulation embarrassed; also in compound fractures with so much loss of bone that traction is not required to prevent overriding.

The same indications can be met by a *long anterior splint* flexed at the knee and suspended from a horizontal bar placed a short distance above it (Fig. 210). Such a splint can be conveniently made of a stout iron rod, like Smith's splint (Fig. 38), but it is better to have the leg horizontal; it permits an easy change of the dressings of the wound without disturbing the fragments, but, like the inclined plane, it cannot be trusted when traction is needed to keep the fragments in position.

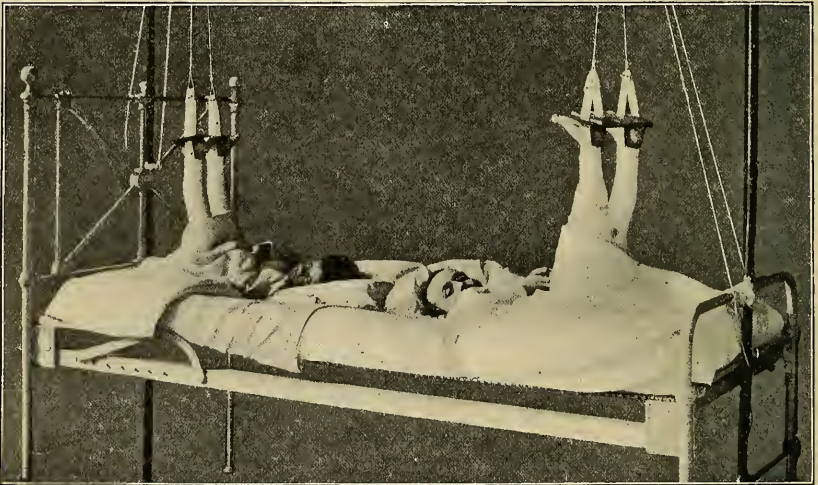
In fractures of the *upper third* the thigh should be flexed and the fragment shall be in line with the

upper one which usually assumes this attitude, and for this the Hodgen splint is the most convenient.

After five or six weeks, in most cases, abnormal mobility will have disappeared or so far diminished that traction is no longer needed; angular displacement is then the only one that is likely to take place, and this can be prevented by plaster-of-Paris encasement. If the abnormal mobility has wholly disappeared I usually remove the apparatus and keep the patient in bed for a few days without any dressing; then I apply a plaster dressing, including the pelvis if the fracture is above the lower third, and allow him to go about on crutches. After another fortnight the plaster is removed.

In *young children* vertical suspension is by far the most convenient and satisfactory method of treatment. Strips of adhesive plaster are applied, as in Buck's extension, to both legs and attached by cords to a support immediately above the child so that the pelvis rests lightly upon the bed (Fig. 211). I have sometimes made this attachment elastic by introducing a rubber cord or by using a support with a flexible arm, but have found no great advantage in it and some disadvantage because of the gradual yielding. The fixed support is also better

FIG. 211.



Fracture of the thigh; vertical suspension. The fracture is compound in the patient on the right.

than the weight and pulley which are sometimes used. The position is well borne and makes it easy to keep the child dry and clean. The contact with the bed should be so light that the hand can be passed easily under the pelvis. In very young children it is sometimes sufficient to bind the flexed thigh to the abdomen.

Dr. A. W. Mitchell devised a splint which permits the child to be carried about. It consists of three wooden splints—body, leg and thigh pieces—fastened together by thumb-screws for

ment. Traction is made by having the thigh piece project beyond the flexed knee, so that the bandage about the upper part of the leg will draw it downward.

In *older children*—over ten years—I have found Buck's extension the best, and decidedly preferable to the double side-splint, with which it is difficult to prevent shortening and angular displacement. Fairly firm union may usually be expected in three weeks.

In fractures of the *lower third* the engagement of the lower end of the upper fragment in the quadriceps, or even in the overlying skin, adds greatly to the difficulty of reduction. This can sometimes be made by flexing the hip and the knee to a right angle, thus drawing the muscles downward along the penetrating fragment, and then completing the disengagement by strong traction in the axis of the shaft, the flexion being maintained. If this fails the skin and fascia must be freely incised over the end of the fragment and the bone disengaged by direct manipulation. If the point of the bone has perforated the skin the opening should be enlarged, both to facilitate the disengagement and to evacuate the extravasated blood. The Hodgen splint should be preferred in the treatment of these fractures, for it permits moderate flexion of the knee and thus tends to avoid the tilting of the lower fragment which may happen when the knee is kept extended.

If the *artery* is torn it may be tied in the wound; if the vein alone is torn it may be tied, or, if not torn entirely across, the deep soft parts may be sutured over it so as to oppose escape of the blood, and the attempt made to save the limb, but if gangrene appears amputation must be done at once. Division of both artery and vein justifies immediate amputation.

Delayed union, if the fragments are in a fairly good position and their mobility is not great, is best treated ordinarily by plaster-of-Paris encasement, including the pelvis, and by bearing some weight upon the limb with the support of crutches. I have seen union become solid as late as the sixth month.

In *failure of union*, when the position of the fragments is bad and the mobility marked after three or four months, resection of the ends and readjustment are required. I have always made the incision on the outer side, cut the ends square, and kept them in contact by a suspended splint or by resting the limb upon an inclined support so that the leg and lower fragment would constantly press downward toward the upper one. Occasionally I have used plaster of Paris over the primary dressing of the wound. For other details see Chapter VIII.

3. FRACTURES AT THE LOWER END OF THE FEMUR.

In this group are here included intercondyloid fractures, separation of the lower epiphysis, and fracture of either condyle.

A. Intercondyloid Fractures.

In these fractures both condyles are separated from the shaft and from each other, the line being T-shaped or Y-shaped. The fracture is sometimes classed as a supracondyloid fracture with splitting of the lower fragment, since that is thought to be the mode of production in most cases; the shaft is first broken and then the upper fragment penetrates and splits the lower (Fig. 213). The claim that the fracture is caused by a violence transmitted through the patella which acts as a wedge and splits off the condyles does not bear the test of experiment or harmonize with the fact that in a fall the blow is rarely received upon the patella. Trélat,¹ in an elaborate article in which it was first sought to give a detailed and full account of fracture of the lower end of the femur, points out that in six cases of supracondyloid fracture the average age was twenty-seven and a half years, while in thirteen cases of intercondyloid fracture it was forty-eight and a half years. The number of cases seems to me too small to warrant the inference that the difference is an essential and constant one.

The main line of fracture across the shaft may be very oblique, as in the common fracture of the lower third, but is usually more nearly transverse in its general direction with splintering which makes the surface irregular, and lies close to the base of the condyles.

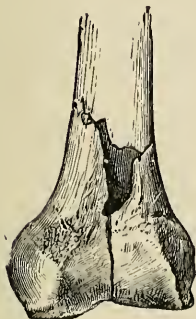The line between the condyles follows the intercondyloid notch, and is vertical and antero-posterior. In a case observed by Nélaton and reported by Trélat (*loc. cit.*, p. 73), the mechanism of the separation of the condyles is shown plainly, the upper fragment being impacted into the lower one, but mainly on the inner side, and the separation of the condyles merely a fissure (Fig. 214). Usually, however, the condyles are completely detached from each other and sometimes separated far enough to allow the patella to sink in between them, and either may be further displaced backward than the other, with a corresponding rotation of the leg, since the tibia retains its connection with them. The crucial ligaments may be torn longitudinally or transversely, and then the attachment of the tibia is less close.

The injury is frequently compound, from within outward by the end of the upper fragment, especially when the fracture is oblique; dangerous pressure by one or the other fragment upon the popliteal vessels is not uncommon, and the vein and artery have been torn, the vein the more frequently. In one of my cases—fracture of both femurs by a fall of forty feet, the patient dying in thirty-six hours—one fracture was compound by perforation of the muscle and skin in front by the upper fragment, the other was simple, but the popliteal vein was torn, and there was a large extravasation of blood in the thigh. In each the lower end of the upper fragment was very irregular, but not broken obliquely, and there was much comminution between it and the con-

¹ Trélat: *Archives Générales de Méd.*, 1854, vol. ii. p. 59.

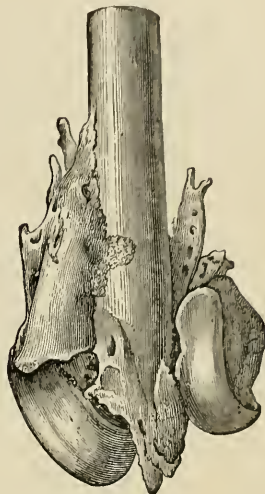dyles; the compact layer on the posterior face of the bone was pressed

FIG. 212.



Intercondyloid fracture of the femur.
(BRYANT.)

FIG. 213.



Comminuted fracture of the femur, with
splitting of the condyles. (GURLT.)

in toward the centre as if the lower fragment had been bent violently backward upon the other.

The recognition of the main line of fracture is easy by attention to the usual signs; that of the line between the condyles is made by noting the independent mobility of the two condyles on each other when they are grasped and moved backward and forward, and pain when they are pressed together laterally.

Shortening of the limb is common, but the sign is seldom needed for the diagnosis; in an impacted fracture it might be useful in distinguishing the lesion from fracture of one condyle alone.

Enlargement of the knee by separation of the condyles is rare, or at least is difficult of recognition; on the other hand, enlargement by effusion or hemorrhage into the joint is constant.

Prognosis. The prognosis is serious as regards both the life of the patient and the integrity of the joint. Of 26 cases collected by Hennequin 7 died, 3 were amputated, and 16 recovered. The gravity of the injury depends mainly upon the implication of the joint and the traumatic arthritis excited thereby, which may easily end in suppuration and which in any case is very likely to result in more or less stiffness.

Treatment. As the tendency to overriding and angular displacement (except when the main fracture is oblique) is not so marked as in the

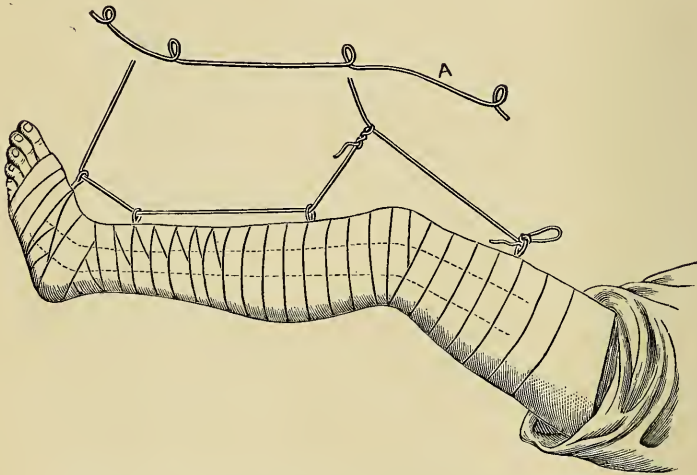
FIG. 214.



Intercondyloid fracture of femur.

higher fractures, continuous traction need not be so vigorous or so prolonged. I prefer the position of slight flexion of the knee and there-

FIG. 215.



Plaster splints. A is a wire attached for the purpose of suspension.

fore habitually use the Hodgen splint. Or the limb may be simply kept on a double inclined plane, or suspended by an anterior splint or a wire gutter, or encased in plaster or in plaster splints.

Because of the length of the limb above the fracture and the more secure hold thereby given to a splint, the limb may be put in plaster or in splints and the patient allowed to leave the bed earlier than in other fractures of the shaft.

Injury to the popliteal vessels may necessitate amputation. The indication is given by the appearance of gangrene of the leg or by direct recognition of the injury to the vessels. It may be proper at the beginning in a compound case to try to save the limb by ligature of the torn artery or by suturing the deep soft parts over the vein if that is only partly torn across; if both are torn immediate amputation is justifiable.

B. Separation of the Epiphysis.

Traumatic separation of the lower epiphysis of the femur is relatively frequent, and reports of cases, generally treated by operation, frequently appear. The first paper dealing specifically with separation of this epiphysis was a very complete one by Delens.¹ Later ones are by J. H. Packard,² J. Hutchinson, Jr.,³ R. H. Harte,⁴ A. H. Meisenbach,⁵ and Charles McBurney.⁶

¹ Delens: *Archives Générales de Médecine*, 1884, vol. xiii. p. 272.

² Packard: *Annals of Gynecology and Pædiatry*, November, 1890.

³ Hutchinson: *British Medical Journal*, December, 1894, p. 671.

⁴ Harte: *Transactions American Surgical Association*, 1895.

⁵ Meisenbach: *Medical Record*, October 5, 1895.

⁶ McBurney: *Annals of Surgery*, March, 1896.

Although the epiphysis may not unite with the shaft before the twenty-fifth year, in none of the reported cases has the patient been more than twenty years of age.

Cause. The cause in almost all cases has been great violence, extending or abducting the knee, and in a singularly large proportion of cases it has been the engagement of the leg between the spokes of a revolving wheel. In one or two cases the injury has been inflicted upon the infant during delivery by the feet and has then been attributed, but probably incorrectly, to direct traction. In a few cases the injury has been caused in attempts to straighten a stiff knee or in osteoclasis for deformity.

Pathology. The separation, as is the rule also at other points, takes place between the conjugal cartilage and the diaphysis, is usually complete and clean, but sometimes leaves attached to the epiphysis one or more scales broken from the diaphysis or diverges to pass through a portion of the diaphysis. The periosteum is always freely stripped from the shaft, often for several inches, remaining attached to the epiphysis as an irregular sleeve. In a few cases the epiphysis has in addition been split longitudinally between the condyles.

The common displacement is of the epiphysis forward and to one side, usually the inner, corresponding apparently to production by hyper-extension of the knee; in other cases it has been to the inner or the outer side, doubtless when produced by abduction or adduction. When displaced forward it has also passed upward upon the anterior surface of the shaft with or without rotation (Plate XXVIII.). In a few cases it has been rotated about the vertical axis so that one condyle presented in the popliteal space, in others about a transverse axis so that the surface of separation was directed backward.

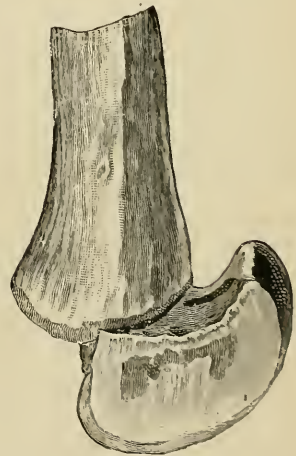
The knee-joint is not often involved, but sometimes the capsule is torn and the joint filled with blood and exudate.

In a large proportion of cases the injury has been compound, the lower end of the shaft projecting through the skin on the side or in the popliteal space. The popliteal vessels have been torn or, more frequently, so pressed upon that circulation was interrupted or seriously diminished. In one case a popliteal aneurism appeared several years later and was attributed to the accident.

In some, even of the cases which were not compound, suppuration has ensued; in others the pressure of the end of the fragment has caused the skin to slough, and in others gangrene of the leg followed.

In a few cases of recovery without displacement arrest or diminution of growth has been observed. Puzey¹ noted in a lad sixteen years old

FIG. 216.



Separation of the lower epiphysis of the femur. Incomplete displacement forward. (St. Bartholomew's Hospital, POLAND.)

¹ Puzey : Liverpool Medico-Chirurgical Journal, January, 1855, p. 41.

at the time of the accident shortening of one inch three years later. In other cases examined with reference to this point growth has not been interfered with.

Symptoms. Examination under anæsthesia should make it possible, unless the swelling is too great, to establish the identity of the two fragments and their relations to each other, to recognize that one is the lower end of the shaft and the other the epiphysis in normal relations with the tibia. This excludes dislocation; and then the distinction between low fracture through the shaft and separation of the epiphysis is made by the character of the crepitus—bony in one case, possibly cartilaginous in the other—the age of the patient, and the relations of the line of fracture to the adductor tubercle which lies immediately above the conjugal cartilage.

When the injury is compound the denudation of the shaft and the regular, slightly curved surface of its end demonstrate its character.

Rupture of, or pressure upon, the artery is shown by the absence of pulsation in the vessels below; rupture of the vein might be suspected if the bleeding was profuse and venous, but could be demonstrated only by direct inspection.

Treatment. The recorded cases show a very large proportion of amputations, primary or secondary, and of deaths from shock, infection, and operation, but it seems reasonable to believe, especially in view of some of the later cases, that the future will show much better results. Patients have suffered in the past both from infection, which can now be more generally avoided, and from a consequent reluctance to take the chances of conservative treatment in compound injuries or to make an incision in the simple ones in order to effect reduction. Some of the amputations have clearly been justified, and will still be justified in similar cases, by the extent of the injury to the soft parts, but I feel sure that a much larger proportion of the compound injuries will be successfully treated with preservation of the limb, and of the simple ones with restoration of form and function. Dr. McBurney's two cases are particularly encouraging.

If, in a simple case uncomplicated by injury to the vessels, complete reduction of the displacement cannot be made by traction and manipulation, it would be not only proper, but, I think, imperative, to expose the fracture by a longitudinal incision, preferably on the outer side in front of the tendon of the biceps, in order to overcome the obstacle, which would doubtless be the interposed periosteum and perhaps some muscular bundles. Schuchardt¹ reports a successful case, and I have had one.

In a compound case free enlargement of the wound in the skin and fascia would probably make reduction possible without the aid of resection of the end of the shaft. If the injury to the vessels is such that the vitality of the limb cannot be preserved, amputation must be done, and it should be as low as the condition of the soft parts will permit, that is, through or a short distance above the fracture. It seems even possible that in some cases the amputation might be done a short distance below the knee so as to preserve that joint to the patient.

¹ Schuchardt: Beilage zum Centralblatt für Chirurgie, 1901, p. 146.

Hutchinson advises that the limb should be immobilized in full flexion after reduction, on the theory that the pressure of the quadriceps in that position would keep the fragment securely in place. I doubt if there is enough tendency to displacement to justify so irksome an attitude.

C. Fracture of Either Condyle.

Fracture of a single condyle may be caused by direct violence, as in a fall upon the bent knee, or by avulsion, the force being exerted through one of the lateral ligaments to tear off one condyle by bending the leg toward the opposite side, or by the direct pressure of the head of the tibia against the condyle on the side toward which the leg is bent. In a case reported by A. H. Crosby¹ the fracture was caused by a twist of the leg while the patient, a youth of twenty-one years, was resting his entire weight upon it.

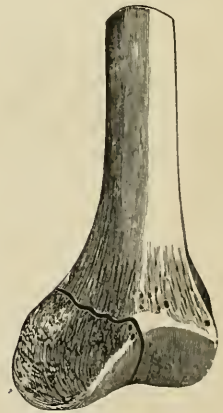
The specimens of fracture of a single condyle are not numerous, but they show that the line may run for a considerable distance upward from the intercondyloid notch so that the fragment terminates above in a long point, or it may turn abruptly above the edge of the articular cartilage toward the side of the bone, as in Fig. 217. A unique case of fracture of the posterior portion of the external condyle was reported by Braun.²

The fragment may be displaced upward, or to one side, or it may be swung around so as to lie partly behind or partly in front of the femur, usually the former. As it remains attached to the tibia the first and third displacements are indicated by the posture of the leg, the second, which is very rare, by the greater breadth of the knee.

As the displacement is usually slight, and the connections untornd, the injury may easily be overlooked, or, if suspected, not recognized with certainty. In a case under the care of Gosselin (quoted by Trélat) the patient was treated for more than a month for a supposed arthritis of the knee; he grew weaker daily and died of exhaustion. At the autopsy the joint was found full of pus and one of the condyles broken. The fragments were in exact apposition, but there was no sign of repair. The diagnosis must be made upon the localized pain, ecchymosis, loss of function, and abnormal mobility and crepitus, recognized by direct manipulation of the condyle or by moving the leg laterally or in the direction of flexion and extension.

The reported cases show a remarkable variety in their course and terminations. Some patients have recovered without greater reaction

FIG. 217.



Fracture of the internal condyle of the femur.

¹ Crosby: *New Hampshire Journal of Medicine*, 1857.

² Braun: *Arch. für klin. Chir.*, vol. 42, p.108.

than would be expected after a simple non-articular fracture ; in others the joint has suppurated, and the case has terminated fatally ; in Dr. Crosby's case the fragment was removed six months afterward, by operation, and the patient made a complete recovery ; and in a case first seen by Hamilton three months after the injury, the fragment remained ununited and could be moved upward half an inch with distinct crepitus and pain by flexing the knee. During the next two years the usefulness of the limb increased steadily.

Treatment. The treatment consists in reduction of such displacement as may exist by acting upon the fragment through the lateral ligament and the leg, and prevention of its recurrence by keeping the leg fixed in the position to which it has been brought in making the reduction. As the lateral ligaments are tense when the knee is extended, and relaxed when it is flexed, the extended position is the one which gives most security. The objection urged by Malgaigne, that it favors ankylosis, is, I think, unfounded ; we know that the common cause of ankylosis lies in the severity or the prolongation of an arthritis, not in the position in which the joint is kept. In the flexed position of the knee a slight displacement upward of the fragment could occur easily, and it would certainly pass unrecognized so long as the position was kept, and would show itself in abduction or adduction of the leg as soon as it was extended. I prefer, therefore, to treat a case in the extended position upon a posterior splint or in a plaster bandage. After three or four weeks the knee may be partly flexed if the fragment has lost its mobility.

Massage is useful to shorten the period of convalescence and hasten the restoration of function. Incision of the joint for the removal of a large amount of blood from it could probably be safely done and would diminish the chance of limitation of motion.

CHAPTER XXIV.

FRACTURES OF THE PATELLA.

ACCORDING to published records fractures of the patella represent from one to two per cent. of all fractures. They are much more frequent in men than in women, and in middle life than in childhood or old age. The youngest of Malgaigne's patients was eleven years old, and he knew of no other younger than seventeen years. The youngest patient in the 127 cases collected by Hamilton was five years old, and the fracture was very different from the usual one since only a small piece was broken from the margin of the bone by a direct blow; his next youngest case was sixteen years old, and in this also the fracture was by direct violence. Dittmer¹ reports one in a boy nine years old.

Causes.

The cause may be direct or indirect, a blow or fall upon the patella or the sudden vigorous contraction of the quadriceps femoris, or the sudden flexing of the knee against the opposition of the quadriceps. The statistics that have been collected to show the relative frequency of these varieties vary widely and are, I think, untrustworthy because of the difficulty, or rather the impossibility, in many cases of recognizing the mode in which the fracture has been produced. The patient slips or stumbles, makes an effort to save himself, falls, and the patella is found to be broken. He is unable to say whether he struck upon the patella or upon the tuberosity of the tibia, whether directly in front or upon the side, or, and this I have often met with, he asserts that he fell upon the patella because he knows it is broken, and cannot understand that the lesion could have been produced in any other way. If the examination is pushed, and the question asked, "How do you know it?" the answer is often, "Why, it *must* have been so."

My own conviction is that the efficient agent in the great majority of cases is the contraction of the quadriceps, either directly or by the forced flexion of the knee against its opposition, and the grounds for this belief are the numerous cases in which this mode of production can be clearly demonstrated, the practical impossibility of producing any but a comminuted fracture experimentally by direct violence, and the position of the patella, which is such that the blow is rarely received upon it in a fall.

The question whether muscular contraction breaks it by direct traction or by bending it over the convexity of the condyles is of purely academical interest, and in most cases it cannot be answered positively because the position of the bone at the moment of fracture with reference to the condyles cannot be known. In a few cases the fracture has been caused, beyond question, by simple traction without bending or cross-strain, as in a case reported by Garreau² in which a second frac-

¹ Dittmer: Langebeck's Archives, vol. lii. ² Garreau: Revue Médico-Chirurg., 1853, p. 375.

ture by muscular action occurred in the upper fragment twelve years after the first fracture had healed with a separation of four centimetres ($1\frac{3}{5}$ inches). In others it is equally certain that the traction of the ligamentum patellæ was inclined somewhat backward from the long axis of the patella, the fracture taking place when the limb was partly flexed.

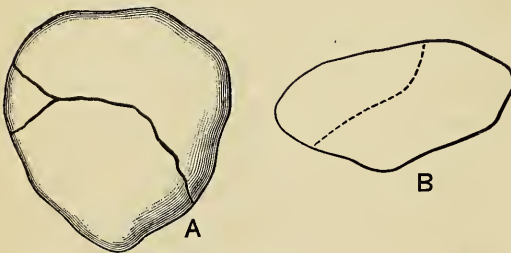
The common clinical form is a vigorous contraction of the quadriceps, either simply in voluntary use of the limb or aided by forced flexion of the knee by forces which overcome the opposition of the muscles. Thus, a man jumps and breaks the patella, or he fails in an effort to avoid a fall and the leg is bent under him, or, as in a case of my own, he seeks to push a heavy box with his foot resting against its side and the knee partly flexed, the foot slips down, the flexion of the knee is sharply increased thereby, and the bone is broken. This forcible flexion is a frequent cause of early refracture while motion is still limited and the descent of the upper fragment prevented by adhesions or peri-articular thickening.

In a few cases there is reason to think that a blow upon the bone has cracked it or originated some process in it by which its complete fracture by muscular action shortly afterward was made easy.

Pathology.

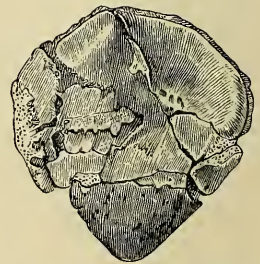In the great majority of cases by indirect violence the fracture is transverse or slightly oblique, and usually at or just below the middle

FIG. 218.



Unusual form of fracture of patella. A, anterior surface;
B, mesial section.

FIG. 219.



Comminuted fracture of the patella. Bony union. Exuberant callus at several points. (GURLT.)

of the bone; sometimes it lies very near one end of the bone, especially the lower, and once or twice I have seen it crossing and separating only the upper inner corner. Hoffa¹ saw a fracture of a small piece of the outer border by muscular action. I have occasionally seen the lower fragment split longitudinally, and I have seen one case (Fig. 218) in which on inspection through an incision the surface of fracture was found to be very oblique downward and backward and was also curved downward on the anterior aspect. Parke² reports a somewhat similar one seen two months after the accident; the injury was apparently caused by direct lateral pressure, and the upper and posterior fragment, comprising nearly half the bone, lay wholly above the other.

¹ Hoffa: Deutsche Med. Wochenschrift, Ver Beil, 1903, p. 111.

² Parke: New York Medical Journal, March, 1893, p. 303.

PLATE XXIX.




Fig. 1.—Fracture of Patella, five months old; after treatment by straight splint.
Active extension almost complete

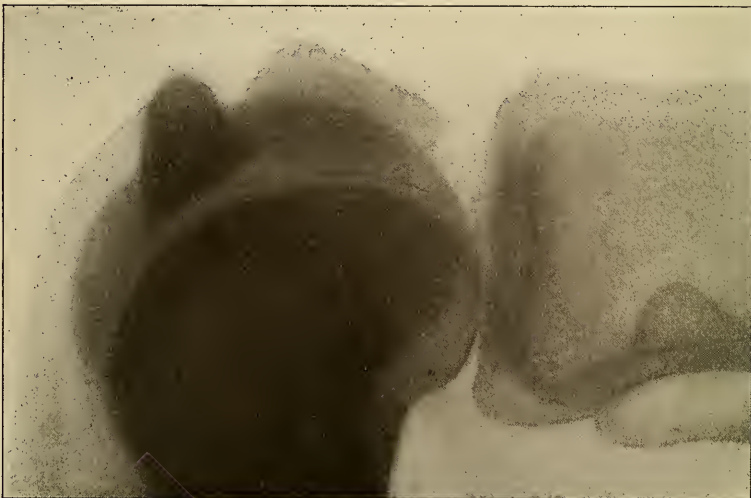

Fig. 2.—Fracture of Patella; two years after mediate suture.

A unique case of fracture in the frontal plane— anterior and posterior fragments—with outward dislocation of the posterior piece, is reported by Kroner in *Centralblatt für Chir.*, 1904, p. 1469. He thought the dislocation preceded the fracture.

Vertical, comminuted, and some oblique fractures are due to direct violence, and rarely show much displacement.

The displacement after transverse fracture is ordinarily well marked, its degree being modified by the extent to which the periosteum and lateral expansions are torn. Occasionally there is none. The separation, which may be an inch or more, is due in part to the retraction of the quadriceps and the tension of the fascia lata and in part to distention of the joint by blood and exudate. While the injury is fresh the quadriceps, even when actively contracted, can rarely separate the fragments for more than a short distance when the knee is fully extended and the hip somewhat flexed. Later, if the fragments remain ununited, the gradual shortening of the muscles increases the interval.

A third cause, which acts less promptly, is the gradual retraction of the ligamentum patellæ; in one of Malgaigne's¹ old cases it was shortened one-half, measuring only three centimetres, and in one reported by Brunner² it was shortened from five and a half to one and a half centimetres.

Occasionally the lower fragment is so rotated that its fractured surface is directed forward.

The other displacements are more readily recognizable later. They are lateral displacement and angular displacement, the angle pointing forward, backward, or to one side. Lateral angular displacement appears to be commonly the result of uneven stretching of the fibrous union after the patient begins to use the limb; anterior angular displacement is not only produced by the pressure of pads or bandages above and below the fragments when the latter are in contact, or nearly so, but it is also the inevitable effect of separation by distention of the joint, and may apparently be caused by cicatricial retraction of the lateral soft parts. I have seen in a skiagram the upper fragment turned so that its fractured surface was directed backward. (Plate XXIX., fig. 1.)

The associated injuries to the soft parts have become well known through the opportunities for direct inspection furnished by frequent resort of late to open arthrotomy in treatment. They involve the fibro-periosteal envelope of the front of the bone, the lateral expansions and capsule on the sides, and the fascial expansions downward.

The fibro-periosteal layer on the front of the bone is usually torn at a level different in part from that of the fracture and rather irregularly, so that it projects from the edge of one or the other fragment, usually the upper, as a ragged fringe, sometimes fully half an inch wide, which drops over the fractured surface and is thus interposed between the fragments when they are brought together. Macewen was the first to call special attention to this fringe and to suggest that it might be a bar to close, firm union. It is sometimes notably supplemented by one or more long strips of fascia (I have seen them more

¹ Malgaigne: Atlas, Plate xiv., Fig. 4, and p. 17.

² Brunner: Deutsche med. Wochenschrift, May 17, 1888.

than four inches long) attached to the upper fragment and drawn up from the region immediately below, lying curled up in the joint between the fragments. The lateral expansions and the capsule are freely torn on each side transversely, except in the rare cases without separation.

The fracture may be made compound by direct violence or by tearing of the skin in the separation of the fragments when it has become adherent to the patella by an inflammatory or cicatricial process. The common instances of the latter are in refracture, especially after operative treatment of the first fracture; much more rarely in a primary fracture after a wound of the skin which has not entirely healed.

Symptoms.

In fractures by muscular action, with or without a fall, a sharp crack may be heard and the patient is usually unable to use his limb. In a few cases he has walked, and, indeed, in most it is possible to walk backward, keeping the knee extended by the pressure of the heel on the ground, or even to walk forward if the uninjured limb is advanced and the other swung up to it but not beyond it.

The knee becomes promptly swollen by an effusion of blood or synovia into it and by tumefaction of the soft parts, especially if a blow has been received upon it, and the two fragments, separated usually by a well-marked interval, can be made out and their independent mobility recognized. This mobility may be very slight if the fragments are close together. Crepitus can often be felt when the fragments are pressed together.

The subjective symptoms are moderate pain when the limb is at rest, increased by movement and by pressing the fragments together and by pressure along the edge of a fragment, and inability actively to extend the leg or to raise the heel from the bed. It must be remembered that in rare, entirely exceptional, cases the fibrous covering of the bone may remain untear and constitute a sufficient connection between the fragments to make a limited use of the limb possible.

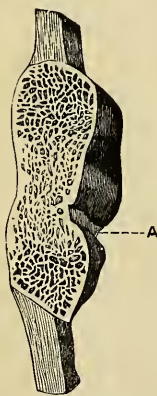
In vertical or comminuted fractures the signs recognized by palpation will vary in accordance with the differences in the lines of the fracture, and in the former active extension will be prevented only by the pain attending the effort.

Course and Termination.

The region swells promptly, partly by reaction of the overlying soft parts, partly by the distention of the joint by blood and synovia; the swelling can be largely prevented or rapidly reduced by methodical pressure, preferably by an elastic bandage.

If the fragments are kept fairly well together and if neither is tilted a fibrous bond forms between them which may ossify wholly or in

FIG. 220.



Bony union after fracture of the patella. (Specimen 201 of the Musée Dupuytren.)

PLATE XXX.

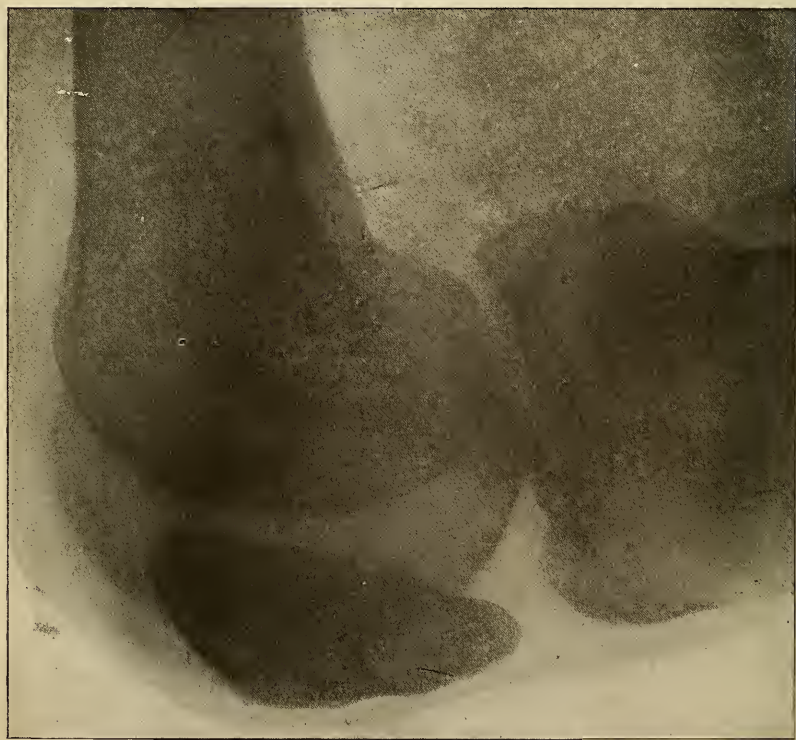

Fig. 1.—Fracture of Patella; three years after periosteal suture.

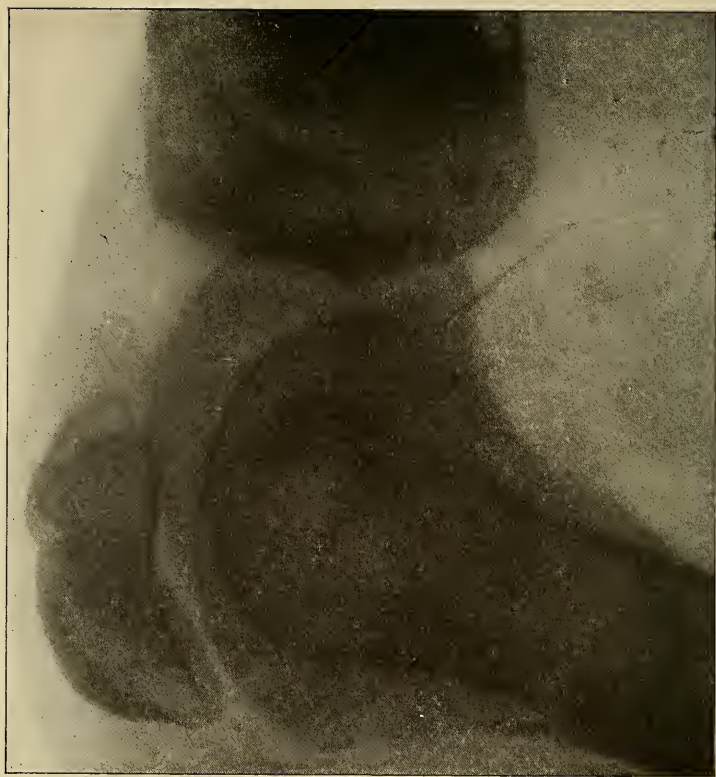

Fig. 2.—Patella; three months after periosteal suture of fracture.

part if the contact is very exact (Fig. 220 and Plates XXIX. and XXX.), but which in cases not treated by operation almost always remains fibrous and usually lengthens somewhat under use during the first few months. Even in some operative cases which have again come to direct inspection after many months, the union which was so close that no independent mobility could be recognized has been found to be fibrous. Some of the skiagrams I have taken have shown bony union only in the posterior half or three-fourths. They also show an angular displacement producing a slight concavity of the articular surface which, according to Chaput,¹ favors full restoration of function. If the fragments are not kept together, or if one is turned so

FIG. 221.



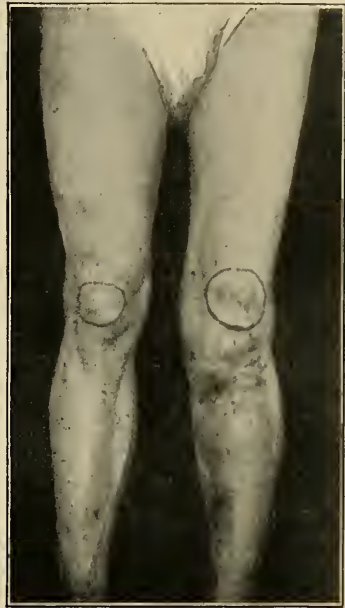Fibrous union with great separation, after fracture of the patella. The band adheres to the broken surface of the lower fragment. (Holmes's System.)

FIG. 222.



Long fibrous union.

FIG. 223.



Hypertrophy of patella after fracture and wiring.

that its fractured surface is directed forward or backward, the union between them is by a bond formed mainly by the overlying soft parts (Fig. 221), but sometimes by a thicker one apparently of new formation (Fig. 222); it seems probable that the latter form is produced by the elongation of a shorter bond formed under favorable conditions of proximity and position.

Hypertrophy of the fragments is frequently noticed and sometimes appears mechanically to limit flexion of the knee; occasionally also bony nodules, sometimes quite large, form within the connecting band.

¹ Chaput: Thèse de Paris, 1885, and Bull. de la Soc. Anat., April, 1888, p. 459.

Once I found ossification of the upper half of the ligamentum patellæ. (Plate XXXI.)

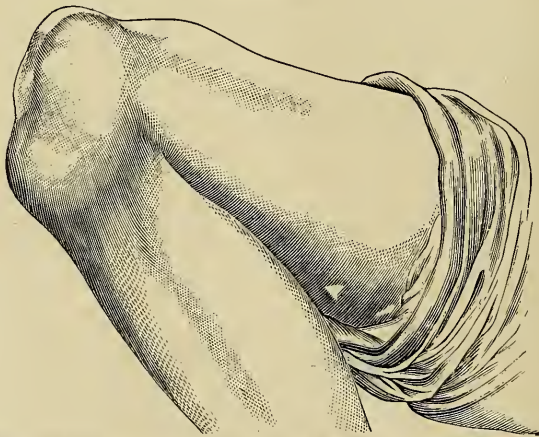
On the first attempts to use the limb, whether these are made promptly or only after a month or two, the joint is found to be very stiff, but usually the range increases quite rapidly and full active flexion and extension are ultimately re-established. In a certain, not large, proportion of cases there is notable loss of function: either inability fully to flex, or almost complete loss of active extension although the joint is freely movable, or inability to make complete active extension, the limb remaining slightly flexed.

These disabilities coincide with and presumably depend upon the varying conditions of the fragments and uniting bond which have been described.

Inability to flex appears to be largely due to retraction of the portion of the capsule attached to the upper fragment and of the fascia lata on the outer side, especially of the upper side of the rent in the lateral expansion, and sometimes to enlargement of the patella, itself the result of hypertrophy of the fragments or of a short stiff bond between them which makes the bone too long to turn over the curve of the condyles. Retraction of the quadriceps seems not to be an important factor in this disability. (See also the section on Disability After Fracture.)

Loss of active extension, when marked and when combined with free flexion, is due to insufficient union between the fragments and the absence of complementary fascial connections between the quadriceps

FIG. 224.



Extreme separation of the fragments after fracture of the patella.

and the leg, such as are found in some cases. It is most marked when the fracture is in the lower half of the bone, because of the loss of the lower fibres of the vasti. It is remarkable that this loss interferes so slightly with ordinary use of the limb in most cases; the patients often walk easily and securely, although they are exposed to fall whenever their weight rests only on the partly flexed limb. They seem instinc-

PLATE XXXI.



Fracture of Patella. Ossification of upper portion of ligamentum patellæ.

tively to depend upon the sound limb whenever the use of the damaged one would be unsafe. There is difficulty in going up and down stairs and in rising from a seat. In the case represented in Fig. 224 the patient claimed not to be aware of any noteworthy defect in the limb although active extension was almost entirely absent.

The common defect is slight limitation of active extension, the patient being unable to raise the heel from the bed without first slightly flexing the knee.

Degeneration of the quadriceps in direct consequence of the trauma has been alleged as a cause of diminution of the power of active extension, and has been used as an argument for early resort to massage.

Rupture of the uniting band or bone ("refracture") is not infrequent in the first few months, or even much later when flexion has remained limited. The cause is forcible flexion of the knee beyond the range that has been acquired, as in a fall; it has occasionally been caused by the surgeon in an attempt to increase the range by passive motion. The mechanism is the pulling away of the lower fragment, the corresponding descent of the upper being prevented by the previously mentioned conditions. Occasionally the soft parts, including the skin, have been so adherent that the rupture has involved them also, thus freely opening the joint. In the past such an accident was frequently followed by suppuration of the joint and the consequent loss of limb or life. This complication is more likely to happen when the skin over the fracture has been transversely incised in operative treatment.

Fracture of a fragment has occurred in a few cases.

The course of a compound fracture depends on the occurrence or avoidance of infection; if it is avoided the course and termination are practically those of simple fracture; if it occurs it creates serious risk to life and limb, leading to ankylosis or amputation.

Treatment.

The obstacles to apposition of the fragments and their close reunion are the pull of the quadriceps, the distention of the joint, and the interposition of the fibro-periosteal fringe or aponeurotic shreds. Later causes of limitation of function are adhesions and retraction of the soft parts of the joint, hypertrophy of the fragments, and possibly degeneration of the quadriceps.

The numerous methods of treatment, which respectively seek more or less specifically to remove one or another obstacle or late consequence, may be grouped as *operative* and *non-operative*, including in the former those in which the fragments are mechanically fastened together either after open arthrotomy or by means introduced subcutaneously or acting temporarily or permanently through the punctured skin; in short, those which distinctly involve the chance of infection of the joint.

The points to be considered in choosing between these two main methods are that a long experience has shown that non-operative methods furnish in the great majority of cases in which they are properly used a result which is functionally satisfactory even if the union

of the fragments is not close, that most of the failures are apparently due to unfitness of the method chosen or its faulty use, that only in a small proportion of cases are the conditions such as to make a bad result inevitable without resort to operative methods, and that most of the later causes of limitation of function are equally active after either method of treatment. That direct mechanical approximation and maintenance of the fragments, if the dangers of the operation are escaped, practically annuls or ensures the removal of the primary obstacles in all cases, notably hastens the restoration of function, and probably makes that restoration more complete in some cases, besides making it possible in those in which otherwise it would certainly fail to be obtained, cannot be denied. On the other hand, operation exposes to infection; and if infection occurs the result is almost certain to be a stiff joint, amputation, or death. In short, it takes less time and makes a good result more certain, but some of its failures are disastrous to an extent for beyond that of non-operative failures.

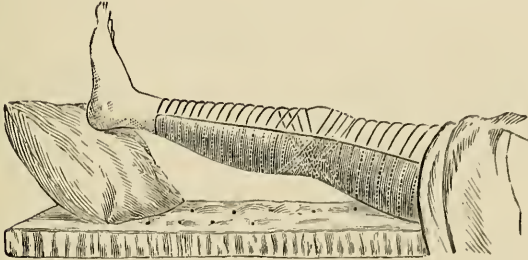
If there was no risk in an open operation it would deserve selection in almost every case, if only because it makes possible the removal of those certain causes of failure which are sometimes present and cannot otherwise be recognized and removed, such as tilting of the fragments and the interposition of bundles of fascia. The propriety of resort to operation turns, therefore, in the absence of special reasons, upon the measure of safety with which it can be done, and while I believe that certain methods, when surrounded by every precaution, can be employed with an assurance of success that justifies resort to them, and while I habitually use them, yet I have never taught them as routine practice, but on the contrary have strongly advised against their use except by those who can bring to them not merely experience in operating but also the *habit* of taking surgical precautions and the aid of trained assistants who have the same habit, who are practising those precautions daily; in short, the personnel of an active surgical hospital service. I do not mean that any one of the many operative methods proposed and used can be done with this assurance of success, but only that the one with which I am familiar, and which now (February, 1907) I have used in nearly two hundred and fifty cases without accident, can be so done, and that only because it is freer than most operations from those more or less unavoidable causes to which we attribute our disasters. I refer especially to the difficulty of making the hands clean. The general practitioner, and even the occasional surgeon, is not only fully justified in using a non-operative method but ought to do so; and he can feel assured that the methods at his command justify the expectation of a satisfactory, even if not perfect, result.

1. Non-operative Treatment. The opposing factors specially sought to be controlled by most of the methods are the effusion in the joint and the action of the quadriceps to create or maintain separation.

The production of the effusion may be opposed by systematic pressure or cold; its absorption may be hastened by pressure or massage, or it may be immediately removed by puncture or aspiration. I prefer pressure with a light rubber bandage; this will remove the effusion rapidly or, if the case is seen early, will notably limit its production.

Immediate removal of the effusion by aspiration or puncture, with or without washing of the joint, is occasionally practised, but, except in rare conditions such as a large intra-articular hæmatoma, has no

FIG. 225.



Dressing for fracture of the patella. The final turns of the roller in front of the knee are not shown in the cut.

marked superiority over the slower removal by pressure. If washing is done it should be with a hot sterile salt solution, not with carbolic acid.

After removal, immediate or gradual, recurrence must be opposed by bandaging; the application of strips of adhesive plaster so as entirely to cover the front and sides of the joint has been recommended, but a well-applied roller is probably equally efficient.

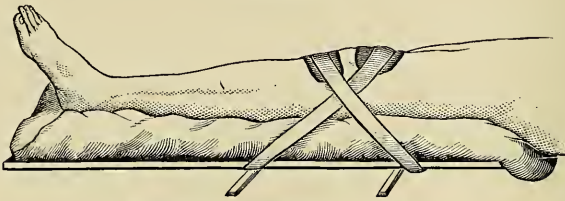
Approximation of the fragments is effected by the hands, and its maintenance by a great variety of devices from a simple circular bandage to complex apparatus. All are combined with a posterior splint for immobilization and usually with confinement to the bed with the foot raised for at least a month. As for active separation of the fragments by the quadriceps, full extension of the knee with elevation of the foot (flexion of the hip) prevents it.

The simplest form is a roller-bandage applied over a long straight or, better, a moulded posterior splint, the turns immediately above and below the fragments being placed obliquely, as shown in Fig. 225. Fixation has been sought in encasement in plaster of Paris by pressing the still soft dressing snugly down above and below the fragments and maintaining the pressure until the dressing has hardened, but an irremovable dressing which prevents inspection exposes to rude disappointment on its removal, for as the limb grows loose within the control of the fragments is lost and separation may occur and remain unrecognized until it is too late to remedy it.

More exact fixation of the upper fragment has been sought by fixed or elastic traction on the skin close above it, so applied that its pressure will be downward and backward and thus act upon the fragment. Thus, a strip of adhesive plaster an inch or two wide is laid across close above the fragment and its ends carried downward on either side to the sides or back of the splint at the calf, as in Fig. 226. For a number of years I used this plan, sometimes with a piece of rubber tubing interposed on each side to make the traction elastic, and was

well satisfied with the results. Sometimes the plaster is cut in a broad U-shape that it may fit better.

FIG. 226.



Fracture of the patella. (LAUGIER.)

Massage has been strongly recommended to reduce the swelling, prevent adhesions, diminish retraction of the capsule, regenerate the quadriceps, and hasten convalescence. It has even been claimed that it could be trusted to secure a good result without immobilization of the joint or confinement to bed, but even its most ardent recent advocates have not repeated the claim. I do not think it removes the effusion as rapidly and conveniently as elastic pressure does; after the second or third week it hastens absorption of the exudate and improves the circulation as after other injuries, but I doubt if it does more than somewhat shorten the period of convalescence.

In most fractures by direct violence the preservation of much of the periosteal envelope prevents separation, and no special measures are required to keep the fragments together.

Thomas¹ reports eleven cases to prove that an excellent result can be easily obtained without confinement to bed. He simply immobilizes the joint by the splint which he uses in disease of the knee, two metal rods lying on either side, attached to the heel of the shoe, and fitted with a perineal band and three straps, one each behind the knee and across the front of the thigh and leg. It is worn for four or five months.

To summarize: an elastic bandage covering the patella and six inches above and below may be applied for a few days to reduce or prevent swelling, and if it keeps the fragments well together it may be continued for a fortnight. Then the limb is placed in a long posterior plaster gutter or on a straight posterior splint and bandaged from the foot to the upper part of the thigh, the turns immediately above and below the fragments being placed obliquely as above shown, and the patient is kept in bed on his back with his foot well raised. A month or six weeks after the accident the limb is encased in plaster and the patient allowed to go about on crutches. If the attention can be given, the splint may be cut open in front and removed daily for massage, and after a month it may be left off at night and then in the house during the day, and the patient encouraged to move the joint. The danger to be avoided is premature forcible flexion of the knee, which is most likely to happen by accident, as in a fall; the prolonged use of the splint is mainly as a protection against this accident. The closer the

¹ Thomas: *Provinc. Medical Journal*, August 1, 1889.

union the shorter the time it needs to be worn, but certainly no great strain should be put upon the bond until after the second month.

A few methods, which may be termed intermediate between the operative and non-operative, have been devised to act directly upon the fragments without the necessity of opening the joint, but as they require multiple punctures of the skin which must be kept open for several weeks, and as these punctures may communicate with the seat of fracture through the spaces created by the extravasated blood, the chance of infection exists as in open operation, while the work is done less easily and effectively.

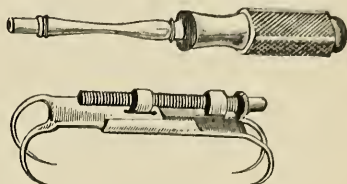
Malgaigne's hooks (Fig. 227), the earliest of these, may be taken as the type. The points of the hooks are passed through the skin and engaged respectively in the upper and lower ends of the patella, and then brought together by the screw until the fragments are coaptated. It is an efficient method and is usually well borne, but the presence of swelling may make the application difficult or impossible. They must be worn three or four weeks. The danger is of suppuration about the points and of its possible extension to the joint. The instrument has been modified by Levis—two separate pairs instead of a double one—by W. K. Otis, who made the individual parts adjustable, and by Duplay, who made it stronger and firmer. It has furnished many good results, and the accidents following its use have been few. Of course the punctures must be carefully protected. To avoid making punctures in the skin Trélat used two gutta-percha plates moulded to the surface above and below and engaged the hooks in them.

I devised and tried in a few cases¹ a modification consisting of a two-pronged fork bent on the flat, which was engaged in the upper fragment with its shank resting on the thigh above, and was drawn downward by an elastic cord. It is easier of adjustment than Malgaigne's hooks and did the work equally well, but suppuration about the points was occasionally free. I long ago abandoned it for the suture.

Mayo Robson² passed a steel pin transversely through the tendon of the quadriceps close to the upper edge of the patella, and another through the ligamentum patellæ close to the lower edge, and then drew the fragments together and maintained them by a ligature about the projecting portions of the pins on each side. I should think it an easier method than Malgaigne's. Dieffenbach had long before driven pegs into the fragments and tied them together.

Anderson³ modified Robson's method by passing the pins through the fibro-periosteal covering of the fragments, a disadvantageous change, I should think, because it brings the punctures nearer the fracture and

Fig. 227.



Malgaigne's hooks.

¹ Stimson: *New York Medical Journal*, January 3, 1885, p. 23.

² Robson: *British Medical Journal*, March 30, 1889.

³ Anderson: *Lancet*, July 2, 1892.

thereby increases the chance of infection of the joint in case suppuration should take place about the pins, as it did in one of his four cases.

Certain other methods of subcutaneous or temporary fixation which resemble the above in some respects will be mentioned in the next section because in all the joint is opened, directly or indirectly, through the gap made by the fracture, and as therefore direct and early infection is possible they should be compared with others carrying the same risk.

2. Operative Treatment. This, which began,¹ in the antiseptic period, with Lister's exposure of the fracture and wiring of the fragments, presents a great number of methods and procedures, some of which are a natural evolution from their predecessors in the direction of simplicity, efficiency, or safety, while others are merely novelties obtained at the price of some disadvantage or based upon the exaggeration of the importance of some indication. The fundamental idea is the mechanical fixation of the fragments by some form of suture, and the associated one is either the removal of the effusion or of the interposed periosteal fringe, or the reduction of the risk by the use of punctures instead of a free incision. Their comparison will be made easier by first considering certain facts and general principles.

The pull of the quadriceps when the knee is fully extended and the hip slightly flexed is so weak that even when the muscle is actively contracted it will not separate the fragments more than half an inch. I have repeatedly observed this during an open arthrotomy, and I have seen several patients pass through an attack of delirium tremens in the first week without tearing apart the fragments although they were fastened together only by catgut or light silk sutures. It is plain, therefore, that a strong suture, one of metal or heavy silk, is not necessary to the proper approximation of the fragments if the joint is not distended and if the foot is kept elevated. Consequently, any additional risk or complexity of procedure involved in the use of a strong suture is not justified. This, in my opinion, is sufficient for the rejection of all methods of suturing which require drilling of the bone, even without consideration of the other disadvantages of a permanent suture through it which have been described in Chapter VII.

The removal of the effusion facilitates approximation, reduces tension, and probably diminishes the chance of the formation of adhesions and peri-articular thickening and retraction. Other things being equal, therefore, methods which include such removal are preferable to those which do not, and if they also permit the adjustment of an interposed periosteal fringe or aponeurotic shred they have an additional advantage.

The periosteal fringe, long charged with much of the responsibility for failure of bony or close fibrous union, has been shown by large experience with operative methods in which it was disregarded to be usually a negligible factor; that is, long series of cases treated by subcutaneous suture have given close union in almost all, and yet it must be believed that a fringe of some size was present in most of them.

¹ In 1834 Dr. Barton, of Philadelphia, fastened the fragments together by a wire passed through them and knotted outside the skin; the patient died.

On the other hand, I think the large aponeurotic shreds which I have seen several times would probably have been a serious obstacle if they had been left, and possibly similar ones have been responsible for some of the failures noted under methods of treatment usually efficient. It is, therefore, not necessary to choose an open method of operating in order to adjust the fringe, but probably in a small proportion of cases there is present a fringe or shred of such size that it will diminish the success of any operation which does not effect its removal. Again, other things being equal, an open method better protects against this obstacle to success.

Infection may occur in any operation which wounds the skin, and the chance of its spread to the joint—the great danger—is greater if that wound communicates with the joint or the seat of fracture. The briefer the existence of that wound or of that connection, the less the danger. All the so-called subcutaneous methods require two or more small incisions, and in all a suture of silk or wire is passed either directly into the joint or through the line of fracture or its immediate neighborhood. If suppuration occurs at a puncture the suture opens a direct road for its spread to the joint. The size of the wound is not a measure of the chance of infection, that comes, if the common precautions are taken, mainly from the hands of the operator and his assistants.

Finally, the permanent presence in the tissues of a foreign body is not, according to general experience, a matter of indifference; occasionally suppuration takes place about it after a long interval, and not infrequently its removal has been required because of pain and irritation.

The operative methods are: (1) by open incision—direct suture of the fragments through holes drilled in them, suture of the fibro-periosteal layer and capsule, and mediate suture through the tendon of the quadriceps and ligamentum patellæ; (2) subcutaneous suture—by wire through the whole length of the fragments, or by silk through the tendons and crossing the front of the bone; (3) subcutaneous permanent ligature surrounding the fragments in the sagittal plane and lying partly in the joint; (4) temporary ligatures passing through the joint as in (3), or through the tendons as in (2), or through the bone, all tied outside the skin.

The methods are far too numerous to permit a detailed description and criticism, even if it were not probable that most of them will be abandoned in favor of the simpler and safer ones. Many of them, too, can be judged in classes. Thus, for reasons given above, I would reject all in which a permanent suture is placed in the bone itself.

Temporary ligature through the tendons (one of the earliest methods proposed), or through the bone, or around it through the joint seems to me to be more dangerous, because of the prolonged communication with the exterior, and less efficient than the similar subcutaneous methods.

The subcutaneous methods which can be done equally well by an open incision appear to have an equal risk with and to lack the advantages which belong to the latter.

Barker's subcutaneous ligature about the fragments (silver or silk

passing through the joint) opens a direct road for the spread to the joint of infection occurring at either puncture or small incision, and as it also fails to provide for satisfactory evacuation of the joint and adjustment of the periosteal fringe I should reject it. It appears to have met with considerable favor and success since its introduction in 1894 and has been warmly commended by several.

My personal experience is limited to the subcutaneous mediate silk suture through the tendon and the ligamentum patellæ (1889–1892, about forty cases) and open incision with the same or the fibro-periosteal suture (1892–1907, over two hundred cases). In the first series infection occurred twice and resulted in a stiff joint, suppuration appearing in one of them after the patient had left the hospital, apparently well, in the second week. In the second series all the cases have recovered without accident and with close union, except one case of slight superficial suppuration which did no harm; all that I have seen after the third month have had good use of the joint except one very stout nervous woman who could not be persuaded to abandon crutches; her patella was freely movable laterally and union was close, but flexion was limited to 30 degrees three months after the accident.

I began with the subcutaneous method because I thought its risks less than those of free incision, but when I found that the extravasated blood often escaped freely through some of the four small incisions and that consequently the suture lay free within the area of fracture and laceration I abandoned it for the single free incision and was soon convinced that the patient was equally, perhaps better, protected. A special advantage of the latter method is that the operation can be done without once touching the cut tissues with the fingers, and to that I attribute the complete freedom from infection. I have frequently done the operation under local anæsthesia—cocaine or freezing.

The method is as follows: The surface having been prepared, an incision is made in the median line slightly overlapping the two fragments; the sides are drawn apart, the fragments lifted in turn with a sharp retractor, and their surfaces freed from clot or fringe; while they are held up the joint is thoroughly washed with a hot sterile salt solution. Then the fragments are drawn snugly together with hooks, the fringe adjusted, and two or three catgut sutures placed in the periosteum along the edge of the fracture, or a single silk or stout catgut suture passed through the tendon and ligamentum patella so that its two strands lie on the front of the bone. Sometimes additional sutures are placed in the rents in the lateral expansions close to the bone. Blake¹ trusts entirely to these. The incision is closed without drainage with an uninterrupted silk suture, the dressing applied, and the limb bound upon a posterior splint. The patient is kept in bed with the foot elevated for a week, the silk suture of the incision is then removed, and a light plaster-of-Paris encasement applied. After a few days the patient leaves the hospital on crutches, and after a month the dressing is cut down the middle in front, and he is directed to wear it only in the daytime. Usually the joint can be flexed at least 90 degrees by the end of the third month, often earlier, and the patient usually discards

¹ Blake: Journal American Medical Association, Oct. 1, 1904.

the splint entirely before that time, since he is told it serves only as a protection against damage by a fall. In no case have I seen the fragments separate under use, but several have come back in the third or fourth month with refracture caused by a fall.

I have thrice used a transverse incision ; it permits more exact suturing of the rents in the lateral expansions, but I prefer the median incision.

I have treated a few cases without immobilization after the tenth day, but the gain in rapidity of restoration of function has not been sufficient to justify the risk of accident.

For Ceci's¹ method, first subcutaneous wire suture through bone ; Aiken's² modification, the wire passing only once through the bone and then back under the skin ; Barker's³ method, subcutaneous ligature through the joint about the patella ; my earlier method,⁴ subcutaneous mediate suture through the tendon and ligamentum, the reader is referred to the original accounts. Other plans not above mentioned are those of Wolff,⁵ open incision, two metal rivets driven into each fragment to receive silver wires by which the fragments are fastened together ; Kittredge,⁶ two similar rivets placed astride the line of fracture ; and Axford,⁷ temporary wire suture through the bone and back outside the skin. Other older temporary measures are Barton's (1834, the same as Axford's), Volkmann's silk loops transversely through the tendon and ligamentum patellæ and tied together over the skin, and Koehler's (1880) surrounding wire ligature, passing like Barker's through the joint beneath the patella but, unlike his, including the skin in its loop.

Compound fractures specially need protection from infection because of the importance of the joint and the danger to life or limb involved in its suppuration. If infection has already occurred the joint must be cleaned as thoroughly as possible and drainage provided on each side. The fragments must be sutured together.

Disability After Fracture. This may be due to stiffness of the joint or, much less frequently, to the loss of active extension. The causes of the former are varied, and but few of those which are permanent, which do not gradually diminish under use, can be removed by operation. Many attempts to relieve have been made upon the theory that the fault lay in separation of the fragments or in the absence of a firm bond between them, the usual plan being to open the joint and bring the fragments together. Failures have been numerous, either through inability to close the gap, or through infection, or through persistence of the disability after an operative success. Even in many of the cases in which improvement has followed the operation it seems probable that an equal improvement would have come in time without the aid of the interference. Chaput,⁸ who has thoroughly

¹ Ceci : Deutsche Zeitschrift für Chirurgie, February, 1888.

² Aiken : British Medical Journal, July 23, 1892.

³ Barker : Lancet, April 18, 1896, and American Text-book of Surgery, 1897.

⁴ Stimson : New York Medical Journal, May 10, 1890, p. 531, and American Text-book of Surgery, 1892.

⁵ Wolff : Deutsche med. Wochenschrift, May 14, 1891.

⁶ Kittredge : Boston Medical and Surgical Journal, November 19, 1891.

⁷ Axford : Annales of Surgery, July, 1898.

⁸ Chaput : Fractures anciennes de la Rotule. Thèse de Paris, 1885, and La Semaine Médicale, June 17, 1891.

studied the conditions, attributes the loss of flexion to hypertrophy or rigid elongation of the united patella by which it is made too long to pass around the condyles, or, much more frequently, to the ascent of the upper fragment (with a separation of two to five centimetres), in consequence of which the upper portion of the capsule and the lateral expansions become so shortened that the descent of the fragment is impossible, and it cannot be sufficiently mobilized without a division of its attachments too extensive to be practicable or perhaps compatible with its vitality; and even if the lower fragment is brought up to the upper one by detachment of the ligamentum patellæ from the tibia (Von Bergmann, 1887) and is united with it flexion would still be lost. This being so, what is required is not the approximation or reunion of the fragments but the removal of the obstacle to the descent of the upper one. Chaput did this in one case by excising the upper fragment and obtained a good result, the patient being able to walk up and down stairs and carry a burden of 200 pounds; the range of motion is not stated. His grouping of the different forms and their respective treatment is as follows:

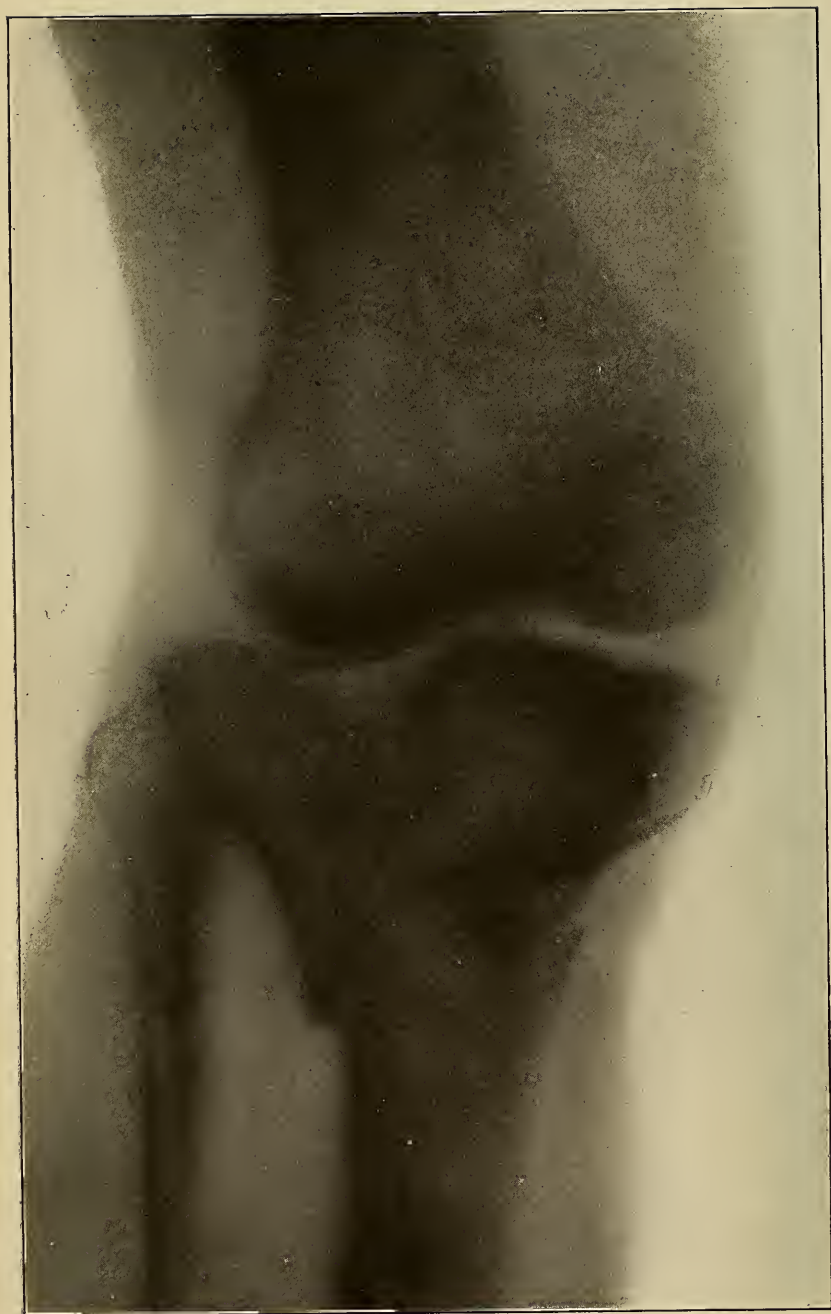1. Close union. Medical treatment and exercise.
2. Elongation of the patella by hypertrophy or a stiff bond with loss of flexion. Extirpation of the patella.
3. Short flexible bond. Massage.
4. Bond two to five centimetres long with loss of flexion. Extirpation of upper fragment.
5. Bonds more than five centimetres long, and those cases of class 4 in which active extension is lost. Suture of the fragments after free separation of the lower portion of the quadriceps and upper part of the capsule from the femur. This denudation of the femur he proposes to effect through a curved transverse incision at the level of the lower fragment or, if the gap is long, through a longitudinal one; for the denudation he would use the elevator or knife and would suture the fragments with wire because the strain might be too great for periosteal sutures.

Rupture of Bond ("Refracture"). This has rarely seemed to me to require more than rest in bed with the foot elevated. As it is caused by the tearing away of the lower fragment from the upper one in forcible flexion, full extension of the joint brings the torn surfaces into contact, and we have only to wait for them to reunite, opposing swelling, if necessary, by appropriate measures. Once or twice I have reopened the joint and again sutured the fragments, and, of course, this would be done if the fracture is compound. The prognosis is made worse by the prolongation of the confinement and the repetition of the trauma and its consequences.

Schanz¹ obtained a good functional result in a fracture five years old with a separation of twelve centimetres. Through an incision on the inner side from below the knee to the middle of the thigh, over the sartorius, this muscle was mobilized and secured by wire sutures upon the front of the fragments. Six weeks after operation the patient could run up stairs.

¹ Schanz: Beilage zum Centralblatt für Chir., 1903, p. 157.

PLATE XXXII.



Fracture of Upper End of Tibia by Abduction of the Leg.

CHAPTER XXV.

FRACTURES OF THE BONES OF THE LEG.

Of the upper end of tibia or both, separation of epiphysis of the tibia, avulsion of the spine, avulsion of the tubercle—Of the shaft of the tibia or both—At the lower end: Comminuted, supramalleolar, separation of epiphysis of tibia, by eversion and abduction (Potts), by inversion, of the posterior portion of the tibia—Of the fibula: Upper end, shaft, separation of epiphysis.

ACCORDING to the table in Chapter I. fractures of the shaft of the tibia or of both bones constitute one-fourth of those of the lower extremity, and more than 6 per cent. of all fractures. The more frequent seat is at or near the junction of the lower and middle thirds. When both bones are broken the fibula is usually broken at a higher level than the tibia.

Statistics show that infancy and childhood are almost exempt, and that the maximum of frequency is found between the ages of thirty and sixty years, those three decades, according to Malgaigne, furnishing equal numbers.

1. FRACTURES OF THE UPPER END OF THE TIBIA AND FIBULA OR OF THE TIBIA ALONE.¹

The causes of these fractures are direct and indirect violence; in the former a blow received directly upon the part, as the fall of a heavy body or the kick of a horse; in the latter a fall from a height or a twist of the limb, especially abduction.

The line of fracture may be transverse, oblique, or longitudinal, in the latter case passing into the joint and separating only a portion of the articular end from the shaft, or there may be a crush of the internal condyle of the tibia with rupture of the external lateral ligament. Transverse fractures by direct violence, the fall of a stone, the kick of a horse, have been observed at four and seven centimetres from the articular edge. Comminuted fractures have been caused by direct violence and by falls upon the feet, the shaft penetrating and splitting the head. Oblique fracture, the line running into the joint and separating the whole or part of either condyle, appears to be caused by abduction or adduction of the leg, the fracture taking place on the side toward which the leg is bent. The term *compression fracture* (Wagner) has been applied to a group comprising fracture of either condyle and more or less marked crushing of the head of the tibia by a fall upon the foot. Excluding the fractures of either condyle, in the production of which abduction and adduction of the leg take part respec-

¹ Including separation of the upper tibial epiphysis and avulsion of the tubercle of the tibia.

tively, they are characterized by swelling in and below the knee and by sensitiveness on pressure.

Of longitudinal fracture I have seen one case, a man of twenty-five years. The line of fracture ran from the inner part of the outer articular surface directly downward in a sagittal plane. The separation at the upper end was about half an inch and was maintained partly by a small fragment lodged deeply in the cleft, but even after removal of the latter the displacement could not be wholly reduced. The cause was a fall from a ladder, but the mechanism was not known. The joint was so loosened that the tibia could be moved outward nearly half an inch. Recovery took place with active flexion nearly to a right angle and marked genu valgum.

The displacement varies with the character of the fracture and the fracturing force; in a transverse fracture without comminution it is usually slight; in comminution of the upper end and in oblique frac-

FIG. 228.

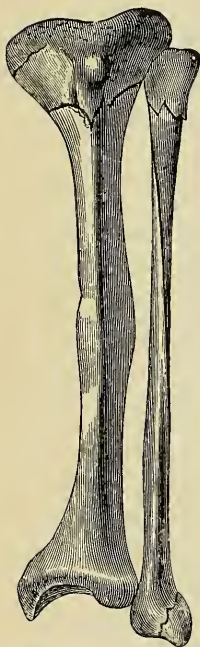
Fracture of upper ends
of both bones.

FIG. 229.

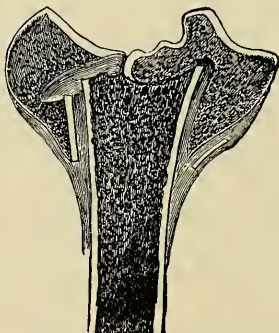
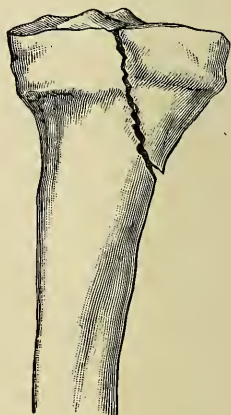
Fracture of the head of the tibia with
impaction and separation of the upper
fragments.

FIG. 230.

Fracture of the head
of the tibia.

ture of either tuberosity the fragment may be notably displaced or tilted. The direct or indirect implication of the joint ensures an effusion within it, and the proximity of the main vessels makes their injury more likely than in fracture at most other points. Both tibial arteries and the popliteal vein have been torn, the injury in every case leading to amputation or death.

Diagnosis. The diagnosis, in reaching which the aid of an anæsthetic may be required, is made by recognition of the irregularity of outline, pain on local pressure and on pressing the leg upward, and possibly abnormal mobility and crepitus. In high transverse fractures care must be taken not to mistake the injury for a subluxation of the knee.

Prognosis. The prognosis of this injury is exceptionally serious, because of the proximity of the joint and the possibility of inflamma-

tory complications and the more or less complete loss of the functions of the knee which that and the derangement of the articular surface in oblique and comminuted fractures involve, and also because of the exceptionally long period that is necessary for consolidation. The average period in seven cases collected by Poncet was about four months. No satisfactory explanation has been given of this peculiarity.

Treatment. Displacement must be corrected by traction and direct pressure according to its character, and retention effected either by permanent traction or by a suspended posterior splint with the knee partly flexed or by encasement of the entire limb in plaster. The indications vary so much with the position, direction, and extent of the fracture that general rules cannot well be made. Complete encasement is valuable to prevent bowing of the knee when the fracture extends into the joint.

When the fracture extends into the joint function may be so limited by an irregular position of the articular fragments that it may be wise to expose them by incision for more accurate adjustment. With proper precautions it would be justifiable if the irregularity is great and not otherwise remediable, but I have met with only one case that seemed to require it.

If the fracture is compound and if suppuration of the joint occurs a free outlet for the pus must be promptly provided by special openings at the sides rather than through the wound which can hardly fail to be unsuitably placed for effective drainage.

Separation of the Epiphysis

has been noted in a few cases. Bruns collected four, Hutchinson¹ says he has records of ten, including three unpublished cases, and Poland² collected twenty-four. The recently reported cases that I have seen are those of Heuston and Manly.³ In Hutchinson's list the extremes of age were one and sixteen years. The common cause appears to be a wrench of the leg, abduction or adduction, by which a transverse strain is made, but Poland thinks it is direct pressure against the epiphysis. One of Poland's was compound; the patient recovered. In twelve the patient died or the limb was amputated. The ages ranged from three to twenty years. In all but one case the process bearing the tubercle of the tibia accompanied the epiphysis. The displacement was forward, forward and outward, or lateral, and usually slight. In a number the diaphysis was also broken, and sometimes extensively. In several of the cases which recovered no trace remained of the injury.

Avulsion of the Spine of the Tibia

by traction through the crucial ligament, which has been noted a few times, is to be classed as a complication of dislocation of the knee rather than as a form of fracture.

¹ Hutchinson: *British Medical Journal*, March 31, 1894.

² Poland: *Traumatic Separation of the Epiphyses*, p. 802.

³ Heuston and Manly: *British Medical Journal*, July 21 and September 22, 1888.

Avulsion of the Tubercle of the Tibia.

To the tubercle is attached the ligamentum patellæ, and all the cases of its fracture which have been reported have been caused by the action of the quadriceps in some violent effort, usually jumping, and most of them in youths between twelve and eighteen years of age. The frequency in youth is to be accounted for by the fact that the tuberosity is a downward prolongation of the epiphysis and remains separated from the shaft by conjugal cartilage until growth is completed. Müller,¹ who wrote the first special article upon the subject, collected seven cases and added one of his own. Other formal papers are by Schlatter² and Osgood.³ To these may be added one by Keyser,⁴ one by Landsberg,⁵ one by Ware,⁶ and one by Gaudier and Bouret.⁷ The size of the fragment has varied in length from two to five centimetres, and in one exceptional case (Richet) the rupture ran partly through the tubercles (both legs) and partly through the ligamentum patellæ.

Symptoms. The symptoms are inability to use the limb immediately following the effort, which sometimes is accompanied by a cracking sound, and the recognition of a movable lump of bone about two inches below the patella. On pressing this lump downward and backward against the tibia crepitus is felt. The knee-joint is more or less distended by an effusion.

It seems to me that skiagraphic appearances—the existence of a clear line between the tubercle and the shaft—have led of late to the diagnosis of fracture in some of the common cases of slight injury which do not deserve to be thus classed. Thus, Schlatter, who claims seven cases in less than three years, includes those in which there was no sudden onset, no disability, no symptom except tenderness on pressure, cases, it seems to me, of slight ruptures of the periosteum or conjugal cartilage or even of exaggerated nutritive activity. I have seen a lump slowly form at the site of the tubercle in such cases. (See also Winslow, *Annals of Surgery*, February, 1905.)

Treatment. The treatment is to press the fragment into place and maintain it there by a bandage or strips of adhesive plaster while the limb is kept extended upon a splint for four or five weeks. Will, who opened the joint under the impression that he was dealing with a fracture of the patella, utilized his incision to pin the fragment in place with a steel drill, and obtained a good result. Dr. Tilton (oral communication) found the fragment so rotated that the fractured surface looked forward. He turned it down and fastened it with periosteal sutures.

The ultimate result has been good in all the cases, but in one the restoration of motion was not complete until after a year.

¹ Müller: Beiträge zur klin. Chir., November, 1887, p. 257.

² Schlatter: Ibid., 1903, vol. xxxviii, p. 874.

³ Osgood: Boston Medical and Surgical Journal, 1903, vol. cxlviii, p. 114.

⁴ Keyser: Reported in Sajous's Annual, 1888, vol. ii, p. 267.

⁵ Landsberg: Centralblatt für Chir., September 28, 1889.

⁶ Ware: Annals of Surgery, November, 1904, p. 739.

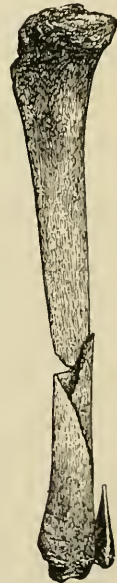⁷ Gaudier and Bouret: Revue de Chir., vol. 32, p. 305.

2. FRACTURES OF THE SHAFT.

Fractures by direct violence may occur at any point; those by indirect violence are much more frequent at or near the junction of the lower and middle thirds than at any other point. It seems probable, as taught more especially by Gosselin, that torsion of the limb is an important factor in the production of the fracture, the twist being due either to the forcible contraction of the muscles or to the propulsion of the upper portion while the lower one is fixed by the pressure of the foot upon the ground.

The varieties of fracture common to other long bones are found here, and in addition a form of spiral, the V-shaped fracture, first pointed out by Gosselin, which although occasionally found elsewhere is much more frequent in the leg. In these, which are especially frequent below the middle of the bone, the upper fragment terminates in front and on the inner side in a more or less sharp triangular point, the lower fragment presents a similar point posteriorly, and from the bottom of the depression in the lower fragment which corresponds to the first point a fissure passes spirally downward and usually runs into the ankle-joint, sometimes splitting off a superficial fragment on the posterior aspect as shown in Fig. 231. The extent of the fissures and the implication of the ankle-joint give this variety of fracture an especial importance.

FIG. 231.



V-shaped fracture.

It is uncommon for the tibia alone to be broken when the fracture is by indirect violence, for the force continues to act, if only for a moment, and breaks the weaker fibula all the more easily, and usually at a higher point than the tibia.

The subcutaneous position of the tibia throughout its entire length greatly exposes its fractures to the chance of becoming compound either by the direct action of the causative violence when the fracture is direct, or by the perforation of the skin by the end of one of the fragments, usually the upper one, when the fracture is indirect.

The displacements show the usual varieties, but the most common and important is the projection of the lower end of the upper fragment when it terminates in an anterior point, as it usually does, the contraction of the predominant muscles of the calf aiding it by creating an anterior angular displacement.

In addition to the usual symptoms of crepitus, abnormal mobility, pain, and loss of function, there is also the irregularity in the outline of the subcutaneous portion of the tibia which may be recognized by passing the finger along it. It is not always possible to say whether or not the fibula is broken as well as the tibia without making a more severe and painful examination than the need of the information will justify. When both bones are broken the mobility is usually much greater than when the tibia alone is broken, and by making gentle

pressure with the finger along the line of the fibula the point of fracture can usually be determined.

Beside the frequent complication of a communicating wound of the skin, and the comminution which is so often the result of direct violence, injury to the principal vessels is occasionally met with. Nepveu,¹ in a very complete and elaborate paper read before the Surgical Society of Paris, collected more than fifty cases, among which are found examples of injury to both tibials, the peroneal, and the nutrient artery of the tibia. Injury to the tibial or peroneal nerves seems to be much more rare. Mourret collected twenty-seven cases of aneurism complicating fracture, five of which were mistaken for abscess and opened.

I have seen hemorrhage occur from the anterior tibial on the eighth day after fracture by direct violence without displacement; the rupture was one and a quarter inches above the fracture and was evidently due to bruising of the artery by the wheel which caused the fracture.

A simple fracture without persistent displacement will usually become firmly consolidated in six weeks; but in the comminuted ones and in those that are oblique with persistent displacement the callus remains weak much longer. Complete recovery is long delayed by rigidity at the ankle, tenderness of the skin, feebleness of the circulation, and neuralgic pains which are more common after fractures of the leg than after those of other long bones. In the old and rheumatic this delay is especially prolonged.

If the suppuration becomes free after a compound fracture it is probable that complete recovery will be postponed for even a much longer time, and that sinuses leading down to bare or necrosed bone will remain open for many months or will reopen at intervals. On the other hand, the subcutaneous position of the tibia makes it easier to drain the cavity of the fracture thoroughly and to remove splinters, and thus makes the danger to life less than after compound fracture of bones that are more deeply placed.

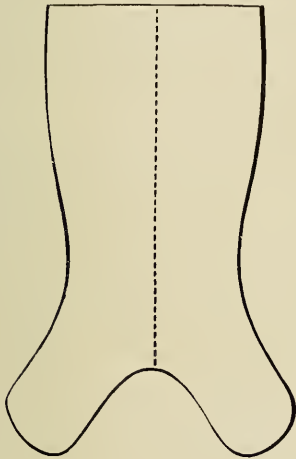
Treatment. Reduction of the displacement can generally be made by traction at the foot and counter-extension at the knee, this joint being slightly flexed to relax the muscles of the calf. In the more difficult cases in which spasm of the muscles opposes reduction compression of the femoral artery for a few minutes, as suggested by Broca, has sometimes seemed to be useful in my experience. In a small proportion of cases complete reduction is impossible, probably because of the interposition of a small piece of bone or of a muscular bundle between the fragments.

Maintenance of the reduction depends largely upon the character of the fracture; when this is nearly transverse and toothed, the displacement is unlikely to recur; but when it is oblique the difficulties of complete retention may be great. The segment of the limb below the fracture is too short to permit traction by strips of adhesive plaster, as in fracture of the thigh, and the surgeon has to depend upon some form of splint or an immovable dressing, neither of which will certainly prevent shortening, although the amount may be so slight as to be without practical importance.

¹Nepveu: *Bulletins de la Société de Chirurgie*, 1875, p. 365.

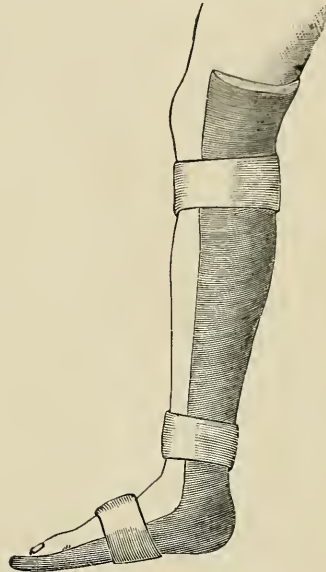
The usual routine of treatment in simple fractures without marked displacement is to put the patient in bed with the limb in a Volkmann splint (Fig. 36) for about a week or until the swelling has subsided, and then to encase it in plaster of Paris. Under the prolonged use of the Volkmann splint some shortening, usually slight, is likely to occur. Immediate application of plaster is objectionable because either the swelling is likely to increase and make the dressing too tight, or it will diminish and leave it too loose. The stocking bivalve plaster splint (Fig. 232) is a convenient means of combining the advantages of the primary Volkmann splint and the later encasement. The details of its construction are given on page 93. Care must be taken to maintain full length of the leg and to avoid angular or rotatory

FIG. 232.



Bivalve or stocking splint.

FIG. 233.



Posterior gypsum splint or gutter.

displacement during the hardening of the plaster. Two angular displacements are specially liable to occur: a lateral one, apex inward, by erroneous correction of the apparent normal curvature in the opposite direction; and an antero-posterior one, by dropping or elevation of the heel respectively. The plaster stocking can be applied while the injury is recent, and loosened or tightened as the need arises, and it permits easy inspection to detect and correct such displacements as may occur beneath it. It also permits massage and the application and change of such dressings as may be needed for associated wounds of the skin or for blisters.

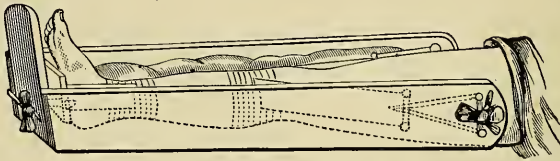
It may become so loose after a week or two that it does not properly support the fragments, and should then be renewed. It should be worn until mobility can no longer be recognized, usually five to seven weeks, and the patient can go about on crutches during most of that

time. If union is delayed beyond that time it is well to let the patient bear part of his weight upon the foot in walking, angular displacement thereby being prevented by a strong plaster encasement.

Instead of a Volkmann splint during the first week side splints of wood or wire or a posterior plaster moulded splint (Fig. 233) or posterior and lateral splints (Figs. 245 and 246) may be used, and they may also, especially the moulded ones, be serviceable during the later stages if wounds of the anterior soft parts require dressing.

A number of devices for maintaining continuous traction have been suggested, but their inherent defects are such that they have never come into general use. Figs. 234 and 235 show two such.

FIG. 234.

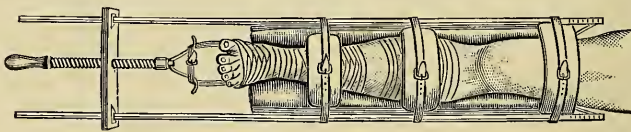


Dr. Neill's dressing for continuous traction.

Direct pressure by a metal pin or a pad controlled by a screw was occasionally used when the projecting end of the upper fragment could not otherwise be controlled and especially if it threatened to perforate the skin. It is now generally deemed better to expose the fracture by incision and remove the cause.

In compound fractures the bivalve or fenestrated or interrupted splint may be used, or anterior and posterior moulded splints one of which holds the fragments in place while the other is removed that the dress-

FIG. 235.



Continuous traction in fracture of the leg.

ing may be changed. The details of treatment of the wound are here of special importance, and particularly the distinction to be made between fractures that are compound by direct violence and those by indirect violence. For these and for *ambulatory treatment* the reader is referred to Chapter VII.

Suspension may be employed with any of these splints and often promotes comfort notably.

3. FRACTURES AT THE LOWER END OF THE LEG.

In this group I place the rare fractures of both bones in which the lower end of the tibia is crushed or splintered, separation of the lower epiphysis of the tibia and the allied supramalleolar fracture, the numer-

ous and varied fractures of one or both bones at or near the joint caused by forcible inversion or eversion of the foot, sometimes aided by the weight of the body, of which the most common is known as Pott's fracture, and the much rarer fractures of the anterior and posterior articular portions of the tibia. The feature which almost all have in common is the action of the causative violence through the foot.

A. Comminuted Fracture of the Lower End of the Tibia with Fracture of the Fibula.

The fractures which constitute this group are too rare and varied to permit a systematic description. The tibia is broken either by direct violence acting upon its side to crush it, or, more frequently apparently, by a fall from a height in which the bone is broken by a transverse strain and then its lower portion split by the penetration into it of the other. Thus, in a case reported by Chassaignac the tibia was broken four finger-breadths above the joint and the lower fragment split into four pieces; the fibula was broken at two places in its lower third. A specimen in the museum at Val de Grâce is shown in Fig. 236; the lower end of the tibia was broken into six fragments.

Diagnosis. The diagnosis must be made by recognition of the abnormal mobility and the mobility of the fragments; probably the aid of anaesthesia would always be necessary to appreciation of the details.

Treatment. The treatment must aim to effect and maintain as complete reduction as possible, acting upon the fragments by traction through the foot and by direct pressure. The implication of the joint and the frequent derangement of the articular surface by fragmentation make loss of function in the ankle-joint inevitable, and therefore the foot must be maintained at right angles to the leg and without eversion or inversion of the sole in order that its usefulness may not be further diminished by a fixed faulty position. If the injury is compound by direct violence amputation may be expected to give a better functional result than conservative treatment in most cases.

B. Supramalleolar Fracture.

This term was created by Malgaigne and applied to fractures which for the most part were low or partial forms of the preceding class, the line of fracture always running into the joint and usually comminuting the end of the bone, but there are cases in which the tibia is broken across within an inch or two of its lower surface and with fracture of the fibula at or above the same level. I have seen one in which the tibia was broken squarely across, one inch above its lower end, the fibula was broken at the junction of the upper and middle thirds, and the tip of the external

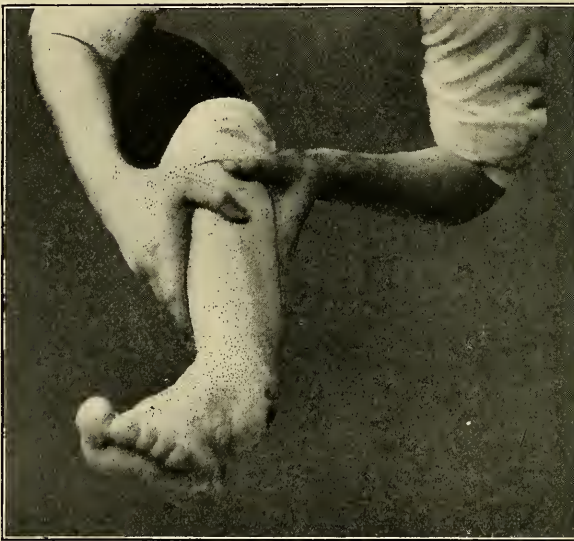
FIG. 236.



Comminuted fracture of the lower portion of the leg.

malleolus was broken off. Tillaux¹ was able to produce this form experimentally by inversion of the foot, and says the fracture then takes place first in the fibula, and only in the tibia if the force continues to act; he reports one case in which dislocation of the upper end of the fibula took the place of fracture of that bone, the line of fracture of the tibia lying three finger-breadths above its lower surface. In the few cases I have seen the mechanism could not be learned, but I see no reason to doubt that it can be effected also by eversion of the foot; in the case above quoted the lower fragment could be easily displaced outward, but not inward.

FIG. 237.



Supramalleolar fracture.

Diagnosis. The diagnosis is made by pain on pressure along the line of fracture and on pressing the foot up against the leg, and possibly by recognition of abnormal mobility and crepitus.

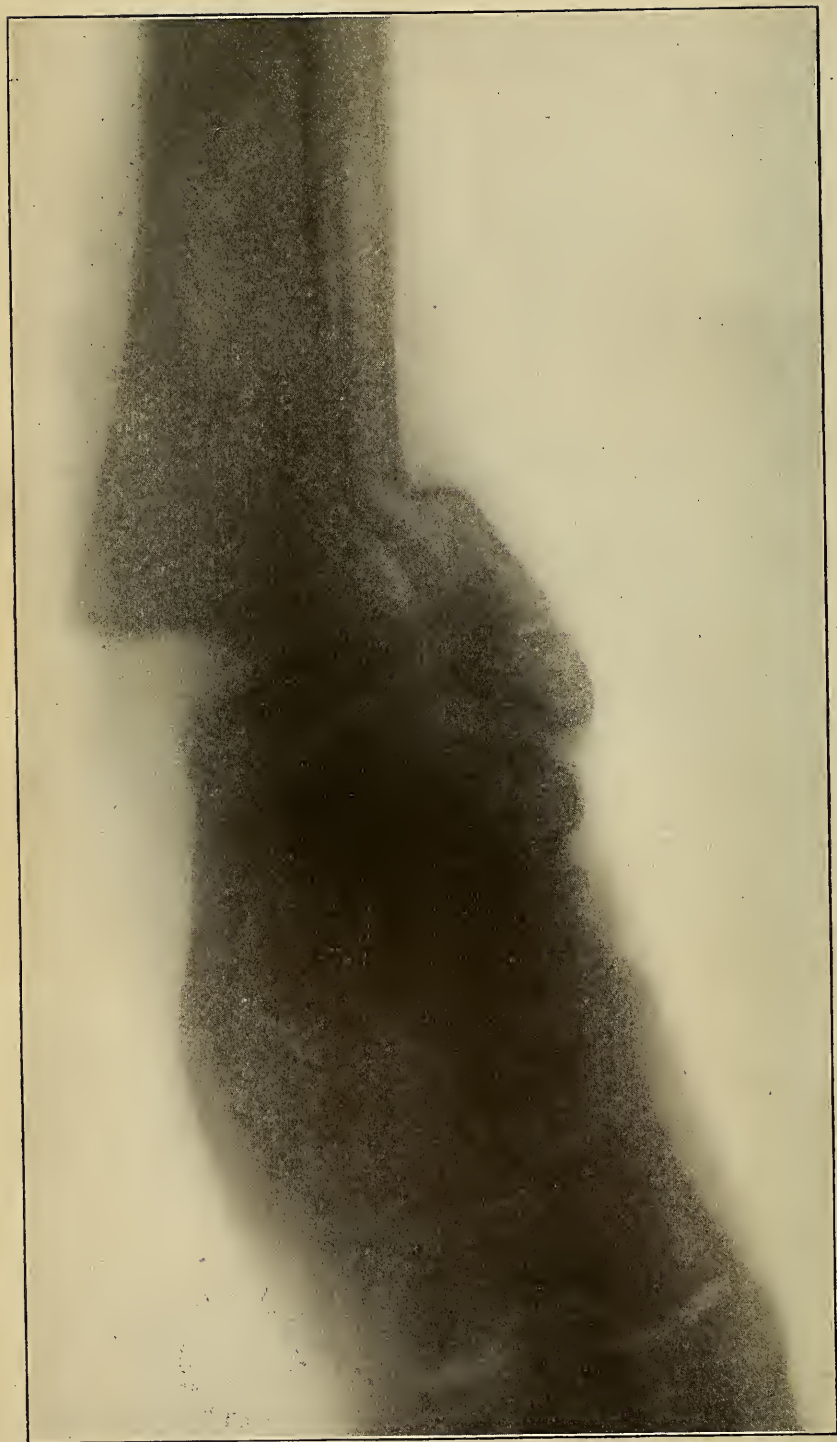Treatment. The treatment is immobilization, preferably in a fixed dressing, using the foot to control the position of the lower fragment.

C. Separation of the Epiphysis of the Tibia.

This is more frequent than that of the upper epiphysis, 11 to 4 in Bruns's 100 cases of all kinds. The cause appears to be a cross-strain in eversion and perhaps in inversion of the foot, sometimes the result of great violence, as in a fall from a height, sometimes a simple twisting of the foot in a misstep. Experiments indicate that it may be produced by forcible dorsal flexion of the foot combined with pressure against the sole.

¹ Tillaux: Anatomie topographique, p. 1174.

PLATE XXXIII.



Separation of Lower Tibial Epiphysis

In some cases, as in Fig. 238, the outer portion of the shaft is broken off, evidently during eversion; and in some the injury is compound with marked protrusion of the shaft through the wound on the inner side. The fibula is almost always broken at a higher point, and although the upper limit of its own epiphysis is situated well below that of the tibia its separation occasionally takes the place of fracture of the shaft.

Hutchinson collected eight reported cases of arrest of growth after the injury, with overgrowth of the fibula and inversion of the foot.

The principle of treatment is the same as in supramalleolar fracture.

D. Fractures by Eversion and Abduction of the Foot. Pott's Fracture.

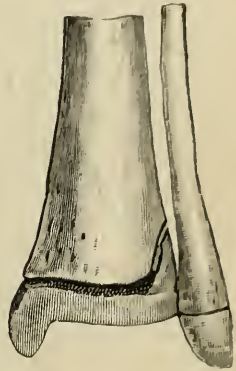
Beside being a very common injury this gains special importance from the frequency with which the cardinal principles of its treatment are overlooked and the occasional great disability which results. The lesions vary much in extent and detail; indeed, occasionally fracture is wholly absent and some of the forms have been classed with dislocations. But these differences are due either to alternative lesions or to the early cessation of the force before the typical form has been reached, and the mode of production in its two forms is constant, so that all the variations are parts of a single nosological entity. The differences make a name anatomically descriptive of the group almost impossible; the one above given, based on the mode of production, is useful to distinguish the group from the following one which has certain points of resemblance, and correctly includes all the forms, but it is not suitable for current use; the alternative title, Pott's fracture, has not only the advantage of convenience but also that of long association with the injury. It deserves, I think, to be retained as the principal name.

Cause and Pathology. The cause is a twist of the foot—eversion and abduction—aided somewhat by the weight of the body. According as the eversion or the abduction predominates the lesions take one or the other of two easily distinguishable forms, as follows:

If eversion is the sole, or main, movement the force is exerted through the internal lateral ligament and breaks the internal malleolus squarely off at its base; then it presses the external malleolus outward, rupturing the tibio-fibular ligament, and breaks the fibula close above the malleolus. Sometimes, instead of pure rupture of the tibio-fibular ligament, there is avulsion of the portion of the tibia to which it is attached, in front or behind or both, but I believe this to be rare. These lesions can be easily produced experimentally by fixing the foot in a vise and pressing the upper part of the leg outward.

If, on the other hand, abduction of the front of the foot is the

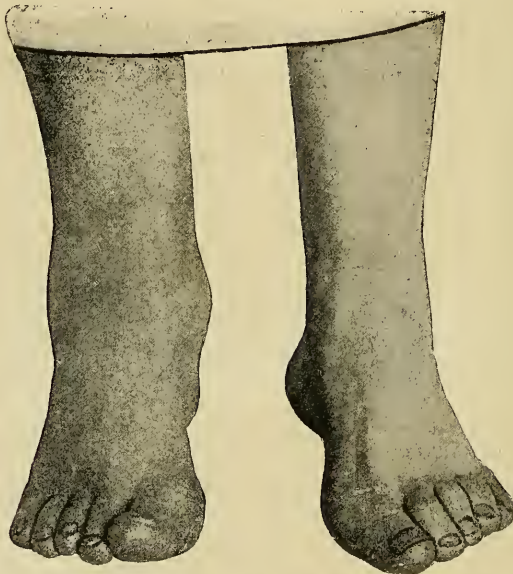FIG. 238.



Separation of the lower epiphysis of the tibia. (BRUNS.)

principal movement the first and last of these three lesions vary: instead of a square break of the internal malleolus at its base, there is an oblique, almost marginal, fracture of its anterior portion, or, more commonly, there is rupture of the anterior portion of the internal lateral ligament; then follows rupture of the tibio-fibular ligament, and, as the movement continues, the torsion of the fibula produces an oblique fracture the upper end of which is found three or four inches above the tip of the malleolus. If the movement is arrested in time fracture of the fibula may not occur. Experimentally this can be easily produced and the sequence of events accurately observed. Clinically it cannot be demonstrated so easily, for the patient can rarely give a

FIG. 239.



Pott's fracture, right side; showing outward displacement and absence of eversion.

detailed account of the manner in which the injury was received, but in one of my cases the mechanism was evident: while the patient was kneeling on one knee, the foot resting on the hyper-extended toes, he was pressed backward so that his buttocks rested on and forced the ankle inward, causing abduction of the front of the foot. The essential lesion is the tibio-fibular diastasis, the rupture of those ligaments, and the consequent widening of the mortise within which the astragalus is held.

Exceptionally the displacement of the foot and fibula may be extreme, even without fracture of the fibula. (See Outward Dislocation of the Foot.) And, also exceptionally, unusual lines of fracture of the tibia may be found, such as a long one running up from the articular surface and separating a fragment consisting of the outer portion of the bone, or a breaking off of the posterior portion of the articular

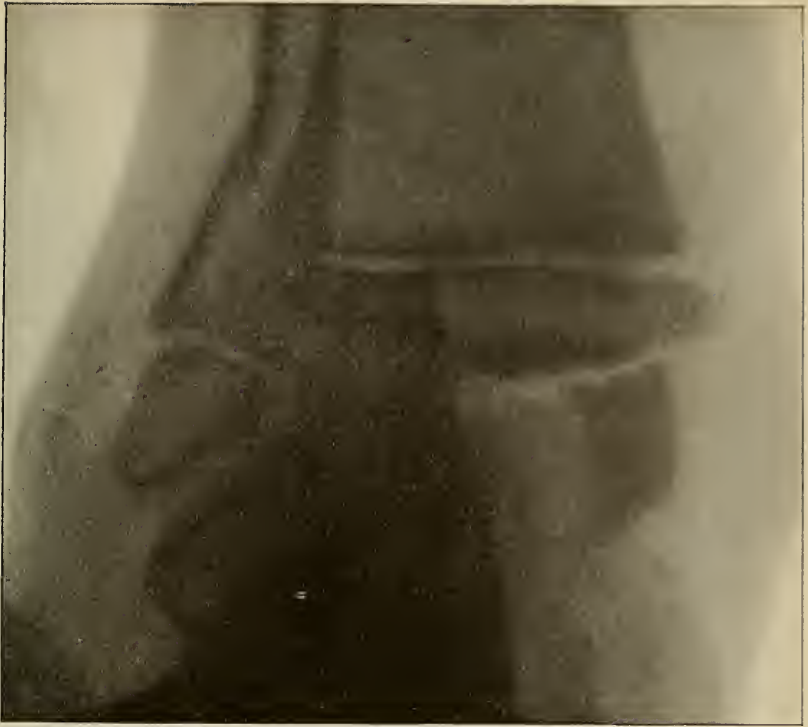

Fig. 1.—Pott's Fracture by Eversion in a Youth; showing also epiphyseal line; internal malleolus broken at its base.

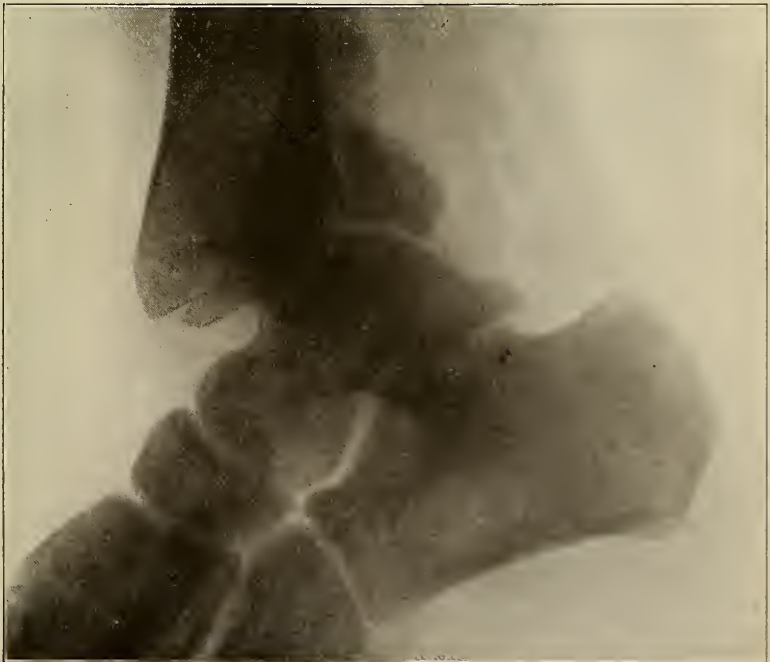

Fig. 2.—Fracture of the Posterior Portion of the Lower End of the Tibia, with Fracture of Fibula and Internal Malleolus.





Fig. 1.—Pott's Fracture by Abduction; male, forty years;
internal malleolus unbroken.

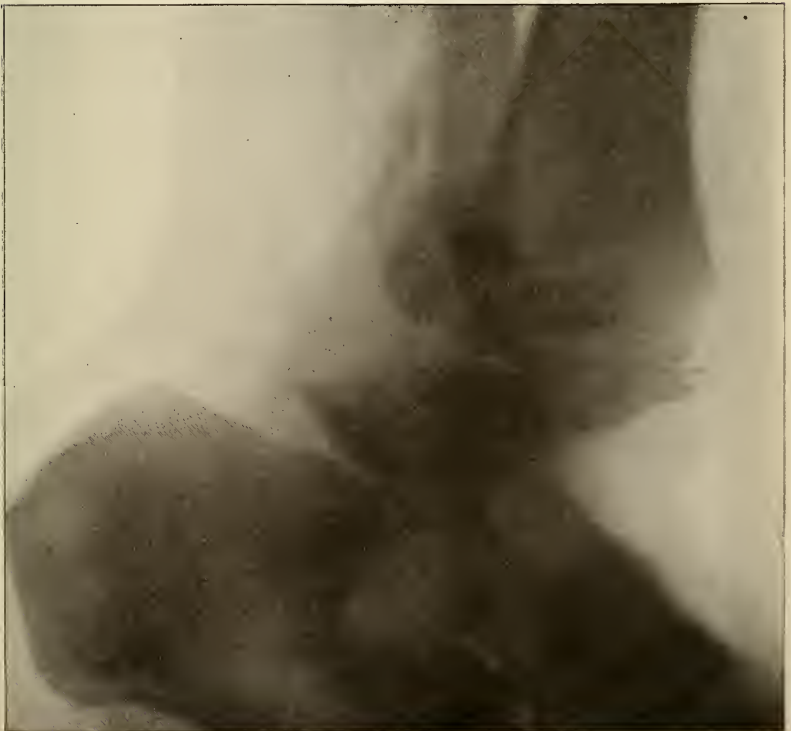
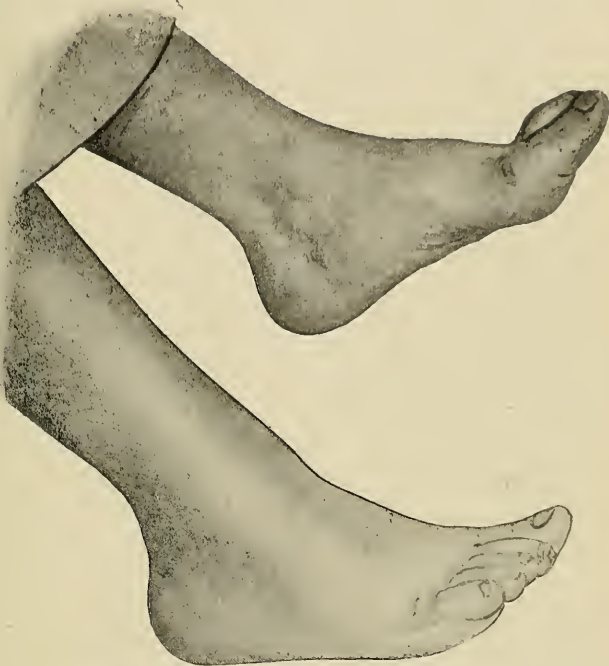
Fig 2 —Pott's Fracture two months old; Backward Displacement.
See also Plate XXXVI., Fig. 1.

surface (see section F); in both of these the weight of the body must be an important causative factor.

Two complications which may appear in the first variety were, so far as I know, first observed and reported by me;¹ I have seen two

FIG. 240.



The same; showing backward displacement.

cases of each. One is the rotation of the internal malleolus about an antero-posterior axis so that its fractured surface lies parallel to and just beneath the skin, the fragment being exceptionally prominent and movable. The other is the interposition between the malleolus and the tibia of a large strip of periosteum torn from the tibia; in this condition also the malleolus is exceptionally prominent and movable. In all my four cases the fracture was exposed and readjustment made through an incision; recovery followed with full restoration of function.

Another, not very uncommon, complication of the first variety is laceration of the skin on the inner side by the end of the tibia, which may project through the wound; this is due to the prolongation of the action after fracture, by which the foot is forced outward and everted and the skin torn across the broken edge of the tibia. The displacement is of the foot (astragalus) and outer malleolus outward and backward. This displacement is usually slight, a quarter of an inch, but

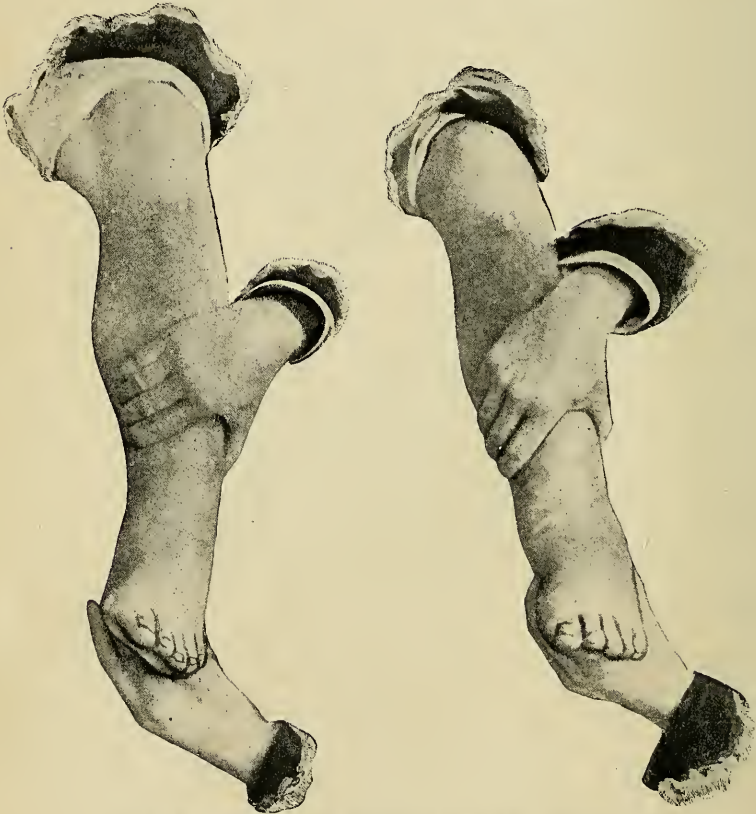¹ Stimson: Transactions of the New York Surgical Society, in *New York Medical Journal*, January 26, 1889, p. 108, and Pott's Fracture, *New York Medical Journal*, June 25, 1892.

it may be much more, and the backward displacement is sometimes so great that the body of the astragalus lies almost wholly behind the tibia.

Symptoms. The appearance of the region is usually so characteristic that the diagnosis can be made at a glance, the characteristic feature being the outward displacement of the foot and the corresponding prominence of the internal malleolus or the adjoining portion of the tibia

FIG. 241.

FIG. 242.



Pott's fracture; method of recognizing abnormal lateral mobility.

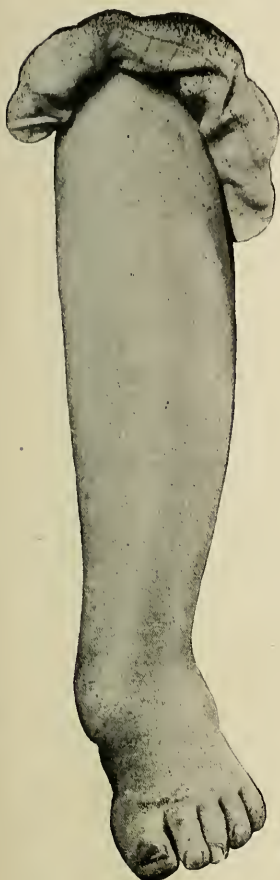
(Fig. 239); in the marked cases the backward displacement is also plainly to be seen (Fig. 240). The former is most apparent when the muscles are relaxed, as by anæsthesia, or when swelling is absent.

The pathognomonic signs are the points of tenderness mentioned below and abnormal lateral mobility at the ankle, which can be shown by grasping the foot with one hand so that the posterior portion of the sole rests in the palm, with the thumb close below the external malleolus, and the index-finger below the internal malleolus, and moving it bodily inward and outward while the other hand grasps the leg above the ankle and steadies it (Figs. 241 and 242). This manipulation

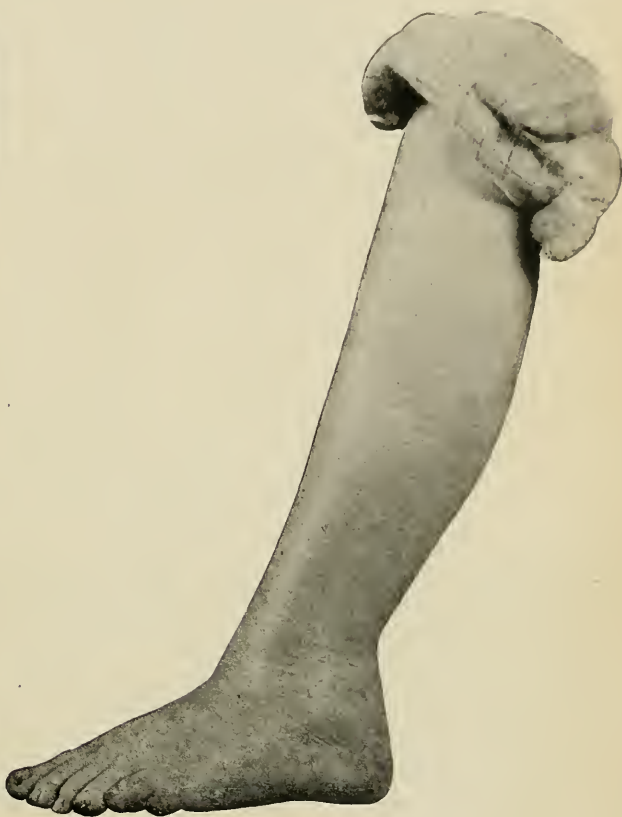sometimes produces a distinct click by the impact of the astragalus against the internal malleolus or of the external malleolus against the tibia.

FIG. 243.

FIG. 244.



Old Pott's fracture; outward displacement.



The same; backward displacement.

In like manner abnormal mobility backward and forward can sometimes be shown by clasping the back of the heel with the fingers of both hands, placing the thumbs on the front of the lower part of the tibia, and then alternately lifting the foot and allowing it to drop back, the patient being recumbent.

Three points of tenderness on pressure are constant and characteristic: one in front at the position of the tibio-fibular ligament, that is, in the groove between the tibia and the external malleolus, showing the rupture of this ligament; one at the base of the internal malleolus or near its anterior border or just in front of it, marking the fracture of the malleolus or the rupture of the anterior portion of the lateral

ligament; the third over the outer aspect of the fibula, close above the malleolus in the first variety, an inch or so higher in the second, marking the fracture of the fibula. Abnormal mobility of the two fragments may sometimes be recognizable.

Marked ecchymosis appears beneath the external malleolus and usually also beneath the internal.

Pressure upward against the heel is not painful, and the patient can sometimes walk if he steps carefully and without much movement in the ankle-joint.

Prognosis. If reduction is made and maintained the prognosis is good, the patient almost always regaining full use of the joint, but if either backward or outward displacement persists (Figs. 243 and 244) the disability is likely to be marked. Backward displacement limits dorsal flexion at the ankle, and the patient is, therefore, obliged to turn the toes well outward in walking; outward displacement brings the weight of the body too far to the inner side of the foot and thus produces a strain upon the internal lateral ligament which promptly causes fatigue and pain.

Treatment. Reduction, to facilitate which anæsthesia is sometimes advisable, is made by pressing the calcaneum forward and inward; the hand is placed against the back and outer side of the heel and pressed forward and then forcibly inward. It is best maintained by a posterior and a lateral plaster splint, such as those shown in Figs. 245 and 246. They are preferable to complete encasement in plaster because they permit inspection of the inner side of the ankle and the immediate

FIG. 245.




Pott's fracture; posterior plaster splint.

detection of recurrence, and to wooden splints (Fig. 247) because they are more secure. They can be conveniently made of a four-inch plaster roller by soaking it and running it back and forth on a table until twelve or fifteen layers of suitable length have been put together. The posterior splint should extend from the toes, along the sole, and up the calf nearly to the knee. The lateral one should begin just in front of the external malleolus, pass over the dorsum of the foot to the inner

side, under the sole, and up along the outer side of the leg to the same height. They are snugly moulded and bound to the limb while still wet with a roller-bandage which may be removed after the plaster has set, its place being taken by a few turns of a bandage just above

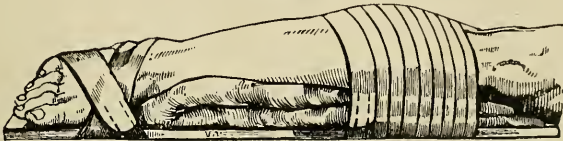
FIG. 246.



Pott's fracture; lateral plaster splint.

the ankle and at the upper end of the splint. While the plaster is setting reduction must be maintained by an assistant or by resting the

FIG. 247.



Dupuytren's splint.

heel on a sand-bag with the limb in outward rotation so that the foot will be pressed forward and inward. I have sometimes placed the lateral splint on the inner side.

Such a splint may be conveniently and safely applied immediately after the accident, for if strangulation should threaten the circular bandages can be loosened sufficiently to relieve the constriction without disturbing the position of the foot. If applied while the limb is swollen the shrinking can be met by tightening the circular bands, but it is better to apply a new one after a few days.

In *compound* fracture with a small wound infection can generally be avoided by the usual measures, and a good result obtained. If the wound is or should become infected drainage must be made on both sides, and the foot kept square upon the leg that its usefulness may be as great as possible after the probable result of ankylosis.

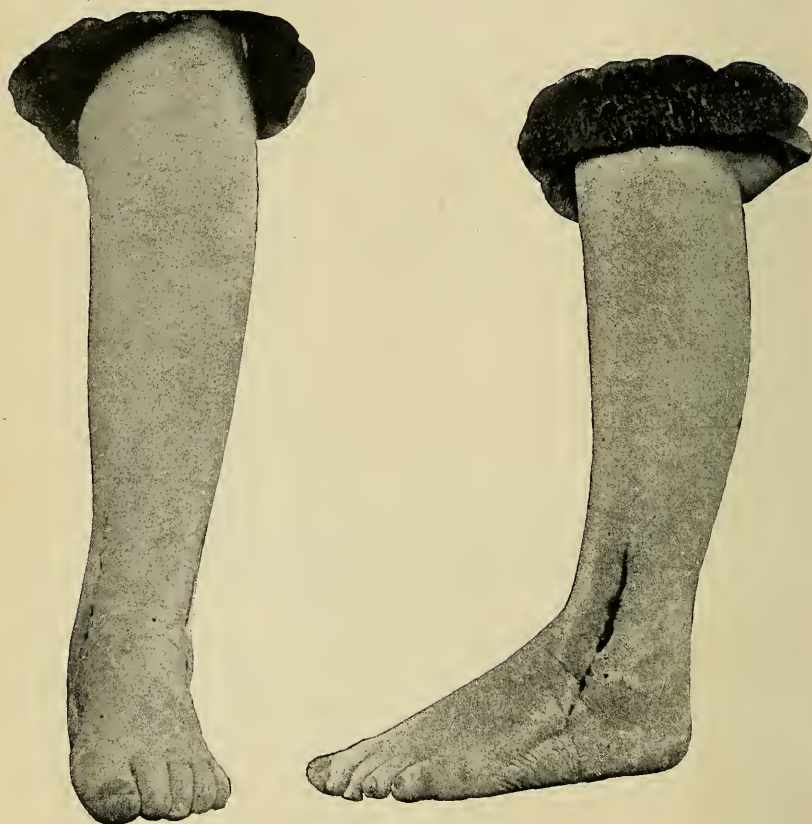In the rare cases of *rotation of the internal malleolus* or *interposition of a strip of periosteum* the condition should be corrected through an open incision.

In *old fractures with unreduced displacement* relief can be had only by operation. Supramalleolar osteotomy enables the foot to be brought back into line with the leg, but does not correct the backward displacement which almost always coexists. I have never employed it, but have always resorted to a formal attempt to bring the astragalus and

external malleolus back to their places, using two lateral incisions, as follows (Figs. 248, 249) :

FIG. 248.

FIG. 249.



Pott's fracture; same case as in Figs. 243 and 244; showing result of operation.

One incision begins at the front of the fibula three inches above the ankle, is carried downward, passing in front of the malleolus, and then curved forward on the side of the foot; the fracture is exposed and the lower fragment again detached. The second incision begins on the inner side of the tibia at the same level as the first and passes down to the front of the malleolus and thence forward to or beyond the tubercle of the scaphoid. Through it the internal malleolus, if it was broken off in the original injury, is again detached from the tibia with a chisel, and the end of the tibia protruded so that it is easy to liberate the astragalus and cut away any new growth of bone that may have formed on the back of the tibia. The foot is then easily restored to place, the incisions closed, and a bulky dressing applied and covered with plaster of Paris. In the nine or ten cases in which I have done this the restoration of form has been complete, and that of function always

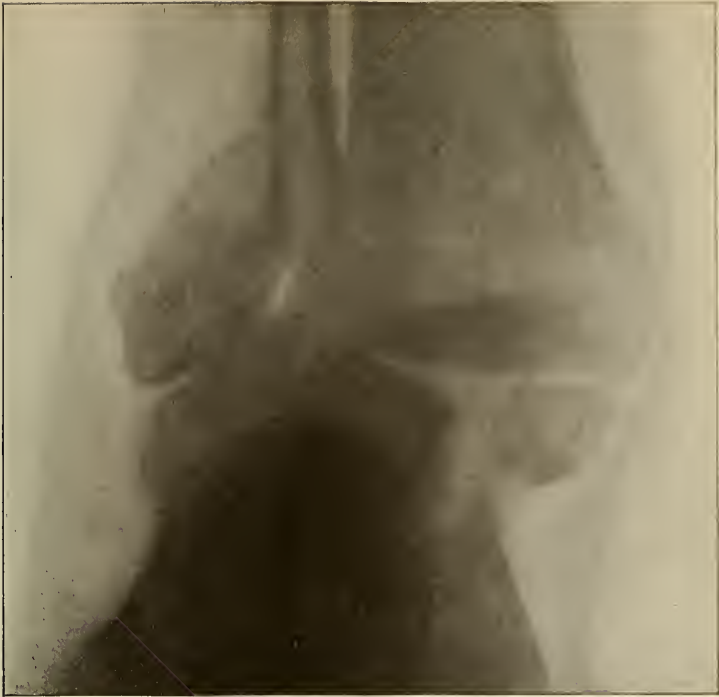

Fig 1.—Pott's Fracture by Abduction ; same as Plate XXXV , Fig. 2.

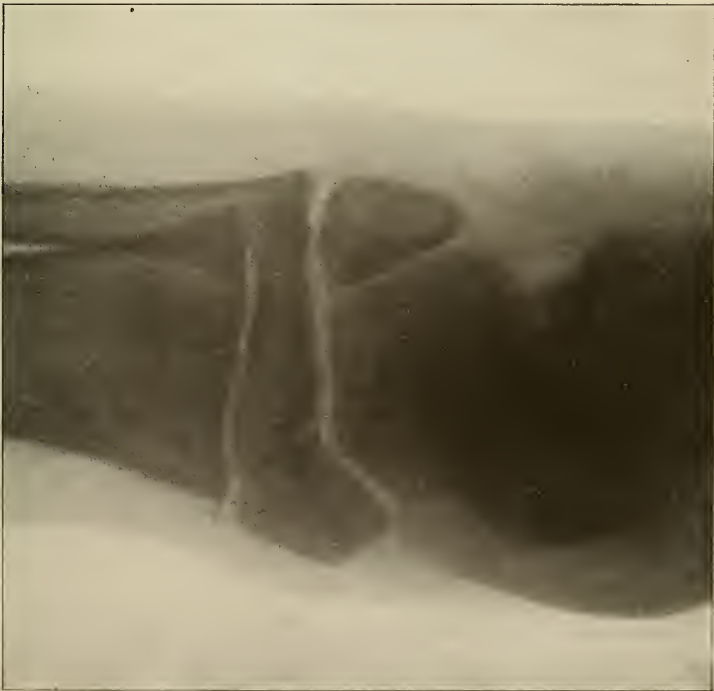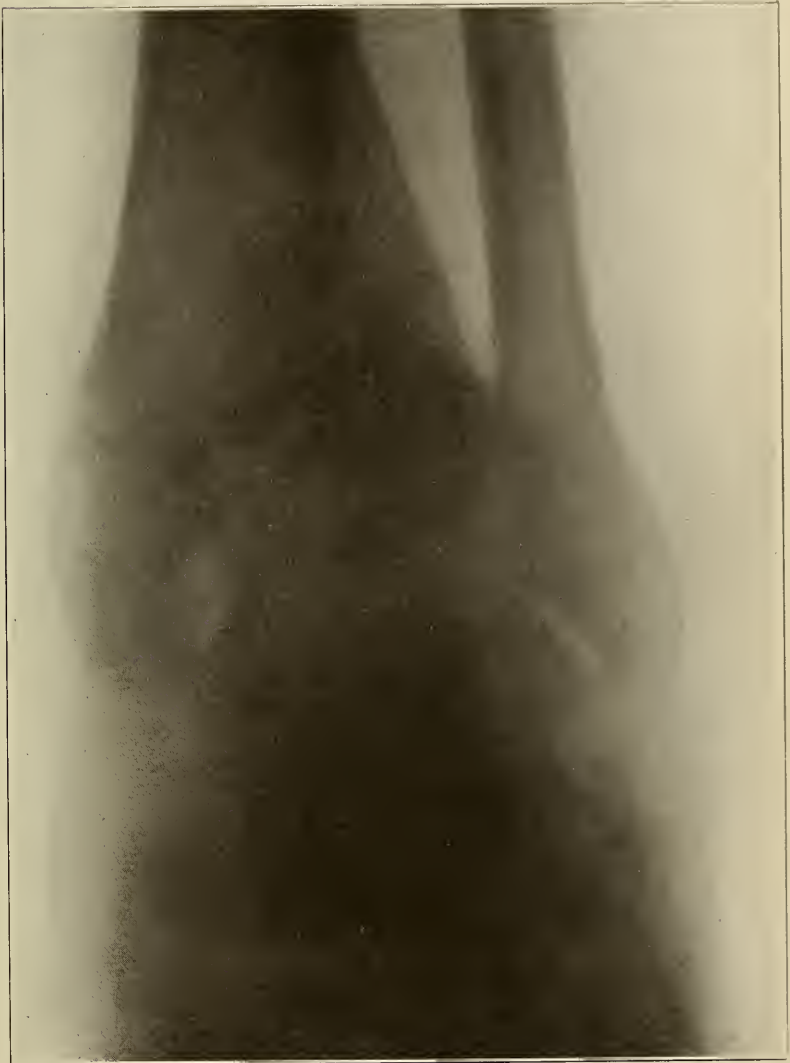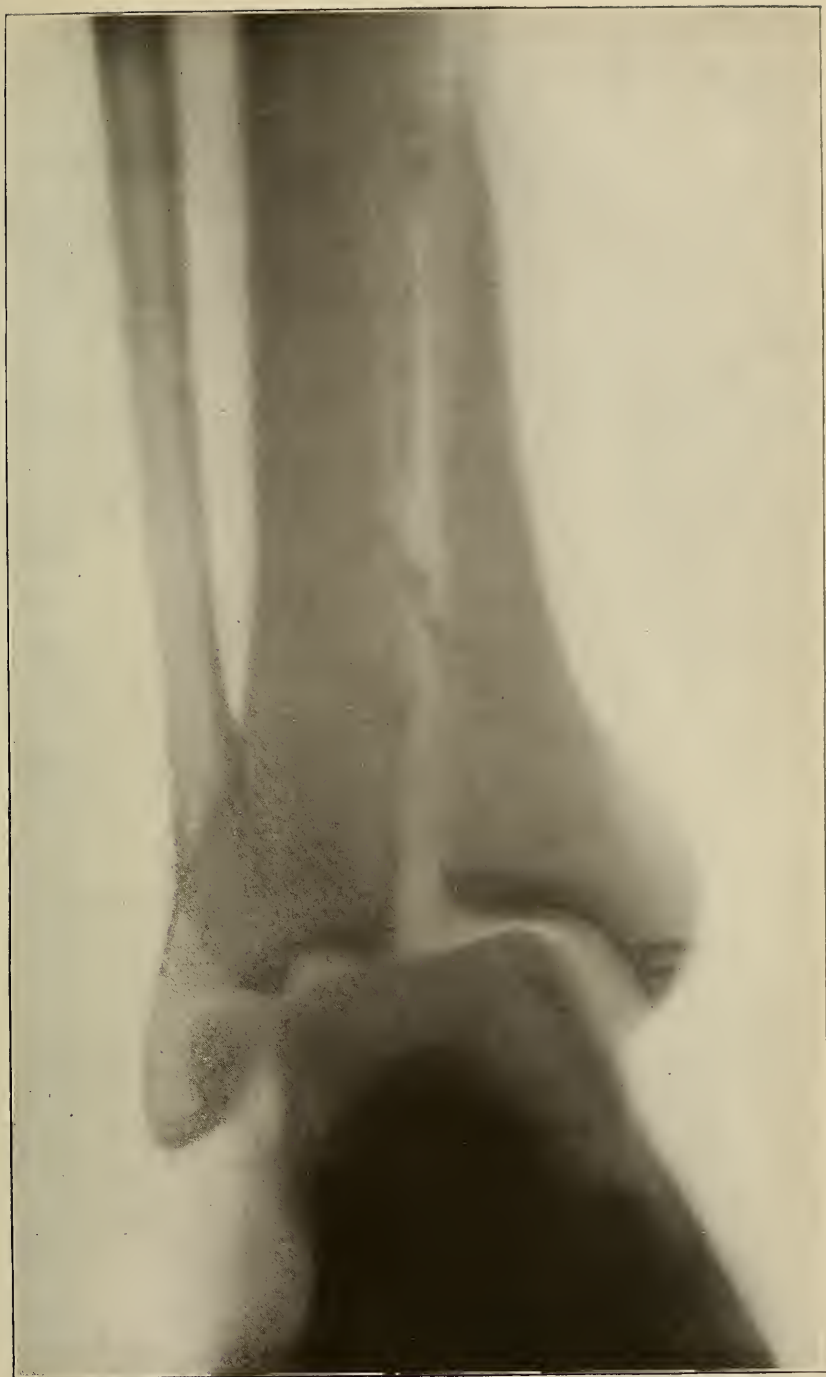


Fig. 2.—Bimalleolar Fracture by Inversion ; boy fourteen years. External malleolus separated at epiphyseal line ; fracture of internal malleolus does not show, but was recognized clinically.

PLATE XXXVII.



Fracture by Eversion, with Interposition of the Astragalus.



Longitudinal Fracture of Lower End of the Tibia by a Fall upon
and Inversion of the Foot.

PLATE XXXIX.

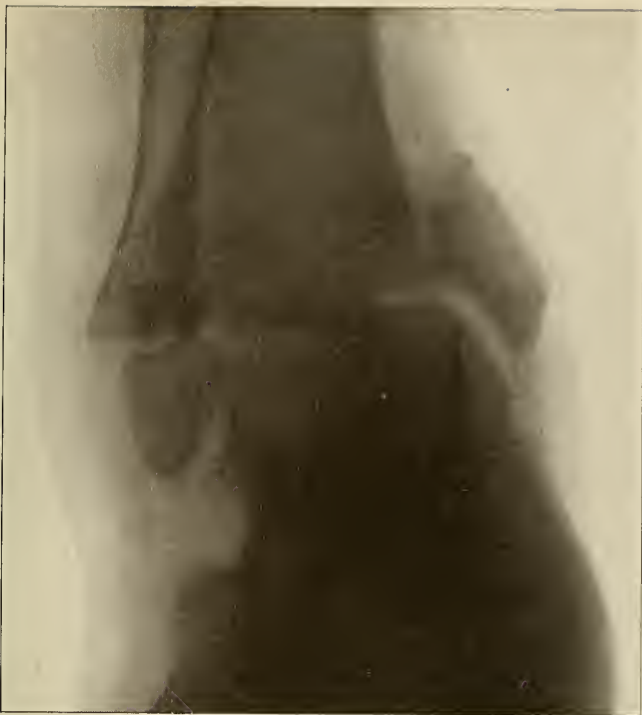

Fig. 1.—Bimalleolar Fracture by Inversion in a Youth. Line of fracture passing above the base of the internal malleolus; external malleolus separated at epiphyseal line.



Fig. 2.—Fracture of Femur Remaining Ununited a Year after Wiring. Note detachment of the wire.

an improvement upon the previous condition and sometimes a very marked one.

E. Fractures of the Malleoli by Inversion of the Foot.

This injury, which also is a common one, presents several varieties differing notably in the extent of the lesions, the immediate disability, and the prognosis. The fibula may be alone broken at or close above the base of the malleolus or at the epiphyseal line in the young, or with its fracture may be associated that of the tip of the internal malleolus or one passing obliquely upward and inward through the tibia and separating a fragment composed of the internal malleolus and a considerable portion of the adjoining bone (Plates XXXVI., XXXIX.). The variations appear to be due to differences in the amount or force of the inversion and to the extent to which the weight of the body acts as a factor. Thus, the first effect of inversion is to break the fibula, either by the pressure of the upper edge of the astragalus against it or by the pull of the external lateral ligament; if the movement is continued, or possibly if its direction is somewhat different, the astragalus presses against and breaks off the tip of the internal malleolus; but if the weight of the body is added, as in a fall upon the inverted foot, the astragalus presses upward and inward against the inner portion of the tibia and breaks off the larger fragment.

The first form of the injury, fracture of the external malleolus or fibula alone, is of slight importance if the tibio-fibular ligament is not also torn, producing no displacement of the astragalus and getting well under a simple protective dressing. The same is nearly equally true of the second form, added fracture of the tip of the internal malleolus, but more time is required before the limb can be freely used. The third form is much more serious and usually results in considerable restriction of motion at the joint.

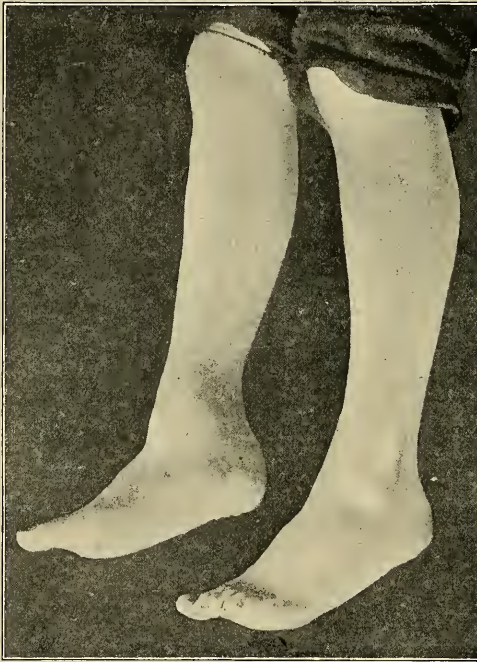Diagnosis. The diagnosis is made in the first two varieties by recognition of tenderness on pressure at the lines of fracture and of independent mobility of the external malleolus by pressing its tip inward while another finger is placed at the seat of fracture to feel the tilting of the upper end of the fragment. In the third variety the line of fracture of the tibia can be recognized by tenderness on pressure and by the irregularity produced by the displacement upward and inward of the fragment.

Treatment. For the first two varieties it is sufficient to immobilize the part by plaster of Paris, taking care to keep the foot well pressed inward while the plaster is setting in order that the malleolar mortise shall not be widened. In the third variety the effort must be made to correct the displacement of the tibial fragment by pressing it downward and outward, and to immobilize with the foot well forward, guarding against backward displacement, and the external malleolus pressed snugly against the tibia, guarding against outward displacement.

F. Fracture of the Posterior Portion of the Articular Surface of the Tibia.¹

This may be a complication of Pott's fracture, the fragment being rather small, or the crush may be so extensive that the symptoms and treatment are very different. In the slighter form the breaking of the tibia is apparently produced by the weight of the body pressing the posterior and outer part of the articular surface against the displaced astragalus, and yet I have known it to be caused by the comparatively

FIG. 250.



Fracture and displacement of the posterior portion of the lower articular surface of the tibia and of the fibula and internal malleolus. (See also Plate XXXIV., fig. 2.)

slight violence of a fall from an almost stationary bicycle. I have never seen it in a fresh injury and do not know whether it could be recognized; the signs of Pott's fracture would be recognizable, of course, and possibly the additional fracture might be shown by displacement of the foot (astragalus) slightly upward as well as backward and outward.

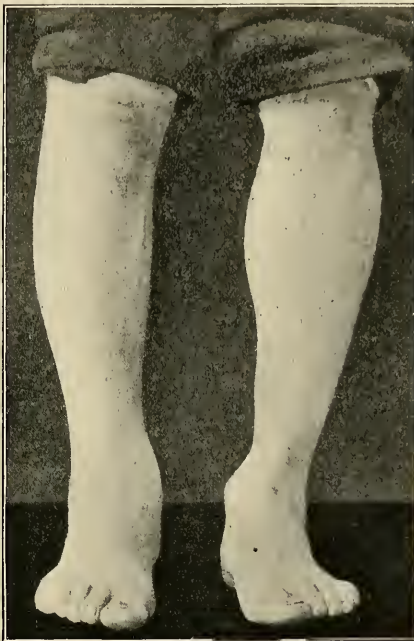The treatment is that of Pott's fracture with special care to bring the foot well forward.

The more severe form is rare and apparently the result of a fall from a height upon the foot. I have one old specimen of extensive crushing

¹ See also Backward Dislocation of the Foot.

with fracture of the external malleolus and its displacement backward, but repair has obliterated most of the details. I have seen another in the collection of Dr. Daudridge, of Cincinnati, in which the posterior half of the tibial plateau is broken off and has united with the back of the tibia after displacement of more than half an inch upward. The fibular fragment is rather short and is displaced angularly, the astragalus having slipped outward between it and the tibia; the internal malleolus is broken off at its base and has accompanied the astragalus. In two old cases treated by operation (Figs. 250 and 251) I have found similar lesions and displacements.

FIG. 251.



Same case as Figure 250.

Probably under an anæsthetic the general condition, if not the details, could be recognized by palpation. The treatment would be to make such reduction as was possible and to immobilize in plaster splints.

In two old cases I have removed the posterior fragment of the tibia, corrected the displacement, and obtained a useful limb with obliteration of the ankle-joint. In a third I removed the remaining articular surface of the tibia and flattened the top of the astragalus so that the two became firmly united; the functional result was excellent.

G. Fracture of the Anterior Portion of the Articular Surface of the Tibia.

Only one or two cases of this variety have been reported. It is evidently produced by the pressure of the astragalus against the anterior

lip of the tibia. Displacement could probably be corrected by traction through the anterior portion of the capsule in forced depression of the front of the foot aided by direct pressure upon the fragment.

4. FRACTURES OF THE FIBULA.

A. Fracture of the Upper End.¹

This may be caused by direct violence, by muscular action (contraction of the biceps), or more commonly by forcible adduction of the leg acting through the external lateral ligament attached to the head of the fibula. In two of the reported cases (Stimson, Weir) the lesion was a separation of the epiphysis. In a number of the cases paralysis of the extensor and peroneal muscles and loss of sensation in the region supplied by the musculo-cutaneous branch of the peroneal nerve were noticed shortly after the accident, and in some persisted until the patients passed from observation. Weir and Marchant exposed the nerve in their cases and found it unbroken but apparently compressed by the edge of the fragment; the patients recovered almost completely from the paralysis.

The upper fragment has been widely displaced upward in most of the cases, and it has usually been impossible to bring it fully back to its place, but it does not appear that any disability has resulted therefrom.

Treatment. The treatment consists in approximation of the fragments by bandaging aided by flexion of the knee to relax the biceps and plaster of Paris to prevent adduction of the leg. If peroneal paralysis exists it would probably be well to expose the nerve for some little distance above and below the fracture in order to reunite it if it is torn or to relieve pressure upon it.

B. Fractures of the Shaft.

These fractures are produced by direct violence. The displacement is slight because of the support given by the tibia, and the diagnosis is made upon the localized pain and possibly crepitus and recognizable mobility or irregularity of outline. Occasionally symptoms indicative of injury to the cutaneous branch of the peroneal nerve are present, presumably by the violence which caused the fracture.

Treatment. The only treatment needed is protection against external violence and movement of the lower fragment by twisting the foot; this is conveniently given by a plaster or silicate dressing extending from the toes to the knee. It should be worn for about three weeks, and care should be taken for a fortnight longer to avoid muscular strain and lateral pressure by the foot at the ankle.

¹ For reported cases, which are not numerous, see the first edition of this work and Gurlt's *Knochenbrüchen*, vol. i. p. 243; Duplay, *Bull. de la Soc. de Chirurgie*, 1880, p. 218; Terrier, *Idem*, p. 222; Leggatt, *Lancet*, March 31, 1888; Hirschberg, *Arch. für klin. Chir.*, vol. xxxvii. p. 199; Weir, *New York Medical Journal*, May 26, 1888; Marchant, *La France Méd.*, February 21, 1889; and Chapin, *New York Medical Journal*, September, 1891, p. 12.

PLATE XL



Fig. 1.—Long Oblique Fracture of Tibia and External Malleolus.

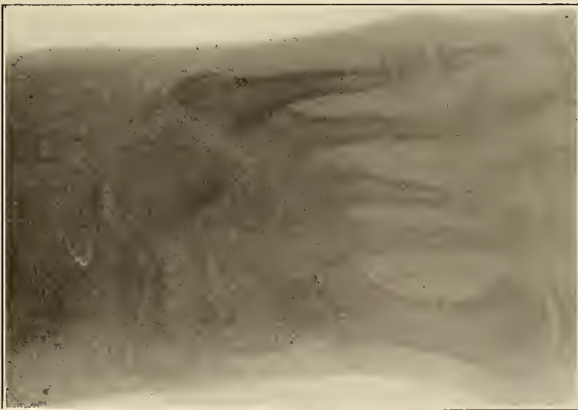


Fig. 2.—Fracture of the Cuboid.

C. Separation of the Lower Epiphysis.

Poland¹ has collected four cases of this injury uncomplicated by fracture of the tibia. In three the injury was compound. One patient (Allis) died of tetanus, in one (Wright) the lower fragment became necrosed, and in the third (Poland) gangrene occurred on the third day after the application of a plaster dressing. In two other cases (specimens in the Middlesex and London Hospitals) there were extensive associated injuries amounting to dislocation of the ankle and requiring amputation. (See also Plate XXXVI., fig. 2.)

¹ Poland : *Loc. cit.*, p. 860.

CHAPTER XXVI.

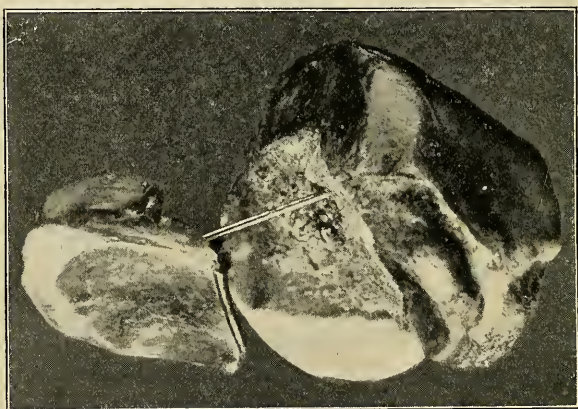
FRACTURES OF THE BONES OF THE FOOT.

1. FRACTURES OF THE ASTRAGALUS.

THESE are commonly the result of falls from a height, the bone being broken between the calcaneum and the tibia, and the lesion being frequently associated with fracture of the calcaneum and with dislocation at the ankle and fracture of the fibula; in other cases the force acts transversely.

The direction and extent of the line of fracture vary greatly; the bone may be divided transversely, or longitudinally, or horizontally, or obliquely, or into several pieces, and the fragments may be widely separated and dislocated.

FIG. 252.



Fracture of the astragalus through the lower articular surface.

When there is no displacement or external wound the diagnosis may be very difficult, because the symptoms are not distinctive and indicate only severe injury to the foot, pain, swelling, inability to bear the weight of the body on it, and perhaps crepitus on handling or flexing and extending it. The diagnosis must be made by exclusion of other injuries, by localized pain, and possibly by recognition of a displaced fragment, or of independent mobility of the head of the bone. I have once found it by the *x*-rays, in combination with fracture of the os calcis and without displacement, when unable to recognize it clinically.

When there is no displacement treatment is directed simply to immobilize the joint and control the inflammation; a plaster bandage should

be applied, especial attention being given to the position of the foot, which should be at right angles to the leg in the antero-posterior plane and without inversion or eversion.

If a fragment is broken from the upper articular surface of the body it should be removed. If the neck has been broken and the head displaced it should be restored to its place, by an incision if necessary, or removed if it is found to be completely detached. If, in addition, the body has been rotated in its socket it must be readjusted, or, that failing, removed. If the body should prove to be crushed or comminuted its total excision, with or without the head and neck, will probably yield a much better functional result than conservative treatment.

In compound fractures by direct violence removal of the astragalus is indicated because functional result is likely to be better than after even successful conservative treatment.

Fracture of the Processus Posticus.¹

This is the portion of the posterior border which lies between the groove for the tendon of the flexor longus pollicis and that for the external lateral ligament. This fracture was first mentioned by Cloquet in 1844, but the correct interpretation of the small piece of bone frequently found in this place has been asserted by the anatomists to be a developmental vagary, the abnormal persistence of a small nodule which appears in the second month between the tibia and the astragalus. They term it the *os trigonum*. According to Lilienfeld, the *os trigonum* when present is almost always found on both limbs, and he claims to have observed 12 cases of fracture, 5 of them associated with fracture of the calcaneum. The diagnosis was made on *x*-ray findings with local tenderness on pressure and swelling.

2. FRACTURE OF THE CALCANEUM.

This bone may be broken by a fall upon the foot from a height, by contraction of the muscles attached to the tendo Achillis, by direct violence, and by forcible inversion of the sole of the foot. The extent and position of the fracture vary with the causes.

The forms of fracture² of the body of the bone may be grouped as (1) Separation of a large heel piece comprising the posterior half; (2) fracture of the anterior portion, often splintered; (3) a general crush, mainly of the centre or anterior two-thirds. (Plates XLI. and XLII.) The cause in most cases is a fall upon the feet.

Symptoms. The symptoms of a vertical or crushing fracture are somewhat indefinite, and the diagnosis is not always easy, as is shown by the fact that surgeons so experienced as Malgaigne, Bonnet, Huguier, and Legouest have mistaken the injury for fracture of the fibula or ankle. The symptoms are increase of its transverse diameter (which, however, may be completely masked by the swelling below and about the malleoli), flatness of the sole and approximation to it of the mal-

¹ Lilienfeld: Arch. für klin. Chir., vol. 78, p. 929.

² See also Cabot and Binney: Annals of Surg., January, 1907, p. 51.

leoli, especially of the internal one, pain, and loss of function. Crepitus is either absent or obscure; abnormal mobility may be recognized by moving the posterior portion laterally. Pain is caused by direct pressure and by a voluntary effort to make plantar flexion against resistance at the toes. The tendo Achillis feels less tense when pressed upon, and the depression on each side of it is obliterated by swelling. The deformity of the heel is best recognized when compared with its fellow from behind while the patient is kneeling.

Treatment. The treatment is immobilization, preferably with massage, for about three weeks; then passive motion, to be continued until the end of the second month. Cabot and Binney suggest the possible advisability in fractures with a large heel fragment of over-correcting the displacement by drawing the heel downward and forward.

When the direction of the violence with reference to the axis of the leg is such that the foot is adducted or inverted by it, the strain is brought upon the external lateral ligament and the sustentaculum tali, with the result of producing fracture of the fibula as described on page 391, or rupture of the external lateral ligament, or avulsion of a scale of bone from the side of the calcaneum where the ligament is inserted, or fracture of the sustentaculum tali.

With the first of these we have not here to deal. A case of *avulsion of a scale of bone* came under my observation at the Presbyterian Hospital in 1880; the patient had fallen from a height of ten feet, striking upon his left foot. I saw him on the following day and found the foot and ankle much swollen, with obscure crepitus and pain on manipulation of the side of the heel below the outer malleolus. The swelling subsided under lead and opium lotions, and in a few days I could distinctly make out a movable flat fragment evidently detached from the outer side of the calcaneum below the malleolus. The movements of the foot and ankle were normal and painless except when the peroneal muscles were made to contract, then pain was felt below the external malleolus. The sheath of the tendons of these muscles was swollen below and behind the malleolus.

Fracture of the sustentaculum tali was first described by Abel.¹ In his first case the injury was thought to be a Pott's fracture of the ankle, and its real character was disclosed at the autopsy. The patient was a young man who in dismounting from a horse slipped on a stone and turned his foot forcibly inward. He attempted to walk, and the position of the foot then changed instantly to marked valgus. A longitudinal wound three inches long below the external malleolus opened the ankle-joint and the joint between the astragalus and calcaneum. There was tenderness on pressure below the internal malleolus, and on the fibula above the external malleolus. These symptoms together with the apparent broadening of the ankle and eversion of the foot led to the erroneous diagnosis mentioned. Erysipelas set in and the patient died on the fifteenth day.

The fibula and tibia were found uninjured, the sustentaculum tali broken off, and the external lateral ligament divided in the line of the wound.

¹ Abel: *Archiv für klin. Chirurgie*, 1878, vol. xxii. p. 396.

Abel afterward saw two cases in which he thought this injury had been received some time before. In both the foot had been violently inverted, and in one the sustentaculum tali seemed to be doubled in size. The symptoms, primary and ultimate, corresponded to the following, which he gives as diagnostic of the injury.

1. The mode of production: forcible inversion of the sole of the foot.
2. The immediate change in the position of the foot, from inversion to eversion, and the permanent sinking of the inner border of the foot and internal malleolus (valgus).
3. Shortening of the heel by slight displacement of the calcaneum forward; this can be best recognized by measuring from one malleolus to the other around the heel, and was verified by experiment.
4. Pain and disability.

The foot should be immobilized in a plaster bandage or splints with the sole sufficiently inverted to favor reunion of the fragments, but without lengthening of the external lateral ligaments if they have been torn.

Fracture by muscular action, contraction of the soleus and gastrocnemii, has been observed a number of times. Malgaigne collected eight cases, rather briefly reported; in two the fracture was caused by a misstep, and in five by a fall upon the feet, in two of which it is noted that the patient alighted upon the ball of the foot. The fracture seems to take place always behind the astragalus and sometimes to separate only a portion corresponding to the insertion of the tendo Achillis. The displacement in some cases was slight, in others extreme, four and one-half inches from the lower edge of the fragment to the bottom of the heel in Constance's¹ case, in which, nevertheless, the patient made a good recovery with perfect use of the limb, although the displacement persisted.

In a case reported by Anningson² the mechanism of the fracture seems very clear. A woman, forty-two years old, after stepping down from a doorway to the sidewalk, a distance of about six inches, cried out that she had "put out her ankle." She walked home slowly, a distance of one hundred yards. A fragment of bone was found two and a half inches above the heel in the line of the tendo Achillis which was lacking below it; its lower edge was a little above the level of the lower end of the internal malleolus; it measured one inch transversely and "had been torn off the posterior surface of the os calcis where a cavity could be felt. The whole depth of the bone had not been torn away, but only the upper three-fourths, and the inferior edge of the fragment was tilted backward. The usual treatment of ruptured tendo Achillis was adopted," and eight weeks afterward the patient was able to walk without limping and complained only of some loss of spring.

I have seen a similar fracture, but with less displacement of the fragment, caused by jumping from a boat, the fracture apparently occurring as the patient alighted on his toes. In another the patient while bending forward was struck upon the back of the leg by a falling beam;

¹ Constance: American Journal of the Medical Sciences, 1892, p. 222, quoting from an English journal.

² Anningson: British Medical Journal, 1878, vol. i. p. 128.

the posterior part of the fragment, as shown by a skiagram, was displaced upward three centimetres, but its anterior portion remained in contact with the os calcis. (Plate XLII.)

The foot should be maintained in the position of complete plantar flexion, and it is sometimes advisable to flex the knee also. This can be done by a plaster dressing, or an anterior splint, or a shoe with a cord extending from its heel to a band about the upper part of the leg or the lower part of the thigh. Gussenbauer¹ successfully treated a case by nailing the fragment in place.

3. FRACTURES OF THE SCAPHOID.

These are very rare except in combination with fracture of other bones of the foot. Bergmann² saw a case in which the bone was broken by a fall upon the ball of the foot, apparently by pressure against the astragalus, and Paublan³ one of "transverse" fracture caused by a fall, the upper fragment was displaced upward out of its socket, the lower was crushed.

Haglund⁴ describes fracture of the *tubercle* of the scaphoid caused in adolescents by muscular action, dancing; he says it may result promptly in pes valgus.

4. FRACTURE OF THE CUBOID.

The only case of which I know is the one shown in Plate XL., a patient of the Hudson Hospital. The fracture was caused by a blow on the outer side of the foot; crepitus was distinct on pressure of the fragment against the cuboid.

5. FRACTURES OF THE METATARSAL BONES.

These were formerly thought to be usually the result of direct violence, and consequently often associated with contusion or laceration of the skin, even when the fracture was not compound. But Robert Jones⁵ broke his fifth metatarsal near its base while dancing, and within a few months subsequently saw three cases similarly produced. And Tobold⁶ reports over seven hundred cases observed in soldiers, almost all caused by indirect violence, as marching, jumping, etc. The second was the one most frequently broken, then the third. Lilienfeld⁷ has seen several cases of fracture of the extreme tip of the base of the fifth metatarsal caused by inversion of the foot, presumably through the pull of the peroneus brevis.

There is but little tendency to displacement except when several bones are broken at the same time, and the usual displacement is of the broken end of either fragment toward the dorsum of the foot.

¹ Gussenbauer: *Centralblatt für gesammte Therapie*, June, 1888.

² Bergmann: *Deutsche Zeitschrift für Chir.*, vol. 80, p. 199.

³ Paublan: Quoted by Capellery and Ferron, *Rev. de Chir.*, vol. 34, p. 98.

⁴ Haglund: *Zentralblatt für Chir.*, 1907, p. 327.

⁵ Jones. *Annals of Surgery*, June, 1902.

⁶ Tobold: *Deutsche militärärztl. Zeitschrift*, 1903, Part 9, abst. in *Centralblatt für Chir.*, 1904, p. 439.

⁷ Lilienfeld: *Arch. für klin. Chir.*, vol. 78, p. 929.

PLATE XLI.

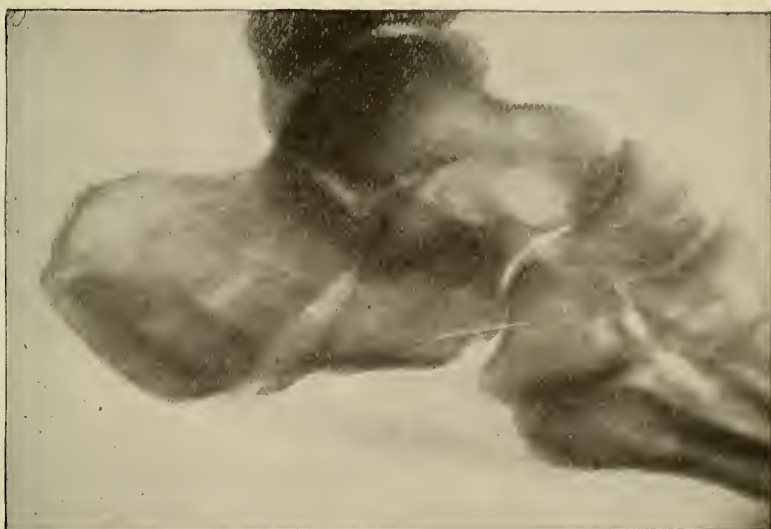

Fig. 1.—Fracture of Os Calcis. (Cabot.)

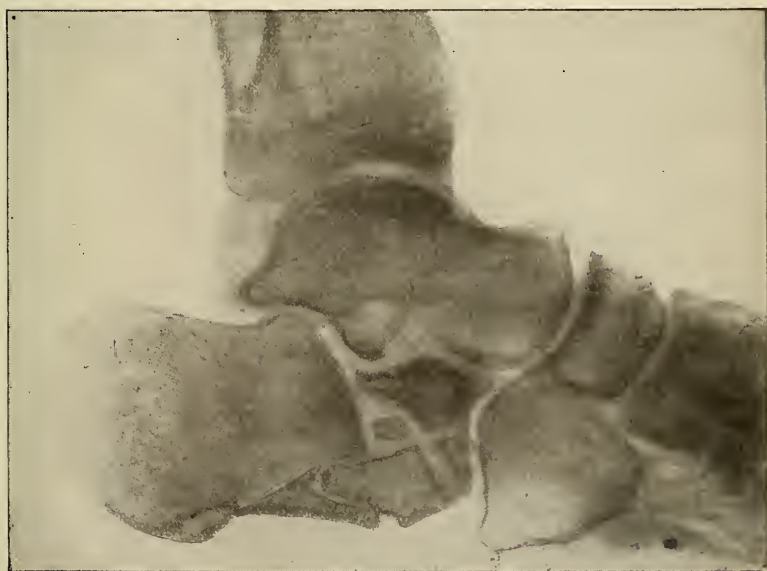

Fig. 2.—Fracture of Os Calcis. (Cabot.)

PLATE XLII.

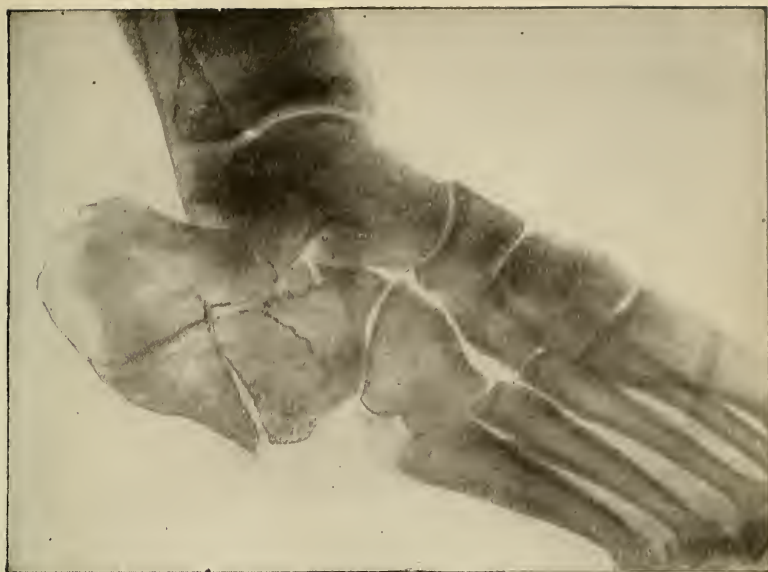

Fig. 1.—Fracture of Os Calcis.

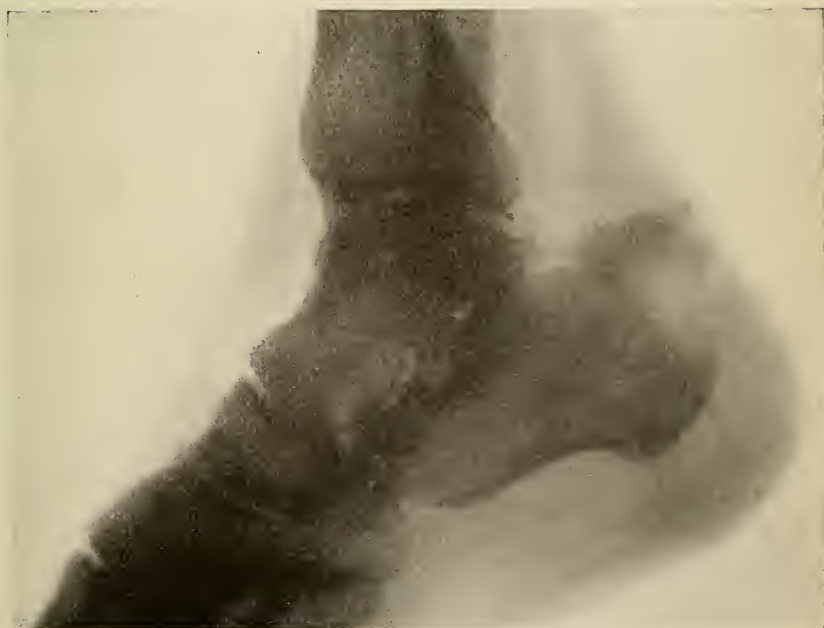

Fig. 2.—Fracture of the Upper Posterior Portion of the Os Calcis by Avulsion.

The diagnosis is made by localized pain, abnormal mobility and crepitus when the first or fifth is broken, and pain when the corresponding toe is pressed bodily backward against the metatarsus.

A simple fracture is not a serious injury, its course is uncomplicated, its result favorable; but a compound fracture may lead to much burrowing of pus, necrosis of the fragments, and grave inflammatory complications, and the treatment should be directed actively to their prevention; if suppuration becomes profuse the freest possible drainage should be provided and counter-openings made on the sole or dorsum as the case may require.

The limb and foot may be supported upon a moulded splint of plaster, felt, or pasteboard, and secured to it with a roller-bandage. In compound fracture the gauze dressings will immobilize the fragments sufficiently.

6. FRACTURES OF THE PHALANGES.

These are caused by direct violence and are usually compound, and, as in similar injuries of the hand, may be the starting-point of very serious inflammatory complications. Immersion of the foot in a bath containing 1 or 2 per cent. of carbolic acid once or twice daily for an hour each time is a valuable means of arresting commencing inflammation.

The dressings of a compound fracture will immobilize the toe sufficiently, and in a simple fracture it is usually sufficient to place the foot on a splint. If it is thought desirable the toe itself may be steadied by strips of adhesive plaster applied longitudinally to its dorsum and sides, or it may be made fast to the adjoining ones.

¹ Jones: *Annals of Surgery*, June, 1902.

² Tobold: *Deutsche militärärztl. Zeitschrift*, 1903, Part 9, abst. in *Centralblatt für Chir.*, 1904, p. 439.

DISLOCATIONS.

CHAPTER XXVII.

GENERALITIES.

A **DISLOCATION** is a permanent, abnormal, total or partial displacement from each other of the articular portions of the bones entering into the formation of a joint.

The term *diastasis* is employed to indicate a direct separation, temporary or permanent, of articular surfaces, without lateral gliding of one upon the other, as when the pubic bones separate at the symphysis, or the tibia and fibula are torn apart, or in some injuries of the spinal column.

If the displacement is only momentary, the parts immediately returning to their normal relations, the injury is classed as a *sprain*.

When a coexisting wound of the soft parts establishes communication between the outer air and the cavity of the joint, the dislocation is said to be *compound*; and when there exist associated lesions of the joint or neighboring tissues so extensive or peculiar as to present special indications or create special difficulties in treatment, such as fracture or laceration of vessels, nerves, or integuments, it is said to be *complicated*; under other circumstances it is described as *simple*.

When the articular surfaces are so far displaced that they no longer touch each other, or that they touch only by their edges, the dislocation is said to be *complete*; if the displacement is less, it is called an *incomplete* dislocation or *subluxation*. Incomplete dislocations are frequent in the ginglymoid and arthrodial joints, and the controversy as to their frequency or infrequency in the enarthroses has arisen not from any doubt as to the nature of the new relations of the articular surfaces to each other or of the extent of the displacement, but solely from differences in definition, some authors maintaining that only those dislocations should be deemed complete in which the head of the bone has entirely left its bony socket, and all those incomplete in which any portion of the head remains within the area bounded by the rim of the socket, whether portions of the articular surfaces are in contact with each other or not. Under that definition many dislocations of the shoulder and of the hip would probably have to be classed as incomplete, if the exact relations of the bones could be determined; and as such accuracy of diagnosis would rarely be attainable, and the doubtful cases would not differ clinically from those in which the displacement is greater, the adoption of such a classification would serve only to embarrass and obscure. It seems to me much simpler and more practical, even if somewhat arbitrary, to call all traumatic dislocations of the hip and shoulder complete in which the centre of the head of the bone has passed beyond the rim of the socket. The incomplete dislocations would then be exceptional, practically only those in which a portion of the rim of the socket is broken off and pushed aside by the displaced

head, as in a case mentioned by Robert¹ in an animated discussion of this subject before the Société de Chirurgie.

In the great majority of cases the dislocation is of a single joint only, but occasionally two or more joints may be simultaneously dislocated, and the injury is then said, according to circumstances, to be *bilateral*, *double*, or *multiple*. When a symmetrical bone, having joints on both sides of the median line of the body, as the lower jaw or a vertebra, suffers dislocation of these joints, the injury is called *bilateral* or *double*, and the same terms are also applied to symmetrical dislocations on opposite sides of the body, as of both shoulders or both hips. When both ends of a bone are dislocated, as has been observed in the clavicle, ulna, and fibula, the dislocation is said to be *double* or *total*.

Multiple dislocations are those in which two or more bones are simultaneously dislocated, as two fingers, a shoulder and a hip. Some authors include under this term those dislocations which others term *total*.

A method of nomenclature accurately descriptive of the different varieties of dislocation has not been established. As a general rule, subject, however, to some exceptions, the bone which is more distant from the trunk or median line of the body, the one that is generally moved upon the other, is said to be dislocated; thus a dislocation at the hip, at the shoulder, is called a dislocation of the femur, of the humerus. Or the joint alone is named, as a dislocation of the elbow, of the hip, of the shoulder. As an example of the exceptions may be mentioned dislocation of the outer end of the clavicle, a term universally preferred to dislocation of the acromion.

The same lack of uniformity appears in the names given to the various dislocations that may occur at the individual joints, and the practice has grown up of using in each case such a name as may most readily and accurately indicate either the general character of the displacement or some important special feature connected with it. When the name of the joint is used, and a term indicating direction is added, as dislocation of the elbow backward, forward, to the inner or to the outer side, the latter denotes the direction in which the *distal* member of the joint has been displaced. Whenever the use of the name of the joint would give rise to ambiguity, it is common to prefer the name of one of the bones constituting it, as a dislocation of the radius and ulna backward, instead of dislocation of the elbow backward. Strictly speaking, it is true that this might be mistaken for a dislocation at the wrist, and that, therefore, it would be well to add "at the elbow," but custom has so well established the meaning of the different terms now in use that in practice such a mistake would hardly be made. Other dislocations, again, have received names denoting the relations of the dislocated bone to certain muscles or bones, as subcoracoid or subpectoral dislocation of the humerus, and dislocation of the (head of the) femur upon the dorsum of the ilium or into the obturator foramen.

The *primitive* or *primary* displacement is the one immediately effected by the causative violence which produces the dislocation; if the dislocated bone afterward shifts to another position, the displacement is said

¹ Robert: Bull. de la Société de Chirurgie, January 19, 1853, p. 389.

to be *consecutive* or *secondary*. This shifting of the position of the dislocated end sometimes has very important consequences as regards treatment, because the end of the bone may thereby be removed from its position opposite the rent in the capsule through which it escaped from the cavity of the joint, and it may need to be brought back to that position before it can be replaced in the joint.

In the great majority of cases a dislocation is produced suddenly by external violence or by muscular action, or by the two acting together upon a healthy joint, and when thus produced it is called *traumatic*. In other cases the joint has been altered by disease previous to the occurrence of the dislocation, and this latter is effected by the gradual action of the muscles or even by gravity; these are known as *spontaneous*, and present many varieties. (See Chapter XXXVI.) A third class, *congenital* dislocations, is composed of those in which the dislocation occurs during intra-uterine life, presumably as the result of a malformation or defective development. Dislocations produced during delivery are traumatic. The second and third classes will be separately considered. (See Chapters XXXV. and XXXVI.)

Statistics. Compared with other surgical injuries, dislocations are infrequent; the proportion to fractures is about 1 to 10.

DISLOCATIONS AT THE HUDSON STREET HOSPITAL, NEW YORK, 1894-1905.
HOSPITAL AND DISPENSARY.

Hip, dorsal	19	} Lower extremity, 89 5.82 per cent.
thyroid	3	
Knee	12	
Semilunar cartilage	13	
Patella, outward	9	
Head of fibula	1	
Ankle	5	
Astragalus	5	
Subastragaloid	5	
Metatarsus and phalanges	17	
Clavicle, outer end	69	} Upper extremity, 1368 89.59 per cent.
sternal end	12	
Shoulder	617	
Elbow	156	
Head of radius ¹	18	
Ulna, upper end ¹	13	
lower end	8	
Carpus	7	
trapezium	1	
semilunar	5	
scaphoid	3	
os magnum	1	
Metacarpal	80	
Metacarpo-phalangeal and phalangeal	378	
Lower jaw	61	} Head and trunk, 70 4.58 per cent.
Vertebrae	6	
Chondro-sternal	1	
Sacro-iliac synchondrosis	2	
	1527	

¹ Including cases with associated fracture.

TABLE OF 400 RECENT TRAUMATIC DISLOCATIONS (KRÖNLEIN).¹
HOSPITAL AND POLYCLINIC.

Joints.	Kind.	Sex.		Age.							Totals.	Percentages of frequency.		
		M.	F.	1-10	11-20	21-30	31-40	41-50	51-60	61-70			71-80	
Hip	Iliac	4	...	2	...	1	...	1	4	8	2	
	Obturator	2	1	2	1	...	3			
	Pubic	1	1	1			
Knee	Lateral	4	...	1	1	1	...	1	4	7	1.7	
	Patella out-ward } backward }	2	1	...	2	1	3			
Foot	1	1	1	...	1	2	0.5		
Metatarso-phalangeal	3	...	1	2	3	0.7		
Shoulder	Subcoracoid and axillary } Erecta	180	23	...	2	53	44	48	35	19	2	203	207	51.7
	Infraspinous	3	2	1	3			
	Of forearm	1	1	1			
Elbow	backward } Of radius	77	17	22	44	14	5	4	3	1	1	94	109	27.2
	Dorsal of ulna	9	6	9	5	1	15			
Wrist	1	1	1	0.2		
Metacarpo-phalangeal	23	4	6	8	4	8	1	27	6.7		
Interphalangeal	7	1	1	...	5	1	1	8	2		
Sterno-clavicular	4	2	1	3	2	6	1.5		
Acromio-clavicular	11	...	1	...	2	4	3	1	...	11	2.7		
Lower jaw	Unilateral	2	2	...	1	1	...	2	4	10	2.5	
	Bilateral	6	...	1	3	1	...	1	6			
Cervical vertebrae	1	...	1	1	0.2		
		336	64	44	69	88	55	60	48	23	3	400		
		400		400										

The following table summarizes the other two with Malgaigne's statistics of the Hôtel-Dieu :

	Cases.	Upper extremity.	Lower extremity.	Trunk.
Malgaigne, hospital	491	85.7 per cent.	12.6 per cent.	1.6 per cent.
Krönlein, hospital and polyclinic	400	92.2 "	5 "	2.8 "
Stimson, hospital and dispensary	1527	89.59 "	5.82 "	4.58 "

These tables show the great relative frequency of dislocations of the upper extremity as compared with those of the lower. Each set of statistics shows that dislocation of the shoulder is far more common than that of any other joint, and that next in frequency come dislocations of the elbow. These two dislocations may be estimated as together comprising from two-thirds to three-fourths of all cases, excluding the phalanges.

As between *males* and *females*, Malgaigne and Gurlt found the injury three times as frequent in the former as in the latter; Krönlein found it five times as great. Dislocations of the lower jaw are an exception, being four times (Krönlein) as frequent in women as in men.

Age. No age is exempt; dislocations have occurred as early as the moment of birth and as late as the age of ninety years. The relative liability to the injury at different ages is shown not by simply comparing the number of cases observed at those ages, but by also com-

¹ Krönlein: Deutsche Chirurgie, Lief. 26, p. 5.

paring these numbers with the number of people at those ages living in the community where the observation is made. This comparison has been made by Krönlein for Berlin, with the following results :

FREQUENCY OF DISLOCATIONS AT DIFFERENT AGES.

	1-10	11-20	21-30	31-40	41-50	51-60	61-70	71-80
Absolute frequency	44	69	88	65	60	48	23	3
Relative number of people living	1872	1620	2529	1679	940	599	282	117
Relative frequency as computed for equal } numbers of people }	10	18	15	16	27	35	35	10 †

From this it appears that a smaller proportion of individuals between the ages of one and ten, and seventy-one and eighty years receive dislocations than in any other decade of life ; and the highest proportions are found between the ages of fifty-one and sixty and sixty-one and seventy. It is further to be noticed that dislocation of the shoulder is very rare, and that of the elbow very common, before the age of twenty-one years. Krönlein's table shows that of 207 cases of the shoulder, in only two were the patients less than twenty-one years old, and that of 109 cases of the elbow 80 were no older, the age in 31 being between one and ten years, and in 49 between eleven and twenty years. Compared with fractures, it appears that the liability to dislocation is least during those periods of life in which the liability to fracture is greatest—that is, in infancy and youth and in old age ; the latter part of this statement may need some modification, for while dislocations are rare after the age of seventy, they are relatively frequent in the preceding decade. The liability to each increases from adolescence through middle life.

CHAPTER XXVIII.

ETIOLOGY AND MECHANISM.

Predisposing Causes; Immediate Causes; Recurrent or Habitual Dislocations.

THE causes of dislocation may be grouped in two classes: *a.* Predisposing; *b.* Immediate or determining.

A. Predisposing Causes.

These are found in certain normal differences of form and function characterizing certain joints, and in accidental or pathological conditions that sometimes arise.

The joint which is most frequently dislocated is the shoulder-joint, and it differs normally from others in the wide range and variety of motion made possible by its form, the laxity of its capsule, and the absence of any firm ligament to hold the bones closely together. A wide range of motion in one direction is not necessarily a circumstance favoring dislocation; on the contrary, it may protect against it by making it difficult to bring into action the fulcrum which is furnished by the edge of the bone when it arrests the motion. In a young healthy person the elbow or knee cannot be dislocated by flexion, because the motion is finally arrested by broad contact of the soft parts, not by the edge of the joint; while, on the other hand, in each case extension is limited by the structures of the joint itself, and hyper-extension at once favors dislocation by rupturing those structures. A long range of motion in one plane does not make the joint insecure so long as the two bony surfaces rest squarely against each other, as they do in the hinge-joints; but when the change of position makes this contact oblique, as in abduction of the arm, a displacing force exerted in the direction of the long axis of the bone is resisted only by the capsule. Under certain conditions, therefore, it may be said that freedom of motion in a joint diminishes, and limitation of motion increases, the liability to dislocation.

Dropsy of some joints favors dislocation by removing the obstacle which the necessity of creating a *vaenum* between the articular surfaces would otherwise interpose. (See Chapter XXXVI., Dislocations by Distention.)

The destruction of the ligaments by violence or disease, and fracture or disease of the bony constituents of the joint, favor dislocation, and the fracture of an associated or parallel bone may have the same effect, as fracture of the ulna favors dislocation of the head of the radius.

B. Immediate or Determining Causes.

A bone may be dislocated by (1) external violence applied (*a*) directly to it at or near its end, or (*b*) indirectly and at a distance from its end; (2) by muscular action.

1. **External Violence.** Dislocations by direct violence are rare, especially if the class is restricted to those cases in which the violence falls upon only one of the bones forming the joint and forces it directly away from the other. Thus, the head of the humerus has been driven backward (subspinous dislocation) by a blow of the fist (Busch) or by a fall in which the front of the shoulder struck against the corner of a table (Krönlein), or inward by a fall upon the outer side of the shoulder, or even downward into the axilla by a force received upon and first breaking the acromion (Krönlein, Stimson).

In dislocations by indirect violence the mechanism may vary greatly. The force in some cases is exerted directly along the long axis of the bone while the limb is in a position in which the articular surfaces do not rest squarely upon each other, and the head of the bone is driven out of its socket, as in some dislocations of the shoulder by a fall upon the outstretched (abducted) arm or by muscular action, or in dislocation of the outer end of the clavicle by a fall upon the shoulder. The mechanism is similar to that of the first form of dislocation by direct violence mentioned above. Or a much slighter force, favored by conditions of leverage established at the joint, tears the capsule or a ligament and produces a dislocation. This is the most common mechanism. The conditions of leverage are found at all points where normal movements are arrested or no movement permitted. The head or neck of a moving bone is arrested by the edge of the corresponding articular cavity, or by a projecting point of bone, or by a tense ligament or portion of capsule; this at once becomes a new centre of motion, a fulcrum, and, the force continuing to act at the end of the bone or limb (the long arm of the lever), the head of the bone (or short end of the lever) is forced away abnormally.

When the force is exerted in a direction in which normally no motion is permitted, as laterally at the elbow, ankle, or knee, it meets at once with greater resistance than that habitually found at the extremes of normal ranges of motion, and if it is great enough to overcome this resistance it is more likely to cause in addition other and perhaps extensive injuries of the soft parts or of the bones.

Violence, then, acting in a given manner, may cause a fracture, a dislocation, or a sprain according to its force, the strength of the resistance offered by the ligaments and the bones to which they are attached, and the prolongation of its action.

2. **Muscular Action.** Contraction of the corresponding muscles can cause the dislocation of a sound joint in either of two ways: it can, by rapidly moving the limb, communicate to it a momentum which acts in the same manner as external violence and produces a dislocation when the normal limit of the range of motion is reached and conditions of leverage are established. A case, probably of this kind, was

observed by Sédillot :¹ a woman, forty-six years old, who dislocated her shoulder by raising her arm to strike a blow. Or, secondly, the muscular contraction acts like external violence received at or near the end of the bone, or transmitted along its longitudinal axis, and draws the bone out of its socket. For this it is essential that one or two muscles should contract violently while the others that normally act upon the joint remain passive, or that the limb should be in such a position that the line of traction of the muscles is nearly parallel to the opposing articular surface. Instances of this kind are common at some joints; dislocation of the lower jaw is commonly caused by muscular action in yawning, laughing, or vomiting, and others have been caused in like manner at the shoulder and hip, and, very exceptionally, at other joints. As illustrative examples may be mentioned the following :

A man, fifty-one years old, dislocated both shoulders (subcoracoid) by drawing himself up with his hands; a painter dislocated his shoulder while painting a ceiling; a woman, by trying to lift a heavy object from a shelf; a man, by trying to lift at arm's length a heavy book from the floor; and a woman, by carrying a heavy load upon her head with both arms uplifted.

Many cases have been reported in which dislocation has been caused by the convulsive contractions of individuals affected with epilepsy, tetanus, or uræmia, or poisoned with strychnine. In many of the cases reported as such the dislocation may have been caused by violence received in falling during a fit or by striking the limb against some object, but in a number of them the history positively establishes the absence of any other cause than the contraction of the muscles.

In these cases, as in fractures by muscular action, it is unnecessary to suppose, and unwarranted to claim, that the strength of the capsule or ligaments is less than usual, or that the structure of the joint varies from the normal in such a way as to facilitate the production of the dislocation.

The power of *voluntary* dislocation of one or several joints has been occasionally observed. In a large proportion of the cases its appearance has followed the occurrence of a traumatic dislocation of the same joint, but in a few instances the history of the individual contained the record of no traumatism or diseased condition to which the peculiarity could be referred.

C. Recurrent or Habitual Dislocations.

Individuals are occasionally observed in whom dislocation of some one joint, commonly the shoulder, but also the hip, jaw, and clavicle, frequently recurs under the influence of some slight cause, and who have acquired this liability as the result of an ordinary traumatic dislocation, or of paralysis of one or more of the muscles of the joint, or of fracture. The first class will be considered in Chapter XXIX.; of the others the following case, reported by Sir Astley Cooper,² will

¹ Sédillot : Dict. Encyclopédique, art. Luxations, p. 23.

² Cooper : Dislocations and Fractures, Am. ed., 1844, p. 9.

serve as an illustration: "A gentleman happened, as a junior officer on board his ship, to be placed under the orders of one of the mates when the captain was on shore, and for some trifling offence was punished in the following manner: his foot was placed upon a small projection on the deck, and his arm was lashed tightly toward the yard of the ship, and thus kept extended for an hour. When he returned to England he had the power of readily throwing that arm from its socket merely by raising it toward his head, but a very slight extension reduced it; the muscles were also wasted, as in a case of paralysis."

The explanation is to be found in the loss of support occasioned by the diminution of the tonicity of the muscles which in such joints as the shoulder, take the place of short, firm ligaments and hold the articular surfaces in contact with each other, a loss which allows the bones to be separated by the action of gravity, or by an effusion into the joint, until the separation is arrested by the capsule. When thus separated, a slight force is sufficient to throw the head of the humerus past the edge of the glenoid cavity and produce a dislocation without rupture of the capsule.

The cases of dislocation due to limited paralysis of peripheral origin must not be confounded with those sometimes accompanying the arthropathies that complicate some paralyzes of central origin and some cases of central nervous disease without paralysis. In the latter the articular portions of the bones are absorbed in the progress of the disease, and thus even a joint the bones of which are normally held close together by ligaments becomes a loose one by loss of bone substance. Strictly speaking, such cases in which the articular end of the bone has been entirely absorbed do not come within the definition of dislocation, but clinically it is proper and convenient so to designate them. (See Chapter XXXVI.)

The **unequal growth** of parallel and associated bones, tibia and fibula, or radius and ulna, may cause dislocation at one or the other end.

¹ Cooper: Dislocations and Fractures, Am. ed., 1844, p. 9.

CHAPTER XXIX.

PATHOLOGICAL ANATOMY IN RECENT DISLOCATIONS; COMPLICATIONS; AND THE PROCESS OF REPAIR AFTER REDUCTION.

PATHOLOGICAL ANATOMY.

As a traumatic dislocation consists in the forcible overcoming of the normal restraints upon the motion of the joint in one or more directions, restraints offered by the ligaments and capsule of the joint, it is almost invariably accompanied by rupture of a ligament or of the capsule. There is some reason to think that dislocation of the inferior maxilla may be an exception to this rule, but the lack of opportunities directly to examine such cases leaves the question in doubt. In enarthrodial joints, especially the shoulder, where the ligaments are loose and where the bones are held together by the tonicity of the muscles and the atmospheric pressure, such a change as dropsy of the joint may so annul the effect of the latter agent and overcome the former by filling the capsule with liquid that insinuates itself between the contiguous articular surfaces, that the head of the bone falls away from its socket and the joint becomes loose like that of a flail; under such circumstances dislocation may occur without rupture or laceration.

The capsule of an enarthrodial joint is torn upon the side toward which the distal bone is displaced; in joints of other forms the ligaments may be broken on either or both sides, the extent and character of the injury varying with the character of the force. The rent in the capsule may be limited in extent and simple in form, merely a longitudinal or transverse slit, or it may be irregular or may even involve the entire periphery. Instead of suffering a rent, the capsule may be torn away from the bone, sometimes bringing with it portions of the bone itself or remaining continuous with the periosteum stripped up from the shaft. Under similar conditions the position of the rent in the capsule is very constant, for it is determined by the posture of the head and the direction of the force. In addition to the laceration of the capsule and ligaments produced by the pressure of the bone, others may be caused by the tearing off of attached muscles that are put upon the stretch by the displacement. This may be effected by the avulsion of the tuberosities upon which the muscles are inserted; the bone yields, and the laceration, starting from the broken surface, extends across and through the adjoining soft parts. This is a frequent accompaniment of dislocation forward and downward of the shoulder; the supraspinatus and infraspinatus muscles, inserted respectively upon the upper and middle facets of the greater tuberosity of the humerus, are put upon the stretch and one or both are torn away from the bone.

The soft parts overlying the capsule may be torn by extension of the

rent in the capsule if they are closely adherent to the latter, or by the forcible passage through them of the displaced bone. The surrounding muscles on the side toward which the displacement takes place may be contused or torn by the passage of the bone, and those upon the opposite side by being put upon the stretch. Blood is freely extravasated into the cellular tissue from the ruptured vessels.

The cartilages of incrustation may be bruised and sometimes chipped in the passage of the surfaces across each other, and projecting portions of bone, apophyses, or the rim of an orbicular cavity may be broken off.

The bone itself seldom passes to any great distance from its normal position; its progress is arrested by the ligaments and muscles that remain untorn and the resistance of the soft parts that it presses upon, and it comes to rest lying directly upon the adjoining bone or with some soft parts interposed. Its position, as taken in the primary displacement, may be changed by the renewal of external violence, by gravity, by a change in the position of the limb, or by the spasmodic contraction of attached muscles, but the secondary position ("consecutive displacement") is habitually determined by the resistance of untorn ligaments which constitute the fulcrum or pivot about which the bone turns.

COMPLICATIONS.

Other injuries, and severer or more extensive forms of those already mentioned, may coexist with a dislocation as complications. They include fracture of the bone, partial or complete rupture of large bloodvessels or nerves, and extensive laceration of the soft parts. To constitute a "complication" of the dislocation the associated injury should be the direct or consecutive result of the original violence upon adjoining tissues, and should create special indications for, or difficulties in, treatment. A fracture of the leg caused by the same fall that dislocates the shoulder is not, in this sense, a "complication" of the dislocation; but a fracture of the ulna accompanying dislocation of the radius, or a fracture of the neck of the humerus accompanying dislocation of the shoulder is a complication, for the two injuries are associated in their origin and in their treatment.

Bones. Not all fractures that coexist with dislocation of even the same bone are necessarily to be deemed complications, since some habitually accompany certain dislocations, may even not be recognizable clinically, and neither receive nor require special treatment. Such are fractures of apophyses or tubercles to which muscles are attached, and some fractures of a portion of the articular end of the bone or of the rim of an orbicular cavity. In others the dislocation is rather to be deemed a complication or incident of the fracture, since it is made possible by it, as in some fractures of the vertebræ and in fracture of the olecranon with displacement forward (or upward) of the radius and ulna.

Relatively common are those in which the force is exerted through the head of the bone upon the margin of the opposing articular surface, breaking off the latter; the dislocated bone leaves the joint through the gap thus created, driving the fragment before it, or else tears the capsule and escapes in the usual manner. The commonest examples

of this kind are found in fractures of portions of the rim of the glenoid and cotyloid cavities, and some fractures at the ankle with displacement of the astragalus. Others, that are closely analogous, are fractures of the coronoid process of the ulna or of the head of the radius, or of both, in dislocation backward of both bones.

Bruising or deep indentation of the head of the bone by impact upon the edge of the socket has been noted several times at the shoulder and once by myself at the hip. It cannot be recognized clinically and is not known to have important consequences, but when the impact is along the anatomical neck of the humerus it may detach the head, and in two cases¹ the head of the femur has been split vertically; in a third² the head and neck were split longitudinally, apparently after dislocation had taken place.

A very rare complicating fracture is that of the central part of the acetabulum when the head of the femur is driven through it into the cavity of the pelvis by great violence.

Much more common, but seldom deserving to be classed as complications, are those fractures by avulsion, already referred to, in which, ligaments or muscles being put upon the stretch, the bony prominences to which they are attached are torn off. Some of them may be looked upon as frequent accompaniments of certain dislocations, for example, fracture of the greater tuberosity of the humerus in dislocation of the shoulder forward and downward, and fracture of the internal epicondyle in dislocation of the elbow.

The form in which the complication most seriously affects the treatment and prognosis is that in which the bone is broken completely across near the dislocated end. The commonest examples are found at the shoulder, where the line of fracture follows either the anatomical or the surgical neck, and the special difficulty in treatment arises from the smallness of the upper fragment, whereby it is made difficult or impossible so to act upon it as to return it to its normal position in the joint. In 68 cases of this kind collected by Thamhayn³ 14 were of the anatomical neck of the humerus, and of these in only 2 was the dislocation reduced; while of the 46 cases in which the fracture occupied the surgical neck 20 were reduced. McBurney's recent (1893) method of reducing with the aid of a hook inserted into the fragment has greatly diminished the difficulty. The mechanism of the combined lesions is sometimes obscure, as regards its details, and varies in the different cases, the dislocation sometimes preceding and sometimes following the fracture, and perhaps sometimes occurring simultaneously. In a specimen figured by Krönlein the head of the humerus, after fracture of the anatomical neck, has been completely reversed and lies wedged between the tuberosities.

Bloodvessels. Injury of a large bloodvessel adjoining a dislocated joint (the dislocation not being compound) is a comparatively rare accident, and one that depends either upon the close relations of the vessels

¹ Birkett: *Medico-Chirurgical Transactions*, 1869, vol. lii. p. 133. Moxon: *Medical Times and Gazette*, 1872, vol. i. p. 96.

² Riedel: *Beilage zum Centralb. für Chir.*, 1885, p. 92.

³ Thamhayn: *Schmidt's Jahrbuch*, 1868, vol. cxl.

and the bones, as at the shoulder and knee, or upon violence so great as to displace the bone to a greater distance than usual, or in an unwonted direction.

In most of the recorded cases the dislocation has been of the shoulder, inward and forward, and the lesion has consisted either in the rupture of a large arterial branch, the anterior circumflex or the subscapular, at or near its origin, or in such stretching of the axillary artery that its inner and middle coats have been torn across, the outer one remaining undivided, or, more rarely, in rupture of the main vein. The injury may result in the immediate formation of a traumatic aneurism or in the gradual formation of an encysted one, or in gangrene of the distal portion of the limb. In some of the recorded cases it is not possible to determine whether the injury to the vessel was the immediate result of the dislocation or of the efforts to reduce it.

The symptoms vary greatly, but, except at the shoulder, are not likely to leave any doubt concerning the nature and details of the injury. Injury to the inner and middle coats alone may in some cases be recognized by the immediate cessation of the brachial and radial pulse, in others only by the subsequent gradual formation of an aneurism. In other cases the prompt appearance and rapid growth of a fluctuating swelling in the axilla, perhaps accompanied by extensive ecchymosis and alarming symptoms of collapse or shock, sufficiently prove the fact of an internal hemorrhage; but the source of the bleeding, whether from an arterial branch, the main artery, or the vein, may remain in doubt, for the radial pulse may persist even when the hemorrhage comes directly from the axillary artery. The subject will be more fully discussed in Chapter XXXIV.

In a case observed by Körte,¹ this complication accompanied a dislocation of the shoulder caused by a blow received upon its upper surface while the arm was abducted; the dislocation was spontaneously reduced before the arrival of the surgeon, and probably the displacement was only slight. An aneurism formed, and was opened under the impression that it was an enlarged lymphatic gland. The autopsy indicated that the lesion was avulsion of the anterior circumflex artery at its origin, and showed also that the inner and middle coats of the axillary artery were torn transversely at a higher point, but the calibre of the vessel was not thereby obstructed.

The following cases illustrate other varieties:

Mr. J. W. Turner² reported two cases of rupture of the popliteal artery complicating dislocation of the knee. In the first a man, twenty-four years old, fell from a height of thirty feet and sustained a compound dislocation of the knee, the condyles of the femur projecting through the integument of the ham. The limb was immediately amputated, and the two inner coats of the popliteal artery were found to be ruptured, the outer coat remaining untornd.

In the second case a middle-aged woman fell while carrying a heavy burden on her back. There was found a dislocation of the knee together with a wound in the ham, through which, it was said, the con-

¹ Körte: *Archiv für klinische Chirurgie*, 1882, p. 636.

² Turner: *Transactions of the Edinburgh Medico-Chirurgical Society*, vol. iii. p. 308.

dyles of the femur had projected. There was no bleeding; the limb became greatly swollen, and the patient died on the tenth day. The artery and vein were found to have been torn completely across.

Dr. M. Goldsmith¹ reported the case of a man, forty years old, who suffered a dislocation of the left femur; "the head of the bone being thrust under Poupart's ligament overrode the margin of the pelvis in such a manner as to underlie the femoral artery; it remained unreduced for two months, when he came under observation with a diffused swelling occupying the groin, filling the iliac fossa, and extending to the middle of the thigh; feeble pulsation; tumor appeared a few days after the accident; pain severe; diagnosis, aneurism; treatment, ligature of the common iliac artery; death on fifth day." The femoral and external iliac arteries were perforated to the extent of an inch on the postero-external aspect; the head of the femur lay in the cavity of the aneurism.

Cases also have been reported of rupture of the anterior and posterior tibial arteries in dislocation of the ankle; and Sédillot² published one in which the brachial artery was ruptured at the elbow by being stretched over the end of the humerus in a dislocation of the radius and ulna backward.

Nerves. Injuries of the nerves may be demonstrated by direct examination or inferred from the symptoms. Examples of the former are uncommon, and in some of the latter it may remain in doubt whether the nerves were injured by the displacement of the bone, or by the efforts to reduce the dislocation, or by the independent action of the violence upon them. It is asserted³ that a fall upon the hand or shoulder, without lesion of the skeleton, is competent to cause palsy of the arm; hence, it is not always to be inferred that a palsy following a dislocation has been caused by the pressure of the head of the bone upon the nerves, and this is especially true of those cases in which a blow has been received directly upon the shoulder, and the deltoid alone is paralyzed.

The injury may be a complete rupture or laceration of one or more nerve trunks, or a contusion with extravasation of blood about the nerve and amid its fibres, or a neuritis originating in an injury of some lesser nerve and extending thence to the main trunk, or an inflammatory process extending to the nerve and causing its compression by newly formed connective tissue, or simple compression by the displaced bone.

Rupture or laceration of the nerve is caused by violent pressure against it of the displaced end of the bone, and, in the case at least of the larger trunks, it appears commonly to be associated with extensive laceration of the other soft parts, including even the overlying skin. Contusion of the nerve may be produced in the same manner, and then represents a less degree of the same injury, or by compression of the nerve between the displaced bone and an adjoining portion of the skeleton, as between the head of the humerus and the wall of the thorax.

¹ Goldsmith: *American Journal of the Medical Sciences*, July, 1860, p. 30; abstract from the *Louisville Medical Journal*, February, 1860.

² Sédillot: *Dict. Encyclopédique*, art. *Luxations*, p. 261.

³ Weir Mitchell: *Injuries of Nerves*, p. 99.

The symptoms vary with the character of the injury; laceration is immediately followed by motor paralysis and loss of sensation in the region supplied by the nerve, which are permanent or persist until the integrity of the nerve is restored; in other forms of injury there are varying degrees of paralysis and loss of sensation, numbness, pain, alteration of local nutrition, and other symptoms of neuritis, limited at first to the nerve directly injured, and afterward perhaps extending to others. In many of the recorded cases a cure has followed the systematic use of electricity.

The statistics of the Friedrich's Hospital collected by Holm¹ show that of 112 cases of dislocation of the shoulder there was general paralysis of the arm in 7, and paralysis of the deltoid alone in 10. In one of them all the muscles supplied by the median nerve were paralyzed, while those supplied by the musculo-spiral were unaffected. This is a very much larger proportion than I have observed.

The recorded cases of rupture of a nerve verified by direct examination are few; the following are examples of different forms:

Hilton² examined the body of a man who died thirteen weeks after having received a dislocation of the shoulder into the axilla; the deltoid was much atrophied, the circumflex nerve was small and was "distinctly lacerated, but its actual condition was changed by some strong cellular adhesions, fixing it with the radio-spiral nerve and the axillary artery to the inner surface of the subscapularis muscle." Bouley³ presented to the Société Anatomique a specimen of complete dislocation outward of both bones of the forearm at the elbow, with fracture of the outer condyle of the humerus, caused by a fall upon the elbow from a height of twenty-four feet. The patient refused amputation and died twenty days after the receipt of the injury. "The lateral ligaments of the elbow were entirely ruptured, both bones of the forearm were situated external to the lower end of the humerus, and the ulnar nerve was lacerated at the level of the articular surface."

Holl⁴ found in the dissecting-room a cadaver with a marked deformity of the elbow, and on examination it appeared that the individual had suffered fracture of the upper end of the ulna and dislocation of the head of the radius upward and inward, and that the ulna artery and ulnar and median nerves had been completely divided and had not reunited.

Müller,⁵ seven months after dislocation of the shoulder which had been easily reduced and which had been followed by gradual paralysis of motion and sensation in the arm, found, by an axillary incision, the artery and main nerves tightly compressed by a cicatricial band about a quarter of an inch wide. On division of the band pulsation at once reappeared in the brachial and radial arteries; sensation and muscular function reappeared gradually.

¹ Holm: Schmidt's Jahrbuch, vol. cxxi. p. 82.

² Hilton: Guy's Hospital Reports, 1847, vol. v. p. 93.

³ Bouley: Bull. de la Soc. Anatomique, 1837, p. 101.

⁴ Holl: Medicin. Jahrbuch, Wien, 1880, p. 151.

⁵ Müller: Centralb. für Chir., 1892, p. 611.

Of the cases that have been observed clinically the injury in most has been attributed to the reduction, as a consequence of too forcible traction, extreme abduction of the limb (arm), or to the presence of adhesions between the nerve and the parts with which it has been temporarily brought into contact. In some of these cases the correctness of this view cannot be questioned; in others the necessary data for an opinion are lacking.

A man¹ fifty-four years old was seized by the right arm and shaken so violently as to dislocate the humerus into the axilla, causing pain in the shoulder and instant loss of feeling and motion in the hand. Reduction on the third day. "Six weeks afterward the whole hand and lower side of the forearm were œdematous, and the former also hard and brawn-like, resisting pressure. The fingers were in the same state, and the whole hand was dark and congested, but not shiny or smooth. The joints from the wrist to the finger ends were sore, swollen, and very stiff. The whole palm was the seat of pretty severe burning, with no darting or other pain." Partial loss of touch and pain-sense in the median and radial distribution. The elbow motions were perfect, wrist flexion good, extension lost; flexion of the fingers good, extension and lateral motions lost from palsy of the extensors and interossei.

A soldier² fell from a tree, striking upon and dislocating his left shoulder; the dislocation was reduced within twenty-four hours, and, the previous pain and numbness disappearing, he remained well for four weeks, when the arm began to waste, with loss of power which became complete in a few months. Sensation was much less altered. At the close of a year there was only partial ability to flex the arm, and slight use of the flexors and extensors of the fingers. Marked atrophy; contraction of the pronators. Rapid relief and final cure were obtained by electricity.

A man³ twenty-five years old was admitted to the Hôtel-Dieu with an intracoracoid dislocation of the left shoulder, caused shortly before by a fall. Any motion communicated to the limb caused great pain and violent involuntary contraction of all its muscles. The next morning the dislocation was found to have become subglenoid, the limb was completely paralyzed, but without loss of sensation, and although communicated motion was still painful, it did not cause reflex contractions of the muscles. Reduction was readily effected with the aid of anæsthesia. The muscles of the shoulder reacted to the faradic current; those of the arm and forearm did not. The limb wasted rapidly; under electrical treatment an almost complete cure was obtained in about two years.

Krönlein⁴ quotes Hutchinson as having seen paralysis of the sciatic nerve follow an ischiatic dislocation of the femur; and Sir Astley Cooper⁵ quotes a case in which numbness of the limb accompanied the same injury. Cooper⁶ also quotes a case of suprapubic dislocation in

¹ Weir Mitchell: *Injuries of Nerves*, p. 103.

² Weir Mitchell: *Loc. cit.*, p. 101.

³ Duchenne: *De l'Électrisation localisée*, 2d ed., p. 179.

⁴ Krönlein: *Loc. cit.*, p. 34.

⁵ Cooper: *Loc. cit.*, p. 67.

⁶ Cooper: *Loc. cit.*, p. 74.

which the pressure of the head of the femur upon the anterior crural nerve caused numbness of the thigh.

Viscera. Excluding the common implication of the spinal cord in dislocations of the vertebrae, there are few recorded cases of injury to parts lying within the body or neck by dislocated bones. Such injuries must, to a greater or less extent, accompany dislocation of the head of the femur through the floor of the acetabulum into the pelvis, and complete dislocation backward of the sternal end of the clavicle has in some cases been accompanied by symptoms indicating pressure on the trachea or œsophagus.

A case that is entirely unique, and interesting not only because of the distance to which the bone was displaced, but also because of the changes subsequently undergone by the bone, and of the ease with which the deformity was borne, is reported by Prochaska² and by Larrey,³ who had examined the specimen. A lad, sixteen or seventeen years old, dislocated his right humerus by a fall upon the abducted elbow, and the head of the bone was driven between the second and third ribs (Prochaska says the third rib was fractured) into the chest, stripping up the pleura, but not perforating it. All attempts to reduce it were unavailing, and the subsequent treatment was limited to venesection, warm baths, and antiphlogistic measures for the relief of urgent symptoms. The patient survived until the age of thirty-one (forty, Prochaska), and, although the arm remained abducted, gained his livelihood by woodchopping. At the autopsy the head of the humerus was found within the thorax, covered by the pleura, and its neck firmly placed between the second and third ribs. The head was so soft that it yielded to the slightest pressure of the finger; the articular cartilage and bony texture of all the portion that lay within the chest had entirely disappeared, leaving only a few membranous remains of the humerus, of which the greater part seemed to belong to the costal pleura. Prochaska describes it as "naked, soft, yielding to the softest pressure, presenting only a thin envelope, and almost empty within, since it had lost more than half of its internal bony substance."

Soft Parts and Integument (Compound Dislocations). Although instances of this complication have been recorded for almost every joint, they are yet of rare occurrence, and mainly restricted to the elbow, knee, ankle, and phalanges. Except in the latter case, they are commonly the result of extreme violence, and the wound of the skin is produced either by the direct action of this violence, or from within outward by the projecting end of the bone.

The complication in the case of the larger joints is very grave, because of the extent of the injury, which is usually great and marked by much laceration and bruising of the tissues, and also because of the special dangers due to the probable infection of the wound.

The treatment may require, in addition to the most rigorous antiseptic measures, the partial excision of the joint, because of the difficulty of otherwise providing efficient drainage of all the recesses and pouches of the synovial sac.

¹ Prochaska: *Disquisitio Anatomico-physiol. Org. Humani*. Wien, 1812, quoted by Malgaigne.

² Larrey: *Mém. de Chir. Militaire*, vol. ii. pp. 405-407.

Compound dislocations of the shoulder and hip are rare, those of the elbow and knee less so, and those of the smaller joints much more frequent.

REPAIR.

Only a few observations have been made of reduced dislocations undergoing, or that have undergone, repair. Clinically it is known that after a period of a few days or weeks marked by gradually diminishing tenderness and swelling, the joint can be freely used without pain, but that sometimes the range of motion remains limited for a much longer period, and that in some cases there is a marked tendency to recurrence of the dislocation. In a few cases, in which patients have died within a few days after having suffered a dislocation, the surrounding tissues have shown the remains of the extravasation of blood that had taken place amid them, and the rent in the capsule has either been occupied by a clot or has been empty and without evidence of repair. It is to be presumed, however, that repair usually takes place after dislocation, as after other subcutaneous injuries, without suppuration or even much inflammatory reaction, that the ruptured capsule reunites or that the gap in it is filled by condensation and adhesion of the adjoining connective tissue, that the lacerated muscles and ligaments are repaired in like manner, and that these cicatrices pursue the evolution common to their class.

This process may, however, be disturbed by various complications. If the injury has been exceptionally severe, if the bone has been widely displaced, and the surrounding tissues much lacerated, if the efforts to reduce have been violent and long continued, if the joint has not been properly immobilized, if passive motion has been injudiciously begun and maintained, or, finally, if the general condition of the patient is unfavorable for repair, the inflammatory reaction may become excessive, and even end in suppuration and pyæmia. If it stops short of this disastrous result, it may yet lead to partial or complete ankylosis through the formation of adhesions between the opposed articular surfaces or the thickening and retraction of the capsule and peri-articular tissues. The older records contain numerous instances in which suppuration appears to have been caused by the efforts to reduce, but this accident has become much less common since the introduction of anæsthesia and the substitution of the so-called "mild" methods by manipulation for the forcible traction by pulleys which was formerly so much in vogue.

Fractures of apophyses, or portions of bone to which muscles or ligaments are attached, are repaired either by bony callus or by a fibrous band, the difference depending on the extent of the separation and the independent motion of the fragment. The fragment may be withdrawn to such a distance that the attached muscle or muscles permanently cease to exercise any control over the main bone, which, in consequence, is exposed to frequent and easy recurrence of the dislocation.

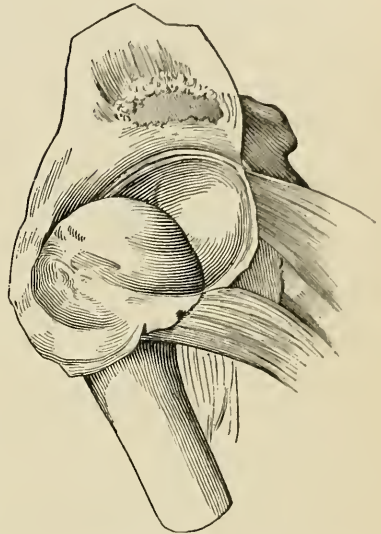
The same infirmity may result from defective repair of fracture of the rim of an orbicular cavity. Instances of the former variety are most common at the shoulder-joint, those of the latter are found at the

hip and shoulder. Another cause of the liability to recurrence at the shoulder—laxity of the capsule—has been indicated by Jössel,¹ who had the opportunity to examine four such cases after death; he found in all that the supraspinatus and infraspinatus muscles had been torn loose from their attachment to the greater tuberosity, had retracted behind the acromion, and had undergone atrophy and fatty degeneration. The relations of the tendons of these muscles with the articular capsule are so close that the rupture of the former involves also that of the latter, and the retraction of the former creates, by drawing back one side of the rent, a large gap in the upper part of the capsule opening into the subacromial bursa. In the process of cicatrization the front part of the capsule, that lying between its attachment to the humerus and the rent, becomes adherent at the edge of the rent to the under surface of the deltoid close by its attachment to the acromion, while the posterior lip of the rent, after retraction with the tendon, becomes permanently fixed at the posterior part of the acromion. The under surface of the acromion is thus left to fill the gap between the two lips, to form the upper limit of the articular cavity, and to be in direct contact with the head of the humerus. In none of Jössel's four cases was the normal communication between the cavity of the joint and the subscapular bursa found to be enlarged; in one the subcoracoid bursa communicated with the joint, and in one the tendon of the long head of the biceps was ruptured, and its torn end had become fixed in the bicipital groove. In two of the cases a small defect with smooth edges was found in the capsule below the tendon of the subscapularis, and in the others the capsule appeared thinned at the same point. Apparently this indicated the place at which the head of the humerus escaped through the capsule at the time of the first dislocation.

The cavity of the joint was greatly enlarged by the changes in the capsule; in the first its capacity was 90 cubic centimetres, as against 28 in a normal joint, and its length along the upper portion was 10 centimetres instead of the normal $3\frac{3}{4}$.

This condition of the capsule, aided by the withdrawal of the control and support normally supplied by the supraspinatus and infraspinatus muscles, seems entirely adequate to explain the easy recurrence of the dislocation, and the recent cases of relief by operative

FIG. 253.



Recurrent or habitual dislocation of the shoulder, showing the opening into the subacromial bursa. (JÖSSEL.)

¹ Jössel: Deutsche Zeitschrift für Chirurgie, 1880, vol. xiii. p. 167.

shortening of the anterior portion of the capsule are corroborative of the opinion.

Gangrene of the limb may ensue upon the rupture of the principal vessels, or even upon extensive laceration and violent inflammatory reaction ; and *paralysis* of one or several muscles may manifest itself immediately or only after the limb is again brought into use, the result of injury to nerve trunks or of contusion of the muscle itself, or of compression of the nerve by a cicatricial band as in Müller's case quoted above, p. 419.

CHAPTER XXX.

THE PATHOLOGY OF UNREDUCED ("ANCIENT," "INVETERATE") DISLOCATIONS.

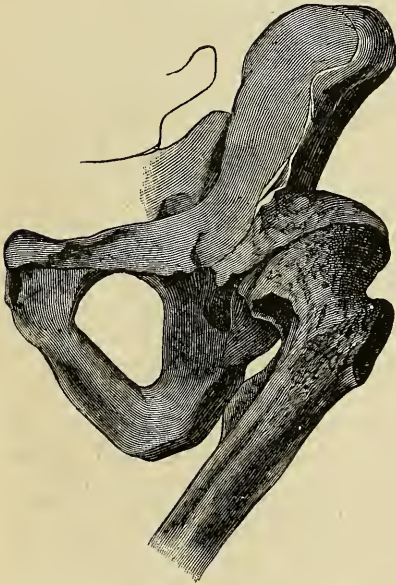
THE changes that take place about joints that have long remained dislocated are well understood, through direct observations of many specimens in man and through experiment upon animals. These changes are partly the direct result of purely inflammatory processes excited by the traumatism and the changed relations of the parts, partly that of disease, and partly that of a seeming effort of nature to create a new and serviceable joint. The changes consist, in general terms, in the condensation and thickening of connective tissue about the displaced bone in such a manner as to protect it against further displacement, and in the change of the bones at the new points of contact partly by absorption and partly by the formation of new bony outgrowths through continued slight irritation of the bone itself, the periosteum, and the adjoining fibrous and ligamental tissues. The irritation which leads to these changes is furnished by motion, use, of the limbs; the most striking examples are found at the shoulder and the hip, and these will be used as the basis of the following description.

The first changes, in point of time, are those in the bruised and torn soft parts amid which the end of the bone has lodged after its escape through the rent in the capsule. The loose connective tissue lying about the vessels, nerves, and muscular bundles, bruised and pressed back by the head of the bone and infiltrated with extravasated blood, reacts in the usual manner under the traumatism by becoming the seat of an exudation and by multiplication of its cellular elements. The latter follow their natural evolution into fibrous tissue, and thus is formed about the bone a continuous fibrous envelope enclosing a cavity within which the end of the bone lies, more or less free, and continuous structurally on its outside with the adjoining tissues, some of which—vessels, nerves, and muscular fibres—may be firmly imbedded in it. Its inner surface is smooth and lined with flat cells resembling those found on the surface of normal or accidental bursæ, and it is moistened by a small amount of liquid which, in some cases, closely resembles synovia. It seems probable that when real synovia is present it is furnished by portions of the original capsule which have remained adherent to the bone and have formed part of the new cavity. Indeed, the new cavity is usually only an enlargement of, or addition to, the original one, its connection with, or its entire independence of, the old one being determined by the character and extent of the rent in the capsule and the distance to which the head of the bone has passed through it; but the capsule may be torn away from the humerus, for example, so completely that it falls together behind it and its cavity is

obliterated by adhesion of the opposing surfaces or is shut off by union of the torn edges. The new capsule is so small and close and the bands formed between the bones by the condensation and increase of the surrounding tissues are so firm that motion is greatly restricted or wholly lost, and restoration of the original relations can be effected only after a division or laceration of those tissues far more extensive than that which accompanied the dislocation.

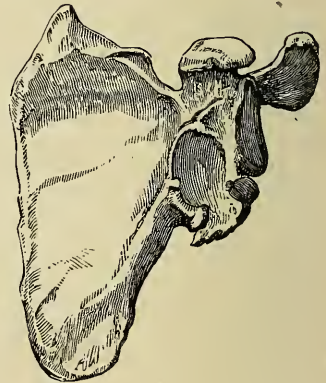
But while these changes in the soft parts tend permanently to fix the bone in its new position, other changes take place in the periosteum and the bone itself upon which the displaced articular end rests and moves, which, on the other hand, tend to make this new position a

FIG. 254.



Old supracotyloid dislocation of the femur, with very complete new acetabulum. From the collection at Bonn. (KRÖNLEIN.)

FIG. 255.



Scapula showing new socket found in an old unreduced subcoracoid dislocation. (COOPER.)

more suitable resting-place and to give it a form and character like those of the part it is to replace. Thus, a new cotyloid cavity may be formed upon the ilium, or a new glenoid cavity on the inner side of the scapula adjoining the old one. In this new formation of bone two processes may take part—production of bone by the periosteum, and ossification of the old ligaments and new fibrous tissue. The periosteum may produce bone either after it has been stripped up or while it is still in place. If, in the dislocation of the head of the bone, a portion of the rim of the corresponding articular cavity is broken off and pushed away, carrying with it a strip of periosteum torn from the adjoining surface, but preserving its connection with both pieces, or if the periosteum is stripped up by the attached capsule or a ligament, as

occurs so frequently at the elbow, this loosened strip forms on its side the limit of the new cavity, and produces on its under surface new bone which is continuous with the old and with the fragment of the rim, if such has been broken off; constituting a bridge between them.

If the periosteum is not stripped up, but the head of the bone escapes entirely from the cavity and comes to rest upon the outside of a layer of periosteum still adherent to its bone, this periosteum, irritated by the pressure and movements, produces new bone between itself and the old, and this production is greatest in the zone just around the point of greatest pressure. The portion of periosteum directly pressed upon disappears under the pressure, leaving a bare surface of bone in contact with the displaced head, or becomes fibrous or fibro-cartilaginous in structure; while in the immediately adjoining portion the osteogenetic property is called into play and a ridge of bone is built up around the

FIG. 256.



Backward dislocation of elbow. Bony fusion between ulna and humerus.

central denuded area. This may be a sharply defined rim rising to a considerable height and closely resembling that for which it is a substitute, or it may be a mass of irregular height and outline, having little or no resemblance to either the glenoid or cotyloid cavity.

The details of this formation, as observed by Baiardi¹ at the hip in animals, consist, first, in the appearance of a circular cartilaginous wall whose free border is continuous with the new-formed fibrous capsule, its base resting upon the ilium and its inner surface in contact with the head of the femur; its ossification (in rabbits) is complete by the thirtieth day, except along its concave surface, where it remains soft, shading off toward the centre of the new acetabulum into a whitish, cartilaginous like tissue, which takes the place of the destroyed periosteum. On its free border it has the structure of fibro-cartilage; on the concave surface it closely approximates that of hyaline articular car-

¹ Baiardi: *Arch. per le Scienze mediche*, 1880, vol. iv., quoted by Krönlein.

tilage. At the very centre the underlying bone is left bare or is covered by fibrous tissue and fibro-cartilage, and becomes denser in structure. Grinewetsky,¹ who experimented on dogs, says he never found a lining of periosteum or cartilage inside the new acetabulum; the bone was always sclerosed. He also notes the absence of endothelium on the inner surface of the new capsule.

The ossification may pass beyond the usual limits and include portions of the capsule,² forming bony stalactites, or even a complete bony case enveloping, and perhaps united with, the head of the bone;³ and in a specimen presented by Moreau,⁴ a dislocation of the femur into the obturator foramen, the membrane filling the foramen had been transformed into a bony plate throughout, except in a strip along its anterior margin.

Some of these experimental observations have been repeated upon specimens of ancient dislocations in man, in some of which the new cavity has been found to be lined with fibro-cartilage,⁵ in others with a granular fibroid tissue without apparent cartilage of incrustation.⁶

The displaced head shows changes varying in extent and consisting in loss of its cartilage, erosion of the bone in places and its increase in others, and occasionally in profound changes of structure throughout. Thus in the case just referred to, reported by Duguet, a dislocation inward of the shoulder of six months' standing, the head of the humerus was worn away behind at the point where it rested against the rim of the glenoid cavity, which also had in great part disappeared; its anterior portion had preserved its cartilage at almost all points, while its posterior portion had none, it being there replaced by rather tight, short fibrous bands uniting the head to the old glenoid cavity. In a specimen presented by Walsh⁷ to the Royal Surgical Society of Ireland, April 25, 1840, of an old dislocation of the shoulder forward, the subscapularis muscle was raised from the scapula by the head of the humerus, the new glenoid cavity was covered by fibro-cartilage, the synovial sac was complete, and the cartilage of the humerus perfect. Old backward dislocations of the elbow (*q. v.*) often show a very complete new radio-humeral joint.

The empty glenoid or cotyloid cavity diminishes gradually in size either by absorption of that portion against which the head of the bone rests or by a general atrophy, presumably due to its disuse, similar to that observed in the alveolar process after removal of the teeth, and its cavity fills up with fibrous tissue that springs from and replaces its lining cartilage. The glenoid cavity has in some cases been still further rendered unfit for use and inaccessible by union with the outer portion of the original capsule, when that has been drawn across its face as the humerus was displaced inward. And yet, occasionally the acetabulum

¹ Grinewetsky: Centralblatt für Chirurgie, 1839, p. 279.

² Thore: Bull. de la Soc. Anatomique, 1839, p. 33.

³ Cooper: Loc. cit., p. 50; and Cruveilhier: Anat. pathol., vol. i. p. 425.

⁴ Moreau: Mém. de l'Acad. royale de Chirurgie, 1769, vol. ii. p. 153.

⁵ Lepine and Désormeaux: Bull. de la Soc. Anat., 1844, p. 167.

⁶ Duguet: Bull. de la Soc. Anat., 1863, p. 144.

⁷ Walsh: Gazette des Hôpitaux, 1840, p. 330.

has remained empty, and its cartilage unchanged for many years (Drehmann).¹

When the use made of the limb is very slight and the head of the bone is immovably fixed in its new position, the development of articular characteristics is slighter and the bone may even diminish notably in size or consistency, as in the case quoted on page 421, in which the head of the humerus passed into the chest and remained fixed there. This atrophy of disused parts is a general rule, and although observed in bone is more marked in other tissues whose nutritive changes and functional activity are greater. In accordance with this general law the muscles which are rendered inactive by the greater or less fixation of the dislocated bone diminish in size, and if their inactivity is complete, or even nearly so, their fibres undergo an actual degeneration and their fibrous tissue predominates to such an extent that they are hardly more than ligaments. The bone, too, is similarly affected throughout its entire length; it becomes smaller, or, if the dislocation has occurred during youth, before development is complete, it fails to develop to the same extent as its fellow on the opposite side, and even its normal curves disappear.

These facts show both the danger and the futility of attempts to reduce dislocations that have long existed; they show that reduction can be accomplished only at the cost of lacerations far more extensive than those involved in the original injury, that among these lacerations may be included rupture of important vessels or nerves that have become adherent to or included in the fibrous bands of new formation, and that even if the bone can be successfully liberated from its attachments and brought back to the cavity from which it was displaced the latter may have become entirely unfit for its reception and for a resumption of its own original functions.

Important changes in the condition of the limb may be caused by pressure upon the bloodvessels or nerves by the displaced bone or by injury done them during attempts at reduction. Instances of the latter are given in Chapter XXXIV.

Persistent œdema, resulting in a condition resembling elephantiasis, was observed by Bartels² in a patient whose shoulder had been dislocated for more than a year. There was also rigidity of the fingers in a position indicating ulnar paralysis, which was relieved by increasing the mobility of the shoulder, but the œdema persisted.

¹ Drehmann: Beiträge zur klin. Chir., 1897, vol. xvii.

² Bartels: Arch. für klin. Chir., 1874, vol. xvi. p. 638.

CHAPTER XXXI.

SYMPTOMS AND DIAGNOSIS.

THE symptoms of a dislocation—those changes in the form, functions, and sensibility of the part by which the presence of a dislocation is recognized—are classed as *objective* and *subjective* or *rational*. The former, which alone are deemed demonstrative, are those which can be recognized by the surgeon on examination; the latter are those for his knowledge of which he must depend, to a greater or less extent, upon the statements of the patient.

The examination of the patient should always be conducted systematically, with the view to learn not merely the existence of the dislocation, but also such details and complications as may be present and may affect the treatment and prognosis; and it should include an examination of the condition of such bloodvessels and nerves as may have been injured at the same time, in order that such injuries, if their later consequences should become manifest, may not be attributed to the treatment. If swelling, a large amount of subcutaneous fat, or pain should prevent a satisfactory examination, anæsthesia should be employed. The character and direction of the force that produced the dislocation should be learned, and also, if possible, the position of the limb at the moment of its dislocation, and whether a “consecutive” has been substituted for a “primary” displacement, or, as evidence of the latter fact, whether one fixed position of the limb has been substituted for another. In doubtful cases the uninjured limb should be used for comparison, and the question should be asked whether or not the suspected joint has been previously the seat of disease or injury the consequences of which may affect the conclusions to be drawn from the examination. The essential point in the examination is to determine the position of the end of the bone, its relations to that one from which it is thought to have been violently separated, and the best evidence of this fact is furnished by feeling the end of the bone with the fingers, by tracing its outline, by feeling it move when the lower part of the limb is moved.

Objective Signs.

Deformity. Beside the attitude of the patient or of the limb, which is often strikingly characteristic, the aspect of the region of the affected joint is changed by the inflammatory swelling, which may appear promptly or tardily and be accompanied by ecchymosis and by alterations in the depth or position of the fold of its flexure and in its normal depressions and prominences. The swelling varies with the length of

time that has elapsed since the injury was received, increasing for a day or two, remaining stationary for a variable time, and then diminishing; in old cases the region is atrophied. If the dislocation has been caused by external violence acting directly upon the region of the joint, the swelling is increased by the effects of the contusion, and ecchymoses appear more promptly than in other cases.

The position, with reference to each other, of the articular surfaces or ends which constitute the joint can often be determined by palpation, and this furnishes the most exact and positive evidence of the character of the injury. In joints that are not thickly overlain by soft parts or masked by swelling or extravasated blood, this position can be readily made out, as at the knee, fingers, elbow, or even the shoulder; at the hip it is easy in some dislocations—*e. g.*, suprapubic—to recognize the head of the femur, in others it is much more difficult.

If the head of the bone cannot be felt, its position (if there is no fracture) can be determined from that of its shaft and recognizable prominences or apophyses. Thus, if the great trochanter can be recognized, the position of the head of the femur can be readily inferred by

FIG. 257.

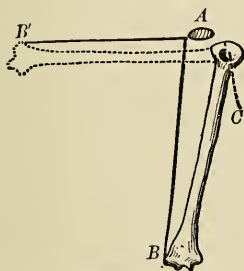


Diagram to show the effect of position upon the apparent length of the arm in dislocation of the shoulder. A, acromion; B, lower end of humerus; C, head of humerus.

FIG. 258.

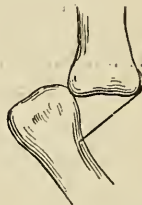

Diagram to show the action of a ligament in limiting the range of motion in a dislocation.

prolonging from it in imagination the neck of the femur in the line indicated by the position of the shaft. In like manner prolongation upward of the line of the lower portion of the humerus indicates the position of the head of the bone, and if it passes to the inner side of the acromion the shoulder must be dislocated or the bone broken.

The continuity of the supposed head with the shaft is determined by recognizing that it participates in slight movements communicated to the lower segment of the limb. By prolonged firm pressure with the fingers an inflammatory swelling may sometimes be pushed aside and the bone distinctly felt.

The limb may appear to be, or may actually be, shortened or lengthened, but this sign is not of so much value as it is in cases of fracture, both because it varies greatly with varying positions of the limbs and because the limbs cannot always be placed symmetrically. The reason why the length of the measured distance varies in different positions of the limb can be made clear by taking an example, as the shoulder.

Here the distance usually measured is that from the edge of the acromion to the external epicondyle of the humerus. Now, this distance diminishes as the arm is abducted, for (Fig. 257) when the arm hangs by the side, the line AB is almost exactly equal to CB plus the distance that C lies below the level of A ; while, on the other hand, when the arm is abducted the distance AB' is equal to CB minus the distance of C beyond the line of A .

The methods of measuring and the precautions to be taken are the same as in the case of fracture and have been elsewhere considered; and the possibility of the previous existence of asymmetry of the limbs, of a difference in their length, has also been described. (Fractures, p. 49.)

Loss of Mobility. In almost every dislocation there is a position which is characteristic of it and which the limb tends spontaneously to assume and retain, even under anæsthesia. This position depends rather upon the tenseness of ligaments and untorn portions of the capsule than upon the muscles, although the latter by being already overstretched may aid in limiting motion or change of position in certain directions. The head of the bone takes up a new position at some distance from its normal one and there establishes a new centre of motion for the limb; consequently the ligaments on the side opposite that toward which the head has been displaced are put upon the stretch if the attempt is made to move the lower part of the bone in the same direction, and, unless torn, fix it at an angle with the other bone to which they are attached (Fig. 258). The bone can be moved toward the attachment of the untorn ligament but not further away from it.

Since the limitation of motion has its principal cause in the non-muscular structures, it cannot be entirely removed by anæsthesia, but such additional limitation as may be due to contraction of the muscles excited by the fear of pain can be thus removed, and whenever the fixity of a limb is used as an element in making the diagnosis the part taken by the muscles in its production should be determined. The diagnostic formula sometimes given that abnormal fixation is characteristic of dislocations, and abnormal mobility of fractures, is a partial statement that may be misleading, for in fracture, or even in contusion, near a joint complete fixation may be effected by the muscles, and in dislocation with extensive laceration of the capsule and ligaments the range of motion may be very wide, and in all it is generally free in some direction.

A therapeutical fact that may often be of importance is to be deduced from the fact that the dislocation must, in most cases, have taken place when the limb was in one of the positions in which, while still dislocated, it is shortened—that is, one in which the distance from its normal opposing articular surface to its lower end is less than that between the corresponding points of the opposite limb in a similar position; by replacing the limb in the position it occupied when the dislocation took place the first step in reduction, that of bringing the head of the bone opposite the rent in the capsule through which it has escaped and relaxing the soft parts, is taken.

Crepitus. A sound or sensation somewhat resembling the crepitus of a fracture is occasionally perceived while a dislocated limb is being handled. It may be the real crepitus of a fracture accompanying the dislocation, or merely the grating of the head of the bone against the edge of the periosteum of the other, or against a fibrous band, or even (it is said) against a blood-clot.

Subjective Symptoms.

Pain. The occurrence of the dislocation is immediately followed by sharp pain in the region of the joint, which may gradually diminish or may continue for some time with unabated severity. In the former case it is presumably due in great part to the laceration and bruising of the tissues; in the latter to the tension of those parts that have not yielded to the strain. In the former case the pain is not materially relieved by reduction; in the latter it immediately disappears when the bone is restored to its place. In addition to this pain about the joint, there may also be tingling or numbness through the limb in consequence of pressure upon the large nerve trunks.

Loss of Function. Inability to use the limb is ordinarily complete, and is due partly to the fixation created by the changed relations of the bones and partly to the pain which movement causes. There is nothing characteristic in this symptom, since it is present also after fracture and even after a severe contusion. Furthermore, it is sometimes absent, or present in so slight a degree that the patient continues to use the limb, conscious only of some slight pain and of a certain inconvenience or lack of freedom in its use.

History. The history of the case includes the character of the violence, the position of the limb at the moment of the accident, possibly the perception by the patient at that moment of a sound, of the sensation of displacement, and the history of any previous injury to or disease of the part or of the opposite limb so far as it may affect its use for the purpose of comparison. It is well to obtain this history before proceeding to the direct examination of the limb.

There can be no uncertainty as to the main fact if the relations to each other of the articular ends can be made out, and the surgeon should not rest content with less than this when it can possibly be attained. In every doubtful case an anæsthetic should be employed, and among the doubtful cases are those in which there is the possible coexistence of a fracture either of a portion of the articular surface or of the entire breadth of the bone near the joint. The latter form of fracture is itself the one with which a dislocation is most frequently confounded; either may be mistaken for the other; and in any such case, every effort should be made to determine the exact positions occupied by the ends of the bones.

In dislocations complicated by fracture of portions of the articular surface or of tuberosities to which muscles are attached, the coexistence of the fracture is often incapable of demonstration and can only be suspected because of the facility with which the dislocation recurs after reduction.

Such complications as injury of a main bloodvessel or nerve will be readily recognized by attention to the characteristic symptoms to which they give rise.

Finally, it should be remembered that the most experienced and careful surgeons have sometimes remained in doubt, or have denied the existence of a dislocation which the subsequent course of the case has shown to have been present, and the charity which the critic may himself so soon need should be cordially extended to others.

CHAPTER XXXII.

COURSE AND PROGNOSIS.

IF the dislocation is promptly reduced and no complications are present, the course is simple and the prognosis favorable. The swelling and pain subside, and the patient is soon able again to use the limb, although usually with some limitation of the range of motion and with pain when these limits are reached. This slight disability may persist for weeks, or even months, especially in those who are constitutionally prone to arthritic complications. I have known a robust, thoroughly healthy man to dislocate his shoulder, the dislocation being so slight that it was immediately reduced by accidental traction on the arm and he was able to use the limb without a day's intermission; and yet, three months after the accident he was unable to lift the elbow in abduction to the level of the shoulder, and could not carry his hand to his hip-pocket without causing considerable pain.

If the inflammatory reaction is more severe, the pain and swelling are greater and more prolonged, and the limitation of movement may become permanent through the formation of adhesions or the condensation and thickening of the peri-articular soft parts. It is very exceptional for this process to go on to suppuration.

If the disarticulation is compound, it may follow either one of two courses; either it is transformed into a simple one by the prompt union of the wound, or suppuration ensues and the patient is exposed to all the accidents of a deep suppurating wound, rendered all the more extensive by its continuity with the interior of the joint. In the latter case the result is certain to be marked by much functional disability, perhaps by total loss of mobility in the joint.

Other complications add to the otherwise uneventful course of a simple dislocation the features peculiar to themselves; thus, injury to a nerve may be followed by temporary or permanent paralysis of the muscles or loss of sensation in the region supplied by it, or by a long train of symptoms indicating an ascending neuritis. And injury to a main artery may be followed by gangrene of the limb, or by the formation of a traumatic or encysted aneurism. The coexistence of a fracture of the neck of the bone creates a condition which for a time predominates over the dislocation; if the latter is promptly reduced the case follows essentially the course of a fracture; if it cannot be at once reduced the course at first is still in the main that of a fracture, and subsequently that of an old dislocation.

The fracture of a portion of the articular edge, or of an apophysis, is habitually followed by no symptoms peculiar to itself, except in some cases a marked tendency to recurrence of the dislocation after its reduction, and this tendency may persist throughout life.

Excluding these complications, the prognosis in a simple dislocation

of a limb, *quoad vitam*, is eminently favorable; the prognosis with regard to the restoration of form and functions depends upon the reducibleness of the dislocation, and this is affected by the character of the joint and of the injury, by complications, and by the time that has elapsed since the injury was received.

The principal obstacle to the reduction of a dislocation commonly lies in the tension of the untorn portion of the capsule and ligaments, but special difficulties may arise from the relations of the displaced bone to the capsule and to various muscles and tendons. The capsule may slip in between the head of the bone and the cavity it has left, and create an obstacle (by its interposition) that cannot be removed by manipulation or traction of the limb, or its torn edge may be drawn tightly about the neck of the bone, as is common at the metacarpophalangeal joint. The cases in which the former happens are those in which the capsule is freely torn at or near its attachment to the humerus or femur, and in which the head of the bone is displaced entirely to the outside of the capsule.

The greater the length of time since the occurrence of the dislocation, the greater will be the difficulty of reduction; and after the lapse of a certain length of time, which is different in different cases, reduction becomes impossible. The cause of this difficulty has been described in Chapter XXX.

The period at which a dislocation is to be deemed unfit for reduction cannot be positively stated; it varies with different joints and different cases. Speaking generally, it is about two months for the larger joints, but it is not prudent to assume that any dislocation which has remained unreduced for a shorter period than two months is reducible, or that every one that is older is, therefore, irreducible; for in the former case we may be led to apply an amount of force that will prove disastrous and in the latter disabilities that are amenable to treatment may be left unrelieved. A better guide is to be found in an examination directed to ascertaining the changes produced in the parts by the original injury or the disuse, and in careful, judicious attempts to make reduction. The object of these attempts should not be to reduce the dislocation at any cost, but to reduce it only if the reduction can be accomplished by moderate force and without grave lacerations. And, indeed, I am convinced that in a doubtful case it is better to expose the bone by incision, and divide the obstructing tissues with the knife, rather than blindly to rupture them by the application of a force whose action cannot be intelligently directed, and whose effects cannot be certainly foreseen and controlled. That the warning is still needed is shown by the recent (1897) death of a patient in the New York Hospital after an attempt to reduce a dislocation of the shoulder of six weeks' standing by traction and manipulation which ruptured the axillary vein and broke the third, fourth, and fifth ribs.

Encouragement to attempt reduction even when the dislocation has remained unreduced for a period much longer than that of two months above mentioned is furnished by not a few recorded cases in which it has been completely successful; instances will be given in the following chapter.

CHAPTER XXXIII.

TREATMENT.

Spontaneous Reduction—Obstacles to Reduction—Anæsthesia—Methods of Reduction—Old Dislocations—After-treatment—Habitual Dislocation.

As a rule, to which there can be very few exceptions, reduction of a dislocation should be attempted at the earliest opportunity. The possible exceptions are cases in which the inflammatory reaction is already very great, and in which it may be anticipated that the additional violence inflicted during reduction would dangerously increase it. But even in such cases it would be well to make gentle efforts to reduce under ether, and to postpone the reduction only if these efforts proved unavailing.

Spontaneous reduction is the term applied to that which takes place without the intentional intervention of any external force. It may take place while the patient is asleep, through the action of the attached muscles or through some chance violence, or by a fall or a sudden movement.

Spontaneous reduction, without the aid of external force, has followed shortly after attempts to reduce which have been unsuccessful but which may be thought to have made spontaneous reduction possible by rupture of adhesions, or laceration of the tissues, or fatigue of the muscles. This variety was termed *consecutive reduction* by Lèveillé, and the term was adopted by Malgaigne, who applied it both to cases in which spontaneous reduction takes place after complete failure of the efforts to reduce and also to those in which an incomplete reduction spontaneously becomes complete or is gradually made complete by prolonged action of some force applied by the surgeon—such as pressure.

The **obstacles** to the reduction of recent uncomplicated dislocations arise from inflammatory swelling of the soft parts, muscular contraction excited by pain or the fear of pain, the inextensibility of untorn portions of the capsule or ligaments of the joints, the interposition of portions of the capsule between the head of the bone and its cavity, and the size and position of the rent in the capsule. Not all of these are present in every case, and they vary in importance. For a long time the muscles were deemed the most important, but observations and experiments upon the cadaver carried on at about the same time by several different persons—Gunn¹ in 1851, Gellé² and Bigelow³ in 1861, Streubel⁴ in 1862, and Busch⁵ in 1863—fixed the attention of

¹ Gunn: *Peninsular Journal of Medicine*, July, 1855, p. 27.

² Gellé: *Archives générales de Méd.*, April and May, 1861.

³ Bigelow: *The Hip*.

⁴ Streubel: *Vierteljahreschrift für prakt. Heilkunde*, 1862, vol. ii. p. 59.

⁵ Busch: *Arch. für klin. Chirurgie*, 1863, p. 1.

surgeons upon the relations between the bone and the capsule, showed the nature and importance of the opposition commonly offered by the latter, and established the basis of treatment by systematic manipulation.

An account has already been given of the part played by the untorn portion of the capsule in determining the position assumed by the limb, a part so important that in "regular" dislocations (the term given by Bigelow to those in which the rent in the capsule is only partial and occupies a certain definite place in it) the muscles surrounding the joint may all be divided without thereby modifying the position of the limb or increasing its range of motion. At the hip the portion which remains untorn in all the typical forms is the anterior portion or Y-ligament; at the shoulder it is the thicker anterior portion forming the so-called coraco-humeral ligament. It is more correct to speak of the obstacle offered to reduction by this untorn portion of the capsule as an obstacle not to reduction in general, but only to reduction by certain methods, for when properly managed it offers no opposition,

and may possibly even be of assistance. It may be compared to the link of a sleeve-button, which in some positions absolutely prevents the button from passing back through the button-hole, while in other positions the passage is easy. Thus, if the head of the bone is lodged behind a projecting portion of the rim of the articulation, the ligament (Fig. 259) is tense, and traction in any direction which tends to separate its points of attachment is effectually opposed by it; but if these points are brought nearer together by moving the shaft of the bone in the direction indicated by the arrow, the ligament is thereby relaxed and its opposition to the movement

FIG. 259.

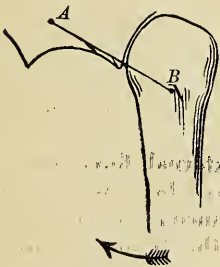

Diagram to illustrate the action of an untorn ligament or portion of capsule in opposing reduction.

of the head of the bone toward its cavity annulled. The position of the untorn portion of the capsule or ligament must be inferred from the posture of the limb and the directions in which motion is strongly opposed.

In "irregular" dislocations, those in which a characteristic attitude is not taken by the limb and in which the mobility is marked, these differences are due to extensive rupture of the capsule; and this, by removing the restraint imposed in other cases by the untorn portion of the capsule, makes reduction remarkably easy without much attention to the position in which the limb is held during the attempt.

In addition to this opposition to movement or traction in certain directions, the capsule may offer other obstacles arising from the form and position of its rent and from its own interposition between the head of the bone and the cavity in which the latter is to be replaced. The tearing of the capsule is caused by the pressure of the head upon it, consequently the rent is on the side toward which the head is displaced, and it may be longitudinal or transverse at either attachment, or present a combination of the two forms. In order that either of these obstacles

should be present, it is necessary that the head of the bone should have passed entirely through the rent—that, in other words, its displacement should be marked. As the rent, under these circumstances, is large enough to allow the head to pass out through it, it is large enough to allow it to be brought back through it if it is not made too narrow and its sides too tense by traction upon them. The effect of traction to narrow the opening can be demonstrated on the cadaver (Streubel, *loc. cit.*, p. 70) by producing a subcoracoid dislocation of the humerus or an obturator or ischiatic dislocation of the femur, exposing the region by removal of the muscles, and then making traction in the extended position. As the capsule is made tense the sides of the longitudinal part of the rent are drawn together, and their lateral separation, which alone would allow the globular head of the bone to pass back, is prevented. The narrowness of the gap is at once relieved by changing the position of the limb in such a manner as to bring the points of attachment of the capsule nearer together, and the transverse portion of the rent can be lengthened by rotating the limb.

Interposition of the capsule between the head and its cavity may exist whenever a secondary displacement has succeeded the primary one and the head has moved from the point at which it escaped along the outside of the capsule, but unless the capsule has been so torn as to form a flap adherent by its base to the edge of the articular cavity, this interposition can be readily avoided by moving the head of the bone back to the position of primary displacement. If, on the other hand, such a flap has formed and has fallen between the articular surfaces, there is no means, short of an operation that directly exposes it, of certainly getting it out of the way; it is attached to only one bone, and consequently cannot be acted upon by moving the other or changing the relations to each other of the two.

Swelling of the soft parts interferes with reduction by increasing the bulk of the limb within the fascia and thereby mechanically opposing changes in position. If it is very great it may be proper to defer reduction and combat the swelling by rest, cooling lotions, and pressure; it will usually subside so promptly that the loss of time thus incurred will not add appreciably to the difficulty of reduction when it is undertaken.

Contraction of the muscles, provoked by the traumatism or the fear of pain, opposes reduction by preventing the preliminary changes of position and neutralizing to a greater or less extent the traction that is made upon the limb. It may be overcome by gentle and long-continued traction, or forcibly, or by anæsthesia, or it may be avoided by taking the patient unawares or distracting his attention at the critical moment.

Anæsthesia is far from being needed in all cases, and as there are certain discomforts and even dangers in its use an attempt to reduce without its aid should usually be made. In New York, and, I think, in most of the large cities of the United States, ether is habitually used in preference to chloroform, and although chloroform is still used in Europe, the greater safety of ether is almost universally admitted. The collected cases of death under chloroform apparently proved the

correctness of an opinion quite generally held that its use in dislocations is especially dangerous, although no satisfactory explanation of the fact has yet been given. Of 101 fatal cases collected by Kappeler¹ between 1865 and 1876, 11 were dislocations, 20 amputations, and 11 operations upon the eyes; of 134 cases collected by Marchand,² 17 were dislocations, and 15 extractions of teeth. It is not always necessary to push the use of ether to complete anæsthetization, for the relaxation is sometimes sufficient during the stage of primary anæsthesia if care is taken not to excite the patient unduly. Gentle traction may be made upon the limb as the anæsthetization is begun, and its direction gradually changed or merged into the desired manœuvres as the muscles are felt to yield.

Methods of Reduction.

Since the nature of the obstacles to reduction has been more correctly understood the methods by forcible traction have been so far superseded by the methods of manipulation that they now possess only an historical interest. They consisted essentially in extension (traction), usually in the line of the dislocated limb, and counter-extension to bring the head of the bone down to the level of its cavity, followed then by measures of "coaptation" to force it into place. The traction was made through bands attached to the lower segment of the limb, and the force was exerted either directly by the hands of several assistants or indirectly through pulleys or screws. The amount of force sometimes exerted by these means can be inferred from the disastrous and even fatal consequences that occasionally ensued, including rupture not only of muscles and ligaments but also of the principal nerves and bloodvessels, and even complete avulsion of the limb. Suppuration of the joint, followed by the death of the patient, an accident which is now very rare, was formerly quite common, and in very many of the cases which recovered the record plainly shows the violence of the reaction and how narrowly the patients escaped with their lives. The occasion for the exertion of so much force arose from the faulty direction in which it was frequently applied, one in which the head of the bone could not be brought down to the level of the cavity without preliminary rupture of the opposing soft parts. The laceration caused by the dislocation was increased by the treatment, in order to enable the bone to follow a course which the ligaments, if untorn, would effectually bar. The method was directed against an obstacle, the resistance of the muscles, which was only one, and that not the chief, of those which opposed reduction, and was pursued in ignorance of the principal one; violence was used to overcome an obstacle which correct anatomical knowledge would have enabled the surgeon to avoid.

It must not be understood that this extreme violence was exerted in every case. In many the traction was made in a proper direction, or at least in one in which the already existing laceration of the capsule allowed the bone to be moved; hence, many dislocations were reduced

¹ Krönlein: *Loc. cit.*, p. 66.

² Marchand: *Des Accidents qui peuvent compliquer la Réduction des Luxations traumatiques*, 1875, p. 134.

with comparative facility, especially those of the shoulder and those of the hip in which consecutive displacement had not materially changed the posture of the limb, and in such cases traction was a proper means to overcome the opposition of the muscles. It was in such cases, too, that the methods of continuous moderate traction by India-rubber, weight and pulley, and suspension by the limb ("pendel-methode") were successfully employed, and will still be when it is desired to avoid recourse to the aid of anaesthesia.

As long ago as in the time of Hippocrates (fifth century B. C.) it had been known that some dislocations of the hip could be readily reduced by manipulation without the aid of violent traction, and Galen (second century A. D.) had pointed out that the head of the bone should be returned to its cavity along the route by which it had escaped, yet these suggestions remained unknown or unheeded and the practice of surgery, as regards dislocations, appears to have been not only ineffectual to relieve in a large proportion of cases, but also characterized by dense ignorance of their pathology and by the crudest notions of the mechanical effects of the means by which their reduction was attempted. Thus, among the methods in vogue, according to Petit, for the reduction of dislocations of the shoulder, at the beginning of the eighteenth century, were those of the door or ladder, the bar, and the *ambi*. In the former the patient was made to stand upon a stool, and the dislocated arm was brought over the top of a door or a rung of a ladder so that the latter occupied the axilla; then, while an assistant grasped the wrist and drew it directly downward, the stool was taken away and the patient left suspended until the surgeon pronounced the dislocation reduced or abandoned the attempt. In other cases the patient was lifted from the ground upon a bar supported on the shoulders of two men and passing under his axilla; or a large, strong man seized the patient's wrist, placed his own shoulder under the axilla, and then suddenly straightening himself raised the patient from the ground, at the same time drawing the arm down forcibly in front of himself. The *method of the heel*, so strongly recommended by Sir Astley Cooper, was also employed by them, and sometimes with success.

The *ambi*, an instrument invented by Hippocrates, was also in favor; it consisted of two oblong pieces of wood joined together at the end by a hinge, of which one was placed vertically against the side of the patient, the hinge pressed well into the axilla, the other under the arm in the position of horizontal abduction. The arm was then firmly secured to the latter piece and forcibly depressed.

As the defective mode of action of these methods became more generally recognized, traction by the hands of assistants or by pulleys or by other apparatus was substituted, but although this was an improvement upon its barbarous predecessors it was still employed blindly, and evidently was often ineffectual. There are indications in the older writings that the practice was not so wholly bad as the teaching, that here and there men were found who not only appreciated the importance of the direction in which traction should be made, but even occasionally reduced dislocations by manipulation alone, but the writer

who seems to have been the first to recognize the importance of the principle enunciated so long before by Galen of bringing back the head of the bone by the route along which it had escaped, and of the position to be given to the limb during the attempt, was Jean Louis Petit. His *Traité des Maladies des Os* was published in 1705; a second edition followed in 1723, and a third in 1741. He clearly pointed out the mechanical defects of the methods then in use, and the necessity of first bringing the head of the bone back to the opening in the capsule through which it had escaped before attempting to replace it in its cavity; and he drew from observation of the different degrees of tension of the different muscles inferences as to the position in which the limb should be placed and the direction in which traction should be made, which were of great practical value, although based upon notions concerning the obstacles that opposed reduction which were incomplete in that they took no account of the untorn ligaments and capsule. Thus, in dislocation forward or downward of the shoulder he abducted the elbow widely, and in those of the thigh backward he flexed the limb and then changed its position when the head of the bone had been brought down to the proper level.

Petit, in thus departing from the practice of his predecessors and contemporaries, had entered upon the right path; he erred in not following it far enough, and his error arose from a too limited notion of the obstacles to be overcome. He noticed that some muscles were tense and others were relaxed, and he sought to place the limb in a posture that would remove these differences, while at the same time traction made in the direction of its long axis would bring the head of the bone to the point at which it had escaped from its cavity. His improvements were appreciated, and his practice was essentially followed by most surgeons until within the last few years. Yet one of his early successors, Pouteau,¹ in a paper embodying ideas conceived in 1749 (see loc. cit., vol. ii. p. 237), pointed out the defects of the method as applied to dislocations of the hip, and supported his own arguments and modifications by the record of several successes. He says (p. 222) that in the first case of dislocation of the hip upward and outward (on the dorsum of the ilium) which he was called upon to treat he employed Petit's method and failed. That is, he made traction with the limb somewhat flexed, counter-extension being furnished by the canvas band of Petit's machine, the centre of which pressed against the tuberosity of the ischium, while its ends lay, one in front of the abdomen, the other behind the buttock. The reflections excited by this failure led him, when the next case presented itself, a few months later, to make traction with the thigh flexed at a right angle, and the effort was promptly successful. He placed the patient on his back on the floor, laid the canvas band along the groin, with one end between the thighs and the other on the outer side of the injured hip, flexed the thigh to a right angle, engaged the ends of the bars in the pockets of the counter-extending band, and made traction; when he deemed the traction sufficient, he gently rotated the thigh outward, and reduction at once took place. Furthermore, he showed that the resistance of the

¹ Pouteau: Œuvres posthumes, Paris, 1783. Pouteau died in 1775.

muscles was due to their involuntary contraction and was to be more readily and safely overcome by prolonged moderate traction than by more violent but briefer efforts. He says (*loc. cit.*, p. 226): "I have several times observed that it is easier to temporize than immediately to overcome the resistance of these muscles; so, when the extension seems to be sufficient I maintain it at the same point for some time and wait for the relaxation which fatigue must bring about. It is then only necessary to profit by this moment of inaction to effect the reduction."

Pouteau's practice closely resembled that which represents the application of the principles of the modern method by manipulation, and is identical with that of moderate traction upon the flexed limb which is now in common use and is, I think, generally preferred to that of pure manipulation. He flexed the limb to bring the head of the bone nearer the opening in the capsule, made traction to lift it to the level of the cotyloid cavity, and then turned it in by outward rotation or abduction, or both. He knew even that the traction could sometimes be dispensed with and the reduction effected by manipulation alone, and, in quoting successes thus obtained by Maisonneuve, he predicts that a simpler method than his own will be found. The failure of his practice to become generalized is probably due to the influence of tradition and of the authority of Petit, reinforced as the latter was by the great advance he had made over the practice of his predecessors, and perhaps to the insufficient publication of Pouteau's views. The paper from which the above quotations are made appears to have been written in 1749, but there is no evidence that it was published elsewhere than in the posthumous collection of 1783, which, consisting of disconnected essays upon various subjects, probably had only a limited circulation. Whatever the cause may have been, the result is beyond question; surgeons continued to reduce dislocations of the hip by traction with the pulleys, the limb being only slightly flexed, and by pressure applied at the upper part of the thigh to move the head laterally into the cavity. Sir Astley Cooper habitually used only traction, followed by rotation of the thigh *inward*.

Prof. Nathan Smith, of New Haven, taught and practised a method of reduction by manipulation which was published in 1831 after his death, in his *Medical and Surgical Memoirs*, edited by his son, Nathan R. Smith, and this, Prof. Bigelow says, "covers the ground of priority of invention." (See Chapter LI., Treatment.)

The next published recognition of the possibility of reducing a dislocation of the hip by manipulation alone was by Desprès, who, in 1835, communicated to the Société Anatomique of Paris¹ "a new method of reducing dislocations of the femur" by flexion and rotation outward. The only comment it excited at the time, according to the records of the society, was the mention a few months later by Pigné of the fact that the same method was described by Beach in a *Treatise on Medicine*, published in New York in 1833, and was there said, on the authority of Sweet, the "natural bone-setter," to have been practised by the savages of North America.² The Desprès incident is mainly

¹ Desprès: Bull. de la Soc. Anatomique, September, 1835, p. 4.

² Beach, like Sweet, appears to have been an irregular practitioner, and it is likely that his assertions, even when known, were not deemed worthy of serious consideration.

noteworthy as showing how completely the previous suggestions had been forgotten or overlooked, even by Pouteau's own countrymen. It is now used by the French as a justification for speaking of the method by manipulation (at the hip) as the "*Méthode de Després.*"

In like manner, other surgeons sought to modify the practice as regarded the shoulder-joint, by advising that the traction should be made in different directions and combined with rotation of the limb. Of these the most noteworthy are Mothe and Lacour, since it is with their practice that the manipulative methods are generally thought to have begun.

The earlier manipulative methods were either empirical or based upon more or less incorrect notions of the nature of the obstacles to be overcome and of the mechanism by which the result was to be obtained, and it is only since the pathology of the different dislocations has been better understood, with reference especially to the position of the rent in the capsule and the influence of the portions which remain untorn, that the different procedures embraced under this method have been intelligently devised and executed. They differ so widely in their details that only the most general description can be given here; they consist in giving to the limb successive positions, by which the head of the bone is first brought opposite the opening in the capsule and then into its cavity, and by which the opening in the capsule is made to gape widely, or is actually enlarged if necessary. For the accomplishment of these ends the limb is used as a means of acting upon the capsule so far as it remains attached to the bone, and the head of the bone is made to take its successive positions by rotation of its shaft, or by using it as a lever which finds its fixed point either upon some adjoining prominence of bone or in the capsule, or by moving the entire limb in the direction of its long axis. Combined with these manipulations it is commonly necessary to employ a certain amount of traction to overcome gravity or such resistance as is offered by the muscles.

It rests essentially upon an anatomical and pathological basis consisting of two parts, the position of the rent in the capsule and the resistance of the untorn portion, and depends for its knowledge of these two factors, in any given case, mainly upon the position occupied by the limb and the limitations of the movements. Resistance of the muscles, when present, is overcome by anæsthesia or by traction.

Such traction as is required is made by the hands of the surgeon or of an assistant, or by the weight of the dependent limb, or by the prolonged action of an elastic band or of a weight suspended over a pulley.

Continuous traction by India-rubber bands was introduced by Legros and Onimus while internes in the Paris hospitals, 1863 to 1866, and advocated by them in a paper published in 1868.¹ They recognized that their object, the fatigue of the opposing muscles, could be equally well accomplished by weight and pulley or a steel spring, but they gave the preference to India-rubber because of the ease with which it could be used. Their reported cases are dislocations of the shoulder and elbow.

The method of application in dislocations forward of the shoulder,

¹ Legros and Onimus: *Des Tractions continues, et de leur Application en Chirurgie.* Arch. Générales de Méd., January, 1868.

for example, is as follows: A loop is made fast to the lower part of the arm by turns of a roller-bandage or by strips of adhesive plaster as in Buck's extension; then the patient is seated in a chair, counter-extension provided by a band passing around the chest under the axilla and over the opposite shoulder and made fast to some neighboring fixed point, the elbow gently raised to or nearly to the position of horizontal abduction, and traction made in the direction of its long axis by a rubber cord passed through the loop attached to the arm and around a fixed point established in an appropriate position. The traction should be about twenty or twenty-five pounds, and needs to be continued for from fifteen to thirty minutes; under its influence the muscles become relaxed and the patient experiences the sensation of great fatigue, the head of the bone gradually approaches the glenoid cavity, and either enters it spontaneously or is replaced by the pressure of the surgeon's fingers, or by a sudden pull upon the arm.

Continuous traction by the weight of the limb is used at the hip and shoulder. The limb is placed in such a position that its weight tends to move it in the desired direction; thus the thigh is allowed to hang down (the knee flexed and the leg horizontal) at the end of a table upon which the body of the patient lies prone. For the shoulder, the patient is placed upon his side on a cot through a hole in which the injured arm hangs directly down. To the weight of the limb in either case that of a sand bag may advantageously be added. (See Chapters XLII. and LI.)

Athrotomy. Occasionally a fresh dislocation is irreducible because of an exceptional position of the bones or of interposition of the soft parts. I have seen this once each at the shoulder, elbow, and temporomaxillary joints, and a number of times at the metacarpo-phalangeal joints and in dislocations with fracture. At the shoulder the head of the humerus had passed below and then so far to the inner side of the subscapularis that its tendon was closely wrapped about the outer side of the neck of the bone and had to be divided; at the elbow, apparently in consequence of repeated attempts to reduce, the denuded end of the humerus had been forced through the fascia in the flexure of the joint, and the tendon of the biceps was lodged behind the external condyle; at the jaw, the meniscus had been torn away from the condyle and was lodged behind it.

If such an operation is done within a day or two after the accident the risk is no more than that of a similar opening of the unlacerated joint; but while inflammatory reaction is active and œdema is marked the chance of suppuration is greater, and it is then well, I think, to await their subsidence before operating.

Old Unreduced Dislocations.

The changes, above described, which take place about a dislocated bone gradually increase the difficulty of reduction by means that are sufficient while the dislocation is fresh, and ultimately make it impossible. The conditions vary so greatly with individual cases and with the different joints, and their extent and detail are so unrecognizable

clinically and so largely a matter of inference that the difficulty cannot be measured simply by the length of time that has elapsed, and too often not even by anything short of an actual trial.

The common practice, until within quite recent times, was simply to employ the usual forcible means more forcibly, to rupture adhesions by forcing the limb in various directions, and then to drag it into place by pulleys or specially devised apparatus. While this succeeded in many cases, and even occasionally in some at the shoulder and hip which had existed for months, yet the record is full of accidents and disasters, and many a grave warning has been uttered against the dangers of the attempt even in apparently suitable cases and against the temptation to subordinate the patient's welfare to a desire to obtain an unusual success.

The dangers of forcible reduction in cases of long standing, and the superiority of operative methods to meet the special indications that may exist in them, are now so well understood that the warning is not much needed in such cases; it is in the more recent cases, those of a few weeks, that it is now specially necessary to be on guard against being unwittingly led to strive too long, to make a stronger and still a stronger pull after less force has failed. The danger is specially great in the old, whose diseased arteries may so easily be bruised or torn, and whose thinned bones may so easily be broken. The following two cases which recently occurred in the service of a surgeon in a prominent New York hospital, within a year of each other (1896-97), illustrate the temptation and the risk.

A woman sixty-seven years old; subcoracoid dislocation two weeks old. Ether; traction by pulleys, estimated at 300 pounds; reduction on second attempt. The following day the radial pulse could not be felt, and gangrene seemed imminent; seven weeks later amputation of the arm; death. The autopsy showed a thrombus in the brachial artery.

Man sixty-eight years old; subcoracoid dislocation six weeks old. Ether; manipulation to rupture adhesions; Kocher's method tried twice, then heel in the axilla. Then arm carried forcibly across the body, the head slipping to the outer side of the glenoid fossa; finally traction in abduction succeeded. Died five hours later. Autopsy showed rupture of the axillary vein and of the short head of the biceps; capsule entirely torn from the humerus; third, fourth, and fifth ribs fractured in the axillary line.

The alternative measures—reduction by operation, excision, and osteotomy—have been made so much safer than formerly by improved surgical technique that they are now resorted to with increasing frequency, and the resulting experience has been such that rules of treatment can be formulated for some of the joints. In backward dislocation of the elbow formal exposure by two lateral incisions and removal of the cicatricial tissue permit complete reduction and usually a notable improvement of function. At the shoulder the range of motion after reduction by operation has generally been small, and the operative difficulties are often great; excision of the head gives greater mobility and meets the frequent special indication of relief of pain due to pressure, but the result is marred by the diminution of active control. At

the hip reduction by operation has proved dangerous and has failed in more than half the trials; even when it has succeeded the functional gain has not often been notable. (See Chapter LIII.)

The facts and general principles to be considered in determining upon resort to operative interference and in making a choice of methods are as follows:

1. At the present time wound infection is of more frequent occurrence after operative reduction of old dislocations of the large joints than in other primarily clean operations, and an almost inevitable result of such infection is ankylosis of the joint; and even in cases which escape infection the restoration of function is usually quite incomplete. Consequently the usefulness of the limb in the existing conditions and the probable gain by interference should be carefully considered.

2. A faulty fixed position may be so improved by an operation that the usefulness will be increased even if ankylosis follows.

3. On the other hand, and this is specially true of the hip, the improvement to be got by a change of position may be far too slight to justify the risks of an operation so extensive as would be required for reduction, and an almost equal improvement might be had by an osteotomy.

4. Pain and trophic changes in the limb due to pressure upon nerves are good reasons for interference; the relief would probably be more surely and easily obtained by an excision of the head of the bone.

5. Excision, when undertaken only to improve function, is suitable at the shoulder and elbow, but must be sparingly employed at the hip where solidity of support is more important than mobility.

After-treatment.

After a dislocation has been reduced, there is needed, in most cases, only a simple retention bandage to confine the limb in an easy position, but in some cases—dislocation of either end of the clavicle, of the head of the radius, and sometimes of the shoulder backward under the spine of the scapula (Busch and Krönlein)—the tendency to recurrence is so great that special dressings are required. The joint should be kept quiet, certainly any movement that causes pain should be avoided, and if the inflammatory reaction threatens to be severe it must be opposed by the application of cold, or uniform gentle pressure if it can be borne. After a week or two the use of the limb may be gradually resumed. In making passive motion or this use of the limb, those positions must be avoided in which the head of the bone would press upon the torn part of the capsule, or in which the sides of the rent would be again separated from each other.

If, as sometimes happens, the joint remains stiff, weak, and sensitive, but is cold rather than warm, and aches and perhaps becomes puffy after use, it needs massage and rubbing, and to be actively moved either by the patient or by the physician. Its sensitiveness and immobility under such circumstances are due to the prolonged disuse, to

¹ For many cases of various forms of operation see Engel, in *Arch. für klin. Chir.*, 1897, vol. lv. p. 603.

retraction and loss of pliability in the peri-articular tissues, and possibly to the presence of adhesions within the cavity itself.

Habitual Dislocation.

A marked tendency to recurrence may be combated by prolonged immobilization of the joint if the injury is comparatively recent, or by special treatment designed to thicken and shorten the capsular and peri-articular tissues. Genzmer¹ successfully employed in two cases of recurrent dislocation of the shoulder repeated injections into the joint of the pure tincture of iodine. The needle was introduced a finger-breadth below the coracoid process, and seven to ten minims were injected. The arm was then immobilized, and the injections repeated from five to seven times at intervals of three or four days. He recommended the same treatment for habitual dislocation of the lower jaw.

Dubreuil² reports a cure at the shoulder by six injections, during a fortnight, of two drops each of a 10 per cent. solution of chloride of zinc into the peri-articular tissues. At the sternal end of the clavicle I have twice obtained a good result by injecting a few drops of alcohol into the peri-articular tissues and immobilizing for a fortnight.

The operative method which seems safest and most efficient at the shoulder is one introduced by Ricard,³ the formation of a permanent fold in the anterior portion of the capsule by three vertical silk sutures. A similar method has been used in habitual outward dislocation of the patella.

¹ Genzmer: *Centralblatt für Chirurgie*, 1883, p. 563.

² Dubreuil: *La Semaine Méd.*, February 27, 1892.

³ Ricard: *Acad. de Méd.*, October 31, 1892.

CHAPTER XXIV.

ACCIDENTS THAT MAY BE CAUSED BY ATTEMPTS TO REDUCE A DISLOCATION.

THE complications or accidents that may be caused by the attempt to reduce a dislocation may appear during the attempt, as the immediate consequence of the manœuvres employed, or subsequently as a more or less remote consequence of the changed conditions, the local injuries, or the inflammation produced by those manœuvres; and they may be localized at or near the dislocated joint, or may be the result of a local distant change or of a more diffused impression upon the organism. They may, therefore, be grouped as: 1st, primary local accidents; 2d, consecutive local accidents; 3d, cases of hemiplegia, syncope, and sudden death. The first group comprises injuries of the skin, cellular tissues, muscles, vessels, nerves, and bones; the second group includes suppuration in or about the joint, and œdema, gangrene, and paralysis consequent to injury to vessels or nerves. The third group includes those cases of shock or exhaustion, sometimes proving fatal, which have become exceedingly rare since the introduction of anæsthetics, and those others, that have come in their place, of death due to the anæsthetic itself.

It is noticeable, on comparison of the cases that have occurred at different periods, that while some varieties of the lesions are common to all times, with their varying methods of treatment, others are in a manner dependent upon the means by which the reduction has been attempted. Thus, violent traction is the sole cause of some; manœuvres, such as abduction and rotation of the arm, the principal cause of others; violent pressure at or near the head of the bone, prolongation of the effort, and anæsthetics, each of its own peculiar varieties. Notwithstanding these differences, certain points may be recognized as common to the greater number, such as the age of the patient and the length of time during which the dislocation has remained unreduced. Injuries of the vessels have been most frequent in the old and in dislocations of long standing, and all the other accidents have, in recent times at least, been rarely seen except in connection with dislocations that have long remained unreduced or that have been complicated by much inflammatory reaction. The reasons for the greater liability to rupture of the arteries under these conditions are not obscure; the loss of elasticity because of atheromatous change in the vessels in the old, and the adhesion of the vessels to adjoining parts as a sequence of inflammation are a sufficient explanation, and the mechanical difficulties created by the contraction and readjustment of the torn tissues in old dislocations explain the others by the force that is required to overcome them.

Integument. The skin may be bruised or lacerated at a distance from the joint by the pressure of the cords through which traction is made, or near the joint by the pressure of the hands or instruments acting upon the dislocated end of the bone, or it may be torn across if the traction is exerted upon it rather than upon the bone. These lesions are seldom serious, and the former may usually be avoided by protecting the surface with thick layers of cotton or flannel. Transverse rupture of the skin between the points of extension and counter-extension is due to a faulty application of the force, by which it is exerted upon the skin alone and not upon the underlying bone. The skin is elastic and tough, and when unaltered by disease will support a very considerable strain, one far in excess of that commonly needed to overcome the contraction of a muscle, but the traction may be so applied that it will act only upon the skin. Thus, if a broad band is strapped snugly about the middle of the arm and traction is made by a cord attached to it, it will draw the skin downward toward the elbow; and if at the same time the skin of the axilla and chest-wall is prevented by counter-extension from sharing in the movement, the intermediate portion is put upon the stretch and may tear.

To guard against the occurrence of this accident the limb should be firmly grasped, if traction by the hands is used, at the enlarged distal end of the bone, so that the skin should not be drawn downward by the slipping of the hands, and the additional precaution may be taken to press the skin of the forearm (in the case of a shoulder dislocation) upward before the limb is grasped, and similar precautions suitable to the region should be taken at the point of counter-extension. If traction is made by a cord or band, it should be attached to the limb just above a bony prominence or enlargement which will prevent its slipping; it should not be made fast simply by enclosing its loop in circular turns of a bandage which maintain their hold upon the skin by friction.

Sloughing of the skin, due to its compression against an underlying bone by direct pressure exerted to force the latter back into place, has been occasionally observed, in a dislocation of the astragalus,¹ and over the olecranon in an attempt made by a bonesetter to reduce a backward dislocation of the elbow.

Emphysema of the Cellular Tissue. This has been noted in one case. Flaubert² reduced a dislocation of the shoulder of five weeks' standing in a woman seventy years old; the first attempt was unsuccessful; in the second traction was made by eight students, and the patient, who at first uttered vehement cries, seemed afterward to be upon the point of suffocating, and her face became purple and injected. An emphysema immediately appeared above the clavicle and spread over the shoulder to the middle of the back. She died on the eighteenth day, apparently in consequence of the tearing away of the lower four trunks of the brachial plexus at their attachment to the spinal cord.

¹ Dauvé: Rec. de Mém. de Méd. et Chir. Milit., 1867, vol. xix. p. 143.

² Flaubert: Répertoire d'Anat. et de Phys., 1827, quoted by Malgaigne.

Rupture of the Muscles. Under this head only those lacerations of the muscles will be mentioned which are occasioned, especially in old dislocations, by violent traction or by forcible, exaggerated, and long-continued manipulation of the limb. The cases in which the injury has been confirmed by autopsy are few, only those in which death has promptly followed in consequence of associated lesions or of the inflammation to which the violence has given rise. Yet, in another of Flaubert's cases,¹ there seems to be no doubt that not only the muscles but also the ligaments and other soft parts were extensively torn. The case was one of dislocation of the elbow backward, twenty-seven days old, in which traction was made upon the forearm by seven assistants; suddenly the parts seemed to yield and change their positions with a sound of tearing, and at the same moment a zone of narrowing or depression appeared at the level of the joint with a bony prominence above and below. It seemed to all present that the muscles and soft parts covering the joint had been ruptured, leaving a gap two inches long. An enormous fluctuating swelling promptly appeared, the radial pulse returned the next day, and the patient recovered.

In the cases confirmed by autopsy the dislocation has always been of the shoulder, and the muscles most frequently torn have been the pectoralis major and the subscapularis.

Avulsion of a portion of a limb is fortunately a very rare accident. Except for one or two cases of avulsion of the thumb, known only by tradition, the only instance of complete avulsion is that in which Alphonse Guérin tore away the forearm at the elbow in an attempt to reduce a subcoracoid dislocation of the shoulder of six weeks' standing.²

The rupture took place mainly through the joint, a small portion of each condyle remaining attached to the muscles of the forearm, and a portion of the olecranon to the triceps. The muscles were softened and brown; the nerves were injected, with nodes at intervals; the veins were dilated. The ends of the long bones were profoundly disorganized, with thinning of the compact shell and rarefaction of the spongy part; they broke under slight pressure and could be easily perforated with the scalpel. Microscopical examination showed degeneration of the nerves, muscles, and bones.

The patient died on the thirteenth day, and the autopsy showed no change in the tissues of the other limbs; the muscles of the shoulder were normal, except the deltoid, the fibres of which were pale and degenerated. The nerves were matted together in the axilla and firmly pressed against the head of the humerus; above the point of compression they were normal, contrasting strongly with the parts below.

It is evident that the accident was favored by great trophic changes in the limb, probably due to pressure upon the nerves in the axilla.

Injuries of the Main Bloodvessels. Although the earliest recorded cases of accidents of this class occurred at about the beginning of the eighteenth century, the subject did not receive the attention of sys-

¹ Malgaigne: *Loc. cit.*, p. 149.

² Guérin: *Bull. de la Soc. de Chir.*, 1864, pp. 121 and 131.

tematic writers on surgery until after the publication, in 1827, of an article by Flaubert.¹ Malgaigne, in 1855, discussed the subject at length in his work on dislocations, mentioning sixteen cases of all kinds, certain and uncertain. Callender,² taking as a text his own fatal case, again collected and collated the known cases; and similar use was made of the material and other cases added to the list by Le Fort,³ Willard,⁴ and Marchand.⁵ In 1882 Körte⁶ reported three personal cases, and wrote a very full and valuable paper on the subject, containing forty-four supposed (actually thirty eight; see first edition, p. 79) cases of dislocation of the shoulder in which the vessels had been seriously injured during the act of dislocation or of reduction; and in 1884 Cras⁷ reported a personal case of injury of the axillary artery, and added a few others to Körte's list. Strictly speaking, several of these cases should not be here considered, since in them the vessel was injured at the moment of dislocation and not during reduction, and in many others it remains uncertain whether the same objection might not be made to them. They are retained because they serve equally well with the others to further the study of most features of the subject.

I have met with only two recorded cases in which a large bloodvessel has been injured in the reduction of any dislocation except of the shoulder. These were both of the elbow, the cases of Flaubert and Michaux, quoted by Marchand and Malgaigne. The former has been already quoted under rupture of the muscles; in the latter the patient was ten years old, and the dislocation was of the elbow backward and outward, the swelling was considerable, the radial pulse was present. Reduction was attempted on the day after the accident, and on the next following day, but without success. The last attempt was immediately followed by swelling of the elbow and by arrest of pulsation in the radial and ulnar arteries; gangrene set in, and six days after the attempt the limb was amputated. The tendons of the biceps and brachialis anticus were found to have been forced by the manipulation around the external condyle to the posterior aspect of the humerus, accompanied by the ruptured brachial artery and median nerve.

In 1885 I⁸ found forty-seven trustworthy accounts of injury to the larger vessels of the axilla in dislocation or reduction of dislocation of the shoulder. Since then Caldwell⁹ has reported a case thought to be rupture of the anterior circumflex artery, and I have learned of one of rupture of the axillary vein (Weir). The latter has been quoted above (p. 446). Caldwell's patient was fifty-eight years old, and the dislocation had been promptly reduced. Six weeks later "there was a large fluctuating swelling in the outer aspect of the shoulder, over the area covered by the deltoid;" pulsation at wrist and in axillary artery; no

¹ Flaubert: *Mém. sur plusieurs cas de luxations dans lesquels les efforts pour la réduction ont été suivis d'accidents graves*, Répertoire d'anat. et de phys., 1827.

² Callender: *St. Bartholomew's Hospital Reports*, 1866, vol. ii. p. 96.

³ Le Fort: *Dict. encyclopédique des sci. méd.*, article *Axillaires*.

⁴ Willard: *Philadelphia Medical Times*, 1873, vol. iii. p. 721.

⁵ Marchand: *Des accidents qui peuvent compliquer la réduction des luxations traumatiques*, Thèse de concours, Paris, 1875.

⁶ Körte (first paper): *Arch. für klinische Chirurgie*, vol. xxvii. p. 631.

⁷ Cras: *Bull. de la Société de Chirurgie*, 1884, p. 739.

⁸ Stimson: *New York Medical Journal*, June 13, 1884, and first edition of this work.

⁹ Caldwell: *Cincinnati Laucet-Clinic*, May 3, 1890.

swelling in axilla. Under the impression that the swelling was due to an abscess an incision was made and about a pint of clotted blood evacuated; this was followed by arterial hemorrhage, arrested by pressure of the thumbs in the wound. The wound was enlarged, but the source of the bleeding was not found. The wound was packed with gauze, and the patient recovered. In 1901 Körte¹ reported another personal case and collected five not included among those already mentioned, and in 1905 Hessmann² one of rupture of the axillary artery, in a man seventy-two years old. He ligated the subclavian artery, and a fortnight later disarticulated the limb. Recovery.

Of these, the axillary vein alone was ruptured in four (Froriep, Price, Weir, Hailey), although I think the last one doubtful, and the artery and vein together in three (Platner, Baum, Sonnenburg).³ In most of the others the axillary artery or one of its branches was injured, but in some the source of the hemorrhage remains uncertain. In thirty-five cases death or amputation of the arm furnished the opportunity to examine the region and determine the character of the lesion; this, in some cases, was a complete or partial rupture of all the coats of the artery or of the inner and middle coats alone, with subsequent formation of a circumscribed aneurism. In other cases the vitality of the wall appears to have been diminished or destroyed by direct pressure, and this to have been followed, after the lapse of a few days, by rupture, or, still later, by the formation of an aneurism. In Gibson's second case an aneurism appears to have formed in consequence of the earlier attempts to reduce, and then itself to have been ruptured when Gibson effected reduction. Rupture always appears to have taken place quite high up, and usually at the point pressed upon by the head of the humerus. Callender found it necessary to divide the pectoralis minor to reach it. In the fatal cases of injury of the vein alone the vessel was torn completely, or almost completely, across.

In seven cases only a small (one-sixth of an inch) oval opening was found on the anterior wall of the artery, and was thought to have been produced by the tearing off of a branch, the subscapular or circumflex.

In other cases the subscapular or the circumflex artery was torn across at or near its origin. The cases of this kind form a considerable proportion of the whole number, and are of great importance because they explain the persistence of the radial pulse noted in several of the histories. In Parker's the swelling was at the axillary border of the scapula behind, "near the situation of the dorsal scapular artery or the subscapular at the junction of the two;" in Caldwell's under the deltoid.

Of thirty-four cases in which the age of the patients is given, in twenty-two they were more than forty years old. The youngest was twenty, the oldest eighty-six. In very few of the cases it is noted that the arteries were atheromatous, although the advanced age of many of the patients makes it probable that the elasticity of the vessels was diminished.

¹ Körte (second paper): *Arch. für klinische Chirurgie*, vol. lxxvi.

² Hessmann: *Münchener med. Wochenschrift*, 1905, No. 42.

³ Possibly to these may be added Volkmann's case of wound of the axillary vein, thought to have been caused by a splinter of bone. The wound was discovered during an operation to excise the head.

In more than half the cases the dislocation was recent—less than three weeks. In not more than one third of them it is reasonably certain that the lesion was caused during reduction; in three cases it was certainly caused by the dislocation; in the remainder the cause is obscure. To these latter belong those cases in which the reduction was promptly effected, and without the use of much force or of exaggerated positions of the arm. In many of the others the attempt to make reduction was greatly prolonged or several times repeated, and the force used was very great or improperly applied.

In some the injury was evidently caused by excessive traction; in others by faulty manœuvres, such as extreme abduction or elevation of the arm, rotation, and circumduction; in others again apparently by direct compression of the vessel against the underlying bone, as by the booted heel in the axilla, or possibly by the thumbs.

Leaving aside the earlier cases in which faulty methods no longer in use were employed, and those old dislocations in which the relations and connections had been permanently changed by fibrous or bony tissue of new formation, it becomes evident that in dislocation of the shoulder the accident is most to be apprehended when the elbow is raised in abduction to the height of the shoulder, or is carried, as in Callender's and Weir's cases, across the chest and face in a wide movement of circumduction; and for this reason, that in these movements the dislocated head of the bone is turned downward into the axilla, and the vessels which lie upon its inner side are pressed down before it and forcibly put upon the stretch, while those branches which run almost directly outward, the subscapular and circumflex, and are fixed to the tissues amid which they branch, are directly and forcibly elongated. Although in dislocation inward the limb is shortened by being abducted, yet the artery is not thereby relaxed, but, on the contrary is still further stretched around the head of the bone. Jössel,¹ in a recent case in which death was caused by associated injuries, found the "nerves of the brachial plexus, especially the circumflex nerve and the subscapular artery, greatly stretched by the head of the humerus;" and, according to Körte,² he found in another case of recent dislocation the subscapular artery torn.

In some of the cases in which it is certain or probable that the injury to the vessels was inflicted at the moment of dislocation, it is noted that the latter was produced while the arm was widely abducted—that is, under circumstances in which the head of the humerus would be driven downward and inward.

If the dislocation is an old one, and especially if there has been much inflammatory reaction, and the vessels have become firmly adherent to the bone or embedded in unyielding cicatricial tissue, the liability to rupture is increased, because of the loss of elasticity occasioned by the latter condition, and because of the limitation of the strain to a shorter segment of the vessel in the former. If, in addition, the distensibility of the vessel has been further reduced by atheroma, the danger is still greater; and this last predisposing cause may properly

¹ Jössel: *Deutsche Zeitschrift*, 1880, vol. xiii. p. 177.

² Körte (first paper): *Loc. cit.*, p. 640.

be deemed sufficient to lead to the rupture, even when the traction is slight and the manœuvres are confined within a narrow range.

The symptoms at the beginning present two widely different forms; in one, the less common, a tumor presenting many of the signs of an encysted aneurism appears in the axilla a few days or weeks after the reduction, and increases in size rather rapidly; if not successfully treated, it soon involves the skin and ruptures externally.

In the other form, the more common, a diffused fluctuating swelling, without bruit or pulsation, appears immediately, or within a few hours, in the axilla, raising the pectoral and deltoid muscles, or is perhaps most prominent posteriorly, and in most cases promptly reaches a large size, even that of the adult head (Lister); the radial pulse sometimes persists. The only exception to rapid growth among the recorded fatal cases is Körte's third case,¹ in which the extravasated blood disappeared slowly, leaving a firm, non-pulsating lump, as large as a walnut, in the course of the axillary artery, which a surgeon supposed to be a lymphatic gland, and undertook to extirpate nearly five months after the accident. It proved to be an aneurism containing much stratified clot; the axillary artery was tied above and below, and the patient died.

In several cases the patients died promptly after the accident, sometimes after profound syncope, sometimes after a short period of apparent well-being, with symptoms of shock or acute anæmia. In two, which finally ended in recovery, the patients were at first greatly prostrated, and death by syncope threatened. In another gangrenous emphysema developed in the arm, and the patient died forty hours after the reduction. In this case the inner and middle coats of the artery were torn across "just beyond the point of origin of the dorsal scapular branch." The radial pulse was at first perceptible, but had ceased the next morning.

In most of the others the swelling increased, and, in a longer or shorter time, ruptured spontaneously, or was threatening to rupture when operative interference (puncture, incision, or ligature of the subclavian) was resorted to. The longest period was in Bellamy's case, six months after reduction, and even in this case the first hemorrhage occurred five weeks after reduction.

In eight cases that recovered without operation, the swelling subsided, and the ecchymosis was slowly absorbed. Probably in some of them the vessel injured was one of the branches of the axillary artery, but in at least one (Sands) the injury was certainly of the artery itself.

In the three cases in which rupture of the vein alone was demonstrated post mortem (Froriep, Weir, Price), the patients died promptly, in an hour and a half, five hours, and on the following day respectively.

The histories show that, although the diagnosis, so far as the general nature of the accident, rupture of a bloodvessel, is concerned, does not long remain obscure, the identity of the injured vessel cannot always be determined. If the tumor pulsates, the diagnosis of rupture of an artery may be made; and if, in addition, the radial pulse is present, it is extremely probable that the injured vessel is not the main artery, but that one of its branches, probably the subscapular or circumflex,

¹ Körte (first paper): *Loc. cit.*, p. 636.

has been ruptured or torn off at its origin. Beyond this it does not seem at present possible to go with much certainty, although the great preponderance of arterial lesions in the known cases—26 out of 29—makes it highly probable in any given case that an artery and not the axillary vein has been torn.

The terminations were as follows : 22 recoveries, 33 deaths, and in 1 (Green's) the result is unknown ; 21 received no operative treatment ; of these 6 recovered and 15 died.¹ In 19 the subclavian was tied, with 8 recoveries and 1 after disarticulation, 8 deaths, and 2 unknown result. In 1 a cure was effected by digital pressure on the subclavian, and in 1 by stuffing the cavity with gauze (ant. eireumflex). In 6 an incision was made in the axilla, and the artery tied above and below the point of rupture ; all died. In one (Körte's second) the small opening in the artery was sutured, and after a hemorrhage on the twenty-second day the artery was tied above and below. The patient recovered with a useless limb after prolonged gangrene and suppuration. In one (Raw) the torn subscapular artery and axillary vein were tied, the patient recovering. In 4 the limb was disarticulated ; 1 recovery, 3 deaths. The treatment in the cases that recovered without operation was simply compression of the swelling and immobilization of the arm, with the application of ice in Malgaigne's, and compression of the subclavian artery in Agnew's.

In drawing inferences from these results, it must be borne in mind that in many of the cases in which operations were undertaken non-operative treatment had previously been employed, and had resulted in a condition that made an operation necessary. Including such, the results of non-operative treatment may be tabulated as follows : Of 38 patients, 6 recovered, 15 died, and 17 (with 10 deaths) subsequently underwent operation, either because death by hemorrhage threatened or because of the existence of a growing aneurism.² A fair inference from the reported cases is that conservative treatment may properly be tried at first, but should not be prolonged if the symptoms do not properly yield ; and, secondly, that, in case of resort to operation, ligature of the subclavian artery or disarticulation at the shoulder is to be preferred to incision of the sac and double ligature of the artery. It is not easy to understand why ligature of the artery above and below has been so uniformly fatal, and notwithstanding the record I should prefer it to disarticulation, and perhaps even to ligature of the subclavian.

Experience with arteries wounded under other conditions has shown that they will sometimes quite readily heal, or the opening made into them will close, under pressure accurately made at the point of injury, and it would, therefore, be proper to attempt to treat this injury by direct, limited pressure. Whether or not it would be possible to recognize the wounded point and make efficient pressure directly upon it cannot be said, since the attempt does not appear to have been

¹ Possibly Körte's second case should be included among the recoveries.

² Körte's second case is an exception ; an error in diagnosis led to an operation after the aneurism had apparently undergone spontaneous cure. In Caldwell's the swelling was thought to be an abscess.

made. In default of such limited pressure, general compression of the swelling in the axilla seems to be the only resource short of operation. The common treatment of ruptured artery, incision and double ligature of the vessel, was immediately resorted to in only two of these cases; both were promptly fatal. Körte's result after lateral ligature of a small opening in the artery is not encouraging, although a number of successes after incised wounds have been reported.

In the reduction of recent dislocations, these accidents show that abduction of the arm especially should be avoided, as also circumduction, violent traction, and rough pressure in the axilla. Kocher's method by manipulation and mine by the unsupported weight of the dependent limb appear well adapted to avoid the danger. It is also to be remembered that the injury to the vessel may be caused by the dislocation itself, and its symptoms may be masked by the swelling commonly present during the first few days.

In old dislocations the probability of the occurrence of the accident is increased by the more forcible measures usually necessary to break up the adhesions that bind the bones in their new relations; and, while it may be proper in many cases to make the attempt to restore the limb to usefulness, the possibility creates another reason for abstention when the patient is old, the duration of the dislocation long, and the adhesions firm. Even a dislocated arm may be very useful, and the fatality of this accident, more than 70 per cent. of deaths, may well cause the surgeon to hesitate to incur the risk merely for the sake of ameliorating a condition which does not endanger life and is quite compatible with activity and usefulness.

Injuries to Nerves. These also have been far more frequently observed at the shoulder than elsewhere, and there is the same difficulty in many of the recorded cases in determining whether the injury was caused by the dislocation or by the manœuvres employed to effect a reduction.

The injury may consist in direct compression of the nerve against the bone, as in attempted reduction by the method of the door or ladder or by the heel in the axilla, or in forcible elongation or complete rupture of the nerve by traction upon the limb, or such change in its position that the nerve is stretched around the head of the bone, or in avulsion of the nerve from the spinal cord. As the autopsies are few in number our knowledge of the lesions is mainly clinical. In a case quoted in the preceding section, one of rupture of the brachial artery near the elbow, the median nerve was also ruptured; and this double injury has been several times encountered in compound dislocation of the elbow.

In a case reported by Flaubert,¹ and mentioned above in the section on Emphysema, a dislocation of the left shoulder five weeks old in a very stout woman aged seventy years, reduction was accomplished with difficulty after prolonged traction upon the arm by eight assistants. Beside the emphysema extending over the neck and back, there

¹ Marchand : Loc. cit., pp. 25, 67.

were syncope lasting an hour, cloudiness of vision, paralysis of the right arm, and left hemiplegia with loss of sensibility in the left arm but with pain referred to it. Thirty-six hours later there was sharp pain in the back of the head and neck and in the ears; pain also in the left thigh, in which sensation was better than in the right; the left arm was insensitve, without pain, and motionless; the right arm numb and somewhat weakened; pulse rapid, skin warm. The next day the pupils were dilated and did not respond to light. On the seventeenth day the respiration was embarrassed, the skin hot, pulse rapid, prostration great; and on the nineteenth day death. The autopsy showed the lower four pairs of the brachial plexus on the left side to have been torn away from the spinal cord; the torn ends plainly showed the delicate filaments by which they took their origin, and the ganglions on the posterior roots could be distinguished. The first pair had suffered no injury. The spinal dura mater was of a dark brown-red color, and the cord, at the point where the nerves had been torn away, was changed into a reddish-brown pulp in which the gray and white substances seemed mingled.

The two following cases recorded by Flaubert¹ bear a close resemblance clinically to this one.

In a man, fifty years old, with a dislocation of the shoulder dating from a fortnight before, traction by three assistants caused numbness and pain in the hand and wrist; a second attempt, with six assistants, instantly caused numbness in the corresponding leg, and the reduction was abandoned. The following night there was sharp pain in the lower cervical vertebræ, subsequently extending to the dorsal region. The arm remained almost completely paralyzed.

A dislocation of the shoulder seven weeks old in a woman sixty-four years of age was reduced by traction made by five assistants. At the moment of reduction the patient felt a sort of rupture at the wrist, followed by a quivering that extended to the lower third of the arm and by complete hemiplegia and great diminution of sensation on the same side, especially in the arm. The lower limb regained its power, but the arm remained paralyzed and atrophied.

In other cases the effects, as indicated by the symptoms, have been limited to the limb, arm or leg, or to portions of it.

Erichsen² quotes from Billroth a case of dislocation of the shoulder of nine months' standing which had been accompanied by partial paralysis of the arm and some atrophy. The reduction was followed by total paralysis. Le Bret³ reported one which occupies a position intermediate between this class and the preceding: a soldier dislocated his right shoulder; reduction was immediately made by traction, and was followed by paralysis of motion in the entire arm, loss of sensation below the elbow and on the right side of the neck, and by ptosis and dimness of vision on the same side. In most of the more recent recorded cases the history leaves it in doubt whether the paralysis was

¹ Quoted by Malgaigne: *Loc. cit.*, pp. 158. 159.

² Erichsen: *Surgery, Am. ed.*, vol. i. p. 415.

³ Le Bret: *Soc. de Biologie*, 1854, p. 119. Quoted by Weir Mitchell.

caused by the dislocation or by the reduction. In the older cases, in which the rough method of the door, ladder, or ambi was employed for reduction, there can be but little doubt that the paralysis was commonly caused by the reduction. At the shoulder the nerve most frequently affected is the circumflex; Marchand thinks this nerve is commonly injured by the dislocation; the others by the reduction. Instances of injury in other dislocations than those of the shoulder are rare. Hutchinson¹ describes a case of ischiatic dislocation of the femur reduced by manipulation under ether, followed by complete anaesthesia of the limb below the knee except on the inner side of it and of the foot.

Maclise² gives a plate of dislocation of the femur backward in which the sciatic nerve is stretched over the neck of the bone; and he says: "In general (in dislocations into the sciatic notch) the great sciatic nerve is bent over the femur and put on the stretch." . . . "I have seen it so situated in regard to the head of the femur that the reduction could not possibly have been effected with safety to that nerve." The plate apparently represents a dislocation produced upon the cadaver, and it seems probable that the text refers to dislocations similarly produced. I have known of only one clinical case in which such relations of the parts have been observed (Quain's).

Fracture. Fracture of the dislocated bone during reduction has occurred in dislocations of the shoulder, elbow, and hip, and not only when great force has been employed, but also during comparatively gentle manipulations to flex, abduct, or rotate the limb.

At the shoulder the recorded cases appear all to have been dislocations of long standing in elderly people, and in most the accident was caused by forcible rotation during traction. Of late years I have heard of several cases of fracture in comparatively recent dislocations caused by attempts to reduce by Kocher's method. The fracture is usually at or just below the surgical neck.

Several authors assert that the ribs have been broken during reduction by the pressure of a firm axillary pad used as a fulcrum, and also say that the lip of the glenoid cavity may be broken during reduction. In Weir's case, quoted on page 446, the third, fourth, and fifth ribs were broken in the axillary line, apparently by pressure of the heel.

At the elbow fracture of the olecranon has been frequently caused, either intentionally or by accident, in the reduction of old dislocations. There is but one recorded case of its fracture in a recent dislocation, and even in this there is some doubt whether the fracture had not taken place before the reduction was attempted.³

Markoe⁴ mentions a case, apparently unique, of fracture of the humerus in an attempt to reduce an old dislocation of the elbow. "While making extension, and at the same time trying to flex the forearm on the arm, the humerus gave way, and a very oblique frac-

¹ Hutchinson: *Medical Times and Gazette*, 1866, i. p. 194.

² Maclise: *Dislocations and Fractures*, Plate xxv. Fig. 2.

³ Daugier, in Malgaigne: *Loc. cit.*, p. 146.

⁴ Markoe: *Diseases of the Bones*, p. 18.

ture was found to have occurred about a hand's breath above the joint."

I have seen one case of backward dislocation at the elbow in which a forcible change of the position from full extension to flexion at a right angle had broken off the trochlear portion of the humerus and displaced it forward and upward.

In dislocations of the hip the femur has been broken, usually at the neck, but once at least at the lower end of the shaft; and it is asserted by some that the rim of the acetabulum also has been broken. The accident appears to have been due not to traction, but to efforts made by the hands of the surgeon to change the position of the limb, rotation or abduction. Although the force thus applied is slight compared with that developed by the use of pulleys, it must be remembered that its effect is greatly increased by the leverage of the limb.

Inflammation, Suppuration, Gangrene. The inflammatory reaction induced by a dislocation is usually moderate, and rarely terminates in suppuration; and when excessive reaction does follow the reduction of a recent dislocation, it is not always possible to determine whether the original traumatism or the reduction is responsible for it. In dislocations of long standing this difficulty does not exist, for the primary reaction has completely subsided, or, if persistent, has become moderate and chronic before the reduction is attempted, and its renewal or exacerbation is plainly due to the interference.

The inflammation may be due to the direct pressure of the apparatus used for making traction, or to laceration of the parts about the affected joint; the latter is the more dangerous because of the probability that the inflammation and suppuration may extend to the cavity of the joint, but the former also has proved fatal.

Of laceration of the parts about the affected joint the following case is an example. It was under the care of Malgaigne, is briefly referred to by him,¹ and is reported in full by Parmentier:² A man, thirty-four years old, with an intracoracoid dislocation of six months' standing. Three attempts to reduce were made, the traction in the last amounting to more than four hundred pounds, and the head of the bone being brought almost back to its place, but an attempt to force it into place by lateral traction with a bandage failed and even lacerated the skin on the posterior margin of the axilla. On the fifth day after the last attempt the patient complained of pain in the axilla, and the following day became delirious, and a large quantity of pus escaped through the laceration of the skin; trismus and tetanus followed, and death two days later.

The autopsy showed abscesses under and behind both pectoral muscles, in the substance of the coraco-brachialis and along its under surface, and communicating with the new articular cavity through a rent in its capsule.

The following case, reported by Mr. Jonathan Hutchinson,³ is even more striking. An elderly woman, drunk, was admitted with a dislo-

¹ Malgaigne: *Loc. cit.*, p. 168. ² Parmentier: *Bull. de la Soc. Anatomique*, 1852, p. 302.

³ Hutchinson: *Medical Times and Gazette*, 1866, vol. i. p. 304.

cation into the axilla ; an attempt to reduce failed. The next day she said the shoulder had been dislocated for several years, but she was not believed, and reduction was again attempted with the aid of chloroform by moderate manual traction directly outward and the knee in the axilla as a fulcrum ; the attempt was continued for ten minutes. Great inflammation followed, the joint suppurated, and the patient died. The autopsy showed a new articular cavity formed below and in front of the glenoid cavity. The soft tissues of the joint were wholly destroyed by suppuration, and every trace of cartilage removed.

An experience of Broca's shows that an unfortunate, even fatal, result may follow an apparently judicious and moderate attempt at reduction.

The patient,¹ a coachman, thirty-nine years old, entered the hospital for treatment six months after he had dislocated his left hip. Traction to the amount of more than five hundred pounds was made with Mathieu's apparatus without success, and the attempt was not repeated. No ill result appearing, the patient was discharged at the end of a week. A fortnight later he was admitted to another hospital with considerable swelling of the hip and peritonitis, and died on the following day. The autopsy showed a collection of pus occupying the old and new articular cavities, filling the external iliac fossa, infiltrating the gluteus medius, and in contact with the entire surface of the internal and external obturators and with the obturator foramen ; also a generalized peritonitis, much more marked in the true pelvis than elsewhere. The course of the lesion was thought to have been : inflammation of the new joint, extension to the old one, then to the obturator internus, and finally to the peritoneum. It was thought probable that the patient had resumed work immediately after leaving the hospital, and that this untimely use of the limb had provoked the suppuration.

In a few recorded cases the inflammatory reaction was so severe that the limb, or the affected segment thereof, became gangrenous. Dupuytren² reported a case in which, after reduction of a dislocation of the thumb by long and violent efforts, the thumb became gangrenous and separated at the metacarpo-phalangeal joint.

These cases are to be distinguished from those in which gangrene has been caused by injury to the vessels or nerves, as in La Motte's case,³ Weir's first case quoted in Chapter XXXIII., page 452, and probably in Delagarde's,⁴ in which, after reduction of an old dislocation of the shoulder, abscesses and points of gangrene formed in the limb and rendered amputation at the shoulder necessary.

Persistent œdema of the limb, a condition resembling elephantiasis, has been observed in a few cases in which unsuccessful attempts had been made to reduce old dislocations, apparently the result of interference with the venous flow. In a case of Malgaigne's, quoted by Velpeau,⁵ the œdema of the arm disappeared simultaneously with the development of numerous varicose veins in the arm and shoulder.

¹ Reported by Tillaux in Bull. de la Soc. de Chir., 1868, vol. ix. p. 266.

² Dupuytren : Quoted by Marchand, loc. cit., p. 129.

³ La Motte : Traité de Chirurgie, vol. iv. p. 343.

⁴ Delagarde : St. Bartholomew's Hospital Reports, vol. iv. p. 89.

⁵ Marchand : Loc. cit., p. 131.

Syncope and Sudden or Early Death; Fat Embolism. Beside the numerous cases already quoted in this chapter which show the dangers to the life of the patient that may arise in the course of an attempt to reduce a recent or an old dislocation, there are still others which indicate that life may be seriously threatened, or even destroyed, by other accidents or complications than the rupture of important vessels or nerves or excessive reaction and suppuration. In some of the fatal cases the failure to make an autopsy leaves the cause of death obscure, but the symptoms point to rupture of a vessel as a possible cause.

E. Bœckel¹ has reported a case the autopsy of which suggests another explanation, not only of some of the deaths by syncope, but also of some attributed to the anæsthetic.

The patient was a man fifty years of age, with a recent ilio-pubic dislocation, who was brought to the hospital after an unsuccessful attempt to reduce. Chloroform was given and reduction made in seven minutes; the patient grew pale, his respiration weakened and promptly stopped. The autopsy showed the heart to be atrophied, both pulmonary arteries plugged by non-adherent clots, rounded like emboli, in the medium-sized branches and those of the third and fourth order, and also *fat embolism* of the lungs very widespread and intense. The iliac and femoral veins were free, but there was a thrombus in the popliteal vein from which it was thought those in the pulmonary arteries had been broken off.

Before the use of anæsthetics, in the times when muscular resolution was sought to be obtained by measures which depressed and weakened the patient, and when the efforts to reduce were made with great violence and sometimes prolonged for hours, exhaustion of the patient habitually followed, and death was sometimes the consequence.

Death by the action of an *anæsthetic*, especially chloroform, is thought to occur in a larger proportion of cases of reduction of dislocation than of other operations, but no satisfactory explanation of the greater risk, if it actually exists, has been given. Of 134 cases of death by an anæsthetic collected by Marchand, in 17 the operation was the reduction of a dislocation; of these 11 were of the shoulder, 3 of the hip, and 1 each of the knee, elbow, and thumb.

¹ E. Bœckel: Mort subite par embolies pulmonaires, simulant la mort par le chloroform après réduction d'une luxation de la cuisse. Rev. des Sciences Méd., Oct. 15, 1881, p. 637.

CHAPTER XXXV.

CONGENITAL¹ DISLOCATIONS.

UNDER the term *non-traumatic* may be included all dislocations which exist at birth (*congenital*), although it is claimed that some of them are due to violence inflicted upon the fœtus in utero, or even during delivery, and those which appear subsequent to birth as the result of non-traumatic changes in one or more of the constituent parts of the joint ("spontaneous," "symptomatic," "inflammatory," "paralytic," "myopathic," "chronic," "tardy," "dislocation by distention," "by relaxation," "by destruction," "by deformity"), and those which may be reproduced at will by the individual, "voluntary."

The existence of dislocations (at least of the hip) in the new-born child, and their non-traumatic character, have been recognized since the earliest times, but the accurate study of the subject may be said to have begun in 1818, with Schreger, who examined post mortem two specimens in a girl two and a half years old and a woman of forty-eight. A few years later, 1826, Dupuytren brought the subject before the Académie des Sciences, and called attention especially to the facts that the affection was often inherited, and often bilateral. Since then the subject of congenital dislocation of the hip has been actively studied by many, and the similar but much rarer affections of other joints have received due attention.

Statistics. Dislocations have been observed at birth in many joints, but not only do those of the hip far exceed all others in number, but the latter are actually, as well as relatively, so rare that their statistics have not much value. Next to that of the hip the most common dislocation is apparently of the shoulder, and then that of the head of the radius. Krönlein says that the records of Von Langenbeck's Polyclinic show 90 congenital dislocations of the hip, 5 of the shoulder, 2 of the head of the radius, and 1 of the knee. It is not exceptional to find several dislocations present in an individual, or one or more dislocations associated with such congenital defects as spina bifida, club-foot, ventral hernia, encephalocele, and exstrophy of the bladder.

As will appear in studying the etiology of this affection, the statistics of congenital dislocation of the hip include cases widely different in their origin, and even some which are acquired and not congenital, that is, some which have been produced during the first few months of life, perhaps before the patient began to walk, by the unopposed action of certain groups of muscles after paralysis of others. It seems prob-

¹ The use of the term *congenital* to classify certain dislocations is objectionable for several reasons, which will appear in the course of the discussion of the subject. It includes forms that radically differ in their etiology and pathology, but as these forms cannot well be distinguished from one another during life, a classification based upon other points cannot be realized in practice, but must be confined to the dead-house and museum.

able, however, that the error thus arising is not a large one, but still, for this and for other reasons, I shall here quote only the more recent statistics, believing them to be the most nearly correct. These are Drachmann's,¹ Pravaz's (quoted by Krönlein), and Krönlein's.²

CONGENITAL DISLOCATIONS.

	Period.	Cases.	Male.	Female.	Single.		?	Double
					Left.	Right.		
Drachmann	1865-1880	77	10	67	24	24	29
Pravaz	1863-1878	107	11	96	27	29	51
Krönlein	1875-1880	90	14	76	32	22	5	31
Total	274	35	239	83	75	5	111

Prahl's³ are not given in sufficient detail to be included in the table; they comprise 18 cases; 3 were males, 15 females, making with those in the table a total of 292, of which 38 were males, 13 per cent., and 254 females, 87 per cent. Angot⁴ says that of about 20 cases observed by him at the Hôpital des Enfants malades in 1882, all were girls. Of 11 cases of congenital dislocation of the knee collected by Hibon,⁵ 7 were girls, 3 boys; and in 1 the sex was not recorded; of these, 3, 1 girl and 2 boys, were stillborn, and presented other very marked deformities.

Etiology.

The discussion of this branch of the subject, which was taken up with much interest after the publication of Dupuytren's memoir, was not fruitful of positive results because of the lack of anatomical material and minute examination, and of failure distinctly to discriminate between different forms and between the original bony defects and the changes produced by the long use of the deformed limb. Since the affection is one which often escapes recognition until the child begins to walk, it was sometimes confounded with dislocations resulting from infantile paralysis, and as it is one which does not destroy life the opportunities for direct anatomical investigation were almost entirely restricted to two classes of cases, the stillborn and those that died shortly after birth in consequence of other important congenital defects, and those in which the original changes had been masked or supplemented by subsequent ones produced by the further displacement of the head of the femur and its abnormal relations to the adjoining parts. In the former, incorrect inferences were drawn from the associated defects, as when the irritation of an over-full urinary bladder or the separation of the symphysis pubis was deemed the immediate cause of

¹ Drachmann: Schmidt's Jahrbüch., 1881, vol. clxi. p. 170.

² Krönlein: Deutsche Chirurgie, Lief. 26, p. 82.

³ Prahl: Inaug. Dis. Breslau, 1880. Abst. in Centralblatt für Chir., 1881, p. 57.

⁴ Angot: Luxations congénitales de la hanche. Thèse de Paris, 1883, p. 11.

⁵ Hibon: Luxations congénitales du tibia en avant. Thèse de Paris, 1881, p. 7.

the arrest of development of the acetabulum; and in the latter the attention was led far astray by prominent changes in the bones. The history of the theories advanced has not only an historical value, but it serves also to indicate certain varieties and prominent features of the affection, and therefore I append the following résumé made by Krönlein. It must be remembered that most of the theories deal exclusively with dislocations of the hip.

1. *The so-called congenital dislocation is traumatic, and arises :*

a, through external violence acting upon the fœtus in utero, or through the action of the muscles of the fœtus itself. Hippocrates and the early writers held that mechanical injuries of the belly of the mother could produce dislocation in the fœtus. Cruveilhier did not entirely reject this theory in some cases. Chatelain, Kleeberg, Zielewicz, even specify in their three cases the injury, a fall in the seventh month, which, in their opinion, had caused the dislocation. Chaussier claims even that a dislocation can be caused by the contraction of the muscles of the fœtus, and narrates in support the case of a young woman who, during the ninth month of pregnancy, felt on three occasions such violent movements of the child that she almost became unconscious. When delivery took place at term, the child had a complete dislocation of the left forearm.

b, during delivery.

Capuron (1834) held that some congenital dislocations of the hip had been produced during delivery, by traction with the finger on the groin in breech-presentations.

2. *Congenital dislocation (of the hip) is a spontaneous dislocation, and is occasioned :*

a, by softening and laxity of the ligamentous portion of the joint (Sédillot, 1836). This opinion was held in part by Stromeyer (1840).

b, by fœtal hydrarthrosis (Parise, 1842) or other joint affections, such as fungous synovitis with effusion (Verneuil and Broca), or caries and destruction of the capsule (Morel Lavallée, Albers, Von Ammon).

3. *Congenital dislocation (of the hip) is due to the peculiar position of the lower limbs of the fœtus in utero.*

a, it is possible that in the strongly flexed position of the hip the pressure of the head of the femur upon the posterior or lower portions of the capsule may, when the latter is abnormally weak cause dislocation (Dupuytren, 1826).

b, congenital dislocation of the hip is due to abnormal adduction of the thigh in utero, to a compressed position of the fœtus due to deficiency in the amount of the amniotic liquid (Roser, 1864).

4. *Congenital dislocation of the hip, like most congenital deformities of the joints, such as club-foot, wry neck, and spinal curvature, is the result of primary muscular contraction, which is itself to be regarded as the result of an affection of the central nervous system (J. Guérin, 1840, and, following him, Chaussier, Melicher, Mercer-Adam, Carnochan, Erichsen, and others).*

5. *Congenital dislocation of the hip is often only the last stage of a*

paralysis and consequent atrophy of the pelvic-trochanteric muscles. This foetal paralysis leads gradually to relaxation of the ligaments, and this, often only after the lapse of time, and especially after the children have begun to walk, and by the action of the weight of the body, to dislocation (Verneuil, 1866). This theory has recently (1878) been brought forward again by some of Verneuil's pupils (Reclus, Dalby), and extended to congenital dislocations of the humerus (Kirmisson).

(Krönlein in this fails accurately to define the position of the supporters of this theory. Their contention is not so much that congenital dislocations are thus produced, but rather that some so-called congenital dislocations originate after birth in a paralysis, and are mistakenly thought to have been congenital. Reclus¹ formulates his conclusions as follows :

a. From the group of so-called *congenital dislocations paralytic* dislocations must henceforth be withdrawn.

b. These dislocations follow "amyotrophies," and may appear at any age, although they have rarely been seen except in infancy.

c. For their production two conditions are necessary—atrophy of a muscular group ; integrity of its antagonists.

d. At the hip the iliac dislocation is the most common. It is due to the contraction of the adductors, which is unopposed because of the atrophy of the gluteal and pelvi-trochanteric muscles.)

6. *Congenital dislocation of the hip is due in most cases—and these should be regarded as typical—to a defect of formation or development,* which prevents the joint from assuming the normal shape. This very generally held theory was presented by Palletta, and then taken up and specially developed by Schreger, Dupuytren, Breschet, Von Ammon, and others.

Schreger emphasizes the fact that so-called congenital defects are not produced by an abnormal change in pre-existing, normally formed parts, but are due to defective formation or arrest of development, and that is especially true of congenital dislocations of the hip.. Dupuytren and Breschet suggest a delayed development of the three pelvic bones forming the acetabulum. Von Ammon,² in his remarkable work, expresses himself very clearly concerning congenital dislocations, which he terms *dysarthroses congenitæ*. "Even if their external appearance," he says, "corresponds somewhat with that of dislocations acquired after birth, yet in their method of formation they differ essentially from them, and they also have only the slightest resemblance to those secondary dislocations that follow joint disease. . . . In many cases there is in part the greatest certainty, and in part the greatest probability, that the affection depends upon an arrest of the constituent parts of the joint at an earlier foetal stage of development. According to him, a congenital dislocation is an arrest of development. The acetabulum does not develop into the usual, symmetrically rounded, deep socket, but retains its earlier saucer shape ; while the head of the femur, continuing to grow, becomes too large for the small acetabulum, and no longer suitable to lodge in it.

¹ Reclus : *Revue Mensuelle de Méd. et Chirurgie*, 1878, p. 88.

² Von Ammon : *Die angeborenen chirurgischen Krankheiten des Menschen*, 1842, p. 9.

Von Ammon recognized not only this typical form of congenital dislocation but also the other varieties that had been described by other authors, and quoted cases and reproduced drawings in illustration of them. So far as the typical form is concerned, but little has been added since his time to our knowledge of its pathogeny, and that little is contained in a paper published by Grawitz¹ in 1878, who, by microscopical examination of twelve specimens of congenital dislocation in seven new-born children, showed that the arrest of development consisted in a failure of the Y-cartilage of the acetabulum to carry on the growth of one or all of the three segments of the os innominatum. He found, in his first case, for example, the acetabulum only as large as that of a fetus of about the fifth month, and the Y-cartilage broader than usual because of diminished ossification of the three adjoining bones, the pubis, ischium, and ilium. The cartilage was hyaline and vascularized, and with normal, elongated cells containing one, two, or three nuclei. On comparison with sections of a normal pelvis of the same size, a striking difference appeared at the junction of the bone and cartilage. The formative zone in all three epiphyses was very imperfect, its cells scanty and widely separated, and the zone of cells arranged above one another in rows adjoining the line of ossification was not one-third as wide as it normally is, and the arrangement of its cells was irregular and broken. In some of the cases the Y-cartilage was centrally interrupted by an interposed wedge of embryonal adipose tissue. On the other hand, the appearances in the femur were those of normal growth, except in one case. In no case was there premature ossification of the Y-cartilage, such as had been alleged shortly before by Dollinger² in explanation of the same affection.

The conclusion, I think, cannot be avoided that while in a limited number of cases dislocations existing at birth, especially in joints other than the hip, may have been caused by traumatism, abnormal position of the limb, or paralysis in the manner alleged by various writers, yet in the great majority of congenital dislocations of the hip the cause is to be found exclusively in arrest of development of the acetabulum by deficient action or vitality of the cells of the Y-cartilage. And to the testimony in support of this opinion furnished by anatomical examination of specimens may be added that drawn from clinical observation, such as the coexistence of other deformities due to arrest of development, the frequency of double and multiple dislocations, the inherited tendency to the affection, and its great predominance in females.

Many of the congenital dislocations of other joints than the hip must also be regarded as due to defective formation of the corresponding bones, but the defect apparently is rather a malformation than the result of an arrest of the development of one of the bones constituting the joint. At the elbow, in dislocation of the head of the radius, this bone is sometimes found relatively, and even actually, longer than the ulna. In a specimen taken from an adult, pictured by Humphry³ (Fig. 260), of dislocation of the head of the radius forward and

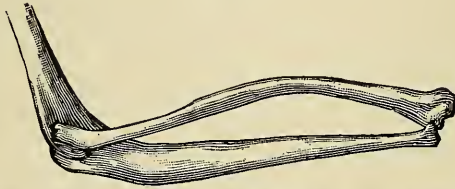
¹ Grawitz: *Virchow's Archiv*, 1878, vol. lxxiv. p. 1.

² Dollinger: *Arch. für klin. Chirurgie*, 1877, vol. xx. p. 622.

³ Humphry: *Medico-Chirurgical Transactions*, vol. xlv. p. 296.

upward, there was ankylosis of the joint between the ulna and humerus, and the lower third of the ulna of the other arm was lacking.

FIG. 260.



Congenital dislocation of the head of the radius upward and forward, with exaggerated growth in length.

In some dislocations of the knee characterized by hyper-extension of the leg upon the thigh the cause appears to have been muscular contraction.

Of the other etiological varieties that have been asserted to exist, one at least seems to have been proved by direct examination to exist, that in which the dislocation follows distention of the capsule and ligaments by dropsy of the joint during intra-uterine life.

Pathology.

The opportunities for studying the pathology of congenital dislocations other than those of the hip have been so very rare, and the study of those that exist has been made so uncertain by the doubtfulness of the diagnosis in some and the difficulty in distinguishing between primary and later changes in others, that but little can be positively said concerning them. In studying specimens of dislocation of the hip it is necessary, as Gurlt pointed out, to distinguish between those obtained from very young children who have never walked, those from older children whose growth was not completed, and those from adults.

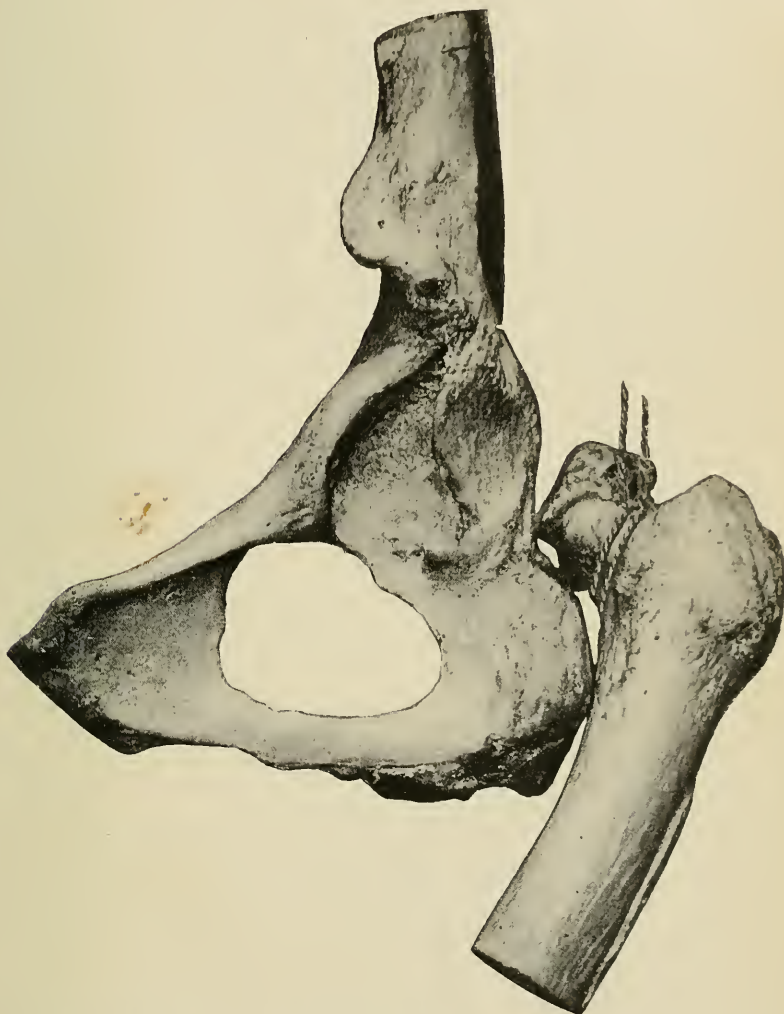
Hip. The common form is dislocation upon the dorsum of the ilium; the only exceptions, and they are extremely rare, are upon the pubis and into the obturator foramen.

In the new-born child with a dislocation the acetabulum is smaller and flatter than normal, and is continuous by its flattened posterior border with another articular surface or new acetabulum lying above and behind the original one. Usually, too, the head of the femur is smaller than normal, although still too large for the acetabulum, and the neck short or almost absent; sometimes the head and neck together have a conical pointed form. The ligamentum teres is long and flattened, the capsule is complete, and embraces both the old and the new acetabulum. The microscopical changes have been described above.

The mechanism of the alteration seems plain; as the femur and its socket originally are developed out of one continuous strip of tissue, they are at first in normal relations to each other, but when the development of the acetabulum goes on more slowly and imperfectly than that of the head of the femur the latter becomes relatively too large, and being no longer firmly held in place it is gradually drawn backward and

upward by the continuous action of the attached muscles, the corresponding edge of the capsule is pressed away from the cotyloid border, and a new articular surface is formed at the point where the head of

FIG. 261.



Innominate bone and femur from a case of congenital dislocation of the hip, after operation for formation of a new acetabulum. (BRADFORD.)

the femur comes to rest. Meanwhile, the defective development of the original acetabulum persists, and its variation from the normal is probably still further increased by the absence from it of the femur. The remaining bones and the muscles, not being put to sufficient use to feel the effect of the changed relations in the joint, suffer no change unless involved in some associated defect of development.

But as soon as the child begins to walk this change in the relations of the bones and muscles to each other makes itself felt, and, as the local developmental weakness persists, two factors are now at work to remove the condition of the parts still further from the normal. The acetabulum by its continued failure to share equally in the growth of the pelvis, becomes relatively smaller and more deformed, the head of the femur is removed still further from it, and becomes deformed in consequence of its irregular bearings upon the surface of the ilium; the ligamentum teres becomes longer, flatter, and thinner, and the capsule thick and strong, and its cavity commonly larger than usual. As the individual advances in life, and after puberty has been reached, the ascent of the femur is finally arrested, partly by the formation of a socket, and partly by the resistance of the capsule and the muscles. The elements of support then resemble in a measure those sometimes found with ununited fracture of the neck of the femur, and the pelvis, instead of resting directly upon the femur, is suspended from it by the capsule, ligaments, some of the pelvi-trochanteric muscles, and even by the psoas-iliacus, the tendon of which, instead of passing downward, curves around the brim of the pelvis, and passes upward, outward, and backward to the lesser trochanter, which is now at a higher level than the acetabulum.

The head of the femur may be separated from the ilium by the interposed capsule, so that the support is entirely by suspension, and there is no real joint, one in which bony surfaces covered with cartilage play upon each other; or the upper and posterior attachment of the capsule may still be found above the head of the femur, upon an overgrowth of bone springing from the ilium and forming the upper part of a new socket, the remainder of which is constituted by the body of the ilium. The latter bone sometimes shows at this point an overgrowth of bone, and sometimes a depression with a corresponding thickening on the opposite, inner surface. In the former of these two last-named conditions, it seems probable that the capsule has been for a time interposed between the femur and the ilium, and has finally disappeared at this point under pressure, the irritation of which has caused the outgrowth of bone before its periosteum has in turn disappeared; in the latter, it is probable that the attachment of the capsule has been pushed back step by step, leaving a bare surface of bone which has worn away under the pressure of the femur, or by absorption; while the associated irritation has led to a conservative thickening on its other side. The communication between the cavity of the capsule about the head and the acetabulum is through a narrowed portion, so that the whole is like an hour-glass. The old acetabulum is narrow and elongated, running upward and backward; the ligamentum teres perhaps destroyed by over-stretching.

The entire pelvis is also changed in shape by the abnormal direction of the pressure to which it is subjected in walking. If the dislocation is unilateral, the crest of the ilium on the corresponding side is carried inward, and the tuberosity of the ischium outward, the horizontal branch of the pubis is elongated, and its direction from the symphysis is more upward and backward; the anterior superior spine of the ilium

PLATE XLIII.

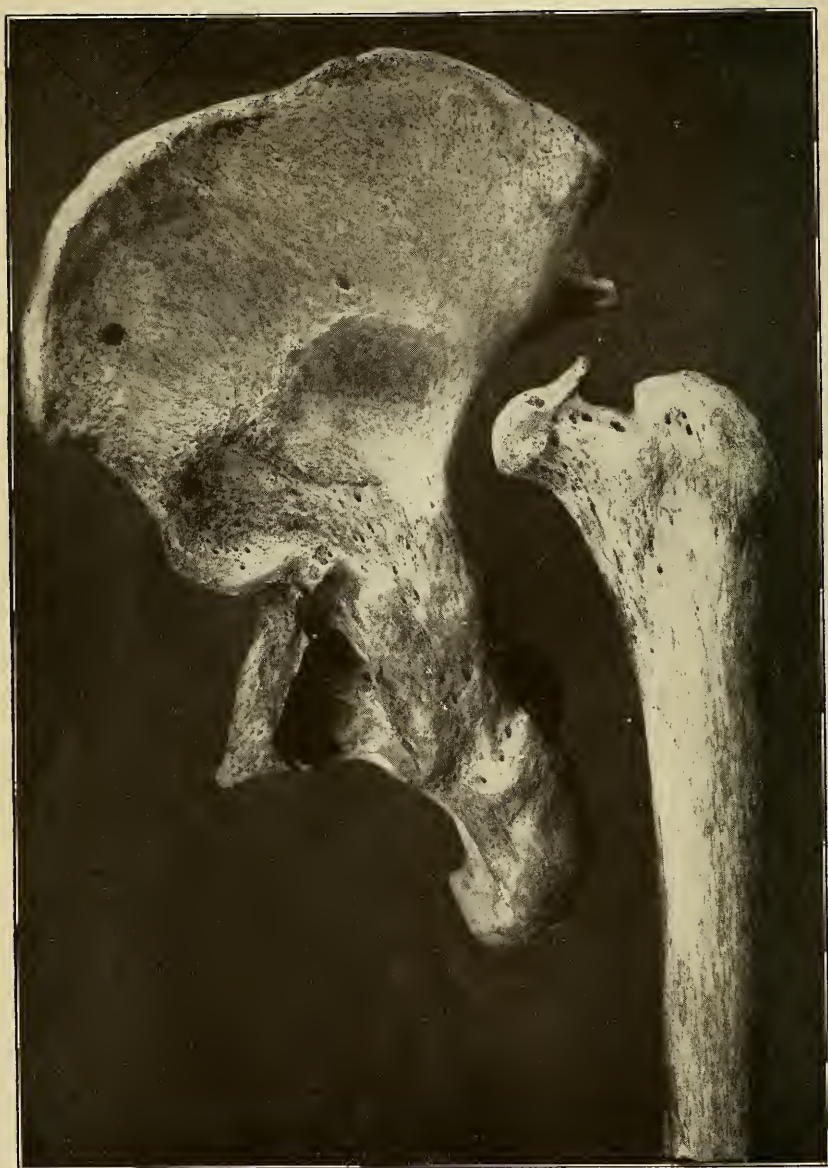

Fig. 1.—Congenital Dislocation of the Hip; girl three years old.



Fig. 2.—Dislocation of Semilunar Bone.

PLATE XLIV.



Congenital Dislocation of the Hip.

is displaced inward and backward, and, in short, the entire bone undergoes a change in shape which carries its centre upward and backward, and makes its lateral surface more vertical.

If the dislocation is double, the same changes are found on both sides, and the sacrum is more sharply curved.

Congenital dislocation of the shoulder may be either subcoracoid, sub-acromial, or subspinous. R. W. Smith,¹ who was the first to describe them, gives examples and plates of the first two forms. He found the original glenoid cavity lacking or rudimentary, and the new one well developed either immediately under the coracoid process or on the outer side of the scapula below the acromion. Most of the cases described as such appear to be traumatic (during delivery) or paralytic. (See Chapter XLIV.)

At the elbow the head of the radius may be displaced upward along the anterior surface of the humerus, or backward, or inward so as partly to overlap the coronoid process of the ulna.

Symptoms and Diagnosis.

The symptoms of congenital dislocations differ very widely from those of the traumatic variety, and not only by the absence of symptoms peculiar to a traumatism, but also in the signs recognizable by palpation, and in the posture and mobility of the limb. In general terms, the dislocation is to be recognized by an examination which determines the abnormal position and altered shape of the corresponding ends of the bones and the range of motion, and by consideration of the history of the case.

In **dislocations of the hip** the changes are very likely to pass unnoticed until after the child has begun to walk, because during this first period they are usually too slight to attract attention, and because an examination for their detection is not likely to be made unless it is suggested by some special reason, such as coexisting malformations, or the history of similar defects in other members of the family. Even after the child has begun to walk, the defect may long remain unrecognized if both hips are affected, because, the deformity of the regions and the shortening of the limbs being symmetrical, they do not attract much attention. Nevertheless, the changes are so characteristic that when an examination is made the diagnosis cannot well remain in doubt.

When the dislocation is unilateral and of the common dorsal variety, the patient limps because of the shortening of the affected limb; and for the same reason the spine shows a lateral curvature, which can be removed by supporting the foot at the proper height. Because of the passage of the head of the femur backward and upward upon the ilium, the pelvis is tilted so that its upper portion is directed forward, and a marked anterior curvature of the lower portion of the spinal column is produced, which disappears when the patient is recumbent.

Inspection and manipulation reveal the ascent of the trochanter, and the head of the femur may sometimes be distinctly recognized. The shortening may be slight, moderate, or very great, and can sometimes

¹ R. W. Smith: Dublin Medical Journal, 1839, vol. xv. p. 261.

be notably increased by pressing the limb upward. Usually the gluteal muscles and those of the thigh are less developed than those of the opposite limb. The movements of the joint are even more free than normal, except perhaps in abduction, but when voluntarily performed they are more or less lacking in precision and firmness.

FIG. 262.

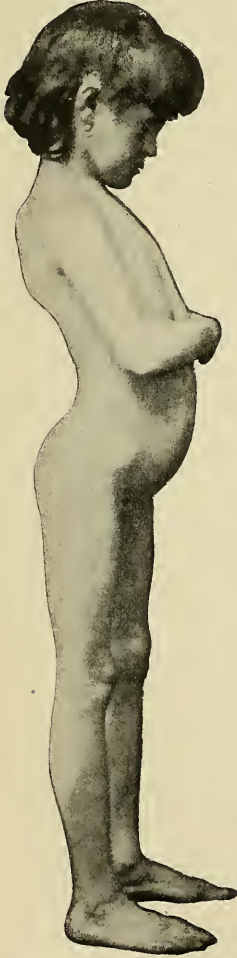
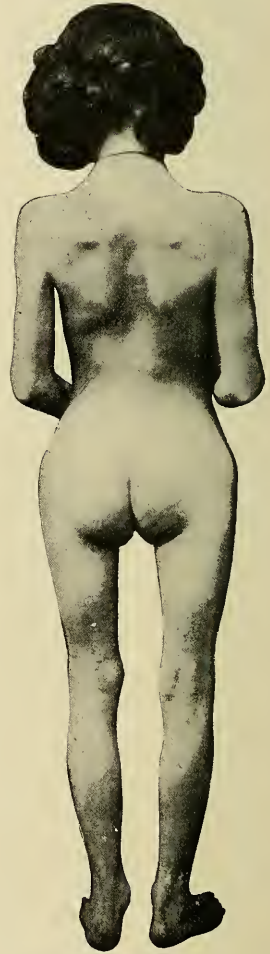
FIG. 263.



Double congenital dislocation of the hip.

When the dislocation is bilateral, the patient walks, not with a limp, but with a peculiar characteristic waddle, which sometimes amounts to a double limp and makes progression difficult and uncertain. The upper part of the pelvis is sharply inclined forward, producing the same lordosis that is found in unilateral dislocation, but without the lateral curvature unless there is a difference in the amount of the defect

on the two sides. The arms appear unusually long, and are sometimes exceptionally muscular. Often the deformity increases with time, and the patient has repeated attacks of pain; in some the flexion and adduction are such that the disability is great.

At other joints, such as the shoulder, elbow, and knee, the position of the bones and the changes in their shape can usually be easily made out.

Prognosis.

The prognosis in all dislocations, except that of forward dislocation (hyper-extension) at the knee, is unfavorable, so far as reduction is concerned.

Treatment.

Until within a few years treatment of congenital dislocations of the hip was practically limited to palliative measures, such as a thick sole in unilateral cases and girdles and corsets which mechanically opposed the tilting of the pelvis and the ascent of the trochanter under pressure, and to continuous traction maintained for months and followed by the use of traction-splints in both unilateral and bilateral cases. By these means the functional condition in many cases appears to have been greatly improved, and much of the improvement to have been maintained.

Lannelongue¹ sought by periosteal irritation to create a buttress of bone upon the ilium which would prevent the ascent of the femur after it had been brought down by traction. He produced this by injection through a hypodermic needle of twenty drops of a 10 per cent. solution of chloride of zinc at several points in the periosteum close above the head of the femur.

Between 1890 and 1900 much attention was given to operative reduction, or fixation, with the formation of a new acetabulum or enlargement of the existing one. Since then this has largely given place to the so-called "bloodless operation" of which Lorenz is so well known an exponent. The literature of the subject is abundant; the reader may advantageously consult articles by Dr. E. H. Bradford and Dr. T. H. Myers in the *Annals of Surgery*, August, 1894, and by Warbasse in the same, June, 1895.

The earlier operative methods exposed the capsule by a lateral (Hoffa) or anterior (Lorenz) incision; then the muscles were separated from the great trochanter, the flexors of the leg divided subcutaneously near the tuber ischii, the abductors near the pubis, the tensor vaginæ femoris by open incision, and the rectus femoris through the first incision. The capsule was opened, and generally detached freely from the femur, the head turned out, and the acetabulum enlarged, or a new one made, by chiselling.

The mortality of the operation was quite serious, and Lorenz² has sought to do away with the division of the muscles. In children not

¹ Lannelongue: *La Semaine Méd.*, December 30, 1891.

² Lorenz: *Volkmann's klin. Vorträge*, 1895, No. 117, and Warbasse, in *Annals of Surgery*, June, 1895.

over five years old, when the femur can be drawn well down, he makes a three-inch incision downward and outward from the spine of the ilium, divides the fascia lata along it and also backward, divides the capsule in front, deepens the acetabulum, and puts the head of the femur in place. In children between six and eight years, when the femur cannot be brought fully down, he exposes the capsule in the same manner while strong traction is made in slight abduction against counter-traction by a perineal band, and after division of the capsule continuous traction until the head is brought down. In cases over nine years of age, with marked shortening and slight mobility downward, preliminary traction by about thirty pounds is made for a fortnight; then continuous forcible traction is made during the operation, and the capsule is divided along the long axis of the neck and transversely near the ilium. It is important to make a deep excavation with a sharp upper margin for the new acetabulum. The limb is fixed in slight abduction for a month, and then massage and passive motion are begun.

Myers recommends for old, deformed, or painful cases Kirrison's subtrochanteric osteotomy, or Hoffa's new operation of removal of the head and neck and of the posterior portion of the capsule, the limb being then dressed in abduction to insure close contact between the trochanter and ilium.

The "bloodless method" (Paci and Lorenz) consists in bringing the head opposite the acetabulum by forcible extension and abduction of the thigh and retaining it there for several weeks by a plaster spica. For the details the reader may consult among many others an article in the *N. Y. Med. Journal*, Dec. 6, 1902, p. 970. It is undisputed that many excellent functional results have been obtained by this means, although the anatomical conditions remain very different from the normal.¹ Joachimsthal² showed a series of skiagrams taken one or two years after reduction which indicated that the rim of the acetabulum and the head and neck of the femur had notably increased in size.

Congenital dislocations of other joints, except the knee, have rarely received any treatment. A few backward dislocations of the shoulder have been reduced by open operation, not a difficult task in a case of my own, for the glenoid fossa was well formed and contained within the capsule of the existing joint. (See Chapter XLIV.)

In dislocations of the tibia forward, with extreme hyper-extension of the knee, a complete cure can usually be effected by forcible straightening of the limb and retention for a short time by splints.

¹ Schede: *Centralblatt für Chirurgie*, 1900, p. 740.

² Joachimsthal: *Beilage zum Centralblatt für Chirurgie*, 1904, p. 164.

CHAPTER XXXVI.

SPONTANEOUS DISLOCATIONS.

THESE are dislocations which have occurred without the intervention of a recognizable traumatism. It is generally held that some of the constituent parts of the joint must have previously been so altered by disease as to facilitate the occurrence; but while this preliminary change does doubtless occur in the great majority of cases, yet there is reason to think that spontaneous dislocation may take place without it, through the continuous action of the muscles, when the limb has been long kept in a favorable position. Roser¹ says he has seen, in three cases, spontaneous dislocation of the hip produced by the reflex muscular contractions excited by pressure on the anterior portion of the spinal cord in patients affected with kyphosis and consequent paralysis. The dislocations occurred slowly, without pain or swelling of the region, and without a sign of coxitis.

The term "spontaneous," although not entirely free from objection, is in general use, and is usually preferred to others that have been proposed, such as *pathological*, *symptomatic*, *inflammatory*, and *consecutive* or *secondary*. Volkmann² has classified them according to the primary changes which precede and facilitate their occurrence, as dislocations, 1st, by distention; 2d, by destruction; 3d, by deformity; including in the first those cases in which the joint has become loose through distention of its capsule and ligaments by an effusion within it, as in the eruptive fevers, rheumatic fever, pyæmia, and the puerperal state; in the second those in which the shape of the articular end of the bone has been changed by caries, as in hip-joint disease; and in the third those in which the shape has been changed by non-suppurative disease, as in arthritis deformans. To these may be added a 4th class, seen mainly in adolescents, in which the shape or growth of the bone has been so modified by the effects of pressure, muscular effort, or gravity that a permanent displacement takes place; and a 5th, "paralytic" or "myopathic," in which the dislocation is made possible by paralysis of some or all of the articular muscles, and is sometimes effected by the contraction of those which have not been paralyzed.

Although the propriety of applying the term dislocation to a change in the relations of two bones whose corresponding articular portions have already been destroyed has been questioned, and although the change of place does not come within the definition of dislocation previously given, and although the condition has but little in common with traumatic dislocations, either in symptoms or in treatment, yet the term has been almost universally accepted and retained in preference to the proposed substitutes.

¹ Roser: Centralblatt f. Chirurgie, 1885, p. 569.

² Volkmann: Pitha and Billroth's Chirurgie, vol. ii. part ii. p. 658.

In all these varieties the immediate cause of the dislocation is the action of gravity or muscular contraction.

Dislocations by Distention (Volkmann). Concerning the pathology of this class but little is known by direct examination, because of the lack of autopsies, but the clinical history is well established. The joint by far the most frequently involved is the hip; a few cases have been observed at the shoulder and knee. In the most common form the course of the symptoms is as follows:¹ A patient is attacked by febrile articular rheumatism or acute mono-articular arthritis; the pain is great, the limb assumes a faulty position; after a few days the pain suddenly ceases, and on examination the region of the affected joint is found to present a deformity similar to that which characterizes a traumatic dislocation. If the condition is left without treatment, the inflammation comes to an end without leaving either osteitis or suppuration, but with persisting deformity; if, on the other hand, the dislocation is reduced, the deformity is thereby entirely removed, and in time complete recovery is obtained.

In other cases the dislocation takes place in the course of some of the eruptive fevers or other febrile condition, sometimes without previous notable pain in the joint and without the knowledge, at the time, of the patient. William W. Keen² collected eighty-four cases of arthritis occurring as a complication of typhoid and typhus fever, in forty-three of which dislocation took place, forty times at the hip, twice at the shoulder, and once at the knee. It is noteworthy that thirty-two out of thirty-five patients were under twenty years of age.

It thus appears that these dislocations resemble those that are traumatic in their sudden occurrence, the absence of any lesion of the bones, and the possibility of immediate and permanent reduction with complete restoration of function.

The presence of a large effusion in the joint and the elongation of the ligaments have been assumed by all observers, and the actual presence of an effusion of some amount has been demonstrated in some of the exceptional cases, knee and shoulder, where such demonstration was possible. On the supposition of this effusion and of the relaxation of the ligaments produced by it, the production of the dislocation has been explained. Verneuil has further called attention especially to the unopposed contraction of certain muscles as the immediate cause.

If it is remembered that at the hip these dislocations are always backward upon the dorsum of the ilium, and are preceded by the long maintenance of the limb in the position of flexion, adduction, and inward rotation which so greatly favor the occurrence of this dislocation, and that the muscles are stimulated to contraction by the pain of the arthritis, it does not appear improbable that this contraction is not only the immediate but also the preponderant cause of the accident, and that the arthritis favors it not by overstretching the ligaments but only by supplying an amount of liquid that removes the obstacle created by atmospheric pressure. These two conditions, pain and effusion,

¹ Verneuil: *Bull. de la Soc. de Chirurgie*, 1883, p. 781.

² Keen: *Surgical Complications and Sequelæ of Typhoid*, 1898,

would explain why the dislocation does not also occur in the course of adynamic diseases in which the limb often remains for a long time in the flexed position.

Certainly the theory of the production of the dislocation by simple overdilatation is incompatible with the easy reduction and maintenance of the reduction noted in several cases. It was unfortunate for some of the patients that their surgeons held to this theory, and were logical enough to refrain from attempting reduction and to leave the patients permanently crippled.

A few cases have been observed in which an acute purulent arthritis has been followed by dislocation; but in such cases it is always possible that the capsule has been in part destroyed by the suppuration.

Paralytic or "myopathic" dislocations are observed especially at the shoulder. The humerus is held up and kept in contact with the glenoid cavity by the tonicity of the attached muscles, and when this tonicity fails the weight of the limb causes separation of the bones and subluxation or complete dislocation. The cavity of the joint, thus enlarged, is filled by an effusion, but this effusion is the consequence of the separation rather than a favoring, precedent, and causative condition, for it is presumably drawn from the surrounding tissues by suction, just as œdema appears under a dry cup.

At the hip they are produced by the unopposed contraction of those muscles which have not been paralyzed. In Roser's three cases of spinal caries, mentioned above, the dislocation was dorsal, and the immediate cause was the contraction of the adductors no longer opposed by the pelvic-trochanteric muscles. The opposite form, dislocation upon the pubis, due to paralysis of the adductors and the consequently unopposed contraction of the muscles on the outer side and back of the hip, has been reported by Bradford¹ and Reclus.²

Another variety may be mentioned, in which by the *unequal growth of parallel bones*, the tibia and fibula or the radius and ulna, one of them is slowly dislocated.

Voluntary dislocations is the name given to those which the individual can produce and reduce at will. Those in which the peculiarity has originated in a previous traumatic dislocation are due to rupture of some of the ligaments or attached muscles and have been described among the consequences of traumatic dislocations; but a number of cases have been recorded in which this cause could not be invoked in explanation. I have seen two such, both of the hip.

Dislocations by destruction and **dislocations by deformity** are of less practical interest to the surgeon because less amenable to treatment, and are to be regarded rather as incidents in, or symptoms of, other diseases than as morbid entities.

In the former, *dislocations by destruction*, Volkmann included those dislocations which occur in the course of chronic tubercular disease of joints or as a consequence of acute traumatic suppurative arthritis. Frequent examples are seen at the hip and knee.

In consequence of the destruction of the articular ligaments or of

¹ Bradford: Boston Medical and Surgical Journal, 1883, vol. cviii, p. 73.

² Reclus: Revue de Méd., et de Chir., 1878, p. 176.

the bones themselves an abnormal mobility is created which allows the bones readily to be displaced by the action of gravity or by muscular contraction. At the hip this displacement is usually upward and backward; at the knee the well-known subluxation of the tibia backward or upward is produced by the contraction of the hamstring muscles, or, if the patient lies long upon one side and the destruction is well advanced, the displacement may be lateral to the distance of an inch or even more.

In the latter, *dislocations by deformity*, Volkmann included the dislocations which occur in the course of such affections as the *morbis coxae senilis* and in the arthropathies of nervous origin, "Charcot's disease," in which the articular ends of the bones disappear by absorption without suppuration.

The remaining form has been specially studied, so far as I know, only by Madelung,¹ and only at the wrist; the dislocation was always of the carpus forward, and was accompanied by marked changes in the shape of the radius and of the bones of the first row of the carpus. The cause appeared to be overexertion, or, rather, prolonged and frequently repeated exertion in patients who, presumably, were predisposed to the change by defective vitality of the bones. Volkmann includes such cases under the general head of *disturbances of growth of joints*.²

¹ Madelung: Deutsche Gesellschaft für Chirurgie, 1878, p. 259, and Arch. f. klin. Chir., vol. xxiii.

² Volkmann: Loc. cit., p. 692.

CHAPTER XXXVII.

DISLOCATIONS OF THE LOWER JAW.

DISLOCATIONS of the lower jaw constitute from 3 to 6 per cent. of all dislocations according to the tables in Chapter XXVII. They may be *bilateral* or *unilateral*, the former being the more common, in the proportion of about 5 to 2 according to Malgaigne, who found 54 bilateral in a total of 76 cases which he collected. Of these 54, 31 were in women, and this greater frequency in the female sex is universally recognized. The injury is rare in infancy and old age; it has been observed in patients eighteen and seventy-two years old, and has been caused in the new-born child by obstetric manipulations.

In the great majority of cases the dislocation is forward, the condyle of the jaw passing in front of the articular eminence at the root of the zygoma. A few instances have been reported of double or single dislocation backward with fracture of the wall separating the articular cavity from the external auditory canal, of dislocation upward into the cavity of the cranium, and of unilateral dislocation outward with or perhaps without, fracture of the body of the jaw. These are, however, entirely exceptional and may be briefly described before proceeding to the consideration of the common form.

Dislocation Backward with Fracture.

Dislocation backward with fracture of the posterior wall of the articular cavity is caused by great violence received upon the chin and acting from before backward. One or both condyles may be driven through the wall into the external auditory canal, breaking the bone and lacerating or pushing backward the outer cartilaginous portion. The production of the lesion is probably easier when the molar teeth are lacking from the upper or lower jaw, or if the mouth is partly open when the blow is received. The symptoms are pain in, and bleeding from, the ear, immobility of the jaw, the mouth being held partly open, and displacement backward, as shown by the relations of the front teeth to each other. The absence of the condyle from its normal position can be recognized by the touch, and the auditory canal is seen or felt to be obstructed by the displacement of its anterior wall.

Dislocation Upward.

Le Fèvre¹ reported an interesting and very exceptional case in which the injury was caused by a fall from a height, the blow being received upon the chin. The jaw was displaced slightly backward and to the left, the teeth were close together, and the mouth could not be opened. Slight bleeding from the left ear. The diagnosis of fracture of the condyle was made. The patient was dismissed in the fourth

¹ Le Fèvre: *Journal Hebdomadaire*. 1834, vol. iii. p. 333.

week, still experiencing difficulty in mastication and deglutition. Subsequently he suffered from violent headache, had several attacks of convulsions, and died about six months after the receipt of the injury. The autopsy showed that the roof of the glenoid cavity had been fractured, the condyle had passed into the cranium between the fragments, the neck of the condyle was in part destroyed, the dura mater was extensively inflamed and thickened, and there was a large abscess in the middle lobe of the brain.

Dislocation Outward.

Robert¹ received at the Hôpital Beaujon a patient who had been injured by the passage of the wheel of a cart across the right side of his face. The chin was deviated to the right, and the mouth was held open. The left condyle of the lower jaw could be distinctly felt under the skin above the root of the zygoma. Greatly surprised at this displacement Robert sought for and found a vertical fracture of the body of the bone on the right side just in front of the ramus. The left coronoid process remained under the temporal fossa, the sigmoid notch crossing and embracing the zygoma. Reduction was made by pressing the left ramus outward until the condyle was freed from its contact with the upper surface of the zygoma, and then drawing it downward and inward to its place.

Neis² reported a similar case and collected others.

Dislocation of the Jaw Forward.

This, the common form, is usually caused by muscular action, as in laughing, scolding, yawning, or vomiting, or exceptionally by violence in widely opening the mouth to introduce some large object, such as an apple or the fist, or in drawing a tooth, or by a blow upon the jaw.

In order to understand this mechanism it is necessary to recall the construction and normal action of the joint. The lower jaw is attached to the skull by a synovial capsule which is strong on its outer side (the external lateral ligament), by an internal lateral ligament not in immediate relations with the joint but extending from the spinous process of the sphenoid bone to the margin of the inferior dental foramen, and by the stylo-maxillary ligament, a strong band extending from the styloid process of the temporal bone to the posterior border of the ramus of the jaw. The joint is occupied by an intra-articular cartilage or meniscus which overlies the upper surface of the condyle and accompanies it in its normal movement forward from the glenoid cavity to the eminentia articularis when the mouth is opened. In front of the point to which the condyle thus moves forward the surface of the eminentia articularis is inclined slightly upward to become continuous with the much narrower lower surface of the zygoma. The fibres of the muscles attached to the ramus which close the mouth run upward and forward, and only those belonging to the deep posterior portion of the masseter are vertical or inclined backward.

¹ Robert: *Archives générales de Méd.*, 1845, vol., vii, p. 44.

² Neis: *Luxation du Maxillaire inf. en haut ou dans la fosse temporale.* Thèse de Paris, 1879, No. 252.

Since the condyle moves forward when the chin descends, the centre of motion of the jaw is not in the condyle, but at a point below it at or near the dental foramen, and as the angle of the jaw is at the same time moved backward the axis of the ramus notably changes its relations to the direction of the fibres of the masseter, bringing the line of the posterior ones behind the centre of motion where their contraction tends still further to open the mouth or to keep it open. Still, the cause, when muscular, is rather to be found in the excessive action of the external pterygoid, aided by relaxation of the external lateral ligament, which latter condition is produced by the wide opening of the mouth, as will be explained more fully in the following section.

Pathology. The opportunities directly to examine cases of dislocation of the jaw have been very few, and experiments upon the cadaver cannot entirely take their place, but it appears to be established that Malgaigne's opinion that the condyle did not advance more than one or two millimetres beyond the point on the articular eminence which it normally reaches is not correct, but that the advance is considerably greater. In an autopsy made by Demarquay in a case of recurrent dislocation the condyle was in front of the transverse part of the zygoma; the interarticular disk was behind it. It also appears that the rupture of the capsule, when it occurs, takes place in front between the meniscus and the condyle, but sometimes the meniscus accompanies the condyle without rupture of the capsule. This makes the persistence of the dislocation, and especially the fixation of the jaw, difficult to explain. The earliest theory, that of Petit, the contraction of the posterior fibres of the masseter, is generally rejected as inadequate. Another, also advanced by the earlier writers and recently brought forward again by Nélaton and accepted by Malgaigne, and supported by at least one specimen which is figured in Malgaigne's *Atlas*, Plate XVII., fig. 1, is that the coronoid process becomes engaged under the malar bone. That this may be an occasional adjuvant cause must be admitted on the facts presented, but that it is not the sole cause, and probably not even a frequent one, is proved by experiments upon the cadaver which have shown the fixation to persist after removal of the coronoid process, and by the fact that in Nélaton's specimen the process is unusually long.

The slightly upward inclination of the anterior surface of the eminentia articularis against which the displaced condyle rests is not of itself sufficient, and the most recent theory, suggested by Demarquay¹ and thoroughly studied by Mathieu,² that the return of the condyle is opposed by the meniscus beyond which it has passed, seems to be open to the objections that the meniscus is so freely movable backward that it would be readily pushed back into the glenoid cavity by the returning condyle, and that in some cases it accompanies the condyle in its excursion. In a case in which I was unable to reduce I³ found on exposing the joint that the meniscus had been torn from the condyle and was so lodged in the glenoid cavity that the condyle could not

¹ Demarquay: Bull. de la Soc. de Chirurgie, 1863, vol. iv. p. 119.


² Mathieu: Arch. gén. de Méd., 1868, vol. ii. p. 129.

³ Stimson: Trans. N. Y. Surg. Soc., Annals of Surgery, March, 1898.

enter it. After removal of the meniscus the dislocation was easily reduced. An autopsy reported by Perier¹ of a case of recurrent dislocation showed absence of the anterior portion of the meniscus and lodgement of the remainder behind the condyle after reduction. These prove not that the meniscus is the cause of the fixation, but that it may prevent complete reduction.

The cause must be found, I think, in the ligaments, the external lateral and perhaps the posterior portion of the capsule, and this opinion is supported by the tenseness of the lateral ligament observed by Weber² and Maisonneuve³ upon the cadaver, by the anatomical relations of the parts, and also by the experience of Kramer,⁴ who operated upon a case five weeks old and found reduction easy after he had detached a portion of the masseter and divided the tense external lateral ligament. The mechanism of its action I conceive to be as follows: The external lateral ligament, forming the anterior part of the outer portion of the capsule, extends from the articular eminence downward and backward to the neck of the condyle, its attachment to the eminence being posterior to the point at which the lower surface of the latter begins to incline upward. This ligament (Fig. 264) is too

FIG. 264.



Diagrammatic of the external lateral ligament of the lower jaw. A, when the mouth is open; B, when the condyle is dislocated forward.

short to allow the jaw to take such a position when the condyle is dislocated forward that the long axis of the neck shall coincide with that of the ligament. When the mouth is widely opened the ligament is relaxed by the approximation of its points of attachment, and the condyle passes forward; then, as the mouth is partly closed, the ligament becomes tense before the condyle has moved back past it, and thus its further movement backward is prevented, and while it remains thus displaced any force that tends to close the mouth increases the obstacle to replacement by making the ligament more tense and pressing the bones more firmly together. Such a force is naturally and constantly exerted by the powerful muscles of mastication, stimulated to contraction as they are by their forcible elongation and the pain and anxiety of the patient. The practical inference to be drawn from this explanation, if it is correct, is that reduction should be sought, not by crowding the body of the jaw downward and backward by pressure

¹ Perier : Bull. de la Soc. de Chirurgie, 1878, p. 222.

² Weber : Handbuch der allg. und spec. Chir., vol. iii. Abt. 1, p. 288.

³ Maisonneuve : Comptes-rendus, Acad. des Sciences, 1862, p. 654.

⁴ Kramer : Centralblatt für Chirurgie, 1901, p. 369.

upon the molar teeth, but by first depressing the chin if possible, opening the mouth wider, so as to relax the ligament, and then pressing the condyle backward and closing the mouth as it passes the articular eminence on its way back.

Symptoms. The symptoms of bilateral dislocation forward are that the mouth is held open, the lower jaw immovable and projected somewhat forward; exceptionally, only the projection is present, and the mouth can be closed. Speech is indistinct, swallowing difficult, and chewing impossible. The condyle can be felt in advance of its usual position, and a depression marking the empty glenoid cavity can be felt in front of the ear. The cheeks are flattened, and the saliva escapes from the mouth. The masseter and temporal muscles are usually tense, and the upper anterior portion of the former is raised by the coronoid process.

If the dislocation is unilateral the physical signs are found upon only one side, the chin is turned to the opposite side, and the functional disability is less.

Prognosis. The prognosis is favorable both as regards the reduction of the dislocation and the degree of disability if it remains unreduced, but somewhat unfavorable in that recurrence is quite probable. If it remains unreduced the parts appear slowly to adjust themselves to their new relations and finally to permit more or less satisfactory approximation of the jaws and restoration of the functions.

Treatment. The dislocation is one which, as a rule, can be easily reduced, one indeed in which, as has been already said, reduction has often occurred spontaneously. The methods employed have, perhaps in consequence of this fact, been numerous, and have varied greatly in the objects aimed at, if not in the actual mechanism by which they have accomplished the reduction. It can be shown, I think, that many of the methods and procedures have been successful not because they met the ideas of their originators concerning the obstacle to be overcome, but because they overcame or avoided another obstacle which had not been recognized. With few exceptions the aim of the different methods has been directly to depress the condyle and then to press it backward, and this aim has been accomplished by direct pressure downward upon the molars, or indirectly by raising the chin after having placed a wedge between the back teeth. Those who found the obstacle in the hooking of the coronoid process under the malar bone sought to disengage the process by opening the mouth more widely, and then pressed the jaw backward; while others, again, pressed the bone directly backward by placing the thumb and forefinger of one hand against the coronoid processes and then elevated the chin by a slight blow upon it from beneath. It is noteworthy that some of the gentlest methods, some which approach most closely to that which I conceive to be the rational method, were employed by the earliest surgeons, even by Hippocrates, and were again and again resumed only to be as often neglected and forgotten. Hippocrates's method, as quoted by Malgaigne, was to lower the chin a little in order, according to Galen, to free the coronoid process from the malar bone, and then to press the jaw backward, the patient being meanwhile encouraged to relax his muscles and yield

himself as completely as possible to the effort made in his behalf. Although the intention and the supposed effect was to free the coronoid process, yet the wider opening of the mouth relaxed the lateral ligaments and facilitated the backward propulsion.

In 1862 Maisonneuve again revived the plan, after having observed in many experiments upon the cadaver that the external lateral, sphenomaxillary, and stylo-maxillary ligaments were tense and that after their division the dislocation could be reduced with great ease. He ascribed the fixation to the pressure of the condyle against the zygoma, a pressure "maintained by the combination of the passive resistance of the ligaments and the energetic contraction of the elevator muscles," and proposed to reduce by direct backward propulsion after diminishing the pressure by opening the mouth more widely.

It is unquestionable that in this, as in most other dislocations, the obstacles to reduction are multiple, and that contraction of the muscles is one of them, and that it especially opposes reduction because it directly resists the attempt to place the bones in the most favorable position. It is also true that methods of reduction are habitually successful which are not based upon correct anatomical principles, but nevertheless those principles exist and are the same as in other dislocations; the opposing ligaments must be relaxed, and the bone should follow in returning to its socket the route by which it escaped from it. In the great majority of cases, as has been said, dislocation takes place while the mouth is widely open and the ramus is inclined upward and forward. Theoretically, then, the same position should be given to it as a preliminary to reduction, and although the opposition of the muscles may create practical difficulties in the way of accomplishing this which will prevent its universal use and cause other methods to be preferred in the simple cases, yet in all difficult cases and whenever this opposition has been annulled by anæstheisa this method should be employed: the mouth should be widely opened and the jaw should be pressed backward, or backward and slightly downward. This pressure may be conveniently made by the thumbs placed inside or outside the mouth against the anterior edges of the ascending rami, the head of the patient being solidly supported behind, or by pressing with the forefingers against the front of the ramus, outside the mouth, and the middle fingers against the side near the angle, while the thumbs and other fingers grasp the body near the symphysis.

In the method by forcible depression of the posterior portion of the jaw the thumbs may be used alone by placing them upon the lower molar teeth and pressing downward and backward. It is well to guard them against bruising by covering them with cloths or leather, and when the reduction is accomplished they should be rapidly withdrawn or slipped to the outer side of the teeth to escape being bitten, an accident that has happened to several surgeons and has indeed been the cause which led to the invention of other procedures.

Instead of direct pressure with the thumbs, hinged instruments have been used, taking their bearings upon both sets of molars.

In cases of long standing in which adhesions have formed and must be ruptured before reduction can be made, these forcible measures are

necessary, for the jaw cannot otherwise be moved through a range sufficient to accomplish the object. Reduction has been obtained as late as the ninety-eighth day after the occurrence of the dislocation. Reference has been above made to the personal case in which reduction was possible only after the detached meniscus had been removed by operation.

Mazzoni treated an irreducible bilateral dislocation of eight months' standing in a woman twenty-seven years old by excision of both condyles, with an excellent functional result.

After reduction the mouth should be kept closed by a bandage and the patient fed on soft food for two or three weeks. It is not unlikely that the marked tendency to recurrence so commonly observed is the result of inopportune use of the jaw, perhaps also, in part, of the favorite method of reduction which tends to elongate or rupture the lateral ligaments.

Annandale¹ successfully treated two cases of recurrent dislocation by opening the joint and suturing the meniscus to the periosteum. Irritating injections into the peri-articular tissues have also been employed.

Pathological or Consecutive Dislocations.

Pathological or consecutive dislocations are uncommon, and only in a few cases² has the condyle, eroded and deformed by antecedent inflammation, been found outside its cavity and sometimes united by bony union to the skull.

Congenital Dislocations.

The only example of this condition of which I have found mention, if a foetal monster reported by Guérin be excepted, is one described by R. W. Smith.³ The patient was a congenital idiot who died at the age of thirty-eight years. The dislocation existed upon the right side and was the result of defective development of the constituent parts of the joint.

¹ Annandale: *Lancet*, 1887, i. p. 411.

² Gurli: *Path. Anat. der Gelenkrankheiten*, p. 109, Cases 5, 11, 15.

³ R. W. Smith: *Fractures and Dislocations*, p. 273.

CHAPTER XXXVIII.

DISLOCATIONS OF THE VERTEBRÆ AND OF THE OCCIPUT FROM THE ATLAS.

Classification and pathology, secondary changes, etiology, symptoms and diagnosis, prognosis, treatment—Dislocations of the occiput, atlas, lower six cervical vertebræ, dorsal vertebræ, lumbar vertebræ.

THE study of dislocations of the vertebræ is closely associated with that of fractures of the same bones, because in many cases the differential diagnosis between a fracture and a dislocation cannot be made with certainty, and because the associated lesions and consequences are the same. For some of the latter, therefore, the reader is referred to the chapter on Fractures of the Vertebræ.

Concerning the frequency of dislocations of the vertebræ widely different opinions have been held; some (Delpech) denying even the possibility of dislocation without fracture, others thinking them extremely rare, and others, again, claiming that they are quite common. The most notable member of the last group is Porta, who, according to Blasius, observed no less than twenty-seven cases in thirty years. By far the most valuable contribution to the settlement of this question, and indeed to the whole subject, is the monograph of Blasius,¹ who collected 294 reported cases, of which 185 were dislocations, 37 diastases, and in 72 it remained undetermined to which of these two classes the lesion belonged. Although an autopsical examination was made in 174, yet in 38 of these the account is so defective that the variety and seat of the injury cannot be determined; and in only 172 of the 294 cases can these details be said to have been established. By far the most common seat is the cervical region, then the dorsal, and last the lumbar region, in which only a very few cases have been observed. The certain cases were divided among the decades of life as follows: first, 7; second, 17; third, 25; fourth, 15; fifth, 14; sixth, 6.

The difference of opinion above mentioned regarding the frequency of the occurrence of the injury in general, doubtless depends in part upon the definitions which the different authors have adopted, since some accept as dislocations only those cases which are not complicated by fracture, while others accept also those in which an associated fracture can be rightly deemed unessential to the production of the dislocation. The latter view is in harmony with the classification of other dislocations, and will be adopted here; a dislocation of a vertebra being

¹ Blasius: Die traumatische Wirbilverrenkungen, in Vierteljahrsschrift für prakt Heilkunde, 1869, vol. cii. ciii.

defined as an injury in which the adjoining articular processes on one or both sides have been partly or completely separated from each other, with or without avulsion of portions of the body of either vertebra or fracture of one or more processes. The term *disatasis* is applied to those dislocations in which, the intervertebral disks and other ligaments having been torn, the vertebrae are longitudinally separated from each other in front or behind, but have not also been so horizontally displaced that the articular surfaces on either side have been put out of line with each other.

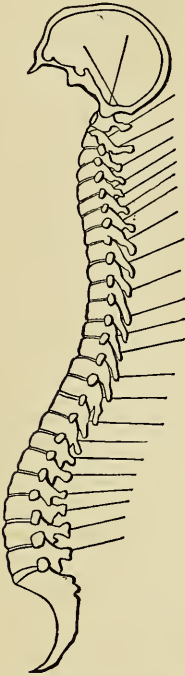
The terminology employed to indicate the seat and variety of the displacement has also varied with the different writers, some speaking of the upper, others of the lower, vertebra as the one that is dislocated, while others have sought to avoid misunderstanding by using such a phrase as "dislocation of the fifth upon the sixth." The latter form can be advantageously employed in the report of cases, or whenever any doubt might arise as to the meaning, but it will be convenient here to follow the more general practice, and speak of the upper vertebra as the one that is dislocated, and of the direction and character of its displacement as those of the dislocation.

Classification and Pathology. The relations of the vertebrae to each other are so complex, and the combinations of different directions which the displacements may present are so variable and numerous, that a classification of the varieties based upon these directions is not only very complicated, but it also fails to offer comparative advantages sufficient to compensate for its complexity. The classification made by Hueter, according to the character of the movement or the direction of the force which produces the dislocation, is simple, and at the same time indicates the main features of the displacement and suggests the proper method of reduction. It fails, however, to distinguish between the varieties; and, therefore, while adopting it, it has appeared desirable also to use in connection with it other terms indicative of special features.

The provisions for normal motion between adjoining vertebrae consist in the elasticity and compressibility of the intervertebral disks between the bodies and in the articulations placed just behind them upon the arches. The normal range of motion, though varying in the different portions of the column, is at best slight, and can be referred in the main to two axes for each pair, one of which lies in the median plane and passes through the centre of the disk from behind forward, with an inclination downward of its anterior end which is slight in the lumbar and lower dorsal regions, more marked in the upper dorsal, and greatest in the cervical regions. The other axis is a horizontal transverse one, passing through the posterior part of the disk. Motion about the first axis produces a lateral bending of the column, and, in the cases in which the axis is inclined downward and forward, with this motion must be associated a rotation of the upper vertebra by which the anterior surface of its body is turned to the side toward which the column is inclined; and the greater the inclination of the axis, the more marked is this associated rotation. The move-

ment is arrested by the contact of the margins of the adjoining articular surfaces with their bases on the concave side, and if it persists beyond this point dislocation is produced, the opposite inferior articular surface of the upper vertebra being raised above the one with which it articulates by the lateral bending, and being carried forward by the rotation. To these dislocations Hueter gives the name *dislocations by abduction or rotation*.

FIG. 265.



Direction of the median axis in the different sections of the spinal column. (HENKE.)

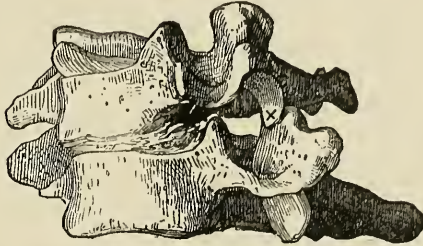
Motion about the other, transverse, axis produces a bending forward (or, to a less degree, backward) of the column, during which the anterior portion of the disk is compressed, the posterior portion stretched, and both inferior articular surfaces of the upper vertebra are moved upward and forward along the superior articular surfaces of the underlying vertebra. The movement is checked, when its normal limit is reached, by the ligaments of the joints and arches, and, if these yield, a dislocation is produced, in which the inferior articular processes of the upper vertebra pass forward and in front of those with which they articulate—*dislocation by flexion*.

Under the first head, **dislocations by abduction**, are to be included the complete or incomplete unilateral dislocations forward or backward, and the bilateral dislocations in opposite directions, described as distinct forms under these names by Blasius, all of which, with one exception (the unilateral dislocation backward) represent only different degrees of the same displacement. Instead of being entirely separated from each other, the articular surfaces may remain in contact at their edges. If the displacement is somewhat greater, the inferior process of the upper vertebra passes further forward, and sinks into the notch between the body and the superior articular process of the lower vertebra (complete unilateral dislocation, Fig. 266), and at the same time the inferior process on the opposite side may be carried backward by the movement of rotation (bilateral dislocation in opposite directions). The unilateral dislocation backward, of which Blasius refers to a few examples exclusive of those of the occiput upon the atlas, may, I think, be attributed to the same mechanism, the displacement being effected in consequence of the yielding of the ligaments of the joint on the side toward which the body is bent, instead of on the opposite side as in the other cases. In a case observed by Cloquet, and briefly mentioned by Blasius, the second lumbar vertebra was dislocated in this manner, the dislocation being complicated, but unessentially, by fracture of the body and arch of the vertebra; all the processes were uninjured. The patient survived several years, and the condition of the parts was

Direction of the median axis in the different sections of the spinal column. (HENKE.)

determined by autopsical examination. Under the second head, dislocations by flexion, are included bilateral dislocations forward or backward. The force continuing to act after the normal limit of forward flexion of the column has been reached, the ligamenta subflava are ruptured, and the posterior portion of the intervertebral disk is torn or separated from

FIG. 266.



Complete unilateral dislocation by rotation or abduction; cervical vertebra. (KÖNIG.)

the vertebra with or without avulsion of a portion of the bone; the articular processes of the upper vertebra lodge in front of those of the lower in the notches. Sometimes the processes do not pass entirely beyond each other, but remain in contact at their extremities; and sometimes, the movement being accompanied by slight rotation of the vertebræ upon each other, one articular process is displaced further forward than the other. The lumen of the vertebral canal may be seriously encroached upon in this dislocation, and its contents injured by compression against the upper edge of the body of the lower vertebra.

The mechanism of the double dislocation backward, of which a few cases have been accurately observed, has not been demonstrated, but the possibility of its production by extreme dorsal flexion of the column is such that it may, provisionally at least, be placed in this class. The motion is arrested by bony contact at the arches, and by the intervertebral disks, the efficiency of whose resistance is increased by their greater distance from the fulcrum about which the rupturing movement must turn. It is interesting to note that in a case reported by Stanley,¹ dislocation backward of the fifth cervical vertebra, the upper five vertebræ were firmly united together by bony fusion. The displacement was so great that the body of the fifth rested upon the laminae and spinous process of the sixth. The additional leverage created by this ankylosis may be invoked as an argument in favor of the theory of production by dorsal flexion.

Transverse dislocation has been diagnosticated in several cases, but the only one in which sufficient anatomical proof has been obtained is the following mentioned by Charles Bell.² A child was run over by a stage-coach and died of croup thirteen months later. The last dorsal ver-

¹ Stanley: *Edinburgh Medical and Surgical Journal*. October, 1841. p. 404.

² Bell: *Injuries to the Spine and Thigh-bone*, 1824. p. 25.

tebra was found completely displaced to the left side of the first lumbar with slight chipping of the bone. The articulation between these vertebræ is of such a character that this form of dislocation would seem impossible without a fracture of the articular processes, and probably it may still ~~probably~~ be deemed so except in a child. The same anatomical conditions exist in the lumbar vertebræ, but in the dorsal and cervical regions the articular surfaces look backward and forward or are only slightly inclined to one side, consequently this form of dislocation must there be regarded as possible.

In the greater part of the dorsal region it would necessarily be associated with dislocation of the vertebral end of the corresponding rib.

In all the clinical cases quoted by Blasius, with one exception, the cervical vertebræ were concerned, and he says that the correctness of the diagnosis is very doubtful in all.

The main groups and varieties, then, are as follows :

Dislocations by flexion, ventral or dorsal.

Bilateral forward.

Bilateral backward.

Dislocations by abduction or rotation.

Unilateral forward

Unilateral backward

Bilateral in opposite directions.

Transverse.(?)

} complete or incomplete.

The *associated lesions* comprise rupture of the various ligaments, muscles, bloodvessels, and nerves, fracture of the bones, and injuries of the spinal cord and its membranes, and those later changes which may be induced by the primary ones.

The *intervertebral disk* is always ruptured or torn away from one or the other vertebra, and this rupture or separation is almost invariably complete, and is accompanied by the avulsion of larger or smaller fragments of the bone. In one or two cases the disk appears to have been crushed.

The *capsular ligament*, on one or both sides according to the character of the displacement, is always torn. The *anterior* and *posterior ligaments* are either torn, wholly or in part, or stripped from their attachments to the bodies of the vertebræ, sometimes bringing with them in the latter case portions of the bone. The *ligaments* between the *laminae* and the *spinous processes* are either torn or put upon the stretch, and those between the *transverse processes* were torn in the only reported case found by Blasius in which their condition was mentioned. Instead of rupture of the ligaments *fracture* of the processes to which they are attached may occur, and various other fractures of the adjoining processes or of more distant parts are frequently observed.

The surrounding and the attached *muscles* may be torn by the displacement or by the direct action upon them of the dislocating violence.

The *veins* coming from the bodies of the vertebræ and those of the meninges of the cord are so large and their relations with the bones

and ligaments are so close that hemorrhage is always free and sometimes very profuse.

In dislocations of the cervical vertebræ the *vertebral arteries* so commonly escape injury that the possibility of their rupture has been denied, but in a case received into St. Thomas's Hospital¹ the vertebral artery was found to have been torn and a large amount of blood to have escaped into the vertebral canal and among the muscles. Blasius admits this case into his list, although all the processes of the fourth vertebræ were broken.

The *nerve trunks* at their point of emergence through the intervertebral foramina may be compressed or torn on one or both sides between the articular process of one vertebræ and the body or pedicle of the other; and in the lumbar or lower dorsal regions the nerves constituting the cauda equina have repeatedly been found torn across or compressed between the body and laminae of the adjoining vertebræ.

The *spinal cord and its membranes* may entirely escape injury, and if injured, the lesion may present any grade between simple compression and complete rupture. The injury may be caused by pressure of the bone against the cord or by the direct elongation of the latter. All the lining membranes may be torn, entirely across or only in part, or one of them alone may be ruptured. Their rupture is necessarily accompanied by the extravasation of blood, usually profuse, between the dura and the bone and amid the meninges. Occasionally an extravasation of blood has been found within the cord itself; thus, in a case reported by Martini,² one of diastasis between the fourth and fifth cervical vertebræ, in which there was complete rupture of all the ligaments and separation to such an extent that the finger could be passed between the bones, the meninges were not torn, and the only lesion found in the cord was a clot three centimetres long in its centre and involving also the cortical substance. A similar case has recently been reported by Quénu.³ It is worthy of note that in three reported cases⁴ in which extensive paralysis was present the autopsy failed to show any lesion of the cord, and that in others there has appeared to be no fixed relation between the extent of the paralysis and the anatomical lesions found in the cord. Probably these three, and the two preceding, were cases of hæmatomyelia. In other cases the cord has been found torn while the ligaments have been only slightly injured.

The analysis made by Blasius to determine the relative frequency and severity of injury to the cord in the different forms and at different seats of dislocation shows that the danger is greatest in dislocation of the lower cervical vertebræ, the fifth and especially the sixth, although even there the cord may entirely escape injury. In the variety which he terms "unilateral forward" (dislocation by abduction or rotation) the danger is less than in the "bilateral forward" or

¹ Medico-Chirurgical Review, 1831, vol. xiv. (18 of analyt. series), p. 227.

² Martini: Schmidt's Jahrbücher, 1861, vol. cx. p. 195.

³ Quénu: Le Progrès Médical, February 27, 1887.

⁴ Colborne: Provincial Medical and Surgical Journal, vol. ii. p. 50; Hafner: Zeitschrift für Wundärzte und Geburtshelfer, 1856, vol. ix. p. 249; and Porta: Della lussazioni delle vertebræ, 1864, quoted by Blasius.

“backward” (dislocation by flexion); in 7 autopsies the cord was found injured in 6, and of 45 cases observed clinically, all of the neck, in 9 there was evidence of injury or compression of the cord, which disappeared in 5 and was followed in 4 by inflammatory and softening processes in the cord. The variety which he terms “bilateral in opposite directions” appears particularly free from this danger; in the few cases he collected paralysis was exceptional and temporary. Of 8 cases of bilateral dislocation backward examined post mortem, the cord was uninjured in 2, and more or less severely injured in 6; of 6 clinical cases, in 3 there was no paralysis, and in 3 the paralysis was temporary. Of 52 cases of bilateral dislocation forward, the cord was uninjured in 17, and was injured seriously and irreparably in 11; in the remaining 24, either recovery followed or a distinction cannot be made between the effects of the mechanical violence inflicted upon the cord by the dislocation and those of the later inflammatory and nutritive changes. It must be remembered that in most of the clinical cases our knowledge of the exact character of the lesion of the skeleton is defective. It has recently been shown that hemorrhage within the gray matter of the cord, *hæmatomyelia*, may be produced by a temporary diastasis of the lower cervical and upper dorsal region, and even without recognizable injury of the column or its ligaments. And yet there is, at first, a motor paralysis which may be as complete as after transverse rupture or crush of the cord. (See Chapter XI., Fractures of the Vertebræ, pp. 143-145.)

Blasius¹ summarizes the analysis as follows: in no form of dislocation is injury of the spinal cord a necessary consequence; such injury is less to be expected in unilateral dislocation, and in unilateral dislocation forward of the cervical vertebræ it is always, or almost always, only a simple compression without crushing; in bilateral dislocation backward or forward, either of the dorsal or cervical vertebræ, the cord is exposed to more serious lesions and seldom escapes entirely uninjured, and when the displacement is forward the cord is mechanically affected in most cases, but the cases of severe injury are fewer than those in which all injury is escaped; finally, the danger is least in bilateral dislocation in opposite directions.

Secondary Changes. When the patients survive for a sufficient length of time the signs of a more or less acute inflammatory reaction appear. While this reaction is not frequent or usually severe, yet in a number of cases pus has been found in the meninges and even in the centre of the cord itself. The cord may be slightly softened and changed in color, or it may be reduced to pulp, and this change may involve only the portion corresponding to the dislocated vertebra or it may extend to a greater or less distance above and below. It is probable also that other changes observed after fracture of the vertebræ, such as extensive suppuration within the pia and the substitution of fibrous tissue for the nervous elements of the cord, may take place, for the conditions are practically the same.

¹ Blasius: Loc. cit., p. 130.

The intervertebral disk seems habitually to disappear by softening and absorption; and the ligaments undergo changes similar to those observed in other ligaments—that is, their torn portions reunite by cicatricial tissue or they contract new attachments in the evolution of the process of repair, and they may even become ossified. The tendency of the reparative process to end in suppuration, which has been observed to be exceptionally marked after fracture of the vertebræ, has been manifested also after dislocation, although possibly only in cases complicated by fracture.

Etiology. The causes have been habitually described as direct and indirect violence and muscular action. The distinction between direct and indirect violence is made by classifying under the latter those cases in which the force has acted upon the column at some distance from the point of dislocation to bend it in one or another direction, and under the former those in which the force has acted directly upon the dislocated vertebra. But the mechanism—in most, if not in all cases—is certainly the same; the column is forcibly bent, and the dislocation is produced by this forcible bending, just as a rod may be bent or broken by grasping and approximating its two ends with or without the aid of direct pressure against its centre. In the cases of dislocation by muscular action the cervical vertebræ alone have been involved, and the movement has been that of exaggerated rotation or dorsal flexion.

Symptoms and Diagnosis. Most of the symptoms of dislocation are the same as those of fracture of the vertebræ. There is usually the same history of violence acting upon the spinal column, either directly or indirectly, to bend it beyond the limit of its normal range of motion, localized pain increased by movement or manipulation, inability to stand, partial or complete paralysis below the point of injury, diminution or exaggeration of the normal mobility of the affected part, with or without reflex muscular rigidity of the upper segment of the column, and deformity recognizable by sight or touch. The symptoms which are thought to be of most service in establishing the differential diagnosis between these two injuries are crepitus and abnormal mobility at the point of injury in fracture, and their absence in dislocation. Unfortunately, crepitus is not always obtainable in fracture by such manipulations as are permissible, and it may be present in dislocation accompanied by fracture—that is, in a condition in which the dislocation is the important injury, and the fracture a comparatively unimportant addition. Rigidity of the column at the injured point is common but not constant in dislocation, and it may be caused in fracture, or even in contusion or sprain, by muscular contraction. But while a positive differential diagnosis may not often be possible, a probable diagnosis may frequently be made, at least when the injury is in the cervical region, by attention to the attitude and rigidity of the neck, by recognition of the change in the relations of the transverse processes, or of the bodies of the vertebræ so far as they are accessible to examination in the pharynx, or of the lower spinous processes, and by the impossibility of correcting the displacement by pressure.

On the other hand, muscular contraction and pain due simply to

bruising of muscles or nerves or to inflammation of the vertebral joints may produce an attitude and rigidity closely resembling those of dislocation.

For the recognition of hæmatomyelia—motor paralysis, thermo-anæsthesia, and analgesia with preservation of tactile sensibility—see Chapter XI.

Deformity. The deformity consists in displacement of the spinous or transverse processes forward or backward or to one side, and is to be recognized by palpation. The displacement of the transverse processes can be recognized by touch only in the neck, that of the spinous processes everywhere except in the upper cervical region unless the patient is very fat. The body of the displaced vertebra is accessible to examination only in the pharynx and occasionally, as in a case reported by Dupuytren, by deep pressure through the anterior abdominal wall.

Pain, although sometimes absent, is commonly present, and is provoked or increased by movements of the body or by direct pressure upon the injured region. In some cases it is referred only to the point of injury, in others it is radiated along the course and over the region of distribution of the affected nerves.

Paralysis, entirely absent in some cases, may be partial or complete within the affected region; usually the two sides of the body are similarly affected (paraplegia), and limitation to a lateral half of the body (hemiplegia) is unknown except where the paralysis has been only partial. Motor paralysis is, as a rule, more marked and extensive than sensory paralysis.

Paralysis has been observed in the muscles of the column adjoining the point of injury, in some or all of the parts of the body below the point of injury, and occasionally in those lying above it. The last-mentioned extension is to be explained by mechanical injury to the cord at a higher point than the dislocation, as by overstretching in diastasis, or by extravasation of blood, or by the extension of inflammatory processes set up by the injury.

Instead of paralysis, or in association with it, may be observed muscular contractions, neuralgic pains, and hyperæsthesia, presumably dependent upon inflammatory changes in the cord and meninges. In a few cases there have been general convulsions, promptly followed by death.

In addition to these symptoms of injury of the cerebro-spinal nerves and centres are others of widely different character and involving many different tissues and organs, which, as Hutchinson¹ has pointed out in a valuable and very interesting paper, may be referred to changes in the sympathetic, especially the vasomotor system. Thus, sudden rises of temperature, general or local and of longer or shorter duration, may be observed, sometimes associated with pallor of the surface or with marked pulsation in the arteries. If the injury is in the cervical region the heart-beat becomes slow but does not also show the intermissions that commonly accompany the slow pulse of injury to the brain.

¹ Hutchinson: London Hospital Report, 1866, vol. iii. p. 357.

Immobility of one or both pupils, with a slight degree of contraction, has been noted; in other cases immobility with dilatation.

Priapism may accompany injury of the lower cervical and upper and middle dorsal regions when it is sufficient to cause paraplegia. Its frequency, compared with all cases in males, was found by Blasius to be 1 to 5 at the fourth cervical, 1 to 3.6 at the fifth, 1 to 2.7 at the sixth, and 1 to 2.5 at the seventh. He adds that it was present in fourteen out of twenty-five cases of fracture of the sixth cervical vertebra. The condition of the member appears, however, not always to be that of normal physiological erection, but rather of simple engorgement, the member remaining comparatively flaccid although swollen. In a few cases the priapism has been provoked only by the additional application of a local irritant, as the passage of a catheter.

The rapid formation of bed-sores has also been attributed to vasomotor or trophic changes, but while it is possible that such changes may act as a predisposing cause, yet the immediate, determining cause appears to be rather the prolonged, unrelieved pressure to which the parts are subjected in consequence of the paralysis.

The occurrence of cystitis and ammoniacal decomposition of the urine within the bladder has also been explained in the same manner, but seems rather to be the consequence of over-distention of the bladder and of the use of the catheter. The later consequences of this cystitis are extremely serious and may hasten or be the immediate cause of death.

Injury to or change in the vasomotor nerves has been thought to be the cause also of changes sometimes observed in the lungs. In two cases elsewhere mentioned I have known fracture of the cervical vertebræ to be followed by expectoration of blood coming from the lungs, and Blasius (following Moritz) describes a pulmonary congestion appearing promptly, marked at first by increased secretion, and rapidly causing death by œdema of the lungs, usually on the second or third day.

Prognosis. The injury is commonly deemed, and with good reason, one that places the life of the patient in great danger. Of the 278 cases he collected Blasius collated 159 in which the diagnosis was certain; of these 36 recovered and 123 died, a proportion of 22.6 per cent. of recoveries, or 1 in 4.4. It is well worthy of note, also, that of these 36 recoveries the dislocation was completely reduced in 27 and partly reduced in 2, and that all these 29 and 5 of the remaining 7 were dislocations of the cervical vertebræ.

In the fatal cases death usually followed promptly upon the receipt of the injury. Of 113 authentic cases more than half died within the first week, the others at varying periods up to five months. Death, especially in the cases in which it occurs promptly, is usually the consequence of the injury to the cord or of the inflammatory processes set up in it by the injury; but even when such injury exists, especially if situated in the lower portion of the cord, life may be indefinitely prolonged. Simple compression of the cord involves less danger to life than its complete or partial division or crushing, and relief of the compression may be followed by restoration of function. If the compres-

sion takes place gradually, even to a very marked degree and at the upper end of the cord, as in several reported cases of cervical spinal caries, prolongation of life is still possible, and even marked and permanent compression at the level of the atlas and axis has in two reported cases not proved immediately fatal. In one¹ of these, dislocation of the atlas forward from both the occiput and the axis with fracture of the odontoid process, the canal was reduced to a triangular slit two millimetres wide on one side and five on the other; the patient survived five months, being completely paralyzed during most of the time. In the other case,² incomplete dislocation of the occiput from the atlas due to caries, the patient survived three months and died of tubercle of the brain.

If the dislocation is reduced the symptoms may disappear promptly, or the paralysis may persist in whole or in part, and the case may even terminate fatally in consequence of the injury done to the cord or its envelopes.

Treatment. This must be directed to the reduction of the dislocation, the prevention of its recurrence, and, if reduction is impossible, to the relief of the consequences of the displacement. If reduction is to be attempted it should be done promptly, and yet it must be added that it has been successfully made in several cases as late as the eighth or ninth day after the accident, and in one after the lapse of two months, and was followed by the prompt or gradual disappearance of the paralysis.

The attempt to discriminate, with reference to the question of attempting reduction, between cases in which the paralysis is due to simple compression of the cord and those in which it is due to its laceration or the effusion of blood within the canal is impracticable, because of the impossibility of making a positive differential diagnosis between those conditions. For the diagnosis of hæmatomyelia see Chapter XI.

The possibility that the attempt may cause the instant death of the patient, especially when the dislocation is in the upper part of the cervical spine, is a weighty factor in the problem, but should not, in my judgment, deter the surgeon if the patient or his friends accept the risk. It should only stimulate him to make the most accurate possible diagnosis as regards the seat, direction, and mode of production of the dislocation, and most cautiously to select and execute the necessary manœuvres. The urgency of the symptoms may leave him but scant time for observation and reflection, and the history of the case may throw no light upon the mode of production, so that the general rule to return the dislocated part along the path by which it escaped from its position cannot be knowingly and deliberately followed. Under such circumstances the surgeon must trust to traction aided by such flexion and rotation of the column as his best scrutiny of the displacement and knowledge of the relations of the articular processes may suggest. Anæsthesia should usually be employed.

The return of the bone to its place is usually indicated by a distinct

¹ Costes: Schmidt's Jahrbüch., vol. lxxix. p. 208.

² Darriste: Bull. de la Soc. Anatomique, 1838, vol. xiii. p. 144.

sound, and the rigidity which is usually present gives place to normal mobility.

If the dislocation is comparatively slight, moderate lateral pressure may effect reduction, as in a remarkable case reported to Blasius¹ by Richter. A lad, eleven or twelve years old, consulted Richter because of deformity and stiffness of the neck caused by a fall. He found the spinous process of the third cervical vertebra slightly displaced to one side, and that pressure upon it caused pain. No paralysis. An attempt to reduce the dislocation by traction on the head failed, and the child was sent home to await another attempt. On the way, the child, who had heard and comprehended the diagnosis, stopped by a wall, leaned his head and shoulder against it, and pressed forcibly with the thumb against the opposite, convex side of the neck, and instantly reduced the dislocation. The story was confirmed by the child's companions, and the surgeon at his visit found the neck straight, normally movable, and free from pain.

After reduction has been made no other retentive measures than rest in bed are ordinarily required, but if there is reason to fear recurrence the parts may be immobilized by gypsum bandages or padded wire splints that embrace the entire trunk if the injury is situated below the shoulders, and the head and chest if it is in the cervical region.

If reduction cannot be made immobilization is still necessary to favor the formation of firm adhesions and the solidification of the bones in their new relations; and in addition measures may be needed to meet the indications of other symptoms. Of the latter the most urgent is the acute hyperæmia of the lungs that has occasionally been observed, and this is most promptly and satisfactorily met by free venesection. The need of regular catheterization in the paralytic cases must not be overlooked. Permanent drainage of the bladder through a perineal incision has been employed, apparently with advantage, in some cases. Suprapubic drainage would probably be preferable on the score of cleanliness and easy attention.

DISLOCATIONS OF THE OCCIPUT AND CERVICAL VERTEBRÆ.

Dislocations are far more frequent in this region than in the others. The fifth cervical vertebra is the one most frequently dislocated. The anatomical differences between the articulations of the atlas with the occiput and axis and those of the other vertebræ are such that a separate description of the injury at the upper end of this region is necessary.

1. Dislocations of the Occiput (from the Atlas).

The articulations between the atlas and the condyles of the occipital bone are formed on each side by a long, oval articular surface on the atlas, which is concave both from before backward and from side to side; the long axis of each runs from in front outward and backward and the outer margin of each is higher than the inner margin, so that each articular surface looks upward, inward, and backward, and

¹ Blasius: *Loc. cit.*, vol. civ. p. 114.

together they constitute a cup-shaped socket into which the rounded condyles of the occipital bone fit, and upon which they have a motion only of flexion and extension. In addition to the ligaments uniting the two bones there are other and strong ones within the canal which directly unite the posterior surface and apex of the odontoid process with the occipital bone and thus aid in opposing the separation of the atlas from the latter.

The dislocation was formerly deemed quite a common one, and to this opinion succeeded another more in harmony with the anatomical conditions of the joint but still erroneous, namely, that it had never occurred. There are, however, three observations which positively demonstrate the occurrence of the injury, those of Costes,¹ Bouisson,² and Milner.³ In the former a lad fifteen years old was thrown down and beaten upon the back of the neck, by which the atlas was displaced forward from its articulations with both the occipital bone and the axis, and the odontoid process of the latter was broken off. The patient's head remained inclined forward, and movements of the neck were difficult. A few days later hyperæsthesia and paralysis of motion appeared, and persisted, without treatment, for four months; then the right arm and leg became painful, and he was taken to the hospital. The pulse was feeble and slightly quickened; at the posterior part of the neck was a firm swelling projecting a little on the right side which subsequently proved to be the posterior part of the axis, and the chin was turned to the left and so depressed as almost to touch the chest. He died thirty-six days after admission to the hospital.

At the autopsy the skull was found dislocated backward from the atlas, the articular surfaces being completely separated on the right side, while on the left the anterior and inner part of the articular surface of the condyle was still in contact with the posterior part of that of the atlas. At the same time the atlas was tilted forward, rotated to the left in front and to the right behind, and displaced forward upon the axis; the odontoid process was broken off at the base and reunited by fibrous tissue in an almost horizontal position with the body of the axis. The posterior arch of the atlas was so closely approximated to the body of the axis that the interval between them was reduced to a triangular slit five mm. wide on the left side and two mm. on the right.

In the second and third cases the patients were instantly killed.

The rarity of the occurrence is readily explained by the extent of the articular surfaces, the strength of the ligaments, and the extra-articular checks to the movement of the skull upon the atlas, the effect of which is to cause exaggerated movements of lateral or antero-posterior flexion of the head to be transmitted to the lower vertebræ.

Treatment. If treatment is called for, the attempt to reduce should

¹ Costes: Schmidt's Jahrbüch., vol. lxxix. p. 208, and Malgaigne: Des Luxations, p. 329. Both these accounts are abstracts of the original report in the *Journal de Bordeaux*, August, 1852, and they differ materially from each other in some points. In the account here given I have in the main followed the former, since Malgaigne's appears to have been taken from an abstract, not from the original paper.

² Bouisson: Schmidt's Jahrbüch., vol. lxxxii. p. 216, from *Revue Méd. Chirurg.* de Paris, vol. ii. p. 355.

³ Milner: St. Bartholomew's Hospital Reports, vol. x. p. 314.

be made by steady traction on the head combined with such coaptative pressure upon it and the vertebrae as would be suggested by the character of the displacement.

2. Dislocations of the Atlas (from the Axis).

The articulation between the atlas and axis is composed not only of the two lateral articulations as in the other vertebrae, but also of that between the odontoid process and the anterior arch of the atlas. This process, which, genetically, is the separated body of the atlas that has united with the axis, is placed vertically behind the anterior arch of the atlas, and is firmly held in place by the strong transverse ligament of the atlas, by the two alar or cheek ligaments which pass from the base of the process to the occipital bone at the margin of the foramen magnum, and by the vertical band of the transverse ligament, the suspensory ligament, and the posterior occipito-axial ligament which overlies the others.

Dislocation forward or backward is possible only after fracture of the odontoid process or rupture of the transverse ligament, or by the slipping of the process beneath the ligament. The number of cases of the injury demonstrated by autopsy is fairly large and contains examples of all three forms. In most of the reported cases the injury was a diastasis or incomplete separation of the articular surfaces, the atlas being displaced forward, and usually so inclined that its anterior arch lay in front of the body of the axis. If, in this change of place, the odontoid process is broken off and accompanies the atlas, the probability of dangerous compression of the cord is somewhat lessened. The other forms that have been demonstrated are dislocations forward and backward of both articular surfaces; dislocation forward on one side only (unilateral dislocation forward) has been observed only clinically except in one case¹ in which there was also a similar dislocation of the sixth cervical. There is some reason to think that some of the obscure reported cases that ended in recovery may have been of the kind designated as "bilateral dislocation in opposite directions," that in which one articular surface is displaced forward and the opposite one backward, for experiment shows that this displacement can exist without causing compression of the medulla. A case observed by Sédillot probably was of this kind. (*Vide infra.*)

The following are examples of the rarer forms :

DISLOCATION FORWARD WITHOUT RUPTURE OF THE TRANSVERSE LIGAMENT. A man² sixty years old fell from a height of four or five metres, striking upon his head, and survived ten hours. The head was held in moderate dorsal flexion, but was freely movable. The odontoid process had passed under the transverse ligament, and compressed the medulla. The right alar ligament was torn, the left untern. The articular surfaces of the atlas had moved forward upon, but had not entirely left, those of the axis. There was no fracture.

A similar case is reported by Orton,³ in which all the ligaments

¹ Francomme : Journ. des Sci. Méd. de Lille, May 29, 1891.

² Journal de Chirurgie de Malgaigne, 1844, p. 370.

³ Orton : Lancet, 1876, i. p. 853.

uniting the axis to the atlas and occipital bone were torn, but the transverse ligament was uninjured, and the odontoid process lay behind it compressing the cord. The injury was caused by a blow of the fist received obliquely from behind, on the angle of the jaw. Death was instantaneous. These two are the only positive examples of this injury.

DISLOCATION BACKWARD. A woman¹ sixty-eight years of age fell while descending a ladder, struck upon her forehead, and died instantly. The atlas was dislocated backward on both sides, the anterior ligament detached, the capsular ligaments in front torn, the odontoid process broken at its base, and the posterior arch of the atlas broken on each side near the transverse process. The fracture of the atlas was thought to have been caused by its impact against the spinous process of the axis.

There is no other reported case in which this variety has been demonstrated post mortem, but Malgaigne quotes from Ehrlich a supposed case which ended in recovery.

BILATERAL DISLOCATION IN OPPOSITE DIRECTIONS. Sédillot² reported the case of a girl who had suffered for some time with stiffness of the neck and deviation of the head to the left, although it could be turned to the right. The injury had been caused by a man who seized her by the head from behind and forcibly twisted it to the side toward which it remained deviated. She died seven weeks later, with increasing paralysis. The autopsy revealed a "dislocation of the atlas," the details of which are not given. The front of the odontoid process was rough, and the odontoid ligaments were torn and partly destroyed, but there was no pus. Only the anterior portion of the cord was softened. Blasius describes this case as one of bilateral dislocation in opposite directions; although it was probably such, the description does not prove it.

In the commoner forms of **DIASTASIS** with inclination and displacement of the atlas forward, and in **COMPLETE FORWARD DISLOCATION** the transverse ligament is ruptured, or the odontoid process is broken off and accompanies the atlas. In diastasis all the ligaments uniting the atlas to the axis are ruptured; in dislocation forward the ligaments of the posterior arch are sometimes untorn. In a case reported by Philips,³ the posterior arch of the atlas was broken off on each side and remained in place, while the anterior portion, including the articular surfaces and carrying with it the fractured odontoid process, was displaced so far forward and downward that it lay entirely in front of, and became united to, the body of the axis. The patient survived forty-seven weeks and died of hydrothorax. The injury gave rise to no marked symptoms except persistent stiffness and pain in the neck, which were attributed during life to a strumous arthritis set up by the injury.

I have met with no mention of injury to the vertebral arteries or veins.

The spinal cord may be torn across in part or entirely, or crushed,

¹ Melchiori, quoted by Malgaigne, loc. cit., p. 333.

² Sédillot: *Gazette Médicale*, 1842, p. 776.

³ Philips: *Med.-Chirurg. Trans.* vol. xx. p. 78.

or simply compressed. In double dislocation forward, it is most likely to escape injury if the odontoid process is broken off. On theoretical grounds, it is also thought not to be greatly endangered in bilateral dislocation in opposite directions.

Cause. The cause has usually been a fall or blow upon the head. In forward dislocation, and in complete diastasis, the force has probably always been so exerted as to bend the head toward the breast; in partial diastasis, with rupture of the ligaments of only one side, the inclination must have been toward the opposite side.

Unilateral dislocation or bilateral dislocation in opposite directions may be produced by exaggerated rotation of the head, as in Sédillot's case.

Symptoms. In simple diastasis without displacement, and without injury of the cord, there may be no symptoms except pain and exaggerated mobility of the head, and even the latter may be lacking because of spasmodic contraction of the muscles. In the common form, dislocation forward, the chin is depressed upon the chest, and a prominence may be felt at the back of the neck, below the occiput, formed by the spinous process of the axis. In the pharynx may be felt the projecting anterior arch of the atlas. Pain is always present, and usually severe. Philips's case, above quoted, is a marked exception in respect of pain, disability, and deformity. The nervous symptoms vary with the degree of injury to the cord.

Prognosis. The prognosis, even accepting the cases of doubtful diagnosis followed by recovery, is very bad. Death may be caused immediately, or suddenly at a later period by the shifting of the loosened bones and the consequent compression of the cord, or by the progress of the changes induced by the primary traumatism.

Treatment. Immediate reduction of the displacement and the prevention of its recurrence are imperative, if the former can be accomplished without such violence as would in itself endanger the life of the patient. Although Philips's case furnishes proof that the persistence of the displacement is not necessarily incompatible with the prolongation of life and activity, and although this proof is supported by the survival in fair condition of several other patients who have received injuries at the upper part of the cervical spine, the exact nature of which was in doubt, but which were followed by permanent rigidity and deformity of the part, yet there can be no question, I think, of the propriety of making or even of the obligation to make, cautious, well-considered attempts to correct the displacement. Even if dangerous pressure upon the cord has not at the time taken place, yet it is certain that the condition is full of the gravest risk. The displacement may gradually increase, as in Dubreuil's case, in which the chin did not touch the chest until the tenth or eleventh day, and death occurred suddenly on the seventeenth, or the fatal increment of displacement may be suddenly added by the relaxation of the spasmodically contracted muscles, or by an incautious movement of the patient, or even of his attendants. This latter has occurred even after complete reduction, as in the following case, which I quote in some detail because it will illustrate many of the prominent features of the injury.

A man¹ fifty-eight years of age fell down a hill-side and remained all night upon the ground unconscious. In the morning he tried to walk and found himself "unsteady." Help came, and he was taken home. When seen by the reporter he was seated in a chair, his chin resting on his sternum, his head and neck rigidly fixed. He was conscious, not paralyzed, and complained of great pain in the neck. There was a marked prominence at the back of the neck below the occiput.

By steady traction upon the sides of the head the displacement was completely reduced with a distinct snap and crepitus, and the pain was relieved. A week later he sat up in bed, and immediately fell back dead, with reproduction of the original deformity.

The autopsy showed that the odontoid process had been broken off with a portion of the body of the axis, and displaced forward with the atlas (the transverse ligament remaining intact) so far that the lateral articular surfaces were almost entirely separated.

As it seems probable from the shape of the bones that dislocation forward, except in cases that are immediately fatal, is very rarely complete, the traction upon the head should be directed somewhat backward, as well as upward, so as to avoid increase of the displacement, and may be combined with counter-pressure against the back of the neck.

After reduction has been effected, and in cases of diastasis without displacement, the head and neck must be made immovable by suitable dressings.

3. Dislocations of the Lower Six Cervical Vertebrae.

These are by far the most common of the dislocations of the spine, and the articulations between the fourth and fifth and between the fifth and sixth are those most frequently affected. The varieties that have been observed and verified are diastasis, bilateral dislocation forward, backward, and in opposite directions, and unilateral forward. Of these the bilateral forward and backward may be classed as dislocations by flexion, and the bilateral in opposite directions and the unilateral forward as dislocations by abduction and rotation. The bilateral forward and the unilateral forward are the most common. The statistics of Blasius show that of 108 cases in which the exact nature of the injury was ascertained 23 were diastases, 41 bilateral dislocations forward, 37 unilateral forward, 4 bilateral in opposite directions, and 3 bilateral backward; to the latter may perhaps be added 8 others in which the diagnosis was not entirely beyond question.

The positively demonstrated cases of BILATERAL DISLOCATION BACKWARD are two reported by Porta and one by Stanley. The latter of the fifth cervical, in which the upper five vertebrae were firmly united to one another by bony fusion, has been quoted above, p. 496. The dislocation was complete, the body of the fifth vertebra resting upon the laminae and spinous process of the sixth. The injury was caused by a fall backward upon the head and back. Theoretically, it may be assumed that hyperflexion forward of a vertebra, combined with direct

¹ Gibson: *Lancet*, 1885, ii. p. 429.

pressure backward upon it, would produce this form of dislocation, for by the flexion a diastasis would be effected in which the posterior and capsular ligaments would be torn, and then the direct pressure backward would rupture the intervertebral disk and produce the displacement. That the injury is rare notwithstanding the frequency of the occasions in which the head is bent forcibly forward is to be explained by the normal freedom of motion in this direction which allows the chin to be depressed upon the breast.

Of the four cases of BILATERAL DISLOCATION IN OPPOSITE DIRECTIONS I have been able to examine the original reports in none. Possibly the one attributed to Malgaigne¹ is the same as the case described in his *Luxations*, p. 371, as unilateral forward; if so, and if it is retained in the list, it would seem proper also to add Martellière's case mentioned by Malgaigne upon the following page, 372, as resembling his own in the associated slight displacement backward of the opposite inferior articular process with rupture of the capsule. In Malgaigne's case there was also chipping of the lower border of the articular surface of the dislocated vertebra on the side of the principal dislocation with the production of a notch in which the upper edge of the underlying process was engaged. Similar chipping of the same border was found in Martellière's case, but the articular process had passed completely beyond the underlying one and had descended in front of it to a distance of nearly one-quarter of an inch. This form is an exaggeration of the unilateral dislocation forward, and their causes and mode of production will, therefore, be considered together.

In BILATERAL DISLOCATION FORWARD both inferior articular surfaces of the dislocated vertebra are carried forward beyond the anterior borders of the underlying ones, and the fixation is effected either by the dropping of the processes into the notches in front of the latter, or, if the movement forward is combined with anterior flexion, by the interlocking of the body of the upper vertebra with the projecting lateral borders of the upper surface of the one beneath. Blasius claims that this is effected almost as frequently by posterior as by anterior flexion, an opinion which it is not easy to accept.

In hyperflexion forward the fulcrum is found at the anterior border of the body of the vertebra, and the first effect is to produce diastasis with rupture of the posterior and capsular ligaments, and then as the projecting lip on the inferior anterior border of the body of the upper vertebra engages in front of the upper border of the lower one, and the force continues to act, not simply to flex but also to crowd the head directly down toward the chest, the body of the upper vertebra slips downward and forward, by which movement the articular surfaces are separated antero-posteriorly. Then if the neck is straightened the body of the vertebra may be raised to its original level, and yet the dislocation will be maintained by interlocking of the articular processes. Under such circumstances there would be no angle in the direction of the neck, but only a depression in the nape and a projection in the pharynx corresponding to the body of the dislocated vertebra.

Occasionally the spinous process with more or less of the adjoining

¹ Malgaigne: *Revue Méd. Chirurg.*, 1853.

laminae is broken off. The intervertebral disk is always torn, and so are usually the ligamenta flava and the interspinous ligament; the longitudinal (anterior and posterior) ligaments are less frequently torn, often only stripped off. The spinal cord may be compressed or crushed or stretched, or may escape injury.

As the articular surfaces are in some cases almost horizontal, it is conceivable that the dislocation may be produced by direct violence acting upon the bone from behind forward, without the aid of either ventral or dorsal flexion of the column.

In UNILATERAL DISLOCATION FORWARD¹ (dislocation by abduction and rotation) the articular surface on one side of the upper vertebra is carried upward and forward until its posterior edge has passed the anterior edge of the one with which it articulates. At the same time the spinous process moves from the median line toward the side of the dislocation, and the anterior surface of the body projects slightly in

FIG. 267.

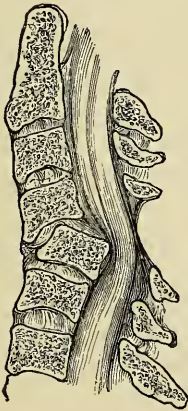
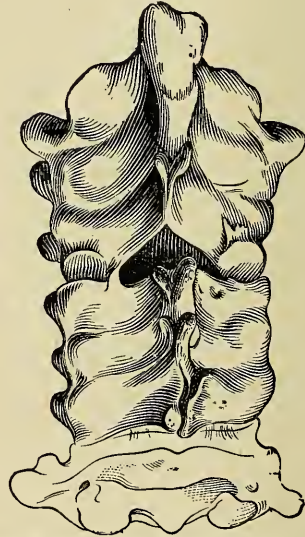
Dislocation of the neck by flexion;
median section.

FIG. 268.

Bilateral dislocation by flexion; fourth cervical
vertebra; from behind. (MALGAIGNE.)

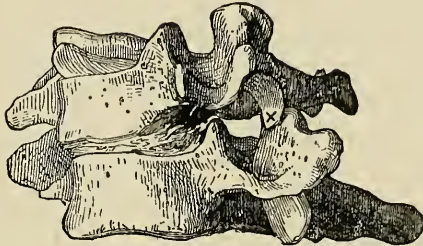
front of that of the underlying one. In short, the movement is one of rotation and abduction about the opposite articular surface as a centre, and by it the vertebral canal is but slightly narrowed, and but little or no violence is done to the cord. The segment of the column above the dislocation is abducted, and forms with the lower part an angle or curve, the convexity of which is on the dislocated side.

The normal motion in the articulations of this region is one of rotation and abduction. The dislocation is produced by carrying the move-

¹ Blasius (loc. cit., vol. civ. p. 82) found only one case of unilateral dislocation *backward*—of the sixth cervical—and even in it there was also fracture of the lamina and body of the seventh vertebra on the side of the dislocation.

ment beyond its normal limits, by any force which over-abducts or over-rotates the upper part of the column. This force may be an external one, or one developed by the muscles attached to the head. Of these dislocations by muscular action Völker¹ collected fourteen more or less certain cases, and made them the basis of a careful study of the subject. Additional cases have since been reported. The movement which produces the lesions is a sudden turn of the head to one side; if it is violent, ill regulated, if its momentum is unchecked by the antagonistic muscles, it carries the head beyond its normal limit, and produces the dislocation in exactly the same manner as if an external force had been applied to the head to turn it in the same direction.

FIG. 269.



Complete unilateral dislocation by rotation or abduction.

In **DIASTASIS** the lesion consists essentially of more or less extensive rupture of the ligaments. It is the same in its forms, nature, and etiology as the other varieties, with the exception of the persistent displacement of the bones and of the change in the relations of the articular surfaces to each other; the displacement is either entirely absent or is slight. A singular instance of the production of a diastasis by muscular action is reported by Lasalle:² a crazy man, confined in a strait-jacket in a chair, jerked his head violently backward and forward, became at once paralyzed, and died a few hours later. The autopsy disclosed a separation between the fifth and sixth cervical vertebrae, with rupture of the posterior ligament, the interspinous muscles, the ligamenta flava, and the intervertebral disk. The possible production of hæmatomyelia is to be borne in mind.

Symptoms. *Unilateral dislocation forward.* The posture of the head has varied so greatly in the reported cases that it is of no value as a symptom. Not only may the abduction of the upper segment of the column, which is necessary to the production of the dislocation, be almost entirely corrected by the sinking back of the articular process of the upper vertebra into the notch of the lower one, but even if it persists it may be so far compensated for or obscured by flexion in the occipito-atloid and rotation in the atlo-axoid articulation, that it will not be recognized. The face is, however, usually turned away from the side on which the dislocation has taken place. A painful prominence, swelling, or rounding can be recognized on the dislocated side;

¹ Völker: Deutsche Zeitschrift für Chir., 1876, vol. vi. p. 424.

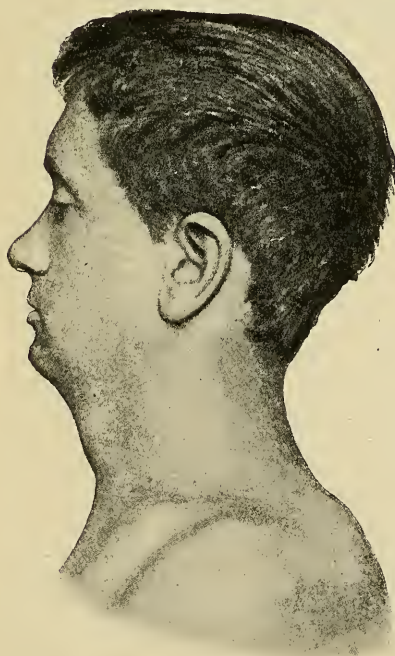
² Lasalle: Gaz. Médicale, 1841, p. 763.

it is due, according to Völker, to the angle created in the column, the slight projection of the transverse process, and the contracted condition of the muscles. Observers differ as to the condition of the muscles on the opposite side, some reporting them relaxed, others contracted. The deviation of the spinous process of the dislocated vertebra to the side of the dislocation is a valuable sign when it can be recognized, but the depth at which the third, fourth, and fifth spinous processes are placed is such that their position cannot usually be determined, and while that of the second can always be felt, its deviation may be unrecognizable, because the position of the underlying ones with which it must be compared remains unknown. The projection of the body of the vertebra in the pharynx is sometimes recognizable by the finger introduced through the mouth.

The last named three signs are diagnostic if fracture can be excluded, but as the last two are unrecognizable in many cases, the first, the existence of a painful prominence on the side of the neck, is the one upon which the surgeon will usually have to depend.

Cases may occur, as they have occurred, in which the symptoms are so obscure that a diagnosis between dislocation by muscular action and muscular rheumatism cannot be positively made. Under such circumstances the manipulations that would reduce a dislocation if it were present should be carefully made. If they reduce the deformity and relieve the symptoms they both establish the diagnosis and cure the patient.

In *bilateral dislocation forward* the symptoms vary greatly. The head may be bent far forward toward the chest with marked prominence in the nape of the neck of the spinous process of the vertebra next below the dislocated one, or it may be bent backward or backward and to one side, with marked projection of the trachea and perhaps larynx, and irregularity in the outline of the front of the column recognizable by palpation through the soft parts. The head may be rigidly fixed, or, more rarely, freely movable. These differences depend partly on the position of the dislocated bone, the presence or



Bilateral dislocation forward of the fifth cervical vertebra. (From a photograph.)

absence of associated fracture, and the extent of the injury to the connecting ligaments, partly on the direction and character of the dislocat-

ing force, and partly on the contraction or relaxation of the muscles which control the position taken by the unaffected joints above the seat of injury. In the majority of cases the head is bent forward, and an angle with its apex directed backward is formed by the two segments above and below the dislocation. Attempts to move the head and pressure at the seat of injury are very painful. In these patients the irregularity in the line of the transverse processes may sometimes be recognized by the touch; and if the dislocation is not too low the projection of the body of the vertebra may be felt in the pharynx.

Of the symptoms of *bilateral dislocation backward* nothing positive can be said. In most of the supposed cases the head has been bent backward, the face directed somewhat upward, the tissues of the front of the neck tense, and respiration and deglutition somewhat interfered with.

In *bilateral dislocation in opposite directions* it seems probable that the head would be fixed in rotation, but possibly not abducted.

Paralysis, partial or complete, is frequently observed. Its immediate importance, its urgency, as a symptom varies accordingly as the dislocated joint is above or below the point of exit of the phrenic nerve. The fourth cervical nerve, from which the phrenic mainly arises, though it receives a branch also from the third or fifth, leaves the vertebral canal through the foramen between the third and fourth vertebræ, but leaves the side of the cord at a somewhat higher point. A dislocation below the third cervical vertebra may cause paralysis of all the accessory muscles of respiration that act by raising the ribs, but, the diaphragm continuing to act, prolongation of life is possible. If, on the other hand, the dislocation is at a higher point, and the trunks going to form the phrenic nerve are injured or the cord is so compressed or torn that the integrity of the corresponding fibres within it is destroyed, or they are all cut off from the respiratory centre, then the diaphragm also, being no longer innervated by these nerves, immediately ceases to act, and the individual dies asphyxiated. In a few cases the threatening symptoms have been instantly relieved by changing the position of the patient or by systematic reduction of the dislocation. In all such threatening cases and in those that are immediately fatal the injury is, as a rule, at one of the upper joints. In the exceptions there have been associated injuries to which the death is to be attributed.

If the paralysis is due to compression or laceration of the cord it may be complete of both motion and sensation below the point of injury, or it may involve only the motor nerves. It seems probable that the partial paralyses are due to pressure not upon the cord but upon a nerve trunk in the intervertebral foramen. (See also *Hæmatomyelia*, in Chapter XI.)

Loss of control over the sphincters, incontinence of urine, and the other secondary symptoms of injury to the cord have been already considered.

Prognosis. The mortality of dislocations of the lower six cervical vertebræ, excluding cases of diastasis, cannot be positively determined because of the uncertainty of the diagnosis in cases that recover; it is

highest, probably 75 per cent., in bilateral dislocation forward, and much less in the unilateral. In the fatal cases death, as a rule, comes promptly, within the first week. Suppuration has been observed about the seat of injury in cases that remained unreduced. In a number of cases gradual improvement has taken place in the attitude and mobility of the neck. In one reported by Walton¹ of supposed dislocation of the third cervical forward the symptoms did not become marked until two months after the accident and then increased to complete helplessness; fifteen months after the accident they suddenly improved, and a month later recovery was complete.

Treatment. In *unilateral dislocation forward*, at least in those produced by muscular action, Völker says reduction is usually easy and free from danger. Mention has been made above of the case in which a boy reduced his own dislocation by resting his head and shoulder against a wall and pressing upon the prominence in the neck with his thumb.

Simple traction upon the head, the counter-extension being made by the weight of the body, followed by rotation of the face toward the dislocated side has proved successful, but it seems better and is generally recommended that the articular process should be freed by still further abducting the head and upper segment of the column (away from the side of the dislocation), and then, when freed, should be rotated backward into place. If traction is used it should be made in the direction of the long axis of the upper segment, not in that of the lower one, for in the latter case the strain would come wholly or mainly upon the untorn connections on the non-dislocated side and rather tend to depress the dislocated articular process still further in front of the corresponding lower one than to raise it above it.

Bilateral dislocations in opposite directions are to be classed with the preceding as dislocations by abduction and rotation, and treated in the same manner. Probably the differential diagnosis could not be made clinically.

In *bilateral dislocations forward* the methods that have been employed with success have combined traction upon the head, either in the sitting or recumbent posture, with pressure upon the front and back of the neck at suitable points.

After reduction the patient should be kept quiet for some time, and if reproduction of the dislocation is feared a retentive dressing should be applied. It must be rigid enough to prevent any flexion of the neck forward or backward, and, after unilateral dislocation, should include the head so as to prevent rotation. Such a dressing can be conveniently made with plaster of Paris.

DISLOCATIONS OF THE DORSAL VERTEBRÆ.

The cartilaginous surfaces of the articular processes in the dorsal region are placed more nearly in a vertical plane than those of the cervical vertebræ; the superior ones look backward and slightly upward and outward, the inferior ones, with the exception of those of

¹ Walton: Boston Medical and Surgical Journal, March 21, 1889.

the twelfth, look forward and slightly downward and inward; the inferior ones of the twelfth are placed like those of the lumbar vertebræ and look outward and somewhat forward. This disposition does not in itself make dislocation to either side by rotation or direct dislocation backward with fracture difficult; dislocation forward is made possible by flexion sufficient to raise the inferior articular processes of the upper vertebræ above the superior ones of the lower. Dislocation between the twelfth dorsal and first lumbar vertebræ seems to be much less favored by the relations of the processes, and yet this is the point in the combined dorsal and lumbar regions where dislocation is by far most common. Blasius¹ collected twenty-two cases in which the character of the dislocation was demonstrated by autopsy; of these one was of the third dorsal vertebra, three of the fifth, one of the sixth, one of the ninth, three of the tenth, two of the eleventh, and eleven of the twelfth; of the doubtful cases ten were thought to be of the twelfth, four of the eleventh, and one each of the fifth, eighth, and tenth.

The observed varieties are the bilateral forward and backward with about equal frequency, the bilateral in opposite directions, and the lateral. Of the latter there are only two demonstrated cases, Bell and Mohrenstein, twelfth dorsal, and even in these Blasius thinks the injury was primarily a unilateral dislocation forward or backward, which was followed by bodily lateral displacement. In the few cases in which the condition of the adjoining ribs is noted, these have been found sometimes dislocated and sometimes fractured not far from the column. The degree of injury to the cord varies with the character and extent of the displacement. Other pathological conditions have been considered above.

Causes. The causes have been forcible flexion of the trunk forward and the direct action of great violence upon the back or side of the spinal column, as in the fall of a heavy object, or the passage of the wheel of a wagon across the body.

Symptoms. The symptoms of the dislocation are found in recognizable changes in the position and relations of the dislocated vertebræ, especially in the prominence of its spinous process or of the underlying one, or in its lateral displacement, and in a deviation of the column which creates an angle at the seat of the dislocation, the apex of which is usually directed backward. In some cases it is noted that the articular processes of one or the other of the two adjoining vertebræ form prominences under the skin.

Excessive mobility at the seat of dislocation has also been observed in most cases.

Paralysis appears to be more common and more complete in the forward than in the backward dislocations, and in a few cases has disappeared after reduction.

The symptoms resemble so closely those of fracture that the differential diagnosis, in the absence of post-mortem examination, can rarely be made with certainty. The failure to obtain crepitus is no proof of the absence of fracture, and when present it may be due to the presence of an associated unimportant fracture. Reduction and the absence of

¹ Blasius: *Loc. cit.*, vol. ciii. p. 46.

a tendency to reproduction of the deformity are the best obtainable evidence that the injury was a dislocation.

Prognosis. The prognosis, as regards either the preservation of life or the full restoration of function, is not favorable. The uncertainty of the diagnosis in most cases of survival and the comparative fewness of the cases deprive the percentages of value, and it can only be said that the injury seems more likely to prove fatal when it is situated in the upper part of the region than when in the lower, and that in quite a number of cases more or less complete recovery has followed.

Treatment. Reduction, by extension and counter-extension at the hip and shoulders, has been tried, and sometimes with success. If it is obtained the patient must be kept absolutely recumbent for several weeks, and preferably with the trunk enveloped in a plaster-of-Paris dressing, and the same measures should be employed even when reduction has not been effected, in order to favor the consolidation of the bones in their new positions.

DISLOCATIONS OF THE LUMBAR VERTEBRÆ.

The possibility of the occurrence of pure dislocation of the lumbar vertebræ, which has been long in doubt because of the close interlocking of the processes and the strength of the ligaments, is proved by two cases collected by Blasius and also, it may be said, by two others in which there was present associated but unimportant fracture of some of the processes. The first two cases are those of Curling¹ and Porta.²

Curling presented a specimen preserved in the London Hospital Museum: the intervertebral disk between the third and fourth lumbar vertebræ was destroyed, with slight splintering of the edge of the bone at one or two places; the body of the third projected nearly half an inch in front of that of the fourth, and the articular processes of the two bones were separated to the same distance; the ligaments connecting the laminae and the spinous processes were stretched but not materially torn.

The other two cases are those of Keig³ and Cloquet.⁴ In the former a sailor twenty-three years old was crushed under a heavy iron cylinder which fell across his back. The second lumbar vertebra was displaced backward seven lines, the upper articular process of the third becoming lodged in the notch of the second; the tip of the right lower articular process of the second was broken off but not separated from the rest; the left transverse processes of the first and second vertebræ were broken off (by muscular action, it was thought), and the spinous processes of the ninth, tenth, and eleventh dorsal vertebræ and the left eleventh and twelfth ribs were broken. The right sacro-lumbalis muscle was completely divided transversely, and the liver and spleen were ruptured.

¹ Curling: London Hospital Reports, vol. iii. p. 355.

² Quoted by Blasius: *Loc. cit.*, vol. ciii. p. 55.

³ Keig: Schmidt's Jahrbüch., vol. cvii. p. 69. (Blasius writes the name Keli.)

⁴ Blasius: *Loc. cit.*, from Journal des Différences, vol. i. p. 453.

In another case Porta found at the autopsy a pure diastasis between the third and fourth lumbar vertebrae, the bones being separated a few lines without lateral or antero-posterior displacement, and all the ligaments being torn; the spinous process of the third was broken at its base.

The conditions which so effectually oppose dislocation with or without fracture are the great breadth, thickness, and elasticity of the intervertebral disks, the large masses of muscle that lie on each side of the spinous processes, and the arrangement of the articular processes by which those of each upper vertebra are received between those of the next lower and are thus absolutely prevented from moving laterally or from being separated by lateral flexion without fracture of one or the other.

Symptoms. The symptoms are irregularity in the line of the spinous processes, local pain, disability, and more or less complete paralysis of the parts below. As the spinal cord is replaced throughout the greater part of this section by nerve trunks, the cauda equina, which less completely fill the canal, the paralysis is less likely to be complete than when the injury is at a higher point, and it is also more easily recovered from if the displacement is corrected.

Prognosis. The prognosis is more favorable than in dislocations of the dorsal and cervical regions, presumably because of the usual absence of injury to the cord, and the less extent of the paralysis; and, while many of the cases have promptly proved fatal, death has usually been due to associated injuries.

Treatment. In backward dislocation reduction appears not to have been difficult; it has been obtained by pressure upon the projecting spinous process, with or without forcible extension of the column. In a case reported by Harrison,¹ dislocation backward of the third lumbar vertebra, reduction was obtained with the aid of anæsthesia by extension and counter-extension, combined with moderate pressure upon the spinous process, while the patient was lying upon his back. The paralysis began to diminish on the following day, and complete recovery followed, although a slight projection in the line of the column persisted. A plaster-of-Paris jacket was worn for four and a half months.

Possibly the plan recommended by some of the older surgeons, of combining flexion forward with traction, would be necessary or useful in some cases. It could be effected by placing the patient on his belly across the side of a barrel, or by raising him on a cloth passed under his belly.

¹ Harrison: *Lancet*, 1885, ii. p. 114.

CHAPTER XXXIX.

DISLOCATIONS OF THE STERNUM.

(SEE ALSO FRACTURES OF THE STERNUM.)

UNDER this title are included only dislocations of the normal divisions of the sternum from one another, not those of the sternum from the clavicles or from the cartilages of the ribs; they are those of the body from the manubrium, and of the ensiform process from the body.

Dislocations of the Body from the Manubrium.

The manubrium, constituting nearly the upper third of the sternum, is united to the second piece, the body, by a layer of interposed cartilage, sometimes hyaline, sometimes more or less distinctly fibrous, and sometimes containing a central synovial sac. Henle speaks of this central sac as of rare occurrence; Maisonneuve and Brinton found it in about two-thirds of the cases examined. Ossification of the band occasionally takes place in advanced life; the earliest age at which it has been observed is thirty-four years.

The second costal cartilage articulates with both these segments of the sternum at their junction. Although this division of the sternum into segments was described by the anatomists, no account thereof appears to have been taken by surgeons until, in 1842, Maisonneuve¹ read before the Académie de Médecine in Paris a paper in which he called attention to the anatomical divisions of this bone, and reported two cases of dislocation of the body from the manubrium which had come under his observation, and in which he had made the autopsies. Earlier records show several cases which were doubtless dislocations, but Maisonneuve was the first to separate them from the class of fractures and apply this name to them.

The injury is not a common one, even if allowance is made for the probable description of some as fractures. Malgaigne, in 1855, could collect only ten examples, although he included in the list several of the older cases reported as fractures; Ancelet² collected sixteen cases of all kinds, Brinton³ thirteen of dislocation forward, and added one of his own. Gurlt,⁴ in his table of fractures and disastases of the sternum, has twenty-nine cases classified as diastasis between the first and second pieces, and three between the second and third. Adding to these those quoted by Ancelet, Brinton, and Servier,⁵ the list is increased to more than forty. Only one of the patients was a woman, and the ages ranged from thirteen to more than sixty-five years.

¹ Maisonneuve: *Arch. gén. de Méd.*, 1843, vol. xiv. p. 249.

² Ancelet: *Gazette des Hôpitaux*, 1863, p. 257.

³ Brinton: *American Journal of the Medical Sciences*, July, 1867, p. 39.

⁴ Gurlt: *Die Knochenbrüche*, 1862, vol. ii. p. 31.

⁵ Servier: *Dict. Encyclopédique*, 1884, art. Sternum.

In sixteen the body was completely dislocated forward and upward upon the manubrium, in three or four backward; in two the dislocation was incomplete forward, and in one the two segments were separated longitudinally.

Causes. The injury has been produced by direct and indirect violence, and, possibly, in one or two cases, by muscular action. Guines,¹ in the report of a case of tetanus in a boy thirteen years old, states that on the seventh day he found the breast elevated, all the false ribs displaced and carried upward, the sternum bent at the junction of the first and second pieces, and forming with the ensiform process an eminence three inches high. The pectoral muscles were forcibly contracted, while those of the abdomen were, if not in their natural condition, at least much relaxed (compared with their previous condition). On the eighteenth day, the tetanus having ceased, it is noted that the deformity of the breast persisted. I understand this to mean that there was an angular displacement at the junction of the first and second pieces, the apex being directed backward, and the ensiform process distant three inches further than usual from the spine.

In two other cases muscular action may possibly have been the determining cause, but the mode of production is obscure; in one of them (Drache, quoted by Malgaigne), a young man fell into a cellar with some falling timber, which rested upon his chest; while striving to free himself he felt a snap in the region of the sternum, and the dislocation was thought to have been then produced. In the other (Ancelet), a boy thirteen years old was exercising on parallel bars with his chest bent forward; his feet unexpectedly touched the ground, and a forward dislocation, complete on only the left side, was produced.

In the case of longitudinal separation (Aurran and David), the patient fell from a height of fifty feet, striking on his back across a low wall so that his head was on one side and his legs on the other. He received at the same time a fracture of the spinous processes of the last two dorsal vertebræ, and the dislocation (a diastasis) seems, therefore, to have been produced by hyper-dorsal flexion of the spinal column, by which the two segments of the sternum were pulled apart. The case seems, to some extent, to confirm the theory of the possibility of dislocation by muscular action. The patient recovered.

In three cases a forward dislocation was caused by violence received directly upon the front of the chest, presumably upon the manubrium. One patient (Aurran) fell with a ladder, striking his chest against one of the rungs; another (Malgaigne) fell against the gunwale of a boat; the third (Frémey²) was struck and killed by the pole of a wagon. Drache's case also is sometimes quoted as an example of direct violence, and so perhaps may be Richet's,³ in which some boxes of soap fell upon a man, and caused a dislocation backward of the body upon the manubrium. Reid's patient was kicked by a mule; the direction of the displacement is not mentioned.

In Duverney's⁴ patient the injury was compound, and was caused

¹ Guines: Arch. gén. de Méd., 1829, vol. xix. p. 396.

² Frémey: Bull. de la Soc. Anatomique, 1868, vol. xiii. p. 419.

³ Richet, reported by Sirey in Bull. de la Soc. Anat., 1857, vol. ii. p. 305.

⁴ Duverney: Maladies des Os, 1751, vol. i. p. 235.

by the forcible compression of the sides of the chest by a falling stone, the second piece being thrust forward (see *Fractures*, p. 175); and in Pitha's¹ it was caused by similar lateral compression between the buffers of two railway cars.

In most of the others the injury was caused by a fall from a height, by which the trunk was probably bent forcibly forward, as shown in several of them by associated fracture of the cervical or dorsal vertebræ. The mode of production in these cases appears to be similar to that by lateral compression of the ribs; the first and second ribs being shorter and more rigid than the others, the manubrium remains fixed, while the second piece is pushed forward and upward by the other ribs that articulate with it and which are themselves pressed forward by the flexion of the spine. Servier demonstrated this action upon the cadaver by exposing the sternum and costal cartilages, dividing the third, fourth, and fifth of the latter, and then throwing the body backward from a sitting position so as to strike upon its shoulders on the floor; the ends of the ribs could be seen to spring forward and inward.

Pathology. In the common form, dislocations of the second piece forward and upward, the bones override, sometimes as much as an inch; the anterior fibrous layer lining the bone is torn, the posterior one stripped from the second piece. The second costal cartilages almost invariably remain in contact with the manubrium. Sometimes the third and fourth have been broken.

In two cases, Nélaton's and Ancelet's, the dislocation was incomplete; in the latter the body was turned about its longitudinal axis so that its left upper corner was elevated above the manubrium and the second costal cartilage to a distance fully equal to the thickness of the bone, while its right upper corner remained in place.

The dislocations of the body backward furnish two autopsies. Sabatier's² patient was an elderly man who, after having been beaten with the fists, was thrown into a ditch thirty feet deep; he survived for a week. The body of the sternum was displaced 2.8 cm. upward behind the manubrium; there was a large extravasation of blood under the skin and in the substance of the right lung, which was extensively bound down by old adhesions.

Richet's patient, twenty-seven years old, was thrown down upon his back by some heavy boxes that fell from a wagon upon his chest and caused many associated injuries; he died of pyæmia on the twenty-second day. The body of the sternum was displaced backward and slightly upward behind the manubrium; the second costal cartilage on the left side remained attached to the body, that of the right side was separated from both body and manubrium, and its end was free in an abscess that bathed the dislocation. There was a complete transverse fracture of the manubrium half an inch above its lower end, and a fracture of the body without displacement at the level of the articulation of the fourth costal cartilages. There was a compound fracture of the left leg, and simple fractures of the left third and fourth ribs and of the right radius.

The complications have been numerous and varied: fractures of the

¹ Gurlt: *Loc. cit.*, p. 225.

² Gurlt: *Loc. cit.*, p. 275.

cervical and dorsal vertebræ, of the ribs and costal cartilages, rupture of the adherent lung, rupture of the lungs and heart (Duverney).

Symptoms. In the severe cases—those complicated by other injuries, especially of the spinal column and thoracic viscera—the general symptoms due to the dislocation may be masked or increased by those of the other lesions; in general terms, the rational symptoms in forward dislocation are more or less transient oppression of breathing and sharp pain at the seat of injury, increased by pressure or by movements of the body or head.

The neck and trunk are bent forward, the lower ribs appear prominent, and the upper ones depressed. The anterior surface of the sternum presents a well-marked elevation at the level of or just below the first intercostal space, which has a sharp, well-defined upper margin rising directly from the manubrium and is continuous below with the body of the sternum. The absence of the second costal cartilages from the upper corners of the body makes it possible to recognize with the finger the shallow, saucer-like depression at these points with which they articulate. The recognition of these depressions, or the distance of the upper edge of the projection from the line of the third ribs, will enable the surgeon to distinguish a dislocation from a fracture of the body; and the presence of the second costal cartilages below the upper edge of the projection will indicate a fracture of the manubrium.

Prognosis. The prognosis is grave; more than half the patients have died of their injuries, though doubtless the fatal result is to be attributed in most of the cases to the associated lesions. In the cases that have survived a failure to effect reduction has not led to any disability; one of the patients in the list had borne his unreduced dislocation for fifteen years without inconvenience. Stetter¹ mentions, without giving the reference, a case observed by Audie of habitual dislocation backward (or of the manubrium forward) which recurred every time the patient rose from the recumbent posture without supporting his head.

Treatment. Reduction is to be made by bending the trunk backward and making pressure upon the projecting piece of the sternum. The patient should be placed upon his back on a firm cushion or on a table with his head and shoulders projecting beyond its end, and then the head and neck should be drawn backward, and counter-extension made on the pelvis. It is recommended also that in dislocation backward the patient should be encouraged to make full inspirations.

After reduction is made a body bandage, or, better, a broad strip of adhesive plaster, should be placed around the chest.

In case of failure to reduce by these or other simple means, resort should not be had to cutting operations unless grave indications due to pressure upon the thoracic organs should exist.

Pathological Dislocations. To the three examples of this kind quoted by Malgaigne, Bourneville² has added a fourth. In two, as a result of frequent pressure against the sternum, displacement took place between the first two pieces, one angular with projection of the upper edge of the second piece, the other of the second behind the first. In the third

¹ Stetter: *Compend von den Luxationen*, 1886, p. 19.

² Bourneville: *Bull. de la Soc. Anatomique*, 1869, vol. xiv. p. 56.

case the body of the sternum and the connected costal cartilages could be pressed back to a depth of two inches. In Bourneville's there was tubercular suppurative at the junction of the first two pieces, with slight displacement of the second forward.

Dislocation of the Ensiform Process.

Of this injury, referred to by many of the earlier writers as a possibility, only five or six more or less well-authenticated cases are on record. They are those of Martin and Billard quoted by Malgaigne, Polaillon,¹ Gallez quoted by Servier, and Hamilton.² In addition may be mentioned the reference made by Malgaigne to an example observed in a new-born child by Seger, and that to one similar to Polaillon's quoted by Mauriceau in the discussion on his case.

Polaillon's patient was a woman thirty-five years old, and her injury was caused apparently by tight lacing to conceal the enlargement of pregnancy; all the others were males, and their injuries were caused by blows received upon the epigastrium; their ages were eighteen, nineteen, twenty-eight, and fifty-three years.

No autopsy was had in any case, and in Polaillon's alone is the condition described with sufficient detail to make it reasonably certain that the separation took place at the line of union between the process and the body of the sternum; the others may have been fractures of the process itself. In Polaillon's the base of the process was displaced backward, and the point looked directly forward. In Hamilton's, first seen by him twelve years after the accident, the cartilage was "bent at right angles with the sternum, pointing directly toward the spine." In the other cases the character of the displacement is not fully described, but apparently the apex of the process was directed backward in most.

In three cases the most prominent symptom was persistent vomiting, which in one (Hamilton's) recurred every five or six days for two years and then ceased spontaneously, in another (Martin) it was relieved by grasping the process with the fingers and drawing it forward into place, and in a third (Billard), after it had lasted a month and threatened to prove fatal, it was relieved by drawing the process forward by means of a blunt hook introduced below it through an incision. Polaillon's patient suffered sharp pain, which was excited by the pressure of the clothing and the ingestion of food, and was extremely severe during delivery; reduction was impossible, and after a time the inconvenience caused by it ceased. In Gallez's case the prominence could be reduced and reproduced with a click by manipulation; the patient suffered only local pain and was promptly cured by reduction maintained by the aid of a small compress fixed over the process by means of adhesive plaster.

¹ Polaillon: *Bull. de la Soc. de Chirurgie*, 1877, p. 9.

² Hamilton: *Fractures and Dislocations*, 6th ed., p. 182. The account leaves it uncertain whether this was deemed a fracture or a dislocation.

CHAPTER XL.

DISLOCATIONS OF THE RIBS AND THE COSTAL CARTILAGES.

UNDER this title are included dislocation of the ribs at their junction with the vertebrae, of the ribs from the costal cartilages, of the cartilages from the sternum, and of the cartilages of some of the lower ribs from one another.

The head of each rib articulates with the bodies of one or two vertebrae by a true joint containing one or two synovial sacs and strengthened by firm ligaments; the tubercle and neck of each rib, except the eleventh and twelfth, are united to the transverse process of the corresponding vertebra by a synovial joint and ligaments and to the transverse process of the vertebra next above by a longer ligament. The union between each rib and its costal cartilage is direct, without a synovial sac, and is strengthened on the anterior surface by the periosteum. The articulations between the costal cartilages and the sternum are, with the exception of the first, true synovial joints, sometimes double, surrounded by a capsule which is strengthened in front and behind to form the anterior and posterior ligaments. The seventh rib is the lowest that articulates with the sternum. The fifth, sixth, seventh, eighth, and ninth costal cartilages are united with one another for a short distance on their contiguous margins by true synovial joints formed by slight projections on their margins and surrounded by capsules which are strengthened by fibres derived from the anterior intercostal aponeuroses.

Dislocation of the Head of the Rib. (Luxatio Costo-vertebralis.)

The first recorded case, and that a doubtful one, was reported in 1753 to the Académie de Chirurgie by Buttet. His patient was a man fifty-five years old who had been run over by a wagon; he was so fat and the swelling was so great that the outlines of the ribs could not be traced, and the diagnosis was based on the fact that when pressure was made upon the front of the chest the sixth rib on the right side could be felt to move with a very distinct, audible click which, moreover, was reproduced whenever the patient made a movement of his trunk.

The next case was Hankel's¹ in 1834: a young man fell into a clay-pit and received an injury in the lower dorsal region; he died on the fifteenth day, and the autopsy showed fractures of the eleventh dorsal vertebra and of the twelfth rib on each side and a dislocation of the eleventh left rib.

During the next following six years six additional cases were reported, and the list has not since been added to except by Webster's

¹ Hankel: Gazette Médicale, 1834, p. 187.

case, the date of occurrence of which is not known but is probably earlier than that of the others, and by Quint.¹

In all but one of the nine (Kennedy) the condition was shown by autopsy. The causes were extreme violence, falls or blows, and in one a gunshot wound. The ribs dislocated were the first, fourth, sixth or eighth, and tenth once each; seventh, eleventh, and twelfth twice each; in one case the right eleventh and twelfth and the left eleventh. In two cases the corresponding vertebra was broken, and in four one or more adjoining ribs were broken. With one exception the patients died promptly or within a few days in consequence of associated injuries. The exception was Webster's; in his the head of the seventh rib was found united with the front part of the vertebra, having been displaced, it was thought, in a fall from a horse several years before; the injury was thought at the time to be a fracture of a rib.

Separation of the Ribs from the Costal Cartilages. (Luxatio Chondro-costalis.)

Of this injury there are only eight, possibly nine, examples on record, and in only one of these was the condition demonstrated by autopsy. Of the latter our only knowledge is through the description of the specimen presented without history to the Société Anatomique by Carbonell.² It showed a separation of the second, third, and fourth cartilages from the ribs, with fracture of the ossified union between the first rib and the sternum and of the fifth costal cartilage one centimetre from its outer end; all five ribs were also broken at their angles, and the right bronchus was torn away from the trachea.

The other cases are those of Chaussier,³ Bell,⁴ Bouisson,⁵ De Kimpe,⁶ Bradley,⁷ Stimson,⁸ and B. F. Curtis.⁹

In four of the cases the patient had been crushed between a moving body and a wall; in two the cause was a blow upon the front of the chest; in one the patient had long suffered with a cough and had thereby produced a hernia of the lung between the eighth and ninth ribs on the left side and another between the seventh and eighth ribs on the right side at the level of their junction with the cartilages, accompanied by a separation between the seventh rib and its cartilage on the right, and between the eighth and its cartilage on the left; at each of these points the rib was movable with crepitus.

In Bell's case the ends of all the ribs on both sides projected distinctly at their junction with the cartilages; in the others the displacement of the end of the rib was in some forward, in some backward. In Bradley's all the ribs from the first to the sixth were depressed; in

¹ Webster, Cooper on Dislocations and Fractures, Am. ed., 1844, p. 450; Boudet, Bull. de la Soc. Anatomique, 1839, vol. xiv. p. 104; Alcock, 2 cases, London Medical Gazette, 1838-39, vol. ii. pp. 586 and 587; Kennedy, Dunne, and Finneane, Dublin Medical Press, February and March, 1841, abstracts in Gazette Méd., 1841, p. 410; and Quint, Bull. Méd. du Nord., June, 1888.

² Carbonell: Bull. de la Soc. Anatomique, 1865, p. 17.

³ Chaussier: Bull. de la Faculté, 1814, p. 50.

⁴ Bell: Surgical Observations, 1817, p. 171.

⁵ Bouisson: Gurlt, loc. cit., vol. ii. p. 251.

⁷ Bradley: Medical Record, August 24, 1890.

⁸ Stimson: New York Medical Journal, March 1, 1890.

⁶ De Kimpe: Gaz. des Hôp., 1852, p. 18.

⁹ B. F. Curtis: Ibid.

mine the second rib was dislocated backward from its cartilage, and the cartilages of the third to the sixth forward from the sternum. In Bouisson's and De Kimpe's the fourth and fifth ribs respectively were displaced forward.

The possible ninth case is Monteggia's,¹ a separation of the second and third costal cartilages in a very emaciated man seventy years old, in consequence of a violent attack of coughing. Gurlt says: "Monteggia declares expressly that it was not a fracture of the cartilage but a separation of the epiphysis," by which must be meant a separation at the costo-chondral junction.

The injury is so closely allied to fracture of the cartilages that the reader is referred for other details to Chapter XVI.

Dislocation of the Costal Cartilages from the Sternum. (Luxatio Chondro-sternalis.)

Of this injury there are fourteen recorded examples: Ravaton, Manzotti, Monteggia, and Bell, quoted by Malgaigne; Cooper,² Flagg,³ Wolfenstein,⁴ Gross,⁵ Bennett,⁶ Mulvany,⁷ Blodgett, two cases,⁸ Stoner,⁹ and mine quoted in the preceding section. There are, in addition, one or two cases, elsewhere referred to (see Chapter XXXIX.), in which separation of the first and second pieces of the sternum has been accompanied by complete separation of the second costal cartilage from the sternum on one or both sides.

In three of the cases (Bell, Cooper, and Blodgett's second) the cause appears to have been traction exerted through the pectoralis major, in swinging dumb-bells, kneading bread, and exercising on parallel bars; and possibly the cause was the same in Blodgett's first case, in which a man while carrying a piano made a violent effort to prevent its fall. In four others the cause was a fall or compression of the chest; in the remainder it is unrecorded or obscure.

The fourth cartilage was displaced singly forward in three cases, forward in combination with the fifth and sixth in two, and backward with the second and third in one; the third singly, the fifth and sixth together, and the fifth, sixth, and seventh together were displaced forward in two cases, the third to the sixth forward in one, and the first and second were together displaced forward and outward once (Blodgett's first). In two cases it is not stated which cartilage was displaced, nor in what direction.

The only autopsy was in Bennett's case. The patient was a woman about fifty-six years old who had been run over by a cart and died a few days later of pleurisy and pneumonia. The third cartilage on the left side was displaced forward, and there was also fracture of the

¹ Gurlt: *Loc. cit.*, vol. ii. p. 250.

² Cooper: *Loc. cit.*, p. 451.

³ Flagg: *Northwestern Medical and Surgical Journal*, August, 1871, quoted by Hamilton.

⁴ Wolfenstein: *Allg. Wiener med. Ztg.*, 1873, No. 44, quoted by Poinset.

⁵ Gross: *Surgery*, 6th ed., vol. i. p. 1132.

⁶ Bennett: *Dublin Journal of the Medical Sciences*, 1879, i. p. 441.

⁷ Mulvany: *Lancet*, 1882, i. p. 432.

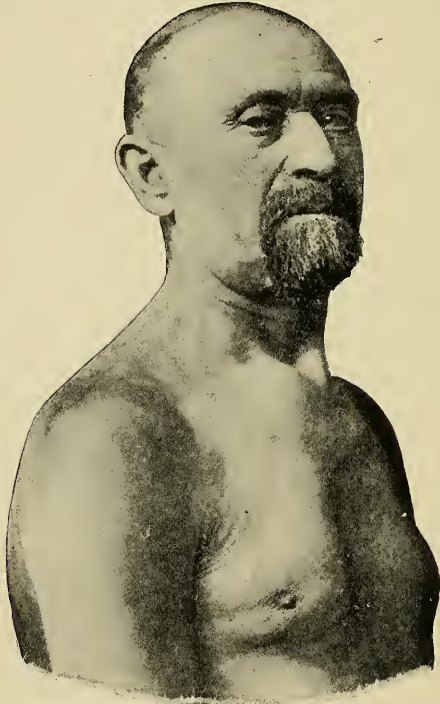
⁸ Blodgett: *New York Medical Journal*, 1883, vol. xxxviii. p. 34.

⁹ Stoner: *The Physc. and Surg.*, October, 1889.

second, third, fourth, and fifth ribs on the same side, and of the second to the ninth ribs on the right side. The perichondrium with the attached ligaments was stripped clean off. The dislocation was reduced by direct pressure and did not recur; it must be remembered, however, in connection with this, that the corresponding rib was broken.

In the single case of backward dislocation (Mulvany) the patient was a boy fifteen years old, who while steering a ship in a heavy storm was thrown violently across the deck by a wave and struck upon the back of his left shoulder against the deck-house. The second, third,

FIG. 271.



Dislocation forward of the third to the sixth costal cartilages from the sternum, and of the first rib backward.

and fourth left cartilages were displaced backward behind the sternum, and the sternal end of the right clavicle was dislocated forward. Reduction could be effected by drawing the shoulders backward, but the displacement immediately recurred when the traction ceased. The patient was kept upon his back for eighteen days, and the deformity was then found to have been much diminished. In two months he was again at work.

Usually there has been sharp local pain at the moment of the accident, subsequently excited by movements of the thorax and by local pressure. In one case (Mulvany) there was slight recurrent hæmoptysis.

The recognition of the injury appears always to have been easy, by

attention to the difference in level between the cartilage and the sternum. In only one case (Wolfenstein) was it mistaken for a local inflammation.

Reduction of the forward dislocations was in every case easily effected by direct pressure, but the tendency to recurrence was marked.

The best treatment would appear to be the application over the displaced cartilage and around the chest of a broad strip of adhesive plaster, as in fracture of a rib, making special local pressure, if necessary, with a compress. Possibly a truss could be used with advantage.

Dislocation of One Cartilage upon Another. (*Luxatio Chondro-chondralis.*)

Malgaigne collected three supposed cases, one of which came under his own observation. I think they should rather be classed as dislocations of the ribs from the cartilages, or of the cartilages from the sternum, although there was also displacement above or below the level of the adjoining ribs.

In the following two the character of the lesion is more apparent :

Hochenzegg¹ presented to the Gesellschaft der Aertze in Vienna a patient thirty years old, who in a fall broke the bond between the seventh and eighth ribs. A year later after a fit of coughing he felt something give away in his side and found a wide space between those ribs.

Aunis² found in a man fifty years old a dislocation forward of the seventh cartilage from the eighth ; it could be reduced by pressure, but immediately recurred. The injury was caused by a fall backward.

¹Hochenzegg: Medical Press and Circular, Dec. 17, 1890.

²Aunis: Gaz. Hebdom., March 13, 1892.

CHAPTER XLI.

DISLOCATIONS OF THE CLAVICLE.

Of the Sternal End: Forward, backward, upward—Of the Acromial End: Supra-acromial, subacromial, subcoracoid—Simultaneous of Both Ends.

Of all dislocations about 5 per cent. are of the clavicle, those of the acromial are five times as frequent as those of the sternal end. The period of greatest frequency appears to be between the thirtieth and fiftieth years, and during it the injury is almost wholly confined to males.

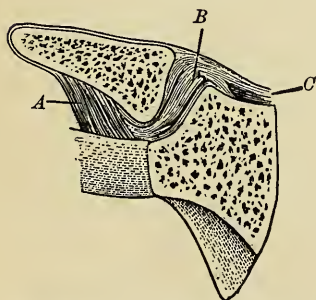
The dislocation may be of either end or of both, and occasionally both clavicles have been simultaneously dislocated.

1. DISLOCATIONS OF THE STERNAL END OF THE CLAVICLE.

Anatomy. The sternal end of the clavicle is so much larger than the clavicular notch of the sternum with which it articulates that it projects above it and in front and behind. The articular surfaces are separated from each other by an interposed fibro-cartilaginous disk, or meniscus, which is most strongly attached above to the upper edge of the end of the clavicle, and below to the cartilage of the first rib. On each side of it is a synovial cavity.

The ligaments of the joint are the interclavicular, costo-clavicular, and the anterior and posterior sterno-clavicular. The interclavicular ligament extends across from the upper edge of the end of one clavicle to that of the other above the interclavicular notch of the sternum, sending bundles of fibres into the meniscus and to the top of the sternum. The costo-clavicular ligament extends from the sternal end of the first rib upward

FIG. 272.



Frontal section through the sterno-clavicular joint. *A*, rhomboid or costo-clavicular ligament; *B*, meniscus; *C*, interclavicular ligament. (HENLE.)

and outward to the under surface of the clavicle as far as to the subclavian vein, partly surrounding the inner end of the subclavius muscle but lying mainly behind it. It sometimes contains within itself a bursa of considerable size. The anterior and posterior sterno-clavicular ligaments cover the joint in front and behind respectively, mainly constituting its capsule. They are short and quite tense.

Motion is possible about all the axes to this extent, that the acromial end of the bone can be made to describe a circle which is the base of a cone having an angle of 60 degrees at its apex in the joint. Movement of the shoulder downward and backward is arrested by contact of the clavicle with the first rib, and if then continued this point of contact becomes the centre of motion, or the fulcrum, and the sternal end of the clavicle is forced upward or forward out of its place, and a dislocation is produced.

Varieties. The dislocation may be complete or incomplete, upward, forward, or backward; and when complete it is usually also inward, toward the median line, and when complete forward or backward it is usually also downward. Possibly a separate class of dislocations, upward and outward, should be made of such cases as those of Stokes (*vide infra*), in which the cause is the prolonged action of the sternocleidomastoid muscle in forced inspiration.

Dislocation Forward. (*Luxatio Claviculæ Præsternalis.*)

This is the most common form, and is usually caused by the shoulder being forced backward, or backward and downward. The means by which this movement has been produced are various; in some cases it has been a fall upon the point of the shoulder or upon the extended hand; in others, the pressure of some heavy object upon the front of the shoulder when the body was supine, as the wheel of a wagon or the foot of a horse; in others, again, by the sudden slipping of a heavy burden carried upon the back by straps passing around the shoulders.

Richerand¹ reported a case in which it was caused in a girl twenty years old by the forcible approximation of her elbows behind her back, and Boyer another in which the shoulders were drawn back to give the patient, a young girl, a more erect and graceful carriage. In like manner, it has been caused by the voluntary throwing back of the shoulders, as in soldiers at drill, and in one case, Bardenheuer,² by the involuntary effort made to prevent the fall of a burden carried upon the head.

In all of these the mechanism is the same: the outer end of the clavicle is carried back to the limit of the normal range of motion, and then it either finds a new centre of motion at the point at which it comes into contact with the first rib, in consequence of which the inner end is carried forward if the movement is prolonged, or the anterior sterno-clavicular ligament is put upon the stretch and ruptured, and then dislocation takes place.

In a few cases it has been gradually produced, apparently by relaxation of the ligaments due to repeated slight strain, the dislocation then occurring whenever the arm was raised and being spontaneously reduced when it was lowered. In one of my cases both clavicles were thus affected. The same condition of easy recurrence and reduction may follow a primary traumatic dislocation.

In a few cases the dislocation has been caused by the pressure of an aneurism at the root of the neck, and in others³ by prolonged, forced,

¹ Richerand: Quoted by Polaillon, *loc. cit.*, p. 729.

² Bardenheuer: *Deutsche Chirurgie*, Lief. 63, a, p. 57.

³ Stokes: *Dublin Medical Journal*, 1852, vol. xiii. p. 459.

inspiratory efforts. In the latter (two cases) the dislocations appear to have been primarily upward, and the displacement forward to have been the consequence of the elongation of the ligaments. In one of them both clavicles were dislocated.

Cazin¹ reported a case in which the dislocation was gradually produced in a boy eleven years old who was suffering from Pott's disease of the dorsal spine with angular deformity and retraction of the corresponding side of the chest, and who had the habit of resting on his elbows in bed. Cazin thought the displacement was due to the diminution of the size of the upper part of the chest, not to the force exerted through the arm.

Age. According to Bardenheuer, Fergusson met with a case in which the dislocation was produced in a child during delivery. The next earliest age at which the injury has been reported is ten months; it was caused by a fall from bed.²

Pathology. The dislocation may be complete or incomplete; in the latter form the posterior portion of the articular surface of the clavicle remains in contact with that of the sternum, and the anterior sterno-clavicular ligament alone is ruptured. In the former the articular surfaces are completely separated, and the posterior edge of that of the clavicle rests upon the front of the sternum; ordinarily it lies nearer the median line and at a lower level than that of its normal position, the greatest recorded displacements being one mentioned by Richerand, three inches downward, and one reported by Jousset³ in which the end of the clavicle lay upon the second rib. This displacement inward or downward or in both directions must be secondary and due to the action of the weight of the corresponding limb and to the contraction of the muscles which draw the shoulder inward, downward, and forward when it is deprived of its normal support, in the same manner and for the same reasons as after fracture of the clavicle. The opportunities for post-mortem examination have been so few that a positive account of the condition of the ligaments cannot be given. That the anterior one is ruptured cannot be doubted, and it is probable that the posterior one also is torn, although in some cases it may only be torn from its attachment and left continuous with the stripped-up periosteum of the posterior surface of the clavicle. In one case⁴ all the ligaments except the anterior sterno-clavicular are described as intact; the meniscus accompanied the clavicle and was partly torn. In a case reported by Cloquet⁵ there was found at the autopsy instead of rupture of the posterior ligament a fracture that split the end of the clavicle into two parts, the posterior one of which remained in place, while the anterior one, continuous with the shaft of the bone and capped by the meniscus, was dislocated forward. Whether or not the meniscus habitually accompanies the end of the clavicle in its displacement is not known.

In the cases in which the dislocation has been slowly produced, Stokes's and probably Heusinger's, the ligaments were found greatly

¹ Cazin: *Gaz. des Hôpitaux*, 1874, vol. xlvii. p. 507.

² T. R. Wright: *Boston Medical and Surgical Journal*, 1880, vol. cii. p. 333.

³ Jousset: *Gaz. Médicale*, 1833, p. 217.

⁴ *Bull. de la Soc. Anatomique*, 1879, p. 809.

⁵ Cloquet: *Nouveau Journ. de Méd.*, 1820, vol. vii. p. 248, quoted by Polaillon.

elongated but not torn. Stokes does not mention the position of the meniscus; in Heusinger's case it accompanied the clavicle.

Occasionally a portion of the edge of the articular surface of the sternum or of the clavicle has been broken off. The sternal portion of the sterno-cleido-mastoid may be pushed aside or even torn away from the sternum, perhaps bringing with it a scale of bone.

Simultaneous dislocation of the acromial end (*vide infra*) and fracture of the shaft have been observed as complications; also a similar dislocation of the other clavicle.

Symptoms. The principal physical sign is the projection of the end of the clavicle and, if the dislocation is complete, its displacement toward the median line or downward. If the dislocation is incomplete the projection can be made to disappear by pressing it backward, but it is likely to reappear when the pressure is removed. In the complete dislocations the weight of the limb, if unsupported, tends to bring the shoulder nearer the thorax and thus forces the end of the clavicle inward or downward.

The other symptoms are sharp local pain, which abates in a day or two, depression of the shoulder, inclination of the head toward the injured side, and inability to raise the arm.

The local swelling may be so great as to mask the position of the bone, and if crepitus should be present the injury may be, as it has been, mistaken for fracture. Another error of diagnosis has been to mistake the dislocated end for an exostosis; and, conversely, hypertrophy of the bone has been mistaken for a dislocation.

Prognosis. The prognosis is unfavorable as regards the complete correction of the deformity, but favorable in respect of the restoration of function. In almost all the reported cases projection of the end of the bone, to a greater or less extent, has persisted, but the patients have been able to use the arm freely and with no sense of loss of power, even when the dislocation has remained complete. In some the condition of "habitual" or "recurrent" dislocation ensues, the bone slipping out of place whenever certain movements of the arm are made. The discomfort caused thereby may be very great.

Treatment. Reduction is effected by drawing the shoulder outward and slightly backward and making pressure backward on the dislocated end after it has been thus brought opposite the joint. Hamilton failed in two cases to effect reduction, but I have met with no other reported failures. The reduction is, however, the least part of the treatment; the difficulty is to keep the bone in its place. The anatomical relations and the mode of production suggest that this would best be effected by keeping the shoulder well forward until after repair of the torn ligaments shall have taken place, and I can account for the failures under this plan, which was recommended by Velpeau and Malgaigne, only by supposing that it was not properly carried out. I have found it easy to maintain the position by a figure-of-eight bandage about both shoulders, the turns crossing in front of the chest, and also by a plaster-of-Paris dressing about the shoulder and chest. In the simpler cases it is sufficient to immobilize the shoulder without drawing it forward, and to prevent the elevation of the arm.

Moulded pads of leather, gutta-percha, or plaster of Paris covering the end of the bone and the adjoining part and held in place by bandages about the chest have given good results.

Direct pressure, usually in conjunction with fixation of the shoulder, has been applied in a great variety of ways, of which the simplest, which may serve also as the type, was that employed by Nélaton. He used an ordinary spring-truss, placing one of its pads upon the sternal end of the clavicle and the other between the shoulder-blades, and carrying the spring under the axilla of the uninjured side. The objection to the use of pressure arises from the probability of irritating the skin or even causing a slough at the point at which it is applied. Combined with rest in bed upon the back and a good position of the shoulder, the maintenance of the pressure for a week has proved sufficient to prevent recurrence, although not entirely to overcome the projection.

In a case in which the total correction of the displacement would be important, the patient should be kept in bed upon the back, in order to diminish the tendency to reproduction of the deformity created by the weight of the shoulder when the body is erect, and frequent inspection should be made to determine the efficiency of the measures. Should all other means fail, digital pressure might be maintained for a week or ten days. The dressings should be worn for at least a month.

Habitual or *recurrent* dislocation has been successfully treated by prolonged retention, and in two cases by myself¹ by peri-articular injections of alcohol; a few drops of alcohol are injected with a hypodermic syringe into the tissues in front of and below the joint, and the arm immobilized, or, at least, elevation of the elbow is avoided. In one case I made four injections at intervals of about a week; in the other one injection was sufficient.

Dislocation Backward. (*Luxatio Claviculæ Retrosternalis.*)

This dislocation, the second in order of frequency of those of the sternal end, may be produced *directly*, by a force acting from before backward upon the end of the bone, or *indirectly*, by a force that presses the shoulder forward and inward. The latter is the more frequent. In the few recorded cases of dislocation by direct violence the cause has been such as a fall of the patient forward, striking upon the clavicle, or the fall upon him of a stone, or the passage across his chest of the wheel of a wagon. In the dislocations by indirect violence the patient has commonly been caught between two bodies, as the pole of a wagon and a wall, or the side of a railway car and a wall, or between two boats, in such a way that the shoulder has been pressed forward and inward.

The dislocation may be complete or incomplete.

Pathology. The only recorded cases in which direct inspection of the parts has been made are those of Tyrrell² and Bennett.³ In the

¹ Stimson: New York Medical Journal, November 23, 1889.

² Tyrrell: St. Thomas's Hospital Reports, 1836, vol. i. p. 261.

³ Bennett: Dublin Journ. Med. Sciences, 1881, vol. lxxi. p. 444.

former a compound dislocation was caused by the point of a pickaxe entering below the end of the bone; the pectoralis major was freely torn from its attachment to the clavicle, but in all probability this was mainly, if not entirely, the result of a direct action upon it of the point of the pickaxe, and is not a common feature of the dislocation. The meniscus remained attached to the sternum, and the end of the clavicle could be easily felt by the finger in the wound.

In the second case the patient was caught between a wall and a railway car and rolled along for some distance. The sternal end of the right clavicle, accompanied by the meniscus, was dislocated backward, and the cartilages of the first, second, third, and fourth ribs of the same side were broken.

The end of the bone is displaced inward or inward and downward, and it is generally stated that it lies between the trachea and the sterno-hyoid and sterno-thyroid muscles, but, in the absence of direct proof of this, I am disposed to believe rather that it may lie between the latter muscle and the sternum, and below the former, for, it will be remembered, the sterno-hyoid arises in part from the posterior ligament of the joint and frequently from the clavicle itself, and the sterno-thyroid lies behind the other and has its origin as low even as the cartilage of the second rib. Possibly the difference noted in the direction of the displacement, inward in some, inward and downward in others, may depend upon varying relations between the bone and these muscles.

Whatever the relations between these parts may be, the end of the bone frequently presses upon the trachea and thereby causes more or less dyspnoea, or upon the œsophagus and causes dysphagia. Of sixteen cases analyzed by Polaillon¹ dyspnoea was present in six and dysphagia in three. The venous congestion of the face and neck coexisting with the dyspnoea has been sometimes attributed to pressure upon the brachio-cephalic vein, but although the region into which the end of the bone is displaced is occupied by most important vessels and nerves, the recorded histories do not show that they have ever been seriously pressed upon.

Beside the complication of fracture of the cartilage of the first four ribs in Bennett's case mentioned above, fracture of the first rib has been noted in a case reported by Dr. N. C. Morse:² the patient was a girl eight years old who had been run over by a wagon and had received a dislocation backward of the sternal end of the left clavicle, with fracture of the first rib, and a dislocation "outward" (forward?) of the sternal end of the right clavicle. Apparently the wheel had crossed the left clavicle and chest. There was great dyspnoea and marked venous congestion of the face and neck which disappeared on reduction of the dislocation. The child recovered. Geissler³ reports a case in which the sternal ends of both clavicles were dislocated backward by a fall upon the back of the head and shoulders. Reduction was incomplete.

Symptoms. The absence of the end of the clavicle from its articulation, and its position behind the sternum are recognizable by inspection and palpation, the course of the bone can be seen and felt to pass

¹ Polaillon: *Dict. Encyclopédique des Sciences Méd.*, art. Clavicule.

² Morse: *Cincinnati Medical News*, 1877, vol. vi. p. 819.

³ Geissler: *Zentralblatt für Chir.*, 1906, p. 709.

inward behind its normal position, and the cavity and border of the articular surface of the sternum can be traced with the finger.

The shoulder hangs a little forward and nearer the chest; sharp pain, increased by movements of the arm or head, is felt at the seat of injury, but usually is prompt to disappear. These voluntary movements are restricted or abolished by the pain.

Disturbance of respiration by compression of the trachea has been noted in only about one-third of the cases, and may be slight or so severe as to threaten suffocation. Ordinarily it lasts for only a short time, even if the dislocation remains unreduced.

Difficulty in swallowing has been less frequently noted than dyspnoea (three times in sixteen cases).

Prognosis. The prognosis is favorable as regards the re-establishment of function even if the dislocation is not reduced, and reduction is, as a rule, easy, and retention more complete than after dislocation forward.

Treatment. Reduction can commonly be effected by drawing the shoulder outward and backward, and this seldom requires more force than the surgeon himself can exert without assistance. In one case Lenoir was obliged to provide counter-extension by a bandage carried around the chest and made fast to the wall, and extension by another bandage passed around the upper part of the arm and drawn upon by two assistants while a third held the elbow near the side. In another of his cases one assistant placed his knee against the patient's back and drew his shoulder backward while a second assistant held up the chin, and Lenoir passed his finger down behind the end of the clavicle and pressed it forward. Reduction took place promptly and with a distinct snap.

Recurrence of the displacement should be opposed by dressings that hold the shoulder back and down. The necessity exists as in dislocation forward to examine the joint frequently with the object of promptly detecting and correcting any faulty position, and to wear the dressings for several weeks.

Dislocation Upward. (*Luxatio Claviculæ Suprasternalis.*)

The first recorded case of this form of dislocation was published by Duverney¹ in 1751, the next was observed by Sédillot² in 1835, and Malgaigne in 1855 could collect only five cases. The number is now increased to about twenty,³ with two autopsies, Duverney's and R. W. Smith's.⁴ It differs from the forward dislocation in that the bone lies behind the sternal portion of the sterno-cleido-mastoid muscle instead of in front of and below it.

The cause in the sudden, traumatic cases, is the forcible depression of the shoulder and the acromial end of the clavicle, by which the upper portion of the capsule is torn and the end of the bone lifted out of the joint; then, the force continuing to act and pressing the shoulder

¹ Duverney: *Traité des Maladies des Os*, vol. i. p. 201.

² Sédillot: *Contributions à la Chirurgie*, 1868, vol. i. p. 261.

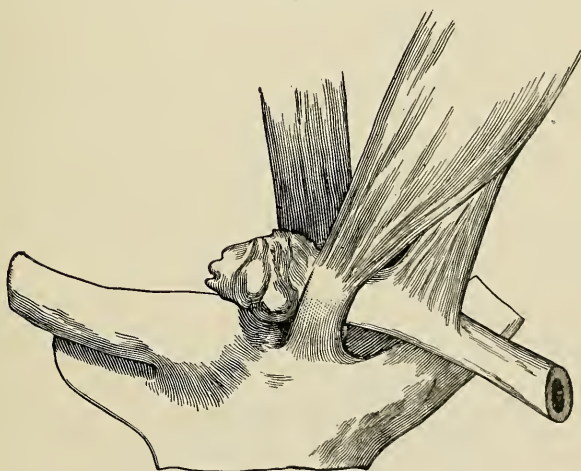³ For the bibliography see Malgaigne, Hamilton, and Polaillon, and cases here mentioned *passim*, and Evans, *Gaillard's Medical Journal*, March, 1888.

⁴ R. W. Smith: *Dublin Journal Medical Sciences*, 1872, vol. ii. p. 450.

inward toward the chest, the bone is forced inward to or beyond the median line and sometimes upward so far even as to rest upon the anterior surface of the larynx. A unique mode of production was reported by Dr. A. N. Blodgett.¹ The patient was carrying one end of a piano when the two men who were carrying the other end allowed it to fall. The patient felt a sharp pain at the root of the neck and front of the chest, and it was found that the sternal end of the right clavicle had been dislocated upward and inward and that the first and second costal cartilages of the same side had been dislocated from the sternum forward and outward.

In Duverney's case all the ligaments were torn and the periosteum was stripped from the end of the clavicle; probably, therefore, the meniscus remained attached to the sternum. In R. W. Smith's case, the end of the left clavicle rested on the upper border of the sternum in contact with the right sterno-cleido-mastoid, having passed behind the sternal portion of the left sterno-cleido-mastoid and in front of the sterno-hyoids. The anterior and posterior sterno-clavicular ligaments and the costo-clavicular were torn; the meniscus accompanied the clavicle. The subclavius muscle was relaxed but not torn. There were dyspnoea and dysphagia; death was the result of associated injuries.

FIG. 273.



Dislocation upward of the sternal end of the clavicle. (R. W. SMITH.)

In a case reported by Stokes,² and mentioned above, the dislocation is described as forward and upward, and the joints as being so loose that the sternal end of each clavicle could be easily moved in any direction; this condition had been produced by the "powerful action of the sterno-cleido-mastoid muscles" in forced inspiratory efforts provoked by great dyspnoea due to ascites. At the autopsy the ligaments were found to be greatly stretched, the sterno-clavicular being half as long again as natural and the rhomboids (costo-clavicular) also elon-

¹ Blodgett: New York Medical Journal, 1883, vol. xxxviii. p. 34.

² Stokes: Dublin Medical Journal, 1852, vol. xiii. p. 459.

gated. The relations of the end of the clavicle to the sternal portion of the sterno-cleido-mastoid are not stated, and it remains uncertain, therefore, whether the case properly belongs in the class of dislocations upward.

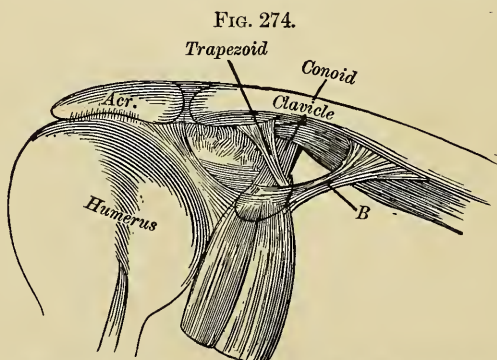
Symptoms. If the dislocation is *incomplete* the only symptoms are the projection of the end of the clavicle above its normal position, and the local pain increased by movements of the head and arms.

The symptoms of the *complete* form are the recognizable displacement of the end of the bone inward and upward to a variable distance, its position behind the sternal portion of the sterno-cleido-mastoid of the same side, the depression of the shoulder, and its approximation to the chest; local pain, sometimes dyspnoea and dysphagia, inhibition of voluntary movements of the shoulder and head because of pain, and sometimes the impossibility of passively raising the shoulder. The emptiness of the clavicular notch of the sternum may perhaps be recognized by palpation.

Treatment. Reduction is effected by drawing the shoulder outward and making direct pressure downward and outward upon the sternal end of the clavicle, but here again the chief difficulty is to prevent recurrence. Fixation of the shoulder by various dressings and the recumbent position to avoid the depression of the shoulder by the action of gravity have been employed with a fair measure of success, the resulting deformity being slight and the re-establishment of the usefulness of the arm complete.

2. DISLOCATIONS OF THE ACROMIAL END OF THE CLAVICLE.

Anatomy. The clavicle is attached to the scapula at two points, namely: at its extreme end to the inner margin of the acromion by the acromio-clavicular joint, and further inward to the coracoid process by the coraco-clavicular ligaments. The articular surfaces forming the



Ligaments uniting the clavicle to the scapula. (HENLE.)

acromio-clavicular joint are flat and oval in shape, the long axis being antero-posterior, and the upper edge of the end of the clavicle rises to a variable distance above the upper surface of the acromion. The

articular surfaces are separated in part, sometimes completely, by an interposed meniscus of fibrous tissue, wedge-shaped, with its base directed upward and attached to the broad, strong *superior ligament*; the *inferior ligament*, usually much thinner than the superior, closes the joint below. The coraco-clavicular ligament is composed of two portions, the postero-internal, or *conoid*, and the antero-external, or *trapezoid*.

Complete dislocation involves not only the rupture of the ligaments of the joint proper, but also of the conoid and trapezoid ligaments to a greater or less extent. The joint allows motion in all directions, the extreme ranges being, according to Albert, 20 to 30 degrees in the horizontal plane, and 60 to 70 degrees in the vertical plane; and its dislocation appears to be commonly effected, not by extending the movement of the joint beyond its normal limit, but by direct displacement of one bone upon the other.

The clavicle may be displaced upward, **supra-acromial dislocation**, or downward and backward, **subacromial dislocation**, or downward and forward under the coracoid process, **subcoracoid dislocation**. The first is by far the most common; the last has been observed by only two surgeons, one of whom reported five cases.

Some authors, following the system of nomenclature used in the dislocation of other joints, term them dislocations of the scapula, but the innovation has not made its way.

Supra-acromial Dislocation. (Luxatio Claviculæ Supra-acromialis.)

The dislocation may be complete or incomplete; in the latter the clavicle is displaced upward to a distance equal or nearly equal to the vertical diameter of its articular surface; in the former the separation of the articular surface is complete, and there is an additional displacement outward over the acromion, or outward and backward, or to a greater distance upward.

The cause is usually a blow received upon the point of the shoulder and directed downward with an inclination inward, forward, or backward. The vigorous contraction of the trapezius by which the clavicle is prevented from accompanying the acromion in its descent seems to be an important, perhaps an essential, factor in the production of the lesion, the alternative factor that has been suggested, arrest of the descent of the clavicle by contact with the first rib, seems more likely to produce dislocation of the sternal end of the bone. Malgaigne found in one case marked tenderness of the trapezius and sterno-cleido-mastoid muscles, and cites the fact as proof of the correctness of this theory in some cases. The absence of such tenderness in other cases should not, I think, be deemed opposing evidence, for an efficient contraction not followed by injury of the muscle is easily conceivable. A case reported by Cloquet,¹ and sometimes quoted as an example of dislocation by direct violence, seems clearly to indicate the important part played by muscular action: A man who was carrying a beam upon his

¹ Cloquet: Journal Hebdomadaire, 1830, vol. vii. p. 400, quoted by Malgaigne.

shoulder made a violent effort to keep it from falling, and found he had thereby produced a dislocation. Polaillon¹ mentions a case communicated to him by Dolbeau in which the dislocation was caused in a woman by an attempt to strike a child. In such a case the momentum of the arm presumably takes the place of the more common external violence received upon the shoulder. In one of my cases the dislocation was caused by a blow from a falling brick, which also broke the acromion at its base and dislocated the humerus. (See Chapter XLII.)

A unique case in which the dislocation was caused by a blow received upon the clavicle from below upward is reported by Hamilton;² a bolt three-quarters of an inch in diameter was driven through the skin on the anterior margin of the left axilla, breaking the first rib, severing the coraco-clavicular ligaments, and forcing the clavicle upward from its place.

Malgaigne reports a case in which the injury was apparently caused by a fall upon the elbow.

Pathology. Our knowledge of the character and extent of the laceration of the ligaments is derived almost exclusively from clinical observation and experiments upon the cadaver, for there are only two autopsies and one museum specimen. One autopsy, reported by Malgaigne,³ was in a case of incomplete dislocation and showed that the articular facet of the clavicle had not entirely left that of the acromion; the superior acromio-clavicular ligament was only stretched or perhaps slightly torn away from the acromion, and the inferior one was in great part ruptured; on the other hand, the strong coraco-clavicular ligaments were torn entirely across. There were other and more serious associated lesions, among them a comminuted fracture of the body of the scapula on the same side.

The second autopsy, made and reported by Dr. P. R. Bolton,⁴ was in a case of my own at the Hudson Street Hospital, April, 1902. Both acromio-clavicular ligaments were torn across, and the conoid and trapezoid ligaments were torn away from the coracoid process.

The museum specimen is one preserved in St. Thomas's Hospital and mentioned by Sir Astley Cooper.⁵ The patient was a man sixty years old who died of pulmonary disease seven weeks after the receipt of the injury. The account from which I quote states only that "the clavicle was found dislocated at its scapular extremity, and projected considerably over the spine of that bone. The acromion process, just where the clavicle is united with it, was broken off." Malgaigne, quoting apparently from some other account, says that Cooper supposed that all the acromial and coracoid ligaments must have been torn. He adds that this is what experiments upon the cadaver indicate, but that it is melancholy to limit one's self to conjectures when the specimen itself can be examined. Cooper⁶ gives also a drawing of a specimen of an old dislocation in which the conoid ligament had become ossified.

¹ Polaillon: *Dict. Encyclopédique des Sciences Médicales*, art. Clavicule, p. 719.

² Hamilton: *Fractures and Dislocations*, 1880, p. 626.

³ Malgaigne: *Loc. cit.*, p. 432.

⁴ Bolton: *Annals of Surgery*, October, 1902, p. 586.

⁵ Cooper: *Dislocations and Fractures*, Am. ed., p. 313.

⁶ Cooper: *Loc. cit.*, p. 312.

Experiments upon the cadaver have yielded results that are not entirely in accord with one another. Malgaigne found that even in incomplete dislocation the capsular ligaments were completely, and the coraco-clavicular partly, ruptured. Bonisson and Ader found that incomplete dislocation could be easily produced after division of the acromial ligaments and without injury to the coracoid, and even to such a degree that the articular surfaces were completely separated vertically from each other. Ader further showed that after division of the coracoid ligaments a complete dislocation could be readily produced and the end of the clavicle removed to a distance of two centimetres from the acromion.

Instead of rupture of the upper acromial ligament avulsion of the edge of bone on either side to which it is attached has frequently been observed clinically.

Among the recorded complications are simultaneous dislocation of the sternal end of the same or of the other clavicle, fracture of the clavicle, of a rib, of the acromion process, of the coracoid process, of the body of the scapula, and subcoracoid dislocation of the shoulder of the same side.

Symptoms. In incomplete dislocation the deformity consists in the elevation of the end of the clavicle to a variable distance, not equal, however, to the thickness of the bone, above the level of the acromion, and this elevation can be readily recognized by palpation, and can generally be reduced by moderate pressure.

In complete dislocation the elevation is greater, more than an inch in some cases, or is combined with displacement outward, backward, or forward. The displacement outward is, of course, due to the approximation of the acromion to the chest. The greatest recorded overriding is one inch (Malgaigne, Klar¹). It has been observed also in some cases that the scapula has undergone a movement of rotation by which its inferior angle is carried backward toward the spine, and the anterior, upper angle is lowered, a movement that is attributed to the action of the weight of the arm; it has been observed only when the displacement inward of the scapula toward the chest has not been very marked.

There is local pain, more or less severe, persisting for a variable length of time, and increased by pressure or by voluntary movements of the shoulder or arm. The interference with voluntary movements of the limb varies greatly, and corresponds measurably with the pain and the extent of the displacement; some patients are completely disabled, others can use the limb quite freely.

Diagnosis. The diagnosis is to be made by recognition of the changed relations of the bones, which is easy in the cases of complete dislocation, and seldom difficult in the incomplete. In the latter case the local pain and the possibility of reducing the bony prominence by pressure, together with its immediate reappearance on the removal of the pressure, will give the clew. The question will then lie between dislocation and fracture of the clavicle near its end, and this may be answered by tracing the outline of the acromion, comparative measurements of the two clavicles, and consideration of the presence or

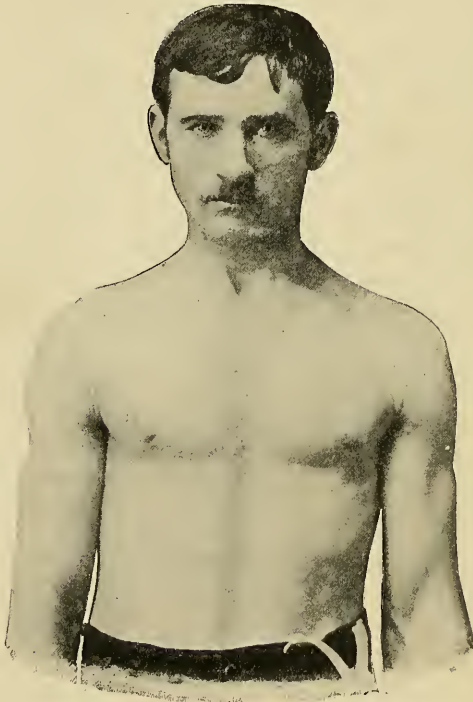
¹ Klar: Deutsche Zeitschrift für Chir., vol. lxxiii. p. 282.

absence of signs peculiar to fracture. The error of mistaking the injury for a dislocation of the shoulder appears to have been quite frequently made, although it is difficult to understand how it could occur if the examination were thorough.

A contusion or sprain of a joint in which the end of the clavicle stood abnormally high might easily be mistaken for a recent dislocation, since it would present all the signs of one, but the error would be of slight importance and would cause no harm to the patient beyond perhaps a needlessly prolonged confinement of the limb.

Prognosis. The prognosis in the incomplete form is good, for although the displacement has commonly persisted in some measure,

FIG. 275.



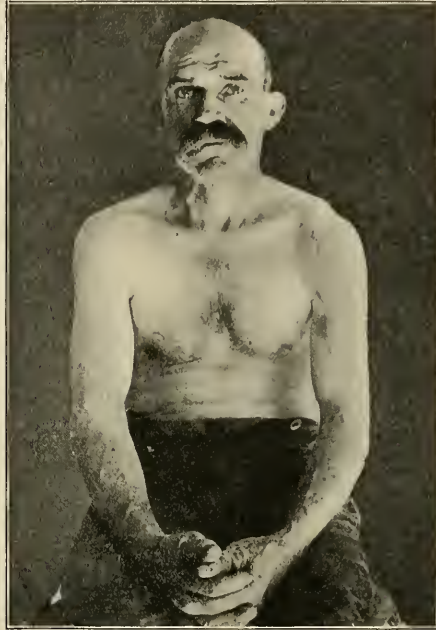
Complete supra-acromial dislocation of the clavicle.

the resulting deformity is slight. In the complete form, with marked displacement, there is, in addition to the common imperfect maintenance of the reduction, an occasional inability even to make reduction. In such cases the functions of the limb may or may not be seriously interfered with by the persistence of the displacement. In the unique case quoted above from Hamilton, of dislocation by direct violence acting upon the clavicle from below upward, the bone remained displaced two inches upward, yet the patient could use the arm as freely and strongly as the other. On the other hand, in one of Bardenheuer's cases, in which the displacement persisted, the diminution of function

was considerable, and the power of abduction of the arm was almost entirely lost.

Treatment. In most cases the reduction of even the complete dislocation can be readily effected by drawing the shoulder either directly upward, or upward and outward, or backward, and at the same time pressing the clavicle directly toward its place. The only opposition

FIG. 276.



Old dislocation of the outer end of the clavicle.

that ordinarily needs to be overcome is the weight of the arm, which draws the shoulder downward and inward away from the clavicle; with this is sometimes associated reflex contraction of the trapezius which draws the clavicle upward, and in a few cases the end of the clavicle has passed through the trapezius in such a way that the interposed fibres of the muscle have constituted a serious obstacle to reduction. To overcome this latter obstacle Moutet¹ subcutaneously divided the clavicular portion of the trapezius close to its insertion and was then able easily to restore the bone to its place and keep it there by a bandage.

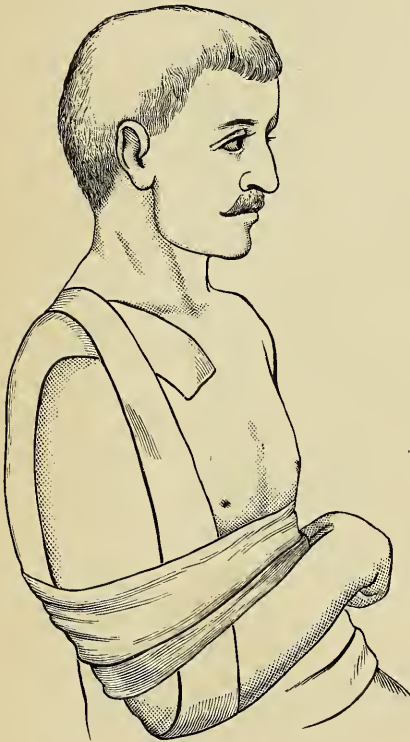In making reduction the arm should be kept near the side and pressed directly upward. If the shoulder needs to be drawn directly outward, this should be done by the hand introduced into the axilla, or by grasping the upper part of the arm with both hands, the fingers resting in the axilla, and the thumbs against the projecting articular surface of the clavicle, and thus drawing the shoulder outward while

¹ Moutet: Montpellier Médical, 1861, vol. vi. p. 219, quoted by Polaillon.

pressing the clavicle inward. In short, reduction is to be effected by forcing the acromion upward, and outward, forward, or backward, as may be indicated by the direction of the displacement, by pressure exerted upon it through the humerus, and by pressing the end of the clavicle in the opposite direction.

The maintenance of the reduction was long deemed difficult. The weight of the arm constantly tends to reproduce the deformity, to carry the shoulder downward away from the clavicle, and the dressings employed did not satisfactorily oppose it. The following simple dressing

FIG. 277.



Dressing for supra-acromial dislocation of the clavicle.

which I devised about 1883 has proved perfectly satisfactory: A strip of stout adhesive plaster, about four feet long and two or three inches wide, is placed with its centre under the elbow, the forearm being flexed at or within a right angle, and its two ends are carried upward, one behind, the other in front, of the arm, and crossed over the shoulder at a point corresponding to the end of the clavicle, and then fastened to the front and back of the chest respectively. While applying it, the surgeon must press the elbow firmly upward and the clavicle downward. The eye or finger can readily detect through the plaster any recurrence of the displacement. The dressing should be worn for three or four weeks.

Wiring of the clavicle to the acromion has been practised a few times in recent and in old dislocations, but is not generally approved; if anything of the kind should need to be done periosteal catgut sutures would probably be sufficient.

Subacromial Dislocation. (*Luxatio Claviculæ Subacromialis.*)

This dislocation, of which Petit was the first to make mention, is so rare that Polaillon, in 1875, could collect only six recorded cases; the list has now been increased to eleven, or, adding Newman's, to twelve. The first four, quoted by Malgaigne,¹ are those of Melle, 1765, Fleury, 1816, Tournel, 1837, and Baraduc, 1842. The others are two observed

¹ Malgaigne: *Loc. cit.*, pp. 448 and 452. Malgaigne thinks Baraduc's case was probably pathological, not traumatic. The reference he gives for Tournel is incorrect; it should be 1837, not 1847.

and reported by Morel-Lavallée,¹ one by Dr. W. B. Chase,² one by Dr. J. X. Allen³ and one by Dr. Eaton.⁴ König⁵ refers to one that was observed in Bruns's clinic, and Bardenheuer⁶ makes several quotations from the report of a case by Uhde, but does not give the reference. He speaks also of a case reported by Gosselin in 1881, but I have been able to find only a clinical lecture by Gosselin on a case of supra-acromial dislocation. To these may be added Newman's case of simultaneous dislocation of both ends of the clavicle (*vide infra*), in which the outer end was displaced under the acromion.

The cause in these cases was direct violence exerted upon the upper surface of the outer end of the clavicle (Melle, Tournel, Chase), a fall upon the shoulder in three (Fleury, Morel-Lavallée's two), and muscular effort in one (Allen).

Allen's patient, a stout muscular girl sixteen or seventeen years old, was chopping wood, and at the moment she had the axe raised and was about to deliver the blow she felt a sharp pain in the shoulder, and the arm fell powerless by her side. When seen six weeks later there was a marked depression on the top of the shoulder, much discoloration in the axilla, and the inferior angle of the scapula was thrown prominently outward. There was complete loss of voluntary motion of the arm and hand, and numbness of the entire limb. Reduction was easily effected by drawing the shoulder outward and backward.

Chase's case may be taken as a type of direct violence. A boy eight years old fell head foremost from a height of twelve or fifteen feet and struck with the top of his shoulder against the rung of a ladder. An ecchymosis over the outer end of the clavicle showed where the blow had been received. The acromial end of the clavicle was dislocated downward and somewhat backward, the shoulder was flattened in front, and the acromion very prominent. Reduction, under anæsthesia, was easily effected by drawing the shoulder outward and backward and pressing the clavicle in the opposite direction. There was no tendency to recurrence and recovery was complete in five weeks.

Of the other two cases of direct violence, in one, Tournel's, the injury was caused by a horse stepping upon the front of the patient's shoulder as he lay on the ground; in the other, Melle's, the patient, who was a Russian soldier, attributed the injury to an effort he made when six years old to lift, with the aid of another child, a keg of water by means of a stick resting on his shoulder. He had also a dislocation of the corresponding humerus, which apparently had been received at the same time.

The autopsy in Melle's case and experiments upon the cadaver show that the ligaments uniting the acromion and coracoid to the clavicle are completely ruptured; the clinical facts show that the displacement of the clavicle is not only downward and outward under the acromion but

¹ Morel-Lavallée: Bull. de la Soc. de Chir., 1863, vol. iv. pp. 51 and 240.

² Chase: Transactions of the Medical Society of the State of New York, 1879, p. 170.

³ Allen: New York Medical Record, 1881, vol. xix. p. 206.

⁴ Eaton: New York Medical Record, 1881, vol. xx. p. 734.

⁵ König: Speciel. Chirurgie, 3d ed., vol. iii. p. 16.

⁶ Bardenheuer: Deutsche Chir., Lief. 63 a, p. 89.

also backward to an extent that leaves the acromial facet entirely in front of the clavicle. This is perhaps to be accounted for by the presence of the head of the humerus, which opposes a displacement directly downward; and the same anatomical fact may explain the coincident dislocation of the humerus in Melle's case. The only other complications observed clinically are fracture of the surgical neck of the humerus, in one of Morel-Lavallée's cases, and simultaneous dislocation of the other end of the clavicle, in Newman's; but in experiments upon the cadaver fractures of the acromion and of the clavicle have been met with. In Melle's case the meniscus accompanied the clavicle.

Symptoms. The pain at the moment of the accident may be severe or slight; voluntary movements of the arm are interfered with, and sometimes entirely prevented; and in one case (Allen) there was persistent numbness and tingling in the arm and hand, indicative of pressure upon the brachial plexus. The appearance of the shoulder is affected by the sinking of the acromion and rising of the inferior angle of the scapula so that it appears to be inclined forward. The shoulder is usually approximated to the side of the head, but may be on a lower level than the opposite one because of the inclination of the trunk. The central portion of the clavicle may be depressed below the level of the soft parts in front and behind; its sternal end projects sharply forward, and its acromial end can be traced with the finger to the point where it engages under the acromion a little behind the articular facet on the latter. An obscure part of the description of Tournel's case, which Malgaigne found unintelligible, seems to mean that the end of the clavicle passed entirely under the acromion and projected beyond its outer border.¹ The outline of the acromion and its empty articular facet can usually be traced with the finger, although in one case the swelling of the soft parts was very great.

Prognosis. The prognosis is favorable; in Tournel's case, in which the reduction was not attempted, the patient had good use of the limb; in Melle's a new joint had formed between the under surface of the acromion and the upper surface of the clavicle, but the effect upon the functions of the limb cannot be known, for a dislocation of the humerus coexisted. In all the other cases in which the record is sufficiently complete reduction was easily effected with or without the aid of anæsthesia, and there appears to have been no tendency to recurrence except in one case.

Treatment. Reduction is made by drawing the shoulder outward and backward, the arm being kept parallel to the trunk, and counter-extension being made by a bandage passed around the chest. Tournel reduced by placing his knee between the shoulders and drawing them forcibly backward; and Uhde did likewise, at the same time pressing the clavicle forward. The arm should be fixed against the trunk, and the forearm supported by a body bandage and sling.

¹ The phrase is: "L'épaule présentait en outre deux saillies; une interne et supérieure formée par l'acromion, l'autre externe et inférieure formée par l'extrémité externe de la clavicle."

Subcoracoid Dislocation. (Luxatio Claviculæ Subcoracoidea.)

Authority for the belief that this singular displacement has ever been clinically observed rests upon the statements of two surgeons, Godemer and Pinjon. Godemer met with his first case in 1833 and with four others in the following five years; Pinjon reported a sixth example in 1842. Godemer's cases were reported to the Société médicale d'Indre et Loire, and published in 1843; his paper was republished by Malgaigne in the *Revue médico-chirurgicale de Paris*, 1847, vol. ii. p. 155; Pinjon's case was reported in the *Journal de Médecine de Lyon*, 1842, vol. iii. p. 58. All systematic writers upon the subject are agreed in viewing these reports with much suspicion because of their remarkable similarity in detail and the great anatomical obstacles to the production and maintenance of the displacement.

The features, as described by Malgaigne, are as follows: Four of the six patients were between the ages of sixty-seven and seventy-one years; the remaining two are described as adults. In every case the injury was caused by a fall upon the shoulder.

The symptoms were: 1st. More or less pain and a large ecchymosis in the coraco-acromial region.

2d. A depression at the normal position of the clavicle; this bone was found to be inclined downward and outward, and its acromial end lodged in the axilla.

3d. The coracoid and acromion processes were prominent under the skin.

4th. The shoulder was inclined downward and forward; the inferior angle and posterior border of the scapula formed posteriorly a projection which disappeared when the shoulder was carried upward and backward.

5th. The arm was dependent, but could be easily moved in any direction except upward and inward.

Godemer made reduction in three cases by grasping the clavicle and disengaging it from under the coracoid process, while an assistant forced the shoulder backward and outward. In his other two cases the swelling prevented reduction before the third day. Pinjon failed to reduce because of the fainting of his assistant; the next day reduction was made by a "bone-setter."

3. SIMULTANEOUS DISLOCATION OF BOTH ENDS OF THE CLAVICLE. (TOTAL DISLOCATION.)

The recorded cases of this injury are now eleven in number: Riche-
raud,¹ Morel-Lavallée,² North,³ Hutchinson,⁴ Haynes,⁵ Col,⁶ Lund,⁷
Rombeau,⁸ Hulke,⁹ Newman,¹⁰ and Cousins.¹¹ Eight of the patients

¹ Richerand: Arch. gén. de Méd., 1831, vol. xxv. p. 108; reported by Porral, his interne.

² Morel-Lavallée: Bull. de la Soc. de Chir., 1859, vol. ix. p. 361.

³ North: New York Medical Record, 1866, vol. i. p. 79.

⁴ Hutchinson: Lancet, 1871, vol. ii. p. 711.

⁵ Haynes: British Medical Journal, 1872, vol. i. p. 99.

⁶ Col: Gaz. des Hôpitaux, 1872, p. 893.

⁷ Lund: British Medical Journal, 1874, vol. i. p. 106.

⁸ Rombeau: Bull. Gén. de Thérapeutique, 1874, vol. lxxxvi. p. 537, reported by Gros.

⁹ Hulke: Lancet, 1855, vol. ii. p. 245.

¹⁰ Newman: Ibid., p. 524.

¹¹ Cousins: Jouru. Am. Med. Assoc., 1906, p. 19.

were males, three females ; their ages ranged between thirteen and forty years.

Haynes's patient, a weakly girl, thirteen years old, produced the dislocation while washing the back of her neck with the hand of the affected side ; there was a complete dislocation forward of the sternal end, and an incomplete dislocation upward of the acromial end of the clavicle.

In all the other cases the cause was external violence, usually very great. The mode of production is varied, the most common form appearing to be force exerted along the transverse axis of the shoulders, and pressing forward the one that suffers the injury.

The sternal end has always been displaced forward, and the only additional change in position that is mentioned is, in Morel-Lavallée's case, that it had moved rather upward than downward. The acromial end was displaced backward in four cases (once to a distance of three finger-breadths), upward and outward twice, and once each forward and outward, downward, and incompletely upward. In Hutchinson's case the displacement is not described further than by saying that "when pressure was made on either end of the dislocated bone the other extremity rose perceptibly and protruded the skin."

In seven of the cases reduction of both dislocations was effected and maintained, and the patients recovered with good use of the limb and but little deformity ; in some of them mention is made of more or less persistent projection of the sternal end. Morel-Lavallée was unable to reduce the dislocation of the outer end, although he made direct traction upon it with a hook introduced through the skin. Lund, with the aid of chloroform, could only bring the bone "into fair position ;" at the end of ten days the ends were found "fixed in their new position." In Newman's case, dislocation of the outer end under the acromion, reduction was impossible ; the patient withdrew from the hospital on the tenth day, and remained disabled. The result in Hutchinson's case is not recorded.

Treatment. Reduction has usually been effected by drawing the shoulder outward and backward, and recurrence prevented by immobilizing it in a suitable position by means similar to those employed when the dislocation involves either end alone. Hulke used a gutta-percha splint moulded over the clavicle and bound down by a bandage that crossed the shoulders and was made fast in front and behind to another about the waist. Cousins kept each end in place by a sand-bag, the patient being recumbent.

CHAPTER XLII.

DISLOCATIONS OF THE SHOULDER.

Anatomy—Statistics—Classification—Anterior Dislocations: Subcoracoid, intracoracoid, treatment.

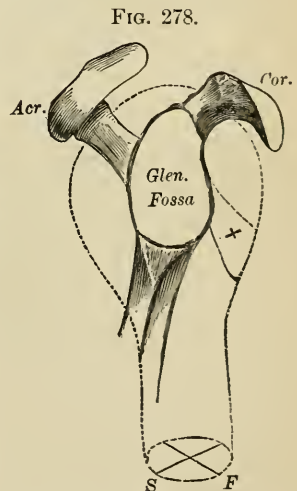
Anatomy.

THE bony surfaces which enter directly into the composition of the shoulder-joint are the glenoid cavity of the scapula and the postero-internal half of the globular head of the humerus. The former is of irregularly oval shape, the more pointed end above and the broader one below, and is slightly concave, being deepened by a low fibro-cartilaginous rim, which is continuous throughout with the capsule, and above also with the tendon of the long head of the biceps. The cavity looks outward and forward in a direction nearly midway between the sagittal and frontal planes of the body when the scapula occupies its usual position.

Against this shallow surface the head of the humerus rests, being held in place by atmospheric pressure, the tonicities of the muscles, and the tension of thickened portions of the capsule in different positions of the limb. On the outer and anterior portion of the upper end of the humerus is the greater tuberosity, bounded internally in front by the bicipital groove which lodges the long tendon of the biceps and has upon its inner side the lesser tuberosity. Between the upper margins of these tuberosities and the globular articular head is a shallow groove, the anatomical neck.

The acromion and coracoid processes lie above, the one on the outer, the other on the inner side, and the strong coraco-acromial ligament uniting them closes in the upper part of the joint, but is separated from its cavity, as are also the two processes, by the interposed capsule and the tendon of the supraspinatus.

The surface of the head of the humerus that is covered by articular cartilage is about one-third of that of a sphere, and the axis passing through its centre meets the long axis of the shaft at an angle of about 130 degrees. The linear extent of the glenoid fossa,



To show the relations of the humerus and scapula. X, the lesser tuberosity. F and S indicate the frontal and sagittal planes.

including its fibro-cartilaginous rim, on a horizontal section is less than half as great as that of the head of the humerus; on a vertical section it is about two-thirds as great. The head of the humerus, therefore, simply rests against the fossa, and its displacement is but slightly opposed by the conditions of contact between them. The muscles which are most closely associated with the joint are the supraspinatus, infraspinatus, and teres minor, attached to the greater tuberosity in the order named from above downward, and the subscapularis, which, arising from almost the whole of the costal surface of the scapula, passes forward, broadly covering the inner side of the joint with its fibres and tendon, to be attached to the lesser tuberosity. The tendon of the long head of the biceps, starting from the upper margin of the glenoid cavity, passes upward and forward over the head of the humerus and then down the bicipital groove, carrying with it a prolongation of the synovial membrane of the joint. The deltoid, from its broad origin on the spine of the scapula, the acromion, and the clavicle, covers the joint superficially on its posterior, external, and anterior aspects; and the coraco-brachialis, the short head of the biceps, and the great vessels and nerves lie upon its inner side.

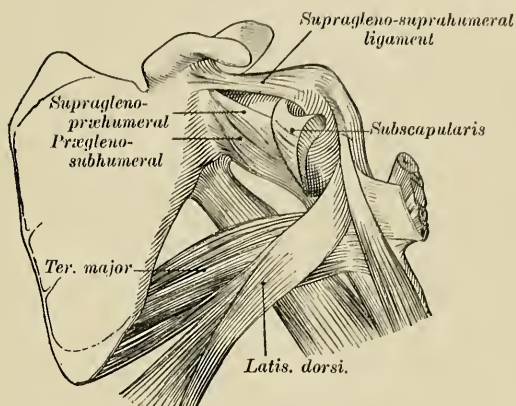
FIG. 279.

Horizontal section through the shoulder-joint: *A*, in inward, *B*, in outward rotation. (HENLE.)

The capsule extends from the free margin of the fibro-cartilaginous rim of the glenoid fossa, or from the surface of bone immediately outside of it, to the anatomical neck of the humerus. At the upper part its scapular insertion is at the base of the coracoid process and separated from the glenoid fossa by the tendon of the biceps; on the posterior and inner portion of the humerus it extends somewhat beyond the cartilaginous surface along the projection upon which the head rests. Between the two tuberosities the synovial membrane by which it is lined is prolonged down the bicipital groove, and is reflected over the long tendon of the biceps. The capsule is reinforced at some points by thickenings of itself which are known as ligaments and by tendons of the scapular muscles; on the inner side it is perforated by the tendon of the subscapularis, and there shows a gap through which the cavity of the joint communicates with the subscapular bursa, a large pouch lying against the inner side of the neck of the scapula and the root of the coracoid process, between them and the upper part of the subscapularis. This opening lies just in front of the upper part of the anterior (inner) margin of the glenoid fossa, has the form of a slit or

creescent, and is usually large enough to admit the end of the finger. When the synovial membrane has been dissected away the gap has the form shown in Figs. 280 and 281, and is partly occupied by the tendon of the subscapularis. The portion of the capsule which forms its

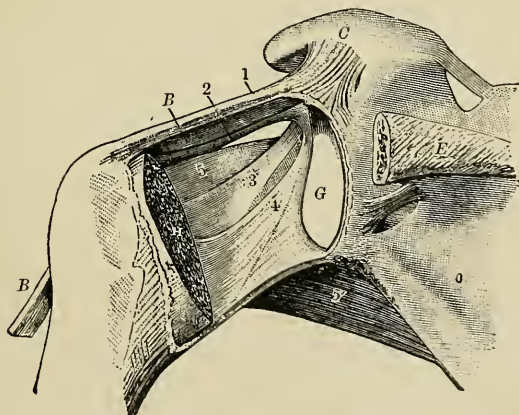
FIG. 280.



The shoulder-joint from in front. (FARABEUF.)

upper margin is called the gleno-humeral ligament, or, to adopt the subdivisions described by Farabeuf,¹ the supragleno-suprahumeral, the portion forming the lower margin is the supragleno-præhumeral, and

FIG. 281.



The interior of the shoulder-joint from behind: 1, coraco-humeral ligament; 2 supragleno-suprahumeral ligament; 3 supragleno-præhumeral ligament; 4, prægleno-subhumeral ligament; 5, upper edge of the tendon of the subscapularis; 5', its lower part; B, biceps tendon; C, coracoid; E, spine of scapula; G, glenoid fossa. (FARABEUF.)

the portion immediately below the latter is the prægleno-subhumeral. These different portions are shown in Figs. 280 and 281, which are copied from Farabeuf's paper. Of them the one that forms the lower

¹ Farabeuf: Bull. de la Soc. de Chirurgie, 1885, p. 391.

margin of the gap, the supragleno-præhumeral, is often of slight strength and underlies and is intimately adherent to the tendon of the subscapularis.

The coraco-humeral ligament is a strong wide band extending from the root and outer border of the coracoid process over the top of the joint to the neck of the humerus above the greater tuberosity, and is intimately connected with the capsule and the tendon of the supraspinatus. It is thought to play an important part in determining the position taken by the limb when dislocated, and the manœuvres by which the dislocation can be reduced.

The tendon of the supraspinatus passes between the acromion and the head of the humerus and is attached to the upper part of the greater tuberosity; it is blended with the capsule and is separated from the acromion by a bursa. Below it come the tendons of the infraspinatus and teres minor, passing to the lower and middle facets respectively and also blended with the capsule.

Outside the capsule is a loose layer of connective tissue which separates it and the tendons of the outer muscles from the inner surface of the deltoid; within this layer is the subdeltoid bursa, extending under the acromion, which deserves special mention because of the fact that when the tendon of the supraspinatus is torn away from its attachment in a dislocation and retracts under the acromion with the adherent capsule, this bursa is thereby opened and placed in communication with the cavity of the joint, and the upper portion of the capsule is thus greatly lengthened. The influence of these new conditions in favoring recurrence of dislocation has been discussed in Chapter XXIX.

With respect to the nerves and arteries it is necessary to speak only of the circumflex nerve and of the arterial branches which pass outward, the two circumflex and the subscapular. The circumflex nerve winds around behind the neck of the humerus to its outer side, to be distributed to the deltoid muscle and to the integument covering it. It may be so injured in a dislocation that the deltoid will be paralyzed, perhaps permanently.

The circumflex and subscapular arteries pass outward to be distributed among the muscles of the scapula and upper part of the arm; when in a dislocation the head of the humerus presses the axillary artery inward, those branches are put upon the stretch because they are prevented by the attachment of their branches to the tissues from moving inward as freely as the main trunk does, and consequently they may be ruptured or torn away from the side of the main artery. This accident may be the consequence of the dislocation itself, or of the efforts to reduce it.

The movements which are most frequently concerned in the production of a dislocation are outward rotation and abduction. In the latter the elbow is raised directly outward and forward from the side of the body by the action of the deltoid, the plane in which it moves being more or less exactly that which would be represented by the prolongation of the broad surface of the shoulder-blade. As the movement is made, the head slides downward on the glenoid fossa, the long head of the triceps, the lower part of the subscapularis, and the lower and inner

portion of the capsule are made tense, and the movement is arrested when the top of the greater tuberosity comes into contact with the upper margin of the glenoid fossa, and the side of the shaft close below the tuberosity touches the acromion. If the movement is now continued, and the arm raised to the side of the head, it is effected by the rotation of the scapula and the elevation of its outer portion. If, on the other hand, the movement is continued while the scapula is kept stationary, the centre of motion is transferred to the point of contact between the humerus and the edge of the acromion, and the head of the bone is forced downward against the already tense capsule and ruptures it at its lower and inner portion, where it presses directly against it.

In outward rotation when the arm is hanging by the side or is but slightly abducted the movement is arrested by the tension of the capsule on the inner side, and at the same time the lower and outer part of the greater tuberosity comes into contact with the outer lip of the glenoid fossa; if the movement is then continued the capsule yields, but the head does not become dislocated unless some other force intervenes to press it inward through the rent that has thus been made.

In all the other movements similar conditions are found, and dislocations following them are less frequent only because the movements are themselves less frequently carried beyond the limits set by the structure of the joint. Thus, adduction and rotation inward are checked by contact of the arm with the body before the capsule is put upon the stretch, and extension of the arm behind the axillary line must be carried very far before a new fulcrum is found, and is also a movement that is rarely produced or exaggerated by external violence.

Statistics.

The great frequency of dislocation of the shoulder is fully explained by the structure of the joint and by its exposure to the dislocating action of direct and indirect violence. This frequency is so great that dislocations of the shoulder are about as numerous as all the other dislocations of the body combined. The tables of statistics given in Chapter XXVII. show percentages varying from 40 to 51 of all dislocations. Malgaigne's statistics of 489 cases contain 321 of the humerus, more than 65 per cent.; Gurlt's collection of 907 cases in the hospitals of Berlin, Paris, and Philadelphia contain 563 of the shoulder, 58 per cent.; Bardenheuer¹ saw 20 in a total of 37 cases treated in one year, 54 per cent. Krönlein's statistics, which are especially valuable because they are made up from both hospital and polyclinic records, give a total of 207 dislocations of the shoulder out of 400, 51 per cent., of which 184 were in males and only 23 in females; of Malgaigne's 370 cases 97 were in women; classified according to age and sex they both show that the injury is rare in youth, infrequent in old age, and most frequent in middle life. The youngest recorded case, excluding obstetrical cases, is Villar's,² fifteen days old. The relative frequency at

¹ Bardenheuer: *Deutsche Chirurgie*, Lief. 63 a, p. 279.

² Villar: *Provincial Medical Journal*, August 26, 1892.

the different ages, established by taking into account the percentages of total population belonging to those ages, differs somewhat from the actual frequency, the maximum being found above the age of fifty years. The proportions calculated from Krönlein's statistics with the aid of the relative numbers of the population at the different ages, as given in Chapter XXVII., are five, nine, eleven, and twelve respectively for the decades from thirty-one to seventy. This relatively greater frequency in advanced years is much more marked in women than in men, a fact which is to be explained by the greater exposure to violence incident to the occupations and habits of men in middle life. It indicates, I think, that a much larger proportion of the dislocations in advanced life are due to falls while walking than in middle life, since that is an accident to which both sexes are more equally exposed than they are to others.

The relations pointed out by Krönlein as existing between dislocations of the shoulder and those of the elbow and fractures of the clavicle are interesting. His statistics show that during the first two decades of life, a period in which dislocations of the shoulder are rare, dislocations of the elbow and fractures of the clavicle are most frequent. Thus, of 109 dislocations of the elbow contained in his table, 80 of the patients were under twenty years of age, and of 100 cases of fractures of the clavicle collected by him 70 of the patients were under ten years of age; while of 207 dislocations of the shoulder none of the patients was less than ten, and only 2 less than twenty years old. He thinks fractures of the clavicle are in childhood the equivalent injury of dislocations of the shoulder by direct violence in middle life, and dislocations of the elbow the equivalent injury of dislocations of the shoulder by indirect violence.

Classification.

The head of the humerus in leaving the joint may pass at first upward or downward, backward or forward, and may come to rest in any one of a great number of positions. The classification of the varieties is beset with much difficulty, because of their number, because of the frequency and importance of the secondary displacements, and last, though not least, because of the number of classifications that have already been made and are more or less current. The confusion has been further increased by the application of the same or very similar terms to different varieties by different authors. With the rare dislocations backward, and the still rarer ones upward, there is no difficulty; the uncertainty arises in connection with those in which the head of the humerus has passed across the anterior lip of the glenoid fossa. A brief account of some of the classifications and terms heretofore and still in use will show their differences and resemblances, and may serve as a convenient introduction and preparation for the classification that must follow.

Sir Astley Cooper's classification, upon which those now in use in England and America have been in the main constructed, recognized four kinds of dislocations: 1. Downward and inward into the axilla;

2. Forward, the head of the humerus lying under the clavicle on the sternal side of the coracoid process ; 3. Backward ; 4. Partial inward, the head resting against the outer side of the coracoid process. It is apparent, from his description, that the first and fourth included the common, frequent cases, those which are now generally termed "subglenoid," or "into the axilla," and "subcoracoid," respectively.

A few years later Malgaigne followed, also with four principal forms, but only one of them the same as Cooper's. His grouping is as follows :

Dislocations into the axilla	{	1. Subcoracoid, complete ; quite common.
		2. Subcoracoid, incomplete ; rare.
		3. Subglenoid ; rare.
Dislocations inward . . .	{	4. Intracoracoid ; most common of all.
		5. Subclavicular ; rare.
Dislocations backward . . .	{	6. Subacromial ; rare.
		7. Subspinous ; very rare.
Dislocations upward . . .		8. Supracoracoid ; only two cases known.

All these titles are now in general use ; but while the last four, and perhaps the second also, are still used to designate the forms which he designated by them, the others have been used with different, sometimes with widely different, meanings. The first form, the complete subcoracoid, was "characterized by the projection of the head of the humerus in the axilla, and its position exactly below the coracoid process ;" it would be included in Cooper's first group, dislocation downward into the axilla. His second subdivision, incomplete subcoracoid, was the same as Cooper's fourth, partial dislocation inward. His third, subglenoid, was one concerning which he seems to have been far from having very precise notions ; he had seen only one case, and had been able to collect only eleven others, and of these the symptoms differed widely, the head of the humerus being described as raising the anterior wall of the axilla in one case and the posterior in another, as resting against the second intercostal space in one and against the third in another, and even as having perforated the wall of the chest and lodged within it. The one feature which they had in common, and which he gives as pathognomonic, was that the head of the humerus was not immediately below and in contact with the beak of the coracoid process, but was separated from it by a greater or less interval. Apparently the class was created simply to collect together the odds and ends, the irregular cases that were not subcoracoid ; and the idea which suggested the name given to it was that the primary displacement took place more directly downward than in the preceding varieties. It will be seen that the name has since been applied to a very much larger proportion of cases.

His second main division embraced two varieties, the intracoracoid and the subclavicular. Concerning the latter there is no misconception ; the term has remained in use, and with the same meaning. The group is made up of those cases in which the head of the humerus has passed entirely to the inner side of the coracoid process, and lies below the clavicle. But the other term, intracoracoid, is generally employed in a much more restricted sense than by Malgaigne. By it he design-

nated the greatest number of dislocations, more than two-thirds of those he saw at the Hôpital St. Louis; he applied it to those in which the head of the humerus, while still remaining under the coracoid process, overlapped it on the inner side by more than half its own diameter. Most of such cases are now termed subcoracoid, and only those in which the head has passed almost, if not entirely, to the inner side of the process are called intracoracoid.

The tendency of the more recent French and German writers is to make a single group of all the dislocations in which the humerus passes to the anterior side of the scapula, containing four or more subdivisions or varieties, two of which, the subclavicular and intracoracoid, in the narrower sense, are accepted by all. Of the remaining two principal ones, the subcoracoid and the subglenoid, the former is made to include the great majority, and the subglenoid is either closely and distinctly restricted to the very rare cases in which the head of the humerus is displaced directly downward upon the tendon of the long head of the triceps, or Malgaigne's grouping is accepted with all its diversities and vagueness. In the former case the group is removed from the principal division of "anterior" or "præglenoidal" dislocations, and made to form by itself another principal division, termed "dislocations downward."

The English and American writers, as a rule, divide the same cases into subglenoid and subcoracoid, basing the distinction between them upon the clinical feature of the greater or less facility with which the head of the humerus can be felt in the axilla; those in which it is more prominent in the axilla are "subglenoid," those in which it is more prominent behind the anterior wall of the axilla, close beneath the coracoid process, are "subcoracoid." The objections to this grouping are that it does not sufficiently distinguish between primary and secondary displacements, and that the clinical features upon which it rests present a complete series of intermediate forms, most of which might be as properly placed in one group as in the other. The arbitrariness and uncertainty of the decision are well shown by a comparison of clinical and pathological statistics. Thus, Hamilton and Bryant say that the subglenoid is of more frequent occurrence than the subcoracoid, and Erichsen says that this is the opinion of most English surgeons; while, on the other hand, Flower,¹ who made an examination of all the specimens contained in the London museums, 41 in number, found that in 32 the dislocation was subcoracoid, and he adds, that of 50 cases recently observed by him in living patients the same was true of "a large majority;"² he calls attention to the fact that "the great frequency of subcoracoid dislocation observed in this series [of specimens] does not accord with the descriptions of this injury generally given in the standard surgical works of the country." A few years later, in the article on the Injuries of the Upper Extremity which he prepared in connection with Mr. Hulke for Holmes's *System of Surgery*, Mr. Flower made a classification in which the influence of this important investigation is apparent. It is as follows:

¹ Flower: Transactions London Pathological Society, 1861, vol. xii. p. 179.

² The number is given as 44 in his article on Injuries of the Upper Extremity in Holmes's *System of Surgery*.

1. SUBCORACOID. Forward and slightly downward. On to the neck of the scapula, in front of the glenoid fossa, and immediately below the coracoid process. *Common.*

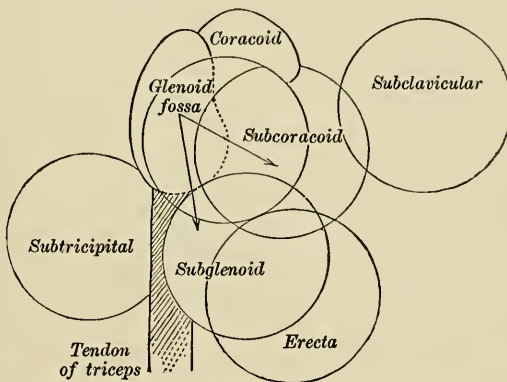
2. SUBGLENOID. Downward and forward. Head of the humerus in front of the inferior costa [border] of the scapula, below the glenoid fossa. *Rare.*

His remaining three divisions are *Subclavicular*, *Supracoracoid*, and *Subspinous*, the latter including Malgaigne's sixth and seventh.

Turning now to the pathological data, to the recorded results of post-mortem examinations and experiments upon the cadaver, and confining our attention for the moment to the forms mainly in dispute, the dislocations forward (or inward) and downward, and to the points that affect the position of the head of the humerus, the following facts appear:

The head of the humerus, when it passes across the anterior edge of the glenoid cavity, must, as a glance at Fig. 278 shows, move somewhat downward so as to get below the beak of the coracoid process; the posi-

FIG. 282.



To show the range of positions that may be taken by the head of the humerus after primary displacement forward or downward in any of the directions between the arrows.

tion of the limb that most favors the production of dislocation is abduction with or without external rotation. The inner and lower portion of the capsule, being pressed upon by the head of the humerus, tears between the tendon of the subscapularis and the triceps, the rent being small or large and varying greatly in extent and direction in the different cases, but it is always on the anterior and inner side, and the head passes more or less completely through it. If the movement is more directly forward and inward and to a less degree downward, as in dislocations by direct violence received on the outer side of the shoulder, the head of the bone pushes the subscapularis muscle before it and lodges close under the coracoid process and between that muscle and the edge of the glenoid cavity. In this case no secondary displacement ensues, and the form would be classed as *subcoracoid* by all. If the movement is forcible and prolonged the subscapularis may be

torn entirely across and the head may pass through it and come to rest on the side of the thorax under the clavicle ; or, as in a case quoted by Malgaigne, it may pass over the upper border of the subscapularis and come to rest at the same point. If, on the other hand, the primary movement downward has been more marked, as in dislocations effected by hyper-abduction of the arm, the head either passes below the subscapularis or tears its lower portion, and then, as the elbow is lowered the head rises, pressing the subscapularis or its untorn portion upward and remaining separated by it from the coracoid process. The extent and direction of this movement of the head are determined largely by the resistance of the untorn portions of the capsule, notably the outer and anterior part, which, by preventing the further descent of that part of the humerus to which they are attached, compel the head to move upward as the elbow descends. Other factors are found in the muscles ; if the head lies under an untorn subscapularis its distance below the coracoid process will be greater than when it lies under only the upper portion of the muscle, and if in addition it has passed under the *teres major* or downward as far as the lower border of the *pectoralis major* the arm will remain widely abducted or even with the elbow above the head (*luxatio erecta*). Or, departing still further from what is usual, it may perhaps even turn backward after it has left its socket and pass under the long head of the *triceps* to lodge behind the glenoid cavity, the alleged *subtricipital* dislocation.

The head of the humerus rests against the inner side of the head or neck of the scapula at any point between its junction with the broad axillary border, or inferior costa, and the middle of the anterior lip of the glenoid fossa, and it may lie either directly against the edge of this lip or further back on the side, as is clearly shown by the specimens of old, unreduced dislocations preserved in the museums. And according as it occupies one or the other position it will be more or less prominent in the axilla or more or less clearly seen and felt behind the *pectoralis major* beneath the coracoid process.

It is evident, then, that the position in which the head of the bone is found bears only a limited relation to the point at which it left the joint, and that a classification which is sharply made upon this position is not only arbitrary and uncertain for a large number of cases, but also favors inattention to points that have an important bearing upon a safe and easy reduction.

It is desirable that a classification should not deal minutely with unimportant variations, and that instead of multiplying divisions it should rather gather into a few groups those varieties that have characteristic and important features in common ; and yet, as some forms differ widely in their symptoms from others with which they are on other grounds closely related, it is equally desirable to recognize and note such differences. The distinction between "regular" and "irregular" dislocations made by Bigelow at the hip can also be made at the shoulder, taking for the dislocations downward and forward the integrity or the rupture of the antero-external portions of the capsule as the determining feature. The following classification is, in the main, the same as that of Mr. Flower, above given, and the later

French and German writers. It differs from that of the majority of the English and American writers in restricting the group of the "subglenoid" and correspondingly enlarging that of the "subcoracoid" dislocations.

Anterior	{	Subcoracoid; very common.
		Intracoracoid; exceptional.
		subclavicular.
Downward	{	Subglenoid; uncommon.
		erecta; very rare.
		subtricipital (?)
Posterior	{	Subacromial; rare.
		Subspinous; very rare.
Upward		Supraglenoid; very rare.

The names of the four principal divisions indicate the direction of the primary displacement; those of the subdivisions the position in which the head of the bone lodges, with the exception of the *erecta*, which takes its name from the attitude of the limb, and the *subtricipital*, which rather indicates the route traversed by the head than the position finally taken by it. Between the anterior and the downward the division cannot be sharply made, and in many of the cases included among the first the primary displacement has more of the downward than of the anterior feature, but it is believed that by enlarging the subcoracoid class so that it will include all but the lowest of the lower forms, by extending its range so that it will distinctly include the lower as well as the higher primary displacements, the necessity of abducting the arm to effect reduction in those cases in which the secondary displacement upward is marked and might otherwise lead into error will be less liable to be overlooked. The difficulty of distinguishing between the subglenoid and the lowest of the subcoracoid will arise in only a very limited number of cases and will be without practical importance; at the most it will be merely a question of nomenclature.

There would be some advantage in further dividing the subcoracoid group into *high* and *low*.

ANTERIOR (AND DOWNWARD) DISLOCATIONS.

1. Subcoracoid.
2. Intracoracoid, subclavicular.

In these dislocations the head of the humerus passes across the anterior lip of the glenoid fossa, taking at first a direction that is forward and inward and more or less downward; it may subsequently move upward or further inward. The class includes two subdivisions, the *subcoracoid* and the *intracoracoid*, of which the latter is here made to include also the more marked dislocation inward known as the *subclavicular*.

The class embraces the subcoracoid, partial and complete, of all authors, most of the subglenoid of most English and American authors, and the intracoracoid and subclavicular of all. The terms "axillary dislocations" and "dislocations into the axilla" are applied

by some to cases that are here called subcoracoid, and the term "pectoral" to the intracoracoid.

1. Subcoracoid Dislocations.

In this form, which includes a large majority of all cases, the head of the humerus lies under and in close proximity to the beak of the coracoid process, or at a distance below it that may equal or even exceed a finger-breadth. The centre of the head may be either directly below the beak of the coracoid process or on its outer or inner side. If more than three-fourths of the transverse diameter has passed to the inner side of the coracoid the dislocation is termed *intracoracoid*. The class, therefore, is continuous with the subglenoid below and with the intracoracoid on the inner side, and the separation from them is arbitrary and artificial, but is justified by custom and convenience in description.

Malgaigne showed, as early as 1835, that in some cases the articular surface of the head of the humerus rested on the anterior edge of the glenoid fossa, and such he termed "incomplete." The formation of a separate class composed of such cases seems unnecessary and even undesirable, for they differ from the complete ones only in degree, and the difference is slight and without practical importance; the symptoms are like those of complete dislocation, the bone is fixed in its new position, and aid is required to replace it in the joint. Moreover, in some the diagnosis (differential, between complete and incomplete) can only be made at the autopsy.

The injury may be produced by direct or indirect violence, a blow upon the outer and upper part of the shoulder or hyperabduction of the arm, or by muscular action. When produced by direct violence the displacement is usually in a direction that is only sufficiently inclined downward to enable the head to pass below the coracoid process; in a case reported by Krönlein¹ and in one of mine² the blow was received from above upon the acromion and only dislocated the humerus after it had broken that process. The extent of the displacement inward is affected partly by the force of the blow and the extent of the laceration of the capsule, and partly by the contraction of the muscles that adduct the limb.

Dislocations by indirect violence are the most common, the force acting to produce hyperabduction of the joint.³

Hyperabduction acts by bringing the outer side of the upper end of the humerus into contact with the edge of the acromion and thus creating a new centre of motion for the continued movement, the effect of which is to cause the head of the humerus to descend and rupture the

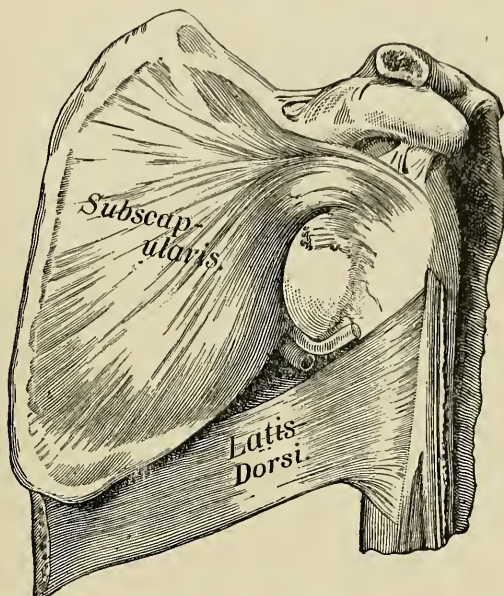
¹ Krönlein: *Deutsche Chirurgie*, Lief. 26, p. 14.

² For details see previous editions.

³ Hyperabduction of the *joint* must be distinguished from that of the *limb*. The former can take place even while the elbow is below the level of the shoulder, for it is determined by the relations between the humerus and the scapula; and as the scapula is freely movable the position of the limb (with reference to the body), when the limit of motion in the joint is reached, varies with that of the scapula.

capsule in its inner and lower portion. After this rupture has taken place and the upward movement of the elbow has ceased, the contraction of the muscles, the deltoid, pectoralis major, and latissimus dorsi, draws the head of the humerus inward past the anterior lip of the glenoid fossa, and then when the elbow is lowered the head rises along the inner side of the joint, for the untorn outer and anterior portion of the capsule is made tense and, by thus preventing the descent of the portion of the bone to which it is attached, compels the movement to take place

FIG. 283.



Subcoracoid dislocation on a cadaver: showing rupture of lower part of the subscapularis.
(B. ANGER.)

about this portion as a centre. As the first new centre of motion at the edge of the acromion determines, in connection with the muscles, the primary displacement, so the second new centre on the humerus at the outer and anterior attachment of the capsule determines the secondary displacement and the final position of the head of the bone and the attitude of the limb.

Muscular action, the contraction of the muscles of the individual himself, can produce a dislocation either by drawing the head of the bone directly out of its socket, or, much more commonly, by creating conditions of leverage and momentum similar to those existing in the production of dislocations by indirect violence. In many of the reported cases it is difficult to recognize the mechanism of the injury. The least questionable examples of dislocation effected by the direct traction of the muscles are those in which the injury has occurred during a convulsion. A considerable number of such have been

reported; in one quoted below (Pollosson, page 563) the limb seems to have been in the position of *inward* rotation at the moment of dislocation. The examples of the other kind are numerous and varied, and the explanation is usually simple. A painter raises his arm to work upon a ceiling, an artilleryman to throw a shot, a patient lying in bed to free its curtain caught under the pillow, a woman to grasp an object hanging on the wall; in such cases hyperabduction of the joint seems to be the probable cause. In others hyperabduction can only be invoked on the supposition that the contraction of the deltoid has lowered the acromion, the arm being fixed in a position below the shoulder, as in Bichat's case of the notary who dislocated his shoulder in an attempt to raise a heavy book from the floor, or in Volkmann's of a woman who tried to lift a heavy pot from a shelf at the height of her shoulder, or Malgaigne's athlete who tried suddenly to lift a man kneeling in front of him, or Duplay's very muscular patient who stumbled while descending a staircase and threw out his arm to save himself from falling but touched no object with it.

In other cases the influence of muscular action is entirely indirect. Thus, Rickert¹ tells of a very muscular man twenty-five years old who received a subclavicular dislocation by resting his hand against a wall over his head and sneezing. Bardenheuer mentions a similar case observed by Saponi. In such a case the mechanism is essentially the same as in that, for example, in which a man supported himself with his arms outstretched against a wagon to receive a sack of grain which another threw down upon his back and thereby dislocated both shoulders.

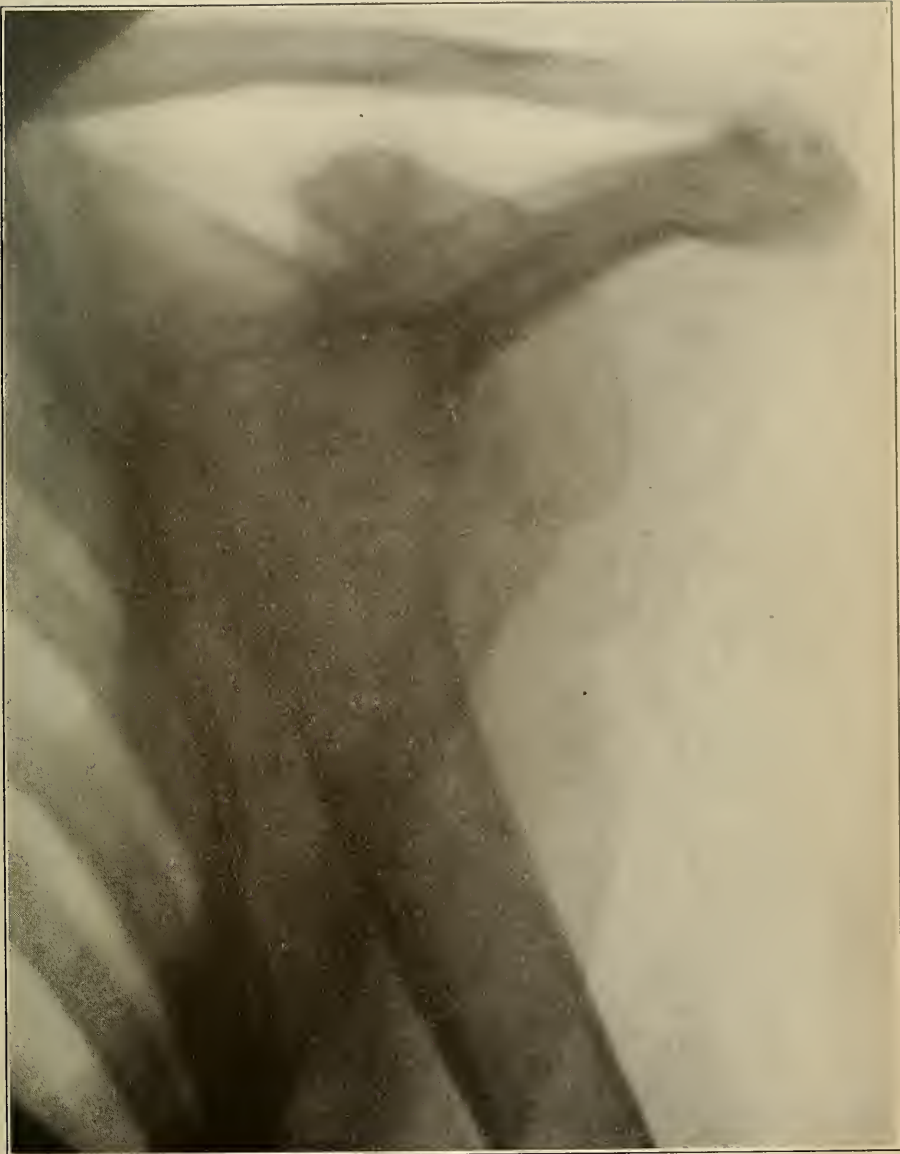It is impossible in most cases to determine the exact position and attitude of the limb at the moment the dislocation occurs, and the relative parts taken by abduction, rotation, muscular action, and direct impulsion in its production. At present it can only be said that every one of the four has proved sufficient by itself, and that they have been found to co-operate in varying degrees.

Pathology. The capsule is torn at its inner and lower portion between the tendon of the subscapularis and the triceps, and the rent extends usually along the inner and lower border of the glenoid fossa for half, sometimes even two-thirds, of the entire periphery. In other cases the rent extends outward and backward, rather than upward, and near the insertion of the capsule upon the humerus. Exceptionally, the rent is very small, or may even be entirely lacking, its place being sometimes taken by the stripping up of the continuous periosteum from the inner side of the neck of the scapula. Eve² reported a case of subcoracoid dislocation in which the capsule was untorn, but was separated from the anterior border of the glenoid fossa, remaining continuous with the periosteum which was stripped up from the costal surface of the scapula. On the posterior surface of the head of the humerus was a deep vertical indentation made by impact against the anterior margin of the glenoid fossa. An almost identical case was

¹ Rickert: Maryland Medical Journal, 1883-84, vol. x. p. 339.

² Eve: Transactions Pathological Society of London, 1880, vol. lxiii. p. 317.

PLATE XLV.



Dislocation of the Shoulder. (Old.)

shown to the London Pathological Society by D'Arey Power.¹ In 1880 I presented to the New York Surgical Society the shoulder-joint of an old man who had died of pneumonia a week after he had dislocated his shoulder. The dislocation was well marked, and reduction was effected with the aid of ether. The joint was opened from behind, and the capsule was found untorn; the tendon of the subscapularis was partly detached at its insertion, but at no point throughout its entire thickness, and the upper facet of the greater tuberosity was broken off in several pieces, but not widely separated.

The subscapularis muscle is sometimes simply pressed inward and separated from the scapula by the interposed head of the humerus, but in many cases it is torn more or less widely from its lower border upward, and its upper portion may lie upon the head of the humerus and separate it from the coracoid process. Occasionally, instead of being ruptured, the muscle is torn away from its attachment to the humerus, perhaps bringing with it the lesser tuberosity. I have seen one case in which the head passed beneath the tendon and then to its inner surface, so that division of the tendon was required to effect reduction.

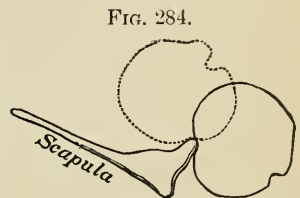
The supraspinatus is sometimes, probably often, torn from its attachment to the humerus, and the same is true in a less degree of the infraspinatus, and occasionally even of the teres minor.

The teres major is sometimes slightly torn, apparently by the partial passage of the head of the humerus between it and the subscapularis.

The anterior edge of the glenoid fossa is occasionally broken off, and detachment of a portion of its fibro-cartilaginous rim seems not infrequent; it is sometimes pushed away to some distance, bringing with it the periosteum of the scapula. The acromion and coracoid process have both been found broken, but such injury appears to have been purely incidental and should be classed as a complication.

The head of the humerus lies against the edge of the glenoid fossa, or further back against the side of the neck of the scapula, and either close up against the beak of the coracoid process behind the coracobrachialis and the short head of the biceps, or lower down at a distance determined by its relations to the subscapularis and by the tension of the untorn portion of the capsule. It may lie largely on the outer side of the coracoid process, or immediately below it, or it may pass entirely to its inner side (intracoracoid dislocation), and it may be in outward or inward rotation (Fig. 284) or in any intermediate attitude.

As has been already said, avulsion of the tuberosities may take the place of laceration of the muscles attached to them; this has been rarely noted of the lesser tuberosity, but frequently of the greater, and especially of its upper and middle facets. Von Thaden,² who



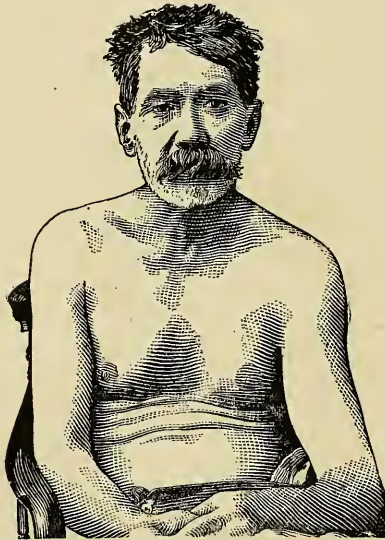Subcoracoid dislocation : to show the different degrees of rotation of the humerus in different positions.

¹ D'Arey Power : *Lancet*, November 24, 1888.

² Von Thaden : *Arch. für klin. Chir.*, vol. vi. p. 67.

made a study of this feature, found that the upper and middle facets were each sometimes torn off separately, but the lower one only in connection with the other two. The complication is of importance because of the consequent loss of the control of the attached muscles over the humerus and the consequent exposure to recurrence of the dislocation (see Chapter XXIX.), and because it opens the way for the escape of the long tendon of the biceps from its groove and its interposition between the humerus and its socket in such a way as to constitute a serious obstacle to reduction. In the specimens Von Thaden examined he found the tendon thus interposed three times. Körte² reported a similar case in which the tendon had slipped entirely out of its groove and was wound around the outer and posterior side of the head. Graessner² found the greater tuberosity broken 24 times in 48 dislocations, but apparently in many of them the fragment was only a small scale of bone, practically an avulsion of the tendon.

FIG. 285.



Subcoracoid dislocation of the left shoulder.

When the tuberosity or a portion of it is thus broken off, the fragment lies over or in the glenoid fossa, and the broken surface of the humerus rests against the inner surface of the neck of the scapula or engages the edge of the fossa. The upper and outer portion of the capsule thus separated from the humerus may remain interposed between the head of the humerus and its socket and prevent reduction. After reduction of the dislocation the tuberosity unites with the humerus with more or less irregularity and deformity.

Except in connection with fracture of one or the other tuberosity

¹ Körte: *Ibid.*, vol. xxvii, p. 747.

² Graessner: *Veröff. aus dem Gebiete des Militär-Sanitäts*, Hft. 35, p. 180.

the long tendon of the biceps is rarely dislocated, but it is sometimes torn away from its insertion or ruptured.

In some specimens of old unreduced dislocation a vertical groove has been found on the articular surface of the head of the humerus which was thought to have been caused by prolonged contact with the edge of the glenoid fossa. Malgaigne, who took a special interest in the specimens as supposed examples of incomplete dislocation, suggested that the groove might have been caused at the time the injury was received by the forcible impact of one bone against the other. It is interesting to find that this suggestion has been confirmed by autopsy in Eve's and Power's cases mentioned above and by two specimens of recent dislocation preserved in the Museum of the University of Edinburgh and reported in an interesting and valuable paper by Caird,¹ and by one reported by Broca and Hartmann;² the indentation lay wholly or in part along the junction of the head and shaft above and behind the greater tuberosity, was from one to one and a half inches long, and from one-quarter to one-half an inch deep, and accurately fitted the inner lip of the glenoid fossa. The suggestion that the causation of fracture of the anatomical neck may be referred to the same mechanism seems very plausible. A similar indentation adjoining the lesser tuberosity is reported by Pollosson³ in a double dislocation by muscular action—convulsions of eclampsia. The position indicates that the limbs were in inward rotation at the moment of dislocation.

The axillary vessels and nerves are pressed inward and are sometimes injured.

Symptoms and Diagnosis. The description of the symptoms will be made simpler by limiting it at first to those commonly found in the medium displacements, and subsequently indicating the differences or modifications peculiar to the exceptional grades and conditions.

The patient sits with his trunk inclined toward the injured side, and supports the forearm with the other hand. The shoulder is flattened on the outer side so that the line of the deltoid runs straight down from the acromion and makes a more marked angle with the arm at its insertion than is usual. The anterior fold of the axilla lies lower, further from the clavicle than its fellow of the opposite side, and its creases appear deeper, as if the arm were applied more closely against the chest, and the outer part of the subclavicular fossa appears full.

The elbow stands a little away from the side and can be easily abducted, but any attempt to bring it nearer the side causes pain and is resisted; it may be in the axillary line, or in front of or behind it. When the elbow is flexed at a right angle the forearm is directed forward and inward; its direction can be passively changed to either side, but not freely. The hand cannot be brought to the opposite shoulder.

Voluntary movements of the dislocated joint are declared by the patient to be impossible, and pain is complained of in the shoulder, sometimes extending down the arm.

¹ Caird: *Edinburgh Medical Journal*, February, 1887.

² Broca and Hartmann: *Bull. de la Soc. Anat.*, 1890, No. 14.

³ Pollosson: *Rev. de Chir.*, November, 1888, p. 927.

If the axis of the arm, viewed from in front, is prolonged upward by the eye it will be seen to pass to the inner side of the glenoid cavity, and if the fingers are firmly pressed against the anterior wall of the axilla in the line of this prolongation and a little below the coracoid process they will encounter the firm resistance of a solid body; palpation shows this body to be globular, and if it can be grasped between the thumb and finger, or if the finger can find some projection on its surface, it will be found to share in slight movements of rotation communicated to the arm by the other hand of the surgeon.

FIG. 286.

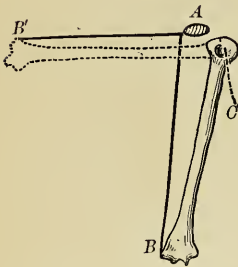


Diagram to show the effect of position upon the apparent length of the arm in dislocation of the shoulder. *A*, acromion; *B*, lower end of humerus.

If now the head of the humerus is sought for by palpation in its normal position it will not be found there; the fingers can be pressed in deeply under the acromion from the outer side; the outer margin of the acromion is prominent and can be easily traced. This is marked when the limb is abducted.

If the elbow be further abducted and the surgeon pass his fingers well up into the axilla he can there feel the head of the humerus more or less distinctly according as the displacement is low or high.

If the distance be measured from the outer margin of the acromion to the external epicondyle of the humerus or the olecranon, it will usually be found somewhat greater, perhaps half an inch, on the injured than on the uninjured side, but if successive measurements are taken as the arms are abducted the difference will disappear, and in complete abduction the distance will be greater on the opposite side. The reason for this is seen by a glance at Fig. 269.

As in most other dislocations, the capital point in the diagnosis is the recognition of the head of the bone and the determination of its relations to the socket from which it has escaped. Ordinarily, both of these can be accomplished at the shoulder with ease and certainty, and the examination is difficult only when the patient is very fat or the parts much swollen.

As the attitude and range of motion of the limb depend mainly upon the tension of the untorn portion of the capsule, they will be modified when the capsule is freely torn. It is in such cases that the diagnostic sign so freely trusted, the inability to bring the elbow against the chest and to place the hand on the opposite shoulder, is lacking or only slightly marked.

When the displacement of the humerus is less than usual, when its head rests upon the edge of the fossa, the "incomplete" dislocation of some writers, the symptoms are modified to this extent, that the flattening of the shoulder and the abduction of the elbow are less—the elbow may even lie close to the body; but the limb is equally fixed and incapable of being voluntarily moved. The pain also is greater. It has occasionally happened that the dislocation has been reduced by the manipulations used to make the diagnosis.

Treatment. The treatment will be described in connection with that of the following variety.

2. Intracoracoid Dislocations (Subclavicular Dislocations).

To avoid misapprehension I repeat that the term "intracoracoid" was applied by Malgaigne to the class of cases which he deemed of most frequent occurrence, comprising two-thirds of the forty-nine cases of shoulder dislocation observed by him at the Hôpital St. Louis, those in which the head of the humerus is so placed that from one-third to two-thirds or three-fourths of its transverse diameter lies to the inner side of the coracoid process. Most of such cases are now habitually spoken of as "subcoracoid," and the terms intracoracoid and subclavicular are restricted to those cases in which the bone is displaced still further inward. As between "intracoracoid" and "subclavicular" thus employed, I prefer the former name because it contains that of the anatomical landmark the relations to which form the basis of the classification.

The injury may be produced by direct violence received upon the outer aspect of the shoulder or by hyperabduction of the arm. The essential causative feature of the variety, as compared with the subcoracoid, is that the action of the original violence is prolonged, or that the secondary cause exaggerates the secondary displacement upward and inward. After a primary displacement forward and downward by abduction of the limb, anything that forcibly presses or draws the arm inward, such as pressure inward against the elbow, or the contraction of the deltoid and pectoralis major, may effect this displacement if the head of the bone has passed under the subscapularis, or if this muscle has been sufficiently torn. The head of the humerus lies against the wall of the chest, or rather against the serratus magnus, on one side, and against the costal surface of the neck of the scapula on the other. The subscapularis usually is widely torn; in McNamara's case, quoted by Malgaigne,¹ it was untor, and the head of the humerus had stripped it away from the scapula and had risen above its upper border, lying against the root of the coracoid process. No muscle or tendon was torn. In one of my own the head of the bone had passed beneath and entirely to the inner side of the subscapularis.

The capsule is extensively torn, and the greater tuberosity usually broken off in whole or in part and lying in the glenoid fossa.

The head of the humerus passes behind the muscles arising from the coracoid process (in one recorded case, Roser's,² in front of the coraco-brachialis and biceps and behind the pectoralis minor) and occasionally is partly interposed between the contiguous borders of the deltoid and pectoralis major, being then subcutaneous. It may lie immediately under or a little behind the clavicle, in one case (Meyer) it even projected above and behind it, and it has usually been found rotated inward.

¹ Malgaigne: *Loc. cit.*, p. 525.

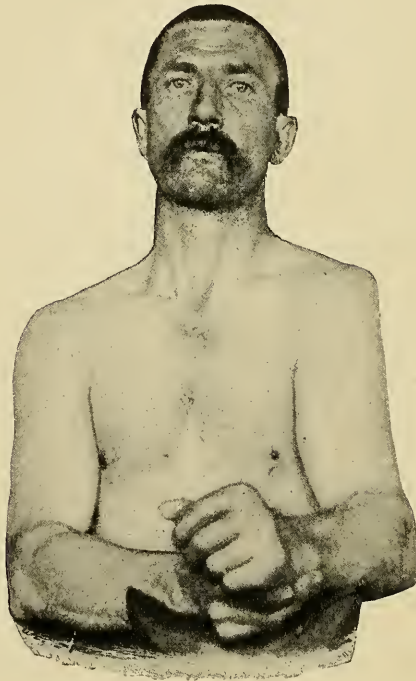² Roser: *Arch. für phys. Heilkunde*, 1844, p. 582. The dislocation had lasted for seven years, and many attempts had been made to reduce it.

The long tendon of the biceps is broken, or displaced across and beyond the fractured surface left by the avulsion of the greater tuberosity.

The main vessels and nerves lie rather behind the head than between it and the wall of the chest.

Symptoms. The attitude of the patient and the general appearance of the shoulder are the same as in the subcoracoid variety; the details differ mainly in degree, some being less, others more, marked. The flattening of the shoulder is greater, as is also, in some cases, the fulness of the subclavicular fossa, but this fulness is nearer the median line. The elbow may lie near the side, even in contact with it; the axis of the arm prolonged upward in front passes well to the inner side of the coracoid process. The fingers cannot be passed between the head of the humerus and the chest-wall, consequently only the

FIG. 287.



Intracoracoid dislocation.

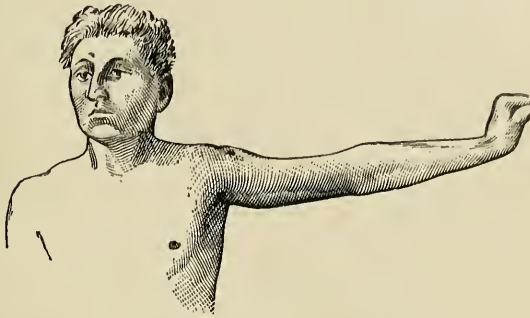
shaft and lower portion of the head can be felt through the axilla; but, on the other hand, the lower anterior edge of the glenoid fossa and the neck of the scapula can sometimes be felt behind the shaft.

Abduction of the limb is not always easy, and is effected by elevation of the scapula rather than by movement of the humerus upon it. Differences in length, when the arm is dependent, are less constant and marked than in the preceding variety, but if the arm can be abducted upon the scapula the shortening is then greater.

The dislocation can be transformed into a subcoracoid by traction downward and outward.

Occasionally¹ the dislocated arm is fixed in the position of complete horizontal abduction (Fig. 288). Such are doubtless cases in which

FIG. 288.



Intracoracoid dislocation, with arm fixed in horizontal abduction. (BARDENHEUER.)

the head has left the socket at a low point while the arm was widely abducted. (See *Subglenoid Dislocations* and *Luxatio erecta*, Chapter XLIII.)

Treatment of Anterior Dislocations.

(See, also, Chapter XXXIII.)

Obstacles to the return of the head of the humerus to its socket may be created by the tension of portions of the capsule which oppose its movement toward the socket, except in certain attitudes of the limb, by the approximation of the sides of the rent in the capsule through which it has passed, by the interposition of portions of the capsule or of the tendon of the biceps, by its engagement behind the edge of the glenoid cavity or the coracoid process, by the contraction or rigidity of the muscles and the swelling of the soft parts, and exceptionally by the interposition of the tendon of the subscapularis (see above). Those which are most frequently concerned are the opposition of the anterior portion of the capsule and the contraction of the muscles.

If the portion of the capsule which extends from the base of the coracoid process and the outer, or posterior, edge of the glenoid fossa to the greater tuberosity and posterior portion of the humerus, including the coraco-humeral ligament, remains untraced, it is stretched downward and forward across the glenoid fossa, and, being drawn tight by the weight of the elbow, it holds the head of the humerus against the scapula. If now the elbow is raised, the capsule is thereby relaxed, and the abducted limb can be easily drawn outward.

If the capsule is so freely torn away from the humerus on the outer side that it falls down between it and the glenoid fossa, it cannot be

¹ Bardenheuer: *Deutsche Chirurgie*, Lief. 63 a, p. 317.

lifted out of the way by manipulation of the arm because its separation is so complete that it is no longer affected by the position given to the latter. It may, perhaps, be pushed out of the way by the returning bone, but that is a matter of chance rather than of skill. Probably, full abduction of the arm followed by traction would be most likely to accomplish the object under such circumstances.

Dislocation and interposition of the tendon of the long head of the biceps occurs only with avulsion of the greater tuberosity, and not always then, for it may, instead, be ruptured. Even when interposed, the tendon may be fairly expected to have preserved its relations with the lower part of the bicipital groove and sheath, and consequently to be still somewhat under control by the humerus. By elevating the arm and flexing the elbow it will be relaxed and raised toward the upper part of the joint, leaving space below for the head of the bone to pass back under it.

Abduction of the arm and external rotation are, then, the means by which the most common obstacles created by the capsule are to be avoided.

The muscles oppose reduction by their contraction excited by pain or the fear of pain; this can sometimes be avoided by taking the patient unawares, or by fatiguing the muscles, and always by anæsthesia. A certain anxiety connected with resort to the aid of anæsthesia has arisen from the fact that a disproportionate number of deaths caused by chloroform have occurred in the reduction of dislocations (see p. 445), but I am not aware that death has ever followed the use of ether under such circumstances. There are many reasons why reduction should be made, when conveniently practicable, without its aid, but I never hesitate to avail myself of the aid of ether in preference to the employment of long-continued, forcible, or painful traction, even in recent cases. In those of long standing, in which adhesions must be broken, the capsule return, and the shortened muscles elongated, it is indispensable.

Reduction in recent cases is usually easy, and it has been safely accomplished after the lapse of many weeks and even months. It is impossible to fix a period after which reduction by traction should no longer be attempted; each case must be judged by itself. Serious, even fatal, accidents have followed the attempt so often that the surgeon is fully justified in advising abstention on the ground that the risk is too great to be taken. Personally, I prefer in a doubtful case to expose the joint by incision and liberate the head of the humerus by rotation and traction. (See Chapter XXXIII.)

In all the methods in which forcible traction is made upon the arm success depends largely upon efficient fixation of the scapula. When the traction is made by specially constructed apparatus the counter-extension is effected by a ring or crutch arranged to bear against the scapula, but when it is made by the hands of assistants the scapula may be fixed by a split band through which the arm is passed. In most cases in which only moderate traction is made a simple band about the chest is sufficient, or the pressure of the surgeon's foot or hand against the side of the chest or the acromion.

Direct Reposition. This method, the use of which can be traced back to the time of Avicenna, has been of late especially recommended by Richef and Von Pitha. It is often successful in recent cases in which the displacement and muscular contraction are not great, and especially when aided by anæsthesia. The arm, somewhat abducted, is supported by the side, and the surgeon, placing his fingers in the axilla on the under and inner side of the head of the humerus, and his thumbs upon the acromion, seeks to press the bone directly into place. Or the position of the hands may be reversed, the thumbs being placed in the axilla and the fingers upon the acromion. Or, the patient being seated, the surgeon supports the flexed elbow upon his own forearm, gets his fingers around the head of the humerus in the axilla, and presses it toward the glenoid cavity while he steadies the scapula with the other hand.

Traction Downward and Outward with Coaptation. In its simplest form, one that is successful in a large proportion of cases, especially with the aid of anæsthesia, the method is practised as follows: The patient is placed upon a bed and counter-extension is provided by a band passed around his chest and made fast to a support on the sound side. If anæsthesia is used the weight of the body is usually sufficient for counter-extension, and this band can be dispensed with. The surgeon grasps the arm above the elbow and pulls steadily downward and outward at first, and then slowly changes the direction by increasing the abduction until the arm is nearly or quite at right angles with the body, while, at the same time, he rotates the arm outward. Or the traction is made by an assistant, and the surgeon, standing beside the patient, watches the movement of the head of the humerus, and when it has approached the joint he presses it upward into place with his fingers or thumb, making counter-pressure on the acromion.

If anæsthesia is not used, or if more force is used, the scapula may be fixed by bands passing over and under the shoulder or by pressure against the edge of the acromion. Or the patient can be laid on his back on the floor, and the surgeon seated beside him places his foot against the side of the chest or the edge of the acromion and draws the arm directly outward.

It is desirable that the elbow shall be kept partly flexed to relax the biceps, and also, if the surgeon himself is making traction, to enable him to rotate the limb inward when the head has been brought close to its socket, since this manœuvre is sometimes an efficient substitute for direct pressure upon the head.

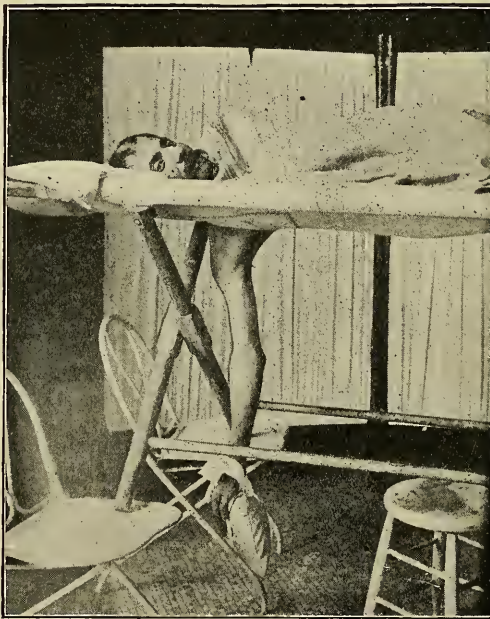
I¹ have of late (1899) employed with uniform success in about a dozen cases a method of making this traction which is easy, expeditious, and apparently safe. A round hole six inches in diameter is made in the middle line of a canvas cot about eighteen inches from one end, and through this hole the injured limb is passed so as to hang vertically downward, the patient lying on his side on the cot (Fig. 269). To the limb, at the wrist or elbow, is attached a weight of about ten pounds, and the cot is raised upon blocks so that the arm will hang free of the floor. In a few minutes, never more than six in my

¹ Stimson : Med. Record, March 3, 1900.

experience, reduction of the dislocation takes place quietly and without pain during the waiting. Instead of a cot, the patient might perhaps be put upon two tables placed end to end so that the body would rest on one and the head on the other, the arm hanging down between, but possibly the lack of snug support of the shoulder, and the consequent muscular effort to maintain the position, would interfere with success or at least delay it. Continuous traction by India-rubber or a weight and pulley, as described on page 450, acts in the same gentle manner.

Another modification is the so-called "*pendel-methode*," which occupies a position intermediate between the above and the following method, hyper-elevation of the arm, and in which the weight of the patient's body is used to make the traction. The patient is laid upon

FIG. 289.



Reduction of anterior dislocation of the shoulder.

the floor on the sound side, and an assistant, standing upon a stool, grasps the dislocated arm and lifts the shoulders from the floor while the surgeon presses the head of the bone toward its socket. If a greater weight is needed another assistant raises the feet so that the body is wholly off the floor, or presses downward against the side of the chest. If a sufficiently robust assistant is not at hand, or if the effort is to be prolonged, the suspension may be made by means of a rope attached to the arm above the elbow. Bardenheuer says that Simon reduced by this means a dislocation that had existed for a year and three-quarters.

Traction Upward. In this method the arm is raised beside the head and drawn upon while counter-extension is made by the hand or

foot upon the top of the shoulder. Duplay, following Malgaigne, speaks of it in rather exaggerated terms as the only rational method, because it relaxes all the muscles. The difference between it and traction at right angles to the body is more apparent than real, because the further elevation of the arm is effected by a change in the position of the scapula upon the chest, without change in its relations to the humerus. The method which was known to Celsus and practised by Brunus in the thirteenth century, was extensively used in England in the last century, but is more particularly connected with the name of Mothe in France, and of Kluge in Germany. Malgaigne says that he himself reinvented it for the fourth or fifth time in 1828 as the result of experiments upon the cadaver. It has commonly been combined in practice with some form of the method next to be described, the *bascule* of the French and German authors, that in which the head of the bone is pressed outward by placing a fulcrum high up in the axilla and then swinging the elbow in toward the body, and has also been frequently supplemented with external, followed by internal, rotation.

In its simplest form, as described by Bransby Cooper, the patient is placed upon his back on the bed or table, and the surgeon sitting beside his head draws the dislocated arm upward with one hand and fixes the scapula with the other; the counter-extension may be aided by a long bandage or towel passing over the shoulder and fixed by both ends to the foot of the bed. After reduction has taken place, and while the arm is being lowered, the head of the humerus should be held in place by direct pressure upon it.

Malgaigne's plan, when more force was needed, was to rest the patient on the floor, and lift the arm directly upward with both hands, counter-extension being made by the weight of the body and aided, if necessary, by pressure made upon the acromion by an assistant. If this failed and he wished to try more force before resorting to the *bascule*, he made the patient stand beside a door and raised the arm to a vertical position by means of a strong band made fast at the wrist or elbow and carried over the top of the door; then the patient was directed to bend his knees until the weight of his body should be entirely supported by the dislocated arm, and, in addition, the surgeon contributed his own weight by clasping his hands over the patient's acromion and kneeling beside him. The addition, proposed by Lacour¹ in 1847, of external and internal rotation to the vertical traction, has added to its efficiency.

The chief objection to this method is that mentioned in connection with the preceding one, the risk of injuring the main vessels in the axilla by unduly stretching them around the head of the humerus, and it is even greater here because the elevation, or abduction, is made without preliminary traction to bring the head nearer the socket.

Another objection is that it is likely to increase the laceration of the capsule and of the subscapularis and thereby promote recurrence of the dislocation.

¹ Lacour: *Mém. de Chirurgie*, 1847, vol. i. p. 387.

Traction with Leverage. This method differs from that of traction downward and outward in the addition, or the substitution for direct coaptative pressure by the hands, of a leverage movement in which the head of the bone is forced outward by the adduction of the limb over a fulcrum placed in the axilla. The fulcrum is usually the closed fist or the heel.

When the hand is used traction is made outward and downward by an assistant, and when the head of the bone has been moved sufficiently far the surgeon places his closed fist well up in the axilla, and the assistant, still maintaining the traction, swings the arm toward the side (adduction), sometimes combining with it moderate rotation.

The Heel in the Axilla. This method, generally known as Sir Astley Cooper's, but really dating back to the time of Hippocrates, was in very general use in England and America until quite recently. It is unfortunately responsible for not a few more or less serious injuries to the bloodvessels and nerves of the axilla.

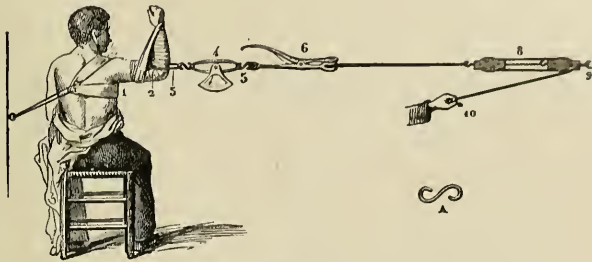
The patient is placed upon his back on a bed or sofa and a towel or stout bandage made fast to the arm above the elbow. The surgeon, facing him, seats himself upon the side of the bed and places the heel of one foot, from which the shoe has been removed, well up in the axilla against the head of the humerus and then makes traction downward upon the towel and maintains it until the bone is felt to slip into place. Remembering that under these conditions traction upon the humerus is directly transmitted to the scapula through the already tense capsule, it seems probable that the method owes its efficiency to the action of the heel as a wedge, which by being forced in between the thorax and the humerus presses the latter directly outward. If the traction is made at first in a direction inclined away from the body, and then brought more nearly parallel to it, the mechanical effect is the same as when the fist is used as above described.

It may be proper to employ this method if no more force is used than can be exerted by the surgeon himself, although accidents have happened even under such circumstances, but it is certainly dangerous and improper to employ it with the pulleys or assistants, and still more so to substitute an iron plug for the heel as recommended and practised by Skey. The large vessels and nerves lie upon the inner side of the head of the humerus and are exposed to be compressed between it and the heel and thus directly bruised or so held fast that they may be overstretched and torn as their distal portions are drawn downward in the sliding of the soft parts of the arm toward the elbow.

Forcible Traction. If more forcible traction is needed than can be made in the methods already described, resort should be had to the pulleys or specially constructed apparatus. The pulleys are made fast to the arm above the elbow by a broad leather band buckled tightly around it or by a strap or band made fast by several turns of a wet bandage. As a further precaution against slipping the forearm should be bandaged and the elbow fixed at a right angle. It is also advisable to interpose a dynamometer between the pulleys and the limb to indicate the amount of force that is being employed, and a pair of "liber-

ation forceps" to allow the traction to be suddenly relaxed and the position of the arm changed.

FIG. 290.



Reduction with the pulleys: 4, dynamometer; 6, "liberation forceps." (DUPLAY.)

The special instruments, of which the most elaborate and ingenious are made in France, are, in the main, modifications of the "adjuster" invented by Dr. Jarvis, of Portland, Connecticut. They consist of two bars movable upon each other by a rack and pinion, one of which is made fast by a leather bracelet to the lower part of the arm, and the other to a ring or crutch that fits against the scapula. A dynamometer indicates the force exerted, and a catch sets it instantly free at will. The instruments are expensive, the occasions for their use are rare, and the method is dangerous.

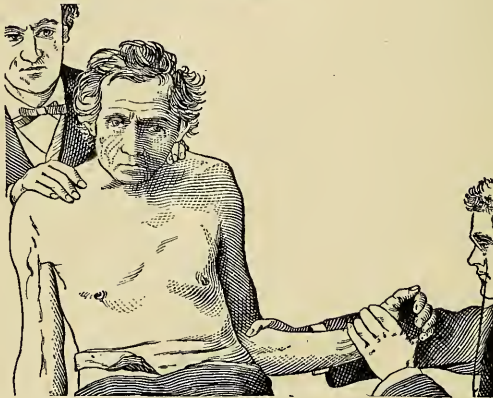
Reduction by Manipulation. (Rotation.) It has been already mentioned that rotation of the arm has long been used in connection with the various methods of extension to effect reduction, and it also appears that from time to time men have sought to reduce, and sometimes with success, by moving the limb in various directions without the aid of much traction, but it is only within the present century that methods of manipulation founded upon a correct appreciation of the obstacles and of the means by which they may be overcome have been devised and practised with intelligence and success. Rotation inward was long employed as the final manœuvre to turn the head of the bone into the socket after it had been brought opposite it by traction, and it still constitutes the final step in the pure manipulative method. External rotation during traction was first employed under the influence of various ideas concerning the part taken by the muscles in opposing the return of the bone, or to dislodge the head from its position behind the lip of the glenoid fossa; then, in the light of more accurate knowledge of the influence of the untorn portion of the capsule, it became the first step in the methods of reduction without traction.

Of these methods the one most highly esteemed and generally practised is that recommended by Prof. Kocher,¹ of Bern. The following description is taken from one given at the Surgical Congress in London, and published by his pupil Ceppi in the *Revue de Chirurgie*, 1882, p. 831: "In the subcoracoid dislocation the posterior portion

¹ Kocher: Berlin. klin. Wochenschrift, 1870, No. 9, and Volkmann's Sammlung klin. Vorträge, No. 83, p. 611.

of the capsule and the tendons of the posterior scapular muscles which cover and strengthen it are untorn and are stretched over the glenoid fossa. The inferior portion of the capsule which forms the lower border of the rent is also very tense. But the tension is greatest at the upper part of the capsule, and especially between the long tendon of the biceps and the upper border of the subscapularis, where it is reinforced by the fibres of the coraco-humeral ligament. This portion of the capsule is twisted in the dislocation, and stretched in the form of a solid cord. If now the humerus is rotated externally until the

FIG. 291.



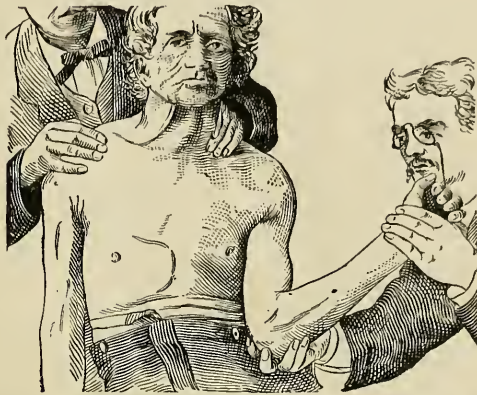
Kocher's method of reduction by manipulation: 1st movement, outward rotation. (CEPPI.)

flexed forearm is turned directly outward, this cord will be at the same time rotated outward, the posterior part of the capsule will be widely removed from the fossa, and the rent in the capsule will gape; but the head of the humerus will still remain solidly fixed against the anterior edge of the glenoid fossa because the upper and lower portions of the capsule have not been relaxed by this movement. It is only when the elbow is carried forward and raised in the sagittal plane, while the arm is still held in external rotation, that the upper part of the capsule is seen to relax, and the head of the humerus, thanks to the tension of the lower portion which keeps it from moving forward, to enter its socket. Rotation inward then completes the reduction."

The method may be formulated in detail as follows: Dislocation of the left shoulder. The patient is seated, and the surgeon, kneeling beside him, flexes his elbow at a right angle and presses it with his right hand against his side; then, holding the elbow firmly in place, he slowly and steadily moves the wrist outward with his left hand (external rotation of the humerus) until the forearm stands directly outward from the side of the body; if this is strongly resisted the pressure must be steadily maintained until the resistance yields. The evidence that the movement has accomplished what was expected of it is the appearance of greater fullness of the outer deltoid region; if this does not appear the attempt will fail. Then, still maintaining the external rotation of the arm and the flexion of the elbow, the

surgeon moves the elbow forward, or forward and slightly inward, until the arm is nearly horizontal; during this movement the fulness of the outer deltoid region becomes more marked, and at its termination the manœuvre is completed by rotating the arm inward and bringing the hand to the opposite shoulder. The bone may slip into place during the second movement, elevation of the elbow. Direct traction outward of the upper end of the bone by a bandage in the axilla is sometimes helpful, and I have sometimes found it advantageous to make

FIG. 292.



Kocher's method of reduction: 2d movement, elevation of elbow. (CEPPL.)

firm pressure downward at the elbow (traction in the long axis of the arm) during the movement of outward rotation.

The method as thus described is applicable to those cases in which the displacement is neither very far inward nor low down, in short, to the higher forms of the subcoracoid variety; and as it depends for its success upon the resistance of the untorn portion of the capsule it will fail whenever the capsule is very extensively torn. When the displacement is far inward or low, traction upon the abducted limb is more likely to succeed.

König¹ modifies it for the lower anterior and subglenoid dislocations by making traction in abduction, rotating outward, and then adducting. This is practically the same as the method described as traction downward and outward and generally known as Lacour's method by manipulation.

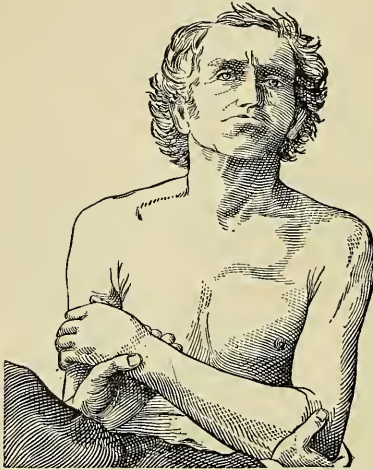
Farabeuf² studied Kocher's method experimentally with a view to determine the mechanism by which its result was accomplished, and reached the conclusion that the efficient agent was the untorn posterior portion of the capsule, and that the upper portion, the coraco-humeral ligament, had little or nothing to do with it. He showed, experimentally, that when this latter had been divided and the posterior portion left intact the manœuvre would still effect reduction, but that when the posterior portion was divided and the upper portion left whole it

¹ König: *Speciel. Chirurgie*, 3d ed., vol. iii. p. 40.

² Farabeuf: *Bull. de la Soc. de Chir.*, 1855, p. 395.

failed, and that then the head of the humerus instead of being moved outward by the external rotation simply revolved about the longitudinal axis of the shaft. His explanation is clear and intelligible. According to it the approximation of the elbow to the side tightens the

FIG. 293.



Kocher's method of reduction: 3d movement, inward rotation and lowering of elbow. (CEPPI.)

posterior portion of the capsule where it extends between the posterior lip of the glenoid fossa and the lower and back part of the neck of the humerus; this prevents the posterior surface of the humerus from moving inward when the arm is rotated outward, and consequently its attachment to the humerus serves as the fixed point or centre about which the bone rolls outward, winding itself, as it were, upon the capsule. The elevation and adduction of the elbow, turning upon the same fixed point, then throws the head backward and further outward, and finally the internal rotation unwinds the capsule and leaves everything in place.

The method is applicable to old as well as to recent cases, but the danger of breaking the humerus during the second step—outward rotation—must be borne in mind, especially in elderly patients.

Schinzinger's method, the introduction of which appears to have antedated Kocher's, was in like manner based upon the persistence of the posterior portion of the capsule, but differed from Kocher's in the second and third steps of the manoeuvre. He rotated the arm outward until the hand was as far back as the elbow, and then either pressed the bone upward and outward into place by direct pressure, or turned it in by slow internal rotation while an assistant made pressure on the inner side of its head to prevent it from slipping back into the position from which it had been removed by the outward rotation. The method is favorably spoken of by several of the later German writers, and is

thought to be especially useful in rupturing the adhesions of old dislocations without the risk of injury to the vessels or nerves.

Circumduction, sometimes known as Heine's method, in which, after fixation of the scapula as for traction, the arm is slowly abducted, raised to the side of the head, inclined slightly backward, and then brought forward and downward across the face and chest, has been recommended and used in old dislocations; it is undoubtedly efficient in breaking up the adhesions, but it is a rough, uncertain, and dangerous plan, and should be condemned.

To recapitulate, the treatment of a recent anterior dislocation of average displacement may be thus summed up: Kocher's method may first be tried; if that fails, traction downward and outward by one of the various methods should be tried, the elbow not being raised higher than the shoulder, combined with direct pressure upon the head, or followed by adduction over the fist in the axilla. If these also fail, the patient should be etherized, and the attempt repeated. When those rare conditions are present which make reduction otherwise impossible—interposition of capsule or tendon of biceps or subscapularis—an open arthrotomy is justifiable if it can be done with proper precautions against infection.

In older dislocations the same plan should be followed, and resort should be had to forcible traction only after other measures have failed.

The signs of a successful reduction are the sound that is usually heard when the bone slips into place, the restoration of form and function, and the diminution or cessation of pain. The sound is not always heard, and, on the other hand, a similar sound may be caused by the rupture of adhesions or by the slipping of the bones upon each other. Complete restoration of form is the best evidence; this is to be determined by an examination similar to that employed in making the diagnosis of a dislocation and by attention to the same signs. The reduction may be incomplete because of the interposition of a portion of the capsule, or because of the presence of tissues of new formation in the glenoid cavity. This incompleteness is shown by the abnormal projection forward of the head of the humerus under the acromion.

After-treatment.

After reduction has been obtained it is highly desirable that the arm should be immobilized for two or three weeks in a position that will favor the speedy repair of the lacerations of the capsule, tendons, and muscles; otherwise the joint may remain in a condition that favors recurrence, and the patient may suffer much inconvenience or even disability in consequence. As the rent in the capsule is on the inner side, and as its edges are separated by external rotation of the limb, the head of the humerus should be directed toward the outer side (adduction of the elbow) and the arm should be kept rotated inward. These two indications are met by binding the limb to the body with the hand resting just below the opposite clavicle. Fixation may be made by a starch or plaster-of-Paris dressing or even by simple bandages, but the most convenient and effective dressing

is a strip of adhesive plaster arranged as follows: beginning in front at the clavicle it is carried over the shoulder and down the back of the arm, then under the elbow to the back of the forearm, and along the latter and the back of the hand to and over the top of the opposite shoulder. A small pad of absorbent cotton or lint should be placed in the axilla and between surfaces of skin that are in contact. If the patient is unruly a second band may be placed circularly about the body and lower part of the arm. This dressing should be retained for two or three weeks, and the arm carried in a sling for a fortnight longer. If passive motion is made, abduction and external rotation should be avoided.

For complications, accidents, prognosis, and the treatment of old dislocations, see Chapter XLIV.

CHAPTER XLIII.

DISLOCATIONS OF THE SHOULDER.—(CONTINUED.)

Downward Dislocations: Subglenoid, erecta, subtricipital—Posterior Dislocations: Subacromial, subspinous, upward dislocations.

DOWNWARD DISLOCATIONS.

1. Subglenoid.

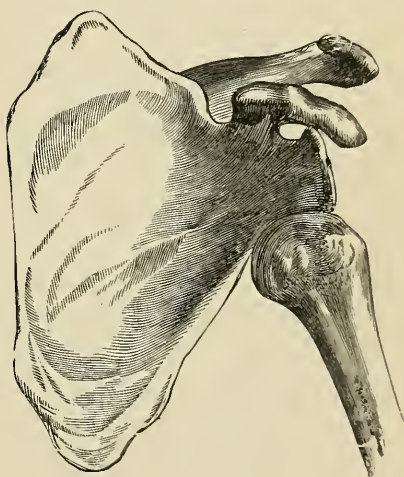
UNDER this title are here included those rare cases in which the head of the humerus is displaced directly downward upon the tendon of the long head of the triceps, and those more frequent ones in which it is engaged under the lower and inner edge of the glenoid cavity, and rests against the flattened upper portion of the axillary border of the scapula on the inner side of the tendon of the triceps. As

explained in connection with the classification given in the preceding chapter, the name is here restricted to a portion of those cases which are termed subglenoid by most English and American authors, to those, namely, in which the head of the bone is low in the axilla.

By some the term is still further restricted in use, and is applied only to the first of the two forms above mentioned, those in which the head is displaced directly downward upon the tendon of the triceps. Although it is denied by some on theoretical grounds that this form can exist, yet it must be admitted not only as possible, but as having been actually observed, on

the evidence of several observers who fully understood the point in dispute. Von Pitha (quoted by Bardenheuer) says that he had seen it only in cases in which he had the opportunity to examine the patient immediately after the accident, and before any movements had been communicated to the limb or attempts made to reduce. He believes that the head can be easily displaced from its new position, and moved upward and forward, the dislocation being thus transformed into a subacromial, by involuntary or communicated movements of the arm, or

FIG. 294.



Subglenoid dislocation.

even by muscular action. Tillaux¹ observed this transformation in a case while he was preparing to make a cast of the limb.

Two varieties, representing extreme displacements, and characterized by exceptional symptoms, the *luxatio erecta* and the *subtricipital* (?), will be separately described.

This form of dislocation was studied experimentally by Malle,² Goyrand,³ and Panas.⁴ They found that if the scapula was fixed and the arm was firmly elevated, the head of the humerus presented through a large rent in the capsule between the subscapularis and the long head of the triceps, and that if the arm was then lowered the head would often return to its socket, but that if it was twisted outward while being lowered the dislocation would persist. The lower border of the subscapularis was always found torn and its untorn portion rested upon the upper surface of the head; and Malle claimed that in order to produce the dislocation upon the cadaver it was necessary to divide the portion of the capsule between the acromion and the lesser tuberosity.

The cause, with the single exception of Desault's doubtful case, in which the injury was said to have been produced by a fall upon the shoulder, has always been the forcible elevation of the arm, as in a fall through a narrow opening or upon the extended elbow, by a horse throwing up his head while being led by the bridle, or as in Goyrand's case of a woman who, having fallen to the ground, had her arm dislocated by a passer-by who sought to raise her. In one of Tillaux's cases a young girl dislocated her shoulder by suddenly raising her arm while playing at raquettes.

The rent in the capsule in the specimens produced experimentally has always been comparatively small, and situated in the lower and inner portion between the triceps and the subscapularis, and differs from that of the subcoracoid form in not extending so far upward along the anterior edge of the glenoid cavity. In a specimen presented by Leroy⁵ to the Société Anatomique the lesions were identical with those produced experimentally. The upper part of the capsule, including the insertion of the supraspinatus and infraspinatus muscles, was torn away from the humerus, from the anterior border of the bicipital groove to the tendon of the teres minor, a distance of four centimetres; in the lower portion was the usual rent, two and three-quarters inches long, extending from the tendon of the teres minor inward and then upward along the anterior border of the glenoid cavity. The head of the humerus lay upon the axillary border of the scapula one inch below the anterior border of the coracoid process, the limb being so far rotated outward that the internal epicondyle was directed forward, and the greater tuberosity rested against the anterior lip of the axillary border and the adjoining portion of the neck of the scapula. The subscapularis was pushed upward and overlapped the head. In another reported to the same society by Bouygues,⁶ the head of the humerus lay below

¹ Tillaux: Anat. topographique, p. 536.

² Malle: Bull. de l'Acad. de Méd., Paris, 1838, vol. ii. p. 941.

³ Goyrand: Mém. de la Soc. de Chir., 1847, vol. i. p. 21.

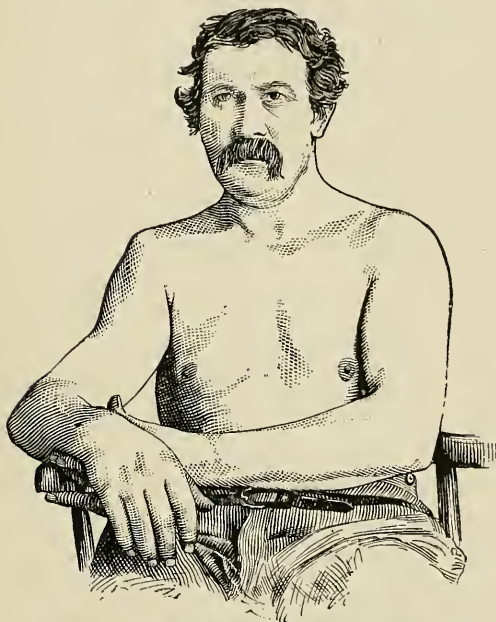
⁴ Panas: Dict. de Méd. et Chir. pratiques, art. Epaule, p. 462.

⁵ Leroy: Bull. de la Soc. Anatomique, 1844, p. 102. ⁶ Bouygues: Ibid., 1888, p. 581.

and in front of the glenoid fossa and beneath the untornd subscapularis, the anatomical neck resting on the axillary border of the scapula and the lower part of the fibro-cartilaginous rim; the upper portion of the greater tuberosity was broken off.

In a case reported by Jössel¹ of subglenoid dislocation caused by a fall from the second story of a house, in which death followed on the second day in consequence of an associated fracture of the skull, the following conditions were found: The subscapular artery was entirely torn across. The head of the humerus lay between the partly torn subscapularis muscle and the triceps "upon the triangular surface of the lower border of the scapula directly below the glenoid fossa." The capsule was entirely torn from the humerus, the subscapularis was

FIG. 295.



Subglenoid dislocation. (From a photograph.)

pushed upward, the edge of the glenoid fossa was a little broken at its widest part, and the upper and middle facets of the greater tuberosity were broken off, the line of fracture running into and opening the bicipital groove.

In Sédillot's case, quoted by Malgaigne as of this kind, the conditions were quite exceptional; abduction was so marked that the arm was held almost horizontal, the head of the humerus was situated half an inch below the glenoid fossa, resting against the scapula, but also engaged between the latissimus dorsi and teres major in front and the triceps behind.

Apparently the failure of the head to rise as usual to the level which

¹ Jössel: Deutsche Zeitschrift für Chirurgie, 1874, vol. iv. p. 124.

would make the dislocation subcoracoid is due to the resistance of the untorn portion of the capsule on the inner side; and the greater abduction of the limb is due to this retention of the head at a lower level, for the untorn outer portion prevents the shaft from sinking unless the head correspondingly rises.

Symptoms. The flattening of the outer portion of the shoulder, the prominence of the acromion, and the abduction of the elbow are all more marked than in the subcoracoid dislocation; and the axis of the arm prolonged by the eye in front passes below and to the inner side of the glenoid cavity. Measured in partial abduction from the acromion to the elbow, the arm appears longer than its fellow, and this elongation may not give place in complete horizontal abduction to as much shortening as is found in the subcoracoid form. The head of the humerus can be plainly felt in the axilla, and is separated from the coracoid process by an interval of from half an inch to an inch.

The differential diagnosis from subcoracoid dislocation is made by recognition of the position of the head below the glenoid fossa; the corroborative symptoms are the more marked flattening of the deltoid and its angle with the arm and the wider abduction of the elbow.

Treatment. Theoretically, the position of the head below the glenoid fossa suggests that traction should be made upward and outward, the elbow being raised above the shoulder, and this plan is generally recommended and usually successful. The objection to it is the added risk of doing injury to the bloodvessels in the axilla by overstretching them around the head of the humerus, as explained in the preceding chapter.

It is prudent, therefore, that a trial should first be made of the method of *direct reposition* (p. 569), and, that failing, of traction in the direction of the arm as found, or with a little more abduction, followed by adduction while pressure outward and upward is made upon the head of the bone, or with the fist in the axilla. The reader is referred to the preceding chapter for the details.

2. Luxatio Erecta.

This striking dislocation, first described by Middeldorpf, and his pupil Scharm¹ who reported the former's two cases, is characterized by the marked elevation of the arm, the forearm usually resting on the top of the head, a position from which it cannot be lowered without causing great pain, and by the prominence of the head low in the axilla. Besides Middeldorpf's two cases I have met with the description or mention of six others by Busch,² Panas,³ Lange,⁴ Alberti,⁵ Hannson,⁶ and Judd,⁷ and a reference by Bardenheuer,⁸ without details, to a case reported by Bertin and two cases reported by Meyer. Three cases have been admitted at the Hudson Street Hospital, but I saw only one of them.

¹ Middeldorpf: *Clinique Européenne*, 1859, vol. ii., and Scharm, *De nova humeri luxationis specie*. Dissert. Inaug. Breslau, 1859; quoted by Alberti, *vide infra*.

² Busch: *Archiv für klin. Chir.*, 1863, vol. iv. p. 30.

³ Panas: *Diet. de Méd. et Chir. pratiques*, art. Epaule, p. 405.

⁴ Lange: *New York Medical Record*, 1879, vol. xvi. p. 400.

⁵ Alberti: *Deutsche Zeitschrift für Chir.*, 1884, vol. xx. p. 475.

⁶ Hannson: *Centrabl. für Chir.*, 1892, p. 18.

⁷ Judd: *New York Medical Journal*, October 19, 1895. ⁸ Bardenheuer: *Loc. cit.*, p. 303.

The only opportunity for direct examination of the parts was furnished in one of Middeldorpf's cases; the patient's right arm was caught in some machinery and he was whirled around, receiving in addition to the dislocation a wound of the deltoid; he died of pyæmia. The greater tuberosity had been torn off, remaining attached to its three muscles, and the acromion was broken. Scharn produced the dislocation five times upon the cadaver; in every case the supraspinatus and infraspinatus muscles were torn away, and in two there was partial rupture of the subscapularis and pectoralis major. The main bloodvessels and nerves were uninjured. My only knowledge of Middeldorpf's cases and Scharn's experiments comes from the brief mention made of them by Alberti.

Lange's case, in which the dislocation was intracoracoid rather than subglenoid, differs also from the others in the less complete elevation of the arm. Bardenheuer¹ says that in his experience, covering about four hundred cases of dislocation of the shoulder, he had never encountered a pure luxatio erecta, but he had met with two cases in which the arm was abducted beyond a right angle with the body. Lange's case might properly be regarded as an exceptional form of intracoracoid dislocation intermediate between the usual form and the luxatio erecta.

The mechanism appears to have been forcible and extreme elevation of the arm, combined in one case (Alberti's) with a blow upon the arm from above downward, and the elevated position after dislocation was plainly due to the tension of the anterior soft parts created by the shifting of the centre of motion to a point so far below the glenoid cavity. In one of Meyer's cases mentioned by Bardenheuer, a woman sixty-two years old, it is said that the dislocation occurred during an epileptic fit. It is stated also that in one of the cases "paralysis of the brachial plexus" persisted after reduction.

The method of reduction adopted in all the cases was clearly the proper one, not only because it succeeded but also because it corresponded to the anatomical indications. Traction in the direction assumed by the arm drew the head directly back toward its socket by the route along which it had escaped.

3. Subtricipital Dislocation (?).

Our knowledge of this very rare, and even questionable, form is limited to a single doubtful case observed clinically by Farabeuf,² and to subsequent experiments made by him upon the cadaver. As the luxatio erecta is produced from a subglenoid by exaggerating the descent of the head of the humerus, so the subtricipital is said to be produced from the erecta by a consecutive displacement of the head upward and backward, at first underneath and then behind and above the long tendon of the triceps, a displacement effected by the descent of the elbow in front.

The case was that of a sailor who injured his shoulder while at sea; five weeks later he landed at Bordeaux, and, attempts made there to

¹ Bardenheuer: *Loc. cit.*, p. 303.

² Farabeuf: *Bull. de la Soc. de Chirurgie*, 1879, p. 778, and 1885, p. 396.

reduce having failed, he went to Paris. The arm was abducted and carried forward, and the head of the humerus rested on the back of the scapula two finger-breadths below the angle of the acromion. Reduction was not obtained.

In his experiments upon the cadaver Farabeuf found that after raising the arm forcibly and thus tearing the capsule at its lower part he could, by a vigorous push or a blow upon the elbow with a mallet, make the head of the humerus descend several centimetres below the glenoid cavity; if then the arm was lowered in front the head of the bone moved backward and became engaged under the tendon, which then held the arm abducted and directed forward and more or less rotated inward.

Farabeuf's case is apparently the one mentioned by Poinso¹ as Sebilleau's and as having been examined by himself in 1881. The limb was then in slight abduction and inward rotation, the elbow and fingers flexed; movements at the shoulder were almost completely lost. The case is described by Poinso¹ as one of dislocation backward (subacromial or subspinous), and no reference is made by him to Farabeuf's opinion concerning it, although he is named among the surgeons who had examined it.

Farabeuf maintains that two very similar cases observed by Richet and Bottey and named by the former *retro-axillary* (see Posterior Dislocations) were really examples of this variety described by him. It seems more probable that Farabeuf was misled by his experiments and that the three cases were merely low posterior dislocations.

Supposing such a case to exist, reduction should be made by first transforming the dislocation into a luxatio erecta by raising the elbow with traction to the side of the head, so as to bring the bone from beneath the triceps, and then reducing by direct traction upward.

POSTERIOR DISLOCATIONS.

Subacromial and Subspinous.

Dislocations backward are divided into two classes, the subacromial and the subspinous, according as the head lies under the projecting outer border of the acromion or further back below the spine of the scapula, respectively. A variety of the subacromial, to which the name *retro-axillary* has been given, has been recently observed and described by Richet and Bottey.

Although I think this division into two groups is quite generally accepted by the profession, yet English and American systematic writers upon the subject have, as a rule, refused to adopt it, giving as a reason therefor the fact that the two differ only in an unimportant feature, the degree of the displacement, and they apply the term *subspinous* to all. Flower² justifies the choice of this name in preference to *subacromial* on the ground that the latter does not express any change from the normal situation of the head of the humerus under

¹ Poinso: Translation of Hamilton's Fractures and Dislocations, p. 867.

² Flower: Holmes's System of Surgery, Am. ed., vol. i. p. 875.

the acromion. On the other hand, it may be fairly urged that, as in the great majority of cases the head is not displaced so far as to the spine of the scapula, the term subspinous is misleading and improper. I have preferred, in accordance with what I believe to be the general practice of the profession, to retain both terms with the distinction between them established by Malgaigne. Of the two groups the subacromial is much the more frequent, the subspinous being very rare.

According to Malgaigne, the earliest recorded mention of this dislocation was in 1834, and when he wrote, in 1855, he could collect only 34 cases, of which he himself observed 3. A very considerable number of cases have been recorded since that time (I found 7 in the *Index Medicus* for the years 1878 to 1882), and Panas's opinion that many escape recognition, by being mistaken for a sprain or an articular fracture, seems fairly justified, for not only are the diagnostic symptoms sometimes very obscure, but Nélaton said that he had within a short period of time seen three cases that had passed unrecognized by surgeons of merit. In Malgaigne's statistics 26 were men and 5 women; and in rather more than a quarter of them the cause was muscular action. Bardenheuer saw one in which both shoulders had been dislocated by a fall forward upon the elbows. (See, also, Chapter XLIV., Congenital Dislocations.)

Experiment upon the cadaver shows that the dislocation can be readily produced by forcible internal rotation of the arm, by which the posterior portion of the capsule is torn and the passage backward and outward of the head is made easy. In some of the cases clinically observed it is plain that this has been the mechanism, and in others it has undoubtedly aided. Thus, Piel, who wrote a thesis on the subject in 1851, saw a woman in whom it had been caused by her husband twisting her arm in a quarrel. In seven of Malgaigne's cases and in several that have since been reported the dislocation occurred during an epileptic fit, presumably by internal rotation of the limb. In other cases the cause has been a blow upon the front of the shoulder (twice a blow with the fist), pressure upon the back of the shoulder while the elbow rested against the ground, an attempt to control the patient in convulsions, once the throwing of a stone by a boy ten years old, and frequently a fall. The anatomical features of the joint, the results of cadaveric experiment, and such histories of cases as are sufficiently complete indicate that the common mode of production is pressure backward and outward upon the head of the humerus, either directly or through the elbow, combined with adduction of the limb across the front of the chest and internal rotation. Such a combination is most frequently found in falls forward in which the weight is received upon the adducted elbow. One of Malgaigne's cases is especially interesting from this point of view, as showing the conditions of the production almost as clearly as an experiment. A woman was trying to take down a box placed high above her head, it slipped suddenly into her extended hand, and the dislocation occurred. In other words, the force was exerted in a suitable direction upon an arm that was elevated, adducted, and rotated inward.

In a case observed by Tillaux¹ the patient, a man twenty-four years old, had his right arm caught in some machinery and was drawn several times about a revolving shaft, receiving a subspinous dislocation, and in addition having the arm almost completely torn away at its middle by being twisted several times upon itself.

Autopsies have been made in six recent cases in which death was caused by associated injuries. In Maisonneuve's case (the specimen is pictured in Malgaigne's *Atlas*, Plate XXII., figs. 5 and 6) the patient fell from a height of thirty feet. The capsule was torn above, below, and on its outer side; the greater tuberosity was torn off, broken into two pieces, and drawn back below the acromio-clavicular arch by the supraspinatus and infraspinatus muscles to which it remained attached. The teres minor and subscapularis were still attached to the humerus; the long tendon of the biceps had been torn out of its groove. The circumflex nerve was uninjured. The head of the humerus lay just below the posterior angle of the acromion and was not in contact with either the spine or the neck of the scapula, but rested against the posterior edge of the glenoid cavity.

In Laugier's² case the subscapularis and supraspinatus were torn from their insertions, and the head of the humerus had passed, as in Maisonneuve's case also, between the infraspinatus and teres minor and was covered only by the deltoid.

Two cases were reported by Jössel,³ one a subacromial, the other a subspinous dislocation. In the first the injury, together with a fracture of the skull, was caused by a fall into a cellar. The head of the humerus had torn through the teres minor and lay under the acromion; the limb was so far rotated inward that the articular surface looked directly outward. The supraspinatus and infraspinatus were uninjured. The capsule showed a triangular rent on the outer side just large enough to let the head through. The tendon of the subscapularis was still attached to the humerus, but under it and close by the tendon of the biceps an irregular, movable piece of bone could be felt, the lesser tuberosity, the fracture by which it was separated extending into the bicipital groove; the tubercle was split into two pieces, both adherent to the tendon.

In the second case the patient fell from a height of two stories, dislocated the left shoulder, and sustained a compound fracture of the thigh; he died on the fifth day. The head of the humerus had torn through the teres minor and lay under the spine of the scapula, separated from it by the interposed infraspinatus; it was directed backward. The long head of the triceps was almost entirely torn through, and a piece was broken from the axillary border of the scapula just below the glenoid fossa. The subscapularis and the adjoining part of the capsule were torn away from the humerus, bringing with them the lesser tuberosity, the fracture of which was broader than in the preceding case.

In the remaining two cases the dislocations were subspinous; in one

¹ Tillaux: *Anatomie topographique*, p. 536.

² Laugier: *Gaz. des Hôpitaux*, 1846, p. 60.

³ Jössel: *Deutsche Zeitschrift für Chir.*, 1874, vol. iv. p. 125.

of them, quoted by Malgaigne,¹ the patient, a man sixty-two years old, fell backward, and the wheel of his wagon, which carried a load of three and a half tons, passed obliquely across the right side of his chest, causing injuries which resulted in his death thirty hours later. Several ribs were fractured, as were also the body of the scapula and the inner portion of its spine. The deltoid, pectoralis major, teres major, and teres minor were torn or crushed, and the capsule was almost entirely detached. When the arm was lowered the head of the humerus lay below the spine of the scapula in the outermost part of the subspinous fossa, the lesser tuberosity corresponding to the edge of the glenoid fossa.

In the other, reported by Collins,² a man sixty years old was knocked down and run over, sustaining, in addition to the dislocation of his right shoulder, fracture of several ribs; he died in a few days of pneumonia. The capsule was torn on all sides; the supraspinatus and subscapularis were torn away at their insertions, and the long tendon of the biceps was detached from the bicipital groove. The head of the humerus lay between the teres minor and the infraspinatus, "immediately beneath the scapular spine."

In an operation for the reduction of old dislocation³ the lesser tuberosity was found to have been broken off.

The important complication of fracture of the anatomical neck has been reported in two cases, one by Delpech, the other by Malgaigne;⁴ in each the cause was a fall upon the shoulder. In Delpech's case the fall was due to an apoplexy which soon proved fatal; the head had passed entirely through a large rent in the postero-external part of the capsule, its fractured surface lay against the subspinous fossa, and its articular surface was directed backward and covered by the infraspinatus muscle. The muscular attachments to the humerus were all preserved, and the long tendon of the biceps was intact.

Malgaigne's case was not seen by him until eleven months after the receipt of the injury; the head of the humerus could be felt as an immovable, hemispherical body, two inches in diameter, and half an inch below the posterior angle of the acromion. The arm was shortened half an inch, the elbow slightly abducted and not rotated. The upper end of the shaft corresponded to the glenoid cavity. The arm was slightly movable; the head did not share in its movements.

The results obtained by experiments upon the cadaver are in harmony with these post-mortem records. In the subacromial variety the head of the humerus is found under the acromion looking backward and inward, with its anatomical neck engaged against the posterior edge of the glenoid fossa, and the lesser tuberosity lying on the latter. The tendon of the subscapularis covers the anterior and inner part of the fossa, and is usually more or less detached from its insertion upon the humerus. The dislocation can be transformed into a subspinous one

¹ Malgaigne: *Loc. cit.*, p. 541. According to Soyez (*Thèse de Paris*, 1880, No. 179) the case was treated by Denouvilliers, who deposited the specimen in the Musée Dupuytren. It is reported by Malgaigne as if he had himself observed it. Hence has arisen the error of supposing that they were different cases.

² Collins: *Dublin Journal Med. Sci.*, 1879, vol. ii. p. 166.

³ Eugel: *Arch. für klin. Chir.*, 1897, vol. lv. p. 603.

⁴ Soyez: *Thèse de Paris*, 1880, No. 179, p. 28.

by diminishing the internal rotation sufficiently to free the lesser tuberosity, and then forcing the humerus backward toward the dorsum of the scapula, tearing the capsule more extensively, lacerating the infraspinatus, increasing the separation of the subscapularis, and tearing off also the supraspinatus from its insertion. The dividing line between the two varieties is necessarily an arbitrary one, and in some cases it must be difficult to determine to which variety the case belongs. Malgaigne's definitions are as follows: The subacromial is one in which the head of the humerus lies under the posterior angle of the acromion; the subspinous, one in which it has been displaced behind the angle of the acromion and lies under the spine of the scapula.

Symptoms. The symptoms in recent cases are not very marked, and the characteristic ones may be masked by the swelling. In the subacromial variety the shoulder seems full behind and flattened in front. The arm hangs by the side, the elbow usually directed somewhat forward, and is rotated inward. The coracoid process can be plainly felt, and perhaps seen; the acromion is prominent in front. The absence of the head of the humerus from its socket is recognized by pressure made in front, and its presence behind and to the outer side is determined by palpation combined with gentle movements of the limb. In the older cases the subsidence of the inflammatory swelling and the atrophy of the deltoid consequent upon disuse make the deformity more marked. Voluntary movements are abolished, and communicated movements restricted and painful. Comparative measurements have not shown constant or notable differences in length. In two cases of my own the arm was rigidly held close to the side, and communicated movements were extremely painful. Reduction by traction, under ether, was easy, and full use of the limb was promptly regained.

The attitude is probably due to the persistence of the anterior portion of the capsule, which is noted in most of the autopsies and all the experiments upon the cadaver.

In the subspinous variety the attitude of the arm in the few reported cases has not been always the same; sometimes the elbow has been held close to the trunk and projected forward; in Malgaigne's it was rotated inward, but otherwise freely movable, and remained in such position as was given to it. In Desclaux's it was held horizontally in front of the upper part of the chest, and, as any attempt to lower it caused great pain, the patient sought to keep it immovable by placing the hand on the top of his head. The local symptoms at the shoulder are much the same as those in the subacromial variety; there is the same prominence of the coracoid process and acromion, the flattening of the front and the fulness of the back of the shoulder, the absence of the head of the humerus from its socket and its presence behind, in this case, of course, further back behind the angle of the acromion and below the spine of the scapula.

Richet, in 1882, treated a case which differed widely in one respect from both the subacromial and subspinous forms, namely, in that the head of the humerus, instead of being in contact with the acromion, lay at a distance of two finger-breadths below it, close behind the glenoid fossa. He considered it a new variety, representing the first stage in

the production of the subacromial, and gave it the name of *retro-axillary*. The case was published by Bottey, his interne, in the *Progrès Médical*, August 5, 1882, and subsequently republished with another also observed by Bottey in his graduating thesis.¹ The two cases resembled each other very closely; the patients were women, aged seventy-eight and seventy-two years, respectively, and the injury was caused in each case by a fall upon the shoulder; in one, while walking in the street; in the other, from her bed, against a chair. The elbow was directed forward and held near the body, and in the second case the patient supported the limb with the other hand because of the pain its weight caused. As both patients were thin and there was no swelling, the head of the humerus could be very distinctly felt behind the posterior edge of the glenoid fossa and slightly separated from it, and distant from the acromion by two good finger-breadths. External rotation of the limb was marked. Reduction was easily effected by direct impulsion, and both patients recovered promptly.

The position of the head may be explained by assuming that the rent in the capsule was exceptionally low, and did not extend upward along the posterior border of the glenoid fossa.

Prognosis. The prognosis is favorable as regards the probability of effecting reduction (in two or three cases the head has been unexpectedly returned to its place by the manipulations employed to make the diagnosis), but it is very unfavorable if the dislocation is left unreduced, for then the range of motion is usually very slight. In a case reported by Sir Astley Cooper, in which the dislocation immediately recurred after every reduction and was finally abandoned, the patient survived seven years, but remained unable to use or even move the arm to any extent. The tendency to recurrence was attributed to the separation of the tendon of the subscapularis from the humerus, and to the consequent lack of support on that side. The same tendency has been noted in other cases. Bardenheuer says it existed in three of his four, and that in two of them movements of the joint gave rise to crepitus. In some of the cases the full use of the limb has been regained in a very short time after reduction, a week or ten days.

Diagnosis. The diagnosis, as has been already said, may be difficult, especially if there is much swelling. The injury appears to have been not infrequently mistaken for a sprain or a contusion. The attitude and the direction of the axis of the arm, except in the rare subspinous cases, are not sufficiently characteristic even to suggest the existence of the injury, and unless the examination is systematically made with a view to determine the position of the head of the humerus, as should be done in all cases of injury in this region, the dislocation may be overlooked. If the head of the bone can be felt and its relations to the acromion determined, no doubt should remain.

Treatment. Reduction has been easily effected in both recent and old cases by a variety of methods. The one that has furnished the largest number of successes is direct pressure from behind forward upon the head of the humerus with counter-pressure upon the front of

¹ Bottey: Deux cas de luxation de l'épaule en arrière et en bas (luxation rétro-axillaire). Thèse de Paris, 1884, No. 13.

the acromion, usually associated with traction upon the arm, or with gentle movements of the limb in various directions. Sédillot successfully reduced a dislocation that had existed for a year and fifteen days.

The position and relations of the untorn portion of the capsule indicate that the best manipulation would be elevation of the elbow in front and toward the median line, combined with inward rotation to relax the anterior portion of the capsule, and followed by direct propulsion of the head from behind toward its socket, or by traction in the direction of the long axis of the arm. Simple external rotation might succeed when the articular surface of the head rests against the edge of the glenoid cavity, as it sometimes does, for by making the front of the capsule tense it would rotate the posterior surface of the bone inward and forward, but the success of this manipulation might easily be prevented by the increased friction between the two bones.

In a case of subspinous dislocation reported by Dr. J. E. Michael¹ reduction made on the fifty-ninth day remained incomplete. The patient was a boy sixteen years old, who had received the injury by a fall from a horse; the head of the humerus lay at the junction of the middle and outer thirds of the spine of the scapula, the arm was slightly rotated inward, and the hand could be raised only to the nipple. After trying elevation and rotation without success, the head was brought by traction so nearly into place that the hand could be placed upon the opposite shoulder, but the form of the shoulder remained imperfect because of the undue prominence of the head of the humerus behind and on the outer side. Six months later the deformity persisted and there was considerable emaciation of the region; there was slight mobility, rotation was entirely lost, and the hand could be brought to the head only with an effort.

UPWARD DISLOCATIONS.

Supraglenoid, Supracoracoid.

The possibility of the occurrence of this rare form of dislocation, which has often been denied, has at last been established by the clinical observation of several cases and the post-mortem examination of two.

The first alleged case was reported by Laugier² in 1834 as an incomplete dislocation upward; the second was by Malgaigne.³ In 1858 Bourget submitted to the Société de Chirurgie a paper upon the subject containing the accounts of three cases observed by himself, two of which he diagnosed as complete dislocations, and one as incomplete, and reproducing the cases of Laugier, Malgaigne, and Avrard. Upon this paper Morel-Lavallée⁴ made an elaborate report, denying the correctness of the diagnosis in all the reported cases and attributing the observed deformity to a prolonged arthritis, and he supported this

¹ Michael: *The Medical News*, 1884, p. 621.

² Laugier: *Arch. gén. de Méd.*, 1834, vol. x. p. 65; also in *Dictionnaire en 30 vols.*, vol. xiii. p. 81.

³ Malgaigne: *Rev. médico-chirurg.*, 1849, vol. v. p. 30, and *Luxations*, p. 530.

⁴ Morel-Lavallée: *Bull. de la Soc. de Chir.*, 1858, vol. viii. p. 490.

opinion by quoting the case of Soden,¹ in which the symptoms were the same as in Laugier's case, but the autopsy, five months later, showed the changes of a dry arthritis. He seems to have attached no importance to the dislocation inward of the long tendon of the biceps. The alleged cases on record are Malgaigne's, two of Bourget, and those of Chassaignac,² Holmes,³ Prescott Hewett (quoted by Holmes), Denouvilliers,⁴ Albert,⁵ Busch,⁶ Verneuil,⁷ Le Dentu, Tuffier,⁸ Robson,⁹ and Streeter,¹⁰ fourteen in all, in one of which (Albert) both shoulders were dislocated in the same manner and at the same time.

The cases that furnished autopsies are Holmes's, Albert's, and Tuffier's. Holmes's patient was a man fifty years old, who had fallen from a height of about thirty feet, striking upon his head, the left side of his chest, and left elbow, and receiving in addition to the dislocation in question a compound dislocation of the radius and a comminuted fracture of the upper portion of the ulna of the same side. The head of the humerus formed a large prominence in front of the outer part of the clavicle; movements of the arm gave rise to crepitus. No attempt to reduce was made, and the patient died on the fifteenth day.

At the autopsy the head of the humerus was found immediately under the skin, having passed through the deltoid near its inner anterior margin; its articular surface was entirely above the glenoid fossa and rested upon the stump left by fracture of the coracoid process near its base. The coracoid process lay on its inner, the acromion on its outer side and somewhat posteriorly; the coraco-acromial ligament appears to have been in part torn. The subscapularis was intact, but the muscles attached to the greater tuberosity were torn through, except a part of the teres minor. The long tendon of the biceps lay below the head on its outer side; it was still attached to the upper margin of the glenoid fossa, but some of its inner fibres had been broken away from the muscle. The capsule was torn at its upper and inner part.

Albert's case was first seen by him several years after the injury was received. The patient had dislocated both shoulders by holding on to the reins of a pair of runaway horses and being drawn along the ground. The deformity was more marked on the left than on the right side, and there consisted of a marked rounded prominence on the front and upper part of the shoulder. Both arms hung close by the side, the axis being directed obliquely from below upward and forward in front of the glenoid fossa. The prominence formed by the head of the humerus was situated in front of the acromion, rising about two centimetres above its upper surface, and this elevation could be increased by pressing the elbow upward; the arms were so far rotated

¹ Soden: *Medico-Chirurgical Transactions*, vol. xxiv. p. 212.

² Chassaignac: *Bull. de la Soc. de Chir.*, 1858, vol. viii. p. 472.

³ Holmes: *Medico-Chirurgical Transactions*, 1858, vol. xli. p. 447.

⁴ Denouvilliers, in Panas: *Dict. de Méd. et Chir. pratiques*, art. Epanle, p. 469.

⁵ Albert: *Chirurgie*, 2d ed., 1881, vol. ii. p. 287; also in *Wiener med. Blätter*, 1879, p. 453.

⁶ Busch: *Arch. für klin. Chir.*, 1876, vol. xix. p. 400.

⁷ Verneuil in Pellier: *Thèse de Paris*, 1878.

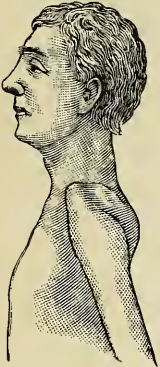⁸ Tuffier: *Bull. de la Soc. Anat.*, 1886, p. 292.

⁹ Robson: *Annals of Surgery*, 1888, p. 175.

¹⁰ Streeter: *Medical Record*, February 26, 1887.

outward that the transverse diameter of the lower end of the humerus coincided with the transverse axis of the trunk. The outer deltoid region was not noticeably flattened, but posteriorly the fibres of that muscle were greatly relaxed and the posterior edge of the glenoid fossa

FIG. 296.



Supraglenoid dislocation. (ALBERT.)

could be distinctly felt through them. The point of the finger could be pressed in between the head and the coracoid process. Slight voluntary rotation and movement of the elbow forward and backward were possible; very slight passive abduction. The left elbow could be flexed only to a right angle, further flexion being arrested by the triceps. On the right side the deformity was the same in character, but less in degree, and there was the same limitation of motion. If pressure was made upon the elbow directly upward the movement could be distinctly felt to be arrested by bony contact, and this demonstrably occurred between the head of the humerus and the clavicle, but if the elbow was first carried backward the head could then be pushed up higher.

At the autopsy the capsule was found attached throughout to the anatomical neck of the humerus and adherent also to the upper part of its articular surface; thence it extended without interruption to the margin of the glenoid fossa, but its cavity was considerably enlarged. The coraco-acromial and coraco-clavicular ligaments were uninjured. The upper third of the head of the humerus lay above the level of the coraco-acromial ligament, and this overlapping could easily be increased to half the head. The glenoid fossa was filled with a thick layer of fibrous tissue.

In the fuller account given in the *Wiener medicinische Blätter*, 1879, p. 453, quoted by Poinso, it is said that the long tendon of the biceps on the left side was ruptured and its end adherent to the bone in the bicipital groove, and that an osteophyte an inch long had grown from the base of the coracoid process.

Tuffier's specimen was found in the dissecting-room. The acromion was broken off near its base and turned up and out; the head of the humerus was in direct contact with the acromion and coracoid, and the joint showed old changes of dry arthritis, including ossification of the long head of the triceps.

To these may be added Robson's observations made during an arthrotomy. His patient was a boy sixteen years old who had received his injury six weeks earlier by the forcible dragging of his right arm upward and backward. The description of the symptoms is not very clear, but the head of the humerus "lay about a finger-breadth in front of the right acromion and immediately to the outer-side of the coracoid process." Motion of the arm was limited in every direction except backward. The bone was exposed by a curved incision on the outer side of the shoulder, and "it was then discovered that in addition to the dislocation of the head of the humerus there was a longitudinal fracture separating the greater tuberosity from the head and

extending down the shaft for some distance beyond the line of incision. . . . Reduction could not be effected in consequence of the glenoid fossa being filled with callus and plastic material thrown out around the fracture."

The other cases are as follows :

Malgaigne. A man sixty years old was thrown from a wagon, striking upon his shoulder while his arm was held close to his side. There was much pain and he was unable to move the limb. A "bone-setter" handled him roughly and sent him away with his arm in a sling. Two and a half months later he consulted Malgaigne. The head of the humerus was dislocated upward and forward above the coracoid process, reaching the under surface of the clavicle, and stretching the overlying deltoid so that on perforation with a pin the latter proved to be only eight millimetres in thickness ; shortening one-fifth of an inch. Traction to the extent of more than four hundred pounds, combined with pressure upon the head downward, outward, and backward and counter-pressure on the acromion, failed to effect reduction, although it made the head so movable that it could be drawn down a finger-breadth below the clavicle. Malgaigne meditated division of the coraco-acromial ligament, which seemed to be the obstacle, but refrained.

Bourget's cases resembled Malgaigne's closely.

Busch. (Fig. 297.) A horse reared and struck the patient, who was holding him by the bridle, upon the inner and anterior part of the shoulder with his hoof. The head of the humerus was displaced upward and forward, the deformity closely resembling that in Malgaigne's case ; the infraclavicular fossa was deepened, the arm hung close by the side, the posterior deltoid region was hollowed, the coracoid process could not be felt in its place. Reduction failed.

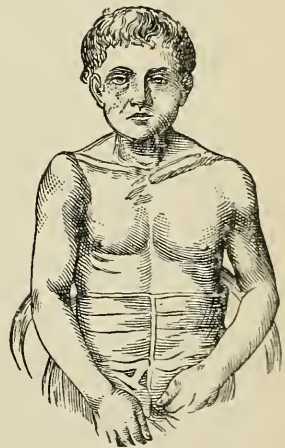Denonvilliers. A man fell upon his arm, but was unable to give the details of the fall. The limb hung by the side and was strongly rotated outward. Ecchymosis, pain, loss of function. The head of the humerus projected forward and upward between the coracoid and the acromion and in front of the clavicle. Oblique traction, combined with a slight movement of leverage, effected reduction.

Chassaignac. A man fell from the third story of a building. The head of the humerus projected directly outward and extended above the coraco-acromial ligament.

Movements of the elbow forward were impossible, backward they were more free than normal. The dislocation was easily reduced by exaggerated elevation of the arm, but recurred when the arm was lowered.

Hewett. The patient was a middle-aged woman ; the head of the

FIG. 297.



Supraglenoid dislocation : Busch's case. (BARDENHEUER.)

humerus lay on the upper and inner side of the glenoid cavity ; there was distinct crepitus which ceased after reduction had been made by traction with the heel in the axilla. Apparently the patient made a complete recovery.

Streeter. "A man of middle age fell down stairs, striking on his elbow. The coracoid process was evidently fractured, and the articular head of the humerus was plainly felt above the clavicle, the patient being very thin. At the present time he is making good progress toward recovery."

Fracture of the coracoid process existed in Holmes's and Streeter's cases, and possibly also in Hewett's and Busch's.

Rupture or displacement of the long tendon of the biceps must occur, and rupture of the muscles attached to the greater tuberosity is noted by Holmes ; it seems not unlikely that the impossibility of reduction in several of the cases was due to the interposition of the tendon of the biceps or the stump of the supraspinatus.

The mode of production cannot be determined with an approach to precision except in the cases of Holmes and Streeter, in both of which the arm was driven upward by a blow upon the elbow. Tuffier's fracture of the acromion suggests a similar cause.

Panas's experiments upon the cadaver show that if the arm is strongly rotated outward while held close to the body, and then pressed bodily upward and forward, the capsule will tear at its upper part and the dislocation will be produced without fracture of the coracoid process, the head of the humerus rising not more than one centimetre above its normal position.

The symptoms consist in the presence of the head of the humerus in the interval between the coracoid process and the acromion above its proper level. The coracoid process can be felt with difficulty, if at all. Usually voluntary movements are almost or quite impossible, and passive movements greatly restricted, and this restriction exists in old as well as in recent cases.

In three cases seen while the injury was recent, Denonvilliers, Chassignac, and Hewett, reduction was easily effected by traction in two and by elevation of the elbow in one, but the dislocation recurred in the latter ; Verneuil reduced on the thirty-sixth day by traction aided by anæsthesia. In Holmes's case the associated injuries were so severe that reduction, for which the aid of chloroform was thought to be necessary, was not attempted. Malgaigne, Bourget, and Busch failed, the duration of the dislocation at the time of the attempt being two and a half, six, and five months respectively. The details of Bourget's second case are not given, and the result in Le Dentu's I do not know. In Albert's the dislocation had existed for many years, and no mention is made of any attempt to reduce. In Streeter's reduction seems to have been made. The persistent displacement in Tuffier's cannot be accounted for except by supposing that the arm was too well supported in a sling while the injury was recent.

CHAPTER XLIV.

DISLOCATIONS OF THE SHOULDER.—(CONTINUED.)

Associated Injuries and Complications—Prognosis—Habitual Dislocations—Old Dislocations—Congenital and Pathological Dislocations.

Associated Injuries and Complications.

THE complications which may coexist with a dislocation have been described in Chapter XXIX., and will therefore be treated but briefly here, and mainly with the view of adding some details to the account already given. In like manner the accidents which may be caused by attempts to reduce a dislocation have been described in Chapter XXXIV.

The injuries which are more or less frequently associated with dislocations of the shoulder, but which are without such special bearing upon the prognosis or treatment as would make them actual complications, have been mentioned in connection with the different forms of dislocation in the preceding chapters. The most important are the lacerations of the different muscles and tendons or their equivalent avulsion from the humerus with more or less of the tuberosities to which they are attached.

Laceration of the subscapularis is frequent, and avulsion of the lesser tuberosity to which it is attached is very rarely substituted for it, apparently only in some of the backward dislocations. The extent of the laceration of the muscle can only be inferred from the extent and direction of the displacement, and it is believed to be without important influence upon the completeness of the repair and the subsequent security of the joint. The position of adduction and inward rotation in which the limb is habitually kept during the period of convalescence favors the repair of the muscle, and since the rupture is usually incomplete the torn portions do not widely retract.

With the muscles attached to the greater tuberosity it is somewhat different. The muscles themselves are rarely torn, but the upper and middle facets of the greater tuberosity to which the supraspinatus and infraspinatus muscles are attached are frequently broken off and more or less retracted under the acromion, or the tendons are torn away from them and retracted. The importance of this associated injury, through its effect upon the subsequent usefulness and security of the joint, may be great; not only may the power of voluntary external rotation be diminished thereby, but the consequent loss of support on the outer side of the joint favors recurrence of anterior dislocation, and the great lengthening of the upper portion of the capsule and the enlargement of its cavity which are effected by the retraction of the supraspinatus and the establishment of free communication between the joint and the

subacromial bursa make the joint much less secure, and this condition is thought to be the cause of the marked tendency to recurrence observed after some anterior dislocations (see Chapter XXIX.). Similarly the avulsion or rupture of the subscapularis in backward dislocations is responsible for the tendency to recurrence that has been so frequently noted in them.

The tendon of the **long head of the biceps** appears habitually to escape rupture; its sheath may be opened by the avulsion of either tuberosity, and then it may slip over the corresponding portion of the head, and, becoming engaged between the latter and the glenoid cavity, thus constitute a serious obstacle to reduction. When ruptured, its end is retracted into its sheath in the bicipital groove and there becomes united with the bone.

Fracture of the greater tuberosity appears to be not often capable of demonstration; at least it has often been found post mortem when it had not been recognized during life, although the proper explanation of the failure to recognize it may be that it was not sought for. If the fragment is retained in contact with the humerus by the untornd periosteum, crepitus may perhaps be obtained by manipulation; and when the fragment is widely withdrawn it may perhaps be felt under the acromion, or its absence may be recognized by the change in the shape of the corresponding part of the humerus, or the fracture may be indicated by exceptional symptoms accompanying the dislocation, such as greater mobility of the limb or the absence of fixed abduction of the elbow, or local pain on pressure. (See page 223.)

Fracture of the lesser tuberosity is much less frequent. To the five cases mentioned in the chapter on fractures of the tuberosities of the humerus (p. 224) may be added the two reported by Jössel and quoted in the preceding chapter in the section on posterior dislocations (p. 586).

Fracture of the Anatomical or Surgical Neck. This serious complication of the humerus is fortunately rare; McBurney¹ was able to collect only 117 reported cases, although his search was aided by those of Oger² and Porrier and Mauclaire.³

It is believed that the fracture follows the dislocation, but it is possible that they may be coincident in fracture of the surgical neck when the dislocation is caused by violence acting on the outer aspect of the shoulder. Fracture of the anatomical neck is difficult of explanation. The probable cause, in my opinion, is the wedge-like action of the inner edge of the glenoid fossa against the anatomical neck (see page 557). I have seen it in one case of dislocation in an epileptic convulsion, during which, it was said, the patient's wrists were firmly held at his side by an attendant.

The fracture may occupy the anatomical or the surgical neck, or may extend through the tuberosities, or may be extensively comminuted. Of 68 cases collected by Thamhain⁴ the fracture in 14 was of the

¹ McBurney: *Annals of Surgery*, April, 1894, and May, 1896.

² Oger: *Luxations scapulo-humérales compliquées de fracture*. Thèse de Paris, 1884, No. 361.

³ Porrier and Mauclaire: *Rev. de Chir.*, October, 1892.

⁴ Thamhain: *Schmidt's Jahrbücher*, 1861, vol. cxi. p. 194.

anatomical neck ; in 2 of these reduction was effected. The displacement in the great majority of cases is forward and inward, the head lying under or on the inner side of the coracoid process ; in a few cases it has been backward under the acromion. The upper fragment may, in addition, undergo rotation that will widely separate its broken surface from that of the shaft. Cases of the rare form in which the head, after fracture of the anatomical neck, has undergone complete reversal while remaining within the cavity of the joint have been quoted in Chapters XIX. and XXIX. The upper end of the lower fragment is usually drawn upward toward the glenoid fossa, overlapping the upper fragment on the outer side, and it may unite in this position by fibrous or bony union with the other fragment, or with the scapula.

The upper fragment usually preserves its vitality and establishes new vascular connections ; in rare instances it has become necrotic and has been eliminated after prolonged suppuration.

The diagnosis appears, in some cases, to have presented serious difficulties, because the fracture removed some of the most characteristic symptoms of the dislocation, such as the fixation and attitude of the limb, and the indication of the position of the head of the bone that is furnished by the direction of its long axis. In general terms, it may be said that when the dislocation of the head has been recognized the coexistence of a fracture may be suggested by the mobility of the limb, its shortening, and the greater extent of the ecchymosis, and proved by the independent mobility of the shaft and head with crepitus. When the signs of fracture are apparent the coexistence of a dislocation can only be recognized by determining the absence of the head from its socket, and this may be made very difficult by the swelling of the soft parts. It must be remembered that the same exceptional mobility may be given to the limb by extensive laceration of the capsule without fracture. The two positive signs, which the surgeon should spare no pains to recognize, are the absence of the head of the humerus from its socket, which proves the dislocation, and its failure to share in movements communicated to the shaft, which proves the fracture.

The treatment presents grave difficulties because the existence of the fracture deprives the surgeon of that control over the movements of the head of the bone which, in a simple dislocation, can be exerted through its shaft. Reduction in a recent case may sometimes (36 out of 80 cases, Oger) be effected by direct impulsion of the head back into place. This should always be attempted, with the aid of anæsthesia and gentle traction upon the abducted shaft in order to utilize such periosteal connection between the fragments as may remain. In two cases of fracture of the anatomical neck I made reduction in this manner very easily, holding the limb in full abduction and pressing directly upon the head with the fingers deeply placed in the axilla.

This failing, the alternative plans were to seek consolidation of the fracture and then to reduce the dislocation, or to prevent union of the fracture and thus obtain a false joint at its seat (Riberi), or to excise the fragment. Nine reported cases of the first plan gave seven failures and two successes, and even in one of the latter reduction was made in

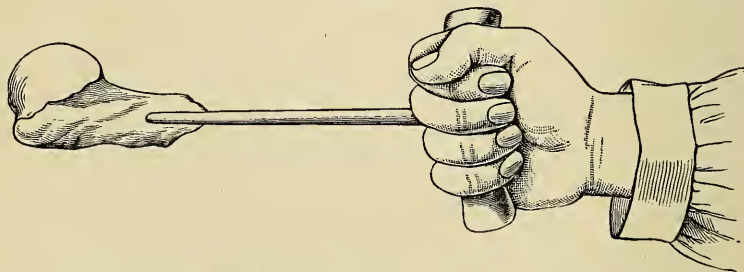
the third week. Seven cases of the second plan have been reported, but it is not easy to determine from the reports the measure of the functional success. In cases in which the displacement was unrelieved the usefulness of the arm was even more impaired than when an uncomplicated dislocation was left unreduced, because of the additional adhesions created by the fracture, and a large proportion of the patients appear to have suffered from the pressure effects of the dislocated head. The complication, therefore, remained a serious reproach to surgery, the only means of relief being excision of the head.

In this juncture Dr. McBurney devised and successfully used a method of reduction which seems perfect in its efficiency and which, at least when the fracture is through the surgical neck, involves less risk than primary excision of the fragment. He makes an incision on the outer anterior aspect down to the upper fragment, drills a hole in the latter, inserts the end of a stout hook bent at a right angle (Fig. 298), and with its aid makes the needed traction and rotation. After reduction has been thus made, he sutures the fragments together with catgut, and then treats the limb as for fracture. He has used the method in four cases, two each of the surgical and anatomical necks, all the wounds healing primarily, and with a functional result as good as that following an uncomplicated dislocation or fracture.

In one case in which I employed it the head was so completely separated from all attachments that it seemed best to remove it, and in another, five weeks after the accident, I made no attempt to preserve the head, believing that its removal would give a better functional result in view of the advanced age of the patient, his epileptic status, and the splintering of the tuberosity.

Schlange¹ has recently reduced in two cases—one a fracture of the anatomical, the other of the surgical neck—by incising through the axilla, drawing the coraco-brachialis forward and the vessels and nerves backward, and making direct reposition.

FIG. 298.



McBurney's hook for making traction upon the dislocated upper fragment.

For statistics of various methods of treatment after failure to reduce, see Sonchon, *Transactions of the American Surgical Association*, 1897, p. 322; B. F. Curtis, *Annals of Surgery*, March, 1900, p. 291; and Schoch, *Beiträge zur klin. Chir.*, 1901, vol. xxix. p. 103.

¹ Schlange: *Arch. für klin. Chir.*, vol. 81, Part 2, p. 9.

Fracture of the shaft associated with dislocation of the shoulder has also been observed several times. It is a less serious complication than fracture of either the anatomical or the surgical neck, because the greater length of the upper fragment makes it easier to effect reduction.

Fracture of the coracoid process has been observed in connection with dislocation of the humerus, not only in the case of supracoracoid dislocation mentioned above, but also in dislocation forward.

Fracture of the acromion has also been occasionally observed. Krönlein's and my cases in which a blow received upon the top of the shoulder first broke the acromion and then dislocated the humerus into the axilla have already been mentioned (p. 558); also Tuffier's, in an upward dislocation.

Fracture of the Glenoid Fossa. Probably the chipping of the edge of the glenoid fossa is not infrequent in dislocation, and passes unrecognized because of the lack of symptoms. Fracture of a large portion has been occasionally observed, both clinically and after death, and is of great importance in favoring recurrence of the dislocation. Malgaigne represents in his *Atlas* (Plate XXII., fig. 4) a case in which the anterior third of the fossa was broken off and had been displaced backward and become united with the neck of the scapula; the symptoms in the case were that the shoulder was less full and rounded than normal, and that the head of the humerus, while still in relation with the anterior part of the acromion, projected a few lines in front of the inner border of the coracoid process.

The special indication for treatment is to prevent recurrence of the dislocation by fixation of the limb and pressure upon the head from the side on which the fracture has taken place.

Nerves. Injury to the nerves, except of a slight and transitory character, is rare, and in most of the cases reported as such the injury has been inflicted during reduction. In two cases in which the injury was demonstrated by post-mortem examination, Hilton's¹ and Parise's,² there was only a partial laceration of the circumflex nerve in the former, and in the latter rupture at different levels of the fibres composing it, only recognizable on minute dissection; the nerve trunk was extensively infiltrated with blood; the dislocation was subglenoid, and the nerve was tightly stretched around the head of the humerus. In Bourgues's³ (subglenoid) the main nerves were so compressed between the surgical neck and the fascia that they showed multiple grooves and punctate hemorrhages. In Müller's (p. 419) the nerves and artery were compressed by a cicatricial band.

It is occasionally found in unreduced dislocations that the sensibility of the skin over most of the deltoid region, which is supplied by the circumflex nerve, is diminished or lost, and that in others after reduction the deltoid is paralyzed. This paralysis of the deltoid is thought frequently to be the result of direct bruising of the muscle by the violence that caused the dislocation, but that explanation does not satisfactorily account also for the loss of sensibility in the skin, and we

¹ Hilton: Guy's Hospital Reports, 1847, vol. v. p. 93.

² Parise: Gaz. Médicale de Paris, 1863, p. 210.

³ Bourgues: Bull. de la Soc. Anat., 1888, p. 581.

must, in such cases, assume that the trunk of the circumflex has been stretched in the dislocation.

In many of the reported cases it cannot be determined whether the injury to the nerve was caused by the dislocation or by the manœuvres made to effect reduction; in some it is clearly due to the dislocation. Illustrative examples have been quoted in Chapter XXIX.

The cause of the paralysis, when it involves more than the circumflex nerve, is very obscure. It has been attributed to compression of the main trunks in the axilla, but this explanation is not satisfactorily supported by post-mortem examination or experiment, and the fact that similar symptoms may follow blows that neither produce a dislocation nor directly involve the nerves adds to the difficulty. Nélaton sought to explain it by supposing a compression of the nerves between the clavicle and the first rib, and some cases have been reported which indicate that this explanation may, sometimes at least, be the correct one. Perhaps elongation, stretching of the brachial plexus in marked descent of the head may be a cause. Cf. Fisk's case, p. 197, and Flanbert's, p. 456. On the other hand, the prompt disappearance of the symptoms in some cases after reduction clearly points to pressure by the head or neck of the humerus upon the nerves as the cause.

The paralysis may appear immediately or may develop gradually during the first two or three days, and it may be complete or partial. In some cases (see Chapter XXIX.) it has been followed by serious changes in the appearance and nutrition of the limb, presumably the effect of an ascending neuritis. In one case Bardenheuer¹ demonstrated the existence of neuritis and perineuritis by exposing the nerves, and worked a gradual cure by stretching their trunks.

Whatever doubt may exist as to the direct cause of the paralysis, the first step in the treatment is to reduce the dislocation; after that has been accomplished, or even if it should fail, electricity should be persistently employed. Some cases respond promptly to treatment, the contractility of the muscle sometimes reappearing after even the single application of a blister, while others, after weeks or months of treatment, will show no improvement. So long as the muscle reacts to electrical stimulation the prognosis is good.

Bloodvessels. The complication of serious injury to the bloodvessels in the neighborhood of the joint is not frequent, and in the recorded cases there is often a doubt whether the injury was caused by the dislocation or by the attempt to reduce it. The subject has been discussed in detail in Chapters XXIX. and XXXIV.

Chest. A unique case reported by Prochaska, in which the head of the humerus was forced into the chest between the second and third ribs, is quoted in Chapter XXIX., p. 427.

Compound dislocations are rare; the wound in the skin is commonly in the axilla, sometimes further inward through the pectoralis major, sometimes behind the joint. It is a very serious complication, although there is reason to hope that a larger proportion of successes will be

¹ Bardenheuer: *Loc. cit.*, p. 335.

obtained in the future under the improved methods of treating wounds than was possible in the past. The essentials of such treatment are immobilization of the joint, drainage, and surgical cleanliness; excision of the head of the humerus may also be required under certain circumstances, such as difficulty of reduction or retention, coincident fracture, uncleanliness of the wound, and imperfect drainage of the joint. The prudent course is to provide abundantly for drainage by not closing the skin wound except, perhaps, in part, and by lightly packing with iodoform gauze for at least twenty-four hours. The last-named precaution provides a prompt and ready means of escape for the blood and exudations, and at the same time does not prevent the wound from being closed a day or two later with sutures and then healing as rapidly and kindly as if it were entirely fresh.

Simultaneous dislocation of both shoulders is deemed a rare occurrence; possibly it is more frequent than is generally supposed, for I found five cases mentioned in the *Index Medicus* for the years 1880 to 1885. It is of interest only as a curiosity, for the combination does not seriously affect the prognosis or treatment. The causes in the five cases referred to were as follows: In one¹ the patient was seized in the street by two thieves who drew his arms upward, outward, and backward, producing subcoracoid dislocations; both joints had previously been repeatedly dislocated. In the second² the patient, while standing on a platform, was caught under one arm by a chain and thrown to the ground. In the third³ a woman, eighty-six years old, fell out of bed, receiving an intracoracoid and a subcoracoid dislocation. In the fourth⁴ a girl, twenty-one years old, was knocked down by a falling wall; and in the fifth,⁵ a girl, the injuries occurred during an epileptic convulsion. In a personal case both shoulders were dislocated by lifting the patient by his hands out of the water into a boat. All of them were anterior dislocations. Mention has been made in the preceding chapter (p. 585) of Bardenheuer's case in which both shoulders were dislocated backward by a fall forward upon the elbows.

Associated dislocation of the elbow has been twice reported. Morel-Lavallée's⁶ patient was injured in a railway accident; the head of the humerus was driven out through the skin of the outer part of the shoulder and projected so far that the elbow was in contact with the axilla; the elbow also was dislocated.

Moxhay's⁷ patient was a man, fifty-six years old, who was struck on the back of the arm by the handle of a wrench and sustained a backward dislocation of both bones of the forearm and a subcoracoid dislocation of the shoulder; the latter injury was not discovered by the surgeon until the seventh week after the accident; it was then successfully reduced.

Injuries caused by attempts made to reduce dislocations have been described in Chapter XXXIV.

¹ G. E. Moore: New York Medical Record, 1880, vol. xviii. p. 96.

² Caskie: British Medical Journal, 1881, ii. p. 854.

³ Güterbock: Berlin. klin. Wochenschrift, 1885, vol. xii. p. 346.

⁴ Zinker: Idem, p. 418.

⁵ Fränkel: Verhandl. Berlin. med. Gesellschaft, 1885, xiii. p. 150.

⁶ Morel-Lavallée: Bull. de la Soc. de Chir., 1858, vol. viii. p. 490.

⁷ Moxhay: Lancet, 1882, ii. p. 938.

PROGNOSIS AND AFTER-TREATMENT.

Since our knowledge of the pathology of dislocations and of the common obstacles to reduction has become so much more accurate and complete, and especially since the introduction of anæsthetics, failure to reduce a recent dislocation of the shoulder has become very exceptional. Bardenheuer says that of 400 such cases treated by him within ten years he has not failed in any, and only once has he had any difficulty. I have been obliged to resort to the knife in only one. The prognosis, therefore, so far as the reduction of recent dislocations is concerned, is eminently favorable. It is also more favorable for the older dislocations than it formerly was, for the same reasons and because of the greater safety of operative interference; and at the same time such cases have become more uncommon, for, as a rule, they are now only those in which the dislocation has been overlooked or not treated.

The prognosis is also favorable as regards the complete restoration of the functions and security of the joint, but this restoration may be delayed or prevented by inflammation or partial ankylosis of the joint or by paralysis of some of the muscles, and the security may be seriously diminished by partial failure of repair or by permanent changes in the joint surfaces.

The after-treatment is directed to the retention of the head of the bone in its place until such time as the repair of the injuries to the capsule and peri-articular tissues is sufficiently advanced, and to the prevention or cure of inflammation and ankylosis.

It occasionally, though very rarely, happens that the dislocation is reproduced within a few minutes of the reduction, without such movement of the arm (abduction or elevation of the elbow) as would explain it, and it is then presumably due to muscular contraction, perhaps aided by the interposition of a portion of the capsule. It suggests the desirability of immediately and securely fixing the arm to the side of the body before the patient is allowed to move after reduction has been made, and of inspecting the limb shortly afterward.

The traumatism is always followed by some inflammatory reaction and the evidences of a more or less prolonged arthritis, but it seldom happens that this is sufficiently violent to cause apprehension or require other treatment than immobilization of the limb. The severer cases are those in which the limb has been too early or too freely used. The fear that prolonged immobilization of a joint would lead to its permanent stiffness is, or has been, too prevalent and has led to much untimely passive or active motion of joints that have been injured, and this in turn, by keeping up the irritation, has increased the stiffness which it was designed to diminish. After the soreness has ceased, about the third week, the patient should be encouraged to try gently to increase the range of motion and freely to use the limb within the limits of pain. The retraction of the capsule, the loss of its pliability, is, except in the case of prolonged inflammation and in some highly arthritic individuals, only temporary and will ordinarily yield to the natural use of the limb.

If the inflammation is more severe or if it has been prolonged by imprudent use of the limb the immobilization should be supplemented by traction downward. Bardenheuer¹ highly recommends in addition that the upper end of the humerus should be kept pressed outward and backward by a pad in the axilla attached to a weight above and behind the shoulder. This necessitates the recumbent posture.

For late changes in the bone see the following section: Habitual Dislocation.

Paralysis of the deltoid causes the loss of voluntary abduction of the arm, and if prolonged leads to permanent shortening of the lower and inner portion of the capsule with consequent limitation of even passive abduction. It may also be followed by the sinking of the humerus downward through lack of the support normally given by the deltoid, and by consequent loss of security in the joint. Usually these paralyzes get well spontaneously or under treatment by blisters or electricity, but sometimes they are permanent.

If the *dislocation remains permanently unreduced* the peri-articular muscles become wasted and the deformity of the region is thereby increased. The head forms a new socket for itself, but its availability for motion is slight, and the use of the limb is confined, as a rule, to the "underhand" movements. In some cases the compensatory mobility of the scapula is such that the hand can be raised to the head, and in some a degree of usefulness has been exceptionally obtained that is far in excess of what is usual. Thus, Prochaska's patient, the head of whose humerus was lodged in the chest after having passed between the second and third ribs, earned his living for many years as a woodchopper.

HABITUAL DISLOCATION.

Habitual dislocation, by which is meant a marked tendency to the reproduction of the dislocation by slight causes, such as the abduction of the arm, is not infrequent and may constitute a serious disability; it is most frequently observed after anterior dislocations, but appears to be relatively more common after the posterior ones.

This tendency has generally been attributed, though without anatomical proof, to laxity of the capsule, itself the consequence of imperfect repair of the rent made in it at the time of the dislocation, but the recent researches of Jössel¹ show, for the forward dislocation, that the enlargement of the capsule observed in such cases sometimes takes place at its upper portion in consequence of the rupture or avulsion of the tendons of the supraspinatus and infraspinatus muscles, which involves the rupture of the capsule at the same level and the creation of a free communication between its cavity and that of the subcoracoid bursa (see Chapter XXIX., p. 429). He found this condition at the autopsies of five joints which had been subject to habitual dislocation

¹ Bardenheuer: Loc. cit., p. 412.

² Jössel: Deutsche Zeitschrift für Chir., 1880, vol. xiii, p. 167.

during life and in four other specimens found in the course of an examination made with this object of all bodies received in the dissecting-room during two successive winters.

Other specimens have shown important changes in the head of the humerus and the glenoid fossa. Löbker¹ presented at the Fifteenth Congress of German Surgeons a specimen obtained, post mortem, from a case of habitual dislocation, which showed changes in the head and glenoid fossa which were thought to be the effect of the frequent recurrence, and another specimen obtained by Vogt by excision in a similar case and showing the same changes in the head of the humerus. The head in each case was normal only on its inner anterior half; the other half had lost its roundness, and showed a depression one centimetre deep and two centimetres wide, extending from top to bottom, and separated from the normal inner half by a sharp prominent border. The surface was covered throughout by cartilage, and the depression was evidently not the result of a fracture with loss of substance. The tuberosities and bicipital groove were intact; the long tendon of the biceps was torn from its insertion, and had become adherent in its groove. There were evidences of the avulsion of the muscles from the greater tuberosity. The outer portion of the glenoid fossa was normal, and separated by a sharp vertical border from the large inner portion which was angularly deflected backward. Both portions were covered with cartilage, and showed no sign of fracture. The head and fossa fitted together in such a way that the inner half of the head articulated with the inner half of the fossa, and the sharp edge of the latter occupied the depression in the former.

He refers to the fact that specimens obtained by excision by Cramer, Küster, and von Volkmann showed similar losses of substance in the head of the humerus, and attributes them to the frequent recurrence or to a persistent subluxation by which the head is made to rest against the inner border of the fossa, instead of squarely against its face.

The symptoms presented by Löbker's case during life are not given, but it does not seem possible that they could have been, at least at the last, such as are found in habitual dislocation, for that is characterized by complete restoration of form in the intervals between the recurrences, while in this case the subluxation must have been persistent.

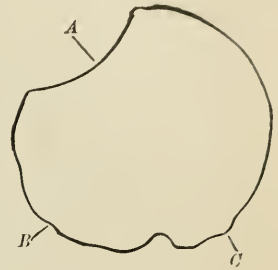
Three cases of habitual dislocation in which the head of the humerus was excised are referred to by Löbker as showing similar losses of substance in the humerus, but a reference to the original reports² shows that in all three the loss was thought to be the result of a fracture, although in the discussion on one of them (Küster's), Riedinger expressed the opinion that it was due to absorption. As the cases illustrate also the method of treatment by excision, I quote two of them briefly.

¹ Löbker: Beilage zum Centralblatt für Chir., 1886, p. 90.

² Cramer: Berlin. klin. Wochenschrift, 1882, p. 21. Volkmann; reported by Popke: Zur Kasuistik und Therapie der inveterirten und habituellen Schulterluxationen, Halle, 1882. Abstract in Centralblatt für Chir., 1883, p. 28. Küster: Beilage zum Centralblatt für Chir., 1882, p. 73.

Cramer's patient was a woman thirty years old, who dislocated her shoulder forward and inward during an epileptic fit, and again in another two months later; the arm was then immobilized for several months, and a special dressing was worn most of the time afterward, especially at the menstrual periods, when the attacks of epilepsy were most likely to occur, but nevertheless the dislocation recurred nineteen times within five years, each time during a fit; reduction was sometimes easy, sometimes quite difficult, and the patient was eager to be relieved of the annoyance and the dread. The head was excised through an anterior incision, and the patient made a good recovery. The functional result was fairly satisfactory and was still improving two years after the operation.

FIG. 299.



Horizontal section of the head of the humerus in Cramer's case of habitual dislocation. *A*, loss of substance; *B*, greater tuberosity; *C*, lesser tuberosity.

The articular surface of the head of the humerus showed a shallow loss of substance on its outer side four centimetres long, two broad, and about three-fourths of a centimetre in depth at the centre (Fig. 299), and there was found a small body of irregular shape, one centimetre in its greatest diameter, with a smooth surface, and attached by a long, thin pedicle to the posterior margin of the glenoid fossa. It was composed of bone covered by fibrous tissue with bits of cartilage between them in places, and was thought to be a fragment broken from the head.

In Volkmann's the posterior third of the head showed a smooth surface not covered by cartilage, which had been "undoubtedly" produced by the breaking off of a wedge-shaped piece. No such fragment could be found in the cavity, and it was thought to have been absorbed. The glenoid articular fossa was altered in shape, having become narrower below than above. The capsule was torn away from the inner and lower margin of the glenoid fossa, thus creating an opening which communicated with the subscapular bursa. On the thickened edge of this opening was attached, by a sort of pedicle, a piece of cartilage-covered bone "which was evidently the remains of a fragment broken from the edge of the glenoid fossa." (This, if so, would be a sufficient explanation of the recurrence.) The patient reported that the condition of his arm was much more satisfactory than before the operation.

These changes in the bones are essentially the same as those described in cases of chronic, non-suppurative inflammation, in some of which it is evident that the process originated in a dislocation. (See Gurlt, *Path. Anat. der Gelenkkrankheiten*, pp. 250-267, and especially Curling's case, p. 280, also described in the *Medico-Chirurgical Transactions*, 1837, vol. xx. p. 336, as a partial dislocation forward.) It seems not improbable that the series of observed changes may be started by an ordinary dislocation, that is, by one that is not distinguished by any exceptional lesion such as partial fracture of the head or of the edge of the glenoid cavity; this is followed by a non-suppurative arthritis

which so modifies the capsule and the shape of the surfaces that a recurrence of the dislocation is made easy. The pedunculated bodies composed of bone and cartilage, sometimes found in the joint and thought to have been broken from the head of the humerus or the edge of the glenoid fossa, may be of new formation. In three of four cases reported by Burrell and Lovett,¹ some of the muscles of the shoulder were notably atrophied. Additional information has recently been supplied by Francke,² who collected 18 cases, Hildebrand,³ who operated upon 2, and Perthes,⁴ who operated upon 4 cases. Francke thinks enlargement of the cavity and relaxation of the capsule the main factor; he found a defect in the head of the humerus in 12 of the 18 cases, and in the glenoid in 9, a rent in the capsule at the edge of the glenoid in 3, and rupture of the outward rotators or avulsion of the greater tuberosity in 5, and free or pedunculated bodies in the joint in 5.

Hildebrand found the glenoid defective and the cavity enlarged by a pouch on the inner side, and Perthes found rupture of the outward rotators in 2, simple enlargement of the cavity in 1, and wide detachment of the capsule and periosteum from the anterior edge of the glenoid and adjoining part of the scapula in 1.

The defect in the head is habitually situated at the posterior outer portion in the form of a deep sharp depression. It has been interpreted as due to the loss of a fragment, to a crush against the edge of the glenoid, and to absorption after bruising.

Hildebrand deepened the glenoid fossa so as to give it a raised inner edge and packed the adjoining pouch with gauze in order to cause its wall to retract. Perthes reattached the outward rotators to the tuberosity in 2 cases, made a tuck in the capsule (Ricard) in 1, and by an extensive operation in the fourth reattached the capsule to the glenoid margin.

The frequency of recurrence varies greatly in the different cases; in some the intervals are long, in others the dislocation is produced every time the elbow is raised, and in some the bone can be voluntarily thrown out of place by the contraction of the muscles.

Ordinarily reduction is very easy, and the patient learns to effect it himself; in others it is at times difficult.

The treatment by injections of iodine and by narrowing the capsule on the inner side has been mentioned in Chapter XXXIII., p. 454. The latter has been employed successfully by its introducer, Ricard, in two cases and by myself⁵ in two. The incision occupies the interval between the deltoid and the pectoralis with an extension from its upper end outward close to the acromion; the corresponding portion of the deltoid is detached and turned outward. In the anterior portion of the capsule thus exposed two or three sutures of stout silk are passed so as to take up a fold about three-quarters of an inch wide and running downward and outward, or a long narrow piece is excised.

¹ Burrell and Lovett: Transactions of the American Surgical Association, 1897, p. 296.

² Francke, Deutsche Zeitschrift für Chir., vol. 48, p. 399.

³ Hildebrand: Arch. für klin. Chir., vol. 66, p. 360.

⁴ Perthes: Deutsche Zeitschrift für Chir., vol. 85, p. 199.

⁵ Stimson: Annals of Surgery, March, 1898, p. 364.

Burrell¹ obtained an excellent result in two cases by excising from the anterior inner portion of the capsule a piece four centimetres long and one wide, and closing the gap with catgut sutures. For better exposure of the field of operation he divided the upper three-quarters of the tendon of the pectoralis major close to its insertion, and part of the tendon of the subscapularis.

Grothe² incised the anterior portion of the capsule and narrowed it by overlapping the sides of the incision.

Excision of the head of the humerus has been resorted to in at least nine cases; and the reported results in some of them were good. I should think the disability would have to be great to justify so radical a measure, one which may in itself be so disabling.

Yeates³ describes an apparatus which he had worn with comfort and advantage to limit the range of motion and thus prevent recurrence.

Another class of cases in which the tendency to recurrence is the result not of a primary traumatic dislocation but of pathological changes in the joint or of paralysis of the muscles will be considered in a subsequent section.

TREATMENT OF OLD DISLOCATIONS THAT CANNOT BE REDUCED BY MANIPULATION AND FORCIBLE TRACTION.⁴

The urgent desire of patients to be relieved of their disability or of the pain caused by the persistence of the displacement has led surgeons to resort with increasing frequency to cutting operations in the hope of restoring the bone to its place or improving its position, or to excise the head. Others sought to improve the position of the limb or to create a false joint by subcutaneous fracture or division with the saw. It is not always easy to determine from the histories of the cases the measure of success or improvement, for in some the report ends with the operation, and in others although the result is called a success the description leaves the reader in doubt as to the completeness of the reduction or as to the improvement in function. With our more accurate knowledge of the changes in the condition of the glenoid fossa and in its relations with the capsule that follow the prolonged absence of the head of the humerus from it, we may well doubt the completeness of any reputed reduction in old cases obtained by subcutaneous measures or feel justified in believing that the benefit attributed to the use of the tenotome was a delusion, and that the really efficient agents were the manipulation and the traction. In this criticism I do not include those tenotomies or divisions of muscles which in the earlier days took the place now filled so much more easily and safely by anæsthetics. It is addressed mainly to a method employed by Polaillon⁵

¹ Burrell: *Loc. cit.*

² Grothe: *Münc. med. Wochenschrift*, 1900, No. 19.

³ Yeates: *Lancet*, June 30, 1888.

⁴ For bibliography see Knapp, *Beiträge zur klin. Chir.*, 1888, vol. iv.; Schoch, *Ibid.*, 1901, vol. xxix.; Engel, *Arch. für klin. Chir.*, 1897, vol. lv. p. 603; Smital, *Wiener med. Wochen.*, 1890, No. 52; Gwyer, *New York Medical Journal*, March 28, 1891; Delbet, *Arch. gén. de Méd.*, 1893; Souchon, *Transactions of the American Surgical Association*, 1897; Legueu, *l'Indépendance méd.*, 1901, No. 15.

⁵ Polaillon: *Bull. de la Soc. de Chir.*, 1882, p. 129.

in 1882, and subsequently used by some and highly recommended by others on his authority.

Subcutaneous Section. Polaillon's patient had an intracoracoid dislocation, produced during an epileptic fit, that had existed for four months. An attempt to reduce with the pulleys, aided by chloroform, failed, but brought the head of the humerus near its socket and directly under the coracoid process. Eleven days later the patient was again chloroformed, a blunt-pointed tenotome introduced through a small cut made through the skin and muscle a finger-breadth below the tip of the acromion, and carried horizontally inward between the deltoid and the point of the humerus, its edge turned backward, and then withdrawn so as to divide the tissues lying upon the bone; the point of the knife was then carried through the same incision to the back of the humerus, and a similar cut made along the outer aspect of the head. Two days later the traction was renewed under chloroform, and the dislocation reduced. A week later, the bone having meanwhile shown a constant tendency to become displaced forward and inward, a tourniquet was applied about the shoulder to keep it in place. A month later the patient was able to raise his hand to his mouth and to put it behind his head, and "the movements were daily gaining in extent."

It is not so uncommon for a second or third attempt to reduce by traction to succeed after the first has failed that the success in this case can be unhesitatingly attributed to the subcutaneous division, and, furthermore, it seems doubtful whether an incision made from the outer side in this manner could divide anything that offered any serious obstacle to the return of the bone. The additional cases, in which this method was successfully employed by Polaillon, are briefly mentioned in a thesis by Bardon-Lacroze.¹

An **open arthrotomy**, by which the surgeon is enabled to see and remove the obstacles to reduction, is not only more likely to be successful than subcutaneous division, but, if carefully done when the tissues have not been lacerated and inflamed by recent forcible attempts to reduce by traction and manipulation, is also, in my opinion, not more dangerous. If the conditions prove during the operation to be unfavorable, excision of the head can be easily substituted. Souchon's statistics show 69 per cent. of the results classed as "fair," "good," and "very good" after reduction by arthrotomy. Among unfavorable conditions are to be counted fracture of the glenoid cavity or its occupation by a mass of fibrous tissue, fracture and marked displacement of the greater tuberosity, and the need of extensive dissection to return the head to its place. The effect of the latter is shown in the comparatively frequent (16 per cent., Souchon) necrosis of the head after reduction. Possibly this could be avoided by keeping the liberating incisions well away from the bone. Knapp, reviewing twelve cases of reduction by arthrotomy and twenty of excision of the head, advises reduction only in comparatively recent cases, excision in the old ones. In a number of cases the surgeon has resorted to excision after having failed to reduce by arthrotomy.

In anterior dislocations reduction by arthrotomy may be done by an

¹ Bardon-Lacroze: Des sections sous-cutanées comme moyen de réduction des luxations anciennes du coude et de Pépale. Thèse de Paris, 1882, No. 209.

anterior incision along the border of the deltoid, aided if necessary by a horizontal extension outward and detachment of the corresponding part of the deltoid from the acromion. This gives free access to the outer part of the head and capsule and permits the removal of the latter from the glenoid fossa if it has become adherent to it, an absolutely necessary step in many cases. The liberation of the head on the inner side and behind is much more difficult, and the inability properly to accomplish it appears to have been the cause of the rather frequent abandonment of the attempt and the substitution of excision.

The after-treatment requires maintenance of a position that effectually opposes recurrence and a rather early resort to very limited passive motion.

Dollinger¹ recommends an incision on the inner side of the cephalic vein from the clavicle to the insertion of the pectoralis major, deepened between the deltoid and pectoral until the coraco-brachialis and pectoralis minor are exposed; these are drawn aside, the humerus rotated outward to bring the tendon of the subscapularis into the field, and the latter divided. The head can then be easily replaced in its socket. He had employed it successfully in seven uncomplicated cases, but does not speak of the late results.

Excision of the head is almost always to be preferred when the dislocation has been complicated by fracture of either the anatomical or the surgical neck, because the resultant conditions—faulty position, increase of adhesions—greatly increase the difficulty of reduction and render the functional result poor if reduction is effected. It has been done by an axillary incision, especially in cases complicated by fracture of the anatomical neck. This method is of comparatively easy execution and may properly be used when there is no thought of attempting reduction; otherwise the anterior incision should be used.

Fracture of the surgical neck of the humerus, which has not infrequently been caused by the attempts made to reduce, has sometimes been taken advantage of to place the limb in a better position, and Desprès² recommends that it should be intentionally produced. Others have done it with the object of subsequently preventing its reunion and establishing a false joint between the upper end of the shaft and the glenoid fossa. Desprès's first operation³ was done with the object of obtaining a pseudarthrosis at the seat of fracture, but bony union took place. The usefulness of the limb was, however, so much increased by the change in its position that he repeated the operation upon another patient merely to effect this change, and was in this case also well satisfied with the result. The proposal to generalize the practice does not appear to have been received with much favor by his colleagues in the Surgical Society.

Other features of this subject have been considered in the first part of this chapter.

Dr. J. Ewing Mears⁴ divided the surgical neck subcutaneously with

¹ Dollinger: *Centralblatt für Chir.*, 1902, p. 1277.

² Desprès: *Bull. de la Soc. de Chir.*, 1879, p. 742.

³ Desprès: *Loc.cit.*, p. 22.

⁴ Mears: *Philadelphia Medical and Surgical Reporter*, 1877, vol. xxxvii. p. 287.

an Adams's saw and obtained an excellent result by pseudarthrosis. His patient was a man, thirty-nine years of age, and the dislocation was of two years' standing. The saw was entered on the outer side, and the division was easily effected in about five minutes. The case deserves to be remembered, and the method is to be preferred to fracturing as less dangerous and more precise. The establishment of a false joint would be more certainly effected by the removal of a piece of the shaft.

CONGENITAL DISLOCATIONS.

This term as commonly employed embraces all dislocations which are recognized at birth or which probably existed then, and which have no recognizable traumatic cause. They present three distinct forms: 1, one due apparently to irregular development of the joint; 2, one in which the bones are normally formed and in which the displacement may have occurred during delivery; 3, a third, also with normal bones, in which the displacement is the late result of a paralysis antedating birth or caused during delivery. While this supposed etiology is not completely established, yet the condition of the parts, the displacements, and the symptoms of each group are so distinct that the grouping is justified even if the etiology should prove to be different. There are, in addition, cases of traumatic dislocation during delivery in which the nature of the traumatism is evident and the condition is immediately recognized and corrected. Some of the paralytic forms have been described as "obstetrical paralyses" (*vide infra*). The forms that have been observed are the subcoracoid and, much more frequently, the subacromial or subspinous.

The condition is a rare one; its relative frequency is shown by Krönlain's collection of 98 congenital dislocations treated in Von Langenbeck's clinic, of which 90 were of the hip, 5 of the shoulder, 2 of the head of the radius, and 1 of the knee. I have seen five cases, all backward dislocations; four of them, possibly all, belonged in the second group above named.

In support of the theory of a pre-natal origin are the facts that the lesion is sometimes double or associated with other congenital defects, and that in one case¹ two children of the same family were similarly affected; and yet it is not impossible that both shoulders or two successive children could receive the same traumatism.

1st Group. *Irregular development.* For our knowledge of the pathological changes we are indebted to R. W. Smith.² In his case of double subcoracoid dislocation, a lunatic woman twenty-nine years old, "there existed on the left side scarcely any trace of an articulating surface in the situation which the glenoid cavity occupies in the normal state; but there had been formed upon the costal surface of the scapula a socket of a glenoid shape, measuring about an inch and a half in its vertical direction and an inch and a quarter transversely (Fig. 300). It reached upward to the under surface of the coracoid process, from which the head of the humerus was merely separated by the capsular

¹ Scudder: Archives of Pediatrics, April, 1890.

² R. W. Smith: Fractures and Dislocations, 1847.

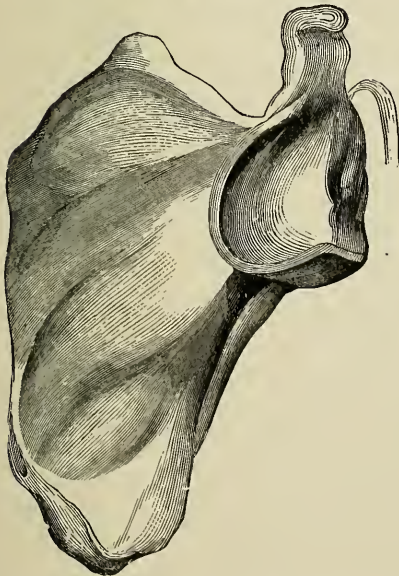
ligament." The glenoid ligament, perfect in every respect, extended all around it. The capsule was perfect.

The head of the humerus (Fig. 301) "was of an oval shape, its long axis corresponding with the shaft of the bone. The oval shape was principally due to the deficiency of its posterior part, and there existed between the greater tubercle and the margin of the head of the bone, where the investing cartilage terminated, a broad, shallow depression corresponding to the edge which separated the normal from the abnormal portion of the glenoid cavity. The shaft of the humerus was small and seemingly atrophied."

Upon the right side, although the condition of the bone was somewhat different, the characteristic features of the deformity were similar.

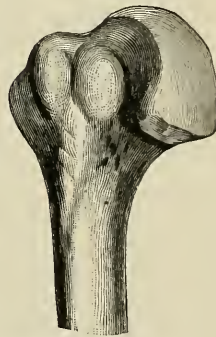
In his double subacromial case, a lunatic woman forty-two years old, "there was no trace of a glenoid cavity in the natural situation; but upon the external surface of the neck of the scapula there was a well-formed socket which received the head of the humerus. It was an inch and three-quarters in length, and an inch in breadth; it was a little broader above than below, and its summit was less than a quarter of an inch from the under surface of the acromion process. It was directed outward and forward, was covered with cartilage, and surrounded by a perfect glenoid ligament. The tendon of the biceps muscle arose from the most internal part of its superior extremity, whence it passed downward and outward very obliquely, in order

FIG. 300.



R. W. Smith's case of double congenital subcoracoid dislocation of the shoulder. Scapula of left side.

FIG. 301.



The same: left humerus.

to reach the bicipital groove of the humerus. The axillary margin of the scapula, if prolonged upward, would have passed nearly altogether internal to the abnormal socket. . . . The capsular ligament was perfect. The scapula was smaller than natural, and its muscles badly developed."

"The head of the humerus, upon the right side, was of an oval or oblong form, somewhat broader above than below; its anterior half

alone was in contact with the glenoid cavity. This portion was covered with cartilage, the remaining half being rough and scabrous, and totally destitute of articular cartilage. The inner edge of the humerus, if prolonged upward, would have passed between these two portions of the head of the bone."

"The greater tubercle was natural, but the lesser was elongated and curved, forming a most remarkable process; it was an inch in length, and bore some resemblance to the coracoid process of the scapula. At its root it presented a smooth, convex, pulley-shaped surface, round which passed the tendon of the biceps muscle." The left humerus differed from the right only in the smaller size of the lesser tuberosity. Both these cases were first seen by Smith upon the autopsy-table, and he gives no history as to the length of time the deformity had lasted. Both individuals had been for many years inmates of the lunatic asylum, and the second one was subject to epileptic convulsions, in one of which she died. It must be admitted that the appearances are not incompatible with the theory of a post-natal origin, perhaps by muscular action in an epileptic convulsion, as in Fränkel's case of double simultaneous dislocation quoted above, p. 601.

The three cases of single subcoracoid dislocation observed during life by Smith seem to have been paralytic dislocations.

2d Group. *Subacromial or subspinous, probably caused during delivery.* These appear to be much the most frequent; Gaillard, quoted by Malgaigne,¹ reported one, Küster² one of both shoulders, Scudder³ two, I have seen four, possibly five, and A. M. Phelps⁴ reported one case, and told me he had seen six others. Cumston⁵ reports one. My reasons for thinking this group probably traumatic are that the limitations of motion closely resemble those of the similar traumatic dislocation in adults, and that the bones as shown in a few operations and in the radiographs of three of my cases (Plate XLVI.) differ from the normal only in being smaller. In my four cases, Scudder's two, and Cumston's, the right arm was affected, in Gaillard's the left; and it seemed possible that as the right shoulder is in front in the great majority of births, the cause might be its pressure against the arch of the pubis. Against this, or at least limiting it, is the double dislocation in Küster's and the breech presentation in one of mine. Of four cases of head presentation delivery was instrumental in one, easy in one, difficult in two.

Küster, operating upon one, found the glenoid fossa normally placed but small, and the humerus rested on its posterior border. In a case I operated upon and in Cumston's the conditions were the same. Dr. Phelps told me he had found the fossa defective at its posterior margin, as if a piece had been broken off. Radiographs of three of my cases show an apparently normal glenoid fossa and humerus, but all the bones of the limb, in all four cases, were smaller than those of the other. My patients when examined were six, nine, nine, and eleven years old; Scudder's were seven and nine, Gaillard's sixteen, Cumston's five; five of the eight were girls.

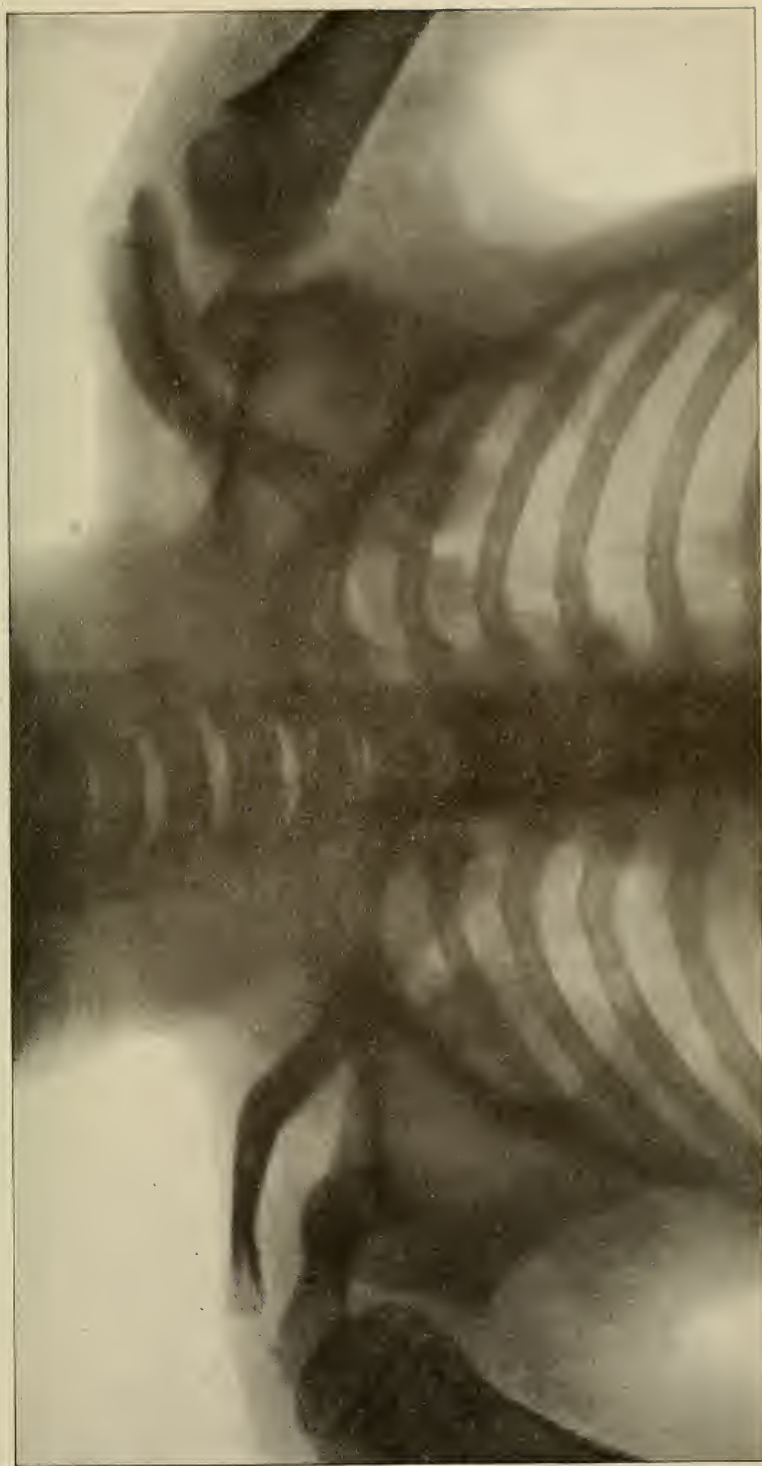
¹ Malgaigne: Loc. cit., p. 569. ² Küster: Ein Chirurg. Triennium, 1882, p. 256.

³ Scudder: Archives of Pediatrics, April, 1890.

⁴ Phelps: Transactions American Pædiatric Association, 1895.

⁵ Cumston: American Journal Medical Science, June, 1903.

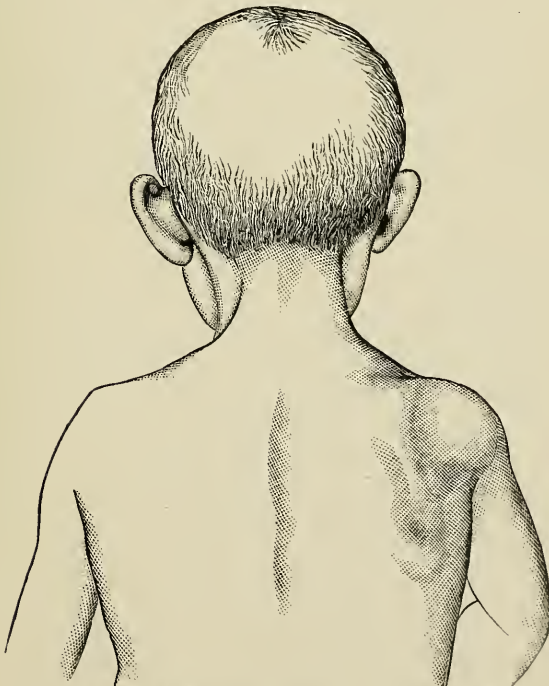PLATE XLVI.



Congenital Dislocation of Right Shoulder; view from behind.

The head of the humerus can be seen and felt beneath and behind the acromion (Fig. 302), sometimes quite close to its normal position, sometimes much further back; in Gaillard's at about an equal distance from the two ends of the spine of the scapula. The elbow is directed forward and a little outward and is markedly rotated inward. This position is noted in all and is evidently characteristic. Motion, active and passive, is limited in all directions, especially outward rotation and adduction. Scudder's and Cumston's electrical examination of the muscles showed little difference between the two sides; in one of mine the muscles supplied by the musculo-spiral and musculo-cutaneous nerves were markedly parietic, in two all were normal, and in one rotation of the forearm was weak, but its range was complete. In all my cases the condition was noticed at birth; in one the child cried whenever the limb was handled, but after two months moved it voluntarily. In my fifth (doubtful) case, seen in 1886, the delivery was instrumental and very difficult; the child, now dead, was four years old when I saw him; the attitude of the limb was similar to that above described, and all voluntary motion at the shoulder was lost; I classed it at the time as an "obstetrical paralysis."

FIG. 302.



Congenital subspinous dislocation of the shoulder.

The treatment in Gaillard's case is interesting: Four times in the course of a week he made horizontal traction on the arm by means of a weight of sixteen pounds, continued for fifteen or twenty minutes, and reinforced occasionally by traction with his hands. On the last

occasion the head moved an inch and a half along the scapula to the edge of the glenoid fossa and was then thrown into it by a movement of leverage. It almost immediately came out again. The next day it was again reduced and kept in place for an hour. Ten days later it was again reduced, and the arm fixed by a bandage; this time the reduction persisted. Two years later the limb was found to have gained half an inch in length; the patient could move it inward, outward, forward, and backward, could lace her clothes behind her back, carry a chair, feed herself, and play on a guitar.

Küster operated (excision) upon one shoulder in his double case, but the patient, who was fourteen months old, died. I operated upon one by an incision along the anterior border of the deltoid with a horizontal outward extension from its upper end and detachment of the anterior half of the deltoid from the acromion. The tendon of the subscapularis, which was tightly stretched across the glenoid fossa, was divided, and the head brought into place. The change in position made the divided deltoid too short, and it was left unsutured. The wound healed primarily, and reduction was maintained. The patient, who had been brought from a distance, passed from observation at the end of a month. In the other three cases the usefulness of the limb was such, although the attitude was awkward, that I advised against operation. Nothing was done in Scudder's cases. Cumston used a posterior incision, but did not like it.

Von Braman¹ made reduction in a child four weeks old, and by carefully maintaining it for several weeks made it permanent. In another patient 13 years old he divided the humerus below the deltoid insertion and rotated the lower fragment 90° outward; this corrected the attitude of pronation and thereby improved function. For 3d Group, paralytic, see next page.

PATHOLOGICAL DISLOCATIONS AND SUBLUXATIONS.

Subluxation or complete dislocation may be made easy by changes effected in the articular surfaces or the capsule by disease, or by paralysis of the deltoid or rotator muscles which normally aid in maintaining the close contact between the bones. The reported instances are not very numerous, and even in some of these the evidence, clinical or post mortem, has left not only the character and extent of the displacement in doubt, but also its essential cause. Such cases do duty with the different writers as supposed examples of widely different lesions, such as partial traumatic dislocations, new forms of dislocations, and chronic arthritis. Gurlt² gives to Adams (Todd's *Cyclopaedia*, article Shoulder-joint) and Canton (*London Medical Gazette*, 1848, vol. vi. p. 410, and vol. viii. p. 111) the credit of having first shown that cases described as partial dislocation by Sir Astley Cooper, Hargrave, and others were actually examples of chronic non-suppurative arthritis. In his own description of the changes effected by this disease in the quoted cases he does not always discriminate between those which were the effect of the prolonged inflammation and those which should probably be attrib-

¹ Von Braman: *Arch. für klin. Chir.*, vol. 81, part 2, p. 351.

² Gurlt: *Patholog. Anat. der Gelenkkrankheiten*, 1853, p. 250.

uted to an antecedent traumatic dislocation which originated the process such as rupture of the tendons of the supraspinatus and infraspinatus and subscapularis muscles, and the establishment of a large opening between the cavity of the joint and the subacromial bursa. A dislocation recurring after such injuries should be classed with the "habitual dislocations."

Of the three classes made by Volkmann—dislocations by distention, by destruction, and by deformity (see Chapter XXXVI.)—the second is by far the most rare, and the third apparently the most common, although the distinction between the latter and the first cannot always be determined clinically. Indeed, I know of only one recorded case in which the history clearly shows an acute non-traumatic effusion in the joint promptly followed by an abrupt appearance of the deformity with instant relief of the pain, such as has been observed at the hip and knee in the course of acute rheumatism or the eruptive fevers. The case was reported by Hannon and is quoted by Malgaigne.¹ A man forty-five years old who had previously suffered with acute rheumatism in the knee and hip, became feverish, and on the following day had an acute inflammation of the shoulder-joint. The pain increased, and on the night between the fifth and sixth days became suddenly very severe; the next morning a subcoracoid dislocation was found, and was reduced with some relief of the pain. The next day the dislocation was found to have partially recurred; it was again reduced, and the limb fixed with a bandage. Recovery followed.

Malgaigne thinks the over-distended capsule is ruptured on the inner side, and thus the dislocation made possible; the view seems insufficient to explain the easy partial recurrence. When the effusion is more slowly produced and is large the head of the humerus is separated from direct contact with the glenoid cavity by a layer of liquid, the depth of which may amount to one centimetre,² under which circumstances it is evident that a slight force would be sufficient to displace the humerus to either side and without rupture of the capsule, just as one easily produces a dislocation in a freshly dissected shoulder after making a small opening in the capsule to admit the air. This requires relaxation of the scapular muscles which normally hold the bones close together, and such relaxation would not be found when the arthritis is acute and painful.

A class of cases, of which quite a number have been reported, are sometimes described as traumatic dislocations upward, but Malgaigne's opinion that they are the result of arthritis is now generally accepted for most of them. They are characterized by the projection of the head upward and forward and rigidity of the limb. Malgaigne quotes a case to show that the displacement may be caused by carrying the arm in a sling that is too short and tight.

Most of the specimens of *dislocation by deformity* are open to the doubt whether they may not actually be nearthroses following traumatic dislocations, and this is especially true of those in which the dislocation is forward. Gurlt³ describes seventeen specimens concerning

¹ Malgaigne: Loc. cit., p. 562.

² Albert: Chirurg. und. Operat., vol. ii. p. 320.

³ Gurlt: Loc. cit., p. 274.

which this doubt exists, and I think he might well have added to them several of those which he describes as examples of chronic inflammation.

DISLOCATIONS DUE TO PARALYSIS.

This variety, rare in the adult, has been shown by the investigations of Duchenne de Boulogne¹ to be much more common in new-born children, the paralysis being due to the pressure of the forceps or to traction in delivery. In consequence of the lack of support which ensues upon the paralysis of the muscles of the shoulder, the weight of the limb causes it to sink downward, the only remaining support, that of atmospheric pressure, being presumably overcome gradually by the accumulation of liquid within the capsule. The condition of the joint then resembles that of hydrarthrosis, plus the relaxation of the muscles, and, as has been above described, any slight force is then sufficient to displace the head of the humerus to one side. Malgaigne says that when all the muscles of the shoulder are paralyzed the displacement is always downward and forward, and usually incomplete; and that when the paralysis is partial the displacement is always effected by the action of the unparalyzed muscles and is reduced by the weight of the limb; in the only cases of the latter kind of which he had knowledge, two in number, the displacement was backward. He saw in a man, thirty-four years old, a double paralytic dislocation.

In new-born children the dislocation is said to be always backward, subacromial. Duchenne saw in ten years eight cases of this kind. In all the cases of obstetrical paralysis which he had seen the same group of muscles was affected, namely, the deltoid, infraspinatus, biceps, and brachialis anticus; in some there was also paralysis of the muscles in the forearm and hand supplied by the musculo-spiral or ulnar nerve. I have seen paralysis of the same muscles (the deltoid, biceps, and brachialis anticus) appear spontaneously at the age of one year, with consequent laxity of the joint that permitted dislocation forward and backward. When the paralysis is caused by the application of the forceps the mechanism appears to be the pressure of the edge of the instrument upon the brachial plexus on the side of the neck; in other cases it is the pressure of the finger used as a hook in the axilla or to bring down the arm when raised beside the head.

In one of Duchenne's cases, treated by Chassaignac, a permanent cure was obtained by a fixation dressing, worn for five or six weeks.

Occasionally the disability of the muscles is due to a traumatism (myopathic dislocation). In a case reported by Wolff,² in which the head of the humerus had sunk almost three centimetres below the acromion, and the disability was very great, the functions of the limb were much improved by an operation; the joint was opened posteriorly along the margin of the glenoid fossa, the articular cartilage removed, and the bones fastened together with strong silver wire. The control over the limb thus obtained through the scapula was such that it could be raised and lowered and even a little adducted and abducted.

¹ Duchenne de Boulogne: *De l'Electrisation localisée*, 1871, 2d ed.; and Panas: *Dict. de Méd. et Chir. pratiques*, art. *Epaule*, p. 514.

² Wolff: *Berl. klin. Wochenschrift*, 1886, No. 52. Abstract in *Centralblatt für Chir.*, 1887, p. 637.

CHAPTER XLV.

DISLOCATIONS OF THE ELBOW.

Anatomy—Classification—Dislocations of Both Bones: Backward, lateral, forward, divergent.

Anatomy.

ON either side of the lower end of the humerus is a prominence, the epicondyle, which can be easily felt, and is of great importance in the recognition of any change in the relations of the bones that constitute the elbow-joint. The inner one, commonly called the epitrochlea, is more prominent and well-defined than the outer one, and its upper margin joins the shaft of the humerus by a sharp curve, while on the outer side of the shaft the supinator ridge connects the side of the shaft with the epicondyle by a gradual slope. Below the epitrochlea is the flattened side of the trochlea, projecting downward and forward about half an inch, with a sharp, well-defined margin which is masked by the ulna when the bones are in place. From this edge the articular surface of the trochlea passes outward like a cone, its diameter becoming rapidly smaller for about half an inch, and then enlarges again, but less abruptly, for nearly an equal distance. Above it, posteriorly, is a deep depression, the olecranon fossa, into which the tip of the olecranon is received in full extension of the joint, and above it, anteriorly, is a corresponding, smaller one, to receive the tip of the coronoid process in full flexion. On the outer side of the anterior and lower part of the trochlea, and separated from it by a shallow vertical groove, is the capitellum, or radial head, of the humerus with which the head of the radius articulates, a rounded prominence looking directly forward.

The ulna articulates with the trochlea by its greater sigmoid cavity, which has a central longitudinal ridge fitting into the central depression of the trochlea, and opposing displacement to either side.

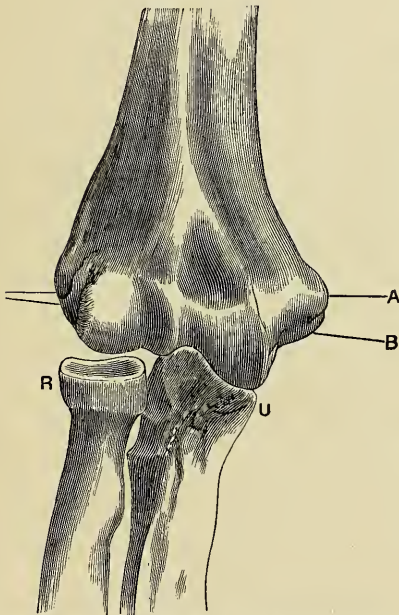
The radius articulates with the capitellum by the slightly concave, circular upper surface of its cylindrical head and with the lesser sigmoid cavity on the outer side of the ulna and coracoid process by the side of its head. This articular surface on the side of the head is about three-eighths of an inch long (from above downward) on the inner and posterior side of the bone, the part that is in contact with the ulna in supination, but is shorter on the outer side at the part which comes in contact with the ulna in pronation.

The long axis of the trochlear cones and the ovoid capitellum coincide with one another and represent the axis of the joint for flexion and extension; this line crosses the lower end of the humerus from a point just below and in front of the external epicondyle to one that is

just covered by the lower part of the epitrochlea, and is inclined downward and inward from the transverse axis of the lower end of the humerus, so that the long axis of the forearm does not coincide with that of the arm, but deviates to the outer side as it passes downward.

When the bones are in place and the forearm fully extended the uppermost part of the olecranon, the "point of the elbow," lies on or close below a transverse line drawn behind the limb from the epitrochlea to the epicondyle; and when the elbow is flexed at a right angle the same point lies a little more than an inch directly below and nearly midway between these two prominences in the prolongation of the long axis of the shaft of the humerus. Ordinarily the relations of these three points to one another can be readily determined, even when the region is swollen, and they are the most convenient and

FIG. 303.



The bones of the elbow: B, the axis of motion.
(TILLAUX.)

below with the orbicular ligament that surrounds the head of the radius, some of its posterior fibres being continued to the ulna.

The anterior and posterior ligaments are thin and loose, and close in the joint between the lateral ligaments in front and behind, respectively.

The orbicular, or annular, ligament, placed like a ring about the head of the radius and the adjoining portion of its neck, occupies three-fourths of a circle of which the remaining fourth is formed by the lesser sigmoid cavity of the ulna; it is thus attached by its two ends to the ulna and encircles the head of the radius. It is reinforced externally and posteriorly by the fibres of the external lateral ligament. The synovial sac extends beyond its lower border for a short distance

trustworthy aid in the recognition of the existence of a dislocation of the ulna.

The outer border of the head of the radius can be felt about three-quarters of an inch below the epicondyle in a line drawn from the latter to the wrist, and it can be felt to move when the hand is gently rotated. This is the only point where the interarticular line is distinctly accessible to palpation; at all other points it is too thickly covered by soft parts or masked by the parallelism and close contact of adjoining surfaces.

The internal lateral ligament arises above from the anterior, lower, and posterior portion of the epitrochlea and is broadly inserted below along the inner margin of the greater sigmoid cavity.

The external lateral ligament, shorter and narrower than the internal, arises above just below the epicondyle and becomes blended

along the neck of the radius, and is then reflected upward and attached to this bone.

The ulnar nerve passes close behind the joint on the inner side between the olecranon and epitrochlea in close relations with the capsule and lateral ligament.

Frequency.

In order of frequency the dislocations of the elbow come next after those of the shoulder and fingers (Chapter XXVII.).

Krönlein's 109 cases arranged according to age, sex, and variety are as follows :

TABLE OF 109 DISLOCATIONS OF THE ELBOW (KRONLEIN).

Variety.	Sex.		Age.							
	M.	F.	1-10	11-20	21-30	31-40	41-50	51-60	61-70	71-80
Forearm, backward	77	17	22	44	14	5	4	3	1	1
Radius, alone	9	6	9	5	1					

This shows the same preponderance in males over females, 4 to 1, that is shown by dislocations in general, and that the great majority, 80 out of 109, occur during the first twenty-four years of life. Attention was called in Chapter XLII. to the difference in respect of age between dislocations of the elbow and those of the shoulder, the latter being rare at the age when the former are common, and most frequent in middle life ; and Krönlein's opinion was there quoted that fractures of the clavicle are in childhood the equivalent injury—that is, are produced by the same cause—of dislocations of the shoulder by direct violence in middle life, and that dislocations of the elbow are the equivalent injury of dislocations of the shoulder by indirect violence. Another possible explanation of the frequency in childhood is, I think, the hyperextension of the joint which is marked at that age and is usually wholly lost in adult life, at least in males.

Classification.

The different forms of dislocation of the elbow are numerous, for the two bones of the forearm may be displaced together in any one of the four principal directions, or each may take a different direction, or either may be dislocated while the other remains in place. The number of named forms has been still further increased by making in some a distinction between "complete" and "incomplete" which not only is not justified by any corresponding important pathological or clinical difference, but which also does not even correspond with the definition of "incomplete" given by those who make most use of the term.

Many of the varieties are closely allied to one another, and produced by causes that differ very slightly. Thus, if the joint is hyperextended, the ligaments torn, and a backward dislocation of both bones begun,

the final position taken will vary with the direction in which the force continues to act, and with the addition to it of lateral flexion of the joint or rotation of the forearm, so that forms as widely different in appearance as direct backward dislocation, lateral dislocation, and divergent dislocation may be produced. It will be proper, therefore, as well as convenient, to describe under the more common type, backward dislocation of both bones, much that concerns many of the other forms, and to limit the descriptions of the latter mainly to the points of difference.

The classification which will be here followed is the same in its principal features as those adopted by most recent writers. The differences are in the grouping and recognition of the varieties.

Dislocations of the forearm on the arm,	{	1. Dislocations backward, backward and outward. backward and inward.
		2. Lateral dislocations, incomplete { inward. outward. complete outward.
		3. Forward dislocations, incomplete, or 1st degree. complete, or 2d degree. with fracture of the olecranon.
		4. Divergent dislocations, antero-posterior. transverse.
Dislocations of the ulna alone,	{	1, 2. Backward and upward, { 1. Incomplete, or 1st degree. 2. Complete, or 2d degree.
		3. Backward and outward, behind radius.
		4. Forward.
Dislocations of the radius alone.	{	1. Backward.
		2. Outward.
		3. Forward.
		4. By elongation, or the subluxation of children.
		5. Associated with fracture of the ulna.

Congenital and pathological dislocations.

DISLOCATION OF THE FOREARM BACKWARD.

This is the most common of all dislocations of the elbow. It is habitually produced by a fall, but although the examples are so numerous the mechanism or mode of production has been the subject of much controversy, largely due to the resort to hypotheses which was stimulated by the lack of definite knowledge. Few who fall are able to describe the circumstances of the fall, to say whether the arm was fully extended or partly flexed, whether the violence was received upon the hand or upon the elbow, and a preconceived theory in the mind of the surgeon is a great help to the discovery of facts that favor it.

The theory of production by *forced flexion* is supported, so far as I know, by only one case, and that a case that has only recently been reported. Stetter¹ had a patient who, while working in a mine, was caught under a falling stone in such a way that his left elbow was

¹ Stetter: Compendium der Lehre von den Luxationen, 1886, p. 43.

forcibly flexed between the stone and the wall and was dislocated backward. When seen, about an hour afterward, the joint was in the position of extension. Reduction was easily effected by traction, and recovery took place without incident. Fracture of the coronoid process could not be recognized.

The theory of *direct displacement* backward ("glissement") formulated by Boyer, and at one time widely held, has not withstood the criticism of later writers and is no longer accepted in explanation of dislocations caused by falls. A case reported by Weber nearly fifty years ago, and much quoted since, is an example of production in this manner, but not in a fall: a young man, wishing to show his strength, held his arm extended while another tried to bend it; the latter not succeeding, struck the front of the upper part of the forearm violently with his fist, at the same time pressing the wrist forward, and caused a dislocation which could not be reduced. In like manner, the dislocation can be produced by a blow upon the back of the arm just above the elbow, as in a case quoted by Malgaigne from Flaubert, in which the patient's arm was caught under an overturned wagon, and in another seen by Hamilton. A similar mechanism has also been observed in outward dislocation.

The theory of *torsion* presented by Malgaigne, according to which the patient in his fall strikes upon the inner side of the slightly flexed forearm and the elbow, the limb being somewhat abducted, is perhaps true of some cases. Malgaigne's explanation is very brief; he simply says the dislocation is effected by "a movement of torsion which brings the coronoid process successively inward, downward, and backward." However obscure the explanation may be, and it suggests an origin in speculation rather than in observation, the fact remains that in a few well-authenticated cases the violence has certainly been received upon the upper and inner part of the forearm and not upon the palm of the hand. Pingaud¹ quotes three such: a rider falling with his horse and dislocating his elbow while the hand still held the bridle; a man falling in the gymnasium with his forearm bent behind his back; another falling backward and rolling upon his side while his hand held his cloak together in front of his chest.

Hyperextension and Abduction. It is now generally believed that the injury is habitually caused by a fall upon the palm of the outstretched hand, the elbow being in complete extension, and that the primary rupture of the ligaments which makes the dislocation possible is effected by hyperextension of the joint. That this was a possible cause was known to Petit, who had seen a compound dislocation thus produced; and Desault and Bichat, anticipating in this, as in so many other things, the slower judgment of the profession, declared it to be the common mechanism, but the investigations which first satisfactorily demonstrated it were made by a young German surgeon in 1844, Roser.² His results were quoted and his experiments repeated and extended to other than backward dislocations by Streubel,³ and to these

¹ Pingaud: Dict. Encyclop. des Sc. Méd., art. Coude, p. 496.

² Roser: Arch. für physiolog. Heilkunde, 1844, Heft 2, p. 185.

³ Streubel: Prager Vierteljahrsschrift, 1850, vol. i. p. 1.

two papers and the articles by Denucé¹ and Pingaud, above mentioned, the reader is referred for details to which space cannot here be given.

Experiment upon the cadaver shows that when this action, of a fall upon the outstretched hand, is imitated, the hand being supinated, the anterior portion of the internal lateral ligament becomes tense and then yields, usually at its upper insertion; then, as the movement is continued, the rupture extends along the anterior ligament, perhaps involving part of the brachialis anticus, the elbow bends inward, and if pressure is made downward upon the head of the humerus this bone passes down in front of the coronoid process and radius, and a backward dislocation is produced.

In whatever direction the force may act it is evident that its first effect must be to rupture one or both of the lateral ligaments, for they are the ones which hold the bones together and they oppose not only lateral motion but also hyperextension. According as one or the other of these is first, or alone, torn, and according to the direction of the force, the details of the position in which the bones come to rest will vary and the displacement will be directly backward or to either side or with more or less abduction or adduction of the forearm.

The frequency with which the tip, or more, of the internal epicondyle is broken off and the flexors of the hand detached from it and the adjoining bone, and with which the external lateral ligament remains continuous with the periosteum stripped up from the back of the external condyle, convinces me that forcible abduction of the forearm, during either extension or partial flexion of the elbow, is the first step in the production of the injury in a large number of cases; this breaks the internal lateral ligament and frees the ulna, and then the bones slip past each other, the external lateral ligament being torn or detached in the movement, and the head of the radius tearing off the corresponding portion of the capsule and adjoining periosteum as it slips up behind the condyle.

The cases in which the coronoid process and the portion of the head of the radius which is anterior at the moment are broken off show that in them the direct impulsion of the bones past each other was effected by great violence acting along the axis of the forearm before these two parts had entirely cleared the lower surface of the humerus.

In one case that came under my observation the dislocation was effected by hyperextension and torsion without the aid of the weight of the body to press the humerus downward. The patient, in jumping down from his wagon, steadied himself by grasping the rail of the seat, and, the height being considerable, the wrench was sufficient to dislocate the elbow.

Pathology. The internal lateral ligament is always torn, usually at its insertion upon the humerus, and the rent extends along the anterior ligament. The external lateral ligament is usually torn or detached from the humerus; its partial preservation in some cases notably affects the attitude of the limb and may create considerable difficulty in reduction. The orbicular ligament is rarely injured.

¹ Denucé: Dict. de Méd. et Chir. prat., art. Coude.

The tip of the internal epicondyle is frequently torn off, apparently by avulsion through the attached flexor muscles; when the fragment is large it remains attached to the internal lateral ligament and is displaced upward and backward.

The flexor muscles of the hand are sometimes quite freely torn from the humerus, the brachialis anticus is sometimes lacerated and in extreme displacements torn across; the tendon of the biceps occasionally slips around the outer side of the external condyle. In the only case in which I have seen all these extensive lesions the end of the humerus was stripped of all its muscles and had passed through the fascia and lay under the skin in the fold of the elbow, but the patient had been subjected to three attempts by different surgeons to reduce under ether, and the lacerations may have been in part due to those attempts.

The capsule at the back of the external condyle is torn off by the edge of the head of the radius and seems frequently to maintain its continuity with the adjoining periosteum, which latter is stripped up for some distance and caps the head of the radius in its new position. This stripping up of the periosteum and its effect in producing new bone if the dislocation remains unreduced, which I pointed out in the first edition, I have repeatedly observed since. (See Chapter XLVII.)

The displacement of the bone varies greatly, both in extent and in direction. The top of the coronoid process may rest against the lower and posterior surface of the trochlea, and the radius still remain in contact with the under surface of the capitellum by the anterior portion of its disk, or the latter may be entirely dislocated and rest against the posterior face of the external condyle.

When the ulna is more and the radius less displaced the deviation of the wrist is to the inner side; and when both bones are completely displaced backward deviation of the wrist to either side will incline their upper ends to the opposite side, and thus bring them nearer to the internal or the external epicondyle respectively.

If, in the production of the dislocation, the lateral outward flexion is more marked than the hyperextension, the capitellum slips along the head of the radius to its inner side, and the latter lodges on the outer surface of the former just below the epicondyle, while the coronoid process rests against the posterior surface of the external condyle, having been carried outward by pronation of the forearm. The long axis of the forearm is deviated to the inner or the outer side; the internal lateral ligament is freely torn. This is the dislocation *backward and outward*, classed by some with the outward, by others with the backward dislocations, and sometimes misleadingly reported as a pure outward dislocation.

Complications. Fractures of the olecranon, the coronoid process, the head, shaft, and lower extremity of the radius, and the epitrochlea have been observed in connection with dislocation backward. *Fracture of the olecranon* is effected, presumably, by the pressure of its tip against the back of the humerus when the posterior part of the lateral ligament proves stronger than the bone, and a fracture is produced with angular deformity and crushing of the posterior portion of the bone

at the seat of fracture. In a case reported by W. H. Daly¹ of fracture of the olecranon, and probably of the coronoid process also, the coexistence of a Colles's fracture at the wrist indicated that the injury was produced by a fall upon the extended hand.

Fracture of the coronoid process is probably produced when the momentum of the fall forces the humerus downward before the hyper-extension has quite carried the tip of the process past the trochlea; and Lotzbeck's experiments indicate that it can also be caused, when the elbow is slightly flexed, by the direct impulsion of the lower end of the humerus in a direction parallel to that of the long axis of the forearm. As the brachialis anticus is attached, not to the tip of the process, but to its anterior face and the adjoining surface of the ulna, the displacement of the fragment is usually slight.

Partial fracture of the head of the radius has been observed in a number of cases, often associated with fracture of the coronoid process. It has been described in Chapter XX. The portion broken off is the anterior or inner third, and the fracture is effected by the direct pressure of the condyle brought to bear upon the periphery of the disk by the displacement backward of the latter.

One case of fracture of the *shaft of the radius* and three of fracture of its *lower end*, Colles's fracture, complicating backward dislocation of the elbow, are reported in a thesis by Dupuy.²

The dislocation may be made *compound* by the projection of the trochlea through the skin in the fold of the elbow, and the brachial artery, and perhaps even the median nerve, may be ruptured. In a case reported by Ledderhose,³ in which the dislocation was made compound by a transverse wound in the fold of the elbow, the musculo-spiral nerve was torn. Five months later the nerve was successfully reunited by suture.

In another, reported by Ferret,⁴ the median nerve, exposed for more than three inches in the wound and tightly stretched, sloughed.

Symptoms. The elbow is usually flexed at an angle about midway between complete extension and flexion at a right angle, but it may be completely extended, or even hyperextended, as in a case reported by Morel-Lavallée.⁵ The limb is shortened, and if viewed from behind the shortening appears to be in the arm, because of the elevation of the olecranon, but if viewed from in front in the forearm. If a few hours have passed since the injury was received, the region of the elbow is occupied by a swelling which may be so great as completely to mask the bony points and the characteristic changes in outline; but if this swelling is slight or absent the antero-posterior diameter of the joint appears increased, and the transverse diameter unchanged. The lower part of the triceps curves backward in the median line to the end of the olecranon, creating a hollow on either side, in the outer one of which may be seen a slight elevation marking the position of the head of the radius.

¹ Daly: Philadelphia Medical and Surgical Reporter, 1880, vol. xliii. p. 71.

² Dupuy: Thèse de Paris, 1882, No. 151.

³ Ledderhose: Deutsche Zeitschrift für Chirurgie, vol. xxv. p. 238, abstract in Centralblatt für Chirurgie, 1887, p. 732.

⁴ Ferret: Progrès Médical, May 7, 1887.

⁵ Morel-Lavallée: Bull. de la Soc. de Chir., 1856, vol. vii. p. 9.

The front of the joint appears full, and the forearm just below it is broadened by the shortening of the muscles that arise from either condyle. Sometimes the outline of the trochlea can be distinctly felt or even seen, but ordinarily it is masked by the overlying muscles.

The forearm may take any attitude between pronation and supination, for, as voluntary rotation is possible, the patient places it in the most convenient attitude. The axis of the forearm may be deviated to either side (Fig. 304).

Flexion and extension are possible within variable, but always narrow, limits and painful; and when flexion is made the prominence of the olecranon behind the joint is increased. Abnormal lateral mobility of the joint exists.

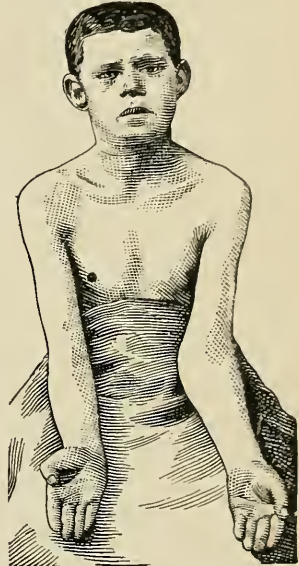
If now the positions of the two epicondyles and the tuberosity of the olecranon can be recognized, it will be seen that the latter is displaced backward and upward, rising, if the limb is extended, above the horizontal line joining the epicondyles, or projecting far behind a frontal plane passing through these two points if the limb is partly flexed. This backward projection of the olecranon will be increased by flexion of the elbow, and at the same time it will descend; while by extension it will be moved to a higher level and brought nearer the back of the humerus.

The head of the radius can be felt, perhaps even seen, under the skin below and to the outer side of the olecranon close behind the external condyle, and can be recognized by the concavity of its upper surface and felt to move under the finger when the wrist is gently rotated.

On the inner side, if the swelling is not too great, the finger passing forward and downward from the tip of the olecranon successively recognizes the curved inner margin of the great sigmoid cavity, possibly also the coronoid process and the back of the trochlea, and then moving around the inner side below the epitrochlea to the front may trace the sharp circular margin of the trochlea and recognize its rounded surface and groove in front.

Diagnosis. The diagnosis should be made upon actual recognition by palpation of the position of the two epicondyles, the olecranon, and the head of the radius. The surgeon should never be satisfied with less than that, and if it cannot be obtained he should refuse to make a positive diagnosis. No attitude of the limb, no measurements, no apparent changes in its diameter, no considerations of abnormal mobility or fixation are sufficient, and the surgeon who trusts to them will be only too likely to add to the already too long series of limbs crippled in consequence of errors in diagnosis.

FIG. 304.



Dislocation of the elbow backward.

Of the different fractures that have been mentioned as complications, those of the olecranon and epitrochlea are easily recognized by manipulation; that of the coronoid process is indicated by easy recurrence of the dislocation after its reduction, but if the patient is etherized at the time this symptom is by no means characteristic, and, furthermore, it is also present in those fractures of the internal condyle which are complicated by displacement of the fragment and dislocation of the radius backward. Fracture of the head of the radius can hardly be recognized unless the fragment should be so displaced that it can be felt on the outer side of the condyle.

The records of discussions over cases presented to the various learned societies show very clearly the difficulty of making a diagnosis in cases that have remained unreduced for any length of time, especially in children in whom the injured or stripped-up periosteum rapidly forms new bone which obscures the original outlines. Much of the uncertainty concerning the character and results of reported cases is due to this fact.

Prognosis. The prognosis is favorable; reduction in recent cases may be confidently expected, with complete or almost complete restoration of function. In old cases, of more than six weeks' standing, the probability of reduction is greatly diminished, although successes have been reported after three, five, and even seven months. The greater the displacement upward, the arm being only slightly flexed, the less is the probability of reduction after the lapse of some time, for the lacerated lateral ligaments have then formed new attachments at points so high on the humerus that they must be again ruptured before the ulna and radius can be brought below the end of the humerus, and in attempting to rupture them by flexing the elbow the olecranon or trochlea may be broken. In addition, the sigmoid cavity fills up with fibrous tissue which obliterates its articular surface and binds it to the back of the humerus. Furthermore, as the injury is most frequent in the young, whose periosteum is active to produce bone when irritated or stripped up, obstacles may thus be created which cannot be overcome except by arthrotomy. In some cases of unreduced dislocation the patients have in time obtained a free range of motion and a useful limb, but usually the mobility is very slight. In a discussion upon the subject in the *Société de Chirurgie (Bulletins, 1861, p. 103)*, it was stated as the experience of several of the members that, in the older cases at least, it was not uncommon to fail to make a complete reduction of the radius, but that nevertheless the patients recovered full use of the joint. Recurrence of the dislocation of the radius alone has also been observed.¹

Even after an early reduction the mobility may be diminished by the results of the arthritis, especially in the old and rheumatic, or by new formations of bone about the joint which mechanically limit its range of motion, or, very exceptionally, by an ossifying myositis of the brachialis anticus.²

Compound dislocations usually do well if kept surgically clean and well drained, and the limb suspended; primary resection, in the absence of special indications, should not be done.

¹ Mason: *New York Medical Record*, 1880, vol. xix. p. 398.

² Mysz: *Deutsche Zeitschrift für Chir.*, 1899, vol. liv. p. 207; Sudeck: *Beilage zum Centralblatt für Chir.*, 1901, p. 137.

Treatment. Much less attention has been paid in the treatment of dislocations backward of the elbow to the obstacles created by the untorn ligaments than in those of the shoulder or hip, and methods are in general and successful use that are directly opposed in character to those based upon a consideration of such obstacles and upon the principle that a dislocated bone should be returned along the route by which it has been displaced. The explanation of this success of faulty methods is to be found either in an extensive primary laceration of both lateral ligaments or in the possible overcoming of the obstacles by increasing the laceration. The easy reduction of most dislocations under ether by direct pressure in suitable directions upon the projecting ends of the bones is an indication that ligamentous obstacles of importance do not exist and that the chief opposition is furnished by the muscles spasmodically contracted on all sides of the joint, and the inference is too often drawn that, provided this opposition is overcome by force or by anæsthesia, the surgeon need not particularly concern himself with the attitude of the limb during his efforts to reduce. But the success of a faulty method should not make us unmindful of its defects; our work should be done skilfully, as well as successfully, and even if our errors will pass undetected and their consequences be promptly repaired, we should not lightly commit them.

Such a generally successful but faulty method is that in which the forearm is flexed as nearly as possible to a right angle, drawn directly away from the humerus in the direction of the long axis of the latter until the tip of the coronoid process is brought below the trochlea, and then, the traction being relaxed, is moved forward and upward into place. Many different methods of effecting this manœuvre have been employed, the one commonly known as Sir Astley Cooper's, although practised in exactly the same manner long before his time, in which the surgeon's knee is placed in the bend of the elbow, being the most common. Cooper's description of it is as follows:¹ "The patient is made to sit down upon a chair, and the surgeon, placing his knee on the inner side of the elbow-joint, in the bend of the arm, takes hold of the patient's wrist, and bends the arm. At the same time he presses on the radius and ulna with his knee, so as to separate them from the os humeri, and thus the coronoid process is thrown from the posterior fossa of the humerus; and whilst this pressure is supported by the knee the arm is to be forcibly but slowly bent, and the reduction is soon effected. It may also be accomplished by placing the arm around the post of a bed, and by forcibly bending it while it is thus confined."

The knee is thus used as the fulcrum of a lever of which the wrist is at the end of the long arm, and the olecranon at that of the short one. The resistance to be overcome is that of the muscles and of the soft parts which bind the ulna and radius to the humerus, and it must be overcome to an extent that will allow the ulna to be directly separated from the lower border of the humerus to a distance equal to the height of the coronoid process, more than half an inch; the lateral ligaments, the upper fibres of the anconæus, and the stout fascia on the outer side of the elbow, must all yield to this extent. That they com-

¹ Cooper: *Loc. cit.*, p. 382.

monly do so is a proof of the amount of the laceration and of the force employed. The method is faulty because it requires for its accomplishment a maximum of laceration on both sides of the joint which may have, and probably has, been escaped in the original injury, and because it requires the simultaneous elongation of the muscles of the front and back of the arm. Possibly forcible pronation of the upper part of the forearm, facilitated by the rupture of the internal lateral ligament, would make it easier thus to disengage the coronoid process and avoid additional laceration on the outer side.

The specific objection made to this method applies equally to all in which reduction is made while the elbow is flexed at a right angle, and in a less degree to those in which the joint is partly flexed. In the latter the modes of application of the force are numerous and varied: traction by pulleys, by the hand, or by a loop placed above the olecranon, and pressure by the thumbs upon the olecranon and head of the radius while the fingers are interlocked in front of the lower end of the humerus. The more extended the limb the more easily will methods of this kind succeed, but they need to be supplemented by flexion or direct coaptation after the coronoid process has been brought sufficiently low.

A possible obstacle in the way of traction in the extended or slightly flexed position is the engagement of the tip of the coronoid process in the olecranon fossa of the humerus in such a way that its under surface rests directly against the upper posterior portion of the trochlea and prevents the ulna from moving bodily in the direction of its long axis. It can be disengaged by pronating the upper part of the forearm, hyperextending the elbow, or pressing the upper part of the forearm backward and the lower part of the arm forward. Except for this possible obstacle traction in complete extension meets the indications sufficiently and without needless increase of the laceration, and the obstacle can be readily overcome, as has just been said, by slight hyperextension as suggested by Roser in 1844.

Traction may be made by the hands of the surgeon himself, or by assistants while the surgeon watches the descent of the ulna, frees the coronoid process if necessary, and presses the radius and ulna forward into place at the proper time; or it may be made by an India-rubber cord or by fastening a weight to the wrist and allowing the arm to hang down.

This method, traction upon the fully extended or even hyperextended forearm, followed by direct pressure forward on the upper ends of the ulna and radius and counter-pressure backward on the lower end of the humerus, or simply by flexion, corresponds as nearly to the fundamental principle of reduction as is practicable in the usual uncertainty as to the exact attitude taken by the limb at the moment of dislocation.

In all cases of doubt or difficulty anæsthesia should be used; and, as a general rule, whenever a lateral displacement is associated with the backward one the bones should be pressed sideways into line before they are drawn downward.

When the lateral element of the displacement is very marked and it is probable that the primary dislocation was directly outward and has been followed by a consecutive displacement backward, anæsthesia

should not be omitted, and after full relaxation has been obtained the first attempt should be to move the olecranon and head of the radius to the radial side of the humerus and transform the dislocation into a pure outward one. By so doing the principle of replacing the bones by the route along which they have been displaced is followed, and the risk of engaging the tendon of the biceps behind the external condyle is avoided. (See also the following section.) If the attempt, cautiously made, does not succeed, the surgeon should next seek to change the displacement into a pure backward one and reduce as before described.

If some time has elapsed since the accident, more than ten or fifteen days, it may be desirable to break up such adhesions as have formed by flexion, extension, and lateral flexion, but it must be borne in mind that forced flexion always carries the risk of fracturing the olecranon. This is sometimes intentionally done to facilitate reduction in old cases; it is of course followed by more or less loss of the power of active extension. The trochlea also has been thus broken.

Fracture of the coronoid process requires no special treatment; apparently the fragment is seldom, if ever, much displaced, for it retains its connection with the capsule and, after reduction, is steadied between the lower end of the humerus and the tendon of the brachialis anticus. The special indication arising from it is to guard against a recurrence of the dislocation, which is best done by keeping the elbow flexed at or even within a right angle. A posterior moulded splint is an additional safeguard.

Fracture of the olecranon requires the special treatment proper to that injury, but as the extended position of the joint, which is most favorable for the prompt and close repair of the fracture, exposes to a partial or even complete recurrence of the dislocation, it must be avoided until after the rupture of the lateral ligaments has been in great part repaired. If, in the flexed position, the olecranon is separated from the ulna it should be drawn down and held in contact by adhesive plaster, or the fracture should be exposed and the fragments sutured.

Fracture of the head of the radius requires prolonged rest of the joint, with a view to reunion if the fragment remains in place; if displaced and readily accessible the fragment should be removed. If the fragment should remain on the inner side of the joint, between the radius and ulna, it would be most easily reached through an anterior incision, in making which, however, special care would have to be taken to avoid injury to the musculo-spiral nerve and its two branches, the radial and posterior interosseous. In one case I operated a month after the accident, because of stiffness of the joint, and found a small piece of the head displaced to the front of the neck and united there. I removed it and all adhesions and covered the raw surfaces with silver foil in the hope of preventing fresh adhesion. Two-thirds of the rotation was preserved.

Fracture of the epitrochlea requires that the muscles of the forearm that arise from this prominence should be kept relaxed.

If the dislocation is compound, but without laceration of the soft parts so extensive as to make amputation unavoidable, the parts must be thoroughly cleansed and replaced, efficient drainage provided through

the wound or through counter-openings, and the limb immobilized in a plaster splint and suspended. Some, perhaps extensive, suppuration is probable in the soft parts, but the joint is likely to escape so far as to preserve a fair amount of motion. Even if the brachial artery is torn the limb may still be saved; and although the additional complication of rupture of the median nerve has been thought to make amputation necessary, I think a different view would now be taken and the attempt would be made to reunite its ends. Fortunately both complications, especially the latter, are very rare.

After-treatment. In uncomplicated cases it is necessary only to retain the limb in a sling for two or three weeks, or until such time as the dependent position does not cause pain. Passive motion, to prevent ankylosis, is not necessary, and is actually harmful during the first fortnight if it causes pain. The limb may safely be immobilized until the injury to the capsule and ligaments shall have been repaired. It will be more or less stiff when first taken out of the dressings, but complete restoration of its functions may be confidently expected under daily use. Exceptions to this complete recovery are sometimes found in the old and rheumatic, in complicated cases, and in the young if the periosteum has been extensively stripped up. In the first class, the old and rheumatic, gentle passive motion strictly confined within the limits beyond which persistent pain and tenderness are caused, may be of service to diminish the subsequent stiffness and hasten its disappearance, and in all it may be useful to change every day or two the angle at which the limb is immobilized.

LATERAL DISLOCATIONS OF THE FOREARM.

Both bones of the forearm may be together dislocated to the inner or to the outer side, and the dislocation may be complete or incomplete. In the incomplete form, in the sense in which the term has been generally, and will here be, used, one of the two bones still remains below or in front of the lower end of the humerus, although it may have entirely left its own corresponding articular surface; thus, in the incomplete outward dislocation the sigmoid cavity of the ulna lies below and embraces the external condyle, and its inner slope may still correspond to the outer part of the trochlea or may have passed entirely to its outer side. In the complete outward dislocation, on the other hand, the sigmoid cavity of the ulna is turned toward (pronation) and embraces the outer side of the external condyle or the supinator ridge, and the head of the radius lies nearer the median line in front of the humerus. Much confusion has arisen from the use of the terms outward and inward dislocation to include also the outward and backward and the inward and backward respectively, both in text-books and in the reports of cases in the journals. The terms will be here restricted to those cases in which the primary dislocation is directly outward or inward, the coronoid process remaining in front of, and the olecranon behind, the transverse longitudinal (frontal) plane of the humerus. In some cases of outward and backward dislocation the question may arise whether the position in which the bones are found is not the result of a consecutive displacement following a primary

outward displacement. I believe such consecutive displacements to be very rare, and that the great majority of backward and outward dislocations belong, by their essential features, among the backward ones with which I have above described them.

In a dislocation backward and inward this question does not arise, for a complete inward dislocation has never yet been reported; but the confusion is, nevertheless, equally great, for the epithet "backward and inward" has been indiscriminately applied to all displacements toward the inner side, including, as Trélat pointed out, three distinct varieties: 1st, dislocations of both bones inward; 2d, dislocations of both bones backward and inward, and 3d, dislocations backward of the ulna alone.

Incomplete Lateral Dislocations.

Doubtless it must be attributed to this confusion in the use of terms that the frequency of incomplete dislocations to the outer or the inner side passed unnoticed until 1863, when a German surgeon, Hahn, who had practised for more than forty years at Stuttgart, published a paper¹ upon the subject in which he stated that he had treated 21 cases of this injury in thirty years, nearly as many as those of dislocation backward observed during the same period; of these 18 were in children, 3 in adults; 12 of the former and 2 of the latter were in males, and in all but one the dislocation was inward. The statement, which was supported in many points by the observations of the reviewer of the paper, Streubel, at once attracted attention and has been confirmed and accepted by subsequent writers; the principal contributions to the subject have been made by Hueter,² Nicoladoni,³ and Sprengel.⁴ Hueter described 6 specimens of outward dislocation obtained by resection and 3 cases observed clinically; Nicoladoni found 4 incomplete outward dislocations in 16 dislocations of the elbow observed in four and a half years; and Sprengel reported that the records of the Halle clinic for the years 1873-1879 contained 32 cases, of which 20 were inward and 12 outward. An important feature of the last communication is that 15 of the 32 (11 inward, 4 outward) were old cases, and in only 1 of them could reduction be obtained. Although it is not so stated, it is probable that in many of them an error in diagnosis had been committed; Hahn says the injury is frequently mistaken for fracture of the lower end of the humerus. In a case seven months old reported by Sprengel the injury had been pronounced by a well-known London surgeon, who gave the patient a written opinion, an intercondyloid fracture of the humerus, and he added that there was no trace of the dislocation said to have existed; Sprengel excised the joint and demonstrated the dislocation. On the other hand, Krönlein's 94 cases (p. 412) contain no examples, and in my experience they are relatively very few.

The cause is usually a fall upon the outstretched hand; exceptional causes are falls upon the inner side of the elbow and blows received

¹ Hahn: Schmidt's Jahrbücher, vol. cxix. p. 74, and vol. cxx. p. 88.

² Hueter: Arch. für klin. Chirurgie, 1867, vol. viii. p. 153, and vol. ix. p. 935.

³ Nicoladoni: Wiener med. Wochenschrift, 1876, pp. 570, 599, 640, and 670.

⁴ Sprengel: Centralblatt für Chirurgie, 1880, p. 129.

upon the forearm. The interlocking of the central ridge of the sigmoid cavity in the groove of the trochlea is such that direct lateral displacement without preliminary separation of the articular surfaces, or without their fracture, is impossible, and it is highly probable that the dislocation is produced by abduction of the completely extended forearm, or possibly by its equivalent pronation when partly flexed—that is, the ulna is moved downward (in the prolongation of the frontal plane of the humerus) and outward, turning upon the humero-radial articulation as a centre, and thus the internal lateral ligament is ruptured. The joint is thus opened upon its inner side, the sigmoid cavity and trochlea separated from each other, and only the radius and capitellum remain in contact at their outer borders. If now the capitellum slips inward along the upper surface of the radius an incomplete outward dislocation is produced; if, on the contrary, the radius slips inward along the capitellum an incomplete inward dislocation is the result. This mechanism can be reproduced upon the cadaver, but it must be admitted that the explanation is theoretical; accurate clinical observations, for reasons often above referred to, are not obtainable, and it is impossible to reproduce all the factors upon the cadaver.

A. Incomplete Inward Dislocations.

Pathology. The autopsies and direct examinations that have been reported and are available to show the new relations of the bones are few in number. There are two autopsies reported by Broca¹ and Jolivet,² and the case above referred to in which Sprengel excised the joint seven months after the injury was received. In the latter the head of the radius rested against the lateral part of the trochlea, and the ulna was displaced so far inward that nearly half of the sigmoid cavity projected free beyond the trochlea; upon this free part, and united with it, lay the fractured tip of the epitrochlea. There was close fibrous union between the opposing surfaces.

Broca's case was a much older one; the specimen and a plaster cast of the limb are preserved in the Musée Dupuytren. It differs from the usual clinical form in the very marked displacement downward and backward of the head of the radius. The new joint permitted full flexion and almost complete extension, and the axis of the forearm was inclined downward and outward 30 degrees from the prolongation of that of the humerus. The distance between the prominences formed by the tip of the olecranon and the head of the radius was six centimetres. There remained no trace of the lateral and annular ligaments; a fibrous capsule of new formation connected the bones with one another. Broca says there was no sign of former fracture, but Denucé,³ who appears to have examined the specimen, says the external condyle appears to have been broken off and displaced forward. The sigmoid cavity embraces the epitrochlea, and forms a new articulation with it; the radius lies below the inner part of the trochlea and projects notably behind it.

¹ Broca : Bull. de la Soc. Anatomique, 1849, p. 272.

² Jolivet : Bull. de la Soc. Anatomique, 1865, p. 184.

³ Denucé : Dict. de Méd. et Chir. pratiques. art. Coude, p. 765.

Jolivet's specimen was obtained by amputation eighteen months after the injury. The elbow was flexed, the forearm semipronated, and there was very slight mobility. The olecranon, displaced inward, embraced the epitrochlea by its sigmoid cavity and projected beyond its inner side. The olecranon fossa was empty; the anterior and inner part of the head of the radius rested upon the outer articular half of the trochlea, the sharp inner border of the latter lying like a wedge between the radius and ulna. The coronoid process lay in a new groove formed at the expense of the epitrochlea and the adjoining side of the trochlea. The posterior edge of the head of the radius could be felt as a prominence at the back of the joint.

Both lateral ligaments are necessarily torn; the annular ligament may perhaps resist, though it must at least be put upon the stretch by the interposition of the inner anterior edge of the trochlea between the head of the radius and the coronoid process. The clinical features indicate that the head of the radius lies rather below than directly in front of the trochlea, even in flexion of the elbow at a right angle.

Symptoms. The axis of the forearm is parallel with that of the arm and a little to its inner side. The prominence of the epitrochlea is lost, that of the outer epicondyle increased. Flexion and extension are quite free, and painless within certain limits.

On palpation, the olecranon can be recognized immediately behind the position of the epitrochlea and extending so far to the inner side as to mask this prominence completely; the triceps shows as a rather prominent elevation running downward and inward. The external condyle can be plainly felt, and the absence of the head of the radius from its normal position recognized; the latter can sometimes be felt below the empty olecranon fossa.

Treatment. Reduction in recent cases appears to be easy by traction in the extended position and direct pressure upon the side of the ulna. Theoretically, outward lateral flexion combined with moderate traction and followed by direct pressure ought to effect reduction readily and without risk of fracture, especially if anæsthesia is employed.

Sprengel's statistics, quoted above, indicate that reduction is very difficult in old cases; out of eleven only one was reduced, but the length of time that had elapsed is not given except in the one case that was reduced, eight weeks.

Broca's specimen and two of Sprengel's cases show that the joint, even if reduction is not made, may have a free range of motion and the limb may be useful; in his other cases Sprengel's attempts to increase the range of motion failed more or less completely.

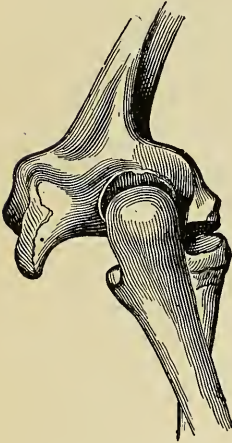
B. Incomplete Outward Dislocations.

This form, although apparently somewhat less frequent than the preceding, has been more fully studied. Its causes and mechanism have been described above.

Pathology. Fig. 305 represents a specimen from an old case presented to the Société Anatomique by Poumet: it is described by Malgaigne, Denucé, and Pingaud as one of the only two cases known,

the other, Pinel's, being very similar. The list has since been increased by the five specimens obtained by Hueter by resection, by Hutchinson's autopsy, and by Sprengel's case in which the dislocation be-

FIG. 305.



Old incomplete outward dislocation. (POUMET.)

came compound. A case which I reduced by arthrotomy three weeks after the accident belongs, I think, in this class, although the coronoid process lay behind the external condyle; the epitrochlea lay in the groove of the trochlea, and a mass of new bone had formed on the back of the external condyle. The last three are the only examples of the condition in the recent state of which I have knowledge, and the information furnished by Sprengel's relates only to the position of the bones.

Sprengel's¹ patient was a girl seven years old; the injury was caused by a fall, was supposed to be a fracture, and was treated by immobilization in a gypsum dressing. Five weeks later she came under Sprengel's observation. On removal of the dressing a slough an inch in diameter was found to have formed, and through the opening created by it the internal condyle presented. The head of the radius could be distinctly felt below the external condyle, the ulna was displaced outward so that the outer half of the sigmoid cavity embraced the capitellum; the forearm was pronated and fixed in a position midway between flexion and extension. Forcible abduction was made as a preliminary to reduction, and the opening of the slough was thereby so enlarged that the position of the bones as described was verified by direct inspection. The child made a good recovery.

Hutchinson's² specimen was of a recent case, the patient having died of associated injuries. The dislocation had been reduced during life; on the table it could be easily reproduced, and the bones could be dislocated to either the outer or the inner side. The sigmoid notch rested against the external condyle and the head of the radius projected beyond the latter. The lateral ligaments were completely torn, and there were several rents in the anterior one; the orbicular ligament was entire, but much stretched. Small portions of cartilage had been broken from the articular surfaces of all three bones.

Poumet's specimen (Fig. 305) is thus described by Pingaud.³ "The ulna, carried directly outward, has completely left the trochlea, which projects on the inner side and contains in its groove a large sesamoid bone [evidently the broken-off epitrochlea, *vide infra*]. The external articular slope of the sigmoid cavity is in relation with the capitellum, which is notably hypertrophied, as is also the epicondyle, while the trochlea and epitrochlea are atrophied. The radius, displaced outward

¹ Sprengel: Loc. cit.

² Hutchinson: Medical Times and Gazette, 1866, vol. i. p. 410.

³ Pingaud: Loc. cit., p. 526.

and especially forward, is in indirect relations with the epicondyle and the remainder of the condyle, outside of which is a small sesamoid bone which completes the surface of articulation on this side. It results from these anatomical relations that the forearm is in slight flexion with rotation inward; the ligaments, especially the lateral ones, are in great part ruptured.

Hueter's six specimens all showed the same displacement, and the epitrochlea torn off and lodged in the groove of the trochlea. The same avulsion of the epitrochlea was found in my case and clinically in seven others, Albert and von Dumreicher¹ each one, Hueter² three, and Eversham³ two, in two of which it prevented reduction, and in the others made reduction very difficult. In two other cases, also observed clinically by Nicoladoni, in which reduction was not attempted because of the length of time that had passed since the injury was received, fourteen and five months respectively, the epitrochlea was broken off; in one it could not be found, in the other it lay below and near the sharp inner edge of the trochlea.

Nicoladoni, after experimenting upon the cadaver, reached the opinion, which seems to be correct, that this avulsion of the epitrochlea is effected through the attached flexor muscles and not through the internal lateral ligament which is inserted only upon its base.

His experiments show that the internal lateral ligament is always ruptured, usually close to its insertion at the base of the epitrochlea, but sometimes nearer to or at its attachment to the ulna. The rupture extends backward along the margin of the sigmoid cavity to the tip of the olecranon, and in front through the anterior ligament to the outer side of the coronoid process. The external lateral and the annular ligaments are untornd. The clinical cases indicate, however, that the annular ligament also is sometimes ruptured.

Symptoms. The elbow is somewhat flexed, the angle varying in the different cases, the forearm pronated. The axis of the forearm is sometimes parallel with and external to that of the arm, sometimes adducted. The prominence of the internal condyle is increased, and the skin is tightly stretched over it. The transverse diameter of the elbow is increased by the projection of the muscles and the head of the radius on the outer side. Flexion and extension are painful and restricted. In the reported cases no mention is made of lateral mobility.

On palpation the epitrochlea, unless broken off, is very readily felt; if it is broken off, the inner side and edge of the trochlea can be plainly traced, and the epitrochlea may perhaps be recognized as a movable body below it, or it may have been drawn past the edge of the trochlea into its groove where it cannot be felt.

On the outer side the head of the radius projects in a line with the anterior or under surface of the condyle, according as the elbow is more or less flexed. The olecranon is more prominent than normal, because it is lifted out of its fossa and lies against the back of the

¹ Nicoladoni: *Loc. cit.*, p. 571.

² Hueter: *Arch. für klin. Chir.*, vol. ix. p. 935.

³ Eversham: *Deutsche Zeitschrift für Chir.*, vol. ix. p. 528.

more prominent external condyle; it is distant from the epitrochlea about two inches. The triceps appears as a prominent cord directed downward and outward to the olecranon. The external epicondyle may be felt by pressing the finger firmly in above the head of the radius and behind the prominence formed by the extensor muscles of the hand.

According to Pingaud, the forearm is so pronated that the posterior surface of the ulna looks outward, and the head of the radius lies in front of the capitellum instead of being displaced outwardly. Such cases belong, I think, to the class of dislocations of the ulna alone.

Treatment. The first indication of treatment is to lift the central ridge of the sigmoid cavity and the coronoid process out of the groove between the capitellum and the trochlea, or, in other words, to separate this portion of the ulna sufficiently from the under surface of the humerus to allow it to be pushed inward past the projecting outer border of the trochlea. This may be effected by hyperextension, or by outward lateral flexion if the head of the radius still rests against the under surface of the humerus so as to form a fulcrum or centre for the movement.

If hyperextension is made, the movement takes place about the tip of the olecranon as a centre, where it rests against the back of the humerus, and the coronoid process is carried downward away from the humerus as well as backward, and when the separation is sufficient direct pressure with the thumbs upon the head of the radius will force the bones into place, or rotation of the ulna inward (supination) will carry the tip of the coronoid process past the margin of the trochlea into the groove. Nicoladoni suggests that in the latter manœuvre an assistant should press with his thumb upon the back of the olecranon to prevent the production of a backward dislocation.

Outward lateral flexion should be aided by traction upon the extended or slightly flexed forearm, by which the articular surfaces will be separated as far as the untorn ligaments will permit, then pressure by the thumb upon the head of the radius will force the inner ends of the bones back into line, and the straightening of the limb completes the reduction.

If the annular ligament is torn, its outer portion and the adjoining part of the external lateral ligament may be interposed between the radius and the humerus and oppose the return of the former; under such circumstances the ulna can still be reduced, but the lateral pressure to effect this must be made upon the olecranon instead of the radius, and then by pronating and adducting the forearm the radius is drawn past the obstacle into place. The suggestion of the existence of this obstacle and of the means by which it may be avoided rests entirely upon experiments on the cadaver. I do not know that it has ever been encountered and thus overcome in practice.

The complication of avulsion of the epitrochlea and its lodgement in the groove of the trochlea seriously increases the difficulty of reduction. As above stated, in two of the five recent cases in which it was recognized reduction failed. The reason of the failure is that the displacement of the fragment from the groove by the returning ulna is

prevented by the sharply inclined inner slope of the trochlea and by the pressure of the overlying muscles and fascia. The fragment needs to be drawn downward as well as pushed inward. Albert succeeded by flexing the forearm at a right angle, and then drawing it forcibly away from the humerus in the direction of the long axis of the latter by means of a cord passed across its anterior surface close to the elbow. The same method, when employed by von Dunreicher, failed, as did also forcible outward lateral flexion and traction, although carried so far as to threaten rupture of the skin on the inner side of the joint.

Possibly the transformation of the dislocation into the direct backward form, or backward and inward, would remove the fragment from the groove and make reduction possible, or it might be practicable to draw the fragment downward out of the way by a sharp hook passed through the skin. Other means failing, the obstacle could be easily reached and removed through an incision on the inner side.

Complete Dislocations Outward.

These dislocations, of which the first observation was reported by Dupuytren in 1807, although the form had been described by Petit nearly one hundred years before, were apparently so rare that Malgaigne could collect only ten reported cases. Of late, reports have so multiplied that, excluding irregular cases, and those of which the description is not sufficiently detailed, and those which seem more properly to belong among the dislocations backward and outward, the number of those available for study and generalization is about twenty-five.¹

In most of the cases the mechanism of production cannot be determined, but the histories of a few are sufficiently complete to show that the cause may be a fall upon the outstretched palm or upon the elbow, or a blow received upon the inner side of the forearm. Hatry's case is a clear example of the first, the patient stumbled and fell forward upon his hand; von Pittha's patient, who fell while her hands were in her muff, is an example of the second; and Mears's patient, who was struck upon the inner and upper part of the forearm by a revolving piece of wood while the elbow was partly flexed in an effort to draw

¹ The bibliography, excluding doubtful cases, is as follows: Dupuytren, *Leçons orales*, vol. i. p. 131; Bouley, *Bull. de la Soc. Anatomique*, 1837, p. 101; Nélaton, *Pathol. chirurgicale*, vol. ii. p. 391; Neilson, *Lancet*, 1844, ii. p. 559; Robert, *Gaz. des Hôpitaux*, 1849, p. 180; Soulié, *Gaz. Médicale*, 1849, p. 717; Verneuil and Triquet, *Gaz. Médicale*, 1851 [?]; Piogey and Dubrueil, *Gaz. des Hôpitaux*, 1851, p. 30; Denucé, *Thèse de Paris*, 1853; Flaubert, *idem*; Puech, *Gaz. des Hôpitaux*, 1859, p. 434; Sistach, *Bull. de la Soc. de Chirurgie*, 1866, p. 520; Varick, *New York Medical Record*, 1867, vol. ii. p. 387; Andrews, *idem*, 1875, p. 720; Von Pittha, *Pittha and Billroth's Chirurgie*, vol. iv., abt. 2, B. p. 71, 4 cases; Hatry, *Lyon Médical*, 1876, vol. xviii. p. 13; Wylie, in *Hamilton's Fractures and Dislocations*, p. 698; Bertin, *Union Méd.*, 1876, p. 609; Osborne, *New York Hospital Gazette*, 1879, p. 613; Mason, *New York Medical Record*, 1880, vol. xvii. p. 397, 2 cases; Towne, *idem*, p. 525; Ekwurzel, *Philadelphia Medical and Surgical Reporter*, 1881, vol. xlv. p. 38; Mears, *Philadelphia Medical Times*, 1880-1, vol. xi. p. 89; Johnson, *Transactions of the Missouri State Medical Association*, 1880, p. 33; Battiscombe, *Lancet*, 1886, ii. p. 397; Heinlein, *Centbl. für Chir.*, February 1, 1890; Stimson, here given; Winslow, *Annals of Surgery*, May, 1900, p. 595. I have not been able to verify the reference for Dupuytren's and Verneuil's cases. The *Gazette Médicale* for 1851 does not contain the latter; in the *Gazette des Hôpitaux*, 1851, pp. 93 and 201, is an article by Verneuil and Triquet which contains a case of *incomplete* outward dislocation.

down some object from above his head, is an example of the third. The mechanism in a fall upon the hand is doubtless the same as that in incomplete dislocation outward produced in the same manner—that is, outward lateral flexion is produced; the internal lateral ligament is ruptured, and then the bones are displaced laterally past one another by the continued action of the weight of the body. In one of von Pitha's cases this lateral flexion was observed by the mother of the patient, a boy, six years old, who saw the elbow bend as he fell from a tree upon his outstretched hand.

Pathology. The only recorded autopsies are those of Bouley and Heinlein; in the former, a compound dislocation with fracture of the external condyle produced by a fall upon the elbow from a height of twenty-eight feet, amputation was refused, and the patient died on the twenty-fifth day. The lateral ligaments of the elbow were entirely ruptured; both bones of the forearm were placed externally to the lower extremity of the humerus, and the ulnar nerve was lacerated at the level of the trochlea. In the latter both lateral and the anterior ligaments were torn, the radial nerve bruised; a fragment was broken from the head of the radius, and the coronoid process was broken. The radius and ulna were also broken near the middle.

Disregarding one or two exceptional forms, the cases may be grouped in three classes according to the character of the displacement, but in some the account is not sufficiently complete to determine to which class the case should belong. In one, apparently the least frequent, the displacement is directly outward and a little upward, so that the inner edge of the sigmoid cavity rests against the outer surface of the external condyle, the elbow being partly flexed, with the olecranon behind and the coronoid process in front of the epicondyle. The radius preserves its relations with the ulna and is situated still further to the outer side, or is carried to a somewhat higher level by pronation of the forearm. This involves complete rupture of the lateral and anterior ligaments. In Neilson's case it was thought the external condyle was broken; the olecranon was three inches above its usual position.

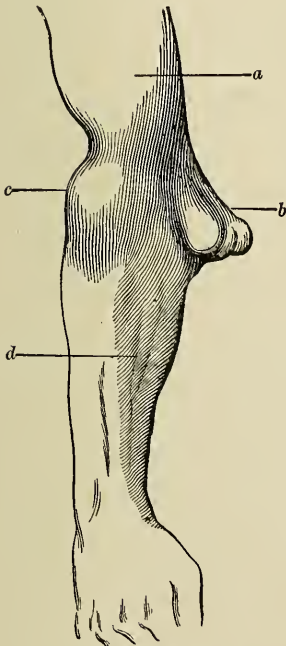
In the second class the forearm is pronated as well as flexed, and this pronation is effected by rotation about the long axis of the ulna, so that the head of the radius lies above, or even further inward than, the ulna. The great sigmoid cavity embraces the outer surface of the external condyle, the tip of the olecranon lying behind the condyle and that of the coronoid process in front of it. The anterior surface of the ulna looks inward. The head of the radius lies above its normal position, in front of the humerus, and possibly still in contact with the upper part of the articular surface of the capitellum. Study of the skeleton indicates that this form can be easily produced from an incomplete outward dislocation by pronation of the limb; it is, I think, the most common of the three classes, and it seems possible that the external lateral ligament may be preserved untrorn. Denucé has given it the name of *sub-epicondylar*, in distinction from the following, third class, which he terms *supra-epicondylar*. He thinks the distinction is an important one and that the difference depends upon the rupture or the integrity of the attachment of the muscles upon the epicondyle.

In the third class the ulna and radius, pronated and flexed, are carried higher up along the outer border of the humerus, two inches in Osborne's case. The sigmoid cavity may embrace the supinator ridge, and the radius still lie in front of the humerus, or both bones may be displaced also backward so that the coronoid process and the articular surface of the radius are posterior to the ridge.

It is noteworthy that in none of the cases is fracture of the epitrochlea mentioned; in one or two it is said that the epitrochlear muscles were torn away at their insertion.

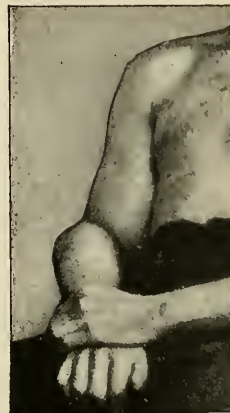Two cases, in which an additional consecutive displacement had followed by which both bones were brought around in front of the humerus and pronated so far that their posterior surfaces were directed forward, were reported by Cloquet¹ and Maisonneuve.² The latter's patient was a woman who had fallen out of bed upon her elbow, and who was so thin that the position of the bones could be accurately determined; the lower end of the humerus projected prominently behind and was there covered only by the skin, while the triceps ran forward and outward over the epicondyle. The ulna was com-

FIG. 306.



Complete outward dislocation.
(DENUCÉ.)

FIG. 307.



Complete outward dislocation of the elbow. Supra-epicondylar. (STIMSON.)

pletely turned around so that its posterior surface looked forward and the sigmoid cavity lay against the front of the trochlea. The head of the radius could not be felt. The limb was slightly flexed and greatly pronated. Reduction was effected by moving the olecranon outward and backward around the external condyle to the

back of the humerus, and then reducing in the usual manner the backward dislocation thus produced.

¹ Cloquet: Quoted by Malgaigne, loc. cit., p. 616.

² Maisonneuve: Gaz. des Hôpitaux, 1867, p. 145.

Symptoms. Of the first variety, dislocation directly outward without rotation of the forearm (Fig. 306), Puech's case may be taken as a type. The patient was a man forty-one years old, and the injury was caused by a fall from a height of about two feet, the elbow striking against some stones. The forearm was extended and supinated; it could be passively flexed nearly to a right angle, but could not be pronated; its axis lay entirely to the outside of the humerus, and the transverse diameter of the elbow was nearly doubled. Tracing the bones with the finger behind, from the epitrochlea outward, the surgeon recognized all the points of the lower end of the humerus, then the olecranon well above and to the outer side of the condyle, and then the head of the radius lower than the olecranon but still above the lower line of the humerus. In other similar cases extreme mobility of the joint is mentioned; as if the two segments of the limb were very loosely attached to each other.

In the second variety, "*sub-epicondylar*," the axis of the forearm appears generally to be inclined downward and inward (adduction); flexion at, or even within (Pitha), a right angle is common; semi-pronation or full pronation. The transverse diameter of the elbow is increased, but not so much as in the preceding variety. The supinator and radial extensor muscles form a well-defined prominence above and in front of the joint; the tendon of the triceps shows as a prominence directed downward and outward, and the tendon of the biceps can sometimes be felt running in the same direction in front.

The outlines of the lower end of the humerus can be distinctly traced from the epitrochlea outward to the capitellum; the external epicondyle is masked by the ulna, but sometimes can be felt by pressing the finger deeply in above the latter. The cup-shaped surface of the head of the radius can be felt unless it has been carried so far inward by the pronation of the limb that it rests against the front of the humerus.

In the third variety, "*supra-epicondylar*" (Fig. 307), the forearm is flexed at, or nearly at, a right angle and pronated; the transverse diameter at the lower part of the arm is increased. The greater the displacement upward, the greater is the passive mobility of the limb in the plane of flexion and extension. The lower end of the humerus is accessible to the touch even more completely than in the two preceding varieties, for it projects completely below, and even its external condyle can be traced. The deformity on the outer side varies with the extent and character of the final displacement, for the bones of the forearm are sometimes carried backward, crossing the humerus, or, as in Maisonneuve's and Cloquet's cases, carried forward to the front of the humerus.

It is noteworthy that in three of the four cases in which reduction was not made the patients had good control of the limb and a free range of motion was established. Wylie's patient thought his arm was as serviceable as ever. Robert's patient was seventy years old and his injury dated from infancy; he had an extensive range of flexion and extension. In Denucé's case (Fig. 306) the olecranon projected nearly an inch behind the humerus, the arm could be fully

extended and flexed nearly to a right angle. In Nélaton's case there was flexion nearly at a right angle.

It is also noteworthy that in no case were there symptoms of interference with the circulation, and in only one case (Mears) were there symptoms of injury to the nerves. In his there were pain in the fingers and numbness in the distribution of the median nerve.

Treatment. Reduction has been effected without difficulty in all the recent cases, except Winslow's, by extension and direct manipulation of the upper ends of the radius and ulna. The laceration of the ligaments and muscles is so great that the bones are freely movable, and special manœuvres intended to relax opposing bands are seldom necessary. Exceptions to this may be found sometimes in the first and second varieties; in the first the head of the radius may pass through and be caught, as apparently happened in Puech's case, between two muscular bundles, which may then need to be relaxed by flexing and abducting the forearm; in the second, which appears sometimes, as has been said, to differ from the incomplete outward dislocations only in the addition of pronation of the forearm, the external lateral ligament remaining untornd, the first movement must be to supinate the limb and thus turn the sigmoid cavity under the capitellum and bring the head of the radius to the outer side; the dislocation is then an incomplete outward one, and is reduced accordingly. In a case in which previous attempts by traction in extension under anæsthesia by other surgeons had failed I reduced easily by flexing the elbow at a right angle and pressing the head of the radius downward and around the lower outer edge of the condyle.

DISLOCATIONS OF THE FOREARM FORWARD.

Although mentioned by Hippocrates and characterized by him as the most painful of all and fatal in a few days, and admitted by all subsequent writers, the first recorded case (and that a questionable one) of this dislocation was published only a hundred years ago, and the number has not yet reached twenty-five, even including seven cases in which the olecranon was broken off and remained in place.¹

Of the 13 cases in which the age is mentioned, 1 was six years old,

¹ The bibliography is as follows: Evers, Monin, Guyot, Wittlinger, quoted by Streubel in *Prager Vierteljahrschrift*, 1850, ii. p. 37, and by Malgaigne, *loc. cit.*, p. 626; Guerre, quoted by Pingaud in *Dict. Encyclopédique*, 1st ser., vol. xxi. p. 708; Chapel, quoted by Malgaigne, *loc. cit.*, p. 617, as a dislocation outward; Colson, Leva, quoted by Debrun in *Annales de la Chirurgie Française et Étrangère*, 1843, vol. ix. pp. 44 and 45, and by Streubel; Richet, *Archives générales*, 1839, vol. vi. p. 472; Prior, *Lancet*, 1844, ii. p. 366; Ancelon, *L'Union Médicale*, 1859, vol. iii. p. 394; Canton, *Dublin Medical Journal*, 1860, ii. p. 24; Secrestan, *Gazette des Hôpitaux*, 1860, p. 598; Caussin, *L'Union Médicale*, 1861, vol. xi. p. 475, and *Bulletins de la Société de Chirurgie*, 1861, vol. ii. p. 451; Richet, *Bull. de la Soc. de Chirurgie*, 1859, vol. ix. p. 110; Morel-Lavallée, *idem*, p. 107; Greenaway, quoted by Hutchinson, *Medical Times and Gazette*, 1866, i. p. 409; Langmore, *Lancet*, abstract in *New York Medical Record*, 1867, vol. ii. p. 10; Rigaud, *Bulletins de la Société Anatomique*, 1870, p. 15; Date, *Lancet*, 1872, ii. p. 597; Mons, *Deutsche Mil. Zeitschrift*, 1877, p. 401; quoted by Poinso, *loc. cit.*, p. 951; Krönlein, *Deutsche Chirurgie*, Lief. 26, p. 30; Stimson, see Plate XIII.; Ray, quoted by Platt, *Fractures and Dislocations of Upper Extremity*, 1899, p. 200; Fulton, *Med. Record*, 1897, vol. lii. p. 738; Staunton, *Brit. Med. Journ.*, 1905, Dec. 9, p. 1520. References have also been made to a case by Ferguson, *Surgery*, 3d ed., p. 241, one by Roser, *Chirurg. Anat.*, 1844, p. 477, and one by Flaubert.

2 were eight, 2 fourteen, 2 fifteen, and 1 each eighteen, twenty, thirty-four, thirty-eight, and forty years old, 1 was an "adult," and 1 "middle aged." The cause in the greater number of cases appears to have been a fall upon the flexed elbow; in one (Pryor) it was a blow by the handle of a crane upon the back of the elbow; in two certainly (Date, Ray), and probably in others, it was a fall upon the palm of the hand; in Fulton's it was traction on the extended arm, without fracture of the olecranon; in one (Caussin) the patient's hand was caught between two cogwheels and both bones of the forearm were broken at the middle as well as dislocated; and in one (Morel-Lavallée) the patient fell from a wagon and was run over, the wheel passing across the elbow and breaking the olecranon and coronoid process.

In seven of the cases the olecranon was broken, and in these the mechanism of the dislocation is easily understood, for, the resistance of the olecranon being removed, the two bones can be easily displaced forward and upward along the front of the humerus by a force acting upon the back of the forearm. Such cases, I think, should hardly be put in this class; the dislocation is secondary to, and made possible by, the fracture of the olecranon. A personal case of this kind is shown in Plate XIII. I have recently (1899) seen another. In the case of a fall or of a blow upon the flexed elbow the direction of the force is probably inclined somewhat away from the axis of the forearm and is more nearly parallel with the posterior portion of the articular surface of the olecranon, and it must be great enough to rupture the lateral ligaments without the aid of leverage. All attempts to reproduce the dislocation upon the cadaver by this mechanism, forced flexion and direct impulsion, have failed, except after preliminary division of the lateral ligaments.

In the case of a fall upon the hand there is clinical evidence to show that this form is closely allied to the lateral dislocations, and that it is produced by lateral outward flexion supplemented by sufficient torsion (supination) of the limb to bring the olecranon forward under the trochlea; in several cases the displacement was outward as well as forward; in Chapel's, so far outward that the case has been classed with the lateral dislocations.

Pathology. One autopsy (Riche), three amputations (Canton, Morel-Lavallée, Rigaud), two compound fractures of the olecranon without amputation (Riche, Guerre), one compound dislocation without fracture (Prior), and experiments upon the cadaver show how great the laceration sometimes is. In Prior's case, in which the patient was struck upon the "under side of the left arm at the elbow-joint" by the rapidly-revolving handle of a crane, there was a large wound at the point where the blow was received, "occasioning a general disconnection of its parts, muscular and otherwise, excepting immediately in front." The radius and ulna were driven upward and forward on the humerus; the condyles of the latter and its shaft for two and a half or three inches projected through the wound nearly at right angles with the forearm, as completely stripped as if cleaned with a knife. There was no fracture. Reduction was made; the patient recovered after much suppuration in and around the joint, and the final result was good, "the limb gaining in freedom and power."

In Canton's case, the patient, a man forty years old, was thrown from a wagon; apparently he struck upon the extended hand, but the forearm was immediately flexed and twisted under his chest. The forearm was flexed, the hand supinated, the swelling very great, and the skin tense and threatening to slough over the internal condyle. The antero-posterior and lateral diameters of the joint were increased, and the head of the radius could be indistinctly felt externally and anteriorly. The diagnosis was not made, and "attempts to correct the maladjustment" failed; after a delay of forty-eight hours, during which the swelling increased and sloughing was established, amputation well above the condyles was resorted to.

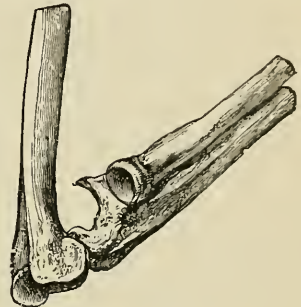
Examination of the limb showed (Fig. 308) that the upper surface of the olecranon rested against the front of the capitellum; the annular and interosseous ligaments were whole, the anterior ligament was ruptured except in its centre, the posterior and both lateral ligaments ruptured. The triceps was completely detached from the olecranon. The two radial extensor muscles and all the muscles arising from the epicondyle except the supinator brevis and the anconæus were detached, as was also the epitrochlear head of the flexor carpi ulnaris. The ulnar nerve was torn behind the condyle. The other large nerves and the main vessels were uninjured.

Richet's first patient was eighteen years old and had fallen from a height of forty-five feet. The forearm was slightly flexed and in supination, and was immovable; it was shortened an inch, measuring from the epicondyles to the lower ends of the radius and ulna. The olecranon was in place and movable; two inches below it was a large wound through which the lower end of this fragment projected. The head of the radius and the broken end of the ulna were recognizable in the fold of the elbow a fingerbreadth above the condyles. Reduction was easy by traction, but recurrence at once followed. The patient died three hours later. The autopsy showed the annular ligament to be intact.

In addition to these two varieties, dislocation with and without fracture of the olecranon, the difference between which is so important, there is another, based upon clinical and experimental evidence, to which the name *incomplete* is given; in it the upper end of the olecranon rests against the under and anterior surface of the humerus instead of passing upward in front of it. So far as can be inferred from the reported cases it is the most common form. The use of the terms first and second degree, to distinguish between the two forms, is, I think, to be preferred to that of incomplete and complete.

In Chapel's case the additional outward dislocation, which is noted in several of the others, was so great that Malgaigne classes it with the outward dislocations. The patient was a boy fourteen years old. The radius formed a marked prominence under the skin on the outer side; on its inner side could be felt the olecranon and its sigmoid cavity.

FIG. 308.



Forward dislocation of the elbow; Canton's case.

The two bones overrode the humerus in front about two centimetres ; the epicondyle lay behind the ulna. Mons's case seems to me to be of the same kind. It is quoted by Poinsoot as a unique example of divergent dislocation, ulna forward and radius outward. The description is limited to this statement and does not definitely exclude the possibility that the ulna may have been displaced outward as well as forward.

Fracture of the epitrochlea has been observed in one case (Date's), a boy fourteen years old, and this is the one in which the evidence that the dislocation was produced by external lateral flexion in a fall upon the hand is most complete. The head of the radius was prominent outside of and below the outer condyle ; above it was a deep depression in which the condyle could be obscurely felt ; the olecranon was below its usual position, resting with its extreme end against the trochlea (first degree, or incomplete). The limb was semi-flexed. Reduction was easy under chloroform ; the radius first, and then the ulna, going back into place with a distinct snap. If this account of the positions of the two bones is accurate the annular ligament was probably torn.

Symptoms. In five of the cases uncomplicated by fracture it is stated that the forearm was lengthened, more than an inch in one of them, and with this coincided a position of the limb which is mentioned in several others, namely, slight or partial flexion, which could generally be changed somewhat in either direction. In one in which the range of motion is specified (Langmore), the limb was held at an angle of 130 degrees, could be flexed to a right angle and extended to 160 degrees ; in another (Colson), hyperextension could be made without causing pain, and during the movement the olecranon passed forward between the biceps and pronator teres.

In correspondence with this lengthening there is flattening of each side and of the back of the elbow, unless the swelling is sufficient to mask it, with prominence of the inner and sometimes of the outer condyle, and the formation of a transverse sulcus appreciable by the touch behind between the humerus and the olecranon. In one case the forearm was also abducted. In Canton's case the forearm was flexed beyond a right angle ; the olecranon rested against the capitellum, and the triceps was torn completely from it. It seems probable that detachment or rupture of the triceps is a necessary condition of the passage of the olecranon to any distance along the front of the humerus, and that the existence or absence of the detachment may constitute the essential difference between the complete and incomplete forms, or the first and second degrees. The clinical features which differentiate the two forms are that in the lesser form the olecranon is prominent below the humerus when the elbow is flexed, and the forearm is lengthened when it is extended or but slightly flexed. In the second, "complete" form, the forearm is more or less shortened when extended, but is lengthened when flexed at or near a right angle, and its antero-posterior diameter is increased because of the projection of the coronoid process in the fold of the elbow. The biceps tendon can be recognized on the outer side of the latter, and beyond it the head of the radius. Posteriorly, in both forms, the olecranon fossa is empty ; the direction of the ulna also plainly indicates the change in the position of its upper end unless the swelling is great.

Course and Prognosis. In only one case (Canton) did the dislocation remain unreduced, and, as in this the diagnosis was not made because of the swelling, there is reason to suppose that a suitable attempt to reduce would have been as successful as it proved in the others. It was also the only case, of those uncomplicated by a compound fracture of the olecranon, that did badly and in which amputation was thought to be necessary. The history of the case, moreover, suggests that the decision was reached rather hastily and on grounds that might be deemed insufficient.

Of the 7 compound dislocations, of which 6 were complicated by fracture of the olecranon, 3 recovered, 2 underwent amputation after the joint had suppurated, 1 died three hours after the accident, which was a fall from a height of forty-eight feet, and in 1 (Krönlein) the result is unknown. Of the 3 recoveries, the joint suppurated in 2 (Prior, Richet's second), the process ending in ankylosis in one of them; in the remaining 1 the patient recovered apparently without suppuration, the fracture of the olecranon united by a fibrous band one centimetre long, and two and a half months after the accident the hand could be brought to the mouth and the elbow extended to an angle of 150 degrees. Whether antiseptic methods will improve this poor record remains to be seen.

Treatment. In all the cases in which the olecranon rests against the lower part of the end of the humerus, the so-called incomplete dislocations, reduction has been easily effected by pressing or pulling the upper end of the forearm downward and backward, or by flexing the limb against the knee or the arm of an assistant placed in the fold of the elbow. In Greenaway's case the bones slipped into place almost spontaneously when the elbow was flexed.

In the cases in which the bones are displaced further upward it is desirable to flex the limb within a right angle and then to pull the upper ends of the bones back into place by a strap passed around the front of the forearm close to the elbow.

Dislocations complicated by compound fracture of the olecranon must be treated in accordance with the general principles of treatment of compound articular fractures, of which they are a severe form, severe because of the greater extent of the laceration of the soft parts. In my own case, simple fracture of the olecranon, seen about two months after the accident, I made reduction by an incision along the ulna which exposed the joint and the fracture.

DIVERGENT DISLOCATIONS OF THE RADIUS AND ULNA.

The characteristic feature of this form is that the radius and ulna do not accompany each other, but are displaced in divergent directions. Two varieties have been observed: the *antero-posterior*, in which the ulna passes up behind the humerus, and the radius passes up in front, and of which there are fourteen recorded cases;¹ and the *transverse*, of

¹ Bulley, Provincial Medical and Surgical Journal, 1841, quoted in the Gazette Médicale, 1841, p. 666; Michaux, quoted by Debruyin in Annales de Chir. Française et Etrangère, 1843, vol. ix. p. 52; Mayer, Gazette des Hôpitaux, 1848, p. 232; Von Pitha, Pitha and Billroth's Chirurgie, 4th vol. 2d Abt. B. p. 78; Chevalier, Arch. Méd. Belges, October, 1870, quoted by Bardeleben, Chirurgie, vol. ii. p. 759; Gripat, Bull. de la Société

which there are two cases, in which the divergence was mainly lateral, the olecranon passing to the inner side behind the epitrochlea, and the radius to the outer side.¹ Several authors make an additional variety, ulna backward, radius outward, on the basis of the case of Samuel White quoted by Cooper,² which seems to me to be a dislocation of both bones backward and outward; and Poinsoot makes a fourth variety of the case of Mons which I have placed among dislocations of both bones forward.

A. Antero-posterior.

Excluding Chevalier's case, of which I have no details, the thirteen patients were, with one exception (Tillaux), males, and with three exceptions, adults; two were nine years old, one thirteen. The cause was usually a fall from a considerable height, or with violence, as from a moving railway car, a horse, or a wagon; in one it was a fall while carrying a heavy timber, in another while wrestling; and in Tillaux's the patient, while lighting a match, struck her elbow against a piece of furniture behind her; the pain was so great that she fainted and fell to the floor, where she was found with her elbow abducted and flexed. Scott's patient was thrown from a horse, striking upon his head and hands; he found his elbow dislocated and the forearm partly flexed; a bystander pulled it straight, and he felt something give way in the joint, and a bone appeared to slip forward; possibly a dislocation of the ulna alone backward was thereby transformed into the divergent one which was afterward recognized. Von Pitha's patient fell head foremost from the second story of a building upon a pile of planks between which the extended forearm was caught and held while the body was violently precipitated backward.

Pingaud,³ experimenting upon the cadaver, found it easy to produce the dislocation by forced pronation of the forearm after division of the internal lateral ligament; this fact, taken in connection with the fall upon the hand noted in several of the cases, indicates that the mechanism, in these cases at least, is a lateral outward flexion, by which the internal lateral ligament is ruptured, followed or accompanied by forcible pronation, and then by the direct movement downward of the humerus between the two bones. Fracture of the epitrochlea observed in one case (Arnozan) supports the theory of outward lateral flexion. In two cases (von Pitha, Gripat) the coronoid process was broken; in both the fall was from a considerable height.

The explanation of the mechanism in the two cases in which the injury was attributed to a fall upon the abducted and flexed elbow

Anatomique, 1872, p. 176; Arnozan, *Bordeaux Méd.*, 1873, p. 402, quoted by Poinsoot, *loc. cit.*, p. 945; Tillaux, *Gazette des Hôpitaux*, 1877, p. 786; Minich, *Lo Sperimentale*, 1880, quoted by Poinsoot; Mason, *New York Medical Record*, 1880, vol. xvii. p. 397; Scott, *Bristol Medico-Chirurgical Journal*, March, 1886, p. 36; Duret, reported by Vanheuserwyn, *Journal des Sc. Méd. de Lille*, Sept. 9, 1892; Petzholdt, *Arch. für klin. Chir.*, 1894, vol. xlix, p. 243; Ferguson, *British Medical Journal*, April 6, 1895, p. 753.

¹ Guersant, reported by Warmont in *Revue Médico-Chirurgicale*, vol. xvi. p. 303, quoted by Pingaud in *Dict. Encyclopédique*, art. Coude, p. 600, and by Poinsoot; Wight, *Physic. and Surgeon*, Ann Arbor, February, 1893.

² Cooper: *Dislocations and Fractures*, American edition, p. 384.

³ Pingaud: *Loc. cit.*, p. 598.

(Michaux and Tillaux) shares in the difficulty which attaches to the explanation of dislocation of both bones backward by the same cause. If the alleged rotation of the ulna backward and outward around the radius, by which the internal lateral ligament is torn, is accepted, it will not be difficult to conceive that the radius may remain in front; but even this leaves unexplained the forcible descent of the humerus between the two bones which requires the rupture of the annular and interosseous ligaments.

In Duret's case the sigmoid cavity looked outward (supination), and Vanheuserwyn found he could reproduce this form upon the cadaver by forced supination of the partly flexed forearm after division of the upper part of the interosseous ligament.

Pathology. Two of the patients (von Pitha, Gripat) died of the associated injuries, but the displacement at the elbow was much greater than that observed in the other cases.

In von Pitha's the autopsy showed a wide separation of the radius and ulna from each other, complete rupture of the capsule, and of the annular, interosseous, and both lateral ligaments, fracture of the coronoid process, and avulsion of the biceps and brachialis anticus.

In Gripat's case, a boy thirteen years old, the coronoid process had been broken off and the olecranon had passed almost directly upward, remaining close to the posterior surface of the humerus; the radius was displaced forward and outward. The internal lateral ligament had been torn away at both its insertions; the external one remained attached at its upper insertion, and to the broken coronoid process and part of the anterior ligament. The annular ligament was torn away at its posterior attachment to the ulna.

Symptoms. The attitude of the limb is noted in nine cases; in six it was slightly flexed, in three nearly straight; in one case supinated, in the others midway between pronation and supination, or slightly pronated. The general appearance of the region probably resembles that of dislocation of both bones backward, for in three of the cases the anterior position of the radius was not noticed until after the ulna had been reduced. Excluding the two fatal cases, the displacement of the ulna upward is still very marked: four centimetres in Tillaux's case, two or three finger-breadths in Michaux's, and one and a half inches above the condyles in Scott's and Ferguson's; in Tillaux's it was also displaced somewhat to the inner side. In four cases the position of the radius is exactly noted; in two (Bulley, Tillaux) it was in the coronoid fossa; in Mason's it rested on the outer portion of the humerus; in Petzholdt's it overlapped the inner edge of the trochlea.

Active movements, both flexion and rotation, are impossible, and passive movements restricted and painful.

In two cases (Mayer, Tillaux) reduction failed, the attempt being made on the fourteenth and eighth days respectively. In both the joint remained quite stiff. In Mason's the attempt was made on the nineteenth day; prolonged efforts under ether brought the ulna into place, but the radius slipped toward the outer side and could not be entirely reduced. The final result is not known. In the others

reduction was effected without much difficulty, usually the ulna first, then the radius, but in Bulley's the radius remained a little forward, and was finally reduced by continuous pressure upon it.

Treatment. Traction should be made in the direction of the axis of the forearm to bring the ulna into place, and in case of need it might be well to combine it with some outward lateral flexion to avoid the opposition of the external lateral ligament; after the ulna is reduced the radius should be pressed back into place with the thumbs aided by pronation and adduction of the forearm. It is quite likely that the return of the radius to its place may be impeded by the interposition of the annular ligament.

B. Transverse.

Of this variety there are only two recorded cases. Guersant's is as follows: The patient was a boy fifteen years old, who fell from a tree, three or four metres, on his left side, striking on the palm of his hand. The elbow was enormously swollen; the transverse diameter was greatly increased, and the antero-posterior one seemed lessened. The head of the radius formed a considerable prominence entirely to the outer side of the epiphysis of the humerus and a little upward along its outer border. It was so far displaced outward that there seemed to be an interval between it and the epicondyle; the skin was very tightly stretched over it.

The olecranon was displaced inward behind the epitrochlea, which it embraced in its sigmoid cavity. In the great space between the olecranon and radius lay almost the entire articular surface of the humerus.

The forearm was semi-flexed, and in a position midway between pronation and supination; voluntary movements were impossible, passive movements very restricted. There was also a fracture of the forearm three centimetres from the wrist.

Wight's patient was a woman thirty years old, who had fallen while walking, the pronated right arm being caught under the body. Supposing the injury to be a backward dislocation he attempted to reduce under ether, and after failing made a closer examination. He then found that the radius was on the outer and the ulna on the inner side of the humerus. No other details. He reduced the radius by pressing on its head while making traction and adduction, and then the ulna by traction and adduction (abduction?), "using the external condyle as a fulcrum, and at the same time firmly flexing the elbow."

CHAPTER XLVI.

DISLOCATIONS OF THE ELBOW.—(CONTINUED.)

Isolated Dislocations of the Ulna and Radius.

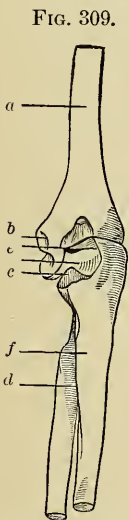
DISLOCATIONS OF THE ULNA ALONE.

SEDILLOT, in a paper presented to the Académie des Sciences in 1837, was the first of modern writers to call attention to this class of dislocations, although Sir Astley Cooper had previously described as of this kind a specimen preserved at St. Thomas's Hospital. Malgaigne and other surgeons and writers strenuously opposed the interpretation of cases cited in support of the claim that the occurrence of this form is possible, and denied the possibility on anatomical grounds, claiming that the ulna cannot be displaced backward and upward unaccompanied by the radius, except after rupture of the interosseous ligament and those uniting the lower ends of the bones, of which there is no clinical evidence. The specimen figured and described by Cooper is claimed by them to be one of dislocation backward of both bones, and one presented by Robert to the Société de Chirurgie, in 1847, was declared by Malgaigne to be of the same character. I have examined Cooper's specimen, which is still preserved at St. Thomas's Hospital, and have no doubt that it is simply an old unreduced backward dislocation of both bones, the error in interpretation having been due to a failure to appreciate the new formation of bone behind the external condyle. Malgaigne admits, however, on the authority of a case observed by himself, the possible dislocation of the ulna alone backward and to the outer side behind the radius. The dispute is in part one of terms; it must be admitted, I think, that the head of the radius in some of the reported cases has changed its relations with the capitellum, but the change is a very slight one, a simple slipping backward or forward for a distance of a few millimetres, without a change in its level corresponding to that of the ulna. The erroneous belief in the impossibility of the occurrence without the extensive lacerations mentioned arose apparently from a failure to consider the effect of a change in the relation of the axes of the arm and forearm, for while the occurrence of an isolated dislocation of the ulna backward and upward might be impossible while those relations remained unchanged, yet if, the joint being extended, the forearm is adducted, turning upon the head of the radius as a centre, the olecranon must necessarily move upward behind the humerus; or, the joint being flexed at a right angle, the same movement of adduction will displace the olecranon backward; in like manner abduction of the forearm can bring the olecranon forward or downward.

The following recorded cases¹ serve as a basis of the description to be given. Some in which the correctness of the diagnosis is in doubt, or of which I have not been able to consult the detailed reports, have been omitted.

1. Backward Dislocation.

Backward dislocation presents itself under three forms. In the first, that in which the displacement is slightest, the ulna is carried backward, either directly or by inward rotation of the forearm about the radius as a centre, until the coronoid process has cleared the trochlea, and then is moved slightly upward behind it by adduction of the forearm (Fig. 309); in the second form, the movement upward is prolonged until the coronoid process lodges in the olecranon fossa; in the third, the primary movement of rotation is prolonged until the olecranon lies behind the radius. The first form is the most common, and is sometimes termed "incomplete," in accordance with a similar use of the term in the backward dislocation of both bones; of the second form there are only two recorded examples (Malgaigne, Wilson). Some writers make an additional variety, dislocation backward and inward, a distinction which it does not seem necessary to preserve.



Dislocation of ulna alone backward, first form. (SÉDILLOT.)

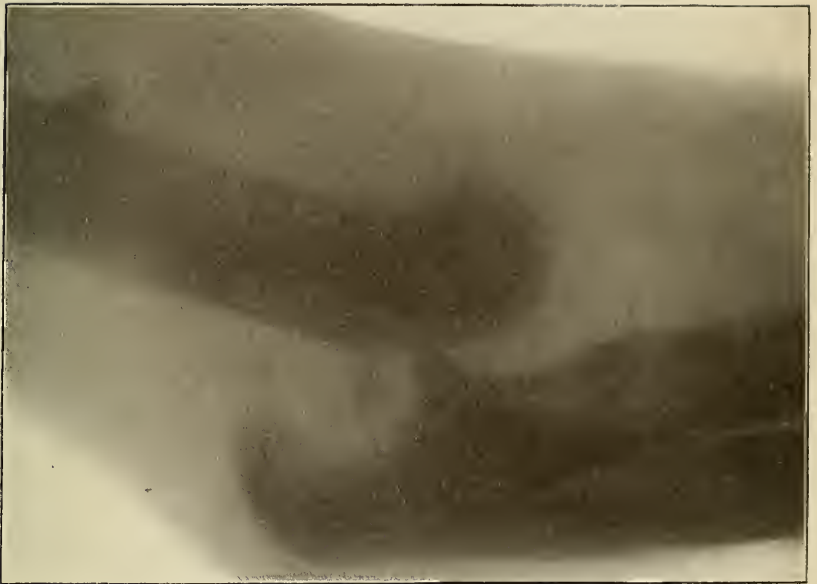Cause. The cause in the larger number of cases has clearly been a fall upon the outstretched hand; in one, Brun, a blow received upon the elbow from behind while the weight of the body rested upon the extended arm.

In von Pitha's case the injury was received in such a way that the mode of production is clearer than in most accidents, and, as the case is typical in other respects, I reproduce the account.

A girl six years old and her little brother were engaged in a trial of strength, in which each sought to move an open door against the other's opposition, the girl standing with her back against the wall and her outstretched hands against the door, the hinges being at her left side. Two other brothers came to the help of the first, and under their combined efforts the girl's left arm suddenly doubled up with an audible snap, and when von Pitha examined it half an hour later, he found "the most distinct picture of a dislocation of the ulna backward." The thin arm was in almost complete extension, the forearm being

¹ Boudant, *Revue Médicale*, 1830, vol. i. p. 85, quoted in full by Sédillot; Sédillot, *Gazette Médicale*, 1839, vol. vii. p. 369; Diday, *idem*, p. 393; Brun (three cases), *idem*, 1844, p. 580; Robert, *Gazette des Hôpitaux*, 1847, p. 272; von Pitha, Pitha and Billroth's *Chirurgie*, vol. iv. part ii. B, p. 87; Malgaigne, *Luxations*, p. 631; Duguet, *Bulletins de la Société Anatomique*, 1863, p. 278; Mathieu, *Gazette des Hôpitaux*, 1866, p. 330; Waterman, *Boston Medical and Surgical Journal*, 1869, vol. lxxxii. p. 187; Wilson, *Canada Journal of the Medical Sciences*, 1880, vol. v. p. 346; Waters, *Maryland Medical Journal*, 1883, vol. x. p. 402; Loison, *Arch. de Méd. et Pharm. Mil.*, September, 1890, inward; Wight, *Brooklyn Medical Journal*, September, 1889; and Stimson, case here given, both forward.

PLATE XLVII.



Backward Dislocation of the Elbow.

slightly inclined toward the ulnar side; the fold of the elbow was somewhat raised by the projecting trochlea; the olecranon was very prominent behind, but barely raised above its normal level; the elbow was notably thicker, but not broader; the head of the radius was in its place; pronation and supination were but slightly restricted, but the least movement of flexion was very painful. Reduction was easily accomplished by grasping with the left hand the humerus above the condyles, and with the right the forearm in such a way that the thumb and fingers specially compressed the ulna, and then supinating, abducting, and extending until there was slight dorsal flexion; at this moment he distinctly felt the lifting of the coronoid process, and on increasing the traction it suddenly slipped back over the trochlea with a snap. Pain at once ceased, and the patient could flex the joint.

Experiments upon the cadaver by Sédillot and Streubel¹ indicate that the mode of production is similar to that of backward dislocations of both bones together—that is, the forearm is abducted (Streubel) or hyperextended (Sédillot) until the internal lateral ligament yields, and then rotated inward and adducted to carry the coronoid process past the trochlea and engage its point against the posterior surface of the latter. If the adduction is increased, and especially if at the same time the orbicular ligament is torn, the olecranon rises to a higher point and may pass to the inner side. If, on the other hand, adduction is absent and the rotation is prolonged, the olecranon is carried around behind the radius, and the form is produced.

Pathology. Two specimens (Robert, Duguet) and one compound dislocation (Boudant) furnish but scanty information of the pathological details, for which we must mainly depend upon experiment. Of the two specimens, Robert's alone was of a recent case.

Duguet's specimen was taken from a man, fifty years old, who had received the injury twenty years previously. There was ankylosis in the extended position, but pronation and supination were preserved. The ulna was displaced backward and upward so that its upper end was two centimetres above the line uniting the two epicondyles, and a nearthrosis had formed between the tip of the olecranon and the back of the humerus above and a little to the inner side of the olecranon fossa. It is probable, therefore, that the coronoid process was lodged in the olecranon fossa. Concerning the radius two statements are made: the first is that it had preserved its relations with the external condyle; the second, that it was appreciably displaced forward, and preserved its movements of rotation. I understand these to mean that the head was directly below the condyle and a little in front of the position it would normally occupy in that attitude (extension of the limb).

In Robert's case the injury was caused by a fall on the palm of the hand; the limb was partly flexed, the olecranon prominent posteriorly and elevated; the head of the radius could not be felt because of the swelling, but it could be moved backward and forward with cartilaginous crepitus. At the autopsy the coronoid process was found in the olecranon fossa, and the radius in place; the humerus appeared to have

¹ Streubel: Prager Vierteljahrschrift, 1850, ii. p. 54.

been twisted so that its anterior aspect looked outward (in other words, the forearm was adducted); the annular ligament and some of the fibres of the external lateral ligament were torn. The condition of the internal lateral ligament is not mentioned. The brachialis anticus and brachial artery were ruptured.

Boudant's patient was a man forty-nine years old, who had fallen from the first story of a building and received a compound dislocation; the wound was eighteen or twenty lines in length on the inner and anterior part of the elbow, and was thought to have been caused by contact with a large, rough stone. It seems, however, not unlikely that it was caused from within outward by the pressure of the trochlea in hyperextension of the joint. The olecranon, which was prominent posteriorly, could be seen through the wound, and the finger introduced into the latter recognized the radius in place. Reduction was easy, and the patient made a good recovery.

The experiments made upon the cadaver show that the internal lateral ligament is always ruptured, and that the orbicular ligament escapes injury if the displacement is not great.

Symptoms. In the *first* and *second forms*, dislocation backward and upward, the limb is usually in almost complete extension (in Duguet's and Waterman's cases it was flexed at a right angle), and cannot be flexed without causing much pain, but pronation and supination are free and painless. The normal deflection of the forearm toward the outer side is lost, and in its place may be a deflection toward the ulnar side. This deflection is easily recognized by the eye when the limb is extended, but when the joint is flexed at or near a right angle it may be overlooked unless comparative measurements are made; in Diday's case the length of the ulnar border, from the epitrochlea to the lower end of the ulna, was an inch shorter than that of the other arm, while the radial borders were of equal length. The antero-posterior diameter of the joint is increased, and the fold of the elbow is filled out by the trochlea.

The olecranon is prominent behind the humerus, and may rise well above the line of the epicondyles; it may be nearer the epitrochlea than usual. The head of the radius can be felt in its place, and it is by the determination of this fact, together with the displacement of the olecranon, that the diagnosis of the variety of the dislocation is made.

In the two recorded cases of the *third form*, dislocation of the ulna backward and outward behind the radius (Malgaigne, Wilson), the elbow was flexed nearly at a right angle. In Malgaigne's the forearm was pronated and deviated outward; the greater sigmoid cavity was directed outward (*sic*), the coronoid process outward and forward. This attitude of the ulna suggests that the dislocation was not effected by rotation of the forearm.

Treatment. In Duguet's case reduction was not made; in the others it was easily obtained. Waterman tried Cooper's method of the knee in the elbow, and Skey's of traction upon the upper part of the flexed forearm in the line of the humerus, without success, and then easily reduced by hyperextension. The readiest method in the first and second forms appears to be that employed by von Pitha, and described

above—supination, abduction, and hyperextension of the forearm. Malgaigne and Wilson reduced (third form) by direct pressure upon the olecranon, first backward to free it from the radius, and then inward.

(A case described by Richet,¹ as a new kind of dislocation by rotation, seems, from its title and from some of its features, to belong to this class, but the account is so incomplete that it is not available.)

2. Dislocation Inward.

Of this there is only one reported case, Loison's. The patient, a man twenty-four years old, fell backward upon the left elbow, bruising the skin on the inner side an inch below the epitrochlea; the wounds suppurated; the diagnosis was not made until the forty-second day. Then the radius was found in place, and the olecranon displaced inward so that the sigmoid cavity embraced the epitrochlea. Four months after the accident, reduction not having been made, the limb could be actively flexed to 80 degrees and extended to 135 degrees; rotation apparently well preserved.

3. Dislocation Forward.

March 13, 1895, I saw at the Hudson Street Hospital a man thirty-five years old, who had injured his right elbow in falling backward, the arm being caught under him. As he complained of handling I gave ether. The following notes were made at the time: The elbow is held at a right angle, but can be somewhat flexed and extended; is movable laterally. The epitrochlea can be plainly felt, also the inner face and edge of the trochlea, the overlying flexor muscles of the hand having been torn away from the humerus. The tip of the olecranon is below and even a little in front of the trochlea, the inner anterior portion of the articular surface of which can also be felt on depressing the skin. The head of the radius is in place in front of the capitellum. The forearm is markedly abducted.

Reduction was easily made by slight rotation backward (pronation) of the ulna and adduction of the forearm. Then by pronation and abduction the dislocation could be easily reproduced. When the bones were in place abduction of the forearm was possible, but not adduction. Apparently the lesions were avulsion of the flexor muscles from the humerus and rupture of the internal lateral ligament. The ulnar nerve was uninjured.

The only other reported case is Wight's; the symptoms were similar, and reduction was easily made.

DISLOCATIONS OF THE RADIUS ALONE.

Although statistics show that these dislocations are not very rare (1.4 to 4 per cent. in the tables in Chapter XXVII.), and although the

¹ Richet: Nouveau genre de luxation incomplète du coude par pivotement. Gazette des Hôpitaux, 1879, p. 737.

earliest writers mentioned them, yet they were almost completely lost sight of until about one hundred and fifty years ago, and even now are far from being clearly understood. Duverney, in 1751, gave a detailed account of two forms. Since that time observations have accumulated, and four varieties are now well established—the dislocations forward, backward, and outward, and one seen exclusively in children, and caused by traction upon the wrist, the nature of which, though not entirely undisputed, is generally believed to be a diastasis or direct separation ; it is usually termed dislocation by elongation.

The mode of production of all the forms is still obscure, and the numerous experiments that have been made upon the cadaver by various investigators, Roser, Malgaigne, Streubel, Denucé, Pingaud, Barros, while they have shown how the dislocations may be produced upon the cadaver, have not made it clear how they actually are produced in the patients who come under observation ; in some cases the clinical facts directly contradict the conclusions drawn from experiment.

1. Dislocation Backward.

This was one of the forms described by Duverney, and one of the earliest to be accepted as proved by later surgeons. Its apparent frequency is in part due to the inclusion in the list of reported cases of those in which the dislocation is associated with fracture of the internal condyle, and probably also of others which belong in the group of dislocations by elongation. Two varieties are described, the complete and the incomplete, the latter resting upon a few questionable and one well-observed case, that of Denucé :¹ a lad nineteen years old fell from a swing, his pronated arm being caught under his body in such a way that the blow, as shown by an ecchymosis, was received upon the middle of the anterior aspect of the forearm. Pain ; limitation of motion ; the elbow semiflexed, the forearm fixed in complete pronation. A bone-setter tried in vain to reduce it, and a fortnight later the patient consulted Denucé, who found “behind the elbow, on a level with the condyle, and to the inner side of the epicondyle, a small prominent tumor, which rolled under the finger in pronation, and was evidently the head of the radius, a little overlapping its ordinary position posteriorly.”

Of the complete cases the instances are much more numerous, but in some of them the question arises whether the upper surface of the radius had entirely left the articular surface of the capitellum, or was still in contact with it by its anterior portion ; if such contact did exist, the term “complete” can be properly applied only to the separation of the radius from the lesser sigmoid cavity of the ulna.

The cause, in the majority of cases, appears to have been a fall upon the outstretched hand ; that the cause was a fall in most cases is certain, but whether it was upon the hand or the elbow is often far from clear, or whether it acted by direct impulsion or by exaggerated rotation.

In a case reported by Cameron² the character and mode of action of the violence are more clearly shown than usual, but they are entirely

¹ Denucé : *Dict. de Méd. et Chir. pratiques*, art. Coude, p. 777.

² Cameron : *Lancet*, 1884, vol. i. p. 885.

exceptional, and the case does not aid to clear up the obscurity in which the question is enveloped. The patient was a man fifty-two years old, who was caught between a wall and a cart backing against it in such a way that his forearm was compressed lengthwise between them, the palm of the hand being pressed against the cart, and the back of the elbow against the wall; probably the hand was completely pronated. When seen, immediately after the accident, the head of the radius lay just under the skin behind the external condyle, where it formed a distinct projection, revealing to the eye its characteristic shape with the cavity on its extremity. The hand and forearm were prone; all movements were painful, and gave the impression of considerable fixity of the joint. Pain at the wrist led to an examination, which showed that "the styloid extremity was also dislocated downward, exactly as in cases in which the radius is shortened by the common fracture of its lower extremity."

While the character of the force and the direction of its action in this case are clear, pressure exerted against the lower end of the radius in the line of its long axis, yet it is far from being clear how such a force, so applied, could produce such a displacement, for the head of the radius is squarely placed against the anterior face of the capitellum, not upon an inclined surface along which it could be displaced. And yet, that there is something in the anatomical structure of the joint which permits the occurrence and forbids the rejection of the case on the supposition of abnormal conditions, is indicated by the fact that two similar cases have been reported by Wagner,¹ in which the mode of production was the same as in Cameron's, but the head of the radius was displaced to the outer side of the condyle instead of behind it, and a flat, wedge-shaped piece was broken off its inner side.

Streubel,² in his experiments upon the cadaver, found that he could produce the dislocation in only one way, by hyperextending the supinated forearm until the head of the radius had been carried completely behind the line of the condyle, then forcing it upward, and at the same time bending the forearm to the radial side, and finally flexing it again while holding the radius pressed firmly back with the thumb of the hand that grasped the forearm. It is by no means probable that this rather complicated manœuvre, which, moreover, has entirely failed in my hands, is a reproduction of what has taken place in the falls that have produced the dislocation. The radius is dislocated not only from the humerus, but also from the ulna, and this requires the rupture of the orbicular ligament. To effect that, something more is required than hyperextension of the elbow, even with the addition of direct propulsion upward of the radius. Supination of the forearm will not effect it, and while direct propulsion backward of the bone would undoubtedly produce the dislocation, the clinical facts do not indicate this as the cause. Possibly in hyperextension and outward lateral flexion, as in Streubel's experiments, the head of the radius may become engaged behind the slight projection of the articular surface of the capitellum at the bottom of the condyle, and be thereby prevented from accom-

¹ Wagner : *Beilage zum Centralblatt für Chirurgie*, 1886, No. 24, p. 93

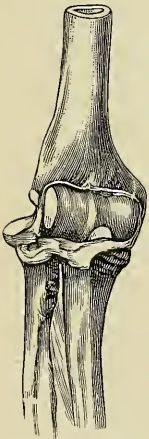
² Streubel : *Prager Vierteljahrsschrift*, 1850, vol. ii. p. 68.

panying the ulna in its return forward when the elbow is again flexed ; this would supply the strain necessary to separate the radius from the ulna, but I must add that all the attempts I have made thus to produce the dislocation were fruitless ; the result was always a dislocation of both bones.

There are no post-mortem records of recent cases, and the dissection of those of long standing is not an entirely trustworthy indication of the condition and the relations of the parts when the injury is fresh. A case observed by Mr. Rivington¹ is of particular importance, because the position of the head is more exactly noted than is usual in the descriptions. The patient was a lad fourteen years old, and the injury had been received five months previously in a scuffle, during which he was violently shaken by the forearm, and thrown down, striking his elbow against the leg of a table. There was a marked prominence "at the back of the joint below the external condyle, and by the side of the olecranon process." "The head of the radius was displaced more directly backward than is usual, according to the descriptions of the books, not lying in any wise behind the external condyle, but a little overlapping the articular end of the humerus." Flexion and extension were almost unimpaired, pronation was good, and supination to more than half the usual extent. Reduction failed.

In a specimen of an old dislocation, which had been received in childhood and had existed for many years, presented by Petit² to the Société Anatomique, the head of the radius was directly below the summit of

FIG. 310.



Dislocation of the head of the radius backward. (COOPER.)

the epicondyle when the elbow was flexed at a right angle. In another specimen found in the dissecting-room and described and figured by Sir Astley Cooper, "the head of the radius could be seen, as well as felt, behind the external condyle of the os humeri. The coronary ligament was torn through at its forepart, and the oblique had given way. The capsular ligament was partially torn, and the head of the radius would have receded still more, had it not been supported by the fascia which extends over the muscles of the forearm. The accompanying figure (Fig. 310) indicates that the head of the radius had risen very slightly above the lowest part of the articular portion of the condyle, and that its position was probably the same as in Mr. Rivington's case.

In another specimen of old dislocation presented to the Société de Chirurgie by Bernadet,³ the head of the radius had been displaced a little backward, downward, and outward ; the external lateral ligament entirely covered the cup-shaped surface of the head ; the annular ligament no longer existed except upon the inner side, and there it was notably thickened and obliquely deviated.

¹ Rivington : *Lancet*, 1879, vol. ii. p. 942.

² Petit : *Bull. de la Société Anatomique*, 1874, p. 904.

³ Bernadet : *Bull. de la Soc. de Chir.*, 1861, p. 462.

In the specimens which Streubel obtained by experiment he always found the anterior portion of the capsule torn and the capitellum projecting through the rent; the external lateral ligament was more or less torn at its anterior border, the internal lateral ligament uninjured; the annular ligament was always torn in front, either at its insertion by the lower sigmoid cavity, or further outward; the oblique ligament was torn, doubtless in consequence of the exaggerated supination.

These facts, though not numerous or entirely free from objection, indicate that the position of the dislocated head of the radius, even in full extension, is lower than that commonly assigned to it in systematic descriptions and shown in the plates accompanying them—that it does not rise above the shallow groove which marks the posterior and lower margin of the articular surface of the capitellum. At this point the upper margin of the head would be but very little below the axis of the joint, and consequently would have to move over only a short distance in full flexion and extension of the limb.

In recent cases the elbow is slightly flexed, the forearm pronated; voluntary and communicated movements are painful and limited in range, but in old cases the freedom of motion is almost completely restored, supination remaining the most imperfect. The diagnosis is made by recognition of the head of the radius behind its normal place in extension, behind and below it in flexion at a right angle. It may lie close beside the olecranon or further to the outer side. Its projection, unless the swelling is considerable, is such that the entire extent of its concave upper surface can be felt. Measurement of the radial border of the forearm from the epicondyle to the styloid process of the radius may show some shortening, half an inch according to Streubel.

Treatment. The dislocation in recent cases has usually been reduced promptly by pressure on the head of the radius, aided or not by traction upon the wrist, and this method has succeeded even when several weeks had passed since the receipt of the injury. But in some cases reduction has been impossible or the displacement has shown a marked tendency to recur, both circumstances probably due in the recent cases to the interposition of a portion of the capsule, but in the older ones also to permanent change in the relations of the shafts of the radius and ulna and to adhesions between them. This interposition of the capsule has been demonstrated in one or two cases in which arthrotomy has been done (see Chapter XLVII.). Probably the best position to give the limb during the attempt is that of supination and full extension, and if direct pressure does not then restore the bone to its place traction should be made at the wrist, and the forearm gradually bent to the inner side, and then the direct pressure renewed.

In some old cases excision of the head has improved function.

2. Dislocation of the Radius Outward.¹

Excluding the cases in which the dislocation is accompanied by fracture of the ulna in its upper portion and those in which the displace-

¹ For bibliography see: Nélaton, *Path. Chir.*, vol. ii. p. 400; Gerdy, *Arch. gén. de Méd.*, 1835, vol. vii. p. 161; Parker, *New York Journal of Medicine*, 1852, p. 189; Pitha and

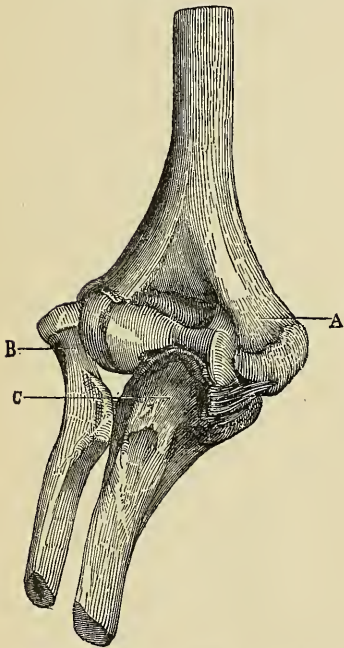
ment outward is comparatively slight and is associated with a more important displacement backward or forward, the recorded instances of this injury are very few, and in some of these, even, the description justifies a doubt whether they should not rather be placed in one of the two other classes.

In Nélaton's case the dislocation occurred in childhood and had existed for twenty years; the position of the radius is shown in Fig. 311. Flexion and extension were preserved; supination was impossible.

Wagner reported to the German Surgical Congress, in 1886, three cases of dislocation outward complicated by fracture of the inner portion of the head of the radius. In the first two cases the injury was caused by pressure against the back of the flexed elbow while the palm of the hand was resting against a firm object in front. Thus, a lad, eighteen years old, pushing a coal-wagon on a tramway with his forearm pronated and flexed, was struck on the elbow by another wagon coming up from behind. A year had elapsed since the accident when the first case was seen, during which the joint had been steadily growing stiffer. The elbow was flexed at a right angle; flexion, extension, and rotation were almost entirely lost. On the outer side of the external condyle was a large bony prominence, the thickened and immovable head of the radius; there were no abnormalities in the other parts of the joint, and no sign of a fracture of the ulna. The head of the radius was excised; it was found thickly enveloped in fibrous tissue, to which the appearance of thickening was due, and had lost from its inner side a flat, wedge-shaped piece constituting about one-sixth of its diameter. The fragment was found adherent to the capsule and was also removed. Recovery took place without accident, and the mobility of the joint steadily increased for some time. At the time of the report, nine years later, flexion could be made to an angle of 80 degrees, extension to 150 degrees, pronation was almost normal, supination somewhat restricted.

In the second case, a man, twenty-six years old, was injured in the

FIG. 311.



Dislocation of the head of the radius outward; the trochlea is much broadened. (NÉLATON.)

Billroth, *Chirurgie*, vol. iv. Part II. B. p. 92; Pingaud, *Dict. Encyclop. des Sc. Méd.*, art. Coude; Wagner, *Beilage zum Centbl. für Chir.*, 1886, No. 24, p. 93; Löbker, *ibid.*, p. 92; Bartels, *Arch. für klin. Chir.*, 1874, vol. xvi. p. 643; Schröter, *ibid.*, vol. xlvi. p. 4. Thomassin's and Chédieu's cases, quoted by Malgaigne, seem to belong among the anterior dislocations.

same manner, and was seen while the injury was fresh. Reduction was effected, after several unsuccessful attempts, by, first, adduction of the flexed limb, then by the utmost possible abduction, with supination, of the completely extended limb, combined with pressure upon the head of the radius. When the dressings were removed, a month later, passive movements were very painful and limited, and, as no improvement followed, excision was done five months after the accident. The head of the radius was found thickened and absolutely fixed, and the fragment reunited to it by a loose fibrous union; the failure of union was attributed to the interposition of a small piece of the articular cartilage. Recovery followed without accident, but the mobility of the joint was not increased.

In the third case the patient had received his injury twenty-two years before, when six years old, by a fall from a horse. "The head of the radius stood outside upon the external condyle," and was flattened on its inner side; there was no sign of any injury to the ulna. The movements of the joints were completely normal.

Löbker, in a paper read before the same congress, reported two cases of the same combination of dislocation outward with fracture of the inner portion of the head of the radius treated by excision. In each case the fragment had become united to the adjoining parts by a pedicle.

Of the 26 cases collected by Schrötter 3 were complicated with fracture of the head of the radius and 13 with that of the ulna.

Bartels reported a unique case in which the heads of both radii had gradually become displaced outward. The patient was a man forty-three years old, who, while lying in hospital with a broken leg, called the surgeon's attention to his elbows. He said that the deformity dated from his eleventh year; his father had at that time put him at hard work, usually pushing a loaded cart; pain was soon felt in the elbows, and increased steadily, but he was kept at work. The head of the radius rested on the outer side of the external condyle when the limb was fully extended and supinated; when extended and pronated, the head was less prominent, and rested partly on the outer part of the articular surface of the capitellum, and when flexed and pronated the head returned to its place.

Barros could produce the dislocation experimentally in only one way, by pressure against the ball of the hand, and simultaneous forcible adduction of the forearm, by which the external lateral ligament was torn.

The general symptoms in the recent cases showed no special or characteristic features; the limb appears to have been partly flexed and pronated, and the movements of the joint restricted. In the older cases, the normal movements were more or less completely re-established.

The diagnosis is made by recognition of the presence of the head of the radius on the outer side of the condyle. Reduction, except when there is fracture of the head or interposition of the torn orbicular ligament, should be easy by adduction of the forearm and direct pressure on the head of the radius.

3. Dislocations Forward.

These are the most common of the three varieties, even excluding from them the not unusual subluxation which occurs in children, and will be described in the next section, and those cases which are complicated by fracture of the ulna (*vide infra*). The dislocation is characterized by the position of the head of the radius in front of its normal position when the forearm is extended, and above it when the forearm is flexed at a right angle. Several authors describe two forms, the complete and the incomplete, including in the latter those cases in which in flexion at a right angle the head of the radius has not entirely left the articular surface of the capitellum, but remains in contact with its upper portion. The distinction between complete and incomplete is an arbitrary one and does not seem to deserve to be retained, for even in the former the head of the radius sometimes descends upon the articular surface of the capitellum when the limb is extended.

The causes mentioned in the reported cases include falls upon the hand or upon the elbow, and traction upon the forearm. In experiments upon the cadaver the dislocation has been produced by forced pronation, in which, according to Filugelli, quoted by Streubel, a fulcrum is established by contact between the radius and ulna in their upper third at the point at which they cross, the effect of which is to cause the head of the radius to move forward and inward, with rupture of the anterior portion of the annular ligament when the pronation is exaggerated.

As in the two preceding varieties, the mode of production is far from clear. That the head should be displaced by direct violence is not difficult to comprehend, but the cases in which this mode of production can be invoked are few. Traction upon the forearm, combined probably with exaggerated pronation, must also, I think, be admitted as an occasional cause, especially in children, both because of its efficiency to produce the dislocation upon the cadaver, and because the histories of one or two cases in adults are not open to any other explanation, as in Boyer's case of the footman who slipped while getting up behind a carriage, and remained suspended by his hands. It seems probable that some of the cases in which the injury was received in childhood, and remained unreduced, may have been dislocations by elongation, and that the head remained fixed in its new position, or perhaps was still further displaced by use. In a fall upon the hand, it seems probable that the dislocation could be produced only by hyperextension and pressure upon the lower end of the radius, aided by supination or pronation, and this opinion is confirmed by experiment. A case of Malgaigne's¹ seems to support this theory, for at the patient's death, seven weeks after the accident, the posterior fourth of the head of the radius was found to have been broken off. In two of Löbker's² cases a piece was broken from the outer portion of the head, which suggests, what is probable also on other grounds, that abduction of the forearm may also be a factor.

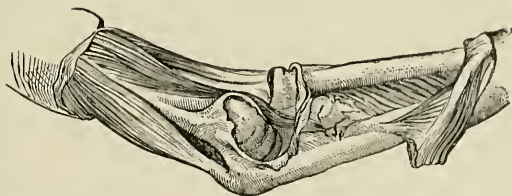
¹ Malgaigne: *Loc. cit.*, p. 651.

² Löbker: *Beilage zum Centralblatt für Chir.*, 1886, No. 24, p. 92.

In a case reported by Ross¹ the dislocation occurred during an epileptic convulsion and was attributed to muscular action, the unopposed contraction of the biceps and pronator radii teres.

Pathology. No autopsies have been reported in recent cases. In experiments upon the cadaver (Strenbel, Pingaud) the capsule has been found torn transversely in front close to its attachment to the humerus (Fig. 312), and the annular ligament untorn and encircling only the neck of the radius while the head projected forward through the rent in the capsule and rested, by its posterior edge only, against the articular surface of the capitellum.

FIG. 312.



Hilton's case of dislocation of the head of the radius forward.

In a number of cases, ten or twelve, the opportunity has arisen to examine old dislocations. Malgaigne has described his own, quoted above, in which the posterior fourth of the head of the radius was broken off and the capsule was intact, and two specimens in the Musée Dupuytren (cases of Desault and Prestat). Cooper² describes and figures a specimen preserved at St. Thomas's Hospital; the others are those of Danyau,³ Debruyne,⁴ two cases, Hilton,⁵ Trélat,⁶ Krönlein,⁷ a specimen in the Museum at Zurich, and Löbker, the two cases above referred to; see, also, Schrötter.⁸

In Malgaigne's, Danyau's, one of Debruyne's, Trélat's, and the two specimens of the Musée Dupuytren the annular ligament was stretched but not torn; in Hilton's its upper portion was torn, but the more external and superficial fibres remained intact and were closely wrapped about the neck of the radius; in Cooper's the annular, oblique, fore-part of the capsular, and a portion of the interosseous ligament were torn through. With reference to some of these cases the question has been raised whether the annular ligament found at the autopsy was not one of new formation.

The head of the radius rests, in partial flexion, upon the anterior surface of the external condyle above and usually somewhat to the inner side of its normal position, and either in contact with the coracoid process or (Hilton) separated from it by the interposed tendon of the brachialis anticus. In some cases a piece has been broken from its posterior or outer border. In several of the cases a hollow had

¹ Streubel: *Loc. cit.*, p. 75.

² Cooper: *Loc. cit.*, p. 392.

³ Danyau: *Annales de la Chir. Française et Etrangère*, 1841, vol. ii. p. 72.

⁴ Debruyne: *Annales de la Chir. Française et Etrangère*, 1843, vol. ix. p. 88.

⁵ Hilton: *Guy's Hospital Reports*, 1847, vol. v. p. 93.

⁶ Trélat: *Bull. de la Société Anatomique*, 1858, p. 487.

⁷ Krönlein: *Deutsche Chirurgie*, Lief. 26, p. 44.

⁸ Schrötter: *Arch. für klin. Chir.*, vol. xlv.

formed for its reception on the anterior surface of the humerus ; the new articulation was either entirely above the old one, or included the upper part of the capitellum, or (Trélat) extended over the outer portion of the front of the trochlea. The head of the radius was deformed and had suffered the loss of more or less of its cartilage of incrustation ; in some cases it was enlarged, in others diminished in size. In Krönlein's specimen an extensive outgrowth of bone had formed upon the inner side, giving the upper end of the bone an appearance similar to that of the upper end of the femur, and articulating with a new cavity upon the humerus ; it is stated that the movements of rotation had been completely restored.

An interesting feature in Hilton's case was that the radius had been displaced bodily upward along the ulna, and this displacement had produced changes at the wrist.

Malgaigne observed and called especial attention to abduction of the forearm, which does not appear to have been observed by others. It furnishes a satisfactory explanation of the displacement of the radius upward as well as forward, which could not otherwise be accounted for except by such a change in the level of the bones at the wrist as was noted in Hilton's case. Abduction of the forearm might easily be overlooked while the joint is partly flexed unless comparative measurements are made.

Symptoms. The elbow is slightly flexed and the forearm almost always more or less pronated ; in a few cases supination has been present. Voluntary and communicated movements are painful, and of the latter flexion nearly to a right angle and almost complete extension are possible, pronation is usually complete, but supination much restricted. Abduction of the forearm has been noted, possibly it is quite common, and when present it can be demonstrated by comparative measurements of the radial borders of the two forearms, the injured one being shortened. The region of the elbow is swollen in front and on the outer side ; the absence of the head of the radius from its normal position is shown by the depressibility of the soft parts on the outer side of the joint below the condyle, and its presence in the fold of the elbow can generally be recognized by the finger ; sometimes it is so prominent there that it appears to be subcutaneous, and the saucer-like depression of its upper surface can be traced when the joint is extended. Flexion of the forearm is abruptly arrested at or near a right angle by the impact of the head of the radius upon the front of the humerus.

In the older cases the restoration of function may be almost complete, the range of motion being limited only in extreme flexion and supination.

In Hilton's case the associated changes at the wrist caused a corresponding deformity there, abduction of the hand ; and it seems not unlikely that even in some recent cases the wrist may be painful or distorted.

Treatment. Reduction has been easy in some recent cases, and difficult or impossible in others. The measures which have been most successful are traction upon the radius at the wrist, the forearm being supinated and extended, combined with pressure upon the head of the

radius. Malgaigne suggests, very properly, that adduction of the forearm would be more likely than traction to overcome the overriding of the radius. Hilton reduced the displacement in his specimen, which had existed for many years, by placing a small wedge between the upper surface of the radius and the humerus, and then flexing the forearm by pressing upon the lower end of the ulna; when flexion was nearly complete direct pressure upon the head of the radius forced it backward into place. The effect of this device was to displace the radius downward along the ulna to a distance equal to the thickness of the wedge, and to rupture the ligaments which bound the two bones together. A marked tendency to recurrence has been frequently noticed, and has generally been attributed to interposition of a portion of the capsule. I am inclined to think it due, in some cases at least, to the persistence of this bodily displacement of the radius upward. If so, the condition would be shown, after reduction, by loss of the outward inclination of the forearm in full extension, and the effort should be made to overcome it by restoring this angle by forcible abduction.

The position of the rent in the anterior portion of the capsule suggests that after reduction the joint should be kept flexed, and although recurrence of the dislocation has taken place with the limb in this position, it does not seem so likely to favor such recurrence as the extended position.

4. Dislocation by Elongation, or the Subluxation of Young Children.¹

Under these names is described an injury which is very frequently observed, but the nature of which, after nearly two centuries of discussion, is still in dispute. Its features are well marked; a young child, generally less than three years old, is lifted or pulled by the hand; it cries out with pain, and refuses to use the limb, which hangs motionless by the side, somewhat flexed at the elbow, and more or less pronated. A careful examination fails to discover marked changes in the anatomical relations of the bones at the elbow or wrist; passive motion at both joints is free, but painful, except supination, which is resisted; often during the manipulations made in the examination, or on forced supination, a slight click is heard, and the child at once is able to use the limb freely without pain.

As early as 1671 Fournier described the injury as an incomplete dislocation characterized by relaxation of the ligaments and elongation of the radius, meaning by the latter direct separation downward or diastasis. Nearly a hundred years later, Duverney gave a clear and

¹ The papers upon this subject are numerous; the following bibliography contains the more important: Gardner, *London Medical Gazette*, 1837, vol. xx. p. 878; Hodges, *Boston Medical and Surgical Journal*, 1862, vol. lxxvii. p. 129; Goyrand, *Gazette médicale de Paris*, 1837, p. 115, and *Bull. de la Société de Chirurgie*, 1861, p. 605; Pingaud, *Dict. Encyclopédique*, art. Coude, p. 580; Hamilton, *New York Medical Journal*, Jan. 3, 1885, p. 8; Duverney, *Maladies des Os*, 1751; Bouley, *De radii superioris extremitatis dimotione, in infantibus frequentiori*, 1787; Rendu, *Gazette médicale*, 1841, p. 301; Perrin, *Journal de Chirurgie de Malgaigne*, vol. v. p. 145; Streubel, *Prager Vierteljahrsschrift*, 1850, vol. ii. p. 90; Van Arsdale, *Annals of Surgery*, June, 1889; A. Broca, *La pronation douloureuse des jeunes enfants*, *Gaz. des Hôp.*, 1903, No. 56.

exact description of it as an injury occurring frequently in children ; he attributed it to forcible traction at the wrist, and gave as its chief symptom the opposition to supination of the forearm, and as the treatment forcible supination with pressure from before backward upon the head of the radius followed by flexion of the elbow. He thought the injury was not merely an elongation of the radius, but also the escape of its head below the edge of the orbicular ligament. Nearly a century and a half has passed since the publication of his views, and but little has been added to his description of the etiology, symptoms, or treatment, and while the years have brought many other theories concerning the pathology his is the one that is now most widely held.

In 1787 Bontentuit presided at the presentation, and, according to Malgaigne, was probably the real author, of a thesis by Bouley before the *Écoles de Chirurgie*, in which the theory of the agency of forced pronation in the production of the injury was advanced ; it was argued that in this movement the radius and ulna came into contact at the point where they crossed each other near the elbow, and that, the movement being continued, the head of the radius was displaced forward or outward.

At the beginning of the present century Martin, in France, 1809, and Monteggia, in Italy, 1814, described the injury and reported cases, but the former, unfortunately, appears to have encountered also some dislocations backward, and he not only included them in the same group, but he also thought that the radius was dislocated backward in all, and this opinion has survived in a measure until the present time, and has led systematic writers to describe a dislocation backward as one of the forms, although it does not appear that there is any other authority for the statement than Martin.

As the injury is one that seems but rarely to fall under the observation of the general surgeon, probably because of the facility with which it is reduced, the authors of the surgical text-books either made no mention of it or followed in their brief descriptions the account given by Martin, or by those who had copied from him. But between 1836 and 1850 several cases were published in England and in France, and new theories concerning its nature were advanced. Gardner in 1837 and Rendu in 1841 attributed the fixation to the locking of the bicipital tuberosity behind the ulna, but the latter, who in two cases had made the important observation that the wrist also was swollen and tender, added to this supposed locking of the tuberosity, which he regarded as probably exceptional, a rupture of the ligaments of the wrist. Perrin, in 1849, thought the head of the radius was caught below the lower edge of the lesser sigmoid cavity, and Goyrand, who saw a large number of cases, thought the lesion was an incomplete dislocation, in which the displacement was so slight as to cause no recognizable deformity at the elbow. Malgaigne, 1854, included it among the incomplete dislocations forward, and others did likewise.

In 1850 Streubel made the theory of incomplete luxation more definite, by showing that if the forearm of the cadaver of a young child was forcibly pronated, the head of the radius moved forward, and the posterior portion of the capsule was forced in by atmospheric

pressure between the radius and the capitellum, and that if then the pronation was diminished, the slight displacement of the radius and the interposition of the capsule would persist even while gentle movements of the joint were made; but that under sudden extension and supination the normal relations would be established. In like manner, forced supination would displace the radius backward, and lead to interposition of the anterior portion of the capsule. In the bodies of adults neither manipulation would produce this result.

In 1856 Chassaignac¹ described, under the title "*paralytic douloureuse des jeunes enfants*," a number of cases of the injury under discussion, together with others of a different nature, and attributed the symptoms in all to injury of the nerves of the limb. Finally, in 1861, Goyrand² returned to the subject in a lengthy paper, in which he abandoned his previous view and advanced the last new theory, that the lesion was situated not at the elbow, but exclusively at the wrist, and consisted in a dislocation of the triangular fibro-cartilage in front of the lower end of the ulna. His experiments showed that in complete pronation the fibro-cartilage was carried so far forward as almost entirely to uncover the end of the ulna, and that in forced pronation the uncovering became complete. In reply to a question asked by Velpeau, he admitted that the displacement did not persist upon the cadaver unless the hand was held upward and supinated, but he thought that the tonic contraction of the muscles in the living would maintain it. He did not explain why such a lesion should be more easily produced in a child than in an adult.

It may be worth while to add that the editor of the *Medico-Chirurgical Review*, in 1839, thought the injury was a separation of the upper epiphysis of the radius, and Fougéu, in 1861, a separation of the lower one.

Pingaud,³ in his experiments upon the cadaver, found, as Goyrand had similarly done in 1837, that the head of the radius could be drawn out through the orbicular ligament by forcible adduction of the forearm, so far that its anterior edge would engage below the lower border of the ligament (Fig. 313), and the bones would remain separated by a distance of about a quarter of an inch, but without displacement of the radius forward, backward, or outward, unless forced pronation was added to the adduction, in which case the head moved forward; and as this condition of the parts coincided with a limitation of the freedom of rotation of the forearm similar to that observed clinically in the cases in question, and as the normal relations of the parts were restored by the same manœuvres which relieved the little patients, he reached the conclusion that the nature of the lesion observed clinically was the same as that which he had produced experimentally, and that the clinical injury was, therefore, a dislocation of the radius downward below the annular ligament, or, in other words, that Duverney's theory was the correct one. He showed further, that the younger the child the more easily could this displace-

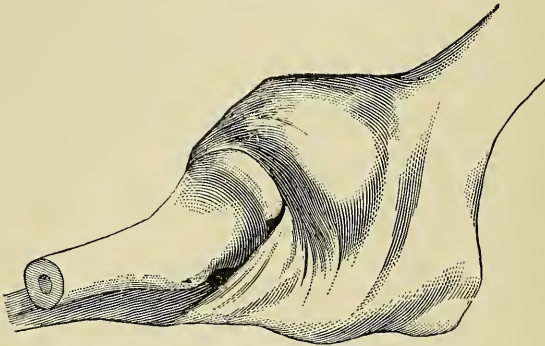
¹ Chassaignac: *Archives générales de Méd.*, 1856, vol. i. p. 653.

² Goyrand: *Bull. de la Société de Chir.*, 1861, p. 596.

³ Pingaud: *Loc. cit.*, 1878.

ment be effected, and the more complete, circularly, would it be. He would not assert that this was the only cause of the clinical condition, but contented himself with proving that it was at least one; his reserve being apparently due to the inapplicability of the explanation to the reported cases in which the radius was said to have been displaced backward, cases which we have seen to rest only upon Martin's assertion. His experiments have been repeated, and his results verified by others; Poincot accepts his explanation fully for the usual cases, and Streubel's for those of displacement backward.

FIG. 313.



Subluxation of the head of the radius. (PINGAUD.)

Turning now to the clinical evidence, for there have been no post-mortem examinations, it appears that the injury is common in young children between the ages of one and three years, and is rarely seen after the age of six years, and not infrequently recurs. Goyrand (*loc. cit.*, 1861) had seen at least two hundred cases in thirty years, and quotes Chabrely (*Journal de Médecine de Bordeaux*, October, 1860, p. 481) as saying that hardly a month passed, he might say hardly a week, in which he was not called to a case, and Fougé as having seen thirty-five cases; in the discussion that followed the reading of Goyrand's paper, Marjolin stated that he had seen about sixty cases. Snedden¹ saw ten cases in ten years in private practice; and Lindeman² saw twenty-four cases and Van Arsdale one hundred in two years in dispensary practice. The cause is traction upon the arm at the hand or wrist, as in lifting a child, or in holding it when it stumbles, and in two cases in drawing the arm through the sleeve of the dress. It seems to me that exaggerated pronation does not enter into the mechanism by which the lesion is produced, but that the violence is simply traction exerted upon the extended elbow, possibly combined with adduction, for traction would tend to make the limb exactly straight, and thus overcome the normal inclination of the forearm outward; or the grasp upon the forearm may be so firm that an actual inward inclination would be produced in case the effort was not a simple traction, but was combined with a movement that tended to swing the child

¹ Snedden: *British Medical Journal*, 1882, vol. i. p. 499.

² Lindeman: *British Medical Journal*, 1885, vol. ii. p. 1058.

upward along a curve whose centre was its wrist and whose radius was its extended arm. At least, in lifting a living child by the arm I have not been able to make exaggerated pronation, for rotation at the shoulder is so free that the limit of pronation is not easily reached, and this is unquestionably true when the child is lifted by both hands.

The child at once cries out in pain and refuses to use the limb, which hangs motionless by its side, or is supported, with the elbow slightly flexed, across the front of the abdomen; the wrist is completely or partly pronated. Examination shows sensitiveness at the outer portion of the elbow, in some cases also at the back of the wrist, and in others exclusively at the wrist, with swelling after the lapse of from thirty to thirty-six hours. The head of the radius is sometimes slightly but distinctly displaced forward, but in most cases no other change than a slight longitudinal separation between the radius and the capitellum is recognizable. There is pain on pressure over the head of the radius.

Although the child does not voluntarily move the joint, it can be freely moved by the surgeon in every direction except supination, and will sometimes be held by the child in such a position as may be given to it. In only one recorded case, Dugès,¹ was the limb in supination; with that exception the constant and pathognomonic symptom is the interference with supination.

These facts, taken in connection with the results of experiment, indicate that Duverney's opinion was correct and that the injury consists in the escape of the front portion of the head of the radius below the orbicular ligament, and that it is produced by traction and adduction of the extended forearm. Goyrand's last explanation—dislocation of the triangular fibro-cartilage at the wrist—cannot maintain itself against the overwhelming clinical evidence of the existence of a lesion at the elbow, supported, as it is, by experiment, especially since it has no better foundation than the impression that the click which was heard during reduction was produced at the wrist and not at the elbow. Against its correctness are the facts that although exaggerated pronation will effect such a dislocation, yet there is nothing to prove that the displacement will not immediately correct itself when the limb is released, and that there is not only no proof of the intervention of exaggerated pronation in clinical cases, but it was, furthermore, certainly absent in some, and probably in all. The only difficulty is to explain the well-established symptoms of injury at the back of the wrist in some of the cases. Possibly such cases may be of a different character from the others, actual dislocation backward of the lower end of the ulna (*vide infra*), and Goyrand's explanation may be true of them; or the symptoms may be due to an associated sprain of the wrist.

The experience of Chassaignac, who treated his cases as paralytic and saw them gradually recover, indicates that the lesion may be spontaneously corrected; but, on the other hand, there is reason to think that some of the cases of forward dislocation of the head of the radius

¹ Dugès: Journal hebdomadaire, 1831, vol. iv. p. 196.

found in adults, which had existed from childhood, were originally of this kind, and that the head had gradually become displaced further forward. All who have treated cases agree that reduction is easily effected, usually by supination ; some add flexion of the elbow.

DISLOCATION OF THE HEAD OF THE RADIUS WITH FRACTURE OF THE ULNA.

The coincidence of a fracture of the shaft of the ulna with dislocation of the head of the radius is not infrequent, and, since the discovery of either of the two injuries may lead the surgeon to overlook the other, the possibility of the coexistence should always be borne in mind. Malgaigne attached so much importance to this warning that he formulated and italicized the following two recommendations :

1. In any fracture of the ulna alone look for a dislocation of the radius.

2. In every fracture of the forearm in which the swelling extends above the elbow, remember that simple fracture is rarely accompanied by so much swelling, and carefully explore the articulation.

To complete the warning a third precaution should be added, namely, that in every dislocation of the head of the radius alone, fracture of the ulna should be sought for.

The complication has received the attention of most systematic writers upon dislocations, and has been made the subject of monographs by Malgaigne,¹ Greiner,² and Dörfler.³ The latter collected nineteen cases, but the injury appears to be of more frequent occurrence than this fact would indicate, for Malgaigne saw four cases, von Pitha two or three, and Dörfler reports four cases from the practice of the surgeon under whom he was serving. I have seen at least ten.

The cause in a certain number of cases—five of Dörfler's nineteen—has been direct violence, as the kick of a horse, received upon the inner or inner and posterior aspect of the upper part of the ulna, first breaking that bone and then driving the head of the radius forward and outward from its place ; in others it has been a fall upon the arm, and it is uncertain whether the ulna was broken by direct or indirect violence. In Gerdy's case the patient declared that he fell upon his extended hand ; and in one that came under my care in August, 1885, the patient, a boy seven years old, had fallen from a wagon and sustained a compound fracture of the ulna at its middle, the wound in the skin being in the centre of the anterior aspect of the limb and having been produced from within outward by the sharp end of one of the fragments ; the radius was displaced forward, upward, and inward so far that its concave upper surface could be distinctly felt. There was no bruise on the back of the forearm, and I thought the fracture had been produced by indirect violence, a fall on the hand.

¹ Malgaigne : *Revue médico-chirurgicale*, vol. xiii. pp. 82 and 90.

² Grenier : *Recherches sur la luxation du radius que complique la fracture du tiers supérieur du cubitus*. Thèse de Paris, 1878.

³ Dörfler : *Fractur der ulna in ihrem oberen Drittel combinirt mit Luxation des Radius* ; *Deutsche Zeitschrift für Chir.*, 1886, vol. xxiii. p. 338.

The only autopsical record I have found is one by Marchand,¹ and, unfortunately, it is not entirely clear. It is stated that the external lateral ligament was torn, the ulna was broken in its upper third, and the head of the radius was displaced to the outer side of the epicondyle; the annular ligament was untorn, but "no longer surrounded the neck of the radius; it seemed rather to embrace the radial capsule (cupule, head?), and the radius seemed to have escaped below it."

Dörfler's experiments showed that the parallelism of the radius and the lower fragment of the ulna was preserved, with production of an angle in the ulna at the point of the fracture; the annular and anterior ligaments were torn. The limb was shortened, and crepitus was perceived on handling it. Clinically, a prominent feature is the marked swelling at the elbow, due in part to the displacement of the radius and in part to inflammatory reaction. The displacement of the radius is usually forward, sometimes forward and inward, forward and outward, or directly outward.

Among the complications were observed subluxation of the lower end of the ulna, wound of the integument either by the direct action of the causative violence or from within outward by the end of the fragment, making the fracture compound, fracture of the epicondyle or external condyle, and more or less paralysis of the extensor muscles of the wrist and fingers due to stretching or rupture of the musculospiral or posterior interosseous nerve.

The prognosis is good if the displacements are promptly corrected; and even if the dislocation of the radius persists the restoration of function may be nearly complete.

On the other hand, failure of union of the fracture has been noted (Norris²), and persistent extensor paralysis (Dörfler).

Reduction in recent cases has been easy; the most suitable method appears to be traction upon the extended limb, followed by direct pressure upon the radius and then by flexion of the elbow. The extended position during traction is desirable in order to avoid the interposition of the torn anterior ligament. After reduction the limb should be kept flexed within a right angle, and midway between supination and pronation.

¹ Marchand: Bull. de la Société Anatomique, 1874, p 680.

² Norris: American Journal of the Medical Sciences, vol. xxxi. p. 20.

CHAPTER XLVII.

DISLOCATIONS OF THE ELBOW.—(CONTINUED.)

Treatment of Old Dislocations—Congenital and Pathological Dislocations.

TREATMENT OF OLD DISLOCATIONS.

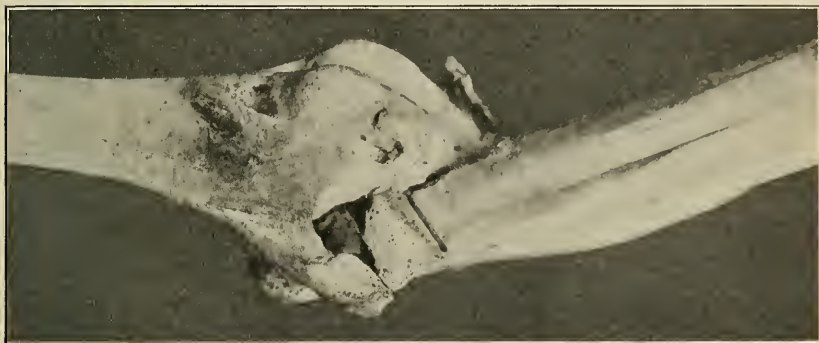THE loss of mobility in old dislocations of the elbow, especially of the backward ones, is often so great that the disability is serious; the patient is unable to bring the hand to the head or chest, and is able to use it only in the arc of a circle whose radius is nearly equal to the length of the extended limb, and he may, in addition, possess only such rotation as can be effected by movements at the shoulder. Although successful attempts to reduce dislocations of several months' standing were occasionally reported, yet failure was the rule, and the only means of alleviating the conditions were fracture of the olecranon and excision of the joint, operations which, while they increased the range of motion, brought with them disadvantages of their own, such as loss of active extension and lack of solidity, which disinclined the surgeon to offer, and the patient to accept them.

Consideration of the anatomico-pathological conditions of an old unreduced backward dislocation not only fully explains the difficulty of effecting reduction, but even makes it appear surprising that reduction should ever have been satisfactorily accomplished. The overriding of the bones along the back of the humerus leads to the formation of new cicatricial bonds between the olecranon and the humerus and to the establishment of new attachments by the torn lateral ligaments so far above and behind the centre of motion of the old joint that almost no flexion is possible without their rupture or elongation, and the return of the bones to their place can be effected only after a more extensive rupture of these soft parts than that which accompanied the dislocation. In attempting to rupture these bonds by forced flexion the forearm is used as a lever the fulcrum of which is situated on the ulna below the coronoid process, and the rupturing strain is exerted through the olecranon upon the ligaments and adhesions connected with it, and it is not to be wondered at that this process should so frequently have been broken in the manipulation. In addition, the greater sigmoid cavity promptly fills with cicatricial tissue, partly of new formation and partly furnished by the upper part of the posterior portion of the capsule which slips in between it and the back of the humerus and permanently occupies the concavity which should, after reduction, embrace the trochlea; this pad of tissue is found so firmly united to the cartilage of the olecranon that its removal in the reported arthrotomies has required the use of the knife. The adhesion of the

capsule to the articular surface of the front of the trochlea and the capitellum has not been found to be so close, and the cartilage of their surfaces has been found, even after the lapse of several months, almost entirely unaltered in appearance.

Furthermore, the injury is common in the young, in whom the osteogenic power of the periosteum is great and in whom the epiphyses are still growing. The effect of the injury, especially if the periosteum is stripped up, is, therefore, to produce new formations of bone around the joint which contract adhesions with the other bones or mechanically interfere by interposition to prevent the reduction of the dislocation; and, further, the epiphysis of the humerus, relieved of the pressure normally exerted upon it by the radius and ulna, grows more rapidly and irregularly, and its articular surface may thus lose its shape and become unfit to receive the others again. This deformity by exaggerated growth has been especially noticed in the capitellum (see *Pathological and Congenital Dislocations*), the extension being downward and forward.

FIG. 314.



Old dislocation of elbow. New socket for head of radius. Bony union between ulna and trochlea.

These changes are clearly incompatible with successful reduction by the means employed in fresh cases, even if the force employed be sufficient to rupture the adhesions and bring the bones down to the proper level. It is true that successes have been occasionally reported, but the reports rarely go beyond the statement that reduction was accomplished, and they leave the subsequent history of the case and degree of re-establishment of the functions unrecorded. Until quite recently the only methods employed have been forcible attempts to reduce by traction and the breaking of adhesions, sometimes aided by subcutaneous division of the tendon of the triceps, or of adhesions on the sides and back of the joint, increase of the range of motion by the same means without reduction, reduction after fracture of the olecranon by forcible flexion, and excision of the joint.

Albert says that Liston, more than forty years ago, successfully reduced an old dislocation after subcutaneous division of all tense bands, and that in 1847 Blumhart successfully practised arthrotomy in a similar case, making two lateral incisions, and dividing through

them all the adhesions that opposed reduction. This case appears to have been entirely lost sight of, and it was not until thirty years later, in 1879, that Trendelenburg,¹ in a paper recommending temporary division of the olecranon to facilitate operations upon the elbow-joint, reported a case of incomplete outward, or outward and backward, dislocation of both bones with avulsion of the epitrochlea which he had treated by making an incision along the tendon of the biceps, and chiselling away enough bone from the lower end of the humerus in front of the coronoid process to allow flexion to a right angle; the result was good to that extent. A little later Volker² reported a case of incomplete outward dislocation of the left elbow of six months' standing in a boy thirteen years old, in which, after division of the olecranon, he had divided the adhesions, dissected away the new tissues in the sigmoid fossa, and had then been able to reduce; as the change in the shape of the bones favored recurrence he removed the head of the radius. His incision was U-shaped, the sides extending along the borders of the triceps, and the bottom of the U crossing the olecranon at the point where it was to be divided. The position of the limb (ankylosis in almost complete extension) and the evidences of serious pressure upon the ulnar nerve were important factors in the determination to operate. He was so pleased with the result that he looked forward with confidence to the adoption of the method in all old dislocations with much disability.

Trendelenburg³ promptly claimed priority in the suggestions of preliminary division of the olecranon, and reported a case of backward dislocation of both bones of eight weeks' standing successfully treated in the same manner. His incision was a curved transverse one, the convexity directed upward, crossing the median line well above the olecranon, and the flap was then dissected and reflected downward to the point at which the olecranon was to be divided; this division of the olecranon was done with a chisel. Because of difficulty in bringing the olecranon down the limb was dressed in extension, but after the nineteenth day, when the wound was healed, the position was gradually changed, and four weeks later the joint could be flexed to a right angle. The olecranon reunited solidly in this case and in Volker's.

In 1885 Nicoladoni⁴ published a short paper on the application of arthrotomy to old dislocations of various joints, and included in it the report of two cases in which he had practised it at the elbow. The first case was an almost complete outward dislocation of the left elbow in a lad sixteen years old, which had existed for eight months; the epitrochlea was broken off and drawn under the trochlea; the limb was in extension, flexion was entirely lost, but rotation was preserved. An incision eight centimetres long was made in front along the inner border of the trochlea, and through this the fractured epitrochlea was removed; a second incision of the same length was made on the outer side of the joint through which, after removal of a small piece of bone

¹ Trendelenburg: *Archiv für klin. Chir.*, 1879, vol. xxiv. p. 790.

² Volker: *Deutsche Zeitschrift für Chir.*, 1880, vol. xii. p. 541.

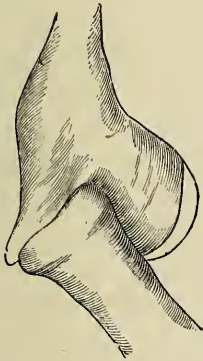
³ Trendelenburg: *Centralblatt für Chir.*, 1880, p. 833.

⁴ Nicoladoni: *Wiener med. Wochenschrift*, 1885, p. 728.

that had been broken from the condyles, the soft parts were separated from the radius and the humerus; then, through a longitudinal cut made in the tendon of the triceps, the adhesions between the olecranon and the back of the humerus were separated, and the bones were then easily restored to place. The wound healed after slight suppuration, passive motion was begun after the third week, and the patient was dismissed after seven and a half weeks with the elbow flexed and movable through an arc of 35 or 40 degrees. Nine months later he wrote that he could flex and extend the joint freely, but that rotation was not quite so free.

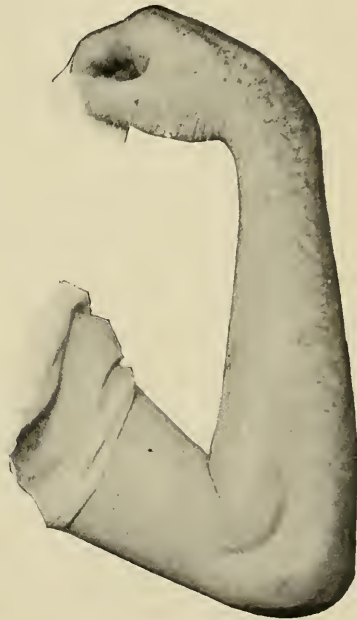The second patient was a large, powerful man, forty-one years old, with a backward dislocation that had existed for six months. The limb was almost completely extended and immovable; there was some passive rotation. The olecranon was situated unusually high. Two lateral incisions, each sixteen centimetres long, were made; through the first, over the outer condyle in front of the head of the radius, the

FIG. 315.



New formation of bone on an old unreduced dislocation.

FIG. 316.



Result of operative reduction of old dislocation.

soft parts were separated from the bone, leaving the periosteum undisturbed, into the trochlea and above the fossa trochlearis in front and behind; through the second incision, on the inner side of the elbow, the flexor muscles were cut away close in front of the epitrochlea, and the separation of the soft parts from the bones completed. The greater sigmoid cavity was found filled with hard cicatricial tissue, which was cut and scraped away after separation of the posterior attachment of the orbicular ligament. Reduction was then easily made. Recovery

took place without incident, and the patient was dismissed at the end of four weeks, the wounds being almost healed. There was good active rotation, but very little flexion; passively, there was complete extension and flexion to a right angle.

In 1886 I operated upon a five-months' backward dislocation in a girl eleven years old by an incision on the outer side and division of the olecranon. My attention had been attracted by a mass of bone attached to the back of the humerus and capping the head of the radius, which I believed to be of new formation and to require removal. The conditions found on exposure (Fig. 315) confirmed this opinion; the mass was cut away and the dislocation was reduced. The case is given in detail in the *New York Medical Journal*, April 2, 1887. The result was not satisfactory, recurrence having taken place under the dressing. The information thus gained fixed my attention upon the importance of the mass of new bone, the formation of which I attributed to the stripping up of the periosteum from the back of the condyle by the displaced head of the radius, enabled me properly to estimate the difficulties, and encouraged me to operate in other cases. In 1891¹ I reported seven additional cases, in five of which I had operated with good results. I have since operated upon several other cases; the results have all been flexion within a right angle and extension varying from 120 to 170 degrees, and preservation of rotation.

The operation² is done by a long incision on the outer side exposing the head of the radius and the mass of new bone; the latter is freely chiselled away, and the capitellum exposed by free division of the soft parts, keeping the knife at a little distance from the bone so as not to damage the periosteum. Through the incision the sigmoid fossa is cleared of fibrous tissue. A second incision, about four inches long, is then made on the inner side, curving close behind the epitrochlea or its site, the ulnar nerve is drawn forward and the olecranon freed; if the epitrochlea has been broken off and displaced upward and backward it must be detached from the humerus, preserving its relations with the lateral ligament. The cleaning of the sigmoid cavity is then completed. If the attachments of the olecranon to the back of the humerus have been thoroughly divided reduction can now be easily made and maintained, unless the dislocation has existed so long that the flexor muscles of the hand have become permanently shortened, in which case they must be partly divided close to the humerus.

Vamosy³ reported Nicoladoni's experience—nine cases successfully treated by arthrotomy between 1886 and 1890. Kunn⁴ reports Maydl's experience of five cases treated by resection and one by arthrotomy; Helferich⁵ reports two cases successfully reduced by the aid of two lateral incisions, and Luksch⁶ reviews the subject on the basis of 60 collected cases.

¹ Stimson: On the Treatment of Old Dislocations of the Elbow, *New York Medical Journal*, October 24, 1891.

² Stimson: *Operative Surgery*, third edition, 1895, p. 139.

³ Vamosy: *Wiener klin. Wochenschrift*, December 11, 1890.

⁴ Kunn: *Internat. klin. Rundschau*, September 6, 1891.

⁵ Helferich: *Deutsche med. Wochenschrift*, August 10, 1893.

⁶ Luksch: *Deutsche Zeit. für Chir.*, 1900, vol. lviii. p. 413.

In old incomplete outward lateral dislocations little is to be hoped for from forcible subcutaneous rupture of the adhesions, for the common interposition of the fractured epitrochlea cannot thus be overcome, and the probabilities are decidedly against the success of an attempt to remove by this means the cicatricial obstacles on the inner side. The choice lies between improving the attitude by forcible flexion, if the limb is extended, and arthrotomy, the internal incision being made in front of the trochlea rather than upon its side.

In old dislocations of the radius alone, in which partial or complete ankylosis renders an operation desirable, the examples quoted in the preceding chapter may serve as guides. In those cases in which the dislocation has occurred in childhood and has been followed by exaggerated growth in length of the radius excision of its head is the only suitable operation, and in other cases it is probably the means most likely to improve function.

Sprengel¹ reports a case of dislocation backward and outward of the head of the radius of five weeks' standing in a boy six years old in which he effected reduction and obtained a perfect functional result by arthrotomy and removal of a portion of the back of the capsule that was interposed between the head of the radius and the ulna. He made an anterior incision along the edge of the supinator longus, exposed the musculo-spiral nerve and its two branches and drew them outward with the outer flap; by this means the capsule was freely exposed to view, and he was enabled to see that the rent was on its outer side, and then by drawing the head of the radius outward with a sharp hook the obstacle to reduction was found to be a fold of the posterior portion of the capsule (probably part of the annular ligament) interposed between the radius and ulna, and firmly adherent to the lesser sigmoid cavity. After having liberated this fold he was able to replace the head of the radius and to close with catgut sutures the rent in the capsule except over a small space on the outer side.

He refers to a case of backward dislocation of the head of the radius in which he obtained a similar success by arthrotomy and separation of the capsule from the upper surface of the radius.

CONGENITAL AND PATHOLOGICAL DISLOCATIONS.

Although a considerable number of cases have been reported as congenital dislocations of the upper end of the radius, yet in many of them the proof that the deformity existed at birth is defective; in some it was noticed at so early a period that the probability of its congenital existence is great; in others, and even in some in which both radii were affected, the displacement can be referred with equal plausibility to causes operating after birth, and the alterations in the shape of the bones to the effect of the displacement and the changed functional conditions.

To the 13 alleged cases briefly quoted and analyzed by Malgaigne, 9 of which are quoted in detail by Gurlt,² may be added several that

¹ Sprengel: *Centralblatt für Chirurgie*, 1886, p. 153.

² Gurlt: *Beiträge zur Vergleich. path. Anat. der Gelenkkrankheiten*, 1853, p. 317.

have been since reported, those of Humphry,¹ Hayem,² Mitscherlich,³ Allen,⁴ Hamilton,⁵ Phillips,⁶ Pye-Smith,⁷ Heele,⁸ and Herskovits.⁹ In addition is a case, a dislocation forward, observed and briefly mentioned by Krönlein.¹⁰

The first 4 were examined post mortem, the others only clinically. In 5 of them the dislocation was backward, in 3 forward; in all both radii were dislocated. Humphry's, Hayem's, Allen's, and Herskovit's were in adults, of whom no previous history was obtained. In Humphry's the lower part of the left ulna was lacking, evidently because of defective development; the right ulna was firmly ankylosed to the humerus nearly at a right angle, and was eight inches long, its lower end was well formed and was on the usual level with the radius; the radius was also eight inches long, and its head was displaced upward and rested against "the forepart of the ridge that ascends from the outer condyle to the shaft," it was somewhat irregular in shape, and its extra length was developed in its shaft and not in its neck as in several of the other reported cases. The trochlea of the humerus was imperfect. The displacement upward was clearly the result of the elongation of the radius, whatever the cause of the original displacement from contact with the capitellum may have been.

Mitscherlich's patient was a girl six years old who had been born with clubfoot; both elbows were deformed, and this defect was thought also to have existed from birth. The head of the radius could be felt in front of the outer half of the coronoid process; extension was perfect, but flexion was limited on the right side to an angle of 70 degrees and on the left to one of 110 degrees; both hands were supinated. Excision of the left elbow was done by von Langenbeck with the object of increasing its range of motion, and the child died in consequence of the operation. The specimen showed that the trochlear surface of the humerus was narrowed in front by extension upon it of the exceptionally large circular surface for the head of the radius. The articular surface of the ulna was normal, but the radius was not in contact with it.

Allen's specimen was taken from the body of an elderly man without history. Both elbows were affected; flexion was normal, extension possible only to a right angle; rotation was entirely lost, the limbs being fixed in pronation. Both radii were displaced backward, but only the left elbow is described in detail. The specimen was not presented as an example of congenital dislocation, but only to show the changes effected in the bones in consequence of unreduced dislocation in early life. These changes modified the shape of the lower end of the humerus and of the radius. The radius crossed the front of the ulna and was united with it by bony union for a distance of about three

¹ Humphry: *Medico-Chirurgical Transactions*, vol. xlv. p. 296.

² Hayem: *Bull. de la Société Anatomique*, 1864, p. 56.

³ Mitscherlich: *Arch. für klin. Chir.*, 1865, vol. vi. p. 218.

⁴ Allen: *Glasgow Medical Journal*, 1880, vol. xiv. p. 44.

⁵ Hamilton: *Loc. cit.*, p. 888.

⁶ Phillips: *British Medical Journal*, 1883, vol. i. p. 773.

⁷ Pye-Smith: *Lancet*, 1883, vol. ii. p. 993.

⁸ Heele: *Lancet*, 1886, vol. ii. p. 249.

⁹ Herskovits: *Wiener med. Presse*, February 12, 1888.

¹⁰ Krönlein: *Deutsche Chirurgie*, Lief. 26, p. 97.

inches at their upper part; below this part the shaft of the radius was much thickened. The neck of the radius was one and a half inches long, so that the head was carried well upward behind the humerus on the inner side of the olecranon, and this overriding was further increased by the abnormal growth of the external condyle downward and outward, the extent downward of the growth being estimated at half an inch. The trochlear surface was deformed, mainly by the loss of much of its inner lip. The olecranon fossa was so far filled up that the septum between it and the coronoid fossa was one-third of an inch thick. The shaft of the ulna was small; its lower end was normal and preserved the usual relations with the radius. The specimen appears closely to resemble those of the earlier cases reported by Sandifort, Dubois, and Verneuil, and has as much, or as little, reason to be thought congenital as most of the others. It is of value in the interpretation of the changes observed in other specimens.

Herskovits's patient was a man twenty-one years old; the head of each radius was displaced backward and outward, the capitellum small. Flexion was nearly complete, extension to 135 degrees, pronation complete, supination lost. No history of injury.

For details of other cases, see first edition.

The arguments upon which the attribution of a congenital character was based in most of the older cases and in those of Humphry and Hayem, and which apply equally well to Allen's, are the existence of the deformity on both sides and the changes in the shape of the articular ends of the bones; in Humphry's and in Deville's there is in addition the lack of the lower part of the ulna.

The irregularities in the bones may, in part at least, be fairly attributed to the change in their relations, especially the very notable one of elongation of the neck of the radius reported in several cases. This is in keeping with similar instances of overgrowth at other points where the normal conditions of pressure have been lost, and with the coincident elongation downward of the external condyle of the humerus noted in Allen's case and in one of R. W. Smith quoted by Gurlt.¹ It requires only that the displacement should occur before the growth of the skeleton is complete.

Blodgett² has recently reported a case and collected 50 others. The displacement in one-eighth was outward, in the others about equally divided between backward and forward. Supination was lost or much restricted in nearly all; flexion restricted when the displacement was forward, extension when it was backward. Elongation of the upper end of the radius existed in three-fourths, bony fusion with the ulna in one-third. In nearly half of the cases some other deformity was present, most often partial deficiency of the radius or ulna. In 3 cases the head of the radius was excised, with gain of flexion and extension in 2 and of rotation also in 1 of them.

Permanent retraction of the pronators, due to prolonged maintenance of the attitude, must be a serious obstacle to the establishment of supination.

¹ Gurlt: *Loc. cit.*, p. 320.

² Blodgett: *Am. Jour. Orthop. Surg.*, 1906, vol. 3, p. 253.

The only recorded case of dislocation of **both bones of the forearm** at birth is one reported by Chaussier and quoted by Pingaud.² A young woman during the ninth month of pregnancy felt her child move so vigorously that she almost lost consciousness. The movements were repeated three times in the course of ten minutes; delivery took place normally at term. The child was weak and presented a complete dislocation of the forearm backward. Malgaigne thought it probable that the lesion was produced, not by the convulsive action of the muscles, but by the striking of the limb against the wall of the uterus.

A few instances of dislocation due to pathological changes within the joint, such as fungous arthritis or relaxation of the ligaments in the course of an acute illness, have been reported.

¹ Pingaud : Dict. Encyclopédique des Sc. Méd., art. Coude, p. 606.

CHAPTER XLVIII.

DISLOCATIONS AT THE WRIST.

Dislocations of the Lower Radio-ulnar Joint—of the Radio-carpal Joint—of the Carpal Bones—Carpo-metacarpal Dislocations.

DISLOCATIONS OF THE LOWER RADIO-ULNAR JOINT.

THESE dislocations, obscurely mentioned by the earlier writers, were first described, according to Malgaigne, in 1771, by Desault, who reported five cases and said he had observed a great number of others. He spoke of the injury as a dislocation of the radius, but Boyer and Dupuytren preferred to call it a dislocation of the ulna, and their choice has been generally accepted and followed. Both *traumatic* and *pathological* forms have been described. The reported cases are comparatively few if those cases are excluded in which the injury is a complication of a fracture of the lower end of the radius, and those injuries observed in young children which are generally thought to be a subluxation of the head of the radius, but which some considered dislocations of the lower end of the ulna; few surgeons who have reported their experience have seen more than a single case. Tillmanns¹ collected 48 cases in addition to one observed by himself, of which the dislocation of the ulna was forward in 16, backward in 18, and inward in 9, and in 5 the direction was not stated; but in 3 of the first group, 8 of the second, all of the third, and 1 of the fourth, there was also fracture of the radius, and in 4 others the ulna perforated the skin and there is reason to think the radius also was fractured. Excluding the cases complicated by fracture and including only 3 of Desault's 5, there remain 12 dislocations forward and 10 backward; to these may be added 2 backward and 3 forward seen or collected by Hamilton, 3 forward collected by Poincot, 1 forward of my own,² 3 forward by Holst,³ Leuven,⁴ and Thon,⁵ and 3 backward by Ridlon,⁶ Horrocks,⁷ and Berger,⁸ making a total of these two varieties of 22 forward and 15 backward. The reported dislocations inward or, more strictly speaking, downward and inward, are really dislocations of the broken end of the radius and the attached carpus upward; to these may be added also the few cases of dislocation of the head of the radius (q. v.) in which the entire bone has been displaced upward along the ulna.

Dislocations Backward (of the Ulna).

The cause in most of the cases tabulated above was exaggerated pronation of the wrist; in some the mechanism is not indicated, and

¹ Tillmanns: Arch. der Heilkunde, 1874, vol. xv. p. 249.

² Stimson: New York Medical Journal, May 25, 1889.

³ Holst: Centralbl. für Chir., June 20, 1891. ⁴ Leuven: Ztblatt für Chir., 1906, p. 1128.

⁵ Thon: Deutsche Zeitschrift für Chir., vol. 84, parts 1 and 3.

⁶ Ridlon: New York Medical Journal, April 25, 1891.

⁷ Horrocks: Lancet, June 27, 1891.

⁸ Berger: L'Union Méd., April 13, 1895.

in others it is not clear. Possibly some of the cases of its alleged production in infants by traction upon or pronation of the hand belong among dislocations of the radius by elongation (q. v.). Sometimes the exaggerated pronation has been effected by external violence, as in Boyer's case, in which a lad engaged his hand between the spokes of a moving wheel; sometimes by muscular action, as in one of Desault's, a washerwoman who was wringing clothes, or in one of Rognetta's, a carpenter who was drilling a hole in a plank; Dalechamp's patient was bitten at the wrist by a horse.

The pathology has not been shown by direct examination of either recent or old cases, and the only experiments bearing upon it are those of Goyrand, quoted in Chapter XLVI., and they show only that by exaggerated pronation the triangular fibro-cartilage uniting the radius and ulna could be carried so far forward as to clear the end of the ulna entirely; he did not succeed in producing by this means a dislocation that would maintain itself without the aid of pressure upon the hand. It seems probable that in the clinical cases there was also rupture of the posterior radio-ulnar ligament.

Symptoms. The hand is slightly or markedly pronated; its adduction has been noted by some, and diminution of the transverse diameter of the wrist by others. Flexion and extension of the wrist are free; supination difficult.

The deformity consists in a marked projection of the lower end of the ulna on the back of the wrist, and a corresponding depression in front; the ulna may, in addition, slightly overlap the end of the radius, so that its axis if prolonged downward would pass to the middle finger.

In connection with these may be mentioned a unique case reported by Schmid¹ of dislocation of the radius forward from the ulna and carpus, caused by a fall upon the hand.

The diagnosis appears to be easy. Malgaigne calls attention to the danger of mistaking the cause for the effect in old cases in which the dislocation follows a chronic arthritis, and also of overlooking an associated fracture of the radius.

Reduction. Reduction has always been readily effected by direct pressure on the radius, aided sometimes by abduction or supination of the hand; occasionally supination alone has been sufficient. Even in old cases—sixty days—reduction has been easily made.

Recurrence has been noted in three cases. In one of Hamilton's the dislocation had existed twenty years, but the movements of the limb were perfect.

Dislocations Forward (of the Ulna).

Dislocation of the lower end of the ulna forward appears commonly to have been caused by direct violence acting in opposite directions upon the lower ends of the radius and ulna while the hand was more or less supinated. It does not clearly appear that the cause has ever acted by carrying the movement of supination beyond its normal limit, although it is not improbable that this was the case in one or two instances.

¹ Schmid: Correspondenz-Blatt d. Württemberg ärztl. Landvereins, November 16, 1892.

No post-mortem examination has been reported, and the pathology of the injury can, therefore, only be inferred. Desault, however, met with a specimen of an old dislocation in the cadaver of a man sixty years old; the hand could not be extended, and rotation was very limited. The sigmoid cavity of the radius was filled with cellular tissue; the head of the ulna, situated in front of this cavity, rested on a sesamoid bone to which it was attached by a capsular ligament. Other injuries had contributed to the loss of motion.

In an entirely unique case reported by Valleteau¹ the dislocation was compound. The patient's forearm had been caught between the spokes of a moving wheel; the ulna projected twenty-eight lines through the skin, crossing the front of the radius, which appears not to have been broken.

Symptoms. The forearm is partly pronated or in varying degrees of supination, the wrist flexed or extended, rotation difficult and painful. The lower end of the ulna is prominent in front, with a corresponding depression behind, and sometimes displaced toward the outer side so that it overlaps the front of the radius and its axis is directed toward the middle of the hand. The radius maintains its relations with the carpus. In my case I could not determine the position of the triangular fibro-cartilage.

The diagnosis is easy, but search should be made, as in the preceding variety, for the possible coexistence of a fracture of the radius.

The best method of *reduction* appears to be by direct pressure upon the ulna and counter-pressure on the radius.

Dislocations Inward and Downward (of the Ulna).

Dislocations inward and downward have been observed in connection with fracture of the radius or, very rarely, with dislocation of its upper end, and are to be deemed complications or incidents of the other and more important injury.

In like manner, the serious complication of perforation of the skin by the ulna has occurred only once except in connection with fracture of the radius.

Pathological dislocations have been reported as the consequence of chronic suppurative arthritis and also of non-suppurative arthritis provoked by a sprain or by a fracture of the radius. Possibly the case reported by Rognetta,² of a negro who suffered from an habitual dislocation of the ulna backward gradually produced by the effects of his occupation as a woodsawyer, belongs in this category, the ligaments having become relaxed in consequence of an arthritis set up by the constantly repeated mechanical violence of the movement.

DISLOCATIONS OF THE RADIO-CARPAL JOINT.

These dislocations, long thought to be common because fracture of the lower end of the radius was habitually supposed to be a disloca-

¹ Valleteau: Gazette Médicale, 1836, p. 250.

² Rognetta: Archives gén. de Méd., 1834, vol. v. p. 396.

tion until Dupuytren forced a recognition of the error, are now known to be of infrequent occurrence. Dupuytren, in the vigor of his correction of the error, went to the other extreme and pronounced them unknown or of very great rarity, and this assertion has colored the general opinion concerning their frequency even to the present time. The statistics that have since been collected are not entirely trustworthy, perhaps, for the error in diagnosis appears still to be made and not all reported cases can be unhesitatingly accepted, but there is reason to think that the rarity is not very great, and there are enough well-authenticated cases to make it possible to trace a general description of the injury. Malgaigne collected 14 cases, 8 of backward, 6 of forward dislocation. Parker¹ collected 33 cases, 23 backward and 10 forward. Tillmanns,² 1874, collected 24, 13 backward and 10 forward; and Servier³ in 1880 collected 26 besides 1 observed by himself, 13 backward, 13 forward, and 1 outward, of which 19 were not contained in Tillmanns's paper. I saw 1 and collected 13 cases published between 1880 and 1887, 12 backward and 2 forward, and it is worthy of note that 5 of these were reported in the *British Medical Journal* within six weeks of one another, March and April, 1880, the reports of the last 4 having been called out by that of the first. Albert speaks of 5 within his knowledge or observation. Even supposing Parker's 33 to include all of Malgaigne's and Tillmanns's, and counting 19 of Servier's, this would still give a total of about 70 cases more or less well authenticated, the correctness of the diagnosis in a number of them being entirely beyond question.

The necessity of receiving with some caution those cases that have been observed clinically and reported with scanty detail is shown by the errors in diagnosis that have been made by experienced surgeons fully aware of the difficulty. Malgaigne⁴ narrates three striking cases. At the time when Dupuytren was first questioning the correctness of the diagnosis in which fracture of the lower end of the radius was habitually taken to be a backward dislocation of the wrist, a patient presenting all the usual signs of this injury died at the Hôtel Dieu. Pelletan declared it to be a dislocation, Dupuytren a fracture, and the former did not vary from his opinion until after the last stroke of the scalpel had exposed the bone and showed the injury to be a fracture with crushing of the lower end of the radius. In 1834 Roux made the diagnosis of dislocation backward in the case of a child that had fallen from a tree; again dissection proved it to be a fracture, with separation of the epiphysis. Still more remarkable was a case reported by Chassaignac⁵ in which he excised the projecting ends of the radius and ulna, thinking the case was dislocation; on careful examination it proved to be a separation of the epiphysis of the radius. The difficulty is probably not so great in dislocations of the carpus forward.

The dislocation may be complete or incomplete backward or forward, and in one case was incomplete outward; it may be simple or compound, or associated with fracture of the radius or ulna. Appar-

¹ Parker: Transactions of the South Carolina Medical Association. Abstract in the New York Medical Record, 1876, vol. vi. p. 396.

² Tillmanns: Loc. cit.

³ Servier: Gazette Hebdom., 1880, p. 211.

⁴ Malgaigne: Loc. cit., p. 703.

⁵ Chassaignac: Bull. de la Société de Chir., 1868, p. 225.

ently fracture of the edge of the articular surface of the radius on the side toward which the carpus is dislocated is not infrequent; such fracture of the posterior lip of the radius is known in this country as "Barton's fracture," but it appears to me properly to belong among the dislocations, the fracture being only an incident or complication. The incomplete dislocations are mainly those in which only the outer portion of the carpus, the scaphoid and semilunaris, is dislocated from the radius, while the inner portion maintains its relations with the triangular fibro-cartilage and ulna; this variety appears to be produced by a movement of rotation (pronation or supination) in which either the radius or the carpus is kept stationary while the other moves away from it; it appears to be sometimes associated with disturbance of the relations of the lower radio-ulnar joint.

In addition to the traumatic, a few pathological and congenital dislocations have been reported.

Dislocations Backward.

Causes. The causes of this dislocation are characterized by great violence, as a fall from a height upon the palm of the hand; in some cases the wrist appears to have been flexed forward, "doubled under" the patient, in a fall while walking, or from a slight elevation.

In two almost identical cases, Billroth¹ and Rydygier,² the mode of production is clearly shown; in the former, the patient, while pressing with the palm of his hand against a railway car in an effort to arrest its motion, was struck upon the back of the elbow by another car moving in the opposite direction, and a compound dislocation of the wrist was produced, the articular surfaces of the radius and ulna projecting through the skin on the palmar surface. Rydygier's patient was caught in the same way between a wagon and a wall alongside of which it was moving.

Pathology. The pathology is illustrated by a number of post-mortem examinations, and by some cases complicated by wounds which permitted direct examination of the joint. The autopsy that has been reported with most detail is that of a case observed by Voillemier.³ The patient was a man twenty-seven years old, who had fallen from the third story of a building, and received injuries which caused his death in four hours. The violence that caused the dislocation of the wrist was apparently received upon the palm of the hand while in dorsal flexion. The external and posterior ligaments were ruptured, the anterior was torn away from the radius, and the internal was intact but was separated from the ulna by avulsion of its styloid process. The tendons and muscles of the back of the forearm were not torn, but had been stripped off the radius, bringing with them the periosteum and small pieces of attached bone. The superficial flexor muscle was widely perforated and torn by the styloid process of the radius at its inner portion, that corresponding to the tendons of the ring and little fingers, the remainder being pushed to the outer side together with the median nerve and radial vessels.

¹ Billroth: *Arch. für klin. Chir.*, vol. x. p. 601, quoted by Tillmanns.

² Rydygier: *Deutsche Zeitschrift für Chir.*, 1881, vol. xv. p. 289.

³ Voillemier: *Arch. gén. de Méd.*, 1839, vol. vi. p. 401.

In Lenoir's case a narrow fragment of the posterior articular border of the radius had been broken off; it remained attached to the capsule and was displaced backward with the carpus. This is the so-called "Barton's fracture of the radius" (p. 294). In no other autopsy of a backward dislocation has this fracture been reported, but it has been suspected to exist in some of the cases observed clinically, and a few specimens of the reunited fracture without history are in existence.

In a case quoted in the *Centralblatt für Chirurgie*, 1884, p. 279, both styloid processes were broken.

In one of my own the semilunar bone remained attached to the radius, and the scaphoid was broken. This attachment of the semilunar was noted by Couteaud,¹ together with a fragment of the cuneiform. His paper contains 15 cases of compound backward dislocation.

Of the incomplete form, that in which only the outer portion of the carpus is dislocated, the only case given in sufficient detail is that of Dupuy:² the patient, a young and muscular porter, while trying to lift a cask had his hand forcibly supinated while the radius remained pronated. On examination two hours later the hand was found flexed and half supinated, while the radius was pronated. Both styloid processes could be distinctly felt, that of the ulna in its normal relations with the carpus, but that of the radius and the articular surface of the latter projecting as a ridge on the posterior aspect of the wrist. No crepitus; no shortening of the limb. Reduction was effected by traction and direct pressure.

In short, the dislocation is habitually accompanied by an extensive laceration of the ligaments, especially the anterior and external; avulsion of the posterior lip of the articular surface of the radius may take the place of rupture of the posterior ligament. The extensor tendons are lifted from their grooves but not torn; the flexors may be torn or pushed to the outer side by the projecting radius; the median nerve and radial artery have always escaped injury, even when the radius has been driven through the skin. The carpus may be displaced directly backward so as to rest upon the posterior surface of the radius, without change in the relations of the several bones that constitute it, or with more or less separation of them from one another, the semilunar bone in two cases being completely detached from the others and remaining attached to the radius; or the displacement may be complete only on the radial side, the movement being one of rotation (supination) of the carpus turning on its inner side as a centre. A superficial transverse rent in the skin on the palmar surface of the wrist observed in one case was probably caused by overstretching of the skin across the projecting end of the radius.

Symptoms. The deformity bears a close resemblance to that of Colles's fracture, but yet the differences are such that Albert³ says he was able to make the differential diagnosis at sight. These differences are that the swelling on the anterior aspect of the wrist and lower part of the forearm extends further down, nearer to the hand, in dislocation than in fracture, reaching even to the ball of the thumb, and ends more

¹ Couteaud: *Rev. de Chir.*, 1906, vol. 34, p. 193.

² Dupuy: *Journ. de Bordeaux*, July, 1850, quoted by Tillmanns.

³ Albert: *Chirurg.*, vol. ii. p. 440.

abruptly; that on the back of the wrist is more sharply outlined at its upper border. In addition, the hand and wrist are commonly more flexed upon the forearm and less movable in dislocation, and may be adducted.

On palpation the styloid processes should be recognized, and their relations to each other and to the bones of the hand and wrist determined; in fracture the styloid process of the radius is displaced upward to or above the level of that of the ulna, its distance from the head of the second metacarpal bone, for instance, is unaltered; while in dislocation the styloid process of the radius remains on a lower level than that of the ulna, and its distance from the head of the second metacarpal bone is lessened; it is also further removed anteriorly from the back of the wrist.

In some of the cases the upper margin of the dorsal swelling could be distinctly felt to be hard and rounded, the convexity directed upward and the bony thickness of the wrist to be notably increased antero-posteriorly, and movable upon the shaft of the radius. The anterior swelling is hard and irregular.

Reduction has usually been easily effected by traction upon the hand and direct pressure on the carpus, and as a tendency to recurrence is not to be anticipated, no other dressings are needed than such as will secure immobility.

In compound cases the treatment should be rigorously antiseptic, with ample provision for drainage. Many surgeons think that a partial excision in such cases favors recovery without accident, but I believe that opinion to be a survival from the pre-antiseptic days, and that cleanliness, drainage, and rest will make excision unnecessary.

The prognosis is favorable in the uncomplicated cases, and even when the dislocation has remained unreduced the re-establishment of the functions of the joint has been satisfactory.

Dislocations Forward.

The causes of the forward dislocations have commonly been a forcible bending of the hand forward or backward. In two cases it was direct violence; in one of them, Moore,¹ the fall of a heavy weight upon the wrist while the latter was resting on the ground (the account does not state whether the forearm was resting on its anterior or posterior surface); in the other, Dieu,² the patient was kicked on the back of the hand by a horse.

Pathology. Seven autopsies have been reported, Malle,³ Letenneur,⁴ Collin,⁵ Jarjavay,⁶ Boinet,⁷ Goodall,⁸ and Dubar.⁹ In addition, there is a compound dislocation, for which Bransby Cooper¹⁰ amputated; the position and extent of the wound are not stated, the only detail that is

¹ Moore: *New York Medical Record*, 1880, vol. xviii. p. 96.

² Dieu: *Bull. de la Société de Chirurgie*, 1884, p. 296.

³ Malle: Quoted by Malgaigne, Tillmanns, and Servier.

⁴ Letenneur: *Bull. de la Société Anatomique*, 1839, vol. xiv. p. 162.

⁵ Collin: *Ibid.*, 1844, p. 335.

⁶ Jarjavay: *Ibid.*, 1861, p. 312.

⁷ Boinet: *Bull. de la Société de Chirurgie*, 1868, p. 211. This specimen was taken from the body of an old woman in the dissecting-room; possibly the case was one of "spontaneous" dislocation.

⁸ Goodall: *Lancet*, 1878, vol. i. p. 937.

⁹ Dubar: *Gaz. des Hôpitaux*, July 28, 1892.

¹⁰ Cooper: *Loc. cit.*, p. 422.

given being that "the flexor tendon of the thumb was torn through." These autopsies show rupture of the anterior and external lateral ligaments, and sometimes of all, the carpus being displaced well upward along the anterior aspect of the radius and ulna; in one case, Goodall, the connection between the semilunar and cuneiform was destroyed, the latter bone retaining its normal relations with the triangular fibro-cartilage, while the scaphoid and semilunar with the rest of the carpus were displaced forward and upward, so that these two bones passed over the free torn border of the ligament stretching from the styloid process of the radius to the cuneiform, which was thus left interposed between them and the articular surface of the radius, and prevented complete reduction. Apparent reduction was easily effected during life, but the displacement at once recurred; there were other wounds, and the patient died of tetanus on the eighth day. The anterior lip of the articular surface was broken off in two cases, and in one of these and another the styloid process of the radius was broken off. Fracture of the styloid process was observed clinically by Maligne, and fracture of the anterior lip was suspected in a case treated by me in 1882, because of crepitus perceived during reduction, and because of the facility with which the dislocation could be reduced and reproduced. Boinet says that in producing the dislocation upon the cadaver he always fractured the anterior lip of the radius.

Symptoms. The hand may occupy any position between moderate dorsal and palmar flexion, the latter being the more common, and the fingers slightly flexed. Voluntary and passive movements of the wrist are restricted and painful. In a case reported by Roland,¹ a boy twelve years old, who had fallen five or six feet and struck upon the back of his flexed right hand, the wrist was immovable in right-angled flexion and the fingers were flexed into the palm and could not be straightened. During the struggles of etherization the bones snapped back into place; there was no tendency to recurrence, and the boy made a prompt recovery, using the hand freely in a few days. The deformity consists in a marked depression on the back of the wrist, the upper border of which is marked by the sharply projecting outline of the radius and the end of the ulna, and in a corresponding rounded prominence on the front of the wrist, formed by the displaced carpus. The hand appears to be shortened at the expense of the wrist, and an actual shortening can be demonstrated by measurement from the styloid process of the radius to the finger. The antero-posterior diameter of the wrist is increased.

In the old cases (Collin, Jarjavay, Boinet) a new articular surface had formed on the anterior surface of the radius and ulna, in two of the cases a full inch above their lower ends. In Collin's the limb was equal in strength and freedom of use to the other, and all the movements were complete except those of abduction and adduction of the wrist, in which there was slight and greater loss respectively.

Reduction has been easily effected, with or without anæsthesia, by traction upon the hand or by direct pressure on the displaced bones or by a combination of the two. In my case slight displacement forward persisted.

¹ Roland: Philadelphia Medical Times, 1879, vol. ix. p. 430.

Dislocations Outward.

Of this form of dislocation only one case has been reported, by Chapplain,¹ of Marseilles. The patient was a man, forty-seven years old, who had fallen from a height of four metres, the weight of his body being received upon his left hand. The hand was widely displaced to the outer side, and through a wound situated upon the inner side of the wrist the bones of the forearm projected and exposed their entire articular surface. The wound of the skin extended from the junction of the posterior and internal surfaces of the wrist, around the latter, and half-way across the anterior surface. The styloid process of the radius had been broken off, and it accompanied the carpus in its displacement. The pisiform was almost completely detached and crushed; the connections of the semilunar with the carpal bones had been ruptured, and it preserved its relations with the radius. There was, in addition, a dislocation of the elbow backward.

The fragments of the pisiform, the styloid process of the radius, and the semilunar were removed, and the dislocation easily reduced. A single suture was placed at the centre of the wound, and the hand and forearm were thickly enveloped in cotton firmly bound on (Guérin's dressing). A second dressing was applied on the eleventh day and removed on the twenty-second, when a large abscess was found on the back of the hand and forearm, and the wound made at the time of the accident nearly healed. A subsequent note, five and a half months after the injury was received, states that the wounds were all healed, the phalangeal and metacarpo-phalangeal joints had almost entirely regained their mobility, the wrist was completely ankylosed, and the elbow only slightly movable.

Pathological Dislocations of the Radio-carpal Joint.

These dislocations, so far as they are due to destructive disease of the joint, are of secondary interest, and do not readily lend themselves to a general description. Malgaigne quotes a few cases, generally reported briefly, of dislocations forward that have been slowly produced in consequence of hydrarthrosis, arthritis, permanent contraction of the flexor muscles, and the retraction of cicatricial bands; he refers also to two cases briefly mentioned by Guérin among his congenital dislocations, one in a child of six years, and the other in a girl of fourteen years with incomplete paralysis of the muscles of the forearm, in which the dislocation was backward and upward and backward and outward respectively. A more common form, one that has been seen with sufficient frequency to have received special study, is the following:

Spontaneous Subluxation Forward.

This affection was first described by Dupuytren² as a condition of the joint which might be mistaken for a dislocation, and of which he

¹ Chapplain: *Bull. de la Société de Chirurgie*, 1874, p. 479.

² Dupuytren: *Clinique Chirurgicale*, vol. iv. p. 209.

had seen a considerable number of cases, especially in men whose occupations compelled them to make repeated, sudden, and violent traction with their hands, as in working a press or dressing cloth. He said that under the influence of these efforts the ligaments of the joint became stretched so that the bones were capable of more extensive change of place than was normal; the carpus, being no longer held firmly against the bones of the forearm, yielded to the traction of the flexor muscles and shifted to a position in front of their lower ends. All the signs of a dislocation were present except pain and inflammation. The more or less considerable deformity and weakness were the only inconveniences of the condition, and were not sufficient to cause the patients to intermit their work or seek medical help. Ordinarily the deformity could be reduced by traction, but it recurred as soon as the parts were left at rest.

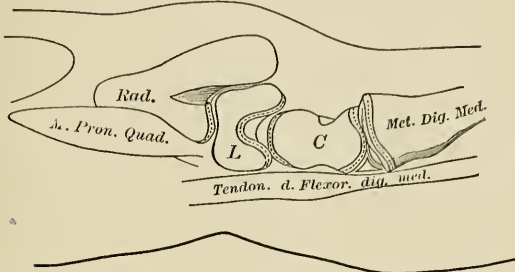
Malgaigne, referring to this description, says that he had for twenty years vainly sought an example of the condition in the largest press-rooms of Paris, and had met with only one, in a patient thirty-six years old, in whom the condition developed at about the age of twelve years apparently as the result of carrying heavy burdens; in this case the carpus was displaced forward and upward, three centimetres above the lower end of the ulna, and one centimetre above that of the radius, the antero-posterior diameter of the wrist was five and a half centimetres on the ulnar side, but could be reduced to four and a half centimetres by pressure, on the radial side it was only four centimetres, but the articular edge of the radius [posterior?] was much depressed and apparently inclined forward. Above the carpus, on the anterior surface of the radius, and apparently adherent to it, was a bony prominence. All movements were free, except dorsal flexion, which was notably diminished.

In 1878 Madelung¹ read before the Seventh Congress of German Surgeons a paper upon the subject based upon the observation of twelve cases and the post-mortem examination of one. Of his twelve patients the dislocation was unilateral in ten (four on the right side, five on the left, and in one the side was not noted), and bilateral in two; eight patients were females, four males. The earliest age at which the condition originated was the thirteenth year; in only two cases did it begin after the twenty-third year. All but one of the patients belonged to the working class, but their occupations were not marked by great muscular efforts. The specimen was obtained from the body of a woman about twenty years old. The appearance of the limb was so typical that he was convinced of the correctness of the diagnosis of spontaneous subluxation, even in the absence of any history of the case. There was no sign of chronic inflammation of the bones of the arm or of any part of the skeleton. The limb was frozen and then sawn longitudinally in two places. The first section was made through the centre of the os magnum and its articulation with the semilunar, and divided the end of the radius so near its ulnar border that a por-

¹ Madelung: *Deutsche Gesellschaft für Chirurgie*, 1878, p. 259, and *Archiv für klinische Chirurgie*, 1879, vol. xxiii, p. 395. See also Abadie, *Revue d'Orthopédie*, 1903, No. 6, and Benneke, *Beilage zum Centralblatt für Chir.*, 1904, p. 157.

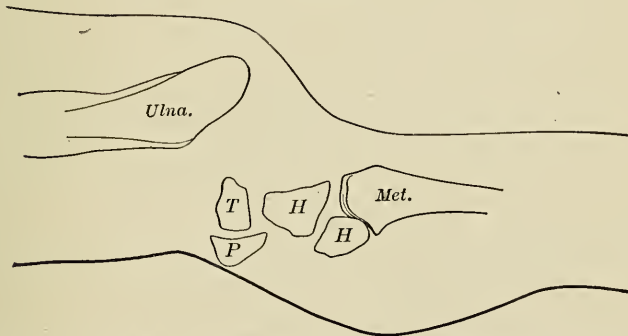
tion of the incisura semilunaris shows in the section. The second section divides the lower part of the ulna into two equal parts and passes through the cuneiform, pisiform, and unciform bones. The sections show that the radial side of the carpus is displaced about half an inch forward and an equal distance upward by the absorption of the anterior half of the lower end of the radius, the posterior half persisting like a malleolus extended over the dorsum of the wrist, and the displacement forward of the ulnar side of the carpus is much more marked. In Benneke's case the *x*-rays showed a similar condition.

FIG. 317.



Madelung's case of spontaneous dislocation of the carpus forward: longitudinal section through (C) the os magnum and (L) the semilunar.

FIG. 318.



The same: longitudinal section through the ulna, (H) the unciform, and (T) the cuneiform.

It seems probable that a case reported by Jean¹ as a double congenital dislocation forward was of this character. On the right side the cuneiform was placed well in front of the ulna; the semilunar and scaphoid not so far in front of the radius, which had formed a new articular surface by loss of its anterior lip. In the left wrist the displacement was of the same character but less marked. Possibly, also, Boinet's case, quoted above, page 685, and R. W. Smith's case² of supposed congenital dislocation belong to this class, and also one observed clinically and reported by Pooley³ as a double congenital dislocation forward.

¹ Jean: Bull. de la Société Anatomique, 1875, p. 398.

² R. W. Smith: Loc. cit., p. 251.

³ Pooley: American Practitioner, 1880, vol. xxi. p. 216.

The production of the deformity in the cases observed clinically was always gradual, requiring from six months to two years for its full development, and in no case could it be attributed to a traumatism, either slight or severe, and in no case were there any signs of acute or chronic inflammation of any part of the joint. In most cases the patients attributed it to continuous hard labor with the hands, but it did not appear that this labor was more than usually prolonged or hard. The women usually attributed it to washing clothes; two of the men were farmers, one a tanner, and one a shoemaker. In the discussion that followed the reading of the paper Hirschberg said he had seen two clearly marked cases, the result of practice at the piano. The deformity in all the cases was accompanied by pain in the joint and was marked especially by the increasing prominence of the end of the ulna. After a time the pain ceased, the deformity remained stationary, and the freedom of use of the limb was unimpaired except by diminution or total loss of dorsal flexion.

After Madelung's attention had been called to the subject by observation of his earlier cases, he took pains critically to examine the wrists of people in all classes of society, and was astonished to find how frequently he encountered slight deviations from the normal shape, all of which were of the type of spontaneous dislocation forward and were characterized not only by the abnormal projection of the end of the ulna but also by change in the articular surface of the radius and the position of the carpus. He attributed the more notable changes in the end of the radius found in the fully developed cases to the arrest of the growth of its anterior portion and to the overgrowth of its posterior portion stimulated by the loss of the opposing pressure normally exerted by the carpus, and he sees an analogy between this change and those observed in *pes valgus* and *genu valgum*. I have seen one case, a young lady who spent much time at the piano. Other cases have been recently reported by Schulze,¹ Sauer,² 3 cases, Schade,³ and Putti.⁴

Symptoms. The most marked deformity is seen when the limb is viewed in profile from the ulnar side; the end of the ulna projects markedly at the back of the wrist; the hand is displaced toward the palmar side, and the antero-posterior diameter of the wrist is greatly increased. Seen from the radial side the displacement forward does not appear so great, and the depression below the end of the radius is bridged over by the extensor tendons; if these tendons are relaxed by dorsal flexion of the hand the posterior part of the articular surface of the radius can be traced with the finger, and its edge can be felt to be rounder than usual. In addition, the entire epiphysis appears to be bent forward.

By traction and pressure the carpus can be brought nearer to the ulna, but it returns at once to its former place when the pressure is removed. No change can be effected in the relations of the carpus and radius.

Sometimes the region is very painful; points that are tender on

¹ Schulze: *Munch. med. Wochenschrift*, 1905, No. 30.

² Sauer: *Beiträge zur klin. Chir.*, vol. 48, part 4.

³ Schade: *Ztllblatt für Chir.*, 1906, p. 811.

⁴ Putti: *Ibid.*, p. 1011.

pressure are seldom found, and usually only at the upper margin of the joint. Every movement of the joint, especially dorsal flexion, is very painful.

Active and passive dorsal flexion is limited to an extent that corresponds to the degree of the subluxation, and in the most marked cases the hand cannot be carried backward beyond straight extension. The range of palmar flexion is more often increased than diminished, unless pain is present.

Treatment. The alteration in the shape of the bones fully explains the failure of the few attempts that have been made forcibly to reduce the displacement, and the fact that the limb recovers nearly its full usefulness after the growth of the skeleton ceases and the progress of the displacement is arrested, furnishes a sound reason against operative interference. Prolonged attempts made by Madelung to improve the position by fixation in gypsum dressings and methodical manipulations did no good beyond relief of pain, and after he had learned the pathology and nature of the affection he limited his treatment to efforts to increase the strength of the arm in all its parts by methodical use and, in some cases, to the wearing of a moulded leather bracelet which could be tightened or loosened and was kept in place by a loop passing between the thumb and index-finger; this prevented movements of the wrist and left the fingers free.

Congenital Dislocations of the Radio-carpal Joint.

The question of congenital dislocation of the wrist is extremely difficult and obscure, for in the great majority of the reported cases the history is so defective that the period at which the displacement took place must remain uncertain, although in most of them it was certainly during infancy or early childhood. In some the congenital origin of the malformation can hardly be called in question, because it is marked by great irregularities of shape and development extending over several bones and joints, but the propriety of classifying such cases as dislocations may well be questioned, for not only do the joint surfaces present hardly a trace of their normal form, but also one or more of the constituent bones may be entirely lacking. Such cases seem much more properly to belong among the "congenital malformations" and to require classification as "club-hands" rather than as dislocations. In most of the reported cases in which the deformity has involved only the wrist the theory of congenital origin has been based upon the absence of the history of any traumatism that could account for the deformity, upon the statements of the patient or his friends that it had existed as long as they could remember, and upon its symmetrical occurrence in both wrists. The history of spontaneous dislocations forward shows how defective this argument is.

The only alleged example of congenital dislocation which is accepted as such by Bouvier¹ and Malgaigne is one reported by Marigues in 1755; it was observed in a stillborn child. The radius was widely separated from the ulna at its lower end, and in the interval between

¹ Bouvier: Dict. Encyclopédique des Sc. Méd., art. Main Bote, p. 166.

them were lodged the bones of the first row of the carpus which were held in place by strong ligaments; the hand was hooked inward, and it was held in this position especially by a strong ligament which extended from the second row of the carpus to the end of the radius.

R. W. Smith¹ describes in detail several specimens of displacement and deformity which he deemed of congenital origin, and quotes a well-known case reported by Cruveilhier in the ninth livraison of his *Anatomie Pathologique*. One of these cases and two or three others which have also been reported as congenital have been mentioned in the preceding section.

DISLOCATIONS OF THE CARPAL BONES.

These present themselves as isolated dislocations of the individual bones or as partial or incomplete dislocations of the medio-carpal joint.

Of the eight bones which form the carpus only the pisiform on the ulnar side and the trapezium on the radial side can be distinctly palpated. The former is felt as a small, hard lump at the junction of the palm and wrist close below the inner end of the lowest of the transverse creases that cross the wrist; it rests upon the anterior face of the cuneiform bone. The trapezium can be readily grasped between the thumb and finger just above the base of the first metacarpal bone. A line drawn straight across the back of the wrist from one end to the other of the lowest transverse crease on the palmar surface crosses the neck of the os magnum directly above the base of the third metacarpal when the hand is extended in line with the forearm, and the finger can feel a distinct depression at this point, the upper margin of which is formed by the lower face of the semilunar; if now the wrist is flexed forward the hollow becomes filled by a projecting piece of bone, the head of the os magnum. The medio-carpal joint is that between the three bones of the first row above and the four bones of the second row below.

Medio-carpal Dislocations.

Of these, one dislocation backward, verified by autopsy, and two forward, observed clinically, have been reported. Possibly some of the cases reported as dislocations of the os magnum were of this kind, and possibly there are intermediate forms between this and dislocation of the semilunar, for the latter is not infrequently accompanied in its displacement by a piece of the scaphoid and once by a piece of the cuneiform in a dislocation of the wrist in which it remained attached to the radius.

A **backward dislocation** was reported by Maisonneuve² in a patient who had fallen from a height of forty feet. The hand, displaced bodily to a plane posterior to that of the forearm, was shortened several lines; behind, a few lines below the styloid processes, was a transverse bony prominence more than a centimetre high, with a depression below, opposite the transverse fold of the wrist. The fingers were flexed, and a considerable effort was required to extend them. The bones of the

¹ R. W. Smith: *Fractures and Dislocations*, 1847, p. 238.

² Maisonneuve: *Mém. de la Soc. de Chir.*, quoted by Malgaigne.

second row were completely separated from those of the first, and over-rode them posteriorly more than a centimetre. A small piece of the scaphoid remained attached to the trapezium, and a portion of the cuneiform, with the pisiform, accompanied the unciform. The internal and external lateral ligaments of the radio-carpal joint were completely ruptured, as were also the anterior and posterior ligaments uniting the two rows of the carpus.

An **incomplete dislocation forward** was reported by Desprès.¹ The patient was presented with his deformity to the Société de Chirurgie, and as there was a difference of opinion concerning the nature of the lesion a committee was appointed to examine and report upon it; they unanimously confirmed the diagnosis. The patient was a man twenty years old; the injury was caused by a fall from a swing, probably upon the back, the hand being caught between the body and the ground. When he came to the hospital, a week later, there was no swelling or redness of the region; on the back of the wrist, a finger-breadth below the edge of the radius, was a depression below which the wrist and hand had their normal appearance, and above which, between it and the radius, the finger recognized a distinct bony resistance. The axis of the hand was deviated outward. On the palmar surface the tendon of the palmaris longus and the thenar and hypothenar eminences were prominent. All the movements of the wrist were preserved, and only forced flexion was painful. Forced extension increased the displacement without notably changing the form of the palmar surface of the wrist. During flexion the prominence of the head of the os magnum was less apparent than in the other wrist; the movement reduced the dislocation.

The treatment consisted in maintaining the hand in the flexed position in which the bone returned to its place by means of a spica bandage; it was begun eleven days after the accident, and by the fourth day the pain had disappeared and the wrist had regained its form and functions. The bandage was worn a week longer.

A **complete dislocation forward** has been reported by Richmond;² the patient was a man, forty-seven years old, who fell upon his hand from a height of about nine feet. The hand, from the wrist to the knuckles, was very noticeably shortened; there was a prominent transverse ridge on the back of the wrist below the ends of the radius and ulna, and below this ridge was a marked depression. On the palmar aspect the base of the hand was unduly prominent, the general direction of the metacarpal bones being quite altered by their bases being pushed forward toward the palm. Voluntary flexion and extension were lost. The ends of the radius and ulna seemed separated somewhat from each other; the transverse dorsal ridge could be demonstrated to be the first row of carpal bones with the semilunar unduly prominent; between it and the radius and ulna flexion and extension, although restricted, could be obtained with considerable ease and without crepitus. None of the carpo-metacarpal joints had sustained any injury. On the palmar prominence the trapezoid could be felt placed more anteriorly than, and considerably above, the level of the trapezium; and nearer the

¹ Desprès: Bull. de la Soc. de Chirurgie, 1875, vol. i. p. 412.

² Richmond: Lancet, 1879, vol. i. p. 844.

ulnar side the head of the os magnum could be felt slightly overlapping the ends of the radius and ulna, which on the palmar surface were quite obscured; and on flexion and extension of the hand the os magnum could be felt to ride on their anterior surface. The displacement of the unciform, although distinct, was much less marked.

Isolated Dislocation of the Different Bones of the Carpus.

This is a very rare injury except in the case of the semilunar, yet instances have been reported of the dislocation of almost every one of them. Eigenbrodt¹ has made a large, though somewhat uncritical, collection of reported cases.

Scaphoid. The reported cases of dislocation of the unbroken scaphoid number about ten, and in some of these the accuracy of the diagnosis may perhaps be questioned.² One in which the diagnosis was confirmed by arthrotomy was reported by King.³ In most the dislocation was backward, and in two reduction was made by direct pressure. For dislocation of a portion of the bone, see Fracture of the Scaphoid and Dislocation of the Semilunar.

A supposed case of backward dislocation was observed at the Hudson Street Hospital in 1899. The injury was an old one, the patient applying for some other affection. The lesion was carefully examined by two members of the house-staff, who concurred in the diagnosis. In Nov., 1904, I saw a case there in which both scaphoids had been partly displaced backward at the central end. There was so little pain and swelling that I doubted the recent traumatic character of the condition, but the patient insisted that it was new and caused by forced palmar flexion. The displacement was irreducible and the interference with function slight. The *x*-rays confirmed the diagnosis.

Another case has been recently reported by Sénéchal⁴; the injury had existed fifteen years and flexion and extension limited one-half. The proximal end of the bone projected on the dorsum on the inner side of the tendon of the long extensor of the thumb. The projecting portion was chiseled away, with improvement in function. Riedl⁵ reports a forward dislocation by a fall, easily reduced by pressure.

A case of dislocation forward of the scaphoid complicating fracture of the lower end of the radius, in which the bone was removed through an incision, was reported by Cameron.⁶ Six years later he⁷ again reported the case, this time as one of dislocation of the semilunar bone, but made no mention or explanation of the previous statement concerning it, although he described the case in the same terms as before.

¹ Eigenbrodt: Beiträge zur klin. Chir., 1901, vol. xxx. p. 805.

² For cases and references see Eigenbrodt.

³ King: Annals of Surgery, August, 1899.

⁴ Sénéchal: Gaz. des Hôp., 1906, p. 1515.

⁵ Riedl: Wiener klin. Wochenschrift, 1906, p. 1520.

⁶ Cameron: Glasgow Medical Journal, 1878, p. 102.

⁷ Ibid.: Lancet, 1884, vol. i. p. 885.

Semilunar.¹ (Plates XLIII, and XLVII.) In the last few years the *x*-rays have shown that dislocation of the semilunar bone, either alone or in combination with fracture of the scaphoid or with disturbance of the relations of other carpal bones, is far from uncommon and is second in order of frequency to fracture of the scaphoid.

The displacement is always forward with rotation on the transverse axis. In Erichsen's case of alleged backward dislocation the identity of the displaced bone was not positively determined. The bone lies beneath the flexor tendons opposite its site or a little higher on the radius, and in the extreme cases it may slip past the tendons and make the dislocation compound by rupture of the overlying skin.

It is habitually produced by dorsal flexion of the wrist, and while the mode of production is still in dispute von Lesser's explanation appears to be the most plausible. He describes three stages, supported by clinical evidence and skiagrams (Fig. 310). In the first, during dorsal flexion, the palmar apex of the bone is fixed by the strong palmar ligaments and the dorsal apex presses against the head of the os magnum (stage of subluxation). Then the dorsal apex slides along the head into the gap between the scaphoid and os magnum and reaches the palmar side of the carpus (complete dislocation), its lower concave surface directed forward; the bone may lie opposite its normal position or higher up on the radius. In the third stage the rotation may increase to 180°. It is interesting to note in this connection that in two of Couteaud's cases of compound dislocation of the wrist the semilunar remained attached to the radius and was once accompanied by a piece of the cuneiform.

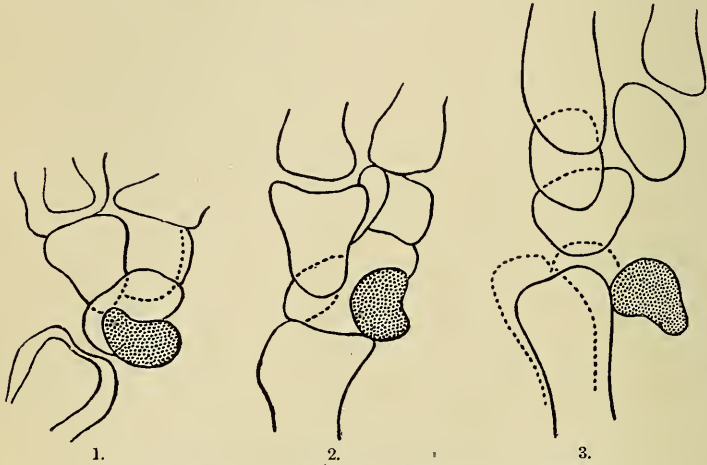
The combination with fracture of the scaphoid is frequent. The proximal third of the scaphoid remains attached to the semilunar and shares in its displacement, which does not go beyond the second stage. In one of my cases (Plate XLVII.) the displacement from the os magnum was complete, but the semilunar could be slipped back and forth upon the radius with loud crepitus. On opening the joint I found a portion of the anterior capsule interposed between the semilunar and radius, and although I could press it partly out of the way and bring the os magnum, semilunar, and radius apparently into proper relations, they would not remain so. I then removed the scaphoid fragment and again reduced, but the position was still so insecure, the semilunar slipping forward very easily, that I removed it also.

Pressure upon the tendons may keep the fingers partly flexed, and there may be numbness or pain in the distribution of the median nerve.

¹ The references are: Mougeot, quoted by Malgaigne; Flower and Hulke, *Holmes's System of Surgery*, Am. ed., vol. i. p. 881; Erichsen, *Science and Art of Surgery*, Am. ed., 1873, vol. i. p. 421; Taafe, *British Medical Journal*, 1869, vol. i. p. 335; Chisolm, *Philadelphia Medical Times*, 1870-71, vol. i. p. 335; Gross, *Philadelphia Medical Times*, 1880-81, vol. xii. p. 220; Buchanan, *Medical Times and Gazette*, 1885, vol. i. p. 113; Forgue, *Gaz. hebdom. de Montpellier*, 1887, vol. ix. No. 1; Albertin, *La Province Médicale*, 1887, p. 420, and a second case in *Lyon Médical*, December 9, 1894; Gamgee, *Lancet*, July 6, 1895; Stimson, *New York Medical Journal*, January 3, 1891, p. 20; a second case in *Annals of Surgery*, March, 1898, p. 265; Bolton, *Ibid.*, August, 1901, p. 291; Richon, *Arch. de Med. et Pharm. Mil.*, 1903, No. 3; Steffel, *Arch. für klin. Chir.*, vol. lxxiii. Part I.; v. Lesser, *Deutsche Zeitschrift für Chir.*, 1702, vol. lxxvii. p. 488; Wittek, *Arch. für klin. Chir.*, 1904, vol. xliii. p. 578; Wendt, *Münch. Med. Wochenschrift*, 1904, No. 24; Codman and Chase, *Annals of Surg.*, June, 1905; Hildebrandt, *Berl. klin. Wochenschrift*, 1905, p. 935; Lilienfeld, *Arch. für klin. Chir.*, vol. lxxvi. p. 641. See also Eigenbrodt.

The diagnosis is made by recognition of the bone under the flexor tendons and of the gap on the dorsum between the os magnum and radius. Associated fracture of the scaphoid is indicated by crepitus and localized pain. Fracture of the scaphoid with dislocation of its proximal fragment, not combined with dislocation of the semilunar, may resemble the latter closely, but is much less common.

FIG. 319.



Three stages of dislocation of the semilunar. (v. LESSEN.)

In some uncomplicated cases reduction has apparently been effected by manipulation, but in a number of them (Codman, Hildebrandt) later examination showed that reduction had been incomplete or that the displacement had recurred. It is, I think, evident that the surgeon cannot be certain that he has fully reduced or that the bone will remain in place, and as removal of the bone has given as good functional results as reduction has, the surgeon is justified, I think, in resorting to removal at once. Nevertheless, late removal seems to give equally good results. In compound cases immediate removal is indicated, and all agree upon its propriety when the scaphoid also is broken.

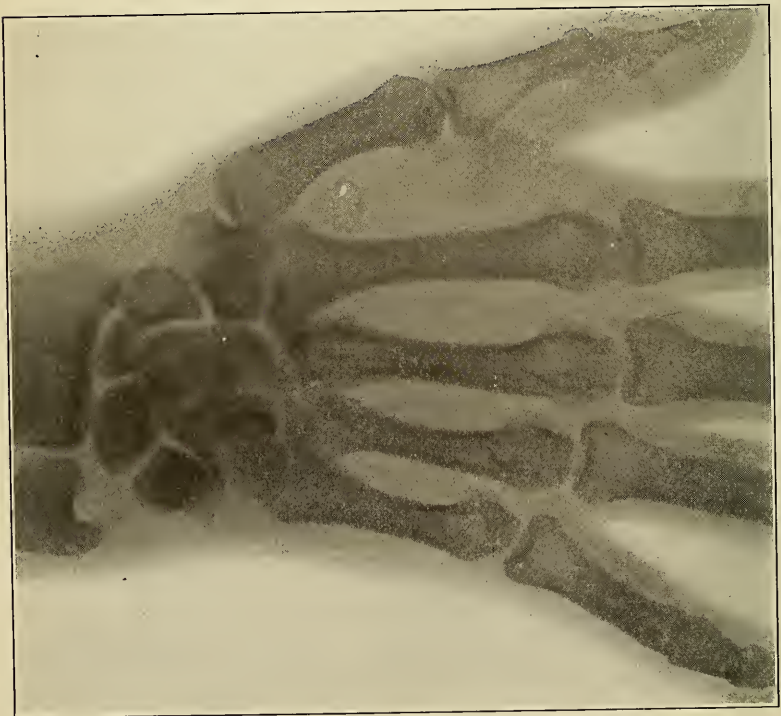
For reduction Codman recommends that the wrist should be hyperextended, the bone pushed into place and held there with the thumbs while the wrist is flexed.

Unciform. There are two recorded cases. One is very briefly reported by Buchanan¹: a man fell from a railway car; "he was found to have a simple luxation of the unciform bone anteriorly. It lay just beneath the skin, and its process could be distinctly outlined. Reduction was effected by direct pressure on the bone while the borders of the hand were approximated." The other is reported by Eigenbrodt. He excised the bone; the process had been broken off.

Pisiform. The pisiform has been reported dislocated in five cases:

¹ Buchanan: Philadelphia Medical and Surgical Reporter, 1881-82, vol. xlvi. p. 418.

PLATE XLVIII.



Dislocation of the Semilunar and Fracture of the Scaphoid.

PLATE XLIX.



Fig. 1.—Old Dislocation Backward of the Os Magnum.

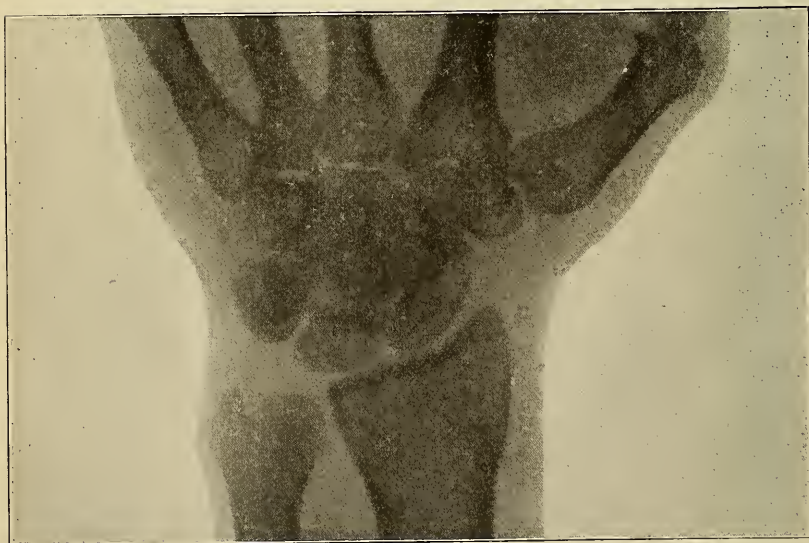

Fig. 2.—Same as Fig. 1.

in two (Erichsen, Fergusson) by muscular effort; in one (Gras¹) by the pressure of the hand upon a flat-iron while ironing clothes. In Erichsen's case the bone was drawn up the arm for a distance of nearly an inch. Doubtless the displacement was the result of rupture of the tendon below the bone.

Os Magnum. Many authors speak of partial dislocation of the head of the os magnum backward as a not infrequent accident produced by prolonged, perhaps not violent, use of the hand, or by a sudden effort, or a fall. Malgaigne classifies the former as pathological dislocations; they are characterized by the appearance on the back of the wrist just above the base of the third metacarpal bone of a small, hard, round lump, especially during palmar flexion, which disappears more or less completely during dorsal flexion, and can sometimes be temporarily reduced by pressure. It ordinarily causes little or no disability.

The more distinctly traumatic cases are those of Richerand (quoted by Cooper²) and Seeger (quoted by Tillmanns). Richerand's patient was a woman who grasped the side of her bed during parturition, turning her wrist forward, and felt a sharp pain in the wrist. A fortnight later, a hard, circumscribed tumor was found at the back of the carpus, formed by the head of the os magnum, which was readily replaced by making gentle pressure on it, and extending the hand. Richerand had seen another similar case, as had also Chopart and Boyer.

Cooper's patient was a young, muscular man, who had fallen upon his hand in such a way as to bring the palmar aspect of the fingers into contact with the forearm. At the point of most pain was a round, hard tumor, rather larger than a marble, which produced a most evident deformity on the back of the wrist opposite to and above the base of the third metacarpal. The hand was slightly bent, and extension caused considerable pain; the tendon of the extensor carpi radialis brevis was displaced slightly to the radial side; the forefinger was abducted from the middle one, and any attempt to approximate them gave great pain at the base of their metacarpal bones; and opposite the base of the middle one was a depression, quite evident to both sight and touch. Reduction was effected by making traction on the fore and middle fingers, while pressure was made upon the os magnum. On flexing the hand the deformity was reproduced; it was again corrected, and the hand placed in splints.

Seeger³ saw in 1829 and 1830 two cases of dislocation of the head of the os magnum backward caused in young men by falls upon the closed fist. Reduction was effected by traction and forcible flexion of the hand, in one case easily, in the other only after several attempts. The hand was kept in splints in the extended position from six to eight weeks, with compresses in front and behind. Recovery was complete.

The only case of total dislocation of the bone of which I know was in a patient who applied at the Hudson Street Hospital in 1899 because of another injury. A lump was noticed at the back of his wrist, which he said dated from an injury received nine years before. Two skiagrams, taken at the time (Plate XLIX.), clearly show the

¹ Gras: *Gazette Médicale*, 1835, p. 542.

² Cooper: *Loc. cit.*, p. 434.

³ Seeger: *Mittheilungen der Württ. ärztl. Vereins*, vol. i., quoted by Tillmanns.

three bones of the first row in place and the projection of the dislocated bone over the site of the os magnum. There was no loss of function.

Trapezoid. The diagnosis of dislocation of the trapezoid backward was made in a case reported by Gay;¹ the patient was a man, thirty-two years old, and the injury was caused by striking with the fist in play. "At the base of the metacarpal bone of the index-finger was a sharp, hard, slightly movable bunch, raised one-quarter of an inch, and tender on pressure." There was no crepitus; the metacarpal bones were of the same length. It could not be reduced. Two months later the deformity was unchanged, but the hand had become nearly as good as the other. Sheldon² reports an almost identical case.

Trapezium. Two cases of dislocation backward of the trapezium alone have been reported by Uhde³ and von Mosengeil.⁴

Uhde's patient was a man, thirty-three years old, who had been knocked down by a wagon. The right thumb and the region of its metacarpal bone was bruised, swollen, and painful, and "at the junction of the first metacarpal and trapezium an unusual mobility of the latter bone was recognizable, and instead of the normal depression between the tendons of the extensor secundi and extensor primi internodii on extension of the hand there was to be seen a small angular tumor corresponding to the trapezium, which projected on flexion of the first and second metacarpals about three and a half lines above the level of the back of the hand, and disappeared on straight extension of these bones with a creaking sound. Six months later the trapezium was found to project one and a half lines on the radial side."

Von Mosengeil's patient had a deformed hand, the thumb and its metacarpal bone having the shape and position of a finger; the displacement, half a centimetre, was produced by a blow received upon the palm of the hand; it was reduced by flexion and pressure.

There is one case in the records of the out-patient department of the Hudson Street Hospital. It did not come under my observation, and the details are lacking in the report.

Os Magnum and Trapezoid. Uhde⁵ briefly describes, under the title "luxatio ossis multanguli minoris et ossis capitati," a case of injury to the wrist marked by a projection on the back of the hand, which he attributed to the displacement of the trapezoid and os magnum. The injury was caused by a fall upon the "anterior ends of the metacarpal bones." It does not appear from the description whether the bones were thought to be dislocated from the metacarpals as well as from the first row of the carpus. The prominence could be reduced by pressure, and reappeared on flexion of the wrist.

A case reported by Alquié, of Montpellier, has been frequently quoted; there was much displacement of the carpal bones on the radial side, but not only was its character uncertain, but in addition the region had suffered from two different accidents, one of which was accompanied by great laceration of the soft parts.

¹ Gay: Boston Medical and Surgical Journal, 1869, vol. lxxxi. p. 188.

² Sheldon: American Journal Medical Science, January, 1901.

³ Uhde: Deutsche Klinik, 1850, vol. ii. p. 539.

⁴ von Mosengeil: Arch. für klin. Chirurgie, 1871, vol. xii. p. 723.

⁵ Uhde: Loc. cit.

CARPO-METACARPAL DISLOCATIONS.

Cases have been reported of the isolated dislocation of every one of the metacarpal bones except the fifth, and of the combined dislocation of two or more.

First Metacarpal. Dislocations of the metacarpal bone of the thumb are the most frequent and important; almost all have been backward.

Very little is known of *dislocations forward*. Sir Astley Cooper¹ says, "In the cases which I have seen of this accident the metacarpal bone has been thrown inward, between the trapezium and the root of the metacarpal bone supporting the index-finger; it forms a protuberance toward the palm of the hand; the thumb is bent backward and cannot be brought toward the little finger." Poinsoy quotes a reference by Vidal de Cassis to a case of incomplete dislocation forward which he had easily reduced.

Albert² saw two cases of incomplete dislocation *outward*; one was old, the other recent. In the latter the injury was produced in a trial of strength by grasping hands. The displacement was easily reduced, but immediately recurred. After reduction the thumb was fixed in abduction by a silicate dressing and so maintained for six weeks. Complete recovery.

Dislocations backward may be complete or incomplete; the former are infrequent, the latter quite common. Of the 73 cases of metacarpal dislocation in my statistics (Chapter XXVII.) almost all were of this bone and of this kind. The cause may be a forced flexion of the thumb into the palm of the hand, or its forced movement in the opposite direction, or direct violence received upon the thenar eminence, as in striking upon the handle of a chisel, or in striking a blow with a hammer, or in the bursting of a gun.

Specimens of old dislocation have been dissected by Foucher³ and Gérin-Roze;⁴ in the former the upper end of the metacarpal bone was displaced backward and a little inward, and was flexed at a right angle to and fused with the trapezium; in addition, the second metacarpal was displaced upward about two centimetres on the back of the wrist, retaining the insertion of the extensor carpi radialis, and the third metacarpal had been broken at its middle. The injury was caused by the bursting of a gun. In Gérin-Roze's case the displacement was directly backward, the anterior edge of the base of the metacarpal resting upon the posterior edge of the inferior articular surface of the trapezium; incomplete reduction could be made.

In the incomplete form the posterior edge of the base of the metacarpal bone can be seen and felt in the interval between the tendons of the extensor primi and extensor secundi internodii as a hard lump continuous with the shaft of the bone and reducible by pressure. The thumb is generally somewhat flexed toward the palm, but may be extended or "straight." Movement is limited and painful, and flexion increases the apparent displacement.

¹ Cooper: Loc. cit., p. 443.

² Albert: Chirurgie, vol. ii. p. 445.

³ Foucher: Bull. de la Soc. Anatomique, 1856, p. 6.

⁴ Gérin-Roze: Bull. de la Soc. Anatomique, 1858, p. 266.

In the complete form the dorsal prominence is more distinct, and rests upon the trapezium which forms a recognizable lump in the ball of the thumb. The thumb is shortened by the ascent of the metacarpal bone, its first phalanx appearing in consequence to have passed upward into the thenar muscles, and it is usually flexed at the carpo-metacarpal joint.

In some, even recent, cases reduction has been impossible, but usually it has been effected without difficulty by traction on the thumb and direct pressure forward and downward upon the projecting end of the bone. Early recurrence has been noted in some cases, and in a few prevention of recurrence has been difficult or incomplete. Moulded splints of leather, plaster, or gutta-percha, and pasteboard or wooden splints with compresses at the back of the joint are ordinarily used, and have given satisfactory results. In one case the only dressing consisted of strips of adhesive plaster, running from the back of the forearm around the ball of the thumb, and back between it and the index-finger to the forearm, so as to maintain the member abducted and extended.

The restoration of function after reduction is complete, and even when the dislocation has remained unreduced some patients have been able to make good use of the thumb; in others the movement of adduction and opposition has been much restricted.

The **second metacarpal** has been reported dislocated forward in two cases and backward in six cases; in one of the latter together with dislocation of the first, and in another with dislocation of the third. An additional case, observed by himself, is mentioned by Demarquay,¹ in which the first and second were together dislocated, but the direction is not stated, and no details are given.

The forward cases are those of Bourget (quoted by Malgaigne) and Marsh (quoted by Hamilton). In Bourget's, the cause was excessive pressure on the upper posterior part of the bone; in Marsh's, it was an oblique blow with a hammer on the back of the clenched hand. In both cases the proximal end of the bone could be felt in the palm, and a corresponding depression on the back; in the former case the lower end of the bone was inclined forward, and the finger appeared shortened nearly one-fourth of an inch. Both were easily reduced by traction on the finger and pressure on the end of the bone.

The uncomplicated backward cases are those of Hamilton,² Humbert,³ and Lyman⁴; the former was caused in a woman, twenty-eight years old, by a fall upon the closed hand. Reduction was easily effected. Humbert's patient was a man thirty years old, who was kicked by a horse upon the hand that held the reins, the blow falling on the back of the lower end of the second metacarpal bone and the adjoining phalanx; the upper end of the bone could be felt as a hard, circumscribed prominence on the back of the hand, and the finger, measured by the adjoining one, appeared five millimetres short. Reduction was made by traction and direct pressure downward and forward. Lyman had to incise and pry the bone into place.

¹ Demarquay: Bull. de la Société de Chirurgie, 1851, vol. ii. p. 171.

² Hamilton: Loc. cit., p. 724. ³ Humbert: Union Médicale, 1868, vol. v. p. 527.

⁴ Lyman: Annals of Surg., June, 1906.

The case in which the dislocation was associated with that of the first metacarpal is that of Foucher, mentioned above.

In two cases seen by Hamilton there was incomplete dislocation backward of the upper end of the second and third metacarpals, caused by striking a blow with the fist; in both cases the dislocation was old, and had persisted in spite of attempts to maintain reduction.

Third Metacarpal. In addition to these two cases, in which the injury was associated with dislocation of the second metacarpal, dislocation backward of the third metacarpal has been reported by Blandin¹ and Roux.² Blandin's patient fell, while holding a roll of paper, and struck his hand against a post; the blow was slight, and caused no pain at the time, but the middle finger promptly became powerless, and the hand numb and swollen. There was a linear transverse ecchymosis at the back of the first phalanx of the middle finger, close by the metacarpal joint, and, on movement, a crackling that resembled crepitus. No other symptoms are mentioned. Blandin made the diagnosis of "diastasis or incomplete dislocation" of the third metacarpal bone, but others who saw the case thought the bone was broken. The title of the report of the case is "incomplete dislocation upward."

Roux's patient had been injured in a mine explosion; a hard, circumscribed, subcutaneous tumor could be seen and felt on the back of the wrist, continuous and moving with the third metacarpal; the middle finger was shortened. The dislocation was reduced by direct pressure, but appears to have recurred, for at the autopsy the base of the bone was found resting on the back of the os magnum; the second metacarpal was broken.

Fourth Metacarpal. An incomplete backward dislocation of the fourth metacarpal was reported by Maurice.³ It was caused by the premature explosion of a cartridge which the patient was putting into a Chassepot gun; the plunger was driven backward against the palm of the hand. There was a prominence half a centimetre high on the back of the hand, corresponding to the upper end of the fourth metacarpal. Reduction was easy, and recovery prompt.

The four inner metacarpal bones (II., III., IV., V.) have been simultaneously displaced in four cases, Vigouroux,⁴ Hamilton,⁵ Tillaux,⁶ and one of my own; in the first and second the dislocation was backward, in the others forward.

Vigouroux's patient was injured, when eighteen years old, by the explosion of a pistol which he held in his left hand. At his death, at the age of sixty-two years, there was found a complete dislocation backward of the last four metacarpal bones; these bones were flexed forward and the proximal phalanx of each of the last three fingers was incompletely dislocated backward. The index-finger and the lower part of its metacarpal bone were lacking. All the joints of the carpus, including that of the trapezium and first metacarpal, were normal.

Hamilton's patient was struck by a bullet which entered at the ulnar

¹ Blandin: *Gazette des Hôpitaux*, 1844, p. 552.

² Roux: *Union Médicale*, 1848, p. 224.

³ Maurice: *Gazette Médicale*, 1868, p. 587.

⁴ Vigouroux: *Bull. de la Société Anatomique*, 1856, p. 15.

⁵ Hamilton: *Loc. cit.*, p. 724.

⁶ Tillaux: *Bull. de la Société de Chirurgie*, 1875, p. 415.

side of the hand and crossed the back of the wrist between the last row of carpal bones and the skin. When seen by Hamilton five years later "the displacement (backward) was very conspicuous; no fragments of bone had ever escaped. The movements of all the fingers, except the index- and little fingers, were unimpaired."

Tillaux's patient, whom I saw when he was admitted to the Lariboisière Hospital, was twenty years old; twelve days before admission he had fallen backward from a window, about ten feet, striking upon the back of his flexed hand. The hand was flexed on the wrist and could not be actively extended. There was a dorsal depression corresponding to the line of junction of the carpal and metacarpal bones, sharply limited above by a transverse prominence which was evidently formed by the second row of the carpus, and on the palmar surface at the same level the ball of the hand was more prominent than usual. The relations of the first metacarpal with the trapezium were unchanged. Moderate traction with direct pressure forward reduced the displacement with a click, and by making pressure in the opposite direction it was again produced. After a second reduction the limb was immobilized for a fortnight. Complete recovery.

My patient was a lad fifteen years old who was admitted to the Presbyterian Hospital in January, 1887, after having fallen down an elevator shaft, a distance of about forty feet, and received, with other injuries, a dislocation of the left carpo-metacarpal joints. When I first saw the patient, three weeks later, the last-named injury had not been recognized. The hand was then in almost complete extension on the wrist and occupying a plane somewhat anterior to that of the wrist and forearm. The back of the wrist formed a rounded resistant prominence, continuous above with the back of the radius and ulna and terminating below in a sharp, well-defined, transverse ridge, which extended completely across from the fifth to the second metacarpal and curved upward on the outer side toward the styloid process of the radius. The finger, passed upward along the back of the metacarpus, was arrested by this ridge, which appeared to be about one-quarter of an inch high and corresponded to the line of the carpo-metacarpal joints. The first row of carpal bones was in normal relations with the forearm and with most of the second row, but the relations of the trapezium could not be clearly made out. I was under the impression that it was displaced somewhat forward from the scaphoid; it had preserved its relations with the first metacarpal bone. The ball of the hand was abnormally prominent, and the antero-posterior diameter of the wrist appeared thereby increased; the transverse diameter was unchanged.

The deformity was easily reduced by traction and direct pressure, but immediately recurred when the pressure was removed. Reduction was maintained for ten days by keeping the limb in a plaster-of-Paris dressing; on removal of the dressing the deformity did not recur, but a few hours later the patient reproduced it while experimenting to ascertain if the reduction was permanent. It was again reduced, and the limb dressed as before. Three weeks later the reduction was complete and permanent except for some projection forward of the first

metacarpal and trapezium, and the wrist and the fingers had regained their mobility.

Dislocation of All Five Metacarpals. Poulet¹ reported a case of incomplete dislocation forward of all five metacarpal bones; the injury was caused by a fall from a horse and was associated with a wound of the skin on the ball of the hand and slight chipping of the anterior edges of the carpal bones. The swelling and the inflammatory reaction were so great that an examination was not made until after the lapse of a month. There was then found on the back of the hand a projection formed mainly by the os magnum, and below it a depression extending from the trapezium to the unciform. On the palmar surface the ball of the hand projected forward, the palmar fold was effaced, and a deep, ill-defined bony prominence could be felt. The interdigital spaces were two centimetres nearer the styloid processes than on the other hand. Partial reduction and restoration of mobility were obtained.

Eriksen gives a woodcut and description of a plaster cast in the University College Museum, London, taken from a patient in whom he thinks this dislocation must have existed; and Rivington² reported the case of a patient who had been run over by a wagon and had sustained a compound dislocation forward of all the metacarpal bones, the base of the third projecting through a transverse wound near the centre of the palm; the first phalaux of the thumb was also dislocated, and the index-finger so injured that its amputation was necessary. The base of the third metacarpal was excised and the dislocation centre of the palm; this was excised and the dislocation reduced. After dangerous suppuration and high fever the patient recovered with a fairly useful hand.

¹ Poulet: Bull. de la Soc. de Chir., 1884, p. 902.

² Rivington: Lancet, 1873, vol. i. p. 270.

CHAPTER XLIX.

DISLOCATIONS OF THE THUMB AND FINGERS.

Proximal Phalanx of Thumb—of the Fingers—Middle Phalanges—Distal Phalanges.

THE tables in Chapter XXVII. show that metacarpo-phalangeal dislocations of the thumb and fingers and dislocations of the phalanges in combined hospital and polyclinic services amount to nearly 25 per cent. of all dislocations. Of the metacarpo-phalangeal dislocations those of the thumb are much the most numerous.

DISLOCATIONS OF THE PROXIMAL PHALANX OF THE THUMB.

These dislocations are not only the most frequent of those involving the phalanges, but they also derive a special interest from the frequency with which the reduction has been found to be very difficult or has entirely failed. The cause of this difficulty has been the subject of much study and experiment upon the cadaver during the last hundred years, which may be said to have culminated in an elaborate paper read by Farabeuf¹ before the Société de Chirurgie of Paris in 1875, in which the anatomy of the joint was described with much detail. This description and his explanation of the cause of the difficulty have been generally copied and accepted by writers in Germany and France. The experience I have gained in arthrotomies indicates that he somewhat overestimated the importance of the sesamoid bones in opposing reduction.

Anatomy. The head of the metacarpal bone projects on its palmar aspect in the form of a well-rounded tubercle or condyle covered with cartilage, and more prominent on its outer than on its inner side. The ligaments of the joint here concerned are the two lateral and the strong anterior or glenoid; the latter is continuous on either side with the others and is stiffened by the development within it of the two sesamoid bones belonging to the short muscles attached to the base of the phalanx. The tendon of the flexor longus pollicis lies nearer the inner than the outer side; it is lodged at its lower end in a firm sheath, which extends upward to, and is connected with, the glenoid ligament.

The short muscles and their attachments are made tense by abducting the thumb, and are relaxed by pressing the metacarpal bone into the palm of the hand. The long flexor and the extensors are relaxed by inclination of the hand toward the radial side. Consequently, to relax as much as possible the various muscles attached to the thumb, the hand should be held in straight extension and slight abduction, and the thumb should be pressed into the palm, adduction.

¹ Farabeuf: Bull. de la Société de Chirurgie, 1876, p. 21.

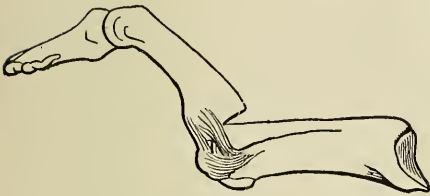
The dislocation may be backward, forward, or to the inner side; complete or incomplete.

Backward Dislocations.

This is the most frequent form, and the one in which reduction of the dislocation is often difficult.

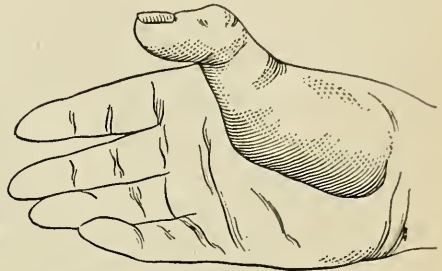
The common cause is exaggerated dorsal flexion of the first phalanx. When the normal limit of the movement is reached the anterior ligament is put upon the stretch and, the movement being continued, yields at its attachment to the metacarpal bone, so that the anterior ligament accompanies the phalanx in its movement.

FIG. 320.



Incomplete dislocation of the thumb.

FIG. 321.



Incomplete dislocation. (FARABEUF.)

a. Incomplete Form. If this movement is not carried further than to the position shown in Fig. 320 the articular end of the phalanx rests against the posterior margin of the head of the metacarpal bone, and is maintained in this position by the tension of the portions of the adductor and abductor muscles which are attached directly to the phalanx, for their line of traction is now posterior to and above the new centre of motion. The attitude of the member is represented in Fig. 321.

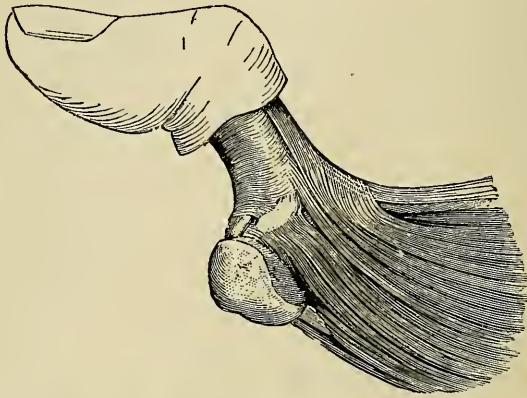
This incomplete form is the one which many people, especially the young, can voluntarily produce by contracting the extensor muscles. The anterior ligament and the sesamoid bones rest like an apron against the antero-inferior articular surface of the metacarpal bone, and the dislocation can be readily reduced by moderate traction upon the phalanx and flexion.

b. Complete Form. If, however, the movement is carried further, the phalanx entirely leaves the articular surface of the metacarpal bone, and moves upward on its dorsum, being followed by the anterior ligament and the sesamoid bones (Figs. 322 and 323). The external lateral ligament is torn, and usually the internal one also; the tendon of the flexor longus pollicis may remain in position, and be tightly stretched across the articular face of the metacarpal bone, as has been seen in some compound dislocations (*e. g.*, Esmarch¹), or, and much more commonly, it accompanies the inner sesamoid bone to the inner side of the

¹ Esmarch: Berlin. klin. Wochenschrift, 1876, p. 629, first case.

metacarpal; occasionally it passes to the outer side of the metacarpal bone, accompanying the external sesamoid, but probably it does so only when, in the production of the dislocation, the thumb is bent to the outer side as well as backward. The head of the metacarpal bone

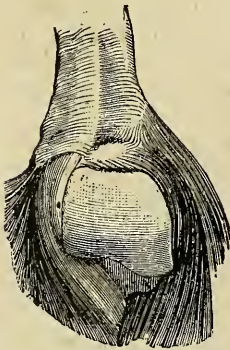
FIG. 322.



Simple complete dislocation; outer side. (FARABEUF.)

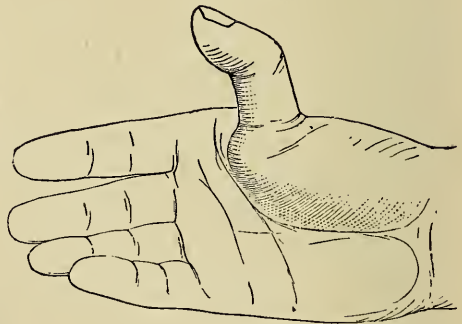
projects through the rent in the capsule, and the tendons of the adductor, abductor, and the two portions of the flexor brevis rest against its sides. The phalanx stands erect upon the dorsum of the metacarpal bone, being held there by the tension of the abductor and adductor.

FIG. 323.



Simple complete dislocation; right thumb. The long flexor tendon is displaced to the inner side. (FARABEUF.)

FIG. 324.

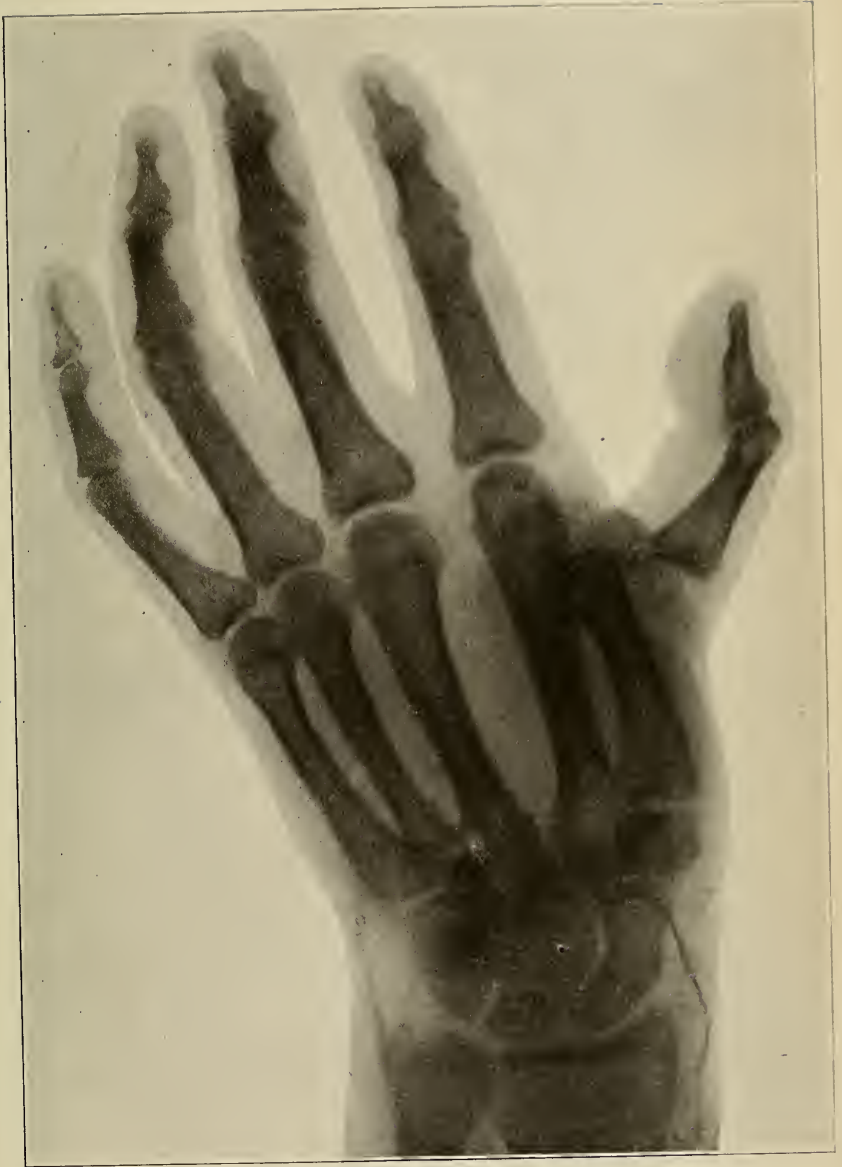

Simple complete dislocation. (FARABEUF.)

The dislocation is sometimes made compound by the rupture of the soft parts on the palmar aspect of the joint.

The appearance of the member is characteristic (Fig. 324 and Plate L.). The phalanx is thrown back vertically upon the metacarpal bone, and the latter is adducted, the thenar eminence being consequently

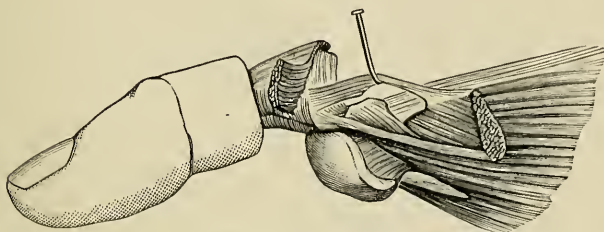
PLATE L.



Fresh Dorsal Dislocation of the Thumb.

increased in thickness and diminished in breadth. The head of the metacarpal bone projects in front as a round, smooth prominence close under the skin, over which the tendon of the long flexor may perhaps be felt. The phalanx is quite movable from side to side, and can be rotated; it can also be turned down so as to be parallel with the metacarpal bone, but this movement should be avoided lest it produce the condition to which Farabeuf gave the name of *complex form*, the essential feature of which he thought to be the interposition of the sesamoid bones between the phalanx and metacarpal, and which presents great difficulty of reduction. The cause of this difficulty, in all the cases in which I have exposed the joint, has been the torn edge of the anterior ligament closely drawn across the back of the metacarpal behind its head, and a slight nicking of that edge made reduction easy. It is believed that flexion of the dislocated phalanx tends to produce this engagement of the capsule, but I know that it can take place without that aid.

FIG. 325.



Complex dislocation of the thumb; outer side. The hook raises the periosteal continuation of the lateral ligament, exposing the reflected and interposed capsule. (FARABEUFL)

Treatment. The attitude of the thumb is maintained by the tension of the short muscles attached to it, and all that is necessary to overcome that opposition is to relax the muscles by pressing the metacarpal bone toward the palm; then reduction is made, while maintaining the phalanx in rectangular dorsal flexion, by pressing its base downward toward the end of the metacarpal and flexing when the proper level is reached. If the torn anterior ligament has not caught behind the head, as just described, it will be pushed before the base of the phalanx and the latter will turn past the head of the metacarpal in flexion as soon as it descends far enough.

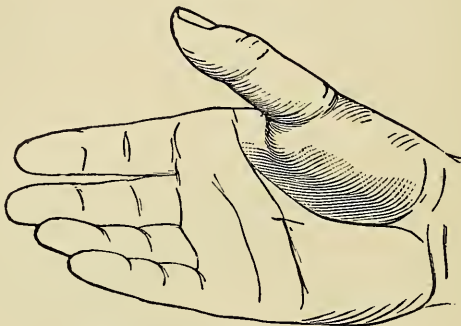
If, on the other hand, the ligament has caught above the head it becomes a serious obstacle; it may sometimes be freed by rotating the phalanx while pressing it downward as just described, and the bone has sometimes been got into place by forcible traction in straight extension. The latter is probably only accomplished after the traction has torn the attachments sufficiently to permit the phalanx to be drawn quite away from the metacarpal, and I think the plan is distinctly inferior to an open arthrotomy.

In reduction by arthrotomy the incision is made longitudinally along the projection of the head of the metacarpal; as soon as this is exposed the sides of the incision are drawn apart and the torn edge of

the ligament, which can be distinctly seen above it somewhat as in Fig. 326, is nicked at its centre; the dislocation is then easily reduced.¹ I presume the nicking might be done without a long incision, by passing in a tenotome. In some cases it has been sufficient to lift the long flexor tendon around to the front from the side of the head, which, I presume, is efficient because the tendon is attached to the capsule and brings it with it in the movement.

The prognosis in the past has not been favorable. Polaillon,² analyzing 58 cases, found that reduction had failed in 11 and had been effected only after numerous and prolonged attempts in 16; in 8 the dislocation was compound, and in 3 of these the head of the metacar-

FIG. 326.



Complex dislocation. (FARABEUF.)

pal bone was excised. In one case (Bromfield), nearly a hundred years ago, such violent traction was made that the terminal phalanx was torn off; the case has been persistently quoted as a warning ever since, but if it is remembered that traction is especially ill-adapted to effect reduction in difficult cases the warning will not be longer needed. In other cases the thumb has become gangrenous in consequence of the violence inflicted upon it by the traction.

In the cases in which the dislocation has been left unreduced and the phalanx has been lowered to a position in which it is parallel with the metacarpal bone, the usefulness of the member has been in great part restored, although, of course, the deformity persisted and the joint was immovable.

Forward Dislocations.

These dislocations, much rarer than the preceding and less difficult to reduce, result usually from a fall or blow upon the back of the flexed phalanx—that is, by exaggerated palmar flexion, but in at least one case (Lombard) from exaggerated dorsal flexion presumably combined with direct impulsion of the phalanx toward the palm; according to Foucart's³ experiments dorsal flexion needed to be combined with forced abduction in order to rupture the internal lateral ligament.

¹ Stimson: New York Medical Journal, March, 30, 1889.

² Polaillon: Dict. Encyclopédique des Sc. Méd., art. Doigt.

³ Foucart: Thèse de Paris, 1876, No. 199, quoted by Poincot.

Pathology. The pathology has been shown by six autopsies, Wood,¹ Meschedé,² Foucart, two cases, Eve,³ and one of my own not before reported. In two of these (Foucart, Eve) the injury was recent; in Meschedé's it had lasted forty-eight days; and in Foucart's second case, in Eve's, and in mine it was of long standing. The recent cases show, as is also found in experiments upon the cadaver, that the posterior and lateral parts of the capsule are torn, including the lateral ligaments, but that the connection between one or both sesamoid bones and the metacarpal bone may persist. The extensor tendons may be stretched directly over the projecting head of the metacarpal bone or they may be deviated to either side; in my case the tendon of the extensor primi internodii appeared to have been detached and retracted. The base of the phalanx lies against the anterior surface of the metacarpal bone, and, in recent cases at least, does not appear to be notably displaced upward; it may lie directly in front, or be somewhat displaced to either side, and the phalanx may be in straight extension or partly flexed.⁴

In the older cases a more or less complete nearthrosis forms between the bones, and fibrous bands and bony outgrowths give the joint sufficient solidity to make it useful.

Symptoms. The deformity is characterized by the position of the phalanx in front of the metacarpal bone, the projection of the head of the latter on the dorsum of the member, and the rather deeply placed prominence formed by the base of the phalanx at the lower part of the thenar eminence. The thumb appears in some cases to have undergone slight rotation about its long axis, and the attempt has been made to show a connection between the direction of this rotation and that of the lateral displacement of the extensor tendons; that is, it has been claimed that when the rotation is such that the nail looks outward the tendons have been displaced toward the outer side, and *vice versa*.

In one reported case the dislocation was made compound by rupture of the soft parts covering the back of the joint; recovery was delayed by a phlegmon of the ball of the thumb.

Treatment. Reduction is generally easy, and is effected either by traction and coaptation, or, better, by forced flexion of the thumb aided, if necessary, by impulsion downward of its base. This latter method is analogous to that recommended in the treatment of the dorsal variety, but there is not the same urgent reason for it that arises in the latter from the relations of the capsule. If any difficulty should arise from the tension of the displaced extensor tendons the phalanx should be inclined toward the side on which they lie before making the usual manœuvre.

Lateral Dislocations.

Bessel-Hagen⁴ reports a unique case of dislocation to the ulnar side. The patient was twenty-eight years old; the injury was caused appar-

¹ Wood: Transactions Pathological Society of London, 1853, vol. iv. p. 250.

² Meschedé: Virchow's Archiv, 1866, vol. xxxvii. p. 510.

³ Eve: Lancet, 1880, vol. i. p. 133.

⁴ Bessel-Hagen: Arch. für klin. Chir., 1888, p. 386.

ently by forcible bending of the thumb toward the opposite side. Reduction by traction and pressure.

METACARPO-PHALANGEAL DISLOCATIONS OF THE FINGERS.

The shallow cavity formed by the articular surface of the base of the proximal phalanx is deepened by the thick anterior portion of the capsule, which forms, as in the thumb, a stout transverse band or apron which accompanies the phalanx in its displacement, and may in like manner become interposed between the bones in a backward dislocation. The resemblance is still further increased by the occasional development of a sesamoid bone in this ligament, especially at the index-finger; its next most frequent appearance is at the little finger.

Dislocations of the proximal phalanges of the fingers are much less frequent, even when taken together, than those of the thumb; and those of the index-finger are more frequent than those of the other three fingers. Of 28 cases collected by Polaillon, the dislocation in 17 was backward, in 10 forward, in 1 not given; 15 were of the index-finger, 4 of the middle, and 3 each of the ring and little fingers; in 2 adjoining fingers were dislocated, and in 1 all four.

Backward Dislocations.

The common cause is hyperextension (dorsal flexion) of the finger. Experiment upon the cadaver and direct observation in compound dislocations or after arthrotomy in irreducible ones, show that the rupture of the capsule takes place in front along its attachment to the metacarpal bone. In a case reported by Willemer¹ the dislocation was irreducible by manipulation, and König resorted to arthrotomy, making an incision on the ulnar side of the palmar surface of the joint (index-finger); he found the anterior portion of the capsule had been drawn back past the articular surface of the phalanx so that it was completely interposed between the two bones, and that a sesamoid bone was developed on it. This makes the case strictly analogous to the complete form of backward dislocation of the thumb, and corroborates the opinion that the cause of the irreducibility in the latter is to be found in the position of the torn anterior ligament rather than in the tension of the tendons of the short muscles.

Lange² says of his case: "The smallest possible cord of the capsule, which was torn from its attachment to the metacarpus, had interposed itself like an apron between the dorsum of the metacarpus and the border of the articular plane of the phalanx. . . . He was obliged to incise and draw outward the light lateral parts of the capsule, when reduction was effected without difficulty. A fair result was obtained."

A similar condition was observed in a case upon which Volkmann³ operated in like manner with a good result, and in one of my own.

¹ Willemer: *Centralblatt für Chirurgie*, 1883, p. 566.

² Lange: *New York Medical Record*, 1879, p. 100.

³ Volkmann: Reported by Ranke, *Berlin. klin. Wochenschrift*, 1877, p. 524.

The symptoms are the prominence of the base of the phalanx on the dorsum of the hand, and that of the head of the metacarpal bone in the palm, more or less shortening of the finger, and loss or diminution of function. The finger may be extended or slightly flexed upon the metacarpus; in one case the first phalanx was in rectangular dorsal flexion. The middle and distal phalanges are straight or slightly flexed.

In 5 of Polaillon's 17 cases the dislocation was complicated by a wound on the palmar aspect of the joint through which the head of the metacarpal bone projected, and in another the skin was so tightly stretched over the end of the bone that it threatened to slough. In 2 cases reduction failed (without operation), and in 5 it was difficult, and was at last effected by rectangular dorsal flexion of the phalanx and direct impulsion downward as in backward dislocation of the thumb.

Treatment. If the dislocation is incomplete reduction may be easily effected by moderate traction followed by flexion, but in the complete cases it is certainly more prudent to act as in the similar dislocations of the thumb in order more surely to avoid the interposition of the anterior portion of the capsule.

Forward Dislocations.

The cause, except in an incomplete case observed by Malgaigne, has always been notable violence received upon the finger, usually in a fall, but the mode of production is not clear. Malgaigne's patient was a shoemaker and caused the dislocation by turning in his hand the shoe upon which he was at work.

The symptoms are the presence of the base of the phalanx in the palm and the projection of the head of the metacarpal bone at the back of the hand. The finger is extended or slightly flexed, and appears usually to be deviated to one or the other side, sometimes very markedly, with displacement of the extensor tendons toward the same side. Reduction has been effected by traction and coaptative pressure. Possibly flexion would be efficient in the more difficult cases, as in the similar dislocations of the thumb.

DISLOCATIONS OF THE MIDDLE PHALANGES.

These dislocations may be backward, forward, or lateral.

Backward.

The usual cause is a fall upon the palmar surface of the extended finger, which produces the dislocation by hyperextension of the phalanx and sometimes ruptures the skin over the front of the joint. The phalanx may remain hyperextended upon the proximal one, even to a right angle, or may be lowered so that its axis is parallel to that of the other. The diagnosis is readily made by examination of the relations of the bones, and ordinarily reduction is easily made by direct impulsion of the hyperextended phalanx or by traction and flexion. The

anterior portion of the capsule resembles that of the metacarpo-phalangeal joints in being thick and rigid, and it is quite possible, therefore, that it may become interposed as above described and make reduction difficult or impossible, as in a case treated by Polaillon¹ in which all measures failed. It seems advisable, therefore, that the first trial should be of direct impulsion upon the hyperextended phalanx, and, this failing, the phalanx, still extended, should be pressed bodily toward the side on which the flexor tendons may be displaced and then rotated so as to carry the tendons forward past the head of the other phalanx.

Forward.

These may be complete or incomplete, according to the extent to which the base of the middle phalanx is displaced upward along the palmar aspect of the proximal one. The symptoms are the well-marked prominence of the head of the first phalanx on the back, and the less marked projection of the base of the second phalanx on the palmar surface when it is extended. With the displacement upward may be associated some lateral displacement or a lateral deviation of the axis of the second phalanx.

Reduction is easily made by traction and coaptative pressure, but in an old case treated by Hamilton the effort had failed, and in one treated by Thorens the aid of anæsthesia was necessary.

Lateral.

Of these but few cases have been reported; Polaillon could collect only eight, of which the dislocation was to the inner side in seven, and to the outer side in one. In a case quoted by him from Chédan the middle phalanges of the last three fingers were simultaneously dislocated toward the inner side, forming almost a right angle with the side of the first phalanx. Duplay,² who saw a case, says "the dislocated phalanx is markedly deviated inward so as to form almost a right angle and to cross the course of the adjoining finger. At the apex of the angle the lower end of the first phalanx can be felt; the dislocated phalanx projects on its inner side."

In Rollet's case of dislocation to the outer side the base of the second phalanx of the ring finger projected upon the outer side of the first phalanx; the second phalanx was somewhat inclined inward, and the distal phalanx was slightly flexed. The shortening was about two-thirds of a centimetre.

In two of the eight cases the dislocation was compound, but the patients recovered without ankylosis.

Reduction was easily effected in every case by traction and coaptation.

DISLOCATIONS OF THE DISTAL PHALANGES.

These dislocations may be backward, forward, or lateral, the former being by far the most frequent; forward dislocations have, I believe, been encountered only in the thumb.

¹ Polaillon: *Loc. cit.*, p. 184.

² Duplay: *Pathologie Externe*, vol. iii. p. 332.

Backward.

Backward dislocation of the distal phalanx is commonly caused by a fall or blow upon the end of the outstretched finger. The dislocation may be complete or incomplete, simple or compound, and it may be directly backward or backward and to one side.

The anterior ligament is torn away from one or the other bone, in the thumb usually from the proximal phalanx, in the fingers from the distal one. The lateral ligaments remain intact, unless the dislocation is to one side as well as backward. The flexor tendon may be torn away from its attachment, or it may be displaced to one side.

Reduction is usually easy, but may be made difficult by interposition of the anterior portion of the capsule when this accompanies the distal phalanx or by the tension of the displaced tendon. In several compound cases of the thumb the obstacle created by the tendon was clearly demonstrated and was overcome by drawing the tendon aside with a blunt hook or dividing it.

The phalanx may be hyperextended, or straight, or flexed across the end of the proximal one. The coexistence of a wound on the palmar surface of the joint is frequent, thirty-two times in fifty-five cases collected by Polaillon, and has led to very serious consequences, ankylosis, gangrene, suppuration extending to the forearm, tetanus.

Although ordinarily of easy reduction, yet in one-quarter of Polaillon's cases reduction failed. As his list is made up largely of reported cases it undoubtedly contains an exceptionally large proportion of difficult and complicated ones, but still the number of failures, thirteen, is large enough to indicate that reduction may often require much care and skill. The principles controlling it are the same as in the backward dislocations of the other joints, and although simple traction has often sufficed it is prudent to refrain from it and to reduce by direct impulsion of the hyperextended phalanx, especially at the thumb. In one case Hamilton divided the lateral ligaments subcutaneously.

Forward.

These dislocations have been observed only at the thumb, and in a large proportion of the reported cases they have been made compound by a wound on the palmar surface. The cause, in the few reported cases, has been a blow upon the end of the phalanx by which it was forcibly hyperextended. In some cases the phalanx remained in this position, its dorsal surface resting against the articular face of the proximal phalanx, and its base projecting on the palmar surface; in other cases the phalanx was slightly flexed, and its base displaced upward along the anterior surface of the proximal one.

Reduction has usually been easy by traction or direct pressure.

Lateral.

These dislocations, of which only four or five have been reported, have been caused by falls, by a kick, and by violently shaking the

hand while grasping it by the end of the finger. The phalanx may preserve its parallelism with the other, being simply displaced upward along its side, or it may form a lateral angle with it, its base resting against the side of the other. In Gogué's case, quoted by Malgaigne, there was a transverse wound fifteen millimetres long through which the head of the middle phalanx protruded. In Dugès's case reduction was not attempted ; in the others it was easy.

CHAPTER I.

DISLOCATIONS OF THE PELVIS. DISLOCATIONS OF THE COCCYX.

THE union of the two innominate bones at the symphysis pubis is by a solid fibro-cartilaginous band, and without an articular cavity, and the rupture of this band, or its separation from one or the other bone, belongs more properly among fractures than among dislocations. Between the articular surfaces of the ilium and sacrum there is usually an articular cavity, but it is often more or less obliterated by fibrous union between the opposed cartilaginous surfaces. Pure separations at these points without fracture are rare, and, except at the pubic symphysis, hardly to be diagnosticated with certainty during life. The reader is, therefore, referred for most that pertains to the subject to the chapter upon fractures of the pelvis.

Malgaigne described the lesions as dislocations, and most writers have followed his example. His classification is as follows :

Dislocations of the pubic symphysis.

Dislocations of the sacro-iliac symphysis.

Dislocations of these two symphyses, or of the ilium.

Dislocations of the two sacro-iliac symphyses, or of the sacrum.

Dislocations of the three symphyses, or of the three bones simultaneously.

Dislocations of the coccyx.

Of these, only the last is, strictly speaking, to be deemed a dislocation.

DISLOCATIONS OF THE COCCYX.

The systematic descriptions of dislocations of the coccyx which are given by the earlier writers were called in question by those of the first half of the present century, some of whom, especially Boyer, went so far as to deny that the lesion had ever occurred. Malgaigne, however, collected six cases of dislocation forward, and described a backward form on the authority of Lauerjat. To these six may be added four that have been since reported, Roeser,¹ Bonnefont,² two cases, and Mouret,³ the first of which is an example of a variety, lateral dislocation, that has not heretofore been described. It must further be said that many cases have been encountered and reported in which a group of symptoms identical with those observed in cases reported as dislocations, and following similar accidents, falls, blows upon the anal region, has been presented, and the conclusion seems to be unavoidable, either that dislocations or fractures of the coccyx are much more

¹ Roeser: *Froriep's Notizen*, 1857, vol. ii. No. 10. Abstract in *Brit. and For. Med. Chir. Rev.*, 1857, vol. xx. p. 414.

² Bonnefont: *Union Médicale*, 1859, vol. i. p. 136.

³ Mouret: *Rec. de Mém. de Méd. Chir. et Pharm. militaires*, 1859, vol. i. p. 350.

frequent than the number of reported cases indicates, or that the prominent symptoms which accompany the recognized cases, the excessive pain, disability, and general nervous disturbance, are due to something else than the displacement of the bone. Against the latter alternative may be urged the immediate relief and prompt recovery which have followed the reduction of the displacement. Six cases in which the general symptoms were similar to those of dislocation, but in which no displacement was recognizable, are reported by Warren,¹ and Mouret's case may perhaps be classed with them.

Of eight of the above cases in which the sex is noted, six were women, and two men; all were adults; and the obscure injury just referred to, in which the symptoms are the same, except that no displacement is recognizable, is also much more frequent in women than in men.

Dislocations Forward.

The usual cause is violence received upon the region of the coccyx in a fall upon the buttocks or astride a bar, or by the breaking of a chamber upon which the patient was sitting. The two men, Ravaton, Mouret, were injured while on horseback, one of them suddenly in jumping a ditch, the other without special cause or incident, the pain coming on gradually, and increasing for twenty-four hours, and then suddenly becoming very severe after a slight change of position, with a sensation of something slipping in the rectum.

The pain at the moment of the accident is so severe as sometimes to cause the patient to faint; there is pain in defecation, and frequent calls to urinate. The pain radiates down the thighs, and sometimes over the trunk, head, and arms; the patient is unable to sit up, and the slightest movement may greatly increase the suffering. Coughing and sneezing and sometimes even every act of inspiration increase the local pain. If the condition remains unrelieved (Turner, a week; Ravaton, seventeen days; Bonnefont, a month) the general health suffers seriously, the patient becomes feverish, and the mind dulled.

External examination may show an ecchymosis and swelling over the situation of the coccyx and a displacement of this bone forward; the finger introduced into the rectum recognizes an angular displacement of the coccyx, in which its point is directed forward, and which is sometimes so great that the bone stands almost at right angles to its normal position, and presses the posterior wall of the rectum sharply forward.

If now the finger is hooked over the projecting end of the coccyx it can be readily drawn back into place, and the reduction is followed by immediate, instantaneous relief of all the symptoms. A marked tendency to recurrence usually exists and may make it necessary to repeat the reduction several times. In one of Bonnefont's cases a gum catheter with a stylet was bent into the shape of a hook and so placed in the anus that by traction upon the projecting portion the bone could be kept in place. In Turner's case the cure was less complete; the coccyx preserved an abnormal mobility for many years, and the patient was obliged to facilitate defecation by introducing her finger into the anus.

¹ Warren: *Surgical Observations*, Boston, 1867, p. 593.

Dislocation Backward.

Dislocation backward is lightly mentioned by some writers as a not infrequent accident during parturition. Malgaigne quoted Lauverjat as follows: "The considerable deviation backward of this bone sometimes causes its dislocation. I have seen one case. The patient suffered astonishingly, and could not sit; I reduced the coccyx and she was immediately cured."

Lateral Dislocation.

Of this only one case, Roeser, has been reported. The patient, a large, corpulent woman, thirty-six years old, fell astride the back of a chair. She at once suffered severe pain in the coccygeal region, much aggravated by attempts to sit, but she was able to go about for some hours. At last the pain became so severe that she took to her bed, when she found she could neither move nor turn. When seen the next day there was so much immobility and stiffness of the body as to suggest tetanus. Besides the severe pain in the coccygeal region she complained of a painful, tense, dragging sensation, extending up toward the nape, and along the arms to the fingers, which felt numb. She could not bear to make the slightest movement. The head was confused, and the intellect somewhat clouded. No unnatural sensation in the lower limbs; urine and feces were passed naturally.

A small swelling was felt on the left side of the fissure of the buttocks, which proved to be the coccyx torn away from the sacrum, and carried toward the left ischium. The end of the sacrum from which it had been displaced could be plainly felt. The finger in the rectum showed the exact nature of the displacement still better, and when firm pressure was made downward and to the right against the displaced bone, it suddenly resumed its normal position. The patient declared she immediately felt quite another being, the confusion of the head and painful sensation along the spine and arms disappearing. At the end of the fifth day no inconvenience beyond a slight burning pain near the sacrum remained.

The severity of the symptoms in all these forms appears to be due to a special sensitiveness of the region which, as has been said, is manifested by similar symptoms associated with no traumatism or local change, or, as in a case of my own, only with a dry arthritis of the joint. The removal of the coccyx in the non-traumatic cases (coccygodynia) gives great relief.

CHAPTER LI.

DISLOCATIONS OF THE HIP.

Anatomy—Statistics—Cases of Compound Dislocations—Classification—Backward Dislocations: Dorsal; everted dorsal, anterior oblique.

Anatomy.

THE bony constituents of the hip-joint are the acetabulum, or cotyloid cavity of the os innominatum, and the globular head of the femur. The former is an almost hemispherical cavity, situated at the junction of the ilium, ischium, and pubis, and formed by the projection from their outer surface of a strong bony rim, which is especially thick and prominent behind and above, and is lacking below for nearly an inch at the point where the cavity adjoins the foramen ovale, the cotyloid notch. The depth of the cavity is increased by a fibro-cartilaginous rim set upon its edge, the labrum cartilagineum, or cotyloid ligament, which crosses the cotyloid notch, and is there termed the transverse ligament. The wall of the cavity is thin at its centre and lower part, and is elsewhere very thick and strong. Its growth takes place at the junction of the three bones which combine to form it, this junction being marked during the period of growth by a thin layer of conjugal cartilage having the shape of an inverted Y.

The head of the femur is rather more than half of a sphere, having a radius of about an inch, and is so placed upon the neck that rather more than half of its cartilage-covered surface is in front and above (in the upright position) and rather less than half is behind and below. At a point a little below that at which a prolongation of the long axis of the neck would touch its surface is a depression, within which the upper end of the ligamentum teres is attached.

The neck is directed inward, upward, and slightly backward from its junction with the shaft, the angle which it makes with the long axis of the latter being about 130 degrees. The great trochanter, continuous with the outer surface of the shaft, overlaps the neck above and behind, its highest part being situated posteriorly and curved inward; the portion which is most external and most nearly subcutaneous is about an inch below the upper margin.

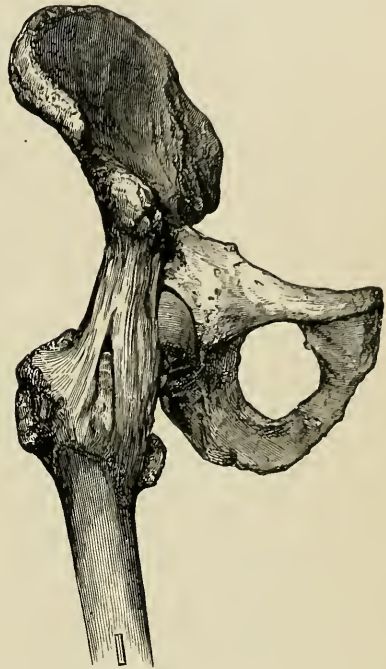
The capsule is attached above along the entire periphery of the cotyloid cavity, just outside the free margin of the labrum cartilagineum, and below to the femur at or near the junction of the neck and shaft, extending in front to the inter-trochanteric line, above nearly to the root of the great trochanter in the digital fossa, behind to the neck itself a little short of its outer limit, and below to the upper part of the lesser trochanter. It is composed of fibres arranged longitudi-

nally and circularly, and varies greatly in strength and thickness at different points. Those portions which are especially thickened by multiplication of the longitudinal fibres are known as accessory ligaments; of these the strongest and most important is the one situated in the anterior part of the capsule, and known as the ilio-femoral ligament, or the ligament of Bertin, or Bigelow's Y-ligament (Fig. 327). This arises from the anterior inferior spine of the ilium, and from the surface of the bone immediately behind it and above the edge of the acetabulum, and its fibres passing downward diverge to form two strong bands, of which the inner passes almost vertically to the lower part of the anterior intertrochanteric line, and the outer to the upper part of the same line. The ligament is about one-fourth of an inch thick at its thickest part, and is very strong, perhaps the strongest in the body, and will sustain without rupture a strain of from 250 to 750 pounds (Bigelow). Its inner portion is especially concerned in limiting extension of the limb; its outer portion in limiting eversion.

The other thickened portions of the capsule are those known as the pubo-femoral and ischio-femoral ligaments; the former arises from the anterior and inferior portion of the acetabular margin and the pubis as far inward as the pectineal eminence, and extends in the anterior and lower part of the capsule to its insertion above the small trochanter. The ischio-femoral ligament is a strong band of fibres on the outer and posterior portion of the capsule, arising from the groove on the ischium below the acetabulum. The pubo-femoral ligament limits abduction; the ischio-femoral limits inversion. On each side of the pubo-femoral band the capsule is very thin; outside and behind the Y-ligament the capsule is very strong, limiting adduction and inward rotation (Bigelow).

The joint is thickly covered in by muscles, of which it is desirable here to mention only one, the obturator internus, which plays an important part in the backward dislocations. This muscle, arising from the inner surface of the obturator foramen and the surface of bone between it and the great sacro-sciatic notch, passes outward

FIG. 327.



The ilio-femoral, or Y-ligament. (BIGELOW.)

through the small sacro-sciatic notch, turns sharply forward, and is inserted upon the front part of the inner surface of the great trochanter in conjunction with the two gemelli which arise respectively from the spine and tuberosity of the ischium. Above it is the pyriformis, below it the quadratus femoris.

The centre of the head of the femur lies about two inches directly below the anterior inferior spine of the ilium, and at about the same distance downward and outward from the centre of, and in a direction at right angles to, a line drawn from the anterior superior spine of the ilium to the spine of the pubis. When the bones are normal and in place, and the limb is partly flexed, a line drawn across the outer aspect of the thigh from the anterior superior spine of the ilium to the lowest part of the tuberosity of the ischium will cross the upper part of the great trochanter. This is known as Nélaton's, or the ischio-iliac line; its relations to the trochanter have great diagnostic importance. In the child, according to Hueter, the trochanter is brought somewhat higher by the relative shortness of the neck of the femur.

Extension and abduction are checked in the living by the ligaments of the joint, flexion and adduction by the muscles or by the contact of the limb with the abdomen in flexion. The range of abduction and adduction is further modified by the position of the limb as regards its flexion and its rotation about the long axis.

The position of the limb in which dislocation of the hip most frequently occurs is that of flexion, adduction, and inward rotation, and the dislocation which then occurs is one of the backward forms, although after the head of the bone has left the socket abduction and outward rotation of the limb may lodge it in the obturator foramen. In this position the posterior and inferior portion of the capsule is put upon the stretch and ruptured. By outward rotation and abduction the head may be forced out at the lower and inner part of the capsule below the pubo-femoral ligament, toward the obturator foramen; in each case a new centre is found for the exaggerated movement in the more or less direct contact between the neck of the femur and the margin of the acetabulum or in the tension of part of the Y-ligament. The force which produces the dislocation, therefore, almost always acts indirectly, either by moving the limb upon the fixed trunk or by moving the trunk upon the fixed limb. In the great majority of cases the Y-ligament remains untorn, and by the restraint which it exerts upon the movements of the displaced femur it determines in a large measure the character of the secondary displacement, the attitude in which the limb comes to rest, and the manipulations by which the dislocation can be reduced. This influence is so great that Bigelow based upon it the distinction which he made between "regular" and "irregular" dislocations, the former including those cases in which the ligament remained untorn and the attitude of the limb was in consequence characteristic; the latter those in which the ligament was more or less torn and the attitude and displacement variable. The distinction has sometimes an important bearing upon the treatment and deserves to be preserved.

Statistics.

The tables in Chapter XXVII. show that the percentages of dislocation of the hip, compared with all dislocations, vary from 1.4 to 2 per cent. Agnew¹ says that of 912 dislocations admitted to the Pennsylvania Hospital 89 (9.75 per cent.) were of the hip. Of Krönlein's 8 cases 4 were in patients not more than ten years old, and of Prah's² 41 cases 12 were of the same age, 8 were between eleven and twenty, and 11 were between twenty-one and thirty years old. This preponderance in youth is, however, not found in Agnew's list or in the 41 cases collected by Malgaigne or the 84 cases collected by Hamilton. The latter were divided as follows :

Under	15 years	15
15 to	30 "	32
30 "	45 "	29
45 "	60 "	7
60 "	85 "	1

Agnew's 89 cases are thus divided :

15 to	25 years	39
25 "	35 "	26
35 "	45 "	12
45 "	55 "	6
55 "	65 "	5
65 "	75 "	1

Although the numbers are larger in Hamilton's collection than in Prah's, yet, as the latter are the integral statistics of a single hospital and dispensary, I think its percentages are more likely to represent the actual proportions than those of a collection of published cases are. I do not know how to account for the absence from Agnew's list of patients under fifteen years of age.

The earliest age at which a dislocation has been reported is six months;³ it was a dislocation upon the obturator foramen, and was caused by the fall of a chair in which the child was tied. In the report by W. A. Johnson,⁴ of a clinical lecture by Prof. Gross, it is said, "upward of six years ago this child, M. S., aged seven years, had a fall," and received a dorsal dislocation of the hip. The note is entitled, "Dislocation of the hip-joint in a child six months of age." Bartels⁵ reported a dorsal dislocation at eleven months caused by the effort made to put on a shoe. Several others have been reported between the ages of eighteen months and five years.

The oldest patient is one reported by Kennedy,⁶ a woman, aged ninety-one years and five months, who received a dorsal dislocation of the right hip by a fall, while walking across a smooth floor; it was reduced on the twelfth day by manipulation, and two days later the patient died. The autopsy verified the diagnosis. The next oldest

¹ Agnew: Surgery, vol. ii. p. 89.

² Prah: Inaug. Dis., Centralbl. für Chir., 1881, p. 57.

³ Powdrell: Lancet, 1868, vol. i. p. 617.

⁴ Johnson: Philadelphia Medical Times, 1876-7, vol. vii. p. 5.

⁵ Bartels: Arch. für klin. Chir., 1874, vol. xvi. p. 650.

⁶ Kennedy: Cincinnati Lancet and Clinic, 1878, vol. i. p. 256.

patient, eighty-six years, was also a woman,¹ and the next a man eighty-one years old, whose dislocation was suprapubic and was verified by autopsy four years later; the neck of the bone was broken by an attempt to reduce while the injury was recent; the case was reported by Verneuil.²

The injury is much more common in males than in females; of Agnew's 89 cases, 11 were women; of 115 cases collected by Hamilton, 104 were males.

Concerning the relative frequency of the different varieties it can be said that those in which the head of the femur is found resting upon the lower part of the ilium behind the outer posterior half of the acetabulum, the so-called "iliac" dislocation, to preserve for the moment the old classification, or still lower down on the upper part of the ischium, "ischiatric" dislocations, are much more frequent than those in which it rests in front or on the inner side of the acetabulum, the suprapubic and obturator dislocations. The dislocations upon the dorsum of the ilium are generally thought, on clinical evidence, to be more frequent than the ischiatic, but a comparison of the cases examined after death does not corroborate this view; Malgaigne collected 10 autopsies of ischiatic dislocations, and only 6 of the iliac, one of these being primarily ischiatic, and Lossen,³ taking only cases reported since 1855, found 19 ischiatic and only 5 iliac. Probably Malgaigne's supposition is correct that many ischiatic cases observed clinically are thought to be iliac; indeed, it will further appear that in many "iliac" dislocations the head of the femur has primarily passed downward and backward, and that its presence upon the dorsum of the ilium is due to a secondary displacement upward. Roser goes so far as to claim that the iliac dislocations, in which the head of the femur has left the cotyloid cavity by its upper posterior portion, are the rarest of all the principal forms. Of the two anterior forms the obturator seems to be more frequent than the suprapubic, but the reported cases are too few to justify a positive assertion.

Simultaneous dislocation of both hips has been reported in about thirty cases (see Chapter LIII.).

Compound dislocations are very rare, as might be expected from the thickness of the soft parts which everywhere cover in the joint. Illustrative cases are those of Walker,⁴ Bransby Cooper,⁵ Macouchy,⁶ Moxon,⁷ a German military surgeon,⁸ Taylor,⁹ Woodward,¹⁰ Langmaid and Cabot, reported by Perkins,¹¹ and Cheever.¹² In the first case the patient fell under a wagon, the wheel passing over the back of his pelvis and right thigh; the head of the femur was forced "forward

¹ Gauthier. Quoted by Malgaigne, loc. cit., p. 805.

² Verneuil: Bull. de la Soc. de Chir., 1865, vol. vi. p. 495.

³ Lossen: Deutsche Chirurgie, Lief. 65, p. 30.

⁴ Walker: Quoted by Cooper, loc. cit., p. 80.

⁵ Cooper: Loc. cit., p. 76.

⁶ Macouchy: Dublin Hospital Gazette, 1872, vol. i. p. 21.

⁷ Moxon: Medical Times and Gazette, 1872, vol. i. p. 96.

⁸ Centralblatt für Chirurgie, 1880, p. 504.

⁹ Taylor: Lancet, 1881, vol. i. p. 732.

¹⁰ Woodward: Boston Medical and Surgical Journal, 1883, vol. cviii. p. 129.

¹¹ Perkins: Ibid., October 16, 1890, p. 362.

¹² Cheever: Ibid., May 28, 1891, p. 523.

upon the groin" and through the skin. Reduction; suppuration; death in three weeks. The second is not spoken of by Cooper as a compound dislocation, but the history indicates that it probably was one; the patient, a lad seventeen years old, was run over by a wagon, the wheel passing across the back of his thigh and producing a dislocation forward and inward, the head of the femur lying to the inner side of the great vessels. A rather large lacerated wound was situated just below Poupart's ligament, a little to the inner side of its centre. Profuse suppuration followed, and the patient died on the twentieth day.

Macouchy's patient was a boy fourteen years old, who fell from a mast to the deck, a distance of sixty feet, and received, in addition to the dislocation, a fracture of the base of the skull. When seen, he was sitting on the deck with the head of the femur appearing between his legs, through his pilot-cloth trousers, as if protruded from his anus. The head, neck, and great trochanter protruded through the integuments covering the posterior third of the ischium, the head of the bone resting on the posterior part of the tuberosity of the ischium of the opposite side. The head was sawn off, and the shaft replaced. The patient died two days later.

Moxon's patient was injured by a moving train and died shortly afterward in Guy's Hospital. The position of the limb was that of dislocation on the *dorsum ilii*. There was a large irregular rent in the skin corresponding to the junction of the left sacro-sciatic ligament with the *tuber ischii*. On passing three or four fingers into the hole a way was found through a pulp of torn muscles and bloodclot, till the fingers rested on the naked head of the thigh bone. The gluteal muscles were much torn up and infiltrated with blood. The head of the thigh bone lay half an inch outside the great sciatic nerve, free under the remains of the *glutei*. It had escaped through the muscles immediately around the joint by passing between the *quadratus femoris* and *obturator internus*. A portion of the head of the bone remained in the socket, attached by the round ligament.

The fifth case was that of an artilleryman who fell in front of the gun; his left leg was bent back so that the heel lay against the back of the shoulder, and the head of the femur projected through the fold of the groin. There was profuse bleeding from the femoral vein. Death in twenty-four hours.

Taylor's patient was a lad seventeen years old, who was overthrown by a falling tree and received a dislocation into the obturator foramen together with an irregular wound nearly two inches long in the perineum through which the head of the femur could be distinctly felt. Most of the muscles had been separated from the descending ramus of the pubis and the ascending ramus of the ischium. Reduction was made with some difficulty, and the limb immobilized on a long side splint. The wound healed promptly, and at the end of nine weeks the splint was removed, but on the next day inflammatory symptoms appeared on the side of the hip, and an abscess formed and was opened. Eight months later Taylor met the patient riding on horseback.

Woodward's patient, a boy twelve years old, was caught under a freight car and rolled over and over, receiving several fractures in

addition to the dislocation. The wound was a slit about two inches long on the inner side of the thigh two and a half inches below the angle of the pubes. The head of the femur, together with the great trochanter entirely stripped of its muscles, projected completely through the opening for about four inches and lay across the scrotum. Its point of exit was just anterior to the adductor longus. No fracture of the femur or pelvis was detected, and the great vessels were uninjured. The patient died in five hours, and after death reduction could not be made.

Langmaid's patient was a girl eight years old who had been run over by a heavy wagon. The wound extended from a point one inch above and within the anterior superior spine across the groin to the inner side of the thigh, the head of the femur presenting in it near its centre. "The muscles directly under the wound were severed, the adductor longus completely, the pectineus, psoas, and gracilis partially." Considerable hemorrhage; the femoral vessels were "outside and beneath the neck of the femur." Reduction. The wound suppurred, but the child recovered with complete ankylosis.

Cheever's patient, a man fifty years old, was thrown down by the fall of a heavy case; the head of the femur protruded through a wound in the groin below the outer part of Poupert's ligament. The head was excised; patient died on the third day. The autopsy showed the femoral vessels to be intact. Death was apparently due to associated injuries, shock, and extensive fat embolism of the lungs.

The gravity of the condition, 7 deaths in 9 cases, is largely due to associated injuries and shock, 5 deaths; in the remaining 4 the wound suppurred after reduction, and 2 of them died. The urgent question is whether or not to excise the head of the femur in order to diminish the danger if suppuration should follow. In fresh, uninfected cases I should think it unnecessary if ample drainage was provided.

Classification.

The classifications adopted by the earlier writers were necessarily faulty and deficient because of the lack of recorded experience and post-mortem examinations. That of Hippocrates, containing four principal forms, outward, inward, forward, and backward, was employed, according to Malgaigne, until the seventeenth or eighteenth century, although the terms do not seem always to have been applied in the same sense. Petit, in the eighteenth century, made two main groups, inward and outward, each with two subdivisions, the four being upward and inward, downward and inward, upward and outward, and downward and outward, but he thought it impossible that the latter form could occur. Verduc, about the same time or a little earlier, sought to establish a classification based upon the place at which the head of the femur came to rest, and in this he was supported by Duverney and Brandi, and thus arose the terms *dislocation upon the ilium*, *upon the ischium*, *upon the pubes*, *into the foramen ovale*. Sir Astley Cooper gave us *dislocations upward, or on the dorsum ilii*, *downward, or into the foramen ovale*, *backward, or into the ischiatic notch*, and

dislocation on the pubes; and Gerdy followed with *suprapubic*, *sub-pubic*, *iliac*, *sacro-sciatic*, and *ischiatric*, the latter being directly downward.

Malgaigne was the first to bring to the subject the results of careful study of many pathological specimens; he showed that in the backward dislocations the head of the femur did not go so far as the anatomical terms used in Cooper's classification, for example, would indicate, but that, on the contrary, it usually remained so near the cotyloid cavity that it partly overlapped it, "incomplete" dislocations, as he called them, and he proposed a classification in four groups, of which the first two were the same as Petit's, though the names are different, as follows:

Dislocations backward	{	iliac, complete, incomplete. ischiatric, complete, incomplete.
Dislocations forward	{	ilio-pubic. ischio-pubic.
Dislocations upward		supracotyloid.
Dislocations downward	{	subcotyloid. subperineal.

The names ilio-pubic and ischio-pubic were taken from those of corresponding depressions on the margin of the cotyloid cavity along which the head of the femur was thought to pass, and, acting on the same plan, Nélaton gave the name ilio-ischiatic to all the backward dislocations, which Malgaigne preferred to divide into two groups.

In Germany Roser and Busch adhered to the method of classification according to the direction taken by the head of the femur; later, Albert made three groups: *backward*, *forward* and *upward*, and *forward* and *downward*, and König and Lossen four: *backward* (*iliac* and *ischiatric*), *forward* (*suprapubic* and *infrapubic*), *supracotyloid*, *infracotyloid*.

In England Sir Astley Cooper's classification has been quite closely adhered to, although some surgeons (Erichsen) place the backward dislocations, those "upon the *dorsum ilii*" and "into the sciatic notch," in one group and call them "dislocations backward and upward."

In America Hamilton used Cooper's classification; and Agnew did the same, although he grouped the iliac and ischiatic together as varieties of a single form "upward and backward."

Bigelow,¹ to whose researches and writings so much of the later advance in the knowledge of the subject and in the treatment of the injury is due, made a classification of seven regular and principal forms, which he based not merely upon the direction in which the bone had been dislocated or the point at which it came to rest, but also upon the integrity of the Y-ligament or the rupture of its outer branch, and the changes in the attitude of the limb which arise from such rupture. Such a classification was open to the objection that it gave equal rank to forms which were only variations of others, and a few years later he modified it² by grouping all under four heads and by suppressing the distinction between the "dorsal" and the "dorsal below the tendon,"

¹ Bigelow: The Hip.

² Bigelow: Lancet, 1878, vol. i. p. 894.

which latter name he had previously given to the lower of the two dorsal varieties, the "dislocations into the sciatic notch" of Cooper. His new classification, then, was the following:

External to the socket; comprising the dorsal and the dorsal with eversion.

Internal to the socket; on the perineum, the thyroid foramen, and the pubes.

Below the socket; dislocation toward the tuberosity of the ischium.

Above the socket; the subspinous, the supraspinous, and the anterior oblique.

This also was open to the serious objection that varieties which were alike in their mode of production, in the point at which the head of the femur left the socket, in the direction it afterward took, and in treatment were placed in different main divisions, and he, therefore, went further and presented in the same paper the following classification which he recommended as a sufficient "practical grouping."

Dorsal, comprising the dislocation on the tuberosity of the ischium, the dorsal, the everted dorsal, the anterior oblique, and the supraspinous.

Thyroid, comprising that in the perineum and that on the thyroid foramen.

Pubic, comprising the pubic and the subspinous.

Turning now to the results of the examination of specimens and of experiments upon the cadaver, it appears that in the more frequent forms the head of the femur passes over the outer, posterior, margin of the cotyloid cavity, usually at or below its horizontal diameter, while the limb is flexed, adducted, and rotated inward; then by the sinking of the knee the femur turns upon its attachment to the Y-ligament as a centre, and the head rises to a higher level along the outer surface of the acetabulum or further backward on the flat surface of the ilium in front of, and seldom higher than the apex of, the great sciatic notch. It is to be borne in mind that this apex is not very much above the level of the highest part of the cotyloid margin. In this movement the head of the femur may pass behind the untorn tendon of the obturator internus, leaving that tendon between itself and the acetabulum; or, if it crosses the margin of the cotyloid cavity at or above its horizontal diameter, it may tear the obturator internus and pyriformis or pass between these muscles and come to rest at the same point as before. The former is the dislocation "below the tendon," the latter the "dorsal" or the dislocation "upon the dorsum ilii," as these terms were originally used, but the distinction is one which cannot often be made clinically. The important difference between them is in the situation of the rent in the capsule, which is higher in the latter than in the former, and will probably permit reduction by traction obliquely downward.

Exceptionally, if, after the dislocation has occurred, the knee is still further lowered and the limb abducted and rotated outward, the outer branch of the Y-ligament ruptures and the head of the femur passes forward along the ilium toward its anterior inferior spine or the interval between the two spines, the "everted dorsal" of Bigelow, the "supraspinous" or part of the "supracotyloid" of others. The

attitude of the limb in this is very different from that of the common backward dislocation of which this is a variety by secondary displacement.

But the head of the femur may not only come to rest directly above the cotyloid cavity by a secondary displacement forward and inward; it may also reach nearly the same point by a secondary displacement outward and backward from a primary dislocation forward upon the pubis. The distinction between the two is radical, for in the former the root of the Y-ligament lies on the inner side of the head, which must be returned to its socket by passing backward behind the acetabulum; and in the latter the Y-ligament lies to its outer side and the head must be returned along the front or inner side of the acetabulum. There is still a third way in which the head may be placed above the acetabulum, although at a somewhat lower level, and that is by direct displacement upward, with rupture of the upper part of the capsule and of the Y-ligament, but this is extremely rare.

The dislocations forward (or inward) and upward and inward and downward offer no difficulties in classification; each has its characteristic symptoms, although the perineal variety of the latter is somewhat sharply distinguished from the obturator or thyroid variety by the greater flexion and abduction of the limb. Bigelow thinks the supra-pubic can be produced by a secondary displacement upward after the head has escaped at the lower part of the capsule during flexion of the limb, in a similar manner and by the same mechanism (lowering of the knee) as a secondary "iliac" dislocation is produced from a primary "ischiatric" one. In short, he thinks (*Lancet*, 1878) that in most cases the head of the femur escapes over the lower margin of the acetabulum and then passes upward as the limb is lowered, and either behind or in front of the acetabulum according as the limb is adducted or abducted, and upon this theory he bases a simple rule of treatment applicable to both anterior and posterior dislocations, namely, flex the limb at a right angle to bring the head below the socket, and then lift it into place.

Finally, the head may be displaced downward upon the adjoining branch of the ischium, and rest there (subcotyloid); the position is one from which the head can be easily displaced backward or forward, and the dislocation thereby transformed into a dorsal or obturator.

The distinction between the two backward forms, upon the dorsum ilii and toward the sciatic notch, which has already been abandoned by eminent surgeons (Bigelow, Erichsen, Albert), does not appear to deserve to be retained, except, perhaps, to establish corresponding varieties in the group; and the anterior oblique, everted dorsal, and supraspinous clearly belong in the same class by their mode of production and treatment. The class of supracotyloid dislocations, made by some writers to contain the two last mentioned, the rare dislocations directly upward, and some of the suprapubic, will be limited to those in which the head appears to have moved directly upward. The corresponding class and term of "subcotyloid" must be retained for the rare dislocations downward "upon the tuberosity of the ischium."

The terms upward and downward must not be taken too literally. They appear to have been rather carelessly used at first without strict regard to the normal position of the pelvis. When the body is upright, the upper border of the symphysis pubis lies a little below the level of the centre of the cotyloid cavity, and the tuberosity of the ischium lies not directly below this cavity, but below and behind. The classification, then, which will here be used is as follows :

Dislocation backward	}	dorsal, comprising the "iliac" and "ischiatric," or those "upon the dorsum ilii" and "into the ischiatic notch" of the writers.			
		everted dorsal, comprising the anterior oblique, "supraspinous," and some of the "supracotyloid."			
Dislocations downward and inward	}	obturator.			
		perineal.			
Dislocations forward and upward	}	suprapubic			
		<table> <tr> <td rowspan="3">}</td> <td>ilio-pectineal.</td> </tr> <tr> <td>pubic.</td> </tr> <tr> <td>intrapelvic.</td> </tr> </table>	}	ilio-pectineal.	pubic.
}	ilio-pectineal.				
	pubic.				
	intrapelvic.				
Dislocations directly upward (supracotyloid or subspinous).					
Dislocations downward on the tuberosity of the ischium.					

As in the classification of dislocations of the shoulder, the names of the principal groups indicate the direction of the primary displacement and, consequently, the position of the rent in the capsule, and the names of the varieties show either the place at which the head of the femur comes to rest or the special symptomatic feature which marks the variety.

BACKWARD DISLOCATIONS.

1. Dorsal.
2. Everted dorsal.

In this class of dislocations the head of the femur in leaving the cotyloid cavity passes over its posterior margin at a higher or lower point while the limb is flexed, adducted, and rotated inward. In the great majority of cases the limb preserves this attitude, and the head rests not far from and behind, or behind and above, the margin of the acetabulum, between it and the great sciatic notch, or it may lie a little higher upon the concave surface of the ilium; these constitute the dorsal variety, and include the "iliac" and "ischiatric" of other writers. In other cases external rotation of the limb takes place with or without abduction and extension; in the latter case the limb crosses the opposite thigh and the toes are everted, the head of the femur lies above the socket, and the lower part of the neck corresponds to the upper and posterior margin of the acetabulum, the anterior oblique variety; in the former case (with abduction and extension) the outer branch of the Y-ligament is ruptured, the head of the femur lies above the socket, and the everted limb lies parallel to its fellow, or slightly abducted—the everted dorsal variety. The class includes all the backward dislocations of other authors, and most of those that have sometimes been grouped under the term "supracotyloid."

1. Dorsal Dislocations.

In these dislocations, which are by far the most common of all dislocations of the hip, the head of the femur lies behind and above the cotyloid cavity, either close to and overlapping its edge (Malgaigne's "incomplete" form) or further away upon the ilium. It may pass below the obturator internus and rise behind it, or between it and the pyriformis, or above the latter, or both muscles may be completely torn across. The group, therefore, includes the dislocations "upon the dorsum ilii" and those "into the ischiatic notch" of Cooper, or the "dorsal" and the "dorsal below the tendon" of Bigelow's first classification, or the "iliac" and "ischiatic" of others.

Causes. Dorsal dislocations are commonly caused by violence that approximates the knee and the pelvis while the thigh is flexed, adducted, and rotated inward, as in a fall from a height, or in the fall of a heavy body upon the back of the patient while he is stooping forward. Less frequently the dislocation is produced mainly or solely by flexion, adduction, and inward rotation, one of the three movements being exaggerated. Thus, in a case reported by Moffat,¹ the patient was drawing a railway carriage along the track; he fell forward and rolled upon his back outside the rail to escape the car, but, as it passed, the end of the footboard caught his leg and bent it upon and across his belly (flexion and adduction). The car had to be raised with a jack-screw to free him, and when released he was lying upon his back with the limb in the position described. When examined at the hospital, the thigh was slightly flexed and rotated inward, the toes overlapping those of the other foot.

In a case reported by Dupuytren, exaggerated adduction appears to have been the chief factor. A delicate man, twenty-one years old, was thrown, while wrestling, upon his left side, and in the fall the left thigh was forcibly carried across the front of the other by contact of the side of the knee with the ground. In a case observed by Malgaigne, and in another quoted by him from Mercier, exaggerated inward rotation appeared to be the principal cause; both patients were women who slipped and twisted the foot inward while walking.

A case, exceptional not only by its mode of production but also by the age of the patient, was reported by Bartels and has been referred to above. The patient was a child eleven months old, and the dislocation was caused by the effort of a shoemaker to put on its shoe while it was sitting on its nurse's knee.

In two cases in which the head was split into two pieces, one of which remained in the socket attached to the ligamentum teres, it is evident that the flexion, adduction, and rotation were not carried far enough to turn the head out of the socket, and the dislocation, strictly speaking, was a complication of a fracture of the head produced by violent pressure of the inner segment against the outer and upper margin of the cavity; in like manner the dislocation may be facilitated by the breaking off of a considerable portion of the acetabular ring. There is reason to think that some dislocations are produced in

¹ Moffat: *Lancet*, 1878, vol. ii. p. 251.

this manner by violence acting directly upon the upper part of the thigh, as in the passage across it of the wheel of a heavy wagon.

It is by no means uncommon for a dorsal dislocation to be produced by the transformation of one downward and inward (obturator) during manipulations made to effect reduction, the head passing below and behind the acetabulum during flexion and adduction of the limb, and, in like manner, a dorsal may be transformed into an obturator dislocation.

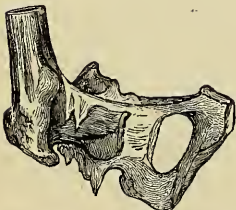
Occasionally dorsal dislocation takes place gradually while the patient is confined to bed by illness, especially by acute articular rheumatism and the infectious or eruptive fevers. These "spontaneous" dislocations are considered in Chapter LIII.

Pathology. The condition of the capsule and of the muscles about the joint and the position of the head of the femur have been clearly shown by direct examination of a considerable number of specimens of recent dislocation, and by old ones, and by experiment upon the cadaver. Among the autopsies of fresh dislocations recently reported may be mentioned those by Moxon,¹ MacCormac,² Adams,³ Morris,⁴ Lee,⁵ Humphry⁶ three cases, Rutherford,⁷ Stimson,⁸ and Walker.⁹

The capsule is torn always in its lower posterior part, and usually also in its under part, but the rent varies greatly in extent and shape. Frequently it lies about midway between the upper and lower posterior insertions of the capsule; sometimes the capsule is torn away from the femur, and, rarely, away from the acetabulum.

In Morris's, Lee's, and Walker's cases the conditions were exceptional; in the former (Fig. 328) "the capsule was ruptured on its lower and inner side, and was clearly peeled up from off the back of the neck of the femur as far as the digital fossa. The rent commenced below the pectineo-femoral band, midway between the acetabulum and the femur and ran (1) outward and backward to the neck of the latter, which it reached just above and behind the small trochanter, and (2) inward and backward across the thin portion of the capsule toward the acetabulum, which it nearly reached a little behind the ischial border of the cotyloid notch. It thus formed two sides of a large opening which was made quadrilateral in form by the detachment of the flap from the back of the femoral neck." Evidently the head had escaped downward.

FIG. 328.



Morris's case of dorsal dislocation; femur flexed and abducted to show the rent in the capsule.

In Lee's case the capsule was "freely lacerated all around, a small portion remaining attached to the femur in front and behind." This was, therefore, an "irregular" dislocation, and to the extensive laceration of the capsule corresponded a variation in the symptoms which

¹ Moxon: Medical Times and Gazette, 1872, vol. i. p. 96.

² MacCormac: St. Thomas's Hospital Reports, 1871, vol. ii. p. 143.

³ Adams: Transactions of the Pathological Society of London, 1870, vol. xxi. p. 305.

⁴ Morris: Medico-Chirurgical Transactions, 1877, vol. lx. p. 161.

⁵ Lee: St. George's Hospital Reports, 1872-74, vol. vii. p. 169.

⁶ Humphry: Lancet, 1886, vol. ii. p. 1011.

⁷ Rutherford: Glasgow Medical Journal, May, 1889.

⁸ Stimson: New York Medical Journal, August 10, 1889, p. 163.

⁹ Walker: Detroit Lancet, July, 1879.

fully corroborates Bigelow's views; the report says: "Two of the main signs of dislocation were absent, namely, the advanced position of the knee with the foot resting upon the opposite one, and marked shortening." The head of the femur was below the pyriformis muscle and immediately behind the acetabulum.

In Walker's the posterior rim of the acetabulum had been broken off, the posterior half of the capsule torn away, and the bone displaced to an unusual distance. The violence had been very great.

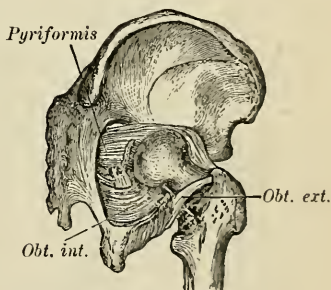
The preservation of the anterior portion of the capsule, the ilio-femoral ligament, is constant, as has been said, in the cases which Bigelow terms "regular," those which are marked by the common and characteristic symptoms of the dislocation, and, as he also pointed out, the strong portion of the capsule at its upper and posterior part is also usually untornd and opposes the ascent of the head upon the ilium.

The ligamentum teres is usually torn from its attachment to the femur, but sometimes is ruptured.

Of the muscles, the quadratus femoris is usually completely torn across, but sometimes (Humphry's third case) is intact; the gemelli commonly are torn, but the obturator internus which is so closely associated with them frequently escapes or is only partly lacerated, probably because of its greater length. The pyriformis and obturator externus are sometimes torn partly or entirely across; the glutei usually escape injury entirely or are only slightly lacerated.

The head of the femur may lie close to the margin of the acetabulum, even overlapping the cavity, or it may be displaced to a variable distance backward or backward and upward. The lowest point at which its centre rests is the base of the spine of the ischium (Adams¹ and Quain²) overlapping both sciatic notches; and the highest, except perhaps in exceptional cases, appears to be opposite the apex of the great sciatic notch, which, in the recumbent position, is directly below the anterior superior spine of the ilium, the line uniting the two passing about an inch above the margin of the cotyloid cavity. Fifty years ago Quain demonstrated by autopsy the error contained in the name given by Sir Astley Cooper to the lower form of dislocation "into the sciatic notch," and formally called attention to it; and a few years later Malgaigne showed that the head of the bone was much less upon the ilium in the higher form than was supposed, and further that in many, perhaps a majority, of the dislocations "upon the dorsum ilii" the femur left the socket at its lower posterior part and subsequently passed upward, so that in such cases the primary dislocation was "ischiatric," and the "iliac" was secondary. This view has been amply confirmed. In 11

FIG. 329.



Dislocation below and then behind and above the obturator internus.

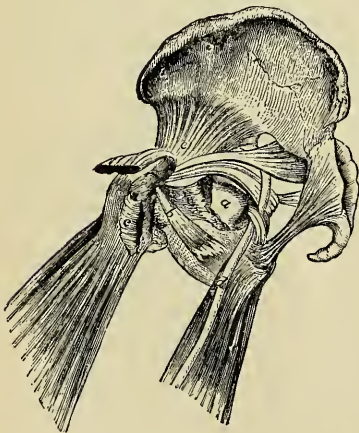
¹ Adams: *Loc cit.*

² Quain: *Medico-Chirurgical Transactions*, 1848, vol. xxxi. p. 337.

specimens of old dislocations which Malgaigne examined, the head of the femur rose in 5 only to the level of a line drawn from the anterior superior spine of the ilium to the apex of the great sciatic notch, in 2 it rose half a centimetre above this line, in 2 one centimetre, in 1 one and a half centimetres, and in 1 two centimetres. There is no reason to suppose that in old dislocations the head is at a lower level than in recent ones, indeed it is probably somewhat higher.

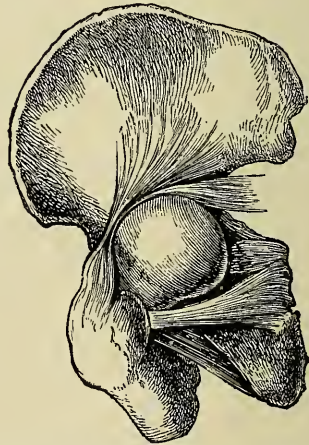
When the head of the femur leaves the socket at its lower part it passes usually below the obturator internus and then rises behind it, so that this muscle is interposed between it and the acetabulum (Fig. 329). Or it may lie immediately beneath the obturator internus and press it forcibly upward, as in Adams's case (Fig. 330), which remained unreduced until the patient's death on the fourteenth day, and in which the muscle was so tightly stretched over the upper part of the head that a deep groove had formed in the articular cartilage of the latter exactly corresponding in size and direction to the tendon; the head rested on the spine of the ischium, and the obturator externus and quadratus femoris were ruptured. Or the head may pass above the obturator internus, between it and the piriformis, as in MacCormac's case (Fig. 331), in which it rested "behind the acetabular ridge opposite

FIG. 330.



Adams's case: *a*, head of femur; *b*, obturator externus ruptured; *c*, quadratus femoris ruptured; *d*, sciatic nerve.

FIG. 331.



MacCormac's specimen of recent dorsal dislocation. The head of the femur lies just behind the acetabulum, below the piriformis, and above the obturator internus and the torn gemelli muscles.

the middle and upper part of the great ischiatic foramen, behind the posterior border of the gluteus medius, and only covered by the gluteus maximus and the integument." This is an example of a real primary "iliac" dislocation, and the rent in the capsule was "merely on the back part, and the neck was as it were locked over the acetabular ridge, and the strong anterior part of the capsule was tightly stretched."

The edge of the acetabulum is sometimes chipped, and in two of the cases above quoted (Quain, Morris) there was a fracture through

the ilium into the cotyloid cavity, and in the latter there was also a fracture of the ramus of the ischium. In both cases the injury was caused by great violence.

In a case reported by Birkett¹ the head of the femur was split vertically, the inner half remaining in the acetabulum and still attached to the ligamentum teres, and the other, continuous with the neck, being displaced backward above the obturator internus. A similar case, quoted above among compound dislocations, p. 715, was reported by Moxon; and in another reported by Riedel² the head and neck were split longitudinally, both fragments being displaced from the socket. Crile³ reported a case of fracture of the posterior third of the head and of the posterior half of the rim of the acetabulum. In my case the head of the femur was deeply indented, apparently by contact with an osteophyte close behind the rim of the acetabulum, and a portion of the labrum cartilagineum had been broken off. In a case seen by Lossen⁴ the neck of the femur had been broken at the moment of dislocation, but doubtless after the head of the bone had left the socket. In several reported cases the neck has been broken during an attempt to reduce, and in a few in which fracture has been recognized it has remained uncertain whether it occurred simultaneously with the dislocation or was caused by the surgeon. (See Chapter LIII.)

The sciatic nerve commonly lies behind the head of the femur and at the most is only slightly pressed upon, but in Quain's case it was stretched over the neck of the femur.

Symptoms. The patient is unable to bear his weight upon or voluntarily to move his injured limb; if he stands upright it shows moderate flexion and adduction, marked inversion, and more or less shortening, the toes resting on those of the other foot. When he is placed upon his back the apparent adduction and flexion are increased, the knee resting just above the other patella or crossing the thigh at a higher point. The contours of the outer and posterior regions of the hip are changed by loss of the normal depression behind the trochanter, elevation of the gluteal fold, and abnormal fulness due to the approximation of the insertions of the gluteal muscles. The trochanter rises to a variable distance above the line drawn from the anterior superior spine of the ilium to the tuberosity of the ischium, and its distance from the first-named prominence is increased. The head of the femur can be obscurely felt through the gluteus maximus and recognized by its movements when the limb is flexed or rotated. The empty socket cannot be felt from in front, because it is covered by the anterior portion of the capsule and the psoas and iliacus, but the depressibility of the soft parts in Scarpa's space is as great as, or greater than, that on the opposite side, whereas in fracture of the neck of the femur this depressibility is diminished.

The limb can be still further adducted and flexed, but it cannot be abducted or rotated outward. The apparent shortening varies greatly in degree in different cases, and the actual shortening cannot always be

¹ Birkett: *Medico-Chirurgical Transactions*, 1869, vol. lli. p. 133.

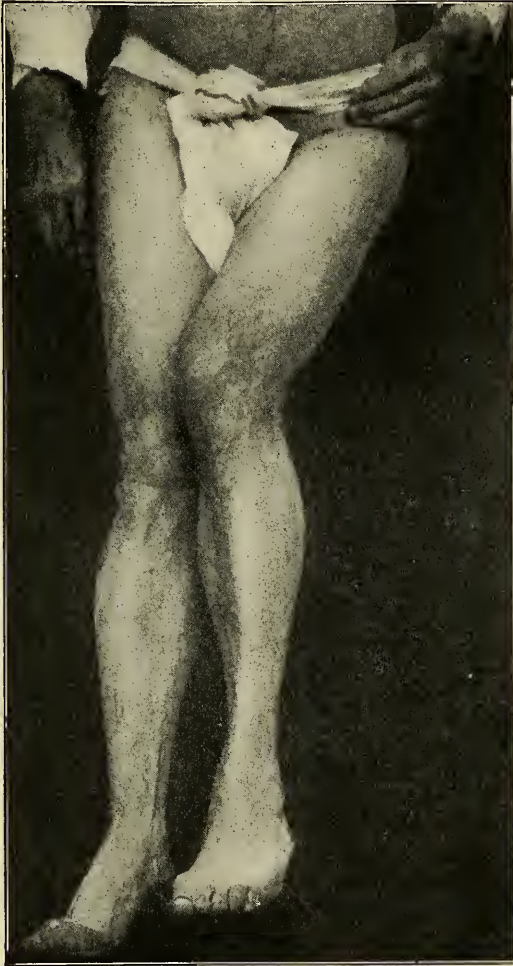
² Riedel: *Beilage zum Centralbl. für Chir.*, 1885, p. 92.

³ Crile: *Annals of Surgery*, May, 1891.

⁴ Lossen: *Deutsche Chir.*, Lief. 65, p. 55.

determined with accuracy because of the difficulty in placing the limbs symmetrically. Concerning this shortening the most contradictory statements have been made; some surgeons, relying solely upon the

FIG. 332.



Dorsal dislocation of the hip.

appearance of the limb and seeing that the knee lay well above the opposite one, have described the shortening as great; others, looking only to the new relations of the bones as shown upon the skeleton, have described the shortening as moderate or even as absent in the lower forms. The error in the first arises from not taking into account the effect of adduction to create an apparent shortening of the adducted limb when compared with its non-adducted, still more with its abducted, fellow; that in the second arises from considering the question only

with reference to the position of extension. If the head of the femur is displaced backward toward the spine of the ischium, the length of the limb measured in extension (if that is possible) from the anterior superior spine of the ilium to the knee or ankle will not be diminished, for the movement backward of the head has been at right angles to the line of measurement and has not brought the knee any nearer to the pelvis; but if the measurement is made while the thigh is flexed at a right angle the measured length will be less by about two inches than that of the other limb in the same position, for now the measured line is nearly parallel to the direction of displacement. When the head is displaced upward as well as backward the difference in the amount of shortening in these two positions of the limb is much less, for the direction of the displacement deviates at about the same angle from the measured line in each attitude. Of course, in each limb the measured length is less when the thigh is flexed, but the difference in the comparative measurements of the two limbs is not affected in the high dislocations and is greatly affected in the low ones. In making measurements the two limbs must be symmetrically placed as regards flexion and adduction, and the fixed adduction of the injured limb sometimes interferes seriously with the accomplishment of this condition, for its knee occupies the position to which the other one should be brought, and, therefore, an equal adduction cannot be given to the sound limb without carrying its knee across at a higher or lower level, and thus giving it an unsymmetrical flexion. It must also be remembered that apparent symmetry of position is not sufficient, the symmetry must be real in that the angles of flexion and adduction *on the pelvis* are the same. Fortunately the exact determination of the shortening is not necessary to the diagnosis of the dislocation.

When the head passes below the tendon of the obturator internus and does not secondarily rise upon the ilium, the inversion and flexion of the limb are greater than when the head comes to rest at a higher point, and may be so great that the limb crosses the opposite thigh as high as its middle. The flexion may be so masked by the tilting of the pelvis that the thigh will lie nearly along-side the other, parallel to the long axis of the body, but the condition can be recognized by attention to the compensatory curve (lordosis) of the lumbar vertebræ; indeed, Syme¹ said he made the diagnosis of ischiatic dislocation without other handling of the patient than that necessary to recognize the lordosis.

The cause of the comparative fixation of the limb, of its attitude, and of the loss of even passive abduction and external rotation was first clearly shown by Bigelow, in his classical monograph upon the *Hip*. Others had recognized, in a measure, the part taken by the strong anterior portion of the capsule in determining the attitude of the limb, but he was the first to study the subject in all its bearings and to present a complete account of the relations and influences of the Y-ligament in all forms of dislocation, one which was at once and everywhere accepted and has been made the basis of the present methods of reduction. He says,² "The inversion is chiefly due to the outer branch

¹ Syme: London and Edinburgh Monthly Journal, 1843, vol. iii. p. 498.

² Bigelow: The Hip, p. 38.

of the Y-ligament, as is shown by the fact that the characteristic sign disappears when this branch is divided."

Diagnosis. The recognition of the character of the injury is rarely difficult. The group of prominent symptoms—loss of function; adduction, inversion, and flexion of the limb; resistance to abduction, extension, and outward rotation; elevation of the trochanter above Nélaton's line—are not found in any other affection except perhaps hip-joint disease of long standing. The mistake most frequently made is that of confounding it with a fracture of the neck of the femur, or, to speak more definitely, is that of supposing a fracture of the neck to be a dislocation. I have met with several instances of this, some of which led to litigation. The differences between the symptoms of the two injuries are striking and usually sufficient to make the mistake impossible if ordinary attention is paid to them; the fixity of the limb in dislocation, with the knee thrown forward and inward against or upon the opposite thigh, the prominence of the trochanter, and, usually, its increased distance from the anterior superior spine of the ilium, contrast strongly with the straight, everted, powerless limb and flattened hip of fracture of the neck. Fractures with inversion and dislocations with eversion are entirely exceptional. When the two injuries have coexisted the diagnosis has sometimes been made by recognizing that the head, which could be felt out of its place, did not share in the movements communicated to the shaft,¹ and sometimes by the splitting and enlargement of the great trochanter.

2. Everted Dorsal Dislocations.

In this class, of which there are but few recorded cases, are here included Bigelow's anterior oblique, everted dorsal, and some of the supraspinous. It is characterized, as the name indicates, by eversion of the limb in place of the inward rotation which is so prominent a feature of the common dorsal dislocation, and this symptom is due in all cases, except perhaps the very rare anterior oblique, to rupture of the outer branch of the Y-ligament. In the supraspinous variety the head of the bone lies above the anterior inferior spinous process of the ilium in the notch between it and the superior spine.

Although occasional cases had been previously reported, the variety was not described by systematic writers before Bigelow, and was not even mentioned by Malgaigne, although possibly one or two of the cases classed by him as supracotyloid may have been of this kind. In a paper by Blasius² on supracotyloid dislocations several cases of this variety (everted dorsal) are included, together with others in which the head had reached nearly the same position by passing outward after primary dislocation forward and upward upon the pubis, and a few in which the dislocation was primarily directed upward. The same grouping has been followed by other writers, and in no reported case previous to 1850 does it appear to have been recognized that the head had reached this position by a secondary displacement after dislocation

¹ Koch: Berlin. klin. Wochenschrift, 1832, p. 492.

² Blasius: Arch. für klin. Chir., 1874, *l.* xvi. p. 207.

backward and upward. Blasius's paper, although published in 1874, must be classed with those of an earlier period, for it is really the republication by his son in a graduating thesis of researches made some time earlier, and it makes no mention of Bigelow's work. It is, in one respect, a publication to be regretted, for the authority of its writer and its date combine to further the acceptance without examination of the grouping, or classification, which cannot properly be accepted in view of the important pathological differences between the individual cases of which it is made up.

Cases reported before 1850 and quoted as of this kind by Bigelow and as possibly such in my first edition, appear to me to be more probably dislocations directly upward by hyperextension of the limb; I have recently seen such a one the symptoms of which closely resembled those quoted. (See Upward Dislocations.)

In 1850 the possibility of the production of this form by transformation of a dorsal dislocation was shown in an attempt made in the New York Hospital to reduce a dislocation "into the sciatic notch." The case is reported by Lente;¹ after traction had been made and suddenly relaxed the thigh was abducted and rotated outward, and this brought the head of the femur above the acetabulum, and below the anterior superior spinous process; the shortening was then about two inches; the limb very much rotated outward, the rotundity of the hip greater than that of the other, and the trochanter major one inch further from the anterior superior spinous process.

Five years later Van Buren² observed in the same hospital a case which, so far as I know, is the first in which the absence of inversion and marked adduction was noted in a case recognized as a dorsal dislocation. The limb "was shortened about an inch; the foot and leg were slightly everted. This eversion, it was afterward ascertained, could be readily increased by manipulation; but there was an evident obstacle at the hip to *inversion* of the foot. The knee was slightly flexed, so that the width of the hand could be readily passed between its popliteal aspect and the surface of the bed. The obliquity of the femur toward its fellow was very slightly increased. Upon the front of the thigh at its upper third a very manifest concavity or sinking in was noticeable, the usual anterior convexity of the limb being lost. The trochanter was about an inch and a half behind and above its usual position, and, during etherization, it was quite movable on attempting rotation of the limb. Finally, the head of the femur could be felt obscurely but pretty certainly rotating in the ischiatic notch, low down, and in contact with its posterior margin. The anterior convexity of the spine at the loins was also much increased, so that under ether more than the width of the hand could be passed between it and the surface of the bed. Thus the case presented all the classical features of luxation into the ischiatic notch, and more than usually well marked, with the exception of adduction of the lower end of the femur and

¹ Lente: New York Journal of Medicine, 1850, p. 314.

² Van Buren: New York Medical Times, 1856, vol. v. p. 126, and reprinted in his Contributions to Practical Surgery, p. 157.

inversion of the foot." After several failures to reduce by manipulation and traction downward, reduction was effected by traction while the limb was flexed at right angles to the pelvis, followed by abduction and extension.

In 1864 Symes¹ reported a case, and suggested for the variety the name of "dorsal with eversion." This was subsequent to Bigelow's researches but previous to his publication of them except in his lectures. The limb was shortened two inches, the foot extremely everted, the buttock flattened, and the head of the femur two inches below the anterior superior spine of the ilium. By flexion of the limb the dislocation was made dorsal, and a feature of special interest is that then, as the limb lay untouched upon the table, eversion gradually took place under the influence of gravity, and the head returned to its former place.

In 1874 Kocher² observed a similar case in a woman, forty-nine years old; the limb was fully extended, markedly everted, and shortened three centimetres; the head could be felt below and to the outer side of the anterior superior spine of the ilium. By flexion and inward rotation the dislocation became dorsal with the characteristic symptoms, and then by extension and outward rotation the original symptoms were reproduced.

Pathology. In a case which I reported to the New York Surgical Society, December, 1887, and January, 1888,³ the head could be distinctly felt below and rather to the outer side of the anterior superior spinous process; the outer branch of the Y-ligament was ruptured and the muscles behind the trochanter extensively lacerated. Complete reduction was prevented by interposition of the antero-inferior part of the capsule.

Van Buren's case, and a very similar one reported by Annandale,⁴ show that the head may lie much further to the outer side and lower.

Bigelow's experiments show that this eversion depends upon the rupture of the outer branch of the Y-ligament. The head of the femur escapes at the back of the joint while the limb is flexed, adducted, and rotated inward, and then by external rotation the outer branch is torn; if, then, the head remains in its position opposite or below the sciatic notch, the position and symptoms are such as are noted in Van Buren's and Annandale's cases, the flexion and slight adduction being due to the remaining untorn branch of the ligament. The change in the position of the head noted in the other cases Bigelow was able to reproduce experimentally from a common dorsal dislocation by carrying the limb "across the symphysis, so that the outer and convex surface of the socket shall correspond to the hollow beneath the neck of the femur. With some force the thigh can now be everted, and afterward brought down across the upper part of its fellow." (This is the form to which he gave the name "anterior oblique.") "If, in this position, it is desired to bring the limb toward a perpendicular, the outer branch of the Y-ligament must be ruptured. Thus

¹ Symes: Dublin Quarterly Journal of the Medical Sciences, 1864, vol. xxxviii. p. 272.

² Kocher: Volkmann's Sammlung klin. Vorträge, No. 83, p. 631.

³ Stimson: New York Medical Journal, January and February, 1888.

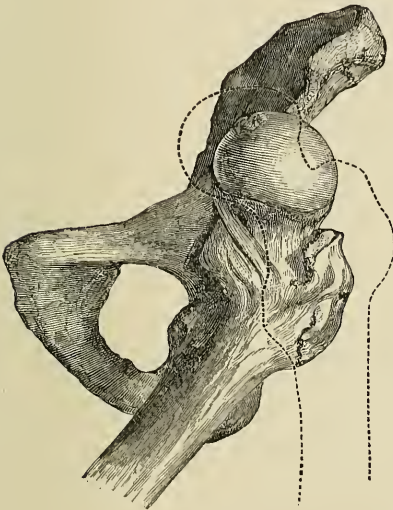
⁴ Annandale: Lancet, 1876, vol. i. p. 208.

liberated, it hangs suspended by the inner ligament, and becomes capable of lateral motion and of rotation; and this is probably the condition under which supraspinous luxation, although rare, usually occurs."

Fig. 333 shows in the dotted lines the head of the femur thus hooked over the remaining part of the ligament.

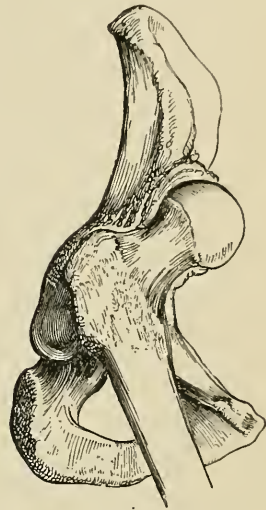
The *anterior oblique* is a variety which I feel some hesitation in preserving, because Bigelow appears to have observed it only in experiments upon the cadaver, and to have known of only one recorded case² in which the attitude resembled that found in his experiments. The specimen in that case is represented in Fig. 334. The mode of production has been quoted in the preceding paragraph. The Y-ligament is untorn.

FIG. 333.



Supraspinous dislocation. When the femur takes the position indicated by the dotted line, only the inner branch of the Y-ligament remains untorn. (BIGELOW.)

FIG. 334.



Anterior oblique dislocation.
Oldnow's case.

Symptoms. The symptoms of the everted dorsal may be the same as those of the common dorsal dislocation, with the exception that there is marked or slight eversion of the limb instead of inversion; or, if the head of the femur has moved forward above the anterior inferior spinous process, they may differ widely, for the limb is then shortened about two inches, slightly abducted, more or less everted, and fully extended. In my case, a woman fifty-five years of age, the limb was parallel with the other and so far everted that the foot rested on its outer border; it could be adducted and flexed but not abducted or rotated inward. Shortening one and three-quarter inches. By flexing and adducting the limb and then rotating inward the attitude and appearance became that of the common dorsal variety. Reduction

¹ Oldnow: Guy's Hospital Reports, 1836, vol. i. p. 97.

was made by flexing to a right angle, rotating inward, and then lifting. The patient died about a month after the accident (associated injuries and phthisis). The eversion of the limb is liable to lead to the mistake of supposing the injury to be a fracture of the neck of the femur, especially in the cases in which the limb is also extended. The greater fixation of the limb and the recognition of the position of the head and of the continuity with the shaft, as shown by its sharing in the movements communicated to the latter, will establish the diagnosis.

The rupture of the outer branch of the Y-ligament is the explanation of the inability noted in some of the cases to reduce by manipulation alone; traction in the flexed position is needed to bring the head forward into the socket; abduction fails to do it because of the loss of the support of the outer branch of the ligament.

Treatment of Backward Dislocations.

The method of reduction so long in use, and which left so many dislocated hips unreduced, that in which it was sought to draw the bone into place by traction upon it with compound pulleys while the limb was almost fully extended, has at last been abandoned in favor of the methods of simple manipulation or of moderate traction in the flexed position, or of a combination of the two. The advantages of the flexed position, the possibility of reducing by the aid of moderate traction when the thigh is flexed at a right angle with the trunk, were repeatedly pointed out by different writers during the last century and the first half of the present one (see Chapter XXXIII.), and the possibility of reducing by manipulation alone (flexion, outward rotation, and abduction) was also demonstrated, but neither seems to have had any influence in modifying the general practice, although some surgeons, notably Prof. Nathan Smith of New Haven, taught and habitually practised traction with the limb flexed at a right angle, and he also, in 1831, formulated a method by manipulation alone.

Desprès,¹ in 1835, independently formulated the method by flexion and outward rotation; and Reid,² in 1851, did the same, preceding the flexion with marked adduction; but they assumed that the principal obstacle to reduction lay in the resistance of the muscles, and their manipulations were designed to overcome or avoid this.

Bigelow³ quotes Smith's description of this method by manipulation from his *Medical and Surgical Memoirs*, edited in 1831 by his son, Nathan R. Smith, as follows: "The first effort which the operator makes is to flex the leg upon the thigh, in order to make the leg a lever with which he may operate on the thigh bone. The next movement is a gentle rotation of the thigh outward, by inclining the foot toward the ground and rotating the knee outward. Next, the thigh is to be slightly abducted by pressing the knee directly outward. Lastly, the surgeon freely flexes the thigh upon the pelvis by thrusting the knee

¹ Desprès: Bull. de la Soc. Anatomique, September, 1835, p. 4.

² Reid: Buffalo Medical Journal, August, 1851.

³ Bigelow: Lancet, 1878, vol. i. p. 861.

upward toward the face of the patient, and at the same moment the abduction is to be increased." Bigelow adds, "this covers the ground of priority of invention. It belongs to Nathan Smith. . . . In 1835, Desprès, and in 1851, Reid, of Rochester, enunciated the same views; the practice was good, but both Prof. Smith and Dr. Reid based the method upon and sought its mechanism in its erroneous theory of muscular resistance."

After 1850 the attention of surgeons and anatomists began to be directed more specifically to the opposition offered by the untorn portions of the capsule and to the position of the rent in it, and many experiments were made upon the cadaver to obtain a more accurate knowledge of the matter. Among these may be mentioned those of Meyer,¹ Gunn,² Roser,³ Bigelow,⁴ Gellé,⁵ Busch,⁶ and Tillaux.⁷ Of these Bigelow's researches were by far the most complete and accurate, and to his classical work must be referred the popularization and general acceptance of the views now held and the methods of treatment based upon them. The importance of the anterior portion of the capsule, the Y-ligament, had indeed been specifically pointed out by one or two earlier writers—it is mentioned in Hyrtl's *Topographische Anatomie*, in Meyer's paper in 1850, and by von Pitha⁸ in 1863—but Bigelow was the first to study its influence in detail, to show its constant action in all typical forms, and to base upon it methods of reduction for the different forms, and to him belongs the credit not only of independent discovery but also of the still more important benefit conferred by impressing the facts upon the profession by his careful, thorough investigations and his clear exposition of the facts and principles.⁹

It is now generally recognized that the chief obstacle to reduction is created by the tension of the Y-ligament in the partly extended position of the limb, and that this is to be removed by flexion of the limb upon the trunk. At the same time the movement of flexion brings the head of the femur down along the back of the acetabulum so that it lies opposite the opening in the capsule if, as is usually the case, it has left the socket at its lower posterior part and has risen to a higher level by the subsequent extension of the limb, enlarging the rent upward in the movement; if, more rarely, the head has left the socket at a higher level while the limb was only slightly flexed, this movement of flexion in reduction, unless carried beyond a right angle, does not place the head below the opening, or at least, if it does so, the movement enlarges the rent downward so that the way is still open for the return of the head to its place. Another reason for making this movement is found in some cases in the interposition of the obtu-

¹ H. Meyer: *Zeitschrift für rat. Med.*, 1850, vol. ix. p. 250.

² Gunn: *Penins. Journal of Medicine*, 1853-4, vol. i. p. 97.

³ Roser: *Archiv für phys. Heilkunde*, 1857, vol. i. p. 42.

⁴ Bigelow: *The Hip*, 1869. Experiments made in 1860.

⁵ Gellé: *Arch. gén. de Méd.*, 1861.

⁶ Busch: *Arch. für klin. Chir.*, 1863, vol. iv. p. 11.

⁷ Tillaux: *Bull. de la Soc. de Chir.*, 1868, p. 274.

⁸ Von Pitha: *Pitha and Billroth's Chirurgie*, vol. iv. part 2. B, p. 161.

⁹ The claim of priority in the discovery of the part played by the anterior portion of the capsule made for Prof. Gunn, of Chicago, is, I think, sufficiently answered by Prof. Bigelow in a letter published in the *Chicago Medical Examiner*, January, 1870, p. 25.

rator internus between the head and the socket, the cases, so-called, of "dislocation below the tendon" in which the head has secondarily risen toward the dorsum ilii. During the movement the adduction and internal rotation of the limb are preserved or even somewhat increased in order to lift the head of the femur away from contact with the pelvis and from behind the projecting rim of the acetabulum.

The directions given by Bigelow in his first publication¹ are as follows :

"*By Traction.* Lay the patient, when etherized, on his back upon the floor, bend the limb at the knee, flex the thigh upon the abdomen, adduct and rotate it a little inward, to disengage the head of the bone from behind the socket. The Y-ligament is then relaxed.

"If the bone can now be abducted beyond the perpendicular, the capsule and other tissues are probably so torn or relaxed that reduction may be accomplished without much difficulty ; the thigh need only be forcibly lifted or jerked toward the ceiling, with a little simultaneous circumduction or rotation outward, to direct the head of the bone toward the socket."

In his later paper in the *Lancet*, 1878, he gives them more briefly in the following terms :

"1. Flex and forcibly lift. If this fails,

"2. Flex and lift while abducting. If this fails, it will be found that the rent in the capsule has been so enlarged that the first method may now prove successful."

Bigelow adds to his first description three other methods of making the manipulation and applying the force, and, although the mechanism is the same in all, the multiplicity of the directions has been criticised by recent German writers, who seem to regard the four as essentially different from one another.

Kocher,¹ after making this criticism, describes what he calls his own method, and this is quoted approvingly by Albert and König. Its identity with Bigelow's appears to me to be complete, although it combines his two methods by traction and by manipulation. It is as follows:

1. *Inward rotation* to relax the capsule and lift the head from the posterior surface of the pelvis.

2. *Flexion*, to a right angle and gently, preserving the existing adduction and inward rotation.

3. *Traction*, to make the capsule tense, so that it can be utilized in the following movement, and to raise the head to the level of the acetabular margin, thus overcoming the action of gravity.

4. *Outward rotation* ; this makes the posterior part of the capsule and outer band of the Y-ligament tense, and turns the head forward into the socket.

There are a number of practical points connected with the carrying out of these directions which require attention. The pelvis may need to be steadied or immobilized during traction, in order that the limb may not be too soon or unwittingly abducted, and this may be done either by the hands of assistants or by the pressure of the surgeon's

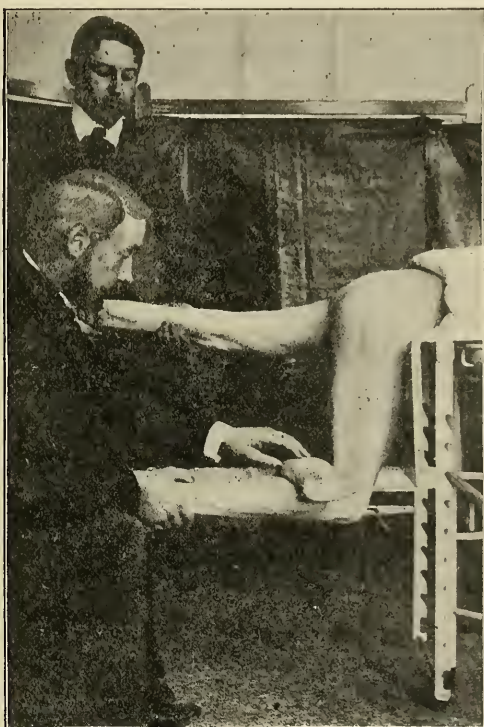
¹ Bigelow : *Loc. cit.*, p. 46.

² Volkman's klinische Vorträge, No. 83.

foot upon the anterior superior spinous process of the ilium of the injured side while he is lifting the thigh.

The traction upon the thigh may be made by the hands of the surgeon, but if the patient is a muscular adult the force that can be thus exerted may be insufficient, and it can then be conveniently supplemented by passing a bandage tied in a long loop under the patient's flexed knee and over the surgeon's shoulders; this leaves his hands free to rotate the thigh by means of the leg. It is important to remember that reduction is to be made by traction, not by manipulation, for if the thigh falls backward by its own weight or is pressed back by the surgeon while he is "manipulating" it may seriously change its relations with the tissues about it.

FIG. 335.



Reduction of dorsal dislocation of the hip by the weight of the limb.

A much more convenient plan, one which I have habitually employed for many years,² is to place the patient face downward upon a table with his legs projecting so far beyond the edge that the injured thigh hangs directly downward while the surgeon grasps the ankle, the knee being flexed at a right angle (Fig. 335). The other limb is held horizontal by an assistant. The weight of the limb now makes the needed traction in the desired direction, and the surgeon has only to wait for the muscles to relax and the bone to resume its place with-

¹ Stimson: *New York Medical Journal*, August 3, 1889.

out further effort on his part than a slight rocking or rotation of the limb. Occasionally I have added the weight of a small sand-bag at the knee or have made sudden slight pressure at the same point. It will often succeed without anæsthesia and sometimes so quietly that there is no jar or sound indicating the return to place. In only two cases has it failed in my hands; both were then reduced by traction in the axis of the partly flexed limb. I presume that in both the bone had left the socket at its upper posterior segment—"iliac" dislocation.

If manipulation alone is used external rotation must be carefully avoided during the first steps, lest it should convert the dislocation into an everted dorsal by throwing the head forward above the socket; and extreme flexion and abduction without simultaneous traction are also to be avoided, in order to escape the conversion of the dislocation into one upon the obturator foramen by the passage of the head below the socket.

The *everted dorsal* dislocations are reduced after having first converted them into the dorsal form. This conversion is effected by flexion and inward rotation, with adduction, if necessary, to make room for the head of the bone to slide upon the ilium; the rupture of the outer branch of the Y-ligament deprives the operator of much of the advantage of rotation, and the dislocation must, therefore, be reduced by direct traction toward the socket, with local guidance of the head. In my own case, in which, after conversion into the dorsal form the tendency of the head again to pass forward above the acetabulum was very marked, outward rotation had to be carefully avoided.

The possibility of fracturing the neck of the femur during manipulation must be borne in mind (see Chapter LIII.).

CHAPTER LII.

DISLOCATIONS OF THE HIP.—(CONTINUED.)

Dislocations Downward and Inward: Obturator, perineal—Forward and Upward: Suprapubic, iliopectineal—Upward: Subspinous, supracotyloid—Downward on the Tuberosity of the Ischium.

DISLOCATIONS DOWNWARD AND INWARD.

1. OBTURATOR or thyroid dislocations, or dislocations upon the thyroid foramen; and 2, perineal dislocations.

In this class of dislocations the head of the femur leaves the socket at its lower, or lower and inner, part, and passes forward and inward to rest upon the obturator foramen (obturator dislocation), or passes still further, and, crossing the ischio-pubic ramus, projects in the perineum (perineal dislocation). The limb is flexed, abducted, and usually rotated outward.

Obturator or Thyroid Dislocations.

These dislocations, although infrequent, are apparently the second in order of frequency of those of the hip, and it seems not improbable that this form, in part at least, is the first stage in the production of some of the suprapubic, and even some of the dorsal dislocations; that is, the head of the bone, having left the socket at its lowest part in forced flexion of the limb, may either be turned backward behind the acetabulum by adduction, internal rotation, and diminution of the flexion, or forward and upward upon the pubis by external rotation and extension; the obturator form is produced by its passage more directly forward and inward upon the obturator foramen by abduction and external rotation.

Cause. The commonest cause appears to be great violence acting upon the back of the pelvis while the limb is flexed and abducted, as in the fall of a heavy object upon the back of a man who is stooping forward with his legs separated. Simple abduction of the extended limb is apparently sufficient to produce the injury, as is shown by a case reported by Corne,¹ in which the thigh of a drunken soldier was forcibly abducted by his comrades. In a case reported by Keate,² and another by Barker,³ the mechanism was apparently the same; in the former the patient, while riding, fell into a ditch, his horse falling upon him and widely separating his legs; the head of the femur lay close to the tuber ischii. In the latter the patient fell from a height of about thirty feet, striking upon a sandbank and having his legs widely separated; both thighs were dislocated.

¹ Corne: Recueil de Mém. de Méd. Mil., February, 1867, quoted by Lossen.

² Keate: London Medical Gazette, vol. x. p. 19, quoted by Bigelow.

³ Barker: American Journal of the Medical Sciences, 1854, vol. xxvii. p. 412.

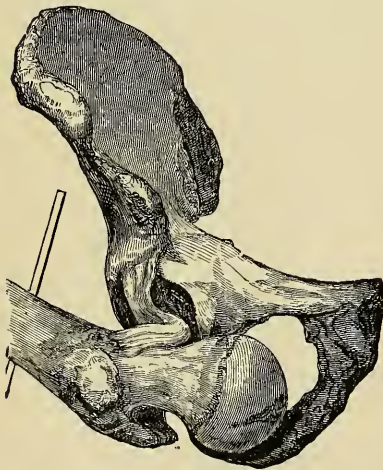
In another set of cases it is difficult to determine whether the cause has been direct impulsion of the head of the femur downward and inward by a force acting on the outer side of the great trochanter, or whether it has been exaggerated abduction by pressure forward of the outer part of the pelvis, as in a case reported by Treub,¹ in which a man while lying on his face was run over by a wagon, the wheels passing obliquely across his left hip at the level of the trochanter and the pelvis from left to right, and received a dislocation of the left hip.

Pathology. The reported autopsies in recent cases are very few.¹ They show rupture of the capsule on the inner and lower side, usually near the acetabulum and sometimes extending along the neck, and laceration of the obturator externus and pectineus. Sometimes the obturator is pushed before the head of the bone. In one case (Duboué) the femoral vein was torn. The head of the femur rests on the obturator foramen or on the ramus beyond it. In a recent one of my own the ligamentum teres was untornd; in another³ it was torn at its femoral insertion, there was a ragged rent in the capsule by the cotyloid notch, and slight laceration of the obturator externus and adductor magnus. In a case reported by Werner⁴ the ascending ramus of the ischium was broken.

Several specimens of old dislocation have been examined: those of Moreau and Stanski, quoted by Malgaigne, Cooper,⁵ and Sédillot.⁶

In these the head occupied the foramen ovale more or less completely, and a new socket had been formed by the growth of bone around it; in Cooper's case the head was so completely enclosed by this new socket that it could not be removed from it without breaking its edge, and yet it was freely movable and was covered with articular cartilage. In Stanski's the Y-ligament had been completely transformed into bone, and the head of the femur lay near the tuberosity of the ischium, the limb being much flexed and abducted. In Sédillot's the head of the femur was atrophied and irregular, but the limb was so serviceable that the patient was a professional soldier, and shared in all the campaigns of the army.

FIG. 336.



Obturator dislocation. (BIGELOW.)

Experiments upon the cadaver corroborate the clinical and post-

¹ Treub: *Centralblatt für Chirurgie*, 1882, p. 729.

² Verhaeghe, *Gazette des Hôpitaux*, 1851, p. 283; Schinzinger, *Wiener med. Presse*, 1880, No. 3, quoted by Poinso; Curling, *Medical Times and Gazette*, 1853, vol. ii. p. 423; Duboué, *Bull. de la Société Anatomique*, 1858, p. 496; Annandale, *British Medical Journal*, 1870, vol. i. p. 101.

³ Bolton: *Annals of Surgery*, October, 1902, p. 586.

⁴ Werner: *Beiträge zur klin. Chir.*, vol. xli.

⁵ Cooper: *Loc. cit.*, p. 50.

⁶ Sédillot: *Gazette des Hôpitaux*, 1861, p. 94.

mortem data concerning both the pathology and the mode of production. If the dislocation is produced by abduction of the extended limb the rent in the capsule is found to lie on the inner side of the joint, while, when it is produced by abduction and outward rotation following flexion, or by transformation of a primary dorsal dislocation, the rent is mainly on the under side, and its extension in front and upward is effected by secondary displacement of the head. The Y-ligament, remaining unton, keeps the limb partly flexed, abducted, and everted, the head of the femur rests against the inner and lower side of the acetabulum, and is prevented from rising by its pressure against this part of the bone and by the unton portion of the capsule above.

A case of compound dislocation has been quoted in Chapter LI.

In a case reported by Cooke¹ the shaft of the femur was also broken just below the trochanters; the patient was a boy nine years old, and the injury was caused by a fall. Probably the dislocation was first produced, and then the bone was broken by a continuation of the force, or by a second blow. Reduction was easily effected by direct pressure on the head, and the patient made a good recovery.

Symptoms. The limb is flexed, abducted, and usually rotated outward, and it appears to be elongated because the foot is projected and brought to the ground by a compensatory tilting of the pelvis forward and downward on the same side (Figs. 337, 338). The trochanteric region is flattened, and the trochanter lowered and displaced inward; the adductors are usually tense. The outward rotation of the limb is not marked and may be absent, or there may even be some inward rotation.

The statements concerning the comparative length of the limbs on measurement are contradictory, presumably because of the failure of some observers to place the two limbs in symmetrical positions, or because of the greater or less abduction and flexion of the limb when measured. Thus, in marked flexion and abduction measurement from the anterior superior spine of the ilium to the knee or ankle will show shortening of the injured limb; while, if the limb is extended and but slightly abducted the measurement may show an actual elongation.

The head of the femur may be more or less distinctly felt on deep pressure toward the obturator foramen from the inner side. The statement occasionally made that the head can be felt to move by the finger in the rectum pressed against the inside of the foramen when the limb is rotated is an error of observation. The same sensation can be obtained when the joint is not dislocated, and is due to the alternate stretching and relaxation of the obturator internus during the movement.

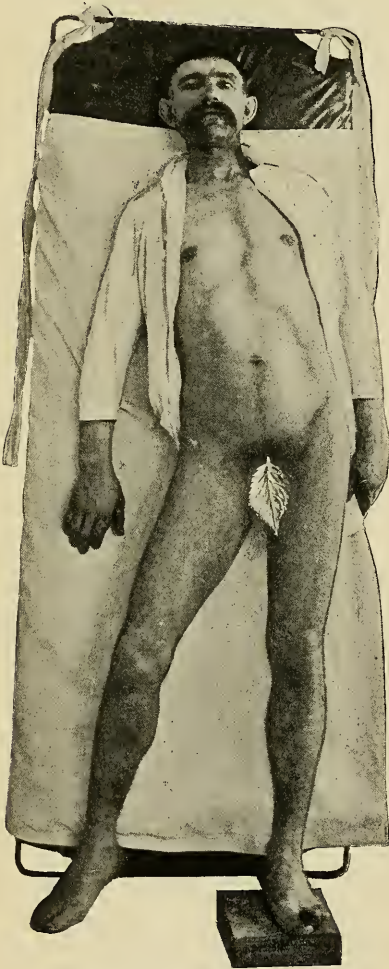
Sometimes the patients have been able to walk quite well immediately after the accident, and some of them have not sought advice until after the lapse of several days. Sédillot states that this was so in three of the five cases which he had seen, and one of the patients came to him only because he noticed that he could not completely adduct the limb.

The diagnosis of the dislocation and of the variety is made by

¹ Cooke: *Lancet*, 1864, vol. i. p. 37.

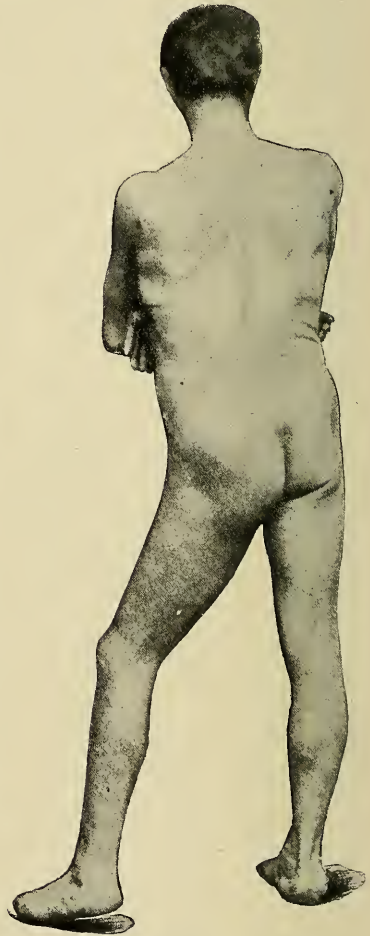attention to the attitude and fixation of the limb, the impossibility of completely extending and adducting it, the elongation in the extended position, the depression of the trochanter, and the presence of the head of the femur in its new position.

FIG. 337.



Obturator dislocation. (STIMSON.)

FIG. 338.



Obturator dislocation. (JOHNSON.)

Treatment. Bigelow, in his original paper, gives ten procedures for reducing thyroid and downward dislocations, which may be grouped as four different methods: 1, manipulation; 2, traction in the axis of the flexed and abducted limb; 3, traction outward against the upper part of the thigh; 4, transformation into a dorsal dislocation, and reduction as such. In his last paper¹ he seems to prefer the last

¹ Bigelow: *Lancet*, 1878, vol. i. p. 861.

method, adducting the thigh in order to carry the head to the dorsum and enlarge the opening in the capsule, and then reducing by flexion and forcible lifting of the head toward the socket.

His directions¹ for reducing by manipulation are: "Flex the limb toward a perpendicular, and abduct it a little to disengage the head of the bone; then rotate the shaft strongly inward, adducting it, and carrying the knee to the floor. The trochanter is then fixed by the Y-ligament and the obturator muscle, which serve as a fulcrum. While these are wound up and shortened by rotation (Fig. 339), the descending knee pries the head upward and outward to the socket. . . . In this manœuvre the action of the ligament may be aided, if necessary, by a towel passed round the head of the femur to draw it upward and outward. Rotation outward may be substituted for inward rotation."

The clinical histories show that inward and outward rotation have succeeded, each after the other has failed, and that the former is quite likely to transform the dislocation into a posterior one; as outward rotation most surely prevents this change, surgeons appear now to prefer it. The directions given by Kocher,² and approvingly quoted by the German surgeons, are as follows:

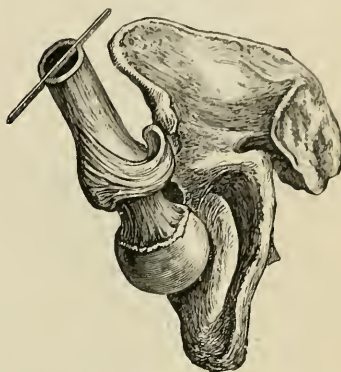
1. Flexion of the thigh to a right angle with the pelvis, while preserving the abduction and outward rotation in which the limb is found. This leaves all parts of the capsule relaxed.
2. Traction, to make the posterior part of the capsule tense, and to bring the head nearer the socket.
3. Outward rotation, which, acting through the tense posterior portion of the capsule and outer branch of the Y-ligament, brings the head upward and backward into place.

Direct pressure or traction outward upon the upper part of the thigh has often proved a valuable aid, either by directly moving the head of the femur toward the socket or by furnishing a fulcrum by means of which the head could be moved in this direction by adducting the knee. One of Bigelow's procedures, for example, is to place the patient "in a sitting posture with a log, or post, or bedpost between his thighs, and pry the head outward over this fulcrum by means of the long shaft of the femur."

My own cases have been easily reduced, under ether, by increasing the flexion and rotation, making traction in the long axis of the limb, and then lowering and rotating inward.

Kocher³ reduced a dislocation of four weeks' standing, which had resisted all other methods, by making continuous traction in the axis

FIG. 339.



Reduction of obturator dislocation by rotation; showing the mechanism of the manœuvre. (BIGELOW.)

¹ Bigelow: *The Hip*, p. 79.

² Kocher: *Volkman's klin. Vorträge*, No. 83.

³ Kocher: *Loc. cit.*, p. 620.


of the limb and combining with it elastic traction laterally on the upper part of the thigh. On the morning of the fourth day reduction was found quietly to have taken place.

In a case in which the dislocation had existed for twenty months and the disability was great, MacCormac excised the head and trochanter with a good result. The patient was a sailor nineteen years old. For details of the case (see Chapter LIII.).

Perineal Dislocations.

The recorded cases of this form are not numerous.¹ It is characterized by the presence of the head more superficially placed than in the obturator variety and displaced to a greater distance from the socket, so as even in one case to press upon the urethra and interfere with the

FIG. 340.



Perineal dislocation of hip. (STIMSON.)

voiding of the urine. In Taylor's case, quoted above among compound dislocations of the hip, page 723, the dislocation was made compound by a rent in the integument of the perineum nearly two inches long; and, possibly, Woodward's case, quoted in the same section, may be looked upon as an extreme form of this variety.

The cause appears to be extreme abduction of the limb, caused in my three cases by the fall of a heavy body upon the patient's back as he stood or knelt with the thigh flexed and abducted. Probably the

¹ See also a paper by Riedinger in *Münch. med. Wochenschrift*, August 16, 1892.

capsule is widely torn, and thus may be explained the varying attitude of the limb in respect of inversion or eversion. In an autopsy reported by Shaw¹ not only was the capsule extensively detached at its inner and posterior insertion upon the acetabulum, but also the iliofemoral ligament was partly separated from the neck of the femur, and a small rent extended from that point into the capsule.

In my three cases² the thigh was flexed and abducted so that it stood far out from the side of the body, making an angle of between 60 and 70 degrees with the sagittal and frontal planes (Fig. 340). When the other limb was placed as nearly as possible in the corresponding position (the same degree of abduction could not be obtained) the distance between the knees was thirty inches, and measurement from the anterior superior spine to the knee showed from one and a half to four centimetres shortening. A rounded mass, the head of the femur, could be felt beginning one inch from the mid-line of the perineum and extending forward to the adductor longus and backward nearly to the level of the anus. Adduction and extension painful and opposed; slight additional flexion and rotation possible. All were easily reduced by the method given above, flexion and traction.

Theoretically reduction should be most readily effected by traction in the axis of the abducted limb and by direct pressure upon the head of the bone or upon the upper part of the shaft, anæsthesia being used to prevent opposition by the muscles. The extensive laceration of the capsule and ligaments would probably make purely manipulative methods ineffective.

DISLOCATIONS UPWARD AND FORWARD, AND INWARD AND FORWARD. SUPRAPUBIC.

Iliopectineal. Pubic. Intrapelvic.

In these dislocations the head of the femur comes to rest upon the superior ramus of the pubis, either at the iliopectineal eminence above and a little to the inner side of its normal position (iliopectineal), or, more rarely, nearer the symphysis pubis (pubic). On the one side the position merges into that of the supracotyloid, and on the other into that of the obturator. Some of the iliopectineal, in which the head has remained very close to the anterior inferior spine of the ilium, have been described by their reporters and others under the name *supracotyloid*, and some writers describe the pubic variety as a variety of the obturator, or, rather, of a class to which they give the name *præglenoid* or *dislocations forward and inward*. Exceptionally the head may pass under or through Poupart's ligament and rest in the iliac fossa, the *intrapelvic* or *suprapectineal* dislocations.

The head of the bone may leave the socket at its upper and inner part, and in this case it appears probable that the head rests on the iliopectineal eminence, or it may leave it at a somewhat lower point

¹ Shaw: Transactions of the Pathological Society of London, 1859, vol. x. p. 211.

² For full details of two see New York Medical Journal, August 3, 1889; the third is shown in Fig. 319.

and pass inward and forward to the symphysis, or it may pass at first inward and downward across the obturator foramen while the limb is flexed, and then move upward to rest upon the upper and front surface of the superior ramus of the pubis as the limb is subsequently lowered. It is to be remembered that the upper border of the symphysis pubis is a little below the level of the centre of the cotyloid cavity in the upright position.

In correspondence with these differences in the position taken by the head are found differences in the mode of production, according as the head is moved more directly upward, upon the iliopectineal eminence, by hyperextension of the limb, or is first turned more directly forward by outward rotation and abduction and then, after rupture of the anterior and inner part of the capsule, is pressed upward or inward. Of the former there are a number of clinical examples in which the limb itself has been hyperextended, or, more commonly, the trunk has been violently pressed backward while the limb was fixed; thus, a man steps into a hole and falls backward; another, wrestling, is forcibly bent backward by his antagonist. Of the latter, outward rotation and abduction, the clinical instances are not so clear, but the possibility of the production in this manner has been fully proved by experiment upon the cadaver; a muscular woman,¹ carrying a keg of potatoes on her back, stumbled and, to avoid a fall forward, threw her body with a twisting movement backward; a man² while swimming made a vigorous thrust with his legs and felt a sharp pain in the groin; he was still able to walk, though with much difficulty, and on examination a dislocation upon the pubis was found.

Pathology. The pathology has been shown by several autopsies in recent and old cases. Aubry³ found the capsule torn along its anterior half near its insertion upon the acetabulum; the psoas and the crural nerve crossed the front of the neck; the head of the femur lay between the psoas and pectineus, raising the latter and the vessels; there was an interval of two centimetres between it and the anterior inferior spinous process of the ilium. Roser⁴ found the rent in the front of the capsule extending from the anterior inferior spinous process down to the notch; the psoas and iliacus were pushed outward, and the vessels crossed the head; the small external rotators were drawn inward and pressed into the acetabulum by the great trochanter. Albert (*loc. cit.*, p. 276) found the head resting against the outer side of the iliopectineal eminence and covered on its inner half by the psoas and iliacus; when it was pressed further upward the muscle lay across its neck. The iliopectineal fascia (the deeper part of the sheath of the vessels) was unorn, but nevertheless the artery was displaced outward by the head so that it rested across its centre and curved outward immediately below Poupart's ligament; the capsule was torn above and in front for about one-third of its circumference, the greater part of the iliofemoral ligament being uninjured; the ligamentum teres was torn away at its insertion upon the head, and the cartilaginous rim of the acetabulum was entirely uninjured; the posterior rotators were relaxed

¹ Albert: *Chirurgie*, vol. iv. p. 274.

² Ure: *Lancet*, 1857, vol. ii. p. 470.

³ Aubry: *Bull. de la Société de Chirurgie*, 1853, vol. iii. p. 377.

⁴ Roser: *Arch. für phys. Heilkunde*, 1857, vol. i. p. 58.

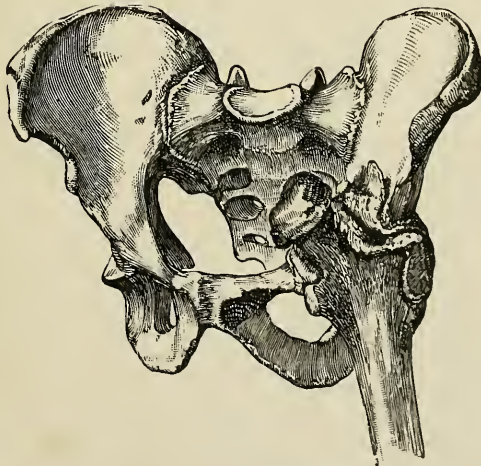
Kocher¹ found the capsule torn along its anterior half close to its insertion upon the femur, the portion which remained attached to the acetabulum hanging as a flap between the head and the socket; the psoas and iliacus were stretched across the neck of the bone, and the vessels lay to the inner side of the head; the ligamentum teres was torn away near its attachment to the acetabulum, and the cartilaginous rim of the socket was uninjured.

Borchard² reports a case with avulsion of the great trochanter and a hernia beneath the detached Poupart's ligament, and cites a similar case reported by Lauenstein.

In a case reported by Stokes³ in which the head had passed over the brim into the pelvis, the superior ramus of the pubis had been fractured and much comminuted. The patient died on the table immediately after reduction, by pulmonary embolus, it was thought.

Cases in which the dislocation was compound have been quoted in Chapter LI., p. 723; in one of them the femoral vein was ruptured. In a case reported by Goldsmith and quoted on p. 424, in which the dislocation had remained unreduced for two months when the patient came under observation, there was found a diffused pulsating swelling occupying the iliac fossa and extending down to the middle of the thigh, which had appeared a few days after the accident; the external iliac artery was tied, and at the patient's death, five days later, the femoral and external iliac arteries were found to be perforated for the distance of an inch on their postero-external aspect, and the head of the femur lying in the cavity of the aneurism.

FIG. 341.



Old unreduced suprapubic dislocation of the hip. (COOPER.)

In one or two cases pressure upon the anterior crural nerve has been manifested by numbness in its area of distribution.

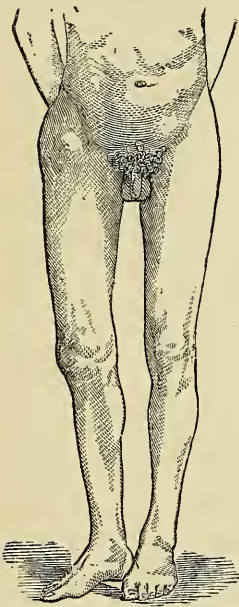
¹ Kocher: *Loc. cit.*, p. 616. ² Borchard: *Deutsche Zeitschrift für Chir.*, vol. lxxvi. p. 572.

³ Stokes: *British Medical Journal*, 1880, vol. ii. p. 916.

A case treated by Bransby Cooper¹ and examined after death at the end of three weeks is reported in detail, but it is not clear how much of the laceration of the muscles was due to the dislocation and how much to the repeated attempts to reduce it. "The anterior part [of the capsule], where crossed by the tendons of the psoas and iliacus muscles," was the only part untorn; the head of the femur lay in the groin on the inner side of the great vessels and above the internal circumflex artery.

In an old case examined by Sir Astley Cooper¹ "the head of the thigh bone had torn up Poupert's ligament, so as to penetrate between it and the pubes. . . . Upon the pubes a new acetabulum is formed for the neck of the thigh bone, the head of the bone being above the level of the the pubes (Fig. 341). . . . The femoral artery and vein were placed on its inner side, so that the head of the bone rested between the crural sheath and the anterior inferior spinous process of the ilium."

FIG. 342.



Iliopectineal dislocation.
"The limb is usually a little more advanced and abducted." (BIGELOW.)

Verneuil,² in attempting to make reduction thirty-six hours after the accident in a patient eighty-one years old, fractured the neck of the femur. Four years later the patient died; the head was found lying in the notch between the anterior inferior spinous process and the iliopectineal eminence, between the psoas and the rectus. In another old case reported by Douglas³ in which there was also a fracture of the neck of the femur the head was on the inner side of the vessels; the history of the case did not show when the fracture had been produced.

Symptoms. The cases in which the head of the femur lies upon the iliopectineal eminence appear to be the more common, and this may, therefore, be taken as the typical form; in it the limb is but slightly, if at all, abducted, markedly everted, and somewhat shortened (Fig. 342), and the head of the femur can be felt more or less distinctly in the groin, with the artery pulsating directly in front of it or to its inner side. When the head is displaced further toward the median line the limb is abducted and flexed as well as everted, and its position is more like that of an obturator dislocation; the capital difference is the position of the head on the pubis where it can be distinctly felt and perhaps even seen. The vessels lie on its outer side. In both forms the outer and posterior portions of the hip are flattened, and the trochanter can be felt covering the cavity of the acetabulum.

¹ Cooper: *Loc. cit.*, p. 78, and *Guy's Hospital Reports*, 1836, vol. i. p. 82.

² Cooper: *Loc. cit.*, p. 71.

³ Verneuil: *Bull. de la Société de Chirurgie*, 1870, vol. xi. p. 145.

⁴ Douglas: *London and Edinb. Monthly Journ. of Med. Sci.*, 1843, vol. iii. p. 1064.

Adduction is difficult or impossible; abduction and flexion usually are easy. Some patients have been able to walk immediately after the accident, but none appear to have done so as freely as some with obturator or supposed supraacetabular dislocations.

The attitude of the limb is like that found after fracture of the neck of the femur, and the differential diagnosis is made by attention to the presence of the head in the groin, the flattening of the outer aspect of the hip, and the depression of the trochanter.

In a case reported by Rothe¹ the patient, a girl fifteen years old, was unable to extend the leg upon the thigh three weeks after the accident, and the disability was attributed to overflexion of the knee at the time the dislocation was received. While pushing a swing forward she tripped, fell on her knee, and was then pressed backward to the ground by the returning swing. Reduction was made under chloroform by flexion, rotation inward, and adduction.

Of the *intrapelvic* (Scriba) or *suprapectineal* (Bartels) dislocation cases have been reported in detail by Scriba,² Bartels,³ and Stokes (above quoted). Scriba's patient, a boy thirteen years old, while standing with his legs wide apart and the left one thrown back, was struck upon the breast and overthrown. The limb was flexed at the knee and hip, adducted and rotated inward. The head of the femur lay above the torn Poupert's ligament deep in the iliac fossa, and the neck rested on the superior ramus of the pubis. The artery, vein, and nerve crossed the head and were fully compressed. Slight inward rotation and adduction were the only movements possible. During manipulation outward rotation suddenly took place and persisted. Reduction was made by lifting the head with the fingers until it rested on the ramus, and then following with acute flexion, adduction, inward rotation, and finally extension.

Bartels's patient was a man forty-seven years old who had been thrown down by a heavy weight. The limb was shortened about three inches, fully extended, parallel to the median line of the body, and widely rotated outward. The fold of the groin was obliterated by a diffuse swelling extending to the upper limit of the left hypogastrium; the head could be distinctly palpated through the abdominal wall, which it slightly raised; the greater trochanter was directed backward and could not be felt. Flexion was impossible; inward rotation very limited.

Treatment. The rule, of which the application is so general, that in attempting reduction the limb should first be placed in the position which it occupied when the dislocation occurred, is not suitable to those suprapubic dislocations in which the dislocation takes place while the limb is extended. Traction upon the fully extended, abducted, and everted limb has indeed been sometimes successful, but it has oftener failed and has led to various accidents. The method was early abandoned because of the risk of injury to the vessels by overstretching across the projecting head of the femur, and flexion was

¹ Rothe: Deutsche Klinik, 1868, p. 343.

² Scriba: Centralblatt für Chirurgie, 1879, p. 703.

³ Bartels: Arch. für klin. Chir., vol. xvi. p. 651.

resorted to to diminish this risk and to remove what was thought to be the principal obstacle, tension of the psoas and iliacus. Of the six procedures given by Bigelow almost all include traction upon the flexed thigh and rotation inward; in some, direct pressure downward and outward upon the head of the bone or the upper part of the thigh is recommended, and outward rotation is mentioned in one as an equally good substitute for inward rotation.

Kocher's method is the same as one of those given by Bigelow, and I reproduce it here because of its more detailed account of the obstacles to be overcome and the means by which the manipulation accomplishes it.

Flexion relaxes the Y-ligament, but nevertheless by tightening the posterior part of the capsule it presses the head more firmly against the brim of the pelvis or even pushes it further upward under Poupert's ligament; it is therefore necessary that the movement should not be allowed to take place upon the head as a centre, but that the head should be enabled or forced to descend along the anterior surface of the pelvis as the knee is raised before the tightening of the posterior portion of the capsule has made this descent impossible. This can be effected by traction in the axis of the limb or by direct pressure downward and backward upon the head. The steps of the method, then, are:

1. Traction in the axis of the limb as it lies, in order to bring the head below the brim of the pelvis; it is rarely necessary to aid this by increasing the extension, abduction, and outward rotation of the limb. By this means the posterior portion of the capsule is made tense, and its point of attachment to the back of the neck of the femur is thereby made the centre for the following movements:

2. Pressure with the hand upon the head of the femur to prevent its return upward during flexion. Sometimes this is sufficient to make reduction.

3. Flexion, in order to relax the Y-ligament; it should not be carried to a right angle, otherwise too much strain will be made upon the posterior portion of the capsule.

4. Rotation inward, by which the head is returned to the socket.

In cases in which the head lies nearer the symphysis abduction of the limb during traction is necessary to relax the Y-ligament and the untorn portion of the capsule and thus allow the head to approach the acetabulum; and in those, possibly rare, cases in which this position is secondary to a primary displacement downward and inward (obturator) the flexion will be seen to bring the head back to the obturator foramen, and then the final steps should be those suitable to that form of dislocation.

DISLOCATIONS DIRECTLY UPWARD.

Subspinous (Bigelow). Supracotyloidea. Sus-cotyloidienne (Malgaigne).

Concerning no other class of reported cases of dislocations of the hip is the uncertainty as to the nature and extent of the lesion, the point

at which the head has left the socket, and the mode of production so great as in those in which the head is found more or less directly above the socket. As has been above said, Blasius grouped under one head—*supracotyloidea*—cases in which the head of the femur comes to rest above the socket either by secondary displacement forward and upward from a primary dorsal (the everted dorsal of the present classification), or by secondary displacement backward from a primary suprapubic, or by direct dislocation upward, and this grouping, which, while very proper in a monograph, seems to me objectionable in a systematic description of all the forms, has been accepted and followed by several of the later German writers, Albert, König, Lossen. Bigelow groups Malgaigne's variety with those cases in which the head lies further to the inner side (suprapubic), and makes them all a subvariety under the name *subspinous*. Hamilton makes no formal classification of them, but contents himself with citing a few cases, mainly as "anomalous dislocations," some as subspinous, others as supraspinous.

The essential feature of the class, as I view it, is the rupture or avulsion of the upper part of the Y-ligament; this differentiates it radically in its probable mode of production and treatment from those in which the head of the bone comes to rest at or near the same place after having left the socket at a lower point in front or behind and passed upward on either side of the untorn ligament.

The incompleteness of many of the descriptions is such that the material for a positive opinion upon the character of the displacement is lacking, and such cases must, therefore, be passed by without definite classification, but there remain a few which sufficiently establish the existence of this variety in which the head is displaced directly upward toward or a little behind the anterior inferior spinous process of the ilium.

The cases in which the position of the head of the femur has been verified by autopsy are those of Wormald,¹ Gerdy,² Travers,³ and St. George's Hospital,⁴ and the doubtful ones of Cruveilhier,⁵ Gély,⁶ and Deville.⁷ Wormald's patient was a man forty years old, who had received his injury at the age of fourteen, and had since had good use of the limb. The head of the femur lay "between the edge of the acetabulum and the anterior inferior spinous process," and was surrounded by the capsule. The ligamentum teres was not ruptured. The cotyloid cavity formed part of the new socket. The limb was somewhat everted and abducted, and shortened half an inch. Gerdy's patient was caught in a revolving shaft and whirled around by it many times. He died on the following day. The head of the femur lay on the outer third of the upper border of the acetabulum, below and just outside of the anterior inferior spinous process; the capsule was torn along the upper edge of the cavity, and the centre of the head was eight lines

¹ Wormald: London Medical Gazette, 1837, vol. xix. p. 658.

² Gerdy: Reported by Baron, Gaz. Médicale de Paris, 1838, p. 630.

³ Travers: Medico-Chirurgical Transactions, 1837, vol. xx. p. 112. Autopsy by Cadge: *Ibid.*, 1855, vol. xxxviii. p. 88.

⁴ St. George's Hospital: Lancet, 1840-41, vol. ii. p. 281.

⁵ Cruveilhier: Bull. de la Soc. Anatomique, 1837, p. 164.

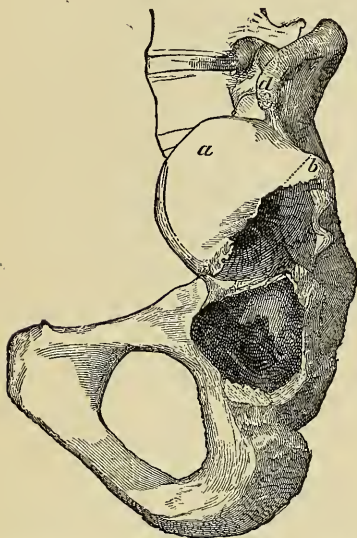
⁶ Gély: *Ibid.*, 1840, p. 303.

⁷ Deville: *Ibid.*, 1843, p. 264.

above that of the latter. Fig. 254 represents an apparently similar specimen.

In Travers and Cadge's case the head lay between the superior and inferior spinous processes of the ilium (Fig. 343) and was covered by a complete bony cap lined with a dense pearly-white tissue resembling fibro-cartilage. The edge of the new cavity was connected with the neck of the femur by a thick capsular ligament. The rectus muscle, which had been torn from its origin, was inserted upon the edge of the new cavity.

FIG. 343.



Old supracotyloid dislocation. Travers's and Cadge's case.

The St. George's Hospital case was a recent one; the head of the femur lay about an inch below and to the outer side of the anterior spinous process, and the trochanter was still further to the outer side and behind; the trochanter minor rested on the outer edge of the acetabulum. The capsular ligament was extensively lacerated at its upper part. The gluteus medius and minimus were nearly torn through about two

inches from their attachment to the trochanter; the gemelli and quadratus femoris were slightly lacerated.

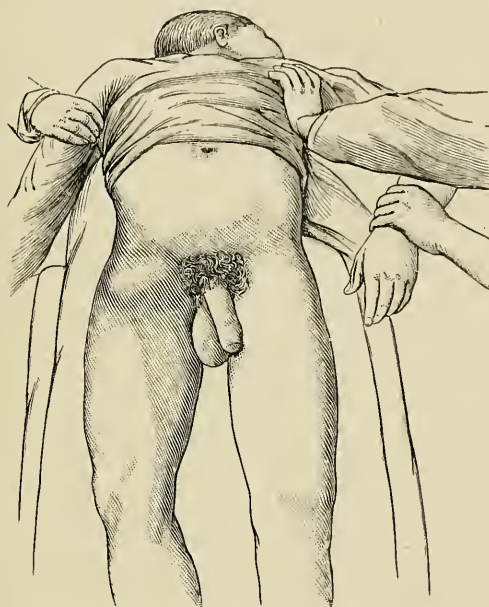
The following case, which I reported in the *Annals of Surgery*, December, 1892, shows the symptoms (Fig. 344). A man forty years old was thrown down by a heavy case which slipped while he was unloading it from a wagon and forced him backward against another box and then sidewise to the ground. When I saw him, three hours later, he was lying on his back with the right thigh extended, slightly abducted, and so far everted that the foot rested along the entire length of its outer border on the bed. The upper anterior portion of the thigh close below the groin was rounded and swollen, and showed two incomplete transverse rents in the skin about two inches long and about two inches below the anterior superior spine of the ilium, which evidently had been caused by overstretching of the skin (hyperextension of the joint). The outward rotation gave the thigh a very peculiar appearance; the bulk of the quadriceps extensor formed a longitudinal mass on the outer side between the anterior (inner) aspect and a deep longitudinal depression extending from the trochanter to the side of the knee. Every attempt to move the limb caused pain and sharp contraction of the muscles.

Ether was administered. The limb could then be easily placed

alongside of and parallel with the other; the shortening was two centimetres. The head of the femur lay directly beneath the skin and could be distinctly outlined. It lay just external to a line drawn downward from the anterior superior spinous process, and its upper border was about one inch below that prominence. Internal rotation was impossible; moderate flexion was easy.

Reduction was easily effected by flexing the hip about twenty degrees, and then making moderate traction along its axis with one hand at the knee, and direct pressure downward and backward upon the head of the femur with the other. By fully extending the thigh and making slight pressure forward against the upper part of its posterior aspect the dislocation was easily reproduced, and was then again reduced as before.

FIG. 344.



Upward dislocation of the hip. (From a photograph.)

Through what was apparently an extensive gap in the soft parts beneath the skin at the point occupied by the head of the femur before reduction I could distinctly feel the surface of the ilium and, a little in front, the anterior inferior spinous process.

A long side splint was applied, and the patient placed in bed.

Convalescence was uneventful, and the patient was discharged, April 15th, thirty-six days after the accident. May 24th he called on me; he walked without a cane, and complained only of a slight feeling of weakness in the limb. Hyperextension of the hip caused no pain; active flexion of the hip was restricted one-half.

I know of no case exactly like it. One reported by Morgan¹ resembles it in the apparent mode of production and the attitude of the

¹ Morgan: Guy's Hospital Reports, 1836, p. 79.

limb, but the head of the bone lay below and to the *inner* side of the anterior superior spine. Possibly Cheever's case, quoted in Chapter LI. among compound dislocations, may have been of the same kind; the description is not sufficiently detailed to make it certain. It was evident that my case just escaped being made compound by rupture of the tense skin. In Mason's and Allin's¹ and in Tiffany's,² the attitude was similar and the head of the bone could be felt below or below and to the inner side of the anterior superior spine. Allin reported his case as a suprapubic dislocation; his patient received the injury by stumbling and falling forward while ascending a flight of steps. In each case reduction was effected with some difficulty by traction and, in Allin's and Tiffany's, rotation inward. Possibly some of the "intrapelvic" dislocations have been produced in the same manner, and differ only in the higher position of the head given by secondary displacement.

There is another small group of cases in which the displacement is thought to be of the same kind but of less extent, and the opinion finds some support in the autopsy of Wormald's case, above quoted. There are eversion, slight shortening, and some flexion of the limb, and the patients have usually been able to walk. The head of the femur cannot be felt; the trochanter is prominent, slightly elevated, and more distant from the symphysis pubis than its fellow is. Milner's³ case is the least doubtful example. It may be remembered that cases with quite similar symptoms have been reported as thyroid dislocations.

In others, with the same attitude of the limb, the head of the femur could be felt directly above the socket or a little to the inner side.

In the first group it is evident that in some the Y-ligament and attachment of the rectus are freely ruptured, and that in others the head is displaced slightly upward and the upper part of the capsule only partly torn, and the neck of the femur probably crossed by the untorn rectus, a condition differing only slightly from the suprapubic.

In the second group it is possible that the head is displaced upward to the outer side of the inferior spinous process where it would be hidden by the overlying muscles, but in that case the marked eversion noted in all is inexplicable without rupture of the Y-ligament. I am disposed to think the cases were all thyroid dislocations, an opinion supported by the slight fulness of the groin and elevation of the femoral artery noted in Milner's.

DISLOCATION DOWNWARD UPON THE TUBerosITY OF THE ISCHIUM. INFRACOTYLOID.

In this form of dislocation the head escapes over the lower edge of the socket and rests just below it upon the outer surface of the body of the ischium. The reported cases are very few,⁴ but it seems prob-

¹ Allin: Reported by Hamilton, loc. cit., p. 785.

² Tiffany: Maryland Medical Journal, 1883, vol. x. p. 525.

³ Milner: St. Bartholomew's Hospital Reports, 1874, vol. x. p. 316.

⁴ For bibliography and cases see: Chaplain, Bull. de la Soc. de Chir., 1874, p. 461; Wendel, Deutsche Zeitschrift für Chir., 1904, vol. lxxii. p. 153, and Nie²erle, Centralblatt für Chir., 1905, p. 31 (20 cases).

able that the dislocation is much more frequent as a primary, transitory one, leading to either a dorsal or an obturator dislocation, being converted into the former by inward rotation and adduction, or into the latter by outward rotation and abduction; and, furthermore, some of the cases have probably been reported as obturator dislocations, for the dividing line between them is somewhat arbitrary; thus, Keate's case, referred to above in the paragraph on the causes of obturator dislocations, is quoted by Malgaigne as a subcotyloid dislocation. The form was first described by Bonn¹ in 1800, and again by Ollivier.²

The cause is the same as that of many dorsal and obturator dislocations, namely, forcible flexion of the thigh, but exaggerated abduction followed by slighter flexion appears also to be capable of producing it. Thus, in a case reported by Roux³ the patient fell with his right leg in a hole; the left one remained stretched out on the ground in abduction and was dislocated; and Ollivier's patient, a man, seventy-two years old, was knocked down by a branch of a falling tree which struck against the lower inner part of his right thigh and forcibly abducted it. Pitha⁴ speaks of a case in which the dislocation was caused by the forcible bending of the body backward, but, as Albert points out, not only is his description of the symptoms unintelligible, but it also does not appear how a rent in the lower part of the capsule could be produced in this way. He describes the supracotyloid and infracotyloid together as "vertical dislocations," and possibly has placed this case in the wrong paragraph.

The only autopsy is one reported by Luke,⁵ the patient, a man, fifty years old, died in consequence of associated injuries; the dislocation, which had been easily reduced, was reproduced at the autopsy, and as the bone could be made to take no other position it was thought that the reproduction was exact. The head of the femur was situated "midway between the ischial notch and the thyroid hole, immediately beneath the lower border of the acetabulum;" the gemellus inferior and quadratus femoris had been torn, and the ligamentum teres completely detached; the capsule was torn in its lower part.

Experiment upon the cadaver shows that the Y-ligament remains untornd and compels flexion of the thigh upon the pelvis, which, however, may be masked, as in other forms, by inclination of the pelvis. The retention of the head upon the tuberosity is due to the narrowness of the rent in the capsule and to the support given by the untornd portions; and as the laceration can be easily extended on either side the easy transformation into a dorsal or obturator dislocation is intelligible.

The flexion may be even to a right angle; Ollivier's patient was brought to the hospital seated in a chair; the limb is more or less abducted, and may be slightly inverted or everted. Measurement in Ollivier's case, when the other thigh was brought into a similar position, showed no difference in length, and by the lengthening which has been noted in other cases was probably meant only an apparent elon-

¹ Bonn: Quoted by Lossen.

² Ollivier: *Arch. gén. de Méd.*, 1823, vol. iii. p. 505.

³ Roux: *Revue Médico-chirurgicale*, 1849, vol. v. p. 364.

⁴ Pitha: Pitha and Billroth, p. 163.

⁵ Luke: *Medical Times and Gazette*, 1858, vol. i. p. 12.

gation due to the abduction and the consequent inclination of the pelvis. The buttock appears rounded and more prominent, especially when looked at from below when the patient is lying on his back with both thighs flexed, and the adductors of the thigh are tense and prominent. The great trochanter is further from the crest of the ilium, and the head of the femur can sometimes, but rarely, be felt in its new position.

Movements of the limb are restricted and more or less painful; flexion to a right angle is usually possible, abduction comparatively free, adduction limited; but in Roux's case the thigh could be carried across the other one. Both of Gurney's¹ patients could walk fairly well immediately after the accident, and Roux's could walk a little at first, but was soon completely disabled by the pain.

Reduction has been easy (Roux was unsuccessful on the thirty-fifth day with the aid of chloroform) and has usually been effected by traction in the axis of the limb, with or without direct pressure upon the head of the bone; sometimes the dislocation has been first transformed into a dorsal or obturator and then reduced.

A suitable method would be: Flexion, if not already present; traction; correction of the existing rotation, if any; to be aided by direct pressure on the head of the femur from behind.

Dislocation into the pelvis through the fractured floor of the acetabulum has been described in Chapter XXII. A brief reference is made by Krönlein² to a unique case observed by him in which, by a fall upon the feet, the head of each femur was driven through the floor of the acetabulum.

¹ Gurney: *Lancet*, 1845, vol. iii. p. 412.

² Kronlein: *Deutsche Chirurgie*, Lief. 26, p. 25.

CHAPTER LIII.

DISLOCATIONS OF THE HIP.—(CONTINUED.)

Complications—Simultaneous Dislocation of Both Hips—Accidents in Attempts to Reduce—Prognosis—Habitual Dislocations—Treatment of Old Dislocations—Congenital and Pathological Dislocations.

COMPLICATIONS OF DISLOCATIONS OF THE HIP.

AMONG the complications of dislocations of the hip are unusually extensive injuries to the soft parts, rupture of or dangerous pressure upon large nerves and blood-vessels, and fracture of bones. Mention has been made of all in connection with the different varieties of dislocation, and it is necessary only to group and briefly summarize them.

Rupture or laceration of the muscles about the joint is doubtless present in some degree in all cases, and is rarely so extensive as to deserve to be looked upon as a complication. In the dorsal dislocations the head of the femur may be so far displaced that the gluteus medius, and even the gluteus maximus may be in part ruptured, and in the thyroid dislocations the adductors may be extensively torn from the inferior ramus of the pubis and the adjoining part of the ischium, as observed in Taylor's compound case above quoted. In the suprapubic form the pectineus may be torn, and in the extreme variety known as "intrapelvic," in which Poupart's ligament is ruptured, the attached muscles forming the anterior wall of the abdomen must also suffer some injury. The extension of the bruising and laceration of course increases the shock and inflammatory reaction, but calls for no special treatment beyond a more rigid and prolonged confinement to bed and avoidance of movement.

For compound dislocations see Chapter LI.

Rupture or injury of the femoral vessels has been observed only in suprapubic and obturator dislocations. The suprapubic ones are those of a German military surgeon¹ and Goldsmith,² quoted in Chapters XXIX. and LI.; the obturator case is that of Duboué.³ In the first mentioned the femoral vein was torn and the patient died promptly; in Goldsmith's an aneurism involving the external iliac and femoral arteries formed, and was treated two months after the accident by ligation of the external iliac; the patient died. In Duboué's case there was also fracture of the pelvis at the junction of the ilium and pubis, but without displacement; the head of the femur rested upon the ischio-pubic branch of the pelvis rather below than upon the obturator externus; the femoral vein was torn. The patient died.

¹ Centralblatt für Chirurgie, 1880, p. 504.

² Goldsmith: American Journal of the Medical Sciences, July, 1860, p. 30.

³ Duboué: Bull. de la Soc. Anatomique, 1858, p. 496.

The **sciatic nerve** in the autopsy of one dorsal dislocation¹ has been found stretched across the front of the neck of the femur, and in several dislocations produced experimentally upon the cadaver it has been found in the same position, but the only recorded instances within my knowledge in which symptoms of injury to it have been present are a case reported by Jonathan Hutchinson² in which the muscles supplied by it were paralyzed and remained so at the time of the report several months after the accident, and one by Allis (*The Hip*) in which the attempts to reduce were thought to have wound the nerve about the neck of the femur.

Associated **fractures** of the head, neck, and shaft of the femur, of the rim and floor of the acetabulum, and of different parts of the pelvis have been reported.

Fracture of the **head of the femur** has been reported in four cases of dorsal dislocation.³

Fracture of the **neck of the femur** occurring coincidentally with the dislocation or subsequently during an attempt to reduce has been observed a number of times. Wippermann⁴ reported one case and collected thirteen others of which he gives abstracts, but his list includes one case (*Hervez de Chegoire*) which was probably a simple fracture without dislocation, and Birkett's, in which the fracture was of the head, and does not include a number of other reported cases; thus, Hamilton quotes no less than twelve cases in which fracture was caused during an attempt to reduce, and of these Wippermann's paper contains only one. The only cases of which I have knowledge⁵ in which the neck appears certainly to have been broken at the moment of dislocation are one reported by Tunnecliff,⁶ one by Post⁷ in which both hips were dislocated, and one by Lossen,⁸ and even in the latter the patient was not seen by the reporter until six weeks after the accident; the patient, an old man, was standing on a ladder when it fell, he struck upon his feet and then, with the injured side, against the underlying ladder, and Lossen supposed the dislocation to have been produced by the second blow. "The head lay on the ilium; the limb, almost consolidated, still showed signs of extracapsular fracture."

When Dr. Tunnecliff saw his patient a month after the accident he was inclined to doubt the existence of a fracture, but he felt forced to accept the evidence as conclusive. He found "the same shortening and oblique position of the limb as described above." On the thirty-eighth day after the accident reduction was effected by free manipulation to break up the adhesions, followed by flexion and abduction with direct pressure on the head; the bone returned to the socket with an audible snap, but as crepitus was felt it was thought that the union of

¹ Quain: *Medico-Chirurgical Transactions*, 1848, vol. xxxi. p. 337.

² Hutchinson: *Medical Times and Gazette*, 1866, vol. i. p. 194.

³ Birkett, *Medico-Chirurgical Transactions*, 1869, p. 133; Moxon, *Medical Times and Gazette*, 1872, vol. i. p. 96; Riedel, *Beilage zum Centralbl. für Chir.*, 1885, p. 92; Crile, *Annals of Surgery*, May, 1891.

⁴ Wippermann: *Arch. für klin. Chirurgie*, vol. xxxii. p. 440.

⁵ In Harcourt's and Chitwood's cases, quoted by Kammerer (*vide infra*), the diagnosis is wholly untrustworthy; De Morgan gives no details.

⁶ Tunnecliff: *American Journal of the Medical Sciences*, 1868, vol. lvi. p. 123.

⁷ Post: *New York Medical Record*, 1878, vol. xiii. p. 366.

⁸ Lossen: *Deutsche Chirurgie*, Lief. 65, p. 55.

the fracture had been destroyed. Five weeks later the patient "could walk with one crutch, and measurement showed but half an inch shortening of the limb. He has progressed favorably since that time."

Post's patient was a girl thirteen years old who, six months before admission, had received a blow upon the back with "a twisting of the body to the right and the lower extremities to the left." Both hips were dislocated, and there was also fracture of the neck of the left femur, the head of which had become necrosed; a sinus communicated with it as it lay on the dorsum ilii. The head was removed through an incision, and the limb straightened. The right dislocation was reduced by manipulation, and the patient became able to walk with crutches, the function of the right limb being fully restored, the left being shortened four and one-half inches.

Possibly reduction might be effected by direct pressure upon the head under anæsthesia, but it seems unlikely. Possibly, also, reduction could be made by pressure through a posterior incision exposing the head, but as the usefulness of the limb, after reduction, would depend largely upon the preservation of the vitality of the head and its union with the shaft, and as this depends upon the preservation of the continuity of a sufficient amount of the periosteum, it is by no means certain that all cases are fit for reduction or that they would remain so after the cutting necessary to effect it. The fact that in three cases the head became necrotic shows that the laceration of the periosteum when the fracture is through the narrow part of the neck is probably greater than in similar fracture without dislocation. The alternatives would be to await consolidation and then seek to reduce, as in Tunnecliff's case, or to seek a pseudarthrosis at the seat of fracture, or to correct the attitude of the limb and seek union with a view to the formation of a new socket for the head on the ilium, or to excise the head if the fracture is near it. Possibly McBurney's hook could be advantageously used in fracture at the base of the neck, or even in fracture through the neck, making the incision in front.

Fracture of the shaft of the femur, occurring coincidently with its dislocation, has been observed a few times. Hamilton collected four cases, those of Bloxham, 1833, Thornhill, 1836, Étéve, 1838, and Markoe, 1853, in all of which it is claimed that reduction was effected. He rejects Thornhill's claim as "altogether incredible," and doubts if a dislocation existed in Markoe's. In Bloxham's and Étéve's the fracture was near the middle of the shaft, in Thornhill's in its upper third, and in Markoe's the site is not mentioned. In Bloxham's the dislocation was on the pubis, and was reduced on the seventh or eighth day by traction with pulleys, the limb having been secured with splints, and by direct pressure on the head of the bone. In Étéve's the dislocation was backward, and reduction was effected by making slight traction upon the upper part of the flexed thigh, and by direct pressure on the head of the bone.

To these may be added Cooke's case of obturator dislocation with fracture just below the trochanter, quoted in Chapter LII., Cooper's of dorsal dislocation with fracture at the middle of the shaft, and Delagarde's of backward dislocation with double fracture of the shaft.

Cooke's patient was nine years old, and reduction was easily effected by direct pressure on the head. Cooper's¹ patient was a lad sixteen or eighteen years old; "as the reduction of the hip was, of course, impracticable," union of the fracture was alone sought at first, and after five weeks, the bone appearing tolerably firm, careful extension by pulleys was made for half an hour, and was successful. He also quotes² another case in which reduction was not made.

In Delagarde's³ case the dislocation was backward, and the shaft was broken in two places. The dislocation remained unreduced, and the head was subsequently excised.

Kammerer⁴ reported a suprapubic case with fracture between the upper and middle thirds in which reduction was not made, and collected twelve other cases of fracture of the shaft with various dislocations.

Possibly reduction might be effected in dorsal cases by using the weight of the limb to make traction in the prone position, as described in Chapter LL., and in other forms traction, with pressure on the head, should be tried; this failing, McBurney's hook (Fig. 298) should certainly be tried, as it involves less laceration and gives better control than forceps applied through an incision.

Associated fracture of the pelvis, usually of the rami of the pubis and ischium, and sometimes extending into the acetabulum, has been reported. It has always been caused by great violence acting directly upon the patient, and has usually been combined with other injuries which have proved fatal.

Detachment of the Labrum Cartilagineum. Zinner⁵ reports a case of dorsal dislocation complicated by a double vertical fracture of the pelvis extending from the pectineal eminence through the margin of the acetabulum to the tuber ischii and through the inner border of the inferior ramus of the pubis, and by detachment of the labrum cartilagineum; the latter was entirely torn away, with the exception of a small piece at its upper outer part, and, with its ends twisted about each other, was wedged between the outer margin of the acetabulum and the neck of the femur and prevented reduction. The ligamentum teres was torn from the acetabulum and remained attached to the head of the femur and to the labrum. Detachment of a portion is probably not rare.

SIMULTANEOUS DISLOCATION OF BOTH HIPS.

Simultaneous dislocation of both hips has been reported in about thirty cases.⁶ Usually the dislocation is not the same on both sides, but if backward upon the ilium in one it is forward upon the obtura-

¹ Cooper: *Dislocations and Fractures*, American edition, 1844, p. 40.

² Cooper: *Loc. cit.*, p. 41.

³ Delagarde: *St. Bartholomew's Hospital Reports*, 1866, vol. ii. p. 183.

⁴ Kammerer: *New York Medical Journal*, February 16, 1889.

⁵ Zinner: *Zeitschrift für Heilkunde*, vol. viii. p. 121; abstract in *Centralblatt für Chir.*, 1888, p. 55.

⁶ For bibliography of 26 cases see Niehans, *Deutsche Zeitschrift für Chirurgie*, 1888, vol. xxvii. p. 467; also a double dorsal dislocation, Pfeiffer, in *Boston Medical and Surgical Journal*, August 4, 1887, and Lewis, *Annals of Surgery*, 1904, vol. xl. p. 735, with bibliography to date. Tschmarke, *Monatschrift für Unfallheilkunde*, 1905, No. 7, reports a case and collects six others later than Niehans.

tor foramen or upon the pubis in the other. The common cause is a heavy blow received upon the back or side while the patient is bending forward, by which he is twisted to one side, so that one thigh is abducted and the other adducted. Of this mode of production Boisnot's¹ case is a good example: a bale of goods fell upon a powerful man, forty years old, striking him upon the left side of the head and neck, and bending him to the right, and caused a dorsal dislocation on the left side, and a suprapubic one on the right. In Barker's case, quoted in Chapter LII., both dislocations were obturator, and were caused by a fall from a height of about thirty feet upon a sand bank, the patient striking upon his feet and having them widely separated. In Schinzing's² case, dorsal on one side and suprapubic on the other, it was thought the latter might have been caused by the efforts of the bystanders to drag the patient from under the bank of earth that had fallen upon him.

Simultaneous dislocations of the *left hip* backward and of the *right knee* forward and upward were reported by Brittain,³ and of the *knee* and *hip of the same side* by Hulke.⁴

ACCIDENTS CAUSED BY ATTEMPTS TO REDUCE.

Before the use of ether and chloroform to obtain anæsthesia, and the general substitution of milder methods in the place of forcible traction by pulleys, it was not rare for severe inflammatory reaction, and even suppuration, to follow reduction or the attempt to reduce, or for the patient to die in consequence of the shock and exhaustion produced by the efforts of the surgeon. Cooper⁵ says "there are plenty of cases on record of fatal abscesses from violent attempts at the reduction of dislocated hips." Such consequences are now extremely rare, but, even when forcible traction or other violent manipulations have not been employed, they must still be expected occasionally to occur as the result in part at least of the original traumatism.

Fracture of the neck or even of the shaft of the femur has been caused in a number of cases by the surgeon in his efforts to reduce, either by forcible traction or by manipulation. Although in modern methods but little force, comparatively, is applied by the surgeon, yet it must be remembered that the force is habitually applied on the long arm of a lever of which the neck of the femur is the short arm, and the fracturing strain upon the latter is thereby greatly augmented. The fracture, apparently, takes place more frequently during rotation or abduction than during the flexion of the limb. In most of the reported cases the account is limited to the circumstances attending the fracture, and no mention is made of the subsequent course of the case. Of the 14 cases collected by Wippermann (*vide supra*), including also the one in which the fracture occurred simultaneously with the dislocation and another in which it probably did, the final result is

¹ Boisnot: American Journal of the Medical Sciences, October, 1867, p. 396.

² Schinzing: Wiener med. Presse, 1880, quoted by Krönlein.

³ Brittain: London Medical Gazette, 1836, vol. xviii. p. 257.

⁴ Hulke: British Medical Journal, 1883, vol. ii. p. 1.

⁵ Cooper: Loc. cit., p. 33.

indicated in 9; of these consolidation of the fracture took place in 3 and failed in 6, and in two of the latter (Czerny, Bryck), in both of which the fracture was secondary and through the narrow part of the neck, an abscess formed, from which the necrotic head of the femur was subsequently removed. See also Kammerer, *supra*.

Fractures produced during moderate manipulation in recent cases should be treated in accordance with the considerations affecting the treatment of simultaneous fracture and dislocation.

In Stokes's fatal case of suprapubic dislocation, in which death was attributed to pulmonary embolus, it is impossible to say whether the fatal result was due to the traumatism or to the reduction. If it was due to pulmonary embolus the clot must have formed before reduction was attempted, and the latter could only have caused its detachment.

In a case of fresh dorsal dislocation that came under my care in Bellevue Hospital in 1886, death occurred an hour and a half after the accident and half an hour after easy reduction by the weight of the limb in the prone position, without anæsthesia. The patient was a muscular young man, a worker in a brewery, and the dislocation was caused by a fall from a wagon. He was brought to the hospital within an hour after the accident, and presented marked symptoms of shock—restlessness, sighing, cool surface, small pulse. No autopsy.

PROGNOSIS AND AFTER-TREATMENT.

The prognosis after reduction in uncomplicated cases is favorable, the patients usually regaining good use of the limb. The inflammatory reaction is usually slight, and other treatment than rest in bed for two or three weeks is rarely required. Occasionally there is a tendency to recurrence which needs to be combated either by slight permanent traction upon the limb or by keeping it in an attitude that is unfavorable to recurrence, extension, abduction, and outward rotation after a dorsal dislocation.

If reduction is not made the patient will be permanently crippled to a greater or less degree. Usually a new articular socket is formed by bony outgrowths about the head which permits some motion, and the principal disability is due to the attitude of the limb, to its lack of parallelism with the other, and to the necessity of tilting the pelvis and curving the spine in order to bring the foot to the ground; but in a few cases patients have also suffered from persistent pain aggravated by use, and even from numbness or paralysis due to pressure on a nerve.

In the dorsal dislocations the attitude of the limb, flexion and abduction, adds considerably to the actual shortening, and the patient may be unable to walk without crutches or a support attached to the sole of the shoe. In unreduced suprapubic, supracotyloid, and obturator dislocations the attitude is often less faulty and in a number of cases the limb has been very serviceable.

HABITUAL DISLOCATIONS.

A considerable number of cases have been reported in which the hip could be voluntarily dislocated by muscular contraction or by

slight pressure upon the foot when the limb was placed in a certain attitude, or in which the dislocation recurred involuntarily during use of the limb. Perier¹ collected fifteen cases, more or less authentic, including one observed by himself and exhibited to the Société de Chirurgie, and Hamilton nine additional ones. In some the peculiarity clearly followed a traumatic dislocation, in others it was the consequence of congenital or acquired alterations in the constituent parts of the joint. Only the former will be here considered, the latter belonging more strictly in the classes of spontaneous or pathological dislocations.

The two most satisfactory examples are one observed by Bigelow² and another quoted by him from a report furnished by Dr. E. M. Moore; both were dorsal. In Bigelow's case "the hip was dislocated while the legs were crossed, a wagon in which the man was riding having pitched into a hole. In a few hours the hip was reduced by flexion. Eight days after the accident, in attempting to walk upon the limb, it was again partially luxated, when the patient himself replaced it by pushing against it with one hand and pressing with the other against his knee. Since that time both luxation and reduction have been comparatively easy, and the patient now displaces the head of the bone backward upon the edge of the socket by muscular action, and reduces it by throwing the leg out sidewise. The luxation is sometimes attended with pain, and the prominence caused by the head of the luxated bone is sensitive to the touch. The displacement is rather a subluxation, and the limb exhibits slight flexion, shortening, and inversion."

Dr. Moore's patient was a soldier, who, while "skirmishing up a hill, sprang back suddenly to avoid the gun of a comrade in advance. His left foot became entangled, and his weight dislocated his hip. He felt the injury, and supposed it out of joint. Some comrades pulled it in. He immediately resumed skirmishing, and marched seven miles, from 10 A.M. until 6 P.M. He lay down at night, and went on duty the next day, sharp-shooting, crawling all day. He continued this kind of duty five days, and returned to camp, when he was immediately put in intrenchments, and worked two days and two nights. Afterward he went on picket, and entered the hospital on the sixteenth day after the accident. At present he can luxate the hip-joint at any time, and does it by pressing the foot on the floor to fix it firmly, contracting the adductors, and throwing out the pelvis. The head suddenly leaves the acetabulum and goes on the dorsum ilii."

As no autopsy has been reported in any such case, the explanation of the peculiarity can only be inferred. It is probable that the rent in the capsule is insufficiently repaired, and the edge of the acetabulum lowered at the point where the head of the femur escapes.

¹ Perier: Bull. de la Soc. de Chir., 1859, vol. x. p. 12.

² Bigelow: The Hip, p. 112.

TREATMENT OF OLD, UNREDUCED DISLOCATIONS.

Hamilton collected fifteen cases in which it was claimed that reduction had been successfully accomplished after the lapse of long periods, and shows that but few, if any, of them can be deemed trustworthy; in a number of them the dislocation was clearly not traumatic, and in the others the reports are brief and unsatisfactory. Sir Astley Cooper's statement that eight weeks was the period after which it would be imprudent to attempt reduction has been taken rather too literally, and the sounder judgment is that the question is to be determined by other facts than the simple length of time that has elapsed, such as the distance of the head from the acetabulum, its mobility, the degree of the inflammatory reaction, the usefulness of the limb, and the health or constitution of the patient.

The operative measures that have been employed either to effect reduction or to improve the functional condition of the limb are open arthrotomy, osteotomy or fracture of the neck or shaft, and excision of the head or of the head, neck, and trochanter.

The first is applicable to relatively recent cases which are thought to be not absolutely irreducible, to be supplemented in case of failure by excision. The others are applicable to older cases, as palliative measures designed to improve the position of the limb and make it movable.

Resort to **open arthrotomy**¹ appears to be increasing quite rapidly. The earlier results, within the antiseptic period, were not favorable, reduction failing in about two-thirds of the attempts, with subsequent resort to excision of the head, but changes in the technique have brought improvement. The important factors are (1) an operative method which will give free access to and permit easy removal of the obstacles so that forcible manipulations and consequent laceration will not be necessary, and (2) successful asepsis. The first minimizes the chance of death by shock; the second is essential to the maintenance of mobility in the joint and the securing of a good functional result, besides avoiding the later risks to life.

The important obstacles earliest to form are adhesions and cicatrices, mainly on the side toward which the head has been displaced; later and less frequent ones involve the socket and the portion of the capsule which crosses it, and the retraction of the muscles shortened by the displacement. It is often difficult to find a method of approach which will make it easy to deal with all these obstacles, for they may lie on opposite sides of the neck. It is also important not to damage the periosteum of the neck and the soft parts at its base, lest the destruction of their vessels should cause necrosis of the head, as has happened in several cases. A forcible attempt to reduce, pushed to the production

¹ For bibliography see 1st edition; Kirn, Beiträge zur klin. Chir., 1889, vol. iv. p. 537; Harris, Annals of Surgery, September, 1894; Engel, Arch. für klin. Chir., 1897, p. 629; Sherman, Phil. Med. Jour., August 20, 1898; Hoflinger, Centralblatt für Chir., 1901, p. 310; Payer, Beilage zum Centralblatt für Chir., 1901, p. 141; Gayet, Revue de Chir., 1902, vol. xxvi. pp. 41 and 269, 29 cases; Maydl, Centralblatt für Chir., 1903, p. 678, 15 cases; Rydygier, *ibid.*, 1904, 377.

of lacerations, should not immediately precede the operation or form a large part of it, lest suppuration should ensue notwithstanding antiseptic precautions. It is noteworthy that suppuration occurred in half of the twenty-four cases collected by Hoffinger.

The incisions employed in dorsal dislocations have been a straight anterior one along the inner side of the sartorius, a posterior one from the base of the trochanter to its tip, passing thence backward parallel to the fibres of the gluteus (Kocher's resection incision), and a convex external one (Ollier), the centre of which passes two and a half inches (Rydygier) below the tip of the trochanter, its posterior portion running toward the posterior superior spine of the ilium, and its anterior toward the anterior superior spine. The trochanter is cut off obliquely and reflected upward with the attached muscles. Rydygier says this gives a full exposure of and easy approach to the head and socket, and the obliquity of the bone section permits the fragment to be brought back into contact even if not fully into place and thus favors bony reunion. Each incision has its partisans, and each probably its more suitable cases.

The straight anterior incision has been used in obturator dislocations.

Excision of the head, or of the head, neck, and trochanter, has been done in a considerable number of cases, either primarily or after the failure of an attempt to reduce.¹

Osteotomy, through or below the neck, has been done by Van Wahl and Kock² and by Villeneuve³ after failure to reduce by arthrotomy; in two the reported result was good, in the third (Kock) the bone healed in a faulty position.

In deciding whether or not to interfere in an old case, and in choosing a method if interference is determined upon, several things beside the mere fact of the existence of the dislocation must be considered. If the limb is useful, if the patient is not suffering from pressure effects, and if he is no longer young, prudence will often dictate abstention. *Quieta non movere!* Or, at the most, an osteotomy may be done to bring the limb into a more convenient and serviceable position. If the patient is younger, if the disability is greater, if the position of the head causes serious pressure effects, reduction by arthrotomy may be attempted, with the determination to abandon the attempt if it proves difficult and to substitute excision. But the surgeon must carefully consider the present usefulness of the limb, the probability of the usefulness that will follow the interference, and the risk to life incurred in the attempt to improve.

Subcutaneous fracture of the neck has never, so far as I know, been intentionally done to correct a vicious position of the limb, but in a number of cases in which it has occurred during an attempt to reduce it has been utilized for this purpose and with good results, although, as above mentioned, necrosis of the head of the femur has twice ensued.

¹ Delagarde, St. Bartholomew's Hospital Reports, 1866, vol. ii. p. 183; Sydney Jones, Lancet, 1884, vol. ii. p. 870; Ratimow, St. Petersburg Med. Wochen., July 30, 1888; Graziana, Centralblatt für Chir., 1890, p. 244; Kammerer, Medical Record, March 4, 1893; Flower, British Medical Journal, Nov. 2, 1895; Browne, *Ibid.*, February 15, 1896; Ostermayer, Centralblatt für Chir., May 11, 1895; Paci, Arch. Italiane de Pediat., vol. vii.

² Van Wahl and Kock: Berlin. klin. Woch., 1882, p. 492.

³ Villeneuve: Rev. d'Orthopédie, 1892, p. 161.

CONGENITAL DISLOCATIONS.

(See Chapter XXXV.)

SPONTANEOUS OR PATHOLOGICAL DISLOCATIONS.

Almost all the different kinds of spontaneous dislocation have been observed at the hip, and many of them with a frequency that has not been observed at other joints. The weight of the body in walking is a factor of much importance and constantly at work, the effect of which is well shown in three cases reported by Lücke,¹ in which the dislocation followed rhachitic changes in the shape of the femurs and the spinal column. The patients were children who, at birth and during infancy, showed no sign of dislocation; after a time rhachitic changes occurred, the displacement appeared; and walking became difficult. Lücke found a marked lumbar lordosis and anterior curvature of the femurs; the trochanters were displaced far backward, and the dislocation was evident. He thought the curvature of the femurs was the primary change, and the lordosis compensatory of it, and that the dislocation was due to changes in the acetabulum following the consequent pressure at an unusual point.

Of similar character are those cases in which the dislocation has taken place in a healthy joint in consequence of the prolonged maintenance of some exceptional attitude, as in a case reported by Franks² of a child five years old, who had been confined to the bed for many months by an arthritis of the *left* hip, and had lain upon its left side with the knees and hips flexed, and the right hip adducted; a dorsal dislocation took place without pain on the *right* side. Here the contraction of the muscles takes the place of the weight of the body in producing the dislocation when the limb is long held in a favorable attitude, and many examples of this effect have been reported in cases in which the joint was the seat of an arthritis, as in acute articular rheumatism, or in continued fevers, typhoid, scarlatina, in which usually there are indications of inflammation of the joint, although in some cases attention was first called to the joint by the appearance of the deformity. (See p. 476.) As the individual usually lies with the thigh flexed and adducted, the dislocation almost always takes place backward and upward; but in a case observed by Stromeyer,³ a man eighteen years old, affected with acute articular rheumatism, especially of the hip, during the entire course of which he had lain on his side, the dislocation was into the obturator foramen.

"Paralytic" or "myopathic" dislocations of the hip, those in which the displacement is effected by the unopposed contraction of certain muscles or groups of muscles, whose antagonists are paralyzed, have been most frequently seen as a consequence of infantile paralysis. As has been shown in Chapter XXXVI. they were formerly confounded with congenital dislocations, and were first clearly separated

¹ Lücke: Quoted by Fergue and Maubrac, *Luxations pathologiques*, Paris, 1886, p. 15.

² Franks: *Lancet*, 1883, vol. ii. p. 15.

³ Stromeyer: *Handbuch der Chir.*, 1844, vol. i. quoted by Fergue and Maubrac.

from them by Verneuil,¹ and afterward studied in detail by some of his pupils, especially Reclus.² When the paralysis involves all the muscles of the hip the joint becomes loose, and the femur may be displaced and replaced at will, but when only a part of the muscles are paralyzed the contraction of the others leads to a permanent displacement. If the posterior muscles are paralyzed, and the adductors remain in good condition, the dislocation is dorsal; if the adductors are paralyzed and the glutei remain sound, the dislocation is forward upon the pubis. One of the cases observed by Reclus may be taken as a good example of one form; a child, which had previously been healthy and well formed, was attacked at the age of seven years with high fever and a paralysis which, at first general, became localized in the glutei and the other pelvi-trochanteric muscles; the other groups, especially the adductors of the thigh, recovered their activity; a well-marked dorsal dislocation followed.³

In a case reported by Bradford,⁴ a girl, eighteen months old, the right thigh was flexed and abducted at a right angle, the adductors were paralyzed, the glutei and tensor vaginae femoris sound. The head of the femur could be felt in the groin upon the superior ramus of the pubis midway between the symphysis and the anterior superior spine of the ilium. Reduction was effected, but the limb remained almost powerless.

The cases should be treated by prompt reduction, if possible, and the maintenance of the limb in an attitude that opposes recurrence.

In three cases reported by Roser⁵ in 1885, at the Congress held at Strasburg, the paralysis was due to spinal disease; in one of them the patient produced the dislocation by swinging his legs forward while walking with crutches; in the other two the dislocation took place in bed without appreciable cause.

The limitation of the paralysis to one group of muscles is to be explained by the fact that the adductors are supplied by the obturator nerve, a branch of the lumbar plexus, and the posterior muscles by branches of the sacral plexus, and that the medullary centres of these nerves are at different points in the cord, that of the former being at a higher point than the other, probably at the upper part of the lumbar enlargement.

Dislocations due to destruction of the bony parts of the joint by tubercular disease are comparatively common; their consideration belongs rather to the subject of disease of the hip-joint.

In like manner the consideration of those dislocations which follow changes in the bones produced by chronic rheumatism or dry arthritis or in ataxia belongs to works upon those subjects. The alterations in the shape of the bones, either by atrophy or by hypertrophy, are so marked that reduction or maintenance of reduction is impossible. In dry, or deforming, arthritis not only are all the constituent parts of

¹ Verneuil: Bull. de la Société de Chirurgie, 1866.

² Reclus: Revue de Méd. et de Chir., 1878, p. 176.

³ See paper by Karewski, Arch für klin. Chir., 1888, vol. xxxvii, p. 346.

⁴ Bradford: Boston Medical and Surgical Journal, 1883, vol. cviii, p. 73.

⁵ Roser: Quoted by Fergue and Maubrac, loc. cit., p. 43.

the joints involved in the changes, but the muscles also become degenerated ; the bones are usually hypertrophied by outgrowths at the borders of the articular surfaces, they lose their articular cartilage, and become eroded at points of contact. The changes in locomotor ataxia are characterized by early and rapid atrophy of the head and neck of the femur with destruction to a greater or less extent of the rim of the acetabulum. Sometimes dislocation takes place abruptly with well-marked and characteristic symptoms ; in other cases the symptoms are more like those of fracture of the neck of the femur, the foot is everted and the trochanter raised, but the movements are exceptionally free and may be painless.

CHAPTER LIV.

DISLOCATIONS OF THE KNEE.

Forward—Backward—Lateral—Antero-lateral—By Rotation—Dislocation of the Semilunar Cartilages—Congenital—Spontaneous or Pathological Dislocations.

Anatomy.

THE knee-joint may be regarded as composed of two joints, of which one is formed by the patella and femur, the other by the femur and tibia; and the latter is composed of two parts, differing somewhat from each other, each of which is formed by one of the condyles of the femur and the corresponding portion of the upper surface of the tibia. The condyles of the femur are separated from each other by the intercondylar notch, and between the condylar surfaces of the tibia is a depression which is interrupted in the centre by the spine.

The ligaments which bind the femur to the tibia and fibula are the external and internal lateral, the posterior, and the crucial. The internal lateral ligament, long and flat, extends from the internal tuberosity of the femur to the inner side of the shaft of the tibia; the external lateral, more rounded and cord-like, extends from the external tuberosity of the femur to the head of the fibula, overlying the tendon of the popliteus above and being embraced by the tendon of the biceps below. The short external lateral ligament, lying somewhat more deeply and posterior to the other, is attached above to the side of the condyle and below to the styloid process of the fibula. The posterior ligament is attached above to the upper part of the intercondylar fossa of the femur and below to the posterior margin of the head of the tibia. The crucial ligaments extend from either side of the intercondylar notch to the depression in front of and behind the spine of the tibia. In full extension of the knee these ligaments are made tense, but in flexion at a right angle the lateral ones, especially the external lateral, are relaxed.

The semilunar fibro-cartilages are intra-articular structures attached to the head of the tibia at their outer margins and ends and having free smooth surfaces above and below; they are triangular on vertical section, the peripheral border being thick, the central thin; as they are rings, not disks, each leaves the corresponding condylar surface of the tibia uncovered at the centre. The internal one is semicircular, and its ends are attached in front of and behind the spine of the tibia respectively; the external one is nearly a complete circle, and its ends are attached to the spine of the tibia between those of the internal one, its posterior end is also attached to the inner condyle of the femur in connection with the posterior crucial ligament. The external cartilage

is movable upon the tibia, this freedom of motion being utilized in the outward rotation of the leg which occurs at the end of extension, while the internal one is more fixed and serves mainly to make a more concave surface for articulation with the internal condyle of the femur. The anterior borders of the two cartilages are connected together by a slight transverse band, the transverse ligament; it is sometimes lacking.

The capsular membrane fills the gaps between the ligaments. It is reinforced on each side by broad fibrous sheets attached to the sides of the patella and derived from the fascia lata and the muscles, the so-called lateral expansions.

The synovial membrane extends well up on the front of the thigh, frequently communicating with a bursa under the quadriceps, and invests the crucial ligaments by a reflection from the posterior wall. Between the tibia and patella it rests upon a mass of fat, forming two lateral folds, the alar ligaments, and sending backward from its middle another fold, the ligamentum mucosum, which is attached to the front of the intercondylar notch. By these folds and the crucial ligaments the joint is divided into three more or less freely communicating compartments.

Functionally, the femoro-tibial joint is a ginglymo-arthrodial, its movements being effected by a combination of gliding, rolling, and rotation of the bones upon each other. In complete extension no rotation is possible, but as the knee is flexed outward rotation appears and increases, reaching 21 degrees at rectangular flexion and 31 degrees at flexion 30 degrees within a right angle. (Mayer.)

In complete extension the patella rests upon the upper part of the trochlear surface of the femur, and as flexion is made it moves downward and is gradually turned outward by the increasing prominence of the internal condyle, so that at the last it rests by its upper and outer facet on the front of the external condyle and by its inner facet against the narrow surface of the outer margin of the internal condyle. As the movement of extension approaches its limit the tibia undergoes slight outward rotation in which the external semilunar cartilage does not participate, that is, the outer condylar surface of the tibia moves backward under the fibro-cartilage; correspondingly, when flexion is begun from the position of complete extension it is accompanied by inward rotation of the tibia. The limitation of extension is affected by the posterior and lateral ligaments, that of flexion by the contact of the soft parts of the calf and thigh and of the posterior margin of the semilunar cartilages with the back of the condyles of the femur. Displacement of the tibia forward, backward, or to either side is opposed by the lateral and crucial ligaments.

Statistics.

Dislocations of the knee, of the femoro-tibial joint, are rare, constituting about 1 per cent. of all cases. They are divided according to the direction in which the tibia is displaced into *forward*, *backward*, *outward*, and *inward* dislocations, and dislocations by *rotation*. Mal-

PLATE LI.

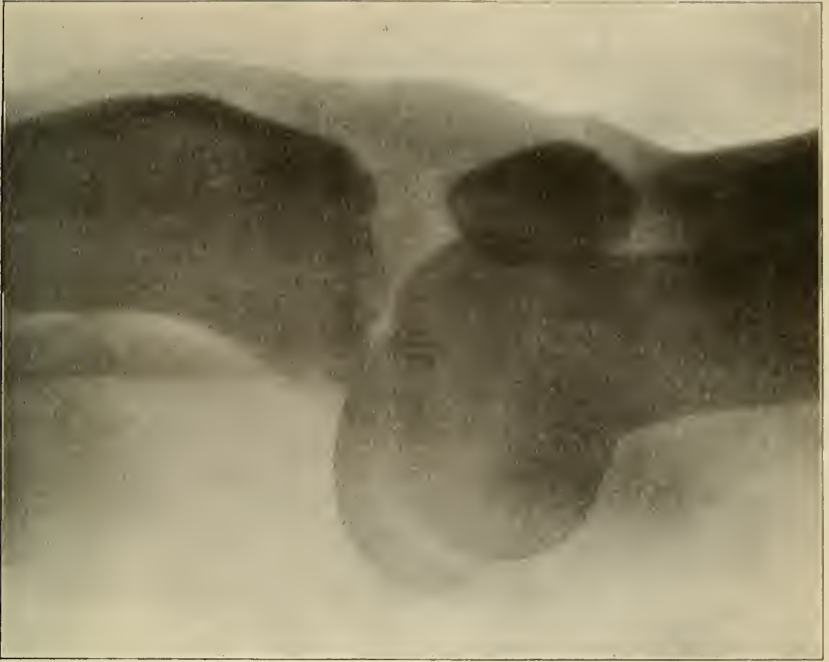

Fig. 1.—Anterior Dislocation of the Knee.

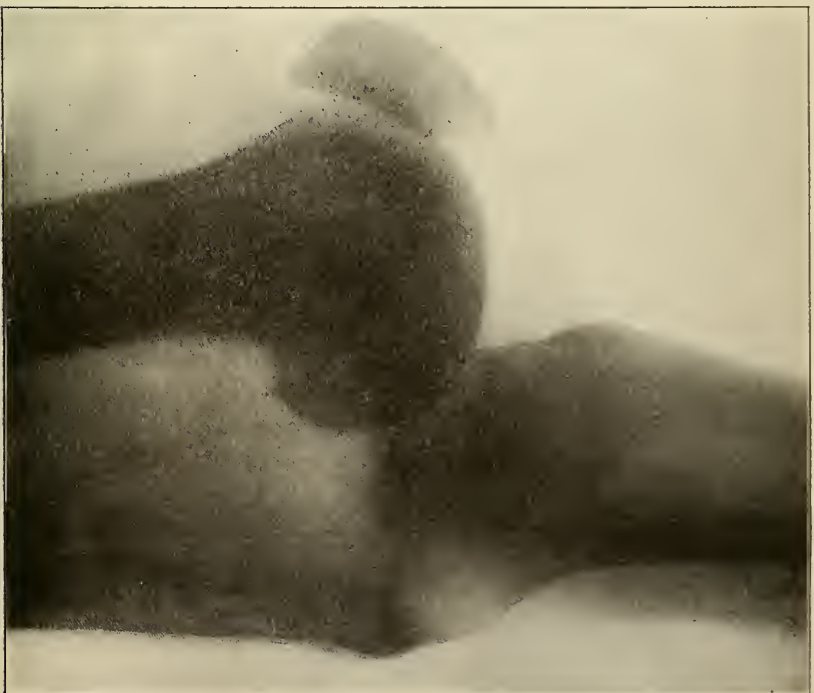

Fig. 2.—Posterior Dislocation of the Knee.

gaigne made additional groups of intermediate forms. The dislocation may be complete or incomplete, simple or compound. A tabulation which I made by the aid of the references to periodical literature in the *Index-Catalogue of the Surgeon-General's Library* showed that of 114 traumatic cases the dislocation was forward in 52, backward in 34, outward in 21, inward in 4, "lateral" in 1, and by rotation in 3. In 21 of them the dislocation was compound; 11 forward, 4 backward, 6 outward.

The injury is very rare in childhood, the two youngest patients in my list being aged ten and eleven respectively; it is of exceptional gravity because of the size of the joint, because it is usually caused by great violence, and because of the frequency with which it is compound and with which the popliteal vessels are injured. Amputation has been resorted to in a large proportion of cases. Simultaneous dislocation of both knees has been observed in a few cases.

DISLOCATIONS FORWARD.

These may be complete or incomplete, simple or compound. The complete seem to be very much rarer than the incomplete; the compound occur in an exceptionally large proportion, 18 per cent. in the tabulation just given, and the wound is habitually made by rupture of the soft parts posteriorly where they are stretched across the projecting condyles of the femur in hyperextension of the leg.

The cause may be either hyperextension of the leg, or violence received upon the front of the thigh or the back of the leg near the knee. The former appears to be much the more common; in it the tibia turns upon its anterior margin as a centre, putting the posterior, lateral, and crucial ligaments upon the stretch, and after their rupture it glides forward along the condyles, or the condyles slide backward along it. The hyperextension may be produced by a force applied to the back of the leg or foot, or, more commonly, by the propulsion of the trunk and thigh while the leg is held stationary and upright; thus, a man running down a hill steps into a hole, the leg entering to its upper third, and falls forward. In a case of my own the patient, a large heavy man, was standing in an elevator which was suddenly stopped while descending rapidly; he received the dislocation without falling or being struck, apparently by hyperextension of the knee. The tibia overrode the femur one and a half inches. The other cause, direct violence, may act upon the front of the knee while the leg is either extended or partly flexed. In another set of cases, of which I have met with the records of four examples, the mode of production is not clear; the patients were caught in rapidly revolving wheels or shafts and whirled around many times, the body passing at some part of its course through a narrow space; in three of these cases both knees were dislocated, in two of them one dislocation being forward, the other backward, and in the third one dislocation was forward and the other inward.

In a case of my own in which the patient was similarly caught by

a shaft he was wedged against the ceiling, but not carried through, receiving forward dislocations of both knees, one compound on the inner side with rupture of all the internal hamstring muscles through their fleshy parts well above the joint. He made a good recovery, but eight months later paralysis of the external popliteal group persisted on one side, and control of the knee was defective on the side on which the muscles had been torn. With the aid of a brace for that knee and a rubber muscle for the paralyzed anterior tibial group he was able to walk and work.

In a case reported by Cotton¹ the ligaments of the joint had gradually grown so weak that the knees bent backward; as the patient got out of bed one morning a compound dislocation, with rupture of the popliteal artery, was produced.

Pathology. In the incomplete form, that in which the upper articular surface of the tibia is still in contact by its posterior portion with the inferior surface of the condyles, the injury to the ligaments and other soft parts appears to be slight; in the only autopsy, one reported by Desormeaux,² the anterior crucial ligament alone was torn, and that only in part. In the complete form, on the other hand, the injuries are very extensive; one or both lateral ligaments, one or both crucial, the posterior, and the lateral ligaments of the patella are completely ruptured or widely torn. The posterior muscles, the biceps, gastrocnemius, popliteus, even the soleus and vastus internus are lacerated or divided; the internal and external popliteal nerves may be torn or bruised, the popliteal artery and vein ruptured, the skin of the popliteal space torn through. Sometimes the ligaments are ruptured, sometimes they are torn from the femur, perhaps bringing with them portions of the bone; the protruding condyles appear sometimes as if they had been cleaned with a knife. The overriding of the tibia and femur may amount to two or even three inches; in Mayo's³ it was said to be fully four inches.

The injuries to the popliteal artery are of exceptional interest and importance. Its inner and middle coats may be torn completely across (Annandale, Cotton, Knichynicki,⁴ Lowe,⁵ two cases, Vevers,⁶ and Stewart and Turner, quoted by Spillmann; in most of them the dislocation was compound); or, as in a case examined by Malgaigne, there may be several small rents at atheromatous, calcareous points. The artery may be simply compressed and remain competent to perform its functions when the pressure is removed (Davis,⁷ Hixon⁸), or it may be so bruised that a thrombus will subsequently form (Brittain). The popliteal vein appears from the reports to have been less frequently torn, but when bruised it also may become occupied by a thrombus. It seems probable that in the cases in which gangrene followed the vein as well as the artery was injured. The opportunities for direct

¹ Cotton: Proceedings of the Connecticut Medical Society, 1880, vol. ii. p. 54.

² Desormeaux: Bull. de la Soc. de Chirurgie, 1853, vol. iii. p. 367.

³ Cooper: Loc. cit., p. 187.

⁴ Knichynicki: Allg. Wiener med. Zeitung, 1873, vol. xviii. p. 255.

⁵ Lowe: St. Bartholomew's Hospital Reports, 1869, vol. v. p. 80.

⁶ Vevers: Lancet, 1869, vol. ii. p. 542.

⁷ Davis: Philadelphia Medical Times, 1876-77, vol. vii. p. 270.

⁸ Hixon: North American Medico-Chirurgical Review, 1858, vol. ii. p. 76.

examination after death or amputation have been numerous; among the reports may be mentioned those by Malgaigne, Volkmann,¹ Albert,² Birkett,³ Annandale,⁴ Brittain,⁵ Madelung,⁶ Spillmann,⁷ and Lowe, above quoted.

Symptoms. The leg is usually in almost complete extension, and when viewed from the side it is seen to lie in a plane more or less anterior to that of the thigh, according as the dislocation is complete or incomplete; it may be hyperextended or partly flexed, and may be rotated in either direction. The outlines of the projecting condyles can be seen and felt in the popliteal space, and above the tibia in front lies the patella, more or less horizontal and freely movable, and the skin above it shows marked transverse folds; the flat articular surface of the tibia can be felt on each side of the ligamentum patella. In the incomplete form the deformity is less marked, and the diagnosis may be difficult if the region is swollen.

The limb may be fixed in its position, or it may be movable in any direction, hyperextension, flexion to a right angle, or laterally.

If the skin is broken the rent is transverse and posterior, and through it one or both condyles may project, or the finger can be readily passed into the joint. The main vessels and the internal popliteal nerve commonly lie in the intercondylar notch, and may sometimes be plainly visible.

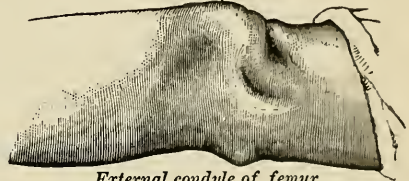
Injury to, or compression of, the artery is shown by the loss of pulsation in the arteries of the foot and ankle; injury to the nerve by loss of sensation or numbness, and, later, by changes due to defective nutrition of the limb and by pain, sometimes severe.

The course after injury to the artery is well shown in the report of Annandale's case, that after injury to the nerve in Le Dentu's.⁸ Annandale's patient complained that the foot felt cold, but sensation in the toes was normal; the dislocation was easily reduced, and the patient did well for a week; then it was noticed that the foot was livid and cold. Two days later blebs had appeared upon it, and the discoloration had advanced upon the leg; three days later the signs of gangrene were marked, and the limb was then amputated above the knee. The inner and middle coats of the popliteal artery, which were atheromatous, were torn about an inch above its bifurcation, and curled inward; the vessel was plugged by a firm clot.

Le Dentu's patient, a man twenty-seven years old, was caught in the belt of machinery and whirled around rapidly, his legs striking

FIG. 345.

Patella



External condyle of femur

Anterior dislocation of the knee.

¹ Volkmann: Beiträge, zur Chir., p. 119.

² Albert: Wiener med. Presse, 1872.

³ Birkett: Lancet, 1850, vol. ii. p. 703.

⁴ Annandale: Lancet, 1881, vol. ii. p. 903.

⁵ Brittain: London Medical Gazette, 1836, vol. xviii. p. 257.

⁶ Madelung: Berlin. klin. Wochenschrift, 1873.

⁷ Spillmann: Dict. encyclop. des Sc. Méd., art. Genou, p. 600.

⁸ Le Dentu: Bull. de la Soc. de Chirurgie, 1880, p. 591.

each time against the ceiling; he received a complete dislocation forward of the right knee, and a complete backward dislocation of the left one; the latter was reduced immediately, the former on the next day. On the nineteenth day the patient complained of sharp pain in both legs, and on examination an eschar as large as a fifty-cent piece was found on the left calf, and another over the right tendo Achillis; the former healed promptly, the latter increased, and part of the tendon sloughed. The pain became very severe in the right leg, it was neuralgic in character, a sensation of numbness with darting pain in the foot and sometimes in the leg, recurring especially at night. It persisted until the thirty-fifth day, and returned a week later. On the forty-fifth day another eschar appeared on the sole of the right foot opposite to the head of the first metatarsal bone. Sensation, which had previously been dulled in front, was now entirely lost throughout the right leg, except in the region supplied by the long saphenous nerve. Four days later the pain ceased, and the eschars began to heal. Seven months after the accident the patient returned to the hospital; there was considerable atrophy of the right leg, loss of power in the muscles that move the foot and toes, and some stiffness at the ankle. The movements of both knees were normal, and the ligaments appeared to have reunited solidly. The patient limped in walking, but the limp was due solely to the atrophy of the muscles and to the persistence on the outer side of the sole of the right foot of one of the three ulcerations that had appeared upon the foot and heel. The trophic troubles were attributed to a neuritis of the popliteal nerves occasioned by their laceration or bruising at the time of the accident.

Paralysis of the muscles of the outer side of the leg has been observed in three other cases, Brand, Unruh, and Poinso¹, in one of which, however (Brand), the fibula had been broken at its upper end.

Of the compound cases, several recovered with good use of the limb; in others, amputation or excision of the joint was done.

The prognosis is grave in the compound cases and in those in which the artery has been injured, and it is not very favorable even in the simpler ones. It must be remembered that gangrene may delay its appearance until the second or even the third week, and that even in some simple cases which have done well for a week or two suppuration of the joint has ultimately occurred. Even after simple dislocations that have done well there is ordinarily some limitation of the movements of the joint.

Treatment. Reduction is easy by traction and coaptation of the ends of the bones; ordinarily, no more force is required in the traction than an assistant can make with his hands. Flexion of the knee to an acute angle has proved successful. The suggestion that the leg should be hyperextended, and the head of the tibia then pressed directly downward, is a dangerous one, because of the chance of injury to the popliteal vessels.

The rule of conduct in the presence of compound dislocations, and of those in which there is evidence of injury to the popliteal artery, has been the subject of recent discussion. Several compound disloca-

¹ Poinso: Translation of Hamilton, p. 1142.

tions in which the artery was intact have recovered, and even with full subsequent use of the joint, and I believe that the conservation of the limb under such circumstances should be attempted.

The same rule should be followed in case of arrest of pulsation in the distal arteries; that is, the surgeon should wait until it has become evident that the vitality of the limb is lost. If the gangrene is dry little is to be feared from delay, but if the limb becomes swollen and discolored, with loss of sensation, indicating arterial supply and venous obstruction, delay is more dangerous and the formation of a line of demarcation cannot be safely awaited.

DISLOCATIONS BACKWARD.

These may be complete or incomplete; in the former the head of the tibia is displaced backward and upward behind the condyles; in the latter it still remains partly in contact by its upper surface with the condyles.

The common cause is direct violence received upon the upper end of the tibia in front, or upon the lower end of the femur behind, but in some cases the application of the force is more indirect, as when the body and thigh are forced forward while the leg is held. In four cases the patients were caught in machinery and whirled around; and in one case a boy, eleven years old, suffered a compound dislocation by having his leg caught between the spokes of a wagon-wheel.

Pathology. The posterior ligament is torn, and usually one or both of the lateral ligaments; in a case of complete dislocation with rupture of the popliteal artery (quoted by Malgaigne¹) in which Robert resorted to amputation, all the ligaments were intact except for two rents, each three centimetres long, in the posterior portion of the capsule through which the tibia protruded. It seems likely that the crucial ligaments, or at least the posterior one, must also be ruptured. The muscles which bound the popliteal space have been reported untraced, but widely infiltrated with blood; and in other cases one or both heads of the gastrocnemius and the popliteus have been torn. The semilunar cartilages may be in part detached or otherwise injured. In a case reported by Vast² a portion of the tubercle of the tibia had been torn off by the strain upon the ligamentum patellæ. The popliteal vessels, both artery and vein, are sometimes completely torn across, and sometimes only the inner and middle coats of the artery are torn, an injury the consequences of which may easily be as serious as those of complete rupture. This injury is produced by the forcible stretching of the vessels across the sharp posterior margin of the head of the tibia.

The patella may be drawn directly downward so as to lie below its normal position, or it may be displaced outward to the side of the condyle. In a case reported by Fitzgerald³ the patella was broken into several pieces, and the joint was opened at the end of a fortnight by the sloughing of the overlying skin. The injury was caused by the

¹ Malgaigne: *Loc. cit.*, p. 945.

² Vast: *Bull. de la Soc. de Chirurgie*, 1877, p. 682.

³ Fitzgerald: *Australian Medical Journal*, 1882, p. 554.

fall of a heavy case upon the front of the knee. The joint suppurated, but the patient recovered without entire loss of mobility.

As complications, fracture of the femur above the condyles, Testut,¹ and fracture of the tibia just below the knee, Adams,² have been reported; also rupture of the tendon of the quadriceps femoris, Walshman,³ Lossen.⁴

Symptoms. The leg is usually hyperextended upon the thigh, the antero-posterior diameter of the knee notably increased, the head of the tibia placed behind its usual position, and, in the complete dislocations, also above the level of the lower surface of the condyles of the femur. The leg may also be deviated somewhat to either side, and exceptionally it may be flexed. The head of the tibia can be felt in the popliteal space, and a marked depression exists below the condyles of the femur in front. The patella may lie against the front part of the under surface of the condyles, or may be displaced to the outer side, or rotated upon its axis. The amount of shortening is slight in the incomplete form; in the complete form it may be one or two inches.

Pressure upon or rupture of the popliteal artery is manifested by absence of pulsation in the posterior tibial and dorsalis pedis arteries, and may result in gangrene of the limb.

The diagnosis is not difficult; and as reduction is usually easy the prognosis in simple, uncomplicated cases is good; but attention should always be paid to the presence or absence of pulsation in the distal branches of the artery, both before and after reduction.

In some reported cases in which the dislocation has remained unreduced, the patient has had good use of the limb. Two such are the cases of Bagnall-Oakeley⁵ and Karewski.⁶ The former's patient was a man, seventy-years old, who had dislocated his left knee at the age of nine months; he had always made full use of the limb, and had earned his living as a brickmaker. A false joint had formed between the femur and tibia, which permitted 15 degrees of flexion. The foot and leg were normally developed; the thigh had an abnormal anterior curvature. The patella could not be recognized, and was thought to have become united with the femur. The different prominences of the lower end of the femur were absolutely subcutaneous and seemed ready to perforate the skin, but there was no trace of previous ulceration.

Karewski's patient was a servant girl, thirty-two years old, whose dislocation had existed for more than sixteen years. The right limb presented a typical dislocation backward, and when viewed from behind looked like a genu recurvatum, while when seen from in front and the side the thigh overhung the leg to a certain extent. The muscles of the calf were somewhat atrophied; the nerves and vessels stretched above the tibia like tense cords. The growth of the bones had been materially affected, the tibia being three centimetres shorter than the other, and also thinner; while the femur was lengthened by three

¹ Testut: Bordeaux Médical, 1874.

² Adams: Lancet, 1881, vol. ii. p. 1108.

³ Walshman: Quoted by Cooper, loc. cit., p. 190.

⁴ Lossen: Deutsche Chirurgie, Lief. 65, p. 131.

⁵ Bagnall-Oakeley: Lancet, 1882, vol. i. p. 53.

⁶ Karewski: Arch. für klin. Chir., 1886, vol. xxxiii. p. 525.

or four centimetres. The overriding of the tibia and femur was four centimetres. Flexion and extension were normal, both actively and passively, and although there was much lateral mobility the functions of the limb were admirably performed. Pain was felt only after exceptional use.

In Lossen's case, in which reduction was attempted at the end of six weeks and failed, the patient finally walked well; extension was complete; flexion to a right angle. The rupture of the external lateral ligament resulted in the production of a genu varum.

Treatment. Reduction, which is usually easy, has been effected by traction with coaptative pressure upon the adjoining ends of the femur and tibia and flexion of the knee and hip. In some cases flexion alone has been sufficient.

Spence¹ successfully treated an irreducible dislocation by open arthrotomy. The patient was a man, sixty years old, who had received the dislocation March 15, 1876, two days before admission to the hospital. After a failure to reduce under anæsthesia, continuous traction with a weight of sixteen pounds was made for three days, and then a second unsuccessful attempt was made. March 22d, traction with pulleys having also failed, the joint was opened by a curved incision below the patella; it was found filled with clots, the internal lateral ligament broken, and the posterior part of the internal semilunar cartilage displaced. After division of the external lateral ligament and the tendons of the hamstring muscles, the dislocation was easily reduced. The wound was drained and dressed antiseptically, the limb placed on a long posterior splint, and continuous traction made with a weight of eight pounds. As the lower end of the femur tended to project anteriorly, pressure was made upon it in front. The traction was maintained until June 15th, and when the patient was last seen, September 13th, the limb promised to be very useful.

In compound dislocations, and in those complicated by injury to the main vessels and nerves, the principles of treatment are the same as in dislocations forward.

LATERAL DISLOCATIONS.

Lateral dislocation, more rare than either of the preceding varieties, may be outward or inward, complete or incomplete, simple or compound. The outward form is more common than the inward. The term *subluxation* has been applied to those cases in which the displacement is slight.

1. Outward Dislocations.

Of the complete form of this dislocation Malgaigne could find only one recorded case, and that a doubtful one; but, since the publication of his work, von Pitha² has reported two cases in which the dislocation was nearly, perhaps quite, complete; Hughes³ has since published a third, and McKenzie⁴ a fourth. Von Pitha's first patient was a

¹ Spence: Lancet, 1876, vol. ii. p. 534.

² Pitha and Billroth: Chirurgie, vol. iv., part 2, B., p. 258.

³ Hughes: Lancet, 1880, vol. ii. p. 974.

⁴ McKenzie: Canadian Practitioner, January, 1893.

young woman who, while carrying a heavy basket on her back, suddenly doubled up under it. The right tibia was so completely dislocated outward that its entire upper articular surface stood out free, so that von Pitha could easily lay four fingers upon it. The skin was tightly and smoothly stretched over the articular surface, and was continuous at a sharp angle with that of the side of the thigh; the edge of the tibia threatened to cut through the tense, thin skin, and in like manner the internal condyle of the femur projected abruptly over the leg. The patella was displaced outward, and was placed obliquely, almost transversely. Reduction was extraordinarily easy. The reaction was so slight that the patient left the hospital on the next day.

His second patient was a robust young man who received his injury by springing to the sidewalk from an overturning wagon; the symptoms were similar, reduction easy. Hughes's and McKenzie's cases were also similar in appearance and ease of reduction. Hughes's patient died promptly; McKenzie's recovered.

In the incomplete form only a part of the head of the tibia, usually all the outer half, projects beyond the side of the external condyle of the femur.

The commonest cause is outward flexion of the knee, abduction, produced by a fall upon the foot or by the pressure of a heavy weight upon the posterior, or by a blow upon the outer, side of the knee; in the latter case the blow is probably received upon the lower end of the femur and not upon the tibia. A rarer cause is direct violence acting transversely upon the outer side of the lower end of the femur or the inner side of the head of the tibia without causing lateral inflection (Annandale). The mode of production appears to be rupture of the internal lateral and perhaps of the crucial ligaments by abduction of the leg, followed by the lateral gliding of the articular surfaces.

The only reports of direct examination of the injured joint are furnished by Hargrave¹ and Bonn, quoted by Malgaigne, and by Wells.² Hargrave's patient died on the fifty-third day, after suppuration of the joint; the internal lateral ligament was completely ruptured, the external partly torn; the anterior crucial torn across, the posterior crucial and the ligaments of the patella intact. Bonn's was an old unreduced dislocation; he says all the ligaments were intact and that the external condyle of the femur rested upon the crest of the tibia. In Wells's case a large scale of bone was torn from the inner side of the internal condyle; the patient died on the fourth day in consequence of gangrene of the limb.

Instead of being directly outward the displacement may also be somewhat backward or forward. When compound, the wound has always been on the inside. In one compound case, Notta,³ the popliteal artery was ruptured and the patient died after amputation.

Symptoms. The symptoms are more or less marked in accordance with the degree of the displacement; the internal condyle of the femur projects more or less markedly on the inner side, and the outer part of

¹ Hargrave: Dublin Quarterly Journal Med. Sci., 1850, vol. ix. p. 473.

² Wells: American Journal of the Medical Sciences, 1832, vol. x. p. 25.

³ Notta: Annales Méd. du Calvados, 1876, quoted by Poinso.

the head of the tibia on the outer side; and the greater the displacement the more likely, according to Malgaigne, is it that the outer part of the tibia will be rotated backward. The displacement outward of the patella shows corresponding variations in degree; it may be simply inclined, so that its vertical axis is directed downward and outward, or it may be carried to the outer side of the external condyle.

The leg may be flexed or extended, and is usually adducted, but may be widely abducted; voluntary movements are generally impossible.

Prognosis. The prognosis does not differ materially from that in the two preceding forms; but it is worthy of note that in a case seen six years after the accident by Desormeaux (quoted by Spillman) the leg was permanently abducted 45 degrees, presumably the consequence of failure of repair of the internal lateral ligament. In another, reported by Morgan,¹ in which the dislocation had remained unreduced for three and a half years, the limb could be flexed to a right angle but could not be voluntarily extended, so that the patient fell whenever the leg became at all bent while he was standing upon it.

Treatment. Reduction, generally very easy, is effected by traction and direct coaptative pressure upon the ends of the bones. It is very important that the limb should be immobilized for a long time after reduction in order that the torn ligaments may solidly reunite. Probably it would be well to keep the limb for three or four months in a firm dressing which would keep it extended and prevent lateral bending. Massage and passive motion might be systematically employed during much of this time if loss of normal mobility were feared.

In a case reported by Braun² of incomplete outward dislocation which proved irreducible arthrotoomy was done. The patient was a man forty-four years old; the leg was rotated inward and abducted at an angle of 145 degrees; the internal condyle of the femur was prominent, and a small movable piece of bone could be felt below its inner side. "A curved incision eight centimetres long was made parallel to the internal condyle." The small piece of bone proved to be the detached internal tuberosity. The rent in the capsule was closely filled by the internal condyle; it was slightly enlarged with the knife, and then reduction was easily made. The patient made a slow recovery; the joint remained stiff.

The treatment of compound dislocations and of those in which the artery has been torn is the same as in forward dislocations (q. v.).

2. Inward Dislocations.

These also may be complete or incomplete, simple or compound. Of the complete form there are only two cases on record, Miller and Hoffman,³ and Galli, both quoted by Malgaigne. The first was a man twenty-eight years old who while getting into a carriage caught his leg between the spokes of the wheel and could not free it before the horses started. The femur was completely separated from the tibia

¹ Morgan: *Lancet*, 1825-26, vol. ix. p. 843.

² Braun: *Deutsche med. Wochenschrift*, 1882, p. 291.

³ Miller and Hoffman: *London Medical Repository*, 1825, p. 346.

and projected outward and downward, the external condyle presenting through a wound in the skin three inches long. Through this wound the joint and the uninjured popliteal artery could be seen. Reduction was made at once without difficulty; recovery.

Galli's patient, a very muscular young man, was thrown from a horse, striking upon the right foot with the limb abducted. The lower end of the femur had almost entirely passed through the soft parts on the outer side; the ligamentum patellæ was ruptured. Reduction was made and the patient recovered.

The causes of the incomplete form are similar to those of the outward dislocations: lateral flexion of the knee or a blow upon the outer side of the tibia or on the inner side of the condyle of the femur.

In a case quoted from Cooper by Malgaigne² in which there was also rotation inward of the tibia, the soft parts covering the external condyle of the femur behind and externally had been ruptured. The limb was amputated, and dissection showed a large rent in the vastus externus immediately above its insertion upon the patella; posteriorly the capsule and gastrocnemius were torn; the lateral and crucial ligaments were intact.

The symptoms of the incomplete form are the projection of the head of the tibia on the inner side and of the external condyle of the femur on the outer side. The leg may be inclined outward or inward, rotated inward, and more or less flexed.

Reduction appears always to have been effected without much difficulty by traction and coaptative pressure; and the only special feature in the prognosis arises from the rupture of the internal lateral ligament, for if its repair is not thorough, or if the limb is prematurely used, the leg tends to deviate outward (knock-knee) under the weight of the body. It would, therefore, be advisable to support the joint for a long time by means of a brace.

ANTERO-LATERAL DISLOCATIONS.

Antero-lateral dislocations constituted in Malgaigne's classification a separate class of very rare occurrence, the tibia being displaced forward and outward. Of the latter form he found only one recorded example and that a doubtful one. In the very rare examples of dislocation forward and inward no special features appear; and the same may be said of the equally rare dislocations *backward and outward*. They may, therefore, be treated as belonging to the forward and backward dislocations respectively.

DISLOCATIONS BY ROTATION.

In this form the dislocation is characterized by a rotation of the leg about its longitudinal axis or about a parallel axis passing through the centre of one of the condylar surfaces of the tibia; in the former case both condylar surfaces are displaced from their corresponding condyles, and the dislocation is said to be complete; in the latter only one of them is thus displaced, and the dislocation is said to be incomplete.

¹ Cooper: Quoted by Malgaigne, loc. cit., p. 960.

The descriptive terms *outward* and *inward* are used, as in normal rotation of the leg, according to the direction in which the toes are turned.

Outward Rotation.

The first recorded case is one reported by Dubreuil and Martellière,¹ at the time internes in Malgaigne's service. The patient was a woman, who while walking in the street was struck upon the back of the leg by the end of a ladder carried upon a cart. She was knocked down by the blow, her foot caught between the rounds of the ladder, and she was dragged a few feet. When brought to the hospital, the leg was completely extended and rotated outward, so that the internal tuberosity was in front, below the trochlea of the femur, the external tuberosity and the head of the fibula behind in the intercondylar notch. The patella lay upon the outer side of the external condyle. There was also a compound fracture of both bones of the leg in the middle third. Reduction was easily made two hours after the accident by slight traction upon the upper portion of the leg followed by inward rotation. Recovery took place, but the joint was not firm, and nineteen months after the accident the patient could not take a step without crutches.

By experiment upon the cadaver the reporters found they could produce the dislocation by forcible outward rotation of the leg continued until the ligaments were felt to yield. The lateral ligaments were then found to be ruptured or torn from one or the other insertion; the capsule, the fascia on the outer side, and some muscular bundles were torn, the semilunar cartilages loosened or displaced. The crucial ligaments were not torn but lay parallel with each other in the transverse vertical plane passing through their upper insertions. In one experiment the tendon of the biceps was torn away from the head of the fibula. The tendon of the semi-membranosus was wrapped under the internal condyle and prevented full extension of the leg.

Sulzenbacher² reported another case and repeated and confirmed these experiments. His patient was a young Italian laborer, and the dislocation was caused by forcible outward rotation of the leg followed by hyperextension of the knee. The leg was extended, neither abducted nor adducted, and so far rotated outward that as the patient lay on his back the outer border of the foot rested on the bed. Beside the rotation there was displacement backward and outward of the upper end of the tibia. Notwithstanding the swelling there was a distinct projection of the condyles, and the soft parts below them were deeply depressible. Below the internal condyle was a movable piece of bone as large as a bean. The upper end of the tibia could be felt in the hollow of the knee projecting backward and outward and so rotated that the outer surface and the head of the fibula lay furthest back and the outer articular surface could be felt through the soft parts. The inner articular surface lay in the depths of the popliteal fossa, the patella laterally, so that it rested snugly on the outer sur-

¹ Dubreuil and Martellière: Arch. gén. de Méd., 1852, vol. xxx. pp. 150 and 288.

² Sulzenbacher: Wiener med. Presse, 1880, vol. xxi. p. 272.

face of the external condyle, its anterior surface being directed outward. There was one inch shortening, and the antero-posterior diameter of the joint was notably increased.

Reduction was easily effected by flexing the leg a little, then rotating it inward and pressing the head forward, and finally extending.

There was a tendency during the first fortnight to sublucation backward and outward; a gypsum dressing was worn during the second fortnight, and on its removal the tendency had ceased. At the end of six weeks the patient could walk with a cane.

The case differs from the preceding one in the additional backward and outward displacement of the rotated leg.

Experimenting on the cadaver, Sulzenbacher found that by rotating the leg outward 45 degrees he got an incomplete dislocation, accompanied by the appearance of a small fragment of bone under the internal condyle similar to that observed in his case, and that then by hyper-extension he could make the dislocation complete and exactly like that of his patient. The lesions found on dissection differed from those noted by Dubreuil and Martellière in this, that the crucial ligaments were ruptured and the external lateral ligament untorn. The small movable piece of bone proved to be the part of the internal condyle to which the internal lateral ligament was attached.

In a case reported by Boursier¹ still another variety is shown, the rotation taking place about the internal condyle as a centre. The patient, while standing with the outer side of his right leg resting against the cross-bar of a pair of skids by which he was unloading a large cask, was overthrown by the rapid descent of the cask which struck against the inner side of the right knee. The pain was very severe, and when raised by his companions he was unable to stand. The knee appeared a little enlarged transversely; the external condyle overlapped the corresponding articular surface of the tibia, forming a rather large, hard, rounded prominence. The patella, firmly fixed upon this condyle, was placed obliquely, its external border tending to turn forward. The relations of the internal condyle and inner surface of the tibia were normal. Palpation was painful along the interarticular line, especially at the outer side. Voluntary movement was impossible. Passively, flexion could be made nearly to a right angle, but was very painful; the limb could not be completely extended, and there was no rotation. No sign of fracture. Reduction was easily made under anaesthesia by slight traction and inward rotation of the leg. The patient recovered completely.

Another case has been reported by Mazel,² and Malgaigne quotes the accounts of two specimens of old unreduced dislocations given by Godman and Pétrequin. Of the former it is only said that "the leg has undergone complete outward rotation, so that the foot points directly outward, the heel corresponding to the hollow of the other foot, and the articulation of the knee crossing its natural position at right angles."

Still another variety, displacement forward of the inner side of the head, the outer remaining in place, has been recently reported by

¹ Boursier: Journ. de Méd. de Bordeaux, 1882-83, vol. xii. p. 225, quoted by Poinso.

² Mazel: Montpellier Médical, 1863, vol. x. p. 76.

Hénaff.¹ "A sailor, thirty-three years old, while squatting with his heels together, thighs abducted, and knees flexed, was struck upon the inner side of the head of the left tibia by an iron ring through which a hawser had begun to run rapidly. When brought to the hospital the leg was partly flexed and not deviated to either side; flexion and extension were limited, abnormal lateral movements very free. The relations of the external condyle and tibia were unchanged; the inner side of the head of the tibia was displaced forward, and the internal condyle was prominent posteriorly. The patella was inclined so that its anterior face looked forward and inward, its inner border rested on the inner condylar surface of the tibia, and its outer border and point raised the skin, the point being nearly in the median line. Reduction was easily effected by traction and internal rotation, and the patient made a complete recovery."

Inward Rotation.

Of this the only recorded instance is one reported by Paris, and quoted by Malgaigne. "The internal condyle of the tibia had slipped behind the corresponding condyle of the femur. The limb was shortened five or six centimetres, and the leg and thigh formed an arc of a circle." Malgaigne supposes this to have been an incomplete dislocation by rotation inward, and explains the alleged shortening as an error of observation. He mentions in connection with it a singular displacement which he had himself seen, and which he thought belonged to this class more than to any other. When seen by him it had existed five years. Although the patient limped, he flexed and extended the leg quite freely. In extension the internal condyle projected very slightly forward and inward, and the relations of the external condyle were normal. In marked flexion the internal condyle projected considerably forward and inward, the inward projection being more than two centimetres, and the external condyle projected slightly forward.

DISLOCATION OF THE SEMILUNAR CARTILAGES.

"Subluxation of the Knee." Hey's **"Internal Derangement of the Knee."**

A certain group of symptoms at the knee, occasioned usually by slight violence, such as the twisting of the leg, or marked flexion of the joint, and having a decided tendency to recur, to which attention was first permanently called by Hey¹ nearly one hundred years ago, have only of late been clearly connected with displacement of a semilunar cartilage as the cause. In many cases the symptoms are identical with those caused by a floating cartilage in the joint, and many of the reported cases, especially the earlier ones, were probably of this char-

¹ Hénaff: Thèse de Paris, 1883, No. 277.

² Hey: Observations in Surgery, Am. ed., 1805, p. 208.

acter. Hey reported five cases, and said he had seen many others; the difficulty always occurred suddenly, sometimes without recognizable cause during ordinary use of the limb, the joint becoming "locked" in the position of slight flexion, with more or less pain, the patient being unable to bring his heel to the ground and walking on the toes, but the joint could always be freely moved passively. It was always relieved by gradual passive extension of the limb followed by sudden full flexion.

In 1731 Bassius (quoted by Malgaigne) reported the first case, but it differs notably from all that have since been reported, for the external semilunar cartilage had become much hypertrophied in consequence of an arthritis, and formed a projection on the outer side as large as the thumb; it could be pressed into place with crepitus, and became displaced when the pressure was removed.

In some cases a distinct projection had been noticed in front, formed by one or the other cartilage, which could be made to disappear by pressure or by flexing and extending the joint, and with the disappearance of the projection the symptoms ceased. It was upon these few cases of recognizable projection and upon the sensation sometimes felt of a distinct slipping or jar in the joint while it is moved, that the theory of displacement of the cartilage rested, it being supposed that it slipped forward upon the head of the tibia so that its thicker posterior margin lay between the condyle and tibia at or in front of the point where they come most nearly into contact or actually touch.

The only pathological data came from chance examination of a few knees without history; thus in two specimens described by Reid¹ and Godlee,² the rupture of the attachments had taken place along the periphery of the cartilage, and it had lodged vertically in the intercondylar notch alongside the spine of the tibia and the posterior crucial ligament. In each the opposing articular cartilage on the condyle and tibia showed some roughening. Reid's patient died in the hospital, and during his stay there had made no complaint of the knee, and had not been observed to limp.

In another, Fergusson (quoted by Marsh) found in a dissecting-room subject "that one of the semilunar cartilages had been torn from the tibia throughout its whole length, except at its ends, so that in flexion and extension it sometimes slipped behind the articular surfaces. The cartilage was flattened in its outer margin, and when it passed behind the condyle of the femur, seemed to fit to the articular surfaces as accurately as the internal cavity does in the natural condition of the parts."

Marsh³ gives a fourth case: "In a subject lately in the dissecting-room of St. Bartholomew's Hospital, a considerable piece had become partially detached from the rim of the internal cartilage, and was found standing up like a tongue, so that it would have had the effect, when it was nipped between the bones (as it was in certain positions of the joint), of locking the knee. A deep groove on the cartilaginous edge of the femur had been formed by long pressure, for its accommodation."

¹ Reid: *Edinburgh Medical and Surgical Journal*, 1834, vol. xlii. p. 377.

² Godlee: *Transactions of the Pathological Society of London*, 1879-80, vol. xxxi. p. 240.

³ Marsh: *Diseases of Joints*, p. 199.

Since 1881, when Nicoladoni¹ exposing what he thought to be a floating cartilage found it was the displaced meniscus, and 1885, when Annandale² reported four cases diagnosed as displacement and formally treated by arthrotomy, the pathology of the condition has been made clear by a number of direct examinations through incisions, and very recently Tenney³ in a most interesting article has given the results of examination of 150 joints of cadavers showing the various forms of change in the cartilages and fringes. The meniscus most frequently displaced is the internal—45 internal and 17 external in 62 cases collected by Schlatter.⁴ The detachment may be of the anterior end or of a variable length of the periphery, or of a piece from the free border of the cartilage. The meniscus may be displaced into the intercondyloid notch, or backward into the joint, or slightly forward in front, or the detached end may escape forward or backward and to the side. Partial detachment of a piece from the upper border seems to be not infrequent; one such case is quoted above; Croft⁵ reports another; I have seen one.

Symptoms. In most cases the patient feels that the knee has suddenly become locked, with more or less pain and loss of power over the limb, which he can neither flex nor extend. Then, after a time, and as the result of manipulation of the joint or of the limb, he feels that all is right again, and walks as well as before. In others the joint has remained stiff and slightly flexed for weeks, or even years (Smith's⁶), and has been cured by pressure with the thumb upon the projecting semilunar cartilage, while the joint was repeatedly flexed and extended. In some cases the cartilage, usually the internal, can be distinctly felt to project in front; in others it appears to be absent, and in others again there is no recognizable change; usually there is pain on pressure at the edge of the tibia beside the ligamentum patella.

Le Fort,⁷ himself the subject of the affection, felt that something became displaced forward in the knee whenever the joint was markedly flexed, and returned to its place with a distinct snap and with pain when the limb was straightened.

In a case seen by Agnew,⁸ a lady, while playing with a kitten on the floor, suddenly found both knees had become locked, so that she was unable to rise.

As in these last instances, flexion of the knee beyond a certain point is, in some cases, sure to produce the condition, and this is then relieved by extension; but in most the occurrence is not so uniform in its mode of production, and the commonest cause appears to be outward rotation of the leg with slight flexion.

Treatment. Treatment has almost always yielded good results, both in relieving the condition and in preventing recurrence. The manipulations which have proved most efficient in the common form, those

¹ Nicoladoni: *Arch. für klin. Chir.*, 1881-82, vol. xxvii, p. 667

² Annandale: *British Medical Journal*, 1885, vol. i, p. 779, and 1887, vol. i, p. 319.

³ Tenney: *Annals of Surgery*, July, 1904, p. 1.

⁴ Schlatter: *Beiträge zur klin. Chir.*, vol. xli, part II.

⁵ Croft: *British Medical Journal*, March 19, 1888.

⁶ Smith: *Transactions of the Clinical Society of London*, 1884, vol. xvii, p. 123.

⁷ Le Fort: *Bull. de la Soc. Chirurgie*, 1879, p. 578.

⁸ Agnew: *Surgery*, vol. ii, p. 114.

due to a twist or turn of the leg, have been the ones recommended by Hey, extension as far as is possible without much pain, and then sudden forcible flexion. When the cartilage can be felt to project pressure upon it should be conjointly employed. Smith¹ insists upon the necessity of repeating the reduction daily for several weeks.

The after-treatment may require permanent pressure by a pad at the point at which the cartilage tends to protrude, or the wearing of a brace that will limit the movements of the joint. Marsh, who has treated many cases, recommends a clamp (Fig. 346) "which consists of a steel band passing across the back of the joint, and ending laterally in two plates, which clasp the joint and skirt the edges of the patella, a pad being placed beneath the plate, should either of the semi-lunar cartilages be felt to project." Prolonged immobilization of the limb in a fixed dressing has been used in a number of cases and seemed to diminish the tendency to recurrence.

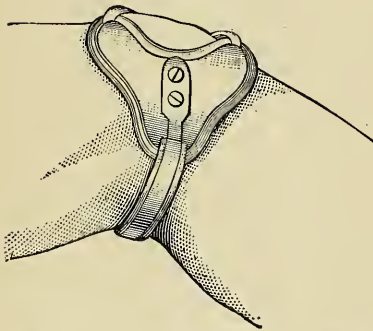


FIG. 346.

Clamp to prevent displacement of a semi-lunar cartilage.

Operative measures to effect a radical cure have been resorted to in a considerable number of cases; the object has been either to remove the displaced cartilage or to restore it to place and secure it there by sutures. The reported results have been uniformly good, the removal of the meniscus appearing to create no functional difficulty. A longitudinal incision on the antero-lateral aspect, or a transverse one at the articular line has been employed. Barker² in four of six cases found the meniscus hidden in the intercondyloid notch, drew it out with a hook, sutured it in place, and got a good result, as he did also in the other two by fixation. I have always found the anterior portion of the internal meniscus displaced inward, sometimes detached at its tip, sometimes broken away from the rest, and have removed it.

CONGENITAL DISLOCATIONS.

Excluding a few cases in which various malformations of the knee have been found in foetal monstrosities showing many other abnormalities, and one or two doubtful cases, I found (1900) nearly 40³ reported cases of congenital dislocation; in 22 the dislocation was unilateral, backward in 2, forward in 20 with hyperextension of the leg upon the thigh, frequently so extreme that the foot lay at the groin. Of the 15 bilateral dislocations 11 were forward, 2 backward, 2 inward; 6 of the cases were stillborn, and many showed other defects of development.⁴

¹ Smith: *Lancet*, June 13, 1891.

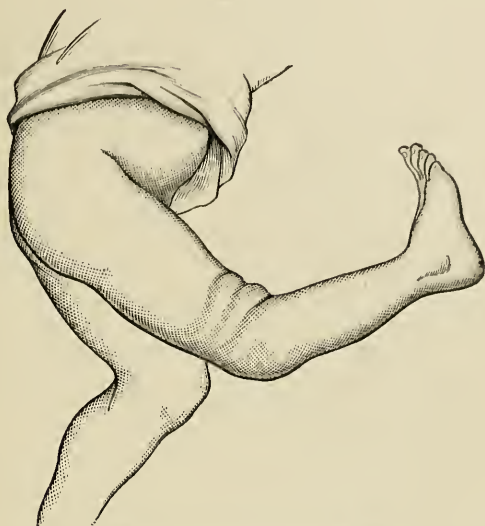
² Barker: *Lancet*, September 18, 1897.

³ In addition to the bibliography given in the 1st edition, see Joachimsthal, in *Berlin. klin. Woch.*, October 21, 1889, p. 923, 4 cases; and *New York Medical Journal*, March 2, 1889, 6 cases.

⁴ See also Musket, *Arch. für klin. Chir.*, vol. liv. p. 852, who collected 82 cases, of which 7 were real dislocations, 3 contractures in flexion, and 72 hyperextensions.

In a few cases there is mention of a blow or fall received by the mother while carrying the child, but it cannot be maintained that such a cause is in any case clear. The facility with which the displacement

FIG. 347.



Congenital dislocation of the knee.

in the unilateral cases could always be reduced, the normal shape of the bones, and the prompt establishment of the functions of the limb point toward an accidental mechanical cause; probably, in the movements of the fetus the leg is extended and becomes engaged in such a position that it cannot be flexed, and then by the pressure of the wall of the uterus hyperextension is effected. Hyperextension in consequence of unopposed contraction of the quadriceps can hardly be supposed, for the flexors have not been found paralyzed. In Hamilton's case of double backward dislocation the flexors were contracted, and their tendons had to be divided before the legs could be straightened.

In Friedleben's (bilateral) the articular surface of the tibia rested against the front of the lower end of the femur; the condyles of the femur and the head of the tibia were normally developed, the patella normally attached, the capsule loose and large.

In Albert's, a new-born child, both legs were in dorsal flexion at a right angle. The articular surface of the femur varied from the normal. The upper part of the synovial sac and the ligamentum alare were lacking. The inner semilunar cartilage was only a narrow strip, the outer one was well developed; the crucial ligaments were very broad and long, the inner one being inserted further inward on the tibia than normal; on slight outward rotation of the leg the two crucial ligaments became parallel to each other. The popliteal vessels and nerves lay behind the external condyle.

The attitude of the limb at birth, in the forward dislocations, was hyperextension to or beyond a right angle, sometimes so extreme that the front of the leg was actually in contact with the front of the thigh; usually there was no deviation of the leg to either side. It was always freely movable, could be brought down to the position of straight extension by moderate force, and in most cases could even be flexed nearly or quite as far as usual; on removal of the pressure the limb resumed the position of hyperextension. While the joint was dislocated the condyles of the femur projected at the back of the popliteal space, the head of the tibia lying against their anterior surface, and the patella situated well up on the thigh. In several cases the skin on the front of the knee was thrown into transverse folds, in the grooves between which sebaceous matter had sometimes collected. Nothing in any case indicated that the dislocation was recent and traumatic, and the experiments made by Hibon upon the bodies of newborn and stillborn children show that in a similar forcible dislocation, even by a force acting continuously for several hours, detachment of one or both epiphyses always occurred, with, however, but slight separation and not always with rupture of the periosteum. In the forcible straightening of the leg the quadriceps became tense, and in a few cases this tension prevented further flexion of the straightened limb.

The results of treatment were almost always very good, the limb showing a complete restoration of form and function after a few weeks; but in two cases the result was not entirely satisfactory. Six weeks after birth the leg in Perier's case showed exaggerated extension and outward rotation; the quadriceps was manifestly retracted, and showed as a tense cord whenever the attempt was made even slightly to flex the leg. In the hope of an ultimate return to the normal condition, Gueniot, who then had charge of the case, limited treatment to the maintenance of the extended position and to slight passive flexion and traction repeated two or three times daily. In the other case, Maas, the limb when first seen was in anterior flexion at a right angle; reduction was easily made, and the limb could then be normally flexed. It was placed in a plaster-of-Paris dressing for six weeks, and as the tendency to recurrence had not then entirely disappeared the dressing was renewed for a time, and afterward a leather knee-cap was worn. In its second year the child walked for a time without support, but at the time of the report, when it was two and a half years old, there was still a tendency to anterior flexion and abduction, and a brace was constantly worn.

SPONTANEOUS OR PATHOLOGICAL DISLOCATIONS.

These are very frequent at the knee, mainly as the result of chronic disease involving the ligaments and the bones of the joint, and of prolonged maintenance of the partly flexed position. There are also instances on record of sudden dislocation due to muscular contraction during an acute arthritis, and quite a number of the class to which Volkmann gave the name *deformations-luxationen*, or dislocations by deformity, those in which the shape of the articular ends of the bones

has been greatly changed without suppuration, as in arthritis deformans and Charcot's disease.

The principal displacements are backward and backward and outward, usually combined with outward rotation of the leg. As a great exception dislocation forward has occasionally been observed.

Ullman¹ reports two cases of bilateral subluxation inward gradually produced by swinging the body from side to side while at work.

Examples of dislocation due to the prolonged action of the flexor muscles, the knee being long held partly flexed because of disease at some point in the thigh, are not very uncommon, and in young people its effect is intensified by the exaggerated growth of the femoral condyles downward by which the lateral ligaments become too short to permit the tibia to return to its place. This last-mentioned change was first pointed out by Volkmann, in 1874, and deserves to be constantly borne in mind, for if the attempt is made forcibly to straighten such a limb the tibia may turn upon its anterior edge as a centre, so that when straightened it is found to lie well behind its proper position, "dislocation by leverage," as it has been termed.

The dislocations that occur in the course of chronic tubercular or other destructive disease must here be passed with simple mention.

¹ Ullman: *Centralbl. für Chir.*, August 11, 1894.

CHAPTER LV.

DISLOCATIONS OF THE PATELLA.

General Considerations—Cause—Outward: Complete, incomplete, vertical—
Inward—Complete Reversal—Congenital—Habitual or Pathological.

DISLOCATIONS of the patella are rare, less than 1 per cent. of all dislocations, according to the tables in Chapter XXVII., and the infrequency with which they have come under the observation of individual surgeons and the incompleteness or the obscurity of the reports of many cases have combined to make the systematic descriptions rather artificial and unsatisfactory. The physical conditions and relations of the patella, which is a sesamoid bone developed in the tendon of the quadriceps extensor and not an integral part of the joint, are entirely different from those of other bones, and the changes in position and relations which it undergoes in displacement are very varied. The anterior articular surface, or trochlea, of the femur extends higher upon the outer than the inner side and presents a central groove bounded laterally by a sharp margin from which the internal and external surfaces of the inner and outer condyles, respectively, run abruptly backward, and the outer condyle projects more sharply forward than the inner one does. The articular or posterior surface of the patella presents a longitudinal ridge nearer its inner than its outer margin from which the surface slopes forward to the edge. From each lateral border of the bone passes a strong aponeurotic expansion, the so-called lateral ligaments of the patella, portions of the fascia lata which receive expansions from the vasti muscles and are attached to the tibia; of the outer one, the "ilio-tibial ligament" is the strongest part and tends to displace the patella outward when the knee is flexed. A superficial layer, given off from the fascia lata on the sides, crosses the front of the patella and is separated from it by a bursa. In full extension of the knee the patella lies upon the upper part of the trochlea of the femur, but it can be drawn almost completely above it by the forcible contraction of the quadriceps. This muscle is inserted upon the upper border and somewhat on each side of the patella, and the long axis of the muscle is inclined to that of the patella and its ligament as the shaft of the femur is to that of the tibia—that is, they meet at an obtuse angle whose apex is directed inward. As a consequence of this inclination the traction of the muscle tends to displace the bone toward the outer side, and this tendency is resisted by the projection of the anterior surface of the outer condyle and by the internal lateral ligament of the patella.

The first collation of recorded cases was made by Malgaigne¹ in

¹ Malgaigne : *Gazette Médicale*, 1836, p. 433.

1836; the 25 cases which he then collected were increased to 46 in 1855, when he published his work on dislocations. Streubel¹ in 1866 collected 120 cases and made a number of experiments upon the cadaver. Elaborate articles were furnished by Panas² in 1872 and Berger³ in 1877, but the most original and at the same time the most recent one is the paper by von Meyer,⁴ Professor of Anatomy at Zurich.

The patella may be displaced to different distances on the outer or the inner side while the knee is extended or partly flexed, and with such displacement may be combined varying degrees of rotation about its own longitudinal axis. These combinations are so numerous and varied that if a classification should be made according to them it would confuse rather than simplify their study and description. As some of the most striking differences depend upon the rotation of the patella upon its vertical axis, it will perhaps simplify the subject first to consider the conditions which determine the fixation of the displaced bone, and in doing this I shall speak only of displacements to the outer side.

The bone may be displaced to the outer side by muscular action or by a force acting upon its inner lateral border; as it passes sideways along the projecting surface of the condyle its outer border is raised and its inner border depressed into the bottom of the trochlear groove; if the force continues to act the patella is carried past the edge of the trochlea to the outer side of the external condyle, and when its longitudinal ridge passes this edge the outer border of the patella may be turned backward by the traction of its outer lateral attachments and the bone comes to rest with its articular surface against the outer side of the condyle, and its anterior surface looking outward; or it may undergo no rotation, and may come to rest with its inner border against the outer surface of the condyle, its anterior surface looking more or less directly forward, and its outer border projecting markedly outward; or, again, it may undergo rotation in the opposite direction and come to rest with its inner border directed backward, its anterior surface looking inward against the outer surface of the condyle, and its outer border directed forward. These three forms constitute the "complete outward dislocations."

If the force is not sufficient to carry the patella entirely past the outer edge of the trochlea, the bone may come to rest with its inner border in the bottom of the trochlear groove, its posterior surface resting partly against the outer surface of the trochlea and partly projecting beyond it, its outer border directed forward and outward, and its anterior surface looking forward and inward—the "incomplete outward;" or the rotation may be somewhat greater, and while the inner border still rests in the groove of the trochlea the outer border looks directly forward, and the anterior surface directly inward—"vertical" or "edgewise" dislocation; or the rotation may be still greater, the anterior surface being turned so as to look directly backward and lie

¹ Streubel: Schmidt's Jahrbücher, 1866, vol. cxxix. p. 311. and vol. cxxx. p. 54.

² Panas: Dict. de Méd. et Chir. pratiques, vol. xvi. p. 40, art. Genou.

³ Berger: Dict. Encyclop. des Sc. Méd., 3d series, vol. v. p. 334, art. Rotule.

⁴ Von Meyer: Arch. für klin. Chirurgie, 1882-3, vol. xxviii. p. 256.

upon the front of the trochlea, and the posterior surface looking directly forward under the skin—"complete reversal."

It appears, then, that the bone frequently becomes fixed, and firmly fixed, in positions of apparently great instability—that is, resting upon the front or side of the femur only by its narrow lateral edge, and the fixation which is given to it in these positions is given by the tension of the soft parts attached to it and by the overlying fascia. It may be compared to a stick on end under a tightly stretched sheet, which will stand not only upright, but also when inclined, so long as its lower end does not slip along the ground, or its upper along the sheet.

FIG. 348.

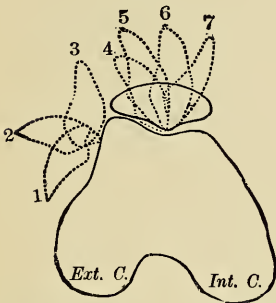


Diagram of outward and edgewise dislocations of the patella.

It also appears, in consequence, that the bone may take many intermediate positions between the extremes, and that consequently the grouping of the different positions must be somewhat arbitrary. The terms in general use are *complete* and *incomplete outward* and *inward* dislocations, *edgewise* or *vertical* (outward and inward) dislocations, and *complete reversal*

in either of the two directions. Another form, dislocation downward into the intercondyloid notch or between the external condyle and the head of the tibia, with some rotation about the transverse axis in either direction, has been observed several times in the last few years. I have termed it *downward with rotation about the transverse axis*. The terms *cunéen*, *cuneata*, and *einklemmung* have been used to indicate the fixation of the patella like a wedge. Simple displacements upward or downward, the result of rupture of the ligamentum patellæ or of the quadriceps, do not, I think, deserve to be deemed dislocations; the bone is not fixed in its new position, and the displacement is only an incident of another and controlling lesion. Among the incomplete outward and inward dislocations those in which one edge of the patella is turned sharply forward differ from the corresponding edgewise ones only in the degree of rotation, and the distinction between them is not only difficult to make in practice, but also does not seem worth preserving. I shall, therefore, group them all as edgewise dislocations, and limit the term incomplete to others in which the rotation is absent or slight.

The outward dislocations are much the more common; it is doubtful if any really complete inward dislocation has been recorded, and of Malgaigne's 46 cases only 6 were incomplete inward. Of the vertical or edgewise dislocations the outward appear to be somewhat more frequent than the inward.

Cause. The cause and mode of production of the different forms are, in many respects, the same. The dislocation may be produced either by muscular action, contraction of the quadriceps, or by external violence acting directly upon the patella. Of the former there are many unquestionable examples; a man dislocates the patella while fencing, a woman by jumping backward and to one side, a boy by

jumping upward and turning partly around to strike a ball. Of the latter, external violence acting directly upon the patella, the common examples are falls and blows upon the knee; in several instances a man riding a horse has struck his knee violently against another moving in the opposite direction. In a number of cases it has been noted that the knee was previously affected with hydrarthrosis, and in a few genu valgum existed. In the cases of frequent, or habitual, dislocation some such predisposing cause is supposed always to exist.

OUTWARD DISLOCATIONS.

1. Complete.

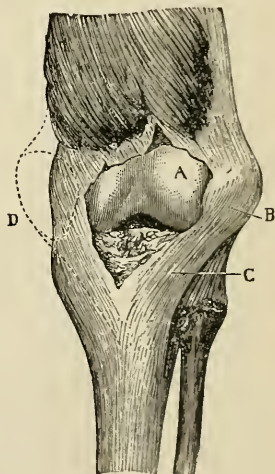
In complete outward dislocations the patella is displaced entirely to the outer side of the external condyle, against which it rests either by its posterior, cartilaginous surface, or, more rarely, by its inner border, its anterior surface being still directed forward, or by the inner part of its anterior surface, the outer border projecting forward and the anterior surface looking inward.

According to von Meyer, and his opinion is based upon clinical observations, as well as upon anatomical and experimental data, the patella can reach this position either by passing outward at or above the upper part of the trochlea in complete extension or hyperextension of the knee, or by passing outward and upward over the lower border of the condyle while the knee is flexed nearly to a right angle. In the former case the dislocation may be produced by muscular action, the contraction of the quadriceps extensor, by which the patella is raised so high that its passage is no longer resisted by the outer border of the trochlea. Hyperextension of the knee favors the displacement by carrying the patella still higher above the trochlea. Other conditions that favor the displacement are exaggerated outward rotation of the leg and bending inward of the knee. As illustrative examples Meyer quotes cases reported by Foucart and Robert. A muscular young man jumping down from a stool (apparently backward) felt a sharp pain, and found he could no longer stand on the right foot; examination showed an outward dislocation of the patella. A woman, carrying a heavy burden upstairs, felt a sharp pain and a cracking in the right knee, and was unable to walk; the patella was dislocated outward.

External violence can produce the dislocation at the same, upper, point.

In either case the further displacement of the patella downward upon the outer surface of the condyle and its fixation there are aided by the subsequent flexion of the knee which involuntarily follows upon the sensation of an injury received there.

FIG. 349.



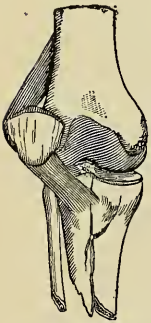
Complete dislocation of the patella outward. (ANGER.)

In studying the manner in which displacement took place, by external violence, while the knee was partly flexed, von Meyer found that the resistance of the ligamentum patellæ compelled the bone to move in a curve downward and outward, so that it lodged over the lower part of the condyle, or even in the groove between it and the tibia, and the tendon of the quadriceps slipped sidewise over the edge of the trochlea, and lay upon the outer surface of the condyle.

Pathology. The pathology of the commoner form has been studied only in experiments upon the cadaver and in specimens of old unreduced dislocations, of which seven cases have been reported. In four of these seven cases the internal lateral ligament of the patella was torn, and in one the rent extended upward in the vastus internus more than three inches above the patella. Experiments upon the cadaver confirm these facts. It may be added that in three cases of long standing the bones had undergone various changes; in some the patella was hypertrophied, in others atrophied; in some it had lost part or all of its articular cartilage; in some the leg was distinctly rotated outward, presumably the result of the traction exerted upon it through the ligamentum patellæ.

The only examinations of uncomplicated recent cases of which I have knowledge are one reported by Andrews¹ and one in which I did an arthrotomy to effect reduction. Andrews's specimen was obtained by amputation, which was rendered necessary by a compound fracture of the leg. The displacement was of the rare form in which the patella has undergone no deviation about its longitudinal axis and rests against the external condyle only by its inner border (Fig. 350).

FIG. 350.



Andrews's case of dislocation of the patella outward.

and forward.

The patient had been run over by a freight car. "The patella was found shoved nearly straight outward with its inner edge resting firmly against the outer condyle, and with its front and back surfaces presenting in a nearly normal direction. . . . At the place where the inner border of the patella rested against the femur the shell and spongy tissue of the condyle were crushed in, making an oval or spoon-shaped hollow about one inch long and five-eighths inch wide. The sharp inner edge of the patella rested firmly in this hollow and was thus effectually prevented from slipping. The rest of the patella was stoutly held in position, like a tent-pole or derrick, by tight bands drawing in three different directions, as follows: 1. By a portion of the vastus externus muscle drawing the outer angle upward, inward, and backward. 2. By a part of the rectus femoris, not represented in the figure, but drawing upward, inward, and forward. 3. By the ligamentum patellæ, drawing downward and inward.

"The vastus internus was torn off. The inner half of the rectus was torn off with the vastus internus, and the lateral attachments of the capsular ligaments to the sides of the patella were effectually ripped away, but the outer part of the rectus was still attached."

¹ Andrews: *Annals of Anatomy and Surgery*, 1883, vol. vii. p. 199.

My patient was a well-grown lad sixteen years old who fell while coasting on skis, his flexed knee striking against a rail. The patella stood out from the side, as in Andrews's case, but the physician who sought to reduce it gave it a half turn, so that when I saw him its outer border projected forward well above the level of the condyle, the knee being in straight extension. I opened the joint widely in front and found the internal expansion widely torn and the vastus internus detached from the patella. Both condyles projected through the rent, and the ligamentum patellæ was engaged beneath and behind the edge of the outer condyle, effectually preventing reduction until after it had been pried out of its position with an elevator. The patient made a good recovery.

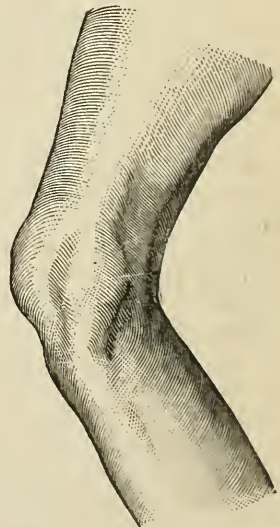
Symptoms. The symptoms are loss of power to stand upon the limb or actively to move the knee, pain, and deformity. The knee is usually partly flexed, but occasionally has been found fully extended. Passive motion is painful, complete extension usually possible, further flexion rarely possible.

The knee appears broadened and flattened anteriorly; the normal prominence of the patella is lost, and in its place is a depression through which the anterior articular surface of the condyles can be distinctly traced unless the swelling is too great. The patella can be readily felt upon the outer side of the condyle, and the tendon of the quadriceps and the ligamentum patellæ show as tense bands under the skin. Usually the patella rests with its articular surface against the outer surface of the condyle and its inner border directed forward, but, as has been already said, it may stand directly out from the condyle, resting against it by its inner border only, or it may be rotated in the opposite direction so that its outer border is directly in front.

Treatment. The method of treatment that has proved the most successful is one proposed more than a hundred years ago by Valentin, which consists in full extension of the knee and flexion of the hip to relax the quadriceps, followed by direct pressure with the hands upon the patella; it may be necessary to increase the laxity of the tendon of the quadriceps by pressing the lower part of the muscle downward toward the knee. Possibly a device which Duplay employed successfully in a vertical dislocation might be used, if pressure with the hands failed; he inserted the points of a strong double hook through the skin, engaged them under the edge or in the anterior surface of the patella, and drew the bone forward. When the ligamentum patellæ is engaged behind the condyle, as in my case, reduction without arthrotomy is impossible.

In cases that have remained unreduced the usefulness of the limb

FIG. 351.



Dislocation of the patella outward. (DUPLAY.)

has sometimes been well restored, the patients being able to walk freely and troubled only in making complete extension. In other cases, again, the disability has been great, the knee being stiff and the patient able to walk only with crutches. Occasionally the accident is followed by a marked tendency to recurrence on flexion of the knee.

2. Incomplete.

The cases to which I limit this group are those in which the dislocation takes place while the knee is extended, and in which the patella rests above and partly to the outside of the outer part of the femoral trochlea, its apex being probably still on the median side of the crest. It is to be remembered that in most systematic descriptions the group is made also to include cases of moderate edgewise or vertical displacement, those in which the inner border of the patella rests in the hollow of the trochlea and the outer border projects outward and forward; but still the majority of the reported cases are of the kind to which I have restricted the use of the term. There are, however, cases of habitual dislocation in which the patella moves outward during flexion of the knee and the outer border turns backward, which might properly be termed incomplete. Malgaigne¹ reports one such in which the condition followed a primary traumatic dislocation, and a number have been reported in which the condition developed gradually or was thought to have existed at birth.

The causes are essentially the same as those which produce the complete outward dislocations in which the patella escapes at or above the upper part of the trochlea, that is, muscular action and external violence received while the knee is fully extended or even hyperextended.

Von Meyer finds the explanation of the incompleteness of the dislocation in the supposition that the lateral movement of the patella takes place while it is still at a lower point upon the femur than it is when it undergoes displacement outward; the outer margin of the trochlea engages in the sulcus at the junction of the patella and ligamentum patellæ, and thus the bone is prevented from being drawn further outward by the traction of the ilio-tibial band.

Direct examination has been reported in only one case, and that an old one, Diday;² the specimen came from a man thirty-four years old; the deformed patella rested on the external condyle and was prevented from moving inward by a bony ridge which occupied the trochlea; the articular surface extended an inch higher upon the outer than upon the inner condyle. The patient walked without difficulty.

The limb is in extension, and any attempt to flex is painful. The inner half of the trochlea can be distinctly traced with the finger, and the patella can be recognized above and to the outer side of its normal position, with its anterior surface looking almost directly forward, and if inclined at all it appears to be usually inclined outward.

The treatment is the same as that of the complete form: flexion of the hip and extension of the knee to relax the quadriceps, followed by direct pressure inward upon the patella. Reduction is easy and sometimes spontaneous.

¹ Malgaigne; *Loc. cit.*, p. 912.

² Diday: *Bull. de la Société Anatomique*, 1836, p. 297.

3. Outward Edgewise or Vertical Dislocations.

According to Malgaigne this form of dislocation was first reported in 1777 by Nannoni, an Italian surgeon, who communicated two cases to the Académie royale de Chirurgie. The subject was not again mentioned until Malgaigne, in 1836, gave a description of it. Since that time a considerable number of cases have been reported; without making a very thorough search I found about thirty, five of which were reported in the *New York Medical Record* between the years 1873 and 1879, and in this enumeration I have not included cases reported as incomplete outward dislocations, although I include such in the classification.

The dislocation is characterized by a displacement outward of the patella and its rotation upon its longitudinal axis, by which its inner border is brought to rest at or near the bottom of the groove of the trochlea, while the outer border projects more or less directly forward and its anterior surface looks inward; it is said by Panas that its apex is also directed slightly backward.

Muscular action is the most frequent cause, and in some cases the contraction of the muscle appears not to have been forcible, as in Martin's¹ patient, a young girl, who caused the dislocation by moving in bed; in others more force has been exerted, as a boy in throwing a snowball, a man in wrestling, another in stumbling, another in jumping. External violence is a less frequent cause; a blow upon the inner edge of the patella by which the bone is pushed outward, its inner border depressed into the hollow of the trochlea, and its outer border raised by the passage of the bone along the slope of the external condyle. The mode of production by muscular action has not been made clear.

The patella may rest partly against the projecting outer portion of the trochlea, or it may touch the femur only by its inner edge even when its outer border still lies somewhat to the outer side of a sagittal plane passing through the inner one, and in one case, Payen, quoted by Malgaigne, the patella had turned more than 90 degrees, so that its outer border lay a little to the inner side of the inner border. Its fixation in this position without lateral support must be attributed to the tension of the overlying soft parts and the untorn parts of the capsule, for in one case in which both the tendon of the quadriceps and the ligamentum patellæ were cut subcutaneously by the surgeon in the effort to reduce, the bone remained as firmly fixed as before.

The knee is generally extended, but in some cases it was flexed half way to a right angle, and is usually immovable because of pain. The deformity is characterized by the sharp projection of the outer border of the patella in front, on each side of which the skin is depressed so that the anterior and articular surfaces of the patella can be felt, but sometimes the skin is stretched tightly toward each side.

The most successful treatment has been that recommended for the preceding forms: flexion of the hip, extension of the knee, and pressure upon the patella, the latter being so directed as to force the projecting

¹ Martin: Arch. gén. de Méd., 1831, vol. xxvi. p. 259.

outer border outward and backward, but this has failed in several cases in which reduction was afterward obtained by forced flexion of the leg or, in one case, by getting the patient forcibly to contract the quadriceps and then pressing upon the patella after it had been thus drawn upward. Possibly Duplay's device, above mentioned, of drawing the patella forward with a strong sharp hook, would be of use by diminishing the friction between it and the femur. Eben Watson, and others following his example, succeeded by slightly flexing the leg upon the thigh during anæsthesia, pressing the patella moderately outward, and then suddenly extending the leg. Three surgeons have resorted to section of the ligamentum patellæ, and one of them also to that of the tendon of the quadriceps, but without success, and in the last one the joint suppurated and the patient died.

INWARD DISLOCATIONS.

These are so similar to the outward dislocations in their nature, causes, symptoms, and treatment that a detailed description is unnecessary.

Complete Inward.

This dislocation is denied by several authors, the only alleged cases being those of Putégnat and Walther, both quoted by Malgaigne. The former was traumatic in origin, but when the patient came under observation the condition was that of habitual dislocation: the patient, a girl thirteen and a half years old, had fallen upon her knees five years before, and since that time both patellæ had been so freely movable that she sometimes amused herself by dislocating and reducing them more than a hundred times in an hour. The right patella could be more easily dislocated outward, the left one inward; but both could be dislocated so completely inward that their anterior surfaces were exactly in contact when the knees were brought together. The ligaments were so relaxed that the legs could not be completely extended by the contraction of the quadriceps.

Of Walther's case, nothing is known but a brief description in Latin of a specimen in a museum at Berlin. Malgaigne thought it might be a complete inward dislocation, but admits that its character is uncertain.

Incomplete Inward.

Of incomplete inward dislocation only one case has been reported, by Key¹; it also was quoted by Malgaigne. The patient, a girl twenty years old, slipped and fell; she felt great pain in the left knee, and was unable to walk. "The patella was found resting on the inner condyle, the outer part of its articulating surface being supported obliquely by the projecting edge of the trochlea of the femur. Gentle pressure on the inner edge of the patella, as the limb lay on the bed, reduced it to its natural position." The joint suppurated, and apparently the patient died or the limb was amputated. The tendon of the vastus externus was partly torn through.

¹ Key: Guy's Hospital Reports, 1836, vol. i. p. 260.

Inward Edgewise or Vertical Dislocation.

This seems to be nearly as frequent as the corresponding outward form. Possibly its relative frequency and the rarity or absence of the complete and incomplete inward forms are to be explained by the greater projection inward of the internal condyle, and the relative shortness of the ligamentum patellæ, which prevents the patella from reaching that side of the condyle.

COMPLETE REVERSAL.

Complete reversal, *the outer border passing in front* to the inner side, so that the anterior surface rests against the trochlea and the articular surface is directed forward, has been reported in only two cases, which are briefly quoted by Malgaigne as follows: "In 1752 J. Sue saw a dislocation produced by muscular action in which he clearly recognized a two-thirds reversal of the patella from without inward without any evidence of rupture of the ligaments. Subsequently Hévin said that he had heard Bruyères read before the Académie royal de Chirurgie the details of a total reversal of the patella upside down, also without rupture of the ligaments; in the latter case the cause was a blow received upon the inner part of the knee."

Complete reversal, *the inner border passing in front* to the outer side, has been reported in three cases, Castara, quoted by Malgaigne, Wragg,¹ and Gaulke.²

Castara's patient, a girl seventeen years old, bent forward to lift a book from a table, resting her weight upon the extended right leg, and pressing the outer border of the patella against the edge of a chair; she suddenly cried out, and Castara, summoned immediately, found the leg partly flexed, and could extend it but very little. The patella rested by its outer border upon the outer and upper part of the trochlea of the femur, which it covered only over a breadth of a quarter of an inch; its inner border inclined outward and projected in this direction two and a half centimetres, its articular surface looking forward and inward. The tendon of the quadriceps and the ligamentum patellæ each formed a quite thick and hard rounded cord above and below. The surgeon grasped the bone with his thumbs and forefingers, and by a simple movement of rotation from behind forward, and from without inward, restored it easily to its place.

Wragg's patient was a negro, who had been struck upon the outer side of the right patella. The limb was extended and immovable. The inner border of the patella had turned forward and outward, and lay about half an inch to the outside of the normal position of the outer border; the outer border could be felt deep in the trochlea about half an inch from its inner edge. The tendon of the quadriceps and the ligamentum patellæ showed under the skin as hard twisted cords; very little passive motion at the knee. The dislocation was reduced

¹ Wragg: Charleston Medical Journal, May, 1856, abstract in Schmidt's Jahrbücher, 1856, vol. xci. p. 362.

² Gaulke: Deutsche Klinik, 1863, p. 108.

easily by pressing with the thumbs against the projecting border, and with the index- and middle fingers against the outer border in the opposite direction. The reaction was slight, and the patient made a good recovery.

Gaulke's patient, a girl seventeen years old, injured her knee in a fall from a horse, and was not seen by him until ten days after the accident. "The patella lay entirely upon the outer condyle of the femur, and had been so turned about its longitudinal axis that its posterior surface looked forward and inward, and the anterior surface backward and outward." After several failures he reduced by making pressure against the projecting inner border with one jaw of a vise, such as is used by carpenters to hold pieces of wood that have been freshly glued together, the counter-pressure being made with the other jaw against the internal condyle. The force of the screw was so applied as to press the inner border of the patella forward and inward, while its outer border was expected to move along the outer slope of the trochlea. After many efforts, the patella suddenly moved with a snap, turned about its long axis, and fell back into place. The patient recovered in a fortnight.

Downward with Rotation About Transverse Axis.

In this the patella is displaced downward and lodged between the femur and tibia with some rotation about its transverse axis in one direction or the other. Eight cases¹ have been reported. In all the cause was external violence acting on the knee, probably while flexed, and in two cases causing also a subluxation of the knee.

The slightest form is represented by Newman's case. A fall upon the knee; "the lower border of the patella was wedged in between the head of the tibia and the condyles of the femur, . . . and the tendon of the quadriceps extensor muscle was thrown forward." The dislocation was easily reduced. It is the only case of the kind.

In 5 cases (Midelfart, Deaderick, Schmidt, Rutherford, Cheesman) the upper border was turned backward into the cleft between the femur and tibia and the quadriceps was torn away from it. In all but one the position was determined by inspection after incision; in Deaderick's it was probably turned the same way. Deaderick reduced by manipulation after many efforts; he thinks binding tissues were torn in the course of the unsuccessful attempts and that this made the reduction possible at last by a manipulation which had previously failed many times. In most of the others considerable force was needed to dislodge the bone after it had been exposed. This was attributed by some to the tension of the ligamentum patellæ, but I should think that engagement of the torn edge of the lateral expansions on the side of the condyles was at least a contributing cause. All these patients made good recovery.

In 2 cases (Szumann, Küttner) the patella lay between the outer

¹ Midelfart, *Ctblatt für Chir.*, 1888, p. 56; Szuman, *Beilage zum Ctblatt für Chir.*, 1889, No. 29, p. 101; Deaderick, *Annals of Surg.*, vol. xi. p. 102; Schmidt, *Ctblatt für Chir.*, 1900, p. 1023, Newman and Rutherford, *Lancet*, June 22, 1901, p. 1761; Küttner, *Beiträge zur klin. Chir.*, vol. xlii. p. 553; Cheesman, *Annals of Surg.*, vol. xli. p. 108.

condyle of the femur and the tibia, its articular surface against the femur in Szumann's, against the tibia in Küttner's, and the quadriceps was tightly stretched across the outer side of the condyle, the end of the femur projecting through a large rent in the internal lateral expansion. The external lateral ligament was torn in Küttner's, both lateral ligaments in Szumann's, and the crucial ligaments in both. In Küttner's the skin was torn and he amputated. Szumann reduced with difficulty after having opened the joint and divided the ligamentum patellæ. It seems probable that in both cases the dislocation was first to the outer side, while the knee was flexed, and that then forced adduction of the leg tore the lateral and crucial ligaments and opened a gap into which the patella was drawn. In both cases the violence was great and repeated; in Szumann's the leg was caught in machinery, in Küttner's in a wagon wheel. Szumann's made a good recovery.

For Lannelongue's and Potel's cases see the next two sections.

CONGENITAL DISLOCATIONS.

In a number of reported cases the term *congenital* has been used although the writers knew that the dislocation had first appeared long after birth; in most of the others it has not been possible to ascertain with certainty the date of the appearance of the condition, and in many the probability is very great that it had been gradually developed long after birth. The reported cases in which it is reasonably certain that the condition existed at birth are not numerous, perhaps fifteen or twenty, but if to these are added the other cases which several of the patients have said existed in other members of their families, the number becomes considerably increased. The principal paper upon the subject is one by Zielewicz¹; Bessel-Hagen² read one before the Berlin Medical Society, and presented 2 cases, but the published abstract is very short. Zielewicz's paper gives the details of 13 cases, in 3 of which the patella was dislocated upward with elongation of its ligament; in the remaining 10 the dislocation was outward. The congenital character of the first 3 is uncertain. Of the outward ones in which the sex is noted, 6 were males, 3 females; in 5 both patellæ were dislocated, and in all the patients were able to make good use of the limb.

Lannelongue³ reported the case of a boy twelve years of age in whom since birth the very small patella disappeared, on semi-flexion of the joint, into the space between the femur and the tibia so that only its apex could be felt. The ligamentum patellæ was only one centimetre long. It has been grouped with those of the preceding section, but I do not think it should be termed a dislocation.

Bessel-Hagen points out that the cases may be grouped in three classes: 1. The *incomplete*, in which the patella lies upon the outer condyle when the knee is extended, and returns to its normal place when the knee is flexed; 2, *complete intermittent*, in which the displace-

¹ Zielewicz: Berlin. klin. Wochenschrift, 1869, vol. vi. p. 25.

² Bessel-Hagen: Deutsche med. Wochenschrift, 1881, p. 45.

³ Lannelongue: Bulletin Médical, 1895, p. 894.

ment occurs during flexion; 3, *complete permanent*, in which the displacement is increased during flexion, and is not overcome during extension.

Caswell¹ reported a case of congenital dislocation of both patellæ in a man, forty-three years old, who said that five members of his family, in three generations, had the same deformity—his father, sister, son, and nephew. Dr. Caswell examined the son and confirmed the statement to that extent.

Shapleigh² saw a man, thirty-nine years old, both of whose patellæ “were dislocated outward, resting on the upper and outer surface of the external condyle of the femur.” They were of normal size. The patient said the condition had existed from birth, and that his grandfather, father, and one of his own children, four generations, had the same deformity. The man walked without difficulty and had served as a soldier during the war.

An anonymous writer³ reported a case of congenital dislocation of both patellæ in a girl whose father, aunt, and aunt’s daughter were in the same condition.

HABITUAL OR PATHOLOGICAL DISLOCATIONS.⁴

A number of varying conditions in the bones or ligaments of the knee may have for consequence the frequent, even habitual, dislocation of the patella in certain positions or movements. Almost without exception, these dislocations are to the outer side and complete. Many cases reported as congenital are probably of this character; Isemeyer,⁵ indeed, published an elaborate paper on the subject in which he claimed that all reported cases of congenital dislocation were really pathological ones.

Among the alleged causes are relaxation of the ligaments, chronic arthritis of different kinds, malformations of the knee, especially genu valgum, and injury of the lower part of the vastus internus.

In genu valgum the increased abduction of the leg upon the thigh produces a corresponding exaggeration of the angle between the quadriceps and the ligamentum patellæ in consequence of which the contraction of the muscle constantly tends to draw the patella outward, and if the patella passes to the outer side of the outer condyle the muscle then aids still further to abduct the leg and increase its deviation. Indeed, in some of the reported cases it has remained in doubt whether the abduction of the leg preceded or was itself the consequence of the dislocation of the patella.

Condamin⁶ reported a case in which persistent outward displacement took place gradually in consequence of operative division of the lower portion of the vastus internus in the treatment of an osteomyelitic abscess.

¹ Caswell: American Journal of the Medical Sciences, July, 1865.

² Shapleigh: Boston Medical and Surgical Journal, 1881, vol. cv. p. 252.

³ New York Medical Journal, 1885, vol. xlii. p. 27.

⁴ For a full discussion, 95 cases, see Della Vedova, Arch. de Ortopedia, 1902.

⁵ Isemeyer: Arch. für klin. Chirurgie, 1866, vol. viii. p. 1.

⁶ Condamin: Lyon Méd., September 30, 1888.

The patella is habitually very movable, and the dislocation takes place or is increased during flexion of the knee and is reduced or diminished during extension. The functions of the limb are more or less interfered with, complete voluntary extension being difficult or impossible. The femur tends to rotate inward, and the leg outward and to become abducted.

Potel¹ saw a boy fifteen years old with hip disease and an acquired genu recurvatum whose patella disappeared on semi-flexion as in Lannelongue's case quoted in the preceding section. The ligamentum patellæ was very short. Its right to be deemed a dislocation is open to the same objection.

A case which resembles Putégnat's of complete inward dislocation in the facility with which the patient could rapidly produce and reduce the dislocation by muscular action is reported by Albert;² the patient was a boy, sixteen years old, with genu valgum on the affected side. When the knee was held at an angle of 160 degrees he could repeat the production and reduction with great rapidity and ease. Flexion at 150 degrees was the limit at which voluntary reduction could be made; voluntary dislocation was possible even when flexion was carried to 90 degrees.

The treatment consists in the wearing of a knee-cap designed to oppose the displacement during flexion or to restrict the flexion to the range beyond which the displacement took place.

Roux³ relieved a case of habitual dislocation outward following rupture of the aponeurosis on the inner side by dividing the vastus externus, suturing the rent on the inner side, and displacing the insertion of the ligamentum patellæ upon the tibia half an inch inward. Bradford⁴ did the same with success.

Another French surgeon (I have mislaid the reference) relieved the condition by narrowing the internal lateral expansion by means of three silk sutures so placed as to make a longitudinal tuck in it; others have excised a piece and closed the opening with sutures.

Schanz⁵ placed five stout silk sutures between the mesial border of the patella and the internal condyle, on tying which the capsule folded into a sausage-like roll.

Hildebrand⁶ treated a case by an osteotomy of the femur, giving the knee the varus position.

¹ Potel: Presse Méd., 1899, p. 149.

² Albert: Chirurgie, vol. iv. p. 396.

³ Roux: Rev. de Chir., August, 1888.

⁴ Bradford: Boston Medical and Surgical Journal, February 20, 1896.

⁵ Schanz: Zeitschrift für Orthop. Chir., vol. vii.

⁶ Hildebrand: Arch. für klin. Chir., vol. lxvi. p. 360.

CHAPTER LVI.

DISLOCATIONS OF THE FIBULA.

Of the Upper End—Of the Lower End—Spontaneous or Pathological.

THE fibula may be dislocated at its upper or at its lower end, and as the result of external violence, or of muscular action, or of unequal growth of the tibia and fibula.

DISLOCATIONS OF THE UPPER END.

Of these there are now about twenty-five reported cases.¹ In the majority the displacement was outward and forward, in others backward, and in a few upward. It is to be remembered that, as the head of the fibula is situated behind the most external part of the tibia, a dislocation forward must also be outward.

Of cases complicated by fracture of either the tibia or fibula, or of both bones, quite a number have been reported. Of those in which the dislocation is produced by the overriding of the fragments by which the head of the fibula is forced upward, it is only necessary to say that, although the reported displacement has been very great in some cases, it does not appear seriously to have affected the treatment of the fracture, and in most cases reduction was easy. In some, in which the fracture united with shortening, there remained a permanent displacement of the head of the fibula upward. The dislocation is not always upward, but is sometimes forward, and sometimes the head has been freely movable backward and forward.

1. Forward.

The cause has been a fall with the leg bent under the body or a muscular effort without a fall, and there is reason to think that the forcible depression and inversion of the front of the foot may be a factor in the production; thus, Savournin's patient caught her heel while descending a staircase and the foot was sharply depressed and turned inward, and in my two patients, one of whom had not fallen, movement of the foot in the direction mentioned caused pain at the site of the dislocation after reduction. Tillaux, also, observed a case of diastasis associated with fracture of the lower end of the tibia (p. 388).

The head of the fibula can be seen and felt in front and outside of its normal position, and the tendon of the biceps shows plainly in an unusual curve. The patient is usually unable to walk because of pain, but can move the knee quite freely.

¹ In addition to the bibliography given in the first edition, see Hirschberg, *Arch. für klin. Chir.*, 1888, vol. xxxvii. p. 199; Leggett, *Lancet*, March 31, 1888; and Stimson, *New York Medical Journal*, May 25, 1889, and February 6, 1892

Reduction has usually been easy by direct pressure while the knee was partly flexed; in Savournin's case while the knee was extended and the foot in dorsal flexion. I was obliged to resort to arthrotomy in one case. Leggett refers to an unreported case in which reduction failed, two attempts having been made under anaesthesia. The obstacle in my case appeared to be a strong fibrous band extending from the head of the fibula to the front of the tibia; after its division reduction was easy.

2. Backward.

In at least one of these, Dubreuil, the cause clearly seems to have been forcible contraction of the biceps; in the others the patients fell, and the cause may have been a twist of the leg which ruptured the tibio-fibular attachments by the pull of the external lateral ligament of the knee, the biceps then acting to displace the bone backward.

In two cases the foot was slightly everted, and in one of them there was a sensation of cold and numbness along the peroneal region of the leg; in one the tendon of the biceps was tense. The displacement is described as backward in all, and its extent as one inch in Dubreuil's.

Reduction was effected without much difficulty in three by direct pressure upon the head of the fibula while the knee was flexed. In Dubreuil's the displacement recurred on the following day, and was then less easily reduced; a knee-cap of leather was then worn for twelve days, and the patient was then able to walk with a cane, but for some time the leg had a tendency to bend outward; ultimately recovery was complete, as it was also in the other two cases.

Erichsen and Oldright did not see their patients until some time after the accident; in the former's the displacement was permanent and the "limb was somewhat weakened, so that the patient could not jump, but otherwise he suffered no inconvenience." In Oldright's the displacement could be easily reduced, but it immediately recurred; local pressure and immobilization of the knee failed to cure. Possibly retention by a strip of adhesive plaster placed round the upper part of the leg would be effective.

3. Upward.¹

Of this form there are only three reported cases, Boyer, Stoll, and Sorbets, and the account of the latter is too incomplete to be of any use or even to establish the accuracy of the diagnosis.

Boyer's patient appears to have received a dislocation outward of the foot or a Pott's fracture of the ankle in which the fibula, instead of breaking, had been pushed bodily upward; the extent of the displacement is not stated; the restoration of the foot to its place corrected the upper dislocation also, and the patient recovered.

In Stoll's case the head of the fibula is described as standing "notably higher than normal on the outer surface of the tibia, and forming there an immovable, firm, sharply projecting tumor, very painful on pressure." He quotes Dubreuil's case as identical, and attributes the displacement to the forcible contraction of the biceps, and, therefore, it seems possible that the dislocation may belong among

¹ This is sometimes called "total" dislocation, because the lower end also is displaced.

the backward ones. The patient was a circus-rider and received the injury in jumping from his horse, alighting upon his toes. The sole was everted, the toes abducted; the inner side of the ankle swollen and tender; passive motion of the knee and ankle very painful; numbness of the outer side of the leg. No fracture could be found. Reduction was made by forcible traction on the foot, the knee being flexed at a right angle, and was accompanied by a snapping sound.

DISLOCATIONS OF THE LOWER END.

Of this the only two recorded cases, excluding, of course, the innumerable ones in which diastasis of this joint has formed one of the lesions of Pott's fracture at the ankle and the few cases in which the same diastasis has been part of inward or outward dislocation of the foot, are one observed by Nélaton in the service of Gerdy and one in the service of Tillaux reported by Dunand.¹ Gerdy's patient came to the hospital thirty-nine days after the accident. The wheel of a wagon had passed across the lower end of his leg and had forced the external malleolus so far backward that it was almost in contact with the outer border of the tendo Achillis; the outer surface of the astragalus could be felt through almost its entire extent. The patient walked fairly well, and Gerdy thought no attempt to reduce should be made.

In Tillaux's case the patient in stepping from an omnibus caught his foot and fell forward. The foot was everted, there was a large ecchymosis on the inner side of the leg and foot, and another on the outer side; the ankle was swollen and tender, especially on the inner side; no fracture could be found. The lower end of the fibula was freely movable forward and backward with cartilaginous crepitus, and could be drawn outward so far that the end of the finger could be inserted between it and the astragalus. The patient made a good recovery.

I have seen one case of dislocation backward from the tibia, possibly with preservation of the relations with the calcaneum. The patient, a lad of seventeen, was admitted to the House of Relief, July 17, 1889, having been injured in the left ankle while wrestling. The foot was abducted, its inner side normal and painless; the lower part of the fibula was prominent, the region swollen and tender. A careful examination was made under ether, and the above diagnosis reached. On adduction of the front of the foot the bone returned to its place with an audible snap. The dislocation was then reproduced by abduction of the foot, and again reduced by adduction.

SPONTANEOUS OR PATHOLOGICAL DISLOCATIONS.

These have been reported as occurring at the upper end in consequence of inflammation of the joint, of rhachitic changes in the bones, and of exaggerated growth of the tibia following necrosis. In the same group may be classed a dislocation outward reported by Bryant, which was due to arrest of the growth of the tibia.

¹ Dunand: Thèse de Paris, 1878, No. 217.

Malgaigne, after quoting a general description given by Cooper, according to which chronic hydrarthrosis leads to the easy displacement of the head of the fibula and to much weakness and fatigue in walking, describes a case under his own care in which this laxity of the joint existed; in certain movements of the knee the fibula was displaced backward, returning almost at once to its place with a cracking sound; the condition followed an arthritis which had produced a similar relaxation of the knee. In a case of rachitic curvature of the leg in an infant Malgaigne thought he could recognize the head of the fibula displaced upward almost to the level of the articular surface of the tibia, and on examining the rachitic skeletons preserved in the Musée Dupuytren he found several examples; the displacement was upward and outward at the upper end, the lower end preserving its normal relations.

Dislocation downward of the upper end due to elongation of the tibia following necrosis was described by Parise (quoted by Malgaigne), who reported three cases. In one of them the elongation was three centimetres on the inner side of the tibia, one and a half centimetres on the outer. Malgaigne subsequently saw and reported a fourth case. The conditions did not affect the functions of the limb.

CHAPTER LVII.

DISLOCATIONS AT OR NEAR THE ANKLE.

Dislocations of the Foot (Tibio-tarsal)—Subastragaloid—Total Dislocation of the Astragalus—Medio-tarsal—Congenital.

Anatomy.

THE principal movements of the foot are that of flexion and extension, or dorsal and plantar flexion, which takes place in the joint formed by the astragalus and the tibia and fibula, and that of adduction and abduction combined, respectively, with inversion and eversion of the sole, which takes place in the joints between the astragalus on one side, and the calcaneum and scaphoid on the other, and is aided by slight motion between the calcaneum and cuboid. The axis of the first joint, the ankle, is horizontal and nearly transverse, its inner end inclining forward; that of the other runs obliquely from a point near the inner tuberosity of the calcaneum upward and forward to a point on the upper surface of the neck of the astragalus.

The astragalus articulates above with the under surface of the tibia, and on the sides with the malleoli, between which it is so snugly placed that no lateral motion is possible. On each side the lateral ligament passes to the astragalus and calcaneum from the malleolus, and the lower ends of the tibia and fibula are bound together by ligaments in front and behind. The range of dorsal and plantar flexion is nearly 90 degrees, and as the articular surface of the astragalus is somewhat narrower behind than in front some lateral motion of the joint is possible in full plantar flexion.

The rounded head of the astragalus articulates with the posterior concave surface of the scaphoid, the inferior calcaneo-scaphoid ligament, and slightly with the anterior end of the calcaneum. On the under surface of the astragalus are two articular facets corresponding to two on the upper surface of the calcaneum, and between them is the strong interosseous ligament which fills the canal formed by a groove on each bone separating its two articular surfaces, and binds the bones firmly together. The maximum range of motion in these joints is about 40 degrees, and is limited partly by bony contact and partly by the ligaments.

In this chapter I shall describe four different dislocations: those of the foot, those of the astragalus, the subastragaloid, and the medio-tarsal dislocations; under the first term are included those in which the astragalus, while maintaining its relations with the other bones of the foot, is displaced from the bones of the leg; under the second, those in which it is also displaced from the calcaneum and scaphoid; under the third, those in which the astragalus remains in the tibio-

fibular mortise and is separated from the calcaneum and scaphoid ; and under the fourth, those in which the scaphoid and cuboid are together dislocated from the astragalus and calcaneum.

DISLOCATIONS OF THE FOOT. TIBIO-TARSAL DISLOCATIONS.

The displacements of the astragalus and the foot are so complex that the nomenclature of the various dislocations presents serious difficulties, and the confusion has been increased by the varying practices of different writers, some of whom treat the tibia as the dislocated bone and apply the terms indicative of direction to it, while others consider the foot as the dislocated portion. I shall here follow the latter practice, and shall use in the classification only four main terms, dislocations *forward*, *backward*, *outward*, and *inward*, disregarding for the moment the many deviations in the direction of the toes and of the sole which are seen in conjunction with the principal dislocations. (The latter two are sometimes subdivided into four : *pronation*, *supination*, *inversion*, and *eversion* ; for the latter two names *adduction* and *abduction* seem preferable.) Of these four the first two are pure dislocations ; in the latter two are frequently placed cases in which the displacement is associated with fracture of one or both bones of the leg, and of which the more common forms have been elsewhere described among fractures at the ankle. It must be freely conceded that the classification, especially in respect of the last two groups, is arbitrary and open to serious criticism, but so are all others that have been proposed, and it is believed that this one has a sound clinical basis in so far that the terms outward and inward correspond to displacement outward, or eversion, or to displacement inward, or inversion of the foot, the symptoms which would at once attract the attention of the surgeon, and that its divisions coincide also with those of the modes of production. A fifth group, dislocation *upward*, between the separated tibia and fibula, may be added.

Two striking varieties, in which the toes are turned directly inward or outward, will be mentioned under inward and outward dislocations respectively. The latter has been classified by some as a separate form, under the title of dislocation of the foot by rotation outward.

The mechanism of the joint and the mode of production of the dislocations have been experimentally studied by many surgeons and anatomists, of whom I shall here name only one, Hönigschmied,¹ whose experiments were exceptionally numerous and whose article is very full. Wendel² collected 108 cases uncomplicated by fracture reported before 1898.

1. Dislocations Backward.

(Syn. Dislocations of the lower end of the tibia forward ; see also Fractures at the Ankle.)

In these dislocations the astragalus, and with it the foot, is displaced backward to a variable distance, with rupture of the lateral ligaments

¹ Hönigschmied : Deutsche Zeitschrift für Chir., 1877, vol. viii. p. 239.

² Wendel : Beiträge zur klin. Chir., vol. xxi. p.123.

and sometimes of other parts of the capsule, and sometimes with fracture of one or both malleoli or of the posterior edge of the lower articular surface of the tibia.

The cause is usually extreme plantar flexion of the foot, in which the posterior border of the end of the tibia comes into contact with the posterior lip of the astragalus (Henke¹), by which a new centre of motion is established behind the line of the malleoli; the continuation of the movement ruptures the lateral and the anterior ligaments, and the bones being thus freed slip past each other. The rupture of the ligaments is the first step, and the fixation of the astragalus behind the tibia takes place by correction of the plantar flexion. Commonly the injury is produced by a fall backward while the foot is fixed. In an incomplete dislocation reported by Sanson (quoted by Albert) the patient's leg was bent under him in a fall in such a way that the dorsum of the foot and the front of the leg rested on the ground, and the buttocks rested on the heel; in this case the mechanism appears to have been pure exaggerated plantar flexion. Examples of pure primary dislocation are rare; but partial, and perhaps complete, dislocations occurring as a secondary result of rupture of the lateral ligaments or fracture of the fibula and internal malleolus, as in fracture by eversion at the ankle, are frequent, and always need to be guarded against in the treatment of this last-named injury; they are produced either by the falling backward of the insufficiently supported foot, as the patient lies upon his back, or by contraction of the flexor muscles, and occasionally subcutaneous division of the tendo Achillis has been resorted to to overcome or prevent it. Wendel collected 26 uncomplicated cases, of which 6 were compound.

Hönigschmied produced the dislocation twenty times and found the results quite constant; in 14 the internal lateral and the anterior branch of the external lateral ligament were the first to yield, being torn away from their insertions, then the middle and posterior branches of the external lateral ligament yielded, and the foot was thus completely freed. The ligaments were torn away, and occasionally small scales of bone came away with them. In 5 experiments on the bodies of elderly people, both malleoli were broken off in 3, and the external malleolus in 2. The internal malleolus broke at its base, and the line of fracture ran downward and backward; that of the external malleolus ran upward and backward, beginning just above the insertion of the anterior branch of the lateral ligament.

Clinically and post mortem the same lesions have been found; fracture of the external malleolus is common, that of the internal malleolus and of the posterior articular border of the tibia is occasionally seen.

The foot appears shortened in front, and the heel lengthened, to an extent that varies with the degree of the displacement, the maximum being about an inch; the lower end of the tibia projects more or less markedly in front and sometimes is exposed by rupture of the skin; the extensor tendons may be felt as tense cords crossing to the dorsum of the foot, and the tendo Achillis curves backward to the heel leaving on each side a well-marked depression between itself and the malleolus.

¹ Henke: *Zeitschrift für rat. Med.*, 1858, 3d ser., vol. ii. p. 177.

The toes may be a little depressed, and perhaps abducted or adducted. If the fibula is broken its mallocolus accompanies the foot in its displacement backward.

Reduction, with the exception of Cooper's first case, in which he appears not to have made the diagnosis at the time, has always been easily obtained by pressing the foot forward and the lower end of the leg backward, and the limb should then be immobilized, preferably in a posterior moulded splint so as more surely to prevent recurrence. Statzer¹ reduced one that was nine weeks old; the internal malleolus was broken.

2. Dislocations Forward.

(Syn. Dislocations of the lower end of the tibia backward.)

In this dislocation, which is much rarer than the preceding, the astragalus, and with it the foot, is displaced forward from beneath the tibia. Malgaigne collected only five cases, Delamotte, Colles, Nélaton, Pierre, and R. W. Smith, and I can add only five more, Huguier,² Sarazin,³ Augarde,⁴ Willemin,⁵ and Hornby,⁶ making ten in all. Wendel collected 11 cases, 6 of which are new.

The mode of production may be by dorsal flexion of the foot followed by impulsion of the tibia downward and backward by a force acting in the direction of its long axis, or by direct pressure of the foot forward and of the leg backward while they are at right angles to each other. Among the recorded cases are clear examples of each, such as R. W. Smith's and Nélaton's of the former, and Huguier's of the latter. R. W. Smith's⁷ patient, while standing with the hip and knee flexed and with the foot resting on a stone in such a manner that the toes were higher than the heel, was struck upon the knee by a falling cask which forced it downward and increased the flexion at the knee and ankle. In Nélaton's case,⁸ a woman, who fell from the fourth floor, the anterior lip of the articular surface of the tibia was broken off, and the upper surface of the astragalus was scratched antero-posteriorly.

In the second method of production the force and counter-force act at right angles to the long axis of the limb, the one upon the front of the lower end of the tibia, the other in the opposite direction upon the back of the heel. Huguier's case is an example: a man, while engaged in turning a railway turntable, fell and caught his foot in such a manner that the heel was fixed and a projecting rail on the moving turntable pressed against the front of the tibia six inches above the ankle and produced a well-marked dislocation of the foot forward.

The symptoms are lengthening of the front of the foot and shortening of the heel, with effacement of the depressions on each side of the

¹ Statzer: Wiener klin. Wochenschrift, 1904, No. 3.

² Huguier: Gaz. des Hôpitaux, 1855, p. 469, and Arch. gén. de Méd., 1868, vol. i. p. 513.

³ Sarazin: Recueil de mém. de méd. chir. et pharm. mil., 1860, vol. iv. p. 66.

⁴ Augarde: Idem, 1880, vol. xxxvi. p. 168.

⁵ Willemin: L'Union méd., 1866, vol. xxix. pp. 50 and 73.

⁶ Hornby: Medical Times and Gazette, 1871, vol. ii. p. 10.

⁷ R. W. Smith: Dublin Quarterly Journal of Medicine, 1852, vol. i. p. 465.

⁸ Nélaton: Pathol. externe, vol. ii. p. 477.

tendo Achilles. The foot is in the position of more or less plantar flexion, and in one or two cases the hollow of the instep was exaggerated. The upper articular surface of the astragalus can be felt in front of the end of the tibia, and the malleoli are nearer to the heel and to the sole than normal.

In four cases reduction was easily made by traction and direct pressure; in Smith's it could not be made, but there is reason to think the efforts were not guided by a correct appreciation of the nature of the injury; Nélaton's patient was killed by the fall; in the remaining cases the details of treatment are lacking.

3. Dislocations Inward.

In this division are placed those cases in which, usually by adduction and inversion (supination), the foot is moved downward and to the inner side, so that the astragalus leaves the tibio-fibular mortise more or less completely. Two distinct forms are observed: in one the foot is markedly inverted and the upper surface of the astragalus can be seen and felt raising the skin under the external malleolus; in the other the inversion of the foot is less or is absent and there is marked adduction, so that sometimes the ends of the toes point directly inward; in the latter form it is thought that the displacement is secondary to a backward dislocation. If the two forms are separated the former is called *supination*, the latter *adduction* or *inversion* dislocation. Wendel's list contains 36 *supination* (22 compound) and 3 *adduction* (2 compound).

Malgaigne includes in the group (which he terms tibio-tarsal dislocations outward) many cases complicated by fracture of the astragalus or of one or both bones of the leg; but of his total of 22 cases, 8 were not thus complicated, and to these I can add 5, Busch,¹ Nunnely,² Eames,³ Carmichael,⁴ and Spaeth.⁵ I have described under "fractures by inversion and adduction of the foot" the lesions and symptoms in cases in which fracture is present and the displacement is slight.

Excluding for the moment those cases in which the displacement is secondary to a backward dislocation, it seems probable that the cause is violent supination, or inversion, of the foot, but the histories of the cases do not positively establish this opinion. In most the cause has been a fall, usually from a height.

The astragalus fits so snugly and squarely into the tibio-fibular mortise that in a considerable proportion of cases its turn about its antero-posterior axis breaks the external malleolus or forces it away from the tibia by the pressure of the upper outer edge of the astragalus. In the experiments which Hönigschmied made by fixing the foot in a vise and bending the leg directly toward the inner side—tibial flexion—the external malleolus was broken 5 times, the external lateral ligament torn from its insertion 12 times, and in 3 cases the joint remained unopened and separation took place between the astragalus and the

¹ Busch: *Lehrbuch der Chir.*, vol. ii., part 3, p. 327; quoted by Lossen.

² Nunnely: *British Medical Journal*, 1868, vol. ii. p. 362.

³ Eames: *Idem*, 1871, vol. i. p. 503.

⁴ Carmichael: *Idem*, 1871, vol. ii. p. 35.

⁵ Spaeth: *München. med. Wochen.*, January 17, 1888.

calcaneum. These results coincide in the main with those obtained in a similar manner by Bonnet, and Honigschmeid accepts the latter's opinion that the fracture of the malleolus is effected by the direct pressure upon it of the outer upper border of the astragalus and not by traction exerted through the external lateral ligament. Bonnet frequently found the internal malleolus also broken, Honigschmeid never.

In one case, Busch, in which there was no fracture, the dislocation was compound and the bones of the leg protruded through the wound in front, the astragalus lay entirely to the inner side of the internal malleolus, and the foot was greatly adducted; Busch thought the dislocation had been primarily backward. Of Wendel's 22 compound cases the bones protruded in 16; 15 were reduced, 5 after resection; one of these died, the others made slow recoveries with useful joints.

In some cases, in which the displacement inward may be assumed to have been secondary to a backward dislocation, the adduction of the foot has been very great, 90 degrees, so that the toes pointed directly toward the other ankle; in the others the adduction is less, but the inversion is great; in Carmichael's "the plantar aspect pointed to the middle line of the body," in Eames's "the plantar aspect of the foot was completely inverted," in Spaeth's the inner border lay directly beneath the tibia. In some the external malleolus was very prominent; in Nunnely's "there was a large and well marked projection below the outer malleolus" over which the skin was very tense, and "there was a deep, narrow depression at the inner malleolus where the skin was also very tight."

Reduction has always been easily effected by traction and eversion of the foot, and in the uncomplicated cases the recovery has been complete.

4. Dislocations Outward.

Most of the displacements reported under this title have been incidental to fracture by eversion and abduction of the foot (Chapter XXV.). But Wendel collected 27 uncomplicated by fracture, grouping them as 19 *pronation* and 8 *eversion* dislocations. Of the 19, 14 were compound. The sole is everted, sometimes looking almost directly upward; the astragalus lies under the internal malleolus, or obliquely across the mortise, or, in compound cases, may be external to the external malleolus. The malleoli are separated. The 5 simple cases were reduced and made good recoveries. Of the 14 compound the tibia projected through the wound in 6; all were reduced, 4 after resection; 1 death.

In four cases, Huguier,¹ Thomas,² Soubie,³ and Knust,⁴ the foot has been so far abducted that the toes pointed directly outward. Wendel collected 8. This form was first observed by Huguier and described by him as "*dislocation of the foot by rotation outward.*" His patient was overthrown by a cask, which rolled upon his legs; Thomas's by a falling mass of straw; Soubie's fell from a height of six feet, alighting upon his left foot, which was then engaged between a large stone and

¹ Huguier: *L'Union Médicale*, 1848, p. 128.

² Thomas: *Revue de Chirurgie*, 1887, p. 821.

³ Soubie: Quoted by Thomas.

⁴ Knust: *Centralblatt für Chirurgie*, 1898, p. 320.

the trunk of a vine while the body was twisted to the right, and the patient fell on his right side ; and Knust's twisted his right foot in like manner, the body turning to the left. In Huguiet's case the external malleolus was separated from the tibia, pressed backward, and rotated outward, and the shaft of the fibula was broken in the upper third. In the other two cases no fracture was found. Reduction was easily effected under anæsthesia in the first three cases ; not mentioned in the fourth.

In January, 1904, I saw at the Hudson Street Hospital a man forty years old who had injured his right ankle by slipping on the sidewalk an hour previously. The foot was abducted nearly 90 degrees, and over the internal malleolus the skin was tightly stretched, and almost the entire articular surface of the tibia could be easily palpated. The fibula was separated from the tibia below and pushed backward by the foot ; it was broken at the middle, without displacement. Reduction was easy by traction and adduction of the foot. Schubert¹ reports two similar cases with fracture of the fibula at the upper end.

5. Dislocation Upward.

In this the astragalus is displaced upward between the malleoli. Wendel collected four cases, but he gives few details and I have been able to consult the original report of only two.² The usual cause was a fall upon the foot ; none was compound ; reduction was easily made, and the result in the three cases in which it was known was good.

6. Compound and Complicated Dislocations of the Foot.

Dislocations of the foot may be compound, primarily or secondarily, with protrusion of the bones of the leg or of the astragalus through the wound, and they may be complicated by rupture of bloodvessels and by other fractures than those of the malleoli already referred to.

In dislocations that are primarily compound the wound of the skin may be made from within outward by the projecting bone or by contact with the ground. In those that become secondarily compound the sloughing of the soft parts may be due to the pressure of the unreduced bones or to bruising of the soft parts inflicted at the time of dislocation.

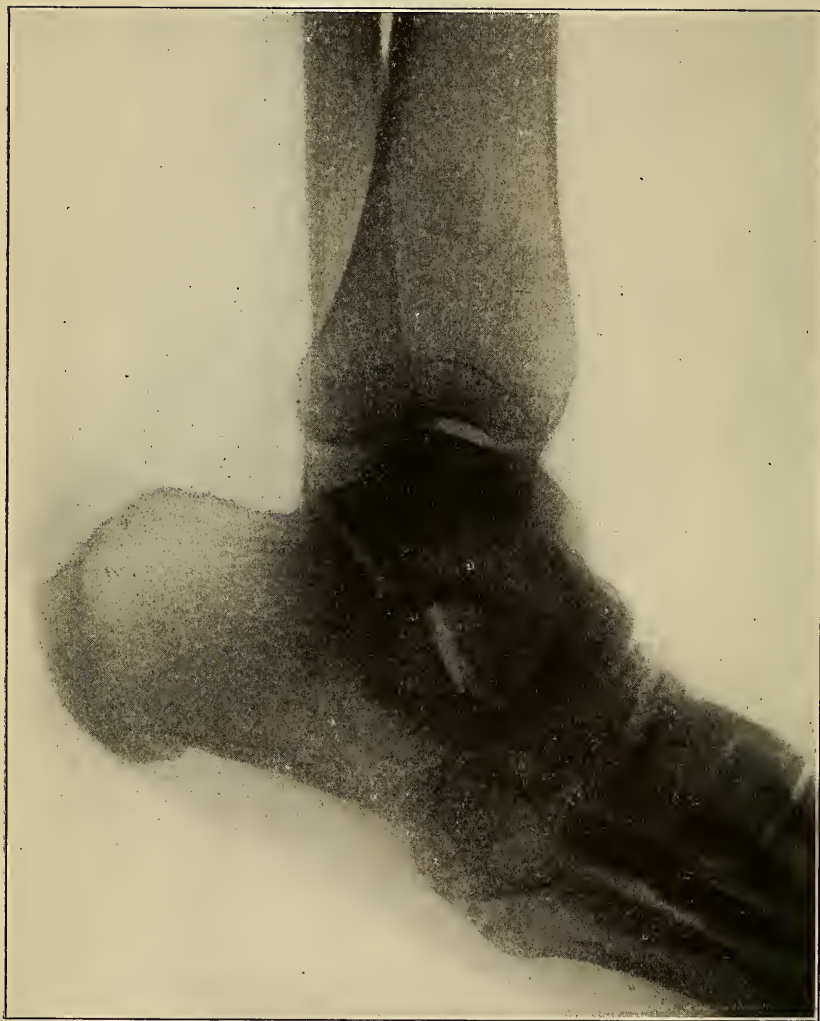Statistics that have been collected from the period anterior to the introduction of antiseptic methods cannot be trusted to show the necessity or desirability of amputation or excision. Later ones (Scudder³) show that conservative treatment may be safely tried in many cases. Amputation or excision is indicated when infection is certain, the patient feeble, or the functional result otherwise likely to be bad. Neither the loss of the astragalus nor ankylosis of the ankle-joint usually causes much disability. Particular attention must be given to drainage, and as the astragalus completely fills the space between

¹ Schubert : *Deutsche Zeitschrift für Chir.*, 1904, vol. lxxii. p. 396.

² *Lancet*, 1856, ii. p. 60.

³ Scudder : *Boston Medical and Surgical Journal*, April 7, 1892.

PLATE LII.



Subastragaloid Dislocation.

the mallcoli separate drainage must be provided for the back and front of the joint.

The limb must be carefully immobilized with the foot at a right angle to the leg and without inversion or eversion, in order that if the joint should become stiff the disability will not be increased by a faulty position of the foot.

SUBASTRAGALOID DISLOCATIONS. DISLOCATION OF THE AS- TRAGALO-CALCANEOID AND THE ASTRAGALO-SCAPHOID JOINTS.

For the establishment of this group in the classification of dislocations of the tarsal bones we are indebted to Broca,¹ who, in a remarkable paper read before the Société de Chirurgie in 1852, carefully analyzed the scattered cases that had been reported under various titles and gave a detailed and systematic description of the various forms of the injury, to which little has since been added except in amplification of the statistics. His plan of subdivision recognized dislocations backward, inward, and outward of the calcaneum and scaphoid from the astragalus. Malgaigne added a fourth variety, dislocations forward, and changed the nomenclature by treating the astragalus as the dislocated bone and applying the terms indicative of the direction of the displacement according to its position with relation to the others. I shall here follow Broca's use of the terms, which is in harmony with that used in the other dislocations.

The dislocation, then, presents four varieties: that in which the calcaneum and scaphoid are displaced inward (and somewhat backward), the head of the astragalus projecting on the outer part of the dorsum of the foot; that in which they are displaced outward; and those in which they are displaced directly forward or backward and downward. The first two are about equal in frequency and together comprise most of the reported cases; of each of the last two only one or two examples have been reported. The most notable addition to the collected statistics has been made by Poinsot.²

1. Dislocations Inward, or Inward and Backward.

The cause is forcible inversion and adduction of the foot, usually combined with violence acting in the direction of the long axis of the leg, as in a fall from a height. The displacement is rarely, if ever, directly inward, but is also somewhat backward, so that the head of the astragalus rests partly upon the cuboid. The only autopsy is one made in an old case by Quénu;³ there was shortening of the dorsum of the foot and elongation of the heel, and the foot was in the position of varus. The head of the astragalus lay upon the interarticular lines between the calcaneum and cuboid and the cuboid and scaphoid, over-

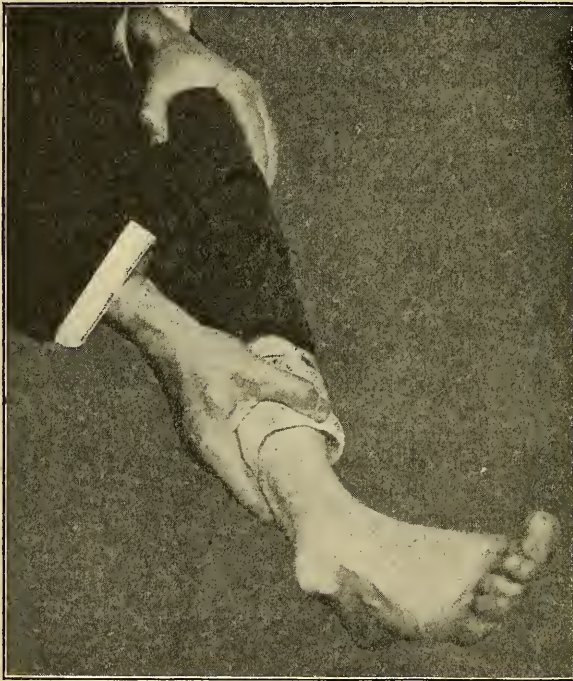
¹ Broca: *Mém. de la Soc. de Chirurgie*, 1852, vol. iii. p. 566, and abstract in *Bull. de la Soc. de Chirurgie*, 1853, vol. iii. p. 241.

² Poinsot: *L'intervention chirurgicale dans les luxations compliquées du cou-de-pied*, Paris, 1877, and his translation of Hamilton's *Fractures and Dislocations*, p. 1196.

³ Quénu: *Progrès Méd.*, 1883, p. 187.

lapping the former half an inch and thus resting on the cuboid. The posterior border of the astragalus lay in the groove between the anterior and posterior superior articular surfaces of the calcaneum, and its posterior lip had been broken off and remained in its normal relations with the calcaneum. There was no fracture of either malleolus. The dorsalis pedis artery and the extensor tendons lay to the inner side of the head of the astragalus; the peroneal tendons had been displaced from their groove and separated half an inch from the fibula. In other cases the displacement has been greater and the skin has been broken on the outer side of the foot; in one of Malgaigne's the head of the astragalus

FIG. 352.



Subastragaloid dislocation inward.

was almost in contact with the fifth metatarsal bone; in one of Letenneur's it corresponded to the outer border of the foot and projected entirely through a wound in the skin, and the calcaneum had been completely displaced from its inferior articular surface. In one of my own the external malleolus protruded through and was tightly grasped by a rent in the skin; evidently perforation had occurred while the foot was in extreme inversion, and I was obliged to lengthen the opening downward for an inch in order to reduce. The patient made a good recovery, with some limitation of inversion (supination) of the foot. The form and degree of the displacement vary with the different combinations of displacement inward, backward, and by adduction of the

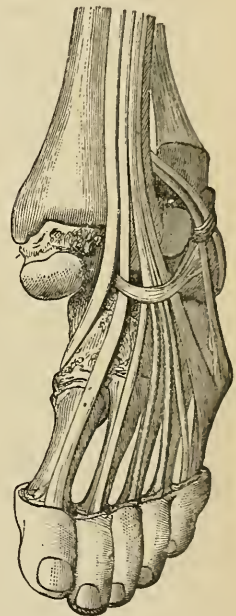
front of the foot, the latter sometimes leaving the posterior part of the calcaneum less displaced inward than its front part. With the dislocation there are sometimes associated injury to the calcaneo-cuboid joint, rupture of its ligaments, and partial dislocation of the bones.

The symptoms are more or less shortening of the dorsum of the foot and lengthening of the heel, adduction of the toes, and elevation of the inner border of the foot; prominence of the tip of the external malleolus and of the head of the astragalus on the outer side of the dorsum, with marked depressibility of the soft parts below each; the internal malleolus is deeply placed under the skin, and below and behind it can be felt the projecting sustentaculum tali, and in front of it the inner surface of the scaphoid.

2. Dislocations Outward.

Of these Malgaigne makes two varieties, distinguished clinically by the existence of marked abduction of the toes in one, and its absence in the other. In the former (his *luxation oblique en dedans*, or *obliquely outward*, according to the nomenclature here used) the posterior articular surface of the astragalus is not separated from the calcaneum, but the foot has turned upon the posterior calcaneo-astragaloid joint, or upon the outer part of the interosseous ligament as a centre, and the scaphoid has been carried to the outer side of the head of the astragalus, and also sometimes either upward or downward. In the second form, that without abduction of the toes, the foot is displaced bodily outward from beneath and in front of the astragalus. The cause in the former is forcible abduction of the foot; in the latter it appears to be either abduction and eversion of the foot, or great violence exerted directly against the inner side of the foot, or the outer side of the lower part of the leg. The dislocation may be primarily or secondarily compound, the wound in the skin corresponding to the head of the astragalus which may project entirely through it. The tendon of the tibialis anticus sometimes lies along the inner and upper part of the neck of the astragalus, which is thus tightly held between it and the calcaneo-scaphoid ligament. In a case of the oblique form quoted by Malgaigne, in which the patient died four days after the accident, the outer part of the interosseous ligament in the sinus tarsi was entire; the inner part was ruptured. In one of the complete outward form, of which the specimen was dissected, and reported by Nélaton¹

FIG. 353.



Subastragaloid dislocation outward. (MALGAIGNE.)

¹ Nélaton: Bull. de la Soc. Anatomique, 1835, p. 33.

(Fig. 353), the head of the astragalus rested against the inner side of the scaphoid, and its posterior lip was engaged in the groove in the upper surface of the calcaneum; the lower part of the internal lateral ligament, the interosseous ligament, and the astragalo-scaphoid ligament were ruptured, and the posterior and outer part of the external malleolus was broken.

The calcaneo-cuboid joint may also be injured, and the bones partly displaced from each other.

The symptoms in the oblique variety are the marked abduction of the foot, more or less eversion, and marked prominence of the head of the astragalus on the inner side; the head is sometimes so depressed that the condition may be mistaken for inward dislocation of the astragalus. In a case reported by Boyer the displacement was slight, and was at first overlooked; when recognized, it was irreducible, but the patient regained good use of the limb.

The symptoms in the variety in which the displacement is directly outward are the marked displacement of the foot, with but little, if any, eversion or abduction, the axis of the leg falling to the inner side, and somewhat in front of the part of the foot to which it normally corresponds. Above the outer surface of the calcaneum and cuboid is a notable depression in the place of the usual prominences formed by the external malleolus and the head of the astragalus. The internal malleolus is very prominent and nearer to the level of the sole, and below and in front of it is the projecting head of the astragalus. On the dorsum of the foot the scaphoid is recognizable with a depression behind it.

3. Dislocation Backward.

In this the calcaneum and scaphoid are displaced directly backward, the scaphoid descending to a lower level so as to lie under the head or neck of the astragalus. Deviation of the foot to either side would create forms intermediate between this and the two preceding ones. A number of reported cases, which were claimed to be subluxations of this kind, the relations between the scaphoid and astragalus being changed while those between the calcaneum and astragalus remained unchanged, were rejected by Broca as errors of diagnosis, but are accepted by Malgaigne as probably correct. In some of them reduction was easy; in others it failed, but the persistence of the displacement did not permanently impair the functions of the limb.

Of the complete form there are only two recorded examples: the first is the much quoted case of Prof. Carmichael, reported by Macdonald.¹ Carmichael, in his effort to avoid a fall when his horse stumbled and came upon his knees, leaned back in the saddle and thrust his feet forward; his weight was received upon the inner side of the ball of the right foot, and the dislocation was thereby produced, the deformity being so great that it was recognizable through his boot. The toes were abducted about 30 degrees, the foot slightly everted; the concavity of the tendo Achillis was manifestly increased and the heel lengthened; the astragalus could not be felt behind the tibia.

¹ Macdonald: Dublin Quarterly Journal Med. Sci., 1838, vol. xiv. p. 235.

Below and in front of the inner malleolus was a hard prominence, over which the skin was tense, formed by the inner surface of the astragalus. The most striking deformity was a prominence on the dorsum of the foot; "immediately in front of the tibia it presented a flat surface broad enough to receive the finger, from which there was an abrupt descent upon the anterior part of the tarsus. Over the projection caused by the head of the astragalus thrown on the upper surface of the scaphoid and cuneiform bones, the integuments were so tense that it was very evident a small additional force would have driven it through the skin." The distance from the internal malleolus to the end of the great toe was one inch less than on the other foot. No fracture could be found. Flexion and extension were very painful. The dislocation was reduced by traction with the pulleys and direct pressure on the heel and leg.

The second case was observed by Thierry, and communicated to Malgaigne by Broca; the dislocation was caused by a fall upon the toes; the head of the astragalus was prominent under the skin, the front of the foot appeared shortened, the heel lengthened; the foot was extended, and not deviated to either side. Good recovery.

An irregular case of subastragaloid dislocation backward and outward in which the scaphoid preserved its relations with the astragalus and the anterior portion of the line of dislocation ran between the scaphoid and cuneiform bones was reported by Kaufmann.¹ The displacement had existed nine months and was then treated by excision of the scaphoid and head of the astragalus with a good result.

4. Dislocation Forward.

Of this only two cases uncomplicated by fracture have been reported, one by Parise, quoted by Malgaigne, the other by Broca.² Plantear's report (*Gaz. Med. de Paris*, 1879, No. 30), sometimes quoted as a third case, is of Broca's. Parise's patient was injured by being crushed under a heavy weight, the thigh being flexed on the trunk, the leg on the thigh, and the foot on the leg (dorsal flexion). Nine months afterward the condition was as follows: the foot was at a right angle with the leg, a little adducted, and very slightly everted; it was displaced forward, so that it appeared lengthened in front, and the external malleolus almost touched the tendo Achillis. The extensor tendons on the instep were tense, and no prominence could be felt beneath them, but on the outer side a bony prominence could be felt, which was thought to be the head of the astragalus, and immediately in front was a depression which admitted the finger. The hollow between the astragalus and calcaneum seemed to be filled. Behind, the prominence of the heel was completely lost, the leg flattened, and its surface interrupted at the level of and a little below the malleoli by a bony prominence which raised the tendo Achillis and overlapped the heel nearly half an inch; above it was another, less prominent, formed by the posterior articular edge of the tibia.

¹ Kaufmann: *Centralblatt für Chir.*, 1888, p. 369.

² Broca: Report by Petit of a clinical lecture, *Gaz. Hebdom.*, 1874, p. 316.

There was no trace of fracture, no separation of the malleoli. There was slight motion in the tibio-tarsal joint; motion in the joints of the tarsus was entirely lost. The patient could hardly walk without crutches.

In Broca's case the displacement was much less marked, and the only symptoms were an increase of one centimetre in the distance from the internal malleolus to the great toe, and a corresponding shortening of the heel, and the absence of abnormal prominence of the astragalus in front of the tibia. By traction and pressure under chloroform the inequality in the measurements was overcome and the patient, at the time of the report, was in a fair way to recover. So far as can be judged from the report, Broca did not consider the diagnosis entirely clear, and the symptoms as given are identical with those of Sarazin's case of incomplete tibio-tarsal dislocation forward. The differential diagnosis between these two injuries would have to be made on the existence of a gap between the astragalus and scaphoid in the subastragaloid dislocation, and the absence of such a gap and possibly the abnormal prominence of the upper articular surface of the astragalus in front of the tibia in the incomplete tibio-tarsal dislocation forward. The recognition of either symptom might be made difficult or impossible by swelling.

Deetz,¹ under the title "subastragaloid dislocation with fracture of the astragalus" reported a case and collected 3 others, and Thienhaus² reported a fifth. In Deetz's case and in one of the three he collected (Günzerich) the fracture was through the neck of the bone, and the anterior fragment, together with the rest of the foot, was displaced forward, so that there was a dislocation of the posterior facet from the calcaneum. But in his remaining two (Sick³ and Mailland⁴) the fracture of the astragalus was horizontal, and the lower fragment was displaced forward from the upper but retained its relation with the rest of the foot, so that the injury was a fracture of the astragalus, not a subastragaloid dislocation. Thienhaus does not describe his fracture, but the skiagram suggests that most if not all of the lower surface went forward with the calcaneum; the external malleolus also was broken. Sick, Mailland, and Deetz reduced, the latter by open operation; Günzerich and Thienhaus removed the astragalus; their cases were old.

Diagnosis of Subastragaloid Dislocations.

If the date of the injury is so recent that swelling has not yet supervened, or so remote that it has disappeared, the diagnosis may usually be made with considerable ease and certainty, but if swelling is present it may be very difficult. The important functional features are the preservation of the normal movements in the tibio-tarsal joint, and the loss or the exaggeration in one or the other direction of the

¹ Deetz: *Deutsche Zeitschrift für Chir.*, vol. lxxiv. p. 581.

² Thienhaus: *Annals of Surg.*, Feb., 1906, p. 295.

³ Sick: *Berl. Klin. Wochenschrift*, 1892, p. 581.

⁴ Mailland: *Gaz. des Hôpitaux*, 1900, p. 1539.

lateral and rotatory movements of the foot which take place in the subastragaloid and medio-tarsal joints. As no lateral motion takes place in the tibio-tarsal joint, except in the position of full plantar flexion, the exaggeration of the normal movement to either side must be due, when the ankle is sound, to injury of the two last-named joints. The physical signs are the preservation of the relations between the astragalus and the bones of the leg, as shown by the normal relations of the malleoli to the head of the astragalus and by the absence of abnormal projection of the body of the astragalus in front or behind the tibia, the changes in length of the front part of the foot and heel, and the change in the relations of the calcaneum and scaphoid with the astragalus and malleoli.

Treatment of Subastragaloid Dislocations.

The statistics collected by Broca and Poinsoot give 23 simple cases in which reduction was attempted; to these may be added Pick's¹ case. Of these 24 reduction was successfully made in 14 and the ultimate result was good; in 2 the reduction was incomplete, and 1 of these died of septicæmia. The 8 failures (excluding the 2 incomplete reductions) gave 4 secondary amputations with 3 deaths, 3 secondary removals of the astragalus with 1 death, and 1 good functional result notwithstanding the persistence of the deformity.

In 7 additional cases in which reduction was not attempted, 4 of the patients (Du Bourg, Dubreuil, Sée, quoted by Poinsoot, and Quénu) had apparently good use of the limb, although in 1 of them sloughing and a violent arthritis followed the accident; in 1, Brown,² reduction was made after six months; in 2 (Sinnigen, quoted by Poinsoot, Raffa³) the disability was such that the patient sought relief; Sinnigen removed the astragalus and external malleolus, and at the time of the report death by septicæmia was expected; Raffa chiselled away the head and the neck of the astragalus and was then able to straighten the foot; recovery without suppuration; good result.

In 2 cases (Verneuil,⁴ Oré, quoted by Poinsoot) primary excision of the astragalus was done, in each with a good result. In Verneuil's there was fracture of the astragalus and rupture of the peroneal artery; in Oré's an attempt to reduce had failed and gangrene of the tense skin was imminent.

Of compound dislocations 17 cases were collected by Broca and 6 additional by Poinsoot in 1884, and to these 1 reported by Jackson⁵ and mine are to be added; of these reduction was made in 11, with 2 deaths, with persistent suppuration apparently maintained by necrosis in 2, and with secondary removal of the astragalus in 1. In 14 reduction was not made; in 3 of these primary amputation was done, in 10 removal of the astragalus, with 2 deaths, and in 1 the head of the astragalus

¹ Pick: *Lancet*, 1880, vol. i. p. 170.

² Brown: *Lancet*, 1876, vol. i. p. 314.

³ Raffa: *Centralblatt für Chir.*, 1885, p. 211.

⁴ Verneuil: *Bull. de la Soc. Anatomique*, 1872, p. 493.

⁵ Jackson: *Lancet*, 1881, ii. p. 590.

became necrosed and was spontaneously cast out, the patient recovering. The results of primary removal of the astragalus according to these statistics are rather better than those of reduction, but, as has been said before, the value of these statistics as a basis for the choice of a method of treatment has been greatly diminished by the improvement in the methods of treatment of open wounds that has taken place in the last few years, and there is good reason to hope that suppuration and its attendant dangers will be less frequent in future.

Reduction, which has sometimes been made by traction with the hands alone, more frequently has needed the aid of pulleys, even when anæsthesia has been employed. The knee should be flexed to relax the muscles of the calf, and the traction in the lateral cases should be downward and usually also forward, and coaptative pressure should be made upon the foot and leg. The cause of the irreducibility in some cases is not entirely clear; it has been attributed to the engagement of the posterior lip of the astragalus in the groove on the upper surface of the calcaneum. In one case of oblique outward dislocation I was obliged to make a longitudinal incision along the head of the astragalus and disengage from beneath it the tendon of the tibialis anticus.

TOTAL DISLOCATION OF THE ASTRAGALUS.

(“*Double Dislocation of the Astragalus.*”)

This dislocation is a combination of the two preceding ones, the tibio-tarsal and the subastragaloid, the astragalus being simultaneously displaced from its normal relations with the bones of the leg, the calcaneum, and the scaphoid. It is much more frequent than either of the other two and is often compound. The astragalus may be displaced forward, backward, or to either side, or to any intermediate position, and may at the same time be rotated about any of its axes, or it may be rotated while remaining in the tibio-fibular mortise. The varieties of dislocation are, consequently, very numerous, but they may be grouped as dislocations *forward, backward, outward and forward, and inward and forward*, these terms indicating the direction in which the astragalus is displaced, and *dislocations by rotation*, including in the latter only those in which the bone remains more or less completely within the mortise.

The causes are varied, the most common being falls from a height upon the feet and violent twisting of the foot, as when it has been caught between the spokes of a wheel. It is seldom possible to determine the exact mode of production in any given case, and experiment upon the cadaver has not done much to elucidate the subject; but it seems probable that dorsal or plantar flexion and abduction or adduction are requisite to rupture the ligaments that bind the astragalus to the other bones, and that then it is forced from its place by pressure exerted through the bones of the leg.

1. Dislocation Forward.

In this form, which is very rare, the astragalus is displaced directly forward. To the briefly described and somewhat doubtful cases collected by Malgaigne, Delorme¹ added only two, in one of which (Morel-Lavallée) the astragalus had been rotated 180 degrees about its vertical axis and both malleoli were broken; the foot was very movable on the astragalus, and the astragalus on the tibia. The sides of the bone could be distinctly felt, and its posterior surface, which looked directly forward. Reduction was easily made. In the other case, Barrall, the dislocation was compound, the head of the astragalus projecting through the wound and resting on the dorsal surface of the scaphoid. Both it and the foot were freely movable. The extensor tendons and that of the tibialis anticus were ruptured, the malleoli and calcaneum were broken.

2. Dislocation Outward and Forward.

In this, the most common form, the head of the astragalus rests on the outer cuneiform and the cuboid or even on the fifth metatarsal, its posterior part lying just within the mortise, and is freely movable; the foot is adducted and inverted and usually displaced bodily inward, so that the external malleolus is prominent and the internal hidden, and sometimes the adduction of the front of the foot is very marked and combined with abduction of the heel. If the dislocation is compound the astragalus presents in the wound, which commonly extends backward to or beyond the external malleolus. The lower end of the fibula may be torn away from the tibia, and either or both malleoli broken. With the displacement may be combined various kinds and degrees of rotation of the astragalus, and sometimes the astragalus is broken.

3. Dislocation Inward and Forward.

In this, the second in order of frequency, the foot is everted and abducted, but sometimes is bodily displaced to the outer side without deviation. The astragalus projects in front of or below the internal malleolus, and its head appears always to be depressed, sometimes so far that the bone must have undergone rotation of 90 degrees about its transverse axis. In a case reported by Hunt² it was so far rotated about its vertical axis that the head was directed toward the middle of the other foot. If the injury is compound the wound lies on the inner side and extends backward below the malleolus. It may be accompanied by fracture of the malleolus.

¹ Delorme: *Dict. de Méd. et Chir. pratiques*, 1879, vol. xxvii. p. 640.

² Hunt: *Philadelphia Medical Times*, 1872, vol. iii. p. 50.

4. Dislocation Inward.

A unique case is reported by Seiler.¹ The astragalus lay directly beneath the internal malleolus and had been so rotated that its lower surface looked inward. A free incision was made and the bone restored to its place. The internal malleolus and sustentaculum tali had been broken. Recovery with good function.

5. Dislocation Backward.

In this form, which also is rare, the astragalus may be displaced backward or backward and to either side, and in some of the reported cases the bone has been broken at the neck and only the posterior fragment has been displaced. Malgaigne² collected 8 cases, including one reported by Denonvilliers, which he places³ among "dislocations by rotation in place," but which, I think, belongs here; the cases are Phillips 2, Lizars, Liston, Turner, Nélaton, *Denonvilliers*, and one anonymously reported in the *Lancet*, 1838-39, vol. ii. p. 559. To these Delorme adds 5—Blatin, *Lejeune*, *MacCormac*, *Pichorel*, and *Cheever*; he also quotes Foucher as having reported two cases, but, I think, erroneously, one of them being Denonvilliers's case, the other Thierry's, a dislocation by rotation. Another case was reported by Munro,⁴ and one by *myself*.⁵ I saw a *second* in May, 1907, and another, *Legros Clark*, is reported in MacCormac's paper, making 17 in all. In the eight printed in italics the bone was broken at the neck, and only the posterior fragment was dislocated.⁶

Of the 9 not complicated by fracture of the astragalus, the dislocation was backward in 6, backward and outward in 1, Turner, and backward and inward in 2, *Lancet*, Munro. Reduction was made in 3 (*Lancet*, Blatin, Munro), and failed in 4, the functional result being good in 3 of the latter; Turner, and apparently Nélaton, removed the astragalus.

Of the 8 complicated by fracture, the displacement in Lejeune's is described as backward, in the others as backward and inward; the difference is slight, for in the latter the most prominent part of the astragalus projects but little beyond the level of the side of the internal malleolus. The tendons of the flexor longus digitorum and tibialis posticus are displaced upon the inner side of the malleolus, and that of the flexor longus pollicis sometimes lies to the outer side of the astragalus and sometimes is pushed directly backward by it. The fragment is also rotated, so that its trochlear surface looks inward, and its fractured surface is directed forward and downward. The line of fracture runs from the anterior border of the trochlea into the groove

¹ Seiler: Correspblt. für Schweiz. Aertze, August 15, 1893.

² Malgaigne: Loc. cit., p. 1058.

³ Malgaigne: Loc. cit., p. 1060.

⁴ Munro: *Lancet*, 1859, vol. ii. p. 364.

⁵ Stimson: *New York Medical Journal*, May 28, 1887, p. 594.

⁶ The following are two of the references: MacCormac (and Clark's case), *Transactions of the Pathological Society of London*, 1875, vol. xxvi. p. 174, with plate of specimen obtained two years later; Cheever, *Boston Medical and Surgical Journal*, 1875, vol. xciii. p. 237.

occupied by the interosseous ligament. In 3, Lejeune, MacCormac, Denonvilliers, the injury was compound; in Cheever's the skin over the astragalus sloughed, but the ulcer soon healed without having exposed the bone.

Reduction was made in none, although Pichorel divided the tendo Achillis, and Cheever successively divided the tendo Achillis, the tibialis anticus and posticus, the flexor longus digitorum, and the flexor longus pollicis at the toe. In three, MacCormac, Clark, Cheever, the patients recovered with good use of the limb; in 1, Pichorel, suppuration followed and the limb was amputated; in 2, Denonvilliers, Stinson, the posterior fragment was removed and both patients died, mine of pneumonia on the ninth day. The result in Lejeune's is not stated.

The astragalus can be felt behind the ankle, either pressing the tendo Achillis backward or lying on one side of it. If the entire bone is displaced the absence of the head from its normal position is shown by the depressibility of the soft parts behind the scaphoid. Marked, incorrigible flexion of the terminal phalanx of the great toe is noted in three of the cases. In mine the tendons of the peroneus longus and brevis were displaced upon the outer side of the external malleolus.

In the three cases in which reduction was made the means employed were traction followed by extension of the foot, traction, direct pressure, and inversion of the foot, and traction and direct pressure; in Munro's case several months elapsed before the patient regained good use of the limb.

6. Dislocation by Rotation.

In this class are not included those numerous cases in which the bone has undergone rotation in connection with displacement from the tibia and fibula, but only those in which it still lies mainly within the mortise.

Two distinct varieties of this class may be made; those in which the bone has been rotated upon its vertical or transverse axis, and also, perhaps, upon the antero-posterior axis, but still remains in great part within the mortise; and those in which the bone still lies almost exactly in its normal position between the malleoli and has undergone only rotation about its antero-posterior axis.

The division between the first variety and that of dislocations forward and inward is rather arbitrary and is perhaps not always to be made clinically, and the three cases collected by Malgaigne differ notably from one another. Barwell,¹ in a valuable paper containing a well-observed and well-reported case of his own and abstracts of all the other alleged cases except Chevallez's, proposes to term the injury dislocation of the foot with version, or with torsion, of the astragalus, applying the term *version* to the cases of rotation about the vertical axis, and *torsion* to those of rotation about the antero-posterior axis. I see no sufficient reason for using the term dislocation of the foot, which has already been employed for another form of injury; and *version* and *torsion* do not in themselves indicate the sense in which they are used, but must be accompanied by a definition.

¹ Barwell: Medico-Chirurgical Transactions, 1883, vol. lxxvi. p. 39.

Malgaigne gives four cases of rotation about the vertical axis, but I have placed one of them, Denonvilliers, among the dislocations backward. To the remaining three Barwell adds two reported by Verebely;¹ in three of them the head of the astragalus lay below the internal malleolus, in one just behind it, and in one just in front of the external malleolus. As they cannot well be grouped I give a summary of each.

Laumonier : The head of the astragalus protruded under the internal malleolus between the tendons of the tibialis posticus and flexor longus digitorum, the trochlea lying transversely in the mortise and forcing apart the tibia and fibula.

Foucher:² The specimen was taken from a subject found in the dissecting-room. The astragalus had been rotated 90 degrees about its vertical axis, the trochlea being still upright in the mortise, and the head below the internal malleolus. The tendon of the tibialis posticus and the posterior tibial artery lay in front of the internal malleolus. The posterior half of the astragalus lay on the calcaneum, the latter bone lying under the external malleolus and displaced forward and outward, and its axis directed forward and inward. The cuboid was partly dislocated downward from the calcaneum. There was no cicatrix; the foot was flattened, the heel shortened.

Thierry : The head of the astragalus projected midway between the internal malleolus and the tendo Achillis, the outer border of the foot was much raised, and it was then seen that the bone was also so turned that its upper surface looked forward and inward, the tibia resting on the internal lateral face of the body of the bone, and the internal border of the trochlea exactly occupied the angle between the internal malleolus and the under surface of the tibia. Amputation; recovery.

Verebely : Male, twenty-nine. Fibula fractured above the malleolus. Under the internal malleolus the skin was very tense; about an inch lower there was a hard bony prominence about half an inch in diameter. Reduction failed. At the end of the third week an abscess was opened, and it was seen that the prominence under the malleolus was the head of the astragalus. After four months' treatment the man could with difficulty put the foot to the ground.

Verebely, second case : Male, forty-five. The foot was at right angles with the leg, the sole looking somewhat inward and upward. "Under the easily distinguishable outer malleolus and in front of it a long projection half an inch in diameter may be plainly felt; this can be moved without much pain backward and forward independently of the other bones. Behind the scaphoid is a considerable hollow." Reduction failed.

Of the second variety, rotation about the antero-posterior axis, Malgaigne gives seven cases, most of which Barwell rejects because of the incompleteness of the description or because the astragalus was more or less displaced from the mortise. Rejecting Boyer's, Smith's, Liston's, and two of Dupuytren's, there still remain Malgaigne's own and

¹ Verebely : Wiener med. Wochenschrift, 1869, vol. xix. pp. 279 and 296.

² Foucher : Bull. de la Société Anatomique, 1854, vol. xxix. p. 388.

one of Dupuytren's; to these are to be added Barwell's and Chevallez's.¹ In all four cases the condition was shown by direct examination: Malgaigne describes a specimen from an old case, Chevallez's patient was killed by the fall that caused the dislocation, and Dupuytren and Barwell excised the astragalus. In Malgaigne's, Chevallez's, and Barwell's the rotation was outward, that is, the upper surface of the trochlea had become external and rested against the inner face of the external malleolus, although in Malgaigne's the rotation was somewhat less than 90 degrees; in Dupuytren's the bone was turned completely upside down, rotation of 180 degrees.

Of Malgaigne's specimen, which is represented in his *Atlas*, Plate XXX., Fig. 5, it is said that the head of the astragalus rested on the scaphoid and cuboid; its trochlea, turned outward, corresponded almost entirely to the inner facet of the fibula, and its inner side lay under the tibia. The rotation, however, was not a complete quarter of a circle, for a portion of the outer side of the body of the astragalus could still be seen partly in contact with the point of the external malleolus and looking downward and outward. There was bony ankylosis between the astragalus and calcaneum, and it was evident that the man had walked only on the outer border of his foot.

In Chevallez's specimen there was subluxation of the head of the astragalus on the scaphoid, the upper surface of the trochlea was turned outward, the calcaneum was broken transversely and its posterior fragment driven up behind the astragalus; the lateral ligaments of the ankle were detached, and the anterior border of the lower end of the tibia was broken.

Dupuytren's patient was a man fifty years old, who had jumped from a ladder, alighting on his heel. There was a large, hard, irregular, and irreducible prominence in front of the tibia and extending to the instep. An incision was made parallel to the axis of the foot, and the head and neck of the astragalus were immediately brought into view. Efforts to remove the bone failed, for the posterior part was grasped and held fast between the tibia and calcaneum. On seeking for the cause of this fixation it was found that the astragalus was turned around in such a way that its upper surface was directed downward, its lower upward, and that the hook-like process at its inferior and posterior part was fixed beneath the tibia so as completely to frustrate our efforts to extract it. The patient did well.

Barwell's patient, a man twenty-eight years old, was injured by the overturning of his wagon. When seen an hour and a half after the accident the foot was greatly inverted, its front somewhat turned in, the heel raised. The inner malleolus was much hidden; beneath it the skin was thrown into two ridges by three deep folds drawn in segments of concentric circles from a centre a little above the malleolus. The outer malleolus projected abnormally, the skin over it was rather tightly drawn. About an inch in front of it and a little below its level was a rounded projection, which also somewhat stretched the skin. An inch and a half up the leg and in front of the fibula was a small

¹ Chevallez: Bull. de la Soc. Anatomique, 1870, vol. xlv. p. 406.

but deep wound. Below and in front of the inner malleolus deep pressure revealed absence of the usual bony substratum, the finger sank into a hollow bounded in front by the tuberosity of the scaphoid, which lay abnormally near the malleolus. The rounded projection in front of the external malleolus could readily be recognized as the head of the astragalus. A little way behind this was a ridge of bone, also evidently a part of the astragalus; it led from the head backward and a little upward, disappearing under the upper part of the malleolus, at the angle between it and the anterior edge of the tibia. This ridge was markedly convex *outward*. The extensor tendons, pressed together, ran in a bundle a little distance inside the rounded projection. The wound communicated with the injury. No fracture could be detected.

It was seen that the relations of the astragalus to the other bones were altered, although it was still within the mortise, but the exact nature of the injury was not recognized. Various attempts were made to reduce, and even the tendo Achillis was divided, but in vain; a moulded splint was applied, and the wound dressed with carbolic acid.

Two days later a semilunar incision was made from the middle of the lower end of the tibia across the head of the astragalus to the tip of the outer malleolus, the flap turned up, and the bone fully exposed. It was a little turned on its vertical axis, the head having moved outward, and 90 degrees on its antero-posterior axis, the trochlea being in contact with the cartilaginous surface of the external malleolus. The inner upper angle of the trochlea fitted closely into the reëntrant angle formed by the external malleolus and the tibia. The bone was not at all displaced forward—that is, it did not protrude abnormally from its socket. The interosseous ligament had been ruptured; the few remaining fibres were divided, and the bone removed. Examination of the cavity failed to show any fracture or detachment of cartilage. The patient made a good recovery, and was discharged nine and a half weeks after the operation.

Treatment of Total Dislocations of the Astragalus.

The statistics, collected by Broca, Dubreuil, and Poincot, show that of 121 cases of dislocations not compound, 43 were successfully reduced, and it is worthy of note that Poincot's list, composed of cases reported between 1864 and 1883, shows 19 reductions in 31 cases, about 60 per cent., and as many of Broca's cases were treated without the aid of anæsthesia it may reasonably be hoped that Poincot's percentage is an indication of the success that will be obtained in the future. Primary extirpation of the astragalus was done in 9 of the 121 cases, with 6 successes, 1 death, and 2 deaths after secondary amputation. Consecutive extirpation was done in 41 cases, with 39 successes and 2 deaths. Of 15 cases in which the dislocation remained unreduced and in which the result is known (excluding those of secondary extirpation) the functional result in 8 was good.

Of 63 compound dislocations, collected by Broca, reduction was made in 9, and of these 9 cases 6 recovered, secondary removal of the

astragalus was done in 2, and 1 died. Poincot adds 2 cases in which reduction was made; 1 was successful, in the other extirpation became necessary.

In 58 compound cases primary removal of the astragalus was done, with 42 successes, 14 deaths, and 2 consecutive amputations followed by death.

For reasons that have been already given, we have the right to expect better results in the future in compound cases, and may feel encouraged to make reduction whenever it is possible. Expectation in irreducible compound dislocations has almost always ended in removal of the astragalus, or amputation, or death, and the cases will probably be very few in which primary removal of the astragalus will not give the patient the most speedy recovery, the least risk, and the most useful limb.

Of 56 simple irreducible dislocations contained in these statistics, suppuration of the joint and sloughing of the skin followed in at least 41, and there is not much reason to suppose that the frequency of this result will be much, if at all, diminished in the future, for the exciting cause—bruising, pressure, and destruction of the blood-supply of the astragalus—will be repeated. It is important, therefore, to determine the proper course to be pursued under such circumstances. In 1884 Dr. McBurney, of New York, successfully reduced a dislocation forward and inward by exposing the head of the astragalus through an incision, and lifting the tendon of the tibialis anticus which tightly embraced the neck of the bone and had prevented reduction; other equally good results have since been obtained by the same means. Primary removal of the astragalus is recommended by Barwell in all cases in which "certain and sufficient but not too persevering, attempts at reduction" have failed, and the facts that four-fifths of the cases left to themselves have ended in suppuration and secondary removal of the astragalus, and that the functional result after removal is good, will be generally accepted as a justification of the advice, but it needs, I think, to be conditioned upon the failure of reduction by arthrotomy.

In short, the plan to be pursued in simple cases is to attempt reduction by traction upon the foot with the hands or pulleys, under anæsthesia, and with the knee flexed, and by direct pressure so applied as first to correct such rotation of the bone as may exist, and then to force it back into place. This failing, expose the bone by incision, and seek to remove the obstacle to reduction and then to reduce; this also failing, remove the astragalus. In cases in which the astragalus is not only dislocated but also broken, I think primary removal is the safest plan, even in cases of backward dislocation of the posterior fragment, although in three such treated without removal the patients recovered with useful limbs.

In compound dislocations reduction is to be sought unless the astragalus is entirely detached or the lacerations are so extensive that suppuration is unavoidable; otherwise, primary removal of the astragalus, or amputation if clearly indicated.

MEDIO-TARSAL DISLOCATION.

In this the dislocation takes place in the medio-tarsal joint, the scaphoid and cuboid being together displaced from the astragalus and calcaneum which preserve their relations to each other and to the bones of the leg. Broca, in the paper above quoted, pointed out that most dislocations previously reported under this title were actually subastragaloid. Partial dislocation of the cuboid from the calcaneum appears to be frequently associated with subastragaloid dislocations, but the cases in which the medio-tarsal joint alone is involved are few. Cases too briefly described to be positively accepted were reported by J. L. Petit, Liston, and Cooper, but more recently four cases have been placed on record in two of which the diagnosis was confirmed at the autopsy. Thomas¹ reported a case in the service of Denonvilliers; the patient's foot had been crushed by the wheel of a cart. The plantar surface was convex, the dorsum so swollen that the bones could not be felt; the foot was shortened, and its anterior portion could be moved laterally, but the movements were painful and accompanied by crepitus. The diagnosis of fracture of the head or neck of the astragalus and rupture of the calcaneo-cuboid ligaments was made. The patient died of erysipelas, and at the autopsy the tibio-tarsal and calcaneo-astragaloid joints were found intact; the head of the astragalus and the cuboid surface of the calcaneum formed a very marked abnormal prominence above the second row of the tarsus; the scaphoid was fractured antero-posteriorly, and its outer fragment projected on the plantar surface; the cuboid was still in contact with the inferior half of the anterior end of the calcaneum; the superior medio-tarsal ligaments were ruptured, and the inferior calcaneo-scaphoid partly detached; the inferior calcaneo-cuboid was unbroken.

Anger's² patient was injured by a fall from a height. There was slight flattening of the arch of the foot, without deviation, and with considerable ecchymotic and inflammatory swelling. He died of erysipelas. At the autopsy the head of the astragalus was found above and in front of the scaphoid, and the cuboid facet of the calcaneum upon the upper surface of the cuboid. The superior calcaneo-scaphoid and internal calcaneo-cuboid ligaments were ruptured and torn from their anterior insertions. It was difficult to reduce the dislocation even after dissection. The only fracture was of the anterior part of the scaphoid, the tubercle of which was almost entirely torn away.

In the third case, Ward,³ the dislocation was old. "The foot presented a remarkably twisted appearance, the anterior part being directed considerably inward, and the inner edge somewhat elevated. The dorsum was shortened one inch. The anterior ends of the calcaneum and astragalus projected distinctly on the dorsum. The external malleolus had been fractured.

In the fourth, Fuhr,⁴ the dislocation was outward. The patient was

¹ Thomas: *Mém. de la Soc. Méd. d'Indre et Loire*, 1887, quoted by Duplay and Delorme.

² B. Anger: *Traité iconographique*, p. 334.

³ Ward: *Transactions of the Pathological Society of London*, 1849-50, p. 254.

⁴ Fuhr: *Münch. med. Woch.*, March 8, 1892.

sixty-six years old and had fallen six feet; the foot was slightly pronated and the projection of the posterior surfaces of the scaphoid and cuboid could be distinctly felt in front of the external malleolus.

CONGENITAL DISLOCATIONS OF THE ANKLE-JOINT.

Kraske³ exhibited at the Ninth Congress of the German Surgical Society two patients, father and son, with congenital dislocation of both ankles, and also the two legs of another child of the same father which had died in infancy and had been similarly affected. The abnormality was a subluxation outward accompanied by, and probably due to, defective development of the fibula. In all three cases the middle and upper part of the fibula was lacking, but in the specimen a small upper epiphysis existed. In the father the lower end of the fibula was only four centimetres long and was obliquely placed, the apex directed outward. The articular surface of the tibia was also oblique, looking downward and outward; the foot was flattened, markedly abducted, and moderately pronated. The legs, compared with the thighs, were abnormally short and slight.

Resection of both ankles had been done upon the son to correct the faulty position of the foot: on the right side the internal malleolus and a comparatively large part of the astragalus had been removed; on the left, the entire lower end of the tibia and a small piece of the astragalus.

Other forms of congenital subluxation belong to the subject of clubfoot.

¹ Kraske: Beilage zum Centralblatt für Chir., 1882, No. 29, p. 85.

CHAPTER LVIII.

DISLOCATIONS OF THE TARSAL AND METATARSAL BONES AND OF THE TOES.

In addition to the dislocations described in the preceding chapter, the bones of the tarsus may be dislocated separately and in various combinations. None of the different kinds has occurred with sufficient frequency to permit systematic grouping and description, and in most of them the exact nature of the injury cannot be said to have been positively established, for the difficulties of the diagnosis upon the living are usually very great and the surgeon is limited to the recognition of the more prominent features. I shall confine the account of them mainly to the enumeration of the different varieties that have been observed, with bibliographical references for the convenience of those who may desire to examine the reports in detail.

Calcaneum. Malgaigne quotes a case in which the calcaneum was bodily displaced to the outer side, but apparently was not entirely separated from the astragalus and scaphoid. Reduction was easy. Also a second, Canton,¹ found upon the cadaver, in which the calcaneum was displaced to the outer side together with the external malleolus; its anterior end lay between the cuboid and scaphoid, almost in contact with the third cuneiform; and the astragalus was rotated inward about 45 degrees.

Scaphoid. The scaphoid has been totally displaced forward in 4 reported cases and inward in two.² In one of the forward cases it was reduced, in another it was extirpated, in the remaining 2 it was unrecognized and remained displaced without serious interference with function. One of the inward dislocations was easily reduced; the other was compound and amputation was done.

The scaphoid has been dislocated forward and outward in connection with the astragalus, the dislocation being compound (Burnett), forward and inward (Rizzoli, quoted by Poincot), upward and backward in conjunction with the first and second cuneiforms and the first two metatarsals and with dislocation of the third metatarsal and fracture of the cuboid (Chassaignac³), upward and inward in conjunction with the first cuneiform (Lonsdale⁴), or with the middle cuneiform (Clarke⁵), or outward, upward, or inward alone (Piédagnel, Walker, R. W. Smith, quoted by Malgaigne, Bryant⁶), or from the cuneiforms only, as seen by Garland⁷ in a case that was compound. In a case reported by

¹ Canton: *Lancet*, 1847, vol. i. p. 505.

² Capellery and Ferron: *Revue de Chir.*, vol. xxxiv. p. 93.

³ Chassaignac: *Bull. de la Soc. de Chir.*, 1861, vol. i. p. 307.

⁴ Lonsdale: *Lancet*, 1857, vol. ii. p. 192.

⁵ Clarke: *London Medical Times*, 1851, vol. iii. p. 233.

⁶ Bryant: *Surgery*, 3d American edition, 1881, p. 813.

⁷ Garland: *Lancet*, 1857, vol. ii. p. 270.

Enos¹ the cuneiform bones and the cuboid were displaced outward from the scaphoid and calcaneum.

Cuboid. The only case of dislocation of the cuboid of which I have knowledge, except in connection with other dislocations as above described, is one reported by Bell,² in which it was displaced upward in connection with the fifth metatarsal by inversion and adduction of the foot. Reduction was made.

Cuneiform Bones. All three cuneiform bones and the second and third have been displaced together, and the first and second have been displaced separately. Isolated dislocations of the first are the most frequent, Lemoine³ collected eleven such cases, to which may be added two observed by Bryant;⁴ the displacement is usually upward and inward, in only one case downward and inward (Fitzgibbon⁵); sometimes the bone is displaced from all the three with which it is normally in contact, sometimes the first metatarsal is displaced with it. The symptoms are flattening of the arch of the foot, prominence of the displaced bone, and a depression at its normal site. In some cases reduction has been easily made; in others the attempt has failed.

The second cuneiform has been separately dislocated upon the dorsum in three cases, Foulker,⁶ Laugier, and Lagarde (quoted by Delorme⁷), the displacement being slight in one and nearly complete in the others, and accompanied in one by other serious injuries of the foot, and followed in another (Foulker) by sloughing of the skin, grave symptoms, and ultimate recovery. In a case of multiple injuries of the foot reported by Lagrange⁸ the second cuneiform was displaced upward from all its connections except that with the scaphoid.

The second and third cuneiforms were displaced together upon the dorsum in a case reported by Key (quoted by Malgaigne); the dislocation, which was incomplete, was caused by direct violence and accompanied by extensive laceration of the skin. The patient died.

All three cuneiforms have been reported displaced together upon the dorsum in several cases, but it does not appear in the histories whether or not they were separated only from the scaphoid or also from the cuboid and metatarsals; in one of them, Bertherand,⁹ they were accompanied by the metatarsals and the dislocation could not be reduced.

DISLOCATIONS OF THE METATARSAL BONES FROM THE TARSUS AND FROM ONE ANOTHER.

Malgaigne collected twenty-one cases of the various dislocations, Hitzig,¹⁰ twenty-nine; Bayer,¹¹ sixty-eight; and Fischer,¹² eighteen of the first metatarsal.

¹ Enos: *New York Journal of Medicine*, 1857, vol. vii. p. 98.

² Bell: *New York Journal of Medicine*, 1859, vol. vii. p. 329.

³ Lemoine: *Revue de Chirurgie*, 1883, vol. iii. p. 118. ⁴ Bryant: *Loc. cit.*, p. 513.

⁵ Fitzgibbon: *Dublin Journal of the Medical Sciences*, 1877, vol. ii. p. 271.

⁶ Foulker: *Lancet*, 1856, vol. ii. p. 283.

⁷ Delorme: *Dict. de Méd. et Chir. prat.* vol. xxvii. art. Pied.

⁸ Lagrange: *Bull. de la Soc. Anatomique*, 1871, p. 180.

⁹ Bertherand: *Bull. de la Soc. de Chir.*, 1856-57, vol. vii. p. 361.

¹⁰ Hitzig: *Berl. klin. Wochenschrift*, 1865, p. 393.

¹¹ Bayer: *Sammlung klin. Vorträge N. F.*, No. 372.

¹² Fischer: *Deutsche Zeitschrift für Chir.*, vol. lxxiv. p. 55.

The first metatarsal is much more frequently dislocated than the others, and the displacement has generally been upward. In one case, Demarquay,¹ the base lay under that of the second metatarsal; and the other end of the bone was also dislocated, compound; Demarquay removed the bone. Fischer saw four such double cases. A frequent cause has been a fall while on a horse, the pressure of the stirrup against the inner and under surface of the bone apparently causing the injury. The symptoms frequently indicate the coexistence of a sprain of neighboring joints. Reduction has always been easy by traction and direct pressure.

Isolated dislocation of the second metatarsal upon the dorsum has been reported in one case, Brault and Belin, quoted by Hitzig; that of the third downward and backward in one, Tufnell;² that of the fourth upon the dorsum in three, Malgaigne, Surmay,³ and Gosselin.⁴

The fourth and fifth metatarsals have been together dislocated upward and inward, Monteggia, and upward and backward, South; both quoted by Malgaigne. The third and fourth, Hartmann, and the first and second, Marit, have been together displaced; both quoted by Delorme.⁵ The first, second, and third were dislocated together upon the dorsum in two cases, Laugier, quoted by Malgaigne, and Wilms, quoted by Hitzig, and downward into the sole in a case reported by Tufnell;⁶ in the latter case the injury was caused by the fall of a horse and was irreducible, but the patient recovered good use of the limb; the later history is recorded in the same journal, 1855, vol. xx. p. 302.

Dislocation of the second, third, and fourth together upon the dorsum was seen by Malgaigne once; the same diagnosis was made by him in another case, but at the autopsy it was found that the fifth was also partly dislocated from the cuboid and that the first together with the internal cuneiform was displaced inward. A case is reported by Favier.⁷

Dislocation of the first four metatarsals have been reported in four cases, Malgaigne, Hitzig, Demarquay,⁸ Ely;⁹ in Malgaigne's the first three were displaced downward, the fourth upward; in Ely's the first inward, the others upward and outward; in the other two the displacement was upward. Malgaigne was able to reduce the fourth, Demarquay the first, and Hitzig all; notwithstanding the persistence of part of the dislocation the two patients had good use of the limb.

All the metatarsal bones may be displaced together upward, inward, downward, or outward; of the latter two forms only one example of each has been reported. Smyly¹⁰ saw all five bones dislocated downward by the fall of a wagon which pressed the heel forward while the toes were fixed; reduction was made. The case of dislocation inward is Kirk's, quoted by Malgaigne, who distrusts the diagnosis.

¹ Demarquay: Bull. de la Soc. de Chir., 1870, vol. x. p. 35.

² Tufnell: Dublin Quarterly Journal of the Medical Sciences, 1855, p. 302.

³ Surmay: Bull. de la Soc. de Chir., 1876, vol. ii. p. 579.

⁴ Gosselin: Gaz. des Hôpitaux, 1876, p. 755.

⁵ Delorme: Dict. de Méd. et Chir., prat. vol. xxvii. art. Pied.

⁶ Tufnell: Dublin Quarterly Journal of the Medical Sciences, 1854, vol. xvii. p. 65.

⁷ Favier: Arch. de Méd. et Pharm. mil., November, 1888.

⁸ Demarquay: Gaz. des Hôpitaux, 1865, p. 534.

⁹ Ely: Annals of Surg., Aug., 1906.

¹⁰ Smyly: Dublin Quarterly Journal of the Medical Sciences, 1854, vol. xvii. p. 317.

Of dislocation **outward** ten cases have been reported: Laugier and Lacombe, quoted by Malgaigne, Tutschek, quoted by Hitzig, Mignot-Danton,¹ Desprès,² and five quoted by Bayer. The interlocking of the base of the second metatarsal between the first and third cuneiform bones must make a lateral dislocation impossible except as secondary to one upward or downward or unless accompanied by fracture; in Laugier's and Desprès's the second metatarsal was broken at its upper end, and in Mignot-Danton's and Lacombe's the third was broken. In four cases reduction was made.

Dislocation **upward** may be complete or incomplete, and sometimes the whole or part of the first cuneiform remains attached to the first metatarsal and is displaced with it. Hitzig collected eleven cases. The most frequent cause is direct violence, but in two cases it was muscular action, the efforts of the patients to avoid falling after having slipped while carrying heavy bundles. The autopsies and the compound cases have shown rupture of the dorsal and of some of the palmar ligaments, rupture and laceration of some of the interosseous ligaments and muscles, fracture of some of the metatarsal bones and occasionally of the cuboid and first cuneiform, and sometimes separation of the first or fifth metatarsal laterally from the others. The metatarsus may remain in line with the rest of the foot or be deviated to either side, and the bases of its bones form a transverse ridge either corresponding exactly to the line of the joints or at a somewhat higher point upon the tarsus. Reduction was made more or less completely in some of the cases; in others it failed, but the patients gradually recovered the use of the limb; in one compound case, Mazot, primary amputation was done.

SUBLUXATION OF THE HEAD OF A METATARSAL BONE.

In the severest form of this affection, first described by Dr. T. G. Morton,³ the head of the fourth metatarsal—less frequently the third—appears to be displaced from its normal relations with the adjoining one on each side, and also with its toes. The most recent paper on the subject, one which contains a full bibliography, is by Jones and Tubby;⁴ the reader is referred to it for the pathology, symptoms, and treatment. It seems appropriate here to refer only to the severe form in which excision of the head of the metatarsal bone or of the entire joint is occasionally necessary for relief.

DISLOCATIONS OF THE TOES.

1. Metatarso-phalangeal Dislocations.

Dislocations of the Great Toe. The most common cause is a fall upon the toe; among the less frequent are the act of kicking, receiving the weight of the body upon the toe alone in going upstairs, and

¹ Mignot-Danton: *Arch. gén. de Méd.*, 1866, vol. ii. p. 405.

² Desprès: *Bull. de la Soc. Anatomique*, 1878.

³ Morton: *Amer. Journ. Med. Sci.*, January, 1876.

⁴ Jones and Tubby: *Metatarsalgia or Morton's Disease*, *Annals of Surgery*, September, 1898.

violence received upon the metatarsus. The injury is frequently compound. The dislocation has been upward, backward, and to one side, the most frequent appearing to be those to the outer side and backward, and secondly those directly backward; the former of these two is almost always compound, with projection of the head of the metatarsal bone through the wound on the inner and lower aspect of the joint. Coexistent sprain or subluxation of the first tarso-metatarsal joint has been occasionally noted. If the lateral displacement is wide the flexor tendon may slip past the head of the metatarsal bone and make reduction impossible except by operation.

Of 14 simple cases collated by Delorme reduction was easily made in 8 and failed in 4; of the compound cases the head of the metatarsal bone was excised in 5, and the entire bone removed in 3; of 14 compound cases in which the attempt to reduce was made, it was successful in 9. The means employed to reduce have been traction and direct pressure upon the base of the phalanx, and arthrotomy in some.

Dislocations of the Other Toes. Dislocation of the four outer, the four inner, or of all five toes together has been reported in several cases, the direction of the displacement being upward and backward or directly outward; in the latter the head of the metatarsal projected through a wound and had to be excised before reduction could be made.

2. Dislocations of the Phalanges.

With one exception, the second phalanx of the third toe, in all the cases that have been reported the dislocation was of the terminal phalanx of the great toe. In one case reduction could not be made; in another, which was compound, a portion of the bone was subsequently cast off.

INDEX TO FRACTURES.

A.

ABSORPTION of bone after fracture, 61,
113
Acetabulum, 308
 rim, 314
Acromion, 211
Age, influence of, on frequency, 20
Allis, relaxation of fascia lata, 335
Ambulatory treatment, 104
Amputation, 109
Anderson, suture of patella, 373
Aneurism after fracture of clavicle, 197
Angle, splint for jaw, 172
Apophyses, separation of, 24
Arrest of growth, 31, 76, 228, 292, 359,
389
Arteries, injuries of, 68, 78
Astragalus, 402
Asymmetry, normal, of limbs, 50
Atlas, 148
Atrophy of limb, 77
 interstitial, 39
Axillary vein, torn, 231
Axis, 148

B.

BAILEY, hæmatomyelia, 146
Barker, suture of patella, 375
Barton's fracture of the radius, 294
Bennett, first metacarpal, 299
Bigelow, neck of femur, 317, 326
Bloodvessels, injury of, 68
Bolton, hæmatomyelia, 146
 neck of femur, 322
Braun, head of femur, 316
Buck's extension, 96, 352
Burrell, fracture of spine, 158

C.

CALCANEUM, 403
Callender, edge of radius, 295
 forearm, 276
Callus, exuberant, 61, 73
 formation of, 57
 painful, 73
 retarding influences upon, 113
 softening of, 76

Callus, weak, 75
Cancer a cause of fracture, 47
Carpal bones, 297
Cartilages, fracture of costal, 188
Causes of fracture, 39
 determining, 40
 muscular action, 41
 predisposing, 39
 acquired tendency, 40
 cancer, 47
 congenital tendency, 40
 disease of nerve-centres, 46
 inherited tendency, 40
 osteomyelitis, 48
 rachitis, 46
 syphilis, 46
Ceci, suture of patella, 377
Chaput, patellar disability, 377
Chest, discoloration of skin by compres-
 sion of, 186
Clavicle, 192
 complications, 196, 200
 etiology, 198
 pathology, 192
 relations to dislocation of shoulder,
 554
 simultaneous fracture of both, 201
 symptoms and course, 199
 treatment, 202
Clinical course, 64
Coccyx, 311
Colles's fracture, 285
Comminuted fractures, 27
Complications of fracture, 67
 early local, 67
 general, 70
 late local, 73
Compound fractures, 31
 treatment, 106
Condylloid process of inferior maxilla,
 167, 168, 172
Coracoid, 213
Coronoid process of inferior maxilla,
 167
 of ulna, 270
Crepitus, 52
Cubitus valgus, 254
 varus, 240, 246, 249, 252
Cuboid, 406
Cuneiform, carpal, 299

D.

- DANDRIDGE, fracture of spine, 157
 Deformity a symptom, 50
 Delirium, 72
 Depressions, 24
 Diagnosis, 50
 Displacements, 35
 Dressings, permanent, 93
 temporary, 87

E.

- EMBOLISM, 77, 120
 fat, 71, 120
 Ensiform appendix, 179
 Epiphysis, separation of, 29
 repair, 63
 Epitrochlea, 249
 Etiology, 39
 Extracapsular, of femur, 318, 323, 337

F.

- FAILURE of union, 64, 112
 etiology, 113
 treatment, 115
 Femoral artery, torn, 349
 vein, torn, 349
 Femur, 315
 absorption of neck, 330
 angle of neck, 316
 fractures at the lower end, 356
 intercondyloid, 356
 of either condyle, 361
 separation of epiphysis, 358
 at the upper end, 315
 of great trochanter, 345
 of small trochanter, 346
 of the head, 316
 of the neck, 316
 bony union after, 328
 causes, 319
 classification, 318
 diagnosis, 336
 excision of head, 344
 fixation of head, 343
 impaction, 326
 inversion in, 327, 333
 pathology, 320
 through the neck, 320
 at base of neck, 323
 separation of epiphysis,
 321
 prognosis, 338
 repair, 328
 symptoms, 332
 treatment, 340
 through great trochanter and
 neck, 344
 of the shaft, 347
 failure of union, 355
 prognosis, 351
 symptoms, 350
 treatment, 352
 in children, 354

- Fenestrated splints, 95
 Fibula, 400
 Fingers, 301
 Fissures, 23
 Fixation, direct, 101
 Foot, 402
 Forearm, 263
 at the elbow, 263
 coronoid process, 270
 head of radius, 272
 neck of radius, 275
 olecranon, 263
 of the shaft, 276
 both bones, 276, 296
 radius, 284
 ulna, 282
 at the wrist, 285
 Colles's, 285
 other than Colles's, 294
 Fractura diacondylica, 248

G.

- GANGRENE, 69
 Glenoid, 216
 Green-stick fractures, 23
 Growth, arrest of, 31, 76, 228, 292, 359,
 389
 exaggeration of, 76
 Gunshot fractures, 33, 108
 Gunstock deformity of elbow, 240, 246,
 249, 252
 Gurlt, statistics, age, 20
 compound fractures, 31
 costal cartilages, 188
 femur, 315
 hyoid, 173
 inferior maxilla, 166
 larynx and trachea, 175
 muscular action, 41
 sternum, 179
 syphilitic, 46
 tumor, 48
 vertebræ, 142, 148, 152-154
 Gutters, wire, 90

H.

- HÆMATOMYELIA, 146, 148
 Heart wound in injury of chest, 180, 184
 Hemorrhage, 68
 Hennequin's splint for arm, 236
 for femur, 342
 Hodgen's splint, 97, 341
 Hudson Street Hospital statistics, com-
 pound fractures, 32
 general, 19
 humerus, 242, 249
 season, 21
 Humerus, 217
 lower end, 242
 above the condyles, 244
 articular process, 259
 capitellum, 259
 development of epiphysis, 243,
 258

- Humerus, lower end, diagnosis, 261
 epitrochlea, 249
 external condyle, 253
 epicondyle, 251
 intercondyloid fracture, 256
 internal condyle, 251
 separation of epiphysis, 258
 trochlea, 261
 treatment, 262
 shaft, 238
 upper end, 217
 anatomical neck and tuberosities, 218
 head, 218
 separation of epiphysis, 225
 surgical neck, 229
 symptoms, 232
 treatment, 234
 tuberosities, 222
- Hutchinson, arrest of growth of leg, 389
 epiphysis of humerus, 225
 trochanter minor, 346
- Hyoid bone, 173
- I.**
- ILIUM, 312
 Immobilization of joints, 104
 Incomplete fractures, 23
 Inherited tendency to fracture, 40
 Interdental splint, 171
 Intra-articular fracture, 30
 repair of, 62
 Intra-capsular, of femur, 318, 320, 336
 Intra-uterine, 48
 Ischæmic contraction, 69
 Ischium, 313
 Iterative fracture, 76
- J.**
- JOINTS, management of, 104
 stiffness of, 76
 Jugular vein, torn in fracture of clavicle, 197
- K.**
- KING, neck of femur, 317
 Kingsley, interdental splint, 171
 Kocher, anatomical neck of humerus, 219
 capitellum, 259
 epiphysis of humerus, 228
 external condyle, 255
 femoral neck, 318, 344
 upper epiphysis, 322
 König, neck of femur, 344
- L.**
- LANE, fracture of acromion, 208
 of coracoid, 213
 of first rib, 183
 Larynx, 175
 Leg, fractures of, 379
 fibula, 400
- Leg, lower end, 386
 by eversion, 389
 by inversion, 397
 comminuted, 387
 anterior portion of tibia, 399
 posterior portion of tibia, 398
 separation of epiphysis of fibula, 401
 of tibia, 388
 supramalleolar, 387
 shaft, 382
 upper end, 379
 epiphysis of fibula, 400
 of tibia, 377
 spine of tibia, 381
 tubercle of tibia, 382
- Liability, inherited, 40
 Ligamentum patellæ, retraction, 361
 detachment, 374
 Loew, statistics of prognosis, 121
 Longitudinal fractures, 26
 Lotzbeck, fracture of coronoid, 271
 Lucas-Championnière, massage, 102
 Lumbar puncture in diagnosis, 137
 Lung, hernia of, 186, 189, 524
 injured, in fracture of clavicle, 198
 of ribs, 184
- M.**
- MALAR bone, 162
 Malgaigne's hooks, 373
 Malgaigne, statistics, age, 20
 femur, 315
 hyoid, 173
 metacarpus, 299
 Marsh, fracture of first rib, 183
 Massage, 101
 Mayor's scarf for clavicle, 204
 Maxilla, inferior, 166
 condyloid process, 167, 168, 172
 coronoid process, 167
 treatment, 169
 superior, 164
 McBurney, epiphysis of femur, 358
 Metacarpal bones, 299
 Metatarsal bones, 406
 Middeldorpf's triangle, 237
 Mobility, abnormal, 51
 return of, 115
 Moore, epiphysis of humerus, 229
 Moulded splints, 91
 Multiple fractures, 31
 Mumford, compound fractures, 33
 Muscles, atrophy of, 77
 degeneration of, 69
 Muscular action a cause of fracture, 41
 Musculo-spiral nerve, 74, 231, 241, 245
- N.**
- NECROSIS, 61
 Nervè disease a cause of fracture, 46
 inclusion in callus, 75
 injury of, 74, 197
 Nose, 160

O.

OBLIQUE fractures, 25
 Olecranon, 263
 Osteomyelitis, a cause, 48
 Os innominatum, 305
 magnum, 299.

P.

PAIN a symptom, 53
 Paralysis a result of fracture, 74
 its effect on repair, 114
 Parkhill's clamp, 101
 Patella, 363
 causes, 363
 course and terminations, 366
 disability after fracture, 367, 377
 pathology, 364
 refracture, 369, 377
 symptoms, 366
 treatment, 369
 non-operative, 370
 operative, 374
 Pathological fractures, 44
 Pathology of fracture, 22
 Pelvis, 303
 acetabulum, 308, 314
 coccyx, 311
 course, 309
 diagnosis, 309
 double vertical fracture, 306
 ilium, 312
 ischium, 313
 lateral portion of ring, 306
 pubic portion of ring, 306
 pubis, 313
 separation in front and behind, 305
 of all three joints, 305
 of pubic symphysis, 304
 of sacro-iliac symphysis, 305
 Periosteal bridge, 37, 58
 fringe, 361
 Periosteum, extent of injury, 57
 share in repair, 58
 Phalanges of hand, 301
 Pisiform, 299
 Plane, double inclined, 98
 Plaster of Paris, 92, 94
 Pneumonia, 72
 Poland, epiphysis of femur, 323, 359
 of fibula, 401
 of humerus, 258
 of tibia, 381
 separation of epiphysis, 29
 trochanter, 346
 Pott's fracture at ankle, 389
 Pouteau, fracture of radius, 285
 Prognosis, general, 120
 Pseudarthrosis, 112
 causes, 112, 113
 symptoms, 115
 treatment, 115
 Pubis, 313

R.

RACHITIS, a cause, 46
 Radius, Colles's fracture, 285
 fractures at wrist other than Colles's,
 294
 longitudinal, 296
 of head and neck, 272, 275
 of shaft, 284
 styloid process, 296
 Reduction, 80
 Repair, 57
 of cartilage, 62, 190
 opposing influences, 113
 Retention, 85
 Rheumatism, a cause, 46
 Ribs, 183
 Riedel, head of femur, 316
 Roberts, fracture of radius, 296
 Robson, suture of patella, 373

S.

SACRO-ILIAC, synchondrosis, 305
 Sacrum, transverse fracture, 310
 vertical fracture, 306
 Sarcoma after fracture, 74
 Sayre, dressing for clavicle, 205
 Scaphoid, carpal, 297
 tarsal, 406
 Scapula, 208
 acromion, 211
 body, 208
 coracoid process, 213
 glenoid cavity, 216
 inferior angle, 210
 neck, 214
 spine, 211
 upper angle, 211
 Schanz, old, of patella, 378
 Season, influence of, 21
 Secondary fracture, 76
 Semilunar, 299
 Senn, fracture of neck of femur, 341
 Separation of epiphysis, 29
 Septicæmia, 70
 Shaffer, fracture of neck of femur, 342
 Skin, injury of, 67
 stained by compression of chest, 186
 Skull, 123
 mechanism and pathology, 124
 pathological and reparative processes,
 132
 symptoms and treatment, 133
 circumscribed, of vault, 134
 fissured, with brain injury, 136
 internal table, 130, 138
 perforation of base, 140
 rupture of middle meningeal, 139
 Smith's anterior splint, 90
 Smith, R. W., neck of femur, 327
 humerus, 221
 Spine, 142. (*See* *Vertebræ.*)
 Spiral fractures, 26
 Splinters, vitality of, 60

- Splints, 87
 long side, 98
 plaster-of-Paris, 92
 suspended, 90
- Spontaneous fractures, 44
- Statistics, compound fractures, 33, 110
 delayed union, 112
 epiphyses, 29
 general, 19, 121
 influence of age, 20
 season, 21
 syphilis, 46
 tumor, 47
 muscular action, 42
 prognosis, 121
- Sternum, 177
- Stiffness of joints, 76
- Stocking splint, 93
- Stromeyer's cushion, 241
- Subclavian vein, torn in fracture of
 clavicle, 197
- Subjective symptoms, 53
 history, 54
 loss of function, 53
 pain, 53
- Suppuration after fracture, 70
- Supracondyloid of humerus, 244
- Supramalleolar fracture, 387
- Suspended splints, 90
- Sustentaculum tali, 404, 830
- Suture of bones, 100
- Symptoms, 50
 objective signs, 50
 abnormal mobility, 51
 crepitus, 52
 deformity, 50
- Syphilis, a cause, 46
- T.**
- TETANUS, 72
- Thomas, head of radius, 272
- Thorburn, fracture of spine, 158
- Thrombosis, 68, 77
- Thyroid extract in delayed union, 116
- Tibia, 379. (*See Leg.*)
- Tibial artery, torn, 384
- Toes, 407
- Trachea, 176
- Traction by suspension, 97, 352
 by weight and pulley, 96
 continuous, 96
- Transverse fractures, 25
- Treatment, 80
 ambulatory, 102
 by amputation, 109
- Treatment of compound fractures, 106
 articular, 110
 of gunshot fractures, 108
 of pseudarthrosis, 115
 of vicious union, 116
- Trochanter major, 344, 345
 minor, 346
- U.**
- ULNA, coronoid process, 270
 olecranon, 263
 shaft, 282
 styloid process, 296
- Ulnar nerve, injury of, 250
- Union, deformed or faulty, 117
 delayed, or failure of, 112
 fibrous, 112
- V.**
- V-SHAPED fractures, 26
- Varieties, 22
 of direction, 25
 of seat, 29
- Velpeau, dressing for clavicle, 205
- Vertebræ, 142
 course and terminations, 153
 etiology, 146
 pathology, 143
 arches, 144
 bodies, 143
 cord, 145
 processes, 144
 symptoms, 146
 atlas and axis, 148
 lower cervical and upper dorsal, 150
 dorsal and upper lumbar, 152
 lumbar, 153
 treatment, 156
- Vertical suspension, 98, 354
- Volkman's foot-rest, 97
 ischæmic contraction, 69
 splint, 89
 suture of patella, 377
- Von Bergmann, of orbital plate, 130
 old fracture of patella, 378
- W.**
- WEED'S splint, 99
- Whitman, femoral neck, 316, 341
 upper epiphysis, 323
- Z.**
- ZYGOMA, 162

INDEX TO DISLOCATIONS.

A.

- ACCIDENTS during reduction, 452, 455
 Acetabulum, fracture of edge, 733
 of floor, 762
 Acromion, fracture of, 558, 599
 After-treatment, 453
 Age, influence of, 415
 Ambi, 447
 Anæsthesia, dangers of, 445
 Aneurism after dislocation, 423
 Angot, congenital, 470
 Ankle, congenital dislocations of, 837
 dislocations at or near, 814
 Annandale, recurrent, of jaw, 491
 meniscus, of knee, 791
 Anterior oblique dislocation of hip, 738
 Arteries injured in dislocation, 422
 in reduction, 452, 457
 Arthrotoomy to reduce, 451
 Astragalus, dislocation of, 815
 "total" dislocation of, 828
 Atlas, dislocation of, 505
 Axillary artery, injured in dislocation,
 423
 in reduction, 452, 459

B.

- BARWELL, astragalus, 831
 Bayer, metatarsus, 839
 Bigelow, hip, classification, 725
 reduction, 443, 741, 748
 Bissel-Hagen, congenital, of patella, 807
 Blasius, vertebræ, 492, 497, 501, 515
 Bloodvessels injured during reduction,
 457
 in dislocation, 422
 Bone, overgrowth after dislocation, 433
 Brachial artery, injured in dislocation,
 424
 in reduction, 458
 plexus, torn in reduction, 464
 injured, 600
 Brachialis anticus, ossified, 626
 Bradford, congenital, of hip, 479
 Broca, subastragaloid, 821
 suppuration, 467
 Burrell, recurrent, of shoulder, 606
 Busch, obstacles to reduction, 443

C.

- CALCANEUM, dislocation of, 838
 Caldwell, rupture of circumflex, 458
 Capsule, an obstacle, 444
 lesions of, 420
 Carpal bones, dislocation of, 692, 694
 Carpo-metacarpal dislocations, 699
 Causes, determining, 417
 predisposing, 416
 Cheesman, patella, 806
 Circumflex artery, injured in dislocation,
 423, 459
 nerve, injured in dislocation, 425,
 599
 Clavicle, dislocations of, 528
 acromial end, 536
 subacromial, 542
 subcoracoid, 545
 supra-acromial, 537
 both ends, 545
 sternal end, 528
 backward, 532
 forward, 529
 habitual, 531, 532
 upward, 534
 Coccyx, dislocations of, 715
 Complications (*see also* Special Disloca-
 tions), 421
 of bloodvessels, 422
 of bones, 421
 of nerves, 424
 of soft parts and skin, 427
 of viscera, 427
 Compound dislocations, 427
 Congenital dislocations (*see also* Special
 Dislocations), 469
 etiology, 470
 pathology at hip, 474
 at shoulder, 477
 statistics, 469
 symptoms, 477
 treatment, 479
 Consecutive reduction, 443
 Coracoid process, fracture of, 599
 Coronoid process of ulna, fracture of, 624,
 638, 647
 Costal cartilages, dislocations of, 524
 Course, 441
 Cras, injuries of vessels, 458

Crural nerve, pressed on in dislocation, 427
 Cuboid, dislocation, 839
 Cuneiform bones, dislocation of, 839

D.

DEATH by anæsthetic, 445, 468
 sudden, after reduction, 468
 Definitions, 411
 Degeneration after dislocation, 427, 434
 Després, method of, 449
 old, of shoulder, 609
 Diagnosis, 436
 Distention, dislocation by, 484
 Divergent dislocation of radius and ulna, 645
 Dollinger, congenital, of hip, 473
 Dörfler, radius, with fracture of ulna, 668
 Dorsal dislocations of the hip, 729
 Dubreuil, habitual dislocation, 454
 Duchenne, paralytic, of shoulder, 616
 Duverney, radius, by elongation, 663

E.

ELASTIC traction, 450
 Elbow, anatomy of, 617
 dislocations of (*see also* Radius and Ulna), 617
 backward dislocations, 620
 after-treatment, 630
 complications, 424, 425, 623
 diagnosis, 625
 pathology, 622
 prognosis, 626
 symptoms, 624
 theories of production, 620
 treatment, 627
 classification, 619
 congenital and pathological, 675
 divergent dislocation of radius and ulna, 645
 forward dislocations, 641
 fracture during reduction, 465
 frequency, 619
 injury of nerves in, 425, 624, 636
 of vessels in, 424
 isolated, of radius, 653
 of ulna, 649
 lateral dislocations, 630
 complete outward, 637
 subepicondylar, 640
 supra-epicondylar, 640
 incomplete, 631
 inward, 632
 outward, 633
 old unreduced, treatment, 670
 relations to dislocations of shoulder and fracture of clavicle, 552
 Embolism, fat, 468
 fatal, 468
 Emphysema during reduction of shoulder, 456, 463
 Engel, operation in old, 770

Ensiform process, dislocation of, 522
 Epitrochlea, fracture of, 622, 635, 644, 646, 672
 Erecta, luxatio, 582
 Etiology, 416
 Everted dorsal dislocation of hip, 736

F.

FARABEUF, anatomy of shoulder, 549
 reduction of shoulder, 575
 subtricipital, 583
 thumb, 704
 Fat embolism, 468
 Femoral artery, injured, 424, 763
 vein, injured, 763
 Femur, fracture of head, 733, 764
 of neck, 733, 753, 764
 of shaft, 747, 765
 Fibula, dislocations of, 810
 lower end, 812
 spontaneous and pathological, 812
 upper end, 810
 Fingers, dislocations of, 704
 distal phalanges, 712
 metacarpo-phalangeal, 710
 of middle phalanges, 711
 Fischer, first metatarsal, 839
 Flaubert, rupture of brachial plexus, 456, 463
 Flower, classification, shoulder, 554
 Foot, dislocations of, 815
 backward, 815
 compound, 820
 congenital, 837
 forward, 817
 inward, 818
 outward, 819
 upward, 820
 Forearm, avulsion of, 457
 Fracture as a complication, 421
 during reduction, 465

G.

GANGRENE, 430, 466
 Gellé, obstacles to reduction, 443, 741
 Glenoid fossa, fracture of, 599
 Grawitz, congenital, of hip, 473
 Greiner, radius, with fracture of ulna, 668
 Guérin, avulsion of forearm, 457
 Gunn, obstacles to reduction, 443, 741

H.

HABITUAL dislocations, 418, 454
 of hip, 768
 of shoulder, 419, 429, 603
 treatment, 454
 Hæmatomyelia, 146, 148, 498
 Hahn, lateral, of elbow, 631
 Harris, operation in old, 770
 Hibon, congenital, of knee, 470
 Hip, anatomy of, 718
 dislocations of, 718-774

Hip, dislocations of, accidents in reduction, 767
 alter-treatment, 768
 backward dislocations, 728
 anterior oblique, 738
 dorsal, 729
 pathology, 730
 symptoms, 733
 everted dorsal, 736
 treatment, 740
 classification, 724
 complications, 763
 compound, 722
 congenital, 474
 directly upward, 756
 downward and inward, 745
 obturator, 745
 perineal, 750
 on tuberosity of ischium, 760
 fracture during reduction, 767
 of acetabulum, 762
 of femur, 733, 747, 764, 765
 habitual dislocations, 768
 ileo-pectineal, 751
 infracotyloid, 760
 injury of nerves in, 465, 753, 764
 of vessels in, 424, 763
 intrapelvic, 751
 labrum cartilagineum, detachment of, 766
 old dislocations, treatment of, 770
 arthrotomy, 770
 excision, 771
 osteotomy, 771
 paralytic dislocations, 772
 pathological dislocations, 772
 prognosis, 768
 simultaneous, of both hips, 766
 spontaneous dislocations, 772
 statistics, 721
 subspinous, 756
 supracotyloidea, 756
 suprapubic, 751
 through acetabulum, 308, 761
 upward, 756
 and forward (suprapubic), 751
 Hitzig, metatarsus, 839
 Hönigschmied, tibio-tarsal, 815
 Hudson Street Hospital statistics, 413
 Hueter, outward, elbow, 635
 Humphry, congenital, of radius, 473, 676
 Hutchinson, suppuration, 466
 vertebræ, 500

I.

ILEO-PECTINEAL dislocation of hip, 751
 India-rubber, traction by, 450
 Infracotyloid dislocation of hip, 760
 Internal derangement of knee, 789
 Intracoracoid dislocation of shoulder, 565
 Intrapelvic dislocation of hip, 751
 Irregular dislocations, 444
 Isenmeyer, pathological, of patella, 808

J.

JAW, dislocation of lower, 485
 backward, with fracture, 485
 congenital, 491
 forward, 486
 outward, 486
 pathological, 491
 upward, 485
 Jössel, recurrent, of shoulder, 429
 subglenoid, 581

K.

KAMMERER, fracture of femur, 766
 Knee, dislocations of, 775
 antero-lateral, 786
 backward, 781
 by rotation, 786
 congenital, 470, 792
 forward, 787
 injuries of nerves in, 778
 of vessels in, 423, 778
 lateral, 783
 inward, 785
 outward, 783
 spontaneous and pathological, 794
 statistics, 776
 internal derangement, 789
 semilunar cartilages, 789
 Kocher on reduction of hip, 742, 749, 756
 of shoulder, 573
 Körte, injuries of vessels, 458
 Krönlein, congenital, 469, 470
 statistics, congenital, 470
 elbow, 619
 general, 414
 Küttner, patella, 806

L.

LABRUM cartilagineum, detachment of, 766
 Lannelongue, patella, 807
 Löbker, habitual, of shoulder, 604
 radius, 659
 Lorenz, congenital, of hip, 480
 Lung, hernia of, 186, 189, 524

M.

MADLUNG, spontaneous, of wrist, 688
 Maligne, classification, hip, 725
 shoulder, 553
 radius, with fracture of ulna, 668
 Manipulation, reduction by, 449
 at hip, 740
 at shoulder, 573
 Marchand, accidents in reduction, 446, 458
 Markoe, fracture of humerus, 465
 McBurney's hook, 598
 Mears, old, of shoulder, 609
 Median nerve, injury of, 425, 624
 Medio-carpal dislocations, 692

Medio-tarsal dislocations, 836
 Metacarpal bones, 699
 Metacarpo-phalangeal dislocations of
 fingers, 710
 of thumb, 704
 Metatarsal bones, dislocations of, 839
 subluxation of head, 841
 Metatarso-phalangeal dislocations, 841
 Meyer, patella, 797
 Morton, metatarsalgia, 841
 Muscles torn during reduction, 457
 Muscular action a cause of dislocation,
 417
 Musculo-spiral nerve torn, 624, 669
 Myers, congenital, of hip, 479
 Myopathic dislocations, 483
 Myositis ossificans, 626

N.

NERVES, injured, 424, 460, 463, 583, 599,
 624, 779
 Newman, patella, 806
 Nicoladoni, old, of elbow, 672

O.

OBSTETRICAL paralysis, 615
 Obturator dislocation, 745
 Occiput, dislocation of, 503
 Edema, persistent, 435, 467
 Old dislocations, pathology, 431
 treatment, 451
 Olecranon, fracture of, 623, 642
 Os magnum, dislocation of, 697, 698

P.

PACI, congenital, of hip, 480
 Paralysis after dislocation of shoulder,
 425, 464, 603
 Paralytic dislocations, 483
 of hip, 772
 of shoulder, 615
 Parker, radio-carpal, 682
 Patella, dislocations of, 796
 complete reversal, 805
 congenital, 807
 downward with rotation, 806
 edgewise or vertical, 803, 805
 habitual or pathological, 808
 inward, 803
 outward, 799
 Pathological dislocations, 481
 Pathology of old dislocations, 431
 of recent dislocations, 420
 Pelvis, dislocations of, 715
 Pendel-methode, at shoulder, 570
 Perineal dislocations, 750
 Petit, principle of reduction, 448
 Phalanges of foot, dislocations of, 842
 of hand, dislocations of, 704
 distal, 712
 middle, 711
 proximal, 704, 710

Pingaud, radius, by elongation, 665
 Pisiform, dislocations of, 696
 Poincot, subastragaloid, 821
 Popliteal artery torn, 424
 Pouteau on reduction of hip, 448
 Prah, statistics of hip, 721
 Priapism in spinal injury, 501
 Prognosis, 441
 Pubic, of hip, 751

R.

RADIO-CARPAL dislocations, 681
 backward, 683
 congenital, 691
 forward, 685
 outward, 687
 pathological, 687
 subluxation, 687
 Radio-ulnar joint, lower, 679
 backward, 679
 forward, 680
 inward and downward, 681
 Radius, head broken, 624
 isolated dislocations of, 653
 backward, 654
 by elongation, 663
 forward, 660
 outward, 657
 pathological and congenital, 473,
 477, 675
 with fracture of ulna, 668
 Recurrent dislocations, 418
 Reduction, 443
 accidents during, 452, 455
 by manipulation, 449
 consecutive, 443
 methods of, 446
 obstacles to, 443
 spontaneous, 443
 Repair, 428
 Retro-axillary dislocation, 589
 Rheumatism, dislocation in, 482
 Ribs, broken, 427
 dislocations of, 523
 Ricard, habitual, of shoulder, 603
 Rutherford, patella, 806

S.

SCAPHOID, dislocations of carpal, 694
 of tarsal, 838
 Schinzinger, reduction of shoulder, 576
 Schrötter, radius alone, 659
 Sciatic nerve, pressure upon, 733, 764
 Scudder, compound, of foot, 820
 congenital, of shoulder, 610
 Semilunar bone, dislocation of, 695
 cartilages, dislocation of, 789
 Servier, radio-carpal, 682
 Shoulder, anatomy of, 547
 dislocations of, 547-616
 anterior, 557
 after-treatment, 577, 602
 of old, 607

- Shoulder, dislocations of, anterior, by
 muscular action, 418
 intra-coracoid, 565
 subcoracoid, 558
 pathology, 560
 symptoms, 563
 treatment, 567
 accidents during, 452, 455
 by manipulation, 573
 Kocher, 573
 Schinzinger, 576
 direct reposition, 569
 heel in axilla, 572
 traction downward, 569
 upward, 570
 with leverage, 572
 classification, 552
 complications, 595
 fracture of acromion, 558, 599
 of coracoid, 594, 599
 of glenoid fossa, 599
 of neck, 596
 of shaft, 599
 of tuberosity, 586, 596
 injury of nerves, 425, 463, 599
 of vessels, 424, 457
 compound dislocations, 600
 congenital dislocations, 477, 610
 downward dislocations, 579
 luxatio erecta, 582
 subglenoid, 579
 subtricipital, 583
 habitual dislocations, 419, 429, 603
 injury of nerves in, 425, 463, 599
 of vessels in, 424, 457
 old dislocations, treatment, 607
 arthrotomy, 608
 excision, 609
 fracture, 609
 osteotomy, 609
 subcutaneous section, 608
 paralytic dislocations, 616
 pathological, 614
 posterior dislocations, 584
 symptoms, 588
 treatment, 589
 prognosis, 602
 recurrent, 419, 429, 603
 relation to other injuries, 554
 retro-axillary, 581
 simultaneous, of both shoulders,
 585, 591, 601
 statistics, 551
 subacromial, 584
 subluxation, 614
 subspinous, 584
 upward (supracoracoid), 590
 Skin torn during reduction, 456
 Smith, Nathan, on manipulation, 449,
 740
 Smith, R. W., congenital, of shoulder, 610
 Souchon, old dislocations of shoulder, 598
 Spinal column (*see* Vertebrae), 494
 Spontaneous dislocations, 481
 reduction, 443
 Sprengel, lateral, elbow, 631
 Statistics, congenital, 469, 470
 death by anæsthetic, 446
 general, 413, 414
 influence of age, 415
 of paralysis, 425
 injury of vessels, 457, 463
 Sternum, dislocations of body, 518
 of ensiform process, 522
 Streubel, lateral, elbow, 631
 obstacles to reduction, 443
 patella, 797
 radius alone, 655
 by elongation, 664
 Subacromial dislocation of clavicle, 542
 of shoulder, 584
 Subastragaloid dislocations, 821
 Subclavicular dislocation, 565
 Subcoracoid dislocation of clavicle, 545
 of shoulder, 558
 Subepicondylar dislocation, 640
 Subglenoid dislocation, 579
 Subscapular artery torn, 459, 460, 581
 Subspinous dislocation of hip, 756
 of shoulder, 584
 Subtricipital dislocation, 583
 Suppuration, 427, 446, 466, 499, 767
 Supra-acromial dislocation of clavicle,
 537
 Supracoracoid dislocation of shoulder,
 590
 Supracotyloid dislocation of hip, 756
 Supra-epicondylar dislocation, 640
 Suprapubic dislocation, 751
 Sus-cotyloidienne dislocation, 751
 Symptoms, 436
 Syncope, 468
- T.**
- TARSAL bones, dislocation of, 838
 Thumb, dislocations of, 704
 backward, 705
 forward, 708
 lateral, 709
 distal phalanx, 712
 proximal phalanx, 704
 Thyroid dislocation, 745
 Tibio-tarsal dislocation, 815
 Tillmanns, lower radio-ular, 679
 radio-carpal, 682
 Toes, dislocation of, 841
 Traction by gravity, 451
 elastic, 450
 Trapezium, dislocation of, 698
 Trapezoid, dislocation of, 698
 Treatment, 443
 Trendelenburg, old, of elbow, 672
 Tuberosity of humerus, broken, 586, 587,
 596
- U.**
- ULNA, fracture with dislocation of radius,
 668
 isolated dislocation of, 649

Ulna, isolated dislocation of, backward,
650
forward, 653
inward, 653
Ulnar artery torn, 425
nerve injured, 425, 635, 643
Unciform, dislocation of, 696

V.

VERNEUIL, congenital, 472
Vertebræ, dislocations of, 494
atlas, 505
cervical, 507
classification, 493
dorsal, 514
etiology, 499
lumbar, 516
occiput, 503
pathology, 493
prognosis, 501
secondary changes, 498
symptoms, 499
treatment, 502

Viscera, injury to, 427
Volker, old, of elbow, 672
Volkman, pathological, 481
Voluntary dislocations, 483
Von Ammon, congenital, 473

W.

WARBASSE, congenital, of hip, 479
Wielard, injuries of vessels, 458
Wippermann, fracture of neck of femur,
763
Wrist, dislocations at, 679
pathological, 687

Y.

Y-LIGAMENT, 719
ossified, 746

Z.

ZIELEWICZ, congenital, of patella, 807

RD 101

1907 Sx5

Stimson

Fractures and Dislocations

W. Rabinowitz

