

*From the Authors*

## CASES AND OBSERVATIONS

ILLUSTRATING THE

HISTORY AND PATHOLOGICAL RELATIONS OF  
TWO KINDS OF HYDATIDS, HITHERTO  
UNDESCRIBED.

By Dr GAIRDNER and Mr LEE,

WITH

MICROSCOPICAL OBSERVATIONS

By Mr H. GOODSIR.

---

*(From the Edin. Med. and Surg. Journal, No. 161.)*

---

1. *Case of Abdominal Disease, in which the substance of various viscera was destroyed by an entozoon, not hitherto described.* Read before the Medico-Chirurgical Society of Edinburgh, on the 1st of May 1844. By JOHN GAIRDNER, M. D. F. R. C. S. E.

EARLY in 1843 I was consulted by a respectable tradesman, then in his 69th year. He complained of a deficiency of power in his lower limbs, affecting both of them equally; and also of some slight pain or uneasy feeling in his back, about the region of the lower dorsal or upper lumbar vertebræ. These, so far as I remember, were his only complaints. I was, at the time, of opinion that the loss of muscular power might be owing to some disorder, functional or organic, of that part of the spinal cord which corresponded with the seat of his uneasiness; and, in the hope that it was only functional, prescribed that he should apply towels dipped in very cold water to that part of the spine, evening and morning, for some minutes each time, and that he should afterwards

rub the part with a rough dry cloth, till it was brought into a state of warmth and of vascular reaction. For reasons which will appear in the sequel, I greatly doubt the accuracy of the notions I then entertained of the theory of the morbid symptoms just detailed; but the patient decidedly improved under the treatment, the sluggishness of the limbs went entirely away, and with it the spinal uneasiness, and he repeatedly expressed himself much satisfied with the results of this very simple management.

In the month of July following, he again consulted me; and had then a new symptom, a considerable tumefaction of the abdomen, with obvious fluctuation.\* No induration of the liver, nor any hard tumour could be detected in any part of the cavity. He complained of his bodily strength being a little impaired, and was quite obviously thinner than formerly. He was also somewhat sallow than usual, though not remarkably so, for he had naturally very little colour when in his best health. His urine amounted in twenty-four hours to about a quart; in colour and appearance it was little different from what it ought to be; when boiled, it presented no trace of albumen. He was remarkably free from pain.

The symptoms just detailed gradually increased. Diuretics of various sorts, and more especially squill, digitalis, mercury, acetate of potass, and nitrate of potass, were perseveringly employed, and excited only occasional and very inadequate diuresis. At first he was able to attend to his business and to go about the streets as usual, but towards the end of the year he became more and more debilitated, and very seriously incommoded by the great distension of his abdomen. His food was frequently returned, apparently in consequence of the pressure exerted on the stomach by the abdominal contents. I proposed to relieve him by paracentesis, which, after some delay, occasioned by his own reluctance to the proceeding, I performed on the last day of the year. The puncture was made in the *linea alba*. On withdrawing the trocar, not a drop of fluid followed it for some seconds. I passed a director through the canula, and a few particles of gelatinous-looking matter came away, followed by some drops of liquid. I adapted a syringe to the canula for the purpose of suction, with the aid of which I withdrew nearly a pound and a half of similar matter, and was then forced to give up, in consequence of the great difficulty of the proceeding, and of the probability of inflammation if it had been longer protracted. The diminution of the distension made a very considerable difference, for some days, in

\* The fluctuation, when carefully attended to, was somewhat peculiar in its character, approximating to that which is experienced on tapping with the finger one side of a vessel of animal jelly, while the other hand is applied to the opposite side of the vessel. The reason of this will be apparent from the history of the case.

the poor man's comfort, and in his capability of receiving food; but he gradually became as bad as ever. I was therefore tempted to make a second effort to relieve him, with the hope that I might possibly be enabled to do so more effectually. I had not been prepared, on the 31st of December, to expect the difficulty which then occurred, and my apparatus for suction was consequently less perfect than I could have wished. When I repeated the paracentesis on the 13th of January last, I was provided with an excellent syringe for this purpose, and was therefore much disappointed to find that I was unable to get away more than ten ounces of the gelatinous matter. He was again greatly relieved for a short time, but again became gradually worse and worse. His death happened on the 14th February last.

I was permitted to examine the body the following day, about thirty-five hours after death.

The cavity of the peritonæum was found to be entirely filled with the same kind of matter which had been withdrawn by operation. It consisted of a number of masses, mostly of a globular or ovoid form, attached by pedicles (Plate V. Fig. 7,) to the inner surface of the peritonæum lining the abdominal parietes, and also to the peritonæal surface of the intestines and other abdominal viscera. The entire quantity of these masses amounted to about twenty-four imperial pints. Across the epigastrie region extended a massy tumour of a dense consistence, which had been concealed during life by the great distension of the abdominal walls. Innumerable masses of the gelatinous-looking matter were attached to this tumour like bunches of grapes, (Plate V. Fig. 5.) When these were artificially separated from it, the surface from which they had been removed presented an appearance like honey-comb. It was at first difficult to say in what organ this dense tumour had been developed; but its connections with the surrounding parts proved it to be the omentum. The tumour was from two to three inches thick, very hard throughout, and, in some parts of it, almost of cartilaginous density. On cutting through it the stomach and colon were found imbedded in it, and firmly fixed together by it. The place usually filled by the right lobe of the liver was completely occupied by the gelatinous bodies. The lobe itself had entirely disappeared. The gall-bladder and biliary ducts still existed, and contained some bile. The common duct was traced to its usual termination in the duodenum. The left lobe of the liver was greatly diminished in size, but a portion of it remained in a tolerably sound state. The textures of the pancreas and of the spleen, though enveloped in the tumour already described, were not nearly so much invaded by the disease as those of the liver. The intestines had a very dark colour, resembling that of melanosis; they were much compressed by the distension of the belly, and had



many of the gelatinous bodies attached to them. Besides those which were attached to the peritonæal surface there were others of small size in the subserous tissue in various situations, and more especially in the immediate neighbourhood of the bladder. The right kidney was natural; the left had a considerable tubercle within it, occupying that position in the organ where the secreting part of it passes into the uriniferous. The thoracic viscera were perfectly sound; the lungs rather unusually dark in colour.

The remarkable substances above mentioned deserve to be more particularly described. It is impossible to doubt that they were real entozoa of a peculiar kind, but they differed in many particulars from ordinary hydatids. They were contained in the general cavity of the peritonæum, instead of being developed, as hydatids are, within a peculiar sac. The fluid which they contained, and that in which they floated, were highly coagulable by heat, forming a firm curd resembling in all respects the white of a boiled egg, and, no doubt, of the same composition. The fluid of common hydatids, as we know from Dr Marcet, (*London Med. Ch. Trans.* Vol. ii. p. 376,) and from Dr Bostock, (*Guy's Hospital Reports*, No. V. p. 468-9,) is not coagulable by heat "except after very considerable concentration." (Marcet.) Ordinary hydatids are mere cysts or vesicles containing fluid; but the fluid of these bodies did not flow out when they were cut into, being retained, like the fluid part of the vitreous humour of the eye, and that with much more tenacity, by a multitude of septa, which were seen passing through them in various directions, and which, besides parting them into lobules, appeared to enter by innumerable minor subdivisions into the composition of these lobules, giving the whole a reticulated appearance. In colour and transparency they very exactly resembled masses of calf's-foot jelly. Their fluid was of a glutinous or mucilaginous consistence. A portion of it, subjected to the microscope, displayed a number of small cysts floating in it, obviously the germs of the large ones. The larger bodies, or hydatids, if they may be so denominated, were in some instances almost of the size of a hen's egg; and they were of all sizes, from that to the minute volume of the microscopic ones already mentioned. I have said that they affected the globular or ovoid form; but, either from compression, or other unknown causes, they were often very irregular and unshapely, and some of them were evidently broken and disintegrated. Many of the more dense among them had a degree of opalescence. The fluid in which they floated bore a very small proportion to the aggregate mass of these bodies themselves, and I have a suspicion that it was chiefly derived from the rupture of the larger ones. Their exterior surface was roughish, in consequence of the existence, at pretty regular intervals, of a great number

of small points, which proved, under the microscope, to be so many minute discs, having in their circumference apertures or *stomata*, communicating with little tubes which ran from them in different directions in the outer coat of the hydatid. (Plate V. Fig. 8.) The external surface of these bodies was less obviously rough in proportion as they decreased in size, but even the smaller ones, under the microscope, shewed similar roughness. Almost all those which were not of merely microscopic magnitude were attached to some part of the textures. Many of them had short thick pedicles; some had pedicles resembling narrow tapes. A very inconsiderable force was generally sufficient to detach them. The few which seemed altogether free had probably been detached by some such slight cause. The adhesion of others was more tenacious, and many of them appeared to be generated between the peritonæum and the textures immediately exterior to it. I have said *appeared*, because the peritonæum was in very many places so altered as to make it difficult to say whether it really existed there any longer or not.

Those who examine the records of such cases cannot fail to remark, that very many histories are given of supposed hydatids, which were not hydatids at all, but merely such cysts as Dr Hodgkin has described under the title of "Adventitious serous cysts." (London Medico-Chirurgical Transactions, Vol. xv. p. 267.) These are developed in the ovary, mamma, testis, and many other textures and organs, with which they have a vascular connection; and such is the want of discrimination with which the term hydatid has been applied to them, that much attention is necessary to distinguish true cases of hydatids from false ones. There is also to be remarked in those narratives of real hydatids, which are to be found in the writings of physicians, a considerable want of perspicuousness, arising from the application of the term cyst sometimes to the hydatids themselves, and more especially the parent hydatids, within which the young ones are generally developed; and sometimes to those *vascular* capsules within which we usually observe the parent hydatids to be contained, much in the same way as a kernel is contained within a shell.\* These vascular capsules, which are adventitious formations from the textures of the several organs in which hydatids are imbedded, I shall, to avoid confusion, term the *nidi* of the hydatids.

I shall now endeavour to discover how far the more distinctive points in this case resemble those of similar cases to be found in the records of past experience.

1st, The absence of *nidi* in the case related was one of its re-

\* For a very accurate account of this appearance, I refer the reader to Mr Howship in Edin. Med. and Surg. Journal, vol. xliii. pp. 15-16.

markable features. If the narratives of cases of true hydatids are read with care, it will be found that these nidi have been almost universally present. Among the fifteen cases of hydatids detailed by Dr Bright in the fifth No. of Guy's Hospital Reports, there are apparently none that were not contained in nidi. In his second case, nidi were found in the omentum, the liver, and the spleen. The excellent representation of the parasitic entozoa which accompanies his description, recalls strongly the appearance of those I lately saw. But they must have been essentially different; for they are described as mere vesicles containing a fluid "as pure as distilled water."

2d. Extensive invasion of the textures of the liver by hydatids is by no means uncommon; but I cannot find in any cases of *equally* extensive destruction of these textures with that which I have related. In Mr Howship's case, communicated to the Medico-Chirurgical Society of Edinburgh, (*Edinburgh Medical and Surgical Journal*, Vol. xliii. p. 13-22,) "the liver was diminished in thickness almost to the peritonæal coat; not more than about half an inch of its parenchymatous substance remaining." The hydatids "were connected together by extensive fibrinous adhesions." From this last expression, and from the description and delineation which follow, it appears clearly that they were contained in the usual *nidi*. They were the common acephalocysts, and therefore differed in structure from those which I saw.

A very remarkable case of the same sort is briefly related by Ruysch, (*Observat. Anatomicæ*, lxxv.) in which he says that a bold and rude surgeon perforated the abdomen in the region of the liver, and discharged a great number of hydatids. A similar operation has often had a successful issue; but in this case the woman died; and it was found on dissection that "*tota substantia hepatis, eo in loco, in hydatides degeneraverat.*"

Cheselden, in his *Anatomy*, relates (p. 212,) a similar case, in which "the gibbous part" of the liver was "*entirely wasted,*" and contained hydatids in a proper nidus within that viscus. Another case will be found in Sandifort's *Thesaurus*, (Vol. i. p. 347,) and one in Meekel's *Handbuch der Patholog. Anat.* (Vol. ii. P. ii. page 409.) A large collection of such cases could easily be made, in not a few of which the hydatids were evacuated by incision during life from the site of the liver. In some, in which, it is to be presumed, the liver was not extensively injured, the health of the individual was restored.\*

\* I would refer more particularly to an excellent case of this sort treated by Guattani, and reported by Lassus in the *Journal de Médecine et de Chirurgie*, Paris, an ix. vol. i. p. 137. Another excellent case is recorded by Dr Monro in his *Morbid Anatomy of the Gullet, Stomach, and Intestines*.



3d. I have not been able to find any case in which the omentum was morbidly altered in the particular manner which I have described. Dr Cooke, in his edition of Morgagni, (Vol. ii. p. 261, *note*,) has spoken of a *horny* state of the omentum from hydatids, which had fallen under his observation. This may possibly have been a similar case.

4th. The albuminous and highly coagulable character of the substance of the entozoon, is another point in the case which I have sought to illustrate from the records of medicine. I shall first of all produce a case of this sort from Bonetus (Sepulchretum, Tom. ii. p. 490,) who very pertinently inquires, "Quis medicorum curare potest hydropem ascitem *limosum, membranis inclusum*?" He says he has heard and read of many such cases, and he gives the following as an example. "Aperiui cujusdam virginis ætate provectoris cadaver, cujus admodum distenti abdominis totam cavitatem repletam conspeximus innumerabilibus vesicis aut sacculis *humore tenaciori et glutinoso* refectis." Here the fluid was glutinous and tenacious, and therefore very unlike that of acephalocysts; and yet, I fear, the case cannot be safely produced as an instance of hydatids, though so regarded by the author. For he does not say whether these "sacculi" were attached or not; and as the subject was a female, it is at least possible, if not probable, that they were serous cysts connected with the ovary.

The following case from Ruysch is not open to the same objections, and is, besides, one of the most remarkable for destruction of the liver which I have met with. I quote his own words. "Anno 1696 hydropici cadaver cultro anatomico subjeci, *cujus hepar, totum quantum erat, ex meris vesiculis constabat, quæ materiam limosam pellucidam continebant.*—*In dicto jecinore ne minimus quidem ramulus venæ portæ, cavæ, ductus biliosi, aut arteriæ hepaticæ videndum sese exhibebat, quantumvis ad illud usque tempus vixerit æger.*" The author then enters into some speculations on the origin of the hydatids which are little to my present purpose, except on account of his characterising them as "*substantiam gelatinosam in se continentes.*" The patient was a male, as is evident from the first words above quoted; the disease was in the liver; the "vesiculæ" contained a matter which was not merely slimy and gelatinous, but *pellucid*; the description of these bodies, so far as it goes, would serve excellently for the appearances presented by the parasites in the case which I have described; and the extensive destruction of the liver completes the parallelism. (See Thesaurus Anatom., i. No. xii.) In a subsequent part of his writings, the author gives a plate representing a portion of this unusual liver. (See Thesaurus Anatom., ii. Table ii. Fig. 3.)

Dr Crowther has presented to the profession a remarkable enough case, in which considerable difficulty was found in tapping from the presence of hydatids. After the death of the patient, a female about thirty, the peritonæum was found greatly thickened; and presented, "on dissevering its laminæ," (such is Dr C.'s expression,) a great variety of "cysts, some round, some oval, some transparent, some opaque," the transparent ones containing "a thick, transparent, syrupy, gelatinous fluid," which is stated to have "coagulated by the application of heat." The abdominal viscera were all sound, the hydatids, if such they were, (and I think it probable that they were such,) being altogether external to the peritonæal cavity. There are few recorded cases in which the effect of heat on hydatids has been mentioned, and it is a pity that in this one, in which their coagulability was ascertained, the structure of the "cysts" is not more minutely described.\* (See Edinburgh Med. and Surg. Journal, Vol. xxv. p. 49-50.)

5th, There yet remains one aspect of my case in which I have endeavoured to illustrate it from the observations of others; I mean, as it regards the external and internal structure, and the mode of attachment, growth, and development of the entozoon itself. I have endeavoured to give an accurate account of its characters in the former part of this paper, and my friend, Mr Harry Goodsir, conservator of the Museum of the Royal College of Surgeons, Edinburgh, whose familiarity with subjects of this description, so eminently qualifies him for the task, has examined it with great minuteness, and introduced the results of his inquiries into a paper which he has recently communicated to the Royal Society of Edinburgh, on the structure, economy, and development of the different species of entozoa. Mr Goodsir suggests *Diskostoma Acephalocystis* as an appropriate name for this species. I have resorted to all the most probable sources of information accessible to me, from which parallel cases might be expected to be adduced, and more especially to the express treatises on the natural history and structure of entozoa in general, or of hydatids in particular, by Rudolphi, † Bremscr, ‡ Cruveilhier, § Kerr, || Owen, ¶ Lobstein, \*\*

\* A collection of cases will be found in Sandifort, 22 in number, in many of which the seat of the parasites was similar to that of those observed by Dr C. (Thesaur., vol. i. p. 451.)

† Entozoorum Hist. Nat.

‡ Traité Zoolog. et Physiolog. sur les vers intest. de l'homme.

§ Article "Acéphalocystes" in Diet. de Med. et de Chirurgie Pratiques.

|| Article "Hydatids" in the Cyclopædia of Practical Medicine.

¶ Article Entozoa in Todd's Cyclopædia of Anatomy and Physiology.

\*\* In his Traité d'Anat. Pathologique, t. i.

Meckel,\* Laennec,† Lamarek,‡ Copland,§ Monro,|| and Hippolyte Cloquet.¶ I have also examined those more incidental accounts of hydatids which are to be found in such pathological works as those of Morgagni, De Haen, Baillie, Abercrombie, and many others, some of which I have quoted in this communication: finally, I have examined a very great number of those still more casual descriptions which are connected with the details of individual cases in the transactions of societies, and in periodical journals, and other works. From all these sources I have not been able to extract a single description of a parasite at all resembling that which was fatal to my patient. I am therefore warranted in asserting that it is a rare one; and that if it has been seen, which it very probably may have been, it has at least never yet been described with that precision which is necessary to its identification.

## 2. Description of the Hydatid found in Dr Gairdner's Case.

By HARRY D. S. GOODSIR, Conservator of the Museum of the Royal College of Surgeons, Edinburgh.

THE hydatids found in this case were globular, of various sizes, (Pl. V. Fig. 7, also preparation 2241, Mus. R. C. S. E.,) and were connected together in groups or masses, each group resembling the ovaria of birds in an active state of development; they were of a bright straw-colour. Each group was covered externally by a membrane, (Pl. V. Fig. 8,) which was formed by the hydatid. At first this membrane, from its appearance, was thought to have been the result of inflammatory action, but a more minute examination proved it to be a tissue *sui generis*, and one which intimately belonged to the hydatid. Its external surface was rough, in consequence of a number of striæ, which ran at irregular intervals across one another, so as to form interspaces of an irregular angular shape, (Pl. V. Fig. 7.) This membrane not only covered the surface of the group, but also dipped deeply between the hydatids and in those specimens which were altogether isolated, the membrane covered them entirely, even to the base of the pedicles, and generally passed from the hydatids to the surface of the peritonæum, where it became gradually thinner and thinner, as it receded from the parent stock.\*\*

When magnified this membrane presented a very peculiar struc-

\* In his Handbuch der Patholog. Anat. v. ii.

† In the Bulletin de l'École de Médecine, &c. de Paris, an xiii.

‡ Histoire Naturelle des Animaux sans Vertèbres, t. i., Paris, 1816.

§ In his Dictionary of Practical Medicine, Art. "Hydatid."

|| In his Morbid Anatomy of the Human Gullet, Stomach, and Intestines.

¶ In the Dictionnaire de Médecine. Articles "Acéphalocyste," "Cysticerque," "Polycéphale," and "Ditrachyceros."

\*\* Transactions of R. S. E., Vol. xv.



ture, (Pl. V. Fig. 5); numerous disks of various sizes were seen scattered over its external surface, and larger disks were sometimes seen with two or three smaller ones upon them. Numerous tubuli ramified through the membrane, and opened on its surface, by means of small stomata, which were generally arranged round the edges of the disks, (Pl. V. Fig. 8.) Immediately underneath the membrane already described, there was a layer of cellular substance which connected it with another of a much more delicate texture. From observations made upon another, and also new form of acephalocyst,\* I have been led to suppose that a third membrane exists in this hydatid, which probably lies internal to the two others, and from which the delicate septa which traverse the gelatinous mass of the body arise.† The stomata and tubes which were observed in the external membrane could not be traced into the deeper parts of the body of the animal.

When a small portion of the external or tubular membrane was placed under the microscope, its internal surface was found to be studded with numerous small shining bodies or cells. In general these cells were compound, containing from one to four, or more young cells in their interior.‡ These I looked upon as the gemmules of this hydatid, which, like the other acephalocystic entozoon, is gemmiparous. The younger or contained cells were sometimes seen free and detached from the parent cell, floating in the gelatinous contents of the parent hydatid. The tubular membrane, as it extends over the peritonæal surface, after arriving at a certain stage of growth, throws off cells similar to those just described from its attached surface, and invariably from spots in the neighbourhood of the large tubes.§

These cells enlarge, not by any apparent cellular development, but, like those of the common acephalocyst, by simple dilatation from the addition of new matter in the interior. As this increases, the tubular membrane in the neighbourhood becomes thicker, owing to the increased number of tubes necessary for the nourishment of the young cell.

In this entozoon there are two modes of propagation, one for increasing the size and extent of its own individual group; the other for the purpose of extending the species to as yet uninfested portions of the infested animal.

The first mode of propagation we have just described; the second would appear to proceed in the following manner:—The gemmules, by some means or other, escape from the parent acephalocyst, reach the uninfested tissues at some distance from the general parasitic mass,|| and thus in time form new groups, which,

\* Vide, p. 279.

† Ibid.

‡ Ibid. p. 564, pl. xv. fig. 2, D. E. B.

† Transac. R. S. E., vol. xv. p. 563.

§ Ibid. vol. xv. pl. xv. fig. 2, C.



in their turn, throw off gemmules also. This goes on for a longer or shorter period, until at length the whole surface of the peritonæum is completely occupied and covered. So soon as this is effected the succeeding gemmules are forced into the deeper tissues. As they increase in size, they tend always towards the surface of the infested cavity, and at length burst from their confinement, adhering, at the same time, to the bottom of their former, containing cellules by pedicles, (Pl. V. Fig. 5.) In this manner a peculiar honey-comb appearance was produced in consequence of the breaking up of the tissues surrounding them, (Pl. V. Figs. 5 and 6, also preparation 2242 in Museum of the Royal College of Surgeons, Edinburgh.)

3. *Case of Ascites connected with a peculiar Parasite within the Peritonæal Sac.* (Read before the Medico-Chirurgical Society of Edinburgh on the 5th June.) By THOMAS M. LEE, Esq.

Jane Robertson, aged 53, had been twice married; first fifteen years ago, and a second time six years afterwards; had had two children, both by her first husband; the elder died while teething, the other is now 12 years old. She had lived in Edinburgh till she was last married, but since then had resided in different parts of the neighbouring country, wherever her husband, who is a labourer, could obtain employment, but had returned to town about fifteen months before her death. Her first husband died of cholera when that disease prevailed in this city. Her father and her only sister died paralytic, and her mother died of consumption. She had two brothers, one is still alive, the other died when a child of small-pox, or soon after having that disease. She is said to have been remarkably stout and healthy up to the time of her second marriage, soon after which her health began to decline, and since then she has had to endure many privations, and has suffered much from mental anxiety caused by domestic differences. She at first complained of drowsiness, and soon afterwards began to lose flesh and colour.

About five years ago, after labouring for some time under a disease of the knee-joint, which, however, yielded to repeated blistering, she had a spitting of blood, which left her very weak; but it does not appear that she was troubled at any time with cough. She has apparently had more or less of ascites for the last three or four years, and during that time has complained of a disagreeable sensation at her stomach, as if there were something in it, the removal of which would have given her relief, and of an inclination to vomit after eating, along with a dread at being touched about the abdomen. I saw her for the first time on the 19th of February last; the symptoms at that time were, anorexia,

globus, a bruised feeling along the lower border of the ribs, pain in the back, tenderness in the left hypochondriac region, pain at stomach immediately after food, with sweetish regurgitation, bread and tea being the sort of nourishment after which she experienced the least uneasiness: the abdomen was considerably distended, and fluctuation could be felt all over it; percussion on the abdominal parietes, while she lay on her back, produced a dull sound except over a small space in the umbilical region. She occasionally sweated at night after rigors, and had sometimes a disagreeable feeling of heat about the soles of the feet. She had been troubled with bowel complaint, but not for the last six weeks; her pulse was 80, her tongue clean, and her bowels regular; her urine, of which she made scarcely four ounces daily, was sometimes passed involuntarily, and was not coagulable by heat. During the next week, I have marked the state of the pulse once, when it was 68; the urine increased to twenty-four ounces under the use of digitalis, squill, and blue pill; she continued to take a blue pill every night until she had taken nine, when her gums became slightly affected. On the 26th of February she was a little feverish, and had had some shivering the night before; her skin was hot; tongue clean; pulse 88; urine twenty ounces. On the 1st of March she complained of a *jagging* pain at the epigastrium, of a feeling as if something heavy fell in her abdomen when she turned, and of a hot ball rising up her throat; she had no appetite and no thirst; her tongue was clean; pulse 68, of fair strength; skin cool; urine ten ounces. On the 11th of March, her mouth, which had been very slightly affected by the mercurial pills for about a week, was well; she still complained of pain, or rather heat after eating; a good deal of pain was excited by pressure on a spot a little below and to the right of the ensiform cartilage; no tumours could be felt in the abdomen; her bowels were regular, but her urine was very scanty and drained away involuntarily, and was said to have a very disagreeable odour; she complained of downbearing, which she had had sometimes before to a very unpleasant degree; she had had no discharge of any kind from the vagina for many years, but had sometimes pain in the region of the uterus and bladder; the *cervix* and *os uteri* felt healthy, but an irregular, hard, and moveable body, about the size of a hazel nut, could be felt through the upper part of the anterior wall of the vagina; (at a subsequent examination two or three of these bodies were felt in this situation); the uterus was not very moveable especially on the left side, and the lower extremity of the cervix was inclined to that side. March 15, had vomited some dark-brown fluid having a sweet taste, which is said to have resembled strong tea, and afterwards had lancinating pain in the right shoulder; tongue clean; pulse 60, of good strength; stated that she



never had any headach or bad taste of mouth. On the 25th of March, she still complained of heat and ball in the throat, abdominal distension had increased; her feet were a little swelled, and pitted when pressed; she felt very weak, but thought she would be well enough if she could live without eating. On the 20th of April she had retched much the night before, and had vomited a little fluid resembling thin mucilage with a little snuff disseminated through it; her tongue was slightly furred, and she complained of pain to the right of the epigastrium; her skin was warmer, and her pulse firmer than usual; she had taken a little wine a few minutes before I called. On the 21st she vomited some more of the brown fluid, and complained much of pain; her pulse was 76, of fair strength, and her tongue was white. After this she was kept pretty easy by large doses of morphia, but sunk rapidly, and died much emaciated on the 11th of May. For the last three weeks of her life, her bowels, which, for sometime had been getting less regular, were almost unmoved,—enemata, which could be administered only in very small quantities, having had a slight effect but once during that time; she had a good deal of thirst, but whatever she swallowed seemed to stick at the lower part of the œsophagus until it was rejected; for the last four or five days, however, she could swallow water freely. The conjunctiva became inflamed a few days before her death. Her mind continued calm to the last.

*Dissection*, May 13.—Present, Mr John Goodsir, Mr Harry Goodsir, Dr Gordon, and myself. When the cavity of the abdomen, which contained four or five gallons of a greenish yellow fluid, having an oily or ale-like consistence, was exposed, none of the abdominal viscera could be seen, except part of the colon, distended with flatus, and projecting over the spine between the kidneys. The intestines were found to be firmly bound down to the posterior part of the abdominal cavity, by a mass of gelatinous-looking matter of a structure somewhat similar to that of cooked tapioca, interspersed with irregularly rounded cysts of various dimensions, one or two fully three inches in their longest diameter, but for the most part about the bulk of the largest sizes of small shot. The peritonæum of the abdominal parietes was also studded with the same bodies, the larger ones being attached by a peduncle generally so slight, that when they were pulled away no trace of their attachment could be distinguished. The larger and many of the smaller cysts were covered by a strong membrane, of a dingy colour, having somewhat the appearance of intestine, but sufficiently transparent to allow of its being seen that they were filled with other cysts of a smaller size. One of the largest of these cysts was found loose in the abdomen, and one or two of a smaller size, which were also loose, were

probably broken from their attachments by my hand coming against them. The smaller cysts were apparently attached more firmly to the peritonæum than those of a larger size. A considerable part of the peritonæum was also covered with a yellowish gelatinous-looking matter, of a globular structure, but without the dingy membranous covering, similar to the contents of the larger cysts. The intestines were so firmly matted together, that an accurate examination of them could not have been made without more time and care than the circumstances would allow; hardened fæces were found in some parts of them, and the vermiform process was inverted, and lay within the gut. The uterus, exclusive of the cervix, was not much larger than a good sized filbert, and lay imbedded in a mass of the gelatinous matter, which was impacted in the pelvic part of the abdominal cavity, and which apparently prevented the bladder from contracting. The peritonæum was a little wrinkled in some parts, from the effusion and subsequent contraction of lymph, doubtless the result of the irritation caused by the presence of the parasite. No omentum could be seen. The liver, which was bound by a firm layer of gelatinous matter to the back part of the diaphragm, was small, flattened, and of a soft consistence. The stomach was apparently healthy; but some patches of ulceration were observed on the mucous lining of the lower part of the œsophagus. The only kidney examined was small, but was not remarked to present any morbid appearance. The substance of the heart was soft, and there was some slight osseous deposit about the aortic valves. There were some calcareous tubercles at the apices of both lungs, but they were otherwise healthy.

4. *Description of the Hydatid found in Mr Lee's Case.* By HARRY D. S. GOODSIR, Conservator of the Museum of the Royal College of Surgeons in Edinburgh.

This acephalocyst is very different from the *Acephalocystis simplex* and the species already described under the name of *Diskostoma acephalocystis*. It differs, however, from the species alluded to in points of considerable importance, and of such a nature as to require the constitution of a new genus for its reception.

It will be remarked, by those who are acquainted with these animals, that the *Acephalocystis simplex* is much less complex in its structure than the *Diskostoma*, on which account there can be no real affinity between them, a connecting link being wanting. In the acephalocyst under consideration we have what is desiderated; and it will be the object of the following remarks to point out its structure, functions, and relations.

In its rudimentary state, the *Astoma acephalocystis* is of a glo-



bular form; but in the parent this form is to a great extent lost, owing to the young cysts within it increasing irregularly in size, and presenting a nodulated appearance. In the larger specimens, the external surface is quite smooth, an appearance which seems to arise from distension, the small or young ones being rough, and corrugated externally. The parent cyst is very strong, fibrous, and dense, and is composed of three membranes, the outermost of which is the strongest, the *remaining two* being much more attenuated, though at the same time of considerable strength. On stripping the external layer from off the two others, and placing it under the microscope, it presented a peculiar reticulated appearance, with a few indistinct masses of ovules on its internal surface, (Pl. V. Fig. 1,) separated by accident from the succeeding or middle layer of membrane, which appeared to be the seat of development of the gemmæ. At the same time the internal membrane and the septa which arose from it, and ran into the gelatinous body of the hydatid, appeared to be matrices for these cellules. The structure of the middle membrane was more fibrous than the external one, (Plate V. Fig. 2.) The innermost of these three membranes was very peculiar in its structure, and differed altogether from the other two. When placed under the microscope it was transparent and colourless, with an immense number of fibrous-looking bands running through it in all directions, which ramified in a manner similar to the extreme capillaries of blood-vessels. A number of ovules were attached to this membrane, but there were few when compared with those in the middle one. In this membrane also numerous reticulated circular masses of considerable size were seen. These were the ovules in an advanced state of growth, (Plate V. Fig. 3.)

The great mass of the body of this animal consisted of the same gelatinous-looking substance of which the Diskostoma was composed, but it was not in such abundance. At the same time numerous septa or fibrils, similar to those observed in Diskostoma, traversed the gelatinous mass. Several distinct ovules were seen attached and apparently growing from the septa in this part, and in the jelly a number of small filaria was frequently observed, (Plate V. Fig. 4.) The middle part of the body of these thread-worms was rather large, and tapered gradually to so fine a point from this to the extremities, that the eye lost all trace of them even under a strong power. The middle part of the body was black, but both the extremities were colourless. The filaria were sometimes seen single, but generally they were lying in masses, twisted, and contorted with one another. They were much more common in some specimens of the accephalocyst than in others.

The free or parent Astoma varied in size from a millet-seed to

that of a large orange, and was of a lightish brown or sand colour. Those that were not larger than a filbert were globular; as soon, however, as they became larger, they assumed the nodulated appearance, which gradually increased with the size of the animal.

When a small portion of the middle membrane was put under the microscope it was found, as already observed, to be filled with small ovules, most of which were of a similar size. Some of these, however, were observed to be larger than others, but it was not till they reached, or came in contact with the inner membrane that the ovules began apparently to increase much in size. As the ovule increases in size it projects into the cavity of the parent cyst, sometimes carrying before it a layer of the internal membrane of the parent; and it is to be observed that, as this process is going on, the secondary animal, or hydatid, is also being distended with young, which again throws off another or fourth series, so that there is a constant formation of young,—one within the other, the parent or original cyst containing all the formations within itself (Plate VI. Fig. 1, preparation 2243, Museum Royal College of Surgeons.) When a parent cyst, therefore, is divided, the internal structure will be found to be very complicated, consisting of cells within cells of all sizes. The parent cyst, after arriving at a certain state of distension, bursts, whereby the young, which had been formerly confined within it, are exposed, and as the original cyst is now useless, it is absorbed, the young in the meantime becoming attached to the peritonæum. (Plate V. Fig. 3, also preparation 2244, Museum Royal College of Surgeons.)

In this species, as in the *Diskostoma*, there are two modes of propagation, viz. one for the extension of the group, and another for the extension of the species to the portions of the body as yet uninfested. The former of these, which takes place at the expense of the parent cyst, is that which we have just described, the latter is exactly similar to the analogous mode in the *Diskostoma*. The younger cells, which have become detached from the membranes, and are seen suspended in the gelatinous fluid, escape, by some means or other, from the parent hydatid, and reach the parts of the body which have hitherto remained uninfested, where, forming a nidus, and, gradually increasing in size, they become independent animals, and in time throw off ovules also. (Plate V. Fig. 2.)

This species, like the *Acephalocystis simplex*, is without any apparent organs of nutrition, unless the ramifications which are seen very slightly in the external membrane, and more strongly in the two internal coats, are looked upon as vessels,—a point which cannot be determined with accuracy.

It was suggested by Dr Gairdner that the cysts might be sup-

plied with blood from the body of the infested being, which would, he thought, prove their affinity to the morbid and adventitious cysts found in the ovaries and other parts of the body. With the view of deciding this point, I had the vessels of a large portion of the intestines, which was infested with the hydatid, filled with minute injection, when I found that, although the intestines were most minutely injected in all parts, the hydatids which were attached to them were perfectly free of blood-vessels. In many instances, also, the peritonæum, round the base of the parasite, where we would naturally look for inflammatory appearances, was found to be most minutely injected, while there was not the slightest vestige of injection on the parasite itself. (See preparation 2245, Museum of Royal College of Surgeons, Edinburgh.)

The propriety, however, of classing these bodies along with the Acephalocysts, or even looking upon them as having any degree of affinity, has been questioned. In a paper read before one of the late meetings of the Royal Society, I proved that the common Acephalocyst and Diskostoma were independent animals.\* Now, the Acephalocyst under consideration, as regards both its structure and functions, has a great affinity to Acephalocystis as well as Diskostoma, so that if the animality of these two is granted the like must be granted to Astoma also.

In investigating the nature of adventitious cysts, and comparing them with the bodies under consideration, it cannot but strike the observer, that a remarkable difference exists between them. In the former, we have a thick, highly-vascular coat, with a number of large vessels permeating it; the minute structure of which consists always of apparently compressed cellular substance, being in this respect exactly similar (and formed in a like manner,) to the vascular coat which surrounds the external cyst of the Acephalocystis, which has no connection with the hydatid, being entirely composed of the tissues of the infested person. In the latter, the minute structure of the tissues is very different and decidedly non-vascular. The mode of propagation, however, is perhaps the most specific mark of difference which we have for the distinguishing of these two very different bodies.


\* Transactions Royal Society of Edinburgh, Vol. xv. p. 561.








*M. baccata* Descriptions of its parts



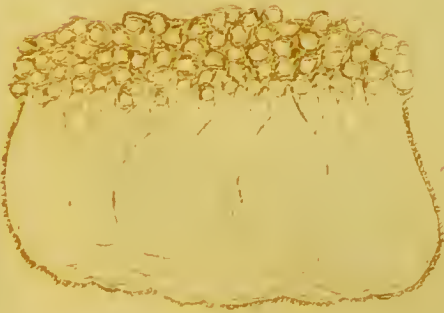

1



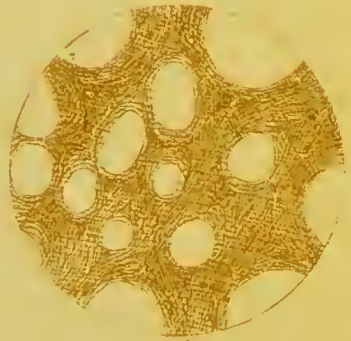
2



3




5



6



7



8



*M. Goodsir's Description of Hydatids.*

