

KELLY (H.A.)

Reprint from *The Southern Practitioner*, January, 1897.

ABDOMINAL HYSTERECTOMY FOR FIBROMA UTERI.

BY

HOWARD A. KELLY, M.D.,

*Professor of Obstetrics and Gynecology in the Johns Hopkins
University, Baltimore.*

CHAS. P. NOBLE, M.D.,

Surgeon-in-Chief, Kensington Hospital for Women, Philadelphia.

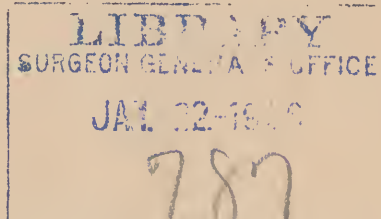
HENRY D. FRY, M.D.,

Professor of Obstetrics in the Georgetown University, Washington, D. C.

AND

WILLIAM D. HAGGARD, JR., M.D.,

Associate Professor of Gynecology in the University of Tennessee, Nashville.



A Discussion, by invitation, at the Nashville Academy of Medicine,
November 12, 1896.



DISCUSSION.

DR. HOWARD A. KELLY, of Baltimore.—Abdominal hysterectomy for fibroma is one of the most important and interesting topics to every gynecologist. The case at the City Hospital, tendered me through the courtesy of Dr. Haggard, Sr., will form the text of my remarks. I there made an enucleation in a little over seven minutes by a new and simplified technique.

When I began surgery, in 1883, a fibroid tumor of the uterus was a *noli me tangere*.

Surgeons opened the abdomen, and, finding a fibroid, at once decided that the case was inoperable; when it was mistaken for an ovarian growth and removed, the mortality was so frightful as to deter others from taking such risks.

The first important step was taken by Hegar, of Germany, when he removed both ovaries and tubes in fibroids, finding, in many instances, that the growth shrivelled from the lessened nutrition. This castration was widely practiced; often with distinct advantages. At first this operation was adopted with enthusiasm, but it now occupies a very restricted field in gynecology.

When Schröder, in Germany, first performed hysterectomies for fibroids, he did as Spencer Wells had done in ovariectomy, strove for an ideal method, and dropped the stump into the abdomen. The large mortality which followed this plan was due we now know to deficiencies in the aseptic technique.

Another class of operators, with Kœberlè, began a plan of treatment, by clamping the stump of the excised fibroid uterus externally in the abdominal incision by the *serre-nœud*, where it became mummified in the lower angle and sloughed away, leaving a granulating pit in the lower abdomen.

Schröder attributed his mortality to two causes, the shrinkage of the stump allowing hemorrhage, and infection from the cervical canal extending into the abdominal cavity. In the extra-peritoneal clamp method of dealing with the stump, these two dangers were avoided, and this plan of operation prevailed for awhile. Dr. Joseph Price, of Philadelphia, was its most

earnest and successful champion in this country, and succeeded in engrafting his views largely in the South and West.

The next step was taken by Prof. Fritsch, of Bonn, and myself, independently, April 1889.* To avoid sepsis the stump was sewed together and then stitched or suspended to the peritoneum in the lower angle of the abdominal wound; at the same time the sutures used in sewing its lips together were left long and held by a pair of forceps lying across the wound so that the stump could be instantly everted and inspected in case of hemorrhage. The smooth convalescence of patients so treated showed that neither hemorrhage nor sepsis from the stump were in reality such great dangers as the profession at that time believed them to be.

This disposal of the dread of hemorrhage and sepsis in this manner, prepared the way for the next important step in the evolution of the subject. Now, under the improved technique, Dr. Eastman, Dr. Krug, and Prof. Chrobak began dropping the stump, and then covering it completely with the anterior layer of peritoneum.

In 1895 I originated a plan of treating myomatous uteri, which I shall now describe. Dr. Pryor, of New York, had published prior to my first publication, an account of a similar plan of treating intra-ligamentary tumors.

By my plan of operating, from half an hour to an hour is saved the patient in the enucleation stage, the most important period of the operation, for with the completion of the ablation of the tumors the question as to the possibility of operating is answered, and all important complications have been met; the steps following the enucleation are more or less routine in character. An abdominal incision is made and the ovarian vessels tied on one side; then the round ligament is tied on the same side and the top of the broad ligament opened and the incision carried across, separating vesical peritoneum from uterus; the bladder is pushed well down with a sponge; next, having in this way exposed it, tie the uterine artery near the point where it leaves the uterus in the pelvic cellular tissue. Now cut boldly across the cervix with the spud while pulling the uterus upward and outward. This develops a cellular interspace in the opposite broad ligament as soon as the cervix is completely divided, in which there is no bleeding and the uterine artery can be distinctly seen and clamped. Now pulling the uterus still further up and rolling it over, a clamp is applied to the round ligament and then to the ovarian vessels, when the fibroid uterus is cut away entirely.

*Vid. American Journal of Obstetrics, April, 1889, page 375, volume 22; also Centralblatt f. Gynecology, Nov. 1, 1889,

There is no haste throughout, but an orderly progression of steps, and yet Dr. Haggard tells me this uterus with its sixteen tumors was removed in four and a half minutes. I have done it at home in three minutes. The rest of the operation consists in applying ligatures in place of the clamps to the ovarian vessels, to the round ligament, and to the uterine artery of both sides. The cervical stump is now closed, and the bladder, peritoneum and anterior layer of the broad ligament are sewn to the posterior layer, when the female plevis is converted into the male form.

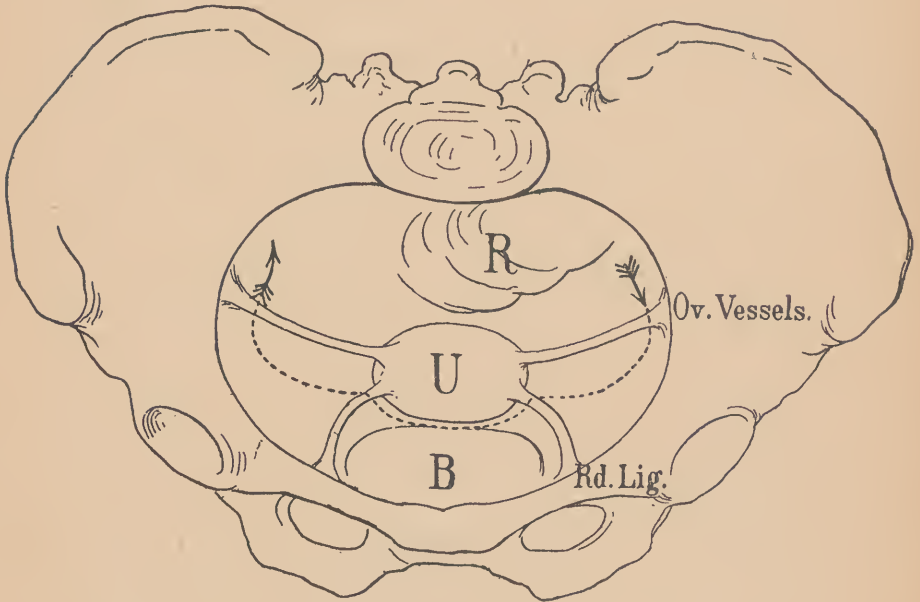


FIG. 1.

Showing line of incision through peritoneum from left to right, through left broad ligament, round ligament, utero-vesical peritoneum, right round ligament, and ending with right broad ligament near the pelvic brim.—*Johns Hopkins Hospital Bulletin*.

There is an occasional interruption in convalescence. If there is hemorrhage into the cellular tissue, causing hematoma or pus, divulge the cervix and let it out. If there is extensive hemorrhage into the cellular tissue, a small drain should be placed in the cervix.

Fibroid uteri should be treated in this way only when they produce symptoms serious enough to justify hysterectomy. If there is but moderate discomfort at the menstrual period, don't remove the organs. But, if there is constant hemorrhage, pain,

severe pressure symptoms, a choked pelvis causing pressure on the ureters, or changing the functional activity of bowel and bladder, operate at once.

When asked why he left the ovaries, Dr. Kelly replied that it was experimental, with the hope of avoiding the unpleasant sequelæ from the sudden induction of the menopause. In all recent cases he had been leaving one or both ovaries, if not displaced or diseased, and had some very satisfactory results in changing entirely the character of the convalescence and the sequelæ. It is, however, too early to speak with assurance.

The next step in the line of progress will be the removal of large interstitial myomata or multiple myomata without sacrificing the uterus or any part of it. Dr. Kelly cited cases in which he had removed seven, eight and nine tumors in this way, and demonstrated with the specimen before him the removal of sixteen myomata without opening the uterine cavity, which he said could just as easily be removed from the uterus while in situ as he had done on the specimen.

DR. CHARLES P. NOBLE, of Philadelphia:—My own experience with hysterectomy began after the pioneer work of Keith and Bantock in England, and of Schröder in Germany, had opened this field to the abdominal surgeon. My first three hysterectomies for fibroid tumors were performed after the method of Bantock, using the *serre-nœud*. These three patients recovered, but the various disadvantages about the method were such as to cause me to abandon it. The chief objections to the method are: 1. It entails sloughing of the stump above the constricting wire. From this point of necrosis, infection of the patient may take place. 2. It entails a long convalescence, as until the stump separates and the resulting wound granulates, the patient must remain in bed—from six to ten weeks being the usual time. 3. A large percentage of patients operated upon with the "*nœud*" suffer from subsequent ventral hernia. The three patients operated upon by myself by this method, each had a hernia, which required a subsequent operation. 4. It is inapplicable to certain tumors, either because of a short stump or short vagina, which makes it difficult or impossible to bring the stump up into the wound; or because of the nature of the tumor, more especially cervical fibroids, which render this technique difficult or impossible.

As the best results of those using the "*nœud*" have been improved upon by other methods which do not have the disadvantages detailed, in my opinion this method of hysterectomy has become obsolete, and the only further function of the *serre-nœud* is to serve as an object of historical interest in medical museums.

Dr. Kelly has referred to Schröder's work and outlined the

bearing which it has had upon the subsequent development of hysterectomy. Schröder was the pioneer in dropping the stump in hysterectomy, and deserves full credit for the impetus which he gave the operation. There are two reasons why his mortality was high: 1. He operated in pre-antiseptic days, and many of

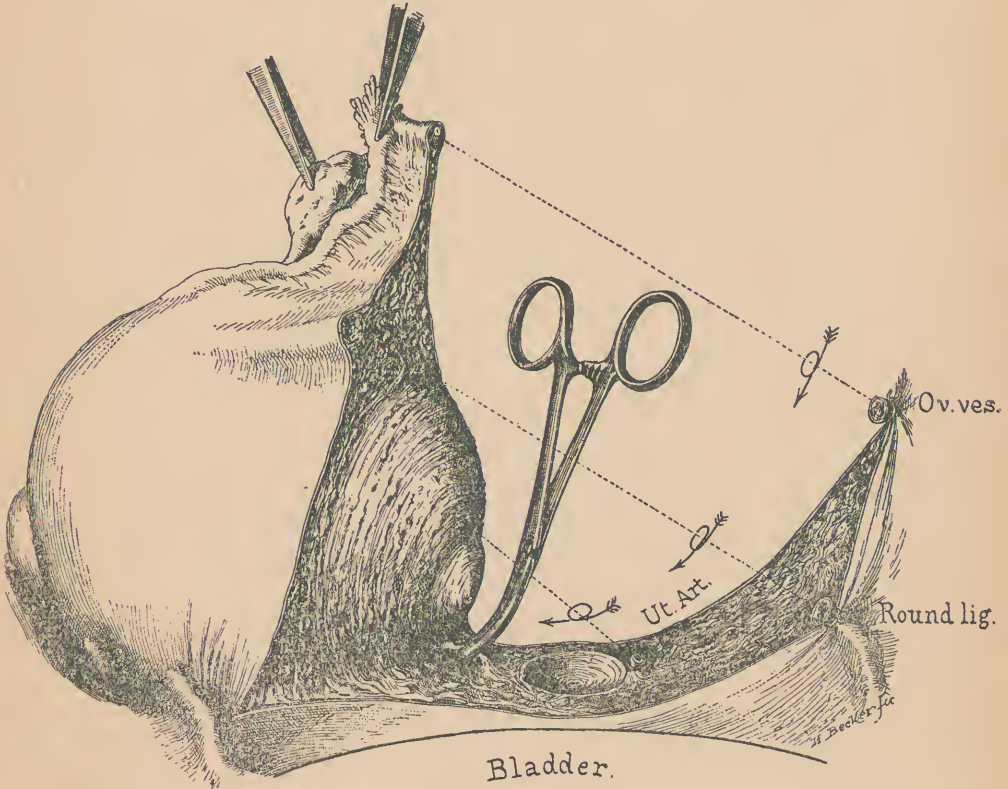


FIG. 2.

Left ovarian vessels tied, left round ligament tied, vesical peritoneum divided and pushed down and left uterine vessels ligated. Cervix amputated and uterus pulled up and out, exposing right uterine artery, which is clamped an inch above the cervical stump. The two following steps are clamping the right round ligament and right ovarian vessels, when the mass is removed.—*Johns Hopkins Hospital Bulletin*.

the patients were infected as a consequence of faulty technique.
2. He failed to recognize that hemorrhage could be controlled simply and safely by the ligation of the two ovarian and the two

uterine arteries. In his work he depended upon a multiplicity of ligatures placed in the cervix itself, rather than upon ligation of the trunks of the uterine arteries. No doubt in many cases these arteries were ligated, but this was by accident, and not by design; as a consequence, a certain number of his patients died from hemorrhage.

Dr. Kelly has treated the development of hysterectomy in his own work. It seems to me that the two essentials in the development of the modern operation of hysterectomy are the perfection of the aseptic technique, and the recognition of the ease and certainty with which hemorrhage can be controlled by ligating the trunks of the ovarian and uterine arteries. All our present good results rest upon this basis.

When I began dropping the stump in hysterectomy, for a time I placed no ligatures whatever in the cervical tissue, and as a rule, this is unnecessary to secure hæmostasis, if the uterine arteries are well ligated low down on the cervix. In none of the cases thus treated was there secondary hemorrhage. More recently to ensure against possible infection from the vagina, I have stitched up the stump with a few catgut sutures before suturing the flap of bladder peritoneum over it.

Dr. Kelly has described the excellent method of hysterectomy which he follows. There is no doubt that by this method the tumor can be quickly removed, and that in the hands of an expert, such as Dr. Kelly, it gives beautiful results. In certain cases of fibroids, notably in those intra-ligamentous in development, and others complicated by dense adhesions of one uterine appendage, this method offers great advantages over any other; but for routine work I prefer to ligate and cut down the broad ligament upon one side, then upon the other side, and to amputate the cervical stump after the blood vessels have been secured. An inexperienced operator, in following the method of Dr. Kelly, might easily lose his wits from the occurrence of hemorrhage after cutting through the stump of the cervix, and in, more or less, wildly applying hæmostatic forceps to arrest bleeding, enclose the ureter in the grasp of the forceps. This accident has happened, and resulted in the wounding of the ureter upon one side.

In the hands of an expert no operation is more simple and satisfactory than the modern hysterectomy for fibroid. There are some points, however, which might be dwelt upon with advantage. The ligature silk should be as fine as possible. The first ligature should embrace the ovarian artery upon one side. The second ligature, of very fine silk, should embrace the round ligament and the small artery and vein which accompany it. A forceps applied alongside the uterus guards against reflux hemorrhage, and permits the upper portion of the broad ligament down to, and including the round ligament, to be cut through. The peri-

toneum in front of the uterus and tumor should then be incised from one round ligament to the other, and the bladder stripped off from the cervix. It will now be found that very moderate pressure upon the open broad ligament with a sponge will push the loose connective tissue away from the uterus down to, or below the level of the internal os, and will expose the uterine artery and vein which run up along the side of the uterus. This should now be securely ligated and cut. The same process should be repeated upon the opposite side. A very important point is to be certain that the ovarian vessels are well secured by their ligatures, and also that the uterine arteries are picked up with forceps, and a separate ligature of fine silk be placed upon them, in addition to the original mass ligature. By observing these points, troublesome hemorrhage will be avoided at the time of operation, and secondary hemorrhage be reduced to a minimum. So far, in my experience, I have never seen a secondary hemorrhage after hysterectomy.

Another method of hysterectomy is to remove the entire uterus. This method has several disadvantages over the one



HYSTERECTOMY SPUD. Used instead of a knife for amputating the uterus at the cervix. The curved blade enables the operator to work easily in a deep pelvis cupping out the stump.—*Johns Hopkins Hospital Bulletin.*

described. It takes longer to do it, because the cervix must be cut out, and the bleeding resulting from cutting through the vagina requires a certain amount of time for its arrest. Another objection, and the more important one, is that the cavity of the vagina is opened and brought in communication with that of the peritoneum. This greatly increases the risk of septic peritonitis. Careful studies of the endometrium in uteri removed by hysterectomy have shown that the endometrium at the level of the internal os is almost, if not constantly, sterile; while it is well known that the vagina constantly swarms with germs. Careful preparation of the vagina before operation, of course, reduces the risk of infection, but does not remove it. As bearing upon the relative advantages of the two methods, it is worth recalling that most of the American gynecologists who have been the advocates of pan-hysterectomy have abandoned abdominal for vaginal hysterectomy whenever the size of the tumor permits. This indicates that their experience was for some reason unsatisfactory, as

the same is not true of those who have made the supra-vaginal amputation.

The French school of surgeons have applied the method of vaginal hysterectomy to the removal of small fibroids, including in this classification all those which do not extend above the umbilicus. The results which they have obtained have been good, but the method seems crude to one who is a master of the niceties of abdominal hysterectomy. During the past summer I had the pleasure of witnessing a hysterectomy by Ségond, of Paris, and am sure that none of its advocates can perform the operation more skilfully than it was done in this case. The two methods may be contrasted as follows:

When an abdominal hysterectomy is completed in an aseptic case, the parts are left in condition for immediate healing. Twelve or twenty-four hours suffice to cover over any peritoneal wounds, and the patient proceeds at once with her convalescence. With the modern method of closing the abdominal wound, by buried and intra-cuticular sutures, the entire operative process is complete at the conclusion of the operation, and the patient is not further disturbed even for the removal of sutures. In the vaginal operation, hemorrhage is guarded against by the use of heavy clamps, which ensures the sloughing of all tissues included in the bite of the forceps. The forceps themselves must remain on for twenty-four hours or longer, giving considerable annoyance to the patient by their presence. As the peritoneal cavity is left in open communication with the vagina at the end of the operation, it is necessary to pack the wound with gauze to invite a localized peritonitis, so as to guard the peritoneal cavity from infection from the inevitable sloughing of the stumps. This process involves, at the best, a foul-smelling septic discharge, which, if it does not infect the particular patient, is a source of possible contamination of others operated upon later, as the hands of the operator may become infected in the subsequent dressing of the patient. At the best, the convalescence of the patient is postponed until localized peritonitis has shut off the field of operation and until the sloughing process is complete. The contrast in the two classes of cases is so great that I find it difficult to understand how the vaginal operation can appeal to one whose aim is the highest development of surgery.

There remains the question of the relative frequency with which the operation for fibroids should be done. My work in the past has been in very close agreement with the principles laid down by Dr. Kelly, but the more I see of fibroid tumors the more I am inclined to broaden the field of operative treatment. This tendency is due to my experience in dealing with degenerated fibroids, and because I have been obliged to operate a large number of times in women of advanced age because of complica-

tions due to the degeneration of fibroids, or on account of secondary diseases arising from their presence. The old theory that the menopause is curative of fibroids of the uterus is very far from correct. It has no influence whatever upon soft fibroids, and but little influence upon many of the hard variety. Its influence is most marked in multinodular fibroids of small size. As I have been obliged to operate numerous times in women of advanced age because of necrotic, calcareous, or myxomatous degeneration, and in a smaller number of cases in younger women on account of sarcomatous degeneration, I am led to question the advisability of permitting fibroids to run their natural course, even though producing minor symptoms when they come under observation. The question may well be asked, what does it profit a woman to retain a fibroid tumor in her economy? Not to go into this question too much at length, I will say that while I would not maintain the position that every fibroid should be removed so soon as a diagnosis is made, I believe the next advance in dealing with this subject will be the more general advocacy of operation early in the course of the disease, with the definite object of conserving the sexual organs. Operations done early, when the patient is in good condition, will permit of the more frequent adoption of myomectomy, which will cure the patient, and at the same time leave the sexual organs intact. This, I repeat, will be the next advance in the field of gynecology.

DR. HENRY D. FRY, of Washington City:—The subject has been so ably and exhaustively treated by the speakers who have preceded me that very little remains to be said concerning the technique of the operation for the removal of fibroma uteri.

Personally, I have had no experience with the method of freeing and cutting away one side first, and then amputating the uterus, and, finally, cutting away the remaining broad ligament. I entered the field about the time when the extra-peritoneal treatment of the stump was being abandoned. Excluding the comparatively small number of cases in which complete hysterectomy was indicated, I have followed the plan of cutting both broad ligaments and amputating the uterus at the internal os.

To introduce another phase of the subject I would ask, what is to be done with the mass of women who have fibroids and apply for relief? Are they all to be subjected to the radical operation? Few of them may be able to obtain the skill of the masters of the profession, and must they submit to the increased risks of an operation at less skilled hands? It is true that certain dangers are run by the presence of fibroids after the menopause; they may undergo malignant degeneration; they may become cystic; they may continue to grow; but will they kill as many as the knife if promiscuously used?

It is a far more common experience that they become quiescent or diminish after the climacteric.

I do not wish it understood that I deprecate hysterectomy for fibroids. I only desire to emphasize the point, that we must select cases for operation, and not look upon every woman having a tumor as a necessary candidate for our surgical enthusiasm.

Now, the principal symptoms which bring these cases to us are hemorrhage and pressure effects. A certain proportion can be relieved by paliative treatment, while in a large number of those suffering from metrorrhagia complete relief is obtained by removal of the tubes and ovaries in selected cases. In my experience, this method has given perfect satisfaction. It is certainly less dangerous than the radical operation, except in skilled hands.

I wish to say a word in regard to the method mentioned to-night of leaving one ovary, or both, when performing hysterectomy; and that word is a protest.

Formerly it was advised to *take out the ovaries and leave the tumor*, now it is proposed to *take out the tumor and leave the ovaries*. The only argument advanced in support is, to prevent the artificial production of the menopause and consequent reflex phenomena. Now, these phenomena are the same in kind and quantity as accompany the natural change of life, and if the woman survives the operation she will go through with them at that time. She does not escape, therefore, why not do a complete operation and let her have it all over? Removal of the uterus removes the physiological importance of the ovaries. There are objections, on the other hand, to the practice of leaving one or both. Degenerative changes may take place, ovarian tumors may develop. The woman may have an abdominal pregnancy. Some women will have a baby even after the uterus is removed, as in the case reported by Kœberle, where the spermatozoids passed through a fistulous tract left after vaginal hysterectomy.

For these reasons, that further complications may ensue by leaving an ovary, I do not endorse the suggestions unless some good ground could be advanced to support it.

DR. WILLIAM D. HAGGARD, JR., of Nashville:—I have been very much impressed with the method of hysterectomy devised and employed by Dr. Kelly. The case which he has referred to, and in which I had the pleasure of assisting him, I regard as one of the most masterful pieces of surgery it has ever been my privilege to witness. All my later training has been in total hysterectomy, and the cases I have done have all been by that method. I admire the beauty and perfection of the technique described to us to-night, but I must object to the strictures placed upon total hysterectomy by Dr. Noble. In seventy-three abdominal hysterectomies occurring in the Woman's Hospital last year, I am positive quite seventy of them were total.

It has been alleged that it takes longer. "Cutting the cervix out" is not a separate step, but only requires stripping the peritoneum down a trifle further than when amputating at the internal os. Ligating the uterine arteries is required in both, after which amputation is made at the vaginal vault rather than above it. The cut end of the vagina rarely requires ligature. When the tumor is removed, hemostasis is complete, and there are no vessels, stump, or peritoneal flaps requiring ligature or suture, and the operation is concluded. What is gained in the rapidity of enucleation by the other method is equalized by the stages of ligaturing and suturing. Hence a contrast of time from the beginning to the completion of both will not show a gain where supra-vaginal amputation is made.

The danger of opening into the vagina seems more theoretical than real. Careful preparation of the vagina, although it constantly swarms with germs, appears to be effectual in curettage, where the uterine mucosa is denuded and lymph channels left open; suppuration is rare in extensive plastic operations on the vagina itself; infection is almost unknown in explorative vaginal section, where the vagina and peritoneum are in continuous and practically unobstructed communication; and the advocates of vaginal ovariectomy and hysterectomy *per vaginam* base their very low mortality on the immunity from sepsis by this method. Moreover, germs in the vagina were evidently not the determining factor that induced certain American gynecologists to abandon total abdominal hysterectomy for total hysterectomy *per vaginam*, as now they deliberately choose the vagina as their avenue of approach. I regard Krug as the chief exponent of pan-hysterectomy in this country, and I believe his allegiance to the abdominal route is still unshaken.

Personally, I am not prepared to champion the vaginal method in fibroma with the same assurance that I have favored that route in septic pelvic conditions. With this element eliminated, I believe pelvic surgery is easiest done through the abdomen, in Trendelenburg's posture. This is typically true of fibroid disease, and if total hysterectomy is contemplated, the technique of Krug is very satisfactory.

The use of strong silk-loops, fixed in opposite sides of the abdominal incision, and at its lower angle, are superior to instrumental retractors. Silk is likewise employed as a temporary hemostatic to the uterine end of the tube, while the other portion of the double ligature is pulled out near to the infundibulo-pelvic ligament and made to secure the ovarian artery. The opposite side is treated similarly. Section of both broad ligaments is made with scissors close to the uterus until the vicinity of the uterine artery is reached. The lower extremities of these incisions are connected by an incision through the peritoneum cover-

ing the anterior face of the uterus. The peritoneum is pushed down until the vagina is reached and opened with scissors. A finger introduced through the opening impinges on the posterior vaginal fornix which is opened behind on the finger directly. The uterus is then moored only by the lower segments of the broad ligaments containing the uterine arteries. A double transfixion ligature is applied to this portion. The upper half tied and the superior end of the other ligature passed under the unsevered ligament containing the uterine artery and tied. It is then cut near the cervix and the corresponding side secured in like manner, and when severed completes both enucleation and hemostasis with safety and celerity. The vagina is then filled iodoform gauze, and when the patient is lowered into the horizontal position the peritoneum falls into neat approximation over the cut end of the vagina. The results are entirely satisfactory.

Perfected technique in any method is the sesame to success.

INTESTINAL OBSTRUCTION FOLLOWING ABDOMINAL HYSTERECTOMY; OPERATION; RECOVERY.*

The patient operated upon by Prof. Kelly† did well until the ninth day. Highest temperature 100° F. On the evening of the ninth day she had an attack of colic immediately after a semi-solid supper, inaugurated by vomiting. The pulse rose from 72 to 100.

She was given mercurials and aromatic spirits of ammonia by the resident physician, followed by salines in the morning. Constipation being unrelieved and pain continuing, she was given more salines and a high enema, which moved the lower bowel only.

Pulse being high, an explanation of her symptoms was sought in the abdominal incision and the cervical stump. The former had healed throughout by early and clean union; the latter was perfectly free from induration and tenderness.

On the eleventh day pain continued unabated, with vomiting; pulse remained high, and obstipation was complete in spite of all attempts to overcome it. By night her pulse was 140, distention marked, and the diagnosis of intestinal obstruction was apparent. I favored immediate operation, but my consultants insisted on waiting until morning, meanwhile giving a large dose of castor-oil and a high saline enema. Both were ineffectual.

The next morning at 8 o'clock—the twelfth day after opera-

* Reported to the Nashville Academy of Medicine at its meeting on Thursday, November 26, 1896.

† Vid. Page 1, first paragraph of remarks of Dr. Howard A. Kelly.

tion and sixty-two hours after onset of symptoms—I opened the abdomen. Pulse 156, weak and thready. The pain, distention and vomiting were all increased, but the latter was not stercoral. Coils of distended gut could be seen in peristalsis outlined through the abdominal wall. There was a point of tenderness in the left iliac region.

Section was made through the left linea semilunaris. Slight adhesions of the intestines to the line of previous incision were found, which were easily broken and the gut drawn out. A distinct adhesion flexure was found and separated. As this entire segment was collapsed, it was obviously below the real point of constriction. Continuing the search, loops of the red, angry, enormously distended gut were drawn into the incision, the proximal end being returned as it was drawn up from below. A slight transverse tear in the peritoneal coat from traction warned me that the point of anchorage was reached. Slipping my hand alongside, I found a dense adhesion, which was carefully freed and brought into view. There was a denuded area on the gut about four inches long and one inch wide. It was too extensive for peritoneal plastic operation, and the patient's condition would have hardly warranted a resection. It was dusted with iodoform in lieu of aristol.

At the site of constriction, though not participating in it, was found a long tubular band about the size of a small lead pencil and three inches long, both ends of which were attached. It was snipped with scissors. It was non-inflammatory. It may have been Meckel's diverticulum.

The rent in the peritoneal coat of the gut was closed by a continuous Lembert suture of silk, the gut returned, and the abdomen hurriedly closed with interrupted sutures of silkworm gut. A high enema of brandy and normal salt solution (one pint) was given on the table to prevent shock. Purgative saline enemas were given in four and eight hours. Bowels moved after twelve hours, fourteen times in first twenty-four hours. Gas was not passed until the next day. Convalescence was undisturbed, except for a slight sinus in the hastily closed incision.

In a recent communication, Dr. Kelly thought the obstruction due to a mild septic peritonitis with its accompanying adhesions. He further said: "There was a great deal of fingering done to release the uterus and tubes from a mass of velamentous adhesions, but I said very little about the matter as I was stripping them up, as I wanted to concentrate the attention of the class on the steps of the enucleation."

In the twenty-eight cases of intestinal obstruction in adults collected in Sajous' Annual for 1895 for the preceding year, the average time of operation was $51\frac{1}{3}$ days. There were six deaths, or a mortality of 21.4 per cent.

