


NATIONAL LIBRARY OF MEDICINE



NLM 00554811 9

Surgeon General's Office

LIBRARY

Section, *Diagnoses*

No. *7867*

Diagnoses

$\frac{14}{B}$


A PRACTICAL
TREATISE
ON
SURGICAL DIAGNOSIS

DESIGNED AS A MANUAL FOR PRACTITIONERS AND STUDENTS

BY

✓
AMBROSE L. RANNEY, A.M., M.D.

ADJUNCT PROFESSOR OF ANATOMY AND LECTURER ON MINOR SURGERY IN THE MEDICAL
DEPARTMENT OF THE UNIVERSITY OF NEW YORK



NEW YORK
WILLIAM WOOD & COMPANY
27 GREAT JONES STREET
1879

Anney

W0

R195p

1879

COPYRIGHT
1879,
BY WILLIAM WOOD & Co.

New York: J. J. Little & Co., Printers,
10 to 20 Astor Place.

TO

WILLIAM DARLING, M.D., F.R.C.S.,

PROFESSOR OF ANATOMY IN THE MEDICAL DEPARTMENT OF THE
UNIVERSITY OF NEW YORK,

AS A TRIBUTE TO HIS GENERAL SCHOLARSHIP AND HIS LIFE-LONG

DEVOTION TO A SCIENCE IN WHICH HE HAS FEW

EQUALS AND NO SUPERIORS,

AND

AS AN EXPRESSION OF THE WARMEST PERSONAL REGARD

ENGENDERED BY YEARS OF PLEASANT

INTERCOURSE,

This Work is Inscribed

BY HIS FRIEND,

THE AUTHOR.

INTRODUCTION.

AT the request of my private classes I publish this volume.

As a text book for students it will, I trust, aid memory by presenting the symptoms of diseases in *marked contrast*; while to the practising physician it may prove a book of easy reference, when questions of diagnosis arise leading towards doubt or error.

I am aware that many points of distinction given will admit of question, as authorities do not always agree. I have, however, selected from such authors as, in my opinion, best merit attention, and have avoided as far as possible all points on which argument is demanded, or from which serious error is liable to follow.

I have endeavored to make, in most instances, selections for contrast of such diseases as are most liable to be confounded, and, for perspicuity, have been forced to frequently duplicate the symptoms of many of them.

In this volume all questions of etiology, pathology and treatment have been purposely omitted, as they have no direct bearing upon diagnosis, and therefore do not properly appertain to it.

Each differentiation is, in most instances, so arranged as to allow the symptoms of each to be reviewed separately by reading from *above, downwards*; while by reading *across* the page the points of contrast become prominent.

The "Common Symptoms" written below each differentiation explain, in general, the possible causes of error in diagnosis.

At the close of this volume will be found enumerated under the head of bibliography those authors to whom I am indebted for many statements advanced and from whom occasional extracts have been given. I have adopted this method of acknowledgment since the arrangement of disease in a *tabulated form* precludes the frequent interpolation of authorities. Confusion would thus often result unless explanatory paragraphs were also inserted and the object of marked contrast in symptoms would be thus thwarted.

If I succeed in placing before students and the medical profession at large a work whose system and arrangement will probably be its chief recommendation, the object of this volume will have been accomplished.

CONTENTS.

PART I. DISEASES OF THE BLOOD-VESSELS.

GENERAL table of diseases of the blood-vessels, Aneurism, Classification of aneurism. Differential diagnoses of aneurism in general: Aneurism and tumor on an artery. Aneurism and erectile tumors, Aneurism and aortic pulsation, Aneurism and abscess over a vessel. Diagnoses of special types of Aneurism: Abdominal aneurism and abdominal tumors, Abdominal aneurism and painful diseases of abdomen, Abdominal aneurism and psoas abscess, Thoracic aneurism and intra-thoracic tumors. Thoracic aneurism and pulmonary consolidation with a murmur in some large vessel, Aneurism of bone and cancer of bone, Cirroid aneurism and pulsatile tumors of bone, Aneurism and encephaloid cancer, Aneurismal varix and aneurism, Cirroid Aneurism and erectile tumors, Cirroid aneurism and nœvi, Aneurism of arch of aorta and aneurism of the innominate artery, Varicose aneurism and aneurismal varix, Varicose aneurism and varicose veins. Diseases of the arterial coats: Atheromatous degeneration, Fatty degeneration of vessels. Diseases of the veins: Adhesive phlebitis, Suppurative phlebitis. Abnormal conditions of vessels: Embolism, Thrombosis. Pages 1-33

PART II. DISEASES OF THE JOINTS.

General classification of Joint diseases. Differential diagnoses of. I. *Diseases of the joints in general*: Synovitis and rheumatic inflammation of joints, Scrofulous synovitis and hydrarthrosis, Acute arthritis and chronic rheumatic arthritis, Acute arthritis and syphilitic periostitis near a joint, Acute arthritis and suppuration external to a joint, Bony ankylosis and fibrous ankylosis. II. *Diseases of special joints*: Morbus coxarius, its varieties, its common symptoms, its diagnosis. Differential diagnosis of morbus coxarius and congenital dislocation of the hip, Morbus coxarius and psoas abscess, Morbus coxarius and sacro-iliac disease, Morbus coxarius and trochanteric disease of the femur, Morbus coxarius and lateral curvature of the spine, Morbus coxarius and rheumatic deformity of the hip, Morbus coxarius and disease of the crest of the ilium, Morbus coxarius and inflammation of the psoas bursa, Morbus coxarius and infantile paralysis. Diagnostic points of tenderness in inflammation of the larger joints. III. *Deformities of joints*: General classification. Talipes, its varieties, Symptoms of talipes varus, Talipes valgus, Talipes equinus, Talipes equinus with paralysis of the extensor of the toes and flexors of the tarsus, Talipes valgus spurious, Calcaneo-valgus of moderate severity (Chinese foot), Flat foot, Diagnosis between spurious valgus and sprain of ankle joint.

Pages 33-67

PART III. DISEASES OF BONE.

Classification of bone diseases. Differential diagnoses of bone diseases, Osteitis and osteo-myelitis, Caries and necrosis, Osteitis and periostitis, Periostitis near a joint and acute arthritis, Abscess of bone and arthritis, Rickets and malacosteon, Exostoses and cysts of bone, Cancer of bone and pulsatile tumors of bone, Pulsatile tumors of bone and aneurismal tumors. Local types of bone diseases. Abscess of the antrum, Solid tumors of the antrum, Cystic tumors of the antrum, Malignant tumors of the antrum, Extra-cranial tumors, Intra-cranial tumors, Exostoses of the cranium. Pages 67-84

PART IV. DISLOCATIONS.

Definition, varieties, causes, and general symptoms of dislocation. Dislocations of special joints : I. *Dislocations of the jaw* : Differential diagnosis between the unilateral dislocation and bilateral dislocation, Unilateral dislocation and congenital dislocation, Dislocation of jaw and chronic rheumatic arthritis of the tempero-maxillary articulation. II. *Dislocations of the shoulder* : Classification of the varieties. Differential diagnoses between, "Sub-glenoid" dislocation and fracture of neck of humerus, "Sub-clavicular" dislocation and "sub-spinous" dislocation, "Sub-spinous" dislocation and separation of the great tubercle of the humerus, "Sub-coracoid" dislocation and "supra-coracoid" dislocation. Dislocations of the clavicle. Varieties and etiology. Subluxation of outer end of clavicle (dislocation of scapula). III. *Dislocations at the elbow joint* : Classification of, Differential diagnoses between both bones of forearm backwards and fracture of humerus above the condyles, Both bones of forearm backwards and radius forwards, and ulna backwards, Both bones of forearm backwards and both bones of forearm forwards, Both bones of forearm backwards and ulna alone backwards, Radius forwards and radius backwards, Ulna forwards and ulna backwards. IV. *Dislocations at the wrist* : Dislocations of the carpus, of the separate carpal bones, of the lower end of the ulna. Differential diagnoses between Dislocation of the carpus and Colles' fracture, Dislocation of the carpus and sprain of the wrist joint, Dislocation of the carpus and transverse fracture of both bones close to the wrist joint, Dislocation of the carpus and separation of the epiphyses of radius and ulna. Symptoms of dislocation of the lower end of the ulna forwards and backwards, and of dislocation of the os magnum. V. *Dislocations at the hip joint*. Varieties of dislocation of the upper end of the femur. Differential diagnosis between "dorsum ilii" dislocation and "sciatic notch" dislocation, "Sciatic notch" dislocation and fracture of the femur with inversion of the foot, "Pubic" dislocation and "thyroid" dislocation, "Pubic" dislocation and fracture of the neck of the femur, Dislocation of the hip and contusion over the trochanter. Table of contrast of the symptoms of each dislocation of the hip. VI. *Dislocations at the knee joint*. Varieties of dislocation of the tibia, and of the patella. Symptoms of dislocation of the tibia forwards, backwards, in rotary displacement, in lateral displacement. Symptoms of dislocation of the patella inwards, outwards, upwards, and in rotary displacement. VII. *Dislocations at the ankle joint*. Varieties of dislocation of the astragalus. Symptoms of dislocation of the astragalus forwards, backwards, externally, internally and upwards. Differential diagnosis between dislocation of the astragalus upwards and fracture of both bones of the leg, Dislocation at ankle and a severe sprain, Dislocation at ankle and a previous deformity associated with injury. . . . Pages 84-134

PART V. FRACTURES.

Definition, Varieties of fractures of long bones. Fractures of flat bones. General symptoms of fracture. Classification of special fractures. I. *Fractures of the skull*. Classification of varieties. Differential diagnoses of complete fracture of the skull and tract of outer table only, Fracture of outer and inner tables only, Fracture of inner table only and apoplexy with complicating injury, Fracture of the base of the skull and cerebral concussion, Cerebral compression and cerebral concussion. II. *Fractures of the upper jaw*. III. *Fractures of the lower jaw*. Differential diagnosis from dislocation of lower jaw. IV. *Fractures at the shoulder joint*. Classification. *Fractures of the scapula*. Differential diagnoses between fracture of body and the spine of the scapula, Fracture of the neck of the scapula and fracture of the neck of the humerus, Fracture of the neck of the scapula and dislocation of the humerus. *Fractures of the clavicle*. Varieties of and their location. Differential diagnosis between fracture of clavicle inside of coracoid process and fracture outside of the coracoid process. *Fractures of the humerus* near the shoulder joint. Varieties of and their location. Differential diagnoses between simple intra-capsular fracture and simple extra-capsular fracture, Impacted intra-capsular and impacted extra-capsular fractures, Fracture of the neck of the humerus and "sub-glenoid" dislocation, Fracture of the neck of the humerus and fracture of the neck of the scapula, Separation of the great tubercle of the humerus and "sub-spinous" dislocation. V. *Fractures at the elbow joint*. Varieties of and their location, Differential diagnoses between fracture of the condyles of humerus, fracture of coronoid and olecranon processes, fracture of the olecranon process and rupture of the triceps tendon, Fracture of the upper ends of radius and ulna, Transverse fracture of humerus and dislocation at elbow joint. VI. *Fractures near the wrist joint*. Varieties of and their location. Differential diagnoses between Colles' fracture and dislocation of the wrist, Fracture of both bones near wrist and dislocation of carpus, Separation of the epiphyses and dislocation of the carpus, Colles' fracture and transverse fracture of both bones near the wrist joint. VII. *Fractures near the hip joint*. Varieties of and their location. Differential diagnoses between simple intra-capsular fracture and simple extra-capsular fracture, Impacted intra-capsular and impacted extra-capsular fractures, Intra-capsular fracture of the femur and chronic rheumatic arthritis with contusion, Fracture of femur with inversion of the foot and "sciatic notch" dislocation of the femur, Fracture of the neck of the femur and the "pubic" dislocation of the femur. VIII. *Fractures at the knee*. Varieties of and their location. Fractures of the patella. IX. *Fractures at the ankle*. Transverse fracture of both bones of the leg. Pott's fracture. Fractures of the malleoli. Compound fractures of ankle joint. X. *Fractures of the trunk*. Fractures of the sternum. Fractures of the vertebræ. Fractures of the ribs. Differential diagnoses between fracture of the ribs and the dry stage of pleurisy associated with contusion, Fracture of the ribs and pneumothorax of a traumatic origin, Fracture of the ribs and emphysema of tissues, Fracture in general in the vicinity of joints and dislocation of bone... Pages 134-201

PART VI. DISEASES OF THE MALE GENITALS.

- I. *Diseases of the testicle*. Inflammatory orchitis. Syphilitic orchitis. Tubercular orchitis. Malignant orchitis. Cysts of testis. Sarcoma of testis. Hæmatocele of testis. Lipoma of testis. Fibrous tumors of testis. Enchondroma of testis. Benign fungus of testis (hernia testis). Chronic induration of testis. Arrested devel-

opment of testis. Congenital malformations of testis. Neuralgia of testis. Atrophy of testis. Incomplete descent of testis. Calcareous deposit of testis. Differential diagnoses between Acute orchitis and neuralgia of the testis, Syphilitic orchitis and tubercular orchitis, Malignant orchitis and syphilitic orchitis, Cysts of testicle and hydrocele, Benign fungus of testis and cancer of testicle with fungus growth, Orchitis and epididymitis. Diagnostic table of the four principal enlargements of the testicle. II. *Diseases of the tunica vaginalis and the spermatic cord.* Simple hydrocele. Hydro-sarcocele. Congenital hydrocele. Encysted hydrocele of the testis. Diffuse hydrocele of the spermatic cord. Encysted hydrocele of the spermatic cord. Varicocele. Cirsocele. Table of causes of varicocele. Lipoma of the spermatic cord. Spasm of the cremaster muscle. Differential diagnoses between Hydrocele and scrotal hernia, Varicocele and scrotal hernia, Encysted hydrocele and cyst of the testicle, Hydrocele and congenital hernia, Hydrocele of the cord and inguinal hernia, Hydrocele and hæmatocele. III. *Diseases of the bladder.* Malformations of, and its varieties: Deficiency of, Multiplicity of, Extroversion of. Inflammatory conditions: Acute cystitis, Chronic cystitis, Ulceration of the bladder, Suppuration of the vesical walls, Gangrene of the bladder. Hypertrophy. Tumors of the bladder. Bar at the neck of bladder. Hernia of the bladder. Inversion of the bladder. Rupture of the bladder. Calculi of bladder. Foreign bodies in bladder. Tubercle of bladder. Paralysis. Atony. Spasm. Neuralgia. Retention of urine. Incontinence of urine. Overflow of urine.

Differential diagnoses between, Cancer of the bladder and vesical calculus, Rupture of the bladder and retention of urine, Retention of urine and suppression of urine, Retention and incontinence due to overflow, Acute cystitis and stone in bladder, Paralysis of bladder and atony of bladder, Chronic cystitis and chronic prostatitis. IV. *Diseases of the prostate gland.* Inflammatory conditions: Acute prostatitis, Chronic prostatitis, Prostatic abscess. Hypertrophy of the prostate, Atrophy. Cancer. Tubercle. Cystic disease. Prostatic calculi. Prostatic hemorrhage. Prostatic phlebotites. Wounds of the prostate. Differential diagnoses between Acute prostatitis and chronic prostatitis, Hypertrophy of the prostate and organic urethral stricture. V. *Diseases of the urethra.* Inflammatory conditions: Gonorrhœa, Urethritis, Chancre and Chancroid of the urethra. Urethral stricture. Urethral dilatation. Urethral rupture. Urethral deformities. Urethral tumors. Urethral abscess. Urethral fistulæ. Urethral spasm. Congestive stricture. Urethral calculi. Foreign bodies in the urethra. Symptoms of urethral rupture within the triangular ligament, perineal abscess, rupture of the urethra in front of its membranous portion, rupture in front of the peno-scrotal junction, Fracture of the penis, Organic stricture, and Urethral tumors. VI. *Diseases of the penis.* Diseases of the glans penis: Balanitis, Posthitis, Herpes progenitalis, Vegetations, Venereal sores, Epithelioma. Diseases of the prepuce: Phimosis, Paraphimosis. Diseases of the corpora cavernosa: Inflammation, Calcification, Gummy tumors, Chronic circumscribed inflammation, Fracture of the penis, Anomalies of the penis.

Differential diagnoses between Chaneroid and chancre, Herpes and balanitic abrasion. Pages 201-269

PART VII. DISEASES OF THE ABDOMINAL CAVITY.

Injuries to the abdomen: Contusions, Wounds, Foreign bodies in the intestinal canal.
Diseases of the intestine: Fæcal abscess, Intestinal obstruction, Hemorrhoids, Pro-lapse of the rectum, Fistulæ of the rectum, Fissure of the anus, Stricture of the rec-tum, Cancer of the rectum, Polypi of the rectum, Pruritus ani, Neuralgia of the rec-

tum. *Hernia*. Classifications of hernia. Nomenclature of hernia. Predisposing causes. Exciting causes. Table of diagnoses of inguinal hernia. Diagnoses of femoral hernia.

Differential diagnoses between Typhlitis and perityphlitis, External hemorrhoids and internal hemorrhoids, External hemorrhoids and condylomata of anus, Internal hemorrhoids and rectal polypus, Rectal prolapse and rectal polypus, Cancer of rectum and stricture of rectum, Fissure of anus and fistulæ of rectum, Direct and indirect inguinal hernia, Serotal hernia and sarcocele, Serotal hernia and hydrocele, Scrotal hernia and varicocele, Scrotal hernia and hæmatocele, Incomplete inguinal hernia and bubo, Bubonocoele and undescended testicle, Inguinal hernia and impaction of fæces, Inguinal hernia and hydrocele of the cord, Femoral hernia and enlarged glands, Femoral hernia and psoas abscess, Femoral hernia and varix of the saphenous vein, Femoral hernia and inguinal hernia, Femoral hernia and lipoma of the femoral canal, Ventral hernia and umbilical hernia, Thyroid hernia and perineal hernia, Diaphragmatic hernia and mediastinal tumors, Congenital hernia and hydrocele, Congenital hernia and infantile hernia..... Pages 269-311

PART VIII. DISEASES OF TISSUES.

Inflammatory conditions of tissue : Tumefaction, Induration, Suppuration, Ulceration. Gangrene of tissues. Erysipelas. Elephantiasis. Lupus. Differential diagnoses between Anthrax (carbuncle) and furuncle (boil), Abscess and circumscribed local œdema, Acute abscess and chronic abscess, Iliac abscess and abscess of the abdominal walls, Psoas abscess and femoral hernia, Abscess of the abdominal walls and enlargement of the spleen, Moist gangrene and dry gangrene, Cutaneous erysipelas and phlegmonous erysipelas. *Tumors*. Classification of solid tumors. Classification of cystic tumors. Tumors classified on a basis of location. Tumors of the brain, of the scalp, of the orbit, of the antrum, of the gums, of the lips, of the tongue, of the jaws, of the parotid gland, of the thyroid gland, of the lymphatics of the neck, of the integument of the neck, of the mammary gland, of the labia of the uterus, of the rectum, of the prostate, of the testicle. Tumors of special surgical regions. Tumors of the axilla. Tumors of the groin. Cancerous tumors. Differential diagnoses between benign and malignant tumors, Scirrhus and encephaloid cancer, Epithelioma and scirrhus, Colloid cancer and scirrhus of viscera, Cancer of axillary glands and tubercular diseases of axillary glands, Cancer of the omentum and enlarged spleen. Tumors of the head : Classification of. Differential diagnoses between sebaceous tumors of the scalp and fatty tumors of the scalp, Sebaceous tumors and exostoses of the cranium, Extra-cranial tumors and intra-cranial tumors, Encephalocele and dropsy of the brain, Encephalocele and cephalæmatoma, Abscess of the antrum and solid tumors of the antrum, Epithelioma and lupus. Tumors of the Breast : Classification. Differential diagnoses between acute mammary abscess and chronic mammary abscess, Cysts of the breast and glandular tumors of the breast, Glandular tumor of the breast and hypertrophy of the mammæ, Scirrhus of the breast and innocent tumors of the breast. Tumors of the Uterus : Classification. Differential diagnoses between congestive uterine hyperæmia and the early stages of pregnancy, Fibroid tumor of the uterus and pregnancy, Retained menstrual blood and pregnancy, Uterine hydatids and pregnancy, Uterine fibroid and a solid ovarian tumor, Uterine fibro-cyst and ovarian cyst, Uterine polypus and uterine fibroid. Tumors of the ovary : Classification. Differential diagnoses between Ovarian dropsy and ascites, Fluid ovarian tumors and pelvic abscess, Unilocular ovarian cyst and venal cyst, Ovarian tumor and pregnancy. Tumors of the pelvis : Classifica-

tion. Differential diagnoses between pelvic cellulitis and pelvic peritonitis, Pelvic hæmatocele and extra-uterine pregnancy, Vaginal polypus and inversion of the uterus, Pelvic hæmatocele and extra-uterine pregnancy. Tumors of the spine : Classification. Congenital tumors of the spine. Spina-bifida. Differential diagnosis between spina-bifida and congenital fatty tumor of the spine connected with the meninges.....Pages 311-375

DISEASES OF THE BLOOD-VESSELS.

DISEASES OF THE BLOOD-VESSELS.

The DISEASES OF THE ARTERIES to which surgical attention is most frequently directed, are of two classes :

A. DISEASES OF THE ARTERIAL COATS, under which will be considered :

1. Atheroma.
2. Fatty Degeneration of the Arterial Coats.

B. DISEASES AFFECTING THE CALIBRE OF VESSELS, comprising :

1. Aneurism.
2. Occlusion of Arteries from Pressure.
3. " " " " Emboli.
4. " " " " Thrombi.
5. " " " " Foreign Bodies.

The DISEASES OF THE VEINS encountered in a surgical practice are :

1. Hypertrophy of the Venous Coats.
2. Atrophy " " " "
3. Degeneration " " " "
4. Adhesive Inflammation—"Adhesive Phlebitis."
5. Suppurative " —"Diffuse Phlebitis."
6. Varicose Tumors of Veins.
7. Obstruction to Veins from Emboli, Thrombi, and outside pressure.
8. Parasites of Veins.

Many of these diseases are with difficulty diagnosed during life by their rational symptoms, or physical signs.

The pathological evidences are often the only means of positively deciding questions of doubt in diagnosis.

It is, therefore, impossible to tabulate the symptoms of *some* with

sufficient positiveness of statement to allow of admission into a volume on diagnosis, without entering into the domain of pathology.

Such as are *so involved* are therefore purposely omitted. I begin with the consideration of ANEURISM.

ANEURISM.

By *Aneurism* is meant a tumor containing blood, and communicating with the calibre of an artery.

Aneurism may be classified from two distinct standpoints :

- 1st. On a *pathological* basis, having reference to the construction of the sac of the tumor.
- 2d. On a basis of the *anatomical* location at which the tumor is developed.

On the first basis, Aneurism may be divided into two great varieties, dependent upon the condition of the arterial coats ; under each of which may be grouped those various types of Aneurism to which a special nomenclature has been applied.

The following table will explain itself :

ANEURISM classified on a <i>pathological</i> basis. 2 great types.	A. Where all the coats of the vessel are intact. 5 varieties.	FUSIFORM ANEURISM, where all the arterial coats are equally dilated throughout the entire circumference of the vessel.
		TRUE ANEURISM, where all the arterial coats are dilated at one spot in the circumference of the vessel.
		NÆVUS, where the capillary vessels are abnormally dilated, and extensive anastomosis exists.
		ARTERIAL VARIX, where a single vessel is uniformly dilated for some distance along its course.
		CIRSOID ANEURISM, where a collection of dilated and tortuous vessels exists.
	B. Where one or more of the arterial coats is ruptured. 6 varieties.	HERNIAL ANEURISM, where a protrusion of the coats occurs through the external coat.
		DISSECTING ANEURISM, where a separation of the arterial coats by blood exists.
		DIFFUSE ANEURISM, where an escape of blood from the artery into surrounding tissues occurs.
		VARICOSE ANEURISM, where an indirect communication between an artery and a vein exists through an intervening sac.
		ANEURISMAL VARIX, where a direct communication between an artery and a vein exists.
		FALSE ANEURISM, where one coat only of the artery remains as a sac for the tumor.

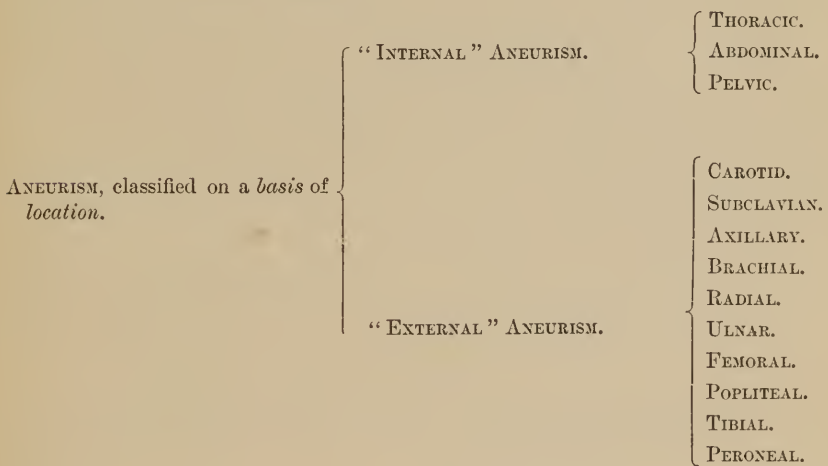
By most authors Aneurism has been differently classified, and separate divisions have been made by some to include distinctive anatomical types.

Thus, the term "*Encysted*," or "*Common Aneurism*," includes in many classifications the following varieties :

True Aneurism.
 False "
 Diffuse "
 Fusiform "
 Dissecting "

Again, the term "*Arterio-Venous Aneurism*" is used by some authors to include both "*Arterial Varix*" and "*Varicose Aneurism*," while to the "*Diffuse*" type of Aneurism the term "*Cystogenic*" was applied by Broca, and is still frequently employed.

Aneurism may be classified in the second place on the basis of its *anatomical location*, as follows :



By this classification the surgeon is enabled to designate and describe the aneurismal tumor before its exact pathological condition is determined, should such be capable of diagnosis during the life of the patient.

The diagnosis of aneurism as a disease is often difficult, and a discrimination between its types is frequently impossible.

A. It may be confounded as a *disease* with

1. A tumor lying upon some large vessel.

2. Erectile tumors.
3. Pulsation of a relaxed aorta.
4. An abscess over some large vessel.
5. Abdominal tumors.
6. Some types of painful abdominal disease.
7. Solid obscure tumors.
8. Intra-thoracic tumors.
9. Tubercular consolidation at apex of lung, complicated with an arterial murmur.
10. Psoas abscess.
11. Cancer of bone.
12. Pulsatile tumors of bone.
13. Encephaloid cancer.

B. The different *types* of aneurism may also be confounded with each other when diagnosis is possible during life, and finally,

C. The *seat* of aneurismal tumors, especially those of the *inter-nal* type, is to be differentiated by variations in the Rational and Physical Signs pertaining to the various localities in which the tumor may be situated.

ANEURISM.

TUMOR LYING UPON AN ARTERY.

CONDITION OF THE TUMOR.

The tumor is soft, elastic and compressible.

The tumor *may* be hard and inelastic.

MOBILITY.

The tumor is usually fixed.

The tumor is frequently movable.

EFFECTS OF PRESSURE.

The tumor is diminished in size on direct pressure.

The tumor is unaffected by pressure.

The tumor is diminished in size by pressure on proximal side of vessel.

The tumor is unaffected by cutting off the arterial supply above.

The tumor increases in size when pressure over the distal end of the artery is made.

The tumor is not affected by pressure made over the artery on the distal side.

AUSCULTATORY SOUNDS.

A *bruit*, or abnormal sound on auscultation, exists over the tumor.

A *bruit* may possibly be present, but is very rare.

This *bruit* is synchronous with the action of the heart, and in large vessels is often *double*.

This *bruit*, if present, is seldom constant, and seldom, if ever, *double*.

It is not affected by the position of the tumor.

It can often be arrested by change in position of the tumor.

PULSATION.

The pulsation in the tumor is *expansive*.

The pulsation, if present, is of a *heaving* character, and not *expansive*.

SYMPTOMS IN COMMON.

Both may pulsate and yield a bruit on auscultation.

- “ “ produce shooting pains along the course of nerves.
- “ “ “ stiffness in muscles, and muscular weariness.
- “ “ “ impaired motion in joints, if so situated.
- “ “ “ absorption of bone, caries, or necrosis.

ANEURISM.

ERECTILE TUMORS.

CONDITION OF THE TUMOR.

The tumor is soft, elastic and compressible.

The tumor is usually of a spongy consistence.

LOCALITY OF TUMOR.

The tumor is always located over the direct course of a vessel.

The tumor may be located where the arterial supply would be normally disproportionate to the size of the tumor.

APPEARANCE OF INTEGUMENT.

The skin is usually normal.

The skin is frequently implicated.

EFFECTS OF PRESSURE.

The distal side of the artery is usually decreased in volume.

The distal side of the main artery is often normal in volume.

PULSATION.

The pulsation is uniform throughout the tumor.

The pulsation is often marked at circumscribed spots, or centres.

The pulsation is markedly expansive.

The pulsation is often not expansive in character.

SURFACE OF TUMOR.

The tumor is smooth and regular in outline.

The tumor is often irregular on its surface, and indistinct in its outline.

AUSCULTATORY SIGNS.

A *bruit* is well marked as a rule.

A *bruit* is often absent.

SYMPTOMS IN COMMON.

Both are indicated by the presence of a tumor.

“ “ associated with pulsation.

ABDOMINAL ANEURISM. PULSATION OF A RELAXED
AORTA.

PALPATION.

A tumor is detected on palpation of the abdomen. No tumor in the abdomen is detected on palpation.

PAIN.

A *pain in the back* always exists, constant and often severe. Pain in the back, if present, is not constant or severe.

AUSCULTATORY SIGNS.

A *bruit* is heard over the seat of the tumor. No *bruit* or abnormal sound exists over the seat of pulsation.

PULSATION.

Expansive pulsation exists. The pulsation is usually of a heaving character.

PERCUSSION.

An abnormal area of dulness exists over the seat of aneurism. No abnormal area of dulness on percussion is present.

CONDITION OF VESSELS.

An atheromatous condition of the superficial vessels is often detected, or a previous traumatic history exists. No atheromatous changes are detected in the vessels, nor is a traumatic history present as a source of origin.

ŒDEMA.

Œdema of the extremities not infrequent from pressure. Œdema in lower extremities seldom present, save from other cause.

FEMORAL PULSE.

The femoral pulse is frequently decreased in volume. The femoral pulse is usually normal in volume.

SYMPTOMS IN COMMON.

Both yield an abnormal area of pulsation.
“ *may* be associated with *pain in the back*.

ANEURISM.

ABSCESS OVER A VESSEL.

OUTLINE OF TUMOR.

The tumor presents a sharp and well-defined outline.

The tumor is indefinite and obscure in outline.

SIZE.

The tumor is usually of moderate dimensions.

The tumor is often of immense size.

CONSISTENCE.

The tumor is soft, elastic and compressible.

The tumor is usually tense, or doughy from œdema.

EFFECTS OF PRESSURE.

The tumor is diminished in size by direct pressure.

The tumor is unaffected by pressure.

PULSATION.

Expansive pulsation is present.

The pulsation is heaving in character.

The pulsation is not affected by attempts to displace the tumor.

Pulsation is often arrested by attempts at displacement.

APPEARANCE OF SKIN.

The skin is usually normal in appearance over tumor.

Skin is usually red and œdematous.

FLUCTUATION.

Fluctuation is seldom present.

Fluctuation distinct during the advanced stages.

TEMPERATURE.

The local and general temperature is usually normal.

The local and general temperature is elevated.

CONSTITUTIONAL SYMPTOMS.

Chills and rigors are absent.

Chills and rigors are frequent as pus forms.

SYMPTOMS IN COMMON.

Both are indicated by the existence of a tumor.

“ “ often associated with pulsation.

“ “ “ “ “ pain.

ABDOMINAL ANEURISM.

ABDOMINAL TUMORS.

MOBILITY OF TUMOR.

The tumor is *immovable* as a rule. The tumors are movable as a rule.

LOCALITY OF TUMOR.

The tumor is situated in the line of the artery. Abdominal tumors are often not in the line of the artery.

CONDITION OF TUMOR.

The tumor is soft, elastic and compressible. Abdominal tumors are frequently hard, and seldom elastic.

PULSATION.

Expansive pulsation exists. Pulsation is either absent, or heaving in character.

AUSCULTATORY SIGNS.

A *bruit* (synchronous with the heart, and often double) is present. Abnormal auscultatory sounds are usually absent.

EFFECTS OF PRESSURE.

A diminution in the size of the tumor occurs from direct pressure. No variation in the size of the tumor is detected on pressure being applied.

PAIN.

A *constant pain* in the back exists (diagnostic). Pain is often absent, or localized over the tumor.

FEMORAL PULSE.

The femoral pulse is often decreased in volume. The femoral pulse is seldom affected, save when the tumor is very large.

SYMPTOMS IN COMMON.

Both are indicated by a tumor.

“ *may* be in the line of a vessel.

“ “ associated with pulsation.

“ “ “ “ pain.

“ “ “ “ change in volume of femoral pulse.

ABDOMINAL ANEURISM.

PAINFUL ABDOMINAL
DISEASES.

Neuralgia, Renal, Intest. and Biliary Colics, etc., etc.

PALPATION.

A tumor is often detected by inspection and palpation, which is *immovable*.

No tumor can be perceived either on inspection or palpation.

PAIN.

A pain exists in the *lumbar region*, which has been long continued, constant and distressing.

The pain is paroxysmal, with intervals of relief, and usually of short duration. It is seldom if ever local, or lumbar in location, but is diffused in some particular direction.

PULSATION.

Expansive pulsation is detected.

No pulsation is present.

AUSCULTATORY SIGNS.

A *bruit*, often systolic and diastolic, is heard over the seat of pain.

No *bruit*, or abnormal auscultatory sound, is heard.

SYMPTOMS IN COMMON.

Both are associated with *pain*.

“ *may* be apparently unassociated with a tumor.

Pulsation and bruit may be undetected *possibly* in both.

ANEURISM OF ABDOMEN.

PSOAS ABSCESS.

TUMOR.

The tumor is usually circumscribed and of moderate dimensions.

The tumor is situated in the track of the aorta, or of some large vessel of the pelvis.

No tumor is perceived below Poupart's ligament in the groin.

The tumor is elongated in shape, as detected by palpation and percussion.

The tumor is located over the track of the psoas muscle, at the outside of spine.

A tumor is perceived in the groin below Poupart's ligament.

FLUCTUATION.

Fluctuation is absent as a rule, but if present, is felt over the site of the tumor.

Fluctuation is often present in the thigh over the location of the tumor.

AUSCULTATORY SIGNS.

A *bruit* is present on auscultation.

No abnormal auscultatory sounds are perceived.

FEMORAL PULSE.

Femoral pulse often decreased in volume.

Femoral pulse normal in volume.

HISTORY OF PATIENT.

No history of spinal disease exists.

A history of spinal disease is present, and often precedes the appearance of the tumor.

PULSATION.

Pulsation of an expansive character exists.

No pulsation is detected as a rule.

SYMPTOMS IN COMMON.

Both are associated with *pain in the back*.

“ “ “ “ a tumor in abdomen.

“ *may* be associated with fluctuation.

THORACIC ANEURISM.

INTRA-THORACIC TUMORS.

LOCATION OF TUMOR.

The tumor is always located in the course of the aorta.

The tumor may possibly be situated away from the direct track of large vessels.

DENSITY OF TUMOR.

Tumor is only moderately resistant to pressure.

The tumor is usually hard and markedly resistant to pressure.

AUSCULTATORY SIGNS.

A *bruit* is heard over the tumor, on auscultation.

No *bruit* is present, unless the tumor is in close relation to some large vessel.

PERCUSSION.

The area of dulness on percussion over the tumor is limited in extent.

The area of dulness on percussion is often extensive.

PULSATION.

The pulsation perceived is *expansive* in character.

Pulsation is usually absent, but when present is *heaving* in character, save in malignant disease, when expansive pulsation may exist.

CONDITION OF FACE AND NECK.

Swelling and œdema of the face and neck exist, but *vary* in their severity and extent, because of changes in the line of pressure from the tumor.

Swelling and œdema of the face and neck, when present, are persistent and *constant* in their extent and severity.

SYMPTOMS IN COMMON.

Both are associated with local dulness on percussion.

“ “ “ “ swelling and œdema of face and neck.

“ “ “ “ possible dyspnoea, cough, pain and impaired deglutition.

THORACIC ANEURISM.

CONSOLIDATION AT APEX
OF LUNG.

*With a murmur in some vessel of
Thorax.*

INSPECTION AND PERCUSSION OF CHEST.

A *tumor* is usually detected within the thorax on inspection, palpation, or percussion.

No tumor is detected on palpation, but an area of dulness at the apex is perceived.

PULSATION.

Pulsation is often perceptible over the seat of tumor.

Pulsation is absent.

AREA OF DULNESS.

Dulness on percussion often extends beyond the median line of the thorax.

The area of dulness is always circumscribed.

The area of dulness on percussion is always confined to one side, unless both apices are affected.

The area of dulness is extended laterally downwards into the axilla.

AUSCULTATORY SIGNS.

The murmur heard is generally diffused over an extended area.

The murmur is heard only over the direct course of the vessel, and is most distinct over the consolidated lung tissue.

SYMPTOMS IN COMMON.

Both are associated with *localized dulness* on percussion.

“ “ “ “ a *murmur* on auscultation.

ANEURISM OF BONE.

CANCER OF BONE.

LOCALITY OF TUMOR.

The tumor occurs in the line of some vessel.

The disease affects the articular heads of long bones, especially the lower end of the femur.

CONDITION OF TUMOR.

The tumor is irregular in shape, and painful.

The tumor is hard, irregular, incompressible and painless in *its earliest* stages.

CONSISTENCE OF TUMOR.

The tumor is of uniform consistency.

The tumor becomes elastic and fluctuant *in spots* during the advanced stages.

RAPIDITY OF THE GROWTH.

The tumor grows slowly.

The tumor grows rapidly and often attains immense size.

EFFECTS OF PRESSURE.

The tumor is modified in size and appearance by impeded circulation, through pressure on the supplying vessel.

The tumor is not affected by pressure, or by impeded vascular supply.

MOBILITY.

The tumor can often be partially separated from the bone.

The tumor is immovably attached to the bone.

APPEARANCE OF VEINS.

The superficial veins are normal in appearance.

The superficial veins are markedly enlarged.

ANEURISM OF BONE

(continued).

CANCER OF BONE

(continued).

PAIN.

Pain is slight, and is rather an *uneasy* feeling than severe.

Pain is deep, lancinating and constant : occurs often early in the disease.

PULSATION.

Pulsation is detected early.

Pulsation is detected late in the disease, and is often absent.

FUNGOID.

No tendency to fungoid growth exists.

“Fungoid excrescences” are frequent.

CACHEXIA.

No cachexia is apparent.
The neighboring glands are normal.

A marked cachexia exists.
The neighboring glands are often involved.

SYMPTOMS IN COMMON.

Both are common in *young people*.

“ pulsate.

“ are indicated by a tumor.

“ may produce pain.

CIRSOID ANEURISM.

PULSATILE TUMORS OF
BONE.

MOBILITY OF TUMOR.

The tumor is unconnected with the adjacent bone.

The tumor is firmly attached to the adjacent bone.

OUTLINE OF TUMOR.

The edges of the tumor are indistinct. It seems to arise by distinct cords beneath the integument.

The edges of the tumor are dense and hard.

PULSATION.

Pulsation is marked, and is expansive in character.

Pulsation is indistinct, and is not markedly expansive in character.

PALPATION.

The walls of the tumor are irregular and knotted, but are soft to the touch.

The walls of the tumor are irregular in their outline, but contain spots of ossification.

EFFECTS OF PRESSURE.

The tumor is altered in its size and appearance by direct pressure, or by pressure over its supplying vessel.

The tumor is only slightly modified by pressure either upon itself or its nutrient vessel.

SYMPTOMS IN COMMON.

Both are associated with the pressure of a tumor.
 “ “ “ “ pulsation.

ANEURISM.

ENCEPHALOID CANCER.

RAPIDITY OF GROWTH.

The tumor grows slowly.

The tumor is of rapid growth.

CONSISTENCE.

The tumor is of uniform consistency and seldom fluctuates.

The tumor is of unequal consistency, being soft and fluctuant often in spots.

MULTIPLICITY.

The tumor is seldom multiple.

The tumor is frequently multiple.

GLANDS.

The neighboring glands are unaffected.

The neighboring glands are usually involved.

CONDITION OF VEINS.

The veins are normal in their appearance.

The superficial veins are prominent and tortuous.

PULSATION.

The pulsation is *expansive* in character, and exists from the commencement.

The pulsation within the tumor appears only in the advanced stages, and is *heaving* in character.

PAIN.

Pain is often absent, and, if present, is frequently referred to distant localities.

Pain is an early and active symptom. Is severe and lancinating in character.

EFFECTS OF PRESSURE.

Marked alteration in the size and appearance of tumor follows impeded circulation within it, or direct pressure upon it.

The effects of pressure, either upon the tumor or its supplying vessel, are unimportant.

SYMPTOMS IN COMMON.

Both are associated with the pressure of a tumor.

“ “ “ “ pulsation.

“ “ “ “ pain.

ANEURISM.

ANEURISMAL VARIX.

CONDITION OF SKIN.

The tumor is covered by normal integument.

The tumor, if near the surface, is usually blue or purple in color.

RAPIDITY OF GROWTH.

The tumor is sometimes rapid in its growth.

The tumor grows slowly as a rule.

CONDITION OF THE VEINS.

The veins are normal in the vicinity of the tumor, both as to their direction and apparent structure.

The vein implicated becomes enlarged, tortuous, and sacculated. The venous coats also become thickened, so as to resemble those of an artery.

FORCE OF PULSE.

The arterial volume and force of the pulse are either normal or decreased.

The force of the arterial pulse is usually preternaturally increased.

AUSCULTATORY SIGNS.

A *bruit* of a blowing character is usually present.

A "*pathognomonic fremitus*" is heard over the tumor, resembling the "buzzing of an insect," "the purring of a cat," etc.

This *bruit* is not continuous.

A "continuous souffle" is heard in the vein.

No venous pulsation exists.

A "*venous pulsation*" is present, which is synchronous with the heart's action, and which is increased by pressure on the proximal side of the vein.

ANEURISM
(continued).ANEURISMAL VARIX
(continued).

EFFECTS TO PATIENT.

The patient is unconscious of any abnormal sound or sensation within the tumor.

The patient is conscious of the peculiar fremitus, which affects the sleep, and leads also to a belief that an insect is imprisoned.

VENOUS RETURN.

The venous return is usually unimpaired.

The venous return is usually interfered with, resulting often in œdema, coldness, pain, atrophy, etc., etc.

SYMPTOMS IN COMMON.

Both are indicated by the existence of a tumor.

“ “ “ “ “ “ “ “ pulsation.

“ “ “ “ “ “ “ “ abnormal sounds.

“ “ affected by pressure over tumor and its supplying vessel.

CIRSOID ANEURISM.

ERECTILE TUMORS.

APPEARANCE OF TUMOR.

The tumor is always irregular in shape, and distinct pouches are often present.

The tumor frequently reveals distinct arterial convolutions.

The tumor apparently arises from distinct cords underneath the integument.

The tumor is often uniform in its general contour.

No distinct arterial convolutions are detected, as a rule.

The tumor is usually very indistinct in its outline.

FLUCTUATION.

Fluctuation is infrequent, but may exist when the vessels are very large.

Fluctuation is usually detected within the tumor.

PULSATION.

Pulsation is strongly marked throughout the entire tumor.

Distinct *points* of pulsation are usually detected.

LOCATION OF TUMOR.

This type of aneurism is most frequently confined to the temporal, occipital and posterior auricular arteries.

No particular anatomical location is especially prone to become affected.

SYMPTOMS IN COMMON.

Both are indicated by a tumor.

“ “ associated with pulsation.

“ *may be* “ “ fluctuation.

CIRSOID ANEURISM.

NÆVI.

ORIGIN OF TUMOR.

The tumor is seldom congenital. The tumor is usually congenital, but may develop even after puberty.

LOCATION OF TUMOR.

The tumor is seldom sub-mucous in situation. The tumor may be either sub-mucous, or sub-cutaneous in character.

The tumor is most frequent upon the scalp. The tumor is most frequent upon the face.

APPEARANCE OF TUMOR.

The tumor is knotty and irregular in shape. The tumor may be markedly elevated or flattened, but is uniform in appearance.

AUSCULTATORY SOUNDS.

A "bruit" is detected, but has simply a blowing quality. A peculiar "cooing noise" is often detected in auscultation.

PULSATION.

Pulsation is usually detected on palpation. Palpation often perceives a peculiar "vibratory thrill."

SYMPTOMS IN COMMON.

Both are associated with a tumor.

"	"	"	"	pulsation.
"	"	"	"	bruit.
"	"	"	"	altered color of skin.
"	"	"	"	elasticity and soft consistence.
"	"	"	"	alteration in the appearance of tumor on impeding venous return.

ANEURISM OF ARCH OF AORTA. ANEURISM OF INNOMINATE.

CONDITION OF FACE AND EXTREMITIES.

The entire face, neck and both upper extremities are frequently livid, swollen and œdematous from pressure on the vena cava.

The right side only is affected, with obstructed venous return, as a rule.

APPEARANCE OF THORAX.

The bulging of the chest wall over the tumor is often located on the *left* side, when present.

The bulging of the chest wall, if present, is confined to the *right* side of the thorax.

LOCATION OF TUMOR.

The tumor is seldom, if ever, felt in the neck.

The tumor is often felt above the thorax, in the neck.

PULSATION.

Pulsation may often be detected by pushing the fingers down behind the sternum, if direct palpation fails to perceive it;—or, by placing one hand on the sternum and one hand on the back, pulsation, if indistinct, may be perceived.

Pulsation is usually detected by direct palpation over the right sterno-clavicular articulation.

EFFECTS OF PRESSURE.

Pressure on the right carotid, or right subclavian artery fails to diminish the pulsation.

Pressure upon the carotid, or subclavian artery of the right side causes either a marked decrease in, or a total arrest of the pulsation within the tumor.

SYMPTOMS IN COMMON.

Both are associated with an altered appearance of the face.

“ “ “ “ frequent bulging of the thorax.

“ “ “ “ pulsation and a bruit.

VARICOSE ANEURISM.

ANEURISMAL VARIX.

ANATOMICAL CONDITION.

The artery and the vein are in communication, indirectly, through an intervening sac or tumor.

The artery and the vein have a *direct* communication. No intervening sac or tumor exists.

CONDITION OF VENOUS COATS.

The venous coats are not markedly altered.

The venous coats are greatly thickened, and resemble those of an artery.

AUSCULTATORY SOUNDS.

The "bruit" is *harsh* in character, and is heard most distinctly over the intervening sac.

The pathognomonic "buzzing fremitus" exists, and is widely diffused.

It is seldom carried into the vein.

It is equally detected in both vein and artery.

SYMPTOMS IN COMMON.

Both yield a "vibratory thrill" on palpation.

" " " venous pulsation.

" are associated with change in the color of adjacent skin.

" " " " defective venous return (often).

" " " " alterations in size and appearance, on pressure upon, or obstructed circulation within the artery.

VARICOSE ANEURISM.

VARICOSE VEINS.

PULSATION.

Venous pulsation is present.

No pulsation in the vein is perceived.

BRUIT.

A *bruit* can be heard over the tumor, which is *harsh* in character.

No *bruit* is heard over the tumor.

VOLUME AND FORCE OF PULSE.

The force of the arterial pulse is often affected, and the volume frequently diminished.

The volume and force of the arterial pulse below tumor correspond with that of opposite side.

EFFECTS OF PRESSURE.

The tumor shows marked alteration in its size and appearance by pressure on the artery.

The tumor is unaffected by pressure upon the arterial vessel below or above the tumor.

CONDITION OF SUPERFICIAL VEINS.

The superficial veins may be normal. The deep veins are usually engorged from defective *vis-a-tergo*.

The veins are seen to be tortuous and dilated on the surface.

SYMPTOMS IN COMMON.

Both are associated with a tumor.

“ “ “ “ discoloration of the integument.

“ “ “ often with pain over seat of tumor.

“ “ “ “ “ impaired usefulness of limb.

“ “ “ “ “ “ venous return.

ATHEROMA OF VESSELS. FATTY DEGENERATION OF VESSELS.

ORIGIN.

Atheroma may result from age, chronic alcoholism, gout, rheumatism, syphilis, exposure, or traumatism; all of which tend to produce a condition of chronic endarteritis.

It is most frequent in the male.

It may affect veins when exposed to irritation, as in *Aneurismal Varix*.

It may be *primary*, when occurring in the old from general impairment of activity, and is in this case usually accompanied by similar changes in other parts; or,

It may be *secondary* to increased nutritive activity of the affected parts, as occurs in atheroma.

CONDITION OF VESSELS.

Rings of ossification are usually detected as the finger is moved along the affected vessel.

The affected vessels become liable to rupture from slight accidents, as a result either of ulceration of their walls, or a rigid and brittle condition of their coats.

When ligation is demanded, the loss of contractile power in the vessel and frequent breaking of the artery betray the disease.

Spots of ossification are absent, if uncomplicated by atheroma; but a condition of defective contractility exists, as shown by the effects of cold, stimulation, etc.

The affected vessels show no decided tendency to easy rupture, unless an atheromatous condition exists.

The ligation of fatty vessels is not associated with frequent breaking of the vessel, nor is its contractile power so seriously impaired.

SYMPTOMS IN COMMON.

Both	frequently	are	associated	with	diminished arterial volume.
“	“	“	“	“	dilatation of vessel at the affected portion.
“	“	“	“	“	tortuosity of the vessel.
“	“	“	“	“	impaired nutrition to tissues when excessive arterial supply is demanded, as in inflammation.

EMBOLISM.

THROMBOSIS.

DEFINITION.

Is an obstruction to a vessel, usually arterial, by a previously moving body.

Is an obstruction to a vessel, usually of the venous system, by a coagulum of blood formed at the seat of obstruction.

ORIGIN.

The embolus may arise from fibrinous vegetations on the heart valves, resulting from a previous endocarditis, from small blood coagula floating in the current, or from foreign bodies in the circulation.

The thrombus may be the result of injury, inflammation, pressure from tumors or ligature, enfeebled or obstructed heart's action, or an altered and abnormal blood condition predisposing to coagulation or producing irritation of the vessels.

LOCATION.

If of cardiac origin, the embolus most frequently lodges in the left middle cerebral artery. If due to disintegrated coagula, the lungs and abdominal organs are more frequently involved.

May affect any situation if an exciting cause exists.

ŒDEMA.

Œdema is seldom present as the arteries are chiefly involved.

Œdema is a common symptom from obstruction to the venous return.

PARALYSIS.

Sudden paralysis, usually hemiplegic, and *aphasia* are produced by cerebral embolism.

Aphasia is not usually present in cerebral thrombosis, and paralysis may be absent.

ADHESIVE PHLEBITIS.

SUPPURATIVE PHLEBITIS.

ORIGIN.

This condition is primarily one of the venous coats.

This condition always begins in tissues external to the vein.

DEVELOPMENT.

It is usually a circumscribed disease.

It is rapidly extended along the course of veins, usually from the smaller toward larger trunks.

GENERAL HEALTH.

It may occur in normal health.

Occurs in abnormal conditions of the system or in debility, but never in robust health.

HISTORY.

It may follow injuries, ligature, amputations, or abnormal blood conditions predisposing to irritation.

It may follow any form of local irritation, as in venesection, ligature of veins or the inclusion of vena comites with large arterial trunks. It occurs in infants from ligating the funis.

PYÆMIC SYMPTOMS.

Pyæmic symptoms are absent, as the coagulum in the vein does not disintegrate.

Pyæmic symptoms are usually produced by disintegration of the thrombus formed in the vein, and by occlusion, from the loosened detritus, of capillaries in other organs.

SYMPTOMS IN COMMON.

Both may be associated with pain.

“ “ “ “ “ œdema.

“ “ “ “ “ prominence of neighboring veins.

DISEASES OF THE JOINTS.

DISEASES OF THE JOINTS.

The *surgical* DISEASES OF THE JOINTS include :

- | | | |
|--|---|--|
| <p>A. INFLAMMATORY DISEASES.</p> <p style="padding-left: 2em;">1st. Of the synovial membrane : “<i>Synovitis</i>.” 9 varieties.</p> <p style="padding-left: 2em;">2d. Of the general structures entering into the formation of a joint: “<i>Arthritis</i>.” 4 varieties.</p> | } | <p>Acute.</p> <p>Subacute.</p> <p>Chronic.</p> <p>Scrofulous.</p> <p>Rheumatic.</p> <p>Gouty.</p> <p>Pyæmic.</p> <p>Gonorrhœal.</p> <p>Syphilitic.</p> |
| <p>B. ANCHYLOSIS—varieties, { 1. Fibrous.</p> <p style="padding-left: 2em;">2. Osseous.</p> <p>C. DROPSY OF JOINTS : “<i>Hydrarthrosis</i>.”</p> <p>D. ARTICULAR NEURALGIA.</p> <p>E. LOOSE CARTILAGES IN JOINTS.</p> <p>F. CONGENITAL AND ACQUIRED MALFORMATIONS.</p> | } | <p>Acute.</p> <p>Chronic.</p> <p>Rheumatic.</p> <p>Syphilitic.</p> |

The various forms of *Synovitis* differ in their symptoms only in degree and causation, and are chiefly diagnosed from each other by the previous history of the patient and the severity of the inflammatory changes.

I have, therefore, omitted many differentiations which might appear strained or self-evident.

I shall consider the various surgical affections of the joints in the following order :

- I. *Diseases of Joints in general.*
- II. *Diseases of Special Joints.*
- III. *Congenital or acquired Deformities of Joints.*

I. DISEASES OF JOINTS IN GENERAL.

SYNOVITIS.

Is a purely local inflammation independent of blood condition.

RHEUMATISM.

Is a disease dependent on an abnormal state of the blood.

LOCALITY.

Is a unilateral affection as a rule. One joint only is affected.

Is generally a bilateral affection. Several joints are usually involved simultaneously.

SWELLING.

The swelling about the joint is irregular, and due to the distension of the synovial pouches.

The swelling about the joint is uniform, if severe.

INTEGUMENT.

The integument over the affected joint is usually normal.

The integument over the affected joints is usually reddened.

SECRETIONS.

The secretions are normal in reaction.

The secretions are usually strongly acid in reaction.

PAIN.

The pain is only of moderate severity.

The pain in the affected joints is often excessive.

HEART.

Heart complications are seldom present; if present they are of independent origin.

Heart complications are frequently the result of the abnormal blood-condition.

TEMP. AND PULSE.

The constitutional disturbance is generally slight.

The constitutional disturbance is often alarmingly severe.

SCROFULOUS SYNOVITIS.

HYDRARTHROSIS.

AGE AFFECTED.

Is usually a disease of youth.

May occur at any age.

PAIN.

The pain is at first slight and often remote from the seat of actual disease.

In the latter stages, however, the pain becomes local and severe; is worse at night, and is increased by impinging the articular surfaces of the joint.

Pain *may* be present in the early stages, if the disease is of inflammatory origin, but is often absent.

A sense of *distension* within the joint is, in the advanced stages, more often the only source of discomfort.

APPEARANCE OF JOINT.

The normal bony prominences of the joint are concealed, and the *hollows* normal to the joint are effaced.

The normal bony prominences of the joint are still apparent, but the *synovial pouches* are distended, rendering them prominent.

MOTION.

The normal movements of the joint are impaired.

Motion of the affected joint is only slightly embarrassed.

SKIN.

The skin over the affected joint is milky-white in color, shiny in appearance, and the blue veins on the surface are apparent.

The integument over the joint is of normal appearance.

SINUSES.

Sinuses form in the latter stages.

Sinuses seldom, if ever, exist.

CREPITATION.

Crepitation appears as the joint undergoes disorganization.

Crepitation is absent, if no complications are present.

PALPATION OF TUMOR.

The tumor is soft, doughy and fluctuant before sinuses form.

The tumor is fluctuant, and elastic to the touch.

HISTORY OF PATIENT.

History of serofulous diathesis exists.

History of traumatism, rheumatism, syphilis, etc.

ACUTE ARTHRITIS.

CHRONIC RHEUMATIC
ARTHRITIS.

PAIN.

The pain is severe and acute in the early stages.

The pain is localized at the joint.

The pain is steady and constant.

The pain is slight at first and increases with the development of the disease.

The pain is not local, but follows the course of nerve-trunks.

The pain is paroxysmal and usually worse at night.

DEFORMITY.

The deformity of the affected joint is at first due only to a serous effusion within it; but in latter stages structural changes occur.

The deformity is marked and progressive, resulting in the distortion of bony prominences, relaxed ligaments, atrophied muscles, etc., etc.

MOTION.

The motion of the joint is frequently destroyed by suppuration.

The motion of the joint is usually only impaired, and a stiffness is experienced.

CREPITATION.

Crepitation occurs from necrotic or carious changes within the joint, as the result of suppurative inflammation.

Crepitation, when present, is due to denuded cartilages, or a deposit of osteophytes.

AGE.

This disease may occur at any age.

Occurs most frequently about 50th year of age.

HISTORY.

Arthritis follows low vitality, exposure to cold or dampness, or traumatism.

This disease may follow high living, exposure, or injury.

ACUTE ARTHRITIS
(*continued*).CHRONIC RHEUMATIC
ARTHRITIS
(*continued*).

LOCATION.

Is not confined to any special joints ; is frequent in the ankle, knee, and hip.

Attacks the *hip* as a rule. In males it may affect any large joint, while in females the small joints are sometimes involved.

SYMPTOMS IN COMMON.

Both are associated with pain.

“	“	“	“	deformity.
“	“	“	“	crepitation.
“	“	“	“	impaired motion.

ACUTE ARTHRITIS.

SYPHILITIC PERIOSTITIS
NEAR A JOINT.

SIGNS OF EFFUSION.

The synovial pouches are prominent in the early stages of the disease.

No symptoms of effusion into the joint exist.

SWELLING.

The swelling is generally diffused around the joint.

The swelling is localized, and often confined to one side of the joint.

PAIN.

The pain is severe and acute from the commencement.

The pain is moderate in severity at the onset of disease.

The pain is steady and constant.

The pain always increases *at night*.

MOTION.

The pain is affected by *motion* of the diseased joint.

The pain is not affected by motion of the joint.

SUPPURATION.

Suppuration is frequent.

Suppuration is rare.

DISORGANIZATION OF JOINT.

Disorganization of the joint is frequent.

The joint seldom becomes implicated or disorganized.

HISTORY OF PATIENT.

A history of exposure, serofula, or low vitality exists.

Evidences of syphilis are often detected in skin, bone, or organs.

EFFECT OF TREATMENT.

Improvement slow under treatment.

Improvement marvellously rapid under iodide of potassium.

SYMPTOMS IN COMMON.

Both are associated with pain.

“ “ “ “ local swelling.

“ “ “ “ tenderness.

“ may be “ “ suppuration.

ACUTE ARTHRITIS.

SUPPURATION EXTERNAL
TO A JOINT.

APPEARANCE OF JOINT.

The swelling present in the joint is bilateral.

The swelling in the vicinity of the joint is unilateral.

BONY PROMINENCES.

The bony prominences normal to the affected joint are prominent in the early stages, unless complicating œdema exists.

The bony prominences of the joint are usually masked by the existing swelling in the vicinity of the joint.

SYNOVIAL POUCHES.

The synovial pouches are prominent in the early stages, from serious distension.

The synovial pouches of the joint are not prominent.

FLUCTUATION.

Fluctuation is often detected over the distended synovial pouches.

Fluctuation is detected at the seat of swelling, without regard to its particular location.

MOTION.

Motion is impaired in the late stages by destruction of the mechanism of the joint.

Motion is often limited, but only by the mechanical impediments resulting from the swelling.

DISORGANIZATION OF JOINT.

Disorganization of the joint is common and extensive.

Grating, crepitus, looseness of the joint and other signs of disorganization are absent.

CONSTITUTIONAL SYMPTOMS.

The constitutional symptoms are marked.

No constitutional disturbance is present—as a rule.

MUSCULAR CRAMPS.

Muscular cramps and *startings* in the sleep are prominent and severe.

No symptoms referable to muscular irritability are present.

TERMINATION.

Frequently amputation is demanded.

Seldom of serious import.

SYMPTOMS IN COMMON.

Chills, pain on motion, unnatural attitude of joint, local heat, and swelling and tenderness on pressure are present *in both*.

BONY ANCHYLOSIS.

FIBROUS ANCHYLOSIS.

PAIN.

No pain is produced within the joint by voluntary attempts at motion.

No pain at the joint results from manipulation in the hands of the surgeon, save at the direct points *compressed* by the fingers.

Pain is present if the patient makes strenuous efforts to effect motion in the ankylosed joint.

Marked and *severe* pain is experienced by any surgical attempts to produce mobility.

MOTION.

All evidences of mobility are absent, and complete solidity exists.

The fixation of the diseased joint is incomplete.

EFFECT OF ANÆSTHETICS.

Anæsthesia is negative in its results, as no perceptible motion in the joint can be thus produced, even under strong manipulation.

Anæsthesia frequently enables the surgeon to establish the normal latitude of motion, where it had previously been restricted.

II. DISEASES OF THE SPECIAL JOINTS.

DISEASE OF THE HIP JOINT:

“*Morbus Coxarius.*”

By this term is designated all the various types of disease confined to the hip joint, which are liable to follow inflammatory changes within that joint, whether these inflammatory changes primarily affect the bone, the cartilaginous structure, or the synovial membrane.

By some authors a classification of *Morbus Coxarius* has been made into the Femoral, the Arthritic, and the Acetabular varieties, based upon the primary seat of origin of the inflammatory process.

In all of these types, however, we have *four prominent symptoms* which are common to all of the varieties, and which are liable to be present. They vary somewhat, however, in degree and intensity, with the location of the primary changes within the joint, and are for that reason often of aid in the diagnosis of the particular type of disease then existing.

These important symptoms are

1. Pain.
2. Suppuration.
3. Dislocation.
4. Anchylosis.

Other *common* symptoms also co-exist in all of the varieties ; among them may be mentioned

Deformity,

Lost or impaired motion and function,

Change in the appearance of the nates,

Change in the spino-pelvic angle,

Abnormal relation between the two anterior superior spines of ilium, especially when in recumbent position,

An antero-posterior curvature of the spine, and possibly a lateral deflection, when the limb is extended upon the trunk.

But these symptoms are diagnostic rather of the disease in general, than of any *particular seat of origin*.

In the following table will be shown in contrast those variations in the four above-mentioned symptoms, which will enable us possibly to detect the seat of the primary inflammatory changes within the joint.

ARTHRITIC.

Pain is *acute* from the onset of the disease, and is located *in the joint*. Is greatly increased by movement of the limb, concussion of femur, or pressure over the trochanter.

ACETABULAR.

1ST SYMPTOM : PAIN.

Pain at first is referred to the iliac fossa, or the side of the pelvis.

Later on in the disease it becomes severe, and gnawing in character, and is referred to the joint itself.

It is increased in all stages by concussion of femur, abduction of limb, or pressure over the trochanter.

FEMORAL.

Pain is referred to the *knee joint* in the early stages of the disease, and is often *slight* at the onset.

2D SYMPTOM : SUPPURATION.

Suppuration may possibly be absent.

An abscess of the intra-pelvic variety usually forms.

It may point in front, above, or below Poupert's ligament;—or, by escaping through the sciatic notch, point behind, at the back part of the thigh.

Pus, when formed, burrows either under the glutei muscles, and points behind, or on the outer aspect of the thigh; or

2d, it burrows under the pectineus muscle, and points on the inner aspect of thigh.

3D SYMPTOM : DISLOCATION.

Dislocation is rare. When present, it is due either to rupture of the capsule, or caries of the head of the bone.

Dislocation into the pelvic cavity often occurs from caries of the acetabulum.

Dislocation is frequent, and is due either to caries of the head of the femur, or new growth in the cavity of the acetabulum.

4TH SYMPTOM : ANCHYLOSIS.

Not infrequent; usually occurs within the acetabulum.

Anchylolysis is rare.

Anchylolysis often occurs in some abnormal position, following a dislocation of the femur.

The diagnosis of *morbus coxarius* in its early stages, before supuration occurs, is of vital importance, as the prospect of complete recovery depends, as a rule, upon its early recognition.

The following guides to its diagnosis will therefore merit the closest attention :

1st. A change in the position of the affected limb and impaired function will exist in the earlier stages.

2d. The pelvis will be found inclined from a *right* angle to the spinal column, as shown by a line drawn between the two anterior superior spines of the ilium, and contrasted with the median line of the body. This pelvic inclination can, however, be restored to the normal position by manual pressure, or, possibly, by a muscular effort on the part of the patient.

3d. On placing the patient in the dorsal position upon the table, all attempts to *straighten* the affected limb until the popliteal space touches the table, will tend to elevate the back at the lumbar region from the same plane, so that frequently the hand can be placed between the table and the spinal column.

4th. In the same position on the table the two anterior superior spines of the ilium will be seen not to be on the same level as they are in health, when the limb is extended ; the affected side being elevated above the healthy side.

5th. Flexion of the thigh and leg, and an altered relation of the affected thigh to the pelvis will remove the pelvic inclination, will bring the spines of the ilium to the same level, and will cause the lumbar region of the spinal column to lie in contact with the couch. When these points are perfectly accomplished the normal relations are restored, and the *actual existing deformity* of the hip is made manifest.

6th. Extension of the affected limb will usually relieve the pain by separating the inflamed surfaces of the joint.

7th. Concussion upon the end of the affected femur with the palm of the hand, when the knee is flexed, will increase the pain by approximating the inflamed surfaces.

8th. Pressure over the trochanter of the affected side will likewise, as a rule, increase the sufferings of the patient.

9th. Motion of the affected limb at the hip joint will usually give pain, and especially will this be marked when motion in some particular direction is attempted.

Great credit is due to Dr. Lewis A. Sayre, of New York, for the

present simplicity of diagnosis in obscure cases of *morbus coxarius*, as well as for his improvements in reparative appliances.

MORBUS COXARIUS is to be diagnosed from

1. Congenital dislocation of the hip.
2. Psoas abscess.
3. Disease of the sacro-iliac articulation.
4. " " trochanter of femur.
5. Lateral curvature of the spine.
6. Rheumatic deformity of the hip.
7. Disease of the crest of the ilium.
8. Inflammation of a psoas bursa.
9. Infantile paralysis.

MORBUS COXARIUS.

CONGENITAL DISLOCATION
OF HIP.

PAIN.

Pain is present as a symptom in all forms of the disease.

Pain is absent, the bone having an abnormal position, but being healthy.

EFFECTS OF PRESSURE.

Pain is produced by pressure over the trochanter, or concussion of the femur.

Pain is often absent on both pressure and motion. Concussion may give *slight* pain.

SHORTENING.

An *apparent shortening* of the affected limb appears early, due to tilting of the pelvis.

Real shortening occurs, however, in the latter stages from absorption of the bone.

This shortening is not affected by upward pressure, after the muscles are firmly contracted.

Actual shortening exists from the date of birth,—as shown by measurement from the ant. sup. spine of ilium, to the internal malleolus at ankle.

This shortening can often be *increased* by upward pressure on the end of the femur.

EXTENSION OF LIMB.

The apparent and real shortening are often *reduced* by extension.

The shortening of dislocation may often resist extension, and is seldom, if ever, completely reduced.

MOBILITY OF LIMB.

The mobility of the limb is *greatly* impaired in late stages.

The mobility of the limb does not vary, and is usually free in character.

SPINAL COLUMN.

A *spinal* deflection from contraction of the psoas muscle exists.

The spinal column is *normal*.

MORBUS COXARIUS
(*continued*).

CONGENITAL DISLOCATION
OF HIP
(*continued*).

RELATION OF THE SPINES OF ILIUM.

The anterior spines of ilium are not upon the same level when the patient lies upon the back.

The anterior spines of the ilium are upon the same level when patient is lying upon the back.

SYMPTOMS IN COMMON.

Both are associated with alteration in the length of limb.
 “ “ “ “ pain on concussion.
 “ “ “ “ impaired mobility of the limb.

MORBUS COXARIUS.

PSOAS ABSCESS.

HISTORY OF PATIENT.

No history of spinal disease can be elicited.

A well-marked history of spinal disease is present.

PAIN.

The pain at first is felt in the knee, hip, or pelvis.

The pain is usually referred to the back or loins.

EFFECTS OF PRESSURE.

Pressure over the trochanter of femur usually causes pain, especially so after perforation of the capsule of the hip.

Pressure over the trochanter of the femur gives *no pain*.

MOTION.

Motion of the femur is painful in all stages of the disease.

Motion of the femur is *painless*, when the thigh is flexed to relieve pressure upon the tumor.

FOLD OF NATES.

The fold of the nates is altered from its normal position.

The fold of the nates is normal in its position.

LENGTH OF LIMB.

The length of the affected limb is altered.

No change in the length of the affected limb can be detected.

CONDITION OF THE JOINT.

The joint is often immovable in advance stages, and there is an escape of pus.

The joint is movable, even after the abscess has discharged pus and established sinuses.

SYMPTOMS IN COMMON.

In both the contracted psoas affects the spinal curve.

“ “ “ relation of the pelvis to the spine is often altered.

“ “ “ evacuation of pus and the previous formation of a tumor in the thigh occur.

“ “ “ pain and impaired function of limb may exist.

MORBUS COXARIUS.

SACRO-ILIAC DISEASE.

EFFECTS OF POSITION OF LIMB.

The altered relation of the pelvis to the spine can be modified by the position of the limb.

The obliquity of the pelvis is not affected by the position of the limb.

EFFECT OF PRESSURE.

The pain on pressure over the trochanter is felt in the hip joint.

Pressure over the trochanter causes pain in the sacro-iliae articulation, but not in the hip joint.

PAIN.

The pain in the hip on pressure is not controlled by fixation of the os innominatum.

The pain on pressure and motion is modified, or entirely controlled by fixation of the os innominatum.

LENGTH OF LIMB.

A change in the length of the limb affected is often present.

The lengthening of the limb is never actual, but only apparently so.

SYMPTOMS IN COMMON.

Both may be associated with local pain.

- | | | | | |
|---|---|---|---|--|
| “ | “ | “ | “ | suppuration and the formation of sinuses. |
| “ | “ | “ | “ | obliquity of the pelvis. |
| “ | “ | “ | “ | detection of necrosed or carious bone, by the probe. |
| “ | “ | “ | “ | apparent lengthening of the limb on affected side. |

MORBUS COXARIUS.

DISEASE OF THE TROCHAN-
TER OF THE FEMUR.

AGE AFFECTED.

Is chiefly a disease of childhood. Occurs chiefly during adult life.

HISTORY.

Occurs, as a rule, after some in- Follows rheumatism, gout, syphi-
jury, as a fall, severe strain, or blow. lis, or some blood diathesis.

APPEARANCE OF NATES.

The fold of the nates is abnormal The fold of the nates corresponds
in its position. with that of the opposite side.

PAIN IN KNEE.

A pain in the knee is often a pro- No pain in the knee, or inner as-
minent and an early symptom. pect of the thigh, is ever present.

APPEARANCE OF SPINE.

The spine is usually curved from The spine is usually normal in
contraction of the psoas. appearance.

POSITION OF PELVIS.

The pelvis is usually tilted. The pelvis is usually normal.

SYMPTOMS IN COMMON.

Both are associated with pain on motion of the femur.
“ “ “ “ “ “ pressure over trochanter.
“ “ “ “ formation of abscess and sinuses.

MORBUS COXARIUS.

LATERAL CURVATURE OF
THE SPINE.

NATES.

The fold of the nates is abnormal in position.

The fold of the nates is unaltered.

LENGTH.

The length of the limb is often altered on actual measurement.

No *real* alteration in the length of the limb is ever present.

PAIN.

Pain is present on pressure over the trochanter, or on concussion of the femur.

No pain is produced by pressure over the trochanter, or by concussion of the femur.

ABSCESS.

Symptoms of abscess appear, followed by the escape of pus and the formation of sinuses.

No symptom of abscess, or of the evacuation of pus occurs.

SPINAL DEFORMITY.

The spinal deformity, produced by contraction of the psoas muscle, is reduced by position of the limb.

The spinal deformity is not affected by position of the femur.

SYMPTOMS IN COMMON.

Both are associated with apparent shortening.

“ “ “ “ altered pelvis.

“ “ “ “ spine.

“ “ diseases of childhood.

MORBUS COXARIUS.

RHEUMATIC DEFORMITY OF
HIP.

AGE.

Is a disease chiefly of childhood. Seldom exists in the young.

HISTORY.

Is preceded by a history of injury; and most frequently occurs in serofulous or weak children. Is preceded by a history of rheumatism.

NATES.

The fold of the nates is abnormal in position. The fold of the nates corresponds with its fellow.

LENGTH OF LIMB.

The length of the limb is usually altered. The length of the limb is usually normal.

ABSCESS.

Abscess and sinuses are common symptoms. Abscess is rare.

COMPLICATIONS.

No disease is present simultaneously in other joints. Other joints are, as a rule, simultaneously involved.

SYMPTOMS IN COMMON.

Both are associated with impaired motion.
 “ “ “ “ possible immobility.
 “ “ “ “ “ crepitus.
 “ “ “ “ pain on pressure.
 “ “ “ “ “ “ motion.

MORBUS COXARIUS.

DISEASE OF THE CREST OF
ILIUM.

LENGTH OF LIMB.

The length of the affected limb is abnormal, as a rule.

The length of the limb on the side affected corresponds with its fellow.

MOTION OF LIMB.

The motion of the affected limb is either impaired or lost.

The motion of the limb is normal on the side affected.

ABSCESS.

The abscess resulting from the diseased joint opens, as a rule, *below* the level of the upper border of the trochanter of the femur.

The abscess resulting from disease of the ilium points and evacuates itself *above* the level of the hip joint.

PROBE.

A probe when introduced usually detects carious bone at the hip, after suppuration has occurred and the abscess has discharged.

A probe when introduced finds the seat of carious or necrotic changes to be above the articulation.

SHAPE OF THE HIP.

The shape of the hip is abnormal; and the nates are dissimilar.

The hip is normal in appearance; and the nates on each side correspond.

SYMPTOMS IN COMMON.

Both are associated with marked pain.

“ “ “ “ the formation of abscess.

“ “ “ “ sinuses, in later stages.

“ “ “ “ low vitality and emaciation.

“ may occur in the young.

MORBUS COXARIUS.

INFLAMMATION OF PSOAS
BURSA.

SHAPE OF HIP.

The hip is altered in its shape and appearance.

The hip is normal in shape and appearance.

FOLD OF NATES.

The fold of the nates is displaced on the affected side.

The fold of the nates is similar to that of the opposite side.

EFFECT OF PRESSURE.

Pain on pressure over the trochanter is perceived.

Pressure over the trochanter of affected side gives no pain.

KNEE SYMPTOMS.

Symptoms referable to the knee appear early.

Symptoms referable to the knee are absent.

TUMOR.

The tumor due to the pointing of pus appears late in the disease, and is usually painless to the touch.

The tumor produced by the inflamed bursa appears early, is located in the anterior part of the thigh, and is *painful* to the touch.

SYMPTOMS IN COMMON.

Both are associated with flexion of the affected limb.

“ “ “ “ pain on motion of the limb.

“ “ “ “ impaired, or restricted function in the joint.

“ *may* be associated with pelvic distortion.

“ “ “ “ “ spinal curvature.

MORBUS COXARIUS.

INFANTILE PARALYSIS.

LENGTH OF LIMB.

The shortening *may*, in some cases, be apparent only; while in some stages even lengthening may exist.

The shortening of the affected limb is actual, as shown by measurement from anterior spine of ilium to the inner malleolus of ankle.

SPINAL CURVATURE.

The spinal curvature is more of an antero-posterior character, as it depends greatly upon contraction of the psoas muscle.

The spinal curvature which often exists is of the lateral variety.

SIZE OF LIMB.

The affected limb may be normal in size.

The affected limb is atrophied and smaller than its fellow, provided one limb only be affected.

SUPPURATION.

Suppuration and the formation of abscess are common.

Abcess is seldom if ever present, save as a complication.

MOBILITY OF JOINT.

The joint is often immovable in the third stage of the disease.

The joint is never fixed or immovable.

HISTORY OF PATIENT.

A history of injury followed by pain in the knee, etc., is present.

A history of gradual loss of muscular power is present.

SYMPTOMS IN COMMON.

Both may be associated with alteration in the length of the limb.

“ “ “ “ “ spinal eurvature.

“ “ “ “ “ atrophy of the limb.

DIAGNOSTIC POINTS OF TENDERNESS ON PRESSURE IN INFLAMMATION
OF THE LARGER JOINTS.

All joints, when inflamed, or when an increased amount of synovial fluid is present, present certain special localities where an abnormal degree of sensitiveness to pressure exists. This local sensitiveness, if detected early, often confirms a diagnosis.

I have enumerated below the anatomical situation of those diagnostic points which pertain to the five principal joints of the body.

In the HIP.	<i>Close behind the trochanter, the fingers being shaped like a cone, and firm pressure made.</i>
“ “ KNEE.	<i>On either side of the patella.</i>
“ “ ANKLE.	<i>In front of the joint, slightly above the malleoli.</i>
“ “ SHOULDER.	<i>The anterior aspect of the joint, pressure being made through the axillary coverings.</i>
“ “ ELBOW.	<i>In front of the joint, over the head of the radius.</i>

III. DEFORMITIES OF JOINTS.

The various deformities of joints which are liable to be met with in a surgical practice, may be divided into, 1st, those of congenital origin; and, 2d, those acquired after the date of birth.

Under the first type, viz. : “THOSE DEFORMITIES WHICH ARE CONGENITAL,” may be enumerated

A. CONGENITAL DISTORTIONS; under which I include

1. Club Foot, in all its varieties.
2. Club Hand, in all its varieties.
3. Sub Luxation, in all its varieties.
4. Distortions, dependent on paralysis.
5. “ “ “ contracted muscles.

B. CONGENITAL MALFORMATIONS; under which head may be enumerated

1. Atrophy of limb, with malformation of long bones.
2. Hypertrophy of phalanges.

3. Atrophy, or absence of phalanges.
4. Imperfect development of carpus, metacarpus, tarsus, or metatarsus.
5. Fusion of toes or fingers (syndactylus).
6. Valgoid malformation of upper extremities.
7. Supernumerary toes, digits, or even entire members.
8. Fusion of inferior extremities ("sympodia;" "monopodia").

Under the second type, viz.: "ACQUIRED DEFORMITIES OF JOINTS," may be enumerated

1. Deformities from wounds, accidents, rheumatism, and diseases of joints.
2. Deformities from rickets, weakness and curvature of bones.
3. Deformities from muscular contraction.
4. " " " paralysis.
5. " " burns.
6. Spinal curvatures and deformities.

Many of the types of malformations which exist under the congenital variety, have been omitted, as they have no direct bearing upon the JOINTS. They are seldom of such a character as either to demand surgical diagnosis, which is usually self-evident, or to be benefited by surgical treatment. To those interested, however, in such deformities, I refer, for reference, to Henle's classification of Congenital Malformations.

I pass to the consideration of *Club-foot* as the most frequent, and, possibly, the most important congenital deformity of the joints.

TALIPES.

By "Club-foot," or "Talipes," is meant an abnormal condition of the tarsus, and frequently of the metatarsus, resulting in an altered relation of the axis of the limb to the axis of the foot.

It is usually divided into the following varieties :

- | | | |
|----------------------------------|---|--|
| TALIPES.
8 distinct
types. | } | 1. Talipes Equinus where the heel is raised
and the foot extended
upon the leg. |
| | | 2. " Calcaneus where the heel is project-
ing and the foot flexed. |
| | | 3. " Varus where the sole of the foot
is turned inwards. |
| | | 4. " Valgus where the sole of the foot
is turned outwards. |
| | | 5. " Equino-Varus where a combination of
the equinus and varus
deformities exists. |
| | | 6. " Equino-Valgus where a combination of
the equinus and val-
gus deformities exists. |
| | | 7. " Calcaneo-Valgus where a combination of
the calcanean and val-
gus deformities exists. |
| | | 8. " Spurio-Valgus or "Flat-foot," where the
plantar arch is defi-
cient. |

Of these types, the *combined varieties*, especially those of the Equinus type, can hardly be considered otherwise than as the simple varus or valgus deformity associated with contraction of the muscles forming the tendo Achillis, and consequent elevation of the heel.

The Gastrocnemius, Soleus, and Plantaris muscles, which form the tendo Achillis, are important factors in the varus deformity, being adductors of the foot as well as extensors. It is seldom, therefore, that Talipes varus fails to escape some elevation of the heel, although the term Equino-varus is not applied until this altered position of the heel becomes a marked element in the deformity.

Talipes can hardly be confounded with any other deformity. I therefore confine the few following pages to its individual types only; my object being rather concisely to record the diagnostic points of each, than to infer the possibility of error in diagnosis.

TALIPES VARUS.

TALIPES VALGUS.

FREQUENCY.

As a congenital disease, this deformity is the most frequent form of talipes.

As a congenital deformity, Talipes Valgus is rare.

DEFORMITY, IF CONGENITAL.

The foot is *adducted*, the sole turned inwards, or upwards, and the internal malleolus is obliterated.

The foot is *abducted*, the sole turned outwards and often upwards, and the external malleolus is obliterated.

PROGRESS OF THE DEFORMITY, IF ACQUIRED.

The disease, if *acquired* after birth, is first manifested by elevation of the internal border of the foot, from contraction of the two tibial muscles and the muscles of the tendo Achillis.

The disease usually first reveals itself by an elevation of the external border of the foot, due to contraction of the peronei muscles, the long extensors of the toes and the muscles of the tendo Achillis.

SYMPTOMS IN COMMON.

- Both are associated, if of long standing, with stiffness in the ankle joint.
- | | | | | | | | | |
|---|---|---|---|---|---|---|---|---|
| “ | “ | “ | “ | “ | “ | “ | “ | a longitudinal furrow in the sole of the foot, from narrowing of the transverse arch of the foot. |
| “ | “ | “ | “ | “ | “ | “ | “ | a slight elevation of the heel. |
| “ | “ | “ | “ | “ | “ | “ | “ | the gradual formation of a soft, cushiony swelling on the <i>dorsum</i> of the foot where the pressure of walking occurs. |
| “ | “ | “ | “ | “ | “ | “ | “ | rigidity of tendons on the side of deflection of the foot. |

TALIPES EQUINUS (*simple*). TALIPES EQUINUS, with paralysis of the extensor muscle of the toes and flexors of the tarsus.

POSITION OF THE FOOT IN WALKING.

The patient walks upon the ends of the metatarsal bones.	The patient walks upon the dorsum of the foot, which is bent upon the ground with the sole looking backwards and upwards.
--	---

ATTITUDE OF THE TOES.

The toes are drawn upwards.	The toes are relaxed or flexed.
-----------------------------	---------------------------------

MUSCULAR POWER.

The muscles on the anterior part of leg can partly control the foot and the toes.	All flexion of the foot and extensor-muscular power over the toes are lost.
---	---

SYMPTOMS IN COMMON.

Both are associated with absence of any *lateral* displacement.

“ “ “ “	increased width of the foot, from separation of the metatarsal bones.
“ “ “ “	projection forward of the astragalus.
“ “ “ “	elevation of the heel.
“ “ “ “	contraction of the muscles of the calf.

Both may occur in the young, and, possibly, in the adult.

TALIPES VALGUS (SPURIOUS). CALCANEAL VALGUS OF MODERATE SEVERITY.
(The Chinese foot as example.)

PLANTAR ARCH.

The arch of the sole of the foot is *diminished*.

The arch of the sole of the foot is *increased*.

INSTEPS.

The instep is less prominent than normal.

The instep is increased in prominence.

LENGTH OF FOOT.

The front part of the foot is normal in its length.

The anterior portion of the foot is much shortened.

MUSCLES OF CALF.

The muscles of the calf are normal in size, and the *tendo Achillis* is prominent.

The muscles of the calf are atrophied, and the *tendo Achillis* is scarcely visible.

OUTER MARGIN OF FOOT.

The outer edge of the foot becomes elevated as the disease advances.

A *deep cleft* exists on the outside of the foot at the peroneus longus tendon, but the outer edge of the foot is *not raised*.

SYMPTOMS IN COMMON.

Both are developed, as a rule, after birth.

“ “ progressive in deformity.

“ “ associated with altered gait.

“ “ “ “ abnormal appearance of outer margin of foot.

TALIPES VALGUS.

SPURIOUS VALGUS

("FLAT FOOT").

AGE.

Is present at date of birth as a comparatively *rare* affection.

May commence in early life, but seldom becomes a deformity till adolescence.

ORIGIN.

It may be acquired, however, from infantile paralysis, convulsions during dentition, standing too long on feet, carrying heavy weights, etc.

If occurring after 18th year of age, is due to rheumatism, excessive standing or walking, or general *debility*.

DEFORMITY.

The external margin of the foot is elevated, the foot is twisted so that pressure falls upon the internal malleolus and inside of the instep, and the metatarsus and toes do not touch the ground. No projection of the astragalus, or widening of the foot is present.

The tarsal arch is destroyed through relaxation of the calcaneo-scaphoid ligaments, and those between the scaphoid, and the cuboid and internal cuneiform bones. The astragalus projects in front, the foot is widened, and the convexity of the dorsum of the foot is lost.

LENGTH OF FOOT.

The length of the foot is diminished, and the toes are often flexed.

Eversion of the toes, and actual *elongation* of the foot occur.

ANKLE JOINT.

The motion within the ankle joint is rapidly impaired.

The *ankle joint* remains useful for a time, but gradually loses its capabilities of motion.

OUTER MARGIN OF FOOT.

The outer margin of the foot is affected early in the disease, and locomotion is performed on the side of instep.

The outer margin of the foot becomes raised *late* in the disease, and locomotion is mostly effected upon the heel, in the later stages.

TALIPES VALGUS
(*continued*).

SPURIOUS VALGUS
(“FLAT FOOT”)
(*continued*).

PAIN.

The pain is of an unimportant character and is often absent.

Pain exists *previous* to the complete breaking down of the plantar arch at the internal malleolus and the sole of the foot from tension on the ligaments; but it ceases when full deformity is reached.

This pain is more severe in slight cases than in severe ones.

EFFECT OF STANDING.

The act of standing increases the deformity in a slight degree in the early stages, but the normal attitude of joint is not reassumed, even in the recumbent position.

In the early stages the plantar arch is effaced on standing, but returns when the weight is removed.

SPURIOUS VALGUS
("FLAT FOOT").

SPRAIN OF ANKLE JOINT.

PAIN.

The pain in the early stages is confined to the internal malleolus and the *sole* of the foot.

The pain is usually within the joint, or at either malleolus, and is seldom if ever present in the sole of the foot.

HISTORY.

No history of sudden wrench or twisting of ankle is present, but rather of prolonged exertion or debility.

A history of some sudden or severe exciting cause exists.

SWELLING.

No swelling, with tenderness to the touch, exists in vicinity of the ankle.

Swelling and tenderness are marked in the vicinity of the ankle joint.

EFFECT OF STANDING.

A marked alteration in the planar arch appears from the weight of the patient when standing.

No alteration in the shape of the foot ensues from the standing position.

RESULTS.

Gradual deformity ensues, unless recognized early, and preventive treatment employed.

Gradual improvement and restored function follow.

SYMPTOMS IN COMMON.

Both are associated with pain in the ankle.

“ “ “ “ pain on standing or walking.

“ may be “ “ a history of excessive exertion or debility.

“ “ “ “ long duration and progressive symptoms.

DISEASES OF BONE.

DISEASES OF BONE.

THE diseases which are confined to the bony structures of the body are frequently relieved by surgical measures only, and are properly classed as essentially *surgical* diseases.

As an enumeration of the various types of diseases of bone liable to be encountered, I would mention :

A. INFLAMMATORY DISEASES OF BONE, comprising :

1. Simple inflammation of bone—"Osteitis."
2. Diffuse suppurative inflammation of the interior of the bone—"Osteo-myelitis."
3. Circumscribed suppuration of bone—"Abscess of bone."

B. INFLAMMATION OF THE COVERINGS OF BONE, comprising :

1. Simple inflammation—"Periostitis."
2. Suppurative " —"Periosteal abscess."
3. Chronic " —"Periosteal thickenings and nodes."

C. GRADUAL CHANGES IN, OR ABNORMAL DEVIATIONS FROM THE HEALTHY TYPE OF BONE STRUCTURE :

1. Atrophy of bone.
2. Hypertrophy of bone.
3. Rachitic condition of bone.
4. Mollities ossium.
5. Caries of bone,—or ulceration of bone.
6. Necrosis of bone,—or gangrene of bone.
7. Spontaneous fracture.
8. Tumors of bone.

The TUMORS of BONE may be divided into two types :

A. *Non-malignant* tumors, including

1. Enchondromata.
2. Exostoses.

3. Cystic.
4. Fibrous.
5. Fibro-cystic.
6. Entozoa.

B. *Malignant* tumors, including

1. Pulsatile tumors of bone.
2. Cancer of bone, 3 types :

}	Colloid,
}	Encephaloid, and
}	Schirrus.
3. Malignant cysts—"Spina Ventosa."

The diseases of bone are to be diagnosed

- 1st. From each other.
- 2d. " arthritic disease of joints.
- 3d. " diseases of the soft tissues.

OSTEITIS.

OSTEO-MYELITIS.

ORIGIN.

It may result from disease, or from traumatism.

It occurs in scrofula, syphilis, rheumatism, and follows exposure.

Is always traumatic in origin; follows amputations, fractures, etc.

It occurs where the medullary canal is exposed to the air, as a rule.

MOST FREQUENT SEAT.

The tibia, bones of the head, and ribs are most frequently affected.

The long bones are most frequently involved.

PAIN.

The pain present is *intermittent*; is worse at night if syphilitic in origin, or is increased by dampness if of rheumatic origin.

The pain is first perceived at the seat of injury, or in the stump in cases where amputation has been performed, and is accompanied by *rigors*.

CHANGES IN THE BONE.

The affected bone gradually enlarges in circumference.

Pyæmic symptoms often rapidly follow, associated with high fever, dryness of the stump, or arrested secretion at the seat of injury, if caused by fracture. The soft tissues are also often retracted.

The bone becomes hard, irregular in contour and incompressible.

The bone undergoes necrotic changes and becomes infiltrated with pus.

TERMINATION.

The disease often terminates in recovery.

Recovery is rare.

SYMPTOMS IN COMMON.

Both may be associated with a traumatic history.
 “ “ “ “ marked pain.

CARIES.

NECROSIS.

DEFINITION.

Is a molecular death of bone tissue, and is analogous to ulceration of the soft tissues.

Is a disease which affects the cancellous tissue of bone.

Is a death of bone tissue in mass, and not in molecules, and is analogous to gangrene of the soft tissues.

Usually attacks the compact tissue of bone.

MOST FREQUENT SEAT.

Is most frequent in the articular extremities of long bones.

Is most frequent in the shafts of long bones.

ETIOLOGY.

Always results from a low grade of chronic inflammation, as in scrofula, syphilis, injury, or an extension of inflammation from other parts.

May be traumatic in origin, and acute; is always due, however, to *defective nutrition* of the bone tissue.

SINUSES.

Sinuses form slowly, as the disease is not often superficial in its early stages.

Sinuses form rapidly after the death of the bone has occurred.

CAVITIES IN BONE.

Tends to create cavities within the bone.

Is usually superficial and seldom results in the formation of central cavities within the bone.

PROBE EXAMINATION.

A fine, grating sensation alone is detected by the probe on examination.

A smooth, denuded, and frequently loose sequestrum is detected by the probe.

SYMPTOMS IN COMMON.

Both may be associated with prolonged suppuration.

“ “ “ “ “ sinuses.

“ are “ “ abnormal sensations on probing.

OSTEITIS.

PERIOSTITIS.

PAIN.

The pain which exists is *deep*, and diffused throughout the bone. The pain is superficial in character, and usually circumscribed.

TUMOR.

The bone undergoes a *uniform* enlargement. The bone develops a local tumor.

SENSITIVENESS.

The bone affected is moderately sensitive to pressure. Extreme sensitiveness to pressure exists over the affected portion.

CAUSATION.

Is frequently the result of simple exposure. Is usually either traumatic or syphilitic in origin.

RESULTS.

Amputation is frequently demanded in severe types. Amputation is seldom required, as the disease usually subsides under treatment, or goes on to abscess and necrosis.

SYMPTOMS IN COMMON.

Both are associated with pain in the region of the bone affected.

“	“	“	“	enlargement of the bone.
“	“	“	“	sensitiveness to pressure.
“	“	“	“	constitutional disturbance often.
“	“	“	“	often with traumatic history.

PERIOSTITIS NEAR A JOINT.

ACUTE ARTHRITIS.

EFFUSION.

No symptoms of effusion into the joint exist.

Symptoms of effusion within the joint are prominent.

SWELLING.

The swelling is localized, and often confined to one side of the joint.

The swelling about the joint is generally uniform, and always bilateral.

PAIN.

The pain is moderate in severity at the onset of the disease.

The pain is severe and acute from the commencement.

The pain usually increases at night.

The pain is steady and constant.

PAIN ON MOTION.

No pain is produced by motion of the affected joint.

Great pain is often associated with motion at the diseased joint.

SUPPURATION.

Suppuration is rare.

Suppuration is frequent.

DISORGANIZATION OF THE JOINT.

The joint seldom becomes implicated or disorganized.

The joint rapidly undergoes disorganization, unless the disease be arrested.

SYPHILIS.

Evidences of syphilis are often detected in the skin, bone or organs.

No evidences of syphilis are detected, as a rule.

RAPIDITY OF IMPROVEMENT.

The improvement under the iodide of potassium is often marvelously rapid.

An improvement is only produced by local measures.

SYMPTOMS IN COMMON.

Both are associated with swelling near the joint.

“ “ “ “ pain.

“ “ “ “ abnormal sensitiveness to pressure.

ABSCESS OF BONE.

ARTHRITIS.

MOTION.

The motion of the neighboring joint is seldom affected.

The affected joint early manifests pain when certain movements are demanded.

SWELLING.

The disease is not externally revealed until *late*, being, as a rule, exceedingly slow in its progress.

The size of the joint increases and becomes prominently affected in the *early* stages.

PAIN.

The pain is usually deep seated in the neighborhood of a joint, but not within it.

The pain is located *within* the joint and is usually steady and constant.

SUPPURATION.

When the circumscribed pus reaches the surface the joint is seldom involved, but a continued escape of pus through a sinus is liable to remain indefinitely until the cause be relieved.

When suppuration occurs the joint usually undergoes rapid disorganization.

SYMPTOMS IN COMMON.

Both are associated with pain in the vicinity of a joint in the early stages.

Both may be associated with suppuration.

“ “ “ “ “ sinuses in late stages.

“ “ “ “ “ the detection of carious bone by probing.

RICKETS.

MALACOSTEON.

OSTEOMALACIA.—MOLLITIES
OSSIUM.

TIME OF ORIGIN.

Rickets commences, as a rule, in infants from the sixth month to the close of the second year. It is rare after puberty.

A softening of bone which occurs after puberty, usually in middle life, or as age advances.

DEFORMITY.

The long bones of the body become twisted or bent.

The disease may affect the whole bony system, or only portions of it.

The flat bones become hypertrophied in their cancellous structure, especially at their edges, and a softening is frequent at the centres of ossification.

The pelvis and the spine are its frequent seats.

The face is often undeveloped in proportion to the cranium.

The stature is often greatly diminished, if the legs or spine be affected.

Spinal curvatures are frequent, and pelvic deformities with shortening of the antero-posterior diameters.

The facial bones are seldom affected, and the proportion to the cranium is normal.

The bones of the thorax become deformed from spinal changes and museular action.

The pelvic deformities are characterized by shortening of the transverse diameters, but the bones are normal as to development.

The bones affected are often arrested in development.

The bones affected are normal in size and appearance before the attack.

DIATHESIS.

Rickets is frequently associated with a serofulous diathesis.

No serofulous diathesis, but a rheumatic history is frequently present, the disease seeming to consist in a fatty degenerative process.

TERMINATION.

The disease frequently ends in recovery, and does not tend to shorten life.

The disease seldom tends towards recovery. May prove fatal, from complications, within a few years.

SYMPTOMS IN COMMON.

Both result in deformities of the bony structures.

“ are due to impairment of normal health.

EXOSTOSES OF BONE.

CYSTS OF BONE
("SPINA VENTOSA").

SITUATION.

Most frequently affect flat bones and the shafts of long bones.

Most frequently affect the jaw and the articular heads of long bones.

SHAPE.

Are usually globular in shape, but they may be pediculated.

Are usually round or oval in shape.

SIZE.

Are of moderate dimensions.

Are often immense in size. They may reach the size of a child's head.

NUMBER.

Are frequently multiple.

Are usually single.

PALPATION.

Are hard and incompressible.

Crackle like parchment, in the late stages, when the bone is thinned.

DEVELOPMENT.

Develop slowly and regularly.

Develop rapidly, as a rule, but often irregularly; often being slow in growth and then suddenly rapid, or *vice versá*.

FLUCTUATION.

The tumor never fluctuates.

Fluctuation exists in localized spots during the advanced stages.

CONDITION OF VEINS.

The superficial veins are normal.

The superficial veins are enlarged.

PAIN.

No pain on pressure exists, as a rule.

Pain is often present on firm pressure.

SYMPTOMS IN COMMON.

Both are associated with a local tumor of bone.

“ “ “ often with symptoms referable to irritation of nerves, muscles, joints, or vessels.

CANCER OF BONE.

PULSATILE TUMORS OF
BONE.

LOCALITY OF TUMOR.

The disease affects the articular heads of long bones, especially the lower end of the femur.	The tumor occurs in the line of some vessel.
---	--

CONDITION OF TUMOR.

The tumor is hard, irregular, incompressible and painless in early stages.	The tumor is irregular in shape, and painful.
--	---

CONSISTENCE OF TUMOR.

The tumor becomes elastic and fluctuant in spots during the advanced stages.	The tumor is of uniform consistence.
--	--------------------------------------

RAPIDITY OF THE GROWTH.

The tumor grows rapidly and often attains immense size.	The tumor grows slowly.
---	-------------------------

EFFECTS OF PRESSURE.

The tumor is not affected by pressure, or by impeded vascular supply.	The tumor is modified in size and appearance by impeded circulation, through pressure on the supplying vessel.
---	--

MOBILITY.

The tumor is immovably attached to the bone.	The tumor can often be partially separated from the bone.
--	---

APPEARANCE OF VEINS.

The superficial veins are markedly enlarged.	The superficial veins are normal in appearance.
--	---

PAIN.

Pain is deep, lancinating, and constant, early in the disease.	Pain is slight, and is rather an <i>uneasy</i> feeling than severe.
--	---

CANCER OF BONE
(*continued*).

PULSATILE TUMORS OF
BONE
(*continued*).

PULSATION.

Pulsation is detected late in the disease, and is often absent.

Pulsation is detected early.

FUNGOID.

“Fungoid exerescencees” are frequent.

No tendency to fungoid growth exists.

CACHEXIA.

A marked eachexia exists.
The neighboring glands are often involved.

No eachexia is apparent.
The neighboring glands are normal.

SYMPTOMS IN COMMON.

Both are common in *young people*.

“ pulsate.

“ are indicated by a tumor.

“ may produce pain.

PULSATILE TUMORS OF
BONE.

ANEURISM.

MOBILITY OF TUMOR.

The tumor is firmly attached to the bone.

The tumor is movable.

PALPATION OF TUMOR.

Osseous plates are felt in the walls of the sac.

The walls of the tumor are felt to be soft and uniform in consistency.

The edges of the tumor are osseous.

The tumor is soft, elastic and compressible throughout.

PULSATION.

The pulsation within the tumor is indistinct, and not markedly expansive.

The pulsation within the tumor is distinct, and *expansive* in character.

OUTLINE OF TUMOR.

The outline of the tumor is indistinct.

The outline of the tumor is often distinct.

EFFECTS OF PRESSURE.

The tumor is only slightly affected as to size or appearance by direct pressure or impeded arterial supply.

The tumor is markedly decreased in size, and altered in appearance by direct pressure upon it, or by obstructing its circulation by pressure upon the supplying vessel.

SYMPTOMS IN COMMON.

Both are associated with a tumor.

“ “ “ “ pulsation.

“ “ “ often with symptoms referable to irritation of joints, nerves, muscles, or vessels.

SPECIAL TYPES.

ABSCESS OF ANTRUM. SOLID TUMORS OF ANTRUM.

DEFORMITY.

The antrum is equally distended. The antrum is *unequally* distended.

INFLAMMATORY SYMPTOMS.

<p>Acute <i>inflammatory symptoms</i> are present, such as :</p> <p>Chills, Great pain, “ sensitiveness to touch, Edema of face, Increased pulse, and “ temperature.</p>	<p>No acute inflammatory symptoms are present (such as pain, œdema, great sensitiveness and constitutional disturbance).</p>
--	--

FLUCTUATION.

Fluctuation often appears in advanced stages. Fluctuation is absent, as a rule.

DISCHARGE INTO MOUTH OR NOSE.

<p>A tendency to the discharge of pus through the teeth sockets, or through the nostril during forced expiration, or in certain positions of the body exists.</p>	<p>No tendency towards a spontaneous discharge of the contents of the cavity of the antrum is apparent.</p>
---	---

EXPLORING NEEDLE.

<p>The exploring needle in cases of doubt decides the diagnosis.</p>	<p>The exploring needle gives negative results.</p>
--	---

SYMPTOMS IN COMMON.

<p>Both are often associated with</p> <p>“ “ “ “</p> <p>“ “ “ “</p> <p>“ “ “ “</p> <p>“ “ “ “</p> <p>“ “ “ “</p> <p>“ “ “ “</p> <p>“ “ “ “</p>	<p>projection of the eyeball.</p> <p>effacement of the nostril.</p> <p>depression of roof of mouth.</p> <p>bulging of the cheek.</p> <p>closure of the lachrymal duct.</p> <p>interference with mastication.</p> <p>“ “ deglutition.</p> <p>parchment-like crepitus when the bone becomes thin.</p>
--	---

SPECIAL TYPES.

CYSTIC TUMOR OF ANTRUM. MALIGNANT TUMOR OF ANTRUM.

RAPIDITY OF GROWTH.

The tumor grows slowly. The tumor grows rapidly.

AGE.

The tumor occurs in the young. The tumor occurs late in life, as a rule.

PAIN.

The tumor is painless. Great pain is present of a peculiar lancinating character.

PALPATION OF TUMOR.

The tumor is smooth, hard and elastic. The tumor has no elasticity, but may be hard, or fluctuant in spots in late stages.

MUCOUS MEMBRANE OF MOUTH.

The mucous membrane of the mouth is healthy. The mucous membrane of the mouth is involved as a rule.

HEMORRHAGE.

No tendency to hemorrhage exists. Hemorrhages occur frequently and are often severe in character.

SYMPTOMS IN COMMON.

Both *may* be associated with protrusion of eyeball.
 “ “ “ “ depression of roof of mouth.
 “ “ “ “ effacement of nostril.
 “ “ “ “ closure of lachrymal duct.
 “ “ “ “ impairment of mastication.
 “ “ “ “ “ “ deglutition.
 “ “ “ “ bulging of the cheek.

SPECIAL TYPES.

EXTRA-CRANIAL TUMORS.

INTRA-CRANIAL TUMORS.

RESPIRATORY MOVEMENTS.

The tumor shows no respiratory movements.

The tumor shows "*respiratory movements*," rising with expiration, and falling with inspiration, from pressure on the vessels.

SIZE OF TUMOR.

The tumor is constant in its size, save as its growth causes it to enlarge.

The tumor is frequently enlarged in size during fits of coughing or of crying.

REDUCIBILITY.

The tumor cannot be made to disappear on direct pressure.

The tumor can be reduced within the skull, either entirely or in part, by pressure upon it.

EFFECTS OF PRESSURE.

No cerebral symptoms of compression are produced by pressure upon the tumor.

Cerebral symptoms indicative of compression often occur on attempts at reduction of the tumor.

The tumor is constant in its size, either under pressure, or when pressure is removed.

The tumor returns after reduction when the pressure is removed.

ABNORMAL APERTURE IN BONE.

No aperture in the cranial bones can be detected.

An aperture in the bone is often felt after the tumor has been reduced.

SYMPTOMS IN COMMON.

Both may be associated with an absence of cerebral disturbance.

“ “ “ “ similar feel and consistence.

“ “ “ “ rapid or slow formation.

“ “ “ “ absence of apparent causation, or knowledge of congenital defect.

SPECIAL TYPES.

EXOSTOSES OF CRANIUM.

SEBACEOUS TUMORS.

PALPATION OF TUMOR.

The tumor has a characteristic bony hardness.

The tumor is often tense and hard, but has *elasticity*.

MOBILITY OF TUMOR.

The tumor is immovable under the skin.

The tumor moves freely under the integument.

CONDITION OF DUCTS.

No abnormal condition of the ducts of the part is perceived.

An obstruction to the ducts is evidenced by a small black spot over the seat of the tumor.

EFFECTS OF PRESSURE.

Firm pressure causes no change in the tumor.

Firm pressure often evacuates the contents of the sac, causing a foul, offensive-smelling, cheesy-like material to exude.

SYMPTOMS IN COMMON.

Both are frequently multiple.

“ “ of slow growth.

“ “ distinctly circumscribed in outline.

DISLOCATIONS.



DISLOCATIONS.

By the term *dislocation* is meant "a *solution* of the *contiguity* of *bone*."

Dislocations may be either complete or partial. To the latter type the term *subluxation* is applied.

Dislocations may result from five distinct classes of causes :

1. Direct violence.
2. Indirect violence.
3. Muscular contraction.
4. Disease of the articular surfaces of the bone.
5. Destruction of the ligaments by ulceration, suppuration, or injury.

The general symptoms of dislocation are

1. Deformity of the joint.
2. Impaired function of the joint.
3. Change in the axis of the injured limb.
4. Disturbed relation of the bony prominences of the joint from their normal bearing to each other.
5. Difficult reduction.
6. Local pain and altered sensibility of parts supplied by special nerves.

Dislocations may be classified into the following varieties :

- A. *Simple Dislocations*, where the articular surfaces of a joint are displaced, but the surrounding tissues are normal.
- B. *Compound Dislocations*, where the displaced articular surfaces of the joint are in communication with the external air.
- C. *Complicated Dislocations*, where nerves, vessels, muscles, cavities, or organs are implicated, from injury produced by the displacement.
- D. *Spontaneous Dislocations*, where the displacement of the ar-

ticular surfaces of a joint occurs from disease, without apparent external causation.

E. *Congenital Dislocations*, where the articular surfaces of a joint are not in their normal position at the time of birth.

Dislocations of special joints will be considered in this volume in the following order :

1st.	Dislocations of the Inferior Maxilla.
2d.	“ “ Shoulder Joint.
3d.	“ “ Clavicle.
4th.	“ “ Elbow Joint.
5th.	“ “ Wrist Joint.
6th.	“ “ Hip Joint.
7th.	“ “ Knee Joint.
8th.	“ “ Ankle Joint.

Many types of these varieties are often obscure, and are sources of frequent error in diagnosis.

Each source of doubt as to the variety of injury present will be considered as the special dislocations are reviewed, since it is impossible to group into a general classification the many points of differentiation which pertain to individual localities.

DISLOCATIONS OF THE JAW.

The dislocations of the inferior maxilla may be unilateral or bilateral.

The condyle of the jaw slips from the glenoid fossa into the zygomatic fossa, and the coronoid process of the inferior maxilla impinges upon the malar prominence.

This type of dislocations ensues either from spasmodic contraction of the depressor muscles of the chin, or from blows delivered upon the chin when the mouth is widely open.

Dislocations of the jaw are to be diagnosed from each other, and from

1. Congenital sub-luxation of one side.
2. Chronic rheumatic arthritis of the tempero-maxillary articulation.

Dislocations of the jaw are quite frequently met with in surgical practice, and having once occurred are liable to occur again.

UNILATERAL DISLOCATION
OF JAW.BILATERAL DISLOCATION
OF JAW.

SEPARATION OF TEETH.

The teeth are displaced, but are not widely separated.

The teeth are widely separated, and the mouth is open.

DISPLACEMENT OF CHIN.

The chin is deflected towards the affected side.

The chin is projected forwards, but is not deflected.

APPEARANCE OF CHEEK.

The coronoid process produces a bulging of the cheek on the affected side.

The cheeks are flattened.

HOLLOW AT EAR.

An indistinct hollow is felt at the ear.

An *empty space* is felt in front of and below each ear.

POWER OF ARTICULATION.

The articulation of words is only slightly embarrassed.

The articulation of labials is impossible.

MASSETER MUSCLE.

The masseter muscle is slightly prominent on side affected.

Both masseter muscles stand out in bold relief.

TEMPORAL FOSSA.

The temporal fossa on the affected side is nearly normal in appearance.

The temporal fossæ on both sides are filled with the displaced temporal muscles.

FACIAL EXPRESSION.

The expression of the face is one of simple distortion.

The expression of the face is one of distress and alarm.

SYMPTOMS IN COMMON.

Both are associated with deformity and pain.

- | | | | | |
|---|---|---|---|--------------------------------|
| “ | “ | “ | “ | impaired mobility. |
| “ | “ | “ | “ | “ articulation of words. |
| “ | “ | “ | “ | “ mastication. |
| “ | “ | “ | “ | <i>salivation.</i> |
| “ | “ | “ | “ | change in expression. |
| “ | “ | “ | “ | projection of the under teeth. |

UNILATERAL DISLOCATION
OF JAW.CONGENITAL DISLOCATION
OF JAW.

MOBILITY.

The movements of the jaw are greatly embarrassed.

Movement of the jaw is but slightly impaired,—is often normal.

TEETH.

The teeth are separated and the chin is deflected.

The *upper teeth* project beyond the under teeth.

SALIVATION.

Salivation is present, and is often annoyingly profuse.

Salivation is slight, and may often be absent.

APPEARANCE OF CHEEK.

The cheek is prominent on the affected side.

The fulness of the cheek is absent, from osseous and *muscular* atrophy.

LENGTH OF FACE.

The two sides are not markedly altered in length.

One side of the face is markedly longer than the opposite.

ALTERATION OF FEATURE.

The features are slightly altered by the deflection of the chin, and the prominent cheek.

The features are twisted, and are not symmetrical.

SYMPTOMS IN COMMON.

Both may be associated with abnormal position of the teeth.

“ “ “ “ salivation.

“ “ “ “ alteration in feature.

“ “ “ “ absence of perfect symmetry of the two sides of the face.

DISLOCATION OF THE JAW. CHRONIC RHEUMATIC ARTHRITIS of the TEMPERO-MAXILLARY ARTICULATION.

ADVENT.

The disease is of *sudden* advent. The disease comes on slowly.

PAIN.

The pain felt is not referred to the region of the glenoid fossa. Constant pain *at the seat of articulation* exists; increased by dampness, or atmospheric changes.

AGE.

Dislocation occurs at any age; is frequent in adult life. It occurs in the *old*, as a rule.

EFFECTS ON FUNCTION.

The function of the jaw is destroyed, in the bilateral variety. The functions of the joint are embarrassed, but not destroyed.

GLENOID FOSSA.

An empty space exists in front of the ear. The *enlarged condyles* can frequently be felt in front of, and below the ears.

GLANDULAR ENLARGEMENT.

No glandular enlargement is present. Enlargement of the parotid, and of the glands behind the ear often exists.

SALIVATION.

Salivation is present, and is profuse. Salivation is usually absent.

SYMPTOMS IN COMMON.

Both are associated with facial distortion.
 “ “ “ “ projecting *under teeth*.
 “ “ “ “ *pain*.
 “ “ “ “ *impaired function*.

DISLOCATIONS AT THE SHOULDER JOINT.

The upper end of the humerus may be dislocated in five directions, as follows :

- A. DOWNWARDS, called the "SUB-GLENOID" dislocation; the head of the bone lying below the glenoid cavity, and felt in the cavity of the axilla.
- B. DOWNWARDS and BACKWARDS, called the "SUB-SPINOUS" dislocation; the head of the humerus lying underneath the spine of the scapula.
- C. DOWNWARDS and INWARDS, called the "SUB-CORACOID" dislocation; the head of the humerus lying deep down underneath the coracoid process.
- D. FORWARDS and INWARDS, called the "SUB-CLAVICULAR" dislocation; the head of the humerus lying under the clavicle.
- E. UPWARDS and INWARDS, called the "SUPRA-CORACOID" dislocation; the coracoid process being fractured by the humerus, and the articular head of that bone being apparent above the clavicle. This dislocation, however, is very rare.

The anatomical names applied to the various dislocations of the humerus out of the glenoid cavity are based, as can be seen by the above, on the abnormal location of the *displaced* articular head of the humerus. I shall employ them in the following diagnoses as they best convey, to my mind, the condition of body, which they are intended to express.

Dislocations of the *Shoulder Joint* are to be diagnosed

- 1st. From each other.
- 2d. " separation of the greater tubercle of the humerus.
- 3d. " fracture of the neck of the humerus.
- 4th. " " " " " scapula.

SUB-GLENOID DISLOCATION. FRACTURE OF THE NECK
OF HUMERUS.

ACROMION.

The acromion process of the scapula is pointed and prominent.

The acromion process is only slightly prominent, since the upper fragment of the humerus is still in its normal position.

DEPRESSION AT SHOULDER.

A distinctly marked depression exists *immediately* below the acromion.

An indistinct depression exists a *short distance* below the acromion process, at the seat of fracture.

TUMOR IN AXILLA.

A large, smooth and rounded tumor is felt high up in the axilla, —(displaced head of bone).

An irregular and pointed tumor is felt low down in the axilla,—(lower fragment of humerus).

CREPITUS.

Crepitus is usually absent.

Crepitus can be easily obtained, but is transient if the extending force be removed.

LENGTH OF ARM.

The length of the arm is *increased*.

The length of the arm is *diminished*.

DIRECTION OF ELBOW.

The elbow cannot be made to touch the affected side of the chest.

The elbow can easily be approximated to the side of the chest.

AXILLARY FOLD.

The anterior fold of the axilla is often prominent.

The axillary walls are normal in appearance.

REDUCIBILITY.

Reduction is difficult, but *permanent* when accomplished.

Reduction is easily accomplished, but is *transient* if the force be removed.

SUB-GLENOID DISLOCATION
(*continued*).

FRACTURE OF THE NECK
OF HUMERUS
(*continued*).

HISTORY.

A history of a fall upon the hand or elbow, when removed from the chest ; or of a direct blow downwards on the upper part of the humerus exists.

A history of direct violence is usually present.

MOTION.

Voluntary motion is lost, and communicated motion is limited in its extent.

Voluntary motion is lost, but communicated motion is very free under an anæsthetic.

SUB-CLAVICULAR DISLOCATION. SUB-SPINOUS DISLOCATION.

HISTORY.

Oecurs in falls upon the shoulder or elbow, when the arm is directed backwards.

Oecurs in falls upon the shoulder or elbow, when the arm is directed forwards.

ACROMION PROCESS.

The acromion process and the depression underneath it are most marked posteriorly.

The acromion process and the depression underneath it are most marked anteriorly.

LENGTH OF ARM.

The length of the arm is *shortened*.

The length of the arm is *normal*, or occasionally lengthened.

POSITION OF ELBOW.

The elbow is directed backwards, and is separated from the chest.

The elbow is directed forwards, and separated from the chest.

The forearm is usually also flexed upon the arm.

PAIN.

The pain is severe in character, and is usually constant.

The pain is only severe when attempts at motion are made.

VOLUNTARY MOTION.

The voluntary motion is very limited.

Voluntary motion is less limited than in any other dislocation.

COMMUNICATED MOTION.

Communicated motion is restricted *outwards* and *forwards*.

Communicated motion is restricted *backwards* only.

HEAD OF HUMERUS.

The displaced head is felt as a tumor rotating with the humerus, below the clavicle.

The displaced head of the humerus is felt to rotate under the spine of the scapula, near its angle.

SYMPTOMS IN COMMON.

Both are associated with deformity.

“ “ “ “ altered axis of limb.

“ “ “ “ pain.

“ “ “ “ possible erepitus.

“ “ “ “ increased circumferential measurement of the joint.

“ “ “ “ impairment of function.

“SUB-SPINOUS” DISLOCATION.

SEPARATION OF THE GREAT TUBERCLE.

TUMOR.

The tumor felt upon the scapula is large and rounded,—(displaced head).

The tumor upon the scapula is small,—(displaced tubercle).

The tumor rotates with the humerus.

The tumor is not affected by rotation of humerus.

AGE.

Is frequent at all periods of life.

Is frequent in youth, under 15th year.

GLENOID CAVITY.

The glenoid cavity is empty as felt through the axilla.

The glenoid cavity is filled.

PROMINENCE OF ACROMION.

The acromion and coracoid processes are prominent.

The acromion and coracoid processes are *not* markedly prominent.

DEPTH OF SHOULDER.

The shoulder affected is not altered in its antero-posterior measurement.

The affected shoulder is greatly *increased in depth*, and the deltoid region is distorted in its appearance.

COMMUNICATED MOVEMENTS.

Elbow cannot touch the side of chest.

The elbow can be made to touch the side of the chest, and the hand can be placed by the surgeon in almost any position.

The hand cannot touch the top of head.

The hand cannot touch the *opposite shoulder*.

REDUCTION.

Reduction is accomplished by extension and motion.

Reduction is accomplished by outward rotation of the humerus and pressure over the humerus and the fragment.

TENDENCY TO RETURN.

The reduction is *permanent* when accomplished.

The reduction is *transient* if the force be removed.

SYMPTOMS IN COMMON.

Both are associated with deformity.

“ “ “ “ pain.

“ “ “ “ impairment of function.

“ “ “ “ a history of accident.

"SUB-CORACOID" DISLO-
CATION."SUPRA-CORACOID" DISLO-
CATION.

ORIGIN.

Occurs in falls upon the shoulder or elbow when the arm is directed backwards.

Occurs from the same form of accident, but with force enough to usually *fracture* the coracoid process.

SHORTENING.

The arm is slightly shortened.

The arm is usually markedly shortened.

MOBILITY OF ARM.

Motion of the arm is restricted *outwards* as the bone impinges upon the coracoid process.

The motion of the arm is restricted forwards and outwards.

LOCATION OF TUMOR.

The tumor is felt underneath the coracoid process of the scapula and is obscure in its outline.

The tumor is felt upon the coraco-acromial ligament, touching externally the inner border of the acromion, and projecting under and raising the deltoid muscle, and possibly piercing it.

POSITION OF ELBOW.

The elbow is directed backwards and is separated from the chest.

The elbow is not directed markedly backwards, but is slightly separated from the chest.

ACROMION.

The acromion process is most prominent posteriorly and the depression under it is more noticeable behind than in front.

The acromion process may be *masked* anteriorly by the deltoid prominence over the dislocated head of the humerus.

SYMPTOMS IN COMMON.

Both are associated with deformity.

"	"	"	"	impairment of function.
"	"	"	"	abnormal axis of limb.
"	"	"	"	pain.
"	"	"	"	restricted movement.
"	"	"	"	history of an accident.

DISLOCATIONS OF THE CLAVICLE.

The dislocations possible to the clavicle are of seven varieties. Three of these are confined to the sternal end, three to the acromial end, while a rare case of simultaneous dislocation of both ends has been recorded.

The sternal end of the clavicle may be dislocated *upwards, forwards, or backwards*; the displaced head being separated from its normal sternal attachments, and the axis of the bone being no longer symmetrical with that of its fellow.

The dislocations of the acromial end of the clavicle are as follows:

1. "SUPRA-ACROMIAL,"—when the clavicle rests upon the upper surface of the acromion process.—(This variety is *most* frequent.)
2. "INFRA-ACROMIAL,"—where the clavicle is, by some violent wrench, slipped underneath the acromion process.—(Very rare.)
3. "INFRA-CORACOID,"—when the outer end of the clavicle is wedged underneath the coracoid process of the scapula.—(Very rare.)

The dislocations of the outer end of the clavicle are of far greater frequency than those of the sternal extremity, although any of the displacements of the clavicle are rare when compared with fractures of that bone.

Dislocations of the clavicle are, as a rule, easy of diagnosis. The deformity produced by the displaced extremity of the bone, the shortening of the shoulder, the impaired motion and local pain will usually render the diagnosis positive.

The dislocation of the *sternal end backwards* may perhaps lead to some confusion in diagnosis, and deserves, therefore, special mention.

This displacement has been known to result from severe direct blows, such as a kick of a horse, a violent fall upon the shoulder, being crushed between a carriage and a wall, etc., etc., and also to occur *independently* of any accident, by progressive *lateral curvature* of the spine.

Its importance, in a surgical aspect, lies in the alarming symptoms which may be produced by the pressure exerted upon the trachea, œsophagus and large blood-vessels, by the displaced head of the sternum. Thus, in several cases, have symptoms of ap-

proaching death been relieved only by rapid reduction, and by appropriate surgical appliances for the maintenance of the bone in its normal position.

The absence, then, of the normal prominence of the sternal end of the clavicle, following a severe injury, or occurring with lateral curvature, should always lead towards a suspicion of partial or complete luxation, and especially so if symptoms indicative of impeded respiration, circulation, or deglutition accompany the deformity.

The so-called *dislocations of the scapula* are too often only partial luxations of the acromial end of the clavicle. In fact it is almost an anatomical impossibility for the scapula to be turned upon its edge, thus allowing the latissimus dorsi muscles to slip behind it, without an altered relation at the clavico-scapular articulation. In this condition, however, the scapula stands out from the back like a rudimentary wing, and causes a most marked and striking deformity.

DISLOCATIONS OF THE ELBOW JOINT.

The dislocations at the elbow joint may be divided into two great varieties :

- A. Where both bones of the forearm are simultaneously displaced.
- B. Where only a single bone of the forearm is displaced from its normal position.

Under the *first class*, A, may be enumerated :

1. Dislocation of both bones of the forearm *directly backwards*.

This dislocation is the *most common* form, and is not infrequently associated with fracture of the *coronoid process* of the ulna.

2. Dislocation of both bones of the forearm *backwards and inwards*.
3. Dislocation of both bones of the forearm *backwards and outwards*.
4. Dislocation of both bones of the forearm *forwards*.

This dislocation is *very rare*, and when present is usually associated with fracture of the olecranon process of the ulna.

5. Dislocation of the ulna *backwards* and the radius *forwards*.

This type of dislocation is infrequent.

Under the *second class*, B, may be enumerated :

1. Dislocation of the ulna *backwards*.
2. " " " *inwards*.
3. " " " *forwards*.
4. Dislocation of the radius *backwards*.
5. " " " *outwards*.
6. " " " *forwards*.

Of these last-named dislocations of single bones of the forearm, many are rare ; and some, if present, are too easily recognized to cause possible error in diagnosis.

Should doubt exist in these cases, however, the impaired mobility of the joint, the deviation from the normal appearances of the bony prominences as compared with those of the uninjured member, and the alteration in length either of the forearm, or of the upper extremity, will easily confirm the diagnosis of dislocation.

I have enumerated in detail in the following pages, therefore, only those dislocations of the elbow joint which are liable to be confounded with each other, or to be mistaken for either fracture or severe contusion in the immediate neighborhood of the elbow.

BOTH BONES OF FOREARM FRACTURE ABOVE THE CON-
BACKWARDS. DYLES OF THE HUMERUS.

HISTORY OF ACCIDENT.

Occurs in falls upon the hand, or on the forearm, when the humerus is fixed.

Occurs in falls upon the elbow.

ANTERIOR TUMOR.

A large, oval-shaped tumor (the lower end of the humerus), is felt anteriorly *below* the crease of the elbow.

A small pointed tumor (the upper fragment of humerus), is felt anteriorly, lying *above* the crease of the elbow.

POSTERIOR TUMOR.

A tumor is perceived posteriorly which exhibits the outline of the displaced bones.

A large posterior tumor is perceived, which exhibits the outline of the two condyles and the olecranon process.

OLECRANON.

The olecranon process is separated from the condyles of the humerus.

The relation between the olecranon process and the condyles of the humerus is normal.

MOBILITY.

The joint is usually immovable.

Extreme mobility is present.

CREPITUS.

Crepitus is either absent, or, if present, is of a rubbing character.

Crepitus is always present, and is of that fine grating character characteristic of fracture.

LENGTH OF HUMERUS.

The humerus is normal in length on measurement from the acromion process to the external condyle.

The humerus is shortened, as detected by measurement from the acromion process to the external condyle.

BOTH BONES OF FOREARM BACKWARDS (<i>continued</i>).	FRACTURE ABOVE THE CON- DYLES OF THE HUMERUS (<i>continued</i>).
---	--

REDUCTION.

Reduction is difficult, but permanent when effected.

Reduction is easily produced by extension, but is transient if the force be removed.

SYMPTOMS IN COMMON.

Both are associated with shortening of the entire limb.

“ “ “	“ a tumor in front of normal situation of joint.
“ “ “	“ a tumor behind the “ “ “
“ “ “	“ pain.
“ “ “	“ history of an accident.
“ “ “	“ alteration in the normal mobility.
“ “ “	“ impaired function.

BOTH BONES OF FOREARM
BACKWARDS.RADIUS FORWARDS AND
ULNA BACKWARDS.

MOTION OF THE JOINT.

Extension and flexion of the joint *may* be retained to a slight degree. All motion is lost in the affected joint.

POSITION OF THE FOREARM.

The forearm is not twisted from its normal attitude. The forearm and hand are slightly flexed and twisted inwards.

DIAMETERS OF THE JOINT.

The transverse diameter of the joint is normal, and the antero-posterior diameter only slightly increased. The antero-posterior diameter of the joint is markedly increased, and the transverse diameter diminished.

CONDITION OF TENDONS.

The biceps tendon is *tense*. The biceps and triceps tendons are both *relaxed*.

ANTERIOR TUMOR.

The anterior tumor which exists is large, and *below* the crease of the elbow. The anterior tumor is small, and is *above* the crease of the elbow.

POSTERIOR TUMOR.

The posterior tumor exhibits the contour of the two displaced bones. The posterior tumor exhibits the contour of the projecting olecranon.

HISTORY OF ACCIDENT.

A history of a fall upon the hand, or upon the forearm when the humerus was fixed, is present. A history of a fall upon the hand, associated with twisting of the forearm exists.

SYMPTOMS IN COMMON.

Both are associated with altered relations between the bony prominences of the joint.

“	“	“	“	greatly impaired motion.
“	“	“	“	an anterior and posterior tumor.
“	“	“	“	alteration in the <i>diameters</i> of the joint.
“	“	“	“	pain.
“	“	“	“	shortening of the entire limb.
“	“	“	“	normal length of the humerus.

BOTH BONES OF FOREARM
FORWARDS.BOTH BONES OF FOREARM
BACKWARDS.

FREQUENCY.

Is of very rare occurrence, and is usually associated with fracture of the olecranon process of the ulna.

Is a frequent dislocation, and may be associated with a fracture of the coronoid process of the ulna.

CONDYLES OF HUMERUS.

The condyles of the humerus are prominent *posteriorly*.

The condyles of the humerus are prominent *anteriorly*.

TENSION OF PARTS.

The parts anterior to the joint are very tense.

The biceps tendon is tense, but the integument is normal.

PROJECTION OF THE OLECRANON.

The projection of the olecranon process is absent.

The projection of the olecranon process is present, posteriorly.

MOBILITY OF FOREARM.

The forearm can be extended straight, and even more than straight; so as to render the coronoid process and the head of the radius prominent.

The forearm may possibly admit of *slight* flexion and extension, and may, in some cases, be immovable.

LENGTH OF FOREARM.

The forearm is usually lengthened.

The forearm is shortened.

POSITION OF FOREARM.

The forearm is slightly flexed, or it may be extended.

The forearm is extended, as a rule.

CIRCUMFERENCE OF JOINT.

The circumference of the joint is diminished.

The circumference of the joint is usually markedly increased.

CREPITUS.

Crepitus exists, if fracture be present.

Crepitus may exist, if the coronoid be fractured.

BOTH BONES OF FOREARM FORWARDS (<i>continued</i>).	BOTH BONES OF FOREARM BACKWARDS (<i>continued</i>).
--	---

PAIN AND SWELLING.

The pain and swelling are very severe. The pain and swelling are moderate in severity.

SYMPTOMS IN COMMON.

Both are associated with	prominence of the condyles of the humerus.		
“ “ “	“	localized tension of soft parts.	
“ “ “	“	alteration in the length of forearm.	
“ “ “	“	altered circumference of the joint.	
“ “ “	“	possible crepitus.	
“ “ “	“	local pain and swelling.	

BOTH BONES OF FOREARM ULNA ALONE, BACKWARDS.
BACKWARDS.

APPEARANCE OF ELBOW.

An anterior tumor exists *below* the crease of the elbow. An anterior depression exists over the seat of the ulnar articulation.

HEAD OF RADIUS.

The head of the radius is dis- placed. The head of the radius is normal.

EFFECTS ON MOTION.

Pronation and supination are lost. Pronation and supination are normal.
Flexion and extension of the joint are lost, or very limited. Flexion and extension of the joint are difficult and very painful.

LENGTH OF FOREARM.

Both sides of the forearm are equally shortened. The ulnar side of the forearm is shortened.

AXIS OF FOREARM.

The forearm is usually in the direct line of the arm. The forearm and hand are slightly flexed.

POSITION OF THE HAND.

The hand is supinated. The hand is turned inwards.

SWELLING.

The swelling is marked, and occurs early after the accident. The swelling is slight, as a rule.

CIRCUMFERENCE OF THE JOINT.

The circumference of the joint is often greatly increased. The circumference of the joint is nearly normal.

SYMPTOMS IN COMMON.

Both are associated with an abnormal projection of the olecranon.
 “ “ “ “ relaxation of the triceps muscle.
 “ “ “ “ impaired function of the joint.
 “ “ “ “ pain and swelling at the joint.
 “ “ “ “ a history of an accident.
 “ “ “ “ shortening in the forearm.
 “ “ “ “ alteration in measurements of the joint.

RADIUS BACKWARDS.

RADIUS FORWARDS.

FREQUENCY.

Is a rare deformity.

Is the most common displacement of the radius.

POSITION OF THE HAND.

The hand is pronated, and the arm turned outwards.

The hand is twisted inwards, as a rule.

LOCATION OF TUMOR.

A tumor is felt *behind* the elbow, which rotates on motion of the radius.

A tumor is felt *in front of* the elbow, which rotates with a similar motion in the radius.

ABNORMAL DEPRESSION.

A depression exists anteriorly over the normal seat of the head of the radius.

A depression exists posteriorly, which is most marked at the external condyle.

MOTION OF HAND.

Supination of the hand is lost; and flexion of the forearm is difficult, or absent.

Pronation of the hand is free, but supination is very painful.

BICEPS TENDON.

The biceps tendon is very tense.

The biceps tendon is relaxed.

HISTORY OF ACCIDENT.

A history of a fall upon the hand when pronated and extended, exists.

A history of a fall upon the hand when supinated and extended, is present.

SYMPTOMS IN COMMON.

Both are associated with free but painful extension of forearm.

- | | | | | |
|---|---|---|---|--|
| “ | “ | “ | “ | inability to permit of flexion to a right angle. |
| “ | “ | “ | “ | an abnormal tumor. |
| “ | “ | “ | “ | “ “ depression. |
| “ | “ | “ | “ | impaired motion of hand and pronation. |
| “ | “ | “ | “ | pain at elbow joint. |

ULNA BACKWARDS.

ULNA FORWARDS.

DEFORMITY.

An anterior depression exists over the seat of the normal articulation of the ulna.

A posterior depression and an anterior tumor are produced.

MOVEMENT OF HAND.

Pronation and supination are normal.

Pronation and supination are liable to be somewhat impaired.

MOTIONS OF FOREARM.

Extension and flexion of the forearm are difficult and painful.

Extension and flexion are painful, but not markedly restricted, as the olecranon is usually broken.

POSITION OF FOREARM.

Forearm and hand often slightly flexed.

The forearm is usually markedly flexed.

SWELLING.

Swelling slight, as a rule.

The swelling about the joint is severe.

OLECRANON.

Olecranon process felt displaced backwards.

The olecranon is usually *fractured*; it may be normal in position, or loose and freely movable.

CREPITUS.

No crepitus is discovered.

Crepitation is often present, as the ulna is usually fractured.

SYMPTOMS IN COMMON.

Both are associated with shortening of the ulnar side of forearm.
“ “ “ “ normal position of radius.
“ “ “ “ . impaired function of joint.
“ “ “ “ local pain and swelling.
“ “ “ “ history of an accident.

DISLOCATIONS AT THE WRIST.

A. The *carpus* may be dislocated in four directions from the radius :

1. Dislocations of the *carpus* FORWARDS.
2. " " " BACKWARDS.
3. " " " INWARDS.
4. " " " OUTWARDS.

Dislocations of the wrist joint are to be diagnosed from

- 1st. SPRAIN of the wrist joint.
- 2d. COLLES' FRACTURE.
- 3d. TRANSVERSE FRACTURE of both bones of the forearm close to the joint.
- 4th. SEPARATION OF THE EPIPHYSES of the ulna and of the radius.

B. All the *separate bones of the carpus* may, in rare cases, be individually displaced ; but the "os magnum," only, is commonly dislocated.

The other carpal bones are so seldom altered in position as to be safely excluded from probable sources of error in diagnosis.

C. The *lower end of the ulnar* may be displaced upon the radius and *carpus*.

This displacement may be either *forwards* or *backwards*.

It is not infrequently associated with fracture of the radius, and follows violent attempts at pronation or supination of the hand.

DISLOCATION OF THE
CARPUS.

COLLES' FRACTURE.

DEFORMITY.

The deformity is bilateral, and has none of the peculiar "silver fork" displacement.

The deformity is confined to the radial side of the wrist, and has been likened to the "silver fork" in common use, the finger being analogous to the tines.

CREPITUS.

No crepitus is present.

Crepitus is present, unless the impaction is firm.

ABNORMAL TUMOR.

An abnormal tumor is present on one surface only of the forearm.

An abnormal tumor exists on each surface of the forearm.

This tumor is *smooth* and *round*.

These tumors are *sharp* and *pointed*.

LENGTH OF RADIUS.

The radius is normal in length.

The radius is shortened.

LENGTH OF UPPER EXTREMITY.

The limb is shortened.

The limb is normal in length on the ulnar side.

STYLOID PROCESS OF ULNA.

The styloid process of the ulna is *higher* than that of the radius.

The styloid process of the ulna is *lower* than that of the radius.

The styloid process of the ulna is not markedly prominent.

The styloid process of the ulna is *markedly* prominent.

SYMPTOMS IN COMMON.

Both are associated with a history of a fall upon the hand.

" " " " deformity near the wrist.

" " " " local pain and swelling.

" " " " abnormal appearance of the styloid process of the ulna.

" " " " loss of function.

DISLOCATION OF THE
CARPUS.SPRAIN OF THE WRIST
JOINT.

DEFORMITY.

The deformity is of a marked character, and is due to *bone* as detected by the touch.

The deformity is often slight, but if severe is due to swelling; no abnormal bony tumor being present.

SHORTENING.

The forearm, including the hand, is found to be shortened, by measurement from the inner condyle of the elbow to the tips of the fingers.

No shortening can be detected by measurement.

MOBILITY OF JOINT.

The joint is less movable than normal, even under an anæsthetic.

The joint shows normal mobility under anæsthetics.

DEVELOPMENT OF SYMPTOMS.

The symptoms appear immediately after the accident.

An interval of time often elapses between the accident and the development of symptoms.

DURATION OF SYMPTOMS.

The symptoms are permanent, when once developed, until reduction is effected.

The symptoms are often relieved by simple local applications.

SYMPTOMS IN COMMON.

Both are frequently associated with great pain.

“	“	“	“	“	“	swelling.
“	“	“	“	“	“	deformity about the joint.
“	“	“	“	“	“	history of an accident.
“	“	“	“	“	“	impaired motion.

DISLOCATION OF THE
CARPUS.TRANSVERSE FRACTURE OF
BOTH BONES CLOSE TO
THE WRIST.

SEAT OF DISPLACEMENT.

The seat of displacement can be located below the radius.

The seat of displacement is above the styloid process of the radius.

TUMOR.

The bony projection is smooth and broad.

The bony projections are rough, irregular in shape, and often pointed.

LENGTH OF INFERIOR TUMOR.

The inferior tumor attached to the hand is *short*, consisting only of the carpus.

The inferior tumor attached to the hand is *long*, consisting of the carpus and lower fragments of the bones of the forearm.

CONDITION OF TENDONS.

The tendons on one surface of the forearm are *tense*.

The tendons of the forearm are relaxed on both surfaces.

STYLOID PROCESSES.

The styloid processes of the radius and ulna are prominent, and abnormal in their bony relations.

The styloid processes of the radius and ulna are not prominent, and are normal in their relations.

LENGTH OF RADIUS AND ULNA.

The radius and ulna are normal in length.

The radius and ulna are both shortened.

MOBILITY.

The joint is partially fixed.

Great mobility exists at the seat of fracture.

CREPITUS.

Crepitus is absent as a rule.

Crepitus is well marked.

REDUCTION.

Reduction is permanent.

Reduction is transient, when the extending force is removed.

SYMPTOMS IN COMMON.

Both are associated with shortening of the upper extremity.

"	"	"	"	local pain.
"	"	"	"	" swelling.
"	"	"	"	" deformity.
"	"	"	"	" impaired function.

DISLOCATION OF THE
CARPUS.SEPARATION OF THE EPI-
PHYSES OF RADIUS AND
ULNA.

AGE AFFECTED.

Occurs at any age.

Occurs in the *young*.

BONY TUMOR.

The bony projection is regular in contour, the separate individual bones being indistinguishable.

The bony projections are often distinct, and can be felt as two smooth tumors.

SEAT OF DISPLACEMENT.

The seat of displacement is below the radius.

The displacement occurs above the styloid process of the radius.

TENDONS.

The tendons are tense on one surface of the forearm.

The tendons are relaxed on both surfaces of the forearm.

LENGTH OF RADIUS AND ULNA.

The radius and ulna are of normal length.

The bones of the forearm are found shortened on measurement.

STYLOID PROCESSES.

The styloid processes of the radius and ulna are prominent.

The styloid processes of the bones of the forearm are normal in their relation to the carpus.

SYMPTOMS IN COMMON.

Both	are	associated	with	the	<i>absence of crepitus.</i>
“	“	“	“	“	shortening of the upper extremity.
“	“	“	“	“	<i>smoothness</i> of the tumor.
“	“	“	“	“	impaired function.
“	“	“	“	“	history of an accident.
“	“	“	“	“	local pain and swelling.
“	“	“	“	“	easy reducibility.

LOWER END OF ULNA
BACKWARDS.

LOWER END OF ULNA
FORWARDS.

HISTORY OF ACCIDENT.

Oecurs during forced pronation of the hand.

Oecurs during forced supination of the hand.

LOCATION OF STYLOID PROCESS OF ULNA.

The outline of the lower end of the ulna is felt behind the joint lying slightly across the radius.

The outline of the lower end of the ulna can be detected as an abnormal tumor in front of the joint.

MOTION OF HAND.

Supination of the hand is impossible.

Pronation of the hand is impossible.

POSITION OF HAND.

The hand is markedly *pronated*.

The hand is in a position of forced *supination*.

SYMPTOMS IN COMMON.

Both are associated with a diminished transverse diameter of the joint.

“	“	“	“	an increase in the antero-posterior diameter of the joint.
“	“	“	“	an internal displacement of the hand.
“	“	“	“	normal regularity in the line of the ulna.
“	“	“	“	limited and painful flexion and extension of the hand.
“	“	“	“	shortening from inner condyle of the elbow to the tip of the little finger.
“	“	“	“	normal length from inner condyle to styloid process of ulna.
“	“	“	“	flexion of forearm, hand and fingers.
“	“	“	“	altered axis between styloid process of ulna and metacarpal bone of little finger.
“	“	“	“	absence of crepitation.
“	“	“	“	increased circumference of joint.
“	“	“	“	local pain, swelling and oedema.

DISLOCATION OF THE "OS MAGNUM." GANGLION AT WRIST.

HISTORY OF CAUSATION.

Is usually produced by a fall upon the hand when in a state of flexion.	Is usually the result of excessive use of the tendons, as in piano playing, etc., etc.
---	--

SITUATION OF TUMOR.

The tumor is situated in a line with the metacarpal bone of the middle finger, and always on the back of the wrist.	The tumor is not confined to any definite locality, and may be on either surface of the wrist.
---	--

VARIATION IN SIZE OF THE TUMOR.

The size of the tumor is often augmented by flexion of the hand.	The size of the tumor is not actually increased by flexion of the hand.
--	---

The size of the tumor is often diminished by extension of the hand.	No diminution in the actual size of the tumor follows extension of the hand.
---	--

PALPATION OF TUMOR.

The tumor is hard and bony on palpation.	The tumor is highly elastic to the touch.
--	---

REDUCIBILITY.

The tumor is reducible by direct pressure.	The tumor is not reducible, save by rupture of its sac.
--	---

SYMPTOMS IN COMMON.

Both are associated with a tumor at wrist.	
" " " " " freedom of motion.	
" " " " " little pain or discomfort.	

DISLOCATIONS AT THE HIP JOINT.

The head of the femur may be dislocated from the cavity of the acetabulum in four directions, as follows :

- A. BACKWARDS, called the "SCIATIC NOTCH" dislocation ; the head of the femur lying within the great sciatic notch.
- B. BACKWARDS AND UPWARDS, called the "DORSUM ILII" dislocation ; the head of the femur lying upon the dorsum of the ilium.
- C. DOWNWARDS AND INWARDS, called the "THYROID," or "OBTURATOR" dislocation ; the head of the femur lying within the obturator, or thyroid foramen.
- D. UPWARDS AND INWARDS, called the "PUBIC" dislocation ; the head of the femur lying upon the ramus of the pubes, underneath the psoas and iliacus muscles.

Dislocations of the femur are to be diagnosed

1. From each other.
2. " fracture of the femur with inversion of the foot.
3. " intra-capsular fracture of the femur.
4. " severe contusion over the trochanter.

In the following pages I shall employ, in speaking of the various dislocations of the femur at the hip joint, those anatomical names given to each from the location of the head of the femur in its displaced position, and mentioned above.

"DORSUM ILII."

"SCIATIC NOTCH."

POSITION OF THE LIMB.

The large toe of the affected side rests upon the opposite *instep*.

The large toe of the affected side rests upon the opposite *large toe*.

POSITION OF TUMOR.

An abnormal tumor is felt plainly on the posterior portion of the ilium.

An abnormal tumor is very indistinctly perceived posteriorly, and in fat subjects it is often not detected.

SHORTENING.

Shortening of the limb is *marked*.

Shortening of the limb is *slight*.

INVERSION OF THE FOOT.

The foot is markedly inverted.

The inversion of the foot is of moderate extent.

DEFORMITY AT THE HIP.

The deformity at the hip is very apparent.

The deformity of the hip is slight, and often scarcely perceptible.

FLEXION OF THE THIGH.

The flexion of the thigh upon the pelvis is slightly marked.

The thigh is markedly flexed upon the pelvis, and attempts at extension of the thigh produce an arching of the back.

SYMPTOMS IN COMMON.

Both are associated with	displacement upwards of the fold of the nates.
" " "	" shortening of the limb.
" " "	" inversion of the foot.
" " "	" displacement of the trochanter.
" " "	" impaired voluntary motion.
" " "	" impossibility of abduction of the limb.
" " "	" " " outward rotation of the limb.
" " "	" flexion of the thigh upon the pelvis.
" " "	" " " leg " " thigh.

"SCIATIC NOTCH."

FRACTURE OF THE FEMUR,
WITH INVERSION OF
THE FOOT.

MOBILITY OF LIMB.

The affected limb is impaired as to its mobility.

The mobility of the injured limb is often increased.

REDUCIBILITY.

Reduction of the deformity is difficult, but permanent when effected.

Reduction of the deformity is easy by simple extension of the limb, but is transient if the force be not maintained.

CREPITATION.

No crepitus is present.

Crepitus is present, unless extreme impaction exists.

SHORTENING.

Slight shortening of the limb is present.

The shortening is well marked.

ABNORMAL TUMOR.

An abnormal tumor exists which is felt to rotate on motion of the femur.

The upper fragment often fails to participate in the movements of the femur.

HISTORY.

Is most frequent in middle life, and is associated with direct violence.

If *intracapsular* in variety it may occur in the old, and from slight and indirect violence.

INVERSION OF FOOT.

Inversion of the foot is permanent until reduction of the dislocation is accomplished.

The foot may become everted after extension of the limb, if the inversion be due to impaction of the fragments.

SYMPTOMS IN COMMON.

Both are associated with inversion of the foot.

“ “ “ “ shortening of the limb.

“ “ “ “ an abnormal tumor.

“ “ “ “ a history of an accident, (as a rule).

“ “ “ “ impaired function.

“ “ “ “ a normal position of the trunk.

“PUBIC” DISLOCATION. “THYROID” DISLOCATION.

HISTORY OF THE ACCIDENT.

Occurs from direct violence to the back of the thigh during abduction of the femur ; or from the body being thrown backwards, while the thigh is fixed.

Occurs in falls associated with violent abduction and inward rotation of the femur ; as in falls where the limbs are separated, especially when a burden is upon the back.

FOLD OF NATES.

The fold of the nates is *raised*.

The fold of the nates is *lowered*.

LOCATION OF HEAD OF FEMUR.

The head of the femur is felt under the psoas and iliacus muscles.

The head of the femur is felt below the groin, and almost in the perineum.

POSITION OF TROCHANTER.

The trochanter of the femur is carried forwards, and is almost in a vertical line with the anterior superior spine of the ilium.

The trochanter of the femur is carried backwards.

LENGTH OF LIMB.

The affected limb is frequently shortened.

The affected limb is lengthened.

POSITION OF FOOT.

The foot is everted.

The foot points straight forwards.

SYMPTOMS IN COMMON.

Both are associated with *pain* which is very severe.

“ “ “ “ tension of the psoas and iliacus.

“ “ “ “ limited voluntary motion.

“ “ “ “ loss of the power of adduction.

“ “ “ “ “ “ “ “ rotation outwards.

“ “ “ “ the axis of the femur pointing downwards and outwards.

“ “ “ “ the history of an accident.

"PUBIC" DISLOCATION.

FRACTURE OF THE NECK
OF THE FEMUR.

TROCANTER.

The trochanter of the femur is carried forwards.

The trochanter is less prominent than normal.

The trochanter is never displaced towards the median line in front.

The trochanter is normal in its prominence.

HEAD OF FEMUR.

The head of the femur is felt in a displaced position.

The head of the bone is felt to be normal in its situation.

CREPITATION.

No crepitus is perceived.

Crepitation is distinctly obtained.

REDUCIBILITY.

The reduction is difficult, but permanent when effected.

The reduction is easy under simple extension, but is transient if the force be not maintained.

MOBILITY OF LIMB.

The mobility of the affected limb is impaired.

The mobility of the injured limb is increased.

SYMPTOMS IN COMMON.

Both are associated with *eversion* of the foot.

- | | | | | |
|---|---|---|---|-----------------------------------|
| " | " | " | " | impaired voluntary motion. |
| " | " | " | " | shortening of the limb. |
| " | " | " | " | a history of an accident. |
| " | " | " | " | severe local pain. |
| " | " | " | " | swelling and possible ecchymosis. |

DISLOCATION AT THE
HIP JOINT.CONTUSION OVER THE
TROCHANTER.

LENGTH OF THE LIMB.

The limb is always altered as to its length, by actual measurement.

The limb is *apparently* shortened, due to relaxed ligaments and muscles, and pelvic inclination to relieve the pain.

MOTIONS OF JOINT.

The motions of the injured femur are restricted, even under anæsthetics.

Free and normal movement can be established under anæsthetics.

TROCHANTER.

The trochanter is altered from its normal relation.

The trochanter is normal in its position.

HEAD OF FEMUR.

The head of the femur is felt to be displaced.

The head of the femur is normal in its position.

EFFECTS OF REST.

The symptoms due to the *displacement only* are constant until relieved by reduction.

The symptoms disappear with rest and local applications.

SYMPTOMS IN COMMON.

Both may be associated with severe local pain.

- | | | | | |
|---|---|---|---|---|
| “ | “ | “ | “ | extensive œdœmyosis. |
| “ | “ | “ | “ | loss of function and voluntary motion in joint. |
| “ | “ | “ | “ | apparent shortening of limb. |
| “ | “ | “ | “ | the history of an accident. |
| “ | “ | “ | “ | <i>eversion</i> of the foot. |

TABLE OF DISLOCATIONS AT THE HIP JOINT.

"SCIATIC."	"DORSUM ILII."	"THYROID."	"PUBIC."
LENGTH OF LIMB.			
Slight shortening.	Marked shortening.	Lengthening.	Slight shortening.
POSITION OF THE FOOT.			
Toe on opposite toe.	Toe on opposite instep.	Foot straight.	Foot everted.
POSITION OF THE LIMB.			
Slight flexion of the thigh and leg. The femur points inwards.	Slight flexion of the thigh and leg. The femur points inwards.	Leg extended, abducted and brought forwards. The femur points downwards and outwards.	Limb is abducted and extended, or slightly flexed. The femur points downwards and slightly outwards.
POSITION OF THE TRUNK.			
Little affected.	Little affected.	Bent forwards. Psoas and iliaeus tense.	Bent forwards. The psoas and iliaeus are tense.
LOCATION OF HEAD OF FEMUR.			
Behind acetabulum.	Behind and above acetabulum.	Below the groin.	At upper part of the groin.
FOLD OF THE NATES.			
<i>Raised.</i>	Raised and everted backwards.	Lower than normal.	<i>Raised.</i>
EFFECTS UPON MOTION.			
Adduction and rotation easy. Abduction and outward rotation impossible.	Adduction and int. rotation easy. Abduction and ext. rotation impossible.	Abduction and flexion easy. Adduction, extension and int. rotation impossible.	Abduction and rotation out. easy. Adduction and rotation inwards impossible.
APPEARANCE OF HIP.			
Hip is prominent.	Prominent and raised.	Flattened and sunken.	Flattened.
POSITION OF TROCHANTER.			
Looks forwards.	Looks forwards.	Is inclined backwards.	Is carried forwards and inwards.
Is less prominent.	Is less prominent.	Is less prominent.	Is nearer the median line.
Is approximated to ant. spine of ilium.	Is approximated to the ant. spine of ilium.	Is removed from ant. spine of ilium.	Is less prominent.

DISLOCATIONS AT THE KNEE.

Two bones may be dislocated at the knee joint, viz. : the TIBIA and the PATELLA.

The dislocations of the tibia from its normal relation to the lower end of the femur may be of five varieties :

- A. Dislocation of the TIBIA FORWARDS, the lower end of the femur impinging upon the popliteal space, and its nerves and vessels.
- B. Dislocation of the TIBIA BACKWARDS, the popliteal space being made tense by the backward projection of the *tibia*.
- C. Dislocation of the TIBIA OUTWARDS.
- D. Dislocation of the TIBIA INWARDS.
- E. Dislocation of the TIBIA from ROTATION of that bone, which is *very rare*, but of which several cases have been reported.

Of these five dislocations the *forwards* and *backwards* dislocations are those most commonly met with in surgical practice.

The dislocations to which the patella is subject may be of four varieties :

- A. Dislocation of the PATELLA OUTWARDS, the bone lying to the outer side of the knee joint.
- B. Dislocation of the PATELLA INWARDS, the bone lying to the inside of the knee joint.
- C. Dislocation of the PATELLA UPWARDS, the inferior ligament of the patella being ruptured and the bone displaced by the contraction of the quadriceps extensor muscle of the thigh.
- D. Dislocation of the PATELLA between the FEMUR and the TIBIA,—called the “ROTARY DISPLACEMENT.” In this case the patella is twisted upon itself, turned upon its edge, and impacted between the two bones forming the articulation at the knee joint.

Of the dislocations to which the patella is subject the *lateral* displacements are, by far, the most common ; and of the two lateral displacements the OUTWARD variety is the one most frequently encountered.

Dislocations of the *patella* are more frequently produced by muscular action than displacements of any other bone, save the inferior maxilla.

They may be complete, or only partial in extent, and can never be produced without more or less extensive laceration of the capsule of the joint as an existing complication.

(Experiments of Professor Streubel.)

The various dislocations at the knee joint admit of little opportunity for error, save in accurately determining the variety and amount of luxation. The *upward dislocation* of the *patella* might possibly be confounded with a transverse fracture of that bone, when the seat of fracture was low down, near its inferior border, or when the dislocation is masked by swelling, thus rendering palpation negative in its results. In this latter case, however, the disappearance of the swelling would reveal the smooth contour of the dislocated bone high up above the knee, while in the former case the small remnant of bone attached to the inferior ligament of the patella might at first be overlooked, but subsequently would be discovered by a careful examination of the joint.

TIBIA BACKWARDS.

TIBIA FORWARDS.

APPEARANCE OF JOINT.

The condyles of the *femur* are felt in front of the joint.

The condyles of the *tibia* project in front.

PATELLA.

The anterior surface of the patella looks downwards and backwards.

The anterior surface of the patella looks upwards and forwards.

POPLITEAL SPACE.

The tibia encroaches upon the popliteal space, which is separated from the femur.

The femur is driven into the popliteal space as a wedge, if the dislocation be complete.

LIGAMENT OF PATELLA.

The ligament of the patella is not prominent.

The inferior ligament of the patella is prominent and tense.

AXIS OF LIMB.

The axis of the limb is markedly irregular.

The axis of the limb is not greatly altered.

LENGTH OF LIMB.

The length of the limb is normal.

The length of the limb is *diminished*.

VOLUNTARY MOTION.

Voluntary motion is destroyed.

Voluntary motion may exist to a slight degree.

COMMUNICATED MOTION.

Communicated motion is very limited and very painful.

Communicated motion is possible in the antero-posterior direction, but it is very painful.

SYMPTOMS IN COMMON.

Both are associated with pain.

“	“	“	“	local numbness and œdema.
“	“	“	“	ecchymosis.
“	“	“	“	increased circumference of the joint.
“	“	“	“	absence of crepitation.
“	“	“	“	displacement of the patella.
“	“	“	“	impaired function.
“	“	“	“	“ motion.

TIBIA IN ROTARY DISLO-
CATION.LATERAL DISLOCATION OF
TIBIA.

FREQUENCY.

A very rare type of dislocation.

Not a rare dislocation.

DEFORMITY.

The *inner* condyle is generally separated from the femur by rotation, the outer condyle being normal; or both condyles may be simultaneously rotated from their normal relations.

The condyles of the tibia project laterally, with a corresponding depression upon the side opposite.

POSITION OF FOOT.

The foot is either everted or inverted, and the tubercle of the tibia is displaced.

The foot is usually normal in its direction, and the tubercle of the tibia points forwards.

POSITION OF LIMB.

The limb is semiflexed, as a rule.

The limb is often extended, but *may* be rotated and slightly flexed.

DIAMETERS OF JOINT.

The *antero-posterior* diameter of the joint is usually increased at one side.

The *lateral* diameter of the joint is usually augmented.

FIBULA.

The head of the fibula is displaced.

The head of the fibula is normal in its relation to the tibia.

SYMPTOMS IN COMMON.

Both	may	be	associated	with	lateral	displacement	of	patella.
“	“	“	“	“	normal	length	of	limb.
“	“	“	“	“	impaired	motion.		
“	“	“	“	“	a	history	of	accident.

PATELLA INWARDS.

PATELLA OUTWARDS.

FREQUENCY.

A very rare accident.

A common form of injury.

ORIGIN.

Occurs from falls upon some projecting body which drives the patella forcibly inwards.

Occurs often in muscular efforts, as in springing sideways to avoid an accident, from wrestling, or it may follow injury from sudden falls upon the knee, especially if the inner side of the patella be struck.

CAPSULAR LIGAMENT.

The capsular ligament is *always lacerated*, and, if the dislocation be complete, extensively injured. (Experiments of Streubel.)

The capsular ligament *may escape laceration*, even if the dislocation be complete.

REDUCIBILITY.

Is reduced with great difficulty from tension of the ligaments.

Is reduced easily.

SYMPTOMS IN COMMON.

Both are associated with *increased breadth* of the knee.

“ “ “ “ slight flexion.

“ “ “ “ fixation of the joint.

“ “ “ “ marked pain on communicated attempts at motion.

“ “ “ “ abnormal anterior aspect of joint.

“ “ “ “ abnormal lateral projection of edge of the patella.

PATELLA ROTATED.

PATELLA UPWARDS.

ORIGIN.

Occurs most frequently from direct blows upon the patella, when the knee is bent, but it has been known to occur from muscular action in jumping.

Occurs either from violent muscular effort to prevent *falling backwards* which results in rupture of the inferior ligament of the patella, or from traumatic division of this ligament.

POSITION OF LIMB.

The limb is forcibly extended and the knee joint is immovable.

The limb cannot be voluntarily extended, nor bear the slightest weight upon it.

POSITION OF PATELLA.

The patella is twisted so that its lateral borders take the position of its upper and lower borders. The outer edge is frequently buried between the condyles.

The patella is carried upwards upon the anterior surface of the femur, and a marked hollow exists below it at the anterior aspect of the joint.

REDUCIBILITY.

The patella is reduced with difficulty. It is performed either by forcible flexion of the knee, by pressure upon the edges of the bone when the leg is extended, or by cutting the tendon of the quadriceps extensor muscle. Occasionally the joint has to be opened and an elevator used to replace the bone.

Is reduced easily by elevation of the heel and strong extension upon the quadriceps extensor muscle.

DISLOCATIONS AT THE ANKLE.

The astragalus may be displaced from its normal situation between the malleoli of the tibia and the fibula, in one of five different directions, as follows :

- A. Dislocation of the ASTRAGALUS FORWARDS, the bone slipping partially or wholly out of its attachments to the bones of the leg.
- B. Dislocation of the ASTRAGALUS BACKWARDS.
- C. Dislocation of the ASTRAGALUS OUTWARDS, the internal malleolus being often fractured, and the deltoid ligament either ruptured, or put upon extreme tension.
- D. Dislocation of the ASTRAGALUS INWARDS, the external malleolus being usually fractured.
- E. Dislocation of the ASTRAGALUS UPWARDS between the two bones of the leg, causing their separation, and increased circumferential measurement of the joint. (This dislocation is very rare.)

Of these dislocations the last three are liable to be associated with fracture, since in the *outward* or *inward* displacements the malleoli are frequently chipped off by the astragalus as it is twisted from its normal position, and in the *upward* displacement the fibula is frequently fractured by the wedge-like action of the astragalus as it is driven between the bones of the leg.

Dislocations of the astragalus are to be diagnosed

1. From each other.
2. " fracture of both bones.
3. " severe sprain of joint.
4. " congenital deformities.
5. " acquired " "

ASTRAGALUS BACKWARDS. ASTRAGALUS FORWARDS.

LENGTH OF FOOT.

The foot is markedly shortened. The foot is markedly lengthened.

PROMINENCE OF THE HEEL.

The heel is made prominent. The heel projection is diminished.

ABNORMAL TUMOR.

The articular surface of the astragalus is felt behind the malleolus. The articular surface of the astragalus is felt in front of the joint.

TENDO ACHILLIS.

The tendo Achillis is tense and prominent. The tendo Achillis is relaxed and concave.

DISPLACEMENT OF MALLEOLI.

The malleoli are displaced forwards and downwards towards the sole of the foot. The malleoli are displaced backwards and downwards towards the sole of the foot.

APPEARANCE OF THE TOES.

The toes are flexed. The toes are drawn upwards.

POSITION OF THE HEEL.

The heel is elevated. The heel is depressed.

SYMPTOMS IN COMMON.

Both may be associated with *crepitus* from fracture of the malleoli.

“ are associated with alteration in the axis of the foot to that of the leg.
 “ “ “ “ alteration in the length of the foot.
 “ “ “ “ impaired function of the joint.
 “ “ “ “ local pain and swelling often.
 “ “ “ “ history of an accident.

ASTRAGALUS UPWARDS. FRACTURE OF BOTH BONES.

SEAT OF FRACTURE.

The fibula is usually fractured, but the tibia is intact as a rule. *Both bones* are felt to be displaced, and often the line of fracture can be perceived in each.

POSITION OF MALLEOLI.

The malleoli are carried downwards towards the sole of the foot. The relation between the malleoli and the sole of the foot is normal.

MOBILITY OF ANKLE.

The mobility at the ankle joint is greatly impaired. The ankle joint has freedom of movement.

CIRCUMFERENCE OF JOINT.

The circumference of the ankle joint is greatly increased. The ankle corresponds in circumference with its fellow.

BREADTH OF JOINT.

The breadth of the ankle joint is greatly increased. The breadth of the ankle joint is normal.

PAIN AND SWELLING.

Great pain and swelling are present within the joint. Pain, swelling and ecchymosis exist at the seat of fracture.

CREPITUS.

If the fibula is not fractured no crepitation will exist. Crepitation is very marked and easily obtained.

SYMPTOMS IN COMMON.

Both are associated with shortening of the leg.
 “ “ “ “ severe pain.
 “ “ “ “ marked and rapid swelling.
 “ “ “ “ crepitus, as a rule.
 “ “ “ “ history of an accident.

ASTRAGALUS EXTERNALLY. ASTRAGALUS INTERNALLY.

SOLE OF FOOT.

The sole of the foot is turned outwards.

The sole of the foot is directed inwards.

SEAT OF FRACTURE.

The internal malleolus is often fractured.

The external malleolus is usually fractured.

SWELLING AND PAIN.

The swelling and tenderness are most marked over the internal malleolus, and are due both to fracture and rupture of the *deltoid ligament*.

The pain and tenderness on pressure, as well as the swelling, are usually most marked at the external malleolus.

ABNORMAL TUMOR.

The articular surface of the astragalus is often felt underneath the internal malleolus.

The articular surface of the astragalus is perceived underneath the external malleolus, if the dislocation be complete.

SYMPTOMS IN COMMON.

Both are associated with crepitation, as a rule.
“ “ “ “ local pain and swelling.
“ “ “ “ impaired function of the joint.
“ “ “ “ a history of accident.
“ “ “ “ an abnormal attitude of foot.

DISLOCATION AT ANKLE.

SEVERE SPRAIN.

CREPITATION.

Crepitus is frequently detected from a fracture of the malleolus.

Crepitation is never present in simple sprain.

ATTITUDE OF JOINT.

An abnormal attitude of the foot is present even under an anæsthetic.

The foot will assume a normal position, if the pain is relieved by an anæsthetic.

TIME OF THE APPEARANCE OF DEFORMITY.

The deformity appears immediately after the occurrence of the accident.

Some interval of time may elapse before the deformity appears, even though the accident be severe.

MOBILITY OF THE JOINT.

The mobility of the joint may be seriously impaired even under anæsthetics.

The normal mobility of the joint will be revealed by anæsthetics.

EFFECT OF REST.

The symptoms and deformity are not affected by rest, and are only relieved by a reduction.

The symptoms often subside on rest and local applications.

SYMPTOMS IN COMMON.

Both	may	be	associated	with	severe	local	pain.
“	“	“	“	“	“	“	constitutional disturbance.
“	“	“	“	“	“	“	extensive swelling.
“	“	“	“	“	“	“	altered attitude of joint.
“	“	“	“	“	“	“	impaired function of joint.
“	“	“	“	“	“	“	impaired mobility.
“	“	“	“	“	“	“	a history of accident.

DISLOCATION OF ANKLE. CONGENITAL OR ACQUIRED
DEFORMITY, WITH INJURY.

HISTORY OF PATIENT.

A normal joint has previously existed. A history of previous deformity will be present.

CONDITION OF THE BONES.

The bones will be normal in development. The bones will probably be distorted.

MOBILITY OF JOINT.

The normal movement in tarsus and metatarsus will be perceived. Ankylosis may exist in the smaller articulations, from disuse.

REDUCIBILITY.

The deformity can be reduced easily, as a rule. The deformity will probably resist all well-directed attempts at reduction.

CONDITION OF MUSCLES.

The muscles of the region will exhibit no unnatural conditions, save, possibly, laceration. Atrophy and contracture of certain muscles, or sets of muscles, will doubtless exist if the deformity be of long standing.

APPEARANCE OF INTEGUMENT.

No abnormal thickening of integument will be discovered. An abnormal thickening of the integument, or a cushion of fat will have been developed, if locomotion has been admitted of upon the deformed member.

FRACTURES.

FRACTURES.

By the term "FRACTURE," is meant "a solution of the continuity of a bone."

The varieties of fracture possible to long bones may be

- A. SIMPLE FRACTURE, where the bone is normal, save at the direct seat of the fracture, and the surrounding tissues are uninjured.
- B. COMPOUND FRACTURE, where the seat of the fracture communicates with the external air.
- C. COMMINUTED FRACTURE, where the bone is broken into fragments of small size.
- D. MULTIPLE FRACTURE, where the shafts of long bones are broken in several distinct localities.
- E. COMPLICATED FRACTURE, where either joints, vessels, muscles, cavities, or organs are involved.
- F. INCOMPLETE FRACTURE, called also the "green-stick" fracture, where the fracture is incomplete but is still apparent from abnormal direction of the bone, or from a false point of motion existing.
- G. IMPACTED FRACTURE, where the fragments of the injured bone are driven into each other by a continuation of the force producing the original injury.

The *flat bones*, when injured, may present the following varieties of fracture :

- A. SIMPLE FRACTURE, where the bone is not displaced from its normal position, or the surrounding tissues involved.
- B. DEPRESSED FRACTURE, where a displacement of the bone's fragments exists.
- C. COMMINUTED FRACTURE, where separate fragments of the bone are detached from their normal position.

- D. FISSURES OF BONE, where a bone is simply split, without displacement.
- E. PUNCTURED FRACTURE, where a sharp instrument depresses or loosens a circumscribed portion only of the injured bone.
- F. "FRACTURES BY CONTRE-COUP," where a force directly applied produces, by *transmission*, a fracture at a point remote from the seat of direct injury.

As we deal, however, almost exclusively with fractures of *long bones*, save in injuries of the cranium, and as the particular forms of fracture pertaining to flat bones will be considered in detail under the "Injuries of the Head," I shall, hereafter, in speaking of fracture, confine my remarks to fracture of the long bones only.

Fracture of long bones may be divided, also, according to the *direction* of the line of fracture, into

- 1st. LONGITUDINAL FRACTURE.
- 2d. TRANSVERSE FRACTURE.
- 3d. OBLIQUE FRACTURE.

SYMPTOMS OF FRACTURE.

The general symptoms of fracture common to most of its varieties may be thus enumerated:

1. CREPITUS, by which term is meant a peculiar grating sensation, perceived by the touch and, in some cases also, by the ear, on approximating the fragments and causing them either to rub together, or rotate upon each other. This symptom may in cases of impaction, or in parts deeply imbedded in tissues, possibly be undetected, but when present it is a most characteristic and positive evidence of the existence of a fracture.
2. A FALSE POINT OF MOTION. This symptom of fracture may also be undetected in some cases, especially in the incomplete and longitudinal varieties. It may also be unperceived, or imperfectly recognized when fractures occur in the immediate vicinity of joints, which are deeply imbedded in muscles,

and where, for that reason, the exact point from which motion proceeds can easily become a subject of question, or of doubt. In these cases, however, the simultaneous appearance of crepitation is often of the greatest diagnostic value, even if the crepitation be in itself obscure.

3. DEFORMITY. Fractures, as a rule, are characterized by marked deformity. Especially is this the case when the fractured bone is superficial in its situation, and the seat of injury uncovered by muscular tissue.

The extent of the deformity depends partly upon the relation of the insertion of muscles to the seat of fracture, though it may also be influenced by the variety of injury received, and by the region of the body at which the fracture is located.

4. IMPAIRED FUNCTION OF THE LIMB, OR PART AFFECTED. This symptom is modified greatly by circumstances. It is not a positively diagnostic indication of fracture, as a severe contusion, or sprain will often produce an equal effect upon the usefulness of a member or some special anatomical region.
5. LOCALIZED PAIN. The seat of pain is often indicative of the location of a fracture, although by pressure upon nerve trunks by displaced fragments, a sense of extreme pain may occasionally be produced at a part distant from the actual seat of injury.
6. LOCALIZED SWELLING AND TENDERNES TO PRESSURE. This symptom, if associated with the previously mentioned local pain in the same locality, is of value as a *confirmatory* evidence, provided there be sufficient reason to suspect the existence of a fracture; but it is of *little actual diagnostic value* in itself, as it may be associated with any accident resulting in inflammatory changes.
7. POSSIBLE CHANGE IN THE LENGTH AND AXIS OF THE LIMB. It is not infrequent in both dislocation and fracture, that alteration does occur both in the normal *length* and in the *axis* of the injured member. In

fact, so common is this deformity in both, and so seldom does it exist without them, that it becomes at once a most important diagnostic symptom in either.

Dislocation can, however, in obscure cases be often excluded by the partial or complete immobility of the limb, and by the difficult reduction of the deformity.

8. ECCHYMOsis. This is liable to occur when a force is applied to produce a fracture that would more than suffice to result in a severe contusion. It can therefore be considered of confirmatory value only in the diagnosis of fracture.

Fracture as a general surgical condition can be confounded in diagnosis only with dislocation or severe contusion.

The *special fractures* are to be diagnosed, however, from the various surgical conditions liable to affect that particular region of the body where the fracture may exist. These will be considered in connection with the various parts of the body, and in the following order :

- A. FRACTURES OF THE SKULL.
- B. " " FACE.
- C. " " SHOULDER.
- D. " " HUMERUS AT SHOULDER.
- E. " AT THE ELBOW JOINT.
- F. " " WRIST "
- G. " " HIP "
- H. " " KNEE "
- I. " " ANKLE "
- J. " " TRUNK.

I pass first then to the consideration of the diagnoses pertaining to fractures of the skull.

FRACTURES OF THE SKULL.

The skull may be fractured either at its convexity, sides, or base.

Fractures of the skull may result from direct or indirect violence. They may be either simple, depressed, comminuted, compound, fissured, or punctured in variety, and may be classified on a basis either of their *location* or of the mode of their *origin*.

I prefer, however, to enumerate without any special basis several forms of fracture of the skull, which often demand a special diagnosis, and which are indicated by a modification of the symptoms common to the ordinary varieties of fracture.

Fractures of the skull can be thus divided into

- A. FRACTURES OF THE OUTER TABLE ONLY, in which type a *depression* of the bone is perceived, but no symptoms of *compression of the brain* are produced. It is a frequent form of fracture, and, when the depression is slight in degree, ordinary examination will usually fail to detect it provided the scalp is not lacerated, as it is often masked by swelling of the scalp and the periosteal covering.
- B. FRACTURE OF THE OUTER, MIDDLE AND INNER TABLES, constituting the so-called "fracture with *depression*, and with symptoms of *compression* of the brain." This form is frequently associated with laceration of the scalp and periosteum, and can be readily diagnosed by a careful digital examination, and by the rational symptoms of the patient.
- C. FRACTURE OF THE INNER TABLE ONLY, constituting "fracture with *symptoms of compression* of the brain, but with the absence of external depression."

This class of injury can seldom be positively diagnosed, save by exclusion.

It is to be differentiated from traumatic concussion of the brain, from meningeal hemorrhage, and from a possible apoplectic attack associated with traumatism.
- D. "FRACTURE BY CONTRE-COUP," or "FRACTURE BY TRANSMITTED FORCE." This usually occurs from violence applied to some portion of the cranium where the bone is of extreme

thickness, as at the occiput or the parietal eminence. The most frequent seat of this type of fracture is undoubtedly at the base of the skull, though the frontal region and the temporal region may also be fractured by transmission of force applied at a seat remote from these localities.

The *outline* of fractures resulting from *contre-coup* is usually of the stellate, or radiating type.

E. PUNCTURED FRACTURES OF THE SKULL. This type of fracture is the result of direct injury received from a pointed instrument. It may consist of a distinctly circumscribed depression of a *small* portion of bone, or a radiating fracture with a marked indentation at the seat of the injury. Its surgical importance rests chiefly upon the cerebral disturbance immediately resulting from it, and also in the peculiar tendency which this class of fractures possesses in developing *epilepsy*, and diseases dependent on *cerebral irritation* or *pressure* in later years.

F. FISSURES OF THE SKULL. This variety of injury is often undetected during life if the scalp or the periosteum be not involved.

In that case the symptoms of a possible complicating hemorrhage of the meninges of the brain, or the development of symptoms of local abscess within the skull at the seat of injury, might give grounds for a reasonable conjecture.

When the scalp and periosteum are involved, however, the *edge* of the fissure can often be detected by the finger nail, or by a careful examination by a probe.

Frequently, however, an incised wound of the periosteum, if cleanly cut, may resemble a fissure of the bone so closely, that nothing but an enlargement of the superficial wound will enable the surgeon to make a positive exclusion of fracture.

G. FRACTURE OF THE BASE OF THE SKULL. Fracture at the base of the skull is usually the result of transmitted violence, either through the spinal column, by falls upon the feet, or by direct violence to the occiput, producing fracture by "*contre-coup*." Its peculiar symptoms are the only means of diagnosis, as no digital examination can, of

course, be made ; but the results of the fracture are so distinctly apparent in the appearance of the patient and the local and general manifestations present, that little doubt as to diagnosis can exist, provided the fracture is extensive.

Fractures of the skull in general can hardly be confounded with any other surgical condition, save *contusion* or a *laceration of the pericranium*, in the latter of which the possibility of fissure or *masked* fracture may be suspected, or the existence of such wrongly diagnosed from the rigidity of the periosteal wound, its marked outline, and its traumatic origin.

I have added to the following set of diagnostic tables, appertaining purely to fractures of the skull, the symptoms of cerebral compression and concussion in contrast, as they must, of necessity, be mentioned in generalities in connection with fracture, and are of too great surgical importance to be incompletely given.

FRACTURE OF OUTER
TABLE.

FRACTURE OF INNER
TABLE.

DEPRESSION AND CREPITUS.

External evidences of injury to the skull are present on palpation ; and possible crepitus may be detected.

No external evidences of injury of the skull are discovered.

CEREBRAL SYMPTOMS.

No symptoms of cerebral compression, or cerebral irritation are present.

Brain symptoms are usually present indicative of cerebral compression, or cerebral irritation.

CONVULSIONS.

Convulsions are seldom if ever produced.

Convulsions of the epileptic type are liable to result as sequelæ ; or they possibly may exist at the time of the injury.

SYMPTOMS IN COMMON.

Both are associated with a history of injury to the head.
 “ *may* be “ “ external symptoms of contusion.
 “ “ “ “ constitutional disturbance.

FRACTURE OF INNER
TABLE.

APOPLEXY, WITH INJURY.

PREVIOUS HISTORY.

No symptoms of a cerebral character have existed.

A history of cerebral symptoms, as syncope, coma, vertigo, aphasia, etc., may have existed.

ATHEROMA.

No arterial atheroma can be perceived.

Atheroma of the superficial vessels may be detected.

BRAIN SYMPTOMS.

Coma, paralysis, stertorous breathing, irregularity of the pupils, and other symptoms of compression *may* be absent, or may appear some time after the injury. Symptoms also of simple local pressure on special nerves may exist.

Symptoms of cerebral compression will usually be well marked, if the hemorrhage has been sufficient to produce a state of sudden coma, or of injury from falling, and will *usually* exist from the *commencement* of the attack.

SKIN.

The skin may not be markedly altered.

The skin is usually flushed, especially in the region of the head.

AGE.

May occur at any age.

Occurs usually after 40th year of age.

SYMPTOMS IN COMMON.

Both may be associated with injury of the scalp.

“	“	“	“	absence of external evidences of depression of bone.
“	“	“	“	cerebral symptoms, such as convulsions, coma, paralysis, etc.

FRACTURE OF THE BASE
OF SKULL.

CEREBRAL CONCUSSION.

CONDITION OF INSENSIBILITY.

Delirium is frequently present, of a noisy character and associated with jactitation.

The patient is usually in a state of coma from which he can be only partially aroused.

The special senses are often unaffected.

The special senses act feebly.

The state of coma if present tends to increase and deepen.

The coma tends to decrease rapidly.

TEMPERATURE.

The temperature is normal, or elevated.

The temperature is lowered.

PARALYSIS.

Paralysis is often present.

Paralysis is absent.

ESCAPE OF BLOOD.

Blood escapes from the ears, nose, or mouth; and an escape of the cerebro-spinal fluid also takes place from the ears, if the petrous portion of the temporal bone be fractured.

No blood or cerebro-spinal fluid escapes from the ear, nose, or mouth.

ECCHYMOSIS.

Sub-conjunctival ecchymosis appears in lower eyelid within 24 hours after the injury as a rule.

No *ecchymosis* is present, unless dependent on direct traumatism.

SYMPTOMS IN COMMON.

Both	may	be	associated	with	a	history	of	indirect	violence.
“	“	“	“	“	“	“	“	“	coma.
“	“	“	“	“	“	“	“	“	alteration in temperature.
“	“	“	“	“	“	“	“	“	impairment of special senses.

CEREBRAL COMPRESSION.

CEREBRAL CONCUSSION.

INSENSIBILITY.

The coma is profound.

The coma is incomplete.

“ “ may not directly follow the injury.

“ “ “ usually immediate.

“ “ is stationary or increasing.

“ “ rapidly decreases, as a rule.

The special senses are in abeyance.

The special senses act feebly.

TEMPERATURE.

The temperature is normal, or increased.

The temperature is lowered.

MOTION AND SENSATION.

Motion or sensation can be each affected separately, or in common.

Paralysis is absent. The limbs are simply weak and flaccid.

Hemiplegia, occasionally paraplegia, or local paralysis may be present.

Convulsions, in severe cases, may exist, with paralysis on the side opposite.

PULSE.

The pulse is usually *full* and *slow*.

The pulse is *feeble*, *rapid* and *intermittent*.

RESPIRATION.

The breathing is slow and *stertorous*.

The breathing is feeble and *sighing* in character.

EYELIDS.

The eyelids are usually closed and immovable.

The eyelids are usually open and movable.

PUPILS.

The pupils are either natural, dilated, or irregular; but they are always sluggish and show decreased sensibility to light.

The pupils are usually *contracted*; but they act feebly, and are generally sensible to light.

CEREBRAL COMPRESSION
(*continued*).

CEREBRAL CONCUSSION
(*continued*).

SPHINCTERS.

The urine is retained as a rule, and the bowels are obstinately constipated. Incontinence of urine and involuntary evacuations occur.

STOMACH.

Vomiting is rare.

Vomiting is frequently present, as the effects of concussion pass away.

FRACTURES OF THE UPPER JAW.

The superior maxillary bone may be fractured either through direct violence, or from injury indirectly transmitted. It is frequently complicated with laceration of the face, and the gums are, in the majority of cases, involved. It may be either of the simple, compound, or comminuted varieties.

Little error can possibly exist in diagnosis, save when the fracture is masked by severe swelling, and unassociated with any injury to the mucous membrane of the mouth. In such an event, the reduction of the swelling will disclose the existence of a probable deformity, although even in the absence of displacement, or before the swelling can be reduced, a possible *crepitus* may be detected through the swollen parts, and thus an early diagnosis can positively be made.

The embarrassment to mastication would probably be also less marked in contusion, than if a complicating fracture were present, and this alone should be a valuable guide in case justifiable doubt exist.

The deformity, in case of fracture of the superior maxillary bone, varies somewhat with the seat of fracture and the form of violence to which it is due.

The face will usually be seen to present a markedly altered appearance, when contrasted with the healthy side, and the laceration of the gums, the displaced teeth, their imperfect articulation with those of the lower jaw, and a possible fissure along the hard palate, will attract even the patient's attention, from the abnormal sensations produced.

FRACTURES OF THE LOWER JAW.

The lower jaw may be fractured either in its body, ramus, condyle, or coronoid process.

The fracture may be transverse, or oblique in direction; unilateral or bilateral in situation; simple, compound, or comminuted in variety. It is almost invariably the result of direct violence.

If the fracture occur at the ramus, slight deformity will exist. If at the condyle, the chin will be deflected towards the injured side, in which respect it differs from *dislocation* of the bone, and an abnormal hollow will exist behind the ear.

If the coronoid process be fractured, displacement of the fragment

by the temporal muscle will ensue, and the separated portion of the bone will be felt to be so displaced by examination of the injured bone through the mouth.

In fractures of the body of the inferior maxillary bone, the anterior fragment is usually displaced either to the inside of the posterior fragment, or below it.

The mobility of the fragments is most marked in the bilateral variety, while in the fracture of the condyle, and also that of the body of the jaw, the rigidity of the bone is markedly decreased. In fracture of the *ramus*, however, and also in that of the coronoid process, the bone retains nearly its normal power of resistance, save in those cases where comminution exists, in which case great mobility is often present.

Fractures of the lower jaw are liable to be mistaken for dislocation of that bone only, as no other surgical condition can present symptoms which could possibly lead to error.

FRACTURE OF LOWER JAW. DISLOCATION OF JAW.

LINE OF THE TEETH.

The line of the teeth is often irregular. The teeth are perfectly normal.

GUMS.

The gums are often lacerated. The gums are never involved.

BLEEDING.

Bleeding from the mouth is common. Bleeding from the mouth is rare.

CREPITUS.

Crepitation can be detected at the seat of fracture. Crepitation is usually absent, but *may* be felt at the coronoid process.

MOTION.

The movements at the articulations are normal. The movements of the jaw are restricted.

DEPRESSION AT EAR.

No depression exists in front of the ear. A depression is present over the glenoid fossa.

TUMOR.

No tumor is present at the cheek. The coronoid process, when displaced, becomes prominent.

CHIN.

The chin is normal in position. The chin is deflected to the side in the unilateral variety; and displaced forwards in the bilateral variety.

SYMPTOMS IN COMMON.

Both are associated with loss of the power of mastication.

“ may be associated with dribbling of saliva.

“ “ “ “ impairment of power of articulation.

“ are “ “ deformity.

“ “ “ “ history of traumatism.

FRACTURES AT THE SHOULDER.

The fractures at the shoulder include all varieties liable to exist either in the Scapula, Clavicle, or Humerus.

The scapula is seldom, if ever, fractured through indirect violence. A severe accident is usually required to cause serious injury to the bone, as it is protected by its muscular coverings, except at the acromion, coracoid, and spinous processes.

The scapula may present the following varieties of fracture :

- | | |
|----|--------------------------------------|
| A. | FRACTURE OF THE BODY OF THE SCAPULA. |
| B. | “ “ NECK “ “ |
| C. | “ “ ACROMION PROCESS. |
| D. | “ “ CORACOID “ |
| E. | “ “ SPINOUS “ |

Fractures of the scapula are to be diagnosed

1. From each other.
2. “ contusion.
3. “ fracture of the neck of humerus.
4. “ dislocation of the humerus.

From contusion the diagnosis of fracture of the body of the scapula is made chiefly on the presence of crepitus, on localized pressure being made over different portions of the bone. We may have, however, in extensive comminution a change also in the relation of the fragments, on pressure outwards being made upon the angle of the scapula when the shoulder is fixed, and possibly even the edges of the separate fragments may be detected through the investing muscles.

Auscultation also is of value, as crepitus may often thus be perceived from the movements of the fragments during inspiration, as a result of the action of the *serratus muscle*, when it cannot be detected on palpation.

The other points of differential diagnosis pertaining to fractures of the scapula will be found enumerated in the following pages.

FRACTURE OF THE BODY
OF THE SCAPULA.

FRACTURE OF THE SPINE
OF THE SCAPULA.

RELATION OF THE FRAGMENTS.

The fragments of the bone can, in some cases, be felt to overlap each other.

Overlapping of the fragments, if present, cannot be discerned, as the muscles attached to the spinous fossæ conceal the displacement.

PAIN.

The local pain is markedly increased by pressure, coughing and by movements of the arm.

The pain is increased by the motions involving the deltoid and trapezius muscles, but is not affected by coughing to any perceptible degree.

CREPITUS.

Crepitus can be detected often by fixation of the shoulder and movement being communicated to the lower angle of the scapula, or by direct palpation when the arm is moved.

Crepitus is slightly marked, and often absent.

BONY PROMINENCES.

The acromion, coracoid and spinous processes are normal. No fracture of the humerus can be detected, and still crepitation and pain on motion exist.

The acromion process *may* reveal abnormal mobility, if the spine is greatly comminuted; and an irregularity in the spine can be detected often by the finger.

SYMPTOMS IN COMMON.

Both are associated with a history of severe contusion.

- | | | | | |
|---|---|---|---|---|
| “ | “ | “ | “ | restricted and painful motion of arm. |
| “ | “ | “ | “ | absence of the symptoms of fracture of the humerus. |
| “ | “ | “ | “ | local pain and swelling over the scapula. |

FRACTURE OF THE NECK
OF SCAPULA.

FRACTURE OF THE NECK
OF HUMERUS.

PROMINENCE OF THE ACROMION.

The acromion process is very prominent.

The acromion process is usually normal in its appearance.

HOLLOW BELOW ACROMION.

A hollow exists below the acromion process, but less marked than in dislocation downwards into the axilla.

No hollow exists *immediately* below the acromion process.

CORACOID PROCESS.

The coracoid process moves with the humerus, and not with the scapula.

The coracoid process moves with the scapula, and not with the humerus.

CREPITUS.

Crepitation is detected by raising the elbow, and rotation of the humerus while the other hand is placed upon the shoulder.

Crepitation is detected by extension and subsequent rotation, or by carrying the elbow inwards, while extension is continued.

REDUCIBILITY.

Reduction of the deformity is produced by raising the elbow.

Reduction is effected by simple extension of the arm.

LENGTH OF ARM.

The arm is lengthened.

The arm is shortened.

SYMPTOMS IN COMMON.

Both are associated with a history of violence.

“ “ “ “ easy reduction and crepitus.

“ “ “ “ a marked tendency towards return of the deformity.

“ “ “ “ severe pain in shoulder, and often in the hand.

“ “ “ “ marked swelling in shoulder, and often in the hand.

“ “ “ “ change in length of arm.

FRACTURE OF THE NECK OF SCAPULA. DISLOCATION OF HUMERUS.

LENGTH OF LIMB.

The arm is lengthened.

The arm *may* be lengthened or shortened.

REDUCIBILITY.

The reduction is easy and is effected by simply raising the elbow.

The reduction is difficult and is effected by extension and manipulation.

The reduction is transient when the force is not maintained.

The reduction is permanent if once accomplished.

ELBOW.

The elbow can be made to touch the side.

The elbow of the affected limb cannot be approximated to the chest.

AXIS OF LIMB.

The axis of the injured limb is parallel with the median line of the body.

The axis of the affected limb is abnormal.

CREPITATION.

Crepitation is present.

Crepitation is absent.

MOBILITY.

Abnormal mobility exists at the shoulder.

Impaired mobility of the affected side is present.

SYMPTOMS IN COMMON.

Both are associated with a history of traumatism.
“ “ “ “ prominence of the acromion.
“ “ “ “ a hollow beneath the acromion.
“ “ “ “ change in the length of the arm.
“ “ “ “ local pain and swelling.
“ “ “ “ impaired function.

FRACTURES OF THE CLAVICLE.

The clavicle may be fractured in one of three situations :

1. At the sternal end.
2. In its body.
3. At its acromial end.

The varieties of fracture which may affect the clavicle are the simple, compound (very rare), comminuted and the incomplete.

Fractures of the clavicle are more often met with in surgical practice than those of any other bone in the body excepting the radius. They most frequently occur from indirect violence, especially from falls upon the shoulder, or upon the hand when the arm is outstretched ; although the bone may be broken from violence directly applied, and, in rare cases, from muscular action.

The most frequent seat of fracture of the clavicle is near the middle of the bone. The acromial end comes next in frequency, while those of the sternal end are comparatively rare.

When the bone is fractured near its middle, the inner fragment is usually retained in nearly its normal position by the strong ligaments located at its sternal end which prevent great latitude of movement, and by the muscles attached to that portion which are nearly counterbalanced. It may however be elevated in position.

Fractures of the clavicle are extremely common in youth, nearly one-half of all the cases occurring before the fifth year terminates. When adults are subjected to fracture, the preponderance of males affected to females is large, although among children the sexes seem to be equally subject to the accident.

Fractures of the clavicle are associated with many symptoms that are *common* to all of its varieties to a greater or less degree ; among these may be mentioned : 1, local pain ; 2, impaired motion of arm in the antero-posterior direction ; 3, inability to touch the head without assistance ; 4, inclination of the neck and head towards the affected side, and 5, a desire to support the elbow of the affected limb. These symptoms are usually present whether the displacement is marked, or very slight in degree, and are of diagnostic value when the finger of the surgeon cannot positively detect any apparent irregularity in the line of the injured clavicle.

It is seldom, however, that the clavicle is broken without giving in itself distinctive signs of deformity; still when the bone is transversely broken, between the conoid and the trapezoid ligaments, by which the clavicle is bound to the coracoid process of the scapula, no displacement occurs, and the line of the clavicle affords no outward evidence of injury, save by the rational symptoms mentioned above.

FRACTURE OF CLAVICLE IN-SIDE OF THE CORACOID PROCESS.

FRACTURE OF THE CLAVICLE OUTSIDE OF THE CORACOID PROCESS, NEAR THE CONOID LIGAMENT.

DEFORMITY.

A marked deformity is present, due to the projection of the inner fragment, and the displacement of the outer fragment downwards, forwards and inwards.

The deformity which exists is slight. The finger can only detect a slight irregularity in the fractured bone.

APPEARANCE OF SHOULDER.

The shoulder is sunken and drawn inwards towards the chest.

The shoulder is normal in its appearance and position.

LENGTH OF CLAVICLE.

The clavicle is shortened.

The clavicle is of normal length, or possibly slightly shortened.

POSITION OF THE ARM.

The arm is rotated inwards and hangs by the side. The forearm being usually supported by the opposite hand.

The arm is normal in its attitude and in its relations to the trunk.

CREPITUS.

Crepitation is detected on raising the arm and drawing the shoulder backwards and outwards.

Crepitation is obscure, and is detected chiefly by manipulation of the fragments.

MOTION AT SHOULDER.

The motion of the arm is restricted or lost, especially in the movements of elevation and circumduction.

The movements of the arm are nearly normal, unless marked displacement exists.

PAIN.

Pain is present on attempts to touch the head or the opposite shoulder with the hand of affected side.

Pain is markedly present, and located at the seat of injury.

SWELLING AND ECCHYMOISIS.

Swelling and ecchymosis are present and are especially marked if the fracture be due to direct injury.

Swelling and ecchymosis are often absent.

FRACTURES OF THE HUMERUS, NEAR THE SHOULDER JOINT.

The humerus may present at its upper third five distinct varieties of fracture which claim special surgical attention, and which often demand accuracy of diagnosis. These may be enumerated as follows :

- A. SIMPLE INTRA-CAPSULAR FRACTURE, where the head of the humerus is separated by violence from the shaft of the bone within the insertion of the capsular ligament of the shoulder joint, and remains as a distinct fragment, but not entirely deprived of nutrition.
- B. IMPACTED INTRA-CAPSULAR FRACTURE, where the humerus is broken in the same locality as in the preceding fracture, but where the fragments are again united by impaction of the *upper* fragment into the lower.
- C. SIMPLE EXTRA-CAPSULAR FRACTURE, where the humerus is broken just below the tuberosities at its surgical neck, and where the fragments remain separated and distinct.
- D. IMPACTED EXTRA-CAPSULAR FRACTURE, in which the anatomical location of the fracture is the same as that of the one preceding, but where the *lower* fragment is driven into the upper fragment of the bone, thus causing an absence of the unnatural mobility which otherwise would exist.
- E. SEPARATION OF THE GREATER TUBERCLE. This is essentially a fracture of youth in which the epiphysis becomes detached from the bone, and is displaced upon the scapula by the action of the muscles inserted into its three facets.

Each of these fractures has distinctive diagnostic symptoms, and each will therefore be specially considered. Fractures of the upper end of the humerus may be confounded with each other, with fractures of the scapula, with dislocations at the shoulder joint, and with severe contusions of the deltoid region.

SIMPLE INTRA-CAPSULAR FRACTURE OF THE HUMERUS.	SIMPLE EXTRA-CAPSULAR FRACTURE OF THE HUMERUS.
--	--

ACROMION.

The acromion process is slightly prominent.	The acromion process of the scapula is normal in its appearance.
---	--

APPEARANCE OF SHOULDER.

The shoulder is less round than normal.	The shoulder is marked by a hollow one or two inches below the acromion.
---	--

POSITION OF ELBOW.

The elbow easily touches the side of the chest.	The elbow stands out, but can be made to touch the chest.
---	---

LENGTH OF ARM.

No shortening of the arm is usually detected.	The arm is markedly shortened.
---	--------------------------------

MOBILITY.

No unnatural point of motion can be perceived.	A false point of motion is clearly detected.
--	--

UPPER FRAGMENT.

The head of the bone cannot be felt displaced.	The head of the bone is felt to be separated from the shaft, and fails to rotate with it.
--	---

CREPITUS.

Crepitus is obtained only on careful manipulation, combined with pressure over the joint and rotation of the arm.	Crepitation is marked on extension being applied to the arm, and the elbow being carried inward towards the chest.
---	--

PAIN AND SWELLING.

Pain and swelling are present in the vicinity of the joint only.	Pain and swelling are present both at the seat of fracture, and often in the hand and fingers.
--	--

SIMPLE INTRA-CAPSULAR FRACTURE OF THE HUMERUS SIMPLE EXTRA-CAPSULAR FRACTURE OF THE HUMERUS

(continued).

(continued).

ECCHYMOsis.

Ecchymosis is infrequent.

Ecchymosis is usually present.

DISPLACEMENT.

The lower fragment only is displaced inwards.

The upper fragment is displaced upwards and outwards, and the lower fragment inwards.

SYMPTOMS IN COMMON.

Both are associated with a history of injury.

“	“	“	“	erepitus.
“	“	“	“	altered appearance of shoulder.
“	“	“	“	pain and swelling.

IMPACTED INTRA-CAPSULAR FRACTURE OF THE HU- MERUS AT SHOULDER.	IMPACTED EXTRA-CAPSULAR FRACTURE OF THE HU- MERUS AT SHOULDER.
--	--

ACROMION.

The acromion process is quite prominent.

The acromion process is normal, or very *slightly* prominent.

HOLLOW AT SHOULDER.

The hollow beneath the acromion is marked.

No hollow beneath the acromion is present.

LENGTH OF ARM.

The arm is shortened.

The arm is normal in length, as a rule.

HUMERUS.

An irregularity in the upper part of the humerus is felt in the axilla.

An abnormal condition of the bone is often undetected.

RELATION OF FRAGMENTS.

The relation of the head of the bone to the shaft is often altered.

The relation of the fragments is frequently a normal one.

CREPITUS.

Crepitation, if present, is due usually to comminution of the great tuberosity, in which case, pressure over it, combined with rotation of the arm will give crepitus.

Crepitation is usually obscure, and if obtained, it is perceived by holding the joint firmly, while an assistant rotates the arm, with the forearm flexed.

MOTION.

Motion is greatly impaired, but is not entirely lost.

The use of the arm is entirely lost, in the majority of cases.

PAIN AND SWELLING.

Pain is severe, but little swelling is present.

Great pain and marked swelling and ecchymosis are usually present.

SYMPTOMS IN COMMON.

Both are associated with a history of traumatism.

- | | | | | |
|---|---|---|---|--------------------------------------|
| “ | “ | “ | “ | impaired function of limb. |
| “ | “ | “ | “ | local pain and swelling. |
| “ | “ | “ | “ | crepitation, in some instances. |
| “ | “ | “ | “ | frequent prominence of the acromion. |

FRACTURE OF THE NECK OF THE HUMERUS. SUB-GLENOID DISLOCATION.

DEPRESSION AT THE SHOULDER.

An *indistinct* hollow exists at a short distance below the acromion. A distinct hollow exists immediately below the acromion.

ACROMION PROCESS.

The acromion process is not markedly prominent. The acromion process is pointed and very prominent.

AXILLARY TUMOR.

An irregular and pointed tumor is felt low down in the axilla: (lower fragment). A large, smooth and rounded tumor is felt high up in the axilla: (displaced head of humerus).

CREPITUS.

Crepitus is easily obtained by extension and movement of the arm. Crepitus is usually absent.

LENGTH OF ARM.

The length of the arm is shortened. The length of the arm is increased.

POSITION OF ELBOW.

The elbow can easily be made to touch the chest. The elbow cannot be approximated to the chest.

AXILLARY WALLS.

The axillary walls are normal. The anterior fold of the axilla is prominent.

REDUCIBILITY.

Reduction is easily accomplished, but transient if the force be not maintained. Reduction is difficult, but permanent when once effected.

COMMUNICATED MOTION.

Communicated motion, under anaesthetics, is free. Communicated motion is limited in its extent.

HISTORY.

Is usually the result of direct violence. Is produced by falls upon the hand or elbow when removed from the chest; or by a direct blow, downwards, upon the upper part of the humerus.

FRACTURE OF NECK OF THE HUMERUS.

FRACTURE OF THE NECK OF THE SCAPULA.

ACROMION.

The acromion process appears normal.

The acromion process is very prominent.

HOLLOW BELOW ACROMION.

No hollow exists *immediately* below it, but one may exist lower down.

A hollow exists *immediately* under the acromion process which is well marked.

CORACOID PROCESS.

The coracoid process is immovable, save with scapula.

The coracoid process moves with the humerus, and not with the scapula.

CREPITUS.

Crepitation is perceived on extension of the arm and carrying the elbow towards the chest.

Crepitation is detected by raising the elbow, and rotation of the arm when the hand of the surgeon grasps the shoulder.

REDUCIBILITY.

Reduction is effected by direct extension of the arm.

Reduction is effected by raising the elbow.

LENGTH OF ARM.

The arm is shortened.

The arm is lengthened.

SYMPTOMS IN COMMON.

Both are associated with a history of traumatism.

- | | | | | |
|---|---|---|---|---|
| “ | “ | “ | “ | crepitus. |
| “ | “ | “ | “ | easy reduction, but of a transient character. |
| “ | “ | “ | “ | loss of motion. |
| “ | “ | “ | “ | severe pain in the shoulder and hand. |
| “ | “ | “ | “ | marked swelling in the shoulder and hand. |
| “ | “ | “ | “ | a change in the length of the arm. |

SEPARATION OF THE GREAT TUBERCLE OF THE HUMERUS. SUB-SPINOUS DISLOCATION OF THE HUMERUS.

TUMOR ON SCAPULA.

A small tumor is felt upon the scapula, which, however, fails to rotate with the shaft of the humerus.

A large, round tumor is detected upon the scapula, which participates in all the motions communicated to the shaft of the humerus.

AGE AFFECTED.

Is liable to occur only in youth.

Is present in all stages of life.

GLENOID CAVITY.

The glenoid cavity is found to be filled.

The glenoid cavity is found empty.

ACROMION AND CORACOID.

The acromion and coracoid processes are not markedly prominent.

The acromion and coracoid processes are very prominent.

POSITION OF ELBOW.

The elbow can be approximated to the chest.

The elbow cannot be approximated to the chest.

CAPABILITIES OF MOVEMENT.

The hand can be made to touch the top of the head, and can be placed upon the opposite shoulder.

The hand cannot be made to touch the top of the head, or be placed upon the opposite shoulder.

REDUCIBILITY.

The reduction of the deformity is effected by rotation of the arm outwards, combined with pressure over the fragment.

The reduction of the deformity is effected by extension of the arm and manipulation.

RETURN OF DEFORMITY.

The deformity shows a marked tendency to return, when the force is discontinued.

The reduction is permanent if once effected.

SYMPTOMS IN COMMON.

Both are associated with a tumor on the scapula.

“	“	“	“	absence of crepitus.
“	“	“	“	impaired functions.
“	“	“	“	history of an accident.
“	“	“	“	local pain in region of the shoulder.

FRACTURES AT THE ELBOW.

The fractures which occur in the vicinity of the elbow joint may be confined either to the lower end of the humerus, or to the upper ends of the ulna and the radius.

The humerus at its lower third may be fractured in five distinct localities, to each of which surgical attention may be directed, and of each of which an accurate diagnosis can generally be made. These five varieties of fracture can be thus enumerated :

- A. FRACTURE OF THE OUTER CONDYLE OF THE HUMERUS. In which the separation of the outer condyle becomes apparent at the external aspect of the joint and the movements of the *radius* may possibly be interfered with.
- B. FRACTURE OF THE INNER CONDYLE OF THE HUMERUS. In which the separation is felt as a movable fragment at the inner aspect of the joint, and symptoms, referable to injury of the ulnar nerve, may possibly exist in the hand and along the internal border of the forearm.
- C. TRANSVERSE FRACTURE ABOVE THE CONDYLES. In this variety of fracture a displacement of the forearm participates in the injury and many symptoms arise leading towards suspicion of a dislocation of both bones of the forearm backwards upon the humerus. It is by no means an infrequent form of fracture, and is liable, in some cases, to become *compound* in variety from perforation of the integument.
- D. THE SO-CALLED T-SHAPED FRACTURE, consisting of the above-named transverse fracture of the humerus complicated with a fissure running downwards between the condyles and frequently involving the joint.
- E. FRACTURE OF THE EPITROCHLEAR PROCESS OF THE HUMERUS, which can often be detected as a small, detached and movable fragment.

Fractures of the humerus near the elbow are to be diagnosed

- 1st. From each other.
- 2d. " dislocation at the elbow.
- 3d. " fracture of the ulna or radius.
- 4th. " severe sprain or contusion of the joint.

FRACTURES OF THE ULNA, AT THE ELBOW.

The ulna if fractured in the vicinity of the elbow may be broken either in its shaft, below the coronoid process, or the olecranon and coronoid processes may be individually fractured.

Fractures of the ulna as a single bone in the vicinity of the elbow are more commonly a complication of dislocations at the elbow joint than a primary affection. The bone if broken by ordinary violence is usually affected in its shaft, either in the forearm at its middle, or nearer the wrist joint.

In fact it is difficult for the ulna to be fractured at either of its processes in the vicinity of the elbow joint without displacement occurring at the same time, since no longer does any barrier exist to prevent the bone from slipping from its articulating surface. It can only be, then, in cases of a severe form of violence directly applied to the bone that uncomplicated fracture of the ulna in the vicinity of the elbow can occur.

As I propose to consider all the diagnoses pertaining to fractures in the vicinity of the elbow in consecutive order, I pass to the enumeration of the fractures of the radius.

FRACTURES OF THE RADIUS, AT THE ELBOW.

The radius is seldom fractured in the vicinity of the elbow, as an individual bone. It is more commonly associated with fractures of the ulna occurring from direct violence.

It may however be broken either below its articular head, or immediately below its tubercle.

If below the tuberosity, the seat of fracture becomes at once apparent from the action of the biceps muscle upon the upper fragment of the bone.

TRANSVERSE FRACTURE OF HUMERUS ABOVE THE CONDYLES. DISLOCATION OF BOTH BONES OF FOREARM BACKWARDS.

HISTORY.

Occurs in falls upon the elbow. Occurs in falls upon the palm of the hand, or upon the forearm when the humerus is fixed.

ANTERIOR TUMOR.

An anterior tumor exists which is small and pointed (upper fragment), and lies *above* the crease of the elbow. An anterior tumor exists (lower end of humerus), which is broad and large, and lies *below* the crease of the elbow.

POSTERIOR TUMOR.

A posterior tumor is felt which is large, and discloses the outlines of the condyles and the olecranon. A tumor is felt posteriorly which discloses the distinct outlines of the two displaced bones of the forearm.

OLECRANON.

The olecranon is in its normal relation to the condyles of the humerus. The olecranon is separated from the condyles of the humerus.

MOBILITY.

Extensive mobility is present. The joint is usually immovable.

CREPITUS.

The crepitus, which is always detected, is of the *grating* character, characteristic of fracture. Crepitus may be absent, or, if present, is of a *rubbing* character.

LENGTH OF HUMERUS.

The humerus is shortened, if measured from the acromion to the external condyle. The humerus is of normal length, as revealed by the same measurements.

REDUCIBILITY.

Reduction of the deformity is easy by simple extension, but is transient if the force be removed. The reduction of the deformity is difficult, but permanent when effected.

SYMPTOMS IN COMMON.

Both are associated with *shortening* of the *upper extremity* (as a whole).
 “ “ “ “ an anterior and posterior tumor.
 “ “ “ “ impairment of function.
 “ “ “ “ a history of an accident.
 “ “ “ “ possible crepitus.
 “ “ “ “ local pain and swelling.

FRACTURE OF OUTER CON- DYLE OF HUMERUS.	FRACTURE OF INNER CON- DYLE OF HUMERUS.
--	--

CHANGE IN CONDYLE.

The prominence of the outer side of the elbow is lost, and a movable fragment is perceived.	The prominence of the internal aspect of the joint is lost, and a movable fragment is felt.
---	---

RELATIONS OF BONES OF FOREARM.

The radius is frequently displaced from its normal position.	The ulna is usually retained in its normal relation to the humerus.
--	---

NERVE SYMPTOMS.

No symptoms due to injury of nerves are liable to be present.	Symptoms due to injury of the ulnar nerve usually exist in the forearm and hand.
---	--

SYMPTOMS IN COMMON.

Both are associated with a *displacement of the fragment* towards the posterior surface of the joint during extension of the forearm ; but on flexion the displacement tends to disappear.

Both are associated with a *prominence of the humerus* at its lower extremity at the seat of fracture during extension of the forearm, which also disappears on flexion.

Both are associated with *pain* on flexion and extension.

“ “ “ “ *imperfect or impaired motion* in the elbow.

“ “ “ “ *crepitus*, by pressure being made over the fractured condyle, and flexion and extension being performed.

“ “ “ “ history of an accident.

“ “ “ “ local swelling and tenderness on pressure.

FRACTURE OF CORONOID PROCESS OF THE ULNA. FRACTURE OF THE OLECRANON PROCESS OF THE ULNA.

HISTORY.

A history of indirect violence, as in falls upon the palm, exists.

A history of direct violence, as in falls upon the elbow when the arm is bent, is present.

PRESENCE OF DISLOCATION.

It is rarely unassociated with dislocation of the ulna or of both bones backwards.

It may occur without displacement of the ulna, or the ulna may be dislocated forwards.

DISPLACEMENT.

The displacement is often very slight if dislocation be absent. A simple *fulness* in front of the joint and a small, hard, movable body are all that are discovered.

The amount of displacement varies with the extent of injury done to the triceps expansion over the olecranon.

If dislocation is present, a special deformity will be produced which will be characteristic.

DEFORMITY.

The condyles and the projecting olecranon are normal and preserve the shape of the joint.

The point of the elbow is gone and the arm is usually semi-flexed, though the fragments are often closely approximated on extension of the forearm.

CREPITUS.

Crepitation is often absent, but when present it is perceived on extension and *local* pressure in front of the joint being exerted.

Crepitation is detected by extension of the forearm, and rubbing the fragments together.

MOTION.

Flexion at the elbow is always impaired, if the radius be dislocated.

The power of extension of the forearm is entirely lost.

SYMPTOMS IN COMMON.

Both are associated with	deformity.
“ “ “	“ possible dislocation.
“ “ “	“ impaired function.
“ “ “	“ crepitus.
“ “ “	“ history of an accident.
“ “ “	“ local pain and swelling.

FRACTURE OF THE OLECRANON PROCESS OF THE ULNA. RUPTURE OF THE TRICEPS TENDON.

TUMOR.

The tumor on the back of the arm is of bony hardness.

The tumor at the back of the arm, due to contraction of the triceps, is not *bony* in character.

LENGTH OF OLECRANON.

The length of the olecranon is diminished.

The olecranon process is of normal length.

RELATIONS OF OLECRANON.

The olecranon no longer is adherent to the ulna, nor are its relations to the condyles of the humerus normal.

The olecranon process is adherent to the ulna, and is normal in its relation to the condyles.

CREPITUS.

Crepitus can be detected by extension of forearm and manipulation.

No crepitus can be detected.

PAIN AND SWELLING.

The pain and swelling are often severe.

The swelling and inflammatory symptoms are slight.

SYMPTOMS IN COMMON.

- Both are associated with *loss of the power of extension of the forearm.*
- “ “ “ “ *an empty space* behind the elbow.
- “ “ “ “ *a tumor* high up behind the joint.
- “ “ “ “ *a history of traumatism.*
- “ “ “ “ *local pain.*
- “ “ “ “ *local swelling.*

FRACTURE OF THE UPPER
END OF THE RADIUS.

FRACTURE OF THE UPPER
END OF THE ULNA.

DEFORMITY.

No displacement of the upper fragment will exist, if the seat of fracture be above the tubercle of the radius ; but if below it, a *marked displacement* is apparent on extension of the forearm, from tension of the biceps tendon.

A displacement will be easily detected, as a rule, on the posterior part of the forearm, on account of the superficial position of the bone in that locality, although it may not be discovered on the anterior surface.

CREPITUS.

Crepitation can be detected by fixation of the condyle, and rotation of the lower fragment of the radius.

Crepitus will be detected on rotation of the lower fragment, and possibly on flexion and extension of the forearm.

MOTION.

Flexion is difficult, or incomplete.

The motions of the forearm may be only slightly impaired if the fracture be transverse.

POSITION OF THE HAND.

The hand is pronated.

The hand has no *fixed* position.

SYMPTOMS IN COMMON.

Both are associated with a history of traumatism.

- | | | | | |
|---|---|---|---|---|
| “ | “ | “ | “ | marked swelling. |
| “ | “ | “ | “ | severe local pain. |
| “ | “ | “ | “ | frequent ecchymosis. |
| “ | “ | “ | “ | crepitus. |
| “ | “ | “ | “ | impaired function and motion. |
| “ | “ | “ | “ | altered, or a fixed position of the hand. |

FRACTURES NEAR THE WRIST JOINT.

The fractures which may occur in the vicinity of the wrist joint are as follows :

- A. "COLLES' FRACTURE," by which term is meant that peculiar type of fracture of the radius located from $\frac{3}{4}$ of an inch to $1\frac{1}{2}$ inches from its lower articular extremity, and associated with the so-called "silver-fork" deformity.

It is usually of the impacted variety of fracture, the upper fragment being driven into the lower fragment, which is therefore frequently comminuted. It is also associated often with an outward displacement of the hand and wrist.

It results most frequently from falls upon the palm of the hand when the arm and the forearm are *extended*.

- B. "BARTON'S FRACTURE," by which term is meant a rare type of fracture located at the lower articular extremity of the radius, in which the styloid process of that bone and an adjacent portion of the articulating surface of the radius are separated from the shaft of the bone, and the wrist joint opened. This form of fracture is so extremely rare, that I know of but two bony specimens indicative of its previous existence in the various anatomical museums. It can be doubtless easily overlooked during life, as the fragments are too low down to admit of great displacement, and crepitation might easily be absent. As the condition is one of extreme infrequency little is known of its symptoms, save on theoretical speculation.

- C. FRACTURE OF BOTH BONES OF FOREARM, TRANSVERSELY near the wrist. This type of fracture is by no means uncommon. It may occur from indirect violence applied to the hand, carpus, or forearm; or from a direct blow received over the seat of injury. It is to be diagnosed from *Colles' Fracture* and from dislocation of the carpal bones.

- D. SEPARATION OF THE EPIPHYSES AT THE WRIST. Like all sepa-

rations of the epiphyses of bones, this accident occurs in youth.

It may result from direct or indirect violence ; and is to be diagnosed from transverse fracture of both bones, and from dislocations of the carpus.

E. FRACTURE OF THE LOWER END OF THE ULNA. This variety of fracture may be confined simply to the styloid process of the ulna, or the shaft of the bone in the immediate vicinity of the wrist joint may be involved. It can hardly be confounded with any other surgical condition, save contusion, when the swelling conceals the deformity, and when crepitation is indistinct.

The fractures in the vicinity of the wrist joint are of very frequent occurrence. Probably no bone in the body is so frequently broken as the radius, and no fracture is so often brought to the surgeon's notice as that first described by Colles, and known by his name.

Fractures in the vicinity of the wrist are to be diagnosed

1. From each other.
2. " dislocations of the carpus.
3. " dislocations of the ulna, (lower end).
4. " severe sprains and contusions about the joint.

COLLES' FRACTURE.

DISLOCATION OF THE
WRIST.

LOCATION OF DEFORMITY.

The deformity present is confined to the radial side.

The deformity affects both sides of the forearm.

APPEARANCE OF RADIAL BORDER.

The so-called "*silver fork*" appearance, due to the displacement of the fragments of the radius, is seen by examining the radial border of the forearm.

No abnormal curves in the line of the radius are perceived.

CREPITUS.

Crepitus is present, provided impaction does not exist.

No crepitus can be detected.

TUMOR.

An abnormal tumor is perceived on *both surfaces* of the forearm, which are both sharp and pointed.

An abnormal tumor is present on only one surface of the forearm, which is smooth and rounded.

LENGTH OF RADIUS.

The radius is shortened.

The radius is normal in length.

LENGTH OF LIMB.

The limb is normal in length upon the *ulnar* side.

The limb is shortened on both the radial and ulnar sides.

STYLOID PROCESSES.

The styloid process of the ulna is lower than that of the radius.

The styloid process of the ulna is *higher* than that of the radius.

The styloid process of the ulna is markedly prominent from displacement of the carpus.

The styloid process of the ulna is not markedly prominent.

SYMPTOMS IN COMMON.

Both are associated with an alteration in the length of the limb.

- | | | | | |
|---|---|---|---|---------------------------|
| " | " | " | " | an abnormal tumor. |
| " | " | " | " | local pain and swelling. |
| " | " | " | " | impaired function. |
| " | " | " | " | a history of an accident. |

FRACTURE OF BOTH BONES
NEAR THE WRIST.

DISLOCATION OF THE
WRIST.

SEAT OF DISPLACEMENT.

The seat of displacement is located above the styloid processes.

The seat of displacement is located at the carpal articulation.

DEFORMITY.

The bony projection or tumor is rough and irregular.

The bony tumor is smooth and rounded.

The inferior projection is long, as it includes the carpus and lower fragments.

The inferior projection is *short*, as it includes only the carpus.

CONDITION OF TENDONS.

The tendons of both surfaces of the forearm are relaxed.

The tendons upon one surface of the forearm are tense.

STYLOID PROCESSES.

The styloid processes are not prominent, and are normal in their relations to the carpus.

The styloid processes are prominent, and are abnormal in their relation to the carpus.

LENGTH OF FOREARM.

The radius and ulna are both shortened.

The radius and ulna are both of normal length.

MOBILITY.

Great mobility exists at the seat of fracture.

Partial fixation of the joint is present.

CREPITUS.

Crepitation is present.

Crepitation is absent.

REDUCIBILITY.

Reduction is easily made by extension, but the deformity returns.

Reduction is more difficult, but is permanent if once accomplished.

SYMPTOMS IN COMMON.

Both are associated with deformity near the wrist.

“ “ “ “ impaired function.

“ “ “ “ local pain and swelling.

“ “ “ “ a history of an accident.

“ “ “ “ shortening of the limb (as a whole).

SEPARATION OF THE
EPIPHYSES.DISLOCATION AT THE
WRIST.

AGE AFFECTED.

Occurs only in the young.

Occurs at any age.

BONY TUMOR.

The bony projections are often indistinct and can be felt as two smooth tumors.

The bony projection is distinct and can be felt as a rounded mass.

SEAT OF DISPLACEMENT.

The displacement occurs above the styloid processes of the radius and the ulna.

The displacement occurs below the styloid processes of the radius and the ulna.

TENDONS OF THE FOREARM.

The tendons are relaxed upon both surfaces of the forearm.

The tendons are *tense* upon one side of the forearm.

LENGTH OF FOREARM.

The bones of the forearm are shortened, on measurement from condyles at elbow to styloid processes.

The bones of the forearm are normal in length.

STYLOID PROCESSES.

The styloid processes of the ulna and the radius are not prominent, but are normal in their relation to the carpus.

The styloid processes of the radius and ulna are prominent.

SYMPTOMS IN COMMON.

Both	are	associated	with	the	<i>absence of crepitus.</i>
“	“	“	“	“	<i>shortening of the upper extremity.</i>
“	“	“	“	“	<i>smoothness of the tumor</i> at the wrist.
“	“	“	“	“	impaired function.
“	“	“	“	“	local pain and swelling.
“	“	“	“	“	easy reduction.
“	“	“	“	“	a history of an accident.

COLLES' FRACTURE.

TRANSVERSE FRACTURE OF BOTH BONES ABOVE WRIST.

DEFORMITY.

The deformity is apparent upon the radial side, and has the characteristic "*silver-fork*" appearance.

The deformity is apparent on both sides of the forearm.

LENGTH OF BONES OF FOREARM.

The ulna is normal in length, but the radius is shortened.

Both sides of the forearm reveal shortening.

LENGTH OF LIMB.

The limb is shortened on the radial side, if measured from the acromion to the styloid process.

The limb is shortened on both sides, if measured from the acromion to the styloid processes.

STYLOID PROCESSES.

The styloid process of the ulna is prominent.

The styloid processes are both normal in their appearance and relations.

CREPITUS.

Crepitus is often absent from impaction of the fragments.

Crepitus is almost invariably present, as impaction is rare.

MOBILITY.

The mobility is not markedly increased at the seat of fracture.

Excessive mobility exists at the seat of fracture.

RELATION OF CARPUS.

The carpus is usually displaced outwards.

The carpus is normal in its relation to the inferior fragments.

REDUCIBILITY.

The reduction is sometimes difficult.

The reduction is always easy, if simple extension is applied.

SYMPTOMS IN COMMON.

Both are associated with deformity at wrist.

- | | | | | |
|---|---|---|---|------------------------------------|
| " | " | " | " | impairment of function. |
| " | " | " | " | alteration in the length of bones. |
| " | " | " | " | crepitus. |
| " | " | " | " | local pain and swelling. |
| " | " | " | " | history of an accident. |

FRACTURES OF THE HIP.

The femur is the bone most frequently involved in injury to the hip joint.

The pelvic bones are too heavy and solid in their structure to often become implicated, save when the violence is terribly severe and so directed as to impinge upon the ossa innominata.

The femur may exhibit the following five distinct types of fracture in the upper third of that bone :

A. SIMPLE INTRA-CAPSULAR FRACTURE OF THE FEMUR. This form of fracture occurs at the anatomical junction of the head of the bone to its neck, inside of the attachment of the capsular ligament of the hip joint. It is most commonly present in the aged, and is usually the result of indirect and slight violence.

It is seldom followed by osseous union, and is often a permanent source of impairment to the usefulness of the limb.

B. IMPACTED INTRA-CAPSULAR FRACTURE OF THE FEMUR. In this form of fracture the location is identical with the fracture preceding, but the condition of the bone is altered by the *lower* fragment being driven forcibly into the cancellous tissue of the head of the femur.

Impaction of the fragments in intra-capsular fracture of the hip is of great surgical importance. Upon its existence depends greatly the hope of osseous union, and the prognosis is proportionately favorable when impaction can be clearly and positively diagnosed. *R. W. Smith, of Dublin*, in his great essay upon fractures in the vicinity of joints, questions if osseous union is *possible* in any other condition save impaction, provided the fracture of the femur be located within the capsule of the hip joint.

C. SIMPLE EXTRA-CAPSULAR FRACTURE OF THE FEMUR. This form of fracture of the femur is usually the result of a direct form of violence which is generally severe in

character. It is most common in middle or adult life. Its location varies from a point immediately in relation with the capsular attachment, to a line corresponding to the junction of the middle and lower third of the bone.

It is associated, as a rule, with marked deformity, great impairment of function of the injured limb, and severe local manifestations.

D. IMPACTED EXTRA-CAPSULAR FRACTURE OF THE FEMUR. This form of fracture differs but little from the preceding variety in its origin or its location. It *may* possibly present equal deformity in case the impaction is oblique or incomplete; and may also be associated with severe local manifestations.

It is, however, characterized by the absence of a false point of motion, and the general impairment of function may be less marked.

In case of rotary impaction of the fragments, an abnormal position of the foot may ensue, which will frequently disappear after firm extension has loosened the impacted fragments.

E. FRACTURE OF THE GREAT TROCHANTER OF THE FEMUR. This variety of fracture occurs as a separate type in cases of falls upon the hip, and also more frequently as a complication of extra-capsular fracture of the neck of the femur.

So frequently does the trochanter become involved in this latter accident that it is considered an almost universal rule, that more or less comminution of the trochanter accompanies every fracture of the neck, from an impaction which primarily occurs, and is subsequently loosened by a continuation of the violence producing the original impaction. Should the violence, however, be slight in amount, this impaction may remain permanent and the trochanter thus escape comminution.

We may safely exclude all fractures of the pelvic bones from the causes of error in diagnosis of injuries received in the region of the hip joint, provided no evidences of previous disease are present, since, if the fracture of these bones be severe and extensive, the location of the crepitus and symptoms referable to the pelvic viscera will easily remove all doubt. Should the fracture be of a local char-

acter, however, and not of the comminuted variety, it is often impossible to either positively diagnose the existence of a fracture, or to locate its situation, provided even that crepitus be obtained.

Fractures of the upper third of the femur are to be diagnosed chiefly from each other, and also from

1. The "*pubic*" dislocation of the hip.
2. " "*sciatic notch*" " " "
3. *Acute rheumatic arthritis with contusion.*
4. *Severe contusion over the trochanter, in the aged.*

In the following pages will be found enumerated the chief points of diagnosis in a condensed form.

INTRA - CAPSULAR FRAC- TURE OF THE HIP, WITH IMPACTION.	EXTRA-CAPSULAR IMPACT- ED FRACTURE OF THE HIP.
---	--

HISTORY OF ACCIDENT.

A history of slight violence and usually of the indirect character is present, in the majority of cases.	A history of severe violence, directly applied, exists.
--	---

POSITION OF FOOT.

The foot is markedly everted.	The foot is slightly everted, or normal in its attitude.
-------------------------------	--

CREPITUS.

Crepitus is frequently detected, as the fragments may overlap and rub upon the acetabulum.	Crepitus is either absent, or is very obscure.
--	--

EFFECT OF EXTENSION.

Extension relieves the shortening of the limb.	Extension, when moderately applied, fails to relieve the deformity.
--	---

AGE.

Is most frequent in old age.	Is most frequent in adult life.
------------------------------	---------------------------------

SYMPTOMS IN COMMON.

Both are associated with shortening of the limb.	
“ “ “	“ eversion of the foot.
“ “ “	“ local pain near seat of fracture.
“ “ “	“ swelling and possible ecchymosis.
“ “ “	“ a history of an accident.
“ “ “	“ a possible crepitus.

INTRA - CAPSULAR FRACTURE OF THE HIP.

CHRONIC RHEUMATIC ARTHRITIS WITH CONTUSION.

HISTORY.

No previous history of disease of the hip, or impairment of the function of that joint is present.

A previous history of pain, deformity about the joint, and impairment of function, precedes the accident.

SUBSEQUENT POWER.

The patient slowly, if ever, regains the power present within the joint previous to fracture.

The patient regains the amount of power and motion which he possessed within the hip previous to the accident, as soon as the effects of the contusion disappear.

SYMPTOMS IN COMMON.

Both are associated with crepitus.

- | | | | | |
|---|---|---|---|---|
| “ | “ | “ | “ | loss of power and loss of voluntary motion. |
| “ | “ | “ | “ | local pain in the region of the hip. |
| “ | “ | “ | “ | swelling and possible ecchymosis. |
| “ | “ | “ | “ | a history of an accident. |
| “ | “ | “ | “ | advanced years. |
| “ | “ | “ | “ | eversion of the foot. |

SIMPLE INTRA - CAPSULAR FRACTURE OF THE HIP.	SIMPLE EXTRA - CAPSULAR FRACTURE OF THE HIP.
---	---

AGE AFFECTED.

Is rarely present in patients under fifty years of age.	May occur at all ages.
--	------------------------

SEX AFFECTED.

Is most frequent in females.	Both sexes are equally affected.
------------------------------	----------------------------------

HISTORY.

Is the result of slight and indi- rect violence.	Is usually associated with severe and direct violence.
---	---

SHORTENING.

The shortening of the limb is at first not severe, but it steadily tends to increase, from absorption of bone.	The shortening of the limb is <i>markedly</i> apparent immediately af- ter the occurrence of fracture, but is stationary.
---	--

FALSE POINT OF MOTION.

A false point of motion is ob- scure.	A false point of motion is ap- parent.
--	---

CREPITUS.

Crepitation is obscurely detected.	Crepitation is well marked.
------------------------------------	-----------------------------

POWER OF MOTION.

The power of motion of the limb is always impaired, but not always destroyed.	The power of motion within the limb is usually <i>lost</i> .
---	---

ARC OF ROTATION.

The trochanter rotates in nearly its normal arc.	The arc of rotation of the tro- chanter is diminished, as the femur is detached from its neck.
---	--

PAIN.

Pain of a <i>slight</i> but <i>deep</i> charac- ter is present.	Pain of a <i>severe</i> and <i>superficial</i> character is present.
--	---

SIMPLE INTRA-CAPSULAR
FRACTURE OF THE HIP
(continued).

SIMPLE EXTRA-CAPSULAR
FRACTURE OF THE HIP
(continued).

ECCHYMOISIS.

Ecchymosis is usually slight or absent.

Ecchymosis is usually extensive.

SWELLING.

Swelling is not markedly apparent.

Swelling is frequently severe.

RAPIDITY OF UNION.

Union occurs slowly, if at all.

Union occurs rapidly and perfectly, as a rule.

SYMPTOMS IN COMMON.

Both are associated with	the history of an accident.
“ “ “	“ impairment of function.
“ “ “	“ shortening of the limb.
“ “ “	“ crepitus.
“ “ “	“ pain and possible ecchymosis.

FRACTURE OF THE HIP WITH “SCIATIC NOTCH” DISLOCATION OF THE FEMUR.

MOBILITY OF LIMB.

The mobility of the injured member is increased. The mobility of the limb is greatly decreased.

CREPITUS.

Crepitus is present. Crepitus is absent.

SHORTENING.

Shortening of the limb is well marked. Shortening of the limb exists only to a *slight* degree.

INVERSION OF THE FOOT.

The inversion of the foot is often changed to eversion, after extension of the limb has loosened the impaction of fragments, to which the inversion is most frequently due. The inversion of the foot is permanent, and is only restored to a normal position by reduction of the dislocation.

ABNORMAL TUMOR.

The separated trochanter often fails to participate in the motions of the shaft of the femur. The abnormal tumor produced by the displaced head of the femur rotates with motion communicated to it through the shaft of that bone.

REDUCIBILITY.

The reduction of the deformity is easily effected by extension, but is transient if the force be not maintained. The reduction of the deformity is difficult, but when once accomplished no tendency to return is manifested.

HISTORY OF ACCIDENT.

Is often produced by indirect violence. Is usually produced by direct violence.

SYMPTOMS IN COMMON.

Both are associated with *shortening* of the limb.
 “ “ “ “ *inversion of the foot.*
 “ “ “ “ local pain in the region of the hip.
 “ “ “ “ impairment of function.
 “ “ “ “ swelling, and possible ecchymosis.
 “ “ “ “ history of an accident.

FRACTURE OF THE NECK
OF THE FEMUR."PUBIC" DISLOCATION OF
THE FEMUR.

POSITION OF THE TROCHANTER.

The trochanter of the femur is *normally prominent*, and is not displaced towards the median line of the body.

The trochanter of the femur is carried forwards, and is much less prominent than normal.

POSITION OF THE HEAD OF FEMUR.

The head of the bone is felt to be in the acetabulum.

The head of the femur is felt as an abnormal tumor in the groin, at its upper portion.

CREPITUS.

Crepitus can easily be detected.

No crepitus is present.

MOBILITY OF LIMB.

The *mobility* of the injured limb is increased, but its power of motion is greatly impaired or entirely destroyed.

The mobility of the limb in the movements of *adduction* and *rotation inwards* is greatly impaired.

REDUCIBILITY.

The reduction of the deformity is easily accomplished by direct extension, but is transient if the force be discontinued.

The reduction of the deformity is difficult, but if once effected no tendency towards a return is apparent.

SYMPTOMS IN COMMON.

Both are associated with *eversion of the foot*.

" " " " *shortening of the limb*.

" " " " *impaired function*.

" " " " *severe local pain*.

" " " " *history of traumatism*.

FRACTURES AT THE KNEE AND ANKLE.

The fractures which may occur at the region of the knee may be confined either to the femur in its lower third, to the tibia and fibula at the upper portion of both bones, or to the patella.

The *femur* if fractured either in its middle or lower third is generally broken by some form of direct violence. In its lower third, it is liable to present the following types of fracture :

- A. Fracture of the outer condyle.
- B. " " inner "
- C. Transverse fracture above the condyles.

These fractures of the femur in this region are generally easily detected by the deformity and the location of the crepitus.

It is not infrequent that fractures of the femur in this vicinity are complicated by wounds of the knee joint, and amputation is often required provided extensive comminution exists, or the symptoms of the patient seem to demand it.

Impaction in these fractures is occasionally present, and, provided comminution of the lower fragment does not ensue, this impaction may not be associated with any serious deformity.

FRACTURES OF THE BONES OF THE LEG IN THE VICINITY OF THE KNEE.

The tibia, although the stronger and larger bone of the leg, is by far the more frequently fractured.

This is partly due to its exposed position, but chiefly to the fact that the fibula is extensively protected by muscles. The tibia, also, is much more liable to receive injury from violence transmitted through the heel and the tarsus, than the fibula.

The variety of fracture which is most frequently present at the upper third of the tibia is the transverse, and *this* seldom, if ever, occurs except from the application of direct violence.

If both bones are simultaneously involved, the presence of crepitus, marked deformity, false point of motion, and shortening renders the diagnosis easy ; but if either is fractured singly, the opposite

bone acts as a splint, and prevents displacement and shortening. In this case an irregularity in the line of the tibia can easily be detected by the finger, if that bone be fractured; but if the fibula be broken, the investing muscles render the diagnosis obscure, provided the seat of fracture be above the middle third of the bone.

A deep-seated crepitus can, however, be often detected by careful manipulation, and the seat and presence of fracture be thus discovered.

Fractures of the bones of the leg in the region of the knee can hardly be mistaken for any other existing surgical affection. Contusion may possibly so mask the symptoms of fracture by its accompanying swelling as to leave doubt as to whether the bone is broken, but it could hardly be mistaken for it.

FRACTURES OF THE PATELLA.

Fractures of the patella most frequently occur from muscular action in an effort being made by the patient to save himself from falling when slipping, or in falls when the knee is bent. It may, however, also occur from falls directly upon the knee, or from any other form of violence directly applied.

Fractures of the patella may be transverse, longitudinal, or oblique in direction; and simple, or comminuted in variety. The transverse fracture is usually the form met with when due to muscular action, and is by far the one most frequently present in surgical practice.

The fractures of the patella can hardly be mistaken for other forms of injury, when they are well defined. The two portions of the bone, in case of transverse fracture, are separated by the action of the quadriceps extensor muscle, and the space between the fragments is increased by flexion of the knee. All power to extend the leg upon the thigh is lost, and endeavors to stand upon the injured leg are fruitless. In the comminuted variety local crepitus can usually be discerned, but in the transverse form, the fragments can hardly be sufficiently approximated to yield marked crepitus, except the position of the thigh be so modified as to relax the rectus muscles, and extension be applied to the upper fragment of the bone.

Fractures of the patella are more common among males than females, and are seldom present in youth. This is explained on the theory of previous structural change within the bone substance,

(*Malgaigne*), but it can hardly be considered as proven. A better explanation of the frequency of fracture of this bone seems to be the *lack* of support which the upper half of the patella receives when the knee is in a state of flexion, as in this position the upper edge is projected forwards, and the posterior surface of the *upper half* of the bone is totally separated from contact with the femur.

FRACTURES AT THE ANKLE.

The fractures which may occur in the bones of the leg at their lower third, or in the immediate vicinity of the ankle joint are more common than those occurring in the immediate vicinity of the knee. This is partly due to the bones gradually diminishing in size as they approach the ankle, and partly to the greater frequency of indirect violence occurring in the vicinity of that joint from transmission through the bones of the foot, and from the leverage exerted by the astragalus upon the malleoli of the leg bones, in case of its displacement.

Fractures of the leg in the vicinity of the ankle may be thus enumerated:

- A. TRANSVERSE FRACTURE OF BOTH BONES. This form of injury is perhaps less common than the oblique variety of fracture which is so frequently present in the shafts of the leg bones, since a natural tendency seems to exist in fractures occurring in the tibia or fibula below their upper third to approach a longitudinal direction, and thus to cause a greater or less obliquity, even if the force be so applied as to tend towards a directly transverse separation of the fragments. Still, in speaking of *transverse* fracture I include all those forms which more nearly approach the horizontal than the perpendicular plane, without entering into too many fine distinctions as to the absolute direction of the line of fracture.

In this type of fracture near the ankle, we may have either slight or marked displacement existing. The degree of this displacement is the most extensive when the fracture is obliquely directed across the bone, since in this condition the fragments glide more easily upon each other; and it is the least apparent in that form of fracture where an absolutely *transverse* separation is present, in which case the bones may often be retained

in almost their normal position, and the line of the fracture may for that reason be more clearly discerned by the location of the crepitus than from any evidence perceived by the careful inspection and examination of the contour of the injured member.

- B. "POTT'S FRACTURE" OF THE FIBULA. This type of fracture is located in the shaft of the fibula, at a point usually about three inches above the external malleolus. The seat of the fracture may, however, vary somewhat in its location, as it is often much nearer the malleolus.

It is associated, as a rule, with an outward dislocation of the astragalus, and the internal malleolus is frequently broken. The internal lateral, or *deltoid ligament*, of the ankle is usually severely stretched or ruptured, and the deformity due to the displacement of the astragalus, is aggravated often by marked local swelling.

This form of fracture of the leg is extremely frequent, probably the most frequent of any fracture of the leg bones. It is produced by twisting of the foot, by catching of the foot in a hole while running, by jumping from a height upon the feet, or from a carriage while in motion. It may also result from violence directly applied.

The deformity which characterizes *Pott's Fracture*, is one of ordinary fracture combined with that of an external dislocation of the foot. A depression is perceived on the external border of the leg opposite the seat of fracture, and the sole of the foot is either directed outwards, or the external border of the foot is elevated.

The internal malleolus is either prominent, or can be felt as a detached and movable fragment; and crepitus can often be detected on extension of the leg and inversion of the foot, thus bringing the fragments into approximation.

- C. FRACTURE OF THE INTERNAL MALLEOLUS. This form of fracture at the ankle may be associated with a normal position of the foot, or with a partial dislocation of the astragalus inwards, resulting either in severe stretching, or rupture of the external lateral ligament of the joint. It is complicated, as a rule, with marked swelling at the external portion of the joint, and is not infrequently

associated with a partial or complete fracture of the fibula.

D. COMPOUND FRACTURES OF THE ANKLE JOINT. This form of accident is one of serious import, commonly requiring amputation if associated with dislocation or severe laceration of the soft tissues. The tibial arteries are not infrequently involved, and serious hemorrhage may exist.

Gangrene of the parts supplied by these arteries may also follow the arrest of the hemorrhage, from the defective nutrition which is liable to result in consequence of the impaired blood supply, and thus additional danger to the patient may ensue.

It is always important therefore in the diagnosis of this accident to investigate the condition of the supplying vessels to the foot, before deciding as to the methods of treatment which are best indicated, or expressing an opinion as to the general prognosis.

Fractures in general in the vicinity of the ankle joint can hardly admit of great confusion in diagnosis. Obscure injuries to the astragalus, or tarsal bones will often fail to give positive evidence of fracture, even when such exists; but the history of the accident, the general deformity, the presence of some of the prominent symptoms of fracture, and the length of duration required for recovery will, in time, remove doubt, in cases where an early and positive diagnosis is impossible.

I shall not attempt therefore to arrange all the possible fractures of the bones of the leg and foot in the vicinity of the ankle joint, in a form of contrast, since many of the most positive symptoms of each are capable of great variations, and in the majority of cases, the bones themselves will disclose from their *superficial location* the seat and extent of the injury received.

I should suggest, however, in case the deformity were slight, and the other symptoms so obscure as to create doubt as to the existing condition of the parts injured, that the opposite member be always used in comparison with the one injured, before deciding as to the actual deformity present, and that repeated examinations under anæsthetics and without them be employed, till a satisfactory conclusion can be reached.

FRACTURES OF THE TRUNK.

Fractures of the trunk may affect the vertebræ, ribs, sternum and pelvis; of these four, *fractures of the sternum* are extremely rare, and usually occur where a severe injury is received, which directly impinges upon the chest, or in cases where the body is suddenly bent backwards or forwards, as in a fall. It is of surgical importance however, when present, since complication of the pericardium, heart, pleura, lungs, and injuries of the great vessels and *fractures of the ribs*, or spine, may be also thus produced, and greatly modify, when present, the prognosis as to life.

As many of these complications, however, can also exist with fractures of the ribs, they will be specially considered under that head.

Fractures of the sternum may be associated with most of the symptoms common to fracture in general. Crepitus may be detected possibly on palpation and on auscultation.

FRACTURES OF THE STERNUM.

Displacement of the fragments, abnormal mobility, localized pain at the seat of fracture, and dyspnœa may all be present, even without the existence of any serious complication of organs or the serous cavities, though subsequent inflammatory changes are always liable to follow any violence to the chest which is sufficient to produce so serious an injury.

It is therefore to be diagnosed chiefly from its complications, and especially from inflammatory changes in the pleura or pericardium.

Fractures of the sternum have in several reported cases been produced by muscular action. *Chaussier* reports two cases resulting from resting upon the head and heels only, during parturition. *Faget* and *Gurilt* report each a case resulting from attempting to lift weights with the teeth, with the body bent backwards.

FRACTURES OF THE VERTEBRÆ.

Fractures of the vertebræ may result from direct injuries to the spine, or from force indirectly applied, as in case of falls upon the feet, knees, pelvis, or head.

In the first set of causes, viz. : those producing fracture from

direct violence, the injury is, of necessity, received upon the back, since in front the spine is most thoroughly protected.

This class of injury almost without exception results in a complicating *dislocation* of the vertebræ in addition to the fracture received, since the anterior ligamentous attachments of the bodies to each other are ruptured by the direct force of the blow, altering the *normal spinal curve*, while at the same time the spinous processes and laminae of the vertebræ are comminuted by the *compression* exerted in endeavoring to resist such an alteration in the spinal axes.

In the second class, viz.: those dependent upon force indirectly applied to the spine, the fracture is found to be usually located at a distance from where the shock was first received. Dislocation of the vertebræ will, as a rule, be absent, but the articular surfaces will generally be comminuted, and the spinous and transverse processes frequently fractured.

In very severe cases, however, where the force transmitted through the spinal column is of a violent character, the *bodies* of the vertebræ may be comminuted, and *displacement* from this cause will often be detected.

In either variety, however, we can judge of the location of the fracture and its severity by the combined local and spinal symptoms.

The *local* symptoms will consist of probable crepitus, deformity, detached and movable fragments, local ecchymosis, and local pain.

The *spinal* symptoms will vary with the seat of fracture and the portion of the cord compressed, or injured. Thus, if above the origin of the phrenic nerve, death may ensue from respiratory paralysis, provided both lateral halves of the spinal cord are injured. If above the origin of the lumbar and sacral plexuses, symptoms of paralysis of the limbs and pelvic organs will be apparent.

The paralysis of muscles may be of the hemiplegic or paraplegic type, as the pressure on the cord is lateral or bilateral, or possibly even local paralysis may result, if special spinal nerves be affected, and the cord be not involved.

In some cases where dislocation of the vertebræ exists in connection with fracture, extension of the spine by suspension of the patient, if practicable, if not, by ordinary means, will often reduce the dislocation, and possibly an audible click will be heard when the reduction is effected.

Fractures of the spine are frequently fatal.

The result of the injury depends more upon the severity of the

spinal symptoms produced by injury to the cord, than upon the location of the fracture or its extent. If dislocation be present, the immediate vertebra will usually reveal the seat and extent of the displacement by the altered relation of the displaced bone. Should the displacement be but slight, the spinal cord may possibly escape injury, and reduction may be followed by recovery without paralysis.

Fracture of the spine can hardly be mistaken for any other type of local injury, as the symptoms are usually unmistakable, and the history of the accident would probably warrant a most justifiable *suspicion* of fracture from its severity, even before the local manifestations were determined.

FRACTURES OF THE RIBS.

Fractures of the ribs occur rarely among the young, as the elasticity of the ribs is great in youth, but are most frequent in elderly people, or in adult life.

They occur as a rule from external injuries applied to the chest wall, as in blows, falls, the passage of wheels over the chest, or from pressure between two opposing forces.

In rare instances fracture of the ribs has occurred from muscular effort, as in attacks of coughing; but in these cases a structural change had probably ensued within the bone, before the fracture occurred.

The ribs may be broken in one of two ways: either by the direct force of the injury, in which case the seat of fracture will correspond probably with the seat of the external contusion, and one or two ribs only will be implicated, the fractured ends being driven *inwards*; or the ribs may be fractured at a point remote from the seat of injury by an indirect force, causing excessive bending of the bones. In these cases the ribs are usually broken at about their middle, and the fractured ends of two or three bones are simultaneously displaced *outwards*.

Fractures of the ribs may be also divided into the complete, and the incomplete. In the former variety, the separation of the fragments is such as to allow of displacement and marked crepitus. In the latter, either the bone itself is imperfectly fractured, or the periosteal coverings still remain intact and prevent any displacement, and often conceal all symptoms of local injury to the bone.

Fractures of the ribs may be unilateral or occasionally bilateral,

in situation; simple, comminuted, or compound, in variety. The middle ribs are the most frequently involved, and the first three ribs are seldom fractured.

Fractures of the ribs may be uncomplicated, or complicated. If complicated, the integument may be lacerated, producing a compound variety of fracture. The bone may be shattered by gun-shot wounds, etc., resulting in the comminuted variety of fracture. The pleura may be involved, producing pleurisy, etc. The lung-tissue may be penetrated, thus inducing pneumo-thorax, pneumonia, pulmonary hemorrhage, emphysema, etc.

The heart and pericardium may become implicated. The intercostal vessels may be wounded, and finally the diaphragm and the abdominal viscera may be injured, provided the lower ribs be involved and greatly displaced.

The proportion of uncomplicated cases of fractured ribs to the total number of recorded cases, is very large,—at least seventy-five per cent. The balance usually recover, however, provided the complication is not of a markedly serious and severe type.

Fractures of the ribs are to be diagnosed from many pulmonary affections, especially if connected with, or created by a severe contusion of the chest wall, or some variety of direct injury. Among the diseases which are liable to be confounded with a fracture of the rib, are pneumo-thorax if traumatic in origin, pleuritic inflammation and emphysema of tissues.

In the following pages will be enumerated the distinctive diagnostic points of each in contrast, with those of fracture of the rib.

In closing the subject of fracture I also append a differential diagnosis between Fracture and Dislocation of bone, as a general *resumé* of the symptoms common to both.

FRACTURE OF THE RIBS.

PLEURITIC INFLAMMATION,
(*in the dry stage associated with
contusion*).

APPEARANCE OF CHEST.

The projecting edges of the fragments of the fractured ribs can often be detected, or an irregularity in the course of the rib may result from its displacement, in case no fragments can be discovered.

The chest wall is often locally depressed in case of fracture.

No projecting fragments can be discovered, or any irregularity in the course of the rib.

The chest wall is normal, until effusion into the pleural cavity produces *bulging* of the affected side.

PALPATION.

Crepitus may often be felt on palpation.

Palpation is negative in its results.

AUSCULTATION.

Auscultation yields the fine grating noise of crepitation.

Auscultation perceives a harsh *friction* sound, before the fluid separates the inflamed pleural surfaces.

COUGH.

Cough is absent, if no complication exist.

Cough, *without expectoration*, is usually present.

SYMPTOMS IN COMMON.

Both are associated with localized *pain in the side*.

“	“	“	“	abnormal sounds on auscultation.
“	“	“	“	diminished expansion of the chest.
“	“	“	“	elevation of pulse and temperature.
“	“	“	“	local ecchymosis.
“	“	“	“	a history of an accident.

FRACTURE OF THE RIBS.

PNEUMO-THORAX,
(of a traumatic origin).

APPEARANCE OF CHEST.

The chest wall is often locally depressed at the seat of fracture.

The chest wall is distended, and the intercostal spaces widened from air within the pleural cavity.

OUTLINE OF RIBS.

The fractured rib can often be felt to be irregular in outline, or the fragments can be felt to overlap each other.

The outline of the ribs is seen and felt to be normal.

DYSPŒA.

The dyspŒa present is due only to the pain, and is not excessive.

The dyspŒa is *intense* and is due to compression of the affected lung by atmospheric pressure.

PALPATION.

A vocal fremitus can be perceived on palpation of the chest when the patient speaks or counts, and crepitus may also be detected.

No vocal fremitus, or crepitus is detected.

PERCUSSION.

The percussion note is normal over the affected side.

Pure "*tympanitic*" percussion resembling that of the abdomen, will be present.

INSPECTION.

The expansion of the affected side is limited, but plainly perceptible.

No expansion of the affected side occurs on inspiration.

AUSCULTATION.

Respiratory sounds are heard over the seat of fracture, though they may be feeble.

No respiratory sounds are heard, provided the lung be not punctured, but if so, "*amphoric breathing*" may exist.

SYMPTOMS IN COMMON.

Both are associated with pain.

“ “ “ “ dyspŒa.

“ “ “ “ history of traumatism.

FRACTURE OF THE RIBS. EMPHYSEMA OF TISSUES.

APPEARANCE OF THE CHEST.

The chest wall is often depressed at the immediate seat of fracture.

The tissues over the chest are inflated with air, and the chest has, therefore, a puffy or distended appearance, which is often extensively diffused.

ABNORMAL SOUNDS.

A fine, grating crepitus may be perceived during inspiration or expiration, both on palpation and auscultation.

A peculiar "crackling" noise and sensation to the touch may be perceived on pressure over the emphysematous tissues, irrespective of respiratory efforts.

OUTLINE OF RIBS.

The outline of the fractured ribs is felt often to be irregular ; or the overriding of the fragments may be detected.

The ribs are felt to be normal in their outline and position, if their contour can be detected through the inflated tissues.

EFFECTS ON RESPIRATION.

Pain is present in the side, and the breathing is often restricted in consequence.

Pain may not be present to any serious degree, nor need the breathing be, of necessity, restricted.

DURATION OF THE SYMPTOMS.

The symptoms are continued for some days after the accident.

The symptoms *may*, in some cases, rapidly subside.

SYMPTOMS IN COMMON.

Both are associated with abnormal auscultation.

“ “ “ “ “ palpation of the chest.
 “ “ “ “ deformity.

FRACTURE IN GENERAL, IN
THE VICINITY OF JOINTS.

DISLOCATION.

DEFORMITY.

The deformity is not *in* the joint, but near it, as is shown by comparison with the opposite side.

It varies in its *seat* and in its *degree*, and is easily removed.

The abnormal projections are usually felt to be small and *irregular* in shape.

The axis of the limb is not uniform, but varies with changes in the relation of the fragments to each other.

The deformity is great, and is located in the joint itself.

It is stationary, and disappears only after reduction of the dislocation.

The abnormal tumor, when perceived, is felt to be large, smooth, and rounded at its edges.

The axis of the limb is abnormal, but is constantly the same and is of uniform direction throughout the whole length of the bone.

MOBILITY OF THE LIMB.

The mobility of the limb is of an abnormal type.

It is augmented in its degree.

It is not always located at the region of a joint.

All attempted voluntary movements are abnormal.

The movements of the joint are greatly restricted, both in degree and direction.

The movements are located in the immediate locality of the normal joint, but not within it.

All attempted voluntary movements are normal in direction, but restricted in amount.

CREPITUS.

Appears at the time of the accident, is easily obtained, and is of a *grating* character.

If present, crepitus is a late symptom; is obtained with difficulty, and is of a *rubbing* character.

PAIN.

Is seldom severe if the parts are at rest.

It continues after reduction.

Is usually severe even though the parts are at rest.

Is always relieved by reduction.

FRACTURE IN GENERAL, IN
THE VICINITY OF JOINTS,
(continued).

DISLOCATION,
(continued).

LENGTH OF LIMB.

Shortening is often present, but lengthening never.

Shortening and lengthening may both, at times, exist.

POSITION OF LIMBS.

Fractured limbs usually lie close to the median line of the body.

Dislocated limbs usually stand out from the body, and cannot be made to lie parallel to its median line.

APPEARANCE OF JOINTS.

The bony prominences in the vicinity of joints are unaltered in their relations to each other.

The relations of the bony prominences normal to the joint are unaltered.

SENSIBILITY.

Numbness of the injured limb is often absent, but if present, is slight in amount.

Numbness is often a prominent symptom ; it is usually present to a greater or less degree.

ECHCHYOSIS.

Is often extensive, and is located in a dependent part.

Is usually slight and superficial, if present.

REDUCIBILITY.

The deformity is easily reduced, but shows a tendency to return.

The deformity is reduced often with difficulty, but when accomplished, no tendency towards a return is manifest.

No sound is perceived at the moment of reduction.

A distinct *snap* is often perceived at the moment of reduction.

DISEASES OF THE MALE GENITALS.

DISEASES OF THE MALE GENITALS.

THE surgical diseases of the male genitals may be divided into

- A. Diseases of the TESTICLE.
- B. “ “ TUNICA VAGINALIS.
- C. “ “ SPERMATIC CORD.
- D. “ “ SCROTUM.
- E. “ “ BLADDER.
- F. “ “ PROSTATE GLAND and URETHRA.
- G. “ “ PENIS.

I shall consider the diseases of the male genitals in this order, enumerating under each of the separate divisions the various surgical conditions liable to exist, and the sources of error in diagnosis which pertain to the various organs under consideration. I shall endeavor in this chapter to elucidate as exhaustively as is compatible with conciseness, those diseases which are most common in a general surgical practice, and shall be content with the enumeration only of such as are infrequent, referring those desirous of more extended information to the various monographs upon the special subjects.

DISEASES OF THE TESTICLE.

The testicles may become *enlarged* from the following named conditions :

1. SIMPLE INFLAMMATORY ORCHITIS which is a frequent sequela of injury, mumps by metastasis, and extension of inflammation down the spermatic cord. It is largely due to an œdematous infiltration of the testicle, but may result in suppuration, and is associated with all the symptoms characteristic of inflammatory processes in general.

2. SPECIFIC DEPOSIT WITHIN THE TESTICLE, or "SYPHILITIC ORCHITIS." This type of disease is a sequela of the acquired variety of syphilis, as a rule. It consists of circumscribed, or infiltrated deposits of gummata. It is a rare affection before the age of puberty, and is most frequently located at the period of its commencement, in the *body* of the testicle. It may, however, subsequently involve the epididymis.
3. CHEESY DEGENERATION OF THE TESTICLE, or "TUBERCULAR ORCHITIS." This variety of degeneration occurs in a tubercular diathesis, and exists in connection with a similar condition of other organs in the large majority of cases. It is essentially a disease of early manhood, and is primarily located in the *globus major* of the epididymis. It is associated, as a rule, with impairment of the general health, and is frequently accompanied by suppuration in its advanced stages, and in some cases by fungoid growth.
4. "MALIGNANT ORCHITIS," or CANCEROUS DEPOSIT IN THE TESTICLE. This variety of disease may occur in all ages. It is a frequent disease after the age of fifty. It is primarily a disease of the *body* of the testicle, but involves the epididymis and the cord in its advanced stages. It is associated with impairment of the general health as the later cachexia is developed. It is chiefly of the encephaloid variety, although scirrhus may occur in this region, and occasionally melanoid cancer may be present.
5. CYSTS OF THE TESTICLE, called also "CYSTIC SARCOMA." This is a rare affection, and consists of compound or proliferous cysts developed within the testicle. They vary usually in size from that of a millet seed to the dimensions of a pigeon's egg, and contain either a transparent, viscid, albuminous fluid, or a blood-stained fluid with coagula. The cysts are usually of an elongated form, and are primarily a disease of the *body* of the testis, although the epididymis may become involved. They are probably produced by an occlusion of the *tubuli*

seminiferi, or the ducts of the *rete testis*. They are sometimes associated with enchondroma.

6. HÆMATOCELE OF THE TESTICLE. This is frequently the result of a blow, as in riding on horseback, and being thrown upon the pommel of the saddle; or of violent muscular efforts, as in attempts to raise heavy weights. It may also occur from direct wounds of the testicle, and during scurvy and purpura.

It is due to the rupture of a blood-vessel, and the blood is usually effused into the cavity of the tunica vaginalis. The testicle under these circumstances immediately enlarges, and symptoms referable to the escape of blood become manifest.

Hæmatocele may occur when hydrocele has preceded the exciting cause of hemorrhage. In this way tapping not infrequently creates a complication, although a lancet, if used, is more liable to produce hæmatocele than a trochar.

The source of hemorrhage in hæmatocele of the testicle may be the spermatic artery, or some of the branches either of the spermatic, or of the artery of the vas deferens. The testicle, as a rule, lies at the posterior portion of the tumor, but as this rule has exceptions, pressure upon the back of the tumor in doubtful cases will yield the peculiar "sickening sensation," usually associated with compression of the testicle, and thus decide its exact location.

7. LIPOMA OF THE TESTICLE. Fatty tumors of the testicle occasionally occur. They are to be diagnosed by their slow and painless growth, by the absence of an exciting cause, by the general health being unimpaired, and by the general characteristics of fatty deposits.

8. FIBROUS TUMORS OF THE TESTICLE. This type of disease is frequently associated with the condition of atrophy of the testicle.

It consists of a marked increase in the connective tissue of the organ.

It may also accompany cysts of the testicle, or it may occur as an independent process, resulting in a painless and marked enlargement of the organ, as is common in the so-called "chronic enlargement" of the testicle, which possesses no distinctive symptoms.

It is questionable if this state of chronic induration is not, in the majority of cases, a direct sequela to a chronic orchitis, the products of the inflammation having undergone organization into connective tissue, instead of becoming absorbed.

9. ENCHONDROMA OF THE TESTICLE. Cartilaginous tumors of the testicle are seldom unassociated with other textural changes within that organ. Still, in rare cases, the deposit has been localized to so marked a degree as to constitute a separate or principal lesion.

While this type of tumor is often associated with cancer of the testicle, yet it can doubtless be regarded as in itself, non-malignant.

10. BENIGN FUNGUS OF THE TESTICLE, or "HERNIA TESTIS."

This term is used to express a condition of the testicle, where a fungus growth protrudes from the testicle and scrotum. The term "*granular swelling*" has been sometimes used to express this condition, but the mode of origin has caused the term "*hernia testis*" to be more universally applied.

This fungus growth consists of a protrusion of the glandular structure of the testicle through the tunica albuginea, the tunica vaginalis, and the adherent scrotum.

It results frequently from suppuration of the testicle and ulceration of its coverings, as a sequela of chronic orchitis. It may, however, occasionally follow an acute suppurative process within the testicle, but these cases are uncommon.

The fungus, on microscopical examination, is found to consist of the tubules of the testicle with intertubular changes, and granulations springing up from those tubules which are nearest to the surface.

The tunica albuginea is thickened around the margin of the opening, through which the fungus

protrudes, the edges of which are everted. The scrotum around the margin of the opening is indurated and thickened, and in some cases is undermined.

11. CHRONIC INFLAMMATORY INDURATION OF THE TESTICLE. This variety of disease, to which the term "chronic orchitis" is applied, is of surgical importance from its tendency to destroy the glandular structure of the testicle.

It usually follows an attack of simple acute orchitis whose duration has been prolonged by repeated attacks, or by excess in alcohol and venery, or traumatism.

It results in a gradual enlargement of the testicle without any markedly acute symptoms, and is more closely allied in its history to that of tubercular deposit.

It differs however from that disease in its primary seat, which is usually within the *body* of the organ, as well as in its general pathological characteristics.

It is a frequent cause of *benign fungus* of the testicle from ulceration of the tunica albuginea.

It is to be diagnosed from cancer of the testicle, tubercular orchitis, and hæmatocele of the testis.

The testicle may present also the following conditions which are *not accompanied with an enlargement* of the organ, but which are of surgical interest :

1. ARRESTED DEVELOPMENT OF THE TESTICLE.
2. CONGENITAL MALFORMATIONS OF THE TESTICLE ; including
 - Inversion of the testicle.
 - Union of the testicles.
 - Supernumerary testicle.
 - Impervious vas deferens.
3. CONGENITAL ABSENCE OF THE TESTICLES : "*cryptorchidism*."
4. NEURALGIA OF THE TESTICLE.

5. ATROPHY OF THE TESTICLE.
6. INCOMPLETE DESCENT OF THE TESTICLE : "*monorchidism.*"
7. CALCAREOUS DEPOSITS IN THE TESTICLE.

Many of these affections can with difficulty be mistaken in diagnosis, and will therefore be simply enumerated. In the following pages will be found contrasted, however, those diseases which constitute the principal sources of error in diagnosis.

ACUTE ORCHITIS.

NEURALGIA OF THE TESTIS.

HISTORY.

Is usually either of traumatic origin, or is associated with a history of venereal disease.

Is a frequent affection in weak and nervous young men, and in masturbators. It also is often associated with varicocele and malarial conditions.

TESTICLE.

The testicle is swollen, but is not retracted.

The testicle is retracted during the attack, if severe, but is normal in its size.

PAIN.

The pain is constant and not paroxysmal.

The pain is paroxysmal in character, and *intense*.

It comes on gradually with the swelling and disappears slowly.

It comes and goes suddenly, without premonition.

GASTRIC SYMPTOMS.

Nausea and vomiting are infrequent.

Nausea and vomiting are often present.

EFFECT OF PRESSURE.

Great tenderness on pressure exists, until the swelling or the acute symptoms disappear.

The testicle is painless on pressure during the intervals between the attacks.

SYMPTOMS IN COMMON.

Both are associated with marked *pain* in the testicle.

“ may be “ “ nausea and vomiting.

“ “ “ “ tenderness on pressure.

SYPHILITIC ORCHITIS.

TUBERCULAR ORCHITIS.

LOCATION OF ORIGIN.

Begins in the *body* of the testicle as a primary disease.

Begins in the globus major of the epididymis, and involves the testicle secondarily.

AGE AFFECTED.

May exist at any age ; but seldom before puberty.

Occurs in early manhood, as a rule.

EXTENT.

Is usually a *unilateral* disease.

Is frequently a *bilateral* disease.

TESTICLE.

The testicle is regular in contour, uniform in its consistence, and harder than normal.

The testicle is marked with hard, knotty nodules, but is soft and elastic between them.

HYDROCELE.

Hydrocele is occasionally present.

Hydrocele is a frequent complication.

TERMINATION.

Tends towards calcareous or fibrous degeneration, or atrophy.

Tends towards cheesy degeneration and suppuration after an interval.

ULCERATION AND FUNGUS.

Ulceration and fungoid growths are absent.

Ulceration and fungoid growths are frequent in the last stages.

FISTULÆ.

Fistulæ are seldom formed.

Fistulæ are frequently formed which heal after the gland has been evacuated.

HISTORY.

A history of syphilis exists, or evidences of it are discovered in the skin or the glands.

A tubercular history is present, and other organs are usually affected.

SEXUAL DESIRE.

Sexual desire is decreased, but the power of coition is usually slowly affected.

Sexual desire is increased, but the power of coition is usually impaired.

MALIGNANT ORCHITIS.

SYPHILITIC ORCHITIS.

AGE AFFECTED.

Affects all ages, even children.

Is very rare before puberty.

PREVIOUS HISTORY.

No previous history of causation exists.

A history of syphilis, or some evidences of it, is usually present.

SEAT OF ORIGIN.

Begins in the *body* of the testicle, but grows rapidly.

Begins in the body of the testicle, but grows *slowly* and painlessly.

CHARACTERISTICS OF THE TUMOR.

The tumor ulcerates, and tends to form a fungoid growth.

The tumor never ulcerates, nor tends to form fungoid excreescences.

The tumor often invades the cord.

The tumor seldom invades the cord.

The tumor is not of uniform consistence.

The tumor is uniform in consistence.

PAIN.

The pain is severe and *lancinating* in character during the latter stages.

Pain is seldom present. A sense of weight only exists.

INTEGUMENT.

The skin is always involved in its advanced stages.

The skin is seldom involved.

FLUCTUATION.

Fluctuation is often detected over localized spots in the testicle.

Fluctuation is absent.

EFFECT OF CASTRATION.

The tumor returns, as a rule, after castration.

The tumor, if removed, never exhibits a tendency to return.

CYSTS OF TESTIS.

HYDROCELE.

FREQUENCY.

Is a rare malady.

Is an extremely frequent disease.

SIZE OF TESTICLE.

The testicle may be either enlarged or diminished in size.

The size of the scrotum is always increased; but the testicle is unaffected as to its size.

TUMOR.

The tumor consists of a localized swelling which may be situated in different parts of the testicle.

The tumor begins from below and extends upwards.

TRANSLUCENCY.

The tumor is not translucent.

The tumor is translucent on placing a lighted candle behind it.

FLUCTUATION.

The fluctuation, if perceived, is very indistinct. It may often be absent.

Fluctuation is well marked, and is always detected.

VEINS OF CORD.

The veins of the cord are enlarged and varicose.

The veins of the cord are normal in their appearance.

SYMPTOMS IN COMMON.

Both are associated with slow development.

“ “ “ “ absence of pain.

“ “ “ “ oval or globular form.

“ “ “ “ smoothness of the surface.

“ “ “ “ elasticity.

“ “ “ “ fluctuation.

BENIGN FUNGUS OF TESTICLE (HERNIA TESTIS). CANCER OF TESTICLE, WITH FUNGUS.

DEFINITION.

Is a protrusion of the tubular structure of the gland through the coverings of the testicle and scrotum. Is a rapidly increasing growth, possessing no resemblance to the glandular structure of the testicle.

APPEARANCE OF TUMOR.

The tumor has a *neck* which is markedly constricted. The constriction at the neck is not well marked.

SURFACE OF TUMOR.

The surface is granular, but is firm in its texture. The surface is *friable* in its texture.

EFFECTS OF PRESSURE.

The tumor is painless to the touch, but the testicle is normally affected by pressure. The testicle fails to yield the normal "sickening sensation" on pressure.

PAIN.

The pain is severe until protrusion occurs, when it ceases. The pain is of a violent and lancing character.

CHARACTER OF THE DISCHARGE.

The discharge from the fungus often contains spermatozoa. Hemorrhage is frequent from its surface, especially when handled; and the discharge is profuse and fetid.

LOCATION.

The disease is always unilateral. The disease *may* be bilateral.

COMPLICATIONS.

The skin, spermatic cord, and neighboring glands are usually normal. The integument, spermatic cord, and neighboring glands are usually involved.

GENERAL HEALTH.

The general health may be good. A marked cachexia exists.

ORCHITIS.

EPIDIDYMITIS.

FREQUENCY.

Is a very rare affection.

Is extremely common.

HISTORY.

Is produced by mumps, cold, gout, traumatism, etc., etc.

Is almost invariably associated with urethral disease or irritation.

PAIN.

The pain is excruciatingly severe, even in cases of moderate enlargement, and is not relieved by position.

Pain is usually of moderate severity, except in extreme enlargement, and is relieved by position.

SHAPE OF TUMOR.

Is usually associated with an *oval* tumor.

The shape is often modified by scrotal œdema.

EFFECTS UPON TESTICLE.

The testicle is extremely hard and very sensitive to pressure.

The *body* of the testicle is, as a rule, normal. If complicated, it is less sensitive than orchitis.

The epididymis is not distinguishable from the rest of the tumor.

The epididymis always becomes distinguishable when the disease is in its decline, although often obscurely so at its height.

HYDROCELE.

Hydrocele is rare as a complication.

Hydrocele is always present in acute cases.

COURSE OF DISEASE.

The disease is slow in its progress.

The disease is usually rapid in its progress.

CONSTITUTIONAL SYMPTOMS.

The constitutional symptoms are often marked.

The constitutional symptoms are absent, or unimportant.

ORCHITIS
(*continued*).

EPIDIDYMITIS
(*continued*).

METHODS OF TERMINATION.

Resolution, abscess, gangrene, atrophy, or chronic induration may occur.

Resolution with chronic thickening of epididymis usually takes place.

EFFECTS ON FUNCTION.

Impotence may result if both sides have suffered destruction of tissue.

Temporary sterility may occur, but never impotence.

(“Genito-Urinary Diseases and Syphilis,”
Van Beuren and Keys.)

TABLE FOR THE DIAGNOSIS OF DISEASES OF TESTICLE.

SYPHILITIC TESTIS.	TUBERCULAR TESTIS.	MALIGNANT TESTIS.	SARCOMA OF TESTIS.
AGE AFFECTED.			
Rare before puberty.	Early manhood and youth.	All ages are affected, but youth most frequently.	Early manhood.
HISTORY.			
Syphilitic.	Serofulous.	No cause or previous history of disease exists.	No history; cause unknown.
SEAT OF ORIGIN.			
Begins in the <i>body</i> of the testicle.	Begins in the <i>globus major</i> of the epididymis.	Begins in the <i>body</i> of the testicle.	Begins in the <i>body</i> of testicle.
GENERAL HEALTH.			
Unaffected.	Usually impaired.	Impaired in the last stages.	Unimpaired till late in disease, if ever affected.
PROGRESS OF DEVELOPMENT.			
Slow and indolent.	Slow in growth.	Rapid in its growth.	Very slow, but often becoming suddenly rapid.
Skin rarely involved.	Skin becomes involved before sup- puration.	Skin involved in its late stages.	Skin unaffected.
Suppuration rare.	Suppuration present.	Ulceration and fungus growth frequent.	No suppuration or fungus growth.
Hydrocele common.	Hydrocele infrequent.	Hydrocele infrequent.	Hydrocele rare.
PAIN IN TESTICLE.			
No pain present; a sense of weight only is perceived.	Absent until sup- puration commences.	A severe and lancinating pain is always present in the last stages.	No pain.
SURFACE OF THE TUMOR.			
Irregular at first, but ultimately <i>smooth</i> .	Nodular and knot- ty throughout.	Smooth but uneven.	Slightly uneven.
CONSISTENCE OF TUMOR.			
Hard and stony.	Hard and resist- ant.	Soft and fluctu- ant in spots.	Fluctuant in spots.
EPIDIDYMIS.			
Seldom affected.	Begins in it, and is affected through- out the disease.	Extends to it in the last stages.	Is seldom involved.

SYPHILITIC TESTIS.	TUBERCULAR TESTIS.	MALIGNANT TESTIS.	SARCOMA OF TESTIS.
--------------------	--------------------	-------------------	--------------------

(Continued.)

SCROTAL VEINS.

Unchanged.	Normal.	Enlarged and varicose from pressure of inguinal glands.	Normal.
------------	---------	---	---------

SIZE OF TUMOR.

Comparatively <i>small</i> .	Never very large.	May be immense.	May be very large.
------------------------------	-------------------	-----------------	--------------------

EFFECT OF PRESSURE.

No pain or any sensation on pressure.	No pain on pressure.	Pain aggravated by handling tumor.	No pain; but squeezing the testicle produces <i>faintness</i> .
---------------------------------------	----------------------	------------------------------------	---

NUMBER OF TESTICLES AFFECTED.

Both testicles often consecutively attacked.	Both testicles often attacked in succession.	Only one testicle is, as a rule, affected.	One testicle only is involved.
--	--	--	--------------------------------

FUNGUS GROWTH.

Is <i>very rare</i> .	Is <i>very common</i> ; and is pale, soft, and bleeds easily. Pus thin. Sinuses exist leading into testicle.	Is <i>constant</i> in the advanced stages. Fungus bleeds profusely. Fungus discharge is bad-smelling and ichorous.	<i>No fungus</i> ever exists.
	Fungus grows <i>slowly</i> .	Fungus grows rapidly.	
	Fungus is <i>painless</i> .	Fungus is very painful.	

DURATION.

Several years.	Several years.	Average is about two years.	Indefinite duration.
----------------	----------------	-----------------------------	----------------------

PROGNOSIS.

Recovery, if well treated.	Radical cure rare.	Bad prognosis. Kills by hemorrhage, cachexia or return after castration.	Good prognosis if removed. If left, may become cancer.
----------------------------	--------------------	--	--

TERMINATION.

Calcareous degeneration.	Suppuration, formation of fistulae, and evacuation of the testicle.	Ulceration and fungoid growth.	Cancerous degeneration, or stationary condition.
Fibrous degeneration.			
Atrophy.			

HÆMATOCELE.

HYDROCELE.

RAPIDITY OF DEVELOPMENT.

The tumor develops rapidly if of traumatic origin, but slowly if spontaneous in character.	The tumor develops slowly.
--	----------------------------

HISTORY.

A history of traumatism is frequently present.	No history of injury exists.
--	------------------------------

FLUCTUATION.

Fluctuation is detected at first, but soon disappears, as coagulation of the blood renders the tumor <i>hard</i> and non-fluctuant.	Fluctuation is well marked at all times and over all portions of the tumor.
---	---

SHAPE OF TUMOR.

The tumor is pyriform in shape.	The tumor is usually <i>ovoid</i> in shape.
---------------------------------	---

EFFECT OF TRANSMITTED LIGHT.

The tumor is opaque, as shown by a lighted candle placed behind it.	The tumor is translucent, save at the posterior portion, where the testicle is usually present.
---	---

APPEARANCE OF SKIN.

The skin is usually discolored.	The skin is normal in color.
---------------------------------	------------------------------

CONSTITUTIONAL SYMPTOMS.

Pallor, prostration, and general evidences of loss of blood exist.	No symptoms referable to hemorrhage are detected.
--	---

WEIGHT OF TUMOR.

The tumor is heavy in weight.	The tumor is light in weight.
-------------------------------	-------------------------------

SPERMATIC CORD.

The cord is free and unaffected in the majority of cases.	The spermatic cord is sometimes involved.
---	---

DISEASES OF THE TUNICA VAGINALIS AND OF THE SPERMATIC CORD.

The tunica vaginalis, or the serous covering of the testicle, may contain within its normal cavity either effused blood, constituting hæmatocele, or an excess of its natural secretion, constituting the disease termed hydrocele.

The first of these has already been considered under diseases of the testicle, although it may properly be also classified as a disease of the tunica vaginalis. The second condition, viz. : that of *hydrocele*, may be of several distinct anatomical varieties.

Hydrocele may be classified into

1. **SIMPLE HYDROCELE.** This condition is the direct result of inflammatory processes occurring in the tunica vaginalis and the sub-serous cellular investment. The inflammatory process is, in the majority of cases, essentially of the chronic variety. The testicle is found enclosed, or rather displaced by the distended sac, which contains an amber-colored fluid, and is usually located at the posterior portion of the scrotal tumor, rather below its centre.

This position of the testicle, although present in the large majority of cases, is not always insured. Old adhesions in the serous coverings of the testicle from previous inflammation often retain that organ in some particular locality, and the fluid is thus forced to accumulate in some special direction.

It is thus probably that the so-called "**MULTI-LOCULAR HYDROCELE**" is produced, in which distinct cysts, having often no communication with each other, are detected.

Hydrocele is without doubt the most common disease of the testicle or its coverings. It affects all ages and all ranks of life. It is most common, however, in infancy and in middle life, and occurs in warm climates more frequently than in cold regions.

It is generally unilateral, and the left side is most frequently affected.

The exciting causes of the disease seem to include

anything which will disturb the nicely adjusted balance between the functions of secretion and absorption. Thus, all causes exciting an abnormal determination of blood to the part, or impeding the free venous return, may result in this condition from interference with the circulation within the gland or its coverings.

The dependent position of the left testicle, and the absence of a *direct* venous return on the left side, afford an explanation of its frequency on that side of the scrotum, although the pressure exerted by the sigmoid flexure of the colon upon the spermatic veins, is also advanced as a possible exciting cause.

Hydrocele is usually developed after a violent strain, or great fatigue, or after a slight blow upon the gland which was considered, at the time, as trivial. It may also accompany hydræmia, and may result from sympathetic connection with chronic diseases of the urethra or bladder.

If hydrocele is accompanied by an enlargement of the testicle, the condition is often distinguished by the term "HYDRO-SARCOCELE."

2. CONGENITAL HYDROCELE. This condition occurs from an imperfect closure of the canal between the cavity of the peritoneum and that of the tunica vaginalis after the testicle has descended. The opening remaining is usually small in size, and the fluid which accumulates seems to be due to gravity of the peritoneal effusion.

A rare form of disease, resembling a congenital hydrocele, accompanies a late transition of the testicle when no hernial protrusion simultaneously occurs.

Congenital hydrocele is to be confounded with a reducible intestinal hernia, and with ordinary hydrocele.

3. ENCYSTED HYDROCELE OF THE TESTICLE. In this form of hydrocele, fluid is effused into an adventitious cyst, or cysts, distinct from the cavity of the tunica vaginalis.

They may be developed in one of two situations :

either at the epididymis beneath the visceral layer of the tunica vaginalis, or beneath that portion of the tunica vaginalis covering the *body* of the testicle.

The first is by far the more common, the latter being very rare.

The cysts of the epididymis often become pedunculated, but if so, seldom exceed the size of a pea. They usually contain a small amount of fluid, and are *hard* and semi-transparent. They are quite common after the age of forty.

When "encysted hydrocele of the epididymis" attains, however, a large size, without undergoing pedunculation, the testicle is usually displaced to the *bottom* of the sac; rarely, if ever, to its posterior portion. The tumor is smaller than an ordinary hydrocele, and seldom exceeds four ounces in contents, although the size may, in rare instances, equal that of a *large* hydrocele. These cysts are frequently multiple, and their contents are either straw-colored and albuminous; or they may be thick, turbid, and filled with coagula. When the body of the testicle becomes the seat of this disease, the term "*encysted hydrocele of the tunica vaginalis*" is applied, in contradistinction to simple multilocular cysts, due to adhesions within the cavity of the serous investment of the testis.

They enclose a milky fluid, and often contain spermatozoa, probably introduced by a rupture of the tubules of the testicle from over-distension.

Encysted hydrocele, in general, is characterized by an imperceptible origin, by a slow and painless growth, and by a stationary condition, after attaining a moderate size, which often remains for years producing no inconvenience or pain.

It is to be confounded only with localized hydrocele from adhesions, but the aspirator will usually decide this question by the character of the fluid contents of the tumor.

4. DIFFUSE HYDROCELE OF THE SPERMATIC CORD. This affection is described by *Pott*, under the denomination of HYDROCELE OF THE CELLS OF THE TUNICA COMMUNIS.

The disease partakes largely of the character of an ordinary œdema diffused throughout the loose connective-tissue of the spermatic vessels, and of the cord, and is enclosed in a layer of compressed tissue, invested by the musculo-aponeurotic structure of the cremaster muscle.

The base of the tumor corresponds to that point where the spermatic vessels join the testicle, and is cut off, at this point, by a dense septum from communication with the tunica vaginalis. It frequently extends along the cord, and may, in rare cases, enter the abdomen. The tumor is smooth, uniform, and nearly cylindrical in shape.

It is a comparatively rare disease, and is produced by obstructed venous return, as exists in case of local pressure from enlarged inguinal glands etc., etc.

It is to be diagnosed from omental hernia, and from encysted hydrocele of the cord.

5. ENCYSTED HYDROCELE OF THE SPERMATIC CORD. This condition is the result of the formation of a distinct cyst, or cysts, within the loose cellular or connective tissue of the spermatic cord. It is usually oval in form, seldom if ever exceeds the size of a hen's egg, and is usually much smaller.

It is situated in one of four locations: either just above the testicle, at the external ring, in the middle portion of the cord, or in the inguinal canal. It is usually a solitary cyst, but in some cases multiple cysts are formed.

It is due, probably, to a *partial or imperfect obliteration* of the peritoneal prolongation which accompanies the testicle in its descent into the scrotum, resulting in an isolated sac, or a succession of pouches being left, which becomes distended with serous fluid.

It is of gradual and slow development, and may possess obscure and indistinct fluctuation.

It can be handled without pain, and is often more or less transparent. It is quite freely movable in the longitudinal direction of the spermatic cord.

It is frequent in infants, but may exist at all stages in life.

It is to be diagnosed from encysted hydrocele of the testicle, if close to the gland, by its mobility and its separation from the testicle when drawn upwards, and from the character of its fluid contents.

When in the inguinal canal it may be mistaken for a hernia.

6. VARICOCELE OF THE SPERMATIC CORD AND TESTICLE.

The term "VARICOCELE" is used to designate a varicose condition of the spermatic veins within the scrotum, while the term CIRSOCELE is used to denote a varicose condition of the veins of the cord and testicle. The two terms are, however, often used synonymously to express any abnormally varicose condition of the spermatic veins independent of the location affected.

In this disease, the venous coats are thickened so as to resemble arteries in their structure, and their course is rendered tortuous and irregular. The calibre of the veins is increased by dilatation of their coats, and the apparent number of the veins is largely increased by the distension of venous capillaries.

The disease is most frequent upon the left side, the proportion being nearly twenty to one.

The causes of this excessive frequency upon the left side have been thus explained :

- 1st. The left testicle hangs lower in the scrotum, and thus the veins of the left side support a heavier column of blood.
- 2d. The spermatic veins of the left side are pressed upon by the sigmoid flexure of the colon when distended.
- 3d. The spermatic vein of the left side joins the renal vein at a right angle to the current of blood, thus impeding the rapid return of blood from the left testicle.
- 4th. The left spermatic vein is by some authorities stated to be poorly supplied with valves ; but the

anatomical accuracy of the statement is questionable.

Varicocele, as a disease, may result from

A. Causes which *impair* the *general vigor* of the parts.

Under this head may be included

1. Masturbation.
2. Abuse of venery.
3. Chronic orchitis, or repeated attacks of acute orchitis.
4. Lack of proper support from a relaxed scrotum.

B. Causes producing varicocele from *pressure*.

Under this head may be included

1. Abdominal tumors.
2. Enlarged lumbar or inguinal glands.
3. Hernia.
4. Trusses, or belts worn around the waist.
5. Accumulation of fat in the omentum and mesentery.

C. Causes producing varicocele by *muscular effort*. This class of causes may include

1. Prolonged riding on horseback.
2. " rowing.
3. " exercise, in running, waltzing, etc.
4. Excessive and violent muscular efforts.
5. Whooping-cough.

Varicocele occurs most frequently at the time of puberty.

If due to mechanical pressure, it is most frequent in those advanced in life. It is a very common affection, and is indicated by a tumor possessing the appearance and feel of a "bag of worms," associated with a sense of weight and local distress, which increases as night approaches, from the relaxation of the scrotum.

A sense of immediate relief is present after coition, but a severe exacerbation of the symptoms follows during the succeeding twenty-four hours.

Varicocele is to be diagnosed from scrotal hernia, with which it has many points in common.

7. LIPOMA OF THE SPERMATIC CORD. Fatty tumors usually

form in front of the spermatic vessels, as a loose and movable tumor, having a soft, doughy feel, and a lobular appearance. They may be mistaken for a hernia of omentum. They possess no distinctive symptoms, and are a source of little, if any, inconvenience.

8. SPASM OF THE CREMASTER MUSCLE, causing RETRACTION OF THE TESTICLE. This occurs in some diseases of the kidney, in the passage of a renal calculus, and in affections of the prostate gland. In all cases it is the direct result of nervous irritation transmitted from other parts. It may be associated in some instances with a local injury to the groin, and may occur when the testicle or epididymis becomes sympathetically inflamed, from an existing urethral lesion. It is of diagnostic value as confirmatory evidence only when the history of the exciting disease is obscure.

HYDROCELE.

SCROTAL HERNIA.

DEVELOPMENT OF TUMOR.

The tumor develops slowly.

The tumor develops suddenly, in the majority of cases.

HISTORY OF TUMOR.

The tumor appeared first at the bottom of the serotum, without cause.

The tumor developed from above downwards, after a strain, injury, etc.

DENSITY OF TUMOR.

The tumor is very hard and *elastic*.

The tumor may be hard or doughy, but is never *elastic*.

EFFECT OF LIGHT.

The tumor is *translucent*.

The tumor is *opaque*.

INGUINAL CANAL.

The inguinal canal is empty.

The inguinal canal is filled.

SPERMATIC CORD.

The spermatic cord is easily felt.

The spermatic cord is concealed.

PERCUSSION.

The percussion note over the tumor is *flat*.

The percussion note over the tumor is usually *resonant*.

FLUCTUATION.

Fluctuation is apparent.

Fluctuation is absent.

COUGH IMPULSE.

No impulse, on coughing, is perceived in the tumor.

A cough impulse is perceptible, as a rule, within the tumor.

AUSCULTATION.

No gurgling is heard within the tumor.

Gurgling within the tumor is often detected.

CONSTIPATION.

The function of the alimentary canal is unimpaired.

Constipation may result from the displacement of the intestine.

REDUCIBILITY.

The tumor cannot be reduced.

Reduction is possible.

VARICOCELE.

SCROTAL HERNIA.

PALPATION.

The tumor is knotty and irregular and feels like "a bag of worms." The tumor is usually smooth on its surface and regular in its outline.

COLOR OF INTEGUMENT.

A bluish tint is usually present. The integument is normal in color.

LOCATION.

Is most frequent on the left side. May exist on either side.

EFFECT OF HEAT.

Tumor increases on the application of heat. The effects of heat upon the tumor are negative.

DEVELOPMENT.

Gradual. Sudden.

PERCUSSION.

A dull percussion note exists over the tumor. Resonant percussion usually exists.

FLUCTUATION.

May exist if the vessels be very large. Never exists.

SPERMATIC CORD.

Not affected. Concealed or displaced.

INGUINAL CANAL.

Uninvolved. Usually filled.

COUGH IMPULSE.

Absent. Usually detected.

REDUCTION.

Reduces often spontaneously by any position favoring increased venous return. Reduction is usually accomplished by taxis alone.

VARICOCELE
(*continued*).

SCROTAL HERNIA
(*continued*).

RETURN OF TUMOR.

The tumor returns when the patient stands up, in spite of pressure at the ring.

The tumor, if once reduced, can be prevented from a return by pressure at the external ring.

SENSATION IN SCROTUM.

A sense of weight, and of constant dragging in the scrotum, exists.

There is a sense of distension only, unless inflammation or strangulation exist.

HYDROCELE, ENCYSTED.

CYSTS OF TESTIS.

LOCATION.

Are most commonly located at the epididymis, but may rarely affect the body of the testicle.

Are most commonly situated in the body of the testicle.

PEDICLE.

The cysts are often pedunculated.

The tumor is rarely pedunculated.

NUMBER.

The tumors are frequently multiple.

The tumor is usually single.

SIZE OF TUMOR.

The tumors are usually quite *small* in size, but may, in rare cases, reach a fluid contents of four ounces.

The tumor is usually of the size of a pigeon's egg when fully developed, and seldom exceeds it.

DEVELOPMENT.

The tumors grow slowly and painlessly, as a rule, and are often stationary in size for years.

The tumor grows slowly, but is often associated with enchondromatous deposits.

CONTENTS.

The tumor, if located on the body of the testicle, usually contains spermatozoa, but if on the epididymis an albuminous fluid and occasional coagula are withdrawn on aspiration.

The tumor seldom if ever contains spermatozoa. An albuminous fluid and coagula are however frequently present.

FREQUENCY.

These tumors are not uncommon after the age of forty years.

Is a rare affection.

HYDROCELE.

CONGENITAL HERNIA.

AGE AFFECTED.

<p>May affect any age; and, if in adults, is not necessarily associated with a history of a previous attack.</p>	<p>Is usually a disease of infant life; but if once present, subsequent attacks in adult life may occur.</p>
--	--

FLUCTUATION.

<p>The tumor is markedly fluctuant in all of its localities.</p>	<p>The tumor is usually fluctuant at its <i>upper</i> portion since the peritoneal effusion gravitates.</p>
--	---

TRANSLUCENCY.

<p>The tumor is <i>always</i> translucent.</p>	<p>The tumor <i>may</i> be translucent.</p>
--	---

PEDICLE.

<p>The tumor is not pediculated.</p>	<p>The tumor has a marked pedicle.</p>
--------------------------------------	--

SHAPE OF TUMOR.

<p>The tumor is pyriform.</p>	<p>The tumor is globular.</p>
-------------------------------	-------------------------------

DEVELOPMENT.

<p>The tumor always develops <i>slowly</i> and gradually.</p>	<p>The tumor <i>may</i> be of sudden occurrence, or may show sudden and rapid increase in its size when once developed.</p>
---	---

INGUINAL CANAL.

<p>The inguinal canal is empty.</p>	<p>The inguinal canal is either distended or involved.</p>
-------------------------------------	--

REDUCIBILITY.

<p>The tumor cannot be reduced.</p>	<p>The fluid portion, when reduced by taxis or pressure, leaves a previously concealed testicle, which also reduces with a marked gurgle and occasions a peculiar <i>sickening sensation</i> during its passage through the inguinal canal.</p>
-------------------------------------	---

HYDROCELE OF THE CORD.

INGUINAL HERNIA.

LIMITS OF TUMOR.

The tumor is circumscribed.

The tumor is frequently scrotal, and is generally diffused.

PALPATION.

The tumor is tense.

The tumor is soft, as a rule.

REDUCIBILITY.

The tumor is usually irreducible, but if not so no gurgle is present on its reduction.

The tumor reduces with a gurgle.

TRANSLUCENCY.

The tumor is often translucent.

The tumor is opaque.

FLUCTUATION.

The tumor is fluctuant.

The tumor does not fluctuate.

PERCUSSION.

The percussion note is dull over the tumor.

The percussion note is resonant over the tumor, as a rule.

BOWEL.

No intestinal embarrassment exists.

Intestinal embarrassment is often present.

IMPULSE FROM TESTICLE.

The testicle, if moved, transmits an impulse to the tumor.

Movements of the testicle have no effect upon the tumor.

COUGH IMPULSE.

Impulse on coughing is absent.

An impulse on coughing is frequently felt in the tumor.

AUSCULTATION.

No gurgling is detected.

Gurgling is often heard in the tumor.

RETURN AFTER REDUCTION.

The tumor returns after reduction irrespective of position.

The tumor remains reduced if the dorsal position is maintained.

HYDROCELE.

HÆMATOCELE.

RAPIDITY OF DEVELOPMENT.

The tumor develops slowly.

The tumor develops rapidly if of traumatic origin, but slowly if spontaneous in character.

HISTORY.

No history of injury exists.

A history of traumatism is frequently present.

FLUCTUATION.

Fluctuation is well marked at all times and over all portions of the tumor.

Fluctuation is detected at first, but soon disappears, as coagulation of the blood renders the tumor *hard* and non-fluctuant.

SHAPE OF TUMOR.

The tumor is usually *ovoid* in shape.

The tumor is pyriform in shape.

EFFECT OF TRANSMITTED LIGHT.

The tumor is translucent, save at the posterior portion, where the testicle is usually present.

The tumor is opaque, as shown by a lighted candle placed behind it.

APPEARANCE OF SKIN.

The skin is normal in color.

The skin is usually discolored.

CONSTITUTIONAL SYMPTOMS.

No symptoms referable to hemorrhage are detected.

Pallor, prostration, and general evidences of loss of blood exist.

WEIGHT OF TUMOR.

The tumor is light in weight.

The tumor is heavy in weight.

SPERMATIC CORD.

The spermatic cord is sometimes involved.

The cord is free and unaffected in the majority of cases.

DISEASES OF THE BLADDER.

The diseases and the surgical conditions which may affect the bladder may be thus enumerated:

A. MALFORMATIONS OF THE BLADDER, under which head may be included

1. DEFICIENCY OF THE BLADDER, in which the ureters open directly into the urethra, or, as in some reported cases, the ureters may enter the rectum, and thus discharge the renal excretion.

In the female sex a few cases have been reported where the ureters communicated directly with the vagina.

2. MULTIPLICITY OF BLADDERS. Two well-known reported cases are on record illustrating this malformation.

In one, that of Blasius, two well-defined sacs existed, into each of which one ureter emptied; in the other, that of Molinetti, five bladders, five kidneys, and six ureters, are said to have existed in one woman.

It is probable that many cases of sacculated bladder from long-standing disease may have been mistaken for this deformity.

3. EXTROVERSION OF THE BLADDER. This condition is not one of extreme rarity. It is often associated with absence of the pubes, and is due to a congenital absence of the anterior wall of the bladder.

A protrusion of its posterior surface, which is red in appearance, is caused by the pressure of the abdominal viscera upon it, and appears as a small vascular flattened tumor.

The extroverted portion usually reveals the openings of the ureters near its centre, and a small rudimentary penis in the male is apparent at its lower margin. In many cases a small pouch, covered with hair, exists, either on the side of, or below the tumor, which, in the male, contains the testicles,

and, in both sexes, often a hernial protrusion of the bowel.

The tumor is extremely sensitive to the touch, often bleeds on slight irritation, and is continually moistened with the urine, which escapes from the open ureters.

This escape of urine not only produces a urinous odor to the patient, but also results in excoriation of the neighboring parts.

B. DISEASES ASSOCIATED WITH STRUCTURAL CHANGES WITHIN THE BLADDER, under which head may be included

- | | | |
|---|---|---|
| 1. INFLAMMATORY CONDITIONS
OF THE BLADDER : | { | Acute Cystitis.
Chronic "
Ulceration.
Suppuration of the vesical walls.
Gangrene. |
| 2. HYPERTROPHY OF THE VESICAL WALLS, associated often with sacculation of the bladder, and resulting from <i>obstructed</i> outlet. | | |
| 3. TUMORS OF THE BLADDER : | { | Fibrous { Warty.
Polypoid.
Villous.
Epithelioma.
Malignant. |
| 4. BAR AT THE NECK OF THE BLADDER. This occurs chiefly in elderly subjects, and may be due to prostatic enlargement, or may be independent of it. | | |
| 5. HERNIA OF THE BLADDER: "Cystocele." Is a rare condition, and occurs as an inguinal hernia in the male, and as a femoral or vaginal hernia in the female. | | |
| 6. INVERSION OF THE BLADDER. This condition occurs rarely, and usually affects children, especially those of the female sex. The bladder is seen to protrude through the urethra. | | |
| 7. RUPTURE OF THE BLADDER. This accident occurs from direct or indirect violence, from an obstructed ure- | | |

thra, or from weakening of the vesical walls from disease.

8. **CALCULI IN THE BLADDER.** These are dependent upon some abnormal condition of urine or the organs containing it. They may be movable or encysted.
9. **FOREIGN BODIES IN THE BLADDER.** These are usually introduced, per urethra, by the patient, either by accident or to elicit sympathy.
10. **TUBERCLE OF THE BLADDER.** This occurs rarely and always with similar changes in the prostate gland and the kidney.

C. **CONDITIONS OF THE BLADDER, NOT NECESSARILY ASSOCIATED WITH STRUCTURAL CHANGES IN THAT ORGAN.** This class of abnormal conditions of the bladder includes

1. **PARALYSIS OF THE BLADDER.** This condition depends upon the existence of some cerebral or spinal lesion. It may follow injury, cerebral or spinal apoplexy, softenings or degenerative changes in the brain or the spinal cord, sexual excesses, shock, fevers, reflex irritation, or poisons.
2. **ATONY OF THE BLADDER.** This condition frequently accompanies any source of obstruction to the free evacuation of the bladder. It may also follow prolonged voluntary retention of urine, cerebral and spinal affections, fevers, and temporary spasm.
3. **SPASM OF THE BLADDER.** This condition is seldom unassociated with an exciting cause, as inflammation, calculi, foreign growths, etc. It is indicated by involuntary, uncontrollable, and exceedingly painful contractions of the bladder.
4. **NEURALGIA OF THE BLADDER.** This is a rare condition. It is associated with many symptoms indicative of stone in the bladder, and is to be diagnosed from it only by the exclusion of that disease.
5. **RETENTION OF URINE.** This condition may exist in the young, middle-aged, or the old. It usually results from prostatic inflammation, urethral stricture, stone in the bladder, prostatic enlargement, foreign bodies in the urethra, urethral spasm, and urethral rupture.

It may also occur from pressure of pelvic tumors, fracture of the pelvic bones, shock and reflex irritation.

6. INCONTINENCE OF URINE. This is a very frequent condition of childhood, but may also affect adults.

In adults it occurs most frequently in females, as sloughing from pressure, use of instruments in labor, and over-distension of the urethra in removing calculi are frequently followed by it. In men it is seldom unassociated with retention of urine, and is therefore, properly speaking, an *overflow* rather than pure incontinence.

7. OVERFLOW OF URINE. This condition results from an habitual engorgement of the bladder, resulting from a retention of its own secretion.

It frequently results from, or accompanies chronic prostatic enlargement, or organic urethral stricture, and is usually first noticed during sleep, although subsequently any movements requiring the action of the abdominal muscles may produce it, by pressure upon the habitually distended bladder.

Many of these conditions require no special guides to diagnosis, their simple enumeration being sufficient to prevent confusion; many may also *co-exist*, since they are often dependent upon each other not only for their origin, but also for their continuance, and thus variations in the symptoms may be produced, which it is difficult to clearly elucidate. As examples of this, we seldom discover a calculus without inflammatory changes within the bladder, and often lesions of a more advanced character are present; again, retention of urine may *result* from structural disease within the bladder, or, if originally independent of disease within that organ, may *excite* the same by urinary decomposition or by simple distension of the bladder itself.

Inflammatory conditions also, or the presence of obstruction to the free drainage of urine, as from tumors, enlarged prostate, cancer, etc., may, in time, result in the formation of a calculus, the nucleus of which originated either as a plug of mucus, coagulated blood, or an aggregation of urinary salts, precipitated by the ammoniacal reaction of the urine.

It is difficult therefore, as evidenced by these few examples, to

draw marked contrasts between diseases which are so often complicated, and which present, in consequence, the combined symptoms of two affections. Besides, many of the structural changes within the bladder, or its congenital deformities and malformations, cannot be *positively* diagnosed during life, although suspicion may be strongly directed towards the possibility of their existence.

I have arranged therefore, in the form of differential tables, only such conditions of the bladder as seem to me most liable to be confounded in a general surgical practice, or to be capable of accurate and positive diagnosis.

CANCER OF THE BLADDER. STONE IN THE BLADDER.

PAIN.

The pain is lancinating in character, and is felt in the pelvis, rectum, back, or hip.

The pain is increased by pressure and catheterism.

The pain is never lancinating in character, and is felt chiefly in the penis.

The pain is often increased by motion or exercise, but is not affected by catheterism.

INTESTINAL SYMPTOMS.

Intestinal obstruction is frequent.

Intestinal embarrassment is rare.

HEMORRHAGE.

Hemorrhage is frequent and often severe.

Hemorrhage is less frequent and profuse.

TUMOR.

A tumor is felt per rectum which is *immovable*.

A tumor may be detected per rectum, and, if so, it is movable.

URINE.

Blood, pus, cancer cells, *organized tissue*, etc., are often mixed with the urine.

Pus, blood, and crystalline deposits are found often in the urine.

AGE.

Occurs after the fiftieth year of age.

Occurs at any age.

HISTORY.

Dyspeptic gastric derangements often precede its development.

An attack of renal colic is frequently the apparent commencement.

CACHEXIA.

A marked cachexia exists.

No cachexia is present.

SYMPTOMS IN COMMON.

Both are associated with *pain* in expelling the last drops of urine.

“ “ “ “ frequent interruption of the stream.

“ “ “ “ frequent hæmaturia.

“ “ “ “ pus in the urine.

“ “ “ “ pain independent of micturition.

RUPTURE OF THE BLADDER. RETENTION OF URINE.

PERCUSSION.

Dulness on percussion over the bladder is either absent, or diffused beyond its normal limits.

Dulness over the seat of the bladder always exists, and is markedly circumscribed.

PAIN.

The pain is not localized, but is rather that of a general peritonitis.

The pain is severe, but is localized in the vicinity of the bladder.

HISTORY.

A history of traumatism, falls, or severe abdominal contraction upon a distended bladder, exists.

A history of urethral stricture, calculus, or nervous causation is most frequent; but traumatism may produce it.

ORIGIN.

A sense of tearing is often perceived by the patient.

No sensation of rupture is produced.

CATHETERISM.

A catheter, if introduced, either fails to reach the urine, or collects abnormal quantities if the peritoneal cavity is filled.

A catheter, if introduced fully into the bladder, always discloses urine and affords immediate relief.

URINE.

The urine, drawn by the catheter, is frequently *albuminous* from admixture of peritoneal effusion, but no *casts* are detected unless a kidney complication exists.

The urine is generally normal or *ammoniacal*, in case its decomposition has occurred within the bladder from prolonged retention.

INJECTION OF FLUID.

If water or milk be injected into the bladder through a catheter *no distension* of the bladder is produced as revealed by a searcher.

The bladder is found, on exploration, to be distended after injection of fluids through a catheter.

SEQUELÆ.

Peritonitis always follows unless the abdomen be opened, the peritoneal cavity washed out, and the rent closed by suture.

No serious results follow, if relief is not too long delayed.

RETENTION OF URINE.

SUPPRESSION OF URINE.

PAIN.

Great pain, in the region of the bladder, results from distension.

Pain in the bladder is absent.

PERCUSSION.

Dulness on percussion exists over the distended bladder.

No dulness, over the bladder, is detected on percussion.

TENESMUS.

Great desire to micturate and vesical tenesmus are present.

No vesical tenesmus, or desire to micturate, exists.

HISTORY.

A history of urethral stricture, direct injury to the urethra, impaction of a calculus, or some local or nervous cause, is present.

A history of injury over the kidney, surgical procedure, severe exposure, or some infectious disease, etc., is usually present.

CATHETERISM.

A catheter, when introduced, affords relief by a withdrawal of the retained urine.

No urine in the bladder is usually detected by the introduction of a catheter, nor is relief of symptoms produced in case a small amount of residual urine is discovered and withdrawn.

CONSTITUTIONAL EFFECTS.

No constitutional effects are produced, provided the condition be not complicated with urinal or local changes.

A *urinous* odor of the skin exists, and rapid symptoms of uræmia develop.

RETENTION OF URINE.

INCONTINENCE OF URINE.

URINAL ESCAPE.

The urine is totally arrested, none escapes.

There is a continual escape of urine.

BLADDER.

The bladder is found to be distended, by percussio over its seat.

The bladder may be occasionally found empty, but is generally distended, as revealed by percussio.

CATHETERISM.

Relief is always afforded by the introduction of a catheter.

The bladder, if *distended* with urine, will be relieved by catheterism.

EXPLORATION OF BLADDER.

No alteration in the neck of the bladder nor change from its normal power of retention of injected fluids, will be discovered.

In cases of *true incontinence*, the bladder will have a defective power of retaining fluids, as revealed by artificial distension by means of injection into its cavity.

AGE AFFECTED.

Is frequent in middle life and in old age, but is infrequent in youth.

Is most frequent in youth and old age.

URETHRAL EXPLORATION.

Urethral stricture or prostatic enlargement is frequently detected, on exploration of the urethra, as an exciting cause of retention.

The urethral canal is often of normal calibre, and free from disease.

ACUTE CYSTITIS.

STONE IN THE BLADDER.

INVASION.

The invasion of cystitis is often sudden and accompanied by acute symptoms as rigors, fever, vomiting, anxiety of countenance, etc.

The approach of symptoms, due to a calculus, is often insidious and dates from a previous attack of renal colic, in the majority of cases.

PAIN.

The pain may be located above the pubes, in the perineum, neck of bladder, loins, or thighs.

The pain is most frequently located in the glans penis.

The pain is of a burning character and is rendered *acute* by pressure.

The pain is most increased by exercise, horseback riding, etc., and during micturition, in some cases.

BLADDER.

The bladder is extremely irritable and cannot retain urine.

The bladder retains urine easily, unless a complicating cystitis exist.

CATHETERISM.

The introduction of instruments into the bladder produces great pain.

The effects of catheterism are negative, as a rule.

URINE.

The urine contains mucus in large quantities, often blood and pus. It is frequently alkaline in its reaction.

The urine may contain pus, blood, crystalline salts, or it may be normal in its appearance and reaction.

SYMPTOMS IN COMMON.

Both are associated with *pain* in region of bladder.

“ may be “

“ *urinal changes.*

“ “ “

“ frequent and often painful micturition.

PARALYSIS OF THE
BLADDER.

ATONY OF THE BLADDER.

DEFINITION.

Is a condition dependent upon a loss of, or impaired contractile power of the organ from imperfect nervous supply.

Is a condition of temporary loss of contractile power, resulting from obstruction to the free evacuation of the organ, or impaired nutrition.

ORIGIN.

Paralysis of the bladder is to be diagnosed chiefly by its origin. It may ensue from

1. Injuries to the brain.
2. " " spinal cord.
3. Softening of nerve centres.
4. Apoplexy of nerve centres.
5. Functional derangements of nerve centres.
6. Organic disease of nerve centres.
7. Reflex derangements of nerve centres.
8. Spinal debility from excesses.
9. Shock.
10. Fevers.
11. Poisons, etc., etc.

Atony of the bladder may also be chiefly diagnosed by its exciting causes. Among these may be mentioned

1. Prostatic enlargement.
2. Urethral stricture.
3. Prolonged voluntary retention of urine.
4. Fevers.
5. Poisons.
6. Extreme debility.
7. Acute local inflammations.

IMPROVEMENT.

The improvement is slow, and often the condition is incurable.

The improvement is rapid if the cause be removed.

FREQUENCY.

Is a comparatively rare disease.

Is a frequent affection.

CHRONIC CYSTITIS.

CHRONIC PROSTATITIS.

ORIGIN.

Is a common disease of the bladder, and may occur from

1. Continuation of an acute cystitis.
2. Decomposition of urine.
3. Abnormal condition of urine ; as extreme acidity, presence of irritating salts, extreme dilution, etc.
4. Foreign bodies in bladder.
5. Extension of inflammation from neighboring organs.

Is a sequela to an attack of acute prostatitis, or may result from an extension of inflammations from neighboring parts.

SIZE OF STREAM.

The stream may be of normal size.

The stream is diminished in size from tumefaction of the prostate.

APPEARANCE OF URINE.

The urine contains pus, often in large quantities, which assumes the character of a semi-transparent, tenacious, ropy deposit, which rapidly settles in the containing vessel.

The urine is generally alkaline in reaction, and often ammoniacal in its odor.

The urine is cloudy and may often contain pus and blood in small quantities.

The urine is generally acid and is never *ammoniacal*, unless some bladder complication exists.

PAIN.

The pain is not markedly confined to the perineum.

Pain exists in the perineum and rectum. Micturition and sexual intercourse are often painful.

URETHRAL DISCHARGE.

No urethral discharge is produced if uncomplicated.

A glecty discharge is often present.

RECTAL EXAMINATION.

The prostate gland is normal.

The prostate is *enlarged* and *sensitive*.

DISEASES OF THE PROSTATE GLAND.

The prostate gland may be the seat of the following varieties of disease :

A. INFLAMMATORY DISEASES, under which head may be included

1. ACUTE PROSTATITIS. This disease is seldom a primary affection except when caused by injury. It usually results from an extension of disease from adjacent or associate organs. It is a rare disease in childhood and in old age, but is frequently met with in middle life. It is frequently of gonorrhœal origin, and may, in rare cases, be of idiopathic occurrence.
2. CHRONIC PROSTATITIS. In this condition, prostatic enlargement is always present, provided a previous acute prostatitis existed, but otherwise it may be absent. It is indicated chiefly by a gleet, pus and blood in the urine, weight and dull pain in the perineum and near the anus, painful micturition, pain in sexual intercourse, and frequent nocturnal emissions.
3. PROSTATIC ABSCESS. This condition, when it exists, is almost invariably the result of an acute inflammation of the prostate.

It most frequently affects the *lateral* lobes of the gland. Abscesses may be solitary or multiple. The seat of rupture may be located in the urethra, bladder, rectum, perineum, or peritoneal cavity. This last-named method of termination, however, is rare, but, when present, is usually followed by fatal inflammation.

B. HYPERTROPHY OF THE GLAND—"PROSTATIC ENLARGEMENT."

This condition is one of simple augmentation of the volume of the prostate, dependent upon the increased nutrition of its constitutional elements.

It most frequently affects the whole gland, but not uniformly. The urethra is encroached upon in most cases, and the prostate is increased both in size and in

weight. When the middle lobe of the gland is hypertrophied, a marked obstacle to catheterism is created. This disease is essentially one of advanced age, as it seldom appears, to any marked degree, before the age of fifty. From its mechanical effects it possesses great surgical importance.

C. ATROPHY OF THE PROSTATE. This condition usually occurs as a result of mechanical compression, or of structural disease within the gland.

It accompanies abscess and tubercular deposit in the prostate, and frequently follows prolonged compression from a stone in the bladder. It may in rare cases be a congenital defect or result from simple senile decay.

D. CANCER OF THE PROSTATE. Scirrhus of the prostate is very rare, encephaloid less rare, but by no means common. Both are present most often in advanced life, but no age is exempt from the development of encephaloid cancer. No absolute cause for the appearance of cancer in this region can always be detected, though it may follow the development of a vesical calculus or the formation of a urethral stricture. The duration of the disease seldom, as a rule, exceeds twelve months. It is one of the causes of hæmaturia. Melanotic deposit is said to be occasionally associated with encephaloid of the prostate.

E. TUBERCLE OF THE PROSTATE. This is a condition of extreme rarity and is always associated with a similar condition of the adjacent organs. The volume of the prostate may be either natural, increased, or diminished, though the latter is, by far, the most frequent condition. No absolute diagnosis of this affection can be made during life, although the presence of tubercle may be suspected. The symptoms of abscess are occasionally developed by suppuration around the cheesy masses.

F. CYSTIC DISEASE OF THE PROSTATE. Cysts of the prostate gland are rarely met with; but, when present, they possess a pathological interest.

They are usually multiple, several existing at a time, and they vary in size from a mere speck to that of an olive. Their contents are transparent and consist of either a thick, viscid, albuminous substance, or a thin

serous fluid. These cysts are due, in all probability, to closure of the prostatic ducts and retention of their secretion.

Little is known as to their progress, symptoms, or termination. By some they are regarded as dependent only upon the previous existence of prostatic concretions.

G. PROSTATIC CALCULI. These little bodies are probably the result of a disordered follicular secretion, dependent upon sub-acute or chronic irritation. They are most common in old age, but may exist at any period of life. They consist almost entirely of phosphate of lime.

When very abundant they may destroy the glandular structure of the prostate and become aggregated into one large cyst.

They may often be positively detected during life by introducing the finger into the rectum, while a bulbous bougie is passed in and out of the prostate.

By this means they may be felt as *immovable bodies*, or if encysted, as a bag of small nodules. Their immobility is a symptom of great diagnostic importance.

H. PROSTATIC HEMORRHAGE. Hemorrhage from the prostate is rare, and present usually in the aged, when catheterism is forcibly employed. It may follow also falls upon the nates, riding upon horseback, blows in the perineum, or excessive venereal indulgence. The hemorrhage is occasionally spontaneous, and in these cases is dependent upon some ulceration or granular condition of the mucous membrane, or the presence of a fungous, erectile, or encephaloid tumor. The blood from the prostate is often unmixed with urine, and often precedes and also follows the act of micturition.

I. PHLEBOLITES. By this term is designated earthy concretions within the veins. In the female, the veins of the vagina and uterus, and, in the male, the prostatic plexus of veins, are most frequently affected. They usually follow chronic irritation. They consist chiefly of phosphate and carbonate of lime, cemented by a small quantity of animal matter.

J. WOUNDS OF THE PROSTATE GLAND. These are the result either of accident or design. In the latter case they are

made by the surgeon for some useful purpose, as the extraction of stone, etc., etc. Wounds of the prostate gland may be, as respects their character, either incised, lacerated, punctured, or gun-shot.

Wounds, due to accident, may result from forcible catheterism, by inexperienced attempts at extraction of a stone, by fracture of the pelvic bones, by puncture through the perineum or rectum of some pointed stick or instrument, and by gun-shot wounds.

The effects of wounds of the prostate gland may be manifested, either as hemorrhage, inflammation, infiltration of urine and consequent sloughing, retention of urine from tumefaction of the surrounding parts, urethro-vesical or urethro-rectal fistulæ, and abscess either within the substance of the gland or between the gland and the rectum.

If unassociated with wounds of the skin, injuries to the prostate are obscure and often difficult of diagnosis. In old age wounds of the prostate are associated with serious hemorrhage. This is explained on the ground of the great increase in the size and the varicose condition of the prostatic plexus of veins.

I have in the preceding pages briefly sketched the general outlines of diseases of the prostate gland.

In some instances I have enumerated, in connection with the description of the disease, the few points upon which our present means of diagnosis of these obscure diseases rest. Atrophy, cancer, tubercle, cystic disease, prostatic calculi, and phlebolites may often exist unsuspected during life, as the symptoms are frequently of a vague and imperfect character. I have, however, arranged in the form of tables the points of contrast between the inflammatory affections of the prostate and the distinctions to be drawn between hypertrophy of the prostate gland and organic urethral stricture.

ACUTE PROSTATITIS.

CHRONIC PROSTATITIS.

HISTORY.

Is usually of traumatic origin, or follows an extension of inflammation from other parts.

Is secondary to the acute form, or may follow a gonorrhœa by an extension of that disease backwards.

PAIN.

The pain is violent and pulsatile, situated deep in the perineum in front of the anus, and is augmented by pressure.

The pain, when present, is local and confined to the pelvis usually in the rectal region.

RECTAL SYMPTOMS.

Rectal tenesmus and marked pain during defecation are usually present.

Rectal tenesmus is often absent, and defecation is seldom painful.

URINE.

The urine is high colored, and may contain pus or blood.

The condition of the urine is affected by the weather, habits of the patient, and the amount of exercise taken.

Retention of urine is frequent.

Retention of urine is infrequent.

RIGORS.

Rigors are frequent if suppuration occurs.

Rigors are seldom present.

RECTAL EXAMINATION.

The prostate, when examined per rectum, is hot, enlarged and tender. In case suppuration occurs it often becomes fluctuant.

The prostate exhibits local sensitiveness to the touch and enlargement. It seldom, if ever, goes on to suppuration, and is therefore not fluctuant.

ABSCESS.

Pus may form and escape through the urethra, bladder, rectum, pelvic fasciæ, or perineum.

Abscess is of rare occurrence.

SYMPTOMS IN COMMON.

Both may be associated with *frequent micturition*.

“ “ “ “ *pain during micturition*.

“ “ “ “ *elevation of pulse and temperature*.

HYPERTROPHY OF THE
PROSTATE.

ORGANIC URETHRAL
STRICTURE.

AGE AFFECTED.

Is most frequent after fifty.

Occurs at any age, but usually after puberty.

HISTORY.

A venereal history is often absent.

Is commonly associated with venereal history.

MICTURITION.

The length of the act of micturition is often hastened by attitude.

Micturition is prolonged, as a rule, but is unaffected by attitude.

BLADDER.

A sense of incomplete evacuation is always present in the bladder.

No abnormal sensations are present in the bladder if not diseased.

URINE.

The urine is frequently ammoniacal from decomposition of the residual urine retained by the enlarged prostate.

The urine is seldom ammoniacal, as the bladder can empty itself completely.

Pus, mucus and blood are common ingredients.

No abnormal deposits exist, save when complications are present.

RECTAL EXPLORATION.

The finger when introduced into the rectum detects the enlargement of the prostate.

The prostate is found to be of normal size, by rectal examination.

URETHRAL EXPLORATION.

Bulbous bougies reveal a perfectly normal urethra in front of the prostatic region, if uncomplicated.

Bulbous bougies, or a urethrometer, reveal the seat, calibre and length of the urethral constriction.

SYMPTOMS IN COMMON.

Both are associated with a *prolongation of the act of micturition.*

“ “ “ “ *impairment of the force and size of the urinal stream.*

“ “ “ “ *frequent retention of urine.*

“ “ “ “ *hemorrhoids from straining.*

“ “ “ “ *changes in bladder, kidneys and ureters.*

DISEASES OF THE URETHRA.

The surgical diseases of the urethral canal may be classified into

A. INFLAMMATORY DISEASES.

Under which head may be embraced

1. GONORRHOEAL INFLAMMATION. This condition depends upon the contact of a *specific poison* with the urethral mucous membrane. It is characterized by all the symptoms of acute catarrhal inflammations, and when long continued, results in new connective-tissue formation outside of the urethral walls. It is the most frequent cause of organic stricture. It is evidenced by local engorgement, a purulent discharge, pain in micturition, and occasionally by constitutional disturbance.
2. "URETHRITIS," or, NON-SPECIFIC INFLAMMATION. This condition is produced by local irritation, and not by the contact of a specific gonorrhoeal poison. It differs from the former type of disease in the absence of its severe local symptoms and the amount of the discharge. It may result in the formation of stricture if of protracted duration.

In very acute forms, urethritis is, clinically, closely allied to gonorrhoeal inflammation.

3. LOCAL ULCERS, of the CHANCROIDAL or SYPHILITIC VARIETY. This type of disease will be considered, in all its bearings, in subsequent pages, arranged in the form of a diagnostic table.

B. DISEASES OF THE URETHRA, AFFECTING THE STRUCTURE OF ITS COATS.

Under this head may be embraced

1. URETHRAL STRICTURE (organic). Under the term urethral stricture I include only *abnormal organic contraction* of the urethral canal. It may present the following types: 1. *Annular*, where a localized ring of contraction exists, as if an external cord were tied around

the urethra. 2. *Linear*, where an elevated ridge exists, parallel to the long axis of the urethra. 3. *Indurated Annular*, or "hour-glass" stricture, where the constricting ring is indurated or thickened at its base. 4. *Tortuous*, where the urethral canal is irregularly constricted. 5. "Bridle stricture," where bands extend transversely across the urethral canal.

It may result from specific or non-specific inflammation, from cicatrizations or adhesions within the urethra, from abnormal urethral growths, and from congenital malformation.

Its early symptoms are chiefly gleet, alterations in the size of the urinal stream, and interference with the act of micturition. Its later symptoms depend upon changes in neighboring parts, produced by its mechanical interference with the free escape of urine, and may be localized within the bladder, rectum, kidney, perineum, or testicle.

2. URETHRAL DILATATION. Urethral dilatation occurs most frequently at the membranous portion of that canal. It is due to obstructed evacuation of urine. It results in the formation often of a perineal tumor, which appears only during micturition. It is a frequent cause of urethral rupture.

3. URETHRAL RUPTURE. This condition may be of traumatic or spontaneous origin. It follows blows or lacerations in the vicinity of the perineum, or it may result from a previously existing local dilatation of the urethra.

It may occur either within the membranous portion, immediately in front of the triangular ligament of the perineum, or anterior to the peno-scrotal junction. It seldom, if ever, affects the prostatic portion of the urethra, unless as the direct result of injury or abscess of the prostate.

Rupture of the urethra is always followed by, or accompanied with extravasation of urine. The symptoms produced by this extravasation differ with the *locality* of the seat of rupture. In all cases, however, if the urine be retained outside of its normal channels, sloughing occurs from decom-

position of the retained urea into carbonate of ammonia and the excessive inflammation produced by it, though the symptoms accompanying this destructive process may vary greatly with the locality affected.

4. URETHRAL DEFORMITIES. The deformities of the urethra may be congenital or acquired. In rare cases the meatus may be located at the side of the glans penis, the urethra may terminate in the groin, the ejaculatory ducts may open as a separate canal on the dorsum of the penis behind the glans, enormous congenital dilatations of the urethra may exist, congenital stricture, and valvules pointing backwards and obstructing the flow of urine but not the passage of instruments, have been reported.

Imperforation, atresia, hypospadias, and epispadias, are, however, the deformities of the urethra most frequently encountered.

5. URETHRAL TUMORS. The tumors of the urethra may be either polypi, vascular granulations, tubercle, or cancer. The first two are most frequently located in the prostatic portion of the canal.

Tubercular or cancerous deposits in the urethra are rarely primary, but are secondary, as a rule, to similar conditions of the bladder, prostate gland, or kidney, which have reached an advanced stage in the disease.

6. URETHRAL ABSCESS. Urethral abscess is most frequently located at the fossa navicularis, the bulb of the corpus spongiosum, or in Cowper's glands. The latter condition is denominated "Cowperitis" by some authorities. When the fossa navicularis is affected, the tumor appears on one side of the frænum, but if the bulb or Cowper's glands are affected the tumor is situated in the perineum.

In either case the symptoms are those of abscess, and the causation is usually gonorrhœal.

7. URETHRAL FISTULÆ. These may exist in the perineum, scrotum, groin, nates, penis, or even above the symphysis pubis in case of extravasation of urine. Uri-

nary fistulæ may be classified as 1. Simple fistulæ where the surrounding parts are normal. 2. Fistulæ complicated by inflammatory induration and deformity of tissues. 3. Fistulæ dependent upon destruction of the soft parts by sloughing.

Fistulæ of the urethra are generally associated with urethral stricture or abscess, but they may follow impaction of calculi or foreign bodies. They also result from injury causing a rupture of the urethra, and, in rare cases, are congenital.

C. CONDITIONS IMPEDING THE NORMAL EXIT OF URINE AND INDEPENDENT OF STRUCTURAL CHANGES. This class of conditions embraces :

1. URETHRAL SPASM. This condition seldom, if ever, exists to a degree sufficient in itself to prevent or impede the normal power of expulsion of urine, except when complicated by organic stricture. It is developed, when present, to the greatest degree in the *membranous* portion of the urethra, in which location the compressor urethræ muscle assists the involuntary muscular fibres of the urethral walls. It may result from acid urine, cantharides, turpentine, alcohol, repressed gonorrhœal discharge, organic stricture, and rectal diseases.

It is associated with marked and intermitting variations in the size of the stream, and if uncomplicated by organic stricture should disclose a normal degree of patency of the urethra after the attack has subsided.

2. CONGESTIVE STRICTURE. This variety of stricture is always dependent upon turgescence of the urethral mucous membrane, arising from an inflammatory condition of that part. It is always associated with more or less spasm of the urethra, and, like that disease, is to be diagnosed from organic contraction by the existence of a normal urethral calibre after the attack has been relieved.

3. URETHRAL CALCULI. These bodies are usually derived from the kidney or the bladder, but, in rare instances, may form behind an urethral obstruction.

They may be single or multiple, and may be associated with retention of urine, or an absence of symptoms of obstruction. If not removed, dilatation of the urethra, ulceration, and frequently rupture, follow.

4. FOREIGN BODIES IN THE URETHRA. Foreign bodies are frequently introduced into the urethra either through accident or during attempts to relieve retention of urine, or to induce sexual excitement by the friction of some extraneous substance upon the urethral walls. Thus pieces of slate pencil, heads of wheat, leather thongs, hair-pins, etc., etc., have, in numerous cases, been reported as present in the urethral canal.

RUPTURE OF THE URETHRA
WITHIN THE TRIANGULAR
LIGAMENT.

PERINEAL ABSCESS.

ORIGIN.

Appears as a sudden tumor in the perineum, associated with an indistinct sense of rupture and abnormal sense of warmth in the perineum.

Begins as a slowly increasing tumor in the perineum.

PREVIOUS HISTORY.

A previous history of urethral stricture is usually present, but no premonitory manifestations of rupture may have existed.

A sense of heat, local pain and soreness have usually preceded the development of the tumor.

FLUCTUATION.

Fluctuation is present from the onset.

Fluctuation appears late.

TUMOR.

Is elastic and tense from the onset, until it burrows or escapes from the perineum.

Is hard and oedematous in its early stages, but becomes fluctuant and elastic later.

MICTURITION.

Retention of urine is frequent and follows rapidly upon the appearance of the tumor.

Retention of urine is seldom present, but, if so, it occurs late in the disease.

EXTENT OF INFLAMMATION.

The scrotum, abdominal walls and thighs, may become rapidly implicated when the tumor leaves the perineum.

The inflammation and suppuration are confined solely to the perineum.

RESULTS.

Tends towards rapid sloughing.

Tends towards pointing and the evacuation of pus.

SYMPTOMS IN COMMON.

Both are associated with a *perineal tumor*.

“	“	“	“	possible <i>retention of urine</i> .
“	“	“	“	<i>suppuration</i> .
“	“	“	“	<i>fluctuation</i> .

RUPTURE OF THE URETHRA
IN THE MEMBRANOUS
PORTION.

RUPTURE OF THE URETHRA
IN FRONT OF THE TRI-
ANGULAR LIGAMENT.

TUMOR.

The tumor is, at first, *confined to the perineum.*

The tumor is never confined to the perineum.

SCROTUM.

If the scrotum be distended by urine, it is only involved after sloughing of the triangular ligament has freed the imprisoned urine.

The scrotum is frequently distended from the onset of the attack and appears red, tense and œdematous.

ABDOMEN.

The abdominal walls often escape infiltration by urine, and subsequent sloughing.

The abdominal walls frequently become involved before the tension of the scrotum is relieved by incision or by sloughing.

THIGHS.

The thighs are involved late, if at all.

The thighs are often infiltrated early.

PELVIC ORGANS.

The pelvic organs may undergo sloughing or a general peritonitis may ensue from extension of the urine into the pelvic fascia.

The pelvic organs are never involved.

RUPTURE OF THE URETHRA IN FRONT OF THE SCROTUM. FRACTURE OF THE PENIS.

ORIGIN.

May be of spontaneous origin, or due to traumatism. Is always due to injury.

It usually follows and is dependent upon *urethral stricture*. Is not dependent upon urethral stricture or any diseased condition.

PENIS.

The penis is red, swollen, tense and œdematous. The penis is greatly swollen and ecchymosed, or, hemorrhage may exist through the urethra or integument.

INTEGUMENT.

The integument is always intact, but is distended. The integument may be lacerated.

HISTORY.

A history of the appearance of the tumor during attempt at micturition is usually present, provided the rupture was not traumatic. The history of some accident to the genital organ while in the state of erection, is usually present.

SYMPTOMS IN COMMON.

Both are associated with great swelling and deformity.
 “ “ “ “ frequent retention of urine.
 “ “ “ “ frequent sloughing.
 “ “ “ “ frequent suppuration.
 “ “ “ “ possible permanent deformity after recovery.

ORGANIC STRICTURE OF ENLARGED PROSTATE. THE URETHRA.

AGE AFFECTED.

Oecurs at any age, but usually after puberty. Is most frequent after the age of fifty years.

HISTORY.

Is commonly associated with a venereal history. A venereal history is often absent.

MICTURITION.

Micturition is prolonged, as a rule, but is unaffected by attitude. The length of the act of micturition is often hastened by attitude.

BLADDER.

No abnormal sensations are present in the bladder if not diseased. A sense of *incomplete evacuation* is always present in the bladder.

URINE.

The urine is seldom ammoniacal as the bladder can empty itself completely. The urine is frequently ammoniacal from decomposition of the residual urine retained by the enlarged prostate.

No abnormal deposits exist, save when complications are present. Pus, mucus and blood are common ingredients.

RECTAL EXPLORATION.

The prostate is found to be of normal size, by rectal examination. The finger, when introduced into the rectum, detects the enlargement of the prostate.

URETHRAL EXPLORATION.

Bulbous bougies, or an urethrometer reveal the seat, calibre and length of the urethral constriction. Bulbous bougies reveal a perfectly normal urethra in front of the prostatic region, if uncomplicated.

SYMPTOMS IN COMMON.

Both are associated with a *prolongation of the act of micturition.*
 “ “ “ “ *impairment of the force and size of the urinal stream.*
 “ “ “ “ *frequent retention of urine.*
 “ “ “ “ *hemorrhoids from straining.*
 “ “ “ “ *changes in bladder, kidneys and ureters.*

ORGANIC URETHRAL
STRICTURE.

URETHRAL TUMORS.

SEX AFFECTED.

Is principally a disease of males.

Urethral tumors affect both sexes and may be of two great varieties, polypoid and vascular.

In males the polypoid tumors are most common; in females, the vascular, or fleshy tumors are usually present.

LOCATION.

Urethral stricture is never detected in the prostatic portion of the urethra and seldom behind the *bulb* of the corpus spongiosum.

In males the tumors are most frequent just within the meatus, but they may affect the *membranous* and *prostatic* portions of the urethra.

PAIN.

Urethral strictures are sensitive, often, to the touch, but rarely give pain except during micturition.

The vascular tumors are extremely painful and sensitive, but the polypoid tumors are painless.

ORIGIN.

Strictures are most frequently of gonorrhœal or traumatic origin.

The origin of these tumors is unknown.

HEMORRHAGE.

Strictures seldom cause spontaneous hemorrhage.

The polypoid tumors seldom bleed, but the vascular tumors often bleed profusely.

MOBILITY.

Strictures are constant in their situation and immovable.

Polypoid tumors may be movable with the urethra.

SYMPTOMS IN COMMON.

Both may produce a small stream.

- | | | | |
|---|---|---|---|
| “ | “ | “ | prolonged and painful micturition. |
| “ | “ | “ | a gleetty discharge. |
| “ | “ | “ | subsequent diseases of adjacent organs. |
| “ | “ | “ | impaired general health. |

DISEASES OF THE PENIS.

The diseases to which the penis is subject may be divided into four groups as follows :

A. DISEASES OF THE GLANS PENIS: under which head may be enumerated the following conditions :

1. **BALANITIS.** This term is used to designate an inflammation of the surface of the *glans penis*. It occurs most frequently in persons of gouty habit, or those possessing an irritable skin. It results often in those not predisposed to its occurrence, from retention of the smegma preputii, from contact with gonorrhœal, menstrual, or leucorrhœal discharges, from lack of cleanliness, and from other sources of irritation.

Its symptoms are similar to those of the following disease.

2. **POSTHITIS.** By the term posthitis, is meant an inflammation of the mucous membrane of the *prepuce*. Its causes and symptoms are identical with those of balanitis. The mucous membrane becomes reddened, mottled and often ulcerated. A purulent discharge is present which arises from the surface of the glans, and not from the urethra. A sense of burning and itching at the penis exists, and scalding during micturition may often be present.

Inflammatory phimosis often occurs from swelling of the prepuce, and warty vegetations are a common result of a prolonged balanitis or posthitis.

3. **HERPES PROGENITALIS.** This type of the herpes eruption appears either upon the glans, the mucous or cutaneous surface of the prepuce, or even upon the body of the penis. It is indicated by the formation of clusters of small vesicles, which often ulcerate when exposed to moisture, as when within the preputial covering, and assume, in rare cases, an angry and deep character. These ulcers more frequently tend, however, towards recovery, but in some in-

stances vegetations, balanitis or inflammatory phimosis result as sequelæ.

4. VEGETATIONS and VENEREAL SORES. "*Veneræal warts*" may be located either upon the glands, prepuce, scrotum, anus, or, in some cases, within the urethral canal. Their common designation is a misnomer, as they are more often due to simple irritation than to a venereal origin.

They are frequent in children and in pregnant women, who are troubled with irritating vaginal discharge. They are almost invariably multiple. True *veneræal ulcers* however are frequently found in the same situations as are venereal warts. They are of two great types: *canceroid* and *chancre*; the former being a purely local disease, the latter being a local evidence only of an existing blood condition. These two diseases are due to the presence of a specific poison, and will be considered in contrast in subsequent pages of this work.

5. EPITHELIOMA. This form of cancer most frequently attacks the glans penis and prepuce, and occurs usually after the age of forty. It is characterized by all the general symptoms of epithelioma in other parts of the body. It will be more exhaustively considered under the head of tumors.

B. DISEASES OF THE PREPUCE: under which head is embraced the conditions of phimosis and paraphimosis.

1. PHIMOSIS. The prepuce may be incapable of retraction over the glans from absence of the opening (atresia preputii), from inflammation, from adhesion, and from congenital defect. It is a normal condition in infancy, and, unless sufficient to cause *inflation* or "ballooning" of the prepuce during attempts at micturition, need cause no surgical interference. Phimosis tends, if extensive, towards imperfect development of the glans penis.

It may also produce balanitis, cystitis, spermatorrhœa, and reflex nervous diseases, if severe in extent and long continued.

2. **PARAPHIMOSIS.** Paraphimosis may be the result of an accidental retraction of a tight preputial orifice over the glans penis, or it may occur as a result of inflammatory œdema, when the preputial orifice has always exhibited a normal condition.

This latter condition often accompanies balanitis, gonorrhœa, chancroid, chancre, or even a severe attack of herpes. It occurs, as a rule, during attempts to apply local treatment to the existing condition of the glans penis.

In all forms of paraphimosis the glans becomes rapidly swollen and livid in appearance, from the obstructed venous return, and thus increases the difficulty of reduction. If not rapidly relieved, sloughing occurs, and destruction of the gland or a urinary fistula is liable to be produced.

C. **DISEASES OF THE CORPORA CAVERNOSA:** under which head are included the following conditions :

1. **INFLAMMATION.** This condition is always one of serious import. It may arise spontaneously from a severe gonorrhœa, or in connection with the exanthematous fevers. It also follows contusions and fracture of the penis. As a rule, suppuration and gangrene result when the inflammatory process is severe. The local pain is very excessive. It is a rare disease.
2. **CALCIFICATION OF THE PENIS.** This condition is analogous to atheroma of the blood-vessels. It is insidious in its approach, occurs in middle life or old age, and is first denoted by an imperfect and painful erection of the penis, the organ being bent where calcification has occurred, as the fibrous sheath loses its elasticity in consequence of the osseous deposit. In advanced cases osseous plates can be detected in the body of the organ.
3. **GUMMATA.** Gummy tumors may, in rare cases, affect the genitals in advanced stages of syphilis. They are to be diagnosed from fatty, fibrous, cystic and erectile tumors, which may also affect the penis. This can be easily done by the previous history of the patient, and the tendency of gummata to sup-

purate and discharge. Gummata seldom reach a large size.

4. CHRONIC CIRCUMSCRIBED INFLAMMATION. This affection is very rare. It consists of a local inflammatory induration, the cause of which is unknown, producing a deformity of the penis during erection.

The indurated mass has *elasticity*, and differs in this respect from the osseous plates produced by calcification. It is usually superficial, with well-defined edges, and is slowly progressive in development, or occasionally stationary for an indefinite period.

5. FRACTURE OF THE PENIS. The fibrous sheath of the corpora cavernosa is occasionally ruptured and the adjacent erectile tissue is involved. This condition constitutes the so-called fracture of the penis. It is always accompanied by extensive extravasation of blood, and, in severe cases, may terminate in gangrene. It is produced by injuries received while the organ is in a state of erection. It terminates usually in recovery, when treated early, but may leave a deformity in erection or a nodular swelling at the seat of fracture, which may render subsequent sexual intercourse difficult and painful.

By some authors the voluntary or spontaneous rupture of a *chordee* during a violent attack of gonorrhœa or non-specific inflammation, is regarded as a variety of fracture of the penis. In this case, however, the corpus spongiosum only is involved, and, as the blood escapes through the urethra, little local deformity is the immediate result, although a severe form of organic stricture inevitably follows.

- D. ANOMALIES OF THE PENIS. The penis may be rudimentary in size, or may in rare instances be enormously developed. It may also be double, as is reported by several authors; and in one case described by Nélaton was congenitally *absent*. These unnatural conditions, however, have little surgical importance, as nature, usually, provides a means of free urinal escape, and the general health is therefore unimpaired.

I have in the preceding pages briefly enumerated the principal surgical diseases of the genital organ. Many of them are infrequent, and can be excluded as probable causes of confusion in diagnosis on that ground; while others are too clearly marked in their symptoms to need further elaboration. I have added, however, the distinctive points of diagnosis between chancroidal ulcers and the syphilitic sore, as they are frequently a source of doubt to the practitioner, and as a radical difference in the prognosis and treatment depends upon an early recognition of the disease existing.

CHANCROID.

CHANCRE.

NATURE OF ULCER.

Is a purely local affection.

Is a local manifestation of an existing blood disease.

INCUBATION.

The ulcer develops immediately after absorption of the poison :— 24 hours to third day after infection.

The ulcer develops from 10 to 24 days after infection, as a rule.

SHAPE OF ULCER.

The ulcer is round, as a rule, but may be oval, or irregular from fusion of multiple sores.

Is generally circular or oval.

EDGES OF ULCER.

Are clean-cut, perpendicular, often everted and undermined.

Are smooth, often elevated, adherent, not undermined, and gradually melt into the floor of the ulcer.

FLOOR OF ULCER.

Uneven, honey-combed, warty or irregular, without lustre.

Smooth, often concave, and shining.

COLOR OF ULCER.

Yellowish ; often a reddish or violet areola exists around the sore.

Grey in centre, darker at edges, sometimes scabbed ; areola is often absent.

SITUATION.

Rarely present except on, or near the genitals.

May exist on genitals, head, hands or nipple.

CAUSATION.

Contact with chancroidal ulcer or inoculation with its pus.

Contact with primary sore, a secondary lesion of syphilis, vaccination, or inoculation upon an abrasion of the surface.

PAIN.

Is usually painful.

Is usually painless and indolent.

NUMBER.

The ulcers are seldom single.

A *solitary* sore is usually present.

CHANCROID
(continued).

CHANCRE
(continued).

METHOD OF ORIGIN.

Begins as a pustule, or an ulcer and remains an ulcer.

Begins as a papule or an erosion, and remains an erosion or ulcerates.

SECRETION.

Ichorous and irritating pus in first stage ; but laudable when ulcer is healing.

Scanty and serous in character, unless the sore be irritated when it becomes purulent.

INDURATION.

Is absent, unless the ulcer be irritated ; is not elastic or abrupt in its termination, subsides after the irritation is removed, is adherent to the skin and sensitive to pressure.

Often precedes the sore, and lasts long after its disappearance. It is hard, elastic, cartilaginous, usually hemispherical in shape and abrupt in its outline. It is very *movable* and *never sensitive* to pressure.

INOCULABILITY.

Is auto-inoculable, is transmissible and can be communicated to animals.

Is not auto-inoculable unless irritated, and is transmissible only to human species.

BUBO.

Suppuration of the lymphatics of the groin is frequent. The bubo is usually painful and mono-glandular.

The enlarged lymphatic glands in the groin are usually *painless, multiple*, and *seldom suppurate*, unless injured or due to a mixed infection.

EXTENT OF ULCER.

Is often of large extent from an accompanying phagadæna, and severe in its local results.

Is seldom phagadenic, and shows little tendency to spread.

DURATION.

Often lasts from one to two months.

Is slow in development, but heals rapidly when once reparative processes commence.

CICATRIX.

Not distinctive.

Pigmented, as a rule.

RESULTS.

No constitutional symptoms are developed.

Secondary symptoms of syphilis rapidly appear.

HERPES.

BALANITIC ABRASION.

ORIGIN.

It may occur from cold, fever, or a nervous condition, as well as from friction, irritation, or the chemical action of acrid discharges.

It follows only friction, mechanical irritation, or the contact of acrid discharges from the glans or prepuce.

LOCALITY.

May be a local disease only, or may exist as an evidence of an abnormal nervous condition in other parts simultaneously.

Is always a local affection.

DEVELOPMENT.

It begins as a group of vesicles.

Begins as an abrasion or a fissure.

PAIN.

Is associated with a stinging and burning sensation as it develops.

Is painful and sensitive.

TENDENCY TO RECUR.

A marked tendency to recur at regular intervals is often exhibited. It is often induced to return by dissipation or excessive venery.

No tendency to periodical relapses is present, but it may be reproduced by a return of the exciting cause.

APPEARANCE OF ULCER.

Is rounded in its shape, often slightly irregular, and its borders may disclose the remnants of previous vesicles as segments of small circles.

Resembles a chancroidal ulcer when fully developed.

SURGICAL DISEASES
OF THE
ABDOMINAL CAVITY.

SURGICAL DISEASES OF THE ABDOMINAL CAVITY.

UNDER this head will be considered, in this volume, the following named conditions,

A. INJURIES OF THE ABDOMEN. The injuries to the abdomen may be of three varieties, as follows :

1. CONTUSION OF THE ABDOMEN. Contusions of the abdomen may be present with or without rupture of the viscera. In either case such an accident is frequently accompanied with intense pain, faintness or syncope and vomiting.

In some cases death has occurred by an impression made upon the solar and cardiac plexuses, without any internal lesion being discovered.

Contusions of the abdomen may produce either rupture of muscles, extravasation of blood, rupture of the peritoneum, rupture of the diaphragm, rupture of the stomach or intestine, lacerations of the liver and spleen, rupture of the gall-bladder, or lacerations of the kidney and the ureter.

Contusions of the abdomen usually occur from flying objects, as cricket-balls, etc., etc., from blows received during altercations, from falls upon the abdomen, cart-wheels passing over the body, or from some other similar misfortune. If uncomplicated by injury to viscera, contusions of the abdomen may result in abscess or recovery.

2. WOUNDS OF THE ABDOMEN. Wounds of the abdominal parietes may be either superficial or deep, and may be associated with the absence of complications, or the protrusion, and possible injury of adjacent viscera.

They may occur from sharp and pointed instruments, from being impaled upon iron spikes, caught

upon iron hooks, tossed by horned cattle, injured by glass, china, or missiles, or by the bites of carnivorous animals.

Wounds of the abdomen may vary therefore greatly in appearance, variety, extent and location. They may be complicated with serious hemorrhage and with the introduction of foreign substances into the abdominal cavity through the wound, even in case the viscera escape injury.

The intestines, stomach, liver, spleen, bladder, omentum, and mesentery may protrude, in case the location and character of the wound favor such a displacement.

Artificial anus may result in cases of wounds of the abdominal parietes, although it is a more frequent sequela of diseased conditions of the intestine associated with sloughing.

3. FOREIGN BODIES IN THE INTESTINAL CANAL. Foreign bodies which are proof against the action of the gastric or intestinal juices are often introduced into the stomach either by accident or with design. The foreign bodies often detected include coins, bullets, fruit-stones, pebbles, marbles, hair, string, oat-husk, pins, fish-bones, false teeth, etc., etc.

The results of the introduction of foreign bodies into the stomach differ with the size and shape of the body introduced.

Small, flat, or oval bodies may be voided without delay, pain, or other symptoms of disturbance. If hair, string, or similar substances, be present in the stomach, they often attain immense size, and, by remaining within that organ, frequently produce symptoms of severe dyspepsia, and subsequently those of ulceration and perforation of its coats.

Irregular-shaped or globular bodies frequently become arrested at the ileo-cæcal valve, if allowed to pass the pyloric orifice of the stomach.

Sharp or pointed bodies are best voided by plentiful eating and the avoidance of cathartics, as, by so doing, the foreign body is more liable to be inclosed in the abundance of fæcal material.

Needles when swallowed often penetrate the walls of the alimentary canal and are transported to distant points often before their removal.

B. DISEASES OF THE INTESTINE :

1. FÆCAL ABSCESS. Abscess of the abdominal region is often dependent upon an artificial aperture in some portion of the alimentary canal. It may arise from perforation of the bowel as a sequel to simple ulceration, the lodgement of a foreign body in the intestine, ulceration of the gall-bladder from a gall-stone, stricture of the intestine, cancerous disease of the bowel, or fæcal impaction as a result of muscular atony or paralysis, dependent upon previous catarrhal inflammation of the intestine.

The most frequent seat of fæcal abscess is in the region of the ilio-cæcal valve—the right iliac fossa; but abscess may be present in any portion of the abdominal cavity.

Fæcal abscesses follow no definite rule as to symptoms, rate of progress, or termination.

They may develop slowly and insidiously, or rapidly with severe local pain and marked constitutional disturbance followed by symptoms of a general peritonitis. In the diagnostic table between typhlitis and perityphlitis will be found embodied the principal features of abdominal abscess.

2. INTESTINAL OBSTRUCTION. Intestinal obstruction may develop suddenly or slowly. When the attack is of sudden advent, and the symptoms markedly acute, the result is usually fatal to life; but when slowly developed frequent relief can be afforded or recovery take place, without assistance, even when all hope of life may have vanished.

The causes of *sudden* intestinal obstruction include, 1. Foreign bodies, either artificially introduced or formed within the intestine. 2. Congenital stricture or malformations of the intestine. 3. Twisting of the intestine or *volvulus*. 4. Obstructions from peritoneal adhesions. 5. Invagination of

the bowel or intussusception, resulting from intestinal tumors, worms, or unexplained causes. 6. Thickened peritoneal coverings and mesenteric attachments from an old hernial protrusion, and 7, strangulated hernia.

The causes of *gradual* intestinal obstruction may be 1. Tumors pressing upon the bowel. 2. Simple stricture of the bowel from ulceration, injury, etc. 3. Cancer of the bowel occluding its normal calibre. 4. Tubercular peritonitis. 5. Abscess from traumatism of abdominal walls. 6. Constipation or impaction of fæces. 7. Inflamed and thickened intestine as the result of injury.

The prominent symptoms of intestinal obstruction are 1. Local and severe pain. 2. Obstinate constipation. 3. Presence often of a tumor. 4. Localized dulness if the tumor cannot be felt. 5. Vomiting which becomes stercoraceous. 6. Tympanitis. 7. Symptoms of general peritonitis or collapse.

C. DISEASES OF THE RECTUM. The rectum may present the following surgical conditions :

1. HEMORRHOIDS. These are of two varieties, external and internal, the former being located at the anus, the latter higher up within the rectum. They are both due to a varicose condition of the hemorrhoidal veins. They are largely dependent upon portal obstruction.
2. PROLAPSE OF THE RECTUM. This is a frequent disease of children. It is due in children to lack of tone in the muscular structure of the rectum, or to general debility. If present in adults, a relaxed condition of the sphincter exists.

It may occasionally be produced by hemorrhoids and by urethral stricture as a result of straining.

3. FISTULA OF THE RECTUM. This condition may arise primarily by either ulceration of the rectum, or the formation of an abscess in the cellular tissue external to the rectum.

Rectal fistulæ may be 1. *Complete*, where the rectal canal and the external opening communicate; 2. *Incomplete* or blind fistulæ, where one of these

openings is absent. *Fistulæ* may vary in their number, situation, length and calibre. They are frequently associated with inflammatory induration of the neighboring tissues.

4. **ULCER OR FISSURE OF THE ANUS.** This condition may be either a true fissure, or a small, oval-shaped ulcer, located just within the anus. It produces the most intense suffering and can be detected only by a *careful* scrutiny of the parts, as it may be overlooked or concealed by the *rugæ* round the anal margin.

5. **STRICTURE OF THE RECTUM.** Stricture of the rectum may involve the whole circumference of the gut, or only a portion of it.

The *extent* of the bowel affected may vary from two lines to two inches, or even more.

The *seat* of stricture may vary from one inch, to four or five inches above the anus.

Stricture of the rectum may arise from cicatrices of formerly existing ulcers, from injuries, from surgical operations on the rectum, or from the pressure of tumors or organs. It is almost always associated with abscess and *fistulæ*, if of long duration.

6. **CANCER OF THE RECTUM.** Scirrhus, epithelioma, and colloid cancer, are met with in the rectum. They usually are first recognized as a hardened or indurated mass in the walls of the bowel causing diminution in its calibre. Cancer in this locality usually results in death within four years from the date of its commencement.

A marked cachexia becomes apparent as the disease develops.

7. **RECTAL POLYPUS.** Polypi of the rectum may be of three types: 1, vascular polypi; 2, warty polypi; and 3, fibro-cellular polypi.

Of these, the first is most frequent among children, and is usually associated with hemorrhage; while the other two are comparatively non-vascular. They are all markedly pediculated, and are much less painful than hemorrhoids.

8. **PRURITUS ANI.** This distressing affection may result

from constipation, abnormal intestinal secretion, ascarides in the rectum, prolonged sitting posture,¹ and uterine diseases. It is usually associated with morbid textural changes around the anus, if long continued, from the irritation of scratching.

9. NEURALGIA OF THE RECTUM. This condition is diagnosed by a severe and continuous pain within the rectum, not markedly affected by the condition of the bowel or attempts at defecation, and associated with no appreciable rectal disease. It occurs most frequently in females who have been in a state of depressed vitality.

The following conditions of the rectum, viz., hemorrhoids, fistulae, fissure of the anus, cancer, rectal polypi and rectal prolapse, will be found contrasted in diagnostic tables at the close of this chapter on surgical diseases of the abdomen.

D. HERNIA.

By the term hernia is meant "a protrusion of any viscus from its natural or containing cavity."

Hernia may be classified, first, on a basis of the ANATOMICAL LOCATION of the protruding viscus, as follows :

HERNIA : Classified on a basis of location.	In the cranial region.	}	HERNIA CEREBRI.						
					In the thoracic region.	}	HERNIA OF THE LUNG.		
	In the epigas- trium.	}	DIAPHRAGMATIC HERNIA. EPIGASTRIC HERNIA.						
					In the mesogas- trium.	}	VENTRAL HERNIA. UMBILICAL HERNIA. LUMBAR HERNIA.	}	OMPHALOCELE—EXOM- PHALOS.
	Above <i>Poupart's ligament</i> .	}	INGUINAL HERNIA. INGUINO-SCROTAL HERNIA. INGUINO-LABIAL HERNIA.						
	In the hypogas- trium.	}	Through <i>pelvic apertures</i> or in pelvic region.		}	OBTURATOR HERNIA. PERINEAL " PUDENDAL " VAGINAL " ISCHIATIC "			

Hernia may be classified, secondly, on a basis of the CONTENTS OF THE SAC:

HERNIA : Classified on a basis of contents :	}	of Intestines.	ENTEROCELE.	
		of Omentum.	EPIPOCELE.	
		of Intestines and Omentum.	ENTERO-EPIPOCELE.	
		of Bladder.	CYSTOCELE.	
		of Rectum.	RECTOCELE.	
		of other organs.	}	HERNIA CEREBRI.
				“ OF LUNG.
“ “ LIVER.				
“ “ SPLEEN.				
“ “ KIDNEY.				
		“ “ STOMACH.		
		“ “ TESTIS.		

Hernia may be classified, thirdly, on a basis of the CONDITION OF THE SAC, as follows :

HERNIA : Classified on a basis of the <i>condition</i> of the sac :	}	REDUCIBLE HERNIA.	{ Where the protruded viscus and its coverings can be replaced in their normal situation.
		IRREDUCIBLE HERNIA.	{ Where the protruded viscus is retained in its abnormal position by adhesions, thickening of its coverings, or a deposit of fat.
		STRANGULATED HERNIA.	{ Where the <i>circulation</i> of the displaced viscus is impaired by muscular spasm, œdema, or a sudden forcing of additional contents into the sac.
		INCARCERATED HERNIA.	{ Where a hernial protrusion of intestine is rendered <i>temporarily</i> irreducible by gas or fœces.
		INCOMPLETE HERNIA.	{ Where the hernial protrusion has not attained the development common to the region in which it exists.
		CONGENITAL HERNIA.	{ Where a hernial protrusion follows the descended testicle before the cavity of the tunica vaginalis is closed, thus giving it one layer only of peritoneal covering.
		INFANTILE HERNIA.	{ Where a hernial protrusion into the scrotum occurs <i>outside of</i> , but parallel to the serous coats of the tunica vaginalis. This condition is not always one of infancy, although so named.

Certain *special* types of hernia are also subdivided on grounds of the surgical relations of the neck of the sac, the direction of the means of exit, or the location of the tumor. Thus *inguinal hernia* in its different forms may be spoken of or described under the following names :

Nomenclature of
INGUINAL HERNIA :

1. INDIRECT HERNIA ; by which term is meant that form of inguinal hernia which passes through both the internal and external abdominal rings.
2. DIRECT HERNIA ; by which term is included all forms of inguinal hernia which pass through the external ring but *escape the internal ring*.
3. EXTERNAL HERNIA. This is a synonym for indirect inguinal hernia, the name being applied from the external relation of the neck of the sac to the *deep epigastric artery*.
4. INTERNAL HERNIA. This also is a synonym for direct inguinal hernia, since in both the neck of the sac lies *internally* to the epigastric artery.
5. BUBONOCELE. By this term is meant an incomplete indirect inguinal hernia. Its name is applied from its resemblance to an inflamed lymphatic gland in the groin (bubo).

CAUSES OF HERNIA OF THE ABDOMINAL VISCERA.

The conditions which may tend towards a protrusion of any of the abdominal viscera may be either *predisposing* or *exciting*. Under the first may be enumerated

Predisposing causes
of Hernia :

- A. WOUNDS OR LACERATIONS OF THE ABDOMINAL WALLS. Hernial tumors of the liver, stomach, intestines, spleen and kidney, have been known to exist as a result of wounds of the abdominal parietes. The extent of the wound, its depth and location, tend greatly to modify its effect upon displacement of viscera.

Predisposing causes
of Hernia :
(continued.)

- B. WEAKENING OR DESTRUCTION OF THE ABDOMINAL WALLS by *inflammation, ulceration, suppuration, or disease*. Hernial protrusions often follow abscess, severe types of ulceration and contusions of the abdominal walls, or when they are subjected to excessive strain, as in violent muscular efforts, prolonged attacks of coughing or sneezing, or in cases of straining during defecation.
- C. THE EXISTENCE AT BIRTH AND PERSISTENCE AFTERWARDS OF A CANAL COMMUNICATING WITH THE PERITONEAL CAVITY. The prolongation of the peritoneal cavity, produced by the descent of the testicle, becomes in the majority of cases a separate sac, called the tunica vaginalis, by adhesion of its surfaces within the inguinal canal during the first month of life and often before birth. In rare cases however this union fails to occur.
- D. A GRADUAL PROTRUSION OF THE ABDOMINAL WALLS INTO AN ABNORMAL RECEPTACLE FOR VISCERA. This condition we see manifested in cases of enormous double scrotal hernia. It occurs where a condition of relaxation of the abdominal muscles or a redundancy of tissues exists to a marked degree.
- E. SEX. Hernia as a disease affects males to a far greater extent than females. Still in the femoral and umbilical types of hernia the contrary holds good.
- F. AGE. Hernia is most frequent in infancy, and is a common affection in youth. It is comparatively rare between the ages of 13 and 21; but as age advances the tendency to this affection steadily increases. In women hernia occurs most frequently from the ages of 20 to 50.

- Predisposing causes of Hernia :
(continued.)
- G. HEIGHT. Hernia occurs more often in tall than in short people, especially so if the general state of health is not robust.
 - H. OCCUPATION. Occupations demanding great muscular effort or intermitting strain upon endurance, tend greatly towards the formation of hernia, especially when aggravated by belts worn around the waist, which, by compressing the viscera of the abdomen, tend to assist in the production of their displacement.

The *exciting* causes of hernia usually consist of some violent muscular effort, under which head may be mentioned

- Exciting causes of Hernia :
- A. LIFTING OF HEAVY WEIGHTS.
 - B. VIOLENT EFFORTS IN JUMPING, RUNNING, OR CLIMBING.
 - C. SEVERE ATTACKS OF COUGHING OR SNEEZING.
 - D. STRAINING DURING ATTEMPTS AT MICTURITION, when urethral stricture is present.
 - E. FALLS ASSOCIATED WITH EFFORTS TO RECOVER BALANCE.

DIFFERENTIAL DIAGNOSIS OF HERNIA.

HERNIA OF THE INGUINAL REGION may be confounded, as a disease, with the following named conditions :

1. HYDROCELE OF THE TESTICLE.
2. SARCOCELE “ “
3. VARICOCELE.
4. HÆMATOCELE.
5. BUBO.
6. UNDESCENDED TESTICLE.
7. IMPACTED FÆCES.
8. HYDROCELE OF THE CORD.

It is often difficult also to discriminate between the *inguinal* and *femoral* varieties of hernia, or to detect the various *special forms* of inguinal hernia from each other. In the diagnostic tables appended, I have endeavored, therefore, not only to exhibit the points of contrast between inguinal hernia and other surgical diseases confined to that locality of the body, but also to make clear the points of distinction between those various conditions of inguinal hernial protrusions, which are liable to be encountered in a surgical practice.

FEMORAL HERNIA may be confounded, in diagnosis, with many surgical conditions of the thigh, which often bear symptoms in common with that disease. Among these conditions leading towards error, may be enumerated as important

1. Enlarged Glands.
2. Psoas Abscess.
3. Varix of the Saphenous Vein.
4. Lipoma of the Femoral Canal.

I have added also, in the following pages, diagnostic tables between ventral and umbilical hernia, thyroid and perineal hernia, diaphragmatic hernia and mediastinal tumors, congenital and infantile hernia, and congenital hernia and hydrocele.

In connection with diseases of the rectum, will be shown in contrast the symptoms of external and internal hemorrhoids, external hemorrhoids and condylomata of anus, internal hemorrhoids and rectal polypi, rectal prolapse and rectal polypi, cancer and stricture of the rectum, fissure of anus and fistulæ of rectum.

I have dwelt but slightly upon the *symptoms* of diseases of the abdomen, as they will be found in full in the following pages. I have left unmentioned in these tables, also, contusion of the abdomen and its results, abscess and ecchymosis, as they have no special features over similar changes in other parts, and properly belong to the following chapter on diseases of tissues, in which they will be considered.

I have introduced, however, a table of diagnosis between *Typhlitis* and *Perityphlitis*, as it seems properly to belong to this chapter; and I have added, in connection with it, a table of the causes and symptoms of *intestinal obstruction*.

TYPHLOITIS.

PERITYPHLOITIS.

DEFINITION.

Is an inflammation of the vermiform appendix of the cæcum.

Is an inflammation of the connective tissue about the cæcum.

HISTORY.

The appearance of a tumor in the right iliac fossa is preceded by *colicky pains* and *distension of the abdomen* from tympanitis.

No early diagnostic symptoms precede the attack. It occurs from traumatism, ulceration of the vermiform appendix, pyæmia, etc.

PAIN.

The pain is *superficial* and is confined to the right iliac fossa and right hip.

The pain is deep-seated in the right iliac fossa.

NUMBNESS.

No numbness is felt in the right thigh and leg.

A sense of numbness is present often in the right lower extremity.

EFFECT OF MOTION.

Motion of the thigh produces pain only in the later stages.

Motion of the thigh produces pain early in the disease.

TUMOR.

The tumor is sausage-shaped and superficial.

The tumor is deeply located and fluctuates in the advanced stages.

PERCUSSION.

Flatness is present over the tumor.

Tympanitic percussion, from the inflated cæcum, exists over the tumor, if uncomplicated.

CONTROL OF THIGH.

The patient can raise the right thigh.

The patient cannot raise the right thigh, as a rule.

ABSCESS.

Suppuration and pointing are rarely, if ever, present.

Suppuration, and pointing, as a rule exist, if the abscess is to open externally.

INTESTINAL OBSTRUCTION.

- | | | |
|--|--|---|
| INTESTINAL
OBSTRUCTION.
(2 varieties.) | { If of sudden origin it
may be due to | { <ol style="list-style-type: none"> 1. Foreign bodies. 2. Twisting of the intestine. 3. Intussuseption of the bowel. 4. Congenital stricture of the bowel. 5. Congenital malformation of the bowel. 6. Strangulation of the bowel by bands of lymph. 7. Strangulated hernia. 8. Entanglement of bowel with mesentery or omentum. |
| | { If of <i>slow</i> development, may result from | { <ol style="list-style-type: none"> 1. Malignant disease. 2. Impaction of fæces. 3. Abnormal concretions. 4. Pressure of tumors, abscess, etc. 5. Tubercular peritonitis. |

SYMPTOMS IN COMMON.

A *tumor* is usually detected in the abdomen. When due to impaction of fæces, this tumor *indents* on firm pressure.

Pain is usually a marked symptom; it is local, as a rule, and deep-seated.

Dulness on percussion exists often over the seat of pain, in case a tumor cannot be detected.

Obstinate constipation exists, which withstands all attempts at removal.

Vomiting is a marked symptom. When *stercoraceous* in character, it is a pathognomonic symptom. If occurring late in the attack it often indicates an obstruction low down in the bowel.

Distension of the abdomen from tympanitis. This condition is very marked when the *large* intestine is obstructed, but much less so if the *small* intestine be the seat of disease.

EXTERNAL HEMORRHOIDS. INTERNAL HEMORRHOIDS.

APPEARANCE OF TUMOR.

The tumor is smooth on its surface.

The tumor is partially covered with integument.

The tumor is seldom pediculated.

The tumor has often a granular surface.

The tumor is entirely covered with mucous membrane.

The tumor is usually pediculated.

SITUATION.

The tumor is always situated at the margin of the anus.

The tumor is attached to the walls of the rectum.

REDUCIBILITY.

The tumor always presents externally, but may often be evacuated by pressure or position.

The tumor can be replaced within the rectum and may remain replaced for days, weeks, or months.

DENSITY.

The tumor is firm in its texture.

The tumor is soft and often friable.

HEMORRHAGE.

Hemorrhage is infrequent and seldom severe in amount.

Hemorrhage often becomes excessive and is of frequent occurrence.

PAIN.

The pain is usually local and confined to the tumor.

The pain is usually of moderate severity and is often absent.

The pain is often conveyed to neighboring regions.

The pain is severe, as a rule, in case the tumor becomes externally apparent.

EXTERNAL HEMORRHOIDS. CONDYLOMATA OF THE ANUS.

SURFACE OF TUMOR.

The surface of the tumor is smooth.	The surface of the excrescences is of a warty appearance, resembling that of a strawberry.
-------------------------------------	--

NUMBER.

A solitary tumor is not uncommon.	The tumors are <i>multiple</i> , as a rule, with deep clefts between them.
-----------------------------------	--

SHAPE.

The tumors are round or oval.	The tumors are flat and broad.
-------------------------------	--------------------------------

DEVELOPMENT.

The development of the tumors is often very rapid.	The development of condylomata is usually slow.
--	---

DISCHARGE.

No discharge is present.	A profuse and irritating discharge exists.
--------------------------	--

HISTORY.

No venereal history is detected as a cause.	A venereal history often exists as a cause.
---	---

EFFECTS OF THE CONDITION OF THE BOWEL.

The tumor is often affected in its size and appearance by the condition of the bowel or causes affecting the portal circulation.	The tumors are independent of changes in the circulation of the rectum or liver.
--	--

INTERNAL HEMORRHOIDS.

RECTAL POLYPUS.

NUMBER OF TUMORS.

The tumors are usually multiple. A solitary tumor is most commonly present.

SIZE OF TUMORS.

The tumor is generally small. The tumor is usually large.

PEDICULATION.

The pedicle is indistinct or absent. The pedicle is marked.

RAPIDITY OF GROWTH.

Hemorrhoids often form with great rapidity. Polypus is usually of slow growth.

COLOR.

Hemorrhoids are usually of a violet color. The tumor is pale in color.

SURFACE.

The tumors are granular on their surface. The surface of the tumor is smooth.

AGE AFFECTED.

The young are rarely, if ever, affected. The young are frequently affected.

EFFECTS OF CONSTIPATION.

The condition of the bowels exerts a marked influence upon the size of the tumors. The size of rectal polypi is not affected by the condition of the bowels.

HEMORRHAGE.

Hemorrhage is frequent and often severe. Hemorrhage is infrequent, save when the vascular form of polypus is present.

RECTAL PROLAPSE.

RECTAL POLYPUS.

TUMOR.

The tumor is continuous all around the circumference of the rectum. The tumor is located upon one side of the rectum.

PEDICLE.

No pedicle to the protrusion can be detected. A pedicle is always easily detected.

STATE OF HEALTH.

This condition is most common in children with enfeebled constitutions. Occurs generally in healthy subjects.

HEMORRHAGE.

Hemorrhage is frequent but is moderate in its severity. Hemorrhage is infrequent, save when the polypus is of the vascular variety.

SYMPTOMS IN COMMON.

- Both occur chiefly in the young.
- “ are reducible within the bowel.
 - “ are not severely painful unless retained after protrusion.
 - “ are pale in color.
 - “ painless to direct touch.
 - “ sensitive to traction upon them.

CANCER OF THE RECTUM. STRICTURE OF THE RECTUM.

AGE AFFECTED.

Is rare in the young, but is common in advanced life.

May affect any age.

LOCATION AND CHARACTER.

It may be detected as a uniform infiltration around the rectum, or as nodular masses in its walls. It is common near the anus, and its surface is often friable.

The constriction is usually annular in character, and is seldom unilateral. It is most frequently detected about two inches from the anus, and it presents no abnormal condition of surface.

DEFECATION.

Defecation becomes difficult *early*, even before marked constriction exists, from loss of contractile power in the rectum.

Defecation becomes difficult *late* in the disease, as the rectal walls are normal in power.

PAIN.

A *violent burning, or boring* pain is present on defecation and often long after its completion.

Pain is often absent.

ABNORMAL SENSATIONS.

A sensation of a *foreign body* in the rectum is present.

No abnormal sensations exist in many typical cases.

HEALTH.

The general health is rapidly undermined.

The general health is *slowly* affected—if much altered.

DISCHARGE.

A slimy, fœtid, and often sanious discharge from the bowel exists.

No discharge is usually present.

SYMPTOMS IN COMMON.

Both are associated with interference with defecation.

“ “ “ “ diminished rectal calibre.

“ “ “ “ tympanitic distension of abdomen in advanced stages.

FISSURE OF THE ANUS. FISTULA OF THE RECTUM.

HISTORY.

Occurs most often in females, debilitated subjects, or in syphilis.	Occurs most often in men, and is preceded by a history of abscess.
---	--

PAIN.

The pain is <i>burning</i> in character.	Pain is often absent and, if present, is not severe in type. A sense of moisture and itching is however present from the excoriation due to the discharge.
“ “ exacerbatcs often during menstruation.	
“ “ is augmented by defecation.	
“ “ is often constant.	
“ “ is frequently not local but radiates to pelvis, back, thighs, etc., etc.	

SPHINCTER OF ANUS.

The sphincter is spasmodically contracted. The finger, if introduced into the rectum, causes great pain.	The sphincter ani muscle is not affected. The bowel can be easily and painlessly explored.
--	--

URINARY SYMPTOMS.

Retention of urine, painful micturition and other urinary symptoms of a reflex character are common.	Reflex urinary symptoms are seldom produced.
--	--

INSPECTION.

A fissure or a small ulcer can be detected at the margin of the anus, if carefully looked for, as it is often concealed by the rugæ.	Inspection of the perineum reveals either a papilla at the seat of the external opening of the fistula, or an orifice, which is often concealed by folds of the skin.
--	---

DISCHARGE.

No abnormal discharge from the fissure or ulcer occurs, sufficient to cause annoyance or notice.	A purulent or faecal discharge exists, causing irritation of the parts, staining the clothing, and generally having an offensive odor.
--	--

INDIRECT INGUINAL HERNIA.	DIRECT INGUINAL HERNIA.
------------------------------	-------------------------

SIZE OF TUMOR.	
----------------	--

The tumor is often very large.	The tumor is usually small in size.
--------------------------------	-------------------------------------

SHAPE OF TUMOR.	
-----------------	--

The tumor is usually flask-shaped.	The tumor is usually globular.
------------------------------------	--------------------------------

LOCATION.	
-----------	--

The tumor is frequently scrotal.	The tumor is seldom scrotal.
----------------------------------	------------------------------

PALPATION.	
------------	--

The tumor is usually an enterocele, and is therefore <i>soft</i> and <i>doughy</i> to the touch.	The tumor is usually omental, and is therefore hard.
--	--

PERCUSSION.	
-------------	--

Resonant percussion usually exists over the tumor.	Flatness on percussion over the tumor is frequent.
--	--

INGUINAL CANAL.	
-----------------	--

The inguinal canal is filled.	The inguinal canal is empty.
-------------------------------	------------------------------

SPERMATIC CORD.	
-----------------	--

The spermatic cord usually lies concealed <i>behind</i> the neck of the sac.	The spermatic cord can be detected at the <i>outside</i> of the neck, as a rule.
--	--

EPIGASTRIC ARTERY.	
--------------------	--

The pulsation of the deep epigastric artery is concealed.	The epigastric artery can be often felt to pulsate <i>outside</i> of the neck of the tumor.
---	---

REDUCTION.	
------------	--

The tumor is reduced by pressure <i>outwards</i> and <i>backwards</i> .	The tumor is reduced by pressure directly <i>backwards</i> .
---	--

SYMPTOMS IN COMMON.

Both are associated with a sudden advent.			
“	“	“	“
“	“	“	“
“	“	“	“
“	“	“	“
			an impulse on coughing.
			reducibility, as a rule.
			possible intestinal embarrassment.

SCROTAL HERNIA.

SARCOCELE.

PALPATION.

The tumor is soft and doughy to the touch. The tumor is usually hard and resistant.

WEIGHT.

The tumor is light. The tumor is heavy.

SURFACE.

The tumor is smooth and regular. The tumor is often nodular and irregular in outline.

PAIN.

The tumor is seldom painful, unless inflamed or strangulated. The tumor is frequently painful.

DEVELOPMENT.

The tumor is of sudden advent. The tumor grows slowly, as a rule.

PERCUSSION.

The percussion note over the tumor is usually resonant. The percussion note over the tumor is usually dull or flat.

INGUINAL CANAL.

The inguinal canal is usually filled. The inguinal canal is empty.

COUGH IMPULSE.

An impulse on coughing is present in the majority of cases. No impulse on coughing can be detected.

BOWEL.

The bowel is occasionally embarrassed. The bowel is never affected.

REDUCTION.

Reduction is accomplished by pressure *backwards* and *outwards*, unless the hernia is strangulated, incarcerated, or irreducible. The tumor is irreducible.

AUSCULTATION.

Gurgling may be detected. No auscultatory sounds are present.

SCROTAL HERNIA.

HYDROCELE OF TESTICLE.

SHAPE OF TUMOR.

The tumor is usually flask-shaped. The tumor is pyriform or ovoid.

DEVELOPMENT.

The tumor is usually of sudden advent ; and develops from above downwards. Develops slowly from below upwards.

PALPATION.

The tumor is soft and doughy to the touch, as a rule. The tumor is hard, tense and *elastic*.

FLUCTUATION.

Fluctuation is absent. Fluctuation is well marked.

TRANSLUCENCY.

The tumor is opaque. The tumor is translucent.

PERCUSSION.

Resonant percussion is present over the tumor. usually The percussion note over the tumor is dull or flat.

REDUCIBILITY.

The tumor is usually reducible. The tumor is never reducible.

SPERMATIC CORD.

The spermatic cord is usually concealed by the neck of tumor. The spermatic cord is neither concealed nor displaced.

INGUINAL CANAL.

The inguinal canal is filled, save when direct hernia enters the serotum. The inguinal canal is empty.

ASPIRATOR.

The effects of aspiration are negative. Fluid is withdrawn by aspiration or tapping.

BOWEL.

The action of the bowel may be embarrassed. The action of the bowel is unaffected.

SCROTAL HERNIA.

VARICOCELE.

PALPATION.

The tumor is usually smooth on its surface and regular in its outline. The tumor is knotty and irregular and feels like "a bag of worms."

COLOR OF TUMOR.

The tumor is of normal color. The tumor is bluish.

LOCATION.

May exist on either side. Most frequent on the left side.

EFFECT OF HEAT.

Negative. Tumor increases on the application of heat.

DEVELOPMENT.

The tumor develops suddenly. The development of the tumor is gradual.

PERCUSSION.

The percussive note is usually resonant. The percussive note is dull.

FLUCTUATION.

Fluctuation never exists. Fluctuation may exist if the vessels be very large.

SPERMATIC CORD.

The spermatic cord is concealed or displaced. The spermatic cord is not affected.

INGUINAL CANAL.

The inguinal canal is usually filled. The inguinal canal is uninvolved.

COUGH IMPULSE.

A cough impulse is usually detected. No impulse on coughing exists.

REDUCTION.

Reduction is accomplished usually by taxis only. Reduces often spontaneously by any position favoring increased venous return.

RETURN OF TUMOR.

The tumor, if once reduced, can be prevented from a return by pressure at the external ring. The tumor returns when the patient stands up, in spite of pressure at the ring.

SENSATION IN SCROTUM.

There is a sense of distension only, unless inflammation or strangulation exist. A sense of weight, and of constant dragging in the scrotum, exists.

SCROTAL HERNIA.

HEMATOCELE OF TESTIS.

ADVENT.

The advent of the tumor is sudden, and it grows from *above*, downwards.

The advent is sudden, if of traumatic origin; but if of spontaneous origin, the tumor may develop slowly. It grows from *below*, upwards.

FLUCTUATION.

Fluctuation is never present.

Fluctuation is always present until coagulation occurs.

PALPATION.

The tumor is soft and doughy.

The tumor is soft at first, but hard after coagulation occurs.

SHAPE.

The tumor is flask-shaped, unless due to direct hernia.

The tumor is pyriform in its shape.

INTEGUMENT.

Normal in color.

Echymotic.

REDUCIBILITY.

The tumor is usually reducible.

The tumor is irreducible.

PERCUSSION AND AUSCULTATION.

Percussion is usually resonant; gurgling may be also heard.

Percussion is dull or flat. Auscultation negative.

WEIGHT OF TUMOR.

The tumor is light in weight.

The tumor is heavy.

SPERMATIC CORD.

The spermatic cord is concealed or displaced.

The spermatic cord is unaffected.

INGUINAL CANAL.

The inguinal canal is usually filled.

The inguinal canal is empty.

CONSTITUTIONAL SYMPTOMS.

None, save when strangulation, or severe inflammation of the sac exists.

Pallor and great prostration are often present from the loss of blood.

BOWELS.

The action of the bowel may be embarrassed.

The bowels are unaffected.

INCOMPLETE INGUINAL HERNIA. BUBO.

PAIN.

The tumor is generally painless. The tumor is usually painful.

PALPATION.

The tumor is usually soft. The tumor is hard, at the onset.

FLUCTUATION.

Fluctuation is absent. Fluctuation is present if suppuration occurs.

LOCALITY.

The tumor is confined to limits of inguinal canal. The tumor is often diffused beyond the limits of the inguinal canal.

REDUCIBILITY.

Reduction is possible and often easy. Reduction is impossible.

OUTLINE OF TUMOR.

The outline of the tumor is often indistinct. The outline of the tumor is usually clearly defined.

ŒDEMA.

Œdema is absent, as a rule. Œdema is present, as a rule.

PERCUSSION.

Frequently resonant percussion exists. Dull percussion exists over the tumor.

COUGH IMPULSE.

A cough impulse is often detected. A cough impulse is usually absent.

HISTORY.

A history of muscular strain is usually present. A venereal origin is often detected.

BOWEL.

The bowel may be embarrassed in its action. The bowel is unaffected.

CONSTITUTIONAL SYMPTOMS.

Absent, unless strangulation, or inflammation of the sac, occurs. Frequent constitutional symptoms occur.

AUSCULTATION.

Gurgling may be detected. No gurgle will be heard.

BUBONOCELE.

UNDESCENDED TESTICLE.

PAIN.

The tumor is usually painless.

The tumor is very painful, and on pressure over it yields the peculiar sickening sensation which is characteristic of compression of the testicle.

SCROTUM.

Both testicles are present.

The testicle is found wanting upon the side corresponding to the tumor.

The scrotum is normal in development.

The scrotum is imperfectly developed on the same side.

REDUCTION.

Reduction of the tumor is associated with a gurgle.

Reduction may be impossible, but if not so, no gurgle accompanies its return to the abdomen.

BOWEL.

The action of the bowel may be embarrassed.

The bowel is unaffected.

SYMPTOMS IN COMMON.

Both are associated with a *small* tumor.

“	“	“	“	frequent reducibility.
“	may be	“	“	sudden advent.
“	“	“	“	impulse on coughing.
“	“	“	“	vomiting.

INGUINAL HERNIA.

IMPACTION OF FÆCES.

LOCATION OF TUMOR.

The tumor is felt only in the inguinal region.

The tumor may be felt at the *side*, as well as in the inguinal region.

DEVELOPMENT.

The tumor develops suddenly after some strain or injury.

The tumor develops slowly with previous colicky pains and from no apparent causation.

PERCUSSION.

The percussion note is usually resonant.

The percussion note over the tumor is flat.

EFFECTS OF PRESSURE.

Pressure causes no permanent change in the tumor unless it effects reduction.

Firm localized pressure over the tumor causes *indentation*.

SENSITIVENESS.

The tumor is not sensitive unless inflamed or strangulated.

The tumor is *always* tender on pressure in its advanced stages.

PAIN.

The tumor is usually *painless*.

The tumor is painful.

BOWEL.

The bowel *may* be unaffected.

Obstinate constipation always exists.

VOMITING.

Vomiting is absent if the hernia be not inflamed or strangulated.

Vomiting is usually present.

SYMPTOMS IN COMMON.

Both are associated with a tumor.

“ may be associated with obstinate constipation.

INGUINAL HERNIA.

HYDROCELE OF THE CORD.

LIMITS OF TUMOR.

The tumor is frequently scrotal,
and is generally diffused.

The tumor is circumscribed.

PALPATION.

The tumor is soft, as a rule.

The tumor is tense.

REDUCIBILITY.

The tumor reduces with a gurgle.

The tumor is usually irreducible,
but if not so no gurgle is present
on its reduction.

TRANSLUCENCY.

The tumor is opaque.

The tumor is often translucent.

FLUCTUATION.

The tumor does not fluctuate.

The tumor is fluctuant.

PERCUSSION.

The percussion note is resonant
over the tumor, as a rule.

The percussion note is dull over
the tumor.

BOWEL.

Intestinal embarrassment is often
present.

No intestinal embarrassment exists.

IMPULSE FROM TESTICLE.

Movements of the testicle have
no effect upon the tumor.

The testicle, if moved, transmits
an impulse to the tumor.

COUGH IMPULSE.

An impulse on coughing is frequently
felt in the tumor.

Impulse on coughing is absent.

AUSCULTATION.

Gurgling is often heard in the
tumor.

No gurgling is detected.

RETURN OF THE REDUCTION.

The tumor remains reduced if
the dorsal position is maintained.

The tumor returns after reduction
irrespective of position.

FEMORAL HERNIA.

ENLARGED GLANDS.

DEPTH OF TUMOR.

The tumor is often felt deep in the groin. The tumor is always superficial.

MOBILITY OF TUMOR.

The movements of the tumor are restricted. The tumor exhibits great mobility.

REDUCIBILITY.

The tumor is reducible by pressure downwards, backwards and upwards. The tumor is not reducible.

NUMBER OF TUMORS.

The tumor is always solitary. The tumor is seldom solitary.

FLUCTUATION.

Fluctuation is never present. Fluctuation is often detected within the tumor.

BOWEL.

Intestinal embarrassment is often present. No intestinal embarrassment is produced.

COUGH IMPULSE.

An impulse on coughing may often be detected on flexion and adduction of the thigh, with the body bent forwards. No impulse on coughing is detected.

AUSCULTATION.

Gurgling within the tumor is sometimes heard. No gurgling is ever perceived in the tumor.

HISTORY.

Is usually due to some severe muscular effort. A serofulous diathesis is often present.

PERCUSSION.

Resonant percussion may exist over the tumor, in some cases. The percussio note over the tumor is flat.

SEX.

Is rare in the male sex. Is equally frequent in both sexes.

FEMORAL HERNIA.

PSOAS ABSCESS.

FLUCTUATION.

The tumor never fluctuates.

The tumor often fluctuates, if superficial.

PERCUSSION.

The percussion note over the tumor may be resonant.

The tumor always yields a dull, or flat percussion note.

RELATION OF FEMORAL VESSELS.

The neck of the sac lies *internal* to the femoral artery.

The neck of the sac lies *external* to the femoral artery.

PAIN.

Pain is frequently absent.

A pain in the back or loins has always *preceded* the development of the tumor.

GENERAL HEALTH.

The general health is often normal.

The health is impaired.

HISTORY.

A severe muscular effort usually precedes the advent of the tumor.

A history of spinal disease or of pelvic affection exists.

BOWEL.

Intestinal derangement is often produced.

The bowel acts normally.

REDUCIBILITY.

Reduction occurs with a distinct and *sudden* disappearance of the tumor, usually with a gurgle.

The tumor disappears *gradually* under direct pressure, but no gurgle is perceived.

The reduction requires pressure *downwards, backwards* and *upwards*.

No absolute direction of pressure is required.

RETURN OF TUMOR.

The hernia remains reduced if the dorsal position is maintained.

The tumor returns as soon as the pressure is removed.

FEMORAL HERNIA.

VARIX OF SAPHENOUS VEIN.

SIZE AND DIRECTION OF TUMOR.

The tumor is usually *small*, and is directed *obliquely across thigh*. The tumor is variable in size, and lies in the *longitudinal axis* of the limb.

PALPATION.

The tumor is usually *hard* and tense, but may be *doughy*. The tumor is soft and often indistinctly fluctuant.

EFFECT OF HEAT.

The tumor is not affected by heat. The tumor is *increased* in size by heat.

SEX.

The tumor is most frequent in females. Is equally common in both sexes.

PERCUSSION.

Resonant percussion often exists. Flatness on percussion is present over tumor.

REDUCIBILITY.

Reduces with a sudden *slip* and a gurgle. Reduces gradually without any gurgle.
Is reduced by pressure directed *downwards, backwards* and *upwards*. Is reduced by direct pressure and a recumbent position.

RETURN AFTER REDUCTION.

The return is prevented when the patient is allowed to stand up, by pressure over the femoral ring. The tumor returns when the patient stands, in spite of pressure on the femoral ring.

BOWEL.

Intestinal embarrassment is not infrequent. No embarrassment of the function of the bowel is ever produced.

SKIN.

The skin is normal in color. The skin is often discolored over tumor.

COUGH IMPULSE.

May be detected by *flexion* and *adduction* of the thigh, with the *body bent forwards*. Is often absent but may exist.

FEMORAL HERNIA.

INGUINAL HERNIA.

SEX AFFECTED.

Is most common in females.

Is most frequent in males.

SIZE OF TUMOR.

Is usually a small tumor.

Is often very large.

SHAPE OF TUMOR.

Is usually round, or, if elongated, lies obliquely across the thigh.

Is flask-shaped and, if elongated, is often scrotal in its situation.

PERCUSSION.

The tumor gives *frequently* a dull note on percussion.

Resonant percussion is usually present.

LOCATION OF NECK OF SAC.

The neck is felt below Poupart's ligament.

The neck lies above Poupart's ligament.

RELATION OF SPERMATIC CORD.

The cord is felt *internal* and *in front* of the neck of the sac.

The cord is felt *external* to, and *behind* the neck of the sac.

SCROTUM AND LABIA.

The tumor never enters the scrotum or the labia.

The tumor often enters the scrotum and the labia.

FEMORAL PULSATION.

Femoral pulsation can be felt *external* to the neck of the tumor when the finger is introduced into the canal.

The finger when pushed into the canal of the tumor fails to detect any pulsation.

SPINE OF THE PUBES.

The spine of the pubes can be felt to lie *internal* to the neck of the sac.

The spine of the pubes can be detected *externally* to the neck of the sac.

FEMORAL HERNIA.

LIPOMA OF FEMORAL
CANAL.

DENSITY OF TUMOR.

The tumor is often hard.

The tumor is always *doughy* to the touch.

OUTLINE OF TUMOR.

The tumor is small and well defined in its outline.

The tumor is not well defined in its outline.

PERCUSSION.

Resonant percussion may exist over the tumor.

The tumor yields a dull percus-
sion note.

ADVENT.

The tumor usually appears sud-
denly.

The tumor develops slowly.

REDUCIBILITY.

The tumor is usually reducible.

The tumor is irreducible.

COUGH IMPULSE.

An impulse on coughing can often be detected by flexion and ad-
duction of the thigh, with the body bent forwards.

An impulse is never present within the tumor, on coughing.

BOWEL.

Intestinal embarrassment is not infrequent.

The bowel is not affected.

SYMPTOMS IN COMMON.

Both are associated with a tumor	in the upper part of the thigh.
“ “ “ “ “	inside of the femoral vessels.
“ “ “ “ “	external to the pubic spine.
“ “ “ “ “	below the spine of the pubes.

VENTRAL HERNIA.

UMBILICAL HERNIA
(OMPHALOCELE ; EXOMPHALOS).

ADVENT.

The tumor is never congenital.

The tumor is often congenital.

AGE.

The tumor may occur at any age.

The tumor is frequent in infants.

APPEARANCE OF TUMOR.

The tumor has a well-defined
neck.The tumor usually has no appa-
rent neck, but consists of a simple
bulging at the navel, which is usu-
ally spherical in its outline.

NAVEL.

The navel is present and in its
normal situation.The navel is absent, as the tumor
supplies its place.

PALPATION.

The edges of an opening or fis-
sure in the abdominal walls can
often be detected.No unnatural opening can be de-
tected.

REDUCIBILITY.

Reduction of the protrusion is
often somewhat difficult.Reduction is effected by mere
pressure upon the protrusion.

HISTORY.

A previous history of traumatism,
abscess, or weakening of the abdo-
minal walls, is present.The history of traumatism or ab-
scess is seldom present.

THYROID HERNIA.

PERINEAL HERNIA.

SEX AFFECTED.

The tumor seldom occurs in the male sex ; when small it may often be impossible to detect its presence.	Is a rare disease ; but it affects both sexes equally, and is easily detected when present.
---	---

LOCATION.

A tumor appears in the thigh near the inferior commissure of the vulva.	A tumor appears in the perineum above the rectum.
---	---

NECK OF TUMOR.

The neck of the tumor can be felt from the outside of the body, in the old and the emaciated. In obscure cases a vaginal or rectal exploration is often required to detect the situation of the neck of the tumor.	A neck to the tumor is not discernible, unless the protrusion is very extensive and involves the perineum. The question of origin is, however, easily decided if the tumor be pronounced.
--	---

SYMPTOMS IN COMMON.

Both	are	associated	with	a	tumor	of	sudden	advent.
“	“	“	“	“	“	“	“	resonant percussion.
“	“	“	“	“	“	“	“	reducibility.
“	“	“	“	“	“	“	“	impulse on coughing, as a rule.
“	“	“	“	“	“	“	“	possible intestinal embarrassment.

DIAPHRAGMATIC HERNIA.

MEDIASTINAL TUMORS.

PERCUSSION.

Tympanitic percussion, or a localized dulness *low* down in the mediastinum or thorax is present, if a hernial protrusion occurs through the diaphragm and is superficial.

Mediastinal tumors are usually situated *high up* in the thorax, as shown by a localized *dulness* on percussion.

AUSCULTATION.

A gurgling sound is often heard over the seat of the tumor.

No auscultatory signs exist, except in case of aneurism, when a bruit will be detected.

ADVENT.

The patient is conscious of the sudden advent of the protrusion into the thorax.

The tumor develops without any marked or sudden symptoms till its size creates pressure.

BOWEL.

Intestinal embarrassment is liable to exist.

The bowel is unaffected.

THIRST.

Extreme thirst is liable to be present.

Extreme thirst is absent.

PERITONITIS.

Symptoms of peritonitis occur rapidly after the appearance of the tumor, if it be strangulated.

No peritoneal symptoms are ever produced.

CONGENITAL HERNIA.

HYDROCELE.

AGE AFFECTED.

Is usually a disease of infant life ; but, if once present, subsequent attacks in adult life may occur.

May affect any age ; and, if in adults, is not necessarily associated with a history of a previous attack.

FLUCTUATION.

The tumor is usually fluctuant at its *upper* portion as the peritoneal effusion gravitates into the sac.

The tumor is markedly fluctuant in all of its localities.

TRANSLUCENCY.

The tumor *may* be translucent.

The tumor is *always* translucent.

PEDICLE.

The tumor has a marked pedicle.

The tumor is not pediculated.

SHAPE OF TUMOR.

The tumor is globular.

The tumor is pyriform.

DEVELOPMENT.

The tumor *may* be of sudden occurrence, or may show sudden and rapid increase in its size when once developed.

The tumor always develops *slowly* and gradually.

INGUINAL CANAL.

The inguinal canal is either distended or involved.

The inguinal canal is empty.

REDUCIBILITY.

The fluid portion, when reduced by taxis or pressure, leaves a previously concealed testicle which also reduces with a marked gurgle and occasions a peculiar *sickening sensation* during its passage through the inguinal canal.

The tumor cannot be reduced.

CONGENITAL HERNIA.

INFANTILE HERNIA.

ADVENT.

Occurs before the cavity of the tunica vaginalis has closed after the descent of the testicle.	Occurs after the closure of the tunica vaginalis.
--	---

FLUCTUATION.

Fluctuation exists at the upper portion of the tumor from gravitation of the peritoneal fluid into the sac.	Fluctuation is absent.
---	------------------------

TRANSLUCENCY.

The tumor is frequently translucent at the upper portion of the sac.	The tumor is not translucent.
--	-------------------------------

REDUCTION OF TUMOR.

The reduction of the fluid contents and the intestinal portion of the tumor leaves the testicle apparent, which also reduces with a gurgle and marked pain.	The reduction of the tumor leaves the testicle <i>irreducible</i> .
---	---

AGE AFFECTED.

Never affects adults unless a previous attack has existed in infancy.	Is most common in infancy, but <i>may</i> occur at any age from an abnormal condition of the parts.
---	---

DISEASES OF TISSUES.

DISEASES OF TISSUES.

I SHALL consider diseases of tissues in the following order :

A. INFLAMMATORY CONDITIONS OF TISSUE.

Under which head may be enumerated

1. TUMEFACTION. Tumefaction of tissue always accompanies severe forms of inflammatory processes. It is due to the excessive supply of blood furnished by the dilated capillary vessels, and frequently to an accompanying œdema of the inflamed tissues. It is associated with local pain and tenderness to the touch, as a rule, and is characterized also by a local and, possibly, a general rise in temperature.

2. INDURATION. Induration of tissue depends upon an abnormal connective-tissue cell-growth and its organization and development into new tissue.

It is the associate of chronic or sub-acute inflammatory processes, as a rule, since, in the *acute* form, the new cell-growth is often too rapid to undergo organization, and suppuration follows.

Inflammatory indurations of tissue are usually unassociated with pain or local symptoms after the cause has disappeared, and are slowly removed by nature, in the majority of instances, through a process of fatty degeneration and absorption. A diagnosis is therefore made from its mode of origin and gradual disappearance.

3. SUPPURATION OF TISSUE. Suppuration of tissues may accompany superficial ulcerative or granulative processes, or may be, in itself, a circumscribed process of destruction of tissue. In the former conditions pus is an unimportant element, but in the latter it occasions marked and peculiar symptoms, and has received a special nomenclature.

Circumscribed pus may exist as *acute* or *chronic abscess*, *furuncle*, *anthrax*, *suppurative inflammation of glands and organs*, and as a symptom of *pyæmia*.

It frequently results in the formation of *sinuses* and *fistulæ*, when the source of irritation remains, as in caries, necrosis, foreign bodies, etc., etc.

The *character* of pus is liable to variations, and separate names have been given the most common varieties. Thus *healthy* or *laudable*, *ichorous*, *sanious*, *curdy*, *muco-pus*, and *sero-pus* are terms most frequently used to express the existing condition and appearance of the discharge.

Suppuration, if circumscribed and retained within tissue, yields both local and constitutional symptoms.

The local symptoms are the development of a tumor, which is at first hard, but afterwards soft or fluctuant, and a change in the skin, which often becomes red, shiny and œdematous if the suppuration be near the surface.

The constitutional symptoms are chills, fever, and elevation of the pulse, followed by *hectic* and exhaustion, if the suppuration be extensive.

4. **ULCERATION OF TISSUE.** By an *ulcer* is meant a superficial solution of continuity of soft tissues, dependent upon *molecular* death. The process of ulceration can never occur *within* the substance of any tissue; it is essentially a condition of the surface. Ulceration may affect the *cutaneous* and *mucous surfaces* of the body, the *lining coat of the blood-vessels* and *serous membranes*.

Ulceration may be the result of, 1. *Enfeebled circulation* or *defective nutrition* from lack of blood, as exists in newly formed cicatrices, the lower limbs in the aged, the alæ of the nose, and the cornea of the poorly nourished. 2. In *specific diseases*, as in scurvy, scrofula, some forms of syphilis, lupus, etc., etc. 3. In *direct inflammation* of an intense character, as in severe mechanical injury, the application of a chemical irritant or long-continued pressure upon a circumscribed locality producing injury to the surface. 4. *Abnormal blood conditions*, independent of congenital or acquired diathesis, may tend

to excite ulceration of the serous lining of the blood-vessels and other serous structures.

Ulcers may be classified as *healthy, weak, indolent, irritable, hemorrhagic, inflamed, varicose, and phagedenic*. The appearance of the edges of the ulcer and of the granulations upon its surface will characterize the first six of these, while the history of origin and rapidity of development by sloughing will render the other two obvious.

B. GANGRENE OF TISSUE. A condition dependent upon an absolute and permanent *arrest of nutrition* to some local part of the body, provided that part retains to a greater or less degree its external form and anatomical characters, is termed "gangrene."

The appearance of the affected part depends upon its previous vascularity, its solidity of structure, the cause and rapidity of the gangrenous process, and the presence or absence of exposure to the air.

Gangrene may be divided into moist, dry, and hospital gangrene, on the basis of its appearance and origin. Of these, the first depends upon *obstructed venous return*; the second upon *impaired arterial supply*; the third upon some epidemic poison causing a tendency to phagedæna.

Gangrene may result from local violence, excessive heat or cold, escharotics, inflammatory congestion and œdema, embolism, thrombosis, ligature of vessels, pressure of tumors, abnormal blood conditions, as in uræmia, fevers, etc., etc., old age, atheroma, and in severe malarial affections in children. Gangrene also follows excessive doses of ergot and phosphorus, and the inoculation of farcy, or glanders poison.

Its symptoms depend upon its variety. In the dry form of gangrene, a simple withering and mummifying process occurs. In the moist variety, the part becomes dark, soft and infiltrated with gases from decomposition, causing an emphysematous crackling if pressure be made upon the part affected. It is characterized by blebs upon its surface, is offensive in odor, and finally separation of the *sphacelus* or *slough* occurs.

In hospital gangrene, a phagedenic process commences within a wound and symptoms of pyæmia often rapidly follow. It is markedly contagious and usually fatal.

C. ERYSIPELAS. Erysipelas is a diffuse inflammation of the skin, mucous, or serous membranes, which rapidly spreads over large surfaces, and is accompanied with febrile movement.

It is, clinically, of three varieties: 1. *Cutaneous* erysipelas, where only the superficial portions of the skin are involved. 2. *Phlegmonous* erysipelas, where the subcutaneous cellular tissue is affected as well as the derma. 3. *Internal* erysipelas, where serous or mucous membranes are involved.

The face is the most frequent seat of the cutaneous form. It commences usually with a chill, rise in temperature to 103° – 104° , nausea or vomiting, and frequent stupor or delirium.

The face becomes reddened and œdematous, the features distorted by swelling, and the eyes closed from œdema when the lids are implicated.

The constitutional symptoms increase with the advance of the disease and terminate with its abatement, in from eight to twelve days. As the skin grows pale, it becomes scaly, abscesses or boils frequently occur, and the beard falls out but subsequently returns.

Erysipelas occurs most in the spring and fall of the year. It may follow absorption of poisonous matter by the lymphatics, and frequently accompanies suppuration, when occurring within the body. It occurs in the debilitated, and in those addicted to alcohol, especially when subjected to injury. It is claimed that diabetes and Bright's disease predispose to it, and it has by no means been proven to be non-contagious. It is a frequent complication of wounds, especially those of the head and hands.

The phlegmonous form occurs most often in the legs. It is associated with great tension of the affected part, subsequent sloughing of the skin, and exhaustive suppuration. Its duration depends on its severity.

D. ELEPHANTIASIS ARABUM.—“*Barbadoes Leg* ;” “*Pachydermia*.” Elephantiasis consists of a hypertrophy of all the structures of which the integumentary covering of the body is composed. The epidermis becomes thickened, roughened as in *ichthyosis*, and intersected with

fissures. The chorion is increased in thickness, and the subcutaneous connective tissue is infiltrated with a gelatinous material, which oozes out on section of the skin, and quickly coagulates. This disease is due largely to an engorgement of the *lymphatic* vessels. It begins as an erysipelas with an œdematous swelling of the lymphatic glands, or as an eczema, phlebitis, or lymphangitis.

Elephantiasis may affect the feet, legs, scrotum, penis, labia and clitoris. The size of the affected part often becomes immense. This disease is essentially one of hot climates. It is endemic in the East Indies, Syria, Japan, Egypt, the Barbadoes, and occasionally on the continents of Europe and America. It seldom begins before puberty, and is most frequent in males. It is sometimes hereditary. The absence of luxuriant vegetation seems to favor its development.

When the scrotum becomes affected, as it frequently does, either independently, or when a similar condition of the leg exists, the penis is usually drawn into the tumor, as it enlarges, and becomes lost to view.

The disease exerts little, if any, influence upon the general health. Patients live for years, burdened with the weight of the growing tumor, without impairment of any vital function. In advanced stages of the disease, obstinate ulcers often form upon the affected parts, or abscesses and even gangrene occur. An acute attack of erysipelas occasionally acts as a cause of death in these cases.

E. LUPUS.—“*Lupoid Ulceration* ;” “*Lupus Vulgaris.*” This disease attacks the face, nose, cheeks, ears, buttocks and extremities. The trunk is rarely affected.

It is also frequently found in the mucous membrane of the lips, hard palate, and throat. It begins as a brownish-red spot, which varies in size from that of a pin's head, to a pea, and which subsequently becomes papular, or elevated, with a frequent increase in its size. This papule next undergoes cell infiltration and becomes nodular in appearance, and in a more advanced stage leads to the formation of an ulcer, through fatty degeneration or molecular destruction of tissue.

The ravages of this ulcerative stage are often terribly severe and associated with marked deformity.

This disease occurs often in children, even as early as three years of age, but it requires at this early age several years to develop. It makes the most rapid strides during puberty.

As it occurs most often upon the face, especially about the nose and mouth, ectropion, or eversion of the eyelid, not infrequently occurs from contraction of the tissues of the cheek.

Epithelial cancer is sometimes developed from lupus after that disease has lasted for years.

The cause of lupus is unknown. It does not develop as rapidly as syphilides, and is often present where the parents are not diseased. It fails also to respond to specific treatment. It is sometimes associated with scrofulous glandular enlargements.

In the preceding pages I have hastily enumerated those changes in tissues, exclusive of tumors, which are most liable to be of surgical interest and value. I have avoided lengthy explanations of pathological processes, but have been forced to enter somewhat into their etiology, as it has a direct bearing upon the subject, which seems, to my mind, sufficient to demand it. I have arranged in the form of diagnostic tables the various forms of abscess, which are frequently encountered, and the diseases with which they are most liable to be confounded. I have also added as a guide to memory differential tables between dry gangrene and moist gangrene, and cutaneous and phlegmonous erysipelas.

ANTHRAX (CARBUNCLE).

FURUNCLE (BOIL).

AGE AFFECTED.

Occurs during or after *middle* life. Occurs at any age.

LOCATION.

Occurs in cellular tissue which is largely supplied with vessels. It is chiefly developed on the *posterior surface* of the trunk, and is seldom present upon the extremities. May occur in any locality.

SHAPE OF TUMOR.

The tumor is elevated, but has a *flat* surface. The tumor is usually *conical* in shape.

POINTING.

The tumor never points. The tumor points rapidly.

METHOD OF EVACUATION.

The tumor opens at several places and becomes honey-combed in appearance. The tumor bursts at one spot only, as a rule.

CONTENTS EVACUATED.

The discharge of pus occurs, and long glistening shreds of dead connective tissue subsequently protrude. The contents of the tumor are chiefly pus.

BASE OF TUMOR.

The base is deeply indurated. The base is little indurated and the outline of the tumor is indistinctly circumscribed.

CONSTITUTIONAL EFFECTS.

The effects upon the constitution are severe and often alarming. The constitutional effects are slight in degree, or absent.

RESULTS.

Is not infrequently fatal. Is seldom, if ever, fatal.

ABSCESS.

LOCAL ŒDEMA,
if circumscribed.

PAIN.

The pain is markedly increased
by pressure.Pain on pressure is slight or ab-
sent.

PALPATION.

The tumor is hard at its circum-
ference, but is soft or elastic in its
centre.The tumor is of uniform consis-
tence throughout.

FLUCTUATION.

The tumor fluctuates as suppara-
tion advances.

The tumor never fluctuates.

CHILLS.

Rigors are often present if the
suppuration be extensive.Chills are absent, unless some
complication exists.*SYMPTOMS IN COMMON.*

Both may be associated with pain.

“	“	“	“	redness of the skin.
“	“	“	“	marked local swelling.
“	“	“	“	elevation of local temperature.
“	“	“	“	constitutional disturbance.

ACUTE ABSCESS.

CHRONIC OR COLD ABSCESS.

AGE AFFECTED.

May occur at any age.

Is most common in the young.

HEALTH.

Often affects the healthy.

Occurs in the debilitated, especially in those of scrofulous or lymphatic temperaments.

POINTING.

The tumor points rapidly.

The tumor points very slowly.

TEMPERATURE.

The temperature of the body is often markedly elevated.

The general temperature is nearly normal.

PULSE.

The pulse is usually increased.

The pulse is usually normal.

SKIN.

The integument over the tumor is usually red, œdematous and adherent to the surrounding parts.

The skin is usually pale and seldom œdematous or adherent.

SIZE OF TUMOR.

The tumor is seldom very large.

The tumor is often immense in size.

SYMPTOMS IN COMMON.

Both are associated with an abnormal tumor.

“ “ “ “ fluctuation.

“ “ “ “ a detection of pus by the aspirator or exploring needle.

“ “ “ “ pointing.

ILIAC ABSCESS.

ABSCESS OF ABDOMINAL
WALL.

ORIGIN.

Follows parturition, instrumental delivery, or puerperal fever.

Is usually independent of parturition.

PAIN.

The pain is often very severe and is accompanied, frequently, with rigors.

Pain is often not markedly severe nor are constitutional symptoms so frequently present.

SITUATION OF TUMOR.

The tumor lies *deep* in the iliac fossa.

The tumor is *superficially* located.

INTEGUMENT.

The skin is involved *late*, if ever.

The skin is involved early in the disease.

MOBILITY OF TUMOR.

The tumor is *immovable* and hard at its commencement.

The tumor allows of slight movement with the abdominal walls.

RECTAL AND VAGINAL EXAMINATION.

The tumor is definitely located by a rectal and vaginal examination, or by conjoined manipulation.

The tumor cannot be detected through the vagina or rectum.

BLADDER AND RECTUM.

The bladder, and often the rectum is affected by pressure of the tumor.

The bladder and rectum are not affected.

DIRECTION OF ESCAPE OF PUS.

The pus may be evacuated through the vagina, uterus, bowel, bladder, skin of the thigh, through the sciatic notch appearing upon the buttock, or into the peritoneal cavity.

The pus is usually evacuated directly through the integument over the seat of the tumor.

PSOAS ABSCESS.

FEMORAL HERNIA.

SITUATION OF THE TUMOR.

The tumor, if in the thigh, lies *outside* of the femoral vessels.

The tumor lies *inside* of the femoral vessels.

PERCUSSION.

The percussion note over the tumor is dull.

Resonant percussion over the tumor *may* exist.

PAIN.

A pain in the back or loins has always preceded the development of the tumor.

The tumor may be unassociated with pain.

FLUCTUATION.

The tumor is fluctuant, if superficial.

The tumor never fluctuates.

HISTORY.

The tumor is preceded by a history of spinal disease, or of a pelvic affection.

The tumor follows some severe muscular strain, as a rule.

BOWEL.

No intestinal embarrassment is present.

The intestinal function is often interfered with.

GENERAL HEALTH.

The general health is impaired.

The general health may be normal.

REDUCIBILITY.

The tumor reduces under direct pressure, but no gurgle on reduction is perceived.

The tumor is reduced by pressure *downwards, backwards* and *upwards*, and a gurgle is detected as the tumor disappears.

TENDENCY TO RETURN.

The tumor returns when pressure is removed.

The tumor will not return, as a rule, as long as a recumbent position is maintained.

ABCESS OF ABDOMINAL
WALLS.

ENLARGED SPLEEN.

SITUATION.

The tumor is superficial.

The tumor is deeply situated.

MOBILITY.

The tumor is only slightly movable.

The tumor is freely movable.

PRESSURE.

The tumor is sensitive to pressure.

The tumor is not sensitive to pressure.

FLUCTUATION.

Fluctuation appears as the disease advances.

Fluctuation is always absent.

PAIN.

The pain is local and constant.

No pain exists, as a rule.

TEMPERATURE AND PULSE.

The temperature and the pulse are usually increased.

The temperature and pulse *may* be affected if malarial enlargement exists.

RIGORS.

Chills may be present.

Chills are absent, save in malaria.

HISTORY.

A history of contusion, or of some exciting cause exists.

The tumor develops without any apparent causation.

INTEGUMENT.

The skin is usually involved and becomes red and œdematous, as pointing takes place.

The integument is normal in its appearance.

MOIST GANGRENE.

DRY GANGRENE.

ETIOLOGY.

A condition of obstructed *venous* return is present, as a rule, although abnormal blood conditions as produced by fevers, uræmia, farey, etc., etc., may excite this form of gangrene.

A condition of impaired *arterial* supply exists, which is dependent upon atheroma, embolism, pressure upon the vessels, ligature, old age, ergot poisoning, etc.

APPEARANCE OF AFFECTED PART.

The diseased part is dark in color, soft, often *emphysematous* from gases due to decomposition, dotted with blebs upon its surface and of offensive odor.

The affected part undergoes a process of desiccation, becoming, in time, shrivelled and mummified without odor or decomposition.

CONSTITUTIONAL EFFECT.

Septicæmia is often produced by absorption of the decomposing animal material by the lymphatic vessels.

Blood poisoning, as evidenced by pyæmic or septicæmic symptoms, is infrequent.

PROGRESS.

The disease progresses rapidly, as a rule.

The disease is frequently of long duration.

SYMPTOMS IN COMMON.

Both are associated with	<i>diminished temperature</i>	in the affected part.
“ “ “ “	diminished sensibility	“ “ “
“ “ “ “	altered color	“ “ “
“ “ “ “	spontaneous separation of the	“ “ “

CUTANEOUS ERYSIPELAS. PHLEGMONOUS ERYSIPELAS.

ORIGIN.

Is usually of idiopathic origin.

Is generally the result of injuries penetrating to the cellular tissue.

SKIN.

The skin is uniform in its redness when the erythema is fully developed.

The color of the skin is not uniform at the onset, but is usually darker at the centre.

SWELLING.

Swelling may often be absent or slight in amount, but when extensive pitting on pressure exists.

A swelling is marked from the onset which at first pits on pressure, but the skin soon becomes too tense to admit of pitting.

PAIN.

A tingling and itching pain is at first experienced, which subsequently becomes of a smarting character.

A burning and often a severe pulsating pain is present at the onset which lasts till the *tension* is relieved.

SUPPURATION.

Suppuration is seldom produced, the attack subsiding with desquamation of the cuticle.

Suppuration forms on the seventh or eighth day, and is preceded by softening of the affected part, return of pitting on pressure and a sense of fluctuation.

SLOUGHING.

Sloughing is rarely, if ever, produced.

Sloughing of the skin rapidly follows unless the tension is relieved and the pus evacuated. The wound being afterwards characterized by the protrusion of dead connective tissue in the form of white glistening shreds.

TERMINATION.

Is usually associated with a good prognosis unless the meninges become affected.

Frequently kills by exhaustion, if extensive, or by blood poisoning.

TUMORS.

TUMORS may be of two great classes, *fluid* and *solid*; the former are called cysts or cystic tumors; the latter are usually named and classified on a basis of their anatomical construction, as revealed by microscopical examination. Solid tumors comprise both inflammatory and non-inflammatory growths, although that term is more properly applied to new formations independent of a purely inflammatory origin.

The qualities which chiefly tend to characterize true tumors from other growths, are

1. A decided tendency to *continuously increase*.
2. An *inherent nutritive activity*, independent of the surrounding tissues.

In attempting to classify tumors, I am led to follow the arrangement of T. Henry Green, of London, as it seems to me more clearly to elucidate this obscure subject than any other classification with which I am acquainted, and combines both simplicity of language with clearness of expression.

Solid tumors may be divided then into three great types: 1. Those of the type of *connective tissue*, in which the stroma of the tumor is usually in excess of the cell element, and the cells are those of the type of normal connective tissue. 2. Those of the type of *higher tissues*, as muscle, nerves, and blood-vessels; and 3. Those of the type of *epithelial structures*, as represented by glandular tumors, cancer, and papillomata. The following table will clearly explain this classification:

SOLID TUMORS.	Tumors of the <i>connective tissue</i> type :	Fully developed connective tissue.	}	" <i>Fibroma.</i> "
		Embryonic connective tissue (SARCOMA).	{	<i>Fibro-Plastic.</i> " <i>Recurrent.</i> " <i>Nucleated.</i> <i>Myeloid.</i> <i>Glioma.</i>
		Granulation tissue.	{	<i>Psamomma.</i> <i>Gummata.</i> <i>Lupus.</i> <i>Glanders.</i>
		Mucous tissue.		<i>Myxoma.</i>
		Adipose tissue.		<i>Lipoma.</i>
		Cartilage tissue.		<i>Enchondroma.</i>
		Lymphatic tissue.	{	<i>Lymphoma.</i> <i>Leukæmia.</i> <i>Tubercle.</i>
	Bone tissue.		<i>Osteoma.</i>	
	Tumors of the <i>higher tissue</i> type :	Type of muscle.	}	<i>Myoma.</i>
		" " nerve.		<i>Neuroma.</i>
		" " blood-vessels.		<i>Angioma.</i>
	Tumors of the <i>epithelial</i> type :	Papillomata ; growing from	{	<i>Cutaneous surface.</i> <i>Mucous</i> " <i>Serous</i> "
		Adenoma.		<i>Glandular tumors.</i>
Carcinoma.		{	<i>Seirrhus.</i> <i>Encephaloid.</i> <i>Epithelioma.</i> <i>Colloid.</i>	

Cystic tumors may also be divided into two great classes with their subdivisions, as shown in the following table, in which not only the varieties of cysts are enumerated, but the mechanism of their formation is also clearly explained.

CYSTIC TUMORS.

<p>A. Cysts formed in <i>preëxisting</i> cavities.</p>	}	RETENTION CYSTS ; (due to <i>obstructed escape</i> of secretion).	<table border="0"> <tr> <td style="vertical-align: middle;">Sebacous cysts.</td> <td style="font-size: 2em;">{</td> <td>True sebaceous tumors. Comedones. Atheromatous tumors.</td> </tr> <tr> <td style="vertical-align: middle;">Mucous cysts.</td> <td style="font-size: 2em;">{</td> <td>Occur only in mucous follicles.</td> </tr> </table>	Sebacous cysts.	{	True sebaceous tumors. Comedones. Atheromatous tumors.	Mucous cysts.	{	Occur only in mucous follicles.
		Sebacous cysts.	{	True sebaceous tumors. Comedones. Atheromatous tumors.					
		Mucous cysts.	{	Occur only in mucous follicles.					
		Cysts in or- gans or glands.	{	Ranula, due to occlusion of salivary ducts. Encysted hydrocele, due to occlusion of tubuli testis. Mammary cysts, due to occlusion of lacteal ducts. Simple cysts of the ovary, due to di- latation of Graafian follicle. Compound cysts of the ovary, due to dilatation of Graafian follicle. Cysts of the liver, due to occlusion of ducts. Cysts of the kidney, due to occlusion of tubes.					
		EXUDATIVE CYSTS ; (due to excessive secre- tion).	<table border="0"> <tr> <td style="vertical-align: middle;">Bursæ. Ganglia. Hydrocele. Cysts of broad ligament.</td> <td style="font-size: 2em;">{</td> </tr> </table>	Bursæ. Ganglia. Hydrocele. Cysts of broad ligament.	{				
Bursæ. Ganglia. Hydrocele. Cysts of broad ligament.	{								
EXTRAVASATION CYSTS ; (due to hemorrhage into closed cavi- ties).	<table border="0"> <tr> <td style="vertical-align: middle;">Hæmatocele. Sanguineous tumors.</td> <td style="font-size: 2em;">{</td> </tr> </table>	Hæmatocele. Sanguineous tumors.	{						
Hæmatocele. Sanguineous tumors.	{								
Cysts due to <i>softening</i> of tis- sues in the cen- tre of tumors, as in	<table border="0"> <tr> <td style="vertical-align: middle;">Lipoma. Enchondroma. Sarcoma.</td> <td style="font-size: 2em;">{</td> </tr> </table>	Lipoma. Enchondroma. Sarcoma.	{						
Lipoma. Enchondroma. Sarcoma.	{								
<p>B. Cysts formed in sacs of <i>inde- pendent ori- gin</i>.</p>	}	Cysts due to <i>ex- pansion</i> and <i>fu- sion</i> of the spaces in connective tissue.	<table border="0"> <tr> <td style="vertical-align: middle;">New bursæ. Serous cysts of the neck. Compound ovarian cysts.</td> <td style="font-size: 2em;">{</td> </tr> </table>	New bursæ. Serous cysts of the neck. Compound ovarian cysts.	{				
		New bursæ. Serous cysts of the neck. Compound ovarian cysts.	{						
		Cysts formed around <i>foreign bodies</i> .	<table border="0"> <tr> <td style="vertical-align: middle;">Parasites. Extravasated blood. Bullets, etc., etc.</td> <td style="font-size: 2em;">{</td> </tr> </table>	Parasites. Extravasated blood. Bullets, etc., etc.	{				
Parasites. Extravasated blood. Bullets, etc., etc.	{								
<i>Congenital</i> Cysts.	<table border="0"> <tr> <td style="vertical-align: middle;">Frequently resulting from a blighted ovum. They often contain hair, bones, teeth, etc., etc.</td> <td style="font-size: 2em;">{</td> </tr> </table>	Frequently resulting from a blighted ovum. They often contain hair, bones, teeth, etc., etc.	{						
Frequently resulting from a blighted ovum. They often contain hair, bones, teeth, etc., etc.	{								

Tumors may be again classified on the basis of *location* as follows :

A.
TUMORS OF THE
HEAD.

<i>Brain.</i>	{	Cysts. Glioma. Myxoma. Lipoma. Carcinoma. Psammoma. Gummata. Cholesteatoma. Tubercle. Hydatids.
<i>Scalp.</i>	{	Lipoma. Sebaceous. Vascular.
<i>Orbit.</i>	{	Glioma. Myxoma. Cystic. Osteoma. Medullary Cancer.
<i>Antrum.</i>	{	Cystic. Erectile. Osseous. Fibroid. Enchondroma. Lipoma. Encephaloid.
<i>Gums.</i>	{	Cystic. Fibrous. Carcinoma. Myeloid.
<i>Lips.</i>	{	Cystic. Epithelioma. Lupus.
<i>Tongue.</i>	{	Cystic. Fibroid. Gummata. Epithelioma. Encephaloid.
<i>Jaws.</i>	{	Cystic. Fibroid. Myeloid. Osteoma.

B.
TUMORS OF THE
NECK.

<i>Vessels.</i>	{ Encysted Aneurism. Diffuse “
<i>Muscles.</i>	{ Cystic. Lipoma. Myoma.
<i>Parotid Gland.</i>	{ Cystic. Fibrous. Enchondroma. Hypertrophy. Abscess. Cancer.
<i>Thyroid Gland.</i>	{ Cystic. Hypertrophy. Encephaloid.
<i>Lymphatic Glands.</i>	{ Lipoma. Hypertrophy. Abscess. Syphilitic Induration. Tuberculous “ Cancer.
<i>Integument.</i>	{ Fibroid. Serous Cysts. Moles. Warts. Keloid. Eloid : (coil-like tu- mor).
<i>Mucus Membranes of pharynx œso- phagus and La- rynx.</i>	{ Cystic. Myxoma. Fibroma. Adenoma. Sarcoma. Papillomata. Carcinoma.

C.
TUMORS OF THE
TRUNK.

<i>Mammæ.</i>	{ Cysts. Fibroma. Adenoma. Enchondroma. Lipoma. Scirrhus. Encephaloid.
<i>Labia.</i>	{ Cysts. Abscess. Hæmatocele. Epithelioma.
<i>Uterus.</i>	{ Cystic. Fibroid. Myoma. Enchondroma. Pulsatile. Carcinoma.
<i>Rectum.</i>	{ Fibrous. Fatty. Carcinoma.
<i>Prostate.</i>	{ Hypertrophy. Abscess. Scirrhus. Encephaloid.
<i>Testicle.</i>	{ Cysts. Tubercular deposits. Gumma. Enchondroma. Benign fungus. Carcinoma.

Special *surgical regions* may also present an abnormal appearance, either from a local increase in size, or from the presence of some abnormal and well-defined tumor, which may demand extreme care in diagnosis, and which, for that reason, I have concluded also to tabulate. Of these special surgical regions, the *axilla* and the *groin* are the two most frequently affected with abnormal tumors, whose diagnosis is rendered difficult from their situation and depth.

Tumors of the *axilla* may be thus enumerated:

AXILLARY TUMORS.	}	Dependent on blood-vessels.	}	Aneurism. Hæmatocele.
		Of lymphatic type.	}	Cancer of lymphatic glands. Tubercular infiltration of glands. Inflammatory enlargement of glands. Enlargement of glands from hyper- plasia.
		Dependent on bone.	}	Dislocation of the head of humerus. Displaced head in fracture. Fragments of bone. Separation of the great tubercle. Osseous tumors.
		Axillary abscess.	}	Due to suppuration of glands. " " " connective tissue. " diseases of ribs. " " " cervical verte- bra. " " " shoulder joint. " " " scapula. " empyema.
		Dependent on organs.	}	Hernia of the lung.

TUMORS OF THE GROIN.

- Abscess of local origin.
 - Due to perityphlitis.
 - “ empyema, the pus burrowing through diaphragm.
 - “ disease of hip joint.
 - “ pelvic suppuration.
 - “ suppuration about kidneys.
 - “ caries of vertebral column, (psoas abscess).
 - In region of inguinal canal.
 - Lymphatic glands.
 - Lipoma of canal.
 - Hydrocele of spermatic cord.
 - Hæmatocele “ “
 - Hernial protrusion.
 - Arrested testicle.
 - Cysts.
 - In the region of femoral canal.
 - Enlarged lymphatic glands.
 - Varix of the saphenous vein.
 - Dislocated head of femur.
 - Enlarged bursa underneath the psoas tendon.
 - Psoas abscess.
 - Femoral aneurism.
 - In the iliac fossæ.
 - Ovarian tumors.
 - Fibrous “
 - Impacted fæces.
 - Aneurism of iliac arteries.
 - Abscess of abdominal walls.

CANCER.

In the preceding pages, I have classified tumors in general, and I now proceed to the consideration of those special forms of tumor, termed by some authors *malignant*, and included under the general head of *carcinoma*.

Cancer is properly an anatomical term used to include all forms

of new growth consisting of cells of an epithelial type, embedded in the alveoli of a fibrous stroma, and destitute of intercellular substance. It has been defined by Waldeyer as an *atypical epithelial neoplasm*. It includes four distinct varieties: 1. *Scirrhus*. 2. *Encephaloid*. 3. *Colloid*, and 4. *Epithelioma*. The colloid variety, termed also *gelatiniform* and *alveolar cancer*, is, in reality, but a *degenerative stage* of one of the other three varieties, and by some authors is considered under the head of "colloid degeneration," since this change may likewise occur in tumors not possessing the microscopical characteristics of carcinoma.

Cancerous tumors are always malignant, but all malignant tumors are not cancerous, since they fail to present the microscopical appearance of cancer. They are however, *clinically*, of equal importance, and I have, therefore, arranged in contrast the points in diagnosis between malignant and benign tumors, for the purpose of aiding in their clinical discrimination.

I shall defer the description of the symptoms of each of the four varieties of cancer, as they are to be found enumerated in the diagnostic tables pertaining to each. I have inserted in this chapter among *special* forms of cancer, only malignant disease of the axilla and omentum, as similar disease in other localities will be found described in other chapters of this work.

BENIGN TUMORS.

MALIGNANT TUMORS.

RELATION TO SURROUNDING PARTS.

Arc not intimately attached to the surrounding tissues.

Arc infiltrated into the tissues and often embody the surrounding structures in their own substance.

MULTIPLICITY.

Arc frequently solitary. If multiple they start simultaneously and advance with the same degree of rapidity. They also affect, when multiple, the *same type* of tissue.

Tend to reproduce themselves, and multiple tumors appear in succession. They often involve many distinct localities and also affect *different types* of tissue.

RAPIDITY OF GROWTH.

The tumors grow *slowly*, as a rule, and, when developed, are often stationary for years.

The tumors grow with great rapidity, when once fully developed.

ULCERATION.

No tendency to ulcerate is marked, but ulceration *may* exist.

A marked and uncontrollable tendency to ulceration exists.

TISSUES ABOUT ULCER.

The tissues near the ulcer are either healthy or simply indurated from inflammation.

The tissues near the edges of the ulcer are altered in their structure from the normal type.

DURATION OF ULCER.

The ulcer heals easily when irritation is removed, or, if extensive ulceration exists, the disease is in time destroyed.

No tendency towards spontaneous repair is manifested, but the disease develops in direct proportion to the rapidity and the extent of the ulcerative process.

STRUCTURE OF GROWTH.

The tumors are homologous and homomorphous. They are similar to some natural tissue of the body.

Arc heterologous and heteromorphous. They differ in their structure and arrangement from natural tissues.

CONSTITUTIONAL EFFECTS.

No constitutional effects are developed.

Constitutional effects are present and well marked in the later stages of the disease.

SCIRRHUS
(FIBROUS OR CHRONIC CANCER).

ENCEPHALOID CANCER
(ACUTE OR MEDULLARY CANCER).

ORIGIN.

Is usually a primary disease.

Occurs, most often, as a secondary affection.

RAPIDITY OF GROWTH.

The tumor develops slowly.

The tumor develops rapidly.

PALPATION.

The tumor is *hard* and *stony*.

The tumor is soft, lobulated and often elastic.

INTEGUMENT.

The skin is usually puckered and depressed before ulceration commences.

The skin is neither depressed nor puckered.

ULCERATION.

The tumor ulcerates late and slowly, as a rule.

The tumor ulcerates early in the disease and progresses rapidly.

HEMORRHAGE.

Hemorrhage from the tumor occurs late in the disease.

Hemorrhage occurs early in the disease.

SEAT.

Is usually present in the breast; it seldom reproduces itself in organs as scirrhous. It may be frequently found also in the alimentary canal.

The tumor is very malignant and tends to rapidly invade organs and glandular structures.

STROMA.

The stroma, as seen by the microscope, is large in quantity.

The stroma is small in quantity. The tumor resembles brain tissue, on section.

EPITHELIOMA

(EPITHELIAL CANCER ; CLAY-PIPE
CANCER ; CHIMNEY - SWEEP'S
CANCER).

SCIRRHUS

(FIBROUS OR CHRONIC CANCER).

LOCATION.

Is usually a primary disease of mucous or cutaneous surfaces. It is rarely found in internal organs.

Occurs in the mammary gland and alimentary canal, in the majority of cases. The stomach, œsophagus and rectum are its most frequent locations internally.

MODE OF ORIGIN.

Begins as a small ulcer, or as a nodule which subsequently ulcerates.

It seldom, if ever, commences as an ulcer.

CUT SURFACE OF TUMOR.

If pressure be made upon the scraped or cut surface of the tumor, a thick, crumbling, curdy material is exuded, often in a *worm-like* form. This exudation consists of epithelial-scales.

A *juice* is extracted from the cut surface, or by scraping the central or softer portions. This juice consists of cells, nuclei and granules.

EFFECT OF DILUTION.

This expressed material does not become *diffused* in water, but remains as minute visible particles.

The juice of scirrhus, when mixed with water, becomes *diffused* and often lost.

MICROSCOPE.

A small section of the tumor, under a microscope, reveals *epithelial nests* and *epithelial spheres*.

A section of the tumor reveals excessive development of a fibrous stroma and epithelial cells in a state, often, of atrophy.

COLLOID CANCER
(ALVEOLAR OR GELATINOUS
CANCER).

SCIRRHUS OF ORGANS.

LOCATION.

Is most frequent in the stomach, intestines and peritoneum.

Is a rare disease of organs, save in the œsophagus, at the pylorus, and in the rectum.

DEVELOPMENT.

The tumor develops rapidly.

The tumor is slow in development.

MALIGNANCY.

It frequently spreads to glands and adjacent tissues.

It is the least malignant of carcinomatous tumors.

APPEARANCE OF CUT SURFACE.

Has a glistening, jelly-like, translucent appearance. Its constituents resemble mucin, save that they contain sulphur and do not precipitate on the addition of acetic acid.

It is a hard, nodular mass, whose cut surface is dense and compact.

MICROSCOPE.

A markedly developed alveolar structure exists, with large *spherical* cells, which are often *laminated* and which contain colloid material in the form of drops.

A fibrous stroma is detected, which is excessively developed, and the cell element is often detected in a stage of atrophy after the tumor has reached advanced stages.

ORIGIN.

Is not a distinct variety of cancer, but is a *degenerative process* of other growths, as scirrhus, encephaloid, sarcoma, etc., etc.

It is a distinct type of cancer, and is often dependent on hereditary predisposition.

CANCER OF AXILLARY
GLANDS.

TUBERCULAR DISEASE OF
AXILLARY GLANDS.

AGE AFFECTED.

Is seldom present in children.

Is most frequent in children.

HISTORY.

No scrofulous history is present.

A scrofulous history exists.

GROWTH.

The tumor grows rapidly, in many cases.

The tumor is of slow growth.

MOBILITY.

The tumor is often restricted in its mobility.

The tumor is very movable.

NUMBER.

The tumor may be solitary.

The tumors are usually multiple.

NEIGHBORING PARTS.

The neighboring parts are often affected, especially the mammæ.

The surrounding parts are not affected.

TERMINATION.

Ulceration rapidly develops after the tumor has become superficial.

Suppuration occurs in the majority of cases, and its evacuation is preceded by a sense of fluctuation within the tumor.

EFFECTS OF REMOVAL.

A return of the disease, after removal of the tumor, within two years is frequently present.

The disease shows no tendency towards a return after removal.

CANCER OF OMENTUM.

ENLARGED SPLEEN.

PERCUSSION.

The area of dulness extends <i>across</i> the abdomen, but is not conveyed backwards.	The area of dulness seldom crosses to the right of the median line, and is always conveyed <i>backwards</i> .
---	---

LOCATION OF TUMOR.

It never ascends behind the ribs.	It frequently ascends behind the ribs.
-----------------------------------	--

SURFACE OF TUMOR.

Palpation detects a rough and uneven surface.	The surface of the tumor is smooth and regular.
---	---

DENSITY OF TUMOR.

The tumor is <i>hard</i> as a rule.	The tumor is soft to the touch.
-------------------------------------	---------------------------------

ASCITES.

Ascites is a frequent complication.	Ascites is seldom present.
-------------------------------------	----------------------------

HISTORY.

A cancerous hereditary taint is often found.	A malarial history is most frequent.
--	--------------------------------------

CACHEXIA.

A cancerous cachexia is developed as the disease advances.	A cachexia is not developed.
--	------------------------------

PAIN.

Pain is a prominent symptom in the advanced stages.	Pain is usually absent.
---	-------------------------

AGE AFFECTED.

Occurs chiefly after forty.	May occur at any age.
-----------------------------	-----------------------

EFFECTS OF PRESSURE.

Tenderness on pressure is common.	The tumor is not usually sensitive to pressure.
-----------------------------------	---

TUMORS OF THE HEAD.

The various tumors of the *cranium* which are met with in a surgical practice are

1. SEBACEOUS TUMORS OF THE SCALP.
2. FATTY “ “ “
3. EXOSTOSES OF THE SKULL.
4. ABSCESS.
5. CEPHALEMATOMA.
6. ENCEPHALOCELE.
7. DROPSY OF THE MENINGES OF THE BRAIN.
8. HERNIA CEREBRI.

The tumors of the *face* include

1. CYSTS OF THE ANTRUM.
2. SOLID TUMORS OF THE ANTRUM.
3. ABSCESS “ “
4. TUMORS OF THE ORBIT AND EYELIDS.
5. CANCEROUS TUMORS.
6. LUPUS.
7. FATTY TUMORS.

The tumors of the *mouth* include

1. RANULA, a cystic tumor from obstruction of sublingual ducts.
2. EPULIS, a fibrous tumor of the periosteum of the gum.
3. PARULIS, a local suppuration of the gum.
4. ENLARGEMENT OF THE TONSILS.
5. TUMORS OF THE TONGUE, encysted, fatty, gumma, erectile, and cancer.
6. POLYPI.
7. HYPERTROPHY OF THE PALATE.

In the following pages will be found diagnostic tables between such of these conditions as are most liable to be confounded. Some of these, however, have been previously recorded under *special types* of bone diseases, but are intentionally duplicated as they properly belong to each division.

SEBACEOUS TUMORS OF THE
SCALP.FATTY TUMORS OF THE
SCALP.

COMPARATIVE FREQUENCY.

These tumors are most frequent in this locality.

Fatty tumors are most frequent upon the back and shoulders, but may exist in any locality, and not infrequently upon the scalp.

MOBILITY.

The tumor is freely movable under the skin.

The tumor frequently involves the skin.

PALPATION.

The tumor is *tense, smooth* and *elastic*.

The tumor is soft and doughy.

OUTLINE OF TUMOR.

The tumor is distinct and regular in its outline.

Outline irregular and indistinct.

ORIFICE OF DUCTS.

A black speck on the tumor indicates the obstructed duct of the sac.

The sebaceous ducts are normal and unobstructed.

EFFECT OF PRESSURE.

The tumor can often be *evacuated* by firm pressure.

The tumor cannot be evacuated by pressure.

SIZE OF TUMOR.

The tumor is of moderate size.

The tumor may become very large.

SUPPURATION.

The tumor frequently suppurates and occasionally ulcerates.

The tumor seldom suppurates or ulcerates spontaneously.

ODOR.

The tumor is often associated with an offensive odor, from an escape of its contents.

The tumor is without odor.

SEBACEOUS TUMORS.

EXOSTOSES OF CRANIUM.

PALPATION.

The tumor is *tense, smooth* and *elastic* to the touch.

The tumor is of bony hardness.

MOBILITY.

The tumor is freely movable under the skin.

The tumor is immovable.

APPEARANCE ON INSPECTION.

On careful inspection of the tumor, the obstructed duct will be perceived as a *black* speck upon its surface.

The tumor exhibits no unnatural condition of the integument or its glands.

EFFECT OF PRESSURE.

On firm pressure the contents of the sac of the tumor may often be evacuated as a cheesy mass.

Pressure upon the tumor causes no evacuation of contents.

ODOR.

An offensive odor is occasionally associated with the tumor from a slight escape of its contents.

The tumor is odorless.

SYMPTOMS IN COMMON.

Both are frequently multiple.

“ “ of slow growth.

“ “ distinctly circumscribed in their outline.

EXTRA-CRANIAL TUMORS.

INTRA-CRANIAL TUMORS.

RESPIRATORY MOVEMENTS.

The tumor exhibits no movements during respiration.

The tumor rises with *expiration* from obstructed venous return to the chest, and falls during inspiration.

SIZE OF TUMOR.

The size of the tumor never exhibits sudden and temporary variations.

The tumor frequently *enlarges* on severe attacks of coughing or crying.

EFFECT OF PRESSURE.

The tumor cannot be made to disappear within the cranium by pressure.

No cerebral symptoms are produced by pressure.

The tumor can often be reduced, either entirely or in part, by direct pressure upon it.

Symptoms of *cerebral compression* are often produced in case the pressure be severe or long continued, but they usually cease when the pressure is removed, as the tumor returns to its former position.

CONDITION OF CRANIUM.

The bony walls of the cranium are intact.

An *aperture* can often be detected in the cranial bones on reduction of the tumor.

SYMPTOMS IN COMMON.

Both may be associated with an absence of cerebral disturbance.

“ “ “ “ similarity in feel and consistence.

“ “ “ “ rapid or slow formation.

“ “ “ “ an absence of apparent causation or a knowledge on the part of patient or friends of a congenital defect or deformity.

ENCEPHALOCELE.

DROPSY OF THE BRAIN.

SITUATION.

Occurs at the occiput, sutures, anterior fontanelle, and occasionally at the root of the nose between the two halves of the frontal bone.

Is most frequent at the anterior and posterior fontanelles, but may also be apparent at any of the cranial sutures.

CONTENTS OF TUMOR.

The protrusion consists chiefly of brain substance.

The tumor is due to an excessive amount of fluid within the membranes of the cerebrum, and the protrusion of the membranes.

APPEARANCE OF TUMOR.

The tumor is usually *pediculated*.

The tumor seldom, if ever, is pediculated.

TRANSLUCENCY.

The tumor is *opaque*.

The tumor is usually translucent.

RAPIDITY OF GROWTH.

The tumor seldom enlarges after birth, but if so, its development is very slow.

The tumor frequently enlarges rapidly and results in marked deformity.

SYMPTOMS IN COMMON.

Both are usually congenital tumors.

- | | | | |
|---|---|---|--|
| “ | “ | “ | painless. |
| “ | “ | “ | soft and possibly elastic. |
| “ | “ | “ | bluish in color. |
| “ | “ | “ | covered by thinned and altered integument. |
| “ | “ | “ | reducible within the cranium. |
| “ | “ | “ | often associated with respiratory movements. |
| “ | “ | “ | “ “ pulsation. |

ENCEPHALOCELE.

CEPHALÆMATOMA.

HISTORY OF TUMOR.

Is usually congenital.

Occurs, after birth, in infants.

SITUATION.

Is frequent at the fontanelles and cranial sutures.

Is never confined to sutures and seldom involves them. Is usually located upon some individual bone of the cranium.

EFFECT OF PRESSURE.

Pressure upon the tumor causes reduction within the cranium and possible cerebral symptoms.

Pressure upon the tumor causes no cerebral symptoms nor a reduction of the tumor.

FLUCTUATION.

Fluctuation is absent.

Fluctuation is present in the tumor before coagulation occurs.

PULSATION.

Pulsation is sometimes present within the tumor.

Pulsation within the tumor is rare.

RESPIRATORY MOVEMENTS.

Respiratory movements within the tumor are generally present.

Respiratory movements are absent.

SIZE OF TUMOR.

The tumor is generally of moderate dimensions.

The tumor may often be diffused over a large area.

INTEGUMENT.

The skin over the tumor is usually very thin and altered in its structure and appearance.

The integument over the tumor is usually normal.

ABSCESS OF ANTRUM.

SOLID TUMORS OF ANTRUM.

DEFORMITY.

The antrum is equally distended.

The antrum is *unequally* distended.

INFLAMMATORY SYMPTOMS.

Acute *inflammatory symptoms* are present, such as
 Chills,
 Great pain,
 " sensitiveness to touch,
 Œdema of face,
 Increased pulse, and
 " temperature.

No acute inflammatory symptoms are present, (such as pain, œdema, great sensitiveness, and constitutional disturbance).

FLUCTUATION.

Fluctuation often appears in advanced stages.

Fluctuation is absent, as a rule.

DISCHARGE INTO MOUTH OR NOSE.

A tendency to the discharge of pus through the teeth sockets, or through the nostril during forced expiration, or in certain positions of the body.

No tendency towards a spontaneous discharge of the contents of the cavity of the antrum is apparent.

EXPLORING NEEDLE.

The exploring needle in cases of doubt decides the diagnosis.

The exploring needle gives negative results.

SYMPTOMS IN COMMON.

Both are often associated with	projection of the eyeball.
" " " "	" effacement of the nostril.
" " " "	" depression of roof of mouth.
" " " "	" bulging of the cheek.
" " " "	" closure of the lachrymal duct.
" " " "	" interference with mastication.
" " " "	" " " deglutition.
" " " "	" parchment-like crepitus when the bone becomes thin.

EPITHELIOMA.

LUPUS.

LOCATIONS AFFECTED.

Affects principally the lips, cheeks, nose, forehead, and serotum. It is also found frequently on the mucous membranes of the tongue, prepuce, labia, uterus, and bladder.

Affects the face, nose, ears, cheeks, buttocks, and extremities. It also affects the mucous membrane of the lips, hard palate, and throat.

DEVELOPMENT.

Begins either as a subcutaneous movable nodule, which undergoes ulceration, or as a small, foul ulcer with indurated edges.

Begins as a brownish-red spot, which subsequently becomes a papule and then ulcerates.

AGE AFFECTED.

Occurs rarely, if ever, in the young, and is usually due to local irritation.

Occurs before middle life. It may often affect young children. Is not dependent upon local irritation.

EXTENT.

Is gradual in its development, and is often unassociated with any very marked deformity.

Its ravages are often terribly severe, and the part affected undergoes, in some cases, marked and rapid deformity.

SURFACE OF ULCER.

The surface of the ulcer is frequently papillated and villous, from an irregular growth of the corium. The surface is often friable, and on pressure frequently exudes a thick, crumbling and curdy material in a *worm-like* form. In some cases the ulcer is scabbed.

The ulcer may often be "serpiginous" in character. It may be scabbed, and, on removal of the scab, the surface may present irregular elevations and depressions on its surface. The skin, hair, sebaceous follicles and sweat glands, are often destroyed.

REPAIR.

Seldom, if ever, tends towards spontaneous recovery.

The ulcer frequently heals with a depressed and puckered cicatrix.

TUMORS OF THE BREAST.

The mammary gland may be affected with the following conditions which result in its enlargement:

1. ACUTE ABSCESS.
2. CHRONIC ABSCESS.
3. SIMPLE CYSTS.
4. COMPOUND CYSTS.
5. GLANDULAR TUMORS.
6. HYPERTROPHY OF THE MAMMÆ.
7. SCIRRHUS.
8. ENCEPHALOID CANCER.

Of these diseases, scirrhus and encephaloid have already been considered together under the head of cancerous tumors, and as they have no special distinctive features when confined to the mammary gland, that table will not be here duplicated. I have arranged the remainder in the form of diagnostic tables, with the exception of compound cysts, which cannot readily be distinguished from simple cysts of the breast, by the rational or physical signs pertaining to either. I have added also a diagnostic table between scirrhus, as the most frequent type of cancer in this locality, and innocent mammary tumors, since the importance of the discrimination can hardly be over-estimated.

ACUTE MAMMARY ABSCESS.

CHRONIC MAMMARY
ABSCESS.

CONDITION OF BREAST.

The breast is red, hot and œdematous.

Breast normal, or slightly œdematous at its lower margin.

ORIGIN.

Follows traumatism or lactation.

Occurs after a period of uterine activity as in menstrual derangement, miscarriage, abortion, or normal confinement.

TUMOR.

Is usually situated near the nipple and is fixed and often immovable.

The tumor is deep seated in the substance of the gland and is *movable*, as a rule.

The tumor develops rapidly and is very painful and sensitive to the touch.

The tumor develops slowly and is nearly painless, and not sensitive.

The nipple is usually affected.

The nipple is seldom involved.

INTEGUMENT.

The skin becomes involved early.

The skin becomes involved late.

NUMBER OF TUMORS.

The tumor is solitary.

The tumor may begin as a number of small nodules which subsequently coalesce.

FLUCTUATION.

Fluctuation is distinct when the tumor is grasped and made prominent.

Fluctuation is often indistinct from the depth of the tumor and thickening of its wall, but *elasticity* is present.

CONSTITUTIONAL SYMPTOMS.

The pulse and general temperature are markedly elevated.

The constitutional disturbance is slight and may be absent.

EXPLORING NEEDLE.

Pus mixed with *milk* is often detected by the exploring needle.

Pus is withdrawn by the needle, but no evidences of *milk* are present.

CYSTS OF THE BREAST.

GLANDULAR TUMOR OF
BREAST.

ORIGIN.

May be due to obstruction of the milk ducts or to cysts of independent origin, (as per table on cystic tumors). Hydatid cysts are sometimes present.

Occurs most frequently in maid-ens between twenty and forty years of age, and is often associated with menstrual derangements or traumatism.

DEVELOPMENT.

The tumor usually develops slowly, but may form rapidly after cessation of the menses or if due to hydatids.

The tumors are most frequently developed at the upper and inner portion of the breast, and, as a rule, grow slowly.

PALPATION.

The tumor is smooth, circumscribed and movable. If due to hydatids, a peculiar fremitus on percussion is obtained.

The tumor is round, oval or lobular, *firm* and *incompressible*, and is very movable. In rare cases it may protrude through the skin, but does not ulcerate or bleed, as a rule.

FLUCTUATION.

The tumor usually fluctuates.

The tumor never fluctuates.

TRANSLUCENCY.

The tumor may be translucent if very superficial.

The tumor is opaque.

NEIGHBORING GLANDS.

The neighboring glands are seldom involved.

The neighboring glands *may* be involved, but are usually not so.

EXPLORING NEEDLE.

Milk, serum, or hydatid cysts may be obtained by an exploring needle from these tumors.

The results of the exploring needle are negative.

GLANDULAR TUMOR OF HYPERTROPHY OF MAMMÆ.
THE BREAST.

ORIGIN.

Occurs most frequently in maid- ens between twenty and forty years of age, and is often associated with menstrual derangements or trauma- tism.	Is most frequent in the married during the term of pregnancy or menstrual derangement. It is never of traumatic origin.
---	--

LOCATION.

The inner and upper portion of one breast is usually affected.	Both breasts are simultaneously enlarged, as a rule, and become very heavy.
---	---

MOBILITY.

The tumor is usually very mov- able.	The breasts are usually less mova- ble than normal.
---	--

SYMPTOMS IN COMMON.

Both are usually	firm and incompressible.
“ “ “	painless.
“ “ “	of slow growth.
“ “ “	unassociated with tegumentary changes.
“ “ “	associated with normal health.
“ “ “	free from enlargement of neighboring glands.
“ “ “	characterized by a normal position and appearance of the nipple.

SCIRRHUS OF THE BREAST. INNOCENT TUMORS OF THE
BREAST.

OUTLINE OF TUMOR.

The tumor is irregular in shape, The tumor may be irregular,
nodular and indistinct at its cir- round or oval, and is usually dis-
cumference. tinctly circumscribed.

MOBILITY.

The tumor is deeply attached to The tumor moves freely within
the gland, and, if movable, simply the breast itself.
slides on the pectoral muscle.

PALPATION.

The tumor is hard and *stony*. The tumor is softer and more
elastic.

WEIGHT OF TUMOR.

The tumor is heavy. The tumor is light.

BREAST.

The breast is shrunken. The breast is normal or increased
in size.

PAIN.

Lancinating, severe and paroxys- Pain is often absent. If present
mal pain exists in latter stages. it is continuous and of moderate
severity.

NIPPLE.

The nipple is retracted. The nipple is normal, as a rule.

AXILLARY GLANDS.

The axillary glands are enlarged The axillary glands may be en-
and hardened. larged, but are never *hardened* or
fixed.

GROWTH OF TUMOR.

The tumor grows rapidly. The tumor grows slowly and is
often stationary for years.

SCIRRHUS OF THE BREAST
(*continued*).

INNOCENT TUMORS OF THE
BREAST
(*continued*).

ULCERATION.

Ulceration is frequent, progressive
and obstinate.

Ulceration is infrequent and easily
treated.

SUPERFICIAL VEINS.

The superficial veins are promi-
nent and enlarged.

The veins are little affected.

HEALTH.

A cachexia is developed.

The general health remains good.

COMPLICATIONS.

Cancerous tumors develop in other
organs and tissues.

Complications are infrequent.

TUMORS OF THE UTERUS.

The uterus may become enlarged from the following named conditions :

1. CONGESTIVE UTERINE HYPERÆMIA.
2. FIBROID TUMOR.
3. HYDATIDS.
4. RETAINED MENSTRUAL BLOOD.
5. UTERINE FIBRO-CYST.
6. UTERINE POLYPUS.
7. UTERINE MOLES.
8. PREGNANCY.
9. CANCER OF THE UTERUS.

I have treated of cancer in previous pages of this book, and shall not again consider it as a special uterine tumor, as it presents no special or distinctive characters in this region other than those perceived in all locations. It may primarily affect the body of the uterus or the cervix. I have added in the following pages, however, the symptoms of the various other conditions, resulting in uterine enlargement, in the form of diagnostic tables, as they are liable to be easily confounded with each other in diagnosis.

CONGESTIVE UTERINE
HYPERÆMIA.

EARLY PREGNANCY.

DEVELOPMENT.

The uterus ceases to develop in size after reaching moderate dimensions.

The uterus steadily increases in size till large dimensions are reached.

SENSITIVENESS.

The tumor is tender and sensitive to pressure.

The uterus is not usually sensitive.

PAIN.

A severe pain in the back and loins exists.

Pain in the back and loins is often absent, but, if present, is not severe.

WALKING.

Walking becomes difficult from the existing pain.

Walking is not interfered with.

FÆTAL MANIFESTATIONS.

After the fourth month all symptoms of pregnancy in its advanced stages are absent.

Evidences of fœtal presence exist after the fourth month, viz. : fœtal movements, quickening, fœtal heart, placental bruit, ballottement, etc.

SYMPTOMS IN COMMON.

Both are often associated with absence of the menses.

“	“	“	“	“	vomiting.
“	“	“	“	“	local uterine disturbance.
“	“	“	“	“	vesical and rectal irritability.

FIBROID TUMOR OF UTERUS. PREGNANCY.

MENSTRUATION.

Menorrhagia or metrorrhagia is present, as a rule.	Amenorrhœa is usually present, but may be absent.
--	---

TUMOR.

Nodules can be detected on palpation of the uterus.	The uterus is uniformly increased in size.
---	--

CONSISTENCE.

The tumor is hard and resistant.	The tumor is more elastic.
----------------------------------	----------------------------

CERVIX.

The cervix is normal.	The cervix is often altered in its condition and appearance.
-----------------------	--

AUSCULTATION.

The auscultatory signs are negative.	Fœtal heart and the placental bruit are heard after the fifth month.
--------------------------------------	--

FŒTAL MANIFESTATIONS.

Quickening, fœtal movements and other manifestations are absent.	Fœtal manifestations develop, unless the fœtus be dead.
--	---

DURATION OF TUMOR.

The duration of the tumor is indefinite.	The duration is limited.
--	--------------------------

LOCATION OF TUMOR.

The tumor may not always be median in location.	The tumor usually lies in the median line.
---	--

RETAINED MENSTRUAL
BLOOD.

PREGNANCY.

CONDITION OF SEXUAL ORGANS.

The sexual organs are abnormal. An examination may detect: Imperforate hymen; adhesion of vaginal walls; adhesion of lips of cervix; congenital defects; traumatic conditions.

The sexual organs exhibit no unnatural acquired condition, or abnormal development.

MENSTRUAL EPOCHS.

At each return of the normal date for menstruation the patient suffers intense pain, but does not menstruate.

The dates of ovarian irritation are not usually perceived during pregnancy, but, in rare cases, menstruation continues without any abnormal symptoms.

CONSTITUTIONAL SYMPTOMS.

The retention and decomposition of menstrual products create constitutional disturbances, which are often severely marked.

No constitutional disturbance, save from exhaustive vomiting, is perceived if the foetus be alive, and no maternal disease exists.

FETAL MANIFESTATIONS.

No evidences of foetal life are detected.

Foetal life is clearly indicated after the fifth month.

SYMPTOMS IN COMMON.

Both	are	usually	associated	with	amenorrhœa.
“	“	“	“	“	a uterine tumor.
“	“	“	“	“	frequent local pains.
“	“	“	“	“	vesical irritation.
“	“	“	“	“	rectal “

UTERINE HYDATIDS.

PREGNANCY.

DEVELOPMENT.

The tumor develops with great rapidity.

The tumor develops with a moderate rapidity.

UTERINE DISCHARGE.

Watery and bloody discharges from the uterus are frequently present.

Uterine discharge is usually absent, but a leucorrhœa may often exist.

Cysts are often spontaneously evacuated from the uterus.

Cysts are never evacuated.

UTERINE TENESMUS.

Uterine tenesmus is usually present.

Uterine tenesmus is usually absent.

CONSTITUTIONAL DISTURBANCE.

The evidences of constitutional disturbance are often well marked.

The constitutional disturbance is slight or absent, as a rule.

AUSCULTATION.

The auscultatory signs are negative.

Fœtal heart and placental bruit are heard after the fifth month.

FŒTAL MANIFESTATIONS.

Fœtal manifestations are absent.

Fœtal movements and quickening are apparent, if the child be alive.

UTERINE FIBROID.

SOLID OVARIAN TUMOR.

MENSTRUATION.

The tumor is usually accompanied by menorrhagia.

The menstrual function is often unaffected.

MOVEMENTS OF TUMOR.

The uterus always participates in movements communicated to the tumor.

The uterus is usually independent of motions of the tumor.

MOVEMENTS OF UTERUS.

The uterus, if moved by a uterine sound, affects the tumor.

The uterus, if moved, exerts no influence upon the tumor, as a rule.

MULTIPLICITY OF TUMORS.

The tumors are often multiple.

The tumor is usually solitary.

PALPATION.

The tumor is *hard*, incompressible and heavy.

The tumor is less dense, and lighter in weight.

UTERINE CAVITY.

The cavity of the uterus is often increased, as revealed by measurement with the uterine sound.

The cavity of the uterus is normal in length.

CERVIX OF UTERUS.

The cervix is in the median line, as a rule.

The cervix is often laterally displaced.

FLUCTUATION.

Fluctuation is absent.

Fluctuation may be detected in localized spots on the tumor, if the tumor is compound in its character.

UTERINE FIBRO-CYST.

OVARIAN CYST.

DEVELOPMENT.

The tumor grows slowly.

The tumor grows rapidly.

AGE AFFECTED.

The tumor occurs after thirty years of age.

The tumor may affect any age after puberty.

CAVITY OF UTERUS.

The uterine cavity is enlarged.

The uterine cavity is normal.

MOVEMENT OF TUMOR.

The tumor, if moved, affects the uterus, and vice versa.

The tumor is independent of the uterus in many cases.

POSITION OF UTERUS.

The uterus is often lifted out of the pelvis and can be detected above the pubes.

The uterus is usually displaced laterally within the pelvis.

The uterus is often in *front* of the tumor.

The uterus is generally *behind* the tumor.

HEALTH OF PATIENT.

The health is little affected.

The health is undermined in two or three years.

FLUID OF TUMORS.

The fluid, if withdrawn, coagulates quickly and spontaneously.

The fluid, if withdrawn, *never* coagulates.

MICROSCOPE.

A peculiar "fibre cell," mentioned by Drysdale, is often detected.

Granular cells, epithelial cells and cholesterine are often detected.

UTERINE POLYPUS.

UTERINE FIBROID.

MOBILITY OF TUMOR.

After the cervix has been dilated a *movable* tumor is perceived within the uterine cavity.

The tumor may often be felt externally, and in some cases only after dilatation of the cervix, but it is always immovable.

PALPATION.

The uterus is smooth upon palpation of its external surface.

The uterus is nodular on its external surface, as a rule.

PEDICLE.

The tumor is usually pediculated.

The tumor is seldom pediculated.

SYMPTOMS IN COMMON.

Both are often associated with menorrhagia.

“ “ “ “ “ metrorrhagia.

“ “ “ “ “ leucorrhœa.

“ “ “ “ “ pain in the back and in the loins.

“ “ “ “ “ dysmenorrhœa.

TUMORS OF THE OVARY.

The various tumors which affect the ovary and its appendages, may be enumerated as follows :

1. FIBROUS TUMORS.
2. FIBRO-CYSTIC TUMORS.
3. CARCINOMA.
4. CYSTO-CARCINOMA.
5. DERMOID CYSTS.
6. COLLOID DEGENERATION.
7. HYDATID CYSTS.
8. CYSTS OF THE BROAD LIGAMENT.

Ovarian tumors may be confounded in diagnosis with, 1. Ascites. 2. Pelvic abscess. 3. Cysts of the kidney. 4. Pregnant uterus. 5. Fibro-cyst of the uterus. 6. Uterine Fibroid. Two of these diagnoses have already been considered in contrast, under the head of tumors of the uterus ; the others will be found arranged in the form of diagnostic tables in the ensuing pages.

OVARIAN DROPSY.

ASCITES.

SITUATION OF TUMOR.

The tumor is most prominent upon one side, save in advanced stages.

The tumor is uniform and symmetrical.

EFFECT OF ATTITUDE.

The tumor remains prominent and globular in all positions of the body.

The tumor *flattens* and *increases in its breadth* on lying down.

FLUCTUATION.

The tumor is locally fluctuant.

The tumor fluctuates through the *entire abdomen*.

ORIGIN.

The tumor begins in one iliac fossa.

The tumor begins symmetrically from below.

PERCUSSION NOTE.

The percussion is dull in front when the patient lies upon her back, but is tympanitic, from displaced intestine, at the sides.

The percussion is resonant in front of abdomen, when patient lies on the back, as the bowel floats; but is *flat* at the sides of the abdomen.

LINE OF DULNESS.

Is constant and not affected by attitude.

Is variable, and is affected by attitude of patient and by amount of fluid present.

PALPATION.

Palpation detects an oval outline and an irregular surface to the tumor.

No circumscribed outline to tumor or irregularity of surface is discovered.

CERVIX OF UTERUS.

The cervix is normal in position.

The cervix is frequently displaced.

GENERAL HEALTH.

The health is usually good until the tumor becomes large.

The health is usually impaired from the commencement.

OVARIAN DROPSY
(continued).

ASCITES
(continued).

ŒDEMA OF LIMBS.

If present, œdema of the limbs *follows* the advent of tumor. It often *precedes* the ascites.

AORTIC PULSATION.

Aortic pulsation *may* be transmitted. Aortic pulsation is never present.

HISTORY.

No apparent cause exists. *Hepatic, cardiac, or renal disease* often co-exists.

SKIN.

Normal color and moisture of the skin exist. The skin is often jaundiced, and is frequently dry like parchment.

FLUID CONTENTS.

The fluid, if drawn by aspirator, may reveal the following characteristics :

1. Amber or brown in color.
2. *Not spontaneously coagulable.*
3. Specific gravity, 1018 to 1024.
4. Paralbumen and metalbumen.

Microscope reveals :

1. *Granular* cells, which become *clear* by action of acetic acid, but not increased in size.
2. Oil globules.
3. Cholesterine and albuminoid matters.
4. Epithelium (eylindrical).

The fluid, if drawn by aspirator, may reveal the following characteristics :

1. Light straw-colored.
2. Spontaneously coagulable, if fibrinous.
3. Specific gravity, 1010 to 1015.

Microscope reveals :

1. Pus cells.
2. Oil globules.
3. Amœboid bodies.
4. Squamous epithelium.

FLUID TUMORS OF THE
OVARY.

PELVIC ABSCESS.

ORIGIN.

The tumor is preceded by no inflammatory symptoms.

The tumor is preceded by symptoms of pelvic cellulitis.

EXTENT OF TUMOR.

The tumor rises gradually above the umbilicus.

The tumor rarely extends to the umbilicus.

MOBILITY OF TUMOR.

The tumor is movable, when of moderate size.

The tumor is fixed and immovable.

PAIN.

The tumor is usually painless, and not sensitive to pressure.

The tumor is exceedingly painful, and is sensitive to the touch.

OUTLINE OF TUMOR.

The tumor is distinct in outline.

The outline of the tumor is obscure.

DEVELOPMENT.

The tumor develops slowly.

The tumor develops rapidly.

SUPPURATION.

The tumor does not point or suppurate.

The tumor tends towards pointing and the evacuation of pus.

CONSTITUTIONAL SYMPTOMS.

Inflammatory symptoms are absent during the development of the tumor.

Chills and often an elevation of pulse and temperature accompany the development of the tumor.

EXPLORING NEEDLE.

The characteristic fluid of ovarian tumors, as described on preceding page, is withdrawn when the exploring needle or aspirator is used.

Pus is withdrawn after the tumor softens and becomes fluctuant.

UNILOCULAR OVARIAN
CYST.RENAL CYST, (DROPSY OR
HYDATIDS).

INTESTINAL DISPLACEMENT.

The tumor displaces the intestine backwards, as revealed by percussion.

The tumor displaces the intestine forwards.

URINARY CHANGES.

The urine is normal.

The urine *may* contain pus, blood, or albumen. It may also occasionally be evacuated in sudden and large quantity, and the tumor then simultaneously subsides.

DEVELOPMENT.

The tumor grows from below upwards.

The tumor grows from above downwards.

FREQUENCY.

Is common, and affects all ages.

Is a rare disease.

MOBILITY.

The tumor cannot be displaced upwards.

The tumor may possibly be capable of an upward displacement, so as to allow of *resonant* percussion above the pelvis.

ORIGIN.

The tumor is never due to cchilococci.

The tumor may be of hydatid origin, or may be due to obstructed escape of urine.

COLON.

The tumor is never crossed by the colon, as shown by percussion.

The tumor is often *crossed* by the descending colon if on the left side.

The tumor lies internally to the ascending colon.

The tumor, if on right side, often lies *externally* to the ascending colon.

MENSTRUATION.

Menstrual derangements are frequent.

Menstrual derangements are usually absent.

LOCATION OF TUMOR.

The tumor involves both sides, if of large dimensions.

The tumor is unilateral.

OVARIAN TUMOR.

PREGNANCY.

SITUATION OF TUMOR.

The tumor is not median in position till far advanced.

The tumor is median in its position.

FLUCTUATION.

The tumor is often fluctuant.

The tumor is seldom, if ever, fluctuant.

ORIGIN.

The tumor begins in one iliac fossa.

The tumor begins in the median line.

GROWTH.

The tumor grows slowly.

The growth of the tumor is rapid.

UTERUS AND CERVIX.

The uterus and cervix are normal.

The uterus and cervix are altered.

MENSTRUATION.

Menstruation is often unaffected.

Amenorrhœa is the rule.

AUSCULTATION.

No abnormal auscultatory sounds are detected.

Placental bruit and fetal heart are heard after the fourth month, unless the child be dead.

FŒTAL MANIFESTATIONS.

No quickening or fetal movements are detected.

Fœtal manifestations are a prominent symptom.

DURATION.

Indefinite.

Limited.

SYMPTOMS IN COMMON.

Both may produce enlargement of the breasts.

“ “ “ pain in the breasts.

“ “ “ areola “ “

“ “ “ morning sickness.

TUMORS OF THE PELVIS.

The various types of tumor found within the pelvis may be enumerated as follows :

1. PELVIC CELLULITIS.
2. PELVIC PERITONITIS.
3. PELVIC HÆMATOCELE.
4. EXTRA-UTERINE PREGNANCY.
5. UTERINE CANCER.
6. INVERSION OF UTERUS.
7. UTERINE FIBROID.
8. UTERINE POLYPUS.
9. RECTAL CANCER.
10. OVARIAN TUMOR IN EARLY STAGE.
11. OSSEOUS TUMORS OF THE PELVIC BONES.
12. VAGINAL THROMBUS.
13. VESICAL CALCULUS, (if large).
14. HERNIA OF BLADDER OR RECTUM.
15. PROSTATIC ENLARGEMENT: (cancer, tubercle, abscess).

Many of these conditions have been treated of in preceding chapters of this work, and will be found included under the diseases of organs, or of special localities of the body. I shall present, therefore, in the following pages only diagnostic tables, in which are contrasted the symptoms of pelvic cellulitis, pelvic peritonitis, pelvic hæmatocele, extra-uterine pregnancy, vaginal polypus, and inversion of the uterus.

PELVIC CELLULITIS.

PELVIC PERITONITIS.

TUMOR.

The tumor will be felt *low* down in the pelvis, and will be most marked on *one side*, as a rule.

The tumor, if detected, will be felt *high up* in the pelvis, and will be located in the *median line*, as a rule. A hardening of the whole pelvic roof is more common than a tumor.

MOBILITY OF UTERUS.

The uterus will be *slightly* movable.

The uterus will be *immovable*.

SUPPURATION.

Suppuration is usually produced.

Suppuration seldom occurs.

TYMPANITIS.

Tympanitis is absent.

Tympanitis is usually present.

APPEARANCE OF FACE.

The expression of the face is normal.

The face has an anxious expression.

CONSTITUTIONAL EFFECTS.

The constitutional effects are slight or absent.

Elevation of pulse and temperature, vomiting, tenderness of abdomen, etc., etc., are liable to exist.

RELAPSES.

No tendency to relapses, during menstruation, is present.

Relapses are frequent at the monthly periods.

POSITION OF UTERUS.

The uterus is not necessarily displaced.

The uterus is usually displaced by subsequent adhesions and contraction of new connective-tissue development.

HISTORY.

Cellulitis most frequently follows parturition, abortion, or operations upon the pelvic viscera.

Peritonitis most frequently follows exposure during menstruation, disease of the ovaries, *gonorrhœa* and escape of fluids into the peritoneal cavity.

PELVIC HÆMATOCELE.

EXTRA-UTERINE PREG-
NANCY.

DEVELOPMENT.

A tumor develops suddenly, with constitutional symptoms of hemorrhage, if due to traumatism; but slowly, if due to spontaneous effusion of blood.

A tumor develops slowly.

MENSTRUATION.

Menstruation may be normal.

Amenorrhœa is usually present.

HEMORRHAGE.

Symptoms of hemorrhage, if present, *precede* or *accompany* the development of the tumor.

Hemorrhage is liable to occur only *after* the tumor has developed.

UTERINE SYMPTOMS.

The early symptoms of pregnancy are usually absent.

The early symptoms of pregnancy, viz. : morning sickness, suppression of menses, areola in breasts, kiestein in the urine, etc., etc., are often present.

FLUCTUATION.

The tumor fluctuates at its commencement, but grows hard as coagulation of the blood advances.

The tumor is often fluctuant throughout its entire development.

TERMINATION.

The tumor tends to decrease in size and disappear after the hemorrhage is arrested.

The tumor tends to develop or to rupture. In the latter case, death from hemorrhage or peritonitis is common.

VAGINAL POLYPUS. INVERSION OF THE UTERUS.

UTERINE PROBE.

The uterine probe, if passed through the vagina by the side of the tumor, will enter the body of the uterus.

The uterine probe will be arrested at the vaginal attachment to the uterus.

RECTAL EXAMINATION.

The uterine body can be detected in its normal position by the finger, when introduced into the rectum.

The finger in the rectum detects the absence of the uterus from its normal position.

CONJOINED MANIPULATION.

By pressing the abdominal walls firmly downwards towards the pelvis while the finger of the other hand is crowded by the side of the tumor into the vagina, the uterus can often be detected by one of the two hands.

The uterus is not detected, save as the cause of the vaginal tumor, by the same means of examination.

RECTO-VESICAL EXPLORATION.

A sound introduced into the bladder will often reveal to a finger in the rectum an intervening tumor, which is the body of the uterus in its normal position.

No intervening tumor will be thus detected, save that in the vagina, and thus the diagnosis of inversion of the uterus may be verified.

ACUPUNCTURE.

Acupuncture will give no pain.

Acupuncture will give pain.

TUMORS OF THE SPINE.

The tumors of the spine comprise those of a congenital variety and the condition called spina-bifida. Among the different forms of congenital tumors of the spine which have been reported may be enumerated

1. Parasitic growths (containing the remnants of an obliterated fœtus).
2. Cystic Tumors (simple and compound).
3. Fibroid Tumors.
4. Fatty Tumors.

Congenital tumors of the spine are most frequently located in the vicinity of the sacral or the lower lumbar regions. They are often connected directly with the spinal membranes, in which case the bony encasement of the spinal cord is locally deficient. They may be present upon the anterior or posterior aspect of the spine and are not infrequently intra-pelvic for that reason. If situated so as to press upon the pelvic viscera they may create a displacement of the coccyx, and a protrusion of the anus and perineum may be also produced.

If the tumor have a direct connection with the spinal membranes, it will, with few if any exceptions, lie in or spring from the median line.

If cystic in its variety it will usually reveal a contents similar to the cerebro-spinal fluid in its chemical composition provided any communication with the cavity of the arachnoid is present, and differs little, therefore, in its actual construction from that of spina-bifida.

Congenital tumors in the spinal region communicate in rare cases with the cavity of some viscus, as the intestine, rectum, bladder, etc. In this event a possible escape of the contents of the tumor into these various organs will be the only means of determining such an abnormal condition.

SPINA-BIFIDA.

This condition is in reality a congenital hernia of the spinal membranes through an abnormal opening in the vertebral column.

It is a frequent deformity and is either distinctly localized or affects the whole or greater portion of the spinal column. The sac

consists of the membranes of the spinal cord and in rare cases the substance of the cord itself is spread out as a thin layer on the internal surface of the membranous coverings.

Its contents consist of an excessive accumulation of the subarachnoidean fluid, occasionally portions of the cord itself or the cauda equina, and, in rarer instances, a deposit of fat and an increased quantity of connective tissue. The spinous processes of the vertebræ are absent over the tumor and the laminæ are either imperfectly formed or entirely absent. Spina-bifida is not often present in the upper portions of the trunk, but is most frequently located in the lower dorsal or lumbar regions.

The symptoms of spina-bifida and congenital fatty tumor arising from the membranes of the spinal cord will be given in the following pages. While they do not possess many points of strong resemblance, still the location of the tumors, their congenital origin, the deficiency of the spinous processes of the vertebræ, and the possibility of associate muscular changes, and nervous symptoms dependent on spinal lesions seem to warrant a contrast of symptoms rather than a separate enumeration of those associated with each.

SPINA-BIFIDA.

CONGENITAL FATTY TUMOR

(CONNECTED WITH THE MEMBRANES OF THE SPINAL CORD).

APPEARANCE OF TUMOR.

The tumor may be circumscribed or elongated for some distance in the longitudinal axis of the spine.

The tumor is usually distinctly circumscribed.

PALPATION OF TUMOR.

The tumor is usually fluctuant or elastic.

The tumor never fluctuates. It is doughy and soft to the touch.

NUMBER OF TUMORS.

Multiple tumors are not infrequent.

The tumor is usually solitary.

SIZE OF TUMOR.

The tumor varies in size from that of a small bird's egg to the size of a child's head.

The tumor is seldom of large size.

EFFECT OF ATTITUDE.

The tumor is usually tense when the patient stands erect.

The tumor is not markedly affected by the attitude of the patient.

Is fluctuant usually when the patient lies upon the abdomen.

EFFECTS OF RESPIRATION.

The tumor is often decreased in size by a full inspiration and is increased in size during expiration.

The tumor is not altered in size by the respiratory function.

EFFECTS OF PRESSURE.

The tumor decreases in size on direct pressure being applied.

The tumor is often resistant to pressure and is, as a rule, but slightly affected.

If other tumors of the same variety co-exist, they often increase in size when the pressure is applied.

Symptoms of spinal compression as evidenced by cries, pain, convulsions, paralysis, etc., etc., may accompany pressure if severely applied and disappear when the pressure is removed.

Symptoms of spinal compression as the result of direct pressure over the tumor are seldom present.

SPINA-BIFIDA
(*continued*).CONGENITAL FATTY TUMOR
(CONNECTED WITH THE MEM-
BRANES OF THE SPINAL CORD)
(*continued*).

TRANSMITTED LIGHT.

The tumor is often translucent, as is perceived by holding a candle behind it.

The tumor is always opaque.

APPEARANCE OF THE INTEGUMENT.

The integument covering the tumor may be reddened, thinned and transparent, or even absent. In some cases however it is normal in appearance.

The integument is usually of normal color and appearance, but is, as a rule, adherent to the tumor.

SYMPTOMS IN COMMON.

Both may be associated with other congenital deformities such as hare-lip, cleft palate, imperforate anus, cranial protrusions, etc., etc.

“ “ “ “ imperfect development of the lower limbs.

Both are rare in the cervical region of the spine.

“ reveal a long axis parallel with that of the spine.

“ are usually broad at the base, but they *may* be pedunculated.

“ may result in atrophy of the lower limbs.

“ “ “ “ paraplegia or extreme muscular weakness and retention or incontinence of urine if the tumor be situated above the second lumbar vertebra.

BIBLIOGRAPHY.

- ACTON, WILLIAM. Urinary and Generative Organs. 1865.
- ASHTON, T. J. Treatise on the Diseases, Injuries and Malformations of the Rectum. London, 1854.
- ASHURST, JOHN. Principles and Practice of Surgery. 1871.
- BARWELL, R. Treatise on the Diseases of Joints. London, 1861.
- BENNETT, J. HUGHES. Article on Pyæmia (Holmes' Surgery), "Cancerous and Canceroid Growths." Edinburgh, 1849.
- BIGELOW, H. J. Dislocations and Fractures of the Hip. 1869.
- BILLINGHAM, O'BRIEN. Observations on Aneurism and its Treatment. 1847.
- BILLROTH, TH. Elements of General Surgical Pathology. 1871.
- BOULLAUD, J. Monograph on the Treatment of Aneurism. 1860.
- BRIGHT, R. Treatise on Abdominal Tumors. 1861.
- BROCA, P. Traités des Tumeurs. 1866.
Des Anéurismes et de leur Traitement. Paris, 1856.
- BRODHURST, B. E. Article on Congenital Dislocations. 1856.
Monograph on the Deformities of the Human Body. 1871.
- BRODIE, SIR BENJ. Treatise on Joints. 1848.
Lectures on Pathology and Surgery.
- BRYANT, THOS. A Manual of the Practice of Surgery. Philadelphia, 1879.
- BUMSTEAD, F. Pathology and Treatment of Venereal Diseases. 1861.
- CALLAWAY. Treatise on Dislocations and Fractures in the Vicinity of the Shoulder Joint.
- CALENDER, GEO. W. Article on Pyæmia. (Holmes' Surgery.)
Article on Diseases of the Veins.
- CASPAR, J. L. Hand-book of Forensic Medicine. 1861.
- CLARK, F. LE GROS. Lectures on Surgical Diagnosis. London, 1870.
- COLLES, ABRAHAM. Lectures on Surgery. 1845.
Article on Aneurismal Sacs. Dublin Quarterly, 1856.
- COOPER, SIR ASTLEY. Monograph on Fractures and Dislocations near Joints. 1842.
Anatomy and Surg. Treatment of Hernia.
Monograph on Diseases of the Breast. 1829.
- COOTE, HOLMES. Article on Injuries of the Face. (Holmes' Surgery.)
Articles on Abscess and Gangrene. " " "
Treatise on Diseases of the Joints. London, 1867.
- CURLING, T. B. Treatise on Diseases of the Testicle. London, 1846.
Observations on Diseases of the Rectum. " 1851.
- DE COSTA, J. M. Medical Diagnosis. 1864.
- DUPUYTREN, BARON. Injuries and Diseases of the Bones. London, 1847.
- ERICHSEN, JOHN. Monograph on Aneurism. London, 1844.
Science and Art of Surgery. Philadelphia, 1854.
Diseases of the Scalp. London, 1843.
- ESMARCH. Monograph on the Use of Cold in Surgery. 1861.

- FERGUSON, WM. A System of Practical Surgery. London, 1842.
Progress of Anatomy and Surgery during the Present Century. London, 1867.
- FLOWER, W. H. Article on Injuries of the Upper Extremity. (Holmes' Surgery.)
- FREER, GEORGE. Monograph on Aneurism. 1807.
- GAY. Monograph on Diseases of Veins. 1868.
- GOULEY, J. W. S. Diseases of the Urinary Organs. New York, 1873.
- GRAY, HENRY. Anatomy, Descriptive and Surgical. Philadelphia, 1878.
- GREEN, T. HENRY. Pathology and Morbid Anatomy. Philadelphia, 1871.
- GROSS, SAML. D. Work on Surgery.
Monograph on Urinary Organs. 1851.
Anatomy and Diseases of Bone and Joints. Boston, 1839.
- GUTHRIE, G. J. Monograph on Injuries of the Head. London, 1842.
Injuries and Wounds of Arteries. " 1846.
- HAMILTON, F. H. Monograph on Fractures. 1860.
- HAMILTON, WM. A History of Anatomy and Surgery from the Creation to the 19th Century. London, 1831.
- HEY, WM. Practical Observations in Surgery. Philadelphia, 1805.
- HENNEN, JOHN. Work on Military Surgery. London, 1820.
- HEWITT, PRESCOTT. Article on Injuries of the Head. (Holmes' Surgery.)
- HILTON, JOHN. Rest and Pain. London, 1863.
N. Y., 1878.
- HODGSON, JOS. Diseases of Arteries and Veins. 1815.
- HOLMES, T. Surgical Treatment of Diseases of Childhood. 1869.
Essay on Aneurism. (Holmes' Surgery.)
Article on Diseases of Bone.
- HOLTHOUSE, CARSTEN. Injuries of the Lower Extremities.
- HOWSHIP, JOHN. Discriminations in Surgical Diseases. 1840.
- HUMPHREY, G. M. Articles on Diseases of the Male Organs. (Holmes' Surgery.)
- HUNTER, JOHN. Essay on Venereal. (Bumstead.) 1853.
Works. Edited by Palmer.
- HUTCHINSON. Injuries to the Elbow Joint and its Vicinity. 1856.
- JOHNSTONE, A. A. Diseases of Joints. (Holmes' Surgery.)
- LAWRENCE, WM. Treatise on Ruptures.
- LEE, HENRY. Monograph on Phlebitis.
Monograph on Syphilis. London, 1863.
Lectures on Practical Surgery. London, 1870.
- LIXTON, ROBT. Work on Practical Surgery. Philadelphia, 1846.
- LITTLE, W. J. Monograph on Deformities of the Human Frame. London, 1853.
- LOOMIS, A. L. Work on Physical Diagnosis. New York, 1876.
- LONSDALE, EDW. A Practical Treatise on Fractures. London, 1848.
- MACLEOD, G. II. B. Work on Surgical Diagnosis. New York, 1864.
- MACLISE, JOS. Dislocations and Fractures. 1858.
- MARKOE, T. M. A Treatise on Diseases of Bone. New York, 1872.
- MALGAIGNE, I. F. *Traité des Fractures*. 1855.
Translation by Packard. Philadelphia, 1859.
- MILLER, JAS. Principles of Surgery. Edinburgh, 1864.
- MOORE, C. H. Article on Cancer and Tumors. (Holmes' Surgery.)
" " Injuries to Vessels. " "
- PAGET, SIR JAS. Work on Tumors.
Lectures on Surgical Pathology. London, 1870.
- PEASLEE, E. R. Monograph on Ovarian Tumors. 1872.

- PIRRIE, W. Principles and Practice of Surgery. London, 1860.
- POLAND, ALFRED. Article on Injuries to the Chest.
Prize Essay on Injuries to the Abdomen.
- POLLOCK, GEORGE. Article on Injuries to the Abdomen. (Holmes' Surgery.)
- PORTER. Monograph on Aneurism.
- PANCOAST, JAS. Treatise on Operative Surgery. Philadelphia, 1844.
- POTT, PERCIVAL. Chirurgical Works. London, 1808.
- QUAIN, J. Work on Anatomy. New York, 1877.
- QUAIN, RICH. "Diseases of the Rectum." London, 1854.
- RICORD, PH. Treatise on Venereal. (Drummond.) 1854.
- ROKISTANSKY. Treatise on Pathological Anatomy. London, 1854.
- ROUX, JOS. Essay on Osteo-Myelitis.
- SANDERSON, J. B. Tubercle and Lymphoma. 1869.
- SAVORY, WM. S. Article on Serofulous Diseases. (Holmes' Surgery.)
- SAYRE, LEWIS A. Diseases of Joints.
Monograph on Orthopedic Surgery.
- SCARPA, ANTONIO. Translation of Treatise on Hernia. 1814.
Translation of Treatise on Aneurism. (Wishart.) 1808.
- SHAW, A. Diseases of the Spine. (Article in Holmes' Surgery.)
- SKEY, F. C. Work on Operative Surgery. 1850.
- SMITH, HENRY. Article on Diseases of the Rectum.
- SMITH, R. W. Treatise on Fractures in the Immediate Vicinity of Joints. Dublin, 1847.
- STANLEY, EDW. Treatise on Diseases of Bone. London, 1849.
- SYME, I. Observations on Chemical Surgery. Edinburgh, 1861.
- THOMAS, T. G. Treatise on Diseases of Women. Philadelphia, 1876.
- THOMPSON, SIR HENRY. { Monograph on Stricture of the Urethra. Philadelphia, 1869.
Diseases of the Urinary Organs. Philadelphia, 1869.
Monograph on the Enlarged Prostate. London, 1858.
- TRAVERS, BENJ. Monograph on Injury to the Intestines. London, 1812.
- TODD, BENJ. Treatise on Urinary Diseases. Philadelphia, 1857.
- VAN BUREN, WM. H. Monograph on Diseases of the Rectum. 1873.
- VAN BUREN and KEYES. Genito-Urinary Diseases and Syphilis. New York, 1874.
- VELPEAU, A. L. M. Works on Surgery (Mott). 1847.
Monograph on Cancer. 1840.
- VIRCHOW, R. Cellular Pathology. 1871.
- WARDROP, JAS. Essay on Aneurism. London, 1828.
- YEAR BOOK ON SURGERY. Sydenham Soc. Trans. 1861.
- ZIEMSEN. Article on Diseases of the Vessels.

INDEX OF SUBJECTS.

	PAGE		PAGE
ABDOMEN, contusion of.....	270	Antrum, cystic tumors of.....	80
wounds of.....	270	malignant tumors of.....	80
Abdominal aneurism.....	11	solid tumors of.....	79
Abdominal cavity, diseases of.....	270	Anus, condylomata of.....	285
Abdominal diseases with pain.....	12	fissure of.....	275, 289
Abscess, acute.....	319	pruritus of.....	275
Abscess and local œdema.....	318	Aortic pulsation.....	9
chronic or cold.....	319	Arthritis, acute.....	36
faecal.....	273	and abscess of bone.....	73
iliac.....	320	and syphilitic periostitis... ..	38
mammary acute.....	349	and suppuration near a joint	39
mammary chronic.....	349	chronic rheumatic.....	36
of abdominal wall.....	320, 322	rheumatic of jaw.....	89
of antrum.....	79, 346	Ascites.....	363
of bone.....	73	Astragalus, dislocations of... ..	128, 129, 130
over a vessel.....	10	Balanitic abrasion.....	268
pelvic.....	365	Balanitis.....	261
perineal.....	256	Barton's fracture.....	172
psoas.....	13, 47, 300, 321	Bladder, atony of.....	235, 243
Anchylosis.....	40	bar of.....	234
Aneurism, abdominal.....	11, 12	calculi of.....	235, 238
and abscess.....	10	cancer of.....	238
and aneurismal varix.....	20	deficiency of.....	233
and encephaloid cancer... ..	19	diseases of (classification)... ..	233
and erectile tumors.....	8	extroversion of.....	233
and psoas abscess.....	13	foreign bodies in.....	235
and a relaxed aorta.....	9	hernia of.....	234
and tumor on an artery... ..	7	hypertrophy of.....	234
cirroid and erectile tumors.	22	inflammatory conditions of..	234
cirroid and nœvi.....	23	inversion of.....	234
cirroid and pulsatile bone	18	malformations of.....	233
tumors.....	18	multiplicity of.....	233
classification.....	4, 5	neuralgia of.....	235
of arch of the aorta.....	24	paralysis of.....	235, 243
of bone and cancer.....	16	spasm of.....	235
of innominate artery.....	24	tubercle of.....	235
thoracic and thoracic tu-	14	tumors of.....	234
mors.....	14	Boils.....	317
thoracic and pul. consoli-	15	Bone, abscess of.....	73
dation.....	15	aneurism of.....	16
varicose and aneurismal	25	cancer of.....	76
varix.....	25	caries of.....	70
varicose and varicose veins	26	cysts of (spina ventosa).....	75
Aneurismal varix.....	20	diseases of (classification)... ..	67
and varicose aneurism	25	exostoses of.....	75, 342
Ankle, congenital deformities of... ..	132	inflammation of.....	69, 71
dislocations of.....	127, 131	malacosteon.....	74
fractures in vicinity of.....	189	necrosis of.....	70
sprain of.....	63, 131	pulsatile tumors of.....	18, 76
Anomalies of the penis.....	264	rickets of.....	74
Anthrax.....	317	Brain, compression of.....	146
Antrum, abscess of.....	79, 346	concussion of.....	146

	PAGE		PAGE
Brain, dropsy of.....	344	Dislocation, Radius alone, backwards.....	105
Breast, abscess of.....	349	Radius forwards.....	105
cysts of.....	351	Ulna forwards.....	106
glandular tumors of.....	350	<i>of the hip</i> (table).....	114
hypertrophy of.....	351	congenital.....	45
scirrhus of.....	352	" Dorsum ilii ".....	115
tumors (innocent).....	352	" Pubic ".....	117, 186
tumors of (classification).....	348	" Sciatic notch ".....	115, 116, 185
Bubo.....	295	" Thyroid ".....	117
Bubonocele.....	296	<i>of the jaw</i>	86, 87
Cancer, colloid.....	337	congenital of jaw.....	88
encephaloid.....	19, 335	<i>of the knee joint</i> (table).....	121
epithelioma.....	336	Patella inwards.....	125
of axillary glands.....	338	Patella outwards.....	125
of omentum.....	339	Patella by rotation.....	126
of rectum.....	288	Patella upwards.....	126
scirrhus.....	335, 337	Tibia backwards.....	123
Cancerous tumors.....	332	Tibia forwards.....	123
Carbuncle.....	317	Tibia by rotation.....	124
Caries of bone.....	71	Tibia laterally.....	124
Cephalæmatoma.....	345	<i>of the shoulder joint</i> (table).....	90
Cerebral compression.....	146	" sub-clavicular ".....	93
concussion.....	146	" sub-coracoid ".....	95
Chancre.....	266	" sub-glenoid ".....	91, 162
Chancroid.....	266	" sub-spinous ".....	93, 164
Chinese foot.....	60	" supra-coracoid ".....	95
Clavicle, dislocations of.....	96	of the scapula.....	97
fractures of.....	155, 156, 157	<i>of the wrist joint</i> (table).....	107
Colles' fracture.....	172, 174	Symptoms.....	108, 110, 174
Colloid cancer.....	337	Os magnum.....	113
Compression of the brain.....	146	Elbow, dislocations of.....	97
Concussion of the brain.....	146	fractures in vicinity of.....	165, 166
Condylomata of anus.....	285	Elephantiasis.....	314
Contusion of the hip.....	119	Embolism of vessels.....	28
Corpora cavernosa, diseases of.....	263, 264	Emphysema of tissues from fracture of the ribs (diagnosis).....	198
Cystitis acute.....	242	Enecephaloid cancer.....	335
chronic.....	244	Encephalocele.....	344, 345
varieties of, etc.....	234	Epididymitis.....	214
Cysts of breast.....	350	Epithelioma.....	336, 347
of kidney.....	366	Epithelioma of penis.....	261
of ovary.....	360	Erectile tumors.....	8
Deformities of ankle.....	57	Erysipelas.....	314
of joints (table).....	55	cutaneous.....	324
Diagnostic points of tenderness in joint inflammations.....	55	phlegmonous.....	324
Diseases of abdominal cavity.....	269	Exostoses of bone.....	75
blood-vessels (table).....	3	cranium.....	82
bone (table).....	67	Exomphalos.....	304
joints (table).....	33	Fatty degeneration of vessels.....	27
male genitals (table).....	203	Fatty tumor of thigh.....	303
testicle (diagnostic table).....	216	of scalp.....	341
tissues (classification).....	311	Femur, dislocations of at hip.....	114
Dislocation.....	85	(diagnostic table).....	120
and fracture in general... ..	199	fracture of (varieties).....	178, 187
of the ankle (table).....	127	fracture of with inversion of foot.....	116, 185
of the ankle.....	128, 129, 130	Fissure of the anus.....	289
of the clavicle (table).....	96	Fistula of the rectum.....	289
<i>of the elbow joint</i> (table).....	97	Flat foot.....	62
both bones backwards.....	101, 102	Forearm, dislocation backwards.....	99
Radius forwards, ulna backwards.....	101	fracture at wrist.....	110, 175
Both bones forwards... ..	102	separation of epiphyses.....	111, 176
Ulna alone, backwards.....	104, 106	Fracture.....	135
		and dislocation.....	199
		its general symptoms.....	136

	PAGE		PAGE
Fracture <i>at the ankle</i> (table).....	189	Hemorrhoids internal.....	284
both bones transversely... 189		Herpes progenerialis.....	261, 268
Pott's fracture.....	190	Hernia, causes of.....	278
internal malleolus.....	190	classification of.....	276
compound of ankle.....	191	congenital.....	230, 308, 307
<i>near the wrist joint</i> (table)..	172	diaphragmatic.....	306
Colles' fracture.. 108, 172, 174		differential diagnoses (table)..	280
transverse of both bones..	175	femoral.....	299, 301, 302
<i>of the clavicle</i> (table).....	155	infantile.....	308
inside of coracoid process..	157	inguinal.....	231, 297, 302
outside of coracoid process	157	inguinal (direct).....	290
<i>of the femur at the hip</i> (vari-		inguinal (indirect).....	290
eties, etc.).....	178	inguinal (incomplete).....	295
extra-capsular simple.....	183	perineal.....	305
extra-capsular impacted..	181	scrotal.....	226, 291, 293
intra-capsular simple.....	183	thyroid.....	305
intra-capsular impacted..	181	testis (benign fungus)..	206, 213
with inversion of foot....	185	umbilical.....	304
<i>of the femur at the knee</i> ... 187		ventral.....	304
of the leg bones at the knee.	187	Hip Joint, contusion of.....	119
of the patella.....	188	dislocation (congenital)....	45
<i>of the humerus at the shoul-</i>		dislocations of (diagnostic	
<i>der joint</i> (table).....	158	table).....	120
extra-capsular simple... 159		deformity, rheumatic.....	51
extra-capsular impacted..	161	fractures in vicinity of... 178	
intra-capsular simple.... 159		Humerus, dislocations (table).....	90
intra-capsular impacted..	161	fracture above condyles... 99	
separation of great tuber-		fractures of at elbow..... 165	
cle.....	164	fractures of at shoulder... 158	
<i>of the humerus at the elbow</i>		fracture of (extra-capsular)	159
(table).....	165	fracture of (intra-capsular)	159
inner condyle.....	168	fracture of (impacted).... 161	
outer condyle.....	168	separation of the great tu-	
transverse above condyles	167	bercle.....	164
T-shaped fracture.....	165	Hydrarthrosis.....	35
of the lower jaw.....	148, 150	Hydrocele.....	212, 218
of the upper jaw.....	148	and congenital hernia.... 230	
of the scapula (varieties)... 151		and scrotal hernia..... 226	
of the body of the scapula.. 152		congenital.....	220
of the neck of the scapula.153,163		encysted.....	220
of the spine of the scapula.. 152		encysted and cyst of testis	229
Fractures <i>of the skull</i> (varieties)....	139	multilocular.....	219
complete fracture.....	142	of cord and inguinal hernia	231
inner table only.....	143	of spermatic cord (diffuse).	221
outer table only.....	142	“ “ “ (encysted).....	222
of the base.....	145	of tunica vaginalis (encyst-	
Fractures of the sternum.....	193	ed).....	221
of the ulna at elbow.....	166	Hydro-sarcocele.....	220
coronoid process.....	169	Ilium, disease of.....	52
olecranon “.....	171	Impaction of feces.....	296
upper end of shaft.....	171	Induration of tissues.....	311
of the vertebræ.....	193	Infantile paralysis of hip.....	54
Furuncle.....	317	Intestine, diseases of (table).....	273
Ganglion at wrist.....	114	foreign bodies in.....	272
Gangrene of tissues.....	313	obstruction of.....	273, 283
dry.....	323	Jaw, dislocation of.....	86, 87
moist.....	323	“ (congenital).....	88
hospital.....	314	fractures of.....	148
Glans penis, diseases of.....	261	Joints, Ankle, sprain of.....	63
Glands of groin (enlarged).....	299	“ dislocations of.....	127
cancer of.....	338	“ fractures of.....	189
tubercle of.....	339	deformities of.....	55
Hæmatocele of testis.....	218	diseases of (table).....	33
Hemorrhoids.....	274	diagnostic points of tenderness	
external.....	284, 285	of.....	55

	PAGE		PAGE
Joints, dropsy of.....	35	Penis, Balanitis.....	261
Elbow, dislocations of.....	97	Posthitis.....	261
" fractures of.....	165	Herpes.....	261
Hip, diagnosis of diseases of..	43	Vegetations.....	262
" diseases of.....	40	Veneral sores.....	262, 266
" dislocations of.....	114	Epithelioma.....	262
" fractures of.....	178	diseases of the prepuce.....	262
Knee, dislocations of.....	121	Phimosis.....	262
" fractures of.....	187	Paraphimosis.....	263
rheumatism of.....	34	Pelvis, cellulitis of.....	368
Shoulder, dislocations of.....	90	hæmatocele of.....	370
" fractures of, 151, 155,	158	peritonitis.....	369
Wrist, dislocations of.....	107	tumors of (table).....	368
" fractures of.....	172	Perineal abscess.....	256
Knee, dislocations of.....	121	Perineal hernia.....	305
fractures in vicinity of.....	187	Periostitis acute.....	71
Lupus.....	315, 347	syphilitic.....	38
Malacosteon of bone.....	74	near a joint.....	72
Mollities ossium.....	74	Perityphlitis.....	282
Morbus coxarius, diagnosis of.....	43	Phlebitis adhesive.....	29
and congenital dis-		suppurative.....	29
location of hip	45	Pleurisy with contusion.....	196
and disease of ilium	52	Pneumo-thorax.....	197
and disease of tro-		Polypus of rectum.....	286
chanter.....	49	Posthitis.....	261
and infantile paraly-		Potts' fracture.....	190
sis.....	54	Prepuce, diseases of.....	262
and psoas abscess..	47	Prolapse of the rectum.....	287
and rheumatic de-		Prostate, atrophy of.....	246
formity.....	51	calculi of.....	247
and sacro-iliac dis-		cancer of.....	246
case.....	48	cystic disease of.....	246
and spinal curvature	50	diseases of (table).....	245
Nævi.....	23	hemorrhage of.....	247
Necrosis of bone.....	70	hypertrophy of.....	245, 250
Œdema, local.....	318	phlebolites of.....	247
Omphalocœle.....	304	tubercle of.....	246
Orchitis, chronic.....	207	wounds of.....	247
malignant.....	204, 211	Prostatic abscess.....	245
simple inflammatory.....	203, 209	enlargement.....	250
specific.....	204, 210	Prostatitis, acute.....	245, 249
tubercular.....	204, 210	chronic.....	245, 249
Os magnum, dislocation of.....	113	Psoas abscess.....	13, 47
Osteitis.....	69, 71	Psoas bursa, inflammation of.....	53
Osteo-malacia.....	74	Pulmonary consolidation and thoracic	
Osteo-mycelitis.....	69	aneurism.....	15
Ovary, cysts of.....	360	Radius, Barton's fracture of.....	172
cyst (unilocular).....	366	Colles' fracture of.....	172
dropsy of.....	363	dislocations of.....	105
fluid tumors of.....	365	fractures of at elbow.....	160, 171
tumors of (classification).....	362	fractures of at wrist.....	172
tumors of (diagnosis).....	367	Rectum, cancer of.....	275, 288
tumors of (solid).....	359	diseases of (table).....	274
Painful diseases of abdomen.....	12	fissure of.....	275, 289
Paralysis, infantile of hip.....	54	fistula of.....	274, 289
Patella, dislocations of (table).....	121	hemorrhoids of.....	274, 284
dislocations (special varic-		neuralgia of.....	276
ties).....	125, 129	polypus of.....	275, 286
Penis, anomalies of.....	264	prolapse of.....	274, 287
diseases of corpora cavernosa..	263	pruritus of.....	275
inflammation of.....	263	stricture of.....	275
calcification of.....	263	Retraction of the testicle.....	225
gummata of.....	263	Rheumatic arthritis of jaw.....	89
fracture of.....	263	Rheumatic deformity of hip.....	51
diseases of glans.....	261	Rheumatism of joints.....	43

	PAGE		PAGE
Ribs, fractures of (table).....	194	Tibia, fractures of.	187, 189, 190
fracture of and emphysema.....	198	Tissues, diseases of.....	311
fracture of and pleurisy.....	196	elephantiasis.....	314
fracture of and pneumothorax..	197	erysipelas.....	314
Rupture of the triceps tendon.....	170	gangrene of.....	313
Sacro-iliac disease.....	48	induration of.....	311
Sarcocele.....	291	lupus.....	315
Sarcoma, cystic of testicle.....	204	suppuration of.....	311
Scapula, dislocation of.....	97	tumefaction of.....	311
fracture of.....	151	tumors of.....	325
Scrotal hernia and hydrocele.....	226, 292	ulceration of.....	312
and varicocele.....	293	Trochanter of femur, disease of.....	49
and sarcocele.....	291	contusion of.....	119
and hæmatocele.....	291	Tubercular disease of axilla.....	339
Scirrhus.....	335, 337	Tumors.....	325
Separation of greater tubercle of the		abdominal.....	11
humerus.....	94, 164	benign (symptoms).....	334
Shoulder, dislocations of (table).....	90	colloid.....	337
fractures of.....	155	cystic (classification of).....	327
Skull, fractures of (varieties).....	139	encephaloid.....	335
tumors.....	340	epithelioma.....	336
Spasm of erector muscle.....	225	erectile.....	8, 22
Spermatic cord, diseases of.....	219	exostoses of cranium.....	82
hydrocele of.....	222	extra cranial.....	81, 341
lipoma of.....	223	fatty of scalp.....	341
varicocele of.....	225	intra-cranial.....	81, 341
Spina ventosa.....	75	malignant.....	332, 334
Spinal curvature.....	50	malignant of bone.....	76
Sprain of ankle joint.....	63	mediastinal.....	306
Sternum, fracture of.....	193	of antum (cystic).....	80
Stone in the bladder.....	238	“ “ (malignant).....	80
Stricture of rectum.....	288	“ “ solid.....	79
of urethra (organic).....	250, 259	of axilla (table).....	331
“ (congestive).....	253	of bladder (table).....	234
“ (spasmodic).....	253	of breast (table).....	348
Suppuration of tissues.....	311	of groin.....	331
Talipes calcaneo-valgus.....	60	of head (table).....	328, 340
equinus.....	59	of neck (table).....	329
equinus with paralysis of the		of ovary (table).....	362
flexors of tarsus.....	59	of rectum (table).....	275
spurio-valgus.....	60, 63	of testicle, cartilaginous.....	206
valgus.....	58, 61	cystic.....	204
varieties of (table).....	57	fatty.....	205
varus.....	58	fibrous.....	205
Testicle, benign fungus of.....	206	hæmatocele.....	205
calcareous deposit in.....	208	malignant.....	204
cancer of.....	204, 212	of the trunk (table).....	330
cartilaginous tumor of.....	206	of urethra.....	253, 260
cheesy degeneration of.....	204	of uterus (table).....	354
chronic inflammation of.....	207	pulsatile.....	18
cysts of.....	204, 212, 229	pulsatile of bone.....	76, 78
diseases of (table).....	203, 207	scirrhus.....	335, 337
diseases of (diagnostic table).....	216	sebaceous.....	82, 341, 343
fatty tumor of.....	205	solid (classification of).....	326
fibrous tumor of.....	205	thoracic.....	14
hæmatocele of.....	205	Tunica vaginalis, diseases of.....	219
hernia of.....	206, 213	Typhlitis.....	282
malformations of.....	207	Ulceration of tissues.....	312
malignant fungus of.....	213	Ulna, dislocation of, at elbow.....	104, 106
neuralgia of.....	207, 209	dislocation of, at wrist.....	112
specific deposit in.....	204	fractures of, at elbow.....	166
undescended.....	297	fractures of, at wrist.....	172
Thrombosis.....	28	separation of epiphyses of.....	111
Tibia, dislocation of.....	121	Undescended testicle.....	312
dislocation of (spec. varieties).....	123, 124	Urine, incontinence of.....	236, 241

	PAGE		PAGE
Urine, overflow of.....	236	Uterus, retained menstrual blood in	
retention of.....	235, 239	cavity of.....	357
suppression of.....	240	tumors of (table).....	354
Urethra, abscess of.....	253	Vagina, polypus of.....	371
calculi of.....	253	Varicocele of spermatic cord.....	223
congestive stricture of.....	253	causes (table).....	224
deformities of.....	253	Varicose aneurism.....	26
dilatation of.....	252	Varicose veins.....	26
diseases of (table).....	251	Varix of the saphenous vein.....	301
fistula of.....	253	Vegetations of penis.....	261
foreign bodies in.....	254	Veins, diseases of (table).....	3
inflammations of.....	251	inflammation of.....	29
rupture of.....	252, 256, 257	varicose.....	26
spasm of.....	253	Vertebra, fracture of.....	192
stricture of.....	251, 259	Vessels, atheroma of.....	27
tumors of.....	253, 260	diseases of.....	3
Uterus, congestive hyperæmia of.....	355	embolism of.....	28
early pregnancy of.....	355	fatty degeneration of.....	28
fibroid tumors of.....	356, 359	thrombosis of.....	27
fibro-cysts of.....	360	White swelling of knee.....	35
hydatids of.....	358	Wrist, dislocations of.....	107, 174
inversion of.....	371	fractures in the vicinity of....	172
polypus of.....	361	ganglion at.....	113
pregnancy of.....	357, 358	sprain of.....	109
pregnancy (extra uterine)....	370		



NATIONAL LIBRARY OF MEDICINE



NLM 00554811 9