





THOS. GILBERT,  
Printer & Binder,  
OFF. POST OFFICE,  
Columbus, Ga.

THE  
ABNER WELLDORN CALHOUN  
MEDICAL LIBRARY  
1923



CLASS     R    

BOOK \_\_\_\_\_

PRESENTED BY \_\_\_\_\_

George S. Murray

Columbus

1946.

Ga



PHOTOGRAPHIC ILLUSTRATIONS  
OF  
SKIN DISEASES.

BY

GEORGE HENRY FOX, A.M., M.D.,

*Clinical Professor of Dermatology, Starling Medical College, Columbus, O.; Surgeon to the New York Dispensary, Department of Skin and Venereal Diseases; Fellow of the American Academy of Medicine; Member of the New York Dermatological Society, the American Dermatological Association, etc.*

---

FORTY-EIGHT PLATES FROM LIFE

COLORED BY HAND.

---

NEW YORK:  
E. B. TREAT, No. 737 Broadway.  
1880.

COPYRIGHT,  
GEORGE HENRY FOX,  
1879.

[ALL RIGHTS RESERVED.]

ARTOTYPE,  
HOBBS & BRISTOLT,  
NEW YORK.

SAMUEL STODER,  
STEREOTYPE,  
40 ANN STREET, N. Y.

## PREFACE.

---

THE study of Skin Diseases without cases or colored plates is like the study of osteology without bones, or the study of geography without maps. However comprehensive or practical a text-book may be, its verbal descriptions cannot compare in value with a sight of the thing described, or, what is next best, its faithful representation. A systematic course of clinical study is only possible in our large cities, and yet the physician in any remote locality may be called upon to treat the rarest forms of skin disease. As success must depend in great measure upon the correctness of his diagnosis, it is hardly necessary to argue the value of a complete series of well-executed plates.

Of late the steadily increasing interest in dermatology has led to a demand for illustrations of skin diseases. Photographs, though serving a good purpose in portraying the characteristic location and configuration of the various affections of the skin, have generally lacked an essential element of diagnosis, viz., the color, or have been disfigured by careless daubing, and colored lithographs have not only been expensive, but in too many instances lacked fidelity to nature both in form and color.

In the series of illustrations now offered to the profession, advantage has been taken of a process recently devised for the reproduction of pictures from photographic negatives. These pictures not only possess the sharpness of detail and brilliancy of ordinary photographs, but, unlike the latter, will not fade through age and exposure to light. The negatives which serve as a basis for the plates of this series have been selected from a very large number, most of which were taken under the immediate supervision of the editor. A few have been collected from other sources. The coloring has been entrusted to a skilful artist, who was formerly a physician, and, having studied skin diseases in the General Hospital at Vienna, is peculiarly fitted for the work. The text accompanying the plates is designed to call attention to the diagnostic characters of the various diseases, and to give in brief some practical suggestions for their treatment. The notes of cases have been made very brief, as a rule, inasmuch as it has seemed unnecessary to give full particulars of a case except where it has possessed points of special interest. No systematic order has been followed in the arrangement of diseases, although certain ones have been placed together with a view to their contrast. On a number of the plates will be found a double illustration, showing different stages or phases of the same disease.

It has been the aim of the author to represent in this series nearly all of the rare as well as the common affections of the skin, with the exception of the Syphilodermata; to present their features *with photographic accuracy*, and to employ color with the utmost care to render the illustrations as life-like as possible. The cutaneous manifestations of Syphilis are so varied and important that merely one or two illustrations would be of little value. It has therefore been deemed advisable to reserve this field for a second work, and to make the present one a more complete series of non-syphilitic affections.

GEORGE HENRY FOX.



# CONTENTS

AND

## LIST OF ILLUSTRATIONS,

WITH SYNONYMOUS TERMS.

	PAGE
ACNE VULGARIS, . . . . .	9
ALOPECIA AREATA, . . . . .	97
CHROMOPHYTOSIS, . . . . .	33
COMEDO, . . . . .	7
CORNUA CUTANEA, . . . . .	95
ECZEMA BARBE, . . . . .	47
ECZEMA CRURIS, . . . . .	37
ECZEMA ICHOROSUM, . . . . .	43
ECZEMA INFANTILE, . . . . .	39
ECZEMA MANUM, . . . . .	49
ECZEMA PAPULOSUM, . . . . .	41
ECZEMA PUSTULOSUM, . . . . .	43
ECZEMA SQUAMOSUM, . . . . .	45
ECZEMA UNIVERSALE, . . . . .	29
ECZEMA E VENIS VARICOSIS, . . . . .	51
ELEPHANTIASIS, . . . . .	18
EPITHELIOMA, . . . . .	61
EPITHELIOMA RODENS, . . . . .	59
EPITHELIOMA SUPERFICIALE, . . . . .	59
ERYTHEMA CIRCINATUM, . . . . .	91
ERYTHEMA EXFOLIATIVUM, . . . . .	91
ERYTHEMA MULTIFORME, . . . . .	77
FAVUS CAPITIS, . . . . .	35
FAVUS CORPORIS, . . . . .	35
FIBROMA PENDULUM . . . . .	28
HERPES FACIALIS, . . . . .	87

CONTENTS.

	PAGE
HYDROA BULLOSUM, . . . . .	89
ICHTHYOSIS SIMPLEX, . . . . .	21
KELOID, . . . . .	15
KERION, . . . . .	71
	( <i>Tinea kerion,</i> )
LEPRA MACULOSA, . . . . .	73
	( <i>Elephantiasis Græcorum,</i> )
LEPRA TUBEROSA, . . . . .	11
	( <i>Elephantiasis Græcorum,</i> )
LEUCODERMA, . . . . .	31
	( <i>Vitiligo,</i> )
LICHEN PLANUS, . . . . .	67
LICHEN RUBER, . . . . .	69
LUPUS ERYTHEMATOSUS, . . . . .	57
	( <i>L. erythematodes,</i> )
LUPUS VULGARIS, . . . . .	55
	( <i>L. non-cædens.—L. tuberculosus,</i> )
MOLLUSCUM, . . . . .	75
	( <i>Molluscum contagiosum or sebaceum,</i> )
MORPHŒA, . . . . .	99
	( <i>Addison's keloid,</i> )
PORRIGO E PEDICULIS, . . . . .	85
	( <i>Porrigo or impetigo contagiosa,</i> )
PHITHEIRIASIS CAPITIS, . . . . .	79
	( <i>Pediculosis capitis,</i> )
PHITHEIRIASIS CORPORIS, . . . . .	81
	( <i>Pediculosis corporis,</i> )
PSORIASIS ANNULATA, . . . . .	53
PSORIASIS NUMMULATA, . . . . .	19
PURPURA SIMPLEX, . . . . .	93
ROSACEA, . . . . .	17
	( <i>Acne rosacea.—Gutta rosea,</i> )
SARCOMA PIGMENTOSUM, . . . . .	101
	( <i>Melanosis.—Melanosarcoma,</i> )
SCABIES, . . . . .	83
SCLERODERMA, . . . . .	19
TRICHOPHYTOSIS CAPITIS, . . . . .	63
	( <i>Tinea trichophytina tonsurans,</i> )
TRICHOPHYTOSIS CORPORIS, . . . . .	65
	( <i>Tinea trichophytina circinata,</i> )
ULCUS VARICOSUM, . . . . .	51
VARICELLA, . . . . .	25
ZOSTER PECTORALIS, . . . . .	27
ZOSTER LUMBALIS, . . . . .	27
	( <i>Herpes zoster.—Zona,</i> )

# CLASSIFICATION & NOMENCLATURE OF DISEASES OF THE SKIN.

- Class I. Glandular Affections.  
 " II. Inflammatory Affections.  
 " III. Hemorrhagic " "  
 " IV. Hypertrophic " "

- Class V. Atrophic Affections.  
 " VI. Neoplastic " "  
 " VII. Neurotic " "  
 " VIII. Parasitic " "

## Class I.—Glandular Affections.

### A. SEBACEOUS.

1. Seborrhoea. *a.* oleosa.  
*b.* sicca.
2. Comedo.
3. Milium.
4. Cystis sebacea.

### B. SUDORIPAROUS.

1. Hyperidrosis.
2. Anidrosis.
3. Bromidrosis.
4. Chromidrosis.
5. Dysidrosis.
6. Sudamina.

## Class II.—Inflammatory Affections.

1. Rubella (or Measles).
2. Rubella (or Rotheln).
3. Scarlatina.
7. Erythema. *a.* simplex. *b.* exfoliativum.
8. Intertrigo.
9. Erythema multiforme. *a.* papulosum.  
(or *E. exudativum*). *b.* tuberculosum.  
*c.* circinatum. *d.* nodosum.
10. Urticaria.
11. Dermatitis. *a.* calorica. *b.* venenata. *c.* traumatica.
12. Eczema. *a.* erythematosum.  
*b.* papulosum (or Lichen simplex).  
*c.* vesiculosum.  
*d.* pustulosum (or Impetigo).  
*e.* ichorosum (or *E. rubrum*).  
*f.* squamosum.
13. Pityriasis.
14. Dermatitis exfoliativa.
15. Psoriasis.
16. Lichen testivus (or Lichen tropicus).
17. Lichen planus.
18. Lichen ruber.
19. Lichen scrofulosus.
20. Prurigo. *a.* mitis. *b.* ferax.
21. Herpes. *a.* facialis. *b.* progentialis.
22. Zoster.
23. Hydroa.
24. Pemphigus. *a.* vulgaris. *b.* foliaceus.
25. Pompholyx.
26. Acne. *a.* vulgaris. *b.* indurata.
27. Sycosis.
28. Forrigo.
29. Ecthyma.
30. Fistula maligna.
31. Erysipelas.
32. Furunculus.
33. Anthrax.
34. Ulcus.
35. Onychia.

## Class III.—Hemorrhagic Affections.

1. Purpura. *a.* simplex. *b.* papulosa. *c.* rheumatica. *d.* hemorrhagica.
2. Scorbutus.
3. Hematidrosis.

## Class IV.—Hypertrophic Affections.

### A. OF PIGMENT.

1. Lentigo.
2. Chloasma.
3. Melanoderma.
4. Nevus pigmentosus.
5. Morbus Addisonii.

### B. OF EPIDERMIS AND PAPILLÆ.

1. Callositas.
2. Clavis.
3. Verruca.
4. Molluscum.
5. Cornu cutaneum.
6. Keratosis pilaris.
7. Ichthyosis.

### C. OF CORIUM.

1. Sclerema.
2. Scleroderma.
3. Morphea.
4. Elephantiasis.
5. Rosacea.

### D. OF HAIR.

1. Hirsuties. *a.* partialis. *b.* universalis.
2. Nevus pilosus.
- E. OF NAIL.
1. Onychogryphosis.
2. Onychauxis.

## Class V.—Atrophic Affections.

### A. OF PIGMENT.

1. Albinismus. *a.* universalis. *b.* partialis.
2. Leucoderma (or *Vitiligo*).
3. Canities.

### B. OF HAIR.

1. Alopecia.
2. Alopecia areata.
3. Trichorexis nodosa.

### C. OF CORIUM.

1. Atrophia cutis. *a.* propria. *b.* linaris. *c.* maculosa.
2. Atrophia senilis.

### D. OF NAIL.

1. Onychatrophia.

## Class VI.—Neoplastic Affections.

### A. OF CONNECTIVE TISSUE.

1. Keloid.
2. Fibroma.
3. Xanthoma.
4. Neuroma.

### C. OF GRANULATION TISSUE.

1. Lupus.
2. Scrofuloderma.
3. Syphiloderma.
4. Lepra. *a.* tuberosa. *b.* maculosa. *c.* anæsthetica.

### B. OF VESSELS.

1. Nevus vasculosus.
2. Angioma.
3. Telangiectasis.
4. Lymphangioma.
5. Rhinoclecrroma.
6. Epithelioma.
7. Sarcoma.

## Class VII.—Neurotic Affections.

1. Pruritus.
2. Dermatalgia.

3. Hyperæsthesia.
4. Anæsthesia.

## Class VIII.—Parasitic Affections.

### A. FROM VEGETABLE PARASITES.

1. Favus (or *Tinea favosa*). (*Parasite—Achorion*.)
2. Trichophytosis (or *Tinea trichophytina*). *a.* capitis. *b.* barbe. (*Parasite—Trichophyton*). *c.* corporis. *d.* cruris. *e.* unguium.
3. Chromophytosis (or *Tinea verticolar*). (*Parasite—Microsporum*.)

### B. FROM ANIMAL PARASITES.

1. Scabies (*Parasite—Acarus*).
2. Phthiriasis (or *Pediculosis*) capitis (*Parasite—Pediculus capitis*).
3. " " corporis ( " — " corporis).
4. " " pubis ( " — " pubis).

 SKIN DISEASES. 



## COMEDO.

---

CASE.—C. D., aet. 16, U. S. Patient at the New York Dispensary. A typical specimen of the lymphatic temperament. In fair health, but addicted to tobacco-chewing and other untidy habits. The skin of the face was thick and doughy, the circulation inactive, and the secretion of the sebaceous glands notably in excess. The nose was large and greasy, and its sides as well as the forehead were dotted with patulous ducts. Upon the cheeks comedos of unusually large size were abundant, but there was very little tendency to the development of Acne. The treatment in this case consisted solely of local measures. In three visits, during the first week of his attendance at the Dispensary, the sebaceous ducts were emptied by means of a comedo-presser and the free use of soap was enjoined. A most marked improvement took place immediately, and in three weeks, no other treatment being employed, the patient was discharged as cured. I have rarely if ever seen a case of this affection so well marked and possessing at the same time so little tendency to follicular congestion.

Comedo is an affection of the sebaceous glands, occurring alone or associated with Acne. It consists in an excessive secretion of sebaceous matter, which becoming hardened, produces a distension of the sebaceous ducts. The skin may be tolerably smooth and dotted with numerous dirty specks, which indicate the gaping mouths of distended ducts, or as is usually the case, small conical papules are seen with black dots at their summits. The dark color of these "black heads" is owing to the adherence of particles of dirt to the exposed end of the fatty plug which occupies the follicle. In patients who work in dusty rooms, and especially among such as are sparing in the use of soap, these black dots increase in number and prominence, until the face looks as though it had been exposed to an explosion of gunpowder. When pressure is applied to opposite sides of a comedo, an inspissated mass composed of sebum and epithelial cells can be extruded in the shape of a curdy or cheesy "worm."

The affection is commonly observed upon the face, although the upper portion of the back is almost as frequently its seat. Not infrequently a few comedos (or *comedones*) are seen upon the sternal region and upon the sides of the neck. The sebaceous glands of the nose, which are numerous and normally of large size, are not apt to be greatly distended, although in nearly every case of this affection white plugs or threads of sebum, an eighth of an inch or more in length, can be expressed from the follicles, both upon the tip and *ala nasi*. In the concha of the ear the black ends of a group of comedos are frequently seen. In this location they are firmly imbedded and pressed out with difficulty. Upon the forehead and temples comedos do not attain as large a size nor are they as numerous as upon the cheeks. They may be soft, whitish, and curdy, curling as they are extruded from the sebaceous ducts, or in cases of long standing they may be more or less hardened, of a yellow-

### COMEDO.

ish color and pyriform shape, and when pressure is exerted upon the walls of the follicle by means of a silver tube or comedo-presser, they pop out with an audible sound. Frequently the comedo is found, upon examination, to be composed of three parts, a black end corresponding to the mouth of the follicle, a yellowish or horny mould of the duct, and a soft whitish extremity representing the fresh secretion of the gland. Microscopical examination of the sebaceous matter composing the comedo will sometimes reveal the presence of an animal parasite called the *steatozoon* or *acarus folliculorum*. Several of these microscopic insects may be found in one follicle. They are perfectly harmless, and occur in healthy follicles as well as in those which are distended by an accumulation of sebum.

The treatment of comedo is usually restricted to local measures, although attention to the state of the general health is necessary in most cases to check the tendency to the disorder. Our first aim should be to evacuate the distended ducts. This is frequently accomplished by the patient, by means of the thumb-nails. The use of a watch-key is a better plan of treatment, but since, on account of its square bore and rough end, it is liable to wound the skin, several little comedo-pressers have been devised as a substitute. The simplest instrument is a silver tube, five or six centimetres in length, with rounded extremities, and a calibre of knitting-needle size. By placing the end of this tube over the summit of the comedo, and exerting a quick, firm pressure, the sebaceous plug can be expressed with the least amount of discomfort. In pressing out comedos over bony prominences, such as the cheek-bone or margin of the jaw, or upon the nose, care must be exercised lest the tube slip and tear the surface of the skin. After the follicles have been evacuated, the face may be bathed with very hot water to lessen the congestion, which, in a greater or less degree results from the use of the instrument. The daily use of soap should be prescribed, both for the sake of its stimulant action on the glands, and for the purpose of removing a portion of the fatty matter from ducts which are not sufficiently distended to warrant the use of the comedo presser. Soap will also remove from the follicular orifices the numerous black specks which, in young persons with over-active glands, are apt to dot the face in spite of unremitting attention to bathing. When there is any tendency to glandular inflammation, and the use of soap is found to aggravate this, it is well to bathe the face in warm water, to which a little borax or bran may be added. Ladies sometimes object to the use of soap in bathing the face, on account of the tense and shiny condition of the skin which is sometimes left. This is easily remedied by slight friction with a piece of flannel or chamois-skin, and if necessary by the application of a little rice powder or lycopodium. As a lotion to be used in cases of comedo, the following is mildly astringent and conducive to the normal action of the glands:

R.	Zinci Sulphatis, . . . . .	4 grams (ʒ i).
	Aquæ Aurant. flor., . . . . .	200 “ (ʒ ʒ vi).
M.		



COMEDO.





## ACNE.

---

CASE.—C. R., *æt.* 20, U. S. A case contrasting strongly with the foregoing one. The patient was of fair complexion, with a naturally delicate skin. He suffered from dyspepsia, but in other respects was strong and well. The cheeks were hyperæmic and nearly covered with dark-red papules and pustules. A few of the latter situated near the angle of the jaw had slightly indurated bases, but there were none of those hard, deep-seated tubercles which, when numerous, produce that lumpy form of the disease to which is applied the term *Acne indurata*. A few comedos were interspersed among the inflammatory papules, and about the zygomatic region were numerous pin-head sized, whitish elevations, due to the distension of glands of small size, seated in the upper portion of the corium. A marked flushing of the face ensued upon mental excitement or slight external irritation. The local treatment in this case was necessarily of a soothing nature. The irritation produced by carefully pressing out the comedos occasioned patches of congestion which would last an hour or more, and lead to the development of fresh pustules. The mildest stimulating applications invariably aggravated the condition, and it was only after the gastric derangement had been nearly cured, and the irritability of the skin lessened by the most soothing treatment that an improvement began to manifest itself.

Acne is an inflammatory affection of the sebaceous follicles, characterized by three distinct lesions, viz.: papules, pustules, and tubercles. The term has been applied by some writers to nearly all affections of the sebaceous glands, whether inflammatory or not, and in this broad application has included comedo, milium, seborrhœa and molluscum. These affections depend upon pathological conditions which are not essential elements of acne. It is a fact, however, that excessive secretion of the glands and accumulation of sebaceous matter in the ducts are conditions which very frequently exist in connection with follicular inflammation.

Acne, even in the restricted sense in which the term is now used, may be regarded as the most common of all cutaneous affections. It may be asserted that the majority of adults, male or female, have not passed through the period of adolescence without having at least a mild form of acne upon either the face or upper portion of the back. These are the regions upon which the affection is most apt to appear. In cases where the face is affected in a marked degree the back, shoulders and breast may be slightly affected, or remain perfectly free; while, on the other hand, in cases where the back is covered with the lesions of acne, the face may be nearly or wholly exempt. The pustules of secondary syphilis are usually disseminated over the greater portion of the body and are sometimes erroneously termed *Acne syphilitica*. These are not true acne pustules, however, and should be spoken of as the pustular syphilide or syphiloderm.

Other eruptions of pustules occurring on various portions of the body result from the ingestion of

## ACNE.

certain drugs, or from certain forms of external irritation. These again are not true acne, even though produced by follicular inflammation. They differ in their causation, run a different course, and never demand the same treatment as does acne. The affection which has been called Acne Rosacea is also of distinct nature and pathology, as will be seen in connection with the illustration of Rosacea. For practical purposes the only necessary division of acne is into two varieties, viz: *Acne vulgaris* and *Acne indurata*. The former, or common form of the affection, is so well known as to require no detailed description. It appears in one patient upon the forehead or cheek in the form of a few small red papules or "hlotches," which may disappear in a week and return when the same dietary error, menstrual irregularity or other exciting cause is repeated. In another patient the papules resulting from simple follicular congestion may suppurate and form pustules. These may increase in number through new ones coming faster than the old ones disappear. Month after month the skin becomes more and more thickened by the products of inflammation; soaps and ointments, lotions and balms, are used by the patient with no perceptible effect, and finally the disease reaches the chronic and disfiguring stage which is represented in the illustration. In time the disease disappears, even without treatment, as it is rarely met with in middle life, but often deep pits remain on the site of former pustules and resemble the marks left by variola.

The causes of acne reside mainly in impaired digestion and menstrual irregularity, and in its treatment a high degree of diagnostic skill is often necessary to detect the cause, and a thorough knowledge of general medicine required to remove it. My limited space will not allow extended remarks on internal treatment, but I must exhort the reader not to rely wholly upon sulphur pastes, corrosive sublimate lotions or medicated soaps, but to do everything possible to improve the general health of the patient, and if then the skin does not speedily get well of itself, the simplest local measures will suffice. In most cases of acne there is great irritability of the skin, and the error is frequently made of using applications which are unnecessarily stimulating. If the patient steams the face at night by holding it over a pitcher of very hot water, and afterwards sponges it with equal parts of bay rum and water, the improvement will often be greater than with more active treatment. A useful lotion in these irritable cases is the following:

℞.	Acidi Acetici, . . . . .	16 grams	(f ʒ ss).
	Glycerinæ puræ, . . . . .	48 "	(f ʒ iss).
	Aquæ Cologniens., . . . . .	64 "	(f ʒ ii).
M.	Sig. Dilute with water and apply night and morning.		

At the outset all comedos should be pressed out, even though the acne is temporarily aggravated by so doing. Pustules should be lanced as often as they form, and hot cloths applied to lessen the inflammation. Indolent tubercles which show little tendency to disappear may be lightly touched with a glass rod dipped in nitric acid or the acid nitrate of mercury. When the cheeks are comparatively smooth, but still reddened, sulphur in one form or another is of service. I have seen excellent results ensue from the use of the following:

℞.	Sulphuris Sublimati,		
	Acidi Tannici, . . . . .	aa 1 gram	(gr. xv).
	Unguenti Petrolei, . . . . .	30 "	(ʒ i).
M.	10		



ACNE VULGARIS.



## LEPRA.

---

CASE.—A. B., *æt.* 54, U. S. Born in New York, of healthy parents. In 1855 he went to Cuba, where he remained nine years and then removed to Baltimore, being at that time in apparently good health. About two years ago he first felt a sensation upon the forehead as though ants were crawling over the skin. At this time the skin of this part began to assume a light-brownish color, and groups of tubercles appeared upon eyebrows, cheeks, nose, hands, feet and ears. He suffered from occasional febrile attacks until February, 1873, when he was admitted to the Baltimore City Hospital. According to notes of this case published by Dr. George H. Rohé in a paper on Leprosy (*Maryland Medical Journal*, July, 1873), the patient at this time was broken down in health. His face was of a smoky yellow hue, resembling dirty chamois skin. The eyebrows, nose, cheeks and chin were lumpy, and the lobes of the ears were elongated and thickened. The anterior and posterior surfaces of the trunk, together with the extremities, presented a bronzed discoloration. The left side was more affected by the disease than the right. His voice was husky, sight impaired, and smell diminished. The hands felt numb, and locomotion was impeded on account of ulceration of the feet. In May, when he left Baltimore and came to me with a letter from Dr. Rohé, his condition was pretty much as above described. He was but a very short time under my care, and is, at the present time, a patient in Charity Hospital. In the illustration may be seen the lumpy condition of the eyebrows, the pits produced on the cheek by absorption of tubercles, and the ulcerations attacking the finger ends and phalangeal joints. The white streaks on the arm resulted from drawing the finger nail over the thickened and discolored skin. The change in the expression of the face could doubtless be better appreciated by comparing a portrait taken before the disease began.

The leprosy of the present day, occurring in Oriental countries and elsewhere, undoubtedly afflicted the children of Israel in the time of Moses. The Scriptural account of the disease, however, as recorded in Leviticus, is for the most part unintelligible, and it is probable that at the time when it was written a number of chronic and contagious affections were confounded with true leprosy. In later centuries this mistake has been repeatedly made, and the numerous leper-houses established throughout Europe at the time of the crusades, doubtless contained a large proportion of syphilitic, psoriatic and other patients. In glancing at the history of leprosy, we find not only a confusion of diseases, but a confusion of names. Suffice it to say that the term *Elephantiasis Græcorum* is now discarded, and the term *Lepra* (unfortunately applied by some writers to a form of psoriasis), is generally adopted in Germany, France and America as the synonym of leprosy.

Leprosy is endemic at the present day in various quarters of the globe. It is common along the shores of the Mediterranean, in India and China, in the West Indies, Central America and Brazil.

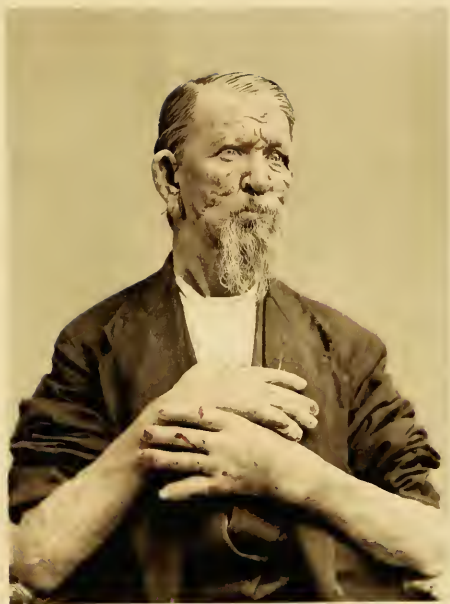## LEPRA.

Although occurring chiefly in warm climates, it is also prevalent in Norway, Iceland and Kamtschatka. In the Sandwich Islands leprosy abounds. On one island (Molokai) there is an asylum to which nearly two thousand cases have been admitted since its foundation in 1865. In certain localities of the United States and Canada there are families or generations of lepers, descended from immigrants who were affected by the disease. In Minnesota there is a Norwegian community comprising a number of lepers who contracted the disease in the old country. In California the disease prevails to a limited extent among the Chinese. At Tracadie, a small French settlement in New Brunswick, Canada, there is a lazaretto containing a dozen or more leprous patients who, with other cases residing in the vicinity, are nearly all descendants of a leprous woman who introduced the disease into the community near the beginning of this century. In New York and other large cities of the Atlantic States, cases of leprosy are occasionally met with, but the disease almost invariably occurs in sailors, or men who have spent some time in countries where it is common. There is no doubt about the hereditary transmission of the disease, although a difference of opinion prevails regarding its contagious nature. Cases are reported where a husband has been leprous and the wife healthy, and *vice versa*, but it is quite probable that the disease is inoculable, and that in some cases it has been transferred directly from one to another.

There are three forms of leprosy based upon the predominance of certain lesions or symptoms, viz.: the *tuberosa*, the *macular*, and the *anæsthetic*. Frequently both macules and protuberances co-exist in the same patient. Anæsthesia in greater or less degree is rarely absent in advanced cases, but it may occur, as the sole cutaneous lesion, neither macules nor tubercles being present. In some text-books but two forms are described; the macular and the tubercular.

Like syphilis, lepra is a constitutional disease, the cutaneous manifestations of which, though highly interesting, are of but secondary importance. A gradual decline in health usually precedes the earliest characteristic indications, which may be faint brownish patches of discoloration or small aggregated tubercles. In a case of tuberosa leprosy the first unmistakable signs are usually seen upon the face. Tubercular thickening invades the lower half of the forehead, and as the tubercles increase in size and become tuberosus, the patient's face assumes a very characteristic leonine expression. The nose and ears are very apt to be the seat of similar protuberances.

The nerves undergo a remarkable change in lepra, the larger trunks of the extremities, as well as the finer branches supplying the skin, becoming thickened and degenerate. The ulnar nerve, in particular, can usually be felt enlarged and hardened. The fingers and toes and other portions of skin supplied by these affected nerves suffer as a natural consequence. In an early stage of the disease they are hyperæsthetic, but as changes in the nerves progress, they become numb and almost lifeless. Ulcers form, which are healed with difficulty. In severe cases the bones of the extremities become carious, and one by one the rotting phalanges fall off and leave disgusting stumps. The tubercles upon the face and elsewhere develop slowly, and though generally permanent, they sometimes decrease in size and disappear by absorption. New ones in greater number usually take their place, and the disease goes from bad to worse, until the strength of the patient fails. Remarks on the diagnosis and treatment of lepra will accompany a plate illustrating the macular form.



LEPRA TUBEROSA





## ELEPHANTIASIS.

---

CASE.—A. C., æt. 19, U. S. Patient of Dr. Chas. Jewett of Brooklyn, notes furnished by Dr. P. L. Schenk of Kings County Hospital. The lower limbs have been enlarged since childhood. Patient had Scarlatina at eight years of age, which was followed by general œdema. From about that time the limbs have been increasing in size. Has been subject to attacks of chills followed by high fever, lasting three or four days. These have occurred at intervals of three or four months and have been followed by a marked increase in the size of the limbs. On the anterior aspect of the legs there are now (Dec. '78) several patches of thickened and roughened epidermis. On the posterior surface of the right leg ulceration began about eighteen months ago. Sloughing occurred about a month ago, and there is now an excavation four inches in diameter and four and a half inches in depth. There are one or two patches of superficial ulceration, oozing a large quantity of clear serous fluid. Since this oozing began the legs have diminished in circumference. The general health is failing.

Elephantiasis is a disease which is entirely distinct from leprosy. Hitherto much confusion has been occasioned by the use of the term Elephantiasis Arahum to designate the disease under consideration, and Elephantiasis Græcorum to designate leprosy. These qualifying adjectives have now been pretty generally discarded in this country, and while the term lepra is applied to leprosy, the term elephantiasis is employed solely in connection with the elephantine disease.

This disease consists in a hypertrophic growth of skin and subcutaneous tissue, and affects chiefly the lower extremities and genitals. The leg and foot are most frequently attacked. It is unusual for the disease to extend above the knee, and extremely rare for both lower extremities to be wholly affected, as in the remarkable case portrayed in the illustration. Cases have been reported of the disease occurring upon the cheeks, breast and upper extremities. Filiform tumors and that peculiar relaxed condition of the skin known as Dermatolysis or Cutis pendula may occur upon these parts and assume elephantine proportions, but they are to be carefully distinguished from true elephantiasis.

The disease is chronic in its course, does not affect the health in any marked degree, and the patient suffers principally from interference with locomotion, depending upon the weight of the affected limb. It is met with in all parts of the world, but abounds in tropical climates, where it attacks by preference those whose constitutions have been impaired by improper diet, excessive exposure and other causes. In the West Indies it is so common that Barbadoes Leg has come to be a well-known synonym.

The disease is intimately connected with conditions which produce obstruction of the lymphatics. œdema plays a most important part in the production and development of the disease, and recurrent

## ELEPHANTIASIS.

inflammatory attacks of an erysipelatous nature characterize its progress. Each attack leaves the skin more swollen and harder, and the attacks continue at a variable interval until the part affected has attained an immoderate size. The scrotum, for instance, may hang nearly to the floor and weigh upwards of a hundred pounds. In the female the labia and clitoris may be similarly affected. The skin of an affected leg is darkened in color and either smooth and œdematous or fissured and scaly. Its sensibility is lessened by reason of the great thickening, but there are no anesthetic patches as in leprosy. In severe cases portions of skin become pendulous and deep creases are formed between them. Upon the dorsum of the foot and anterior aspect of the leg it is not uncommon for the skin to present a verrucous surface, covered with dry and blackened papillary elevations. Eczema often appears upon the surface of the skin, and fissures occur at the bottom of the furrows. Slight ulceration is present in many cases, and from the denuded patches a large quantity of lymph is poured out. Sloughing may take place, especially when the strength has failed and the patient is unable to leave the bed.

Elephantiasis is neither contagious nor transmitted through hereditary influence. Its causes are obscure, but are doubtless connected with the patient's manner of living. Malaria has been cited as a cause, but proof is lacking as to its influence. Varicose veins, cicatrices, gummy deposits, bone callus and other local conditions inducing obstruction of the venous and lymphatic circulation have been alleged to act as exciting causes. A very interesting and plausible theory has been advanced that the disease is of parasitic origin, and that, furthermore, the mosquito is responsible for its existence. Dr. Manson, a British surgeon, resident in China, has discovered the *filaria sanguinis* in the blood of elephantiasis patients, as also in the blood of patients affected by the so-called lymph-scrotum and chyluria. He believes with others that this parasite has its habitat in the lymphatics and by causing obstruction and distal fullness of these vessels, gives rise to elephantiasis. As in the case of tape-worm ova, the immature *filaria* can only become developed outside of the human body and the mosquito is accused of being their intermediate host. In the stomach of this insect the undeveloped *filaria* is supposed to undergo a metamorphosis, and being discharged with the young of the mosquito upon the water, finds its way again into human lymphatics and occasions elephantiasis.

The treatment of this disease, though often gratifying, is not always attended with the desired success. In the early stage, rest, poulticing and other antiphlogistic remedies should be employed during the erysipelatous attacks. Later, bandaging is of service, as it tends to lessen, though seldom permanently, the size of the leg. Hebra recommends elevation of the limb and union of mercurial ointment. Compression and ligation of the femoral artery has been practiced in a number of cases with partial success. The improvement which follows this method of treatment is due to the removal of arterial pressure, which interferes with the function of the lymphatics. This pressure being removed, a rapid absorption of the effused serum often takes place, and in some cases the decrease of the infiltration is permanent. When the genitals are affected to a marked degree the knife is the remedy most in vogue, and by its skillful use most brilliant results have been achieved.



ELEPHANTIASIS.



## KELOID.

---

CASE.—H., *æt.* 27. Patient of Dr. Wm. T. Bull. About eighteen months before the photograph was taken this patient had a severe attack of variola, which left considerable pitting of the face. About the time of leaving hospital tumors appeared on either cheek, which have slowly increased in size. A small one was excised, but the growth reappeared almost as soon as the wound had healed. The disease as it occurs in this patient would be commonly termed spurious or cicatricial keloid. In appearance, however, it differs in no material respect from the spontaneous form, and presents a strong contrast to the reticulated cicatricial hypertrophy which is frequently observed upon the face as a sequel of variola. The bifurcated process extending forward upon the cheek is decidedly characteristic, and no stretch of imagination is required to detect a close resemblance to the claw of a crab. The growth will be noted upon the scalp where it assumes the form of linear ridges, as upon the side of the nose. The lobe of the ear, which is sometimes the seat of cicatricial keloid, is unaffected in this case, although it has been pierced to hold a ring.

Keloid is a cutaneous tumor which usually develops upon the site of a cicatrix. It results from a new growth of connective tissue, and may affect various portions of the body. It is variable in size, and though usually small, it may in rare cases assume immense proportions. It is generally a single growth, but may occur in the form of multiple tumors, especially when it arises from cicatrices. Its shape is usually oval or irregular, and more or less flattened, and one or more straight or bifurcated processes are seen projecting in every typical case. These have given origin to the name keloid (like the claw of a crab). In some instances the growth rises abruptly from the surrounding healthy skin and forms a plump convex tumor, while in other cases it is reticulated in appearance, from the interlacing of cicatricial ridges. The margins of the growth are sometimes elevated and inclose a central depressed area. Its surface is smooth, of a whitish or dull pinkish hue, and is frequently streaked with a fine network of small dilated vessels. The growth is firm and elastic to the touch, usually tender when pressed upon or squeezed, and in some instances gives rise to severe intermittent pain even when carefully protected. The processes radiating from the growth tend to contract and produce a puckered condition, such as surrounds the cicatrix of an extensive burn. A favorite site of keloid is the sternal region, where it appears as an elongated flattened tumor crossing the median line in a transverse direction. It occurs frequently upon the back and sides and also upon the scalp and face. It is slow in its development and is never associated with any constitutional symptoms. It neither ulcerates nor tends as a rule to spontaneous disappearance, but after reaching a certain size remains in the same condition for many years.

## KELOID.

The cause of keloid is unknown. Observation teaches that in the vast majority of cases it develops at some point where eutaneous injury has taken place. The cicatrices of acne upon the back, of boils or carbuncles upon the nape of the neck, of variola upon the face, and of vaccination upon the arm are frequently observed to be the site of keloidal growths. Negroes appear to be more frequently affected by keloid than white persons. Whether this is due to a peculiarity of the race or to the fact that their skins are more frequently pitted with variola, scarred by strumous abscesses, and disfigured by the lash, may be a question. The disease is never hereditary. A division of keloid has been made into a spontaneous and a cicatricial variety, the former embracing those cases of idiopathic origin, the latter comprising those which develop upon cicatrices. As it is well known that keloidal tumors of considerable size and attended by pain result from the most trifling injury to the skin, it seems quite probable that every case of keloid is of traumatic origin, and that the so-called idiopathic cases have been produced by the prick of a pin or some other insignificant injury of which the patient took little or no notice at the time. The term spurious keloid might be advantageously abandoned or applied to a form of hypertrophic development of cicatricial tissue sometimes met with, and which differs from true keloid.

The name keloid, like many other dermatological terms, has been diverted from its original signification and applied to distinct affections. We hear accordingly of Alibert's keloid and Addison's keloid. Concerning the nature of the latter affection, or Morphaea, there is much doubt existing among dermatologists, but one thing is certain, it is not keloid. The diagnosis of the disease is usually an easy matter. The firm, elastic tumor, the processes (which however are not invariably present), the puckering of the surrounding skin, the long duration of the growth and the unimpaired health of the patient are characteristic features which will serve to distinguish it from other affections. The diagnosis of genuine from spurious keloid depends, according to writers who make the distinction, upon the idiopathic or traumatic origin. The origin, as has been remarked, is often uncertain and the distinction is unnecessary. It must be remembered, however, that cicatrices often become thickened and lumpy through condensation of tissue and are with difficulty distinguished from keloid.

In the treatment of the disease success seems to depend in great measure upon idiosyncrasy on the part of the patient. A method which will succeed admirably in one case will fail utterly in another, and caution must be observed in stating beforehand what the result of treatment will be. Excision of the tumor or destruction by caustics usually does more harm than good, as the growth usually reappears even before the wound is healed, and soon reaches a greater size than before the operation. This is especially the case when the growth is progressive. When there has been no increase in size for several years, caustic potash or glacial acetic acid may be cautiously used. I have recently seen a case of reticulated keloid following variola, which was greatly improved by parallel incisions and the use of the concentrated acid. An ointment of iodide of lead or of iodide of potassium or elastic collodion may be applied with a certainty of at least doing no harm. Where excessive pain is present hypodermic injections of morphia or anodyne lotions are required.



KELOID





## ROSACEA.

---

CASE.—Margaret K., æt. 45, Ireland. Patient at the Skin Clinic of the Woman's Medical College.

The eruption had troubled her more or less for six years and had been much worse than usual during the last month. Menopause occurred two years before. She complained greatly of discomfort after eating and often vomited her food. This gastric irritability having subsided under a restricted diet, together with the use of pepsin and bismuth, she was ordered Aug. 6, 1878, a mixture containing sulphate of iron and sulphate of magnesia, and for local application an ointment of sulphur, four parts, tannic acid, four parts, eosmoline, ninety-two parts. This was followed by a rapid improvement, and when seen on Sept. 17, all trace of eruption had disappeared, and she felt much stronger and better.

Rosacea is a chronic disease of the middle period of life, occurring upon the face, and resulting from a dilatation of blood-vessels and an increased growth of connective tissue. Its chief features are redness and a tendency to the development of tubercles and pustules. The affection has been described by writers on dermatology as a form of acne, and even those who have believed it to be a distinct affection have generally employed the term Acne-Rosacea. Some writers, in order to distinguish the affection from acne, as should be done, have employed the old but expressive term *Gutta Rosea* or *Gutta Rosacea*. Recently rosacea has been disjoined from acne in name as well as in nature, and this usage will doubtless tend to dissipate the erroneous idea that they are forms of the same disease.

Rosacea is common in both sexes and is most frequently met with between the ages of thirty and fifty. Its site is characteristic. If the face were mapped out into vertical thirds the middle section would include nearly all cases of rosacea. The parts most frequently affected are those portions of the cheeks below the infra-orbital ridges. In severe cases a fiery triangle may be seen on either cheek, lying between this ridge and the zygomatic minor and labio-nasal muscles. A milder form of the disease often exists upon the central portion of the forehead, just above the bridge of the nose, and at a short distance from the angles of the mouth isolated rosy drops are frequently observed.

The simplest form of rosacea is that which appears in the form of dull red macules or slightly-elevated papules, resulting from chronic congestion or dilatation of the superficial vascular plexus around the mouth of a follicle. These "rosy drops" sometimes present a central point of a somewhat darker hue, more elevated and at times surmounted by a scale or the thin crust of a minute pustule. The confluence of these circular "drops" forms a purplish-red patch, presenting a swollen and uneven surface dotted with pustulous follicles and somewhat resembling the skin of an orange in texture. As the disease advances the patch becomes studded with tubercles which usually tend to suppuration.

## ROSACEA.

The rounded summit of the tubercle assumes a yellowish-white appearance and a minute superficial drop of pus, evacuated when the patient is washing or wiping the face, gives place to a thin, dark colored crust. In many of the tubercles a more decided form of suppuration occurs, and in a case of long standing numerous hemispherical pustules or abscesses are accordingly present. These pustules are not of glandular origin, as in acne, and may be easily distinguished from true acne pustules by their rounded summits and the absence of a central comedo. Similar pustules or small superficial abscesses not unfrequently occur in acne, especially in the indurated form, and are not connected with the sebaceous glands.

Dilatation of the superficial blood-vessels, though commonly occurring in rosacea, is not an essential element of the disease. Where the condition is marked, as it often is upon the wings of the nose, constituting the most striking feature of the affection, the term *Rosacea varicosa* has been employed.

The most remarkable form of the disease is that known as *Rosacea hypertrophica*. It is a late stage of the affection and occurs chiefly on the nose. The tumid or lumpy condition of the skin which is characteristic of the disease in its common form, becomes exaggerated to such an extent that the nose assumes astonishing proportions. A number of tumors project from the sides or tip, varying in size from a large pea to a small egg, and frequently become pedunculated. The nose may attain the size of the fist, and either partially obstruct vision or hang down in front of the mouth. This condition is, fortunately, so rare, as to constitute a dermatological curiosity.

*Rosacea* resembles acne, in being largely dependent upon disturbance of gastric and uterine functions. The treatment in most cases consists of a combination of internal and local remedies. To achieve success with the former we must ferret out all predisposing and exciting causes. Abnormal states of internal organs must be rectified. Injurious habits must be abandoned by the patient and strict attention paid to hygienic rules. To derive benefit from local applications it is necessary to determine the amount of stimulation required by each individual case. In mild cases, where there is much irritability and little thickening of the skin, the following lotion may be used while the cure is being effected by internal treatment :

℞	Sodii boratis, . . . . .	4 grams (ʒ i)
	Glycerinæ puræ, . . . . .	8 " (f ʒ ii)
	Aquæ rosæ, . . . . .	128 " (f ʒ iv)

M. Sig. Use as a lotion for the face *ad lib.*

Where a little more stimulation is desired the following may be applied to the affected part at night and the powder allowed to remain until morning.

℞	Sulphur. precip., . . . . .	10 grams (ʒ iii)
	Spirit. Lavandul., . . . . .	90 " (f ʒ iii)

M. Sig. Shake before using.

Equal parts of the oxide of zinc and ammoniated mercury ointments are useful where more stimulation is required; and when there is marked infiltration of the skin a course of nightly frictions with green soap is almost indispensable. Dilated blood vessels should be well scarified, and after the blood has ceased flowing a thick coating of elastic collodion painted over them. In the hypertrophic form of the disease surgical treatment is indispensable.



ROSACEA



## PSORIASIS.

---

CASE.—J. S., *Æt.* 40. The eruption in this patient was of about five years' standing, and although some patches had disappeared and new ones taken their place, it had been characterized throughout its course by a few discrete circular patches covered with thick scales. No especial change had taken place, as usually happens, at certain seasons of the year. The patient was a large, strongly-built man, and seemingly enjoyed the best of health. At times the eruption itched slightly, especially when heated by fast walking or other physical exertion. The scalp was but slightly affected, and the nails presented a peculiar condition occasionally met with in this disease. Upon a few of his fingers, and upon nearly all of his toes, the free margin of the nail was raised from its bed by a hard yellowish mass of horny epidermic scales. This produced a lateral curving of the nails and a splitting of the free ends. The treatment adopted at first in this case consisted of Fowler's solution internally with oil of cade rubbed daily into the affected skin after the scales had been completely removed by means of a curette. Improvement followed, but treatment was discontinued during absence from the city. Later a ten per cent. ointment of chrysophanic acid was used with excellent result.

This very common affection consists in circumscribed patches of red and thickened skin, covered usually with whitish or yellowish-white scales. The patches may be isolated or confluent. In the former case they vary in size from a pin-head to a saucer, and are circular in form. In the latter case they give rise to large irregular patches, with scalloped borders, and frequently with inclosed areas of normal or slightly pigmented skin. In some cases the entire body and especially the trunk may be affected, and appear reddened, thickened, and more or less scaly. The patches always begin in the form of small red papules, surmounted by a thin scale. These may be scattered abundantly over the body, and show little or no tendency to increase in size (*P. punctata*). They are more apt, however, to assume the size of a cent or quarter-dollar, and when numerous and aggregated they appear as though a handful of thin mortar had been spattered over the skin (*P. guttata*). In a small number of cases the patches are few and large, and, as in the illustration, appear like silver coins of large size (*P. nummulata*). Generally the patches tend to coalesce as they increase in size, and lose their circular outline (*P. diffusa*). In nearly all cases the central portion of the patch is the first to disappear, and in consequence scaly rings are produced (*P. annulata*) and in rare instances crescentic and serpentine lines (*P. gyrata*). The scales of psoriasis are imbricated, and in most cases easily removed. In appearance they have been compared to silver and to mother of pearl. Their thickness is usually in proportion to the amount of infiltration of the subjacent skin.

## PSORIASIS.

In diffused patches they are often branny in character, while in chronic cases they become thick and hard, like plates of armor. The extensor surfaces of the extremities, the back and the scalp, are the favorite sites of the affection. Upon the elbows and knees and along the frontal margin of the scalp it commonly occurs, although it is not invariably present upon these parts.

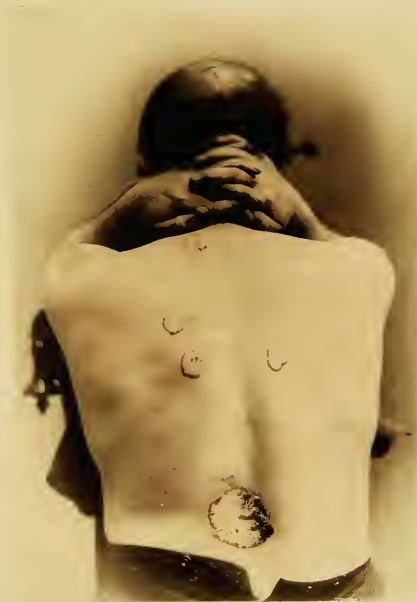The etiology of psoriasis, in spite of much investigation and more discussion, is still obscure. While some writers connect it with a dartsous or rheumatic diathesis, or insist upon its dependence upon malaria, others regard it as a purely local disease, and claim for it a traumatic origin. The majority of psoriatic patients seem as strong and hearty as the average of mortals, and if not in perfect health apart from their cutaneous blemish, they at least believe themselves to be so.

The diagnosis is generally easy, especially in typical cases. It must be constantly borne in mind, however, that the eruption may be in its declining stage or modified by previous treatment, in which case it differs greatly in appearance from the eruption when seen at its height and before treatment. If a psoriatic patient is stripped sufficiently to reveal the greater portion of the eruption, a diagnosis can readily be made by observing the characteristic configuration of the patches even when viewed at a considerable distance. When the eruption is seen in its incipient stage, and only a few scaly points or drops are present, a diagnosis can often be arrived at by observing the ease with which the scale can be removed by the finger nail, and the bleeding corium which is exposed beneath it. Too much stress, however, is often laid upon this point, as in some cases of eczema, where the eruption is recent and accompanied by slight scaling and little or no infiltration of the true skin, the finger nail may remove the epidermis as readily as in psoriasis, and a number of bleeding points will be seen springing from the lacerated papillae. If the condition of the eruption, together with its location, does not settle the diagnosis, the history of the case will generally furnish the necessary clue. Its occurrence at certain seasons of the year, and its partial or complete disappearance at others, its absolute and persistent dryness, and its tendency to relapse after being apparently cured, are features of the case which point only to psoriasis.

The treatment of the disease is simple as far as regards the removal of the eruption. It is a much more difficult matter to prevent its relapse. Psoriatic patients are not usually in need of tonics. Some errors in digestion may be discovered and require to be corrected. An alkaline plan of treatment may be called for by the association of the disease with a rheumatic or gouty habit, and should be our chief reliance whenever the patches are hyperæmic and irritable. The acetate or citrate of potassium may be given in from one to two gram doses, in a half glass of water, a short time before meals. In chronic cases arsenic is an old, a well-tested and an efficient remedy. It may be given in the form of the liq. potassii arsenitis, the liq. ferri chloridi, or the so-called Asiatic pills converted into a powder (Piffard).

R. Acid. arseniosi, . . . . .	2 parts.
Piper nig., . . . . .	18 "
M. Sacch. lactis, . . . . .	80 "

From one to five grains of this powder may be taken with each meal, being sprinkled on the food in place of salt, if agreeable to the patient. The local treatment of the disease will be discussed in connection with another plate.



PSORIASIS NUMMULATA





## ICHTHYOSIS.

---

CASE.—A boy about 10 years of age; a patient from the Children's Department of the New York Dispensary, under the care of Dr. G. W. Robinson. At birth, and for some time after, the skin was normal, according to the mother's statement, and only within the last two years did it attain the degree of roughness which is shown in the illustration. No other member of his family had ever been affected in like manner. Cod liver oil was used in this case, both internally and by inunction, and its constant use kept the patient's skin in an almost normal condition. The photograph of this case was taken in the sunlight, the patient lying upon his back. The polygonal scales, with raised edges, may be noted upon the outer surface of the thigh, and characteristic parallel wrinkles are seen encircling the elbow.

Ichthyosis is a chronic disease of the skin, characterized by dryness and roughness. It varies in severity from cases in which the abnormal condition of the skin is so slight as to be perceptible to the touch rather than to the eye, to cases in which large polygonal scales or blackened horny projections take the place of the normal epidermis. This variable degree of severity has led to a division of the disease into forms to which the names xeroderma, ichthyosis simplex, and ichthyosis hystrix have been applied. These terms are convenient for descriptive purposes but it should not be inferred that xeroderma and ichthyosis are distinct affections. Nor is ichthyosis hystrix to be understood as meaning anything but a peculiar form of ordinary ichthyosis.

In the mildest cases of the disease, very frequently observed in infants and young children, there is a deficiency of the sebaceous secretion as well as of perspiration and a harsh or mealy condition of the epidermis. The skin is a trifle darker than normal, and suggests the idea of a lack of soap and water. In other cases, or in these same cases at a later period, the epidermis becomes hypertrophied, and cracks in a characteristic manner. Small lozenge-shaped or pentagonal scales result, which are slightly raised at their margins. In a more severe or further advanced condition these hypertrophied epidermic plates become darker in color, and assume a yellowish or greenish hue, while the furrows between them appear like a network of white interlacing lines. The plates, though horny and sometimes glistening, are never found lapping one over another, as might possibly be inferred from the name of the disease or its common synonym of "fish-skin disease." In cases of unusual severity one or more patches of skin may become covered with black papillary projections, presenting an appearance which is suggestive of the bark of a tree. These patches are similar to those warty growths which appear upon the skin in elephantiasis. When these papillary projections, which are always thickly crowded together and usually flattened, become elongated and pointed, the term ichthyosis hystrix has been applied to the condition, from the

## ICHTHYOSIS.

fancied resemblance of the spines to the quills of a porcupine. Cases presenting this form of the disease have been on exhibition as "Porcupine men." "The man-fish of Tennessee" is a marked case of ichthyosis, now traveling through the country. An excellent description of this medical curiosity by Dr. Yandell, may be found in the *Louisville Medical News* (Nov. 30, 1878).

The disease affects the greater portion of the skin. The palms and soles are always free, and the flexures of the joints are devoid of scales, although abnormal dryness of the skin is present. Around the elbows and knees the epidermis is broken up into smaller plates, and numerous elliptical wrinkles or folds of skin occupy these parts. The disease usually begins in infancy and never in adult life. In the majority of cases the mild or xerodermatous form tends to remain through life, while in some instances the affection increases in severity from year to year. It is sometimes hereditary. Two or more children in one family may be affected, while others in the same family show no tendency whatever to the affection. It is attended with little or no discomfort beyond the consciousness, on the part of the patient, that his skin is not as it should be, and it exerts no influence on the patient's general health. Mild cases are often temporarily cured in hot weather, when the perspiratory glands are active, and even the most aggravated cases are considerably better in summer than in winter. In the latter season ichthyotic patients usually suffer considerably from the cold, and when exposed to high winds the face and hands are unusually prone to become chapped and painful.

The diagnosis of the disease is easy, when its extensive distribution over the body, its absence of redness and itching, and its chronicity are taken into account. Pityriasis simplex is the only affection to which it bears any resemblance, but in pityriasis the skin is not so generally affected, there is hyperæmia beneath the scales, and these are constantly falling, or are easily rubbed off, while in ichthyosis there is no hyperæmia, and the scales remain upon the skin.

The treatment of ichthyosis, or at least its cure, is not easy. The skin may be made quite smooth by appropriate applications, but as soon as these are laid aside, the roughening and scaling tend quickly to reappear. Inunction is the chief remedy in the treatment of mild cases. Cosmoline, vaseline, benzoated lard, almond, linseed, and cod-liver oils are useful, and as each accomplishes the object in view, viz., the lubrication of the preternaturally dry skin, it matters little which one is selected. Balmanno Squire thinks that glycerine diluted with three times its quantity of water is more effectual than oil in keeping the skin in good condition.

In severe cases, where the epidermic plates are thick and horny, inunction may still be advantageously employed, but greater dependence must now be placed upon soap frictions and constant lathing. Some patches on the extensor surface of the extremities may be so hard as to require blistering. The Turkish bath renders excellent service in all cases of ichthyosis. The profuse sweating is useful, as is shown by the improvement which naturally takes place in hot weather, and the shampooing removes the superfluous epidermis. The body should be thoroughly anointed immediately after each bath. Jahorandi has been given internally in this affection, and has produced a rapid improvement in the condition of the skin, but there are objections to the use, and the Turkish bath is to be preferred.



ICHTHYOSIS SIMPLEX



## FIBROMA.

---

CASE.—M. K., æt. 48, Ireland. Patient of Dr. James R. Wood. The pendulous growth upon the right side of this patient's head, and a number of small and soft tumors on various parts of the body, were congenital. During childhood, and even until thirty years of age, the tumor of the scalp steadily increased in size, from year to year. Since coming to this country, sixteen years ago, patient thinks there has been no permanent change. At times, however, the growth feels heavier and warmer than at others, and there is an increase in size, due to a temporary afflux of blood. Patient suffers more inconvenience from the weight of the tumor in summer than in winter. When exposed to a low temperature in winter, the lax tissue becomes icy cold, but has never been at all numb. About five years ago, while at work, a shovelful of gravel was accidentally thrown against the right side of his head, on account of which accident he entered Bellevue Hospital, April, 1874. The growth was injured, several slight wounds continued to discharge, and an attack of erysipelas supervened. Since then he has been employed in hospital and has suffered again from erysipelas, to which affection he seems unusually prone. The small tumors found elsewhere on the body have undergone no change since childhood. Upon examination, the tumor of the scalp is found to be soft, and composed of a flaccid and pendulous fold of skin and subjacent tissue. It has a broad base line extending from the vertex posteriorly around to the forehead anteriorly, and occupying the line of the usual parting of the hair. From the side of the head where it naturally hangs, it can be raised and carried over the top of the head. By grasping either extremity of the base of the tumor with the thumb and fingers, the two layers of scalp can be felt sliding one over the other and forming a fold about one and a half inches thick. The free edge of the fold which hangs down over the right ear, and as low as the angle of the jaw, is somewhat thicker than the base, and is notched as though resulting from the confluence of four or five pendulous tumors arranged side by side. On the outer surface of the growth are several vertical linear depressions terminating in these notches. The ear, though pressed by the tumor, is of normal shape, but above the right zygoma there is a marked depression. The bones of the temporal fossa are extremely thin, and yield on pressure. The scalp involved in this pendulous fold is thin, and of a dull reddish hue. On the under side of the tumor, the scalp is nearly as white as it is on the normal side of the head. There is no pigmentation of the growth, although the patient's complexion is quite dark. Its sensibility is unimpaired, a touch being felt on the pendulous scalp as readily as on the other side of the head. The hair grows sparsely, but is as soft as on the normal scalp. The follicles are apparently normal in number and structure, but the stretching of the scalp, produced by the excessive growth of connective tissue, has separated them, and they average a quarter of an inch apart. The hairs can be pulled out more readily than elsewhere. There are a half dozen small tumors on the face and head, varying from a pea to a walnut in size, and not differing

## FIBROMA.

in any essential regard from the large growth. On the right hip and left leg are two soft sessile fibro-areolar tumors nearly as large as a hen's egg. Scattered over the body and extremities are nearly one hundred of the same, varying in size from a pea to a walnut, some appearing like prominent pouches of skin, others more deeply seated, merely producing hemispherical elevations of the skin.

In applying a name to the pendulous tumor represented in the illustration, I might refer to the literature of cutaneous tumors and choose from a long list of names which have been applied to similar growths. *Molluscum pendulum*, *Molluscum fibrosum*, *Fibroma molluscum*, *Pachydermatocele*, *Cutis pendula*, *Dermatolysis*, *Elephantiasis Arabum*, and *Elephantiasis mollusca*, are terms employed by various writers. I prefer the term *Fibroma pendulum*.

Fibroma consists in a hyperplasia or new growth of connective tissue, and occurs in various organs of the body. The growth may be single or multiple, firm or lax in structure, and is always benignant in character. Occurring in the skin, it involves the corium and the reticulated subjacent tissue, and produces circumscribed tumors of variable form and dimensions, usually soft and flaccid, and either small and sessile (*fibroma simplex*), larger and pedunculated (*fibroma pyriformis*), or plicated, i. e., hanging in one or more folds from a broad base (*fibroma pendulum seu plicatum*). It is sometimes congenital, increasing gradually in size up to a certain variable limit, and sometimes presents itself as an acquired growth. In many instances it seems to be hereditary and affects two or more members of a family. In its most common form, fibroma occurs as a small, soft, pouch-like tumor, or polypus of the skin, connected by a pedicle and usually seated on the neck, breast, or back (*Acrochordon*). The trunk and extremities may be studded with a countless number of these small, soft tumors, varying in size from a pea to a walnut and producing a most striking appearance, although exerting no influence upon the health and general condition of the patient.

Occasionally a single fibroma will become large, pendulous and pedunculated. One of my series of Photographs of Skin Diseases (No. 18) represents a woman with a pyriform tumor about the size of her fist hanging by a long slender pedicle from between the left breast and the axillary region. In most of these cases the skin is nearly normal in structure and appearance, being merely stretched by the increased growth of fibrous and areolar tissue beneath. Finally we come to a series of rare cases in which the fibrous growth hangs in one or more folds as is seen in the illustration. This growth differs in no essential regard from the pedunculated tumor, although the corium is apt to be specially involved. The sebaceous ducts are sometimes distended and white cheesy threads can be extruded by pressure. This pendulous form, whether occurring in folds or as a large pedunculate tumor, generally co-exists with a number of small sessile fibromata, and is identical in nature though differing in shape and appearance. Under the name of *Dermatolysis* it has been described as an hypertrophy of the skin, an affection distinct from fibroma. The skin, indeed, may be thickened in some cases and appear coarse in texture, but in others it is atrophied from tension and appears smooth and fine.

The treatment of fibroma is not imperative, as the affection occasions no discomfort. When the tumors are small they may be let alone, when large and pedunculated, they may be removed by the knife, galvano-caustic loop, or elastic ligature. In the pendulous form, the liability to erysipelas must be considered before attempting an operation, but such growths have been successfully removed.



FIBROMA PENDULUM





## VARICELLA.

---

VARICELLA, or chicken-pox, is a well-known exanthematous affection of infancy and childhood. The name suggests a relationship to variola, or small-pox, and there exists indeed a resemblance between the two. Until the inoculation of small-pox prevailed in Europe, varicella was regarded as a mild form of this disease, and its history is intimately associated with that of variola.

At the beginning of the eighteenth century, Lady Wortley Montagu, the wife of the British Ambassador at Constantinople, became acquainted with the practice of inoculating small-pox in order to lessen the severity of the disease, and having subjected her own children to the operation, advocated the practice with such earnestness that it soon prevailed not only in England but throughout Europe. It was at this time that the attention of physicians became directed to the study of varicella, and the question of its specific nature assumed a vital importance in determining the value of inoculation. This practice, so startling an innovation upon established custom, naturally met with opposition. Its opponents, observing that patients after having contracted the disease by inoculation were subsequently attacked with what they considered to be small-pox, claimed that inoculation possessed no prophylactic value. Its supporters, on the other hand, claimed that the pustular and vesicular eruptions sometimes occurring after small-pox were not cases of true variola, but distinct affections, to which they gave the names varioloid and varicella. After Jenner's discovery of vaccination the controversy respecting the identity of variola and varicella raged more fiercely than ever. At the present day there are none in the medical profession who claim that varioloid, or the modified form of small-pox which sometimes occurs after vaccination, is distinct from variola. As to varicella, however, the majority of physicians, who are able to pass judgment on the question, are agreed that it is a distinct specific disease.

Varicella is pre-eminently a disease of childhood and is never met with in adult life. It is rarely if ever seen twice upon the same individual, although an attack of mild small-pox or varioloid may either precede or follow the eruption. The serum contained in the vesicles is not readily inoculable, and the eruption has no prophylactic or modifying influence over future attacks of small-pox.

Varicella occurs sporadically and in epidemic form. In large cities cases are always to be found, and epidemics of this disease occur with far greater frequency than do those of small-pox. Some claim that the disease is not contagious and assert that its occurrence among several children of a family is merely the result of epidemic influence. It certainly does not appear to be as contagious as the other exanthemata. I have known three out of five young children to be affected in one household while the other two escaped. The period of inoculation is supposed to be longer than that of small-pox or measles. During this period the child may evince some signs of languor,

## VARICELLA.

but generally there is only a slight fever of a few hours' duration preceding the eruption, and very frequently the eruption itself is the first indication that the child is not in perfect health. The eruption at the outset presents small red macules or slightly-elevated papules upon the body, and shortly after upon the face and extremities. In a few hours a minute vesicle is noted in the center of each red macule, its shape varying in different cases, being either conical or hemispherical, and usually from a pin-head to a small pea in size. The vesicles are disseminated and vary in number from a few score to several hundred. They are quite superficial, covered by a tense layer of epidermis, and surrounded usually by a narrow zone of inflammatory redness. The contained fluid is clear, colorless, or slightly tinged with yellow, and of an alkaline reaction, differing in this regard from the acid serum of eudamina. The vesicles after the first day may appear cloudy, but they never become purulent. The fever subsides on the third or fourth day, unless kept up, as is often the case, by successive crops of vesicles. These may become flaccid through absorption of their contents when one or two days old, or they may burst from excessive distension or be scratched by the patient, in which case they dry in the centre and form yellowish or brownish thin horny crusts. At this stage new papular lesions may appear, and aborting in their course, fail to become vesicular. Some of the vesicles enlarge by peripheral extension and form bullæ, which are unilicited when the centre of the vesicle has begun to dry. The crusts fall in a few days or are scratched off by the patient in his endeavors to alleviate the pruritus or burning of the skin, which is always present in greater or less degree. Beneath is left a small, circular and slightly-depressed patch of reddened skin. Scars sometimes remain through life, presenting a characteristic form and a peculiar whiteness and softness.

The diagnosis of varicella is easily made if the eruption is seen at the outset. The red papules noticed on the child's body or neck on the first day are suggestive of mosquito bites and are frequently mistaken for them. The development of vesicles, however, shows that the eruption is either chicken-pox or the vesicular stage of mild small-pox. If an epidemic of variola is in progress the diagnosis of the case becomes a matter of considerable importance, and an error may prove unfortunate for both patient and physician. Although variola is as a rule a far more severe disease than varicella, it may run an extremely mild course, and does so frequently when modified by a previous vaccination. In such a case the differential diagnosis is not always easy, but the chief points upon which it may be established will be seen by reference to the following comparative table.

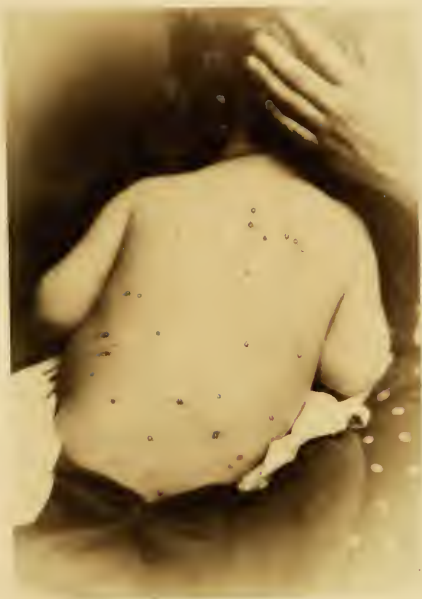### VARICELLA.

Is not inoculable as a rule.  
Attacks children recently vaccinated.  
Is unaffected by previous vaccination.  
Vaccination will succeed after varicella.  
No prodromal fever of any consequence.  
Fever begins with the outbreak of the eruption.  
Eruption spreads rapidly over the body and vesiculation takes place on the first day.  
Vesicles are superficial, and have no hard base.  
Occurs always in children.

### MILD VARIOLA OR VARIOLOID.

Is readily inoculable.  
Rarely occurs until years after vaccination.  
Is modified, if not prevented by vaccination.  
Vaccination will not succeed after small-pox.  
Initial fever lasting two or three days.  
Fever abates when the eruption appears.  
Eruption spreads slowly from face to extremities and the vesicles develop gradually.  
Papules are deep-seated and feel "shotty."  
Occurs chiefly in adults.

The treatment of Varicella consists simply in judicious nursing.



VARICELLA



## ZOSTER.

---

- CASE I.—Johnny G., *æ*t. 3½. A patient from the Children's Department of the N. Y. Dispensary, kindly placed under my observation by Dr. G. W. Robinson. On September 30th, according to the mother's account, the child was as well as ever and had been in usual health of late. October 1st. Dull and uneasy in the afternoon, and at night feverish. October 2d. A patch of fine vesicles was noticed on the left side of the dorsal vertebra, with patches of hyperæmia on the side of thorax. During this night and the succeeding one, the child was very restless, and complained during the day of the eruption hurting him, although he was able to keep playing about the house. When seen by me on October 4th, the vesicles on the side had coalesced and formed large tense bullæ of the size of pigeon's eggs. Bromide of potassium was ordered. On the 5th, after suffering much and sleeping little during the previous night, the bullæ were found to be less tense than on the preceding day. The vesicles of the patch near spine, which first appeared, were now flattened and contained a cloudy or sero-purulent fluid. It was at this stage of the eruption that the photograph was taken. The mother was instructed to dust the eruption freely with starch powder, and small, frequently-repeated doses of the tincture of mezereum was given. October 7th. Has slept better for two nights, and to-day is quite good-natured. Near spine the eruption consists of small, confluent, purulent vesicles, the whitish patches tending to become dark in the center. The eruption on breast is rapidly drying. There are two thin, blackish scabs where the bullæ were, one of them being depressed, and suggesting the possibility of its leaving a scar.
- CASE II.—P. T., *æ*t. 24. The eruption on right side was first noticed upon arising in the morning, the patient having been somewhat feverish, and perspired freely during the preceding night. The eruption, photographed on the third day, was beginning to fade, and a few groups of small vesicles had coalesced and flattened. Patient was pale, and had a tired, anxious expression, although claiming to be as strong and well as usual. There was a constant burning in the affected skin, and tenderness on pressure on the right side of spine.

The name Herpes has been used by dermatological writers, as a generic term to include all eruptions in which groups of vesicles are present. This use of the term associates Zoster with Herpes of the lips and prepuce, and with other rarer affections, which differ widely in their clinical features. It is advisable therefore, to class Zoster as an affection *sui generis*. The characteristics which serve to distinguish Zoster from Herpes may be concisely stated as follows. Zoster is almost invariably unilateral, and rarely occurs more than once in a lifetime. It presents large isolated patches of tense vesicles, seated on a highly-congested base, and usually following the course of a cutaneous nerve for a considerable distance. It is associated with neuralgic pain and a lancinating sensation in the affected skin. It usually runs a regular course of from two to four weeks and occasionally leaves

## ZOSTER.

ciatrices. Herpes is usually bilateral if at all extensive, and may be tolerably symmetrical. It occurs many times in the same patient. There is no tendency to distribution along the course of a single nerve for any distance. The pain is not of a neuralgic character. There is a great variation in the severity and course of the affection and no scars are left.

Zoster may be defined therefore, as a vesicular eruption, remarkable for its unilateral occurrence and its limitation to the cutaneous distribution of one or more nerves. Though not a very common affection it is one easily recognized, and is generally known among the laity by the name of "shingles." The eruption usually occurs upon one side of the chest or waist, forming a portion of a girdle, from which circumstance is derived the name. It may also occur upon the head or limbs, following in every instance the course of a nerve. It is only in extremely rare cases that the eruption is bilateral. The sexes are about equally liable to attacks and the eruption occurs at almost any age. In children it is annoying while it lasts, but no neuralgia is left behind, as is often the case in the aged.

The eruption usually begins after a short febrile attack, appearing in the form of one or more patches of intense hyperæmia. A pricking or tingling sensation sometimes calls the patient's attention to the part before the vesicles have appeared, but usually the patch when first seen is dotted with pearly vesicles which rapidly attain the size of hemp-seed. Frequently the vesicles vary in size upon different patches in the same case, the least developed patch bearing pin-head sized vesicles, while those upon another patch have reached the size of small peas and are distended by a clear, yellowish serum. The vesicles usually reach their maximum development in four days, remain tense for a day or more, and then gradually flatten. The inflammatory base changes in color from a bright scarlet to a dull crimson, and the amber-hued contents of the vesicles become cloudy and even pustular. In the second week, blackish crusts or scabs form, which gradually fall during the third or fourth week. The eruption may fail to reach its full development and begin dry on the second or third day.


There are, strictly speaking, no varieties of Zoster, the same characteristics appearing wherever the eruption may be situated. Regional adjectives are conveniently used, such as *Z. capitis*, *Z. faciei*, *Z. nucae*, *Z. brachialis*, *Z. pectoralis*, *Z. abdominalis*, *Z. lumbalis*, and *Z. femoralis*. The term *Zoster bullosa* might be applied to one of the cases illustrated, in which we find an accidental elevation of the epidermis by a rapid exudation of serum and a resulting confluence of the vesicles.

The cause of Zoster is to be found in some abnormal condition of the nervous system in general, or in some injury or disease of the nerve supplying the affected portion of skin. The occurrence of the disease is usually a surprise and no conditions exist which would lead one to anticipate an attack. The diagnosis is generally an easy matter, although when imperfectly developed, as it may be upon the scalp or extremities, its recognition may be difficult.

Zoster will always run its course without special treatment. It is useless to attempt to abort the vesicles with nitrate of silver or blisters. The part should be protected against the friction of the clothing by a soft linen cloth, and starch powder may be dusted on to absorb the fluid when the vesicles rupture. When severe pain is present, fifty centigrams of sulphate of morphia may be added to fifty grains of elastic collodion and painted over the patches. Internally, the phosphide of zinc, two centigrams every three hours, has been praised. As the course of the disease is variable, it is difficult to judge of the effect of an internal remedy except from observation of numerous cases.



ZOSTER HERPETIFORMIS



ZOSTER LUMBALIS





## ECZEMA.

---

CASE.—S. J. W., æt. 57. The eruption in this patient had begun five years before, on the abdomen, had gradually spread, and for a year or more had been universal. The skin was everywhere reddened, more or less thickened, and where not covered with large adherent flakes of exfoliating epidermis, as on the arms and thighs, it presented a fine branny desquamation which may be seen in the illustration upon the patient's back. Removal of the clothing always occasioned a shower of fine scales. Upon the inner aspect of the thighs, in the axillary region, and around the neck were several aggravated patches which now and then became moist. These patches were badly excoriated, and the itching of the whole body was almost intolerable. The case was a type of no single form of eczema, but the erythematous, exuding and squamous forms of the affection were all present at one time upon different portions of the body. The patient was first ordered a gram of acetate of potassium, three times a day, while diaclylon ointment was applied to the exuding patches. He was then put upon the linseed-oil treatment, recommended by Sherwell, a pint being well rubbed into the skin morning and night, and as much of the large East Indian seed given internally as the patient could conveniently chew and swallow. Under this treatment the itching abated, and the skin grew paler and smoother. After a few weeks, however, he returned to his home in a neighboring State, and here my notes of the case cease.

Eczema is the protous of cutaneous affections. It is capable of assuming such a variety of appearances that there is scarcely an affection of the skin to which it may not bear a resemblance, and with which it may not be confounded. It attacks every part of the body, and presents peculiarities dependent upon its location, as well as upon the age, occupation, habits and general condition of the patient.

The term eczema (from  $\epsilon\kappa$  and  $\zeta\epsilon\omega$ ), meaning "to boil out," or "effervesce," implies a catarrhal condition of the skin. A moist surface, or at least a tendency of the affected skin to become moist through exudation of a gummy, albuminous serum, is the chief characteristic of the disease. It has been claimed that a moist surface is always present at some time in the course of the disease, but clinical experience shows that cases of erythematous and papular eczema may remain dry from beginning to end. Even these cases, however, evince a tendency to develop a moist surface upon slight external irritation, and moist patches are not infrequently found upon an extensive eruption which elsewhere is perfectly dry. Frequently patients will state that their eczema, now in its decline, has always been dry, and the thickened patch of skin may appear to be due to increased cellular growth or some cause other than infiltration of the skin with a serous fluid. If the scaling epidermis be rubbed briskly with soap and a piece of rough cloth it will be readily removed, and the catarrhal, and hence the eczematous nature of the patch, will be revealed by the minute pearly beads of serum,

## ECZEMA.

which ooze out on the surface of the partially denuded corium. It is this tendency to exudation upon the surface of the skin which distinguishes a patch of eczema from simple inflammation or dermatitis.

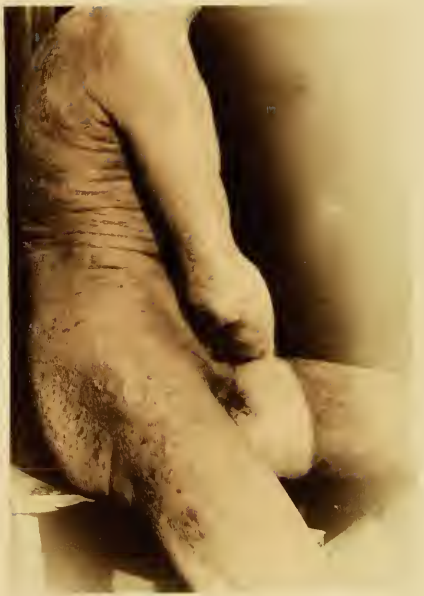The exudation in eczema varies in amount, being so slight in some cases as not to appear upon the surface, while in others it is poured out so abundantly that the whole epidermis is washed away and a smooth, red, moist patch is exposed. It varies also in character. In some cases the exudation is plastic, and being retained in the cutaneous tissue produces papulation on the surface, and infiltration and hardening of the subcutaneous cellular tissue, while in other cases it readily permeates the cells of the rete, and elevates the horny layer in the form of vesicles. Upon the surface of the skin the exudation feels sticky, and cloths or bandages soaked by it stiffen upon drying, and appear stained. In strumous and ill-conditioned subjects, the exudation assumes a purulent character. This variation in the character of the exudation results in a variety of lesions, no one of which has any claim to be regarded as the special lesion of eczema. The disease is not merely a vesicular affection, as it was classed by the earlier dermatologists, but is frequently papular and pustular as well, and in many instances there is no vesiculation from beginning to end. When the surface exudation is profuse the serum dries and forms crusts. The crust of typical eczema is thin and dark, cracking, and allowing the exudation to ooze from the cracks. Often it is composed partly of dried blood, the result of scratching. When the exudation is purulent the crusts are lighter in color and thicker, increasing in bulk by augmentation from beneath. The exudation is sometimes of a thick, honey-like character, producing a bright yellow crust.

The thickening of the skin in eczema is most marked in chronic cases. It is partly due to cellular infiltration, and partly to the exudation of plastic serum into the subjacent areolar tissue. In acute cases and in parts of the body liable to passive congestion, *e. g.*, the legs, a temporary edema often increases the thickness of the integument.

The itching of a patch of eczema is a feature which is rarely absent, but, on the contrary, usually present in a marked degree. In adults it is apt to be most troublesome in the erythematous and papular forms of the disease. In children it is usually severe, although, in the pustular form which occurs so often in those of a strumous diathesis, the symptom is always mild.

The pathological process which takes place in the affected skin consists mainly in congestion and cell-proliferation. In some cases the congestion is the main feature, and the affection is only to be distinguished from erythema by the characteristic pruritus and desquamation. In most cases, however, there are marked cellular changes, as has been shown by microscopical examination. The disease in its mildest form may begin as a simple hyperæmia. The skin becomes slightly thickened, itches more or less, and finally desquamates. Usually, however, the initial hyperæmia is followed by the development of papules, vesicles or pustules. Pruritus and exudation become prominent features, and eventually the affected skin desquamates, as in the former instance. The disease, then, always begins in hyperæmia and ends in desquamation. It is characterized by a tendency to moisture of the surface, which may result in crusting, by infiltration of the deeper tissues which produces thickening, by the development usually of papules, vesicles or pustules, and by slight or severe itching.

The differential diagnosis and the treatment of eczema will be given in connection with other plates.



ECZEMA UNIVERSALE.



## LEUCODERMA.

---

CASE.—Mrs. B., æt. 68, Scotch, widow. A patient of Dr. E. B. Bronson. The affection began two years ago, in the form of white spots on the hands. Has always been healthy, and is in good condition now. The skin of the face, neck, and arms is, for the most part, of a decidedly darker hue than normal, looking as though tanned from out-door exposure. It is marked by irregular, sharply-defined patches which, appear bleached, and are most noticeable on the nape of the neck, backs of hands, along the frontal border of the hair, on the lower eyelids, beneath the ears, and upon the arms. Patient thinks a brother was similarly affected.

Leucoderma, or Vitiligo, as the affection is sometimes termed, is an acquired loss of pigment, occurring in spots or patches on various portions of the body. It is a rare affection, occurring generally in the middle period of life, and often in persons who are seemingly in good health. The spots of leucoderma, unlike the white piebald skin of partial albinismus, tend to a gradual increase in size, although in many cases they may remain stationary for years, and sometimes there is noted a spontaneous return of pigmentation. The spots are always round at the beginning, become oval as they increase in size, until, coalescing, they form large and irregular patches, of a milk-white color, or slightly roseate where there is an active circulation of blood in the part. The skin adjacent to the leucodermatous patch is usually somewhat darker than normal, thereby rendering the affection more striking in appearance by contrast. This increased pigmentation is most marked in a narrow zone, just beyond the advancing edge of the white patch, which it sharply defines. It shades gradually off as it recedes from the patch, and at the distance of an inch or less the skin presents its normal hue.

The affection consists in an abnormal distribution of pigment, that which is taken from the affected patch being apparently deposited in the immediate vicinity. At the outset there are usually a number of small, isolated spots, which naturally become fewer as they increase in size and coalesce. The favorite starting-point of leucoderma seems to be the face, neck and hands. From these parts the affection may spread indefinitely, and eventually affect the greater portion of the body. Hebra mentions a case of long standing, in which the white patches had coalesced and covered nearly the whole body, the normal pigment remaining only in small broken patches upon the backs of the hands and feet, the elbows and the face.

Since the affection is simply due to an absence of pigment in the cells of the rete, it follows that the patch is neither elevated nor sunken, neither thicker nor thinner, neither harder nor softer than the normal skin. In some cases the leucodermatous patches appear to be unusually susceptible to the action of the sun and other external irritants. There is never any desquamation, and to the touch alone, this, unlike the majority of skin affections, imparts no information. The patient suffers no in-

## LEUCODERMA.

convenience, or at least experiences none of the subjective sensations of cutaneous disease, such as pain, hyperæsthesia, anæsthesia or pruritus, and the affection has no influence upon his general condition. When hairs exist upon the patches their growth is unimpaired, although they are usually lighter in color, if not quite devoid of pigment. The affection sometimes affects the scalp.

It is sometimes difficult, in glancing at a case of leucoderma, when the loss of pigment is extensive, to say at once which is the normal skin—the dark or the light patches. A fact to bear in mind is this. The advancing margin of a leucodermatous patch is always rounded or convex, and the edge of the normal skin is of necessity concave. Accordingly, if in a given case where doubt at first glance might exist, it is noticed that the whiter skin has a convex or scalloped margin, it is evident that we have either a patch of leucoderma or partial albinismus, *i. e.*, an affection characterized by loss of pigment; while, on the other hand, should the whiter portions of skin be found to have a concave border, or to be indented, as it were, by the dark patches, it is evident, in that case, that the white parts are the normal skin, and that we have a case of chloasma or pigmentary nevus to deal with; in other words, an affection characterized not by loss, but by increase of pigment. At the outset the round spots of leucoderma can be readily recognized as such, but when the skin is affected to such a degree that neither the normal nor the affected skin is greatly in excess of the other, the diagnosis may be difficult. It is simplified, however, when the peculiarity of the development of the affection, *viz.*: its always presenting a convex or scalloped margin, is borne in mind. From partial albinismus, which in the negro race it very much resembles, it can be distinguished by the fact of its not being congenital, but developing in adult life, and from the additional feature of its not being stationary, but usually tending to indefinite extension. In leprosy, circular white patches are met with which resemble leucoderma. They do not result simply from absence of pigment, however, and can be distinguished by the atrophic changes and loss of sensibility.

Of the treatment of leucoderma not much that is encouraging can be said. By some it is pronounced incurable, and there is a difference of opinion among writers as to the spontaneous return of pigment to leucodermatous patches. Arsenic, iron, phosphorus, cod-liver oil, and other remedies likely to exert an influence upon the nutrition of the skin may be tried, with the conviction that they will act as well, if not better, than anything else that might be given internally. Locally, an attempt may be made to lessen the pigmentation surrounding the white patches by painting the dark border with strong acetic acid, or a one per cent. solution of corrosive sublimate, or by blustering it lightly. This will not tend to cure the actual disease, but may lessen the unpleasant contrast existing between the white patch and the surrounding skin, and thus render the affection less striking in appearance. The same result might possibly be attained by applying mustard or other irritants to the white patches, in the faint hope of inducing inflammation, and a subsequent pigmentation, such as is so often seen after eczema and other chronic skin affections. When the patches are extensive the following lotion may be tried:

℞	Zinci Acetatis, . . . . .	6	grams	(℥ iss)
	Glycerinæ, . . . . .	2	“	(f ℥ ss)
	Spiritus Limonis, . . . . .	92	“	(f ℥ iiii)

M



LEUCODERMA





## CHROMOPHYTOSIS.

---

CASE.—D. M., æt. 25. A patient at the New York Dispensary. The fungous growth in this case was extremely luxuriant, and though not covering the skin as extensively as it frequently does, the spots were more elevated and more striking in appearance than in any case which I have ever seen. To the left side of the trunk the tincture of iodine was applied every second day. This, while producing the characteristic yellowish-brown staining of the normal skin, gave to the affected patches a very dark brown color, and rendered the contrast far more striking than before. To the right side was applied a twenty-five per cent. solution of ear-holic acid. This produced no immediate change, but being rubbed in thoroughly three times a day, removed the disease more rapidly than did the iodine. The patient was ordered to have his back rubbed daily with ordinary kerosene, which proved an efficient remedy.

Chromophytosis is one of the three important affections of the skin which owe their origin to the growth of a vegetable parasite or fungus. The other two are Trichophytosis (or common ringworm) and Favus. It is contagious, though not in a marked degree, and patients seldom have any idea of the manner in which they contracted the affection. The trunk and upper extremities are its favorite and almost its sole seat. It sometimes extends upon the neck, and even upon the cheeks, and may be found, in rare instances, upon the thighs. It usually commences upon the upper portion of the breast, and in many cases is quite symmetrical in its development. Although, at the beginning, the eruption may be one-sided in respect to situation, in nearly all cases of long standing, where the whole trunk is more or less affected, the symmetrical distribution of the eruption is a marked feature.

The affection begins in the form of a few pin-head-sized, yellowish, scaly spots, which gradually increase in size and number. When first noticed by the patient, there may be a score or more of isolated, brownish-yellow, pea-sized circular patches, showing very distinctly upon the background of normal skin, or there may be a small irregular patch of the same color, variable in size, with a few isolated circular spots scattered near its margin. As the eruption increases in extent, it spreads over the upper portion of the chest and follows down the median line as a rule towards the pubis. The back likewise becomes affected, though not generally in so marked a degree as the breast. The sternal region, though often the first to present the eruption, frequently becomes free in an advanced stage. The groins are usually exempt, and the axillæ and sides of the chest are not as thickly covered as the breast and back.

The circular discs are usually slightly elevated, but the diffused patches are less so, and sometimes can with difficulty be distinguished from normal skin. The margin may be quite abrupt, or it may shade off so imperceptibly that it is difficult to say exactly where the affected skin begins.

## CHROMOPHYTOSIS.

Itching is present in a moderate degree in some cases, but generally there is nothing to attract the patient's attention to the trouble, and in patients who bathe little, the affection may exist for a long time, and then be accidentally discovered. Though occurring often among those who pay due attention to personal cleanliness, and hence met with in private practice, it is far more common in that class of persons who perspire freely and bathe seldom. In Dispensary practice patients rarely apply for treatment, unless a guilty conscience leads them to mistake the eruption for a manifestation of syphilis; and yet, where patients with syphilis and other affections are stripped for examination, chromophytosis in greater or less extent is very frequently observed.

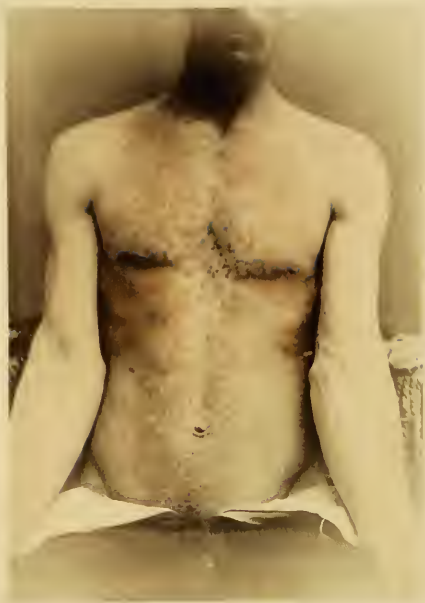The disease may persist for the greater portion of a lifetime if nothing be done to remove it. In some cases a small patch or number of patches show no tendency whatever to spread, while in other cases portions of the body become quickly covered, and the eruption shows a marked tendency to return after treatment. The disease is only met with in adults, and occurs with nearly equal frequency in either sex. It is common in early adult life, and rarely if ever seen upon the aged.

The affection is generally recognized with ease, by the color, the peculiar configuration of the patches, and the scaling of the epidermis when scratched lightly with the finger nail. In cases where the patient has bathed and used soap freely, the disease may be extensive, and yet be only recognized by the yellowish or tawny hue which it imparts to the skin. In case of doubt, the microscope will settle the question at once.

As the disease is a strictly local one, local measures will effect a cure. Care must be taken, however, that the treatment is faithfully carried out by the patient, else the disease will only be apparently cured, and in a short time will reappear. Two points should always be borne in mind. Firstly, that the affection is confined to the epidermis, and whatever means will remove the outer layers of epidermic cells will necessarily remove the disease. Secondly, that it is useless to cure nine-tenths of the disease, for if a single spot be left, or even if the same underclothing be worn again, without being thoroughly cleaned, the eruption is almost certain to return.

Sapo will cure a great many cases, if the skin be scrubbed, rather than rubbed with it, or if it be rubbed into the affected patches daily, and allowed to remain for a week. A bath taken then will remove considerable dead epidermis, and with it the spores and mycelium of the parasite. Common soft soap may be used when the *sapo viridis*, or green soap, is not easily obtained. The tincture of iodine, painted over the patches, and daubed on the small circled spots, will cause the epidermis to peel off, and thus remove the disease. This remedy, even diluted, changes the color of the affected patches to a much darker brown than the normal skin, and hence is of advantage in revealing the presence of minute spots which might readily be overlooked. An ointment of chrysophanic acid quickly cures the affection, but is objectionable on account of its tendency to inflame the skin, and to stain the clothing. When the patient is apparently free from the eruption, it is well to apply for several weeks a lotion of carbolic acid of five per cent. strength, or the following more agreeable preparation :

R.	Sodii Hyposulphit,	. . . . .	8 grams (ʒ ii)
	Aque Rosæ,	. . . . .	192 " (f ʒ vi)
M.			



CHROMOPHYTOSIS



## FAVUS.

---

CASE I.—Favus capitis. The patient was a little girl in the Children's Dept. at the N. Y. Dispensary, and under care of Dr. E. P. Williams. The case was of long standing, and the crusts were thick, light in color and friable. The child was brought only once to the Dispensary, and two years later, when I accidentally ran across the case again, I found that the mother had spent the meantime in taking the child from one public charity to another, without ever following the advice given at any one.

CASE II.—Favus corporis. From the collection of O. G. Mason, Photographic Dept. of Bellevue Hospital. The illustration shows the characteristic bright yellow, cup-shaped crusts which are seen in an early stage of the affection.

Favus is a parasitic disease occurring upon the scalp or on non-hairy parts, and is characterized by the development of sulphur-colored cup-shaped crusts. These are not met with at all stages of the disease, although they are generally present. At the beginning there may be simply a circular furfuraceous patch, which on the body cannot be distinguished from trichophytosis or ringworm. Soon, however, bright yellow specks are seen, and as the cup-shaped crusts rapidly develop, it will be noted on the scalp that each one is seated at the mouth of a hair follicle, and that its centre is generally perforated by a hair. As these "cups" become numerous they tend to coalesce, and a thick, irregular crust of lighter color is formed, and the original cup-shaped crusts can be found only about hairs at the margin of the large patch.

If, in any case of incipient favus, the crusts be removed and the hair shaven, the scalp will appear smooth and in a tolerably healthy condition, and the development of the disease may be conveniently studied. In about two weeks the parasitic growth which has remained in the follicles will show itself on the surface of the scalp in the form of minute yellow crusts around some of the growing hairs. These crusts being covered with a layer of epidermis are not, strictly speaking, upon the surface. When in a few days they have reached the size of a split pea, the margin becomes elevated, and the centre depressed, forming the favus "cup." This is concave on the upper surface, and convex beneath, fitting into a corresponding depression in the scalp, which is covered with a very thin layer of epidermis. The peculiar form of the cup arises in the following manner. The spores of the parasite grow between the layers of the epidermis, at the funnel-shaped mouth of the hair follicle. As the fungous mass increases in bulk, it raises the superficial layer at the periphery of the disc above the surface of the skin, while in the centre, where the epidermis is in connection with the hair, and immovable, a pit is consequently formed. On the under surface nothing hinders the mass in its growth from pressing down upon the succulent cells of the rete, and the convexity of the inferior surface of the cup, and the corresponding depression of the scalp, is thus produced. When a case of

## FAVUS.

favus goes untreated the crusts invade a large portion of the scalp, increase in bulk while fading in color, and finally, becoming quite friable, break and tend to fall off in piecemeal. The pressure of the cups causes atrophy of the hair roots, and bald spots of a dull, purplish-red hue, and cicatricial appearance are seen after the fall of the crusts. The hair never grows with its normal luxuriance after a severe attack of favus, but the scalp is covered with a sparse growth of wiry and curling hairs. The disease, untreated, persists until the whole scalp is affected, and the hair very nearly destroyed.

The disease presents somewhat different features according to its seat. On the head, where it usually appears, it is not often seen by the physician at the outset, but only when, through ignorance or willful neglect or mismanagement, it has been allowed to extend over considerable ground. Favus epidermidis, or favus corporis, as it is more appropriately termed, is not apt to be as severe as favus capitis. It does not present the accumulation of friable crust, and is far more amenable to treatment, on account of the inability of the spores to take root in deep follicles. The reddened and scaly circular patches which precede the development of the cups, and present a notable similarity to patches of ringworm, can be well studied in these cases. Sometimes favus co-exists upon the scalp and non-hairy parts, but in a number of cases of favus corporis coming under my observation, the scalp has been free. It has been reported as attacking the finger-nails, and from the itching of the affected scalp its transference to the nails would not appear strange.

Favus occurs chiefly in childhood, although, from lack of proper treatment, it may persist upon the scalp and be observed in middle life. It is rare in this country, as compared with its occurrence in some parts of Europe. The disease is contagious, and as it is transferred directly from one person to another, those most liable to contract it are children in schools and crowded tenements. Though a local disease, it seems to flourish best upon the scalp and skin of those who are poorly fed and cared for, and those in impaired health. Family pets are often a source of the disease, and in every case of its occurrence in a household, it is well to examine the dog and the cat. Mice seem peculiarly subject to favus, and are often caught with large, yellow crusts upon their heads. Through the cat they transmit the disease to some member of the family. In spontaneous cases, it is probable that the spores have been carried through the air, and found a favorable nidus upon a moist scalp or patch of skin. A well-marked case of favus of the scalp exhales a peculiar odor, which has been likened to that of mice. To me, the odor is more like that of an ill-kept menagerie.

The treatment is simple, although it requires much time and patience to cure a case in which the scalp is extensively affected. Favus of non-hairy parts can be readily cured by softening and scraping off the crusts and applying one of the numerous parasiticide remedies. A few weeks, at most, suffice for a cure. Upon the scalp the spores of the parasite have usually invaded the deepest portion of the follicles, and consequently no superficial applications can effect a radical cure, at least, until the hairs have been pulled out. This must be done over the whole of the affected surface, and in obstinate cases, repeated a number of times. After the epilation, a one-half per cent. lotion of corrosive sublimate, or a three per cent. ointment of chrysophanic acid may be well rubbed into the scalp several times a day, and continued until both scalp and hairs have apparently assumed a tendency to healthy growth. Even now, however, it cannot be asserted that the disease is cured, without a microscopic examination of some of the new hairs from different portions of the scalp.



FAVUS CAPITIS



FAVUS CORPORIS





## ECZEMA.

---

CASE.—W. H., *et. 25.* A patient at the New York Dispensary. The disease was of one month's standing, situated on the legs, and on the backs of the hands. It was a typical specimen of the moist and crusted form of eczema. A poultice applied over night removed the crust, which was in great part loosened by the copious exudation beneath, and a reddened and moist surface was exposed. The patient was ordered a mixture of acetate of potassium, internally, and the oxide of zinc ointment to be spread thickly on soft cloths, and applied constantly over the affected skin. This produced a marked improvement, but the patient being careless in following out directions, and unable to abstain wholly from liquor, the cure was not particularly rapid. In six weeks, however, the legs were dry and slightly scaling, when he was ordered a mixture of sulphate of iron and magnesia, with the ungt. cadini locally.

According to the German school, eczema is a local disease, and independent of any constitutional vice or humor. External treatment is, therefore, of the greatest curative value. The idea of "driving in" the eruption, or of its possible metastasis to some internal organ is rejected, and the relapse which so often occurs in eczematous patients is referred to a perverted cell-growth of the affected part rather than to any disposition to the affection existing throughout the economy.

The French school has always been the champion of the constitutional nature of eczema. The dartsrous diathesis which, emigrating to America, appears as the rheumatic diathesis, is a term employed to indicate that general condition of which the eruption in eczema (and psoriasis as well) is believed to be a mere outward expression. The local treatment, according to the supporters of this view, is of minor importance, and a radical cure is only to be obtained by remedies aimed at the constitutional defect.

The English writers on dermatology, while not generally accepting this view of the diathetic nature of eczema, lay great stress upon its association with and dependence upon gout, rheumatism, dyspepsia, etc., in a large proportion of cases, and are more disposed to favor a judicious combination of internal and external remedies. In America, these opposing views meet on a common ground, and time will undoubtedly declare the "survival of the fittest."

The predisposing causes of eczema are not thoroughly understood. There are plenty to be found outside of the profession who satisfy themselves by saying that it arises from "heat in the blood," or "bad humor," or "scurvy," and there are many able writers in the profession, who delude themselves into the belief that everything is clear when the disease is ascribed to "assimilative debility," "perverted innervation," or to some favorite "diathesis." We know that eczema is frequently associated with a rheumatic tendency, and with some of the many phases of dyspepsia, and that it is aggravated by poor food, intemperate habits, care, and overwork. Its association with

## ECZEMA.

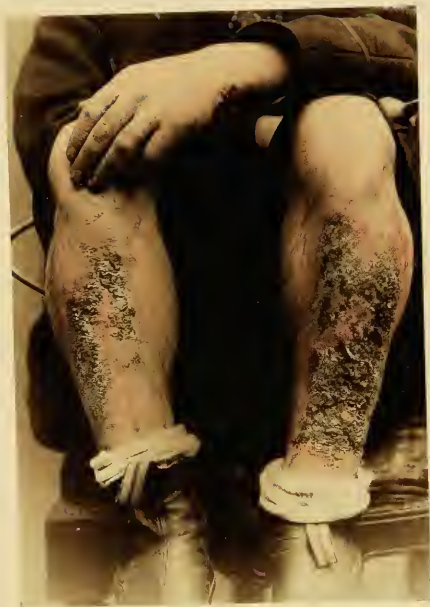dentition, gestation, worms, diabetes, etc., has been noticed so often as to suggest a relationship, and the fact should not be lost sight of when called upon to treat the disease. If not hereditary in many instances, it is certainly more prone to occur among those who inherit the delicate and irritable skin, and the rheumatic and gouty tendencies of their eczematous progenitors. The exciting causes are mostly local. Any continued irritant of mechanical or chemical nature will produce an eczema upon almost any skin, and all the more readily when some of the predisposing causes exist. The use of overstimulating ointments in other skin affections—as sulphur in scabies, mercurial ointment in phtheiriasis pubis—often evokes an eczema. Grocers, bakers, bricklayers, and others engaged in peculiar occupations, often acquire an eczema upon the hands and other parts exposed to the irritating action of sugar, lime, brick-dust, etc. Persistent moisture favors the development of the disease, and hence infants and corpulent adults are often affected where the folds of the skin come in contact. Washerwomen are very prone to a severe eczema of the hands, which is often incurable so long as the hands are frequently in water.

The constitutional treatment of eczema may be summed up in the advice to improve the patient's health in every possible way. There is no routine plan to pursue, or at least there should be none. Give tonics when needed, regulate the diet, improve the digestion, when impaired, relieve existing constipation, and rectify, if possible, all errors of hygiene. There is no specific treatment in eczema, no single remedy of pre-eminent value. The administration of arsenic, as a first and last resort in every case, is a prevalent custom which I must emphatically condemn. Arsenic is a valuable remedy in pemphigus and psoriasis, and indeed in some cases of eczema; but of so little value is it in the latter disease, as compared with other remedies, that I very rarely find any occasion to prescribe it.

The value of purgation in eczema is debated. While not accepting the old idea of a *materies morbi* being carried out of the system in this way, I must say that clinical experience demonstrates that in many cases of both acute and chronic eczema, particularly of the erythematous variety, the administration of purgatives for a few days will be followed by an immediate and a permanent improvement, and this, too, in cases which are not being treated locally, or in which local applications have had comparatively little effect. Diuretics, by stimulating the kidneys, and thus relieving the skin of some of its functional duties, certainly produce a most decided improvement in many cases of eczema, and are almost indispensable when treating patients with gouty or rheumatic tendencies.

Our natural mineral waters have a very beneficial effect in most cases of chronic and obstinate eczema, and the Ballston waters, which contain a large amount of lithia, I can especially recommend. Of the alkaline salts, either the acetate or the citrate of potassium, in one or two-gram doses (gr. xv.—xxx.), will be found of great service. This should always be taken well diluted, and either a half-hour before or an hour after each meal. In children and in ill-nourished adults cod-liver oil is of great value, and when anæmia is present, or the system of the patient indicates a general lack of vigor, iron may be given alone or in combination.

The forms of eczema and their local treatment will be discussed in connection with later illustrations.



ECZEMA CRURIS



## ECZEMA.

---

CASE OF ECZEMA INFANTILE.—W. K., aged seven months. Skin Clinic of the Woman's Medical College. The eruption, which was a typical instance of the exuding and crusted form of eczema (*E. ichorosum*), so commonly met with in infancy, was of about six weeks' standing when first seen by me. It had begun upon the scalp, and from there had spread rapidly over the face. There was a most severe itching, and enlargement of the cervical glands. The mother was in poor health, giving a clear history of syphilis, contracted eight years before, and followed by two miscarriages. The infant was only partly nursed, and was cutting its third and fourth (upper incisor) teeth. The mother was directed to dilute the child's milk with lime-water, to refrain from washing the face, and to apply the oxide of zinc ointment freely spread on soft rags kept in place by means of a mask. Under this treatment the eruption quickly improved, but soon returned again upon neglect in its continuance. An emulsion of oleum lini (33 per cent.) was now prescribed, to be rubbed well into the skin, and a half-teaspoonful to be given internally three times daily. In less than a week the face was much less inflamed, appearing paler and smoother. The mother thought that the emulsion was superior, as a local application, to the zinc oxide ointment; and as to its internal use, I can only say that it was taken as readily as cod-liver oil, and the child got well very quickly. The illustration shows the highly inflamed condition of the skin, with scattered greenish-yellow crusts, and here and there a blackish scab where the skin has been excoeriated by the nails.

Following Willan, the illustrious pioneer of English Dermatology, some writers have divided eczema into a mild variety (*E. simplex*), an inflammatory variety (*E. rubrum*), and a purulent variety (*E. impetiginodes*). This division is rather broad and indefinite, and as many cases do not fall naturally into one of the three classes it is of little practical value. As a guide in the study of the disease, an aid in the description of cases, and a hint as to the requisite mode of treatment, it is a better plan to divide eczema into stages through which the majority of cases pass in their progress toward recovery, and to classify all cases in accordance with certain well-marked clinical forms or phases assumed by the eruption, and to which a special nomenclature is applicable.

The stages of eczema are three. The initial stage is characterized mainly by hyperæmia, with slight interstitial exudation, and in most cases by an eruption of papules, vesicles, or pustules. This lasts but a few days or weeks at the most before passing into the second stage, which is characterized by exudation and crusting. The exudation may be serous or sero-purulent in character, and the inflammatory symptoms are usually well-marked. The surface exudation destroys the integrity of the epidermis and dries into light-colored crusts when not mingled with blood, which

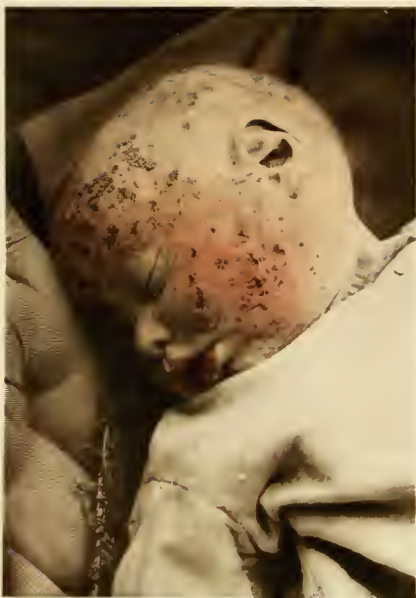## ECZEMA.

often flows freely from numerous excoriations. The second stage of eczema is of indefinite duration; but sooner or later the exudation subsides, the crusts fall, leaving a thin, newly-formed epidermis, and we have then the third or terminal stage, characterized by desquamation and a certain amount of induration of the affected part. In some instances the initial stage passes directly into the terminal stage, without the occurrence of exudation upon the surface or the development of any lesion besides the erythematous patch, and not infrequently the third stage relapses into the second, the scaling surface again becoming moist. Very often a case of eczema will exhibit the three stages on different portions of skin at the same time. At the spreading margin of an exuding patch (second stage) we see hyperæmia and vesiculation (first stage), while a neighboring patch may have become dry and scaly (third stage). The terms "acute" and "chronic," as applied to eczema, are conveniently used in describing cases, and are always suggestive of the appropriate plan of treatment; but it must be borne in mind that these terms, as commonly employed, do not refer so much to the length of time which the eruption has existed as to the grade of inflammation which it presents. An eczema of thirty years' standing might, therefore, during an exacerbation, be regarded as an acute eczema, and treated as such until the inflammatory symptoms have subsided.

The clinical forms of eczema are numberless, and scores of expressive terms have been coined and applied to them. It is simply a question of convenience whether we shall employ five terms or fifty for purposes of description. Certain it is, however, that there are six striking phases assumed by eczema, and in accord with Wilson, the most admirable writer on this disease, the following clinical forms will be described:

1. Eczema erythematosum (Pityriasis).
2. Eczema papulosum (Lichen simplex).
3. Eczema vesiculosum.
4. Eczema ichorosum (E. madidans. E. rubrum).
5. Eczema pustulosum (E. impetiginosum).
6. Eczema squamosum.

The first two and last of these forms are always dry (*E. siccum*), while the remaining three are more or less moist (*E. humidum*), although the moist surface is sometimes concealed by a crust. These forms of eczema may be accompanied by exceptional peculiarities, such as a circumscribed border, the existence of œdema, and the development of tubercles, fissures or a warty surface. The term *Eczema marginatum* is applied to an erythematous or papular patch which does not shade off at its borders, as is commonly the case in eczema. The condition is frequently seen about the genito-crural folds, and is likely to be confounded with trichophytosis of this region, of which it is sometimes a sequel. The term *Eczema rimosum* (*sau fissum*) is used when a squamous or ichorous eczema of the hand or of the flexure of joints is accompanied by the development of numerous fissures (see plate of *E. squamosum*). *Eczema verrucosum* indicates a warty condition, most frequently seen near the ankle, and generally in connection with ulceration. These accidental features are of little importance, and cases of eczema exhibiting them will be found to fall naturally into one of the six divisions.



ECZEMA INFANTILE.





## ECZEMA.

---

CASE OF ECZEMA PAPULOSUM.—Mary J., æt. 8. This girl was overgrown, pale, and poorly nourished. The eruption consisted of aggregated patches of small yellowish-red papules, with flattened, glistening summits, each dotted by a follicular opening. There was no tendency to exudation upon the surface of the skin, except from the papules which had just been excoriated by her finger-nails. The itching was annoying, and most of the papules were surmounted by dark, pinhead-sized crusts of dried blood.

Although eczema presents itself under innumerable phases, it can generally be recognized with ease when we bear in mind that its characteristic features are redness, itching, moisture, and scaling, two or more of which features are invariably present.

Erythematous eczema, as the name implies, is characterized mainly by hyperæmia. There are no vesicles, pustules, or well-marked papules, no moisture—nothing but a tolerably smooth, reddened surface, with a moderate amount of fine desquamation. In its incipient form it is merely a persistent erythema, with slight infiltration of the skin and consequent pruritus. By scratching, or other external irritation, the skin may become considerably thickened and covered with fine branny scales. This form (classed with *E. squamosum* by Hebra, and described as pityriasis by older writers) is frequently met with on the face, and usually predominates when the disease extends over the greater portion of the body. In the plate of *E. universale* it is seen, together with patches of the ichorous and of the squamous form.

When the hyperæmia, which is the distinguishing feature of both erythematous and papular eczema, is not merely confined to the superficial network of blood-vessels, as in the erythematous form, but involves also the follicular plexuses, we have discrete congested papules developed upon a reddened patch of skin. This papular eczema may be transitory when produced by external agencies (a poultice or water-dressing, *e. g.*), but it is often chronic and obstinate. When the congested follicles are not seated upon a hyperæmic and infiltrated patch but are scattered in groups upon the normal skin, the term lichen simplex has been used to denote the condition. While it is convenient for purposes of description to use the old terms lichen, impetigo, and pityriasis, it must be borne in mind that they are not distinct affections, but merely modifications of the papular, pustular, and squamous forms of eczema.

Vesicular eczema was formerly regarded as the type of the disease. Vesicles, however, are rarely present in cases of eczema when seen by the physician, and hence are of little use in diagnosis. In many cases there has been neither vesiculation nor even a moist surface throughout the course of the disease. The vesicular form of eczema is quite uncommon. It consists of numerous small acuminate

## ECZEMA.

vesicles, crowded together upon a highly-congested base. It may run an acute course, and terminate in a week or ten days (and this is usually the case when it is due to the action of some severe local irritant), or the exudation may continue after a rupture of the vesicles, and the disease then assume the ichorous form. Vesicular eczema attacking the face is often mistaken for erysipelas, especially when its outbreak is accompanied by slight fever. The smooth, tense skin, with an abrupt margin of the patch, is not seen, however, in eczema, and the speedy development of fine vesicles, or an exuding surface, dispels all doubt.

In the ichorous, or moist form of eczema, we have the condition of most frequent occurrence. The affected part is swollen and tender, and the surface either presents a reddened, raw appearance (*E. rubrum*), or is covered by a thin, dark crust, through which and beneath which the characteristic gummy exudation appears. Vesiculation may or may not have preceded this condition. The exudation may have permeated the epidermic cells and washed them away *en masse*. Indeed, a moist surface may be present in some cases without even destruction of the epidermis. When folds of skin lie in contact, as they do about the neck and joints of fat babies, and beneath the breasts and in the inguinal region of obese females, the epidermis becomes macerated, and frequently assumes the character of epithelium. For a short time the skin may appear as though converted into a mucous membrane, and discharge a viscid serum (*E. mucosum*). Eczema ichorosum, in which the disease is at its height, cannot be well confounded with any other affection of the skin.

The pustular form is in some cases not readily distinguished from the ichorous form. The exuding serum, instead of being clear and watery, may be of a thicker, honey-like consistence, and dry into yellowish crusts. The contents of the vesicles may assume a sero-purulent character, or pustules may be scattered over the surface along with vesicles, while in either case yellowish or slightly brownish crusts are formed, which increase in thickness from additions to the under surface. Pustular eczema is common in strumous and poorly-nourished subjects. It is very apt to appear in connection with scabies and with phtheiriasis both of the body and of the head. Isolated pustules are frequently developed when external irritation coincides with impaired vital energy, *e. g.*, after a season of intensely hot weather, but it is an open question as to whether these are justly regarded as being eczematous in nature. Though eczema commonly leaves no scars, this pustular form, the "milk-erust" of infancy, sometimes pits the cheeks, and, even in later years, the child shows marks which might be mistaken for the effect of variola.

The squamous form is the terminal stage of one of the other forms. It is but an exaggeration of the erythematous form—the acute hyperæmia and branny desquamation giving place to thickening and induration of the skin and subjacent tissue, with exfoliation of the epidermis. It sometimes occurs in patches upon the extensor surface of the extremities, when it is with difficulty distinguished from psoriasis. The gradual shading off of the patches at their margins, contrasting with the circumscribed border of psoriatic scales, and the existence of moisture beyond that condition which exists in psoriasis when the scale is removed and the corium exposed, are features which will usually determine the diagnosis. Squamous eczema, when universal, resembles Dermatitis exfoliativa; but in this rare affection the flakes of epidermis are much more abundant, there is no thickening of the skin, no moist patches, no severe itching, and frequently there is a high grade of fever and great prostration.



ECZEMA PAPULOSUM.



## ECZEMA.

---

CASE I., ECZEMA ICHOROSUM.—C. M., *æt.* 6. This boy seemed to be in fair health, although eczema in a more or less aggravated form covered the greater portion of his body. His skin, where it was normal, was soft and delicate, and he manifested unmistakable signs of a strumous diathesis. The eruption began upon the head when he was only three months old, soon appeared on the trunk and extremities, and since that time had never entirely disappeared. This unusual extent and persistence of the eruption was chiefly owing to neglect on the part of his parents, who had been told by viscaeres in their neighborhood that the eruption could not be cured (all of their remedies having failed), that it would be injurious to cure it, and that it would go away of itself when the boy was seven years old, &c., &c. With iron and cod-liver oil internally, and emollient applications to the skin after removal of the crusts, a cure was effected in a few months.

CASE II., ECZEMA PUSTULOSUM.—An infant with a recent and comparatively mild form of eczema. This began as a pustular eruption, the yellowish, honey-like contents of the pustules rapidly developing a crust which increased in thickness from below, while the surface grew darker in color from exposure to the air. This thick crust, which ought never to have been allowed to develop, was easily removed by the application of a poultice, and the skin beneath, though somewhat inflamed, and denuded of its epidermis, was tending to recover its normal state, and needed but a simple dressing, to exclude the air and allow recovery to take place.

The success of local treatment in eczema depends upon its adaptation to the case in hand. Innumerable are the remedies which have been recommended, but without a knowledge of the principles which govern its use, no remedy can be of much service. I will venture to assert, that so far as local applications are concerned, the great majority of cases of eczema can be successfully treated with two simple ones, which are always on hand, or very easily obtained, *viz.*, sweet oil and soft soap. Of course, I do not advise the reader to use these, since there are various emollient applications superior to the former, and stimulating remedies which may advantageously supplant the latter, but I hold that it is far better to know how and when to use even the two remedies mentioned, which typify two opposite modes of treatment, than to have a well-stocked drug store at command, and to use its contents without definite purpose. What will a bland oil or an emollient ointment accomplish in the treatment of eczema? It will soften and remove any crusts which may be present, it will soothe the inflamed parts, and alleviate the itching, and it will protect the denuded corium from the desiccating influence of the air and the irritating action of water, and thus allow the growth of a new and healthy

## ECZEMA.

epidermis. In the acute eczema of infancy, and in the acute form of the disease, at whatever age it may be met with, it matters little what oil or ointment or lotion be employed so long as it is the most soothing application that can be made. What will soap accomplish in the treatment of eczema? It will free the surface of the skin from a mass of dead epidermis, it will give exit to confined serum, it will stimulate the circulation of blood in the diseased skin, and thereby promote the absorption of the infiltrated products of inflammation. In chronic cases, where there is thickening and induration of the skin, with persistent desquamation and annoying pruritus, cases in which emollient applications are utterly inefficacious, soap frictions will change the character of the eczema from a chronic to a sub-acute form, a condition tending naturally to recovery. In fact, as quinine in the treatment of malaria, so is *sapo viridis*, or ordinary soft soap, in the treatment of chronic eczema.

The most common mistake made in the local treatment of eczema is in the application of over-stimulating ointments and irritating lotions to parts which demand the most soothing measures, and in the application on the other hand, of the oxide of zinc, or some other slightly astringent ointment, to cases in which nothing short of soap frictions or some equally harsh remedy will prove of the slightest benefit. At the risk of repetition, let me say again, that the grade of inflammation determines the selection of a soothing or a stimulating plan of treatment. If the affected part is swollen and hot, pouring forth a profuse discharge, and accompanied by an intense, burning pruritus, the local applications cannot be of too soothing a nature. If the skin is dry, thickened, indurated and scaly, the local treatment can hardly be too severe. Where the disease is extensive, as in *Eczema universale*, it is generally necessary to vary the character of the treatment upon different portions of the body.

Such, briefly stated, are the principles which govern the local treatment of eczema. As, in general treatment, the habit and idiosyncrasies of the patient must be borne in mind, so in local treatment must the character of the lesions be studied and routine practice avoided. The reader must cast aside the vulgar notion that a wonderful therapeutic power dwells in the remedy which is used, and learn that success in treatment is wholly due to the skillful adaptation of remedies to the requirements of each case.

The question as to whether the rapid cure of eczema may prove prejudicial to the patient has been freely discussed. The experience of nearly all dermatologists answers this with an emphatic negative. No pecant matter is ever eliminated from the system in the form of an eczematous discharge, and under no circumstances can the disease be regarded as salutary. It is true that the eruption, in rare instances, seems to alternate with affections of the respiratory apparatus; but this merely shows that inflammation of the skin is not apt to co-exist with inflammation of an internal organ. If a child under treatment for eczema is exposed to cold or injured by a fall, and contracts pneumonia or meningitis, the eruption naturally subsides, in consequence of the determination of blood to lungs or brain. The rapid cure of the eczema, instead of being the cause, is rather the result of the internal phlegmasia. In this way an eruption may be said to be drawn in, but it is impossible for local treatment to drive it in. I have no doubt but that in some cases of infantile eczema harm has resulted from the application of strong mercurial ointments to a large extent of skin; but it has been the mercury and not the disease which has been driven in. Death or severe illness, from whatever cause, is preceded by the subsidence of any eczematous discharge which has pre-existed, and illogical friends of the patient are not only liable, but often disposed, to mistake the cause for the effect.



ECZEMA PUSTULOSUM.



ECZEMA ICHOROSUM.





## ECZEMA.

---

CASE OF ECZEMA SQUAMOSUM.—J. Z., *et.* 20. The eruption in this case began as an acute eczema. The inflammation rapidly subsided into a sub-acute condition. Painful cracks resulted from motion of the arm, and the epidermis peeled off in large flakes, as seen in the illustration. A mixture of lime-water and linseed oil, equal parts, was freely applied, and the arm placed in a sling.

The local treatment of eczema, while depending upon the clinical form and stage of the disease, must be greatly modified in accordance with peculiarities of the region which is affected.

Eczema of the scalp, particularly in children, is prone to assume the ichorous form, and to become crusted. A poultice applied over night will remove the crust, when benzoated oxide of zinc ointment freely applied to the scalp, night and morning, will soon effect a cure. It is hardly necessary to say that a thin layer of ointment, smeared over a thick crust, will have no effect upon the diseased skin beneath. Cutting the hair short facilitates treatment; but in the case of women and young girls, who are reluctant to be cropped, it is never absolutely necessary. In the chronic cases, occurring chiefly in adults, the scalp is sometimes reddened, thickened, and covered with fine white scales. A shampoo, consisting of aromatic spirit of ammonia, one part, and water, four to six parts, will cleanse the scalp, after which perfumed cosmoline may be freely used as a pomade. When there is no tendency to moisture, ten per cent. of ammoniated mercury ointment may be added.

Eczema of the face, so common among infants, can often be cured, after numerous applications have failed, by using any one of them which is unirritating, and instructing the mother or nurse to cease washing the child's face. The diachylon ointment or the oleate of zinc ointment are satisfactory applications; but it is of little use to merely grease the face with them. The ointment must be spread thickly on soft rags or pieces of impermeable lint, re-applied twice daily, and held in close contact with the skin by means of a mask or piece of stout linen cut to fit the face, with holes for eyes, nose and mouth, and tapes to fasten beneath the occiput. The custom of tying an infant's hands or muffling them in stockings, in order to prevent the scratching during sleep, is cruel. A soothing ointment and a well-fitting mask which the child cannot pull off, will quickly subdue the itching and give both infant and attendant a good night's rest.

Eczema of the lips is usually one of the most intractable forms. I have had good success with an ointment of thymol (one to three per cent.) where a dry, wrinkled and scaly condition surrounds the mouth. A case of long-continued scaling of the opposing surface of the lips in a gentleman still under my care has resisted every remedy, internal and external, which has been used, and the affection, though by no means a serious one, appears to be practically incurable.

## ECZEMA.

Eczema of the anterior nasal passages may exist with or without an eruption upon the face. It occasions redness, swelling, and soreness of the nose, and interferes with normal respiration. The accumulated crusts should be removed by spraying the nostrils with a weak solution of borax or common salt in water, after which a pledget of lint, smeared with vaseline or diluted citrine ointment, may be inserted in one or both nostrils.

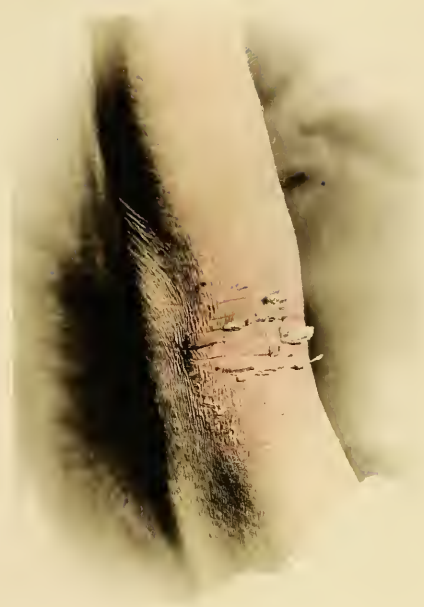Eczema of the external auditory canal is usually regarded by aurists as extremely obstinate in most cases. The frequent syringing of the ear for purposes of cleanliness tends to aggravate the disease. By reducing the zinc oxide ointment to a fluid consistence by the admixture of glycerine, and applying it frequently by means of a camel's-hair brush, the canal may be kept clean and the eczema cured.

Eczema occurs beneath the breasts of corpulent women, and where folds of skin rub together. It is the result of continued heat and moisture. In the intertrigo or subsequent genito-crural eczema of infants, the so-called "sprew" of nurses, the breech-cloths must be instantly removed when soiled or wet. In all cases, the red or raw surfaces should be washed occasionally with bran-water, dusted often with lycopodium, and kept separate by the interposition of soft linen.

In eczema of the serotum and perineal region in males, and of the vulva in females, the itching is always intense and annoying, and the condition is only aggravated by scratching. An ointment of thymol (three to five per cent.) or a lotion of carbolic acid in glycerin (fifteen to twenty per cent.), used with caution, will generally afford relief when weaker applications have failed.

Eczema manifests a decided disposition to attack the flexor surface of joints, and is frequently seen in the axilla, bend of elbow and popliteal space. In recent cases it is important to prevent drying of the skin and the consequent formation of painful fissures on motion of the part.

Eczema of the lower portion of the legs is common in middle life and old age. It is usually of long standing, and requires stimulation. When the eruption is dry, as in the erythematous and papular forms, the skin is simply reddened, harsh, itchy, and more or less excoriated. Daily frictions with green soap will soften the skin and relieve the itching. After using the soap, the legs should be carefully dried, and a slightly astringent ointment applied. In the squamous form, the soap frictions will remove the scales and often cause an exuding surface to appear. This temporary aggravation, however, by stimulating the flow of the blood through the part and promoting absorption, will speedily reduce the thickening of the skin. In the ichorous form of eczema (well shown in the plate of *Eczeina cruris*), and in the squamous form when there is any tendency to a discharge, the application of vulcanized rubber cloth is one of the best plans of treatment. It cleanses and cools the surface, promotes a copious flow of serum, and quickly lessens pain and swelling. The cloth should envelop the leg with the rubber surface next to the skin, and be held in position by a roller bandage. When the ankle is affected, the cloth may be gored or cut so as to fit smoothly. The rubber bandages, to be described later in the treatment of varicose conditions, are sometimes preferable, though more likely to irritate the healthy skin. When the leg has returned to its normal size, and the exudation has nearly ceased, the rubber is no longer of service, and the cure may be completed by applying the nitrate of mercury ointment, one or two parts, to the oxide of zinc ointment, eight or nine parts. When the skin is infiltrated, itchy and scaly, but only to a slight extent, the preparations of tar can be advantageously employed. Where there is an exuding surface the use of tar is contra-indicated.



ECZEMA squamosum.



## ECZEMA OF THE BEARD.

---

CASE.—J. G., æt. 21. Patient at the New York Dispensary. The eruption was of six months' standing, although it had been preceded by blotches upon the face since puberty. It had begun upon the chin, where it existed in a most aggravated form, thick, blood-stained crusts being held by the closely cut hairs of the beard. Near the angle of the jaw the exudation had ceased, the crusts had partly fallen, and given place to a patch of whitish scales (*E. squamosum*). The upper portion of the beard, in front of the ears, was but very slightly affected, while the upper lip was covered with dark, granular crusts. The disease existed behind the ears, and along the margin of the eyelids. There were patches with a yellowish crust on the hairy portion of the abdomen and pubic region, and the scalp was slightly affected. The patient had never suffered from severe eczema on non-hairy parts.

The bearded portion of the face is the seat of several skin affections, chief of which are eczema, sycosis and trichophytosis. These affections, when attacking the beard, present no important features which are not present when they occur upon the scalp or elsewhere. Eczema of the beard, though naturally occurring only in adult males, tends to assume a severe grade of inflammation, but differs in no essential regard from eczema of the scalp. Sycosis is an affection which generally attacks the beard, but in rare instances it occurs on hairy parts elsewhere, and presents the characteristic features of the disease, viz., suppurating nodules, developing about the roots of the hairs. Trichophytosis or "ringworm" of the beard has, in the great majority of cases, the same features as when met with upon the scalp and non-hairy parts, and does not deserve a different name. Indeed, much confusion has been introduced into dermatology by the application of different names to the same disease occurring on different portions of the body.

In order to show the points in the diagnosis of eczema of the beard, it will be convenient to describe briefly the features of these other affections.

Trichophytosis barbæ, or ringworm of the beard, is a tolerably common affection, which begins usually with one or several small circular patches, which are reddened, slightly scaly, and which tend to increase steadily in circumference. Sometimes the affected patch becomes swollen, and the surface assumes a lumpy appearance. It rarely, if ever, affects the whole beard, as does eczema, and is generally present in its characteristic circular form upon the face, neck or other non-hairy parts. It is generally a dry eruption, although, in the lumpy form (*Kerion*), there may be a yellowish, honey-like discharge from the hair follicles. Unlike eczema, it does not usually present a moist or crusted surface.

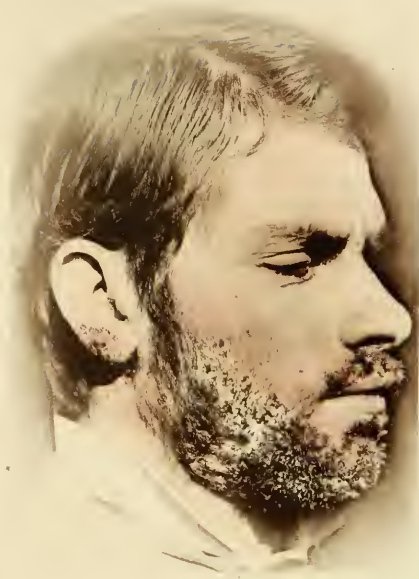Sycosis is a term which is often loosely applied to nearly every affection of the bearded portion of the face (*S. parasitica*, *S. non-parasitica*). Its use should be restricted to that inflammatory condition

### ECZEMA OF THE BEARD.

of the hair follicles and adjacent cellular tissue which is characterized by pustules perforated by hairs which in time become so loosened that they can be extracted by the gentlest traction of the epilatory forceps. The affection involves the deeper tissues of the skin, and causes a painful swelling of the part. It is often associated with eczema, and by some is regarded as nothing more nor less than a pustular form of this disease.

Eczema of the beard is characterized by the symptoms of eczema in general, redness, burning or itching, exudation, with a tendency to the formation of crusts, and finally, thickening of the skin and desquamation. Some writers claim that a pustular eczema of the beard, which of all the forms of eczema bears the closest resemblance to sycosis, can be distinguished from the latter by its extending beyond the hairy parts, upon the cheeks and neck, whereas, sycosis is strictly limited to the hairy parts. This point is not always to be relied upon. In the accompanying illustration, the eczematous nature of the eruption is clearly shown by its occurrence upon those favorite localities, the ear and eyelids, but its tendency to attack and confine itself, like sycosis, to the hairy parts, is shown by its presence in the pubic region, and its conspicuous absence beneath the corners of the mouth, where the growth of the beard has not begun.

The first step to take in the treatment of eczema of the bearded portion of the face is to dispose of the beard. This may be clipped very closely with fine scissors, shaved, or pulled out, as the necessities of the case demand. When the eruption is crusted, or the skin acutely inflamed, and exuding freely, shaving is for the time almost impossible. The hairs should be cut as short as possible with scissors, when, by a poultice or repeated innction of oil, the crusts can be removed. If now the skin is tender, and shaving proves to be a painful operation, it is well to continue the use of the scissors in preference to the razor. In the majority of cases, however, shaving can and should be performed at least thrice weekly, while the ordinary treatment for eczema is carried out. When the affected part is hot, swollen, and discharging serum, I have seen excellent results follow moderate purgation kept up for two or three days, combined with hot fomentations, or the application of the zinc oxide ointment spread on soft rags, and held in place by a bandage. An infusion of senna or viola tricolor, or the compound jalap powder may be used as a purgative. When the acute inflammation has subsided under the influence of emollient applications and due attention to the patient's general health, and the eruption has assumed the character of a dry, reddened and scaly patch, the officinal ointment of sulphur or of the nitrate of mercury may be used, diluted with from three to five parts of cold cream. When the morbid process shows a tendency to extend from the surface to the deeper portion of the hair follicles, the skin usually assumes a lumpy appearance resembling sycosis, and pustules develop around the hairs. In such a case, the treatment already mentioned is of but little benefit, and epilation is called for. The hairs are usually firm, and consequently extracted with pain. A small drop of blood occasionally follows the epilation of certain hairs, but this only acts as an anti-phlogistic, and the improvement within twenty-fours is often as surprising as it is pleasing. To allay the pain I have in some cases held a piece of ice in contact with the skin for a few minutes before extracting the hairs. When the inflammation has attacked the deeper parts, the hairs are loosened, come out with gentle traction, the root sheaths being bathed in pus. In such cases the excessive suppuration is apt to destroy the follicles, and lead to permanent baldness of the part.



ECZEMA BARBE.





## ECZEMA OF THE HANDS.

---

ALTHOUGH eczema may attack either the palmar or the dorsal surface of the hands, it rarely occurs in a marked degree upon both at the same time. One hand only may be affected, although the disease is commonly found on both, and is sometimes quite symmetrical. On the back of the hand, eczema is more apt to be of internal origin, and to co-exist with patches on the arm or elsewhere. When of long standing it may be papular or squamous, but it usually assumes the ichorous form. On the palm, eczema differs in many respects from the disease as it occurs elsewhere, and demands a peculiar mode of treatment. As met with in practice it is usually dry, and characterized by horny scales, and by deep, painful fissures occurring in the lines of flexion. Sometimes the whole palm is affected. More frequently the disease occupies but a portion, and appears as a single diffused patch or a number of isolated scaly patches of a more or less circular form. Eczema of the palm is usually chronic (in one sense of the term) from the very outset. It begins at one or more points with redness and itching, and after much gentle scratching or rubbing with the other hand it develops into a somewhat thickened and scaly patch. This increases in size by peripheral extension, or creeps over the palm with a circumscribed and curving border, very much like a squamous syphilide. There is a wide variation in the appearance of different cases. Upon a soft-skinned palm, the redness, infiltration and desquamation of typical eczema are seen, while in another case nothing is apparent but whitish patches of horny epidermis, which the patient is constantly picking or digging with the finger-nails of the other hand. Where much inflammation is present of an acute grade, the palms become swollen, and numerous fissures result from flexion and extension of the hands, until the latter become too painful to be used, and are held by the patient like claws, in a rigid and semi-flexed position. In old cases, where the outer layers of epidermis have been gradually removed, the skin of the palms is notably reddened, feels harsh and dry, though quite smooth, and the natural lines and furrows are greatly exaggerated. When the fingers in such a case are forcibly extended, the blanching of the palm, which occurs to a slight degree in a healthy hand, is well marked and characteristic.

The diagnosis of eczema of the hands is usually simple. Palmar eczema, however, may bear such a strong resemblance to scaling syphilitic patches that experienced dermatologists are often unable to make a positive diagnosis from a mere study of the lesions. According to text-books, eczema presents irregular patches, covering perhaps the whole palm and itching severely, while syphilis is characterized by smaller circular patches, with more infiltration of the skin, a circumscribed border, and an absence of itching. But there are very many exceptions to this rule. Eczema may occur in the form of small circular patches and in the center of the palm, may have a well-defined border and spread over the palm in a serpiginous manner, while a palmar syphiloderm may

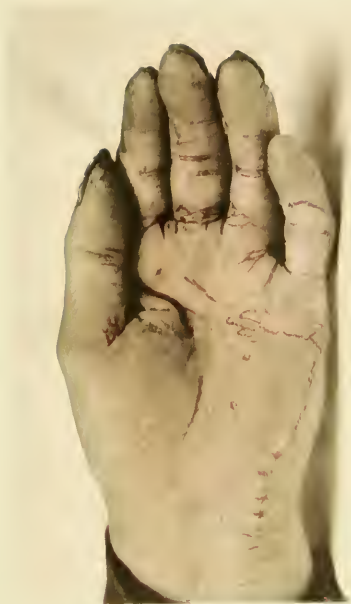## ECZEMA OF THE HANDS.

itch and crack and be aggravated by putting the hands in water, and, in short, appear exactly like an eczema. I know of but one infallible rule to apply. If a number of small scaly spots are arranged in a semicircular or horse-shoe form, with an inclosed area of healthy skin, or if a spreading circular patch exhibits an infiltrated margin and a healthy or healing center, the patch is of syphilitic origin. In a doubtful case the history of the patient is of little value, as the palmar syphiloderma, liable to be confounded with eczema, is a late manifestation of the disease, and so many syphilitic persons, particularly females, are unaware of ever having contracted the disease. The scaling papules, accompanying or following the early secondary eruption, ought never to be mistaken. Even with a clear history of syphilis, eczema may occur as an independent affection. "Psoriasis" is a term applied by many to every scaly palmar patch, irrespective of its etiology. I have never yet met with a case of true psoriasis upon the palms, either occurring alone or in connection with psoriasis upon other parts, and am convinced that nearly all, if not quite all cases reported as psoriasis of the palms have been syphilitic or eczematous.

The local treatment of eczema occurring on the backs of the hands requires no special directions. Soap frictions are useful in the papular form, accompanied with induration of the skin, and even in the case of moist patches, soap, though a harsh remedy, may be used once or twice to remove the dried exudation and dead epidermis in order to give a free exit to the confined serum. The diachylon ointment may then be spread thickly on pieces of soft cloth, and kept constantly applied to the moist, reddened surface. The affected fingers may be bandaged separately and tightly, and the hands must be kept out of water until a new epidermis has formed and there are no more fine beads of exuding serum.

Eczema of the palm requires a method of treatment quite different from that of eczema elsewhere. The thickened epidermis must be removed, the painful cracks healed, and the infiltration of the corium absorbed. The skin must then be kept in a soft pliable state, by applications, until the redness has in great measure faded and there is little tendency to itching and scaling.

Though the occasional dipping of the hands in water is harmful, there is scarcely a better mode of lessening the inflammation, and at the same time macerating the epidermis than by ordering the patient to place the palms in a shallow vessel containing a little more than enough water to cover the bottom. The water should be as hot as can be borne, and the palms kept in it for at least fifteen minutes at a time. Where there are horny patches, unaffected by the water, glacial acetic acid, or liquor potassii applied on a glass rod will be found to soften them quickly. These strong applications must be handled with care, lest severe pain be caused by their getting into the cracks. But the cracks are merely the result of the thickened and indurated epidermis, and it is useless to heal them and have them break open again. If their cause, viz., the thickened epidermis, be removed, they will heal of themselves and remain healed. Rubber gloves worn constantly (with the rubber side next to the skin) act beneficially in most chronic and obstinate cases. After the thickened epidermis has been removed and the cracks healed, the palms may remain for a long time reddened, dry and harsh, with a constant tendency to become worse again. An ointment containing ten per cent. of oil of cade in vaseline does well in such cases, but success will depend less upon local measures than upon the internal treatment adapted to eczematous cases in general and to this patient in particular.



ECZEMA MANUM.



## VARICOSE ECZEMA: VARICOSE ULCERS.

---

CASE I.—M. H., æt. 60. Patient at the New York Dispensary. For thirty years the superficial veins of both legs had been varicose, and during the past four years he had suffered more or less from eczema in this region. At the time of sitting for the photograph, the disease, through neglect or mismanagement, had assumed the ichorous form. It was mostly covered by a dark-greenish or blackish crust, which had split after drying and contracting. The curling up of the edges of this rent showed the red, raw skin beneath bathed in an ichorous discharge.

CASE II.—B. R., æt. 55. This patient had a moderate varicosity of the superficial veins of the leg, with an ulcer near the inner malleolus of four months' standing. The skin around the ulcer was congested and extremely sensitive to pressure. It had been gradually growing worse, though under treatment. An elastic tubular bandage was applied to the calf, and adhesive straps to the ulcer, under which treatment the redness and soreness about the ulcer rapidly disappeared, and healing began at once.

The permanent dilatation of veins to which the term varicose is applied begins usually in early or middle life, and affects chiefly the internal saphenous and its branches. The enlarged vein may be simply distended, or it may be hypertrophied, and either form a tumor by doubling on itself, or run a serpentine course for a short distance. About the ankle and on the dorsal surface of the foot, it is common to find the venous twigs dilated, and appearing as numerous purplish blue dots or streaks. The cause of varicose veins is not always apparent, although ill health, standing occupations, pregnancy, tight garters, &c., doubtless exert an influence in their production. The result of their presence, however, rather than their causes, renders them of importance from a dermatological standpoint. In many persons varicose veins of the lower extremities exist for years without producing any effect upon the skin, or even inducing any feeling of discomfort. Given, however, a tendency to eczema in such a case, and it will not be long before some external irritation will provoke an eruption which will prove rebellious to ordinary treatment, on account of the œdema and infiltration of the skin, which in time becomes associated with varicose veins of the leg.

The treatment of varicose eczema involves the ordinary therapeutic measures adapted to the cure of the disease, with the addition of a support for the enlarged veins. So long as the limb is allowed to swell daily from the pressure of a column of blood, so long will lotions and ointments fail to effect a cure. Where the limb cannot be maintained in a horizontal position (and exercise is as desirable in many cases as it is unavoidable), some form of a bandage or elastic stocking is required. The ordinary roller, if smoothly applied, answers a two-fold purpose in compressing the limb and keeping the dress-

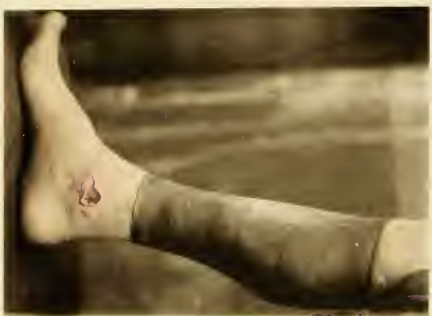## ECZEMA.

ings in place. But rarely do we find a patient who can make the reverse turns properly, and a bandage twisted around the leg and drawn tight to keep it from sliding down will do more harm than good. A flannel roller is preferable to one made of cotton cloth, on account of its greater elasticity and softness, and when applied moist it will produce a tolerably firm compression of the leg. As for the elastic stockings in the market it may be said that the cheap ones are useless, while the good ones are too expensive for a large class of patients. The rubber bandage introduced by Dr. Martin has of late become widely known and deservedly popular. It not only supports the dilated veins and thus tends to remove a cause of the eruption, but by its local action it macerates the epidermis, and facilitates the escape of serum confined in the skin and subcutaneous tissue. By its elasticity it exerts a constant pressure on the leg, and induces a rapid absorption of the products of inflammation. It is, in fact, a happy combination of the impermeable rubber dressing and the elastic stocking. It can be applied by any patient of average intelligence, as no reverse turns are needed, it can be tightened or loosened with ease, and, unlike the ordinary roller, which speedily becomes loose, it maintains its pressure even when the leg decreases in size by subsidence of the œdema. The rubber bandage should be applied in the morning before the patient gets out of bed. At night, after its removal, both leg and bandage should be washed and carefully dried. The bandage may now be re-applied, or if the infiltration has nearly disappeared, and especially if the skin is much irritated, it is better to dress the leg with an emollient ointment and to wait until morning before re-applying the bandage. In cases where the bandage is applied for an eczema of the ankle or lower part of the leg, the healthy skin above may become irritated. This can be prevented by dusting the sound skin night and morning with powder of starch, oxide of zinc or bismuth, but it indicates an eczematous tendency on the part of the patient and suggests greater reliance on internal medication.

Varicose veins play an important part in the causation of ulcers of the legs, but they are rarely the sole cause. In many persons they exist for years, without causing either eczema or ulceration, and, indeed, an ulcer may co-exist with varicose veins, without there being any relation between the two. It is therefore a mistake to call every ulceration on the leg a varicose ulcer, simply because enlarged veins are present. The true varicose ulcer develops usually upon an eczematous base, but it may be a simple, traumatic ulcer resulting from a fall, a kick, or a scratch, and aggravated or kept from healing by the presence of varicose veins. A simple ulcer occurring about the ankle, where œdema is so common, is very apt to be aggravated by the pressure of blood in dilated veins. It may be irritable or indolent, and in time it may become callous. The applications which have failed to cure it, will often succeed, when the blood pressure, and consequent congestion, is removed. The ordinary rubber bandage is of excellent service in these cases, and nothing does so well in the treatment of an ulcer with thickened edges. In other cases I have used with success a device which I term the elastic tubular bandage. This can be made of rubber sheeting, just thick enough to be sufficiently strong, and of varying size to suit various legs. When drawn upon the leg, it is like an extra skin, fitting closely, though pressing less upon the lower part of the leg than upon the calf, where the pressure is desired. It can be worn for a month or more at a time, rolling it up from the bottom halfway, then down from the top, when ablation of the skin is called for. It is far lighter, and consequently much more comfortable than the ordinary rubber bandage.



ECZEMA F. VENIS VARICOSIS.



ULCUS VARICOSUM.





## PSORIASIS.

---

CASE OF PSORIASIS ANNULATA.—O. H., *æt.* 22. Three years ago this patient was first attacked, a scaly spot appearing upon the scalp near the vertex. This was in the spring, and before the following winter the eruption had developed to about as marked a degree as is shown in the illustration. Under different physicians a variety of remedies were employed, including cod-liver oil, alkalies and arsenic internally, and glycerine, iodine, acetic acid, Vlemingkx' solution, tar, etc., locally. When first seen by me, he had for over a year been taking large doses of liquor potassii, and his health was considerably impaired. The eruption, which had varied in form and severity at different seasons, though never manifesting a tendency to disappear, was now present upon the greater portion of the body. Upon the breast and back were scaly ridges forming circles of varying size, many of which were confluent and embraced areas of smooth and slightly reddened or pigmented skin. On the extremities and particularly on the hands were guttate or nummular spots of recent appearance. The eruption upon the scalp was quite noticeable along the margin of the hair on the forehead and neck. On the face were irregular patches of a very faint red color and free from scales.

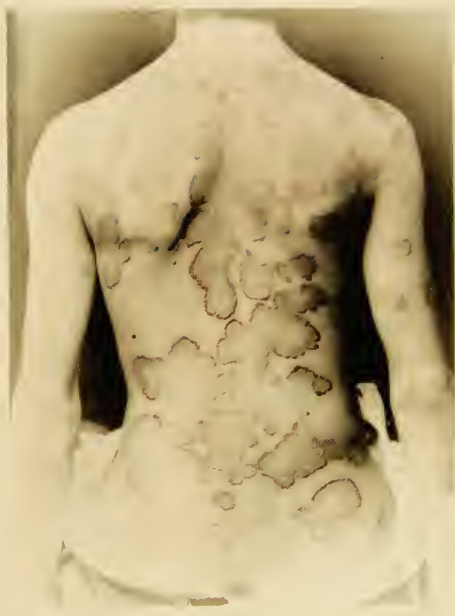The first step in the treatment of this case was to stop the heroic internal medication. Then, with Turkish baths three times a week, and a moderate amount of exercise, to which the patient had long been unaccustomed, his health began to improve, and the eruption began to subside. An ointment of ammoniated mercury (U. S. P.) applied to the head, improved the condition of the scalp, and removed the eruption from the face, while the oleum rusci rubbed into the patches upon the body, rapidly caused the rings to break up into small isolated spots of infiltrated skin. In three weeks there was a decided change for the better in the condition of the skin. The liquor potassii arsenitis was now given in doses, varying from three to ten drops (as large as he could tolerate), and the tar superseded by a 20 per cent. ointment of chrysophanic acid applied at first on only one-half of the body. This proved to be far more efficacious than the tar, and in two months the patient left the city for his home with only a few reddish papules remaining as a relic of the eruption.

In nearly every case of psoriasis there is undoubtedly a morbid condition of the economy, an ill-defined something, deeper than the scaly patches. Some call this the disease, and regard the cutaneous affection as a mere symptom. Others apply the term psoriasis solely to the cutaneous lesions, and look upon internal morbid conditions as predisposing causes. The supporters of the diathetic nature of psoriasis assert that local measures cannot cure the disease, while others claim that when the skin is restored to its normal condition the disease is cured for the time being, although the imperfectly understood causes still existing may induce its return. This is a mere quibble. Local applications will restore the skin to its normal state in nearly all cases, while in many it is extremely

## PSORIASIS.

difficult to prevent relapses, even with internal treatment. Most cases of psoriasis demand a combination of internal and external treatment, but where the general health is good, local treatment is of chief importance. In estimating the value of any local application or plan of treatment it must always be borne in mind that psoriasis is rarely stationary, but tends to improve or to completely disappear at certain seasons of the year. The value of a remedy can only be determined, therefore, by observation of its effect in a large number of cases.

In the local treatment of psoriasis, our aim should be three-fold, viz., to soothe the skin, to soften and remove the scales, and to promote absorption of the infiltrated patches. In no disease of the skin is bathing of more importance than in psoriasis. The Turkish bath fulfills each of the three indications above mentioned, and often does more to improve the general health of the patient than the administration of drugs. When the psoriatic patches are red, itchy and irritable, as they frequently are, the mistake is too often made of giving arsenic internally, and applying stimulating applications to the diseased skin. It is far better, in such cases, to prescribe a daily bath with innunction of cosmoline, or vaseline, until the acute inflammatory symptoms have subsided. Intense itching may be allayed by means of a lotion of carbolic acid (10-15 per cent.) in glycerine. The irritability of the patches being subdued, soap frictions may be added to the bath to remove the accumulated epidermis, although, when the scales are but moderately thick, they are quickly softened and removed by the stimulating ointment employed to lessen the infiltration of the skin. When in inveterate cases the scales are like plates of horny armor, they need to be softened by painting them with acetic acid and scraping them off with a curette, or by enveloping the limb, or even the body, in a closely-fitting garment of vulcanized rubber cloth, worn with the smooth side next to the skin. To the red and thickened patches now exposed may be applied one of numerous stimulating remedies of variable strength. Tar has been most extensively employed, and its most convenient form, the oil of cade, is a serviceable application. It should be rubbed into the patches in its pure state, as it is of little service when diluted. The mercurial preparations used in the form of ointments are scarcely inferior to tar in their effect, and vastly superior as regards the cleanliness and comfort of the patient. I rarely use anything but the ointment of ammoniated mercury upon the face and scalp, while for patches on the body I have used with satisfaction an ointment of calomel (10 per cent.) in cosmoline. Recently a remedy has come into use which acts with surprising effect in many cases of psoriasis. And it is in those inveterate cases which have heretofore resisted treatment that goa powder, or its active constituent, cbrysophanic acid, displays its brilliant curative powers. In the irritable cases it fails, or aggravates the disease, and in those cases which yield readily to the other applications already mentioned, chrysophanic acid cannot be recommended, on account of its objectionable qualities, viz., its liability to inflame the skin and to stain the clothing. It is best employed in the form of an ointment, made by dissolving the acid in hot lard or vaseline. The strength may vary from five to twenty per cent. according to the severity of the disease and the susceptibility of the healthy skin to its action.



PSORIASIS *IMPLICATA*.



## LUPUS VULGARIS.

---

CASE.—G. W., æt. 30.—Patient at the clinic of the University Medical College. The disease had existed for twenty-one years. It began, according to patient, in the form of a small scaly pimple midway between right eye and ear, a region now occupied by cicatricial tissue. It spread very gradually, in spite of the endeavors of several physicians, who employed both internal remedies and caustics. Four years before the photograph was taken a patch appeared upon the scalp near the vertex. This has not been treated as yet, and is slowly enlarging. At the college clinic Dr. Piffard scraped with the dermal curette a portion of the patch near the ear. On a subsequent occasion he scraped and cauterized a portion of the lower edge of the patch, the patient being under the influence of chloroform. The patient now being transferred to my care, I endeavored to check the spread of the patch, and particularly to prevent its further extension upon the eyelid. Caustic potassa in solid stick was applied successively to portions of the edge of the patch. Absorbent cotton wrapped about a probe and dipped in the liquefied potassa was used when working upon the eyelids. By means of these applications, frequently repeated, the elevated margin of the patch was soon reduced to a level with the adjacent healthy skin, the ridge of lupus infiltration being converted into a cicatricial belt. The patch was then covered with adhesive mercurial plaster for a few weeks. It is now quite smooth, of a dull reddish hue, looking at a distance somewhat like a faint port-wine mark. The center, composed mainly of old cicatricial tissue, is comparatively white. There are neither tubercles, pustules nor scales at present. The lower portion of the patch, to which the thermo-cautery was applied, is remarkably smooth, and the edge of the patch can hardly be made out, as the redness of the burn shades off into the surrounding healthy skin.

Lupus is a chronic affection, presenting circumscribed, dull reddish patches of diseased skin, which tend to ulcerate, and invariably leave a scar. Except in its severe forms there is a notable absence of pain, itching and other subjective sensations. The disease runs a variable course in different cases, and presents variations in appearance at different stages. The most characteristic lesion is a small yellowish-red papule, which can frequently be noted at the margin or in the vicinity of a patch. It is not present in all cases. Sometimes the disease begins as a dull reddish macule, which becomes slightly elevated and scaly as it increases in size. This mild or erythematous-squamous form of the disease may occur in one or in several patches of irregular form. It creeps slowly over the surface attacked, and in many cases disappears without ulceration. The cellular infiltration, however, usually produces a certain amount of atrophy of the skin, and being absorbed, leaves a more or less distinct cicatrix. When, as is commonly the case, the disease develops by the aggregation of small, solid papules, the patches usually present an elevated, crescentic and sometimes a scalloped border. Not infrequently a prominent ridge of infiltrated skin will be seen surrounding a tolerably smooth, and

## LUPUS VULGARIS.

in some cases a cicatricial center. As the papules of lupus increase in size and become tubercular they evince a marked tendency to soften, and to form small ulcers, especially at the advancing border of the patch. This now will present a reddened and scaly surface, with numerous small crusts near the periphery and areas of cicatricial tissue in the center. When the cellular growth invades the deeper portion of the skin ulceration is likely to occur, sometimes assuming a serpiginous form, and often proving difficult to heal. The face is the favorite seat of the disease, and the cheeks, upper lip and wings of the nose are affected with great frequency. It also occurs on the scalp, trunk, and particularly on the backs of the hands and fingers. The mucous membrane of the oral and nasal cavities may be affected coincidentally with the skin.

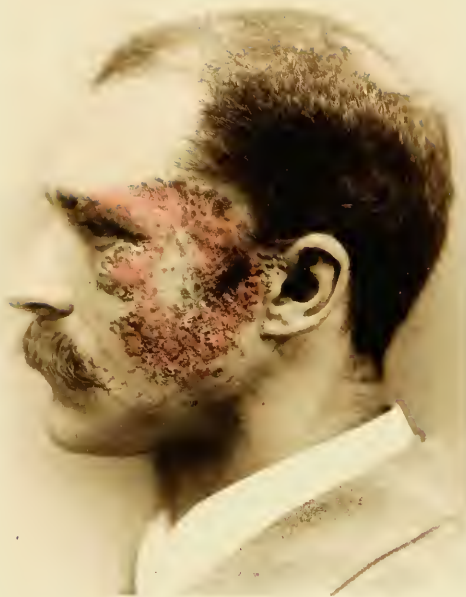The disease is never congenital, and rarely, if ever, hereditary. It generally develops in childhood or early life, although I have noted its first appearance in a man of sixty. The sexes suffer with about equal frequency.

Lupus is regarded by some writers as being invariably a cutaneous manifestation of serofula. It surely occurs in some patients who are far from presenting signs of a strumous diathesis. On the other hand, serofulous abscesses often lead to an ulcerative process in the skin (serofuloderma), which surely ought not to be designated as lupus.

The diagnosis of lupus is generally easy, but the tubercular and ulcerative forms of the disease sometimes bear such a strong resemblance to syphilis that nothing but experience in the treatment of the two diseases will enable one to decide as to the nature of the case. The age of the eruption is of the greatest importance in arriving at a conclusion, since lupus is a disease of slow progress, while the cutaneous manifestations of syphilis develop with considerable rapidity. If a patch of tubercles or an ulcer on the face is of doubtful nature, it may be considered syphilitic if it is extensive and has developed within a few months, while, if it has existed without much change for several years, it is assuredly lupus.

Lupus is by no means the obstinate or incurable disease which the majority of physicians think it to be, provided the patient will submit gracefully to the proper treatment. This is simple, though in many cases it is of necessity somewhat heroic. The quickest way to cure the disease is to destroy it, and the scar resulting from treatment will probably be much less unsightly than that which would, in time, result from the ravages of the disease. Scarring indeed, is inevitable in all cases save the most superficial. These mild cases may be successfully treated by the employment of vigorous soap frictions, and the application of highly stimulating ointments. But when the patch is deep-seated, the speediest, surest, and even the pleasanter plan of treatment is to excise it while it is small. Much destruction of tissue and consequent disfigurement might have been spared in hundreds of cases by a timely use of the knife.

Where tubercles are scattered over a considerable extent of surface, an arsenical paste, or a fifteen per cent. ointment of pyrogallie acid may be applied to the patch, or each tubercle may be bored out with a solid conical-pointed stick of fused nitrate of silver. In cases of extensive ulceration, healing may sometimes be induced by the use of acetate, sulphate or chloride of zinc, caustic potash, nitric acid, or the acid nitrate of mercury, but it is usually advisable to destroy the diseased tissue by scraping the ulcer thoroughly, and then applying the actual cautery.



LUPUS VULGARIS.





## LUPUS ERYTHEMATOSUS.

---

CASE.—V. W., æt. 45.—Patient of Dr. Weisse, presented at a meeting of the N. Y. Dermatological Society. The disease, which was of eighteen years' standing, began as a red patch on the right cheek, and extended gradually until it invaded the forehead, ear and neck. The affected skin was red and hot, rather smooth, but scaling slightly in circles extending peripherally from the nose. It appeared tightly drawn, was moderately thickened and but slightly elevated. The margins of the eruption were sharply defined.

Lupus erythematosus, though described in most text-books apart from lupus vulgaris, is not to be considered as a distinct affection. It is merely a peculiar variety of lupus, in which the cellular infiltration is quite superficial, involving in a characteristic manner the sebaceous follicles. Unlike the common lupus already described, this comparatively rare form does not tend to ulceration, although, when the infiltration is sufficient to produce atrophy of the skin, a cicatricial surface results. The name lupus erythematosus is an unfortunate one, since the common lupus (*L. vulgaris*) is frequently superficial and erythematous, and confusion has arisen from a restricted use of the adjective. The distinctive peculiarity of the variety of lupus now under consideration being the involvement of the sebaceous glands, it would be far better to employ a term such as lupus *sebaceous* or lupus *acneiformis*. Hebra, who first described this peculiar affection of the skin in 1845, gave to it the name *Seborrhœa congestiva*, but later saw fit to class it as a form of lupus.

The course of the disease is notably chronic. In rare instances it has been observed to attack a large extent of cutaneous surface like an acute eruption, and to be accompanied with severe constitutional symptoms. Frequently injudicious treatment or some other cause may induce a patch of long standing to become acutely congested. Such an exacerbation of the disease is often coincident with the development of new lesions. As a rule the affection exerts no perceptible influence on the general health of the patient. It is far more likely than the common form of lupus to be accompanied by subjective sensations, such as burning or even a slight itching. The disease usually makes its appearance in the form of small, red, pinhead-sized macules, which will not quite disappear on pressure. They present slight depressions in the center, where the sebaceous follicles open upon the surface of the skin, or, as is usually the case, these minute pits are filled with fine, adherent, fatty scales. These characteristic primary lesions may be disseminated or grouped. In the latter case they form patches of a dull reddish or violaceous hue, dotted with numerous whitish points, or covered with fine adherent scales, which, when gently raised, show prolongations from the under surface corresponding to the sebaceous follicles. The patches, of which there may be one or several, are usually sharply

## LUPUS ERYTHEMATOSUS.

defined. They may have an irregular outline, with primary efflorescences scattered about the margin, or be circular in form, in which case they are apt to become depressed as the disease progresses. The disease almost invariably attacks the face. Occurring, as it frequently does, upon the bridge of the nose, and extending laterally upon either cheek, the configuration of the patch is suggestive of a butterfly with outspread wings.

Like the vulgar form, lupus erythematosus is sometimes associated with indications of struma. It is more frequently met with in females, and in this sex is more apt to run a severe course. It does not develop in childhood, as does lupus vulgaris.

It is often quite difficult to distinguish lupus erythematosus from the superficial or erythematous-squamous form of lupus vulgaris. But since the nature of these two varieties is essentially the same, and a similar treatment required in either case, the differential diagnosis is of little practical importance. Still, it is well to bear in mind, that, whereas one variety has numerous white specks, or in some cases minute horny projections upon the diseased surface, the other variety presents small papules, and at a more advanced stage, tubercles, pustules and ulcers. The age of the patient may furnish a clue, as only the common variety of lupus is met with before the age of adolescence. A patch of chronic eczema of the face, or a rosacea, might be mistaken for erythematous lupus, and harm result from the unnecessary use of caustic applications. But these affections have not the sharp border of lupus, and while the former differs in being quite itchy, and perhaps moist, at times, the latter may be recognized by its development of tubercles and pustules.

In the treatment of this affection, I know of no indications for any particular remedy, although whatever will improve the general health of the patient should naturally be given; it may be iron in one case, cod-liver oil in another, and arsenic, strychnia, or phosphorus in others. The internal use of the iodide of starch in lupus erythematosus has recently been recommended upon such good authority (Anderson), that I mention it, though without experience in its use. The local treatment is of the highest importance. Frictions with green soap may be at first used to remove the scales and to promote absorption of the diseased tissue. Tar, sulphur, and other stimulating applications may now be used with more or less effect, but my experience has led me to rely far more upon the constant application of adhesive mercurial plaster. In some mild cases this will effect a cure. Generally, however, stronger applications are called for. A tincture of iodine of double strength combined with an equal part of collodion, may be used as a varnish, and renewed as often as it peels.

Where the infiltration is deep, a strong solution of caustic potash may be applied to successive portions of the patch. In severe cases the dermal curette may be employed to scrape away the diseased tissue, and the raw surface very lightly touched with the galvano cauter. When active congestion is present, caustics should be withheld until after a course of soothing applications has put the skin in a less irritable condition. Otherwise, a mild caustic may stimulate rather than decrease the affection.



LUPUS ERYTHEMATOSUS



## EPITHELIOMA.

---

- I.—CASE OF EPITHELIOMA RODENS.—Negative from the Bellevue collection. The disease in this case probably began upon the lid, gradually invaded the conjunctiva and destroyed the eye. The peculiar elevated and sinuous border of the ulcer is well shown in the illustration.
- II.—CASE OF EPITHELIOMA SUPERFICIALE.—Patient at the skin clinic of the University Medical College. The circular form of the patch, with its nodular margin and central depression, is quite characteristic. The growth was removed by Prof. Piffard in the presence of the class, and the wound healed quickly.

The term cancer implies a malignant growth which tends to invade and destroy certain tissues (notably the cutaneous and glandular), which is prone to recur after excision, and which induces a peculiar diathetic condition frequently ending in death. Epithelioma is one of the least malignant forms of cancer, and develops primarily on a cutaneous or mucous surface.

Like other affections of the skin, epithelioma presents a variable appearance in different subjects, in different parts of the body and at different stages of its growth. Four clinical forms may be described, viz., a superficial, a rodent, a deep-seated and a papillomatous form. These forms or phases may present themselves in a single case as successive stages in the progress of the disease.

The superficial form appears at first as a small, roundish, slightly-elevated patch of colorless infiltration. It may remain in this condition for three or four years, scarcely noticed by the patient. Slowly one or more flattened papules of a yellowish-white or waxy hue are developed, forming a rather prominent and dense growth, usually of circular or oval form. Arriving at the size of a three or five-cent piece the central portion becomes depressed, while the border remains smooth and glossy or assumes a nodular aspect. Frequently the growth is composed of three or four nodules grouped so as to resemble the crown of a molar tooth, with fine blood-vessels running between them, and ramifying in the central depression. When superficial ulceration develops a thin scab in this central pit, the growth bears some resemblance in form and appearance to a well-developed vaccine vesicle.

The rodent form, *i. e.*, a rodent ulcer, may begin, as has been intimated, in the center of the superficial, hutton-like epithelioma, and, by extending in depth and circumference, gradually convert this into a circular, polygonal or irregular ulcer with a sharp-cut border, an elevated, indurated and flattened margin, and a clean glazed surface. By the growth of dense waxy nodules at the periphery, and the necrosis of the inner surface of the wall, this ulcer increases in size, and in a few years becomes as large as a silver dollar, or larger. It is remarkably slow in its growth, and may exist for fifteen or twenty years without affecting the general health of the patient, or involving the neighboring lymphatic glands. The rodent epithelioma often originates in an insignificant "pimple" or "wart,"

## EPITHELIOMA.

which becomes scratched or injured, and forms a blackish scab. This, when removed, discovers a small ulcer of trifling appearance, but which shows little tendency to heal. If, under treatment, it cicatrizes, it is only to break out again and to form a larger sore. This ulcer may be annular, and inclose an island of cicatricial tissue, or crescentic in form, or serpiginous in its character, creeping over the surface and leaving a superficial scar in its track. The induration is so superficial as not to be always readily distinguishable, destruction of tissue seeming to keep pace with the new growth.

The deep-seated or infiltrating form of epithelioma may follow the superficial or rodent form, and its clinical features will depend upon its location. When the eyelid is attacked the disease usually begins as a superficial nodule. In a few years or sooner the whole palpebral opening becomes affected, and the disease assumes the rodent form. Destructive ulceration may now attack the conjunctiva and quickly destroy both lids and eye. Indeed, the disease often progresses in depth, destroys the bones of the orbit, and produces a most frightful cavity. A similar destructive process sometimes ensues when the disease is situated near the nasal orifice or the oral commissure. When the infiltrating form begins as such, which is usually the case upon the lower lip, there is developed a hard tumor of pea or marble size, slightly elevated above the surface. It is at first movable, but later adheres to the subjacent tissues. This tumor is almost invariably single, and eventually becomes an ulcer, through necrosis of the central portion of the mass and the formation of an abscess. It runs a more rapid course usually than the rodent ulcer, and differs from this form of epithelioma chiefly in its tendency to implicate adjacent glands. The papillomatous form is uncommon, and may be regarded as a peculiar warty development of the superficial or rodent form.

Epithelioma usually attacks the face, thirty per cent. of all cases appearing upon the lip. It occasionally occurs upon the genitals, particularly in the male, and may occur elsewhere. The superficial or rodent form occurs usually about the eyes and nose, while the favorite seat of the infiltrating form is the lower lip. On the scrotum the growth is at first superficial, but soon progresses in depth. On the glans penis, and especially the coronal portion, the superficial or papillomatous form is most apt to occur, frequently with swelling and induration of the lymphatic vessels of the dorsum penis. Epithelioma usually occurs in patients over fifty, but it may occur before that age. Seventy-five per cent. of cases occur in males. In old persons subject to epithelioma, a peculiar atrophic whiteness of the skin over the temples is sometimes observed, with various indications of degeneration, such as numerous small specks of xanthelasma and patches of seborrhea covered by horny and blackened scales. The etiology of the disease is obscure, and in most cases neither patient nor physician can assign any reasonable cause for its development. In a small percentage of cases a family history of cancer can be traced. Local irritation undoubtedly acts as a predisposing cause, but its influence has been greatly overrated. For instance, the term smoker's cancer has been used as a synonym for epithelioma of the lip, and where a patient, like the subject of our illustration, has for years performed his daily labor with pipe in mouth, the name might seem to be warranted. But other men smoke constantly at their work and do not have epithelioma, while the disease frequently attacks women, and men who never smoke. In like manner the chimney-sweeper's cancer, or epithelioma of the scrotum, occurs in countries where the construction of houses is such as to furnish no occupation for this class of laborers.



EPITHELIOOMA RODENS.



EPITHELIOOMA SUPERFICIALE.





## EPITHELIOMA.

---

CASE OF EPITHELIOMA OF LIP.—P. D., æt. 73.—This patient came from a long-lived ancestry, his father having died at the age of 105. He had always been a strong, healthy, hard-working man before the development of the epithelioma, and had worked generally with a pipe in his mouth. Two and a half years before the photograph was taken, a small lump began to be felt on the left side of the lower lip. This became hard, superficially eroded, and covered with a scab. Gradually the growth invaded the greater portion of the lip, although it was over two years before destructive ulceration began. When applying for treatment at the Northwestern Dispensary, the lower lip presented a deep irregular ulceration with a marked degree of induration. Near the oral commissure, the borders of the ulcer were quite protuberant and everted. In the central portion of the lip there had been loss of tissue, and there was such a continual dripping of saliva that the patient usually kept a handkerchief pressed upon his chin, and in sitting for his photograph it was necessary to put a rubber cloth over his breast to protect his clothing. On upper lip, beneath one nostril, there was a pea-sized, whitish, indurated nodule. At the junction of the wing of the nose and lip there was a slit-like ulcer, with a slightly indurated edge and bottom, nearly healed. This is not seen in the illustration, being in the shadow of the nose. Patient stated that ten years before he was cut at this spot by a barber. The narrow, depressed cicatrix had only become indurated and slightly eroded during the past three months.

The treatment of epithelioma usually demands prompt and active measures. When the disease is evidently increasing in extent by involving adjacent tissue, there should be no temporizing. The earlier the patch can be destroyed the better, and it is as well to destroy a little healthy skin at the margin of a small patch as to allow the disease to invade and destroy it. When progress is very rapid, the immediate removal of the diseased part, or its complete destruction by means of a powerful caustic, is the only treatment worthy of being considered. As to value of tonics, good food, and fresh air, I need not speak, as no one will doubt their indirect influence in lessening the spread of the disease, and in augmenting the beneficial effects of an operation. But while internal treatment may be advantageously employed to put the patient in the best possible condition before attempting to remove the growth, no time should be lost in the endeavor to eradicate it by internal medication whenever it evinces a disposition toward active growth. The question as to whether internal medication can possibly have a direct effect upon the growth of epithelioma is *sub judice*. Although the results following the use of most of the anti-cancerous remedies which have enjoyed a widespread though transient reputation, are either disappointing or

## EPITHELIOMA.

delusive, it by no means follows that a specific remedy, or one acting as decidedly as does quinine in intermittent fever, may not exist. The majority of writers agree in rejecting the idea that any direct influence can be exerted on epithelioma by the use of internal remedies. A certain number of experienced physicians claim, on the other hand, that the disease is amenable to internal treatment. Neligan, who describes the rodent form of epithelioma under the head of *lupus devorans*, lays stress upon the importance of administering iodine, iodide of potassium, and cod-liver oil in small doses continued for a length of time. He regards the employment of topical agents as auxiliary to the constitutional treatment, which he claims should engage the chief attention of the physician. I have not such confidence in the efficacy of these drugs, but in cases where the disease is not progressive, and especially where the patient objects to the use of the knife or cautery, I would advise the administration of the remedies mentioned, or preferably arsenic, in small and long-continued doses. Fowler's Solution might be advantageously used both internally and externally, since in some cases of epithelioma with slight ulceration, healing has been observed to follow a daily penciling of the sore with ten to twenty drops of the solution (Anderson).

In the use of caustics in epithelioma failure and even harm often results from an insufficient application of the caustic, through fear of going too deeply, or occasioning too much pain. The growth, instead of being totally destroyed, merely becomes inflamed, and is stimulated to a further increase in extent. As a rule the burning must be thoroughly done or not done at all. The choice between the knife and caustic depends upon the extent, location and character of the growth, when there is no whim or prejudice on the part of the patient. When the growth is large, it is usually advisable to scrape or excise as thoroughly as possible, and to apply the deliquesced chloride of zinc to the raw surface, especially when fears are entertained of a recurrence of the disease. When the growth is superficial, one or two applications of a caustic paste will answer the purpose. Hebra's arsenical paste (arsenious acid, one part, red sulphuret of mercury, three parts, and cold cream, twenty-four parts), though a painful application, acts merely upon the diseased tissue, sparing the healthy skin. It should be applied on a piece of linen, and allowed to remain for twenty-four hours, being renewed if necessary. Marsden's paste is prepared as follows: To equal parts of arsenious acid and powdered acacia add sufficient water to moisten and make a thick paste. This is to be spread over the cleansed surface of the part to be destroyed, and covered with absorbent cotton. A slough forms, dries, and falls in a week or more. As a rule, the best caustic is the one with which the operator is most familiar. I prefer the caustic potassa, either solid or liquefied. This forms a blackish slough, small or large, as is desired. Its action can be readily checked by applying vinegar or dilute acetic acid. The pain resulting is not very severe, and quickly ceases, having this great advantage over an arsenical paste. An ointment of pyrogallic acid (20 per cent.) applied as a paste has recently been highly recommended.

The removal of an extensive epithelioma, occurring upon the lip or elsewhere, frequently involves a plastic operation to restore the lost parts. In such cases, the knife is far preferable to caustics, as the removal of the disease and the restoration of the part can be combined in one operation. In excising a small growth from the neighborhood of the eye the rule is commonly laid down that the line of the cicatrix should radiate from the center of the pupil, to prevent distortion of the lids.



EPITHELIOMA.



## TRICHOPHYTOSIS.

---

Trichophytosis is an affection of the skin resulting from the growth of a microscopic plant called the Trichophyton. It is quite familiar to the laity as "ringworm." In dermatological literature it appears under a confusing variety of titles, the most common of which are *Herpes tonsurans* and *Tinea trichophytina*. It is one of the three vegetable parasitic diseases of the skin, the other two, chromophytosis and favus, having already been illustrated and described. Like these, trichophytosis is contagious, possessing the quality in a far more marked degree than chromophytosis. Children are more susceptible than adults to contagion, and when once introduced into a family or school the disease is apt to be conveyed from one to another until nearly all are affected. It is sometimes observed in horses, cows, cats, and other domestic animals.

From the peculiarities presented by trichophytosis, according to its location, five regional forms of the disease may be conveniently described. These are given below in the order of their importance, and with their most frequent synonyms appended.

Trichophytosis capitis. . . .	<i>Tinea trichophytina tonsurans.</i>
"	<i>harbae. . . . Tinea sycosis. Sycosis parasitica.</i>
"	<i>corporis. . . . Tinea trichophytina circinata.</i>
"	<i>eruris. . . . Eczema marginatum.</i>
"	<i>unguium. . . . Onychomycosis.</i>

On the general surface of the body (*T. corporis*), where the eruption can be most satisfactorily observed, the disease begins either in the form of a group of minute vesicles, or a small, reddened, scaly macule, which, increasing in size, presents a circular outline and a slightly elevated margin. The skin is but slightly inflamed as a rule, and at the advancing border of a typical patch a circle of minute vesicles may be sometimes discovered upon close examination. The patch extends at the periphery, and as the elevated margin creeps over the healthy skin, the central portion becomes but slightly, if at all elevated, and far less scaly than the border. In many cases the inclosed area becomes quite normal or remains somewhat pigmented, and the eruption presents a characteristic annular appearance. There is rarely but a single focus of disease, and in many instances a score or more of circular patches may be counted. Where these are near each other they coalesce as they increase in size, and large patches of irregular outline result.

Trichophytosis of non-hairy parts (*T. corporis*) occurs in both sexes, and at almost all ages. It has been reported as occurring upon an infant six hours old.

In the genito-crural region (*T. cruris*) the parasite grows luxuriantly, owing to the heat and

### TRICHOPHYTOSIS.

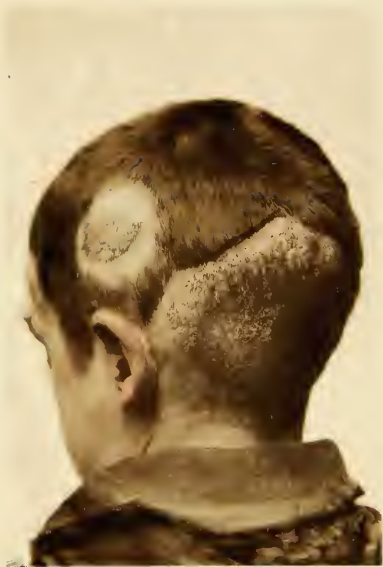frequent moisture of the parts affected, and the eruption extends upon the buttocks and inner surface of the thighs. It produces in this region an unusual amount of dermatitis, and in many subjects a pronounced eczema. In the tropics this form of the disease is common and obstinate.

On the scalp (*T. capitis*) or bearded portion of the face (*T. barbae*) the disease begins in the form of one or several small, scaly patches. After having existed a short time without treatment, the hairs springing from the patch lose their luster, become brittle, and finally break off very near the surface of the skin. The patch, which has now perhaps reached the size of a cent or quarter dollar, appears bald at first glance, but on close inspection is found to be covered with white powdery scales, through which the broken hairs project like stubble. *Trichophytosis capitis* is never seen in adults, although the occurrence of the disease upon the bearded portion of the face is by no means uncommon. *Trichophytosis* of the beard may be contracted in the barber's chair, and constitutes one form of the so-called "barber's itch," which term is usually made to include eczema and sycosis. It does not arise from the use of an unclean razor, as is commonly imagined, but from the use of a damp, soiled towel, which furnishes a most excellent nidus for the growth of any vegetable parasite.

*Trichophytosis* affecting the nails (*T. unguium*) is extremely rare, but it may occur either alone or in connection with rings of the disease upon the hands or other portions of the body. The nails, one or more of which may be affected, become thickened, discolored and friable. Those of the fingers are more likely to suffer than those of the toes.

The diagnosis of *trichophytosis* is generally so simple that it can be made by the patient. When the eruption, however, has been treated and partially cured, or when, on the other hand, it has been maltreated or overtreated, so that it has become obscured by a secondary eczema, the physician must be cautious in venturing an opinion until a microscopic examination has determined the presence or absence of the parasite. The diseases with which it is most likely to be confounded are favus, psoriasis and eczema. In the early stage of favus, before the characteristic yellow crusts have developed, the appearance presented is very similar to ringworm, and a diagnosis can only be based on a microscopic examination of the hairs. Psoriasis sometimes appears in the form of circular, reddened patches, with a very moderate amount of scaling, closely resembling the patches of *trichophytosis*, and when on the wane they tend moreover to heal in the center, and form rings which have often been mistaken for ringworm by physician as well as patient. The peculiar location and symmetry of the eruption in psoriasis will generally serve as a guide in diagnosis.

Eczema may simulate every skin disease. In its dry and scaly stage, especially when occurring as one or more small roundish patches, such as may be met with on the face, breast or hands, it resembles *trichophytosis* in being hyperemic, scaly and itchy in a moderate degree. The patch of eczema, however, is rarely circular, and generally shades off into the surrounding skin instead of presenting an abrupt margin. Furthermore, there is never any tendency toward healing in the central portion of the patch. *Trichophytosis capitis* is often confounded with eczema, but the circular form of the patch, the absence of moisture, and particularly, the mealy epidermis and the short, broken hairs ought to reveal the nature of the affection in most cases. In all doubtful cases of skin disease, where *trichophytosis* or one of the other parasitic diseases is suspected, microscopical examination of a few scales or hairs must be resorted to in order to settle the question of diagnosis.



TRICHOPHYTOSIS CAPITIS.





## TRICHOPHYTOSIS.

---

CASE.—An infant with an acutely inflamed patch upon the wrist. The motion of the hand had produced one or two painful cracks. The disease had been transferred to the forearm of the mother, where it appeared in the form of a typical, orbicular, scaly patch, consisting of two well-marked concentric rings.

As trichophytosis is essentially a dermatitis of greater or less severity, resulting from the growth of a parasitic fungus in or upon the skin, its treatment must consist mainly in the use of local measures. As the trichophyton will take root and thrive upon a perfectly healthy skin, it is evident that internal treatment cannot effect a cure. At the same time, clinical observation teaches that in certain conditions of the system the skin affords a more favorable soil for the development of the fungus. The affection appears to be more disposed to spread, and to be less easily checked by the action of parasiticides, when the patient is ill-nourished or physically deprived. Internal remedies may, therefore, in a slight degree at least, prove conducive to a cure, and in the majority of cases it is advisable to look well after the general health while carrying out the local treatment. Cod-liver oil, by promoting nutrition of the skin, and bathing, by rousing into activity the cutaneous functions, produce a beneficial effect, and are especially called for by the class of patients affected, many of whom are of a lymphatic temperament, averse to fatty food, and with a dull, torpid, pasty skin.

The main objects of local treatment should be, (1) to reduce any undue amount of inflammation, should such be present, and (2), to destroy the very last germ of the parasite. Success depends upon the appropriateness of the remedy. Failure may result from the use of one which is too weak, or from the too long continued use of one which is unnecessarily strong. In most cases vigorous local treatment may be instituted at once, but on the soft skin of childhood, and on certain regions in the adult where the skin is thin and easily inflamed, it is preferable to employ the milder parasiticide remedies for a greater length of time, than to risk the production of a severe dermatitis or eczema. To destroy the parasite it is usually necessary to destroy the epidermis and hairs which are invaded. Where the disease occurs on non-hairy parts, it is commonly superficial and easily cured. As the spores and mycelium grow between the cells of the horny layer of the epidermis it is evident that whatever will remove this layer will carry away with it the parasitic growth. When this, however, has grown down into the hair follicles, and even penetrated the hairs themselves, the disease is not readily cured. It may indeed prove exceedingly intractable, and recur after it is apparently well.

On the general surface of the body, where the hairs are fine or absent, the disease can be removed mechanically by scrubbing the affected part daily with sapo viridis. This alone will

## TRICHOPHYTOSIS.

usually suffice, but the patient is apt to be more contented, and indeed, the cure may be hastened, if he applies an ointment or a lotion to the affected part between the soap frictions. An ointment of thymol (three to five per cent.), or of carbolic acid (ten to fifteen per cent.), or a lotion of the hyposulphite of sodium (twenty per cent.), will be found very useful. These remedies have the power to arrest the development of vegetable spores, if not to utterly destroy them, but to secure their beneficial action they must be applied with great frequency, as the parasitic spores multiply with amazing rapidity, and no time should be lost between the applications. Most of the so-called parasiticides, however, merely have an astringent or slight caustic action, and would be more properly termed epidermicides. Common ink, and a copper cent dipped in vinegar, are valued remedies among the laity, and not wholly without effect; but the physician will do better to paint the patches with acetic acid or the tincture of iodine. The latter is objectionable when the affection is on the face or hands, owing to the staining of the skin. If decolorized, the tincture loses much of its efficacy. A still better application is a five per cent. ointment of chrysophanic acid, or one of the remedies already spoken of as acting in a truly parasitocidal manner. Blistering a patch with cantharidal collodion, or some other epispastic, is a most efficacious plan of removing the disease, but is rarely called for.

In the genito-crural form of the disease the parasitic growth is rather difficult to get rid of, as strong applications must be used with caution. But the chief difficulty in treating this form arises from the fact that it is so frequently associated with an erythematous eczema. The skin is reddened, thickened and itchy, and even when the parasite has been destroyed by the use of pure sulphurous acid, or the remedies already suggested, the outline of the patches and their general appearance remain pretty much the same. In other words, the eczema still remains to be treated.

The treatment of trichophytosis capitis is similar to the treatment of favus, after the crusts have been removed, and consists mainly in epilation. In trichophytosis the hairs are more difficult to extract than in favus, since, owing to the penetration of spores into the fibrous portion of the shaft, the hairs break, and a patch has to be epilated repeatedly before the scalp is left smooth and clean. The prognosis in this affection is much better than in favus of equal extent, since the hair bulbs are not so apt to be destroyed, and consequently the bald, depressed spots and the sparse, wiry hair, which usually result from a severe attack of favus, do not follow. After trichophytosis of the greater portion of the scalp, the hair may in time grow as thick and strong as ever.

Epilation may be performed in various ways. I have made some use of an epilating paste, composed of resin, wax and balsam of tolu, molded into the form of a convenient stick, about an inch in diameter. One end of this being melted by heat and pressed upon the patch, a sudden twist and jerk will extract a large number of hairs at once; but the epilating forceps are almost universally used for this purpose. They should be carefully made, with broad, accurately-closing and slightly-roughened blades. If too stiff they are certain to tire the fingers of the operator where a patch of any size is to be epilated. When the scalp or beard is recently affected, the patches small, and the hairs normal, epilation is not necessary. The patches may be shaved, and parasiticide applications vigorously applied for a considerable length of time. If, now, the microscope shows no indications of a parasitic disease after repeated examination of the hairs and epidermic scales, the shaving may be discontinued, but the patches must be closely watched for a month or two, lest the disease reappear.



TRICHOPHYTOSIS (CORPORIS).



## LICHEN PLANUS.

---

- I.—CASE OF DISSEMINATED LICHEN PLANUS.—M. A., æt. 35.—Patient of Dr. Sherwell. The eruption, which was of about three months' standing, covered an unusually large amount of surface, being well marked upon the neck and back, where the papules had coalesced and formed large tracts of diseased skin. Both upper and lower extremities presented numerous disseminate papules, with the characteristic flattened summit and central pit. The itching, which was at first distressing, decreased under treatment, and the papules soon became reduced to macules, appearing as though they had been ironed smooth, though still retaining their glistening appearance. The internal treatment in this case consisted of quinia, strychnia and nitro-muriatic acid, while the bichloride of mercury and dilute hydrocyanic acid in emulsion of bitter almond was employed as a lotion, being rubbed into the skin after frequent bathing. The patient had also frequent inunctions of linseed oil, and at last accounts was nearly well, having grown much stouter and improved in general appearance.
- II.—CASE OF AGGREGATED LICHEN PLANUS.—C. F., æt. 50.—Patient of Dr. Bronson. The eruption, of about three months' standing, began as small red and itchy papules on the anterior surface of the forearms. Similar lesions developed elsewhere, and when photograph was taken, there were papules scattered over the legs, thighs and chest, presenting a shiny, glistening appearance, with a flattened summit, and a slight umbilication. On the anterior surface of the wrists the papules had coalesced into large red, or purplish-red, patches, with branny scales, and numerous striations, or little fissures, through the epidermis. The eruption at all points itched excessively. The patient was ordered five-drop doses of Fowler's Solution, to be gradually increased, and, externally, a soothing lotion. The patient was not seen for four months, during which time the disease had continued, with occasional eruptions of new papules, while old ones disappeared. Of the confluent patches on the wrists there remained only dark discolorations.

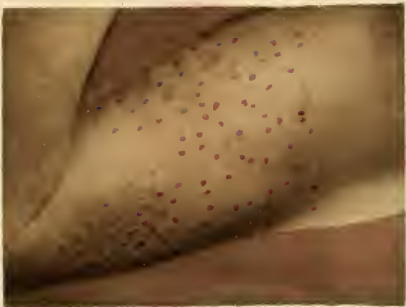
Lichen is a name which was applied by the older dermatologists to all diseases of the skin, the lesions of which consist of persistent papules. Several varieties of lichen were described, but as a more careful study of the natural history of skin diseases has shown that these are not varieties of one disease, but papular stages or forms of widely different diseases, most of them have become obsolete as forms of lichen, being known at present under different and more appropriate names. Lichen simplex, according to many writers, is nothing more nor less than a papular form of eczema (See plate of *E. papulosum*). Lichen lividus is *Purpura papulosa*; Lichen urticatus is *Urticaria papulosa*; while Lichen syphiliticus is *Syphiloderma papulosum*, a name expressing the nature of the disease, which is, of course, of vastly more importance than the form and appearance of the cutaneous lesion. There still occur, however, papular eruptions which cannot be considered as mere papular forms of any disease otherwise named, and to such the term "Lichen" is justly applied.

## LICHEN PLANUS.

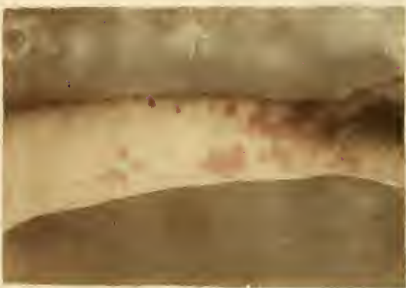Lichen planus consists in an eruption of peculiar papules, which may be disseminated or aggregated, and either occupy a limited region, or extend over a large extent of the general surface of the skin. The chief peculiarity of the papules, and one which gives rise to the name, is their flattened summit. They are but slightly elevated, and though rising abruptly from the healthy skin, they do not possess the conical or rounded summit of ordinary papules, but appear as though they had been shaved off or pressed down. The summit is smooth and horny, and sometimes presents a glistening appearance. Usually a punctate depression, or umbilication, is seen in the center of this flattened surface. The base of the papule is often angular in its outline. In size, the papules vary greatly in different cases, and slightly upon different portions of the body. They are usually of the size of a pin's head, but may be considerably larger. As in the case of the papular syphilide, both a miliary and a lenticular form of Lichen planus may occur. The color is a pale yellowish-red when the papules are small, and "dull crimson," or violaceous, when they are larger, the center being somewhat lighter than the rim of the papule. The papules may be regularly disseminated over a given surface, or strewn in groups, even when not coalescing. The papules, when once developed, persist as such, never evincing the slightest tendency to vesiculation or pustulation. They do not increase in size, and patches are formed by the springing up of new papules among the older ones. The isolated papules are not scaly; but when they become aggregated they lose their peculiarities of form and appearance, and irregular patches of thickened skin result, with a dry, harsh, horny surface, which to the touch feels like a file, or even a nutmeg-grater. At the border of such a patch the typical papules may sometimes be observed. The disease is attended with a certain amount of itching in every case, and the utmost distress is sometimes occasioned by this symptom. It develops with variable rapidity, requiring but a few weeks in some cases to produce an extensive eruption. Limited patches, on the other hand, often remain for months without change. The disease is chronic in most cases, and shows little disposition to yield readily to treatment.

The cause of the affection is obscure. It is certain, however, that those affected by it are far from being in perfect health. The debilitated condition of the system in this disease is more noticeable than in eczema, and far more so than in psoriasis. The eruption may occur in either sex, in the young as well as the old, and upon almost any portion of the body. It occurs far more frequently in females, according to my experience, and usually in middle life. The anterior surface of the forearm and wrist is, perhaps, the most favorite locality.

The diagnosis of Lichen planus is not generally difficult for one who has had the opportunity of seeing a well-marked case of the affection. But, as the disease is comparatively rare, the reader may be called upon to diagnose and treat a case without this advantage. If the case is typical it will correspond with the description given, and with that of no other disease. The papular syphilide ought not to be mistaken for it, owing to the regular distribution of papules over the body, and the absence of itching in the former affection. The papules of eczema are itchy, often affect a limited region, may be both disseminate and grouped, and resemble Lichen planus at first glance. They are brighter in color, however, conical in form, and never present the angular base, flattened summit, and central depression, which characterize the papules of the latter affection.



LICHEN PLANUS.



LICHEN PLANUS.





## LICHEN RUBER.

---

CASE.—C. T., æt. 35.—Patient of Dr. Sherwell. The eruption first appeared at the age of seven, in the form of discrete papules on the backs of the hands, and successively invaded the extensor surface of arms, the neck and shoulders, dorsum of feet, knees, and finally the trunk. The eruption has remained distinctly papular from the outset, and of a dull red hue, spreading through development of fresh papules. When photograph was taken, the patient was in a poorly nourished condition. The itching of the eruption was generally slight, though at times of an intense character. The mucous membrane of tongue and pharynx was roughened. The nails, which from the commencement were thin and brittle, were all affected, the matrix being rugose and shallow. The patient has been under intermittent treatment by tonics, alteratives and soothing applications externally for two years. The improvement has been slow but decided. She had previously taken arsenic, with little or no effect. Has seemed to improve the most under inunctions of oleum lini, with the crushed seed and milk taken internally.

Lichen ruber was first recognized as a distinct affection of the skin by Hebra, who selected the name on account of the development of papules, and the dull red line which they present when not whitened by a slight desquamation of the epidermis. The disease, as described by Hebra, is one of the rarest of cutaneous affections. The subject of our illustration, together with a case reported by Dr. White of Boston, are, as far as I know, the only instances of the disease which have been met with in this country. Cases of extensive Lichen planus I have seen, but these seem to me to differ in their nature from the Lichen ruber of the Germans. From my recollection of cases of the latter disease seen in the hospital at Vienna, from the descriptions given by Hebra, Neumann and others, and from my examinations of Dr. Sherwell's case, I should not be inclined to associate Lichen ruber with the Lichen planus described first by Wilson, and later by other English dermatologists. I must defer, however, to the unanimous opinion of Wilson, Tilbury Fox, Kaposi, Taylor, Bulkley and Duhring, who declare the identity of the two affections. Piffard is inclined to believe that they are distinct, and writes as follows: "This view, that *L. planus* and ruber are identical, supported by such eminent authority, is very plausible, and might be accepted as definitive, were it not for certain prominent facts which its advocates fail to satisfactorily explain. In the first place, WILSON observed fifty cases of *L. planus* characterized by umbilicated papules and pigment stains, and which pursued a benign course. HEBRA observed fourteen cases without umbilicated papules or stains, most of which terminated fatally. It is hardly supposable that a careful observer like HEBRA would have overlooked the umbilications, if present, or that WILSON should have met with mild cases only, and HEBRA with severe ones. Now,

## LICHEN RUBER.

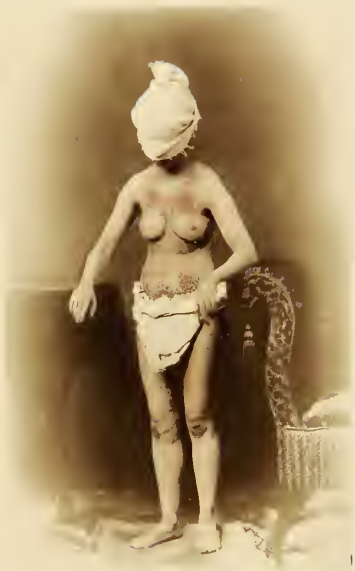subsequent to WILSON'S publication, HENRA and KAPOSI have observed a number of examples of a benign, umbilicated, papular eruption, which they have included under their old name of 'ruber.' It does not follow, however, that because they have done this, that the two are the same disease. NEUMANN, in 1868, described the microscopical appearances of the original *L. ruber*, and BIESZANECKI, in 1872, those of the umbilicated eruption. As will be seen later, these differ widely. Lastly, no one, so far as I am aware, has seen the transition of a typical *L. planus* into *L. ruber*."

In many respects *Lichen ruber* resembles *Lichen planus*, and it is only necessary to refer briefly to certain points of difference, without deciding the question as to whether the two are distinct affections, or forms of the same disease. The papules at the outset are of a brighter red color, conical in shape, and surmounted by a thin, adherent scale. When aggregated, as is usually the case, the same roughened surface is produced as in *L. planus*.

The eruption affects no particular locality, but tends to become general. The nails suffer in a characteristic manner, becoming thickened, with an uneven surface and a broken extremity. This condition, together with the infiltration of the skin, interferes considerably with the free use of the hands and feet. When the disease has existed for some time, the patient tends to become emaciated, and in time the strength fails, and death ensues. The different prognosis given by different writers results evidently from the fact that some confound the general eruption of *L. planus* with the true *L. ruber*. Whereas, a cure may confidently be expected in the one case, it can only be hoped for in the other.

The treatment of *Lichen planus* and *Lichen ruber* may be discussed together, as whatever will benefit the former will most likely prove of some service in the latter.

The general health in all cases being impaired in a marked degree, the strictest attention should be paid to dietary and hygienic measures. The digestive organs must be kept in as normal a condition as possible, and the most nourishing and easily digested food prescribed. Of internal remedies, the alkaline diuretics seem to be productive of the best results by relieving the cutaneous congestion. In many cases of either of the diseases in question, and indeed in any case of chronic skin disease where an imperfect oxygenation of the blood exists, it is advisable to administer a gram or more of chlorate of potassium, well diluted, fifteen minutes after each meal, and twenty drops of dilute nitric acid in water, fifteen minutes later. Wilson recommends quinine, nitro-muriatic acid and chalybeates. In *Lichen ruber*, a long continued course of arsenic is advised by Hebra, while the effect of the linseed oil treatment of Dr. Sherwell in the case illustrated, would suggest its trial in other cases. Locally, baths and other soothing measures are called for when the amount of congestion is extreme, but as a rule, cases of *Lichen planus* will stand mild stimulation by soap frictions and the preparations of tar.



LICHEN RUBER



## KERION.

---

CASE.—D. M., aet. 15.—Patient at the New York Dispensary. This boy was of diminutive stature, pale and strumous in appearance. At four years of age he had had an abscess in the axilla, which continued to discharge for more than a year. The present affection was of six months' standing, and had begun in the form of small "boils," which did not suppurate, but resulted in a circumscribed alopecia. When first seen by me the *vertex capitis* presented a group of small tumors, each about as large as half a marble, crowded together, or rather heaped upon each other, giving the affected part a lumpy or mountainous appearance. The elevated portion of scalp was of a dull, purplish-red hue, and for the most part devoid of hair. No hairs had been pulled out, according to the patient's statement, although there was a white margin of bald scalp skirting the upper or anterior and oldest portion of the patch. The hairs springing from the occipital edge, and from the furrows between the hemispherical tumors, were surrounded by a gummy exudation which oozed from the follicles. Each tumor, or mound, presented a bald, dry, and shiny summit, and bore a striking resemblance to a thin-walled superficial abscess. As the tumors were found on palpation to be rather soft, it seemed almost certain that they contained pus or other fluid demanding evacuation. Upon puncture, however, only a drop of bloody serum escaped; and when, at a meeting of the New York Dermatological Society, where the patient was shown, an experienced surgeon declared unhesitatingly that pus was present, a free incision was made with only a scanty discharge of blood and serum. On other portions of the scalp there were a few pea-sized bald spots, each one indicating, according to the patient's account, the site of a former "boil." The disease in this case was considered to have had a parasitic origin, although a microscopic examination made at the time the photograph was taken (November 30) revealed no fungus. The treatment consisted in the administration of the syrup of the iodide of iron in cod-liver oil, with epilation of the hairs upon and around the elevated patch. Two weeks after beginning the epilation, a circular patch of scalp, on the right margin of the epilated area, became suddenly inflamed, and occasioned a sharp, pricking and painful sensation. In three days this patch increased a trifle in size, and the pain lessened. On December 18, the color of the large epilated patch had faded considerably, and the mounds were scarcely perceptible. There still existed some deep-seated fluctuation, but an exploring needle merely evacuated blood and serum. The inflamed patch was as large as a half dollar, elevated, and with an abrupt margin and a reddened surface, dotted with one or two small pustules and crusts of dried exudation. The dark yellowish, honey-like serum, which had been exuding in abundance, had now ceased to flow, and the pain had disappeared. The hairs were loosened, and came out with gentle traction. The hair hulls were somewhat swollen, and to some the root sheaths were attached. The mother of the boy was instructed to continue the epilation, which she failed to do in a satisfactory manner, and the cure progressed very slowly. In February the scalp was nearly though not entirely well.

## KERION.

Kerion is regarded by most writers who have described the affection as an unusual form of trichophytosis, or ringworm of the scalp (*Tinea kerion*). In this series of illustrations I have placed it apart from trichophytosis, as I do not regard it as essentially parasitic in its nature, although there is no doubt that the *trichophyton* acts with extreme frequency as an exciting cause of the affection. The disease usually begins with the development of one or several small, pea-sized tumors, which are always reddened and "boggy," and which often present a deceptive feeling of fluctuation which is apt to lead one to declare them abscesses. In spite of the appearance presented by these little tumors, it is a noteworthy fact that they rarely if ever suppurate. The fluid contained in the deeper portion of the corium, and which gives to the swollen part its soft, spongy feeling, is a highly albuminous serum, which appears in the form of viscid, honey-like drops, at the dilated orifices of the follicles, especially after the hairs have loosened and fallen. This loss of hair, which usually takes place soon after the affection has developed, is limited to the portion of scalp affected. The little tumor remains for an indefinite period of a livid red hue, and then tends to gradually fade and flatten, unless similar lesions develop in its immediate vicinity. Sometimes, especially in young children, it enlarges peripherally, and forms a soft, flattened, and but slightly elevated disk, as large as a half dollar. Generally, a group of closely packed tumors, or mounds, develop, and the symptoms already described as pertaining to a single small tumor present themselves in an exaggerated form.

The diagnosis of so well-marked a case of kerion as the subject of our illustration is attended with no difficulty. The bald and lumpy condition of the scalp is not seen in any other affection. In the earlier stage of kerion a mistake might readily occur. Where there are a number of scattered red and soft tubercles upon the scalp, they might be mistaken for boils, abscesses, or for syphilis. The latter disease would not be likely to occur at the age when kerion is commonly met with, unless it were hereditary, in which case it would not manifest itself in the form of tubercles limited to the scalp. Boils would be recognized by their more conical form, indurated base, and tendency to suppuration, while a number of small equal-sized abscesses would not be apt to occur upon the scalp without apparent cause. After the hair has fallen from the little tumors, and the boggy feeling lessened, they might be regarded as indications of incipient alopecia areata; but in this affection the bald patches show no signs whatever of past or present inflammation, the affected scalp being white, smooth, and not at all elevated. Where a portion of scalp is suddenly attacked, and a copious discharge of gummy serum takes place, the affection bears a resemblance to an acute eczema. It will be noted, however, that the hairs are loosened, and pull easily, which is never the case in eczema of the scalp.

The treatment of kerion consists in improving the general tone of the patient, and in thoroughly epilating the affected part. Whether the disease is of parasitic origin or not, epilation is demanded by the condition of the hairs, which are not broken off, but lie, as in case of sycosis, like foreign bodies in the inflamed follicles. Their extraction removes a source of irritation, and the free discharge of viscid serum through the follicles lessens the boggy condition of the scalp and promotes the subsidence of inflammation. It must not be expected that epilation will effect a speedy cure of the affection, even when the trichophytic fungus is present as an exciting cause. As the fungus, in this case, is not the sole cause of the peculiar phlegmonous condition, its removal with the hairs, will not produce as striking an improvement as in cases of ordinary trichophytosis capitis.



KERION





## LEPRA MACULOSA.

---

CASE.—F. W. F., about 35 years of age, born in Prussia. Four years before the photograph was taken he noticed a painful swelling of left leg, while residing in Central America. The ankle joint became stiff. This was followed by a loss of sensation at the tip of nose, edge of lower jaw, and other portions of the face. During the first year red spots appeared on the trunk and extremities. During the second year the hands became painful, the finger ends swelled, and the nails fell off. In the third year the spots changed to a light-brownish hue, and anæsthesia of various portions of the body developed. Bullæ had frequently made their appearance on his toes, and he could only use his fingers with difficulty. The treatment in this case was not systematic, but arsenic seemed to produce a better result than gurjon oil.

The diagnosis of a case of leprosy is more or less easy, according as the disease is more or less developed. In an advanced stage, its peculiar features proclaim the diagnosis at a glance, but in its incipency it may pass unsuspected for months or years, especially when met with in a country or region where it does not prevail. The earliest symptoms are usually a gradual loss of strength from no apparent cause, chilly sensations, vague pains, and numbness of the extremities. Later, the disease is characterized by the development of numerous brownish patches upon the extremities, nodules above the eyebrows or about the ears, and tracts of anæsthetic skin particularly on the hands and feet. The diseases with which leprosy might be most readily confounded are syphilis, lupus, leucoderma, scleroderma, and morphea; but the features of a case, if at all well marked, will usually proclaim its nature as soon as the diagnosis of leprosy is suggested.

*Lepros tuberosa* may bear a resemblance, at first glance, to tubercular syphilis, the forehead being a favorite seat of either disease. But the infiltration of the skin in leprosy is more diffused, the protuberances are of variable size, often larger in the center of the patch, and always of a dull, bronzed hue. The syphiloderma in this locality presents small, hard tubercles of a brownish-red color, arranged often in a circular or crescentic form, tending to ulceration and sometimes enclosing a smooth area. *Lepros maculosa* may simulate leucoderma, both in form and color, but the patches in the former are never perfectly smooth as in the latter affection.

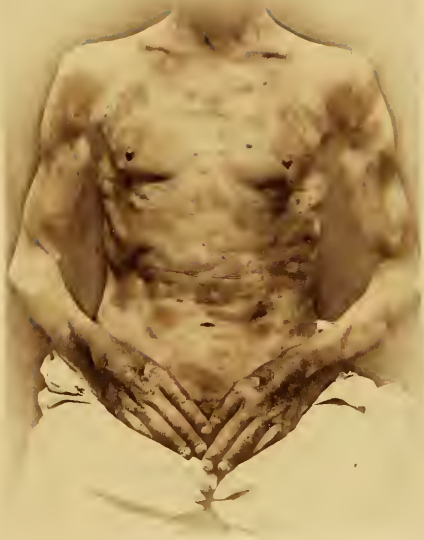
Leprosy is a disease which may be regarded as practically incurable, since there is no remedy or plan of treatment which can be adopted with any certainty of restoring the patient to perfect health. And yet many cases improve to a greater or less extent under treatment, and some have been reported in which an apparent cure of the disease has been effected. The first step in the treatment of leprosy is to remove the patient, if possible, from the locality in which the disease has been contracted. Hutchinson has reported the case of a woman whose parents had always resided in England, and who contracted the disease in a severe form during a twelve years' sojourn in Jamaica. She became

## LEPRA MACULOSA.

apparently free from all symptoms after her return to England, and during a period of twenty years there was no return of the disease, and the woman considered herself as perfectly well. A mere change of residence could not be expected to effect a cure, since leprosy is known to run its course to a fatal termination in almost every climate; but a change of diet and habits is doubtless a factor of far greater importance. In this case, Hutchinson attributed the cure mainly to a cessation of a diet composed largely of unwholesome fish, which in leprosy countries is supposed by many to be an active cause of the disease. The next step is to place the patient under the best hygienic conditions, and to treat the symptoms of the disease on general principles. Where ulceration of the extremities has taken place, the sores should be kept scrupulously clean, and dressed with some slightly stimulating application, such as balsam of Peru. For the pain, which is usually annoying in an advanced stage of the disease, morphia may be given. Stretching of the ulnar nerve under anesthesia has been resorted to in some cases of leprosy, with a view to restore its function. This operation seems to have produced at least a temporary benefit in a considerable number of cases. The thickening of the nerve has been lessened, and the anæsthetic portions of skin supplied by it have been restored to sensibility. As regards internal treatment, many remedies have been vaunted, but as yet no specific has been found. There are certain balsams and oils, which, if used for a length of time, produce a favorable change in the condition of the patient, though it cannot be said that they have the power to cure the disease. Chief among these are gurjon balsam and cashew and chanuloogra oils. The former is used by British surgeons in India and other tropical localities, with good results. For internal use, an emulsion is made of equal parts of the oil and lime-water, and administered in half-ounce doses, twice daily. As an external application, the oil is mixed with three parts of lime-water, and with this the whole body is thoroughly rubbed. Under this plan of treatment patients in an advanced stage of leprosy improve in health, the ulcers heal, the tubercles soften and disappear, and the anæsthetic parts resume their sensibility. Cbaulmoogra oil (expressed from the seeds of *Gymnocardia odorata*) has of late been highly recommended, and is given in doses of from five to twenty drops, three times daily. One case of macular leprosy, in a boy of nine, which I have recently had the repeated opportunity of seeing, has manifested a considerable degree of improvement under an ordinary anti-syphilitic course of treatment.

In most regions where leprosy abounds, the spread of the disease is checked by the segregation of all leprosy patients, under governmental authority. The wisdom of this plan, as a prophylactic measure, cannot be impugned, although the question of the contagiousness of the disease is still mooted.

The prognosis of leprosy, as is evident from the foregoing, is decidedly unfavorable. In the tuberoso, which is the most grave form, death may be expected to take place in from three to nine years after the first symptoms of the disease are noted. Very frequently pyæmia sets in, and carries off the patient with unexpected suddenness. The case of *Lepros tuberosa* illustrated in the first number of this work died shortly after its publication, or in less than three years after the development of the disease, according to his statement. The macular or the anæsthetic form of the disease may develop gradually, and exist for a long time without any very marked impairment of the patient's health. Twenty-four years has been fixed as the extreme limit of the disease by physicians who have had the opportunity of observing it where it is endemic.



LEPRA MACULOSA



## MOLLUSCUM.

---

CASE I.—Joanna E., æt. 5.—This patient was a red-cheeked, chubby little girl. Examined April 8, 1876. There were six or eight mollusca on left thigh, of a year's standing. She was brought to me for treatment on account of a group of the larger ones having inflamed, suppurated and formed a dark crust. In this case there was no history or evidence of contagion. Her little brothers and sisters, though playing with her by day and sleeping with her at night, had never been affected, nor had any of the neighbors' children. One sister had ordinary warts on her hands.

CASE II.—Fannie W., æt. 1½.—This child exhibited nearly one hundred mollusca of varying size, mostly located beneath the chin. A bean-sized tumor resulted from the close proximity of several. There were a few scattered on neck, breast and about the eyes. Although an older sister had nothing of the kind, the little patient lived next door to a little girl whom I had treated months before for the same affection. The mollusca in this case were rapidly removed with a pair of curved scissors, the child being under the influence of a few whiffs of ether.

The term molluscum has long been applied to two distinct affections, viz., one which will be presently described (*Molluscum contagiosum* of Bateman), and one which has already been illustrated and described in this work (*Fibroma*, or the *Molluscum fibrosum* of certain writers). The affection to which the term molluscum should be limited consists of little soft tumors, varying in size from a pin's head to a small pea, with constricted base, a central depressed orifice and whitish, curdy contents. They are not of very infrequent occurrence among children, and are as interesting to the dermatologist as they are harmless to the patient. The affection commonly attacks children, and the face and neck is its most common seat. The tumors exhibit a tendency in many cases to congregate about the eyes, and occasionally about the mouth. I have met with them exceptionally upon the scalp, ears and tip of nose. In adults the genitals are the part usually affected, although the mollusca sometimes occur on nearly all parts of the body.

Each individual tumor is of slow development and indefinite duration. It begins as a pin-head sized, whitish elevation of the epidermis, with a minute central depression, which becomes more prominent as the growth increases in size. When it is as large as a hemp-seed the summit becomes flattened, the base more or less constricted, the center of the growth appears whiter than the wall of the tumor, which is usually of normal skin-color, and lateral pressure causes a whitish, cheesy substance to exude. Under the microscope this is found to be composed mainly of peculiar round or oval bodies known as the "molluscum corpuscles." The tumors have usually a waxy, transparent aspect, although, when they have attained the size of a large pea, the walls are often traversed by fine blood-vessels,

## MOLLUSCUM.

and present a pinkish appearance. No pain or other subjective sensation accompanies the growth, which may persist for a year or more, never getting larger than a large pea, and finally withering or undergoing a process of destructive inflammation.

In a large proportion of cases the hands of the patient will be found to be the seat of ordinary warts.

The etiology of molluscum is obscure. Its occurrence in several members of one family, and the fact that it has been observed to affect suddenly a number of children in a hospital ward, have led to a belief in its contagious nature. But this is by no means proven. Although the disease occurs with much greater frequency among the poorer classes, it cannot be considered as the offspring of poverty and uncleanness. Damp and crowded dwellings may favor its development, and I have known a number of cases to occur in such a locality. Ill health is not always a factor in its production, for while most of the molluscous children I have examined were strumous or weakly, there have been some upon whose faces not even the dirt could conceal the glow of health.

The diagnosis is very simple, the tumors being so peculiar in appearance that, when once seen and recognized, they could hardly be mistaken when met with a second time. I have seen numerous mollusca upon the face of a young woman, which, on account of their whitish, flattened summits and central depression, bore a striking resemblance, when observed at a distance, to the umbilicated pustules of variola. A mistake in diagnosis, however, could scarcely occur.

Fibromata, when small, might be mistaken for mollusca, and especially as the sebaceous glands in the former tumors frequently contain an accumulation of sebum, which can be pressed out in the form of cheesy threads. They do not present, however, a central depression, do not occur in groups, do not have the plump feeling of mollusca, but, on the other hand, are apt to be quite flaccid, and finally, when multiple, as they usually are, they vary considerably in size, and usually become much larger than mollusca.

The treatment of molluscum is simple, the object being to remove the excrescence and to excite as little inflammation as possible in so doing. When the mollusca are so situated as to admit of abscission, the most advisable plan of treatment is to shave them off with a razor, or a long, thin-bladed knife, at a level with the surrounding skin. The hemorrhage occasioned scarcely amounts to more than a drop, and it is quickly checked by touching the freshly-cut surface with nitrate of silver. When the mollusca are not seated upon a projecting, or at least upon a convex part, but occur in certain localities where, especially in the case of struggling children, a knife could not be handled with safety, a pair of curved scissors may be used in its stead. For very small mollusca, nothing more than slight cauterization is required to arrest their growth and to hasten their disappearance. They may be bored very gently with a conical stick of nitrate of silver, or touched with a fine glass rod dipped in strong acetic acid. When a cluster of tumors have coalesced and undergone a process of destructive inflammation, the hard crust should be removed by a poultice or dressing of cosmoline, and a little balsam of Peru applied to heal the superficial ulceration. When a molluscum, however large, is removed, no scar is left, under ordinary circumstances, since the growth is epidermic in character, and can scarcely be said to involve the corium, or true skin. When an inflamed molluscum is scratched or irritated to the degree of purulent secretion, a slight pit may be expected to result.



MOLLUSCUM



MOLLUSCUM





## ERYTHEMA MULTIFORME.

---

CASE.—C. R., æt. 57.—Patient of Dr. N. G. McMaster. This patient, born in Bohemia, and a silk weaver by occupation, was spare and sallow, but had a good previous history, and manifested no tendency to constitutional disease of any kind. The eruption began about a week before the photograph was taken, as a small, bright-red and itchy spot on the inner side of the right wrist. A few hours later a chain of similar lesions extended up the inner side of forearm and arm. Then a spot appeared on inner side of right ankle, followed rapidly by others, extending up leg and thigh to groin. These differed from those on upper extremity in being larger, in having a more livid color, and in being accompanied by considerable œdema of the limb. Toward evening the opposite, or left extremity, became attacked in a similar manner. In short, the eruption, within a space of fifteen hours, appeared on the inner aspect of both upper and lower extremities, in the form of circular elevated macules, which were extremely itchy for the first twenty-four hours after their development, and which gradually increased in size and coalesced. When seen by Dr. M. at the University College Clinic, the eruption presented a large number of discolored disks or rings, mostly confluent, and forming patches with a scalloped margin. At the shoulder the rings were about three inches in diameter, and their size gradually decreased in approaching the wrist, where they measured about an inch. The rings were very striking in appearance, being of a bright, purplish-red color, shading off through hues of red and dull yellow, and inclosing a central area of apparently normal skin. On the lower extremities the patches were more confluent and of a deeper hue. The treatment prescribed in this case was a recumbent position, a moderate dose of castor oil, a light diet and frequent bathing of the limbs with vinegar and tepid water. In about two weeks the lesions began to fade, and in a month there was no trace of it, save a slight œdema of legs, which persisted for several weeks. The patient stated that the eruption disappeared in an inverse order to that in which it appeared, leaving the right wrist last.

The term erythema indicates a pathological congestion of the skin. When hyperæmic redness is the sole lesion in any case, the affection is called Erythema *simplex*. When the congestion of the skin is accompanied by a peculiar plastic exudation, we have an entirely different affection, and one to which Hebra has applied the distinctive title of Erythema *exsudativum multiforme*. Although the generic term erythema, adopted by Willan in his lesional classification, is still in use, the reader must bear in mind that Erythema *simplex* and Erythema *multiforme* are not mere varieties of one cutaneous disease, but that they are quite independent affections, according to a classification based on etiology or pathology.

Erythema multiforme is an acute inflammatory affection, characterized by a marked degree of superficial plastic exudation. This leads to the rapid development of either papules, tubercles, elevated

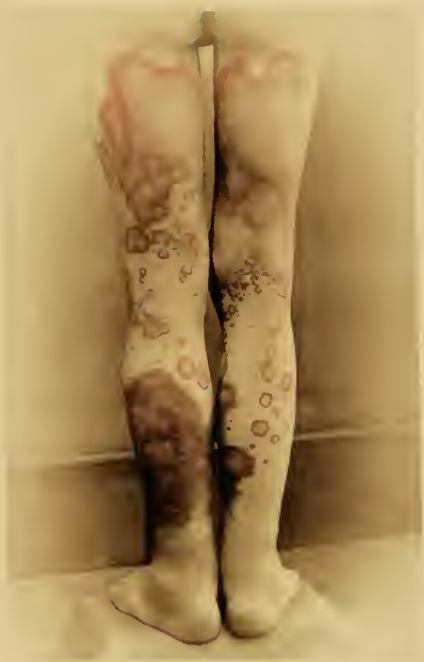## ERYTHEMA MULTIFORME.

rings or diffused marginate patches. The varying character of the eruption has led to the establishment of a number of clinical forms which differ from one another only in external appearance. Erythema *populatum*, which may be taken as the type of the affection, is the most common form, and occurs chiefly on the backs of the hands and forearms, and, in some cases, on the feet and legs as well. The lower extremities are rarely affected alone. In *E. tuberculatum* the papules are simply larger and firmer. They present at times a whitish summit and appear like hülle containing gelatinous contents. In a case which I recently saw, the tubercles on the backs of the fingers were dark and purpuric in character. In *E. annulatum* a large flat papule or disk of exudation presents a depressed central area, and in rare instances, one or more outer circles form, and by exhibiting a variation in color give rise to the name *E. iris*. *E. marginatum* is applied to the eruption when it appears in the form of diffused patches with an abrupt and elevated border which is usually scalloped from the coalition of smaller circular patches. *E. nodosum* is a peculiar form, in which one or more large, painful swellings appear upon the limbs or elsewhere. Although this form is almost always met with alone and is usually described as an affection distinct from *E. multiforme*, I have, in one case, seen it coexisting with the papular and marginate forms. In rare instances, the eruption becomes vesicular and even bullous, and to such cases the terms *Herpes iris* and *Hydroa* have been applied.

The eruption, in the beginning, whether papular or of whatever form, is seated upon a slightly swollen and reddened base. Within twenty-four hours the encircling hyperemia subsides, and leaves the eruption contrasting strongly with the normal skin. The color changes gradually from a bright red to a dull, livid or purplish hue, and the affection runs its course in from one to six weeks, according to the intensity of the exudative process. An average case will last from two to three weeks. Frequently the lesions develop successively, and the attack is thereby prolonged. Recurrent attacks at a certain season of the year are not uncommon. The outbreak of the eruption is often associated with malaise and slight fever, and according to my experience the eruption is usually quite annoying on account of the burning sensation or pruritus, which is nearly always present. Most writers, however, speak of the subjective symptoms as being insignificant.

The causes of erythema multiforme are rarely apparent. It is frequently met with in the spring and autumn, and the sudden changes of temperature so common in this climate seem to me to be an etiological factor of importance. In dispensary practice I have had occasion to note that immigrants are a class peculiarly liable to be affected. In many cases a lowered tone of the system is evident, but the disease does not seem, like malarial fever, to be attributable to dietetic errors. It is generally met with in youth and middle age, and neither sex is exempt.

The treatment of the affection may be expectant or consist chiefly in good nursing. Frequent warm baths are beneficial. A teaspoonful of carbonate of sodium may be added to the water when the eruption is extensive and accompanied by pruritus. There is nothing to be gained by applying ointments or even dusting powders. A linen cloth saturated with a lead lotion may be applied to the affected skin at the outset, when the inflammatory symptoms are very acute.



ERYTHEMA MULTIFORME



## PHTHEIRIASIS.

---

CASE OF PHTHEIRIASIS CAPITIS.—This was a little girl who “caught lice” at school, a circumstance not always avoidable. Being neglected by her parents, or those who were supposed to care for her, she was allowed to suffer unnecessarily. The illustration shows the characteristic indications of the presence of lice, viz., the occipital eczema glueing the hairs together, the swollen cervical glands and the porriago or eruption of contagious pustules upon the neck.

Phtheiriiasis, or Pediculosis, or, in plain English, “lousiness,” is a term which includes both the presence of lice and the cutaneous lesions to which their presence gives rise. In some cases, where an eczematous tendency on the part of the patient exists, the external irritation and consequent scratching is sufficient to occasion patches of typical eczema. The older writers regarded the affection in the light of a specific dyscrasia, of which the pediculi were a natural result, and among the laity at the present time it is a common belief that the lice come out of the skin, where they are supposed to be bred by the disease.

Pediculi are insects belonging to the group of hemiptera. They are without wings, possess a sucking mouth, and undergo no metamorphosis. There are three members of the family which are parasites of the human body, viz., the pediculus *capitis* or head-lice, the pediculus *corporis* or body-lice and the pediculus *pubis* or crab-lice. These occasion the three affections known as Phtheiriiasis *capitis*, Phtheiriiasis *corporis* and Phtheiriiasis *pubis*.

The pediculus *capitis* is of a whitish color, and varies in size from one to three millimetres in length. Attached to its thorax are six hairy, jointed and clawed legs, with which it is enabled to travel rapidly along and among the hairs. It is only met with upon the scalp. The lice deposit their ova either singly or in groups upon the hairs. These ova or “nits” are found, upon close examination, to be whitish, pyriform bodies, glued to the hairs with the smaller end close to the shaft and pointing toward the scalp. They are always deposited near the root of the hair, and accordingly, when observed near the free extremity, it is an indication that the affection has existed for a considerable length of time.

The pediculus *corporis* bears a strong resemblance to the pediculus *capitis*, although it is somewhat larger. Its habits are quite peculiar. It does not burrow in the skin like the acarus or itch-mite, nor is it ever found in the hair, like the other species of pediculi. It inhabits the clothing and merely pastures upon the skin. It does not bite, but sucks the blood of its victim through a haustellum or proboscis which it inserts into the skin. Its appetite is voracious, and when observed beneath a watch-glass, during meal-time, its body may be seen to increase in size and assume a darker or reddish color. When numerous the pediculi may be seen traveling over the free surface of the

## PHTHEIRIASIS.

patient's apparel, but when a strict search is necessary to discover them, they will generally be found secreted in the folds and seams of the various garments. In cheap lodging-houses, police stations and wherever lousy persons are in the habit of sleeping, the bed-ticks and woollen blankets may become infested.

*Pbtheiriiasis capitis* is an extremely common affection among the lower classes. Though most frequently attacking children, and especially those who associate with a number of others in schools, asylums and similar institutions, it is not infrequent among adults. Filth and neglect act as predisposing causes, but at the same time, children who have every possible attention paid them are often affected, and even ladies of wealth and refinement sometimes discover that they have been unconsciously harboring a large number of the unwelcome and disgusting vermin. Men, on account of their short hair, are much less likely to be attacked. It is a notable fact that certain individuals are peculiarly liable to become affected whenever exposed, and, in case of some children whose heads are carefully washed and cared for, it is a puzzling matter to account for the repeated presence of the insects in the hair.

The first symptom produced by the presence of the pediculi is an unpleasant itching of the scalp. In children, the continued scratching produces excoriations, and a scrous or sero-purulent discharge soon appears, which tends to mat the hairs. An eczema, especially upon the occipital region, is frequently evoked, and this is so characteristic that, when limited to this region, it should always lead to a search for pediculi as its probable cause. An eruption of contagious pustules, as in the case illustrated, may appear upon the neck and shoulders. In strumous children the irritation of the scalp may lead to a marked swelling of the lymphatic glands of the neck.

The diagnosis of the affection is readily made if the pediculi are found, but the presence of nits upon the hairs is alone sufficient to establish it, since they indicate that there have been, and probably will be, pediculi in the hair, even though none may have been discovered by a careful investigation.

When eczema of the scalp exists the presence of pediculi is often overlooked, and the affection may be unsuccessfully treated until its parasitic origin is discovered. As above stated, occipital eczema is an almost certain sign of phtheiriiasis.

The treatment varies with the extent of the affection and the social condition of the patient. In dispensary practice it is usually advisable to have the child's hair cut close, especially in warm weather. If no eczema is present the lice and nits may be destroyed by rubbing the scalp night and morning with ordinary kerosene. Caution should be given respecting the danger of setting the child's head on fire by rubbing in the oil in too close proximity to a gas-jet or candle. When severe eczema is present this must be treated by means of a soothing ointment, although it is sometimes advisable to destroy the parasitic cause of the eczema at the outset, even though the treatment should aggravate the eczematous condition. In private practice it is not necessary to have the hair cut, and, with proper attention, it will be found easy to cure the affection by careful combing and the nightly inunction of the ammoniated mercury ointment. The nits are sometimes difficult to remove, but this may be accomplished by rubbing each affected hair from root to tip with a sponge or soft cloth dipped in alcohol or cologne-water.



PHTHEIRIASIS CAPITIS





## PHTHEIRIASIS.

---

CASE OF PHTHEIRIASIS CORPORIS.—A patient at the New York Dispensary. This was a tramp, who for some time had been a nightly guest in a crowded police station-house, and whose clothes had probably not been removed for months. They were infested with pediculi, and his body was covered with excoriated papules and scratch marks. The illustration shows the characteristic location of the eruption between the shoulders and the parallel scratches, produced by a vigorous use of the finger-nails.

Phtheiriasis *corporis* implies the presence of lice in the clothing, together with the existence, to a greater or less degree, of certain cutaneous lesions. The affection is a common, and often a chronic one among the poor and miserable, and under certain circumstances, the possessor of wealth and refinement is not protected against an acute attack. As Professor Hebra once remarked to his students, it is not always a disgrace to have lice, but it *is* a disgrace not to get rid of them speedily.

The lesions constituting the eruption in Phtheiriasis *corporis* are: (1) peculiar hemorrhagic specks or so-called "bites," (2) small wheals or inflammatory papules, (3) excoriations, either presenting a raw surface, or covered with a crust of dried blood, (4) scratch marks of parallel direction, such as are not met with upon the skin, except as a result of phtheiriasis irritation, and (5) pustules, furuncles, and superficial ulcerations.

The eruption is observed chiefly upon the body and thighs. It is always most marked in certain localities which correspond to the seams and folds of the clothing, where the pediculi secrete themselves, and deposit, in great numbers, their small, white, and shining eggs. A tract of skin that can be almost covered by the palm, lying between the upper portion of the scapulae, is a spot most likely to present excoriations, since it is a favorite habitat of the lice, and quite accessible to the hands of the patient. The eruption in this locality usually presents a striking appearance, the skin being frequently pigmented, and showing old cicatrices scattered among the recent excoriations. The eruption is also apt to be well marked around the loins, presenting a distribution which might be termed the phtheiriasis girdle. This is commonly observed when the trousers are supported by a belt. Excoriations are common about the trochanteric region and outer aspect of the thighs, when the trousers are chiefly infested. I have seen a patient with dark stripes running down the thighs and legs, and corresponding to the seams, which were swarming with pediculi and their ova.

The diagnosis of phtheiriasis *corporis* can usually be made by observing the patient at a respectful distance—a very fortunate circumstance for the physician, who in charity practice has to treat a large number of cases. When the patient strips, the nature of the affection, if it be of long standing and

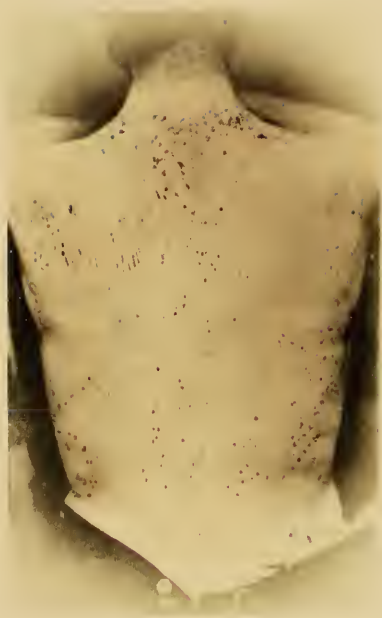## PHTHEIRIASIS.

well marked, is evident from the characteristic location of the scratch marks, and from the fact that the patient finds it impossible to keep his hands still. There is no other disease in which the pruritus is so intense as in a severe case of phtheiriasis. Exposure of the body to the cool air seems to excite the desire to scratch. If the patient is requested to stand perfectly still, with his hands hanging, he may retain this soldier-like position for a few seconds, when he will probably begin, with both hands, to rub and scratch, and even to tear the skin, until it is bleeding at numerous points. The pruritic character of the eruption being thus manifest, we are led at once to exclude a diagnosis of syphiloderma and every other non-pruritic skin affection, and to think of urticaria, prurigo, eczema, or scabies, eruptions which are always accompanied by severe itching. The irritability of the skin, shown by the parallel pink streaks which follow in the wake of the finger-nails, and the rapidly developing white ridges or small wheals, is a striking feature of urticaria, and might lead to the diagnosis of this affection. But in urticaria the severe excoriations are lacking, and the eruption is usually of recent and sudden development. Prurigo in the severe form, which is seen in the skin clinic of Vienna, is rarely, if ever, met with in this country. In a mild form it is occasionally encountered, and can be distinguished from phtheiriasis by its attacking chiefly the extremities, and being invariably a disease of long standing.

A case of phtheiriasis might be diagnosed as one of papular or pustular eczema, the difference in the appearance of these eruptions not always being very marked; but the characteristic location of excoriations across the back of the shoulders, around the waist, and upon the outer surface of the hips and thighs, should point at once to their parasitic origin. Scabies, when affecting the body extensively, may resemble phtheiriasis, but it manifests a strong preference for the hands, forearms, lower part of abdomen, genitals, and the inner aspect of the thighs, while avoiding the favorite seats of phtheiriasis lesions. It is intensely pruritic, as the common name of "the itch" suggests, but the patient scratches with comparative gentleness, and never digs the skin with fury, as in case of phtheiriasis.

It will thus be seen that the diagnosis is easy, in a severe form of the affection, but frequently cases occur in which only a moderate pruritus, with very few excoriations, is present. Here it may be impossible to discover any pediculi, and it is sometimes extremely difficult to distinguish the affection from the Pruritus *cutaneus*, which is a neurotic affection, depending upon some internal disorder. The hemorrhagic points produced by the haustellum of the pediculus can generally be discovered, however, and serve an excellent purpose in pointing out the parasitic origin of the trouble. When in private practice there exists a suspicion of pediculi (and phtheiriasis is not wholly confined to dispensary patients), it is far preferable to quietly hunt for these characteristic lesions of the disease, than to give offense to a patient by instituting a fruitless search through the clothing.

The treatment will be given in connection with the illustration of "*Porriego e pediculis*."



PHTHIRIASIS corporis



## SCABIES.

---

SCABIES, or "the itch," is an affection of the skin, resulting primarily from the hurrowing of minute insects called "acari." The presence of these parasites in the skin occasions a severe pruritus, and evokes a characteristic eruption, which cannot be duly appreciated and rationally treated without a certain knowledge of their anatomical structure and peculiar habits.

The *Acarus Scabiei*, or itch-mite, is a minute and almost microscopic insect. It can be readily seen with the naked eye when extracted from its burrow or *cuniculus* by means of a needle, but its features can only be studied beneath the microscope. The mature acarus is of oval shape, and provided with eight legs. The male is smaller than the female, does not burrow as does the latter, and is not readily found. The young acari possess but six legs (two posteriorly), and these are in time thrown off with its skin, when the mature eight-legged insect appears. If a female, she becomes speedily impregnated by the male, who roams at night upon the free surface of the skin. She then proceeds to burrow, and deposits her ova to the number of a dozen or more beneath the epidermis. At the end of this burrow she dies, unless prematurely removed by the finger nail of her unwilling host. The ova are hatched within fourteen days, and find their way to the surface of the skin. Here the maiden acari are wooed, become impregnated, and the burrowing and hatching process is repeated. The burrows are generally found where the skin is thin and warm, as between the fingers, upon the penis in the male, and the nipple in the female. They appear as dotted, slightly elevated and curving lines. Vesicles and pustules are frequently observed in their vicinity, but the extensive eruption which, in some severe cases, covers the body and extremities, is not a direct effect of the hurrowing of the acari, but results from the free use of the finger-nails. The itching is almost intolerable, especially in the night, when the patient is warm in bed.

The eruption in scabies is localized in great measure according to the character of the patient's clothing, and differs in this respect in men, women and children. Upon the hands and wrists it is common in all, but its prevalence about the breasts in women, and upon the genitals in men and boys seems to depend upon the ease with which they can scratch in those localities, especially at night. In young children, who wear long, close-fitting night-dresses, the ankles, which alone are exposed, are usually the seat of an eruption. The face and scalp are usually free from eruption, even in the most severe cases of scabies. A secondary eczema, however, may be found upon the head, as well as on the body. The disease is usually contracted at night, from some affected bedfellow. The physician may handle the hands of a patient with impunity, according to my experience. Nevertheless, one writer has stated that he contracted the disease "from incautiously handling and hunting for the mite on a child's arm."

## SCABIES.

The diagnosis of scabies may be based upon the discovery of burrows, or, in the event of not finding them, upon the characteristic locality of the excoriated papules which constitute the eruption. The burrows are more apt to be found in mild and recent cases than in severe cases, where the hands are covered with vesicles and pustules. When the occupation of the patient causes the hands to be kept very much in water, they may appear perfectly free from the disease, and yet a characteristic eruption exist on the body.

The treatment of scabies depends upon the age of the patient, the chronicity of the disease, and the presence or absence of a secondary eczema. In infants, whose tender skin would certainly become inflamed from use of the ordinary stimulating sulphur ointment, equal parts of vaseline and balsam of Peru may be employed with a satisfactory result. In children and adults stronger applications may be made, although it must be remembered that some skins can bear what others cannot. *Stryx* balsam, in the form of a liniment, made by adding twenty per cent. of olive oil, or as an ointment, made with an equal part of cosmoline, is an agreeable and effective application. Sulphur, however, has long been the chief remedy in scabies, and although others may be equally good, there seems to be none more efficacious in the majority of cases. It is frequently combined with carbonate of potassium, mercury, tar, chalk, &c., but as far as my experience goes, these compound ointments possess no marked advantage over a simple sulphur ointment, which, if applied in strength suitable to the case and to the various parts of the body, will leave nothing to be desired. The *Ungt. Sulphuris* (U. S. P.) consisting of one part of sulphur to two parts of lard, is rather stronger than is necessary, especially when its application is to be repeated, and combined with baths and scap frictions. A twenty, or even a ten per cent. ointment is preferable in most cases, for the patient generally prefers to be cured pleasantly and permanently, to being cured quickly. In a recent case of the affection, smearing the hands at night with the ointment may suffice to effect a cure; but when the disease is of long standing, the whole body with the exception of the head, should be anointed. Before going to bed, the patient may remain for a quarter of an hour in a warm bath. This macerates the epidermis upon the hands and other affected parts to such a degree, that a brisk friction with soap will doubtless exhume some of the acari, and certainly increase the effect of the ointment which is to be subsequently applied. *Hebra* warns against the injudicious use of frequent warm baths, but the effect of bathing, in predisposing the skin to eczematous inflammation is only noticed when one employs the very strong applications which he recommends. If the eruption is seated on a delicate skin, and especially if an eczematous tendency manifests itself, baths may be discarded, while the ointment is used with great care, and not continued but for a few days at a time.

Disinfection of the clothing is unnecessary in most cases, if not in all. It is important, however, to treat not only the patient who applies for treatment, but also the bed-fellows, playmates or associates who may be similarly affected. Otherwise the disease will be re-contracted as soon as it is fairly cured.

The duration of the treatment must necessarily vary. Ordinary cases can be cured in from five to ten days. It is always difficult to say just when the patient is cured, and when, therefore, the treatment should cease. Too often the treatment is continued on account of an eruption which is not due to the acari, but to the irritating applications which are being employed.



SCABIES



SCABIES





## PORRIGO E PEDICULIS.

---

CASE.—A patient at the New York Dispensary. He had suffered, for several months, from phtheiriasis, and the pustular eruption shown in the illustration had developed recently. The crusts were thick, of a greenish-yellow color, and most of them presented a central depression, similar to that observed in a vaccine pustule. Many had fallen spontaneously, and others were but lightly adherent, and when picked off, left circular pinkish macules. Those which had been violently removed by scratching, had left a raw surface or ulceration of the most superficial character. It was quite evident that wherever the skin was excoriated by the finger-nails, the pustules were liable to develop. An auto-inoculation being made, a small vesico-pustule formed within twenty-four hours, and, in the course of three or four days, developed a typical, thick yellow crust.

The name Porrigo has been applied, by the older writers on skin diseases, to so many pustular, as well as non-pustular affections of widely different nature, that, at the present day, it is scarcely able to retain a position in dermatological nomenclature. As there exists, however, a contagious pustular affection of the skin, which is neither eczematous nor unmistakably parasitic, and to which no settled name is attached, I am disposed to follow the example of Startin, Nayler, and Hutchinson, and to apply to it the old and misused term, Porrigo.

The affection is an acute one, and is characterized by the rapid development of one or many flat, vesico-pustules, which spring from an apparently normal skin. These are quite superficial, tend to enlarge peripherally though remaining flattened, and usually attain the size of a ten-cent piece. The crusts which form are thick, friable, varying from a straw color to a greenish-yellow, or brownish hue, and often presenting a central depression, like a vaccine crust. They are lightly adherent, and when forcibly removed, expose a raw, purulent surface, but no deep ulcer. When allowed to dry and fall, a thin, reddened epidermis remains for a short time, and disappears without leaving any scar. The chief peculiarity of the pustules is their contagious character. When occurring, as they frequently do in connection with phtheiriasis, it is quite apparent that they tend to develop wherever the skin is excoriated, and it appears quite probable that the pus partakes of an infectious nature, and is carried from one point to another by the finger-nails. New pustules may be readily produced by intentional auto-inoculation. The affection is quite common among children, but it also attacks adults. Frequently several members of a household are successively affected, and epidemics have been reported to occur. The pustules are most frequently met with upon the scalp and face. The trunk and extremities, and particularly the fingers, may also be its seat. It occasionally develops when no apparent cause exists. Local irritation of some sort, however, can generally be detected, and to the irritating

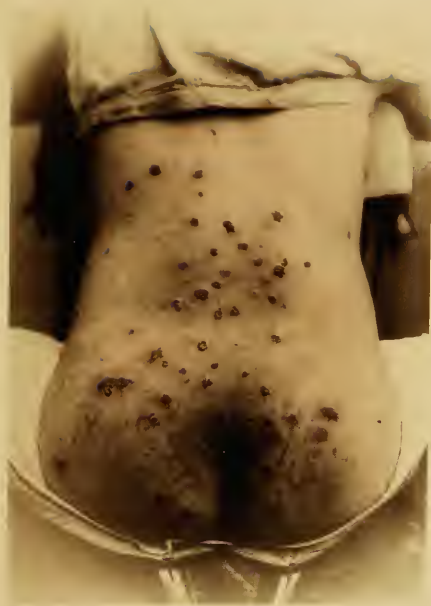## PORRIGO E PEDICULIS.

presence of pediculi the affection is frequently attributable. A fungus has been described as existing in the crusts, but it has not been proven to be the essential cause of the affection.

The diagnosis is easy, although some confusion arises from the varying descriptions of Impetigo and Eczema *impetiginosum* which are found in the text-books. The term Impetigo is regarded, by most recent writers, as a synonym of pustular eczema, "an eczema," according to Tilbury Fox, "occurring in a pyogenic habit of body." The Impetigo *contagiosa*, described by this late writer, appears to me to be simply a form of Porrigo which occurs largely among children, and is usually accompanied, at the outset, by slight febrile symptoms. Such cases I have had repeated opportunities of studying, and have verified the admirable description of the eminent English author. I see no reason, however, why the name which is applied to these cases (be it Porrigo or Impetigo *contagiosa*), should not also be applied to an eruption of isolated, contagious, vesico-pustules in adults, although unaccompanied by febrile symptoms, and occurring as a complication of phtheiriasis. Between Porrigo and Eczema *pustulosum*, there are essential differences in respect to etiology, clinical appearance, and amenability to treatment. Eczema is generally associated with a condition of the system which predisposes to a catarrhal inflammation of the skin. It involves the corium to a greater depth than do the superficial pustules of Porrigo. It is never contagious, and is, as a rule, not readily cured. Porrigo, on the contrary, is almost wholly local in its nature, tends to run a rapid course, and yields to the simplest treatment.

To cure the affection it is first necessary to remove the crusts, which can be done without violence after the application of a poultice or folded cloth wrung out of hot water. A five per cent. ointment of carbolic acid may then be applied to the affected skin for a few days.

The treatment of Phtheiriasis *corporis*, with which affection Porrigo is frequently associated, consists in getting rid of the pediculi, and soothing the irritation of the skin, which their attacks have occasioned. In dispensary practice, I might say that the first aim of treatment should be to convince the patient that the eruption is not due to "heat" or "humor" in the blood, but that it is the natural result of lice in his clothing. The patient may be ignorant of the existence of lice, though generally he is conscious of their presence, but yet so thoroughly possessed with the idea that they are the effect, rather than the cause, of the eruption, that it is in vain to argue the point, and hopeless to give directions for treatment. Such cases can only be treated satisfactorily in hospitals, where enforced cleanliness is possible. When the patient appreciates the fact that the lice cause the eruption, he may be directed to change his clothing throughout, with a fair prospect of his doing so. It is not sufficient, as many patients imagine, to put on a clean shirt once or twice in the week, or even oftener. The patient must be told and shown, if necessary, that the outer garments are infested, and that it is essential to change these as well as the underclothes. While the latter are being boiled, the former may be baked in a hot oven, with the probable result of destroying both lice and ova. It may not be superfluous, however, after the clothes have been thoroughly haked, to sprinkle the seams, where the ova were most numerous, with sulphur, pyrethrum or staphisagria. As regards the eruption on the body, this will quickly disappear when its cause is removed. A daily warm bath will prove agreeable and beneficial when the skin is greatly irritated. For dispensary patients I usually prescribe an ointment or lotion of carbolic acid, which tends to allay the itching, and to repel the parasite.



PORRIGO e PEDICULIS



## HERPES.

---

CASE.—John B., *æt.* 9.—After four days of fever, the eruption suddenly appeared (June 7) in the form of erythematous and vesiculated patches upon the face. The illustration shows its appearance upon the following day, at which time the vesicles had become larger and partly confluent. The patient now had considerable fever. His mother stated that he had been very restless during the preceding night, and that his body had been very red. He was ordered a drop of the tincture of *rhus* every three hours, and on the following day (June 9) was better. On June 10 the eruption was drying into thin crusts. On the 11th the patient was doing well, but, as the mother expressed it, still felt “droopy.” He complained of some abdominal pain, although his bowels were free. The eruption was attended by some itching, and the face had been scratched in several places. No reason could be assigned for this attack. The mother stated that the boy had suffered repeatedly from a similar eruption of blisters upon the nose, mouth, and cheeks, but never before in such a marked degree. The attacks had always been preceded and accompanied by more or less fever.

Herpes, a term old enough to have been used by Hippocrates, has been applied, by writers in times past, to numerous and varied affections. Even at the present time there are some who apply it, with varying adjectives, to both vesicular and bullous, as well as to parasitic, affections. The tendency of modern dermatology has been toward a limited application of the term to acute affections, characterized by the development of vesicles in groups. From a clinical point of view, I deem it convenient and advisable to regard zoster and hydroa, two vesicular or vesiculo-bullous affections, as distinct from the ordinary herpes, so frequently met with upon the lips and prepuce. The reasons for separating zoster from herpes have already been stated in connection with a former illustration, and the relations of herpes to hydroa will be given later, in connection with a plate representing the latter affection.

Herpes may be defined as an acute inflammatory affection, consisting of one or more groups of vesicles, occurring on the face or external genitals, and in the former location accompanied frequently by fever. This definition limits the application of the term to two comparatively insignificant forms of vesicular eruption, called in accordance with the regions affected, *H. facialis* and *H. progenitalis*.

Herpes *facialis*, in its most frequent form, is met with upon the margin of the lips, constituting what is commonly termed a cold sore (*H. labialis*). The vesicles, in such a case, are not usually distinct, and the person affected may note but one or more slight swellings of the lip, attended by an unpleasant burning sensation, and the rapid development of a thin crust or scab. The affection may result from no apparent cause, but the patient is frequently conscious of having “caught a cold.” The eruption often extends from the vermilion border of the lip upon the cutaneous surface, and groups

## HERPES.

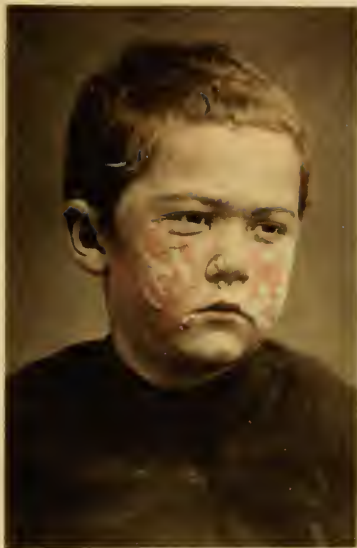of vesicles are seen upon the side of the nose and cheeks. When developed to this extent, the eruption, particularly in children, is apt to be associated with more or less fever. In rare instances, the forehead, eyelids, ears, as well as the mucous surface of the tongue and buccal cavity become the seat of the eruption. However numerous may be the groups of vesicles, they are usually developed simultaneously, the affection differing in this respect from zoster and hydroa. The vesicles develop upon an erythematous base, are rounded and tense, and though larger than the vesicles of eczema, are not equal in size to those which are seen in cases of hydroa. An uncomfortable, burning sensation accompanies their outbreak, but subsides as soon as the eruption has attained its maximum development. There is never any of the neuralgic pain which is so common a feature of zoster. The vesicles rarely rupture when protected from external irritation, but dry speedily, in the course of a week, to thin, dark crusts, which fall and leave a slightly reddened surface. In certain patients, as, for example, in the subject of our illustration, there is a marked tendency of the eruption to recur at intervals.

The etiology of facial herpes is not thoroughly understood. That it is frequently due to reflex nervous irritation is quite apparent from the fact of its common occurrence in the early stage of pneumonia, and in the urethral fever following internal urethrotomy. The old idea that its occurrence is a favorable prognostic sign appears to have no scientific basis.

The treatment of the affection is mainly expectant. A dusting powder is the best external application when the eruption is extensive. Spirit of camphor, or some similar stimulating liquid may be applied frequently to an incipient "cold sore" in the hope of checking its development. If it fails, as it generally does, cold cream may be applied with good effect, for the purpose of softening the crust which forms.

*Herpes pro genitalis* consists in the eruption of one or two small groups of vesicles on an erythematous base, and is unaccompanied by fever. In the male the sheath of the penis, the prepuce or the glans may be its seat, while in the female it may be found upon the labia and pubes. When upon a cutaneous surface, it is usually recognized without difficulty, but upon the mucous surface of the genitalia the vesicles become quickly macerated, and a mere erosion results. Herpes of the internal surface of the prepuce is a quite common affection, and one which is frequently regarded by both patient and physician, as being of venereal origin. This may be the case, as the irritation of the sexual act may evoke the eruption, especially in one predisposed to herpes of this part. Moreover, it may be the result of direct contagion, since the serum contained in the vesicles has been successfully inoculated. But usually herpes of the prepuce is an innocent affair. The affection frequently occurs in those who have never had any venereal disease, nor indulged in impure intercourse. The vesicles are usually accompanied by slight soreness, and in some cases by a decided pruritus. If the part is in a cleanly condition, the eruption runs a rapid course and disappears in four or five days. A tendency to recur is noted in certain patients, as was seen in the case of herpes of the face. Those who have suffered from venereal disease are especially liable to recurrent attacks, some patients suffering in this way for years. Shortly after the healing of a chaneroid, herpes is prone to occur, in which case it is very apt to be erroneously regarded as a relapse, or as a fresh infection.

The treatment of this form of herpes is simple. Keep the part clean and dry.



HERPES FACIALIS.





## HYDROA.

---

**CASE.**—Henry B., act. 15.—The eruption in this case was limited to the parts shown in the illustration. The photograph was taken about the tenth day, at which time the bullæ were becoming flatter, their contents somewhat turbid, and the epidermis over the confluent patches was wrinkled from absorption of serum. The arms felt stiff and sore. There was no marked itching, and little or no constitutional disturbance. Iron and quinine were given internally, and powdered starch applied locally as an absorbent. The eruption disappeared in about three weeks. Two and a half years later the patient came to me again with a somewhat similar eruption upon the hands, face, and scrotum. The palms were affected this time as well as the backs of the hands. This attack was more severe than the former, and was accompanied by soreness of the joints. Its duration was also about three weeks. Small doses of the tincture of the rhus toxicodendron were given, with an apparent effect in lessening the local pain and checking the development of the bullæ. (A fuller description of these two attacks may be found in the Archives of Dermatology, Vol. III., p. 25, and Vol. IV., p. 211.)

Hydroa, a term first employed by Bazin, has gradually come into use during the past twenty years. It has hardly acquired, as yet, a definite signification, but is applied to certain cases of vesicular or vesiculo-bullous eruption, possessing clinical features which serve to distinguish them from herpes and from pemphigus, with which affections they were formerly confounded. The disease is not a common one, and while the cases met with present salient features which mark their identity, they vary in their clinical aspect to such an extent that a concise definition cannot be given, which will include all forms of the affection. The leading characteristics of hydroa are its symmetrical distribution, its peculiar locality, its tendency to recur at longer or shorter intervals, and the constitutional derangement which usually accompanies the eruption. It begins, as a rule, by the sudden development of erythematous papules or patches, upon the central portion of which a single vesicle or group of vesicles is rapidly formed. These are usually of large size and hemispherical. They contain at first clear serum, which in a few days becomes cloudy and gives to the patches a whitish or even a yellowish aspect. There are generally some isolated vesicles or bullæ, and these do not always spring from an erythematous base. They may attain the size of a pemphigus bulla, and become surrounded as they mature, by a narrow zone of inflammation. The groups of vesicles tend to become depressed in the center, and sometimes an advancing vesicular margin is noted. A tendency to successive crops of vesicles is common, and when the eruption is subsiding at one point, a relapse may take place upon some other portion of the body.

The serous contents of the vesicles and bullæ tend to become absorbed, and leave merely a

## HYDROA.

desquamating epidermis, but when the lesions are ruptured by scratching or other external violence, a yellowish crust or a dark scab may form. The subjective symptoms, in a mild case, consist chiefly in a burning sensation, but in many cases, and especially in those which run a more chronic course, the itching may be intense. There is generally a marked impairment of the general health preceding the attack, and while the eruption is present, the patient is usually wholly unfitted for his customary duties. There occur now and then rheumatic complications, and effusion into the knee joint has been reported. The disease commonly runs an acute course, the successive crops of vesicles disappearing in a few weeks or months, but it may persist for years. It is non-contagious, and though in many instances a severe affection, it is rarely, if ever, fatal.

The favorite seat of hydroa is upon the extensor surface of the forearms and hands, the face and ears, the genitals, knees and feet. In many cases the oral cavity is likewise affected, the uvula and soft palate being frequently the seat of vesicles, or presenting an inflamed or eroded appearance. The affection is apt to attack young persons, and appears to be most common in the early winter and early summer. Some may have a number of attacks during the year, and cases have been reported where an annual attack has occurred since childhood. The causes of hydroa are obscure, but it is evident that the eruption is due to derangement of the nerve-centers, and not dependent upon any blood changes.

The diagnosis is not difficult, but as there are no sharp boundary lines between herpes, hydroa, and pemphigus, cases often occur which illustrate the relationship of hydroa to one of the other affections named, and a question might arise as to the most appropriate term for a given case. The main features of the three affections may be contrasted as follows:

	HERPES.	HYDROA.	PEMPHIGUS.
<i>Lesion.</i>	Vesicles in groups.	Large vesicles or bullæ, isolated or grouped.	Bullæ, always isolated.
<i>Location.</i>	Face and genitals only.	Face, forearms, scrotum, knees and feet. Rarely general.	All portions of the body.
<i>Course.</i>	Acute, lasting but a few days.	Acute or chronic, lasting a few weeks or longer.	Chronic, lasting for years.
<i>Treatment.</i>	None required.	Treatment may hasten the cure.	Is rarely cured, and often fatal.

The chief aim of treatment in a case of hydroa should be to restore to the patient his natural degree of health of mind and body, taking little account, in most cases, of the eruption upon the skin. The nervine tonics, such as arsenic, quinine, and cod-liver oil, are highly recommended, and with these, and the beneficial effects of a complete cessation from work and worry, with perhaps a change of scene when it is practicable, a speedy cure may be expected. When the patches are in a highly inflammatory condition, the common lead and opium wash is of service, and when itching is a prominent symptom, the parts may be rubbed with camphorated oil.



HYDROA PULICUM



## ERYTHEMA CIRCINATUM.

## ERYTHEMA EXFOLIATIVUM.

---

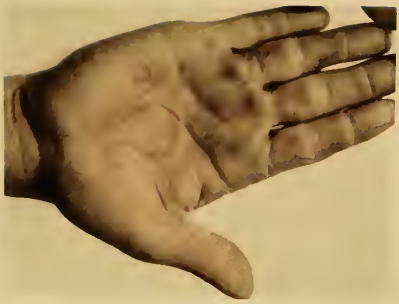CASE OF ERYTHEMA CIRCINATUM.—W. R., *æ*t. 34, American.—By occupation, a pilot.—This patient was sent by Dr. Robert Abbé to a meeting of the New York Dermatological Society, and afterward kindly placed under my observation. He was a large and powerful man, apparently in perfect health. A searching examination made by Dr. Abbé failed to reveal any history or evidence of syphilis. He had never had any eruption elsewhere upon the skin, and with the exception of a slight attack of rheumatism, had never been ill. His tongue was clean, his appetite good, his bowels slightly constipated, and his urine clear. He stated that, six weeks previously, a small, itely red spot appeared in the center of his left palm, and gradually increased in size. A few days later two similar spots appeared in right palm. About six months before this, the patient had suffered from a similar, though milder attack. There were, at that time, two or three circular, non-elevated patches in each palm, which itched exceedingly, and disappeared in about a month without treatment. No scaling followed. Upon examination of the palms during the second attack, the center of each was found to be the seat of a nearly circular, purplish-red ring. The circle in the left palm (apparently the right in the illustration), presented an irregular border, and appeared as though one or two small rings had coalesced with the central circle by centrifugal extension. On the right palm were three small lesions, in addition to the central circle, two being near the latter, and one on the long finger, near its base. These small lesions were just beginning to grow annular by a fading of the color in the center. The central circles were of half dollar size, and not at all elevated, although Dr. Abbé assures me that they were so at the outset. Their most striking feature consisted in a double border, the inner one being of a purplish-red color, and evidently indicating the height of the exudative process, the outer one appearing whitish, like the epidermis raised by a blister. The lesions were not very striking in appearance, especially the incipient ones. But the purple band of the central circles showed very plainly when the fingers were forcibly extended, so as to blanch the surrounding tissue, or when the palm was rubbed briskly for a few seconds with the corner of a dampened towel. The eruption was accompanied by a severe and annoying itching, which kept the patient rubbing or picking at the palms, but the epidermis was not at all excoriated.

The treatment adopted at first in this case was purely expectant, but as the eruption showed no tendency to disappear of its own accord, as it had done six months before, the patient was ordered nightly frictions with green soap, to be followed by the inunction of mercurial ointment. This appeared to have no effect, and on January 6, two weeks after the photograph was taken, the rings were increasing in size, and very itchy, especially after washing the hands. Rochelle salts internally and ehrysophanic acid ointment locally were ordered, and the eruption disappeared after a duration of ten weeks.

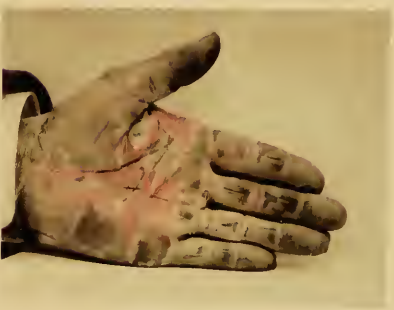*ERYTHEMA CIRCINATUM—ERYTHEMA EXFOLIATIVUM.*

CASE OF *ERYTHEMA EXFOLIATIVUM*.—Chas. O., æt. 23, German.—By occupation, a porter.—The patient had a sallow complexion, but was strong and apparently in good condition. He gave the following history. In his youth, from the age of four to fourteen, he had suffered every summer from a general "peeling of the skin." The attack would usually confine him to his bed for five or six weeks, and he remembers that large sheets of skin could be loosened and removed entire from his body. At the close of each attack, the thick skin of the soles of the feet would separate in two portions, one from the ball of the foot and one from the heel. His four brothers and one sister were all healthy, as was the patient himself, between these annual attacks. From the age of fourteen to twenty-two he was in good health, and free from his early trouble, with the exception of a single mild attack, which occurred when about nineteen. During the past six months he has had at least six mild attacks, in such rapid succession that the erythema would sometimes appear upon the body before the palms had finished scaling as the result of a former attack. When first seen by me (January 20), the patient stated that on the morning of the previous day he had awoke to find his body and extremities reddened, as was usual at the beginning of an attack. An examination revealed a vivid erythema upon the sides of the trunk, the neck, arms, and thighs. The skin on the palms was dry and harsh, and apparently beginning to separate. (This condition resulted from a previous attack, which occurred a few weeks before.) It began to exfoliate shortly after, and presented the appearance shown in the illustration. The erythema quickly became universal, with the exception of the face, penis, and backs of hands, and was immediately followed by a desquamation of the epidermis. On the scalp it occasioned an acute attack of pityriasis. On January 26 the attack was waning; it had been severer than his recent attacks, but did not compare in severity with those which he had as a boy. The skin of the body appeared of a dusky red hue, indicative of venous congestion. The skin on the inner side of the thighs and gluteal region was quite dark, and on close examination presented a slightly powdery surface. Drawing the finger nail rapidly over it a number of times produced at first whitish, chalky lines, which rapidly assumed a bright red color, contrasting strongly with the surrounding livid hue. There was no evidence of urticaria, and this irritation of the skin was unaccompanied by itching. The knees appeared whitish from the presence of thin, adherent scales, and there was a certain amount of pityriasis on various portions of the body.

On March 2, patient came to me with another attack. Two days before he had felt perfectly well. He slept well that night, but awoke on the following morning with the redness of whole body, excluding head, hands and feet. The skin was hot as well as red, and he experienced a burning sensation, especially at the flexures of the joints. He felt weak during the day, and complained of nausea, but again slept well. When seen by me the brightness of the erythema was already fading, and the skin appeared like that of an Indian, or as it sometimes appears after staining with chrysophanic acid. His red flannel underclothing, which had lost its brightness by long use, very nearly matched the shade of the skin. The hyperæmia was intense, but of a passive character, and the body contrasted strongly with the face, which was pale and sallow. On March 5 the purplish redness had faded, and where the skin was naturally thin, the desquamation was beginning at numerous points, in the form of small siliquose elevations of the epidermis. From these points the desquamation proceeded centrifugally, leaving patches of normal skin, surrounded by an irregular white line of exfoliating epidermis. On March 7 there were islands, not of denuded skin, as before, but of old epidermis. These remaining patches appeared of a dirty, yellowish-brown color, and were dotted by the siliquose elevations of epidermis, and small circular spots, from which the epidermis had fallen. The patient was feeling perfectly well.



ERYTHEMA



ERYTHEMA





## PURPURA.

---

CASE.—Mrs. J. H., æt. 31, widow.—Occupation, a cook. Patient at the New York Dispensary, under the care of Dr. G. W. Robinson. At the age of 21 she first menstruated, and again a year later. Since that time there has been no menstruation. Has suffered from dyspepsia for twelve years. In May, 1875, she had an apoplectic seizure, and was paralyzed and in hospital for four months. Upon her dismissal she went into service, but kept her place but two days on account of a purpuric attack affecting the legs, which disappeared in about a week without treatment. She had repeated attacks during the succeeding year, and in June, 1876, upon applying for treatment at the dispensary, the following notes were made: Appearance very stupid. Uncertainty of speech. Right arm and side not as strong as the left. Tongue coated. Craving appetite. Bowels constipated. Confluent patches of purpura below the knees, with œdema and tenderness of the legs. Small discrete spots above the knees. She was given a mixture of iron and ergot, and the lower limbs were bandaged, under which treatment she grew well and strong in about six weeks. A month later she returned, with a slight attack, from which she recovered in a week, under similar treatment.

An effusion of blood from the cutaneous capillaries may take place from three causes, viz., external violence, increased blood-pressure, and weakness of the vascular walls. To all of these forms of cutaneous hemorrhage some writers have applied the term purpura, which is manifestly wrong, since it places a flea-bite or a "black-eye" in the same category with scurvy. The term purpura should be used in a restricted sense, and applied only to an independent disease, in which cutaneous hemorrhages occur as a primary lesion. This excludes the hemorrhage resulting from a blow, fall, or the bite of an insect, as also that which is due to obstruction of the venous circulation. It excludes the hemorrhage which occurs secondarily in the course of the exanthematous fevers (*e. g.*, Variola hemorrhagica), and in certain inflammatory skin affections, such as erythema, urticaria, and pemphigus. Finally, it excludes scorbutus (or scurvy), as being an affection due to a definite and well-known cause.

It is customary to describe four forms of purpura. In the most common form, or purpura simplex, numerous small spots, of a bright purplish-red or claret color, appear suddenly on the lower extremities, and in rare instances on other portions of the body. They occur spontaneously, and are usually unaccompanied by any marked general symptoms. The bright color changes in the course of a few days to a dull red, and after assuming the greenish and yellowish hues so frequently noted after an ordinary bruise, the spots gradually disappear. Fresh extravasations often appear from time to time during the course of the affection, and thus a contrast of colors may result.

## PURPURA.

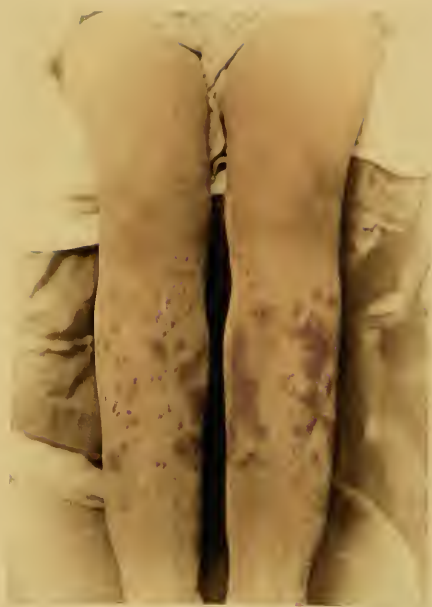The spots commonly vary in size from a pinhead to a small pea, are not at all elevated, and do not disappear on pressure. Sometimes they are slightly prominent at the outset, and sometimes large livid patches develop, as may be seen in the illustration.

Purpura hemorrhagica is a more aggravated form of the disease, in which large cutaneous extravasations are seen, not only on the skin, but also upon the mucous membranes. Hemorrhages from the nose and gums occur, as also bloody stools and urine. The constitutional symptoms are marked, and the weakness resulting from a continued loss of blood may lead to a fatal termination.

Purpura (or peliosis) rheumatica is a peculiar affection (conveniently regarded at present as a form of purpura), in which arthritic pains and fever precede an eruption of small hemorrhagic macules upon both trunk and extremities. The disease usually runs a brief course, although a repeated onset of fever and rheumatic pains, followed by cutaneous hemorrhages, may protract it for months. It commonly attacks those who have a rheumatic tendency, but are otherwise apparently well.

The diagnosis of the simple and hemorrhagic forms of purpura is unattended with difficulty. To the practiced eye the cutaneous lesions are characteristic, but their hemorrhagic nature can be easily verified by noting the fact that they do not change in color under pressure of the finger, a circumstance which enables the tyro to distinguish them from inflammatory lesions. Scorbutus, or sea-scurvy, is regarded as distinct from purpura hemorrhagica, on account of its gradual development, the marked swelling of the gums, with loosening of the teeth, and the extreme debility, which are its prominent features; and from the fact that it occurs so frequently among sailors and those who cannot or do not eat fresh vegetables. Purpura rheumatica may be readily mistaken for rheumatism during the few days which precede the outbreak of the characteristic eruption. Tillyny Fox regarded this form as simply an erythema, complicated by hemorrhage.

The treatment of purpura consists chiefly in removing any cause which may be ascertainable, and in enjoining absolute rest where the hemorrhages are severe and frequent. Iron, ergot, the mineral acids, and quinine are remedies of value, although too much reliance may be placed upon their action, and too little thought given to the question of rest, proper diet, and the hygienic influences which surround the patient. In mild cases of purpura *simplex* a moderate amount of exercise is rather advantageous than otherwise, and often the treatment need not interfere with the daily duties of the patient. No remedy can be given to hasten the disappearance of the hemorrhagic spots, but full doses of the tincture of the chloride of iron will usually check the development of new lesions, and improve the general condition of the patient. In purpura *rheumatica* the patient usually recovers speedily under good nursing, although an anodyne may be necessary to relieve pain, and a tonic of iron or quinine prove serviceable at the close of the attack. In purpura *hemorrhagica* the patient must be kept as quiet as possible. Ergot may be given by the mouth or by hypodermic injection. For the latter purpose dissolve five centigrams of ergotin in warm water and glycerine. This, with the use of ice, will promptly control the hemorrhage from the mucous membranes. A diet of fresh vegetables, which invariably produces such a beneficial change in scorbutus (sea scurvy) is of no value in the treatment of purpura hemorrhagica.



PURPURA SIMPLEX.



## CORNUA CUTANEA.

---

CASE.—E. H. C., *æt.* 58.—Patient of Dr. Geo. F. French, of Minneapolis, Minn. About three years ago a lesion appeared on the edge of the lower lip, near the angle of the mouth, which, in a few weeks, bore a resemblance to a rupial crust. In three months it had assumed a horny consistence, and at the end of a year was one-half an inch in length. About this time two more horns appeared on the opposite side of the lip, and in six months attained the size of the first. Six months later these three horns were cut off close to the lip, but in a year they grew to three or four times their former dimensions. Two months ago, while in the woods, and pushing his way through the brush, the horns were torn apart, and the lacerated wound, which has never healed, discharges, at the present time, a foul, unhealthy pus, and the sore presents an epitheliomatous appearance. The horns from this patient, which Dr. French was kind enough to send me with a photograph, are three in number; the smallest one is about an inch in length, of a dull yellowish white color, tolerably smooth, quite dense, and sharply curved near its apex. The others are over two inches in length, of a brownish-yellow hue, and rugose in appearance. They are also curved, but not so sharply as the smaller one, are slightly twisted, and present a bifurcation a little more than an inch from the base. The apices of one horn lie close together, one being shorter than the other, while those of the other horn tend to diverge. The basic portion of the larger horns is hollow, and readily crumbles, now that they have become dry.

In medical literature we find many accounts of human horns springing from various portions of the body. These cases create surprise and wonder at first thought, but when we consider that the outer layer of the epidermis, together with the nails, is a natural growth of horny character, we become far less surprised by these unnatural horny growths. The favorite seat of horns may be said to be the head, although there is scarcely a portion of the whole body which has been spared. They have been reported as occurring on the scalp, forehead, temple, nose, cheek, lip, jaw, breast, back, pubes, glans penis, scrotum, præputium clitoridis, thigh, knee, leg, hand and foot. Though usually occurring in the aged, they have been met with in young children. In size and shape they vary considerably, some being short and stumpy, others conical, and many long, curving, and somewhat spiral. Rayner mentions the case of an old woman with a conoidal horn springing from the forehead, which was six or seven inches in diameter at the base, and which projected six inches. Naylor speaks of a horn ten inches in length, and curved like a ram's horn. The shorter horns, with a rounded extremity, are usually thicker at the base than those of greater length. The long ones are always curved when a few inches in length, and often twisted. The surface is always rough, and usually ridged transversely. When of a marked horny character the horn may present longitudinal striae, and show a tendency to split in

## CORNUA CUTANEA.

this direction. The color of a horn varies from a yellowish to a dark brown or blackish hue, and is lighter at the apex than at the base. The consistence of the growth also varies, some horns being soft and friable, and others quite dense. The outer portion is always harder than the inner. The base of a horn, like the base or youngest portion of a nail, is often surrounded with a thin layer of epidermis. When removed, the horn presents a conical cup-like depression, which fits over a fungoid mass projecting above the level of the skin. When cut across, it may be found to be cylindrical or flattened from side to side. Microscopical examination shows it to be composed chiefly of epidermic cells, usually arranged in a concentric manner. The horn may spring from the free surface of the skin, or originate in one of the larger sebaceous follicles. It may therefore be regarded as being either an exaggerated wart, having a soft, pulpy, papillomatous base, surmounted by a cone of dense epidermis, or as being a dried and hardened sebaceous or epidermic mass, which derives its shape from being slowly extruded from a sebaceous cyst. In some cases the nail, especially that of the great toe, becomes greatly thickened and rounded and finally assumes the shape and other characteristics of a horn.

Cutaneous horns develop slowly, and are painless when unirritated. The base may become inflamed from injury done to it by violent movement of the growth. A horn may continue to grow, whatever size it has attained, but the longer it is, the greater is its liability to become accidentally knocked or torn off. When it falls in this way, or is merely cut off on a level with the surrounding skin, the growth is reproduced, and a succession of horns may occupy a given site. Not infrequently two horns take the place of a preceding one.

The diagnosis of a case is easy when the horn is present. The base from which it springs might be mistaken for an epithelioma or malignant growth of some kind. On the lip, indeed, epithelioma has been observed to follow a horny growth.

The treatment called for in the case of a cutaneous horn consists in not only removing the growth, but in destroying the base from which it springs, in order to prevent its reproduction. The horn itself, being frequently quite movable, can be readily torn from the skin with a slight amount of violence, especially when the part has been previously softened. The base should now be scraped with the curette, and cauterized lightly with caustic potassa, or the chloride of zinc. This will produce a radical cure, and leave but a trifling scar in place of the unsightly excrescence. When the horn springs from a distended follicle or cyst, extirpation of this with the horny growth is usually recommended.



CORNUA PHOTOM.





## ALOPECIA AREATA.

---

CASE.—J. L., æt. 46.—A patient of a marked nervous temperament, but apparently in perfect health. He states that his father was bald, that an elder brother has thick hair, and that a younger sister had a single bald spot on her scalp two years ago, which recovered without treatment. His own baldness began nearly a year ago, at which time, after having his hair cut, his wife noticed three small bald spots on side of head and occiput. Since then numerous bald spots have appeared upon the scalp, cheeks and upper lip. These have coalesced, and at times formed long patches or streaks of baldness, especially upon the scalp. There is a single spot on the posterior ulnar aspect of the left forearm. On the upper part and side of the head there are a number of spots which are quite bald, and others which present a growth of sparse white hairs. To the left of the sagittal suture is a line of closely cut dark hairs which have not fallen. The vertex, though practically bald, is covered with very fine hairs, and the occiput presents, at a distance, a peculiar piebald appearance, there being fifteen or twenty areas, varying in size from a ten cent piece to a silver dollar. These leave an intermediate net-work of dark hair, which represents the original growth. The back of the neck is unusually hairy, while on the lower portion of the occiput a transverse patch of baldness extends from ear to ear, broken by a narrow vertical line of hair on the left side. The eye-brows are unaffected. The beard, which had always been of a dark brown color, began to be streaked with white on either side of chin shortly after the bald spots appeared on the scalp. The patient has noticed no change in his health, either before or since the development of the baldness. He asserts that he feels as well now as he ever did.

Alopecia areata is a form of baldness, which begins suddenly, at one or more points, and rapidly produces smooth, white patches of circular shape and variable size. These tend to increase peripherally to a greater or less extent, and often run together in such a manner as to form large irregular patches, or long streaks of baldness. The disease not only attacks the scalp and beard, but also the pubes and axillæ, and in rare instances not a single hair remains upon any portion of the body. It has no relation whatever to ordinary baldness, occurs very frequently in young persons, and may attack those who have naturally a luxuriant growth of hair. It is unaccompanied by itching or other subjective sensations. After a variable length of time a new growth of fine downy hair appears upon the bald spots. This new growth is frequently white at first, but gradually becomes pigmented, and in time no trace of the affection is to be seen. When the bald spots are numerous some will be found to recover far more quickly than others, and in some cases, when the hair is apparently growing normally once more, a relapse may suddenly occur. Concerning the etiology of

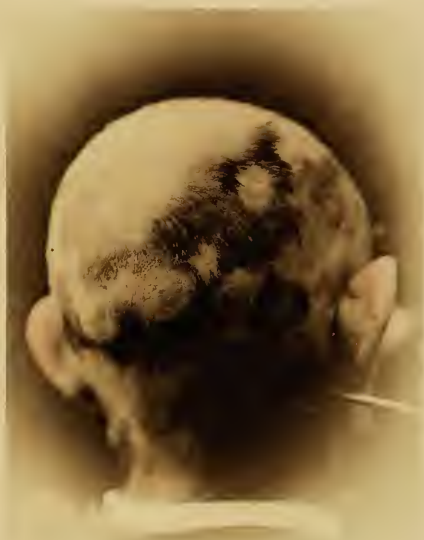### ALOPECIA AREATA.

the disease, very little can be positively asserted. It appears to be dependent upon a trophoneurosis or functional nerve derangement. A parasitic origin has been claimed for it, but the claim is by no means established. Two or more cases frequently occur in a family, and seem to indicate an hereditary tendency or predisposition.

The diagnosis of the affection is easy. Trichophytosis of the scalp may bear a resemblance, but in the latter affection the hairs break off instead of falling out, and leave rough, scaly patches, quite different from the smooth, velvety areas of the former. The two affections, however, may co-exist in some cases.

The treatment of alopecia areata is, to a certain extent, empirical, and the results obtained are exceedingly variable. In some cases there is a tendency to spontaneous recovery, and hair may grow again upon the bald spots in the course of a few months, even without treatment. Indeed, nearly every case will get well in time, but it often requires a long time, one or two years, perhaps, and though, in many cases which recover spontaneously, the credit is unjustly awarded to the remedies employed, it is, nevertheless, certain that judicious treatment tends to hasten a cure. In every case a guarded prognosis should be given as to the time required to effect a cure. Otherwise the result may bring discredit to the physician and disappointment to the patient.

As nervous debility, headaches, and other ills, often precede or accompany the affection, it is important that these be detected and appropriately treated. If the general condition of the patient is not what it ought to be, attention should be directed to this point rather than to the baldness. There is no special internal remedy which can be recommended above others, although on theoretical grounds the various nervine tonics would seem to be indicated. The local treatment consists in epilation of the loose hairs surrounding the bald patch; in occasional blistering of the denuded scalp; in frequent shaving of the new growth of hair, and in the persistent use of various strongly stimulating remedies. Blistering and shaving are remedies highly esteemed by some, but it is a question whether they are as beneficial as they are disagreeable. I have usually dispensed with them, and relied mainly on the use of local stimulants, of which the strong solution of ammonia is one of the most efficient. If the odor of the ammonia is objectionable, a lotion of equal parts of the tincture of cantharidis and bay-rum may be applied morning and night. A host of other stimulating remedies have been recommended, but they all act in the same way. There is no benefit to be derived from changing from one to another, except as it may amuse the patient or curb his impatient desire for a speedy cure.



ALOPECIA AREATA



## MORPHŒA.—SCLERODERMA.

---

CASE OF MORPHŒA.—Alice D., æt. 35.—Patient at the New York Dispensary, under the care of Dr. P. A. Morrow. The patch upon the upper part of the right arm had developed within a year. It occasioned no pain or inconvenience, and her attention was attracted to it by accident. The patch had a hard horny feeling, and could be pinched up from the underlying tissues. It presented a white waxy appearance, like the surface of leaf-lard, and had a glazed and shiny aspect. Its upper and outer borders were marked by a broad margin of a mottled brownish pigmentation, interspersed with numerous milky white spots. Upon the right cheek there was a circumscribed patch, which appeared to be undergoing the first changes of the disease, and which might have been mistaken for a patch of leucoderma. The patches on the arm were very itchy, but no other subjective symptoms existed. In four months, during which time I had repeated opportunities of studying the case, through the kindness of Dr. Morrow, no material change took place. The dead white color of the large patch assumed a yellow or yellowish white hue.

CASE OF SCLERODERMA.—Mary M., æt. 10.—Patient of Dr. V. P. Gibney. The affection began at the age of three years. The progress had been steady and gradual, not marked by pain or tenderness. The lower half of the left side of the face presented a typical *hemiatrophia facialis*, and an examination of the scalp revealed a patch of canities and another of alopecia areata. (For a complete report of the above cases see Archives of Dermatology, April, 1879.)

It is convenient to speak of morphœa and scleroderma together, as there is a kinship between the two affections, and, according to several recent writers, a pathological identity. But whether they are forms or stages of the same disease or not, a clinical differentiation is generally easy, and until a fuller knowledge of their nature has been acquired, it appears advisable to retain both terms in use.

Morphœa is a circumscribed affection. When first noticed there are usually one or more round or oval whitish patches of skin, with a faintly marked border, of a darker hue. When multiple, these patches vary in size, and are usually distributed along the course of a nerve. They increase but slowly in size, and assume either an alabaster whiteness or a dull, creamy tint, which has been aptly compared to the color of an old billiard ball. They are seldom raised, but, on the contrary, they may be slightly depressed below the surface of the skin, and appear atrophic in character. The surface may be smooth and waxy, or roughened by numerous fine wrinkles, which give to it a peculiar shriveled appearance. Sometimes a patch is quite firm to the touch, although the hardness, when present, is always superficial. On the other hand, it may differ little to the touch from the surrounding normal skin. The narrow border frequently assumes a dull red or lilac hue, and constitutes a conspicuous

### MORPHŒA—SCLERODERMA.

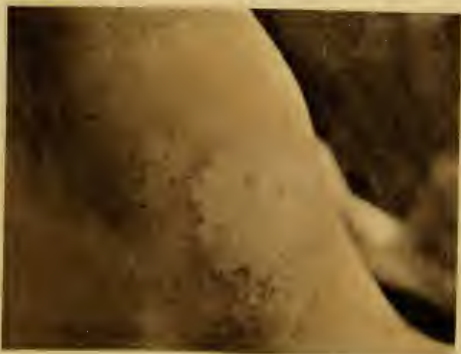feature of the affection. Dark macules, of a similar tint, are often noted as preceding the development of the small white patches. The affection is most common on the extremities, though met with also on the neck and trunk. There is no pain or discomfort produced by the presence of the patches, and after a lapse of years they may tend to disappear spontaneously.

Scleroderma is a diffused induration of a tract of skin and its subjacent connective tissue. The affected part at first becomes stiff, and later assumes a certain density and tension, which is well expressed by the term "hide-bound." The skin itself presents no lesions to the eye, save in some cases a decided pigmentation. The affected part may appear shrunken, but the peculiarity of the affection is best revealed to the touch. There is usually no margin to a patch of scleroderma. The hardness gradually shades off into the surrounding normal skin. Large tracts of skin are often involved by the disease—the whole side of a limb, for example. Like morphœa, it progresses slowly, lasts indefinitely, and in rare instances subsides spontaneously.

From the above brief description a striking difference is seen to exist between typical cases of morphœa and scleroderma. But in some cases the patient presents lesions characteristic of each affection. The diagnosis is consequently uncertain, and the conviction is fostered that the two affections are identical in nature. Both morphœa and scleroderma have been observed more frequently in women than in men. Cases occur infrequently in childhood. No known cause exists, and the patients affected may in other respects appear in average health.

Morphœa, in its incipient stage, is to be distinguished from scleroderma, to which it may bear a resemblance. The marked change in the character of the skin, apart from its mere loss of pigment, and the partial anæsthesia which usually exists, are points of diagnostic value. The whitish anasthetic macules which sometimes occur in leprosy resemble morphœa, but their nature is generally revealed by the co-existing indications of the leprosy diathesis. Scleroderma can hardly be confounded with other cutaneous affections. It should be remarked, however, that there exists an acute affection of the skin, in which hardening of the integument takes place rapidly over a large portion of the body, and disappears in a short time. This must be distinguished from scleroderma, and may be conveniently called scleriosis or sclerema, the latter of which terms has been usually applied to a similar affection occurring in infants (*Sclerema neonatorum*).

Little can be said as to the benefit to be expected from treatment in cases of morphœa or scleroderma. Under arsenic internally and the local application of the constant galvanic current there seems to be the best prospect of achieving success. The use of the galvanic battery in cases of scleroderma has been followed by very good results. The progress of these affections is slow and the prognosis is uncertain. A marked improvement, if not a perfect cure, is always a possibility, and since the local condition is more or less dependent upon the general health of the patient, nothing in the shape of tonic and hygienic treatment should be neglected.



MORPHEA.



SCLERODERMA.





## SARCOMA PIGMENTOSUM.

---

CASE.—William R., *æt.* 22, American, driver.—This patient was successively under the care of Dr. Geo. K. Smith and Dr. S. Sherwell, of Brooklyn, and Dr. L. D. Bulkley, of New York. To Drs. Sherwell and Bulkley I am indebted for a complete history of the case, and to the latter for the negatives used. The patient had always been healthy as a child, with the exception of a few convulsions. Six years before the photographs were taken he received a blow on the outer side of the right eye-ball. Shortly after a minute black speck appeared on the site of the bruise, which steadily, though slowly, increased in size. Small tumors appeared later on various portions of the body, none of which caused any pain. In June, 1874, there were about forty or fifty tumors, varying from a slight nodosity to a large horse-chestnut in size. Dr. Matthewson examined the deeper tissues of the eye ophthalmoscopically without finding any evidence of lesion there (*vide* Trans. Amer. Ophthalmological Soc., July, 1874). At this time only one of the tumors, one situated on the breast, presented any ulcerative change, and this was merely abraded as a result of friction. There was no region of the body exempt, nor any especially favored in the distribution of the tumors. One of hazel-nut size on the right temple was excised by Drs. Smith and Sherwell, to relieve the deformity and for microscopical examination. The tumor was friable in structure, and almost black in color. Microscopically a great excess of pigment matter was found, and many large cells, with two or even three nuclei. The urine was of smoky color, and microscopical examination showed the uric acid crystals to have a blue refraction, and there were minute granules of pigment present of a dark blue color. The patient's general health seemed fair, although the prognosis which had been made in his case rendered him despondent.

From this time forward the development of the tumors was pretty rapid, new ones being discovered almost daily. Some disappeared wholly, or in part. The general surface of the skin grew darker, and the face resembled the appearance seen in Addison's disease. In December, 1874, when coming under the care of Dr. Bulkley, the following condition was noted by him: The whole surface, from head to foot, is more or less covered with a development of sub-cutaneous tumors of various sizes and shapes, varying from that of a very small split pea, to an inch and even two inches in diameter. Most of the masses are circular, but some are oval, and occasionally a long one is observed, as on the right forearm, where there is one two inches long by three-quarters of an inch wide. Some of the lumps appear to be made up of several tumors closely set together. Most of the tumors are distinctly raised above the skin to various heights, some being round on top, others quite flat; even those of an inch or more in transverse diameter may be elevated only a quarter of an inch or so above the level, and be quite flat on top. These appear to be such as have reached their height of development, and are undergoing absorption. All of the tumors are decidedly hard and firm to the feel. Some of them are colored, of various shades, from a greenish brown to a deep

## SARCOMA PIGMENTOSUM.

blue-black, but most of the tumors externally appear of the color of the skin. Over these latter the skin is quite freely movable, but over those of a dark color, which are really those undergoing atrophy and flattening, the skin is thick, hard, and united with the tumor. It is impossible to give the exact number of the separate masses, so many smaller ones are deeply imbedded beneath the skin, and can be found only by palpation. When stripped, the body appeared to be very thickly sprinkled with them. Last week his brother counted one hundred and fifty by the eye. As previously remarked, some of the tumors are now disappearing. After having attained a certain size, or rather height, as apparently sub-cutaneous tumors covered with skin of a normal color, they become first of a purplish color, which deepens until of a deep black. While this is going on the tumors seem to flatten, then absorption appears to take place, the surface sinking and the color fading somewhat, until now some of the older ones on the chest and abdomen are seen only as flat discolorations, presenting a hue much like that of a nitrate of silver stain. The patient states that all of those tumors which have undergone this change have previously bled spontaneously, or from friction of the clothing. Some of the lumps showed signs of recent hemorrhage.

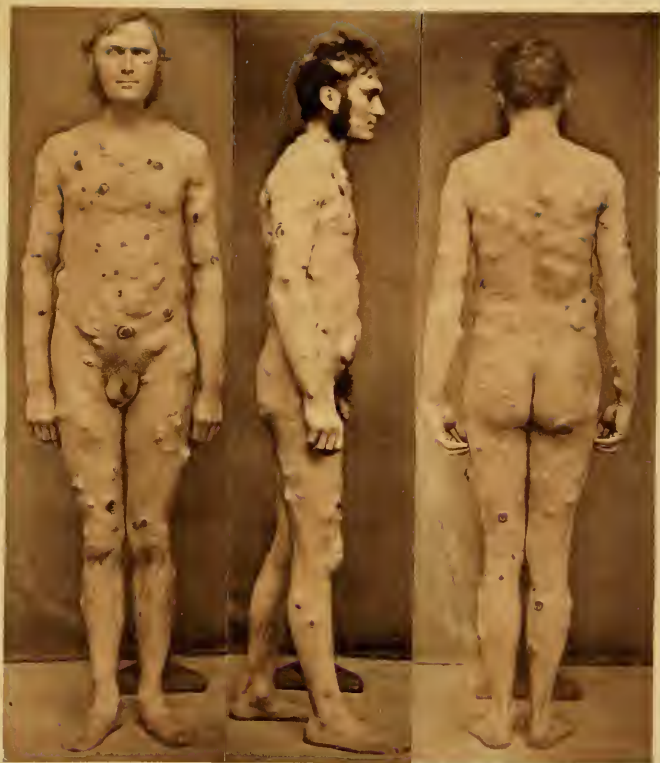A very curious condition develops in connection with some of the tumors, notably in those upon the chest and abdomen. During the process of absorption, when the mass has flattened considerably, there appears a ring or collar around the tumor, which is very distinctly marked in a number of places at the present time. This ring is about a quarter of an inch in width, and, in some instances, hard and slightly elevated, and of a bluish-black color. In other places the ring appears simply as a colored band, not elevated, around the central pigmented spot, separated from it by a very narrow portion of healthy skin. In some instances this ring is seen around tumors over which the integument is slightly, if at all colored. The patient asserts that this circle is always formed around a tumor which has become discolored, and also that those which become discolored on the surface always bleed at some time.

The subsequent history of the case can be told in a few words. The patient rapidly lost in strength and flesh, and the tumors continued to develop anew, and also to undergo the processes of absorption and disappearance before described, only the total mass of cutaneous tumors was steadily on the increase. Tumors reappeared in the site of those excised.

In six weeks he was in a greatly depressed state. Swelling of the legs had appeared. These were bandaged, but on account of his weakness he entered Roosevelt Hospital.

He remained in the hospital about three weeks, and died there on May 16. During this period the urine was acid, specific gravity 1.018, was dark colored and contained a trace of albumen. He failed rapidly, becoming more and more bronzed, until, at the time of death, the general melanic state of the skin was very striking.

Autopsy by Dr. Delafield, May 17, 1875. The entire skin is of a dark color. On the surface of the body, just beneath and in the skin, are seen a great number of tumors, from the size of a pea to that of a hen's egg; many of them of a dark purplish-black color. The dura mater is grayish, and on its inner surface coated with a thin layer of fibrin. The pia mater is normal, except for one small pigment nodule. The substance of the brain is not pigmented, and appears normal. On the right eye, in the sclerotic, close to the outer edge of the cornea, is a small black nodule, the size of half a grape seed. The lungs are not pigmented; the left lower lobe is œdematous, and partly hepatized. The pericardium is distended with clear serum; heart normal. The peritoneal cavity contains purulent serum. The liver and spleen are pigmented, and black nodules are found in the liver. The cervical bronchial, and mesenteric glands are all large and black.



SARCOMA CUTANEOUM





