

XXVII. *On the MEGATHERIUM (Megatherium Americanum, CUVIER and BLUMENBACH).*Part III.—*The Skull. By Professor OWEN, F.R.S. &c.*

Received November 8, 1850—Read May 8, 1851.

THE vertebral segments which coalesce more or less completely to form the important and characteristic part of the skeleton called the 'skull,' constitute, in the Megatherium, one which is remarkable for its small relative size to the rest of the body, for the slight diminution of the transverse diameter from the occiput forward to the nasal bones, for the length and strength of the ascending and descending processes from the orbital end of the zygomatic arch, and for the peculiar depth of the lower jaw, especially at its middle part, where it lodges the molar teeth.

The widest part of the long and narrow cranium is formed by the zygomatic arches, Plate XXII. fig. 2, ²⁶, ²⁷, and the deepest part by the dentigerous portion of the lower jaw, Plate XXI. fig. 2, *d*.

In the skulls and portions of skulls of the Megatherium which have come under my observation, all the cranial and most of the facial sutures, save those that unite the tympanic to the rest of the temporal bone, had been obliterated, and the originally complex assemblage of bones forming the cranium and upper jaw had been reduced to a continuous whole.

Viewed from behind (Plate XXIII. ¹), the skull shows the unusual degree to which the pterygoid, ²⁴, palatine, and maxillary portions descend below the level of the true 'basis cranii' (¹): in consequence of which the foramen magnum (*o*) and occipital condyles (²) appear to be situated in the upper half of the direct back view.

The basioccipital (¹) is a broad depressed plate with a thin, smoothly rounded, concave posterior border: it slightly increases in thickness as it advances forward to blend with the basisphenoid (Plate XXIV. ⁵), but develops on each side a rough low triangular protuberance, ^z, for muscular attachments, anterior to the occipital condyles. In a side view (Plate XXI. fig. 1), these condyles (²) form the most prominent parts of the occipital region, which, as it rises above them, slopes forward, giving a low character of intelligence to the cranium: the plane of the posterior surface of the skull forms with the basal plane an angle of 105°. Each condyle (Plate XXIII. fig. 1, ², ²) is a convexity of a subtriangular form, with the base straight and the sides curving to an obtuse apex: the extent of their convex curvature in the vertical or antero-posterior direction (Plate XXI. fig. 1, ²) equals that of a semicircle, and indicates that the Megatherium possessed considerable freedom and extent of motion of the head. The parallel bases of the condyles are turned toward each other and flank the sides of the foramen magnum, Plate XXIII. fig. 1, *o*. This

foramen is a wide or full ellipse with the longer axis transverse, and the plane, through the greater prominence of the upper border, inclined backward and downward at an angle of 135° with the basioccipital. The occipital region (*ib.* 1, 3, 8, 8) is semicircular, its contour being formed by a thick rugged ridge continued from the superoccipital (3) on each side to the mastoid, 8: the osseous wall included between this arched ridge and the condyles (2), is divided into four shallow depressions, by a sharp median vertical ridge terminating below at a venous foramen just above the upper border of the foramen magnum, and by a pair of thick obtuse ridges (*r*) extending from the sides of the arched ridge obliquely inwards to near the apices of the occipital condyles, and thence to the paroccipitals (4). The depressions so defined are roughened by muscular implantations.

The paroccipital (Plate XXIII. fig. 1, 4) is a moderately developed triangular tuberosity abutting against the back part of the articular cavity for the stylohyal (Plate XXIV. 16), and separated by the outer occipital depression from the mastoid (8). The precondyloid canals (Plate XXIV. *p*), or those that transmit the motory-lingual or ninth pair of nerves, begin by a large oblique aperture at the middle of the inner side of the base of the condyles, and extend along a course of $2\frac{1}{2}$ inches in extent forward and outward to open upon the back part of the rough fossa between the paroccipital (4) and petrosal (16) externally, and the basioccipital and basisphenoid internally, which fossa answers to the 'foramen lacerum in basi cranii' of ordinary mammals. The carotid foramina (*c*) open upon the fore-part of this fossa. The external precondyloid foramina (*p, p*) are situated on the inner side of the paroccipitals, are each an inch in diameter, and thus indicate the considerable muscular development of the tongue, and its great use in stripping off the leaves and smaller branches of the trees affording the nourishment of the Megatherium.

The basisphenoid (Plate XXIV. 5) presents on each of its hinder angles a low rugged subcircular protuberance (*x*) for muscular insertions; in advance of which it slightly expands, the lateral margins inclining downwards so as to form the beginning of the smooth channel that contracts and deepens as it advances towards the posterior aperture of the bony nostrils. The broad subvertical pterygoid plates (24) are continued insensibly from the deflected margins of the basisphenoid; they are smooth on the inside, irregularly channelled for muscular attachments on the outside. The posterior aperture of the bony nasal canal (Plate XXIII. fig. 1, *n*) is a long and narrow vertical oval, bounded below by a low transverse ridge (Plate XXIV. *r*), which extends from the hinder border of the bony palate about two inches backwards upon the smooth surface of the pterygoid plates, where it gradually subsides: this ridge forms the angular termination of the bony palate (*ib.* 20) behind. The substance of the basisphenoid is excavated by air-sinuses, continued backward from the ordinary position of the sphenoidal sinuses, and extending into the basioccipital as far back as the jugular foramina, *j*. They are exposed by fracture of the walls in the protuberances marked *x, x*, in Plate XXIV.

From the state of the sutures already alluded to, the limits of the superoccipital, parietal, and frontal bones cannot be defined. Above the arched superoccipital ridge (Plate XXII. fig. 2, *s*) there are two semielliptical rough depressions (*a, a*) for muscular attachments; and, in advance of these, the upper surface of the cranium shows two other similar but shallower muscular impressions, *b, b*. The smooth surface of the parietal, gradually narrowed to an inch in width (*r*) between the temporal ridges (*t*), again as gradually expands into the frontal region (*u*), and it is perforated, a little anterior to the middle of the temporal fossa, by a submedian vascular (venous?) foramen (*v*), about half an inch in diameter. The temporal fossæ (Plates XXI. & XXII. *27, t, 12*) are remarkable for their great antero-posterior extent, and for the encroachment upon them by the peculiar process (*c*) sent upward and backward from the malar bone, *26*. They are partially defined anteriorly by the extension of a postorbital process (Plate XXI. fig. 1, *12*, Plate XXII. fig. 2, *12*) downward to the malar bone (*26*); but, beneath and within this slender process, they communicate freely with the orbits, *o*. The posterior boundary ridge, continued from that on the parietal bone, curves forward below and is continued into the sharp upper border of the zygoma, Plate XXI. fig. 1, *27*. The surface of the temporal fossæ is grooved and perforated posteriorly by large vessels, and is everywhere strongly impressed by the attachments of muscular fasciculi. The base of the zygomatic process of the temporal bone has an extensive origin (Plate XXII. fig. 2, *t, 27*), not less than 6 inches in antero-posterior extent; its free portion, to where it joins the malar, being 3 inches in length. It is a strong trihedral bar of bone, rather concave on the upper and outer sides, and forming on the underside the glenoid articular cavity for the lower jaw. This cavity (Plate XXIV. *g*), of an oval form with the long axis transverse, measures 3 inches by $2\frac{2}{3}$ inches, and is half an inch in depth. Behind this cavity the base of the zygoma (Plate XXI. fig. 1, *27*) has coalesced with the mastoid (*s*) and petrosal (*16*) elements of the temporal, which combine to form the meatus auditorius externus, *e*. This canal is subcircular, about 10 lines in diameter at the deeper part, where it is formed by the above elements, but doubtless wider at its outer part, where it was completed by the tympanic bone. This bone is wanting in the skulls of the Megatherium hitherto transmitted to England: the absence of any fractured surface upon the contour of the orifice of the auditory canal indicates, however, that the bone was a free element of the temporal in the Megatherium as in the *Myiodon** and *Glossotherium*†. The mastoid (Plate XXII. fig. 1, *s*) forms a rugged process, in depth or length not exceeding the paroccipital (*4*), but of greater breadth and thickness; above it, externally, and probably in the line of the primitive suture with the squamosal, is a venous foramen, Plate XXI. fig. 1, *27*. The petromastoid—probably the petrosal part in a greater degree—forms the hemispheric articular cavity (Plate XXIV. *16*) for the stylohyal (*38*), the anterior rugged wall of which cavity extends downwards farther than any

* Description of the Skeleton of an Extinct Gigantic Sloth (*Myiodon robustus*, OWEN), 4to, 1842, p. 28.

† Zoology of the Voyage of the Beagle, 'Fossil Mammalia,' 4to, 1840, p. 59. pl. 16. fig. 4.

other part of the proper basis cranii, Plate XXI. fig. 1, ¹⁶: the petrosal, anterior to this, sends down a shorter rough pyramidal process. The carotid foramen (Plate XXIV. c), a full ellipse with diameters of 5 lines and 4 lines, is situated between the petrosal and basisphenoid at the fore-part of that oblong depression which is terminated behind by the large precondyloid foramen.

The stylohyal (³⁸) has the form of a hammer, with a long, slightly bent handle, terminated by an obliquely truncated rough surface for syndesmosis with the ceratohyal. At the opposite end the handle is subcompressed, and the head is formed by a sudden expansion in the vertical direction, terminated posteriorly by a straight but rugged margin, and with the upper end produced, thickened, and forming a smooth convexity, or condyle, adapted to the cavity above described in the petromastoid. The lower end of the head or expanded part of the hammer-shaped bone is more produced, more rugged, and terminates obtusely. The outer surface has a wide depression at the middle, which is rough, with several short and well-marked ridges. The length of the specimen described is 8 inches, the breadth or depth of the expanded end is 3 inches and a half.

The upper part of the coalesced frontals (Plate XXII. fig. 2, ¹¹) forms a smooth triangular plate, rapidly expanding to the postorbital processes (¹²) and very slightly convex. Some indistinct traces of the fronto-nasal suture seem to show that the nasal bones (Plate XXII. fig. 2, ¹⁵) extended backward beyond the transverse parallel of the postorbital processes: more distinct traces of the naso-maxillary sutures (²¹), show that the coalesced nasals were 2 inches 9 lines across at their narrow posterior part, where they are flat above: at first slightly contracting, they then gradually expand, and become more and more convex transversely to their anterior extremity. Here the nasal bones are also thickened, are rugged for the firmer attachment of the cartilaginous parts of the nose, and their under surface, being excavated by two longitudinal grooves, the thickened terminal surface is divided into a middle (Plate XXIII. fig. 2, *m*) and two lateral (*n, n*) parts, the latter being convex and subangular, and the middle expansion slightly excavated. As in the Two-toed Sloth (*Choloepus didactylus*), the under surface of each nasal bone sends off a terminal plate or process for the attachment of a turbinal cartilage or ossicle. A narrow median groove indicates the original suture between the nasal bones along their anterior half.

The cranial cavity of the Megatherium is considerably smaller than the cranial part of the skull, the outer wall or plate of bone being separated by large irregular air-cells from the vitreous plate, or that case of bone which immediately invested the brain and its membranes. The vertical diameter of the cranial cavity is 4 inches 8 lines; its transverse diameter, which is greatest at the posterior third part of the cavity, corresponding with the posterior part of the cerebrum, is 6 inches. The brain of the Megatherium, to judge from its bony case, must have been less, by nearly one half, than that of the Elephant; but with the cerebellum relatively larger and situated more posteriorly to the cerebral hemispheres: whence it may be inferred

that the Megatherium was a beast of less intelligence, and with the command of fewer resources, or less varied instincts, than the Elephant.

The 'maxilla superior,' or maxillary bone, may be divided into a palatal, alveolar, and facial portion: the latter (Plate XXI. fig. 1, *21*) is remarkable for the excess of its vertical over its antero-posterior extent: it forms, with the coalesced lacrymal (*l*), the anterior and part of the inferior boundary of the orbit by a strong sub-vertical outstanding plate, curved with the convexity forward, perforated at the middle part of its base by the antorbital canal (*r*), which is double on the left side, and near the upper part of its thick obtuse margin by the lacrymal canal (*l*): it is smooth behind, or next the orbit, rather rough and irregular in front: a rough, shallow depression (Plate XXIII. fig. 2, *s*) near the upper part of this surface indicates the origin of a strong labial muscle. The outer surface of the facial plate of the maxillary is smooth and slightly undulated; it evidently extends as far as the postorbital process upwards and backwards, in connexion with the nasal bone: its anterior border (Plate XXI. fig. 1, *n*), terminating the side of the nostril, is vertical, slightly concave and sharp, and is smoothly excavated on the inner side or towards the nasal cavity. The lower part of this nasal wall presents a deep and rough sutural notch for articulation with the premaxillary bone.

The alveolar part of the maxillary (Plate XXIV. *i, v*) extends about an inch below the suborbital process. The extent of the alveolar tract is 10 inches; its greatest breadth is 2 inches 4 lines, viz. between the second and third teeth. The number of alveoli is five. The first (*i*) has a subtriangular transverse section, with the apex very obtusely rounded off and turned forward; the borders of this alveolus are sharp and somewhat produced below the level of the surrounding bone. The second alveolus (*ii*) is close to the first, and the corresponding teeth are nearly in contact; its transverse section is quadrate, the hinder side being the broadest, the outer side the narrowest; the fore-side is more curved than the back one. The partition between this and the third alveolus is thicker than the preceding one, and the teeth stand further apart. The third and fourth sockets are most nearly of a square form, but the transverse diameter predominates; the fifth socket (*v*) is suddenly reduced in size, and resembles most the first in form, but with the rounded apex of the triangle turned backwards.

No trace of the suture between the maxillary (*21*) and palatine (*20*) bones remains: the alveolar border beyond the fifth socket (*v*) rapidly contracts to the thin vertical pterygoid plate (*24*).

The bony palate terminates behind in an angular notch, formed by the ridges (*r, r*) before described. The bony palate forms a narrow tract, with parallel lateral borders gently diverging at the fore and back part of the tract, which is very slightly concave transversely: it is perforated by numerous foramina; two long ones, like fissures (Plate XXIV. *v, v*), opposite the interspace between the third and fourth molars, seem to represent the post-palatal foramina; there are, also, some large foramina (*u, u*)

between the first alveoli. The extent of the palatal part of the maxillary in advance of these alveoli is about 1 inch to the hindmost part of the premaxillary, ²², and $2\frac{1}{2}$ inches to the apex of the process ⁽²¹⁾ articulating with that bone.

The premaxillaries (Plates XXIV., XXI. fig. 1, and XXII. figs. 1 & 2, ²²) have coalesced along the major part of their extent, leaving only a median fissure on their upper surface (Plate XXII. fig. 2, ²²), of about $1\frac{1}{2}$ inch in length, at about the same distance from their slightly expanded anterior ends; at their under surface (Plate XXIV.) the same fissure is more advanced, and contracts to a few foramina. They form a slender, elongated, subdepressed, four-sided portion of bone, and constitute a singular anterior termination of the skull.

At the base or back part this portion of bone measures $4\frac{1}{2}$ inches across; the fore-end is 2 inches 9 lines across; the narrowest part, near this end, is 2 inches 4 lines across; the vertical diameter is pretty nearly throughout 1 inch 6 lines, but decreases anteriorly. The posterior third of the bone sends upward from its median line a ridge, which enlarges as it approaches the corresponding ridge from the maxillaries, and there presents a smooth and gradually expanding groove at its upper part, for the support of the vomer or its cartilaginous septal prolongation (Plate XXIII. fig. 2). Anterior to the median ridge begins the groove which sinks into the fissure, and is then again continued forward as a groove to within an inch of the fore-end of the bone: this part (Plate XXIV. ²²) seems crossed by a rough plate or cap of bone, flat, and about an inch in breadth at its upper part, and there terminating behind, as it does below, in a free margin.

The under surface of the premaxillary mass (Plate XXIV. ²²) is rather convex antero-posteriorly, as also transversely along its middle third: the groove indicating the primitive suture runs along the whole of this surface, and sinking into its fore-part, opens by two or three foramina into the fissure which is seen on the upper surface. The back part of the under surface of each premaxillary is notched to receive a triangular process of the palatine part of the maxillary ⁽²¹⁾: the more slender median parts of the notches partly divide the prepalatal or incisive fissure (*s*), which thus presents the form of a chevron.

The malar (Plate XXI. fig. 1, ²⁶) is a singularly developed mass of bone, and has always attracted attention as one of the most remarkable features of the skull, from the period of the earliest notices of the Megatherium. Its bulk and complex shape appear to relate to the unusual share which a modified and largely developed masseter muscle must have taken in the act of mastication.

Firmly articulated by extensive reciprocally indented sutures, at one end with the maxillary ⁽³¹⁾, at the other end with the zygomatic bones ⁽²⁷⁾, and giving an extensive surface of attachment, by a peculiar upward prolongation, to fasciculi of the temporal muscle, it afforded the requisite fixity for the origins of the large and complex masseter.

The suture with the maxillary is in great part obliterated in the skull under descrip-

tion; but a portion remaining on both sides shows that the malar ascended to the level of the antorbital foramen, Plate XXIII. fig. 2, *r*: it forms the lower and a great part of the hinder boundary of the orbit; the latter by a triangular, slightly bent postorbital process (Plate XXI. fig. 1, *a*), which almost touches the corresponding more slender process of the frontal (ib. ¹²). The ascending process (ib. *c*) is a long, narrow, unequal-sided triangle with an obtuse apex; the descending process (*d*) is a longer and stronger one, extending, when the mouth is shut, outside and for three inches below the alveolar border of the lower jaw: its extremity is obtuse and recurved. The fourth process (ib. *b*), which may be called the 'zygomatic' one, extends beneath the end of the corresponding process of the temporal bone, but the obliteration of the suture in the present skull prevents a precise definition of its limits. The whole outer surface of the malar is slightly convex, moderately smooth, with a defined surface for muscular attachment near the back part of the base of the descending process. The inner surface shows, by its well-marked ridges and depressions, the vigorous action of the muscular fasciculi which derived their origin from that part.

The orbit (Plate XXI. fig. 1, *o*), of proportionally small size, as in all large mammalian quadrupeds, presents a long vertically oval form; or rather, by the convex border of the malar (*a*), is reniform. Its peripheral contour is almost completed by the descending postorbital process of the frontal (ib. ¹²) in the present skull; anterior to which the prominent boundary is effaced by a broad smooth channel, where the orbital surface is more directly continued upon the facial surface of the maxillary: this part answers to the supraciliary notch in quadrupeds. The lacrymal bone being completely coalescent, if not connate, with the maxillary, is recognisable only by the lacrymal foramen (ib. *l*), which is just within or behind the obtuse anterior border of the orbit. Admitting the essential presence of the lacrymal by this character, it then combines with the frontal, maxillary and malar bones, to form the contour of the orbit. Within this frame, the orbit, as already remarked, communicates extensively with the temporal fossa.

The anterior aperture of the bony nasal canal (Plate XXIII. fig. 2, *m, n, 22*) is sub-circular, and is formed by the nasals, maxillaries and premaxillaries; the deep vertical sides being contributed wholly by the maxillaries.

The formation of the external bony aperture of the organ of hearing has already been described.

Mandible.—The chief characteristic of the mandible or lower jaw is the near equality of its vertical to its horizontal or longitudinal extent, due to the height of the coronoid process, and more especially to the depth of the dentigerous part of the bone. The latter dimension relates to the interesting modification of the principle of maintenance of the efficiency of the masticating machinery, as contrasted with that in the great proboscidian quadrupeds with a similar diet to the Megatherium.

The condyle of the jaw (Plate XXV. fig. 1, *a*) is transversely elliptical, 3 inches in

the long, 1 inch 10 lines in the short, diameter: it is moderately convex, and least so from behind forwards: it seems but a small surface for the articulation of so massive a bone, laden with large teeth, to the cranium; but the adequate firmness of suspension was afforded by the enormous muscles which seem to have embraced every other part of the ascending ramus of the mandible. The coronoid process (Plates XXI. and XXV. fig. 2, *b*) was lofty compared with its antero-posterior diameter: it is mutilated in the present skull, but seems to be entire in that of the skeleton at Madrid; and its form and extent may be appreciated in the figures published by BRU* and PANDER†. It is much compressed, begins to curve upward immediately anterior to the neck of the condyle, being continued from the middle of that part. The angular process (*ib. c*) of the lower jaw curves backward $4\frac{1}{2}$ inches below the condyle: it is a broad triangular plate, moderately convex externally, concave internally and chiefly by a slight inward bending of the lower margin, Plate XXV. fig. 2, *c*. A few ridges on the comparatively smooth outer surface indicate the insertions of muscles; but the inner surface is strongly sculptured by pits and grooves with strong intervening bony crests. The oblique beginning of the dentary canal (*e*) is situated 6 inches below the condyle, and the foramen is 2 inches from the last alveolus, but above its level. The anterior border of the base of the coronoid process is below the interspace between the fourth and fifth alveolus; on its inner side is a large elliptical outlet of a division of the dentary canal, Plate XXI. fig. 2, *f*. The outer and inner surfaces of the coronoid process present characters analogous to those on the same surfaces of the angular process, in regard to muscular traces, but the concavity is on the outer side of the coronoid.

The contour line, which is usually continued forward, straight, or with a gentle curve or undulation in ordinary quadrupeds, is interrupted in the Megatherium about one foot from the apex of the angular process by a notch, from which the contour line describes an abrupt deep convex curve below the molar teeth, and then as suddenly rises and passes by a concave curve to the under side of the long and slender symphysis, *d, d*. The depth of the dentigerous part of the horizontal ramus is 9 inches 6 lines; it is slightly convex externally, and forms a flat deep vertical wall internally, Plate XXV. fig. 2, *d, iii*.

The antero-posterior extent of the alveolar border is 9 inches (Plate XXV. fig. 1). The first socket is irregularly four-sided, the front side being the shortest, slightly convex, and with the angles rounded off between it and the outer and inner sides: the outer side forms rather an acute angle with the hinder side. The area of the second socket is more regularly quadrate, with the transverse diameter the longest; that of the third socket is nearly a true square; the fourth and last is similar to, but

* GARRIGA, J. Descripción del esqueleto de un cuadrupedo muy corpulento y raro, &c. fol. Madrid, 1796, tab. i. and ii.

† Das Riesen-Faultier (*Bradypus giganteus*), fol. trans., Bonn, 1821, tab. iii. See also CUVIER, 'Ossemens Fossiles,' 4to, tom. v. part 1. pl. 16. figs. 1 and 2.

smaller than, the first, with the shortest and most curved side at the back part, and with the antero-posterior diameter a little exceeding the transverse one. The intervals between the alveoli are narrow and subequal.

The rami of the jaw are blended together at the symphysis, which is of great extent, Plate XXI. fig. 2, Plate XXV. fig. 1, *d, d*: it begins posteriorly at the fore-part of the mandibular convexity, opposite the second alveolus, whence the symphysis rapidly contracts to the shape of a scoop or spout, which is prolonged $8\frac{1}{2}$ inches from the alveolar part, and terminates in a thick, rough, rounded and emarginate extremity: the canal at the upper part of this spout-like symphysis is semicylindrical, slightly bent down at the end, and 3 inches in diameter; it becomes roughened by numerous small vascular impressions near the end, but elsewhere is smooth, and has obviously served for the support, during acts of protrusion and retraction, of a long cylindrical tongue. The margins of the canal are thick and rounded. The 'mental foramina,' or anterior outlets of the dental canal (Plate XXV. *g*), are two on the right side and three on the left, from 4 lines to 8 lines in diameter.

The teeth are of one kind, molars, five on each side of the upper jaw (Plate XXIV. and Plate XXVI. fig. 2, *i, ii, iii, iv, v*), four on each side of the lower jaw (Plate XXV. fig. 1, Plate XXI. fig. 2, *i, ii, iii, iv*), eighteen in total number.

In the upper jaw, the first or anterior molar (*i*) is the second in point of size, the last (*v*) being the least. The first molar (Plate XXVI. fig. 2, *i*) is $8\frac{1}{2}$ inches in length; the pulp-cavity extends six inches from the base; it presents two slight curvatures, one having the convexity turned forward, and the other inward. The transverse section (Plate XXIV. *i*) gives an irregular semicircle, with the convexity turned forward, and the flat side next the second tooth; the angles at which this side joins the curve are rounded; the outer angle is somewhat produced, and the outer side of the curve is flattened. The central axis of the tooth, formed by the vaso-dentine*, is irregularly tetragonal; the cement is thick on the anterior and posterior surfaces, thin on the sides of the tooth.

The second molar (Plate XXIV., Plate XXVI. fig. 1 & fig. 2, *ii*) is the largest of the upper series; it exceeds 9 inches in length, is of a tetragonal form, with two slight curvatures, as in the first molar. The posterior and broadest side is nearly flat, the anterior side somewhat convex, the outer and narrowest side is concave, the inner side is sinuous, having a median longitudinal eminence between two longitudinal concavities. The central axis of vaso-dentine (Plate XXVI. fig. 2, *v*) is more compressed from before backwards than in the preceding tooth, and its posterior surface is concave; the two transverse ridges of the grinding surface of the tooth formed by the dentine (ib. *d, d*) are nearly equal; but the sloping side formed by the vaso-dentine is larger than that formed by the cement (ib. *c*).

The third tooth (Plate XXIV. *iii*, Plate XXVI. fig. 2, *iii*) is of nearly the same size

* See 'Odontography,' and Art. TEETH in 'Cyclopædia of Anatomy,' vol. iv. for the definition of the different dental tissues.

and form as the second, but is somewhat narrower; the anterior and outer angle is less rounded off, and the external longitudinal depression is deeper: it is further removed from the second tooth than this is from the first.

The fourth molar (Plate XXIV. *iv*, Plate XXVI. fig. 2, *iv*) is smaller than the two preceding, but of nearly equal length, viz. $8\frac{1}{2}$ inches, and is distinguished from the other teeth by being curved in only one direction, and that in a very slight degree, the concavity looking, as in the other teeth, outward: the central axis of the tooth, in reference to the anterior and posterior planes of the skull, is straight: the anterior and posterior layers of cement decrease in thickness as they approach the base of the tooth, so as to describe a slight curve, the convexity of which is turned, on both sides, towards the adjoining tooth. The fourth molar is tetragonal, and with more equal sides than the two preceding teeth; the outer and inner sides are concave, the anterior and posterior ones convex; the angles are rounded, but the anterior and inner angle is more produced than the rest. The grinding surface presents two equal transverse ridges, the contiguous sides of which are the longest.

The fifth molar (Plate XXIII. fig. 1, Plate XXIV. *v*, Plate XXVI. fig. 2, *s*) is 5 inches in length, 1 inch 2 lines in transverse, and $10\frac{1}{2}$ lines in antero-posterior diameter: its principal curvature presents its concavity forward, or toward that of the anterior tooth; the curve in the transverse axis of the skull is scarcely appreciable. The transverse section of this tooth is rhomboidal, with the angles rounded, and with the longest diameter intersecting the antero-internal and the postero-external angles. The dentinal axis is transversely quadrilateral, with the posterior angles entire, and the posterior surface concave: the layer of cement which covers this surface is the thickest, and its posterior surface is convex: the layers which cover the outer and inner sides of the tooth are, as in the rest, the thinnest; the anterior layer is less than one-third the thickness of the posterior layer. The anterior ridge of dentine is slightly prominent, and the posterior alone forms the summit of a transverse eminence with sloping sides, but these diverge at a more open angle than in the preceding teeth.

At the date of the publication of my 'Odontography,' no specimen of the lower jaw of the Megatherium had reached England, and certain detached teeth with slight differences from those known to belong to the upper jaw were conjecturally referred to the lower one*. The entire bone, with the dental series complete (Plate XXV., Plate XXI. fig. 2, *i*, *ii*, *iii*, *iv*), shows that three of those teeth were rightly so referred; but that the small molar alluded to at p. 342, *op. cit.*, does not belong to the lower jaw, which has only four teeth in each ramus.

The first molar (Plate XXV. and XXI. fig. 2, *i*) is 8 inches in length, with a pulp-cavity of 5 inches in depth; it presents a curve, with the convexity forwards, which is more marked than in any of the upper molars. The anterior surface is so much less convex transversely than in the first upper molar, that the transverse sec-

* Odontography, p. 341.

tion presents a tetragonal rather than a semicylindrical figure; the anterior side, however, being only three-fourths the breadth of the posterior one, by which the first lower molar may be distinguished from all the tetragonal teeth of the upper jaw. Both the inner and outer sides are slightly concave transversely, the posterior side is moderately convex. The posterior ridge has a base twice as thick as the shorter anterior ridge. The greatest transverse breadth of the crown is 2 inches, the greatest fore and aft breadth is 1 inch 7 lines.

The second molar (Plates XXV. and XXI. fig. 2, *ii*) is the largest, at least the broadest transversely, of those of the lower jaw. It is 9 inches in length, with a minor curvature, convex forward. The anterior side is the broadest, being more extended inward than the posterior side: its transverse diameter is 2 inches 3 lines, the fore and aft diameter of the crown is 1 inch 10 lines: the base of the hinder eminence in the latter diameter exceeds that of the front eminence chiefly by the greater extent of dentine exposed.

The third molar (Plates XXV. and XXI. fig. 2, *iii*) is of the same length as the second, but has its two diameters more nearly equal, the transverse section being nearly square, the anterior division being rather the broadest transversely, and of equal thickness from before backwards. Both this and the preceding tooth are convex transversely before and behind, concave at the sides.

The last lower molar (Plates XXV. and XXI. fig. 2, *iv*), with an equal antero-posterior diameter to the preceding, is shorter and narrower transversely, especially in regard to its posterior division, which is more rounded, or convex transversely, behind, than in any of the antecedent teeth. The hinder slope of the hinder ridge is more nearly horizontal, and those towards the middle of the tooth are less deep: the modification of the grinding surface of this tooth relating to the flatter surface of the fifth molar above, and its greater antero-posterior extent as compared with its breadth compensating for the absence of a fifth molar in the lower jaw. The grinding surface of the four lower molars equals that included between the anterior ridge of the first molar and the posterior ridge of the last molar in the upper jaw.

Each molar has its base undivided, but excavated by a deep conical pulp-cavity (Plate XXVI. fig. 2, *p, p*), from the apex of which cavity a fissure is continued to the middle of the grinding surface of the tooth, where it is more conspicuous in the upper (Plate XXIV.) than in the lower molars. Plate XXVI. fig. 2, exhibits a longitudinal section of the five molars of the upper jaw, *in situ*. The central axis of vaso-dentine (*v*) is surrounded by a thin layer of true or hard dentine (*d*), and this is coated by cement (*c, c*), which is of great thickness on the fore and hind surfaces, but is thin where it covers the outer and inner sides of the tooth.

As the outer layer of the vaso-dentine is first formed by the centripetal calcification of the pulp, the thin crust of that substance at the open base of the tooth includes a space equal to the vaso-dentine at the crown of the tooth: the contraction of the base of the tooth is due to the progressively-diminishing thickness of the cement as

it approaches that part; the intervening vacancy (*m, m*) in the socket indicating the primitive thickness of the vascular capsule, by the ossification of which the cement is formed.

The vaso-dentine (Plate XXVI. fig. 3, *v*) is traversed throughout by medullary canals, $\frac{1}{500}$ th of an inch in diameter, which are continued from the pulp-cavity and proceed, at an angle of 50° to the plane of the hard dentine, parallel to each other, with a slightly undulating course, having regular interspaces, equal to one diameter and a half of their own area, generally anastomosing in pairs by a loop (*ib. l, l*), the convexity of which is turned toward the origin of the tubes of the hard dentine, forming a continuous reflected canal.

The loops are situated near, and for the most part close, to the hard dentine. In a few places one of the medullary canals may be observed to extend across the hard dentine, and to anastomose with a corresponding canal in the cement. The interspaces of the medullary canals of the vaso-dentine are principally occupied by dentinal tubes, which have an irregular course, form reticulate anastomoses, and terminate in very minute cells, at least one hundred times smaller than the calcigerous radiated cells of the cement.

The more regular and parallel tubes, which traverse the thin layer of unvascular dentine (*ib. d*), are given off from the convexity of the terminal loops of the medullary canals. The course of these tubes is more directly transverse to the axis of the tooth than is that of the medullary canals from which they are continued. They run parallel with each other, but with fine undulations throughout their course. They have a diameter of $\frac{1}{10,000}$ th of an inch, and have interspaces of about twice that diameter. As the dentinal tubes approach the cement they divide and subdivide, and become more wavy and irregular; their terminal branches take on a bent direction and form anastomoses, dilate into small cells, and many are seen to become continuous with the radiating tubes of the cells of the contiguous cement.

The cement (*ib. c*), which enters so largely into the composition of the grinders of the Megatherium, is characterized in that extinct animal by the size, number, and regularity of the vascular or medullary canals (*ib. m, m*) which traverse it. They present the diameter of $\frac{1}{2000}$ th of an inch, and are separated by intervals equal to from four to six of their own diameters. Commencing at the outer surface of the cement, they traverse it in a direction slightly inclined from the transverse axis towards the crown of the tooth, running parallel with each other; they divide a few times dichotomously in their course, and finally anastomose in loops, the convexity of which is directed towards, and in most cases is in close contiguity with, the layer of hard dentine. Fine tubules are sent off, generally at right angles, from the medullary canals, which quickly divide and subdivide, form anastomosing reticulations, and communicate freely with the similar tubules that radiate from the lacunæ or calcigerous cells, *ib. r, r*. These cells are dispersed throughout the dentine, and present an oblong form, with the long axis transverse to that of the tooth, measuring $\frac{1}{2000}$ th

of an inch in diameter. The cavity of the cell, which is not quite occupied by their opaque contents, is often very clearly demonstrated. The tubes, which radiate from the cells nearest the hard dentine, and from the terminal loops of the vascular canals, intercommunicate freely with the tubes of the hard dentine. The tooth of the Megatherium thus offers an unequivocal example of a course of nutriment from the dentine to the cement, and reciprocally.

In the structure which the fossil teeth of the Megatherium and its extinct congeners clearly demonstrate, we have striking evidence of the rich organization of those once-deemed extravascular parts, and that they were pervaded by vital activity. All the constituents of the blood freely circulated through the vascular dentine and the cement, and the vessels of each substance intercommunicated by a few canals continued across the hard or unvascular dentine.

With respect to those minuter tubes, the more important as being more immediately engaged in nutrition, which pervade every part of the tooth, characterizing by their difference of length and course the three constituent substances, they form one continuous and freely intercommunicating system of strengthening and reparative vessels, by which the plasma of the blood was distributed throughout the entire tooth for its nutrition and maintenance in a healthy state*.

The grinding surface of the molars of the Megatherium differs, on account of the greater thickness of the cement on their anterior and posterior surfaces, from those of all the smaller Megatherioids, in presenting two transverse ridges; one of the sloping sides of each ridge being formed by the cement, the other by the vascular dentine; whilst the unvascular dentine, as the hardest constituent, forms the summit of the ridge, like the plate of enamel between the dentine and cement in the Elephant's grinder. The great length of the teeth and concomitant depth of the jaws, the close-set series of the teeth, and the narrow palate, are also strong features of resemblance between the Megatherium and Elephant in their dental and maxillary organization. In both these gigantic phyllophagous quadrupeds provision has likewise been made for the maintenance of the grinding machinery in an effective state; but the fertility of the Creative resources is well displayed by the different modes in which this provision has been effected: in the Elephant, it is by the formation of new teeth to supply the place of the old when worn out; in the Megatherium, by the constant repair of the teeth in use, to the base of which new matter is added in proportion as the old is worn away from the crown. Thus the extinct Megatherium had

* The first statement of the continuation of filamentary processes of the pulp into the tissue of the growing tooth was published in the 'Comptes Rendus de l'Académie des Sciences,' Paris, 1839, p. 787, and the earliest observation of their continuation into the dentinal tubuli was, I believe, recorded in the following passage:—"I had the tusk and pulp of the great Elephant at the Zoological Gardens longitudinally divided, soon after the death of that animal in the summer of 1847. Although the pulp could be easily detached from the inner surface of the pulp-cavity, it was not without a certain resistance; and when the edges of the co-adapted pulp and tooth were examined by a strong lens, the filamentary processes from the outer surface of the pulp could be seen stretching as they were withdrawn from the dentinal tubes before they broke."—Art. **TEETH**, Cyclopædia of Anatomy, vol. iv. p. 929.

both the same structure and mode of growth and renovation of the molar teeth, as are manifested in the present day by the diminutive Sloths.

Comparison of the Skull and Dentition.

The important affinity indicated by the dentition is confirmed by the characters of the skull. In no other edentate family, save the *Bradypodidæ*, is the cheek-bone so nearly developed to the megatherioid proportions of that bone; in no other does it ascend above the zygoma into the temporal fossa or descend below the level of the molar teeth. The large and complex malar bone is also associated, in the Sloths, with a terminal position of the great anterior and posterior orifices of the cranium, with terminal occipital condyles, and in the Ai (*Bradypus tridactylus*) with a sloping occipital region. The cranial division of the skull is relatively as great in the Sloths as in the Megatherium; and the actual capacity of the cerebral cavity is masked by a similar expansion of the air-cells, which almost everywhere surround that cavity, and raise the outer plate of its bony parietes above the inner one. The occiput presents the same expanded proportions, the same broad depressed basilar plate, and the anterior condyloid foramina are of large relative size. The tympanic is small; it nearly completes a circular frame for the ear-drum, to which function it is limited, and it long remains a separate bone. The detached and, in the skull described, lost tympanics of the Megatherium have been evidently restricted to the same office. The temporal fossa, in the Sloths, is long and large, and communicates freely with the orbit, the outer boundary of which, however, is not completed in any living species of Sloth. The nasals become confluent in old Sloths, and develop turbinal laminæ from their under surface. The premaxillaries are edentulous and without any ascending process. The rami of the lower jaw expand and branch out behind into a coronoid, a condyloid, and a long and deep angular process, and they are ankylosed anteriorly at a broad sloping symphysis. Only in the genus *Bradypus*, amongst known existing quadrupeds, do the alveoli of both jaws correspond in number, simplicity, relative depth and position with those of the Megatherium. The still more important agreement between these existing and extinct *Bruta*, in the peculiar structure of the teeth, yields the crowning proof that it is to the diminutive arboreal Sloths that the gigantic Megatherium and its less bulky though larger extinct congeners have the closest natural affinity.

The chief differences observable in the cranial anatomy of the Sloths, as compared with that of the Megatherium, are the greater relative depth and breadth, and the more convex outline of the coronal aspect of the skull; but this difference would be, doubtless, much less marked in the immature than in the adult Megatherium. The zygomatic process, in the Sloths, is relatively shorter, and does not attain the malar bone; this, therefore, has not the middle process for supporting the zygoma, and is two-pronged, instead of being, as in the Megatherium, four-pronged. The chief characters by which the Megatherium deviates, in its cranial structure, from the bradypodal and approaches to the myrmecophagal type, are the elongation of the slender edentulous

fore-part of the upper jaw, and of the corresponding grooved slender edentulous part of the lower one: but the prolongation of the upper jaw is due to relatively longer premaxillaries than are developed in any of the true Edentata. The zygomatic arches, moreover, are more defective in the Anteaters and Pangolins than in the Sloths; the malar part especially being minute or obsolete. Only in the *Orycterope* and *Armadillos*, amongst the existing *Bruta*, is the zygomatic arch complete, but it is simple, without ascending or descending processes. The great *Glyptodon*, indeed, exemplifies that tendency to community of characters so often presented by extinct species, in an inferior prolongation of the malar bone analogous to that of the Sloths and *Megatherium*. With other existing mammals than those of the Edentate order, it would be lost time to pursue the present comparison with a view to the elucidation of the affinities of the *Megathere*. It needs only to place the skull of this animal by the side of those of the *Elephant*, *Rhinoceros*, *Sivatherium*, *Ox*, *Elk*, *Horse*, *Dugong*, or other vegetable-feeding mammal of corresponding or approximate size, to be struck with the peculiarities of the fossil, and to be convinced that the habits and mode of feeding of the *Megatherium* had been such as are no longer manifested by the larger *Herbivora* of the present day.

It remains then to inquire whether, among the extinct forms of the mammalian class to which was assigned the office of restraining the too luxuriant vegetation of a former world, there be any that, from their cranial or dental characters, may be concluded to have resembled the *Megatherium* in the mode of performing that task.

The skull of the *Myiodon*, while it presents all the essential resemblances to that of the *Megatherium* which have been pointed out in the skull of the Sloth, as, *e. g.* the long cranium, the terminal position of the occipital condyles, and of the occipital and nasal apertures, and the large and complicated malar bones, approximates still more closely to the *Megatherium* in the junction of the malar with the zygomatic process of the temporal, and in the relative depression and flatness of the elongated cranium. But in thus receding from the existing Sloths, the *Myiodon* does not approach any other existing genus, but only another member of its own peculiar extinct family.

The most marked differences in the skulls of the *Myiodon* and *Megatherium* depend on the minor length of the teeth and consequent depth of their sockets in the smaller species, which require a less vertical extent of the maxillary bone in the molar region and of the corresponding part of the lower jaw, the lower border of which is consequently nearly straight in the *Myiodon*, as it is in the existing Sloths. So great a proportional extent of the descending process of the malar bone is consequently not required, and this process is more oblique in direction, and is relatively broader and thinner than in the *Megatherium*. In these differences also the *Myiodon* shows its closer resemblance to the Sloths. The basioccipital is relatively broader, and the occipital condyles are wider apart in the *Myiodon*; the occipital plane is more inclined and the zygomatic process proportionally weaker than in the

Megatherium. The minor depth of the lower jaw and the lighter grinding instruments call for a less extensive origin of the temporal muscles, and accordingly the superior boundaries of their fossæ are separated in the adult *Myiodon* by a wide and smooth parietal tract*, as in the Sloths. The postfrontal process is rudimentary in the *Myiodon*, and the postorbital process of the malar bone is obsolete; the orbit is consequently without any bony boundary behind; the malar, accordingly, has but three processes, and is thus less complicated than in the Megatherium. The interorbital part of the skull is relatively narrower, the maxillary part relatively broader, than in the Megathere. No trace of premaxillaries was present in the skull of the *Myiodon robustus* described by me, and the broad truncated symphysis of the lower jaw indicates that they must have been very small if they existed: the peculiar length of the premaxillaries in the Megatherium, and the corresponding prolongation of the long and narrow symphysis mandibulæ, offer the most conspicuous differences in the conformation of the skull, and proportionally remove that genus from the existing Sloths. The bony palate is absolutely broader in the much smaller skull of the *Myiodon* than in the Megatherium, and it gradually contracts from the first to the fifth molar: it is, *e. g.* 5 inches in breadth between the first molars in the *Myiodon robustus*, and only 2 inches in breadth between the same teeth in the Megatherium.

The opportunity of a comparison of the skull of the *Megalonyx* with that of the Megatherium is yet a desideratum: it would probably demonstrate some intermediate modifications between the latter and the *Myiodon*.

The extinct megatherioid animal of which, after the *Myiodon* and the Megatherium, the most complete cranium has hitherto been obtained, is the *Scelidotherium*†.

In many respects the skull of this animal resembles that of the Megatherium more than does that of the *Myiodon*. The plane of the occiput is rather less inclined from below forward than in the Megatherium, but more resembles that part than in the *Myiodon*: the upper boundaries of the temporal fossæ more nearly approximate than in the *Myiodon*: the bony palate is narrower, and its sides more parallel than in the *Myiodon*; but instead of being concave transversely, as in the Megatherium, it is convex: the alveoli are nearer together than in the *Myiodon*, and the first is not separated by a wider diastema than the rest. The symphysis of the lower jaw is much prolonged, but is less deeply channelled above than in the Megatherium, and is not so distinctly defined by the abrupt increase of depth of the ramus behind it which characterizes the Megatherium; the molar part of the mandible makes, however, a greater convexity below than in the *Myiodon*.

With these marks of approximation to the Megatherium there are, however, the same differences as in the *Myiodon* in regard to the widely open orbit, the more simple, trifurcate, malar bone, the minor depth of the alveolar portions of the jaws, and the straighter outline of the lower border of the mandible. In both the *Myiodon* and

* Memoir on the *Myiodon*, 4to, 1842, pl. 3.

† Fossil Mammalia of the 'Voyage of the Beagle,' p. 73. pls. 20, 21, & 22.

Scelidothere the coronoid process is relatively shorter than in the Megathere, and the foramen near the fore-part of the base of that process is outside and below that base, not on the inside of it as in the Megatherium. The mastoid process is relatively shorter and the stylohyal pit is shallower; the lacrymal bone is more distinct, and the foramen is larger in the Scelidothere than in the Mylodon or Megatherium. In all the essential characters of the lower jaw, as in the number, structure and kind of teeth, the extinct megatherioid quadrupeds more closely resemble each other, and the existing Sloths, than any other known existing or extinct animals.

The number of the teeth, their length, equable breadth and thickness, and absence of fangs, their deeply excavated base, and the unlimited growth resulting from the persistent matrix, together with their composition of cement, dentine and vaso-dentine, without any true enamel, are characters common to the Megatherioids and Sloths. The form of the teeth differs in, and characterizes, each genus. It would seem that the Megalonyx, in the elliptical or subcylindrical shape of such of its teeth as are known, more closely resembled the existing Sloths than do the other Megatherioids. The Unau (*Cholæpus didactylus*) resembles the Mylodon in the distance between the first and the second molars of the upper jaw; but the advanced molar assumes, in that existing Sloth, the form and proportions as well as the position of a canine, and the corresponding tooth of the lower jaw is similarly developed and separated from the other three teeth by a nearly equal interval. In the Ai (*Bradypus tridactylus*) the first molar in both jaws presents nearly the same proportionate size to the rest, as in the Megatherium, and is not separated from them by a wider interval than the rest, as it is in the Unau and Mylodon. In both species of existing Sloth, the last molar of the lower jaw is as simple in form as in the Megatherium: in the Mylodon and Scelidotherium it is larger and more complex in shape, the grinding surface being divided into two lobes by two oblique channels, which traverse longitudinally one the outer the other the inner side of the tooth: these grooves are more shallow in the Scelidothere than in the Mylodon, and the lobes of the tooth are more equal and more compressed. The grinding surface itself, in all the molars of both Mylodon and Scelidothere, resembles that in the Sloths; the two transverse ridges are developed only in the teeth of the Megatherium, which are longer in proportion to their thickness than in the Mylodon, Megalonyx, or Scelidothere. These modifications, with the narrow palate, the close-set series of teeth, their great length, and the concomitant depth of the jaws, are features of resemblance to the maxillary and dental characters of the Elephant; but the fundamental structure of the teeth, not only of the Megatherium, but of all its extinct congeners, is manifested in the present day exclusively by the restricted and diminutive family of the *Bradypodidæ*. I conclude, therefore, the present section of this memoir by repeating the remark which I was led to make in a former memoir*, relative to the existing Sloths:—"These Mammals

* On the *Mylodon robustus*, 4to, p. 45.

present to the zoologist, conversant only with living species, a singular exception in their dental characters to the rest of their class; but there has been a time when this peculiar dentition was manifested under as various modifications as may now be traced in some of the more common dental types in existing orders of Mammalia."

Comparative Table of Dimensions of the Skull of MEGATHERE, MYLONDON, and SCOLIDOTHERE.

| | <i>Megatherium Americanum.</i> | <i>Myllodon robustus.</i> | <i>Scelidotherium leptocephalum.</i> |
|---|------------------------------------|-------------------------------|--|
| | ft. in. lin. | ft. in. lin. | ft. in. lin. |
| CRANIUM. | | | |
| Length from the occipital condyles to the fore-end of the upper jaw | 2 7 0 | 1 6 6 | 1 8 4 |
| Length from the occipital condyles to the fore-part of the malar bone | 1 8 0 | 1 2 0 | 0 11 6 |
| Length from the fore-part of the malar bone to the fore-end of the upper jaw..... | 0 10 6 | 0 5 0 | 0 8 8 |
| Breadth across the widest part of the zygomatic arches..... | 0 6 0 | 0 10 9 | 0 7 0 |
| Least breadth at the interspace of those arches | 0 6 0 | 0 5 4 | 0 3 7 |
| Breadth of the fore-part of the nasal bones..... | 0 4 6 | 0 3 3 | 0 2 8 |
| MANDIBLE. | | | |
| Length | 2 3 0 | 1 3 6 | 1 6 6 |
| Breadth between the hinder ends (angles) of the rami | 0 7 0 | 0 6 3 | 0 4 7 |
| Breadth between the condyles | 0 4 0 | 0 4 2 | 0 1 8 |
| Breadth between the posterior sockets of the teeth | 0 2 3 | 0 2 10 | 0 1 6 |
| Breadth between the anterior sockets of the teeth | 0 1 9 | 0 4 0 | 0 1 8 |
| Breadth across the fore-part of the symphysis..... | 0 4 5 | 0 5 4 | 0 2 5 |
| Depth of ascending ramus from the upper part of the condyle | 1 5 0 | 0 5 7 | 0 5 8 |
| Depth of ascending ramus at the fore-part of the base of the coronoid process | 0 9 0 | 0 3 7 | 0 3 7 |
| Depth of horizontal ramus at the fore-part of the first socket.. | 0 8 0 | 0 3 0 | 0 2 7 |
| Length of the symphysis following the outer curve | 1 1 0 | 0 4 3 | 0 7 3 |
| Fore and aft extent of base of coronoid process | 0 9 0 | 0 3 8 | 0 3 9 |
| From the back part of the condyle to the end of the angular process..... | 0 6 0 | 0 3 2 | 0 3 6 |
| From the end of the angular process to the last socket | 0 9 7 | 0 6 6 | 0 6 5 |
| From the first socket to the anterior margin of the jaw..... | 0 9 0 | 0 3 6 | 0 7 10 |
| Extent of the alveolar series..... | 0 9 0 | 0 5 4 | 0 4 4 |
| Breadth of the condyle..... | 0 3 0 | 0 2 6 | 0 1 10 |

DESCRIPTION OF THE PLATES.

All the figures, save where otherwise expressed, are one-fourth the natural size.

PLATE XXI.

- Fig. 1. Side view of the skull of the Megatherium.
 Fig. 2. Inner side view of the mandible and of the section of the symphysis.

PLATE XXII.

- Fig. 1. The opposite and more mutilated side view of the same skull, showing the surface of the temporal fossa.
 Fig. 2. Upper view of the same skull.

PLATE XXIII.

- Fig. 1. Back view of the same skull.
 Fig. 2. Front view of the same skull.
 Fig. 3. Back view of the mandible.
 Fig. 4. Front view of the same mandible.

PLATE XXIV.

Base view, natural size, of the same skull, and grinding surface of the upper teeth.

PLATE XXV.

- Fig. 1. Upper view of the mandible, and grinding surface of the lower teeth.
 Fig. 2. Side view of the mandible.

PLATE XXVI.

- Fig. 1. The second upper molar tooth :—natural size.
 Fig. 2. Longitudinal section of the alveolar part of the upper jaw and of the five upper molars, *in situ* :—three-fourths of the natural size.
 Fig. 3. Transverse section of a portion of a molar tooth of the Megatherium :—magnified 500 linear diameters.

The letters and ciphers on the several figures are explained in the text.

Fig. 1.

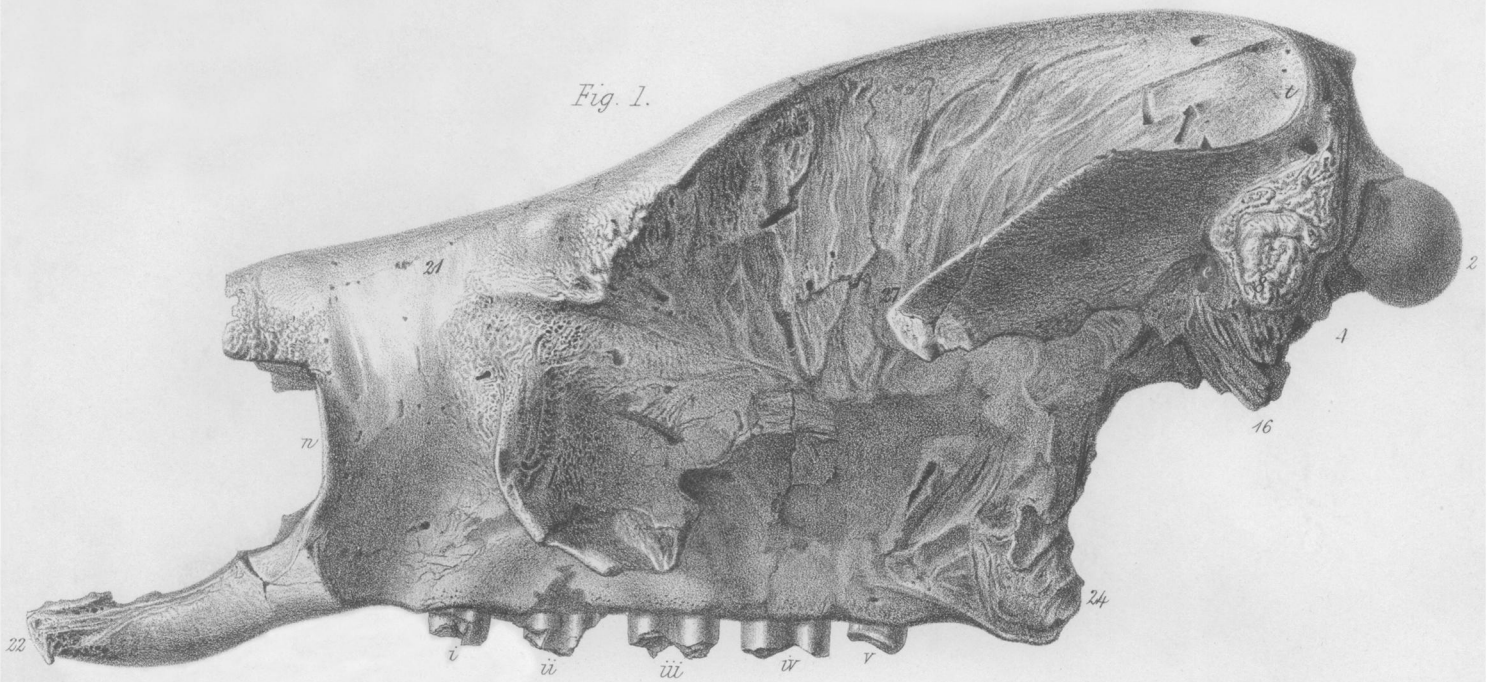


Fig. 2.

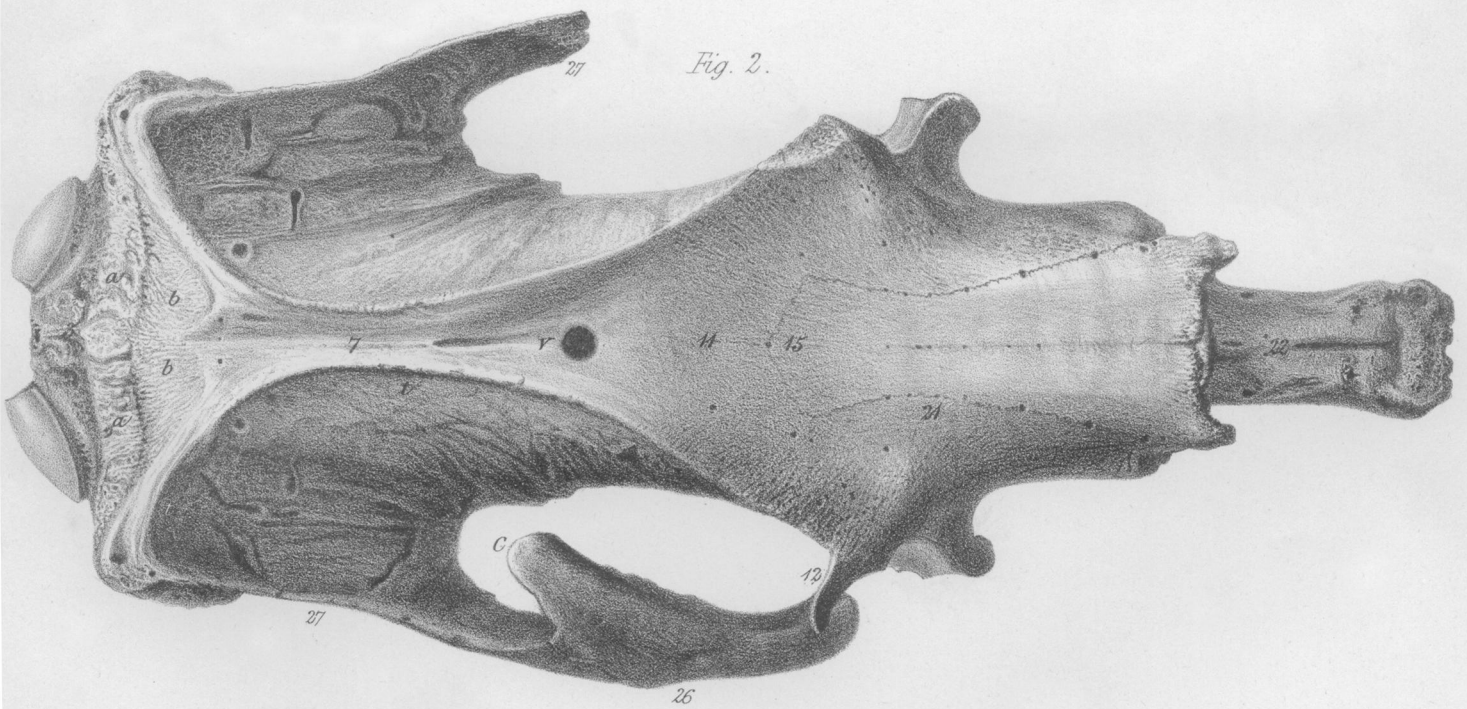


Fig. 1.

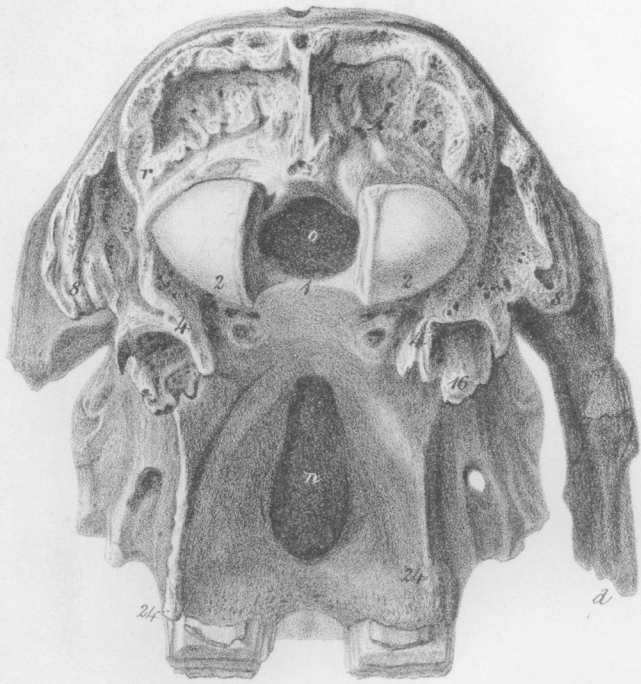


Fig. 2.

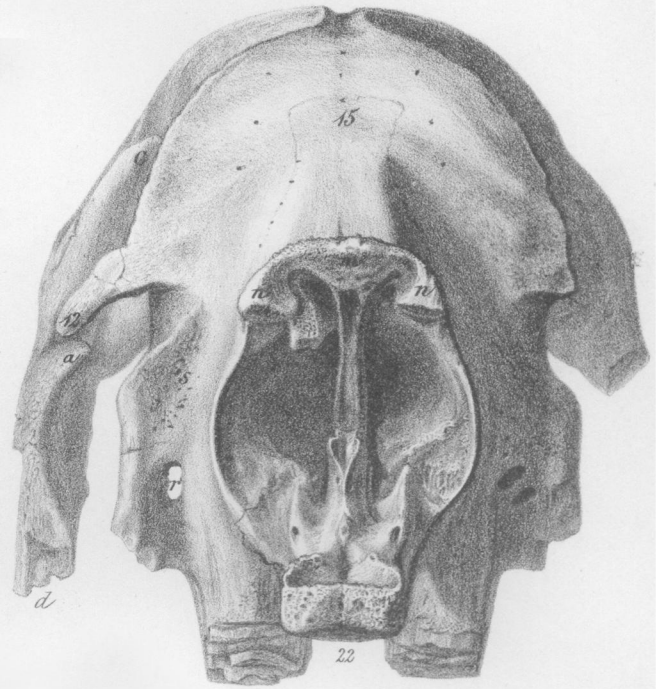


Fig. 3.

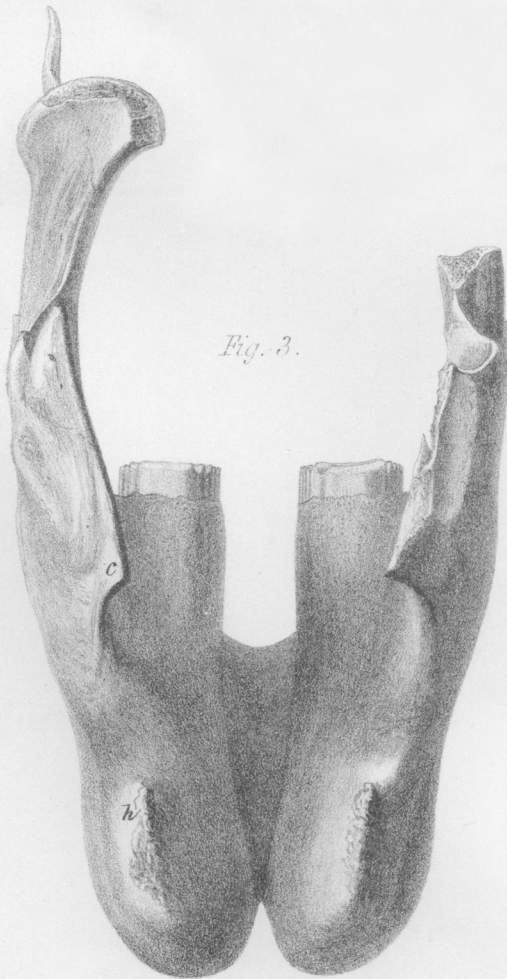
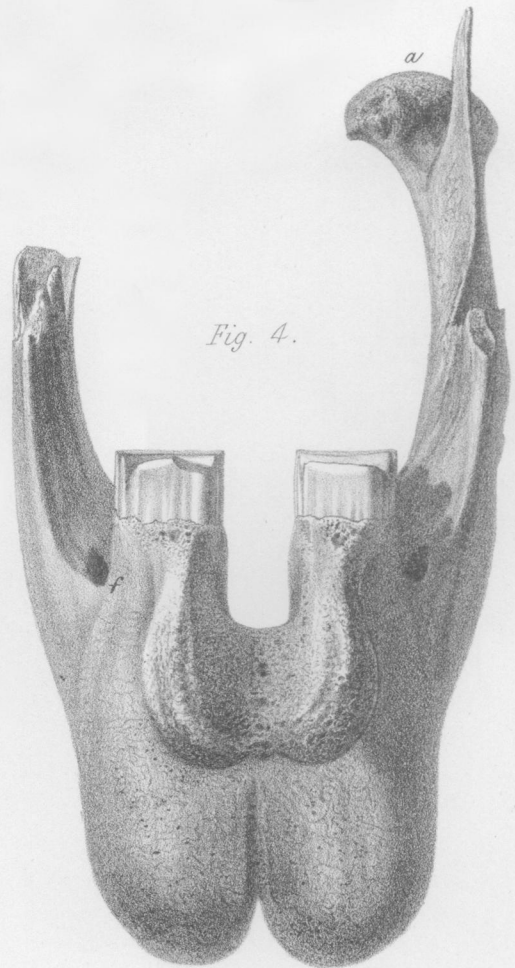
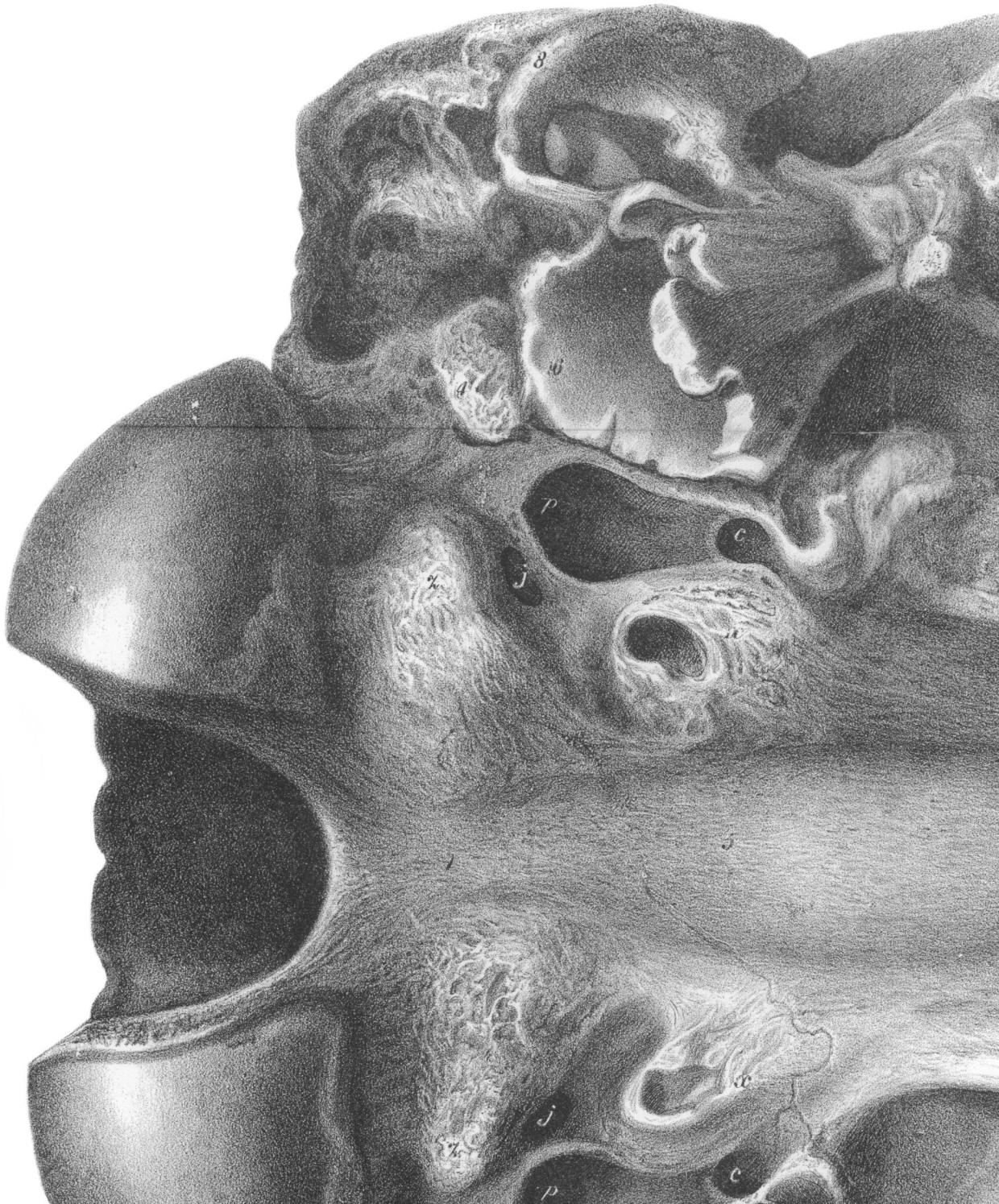
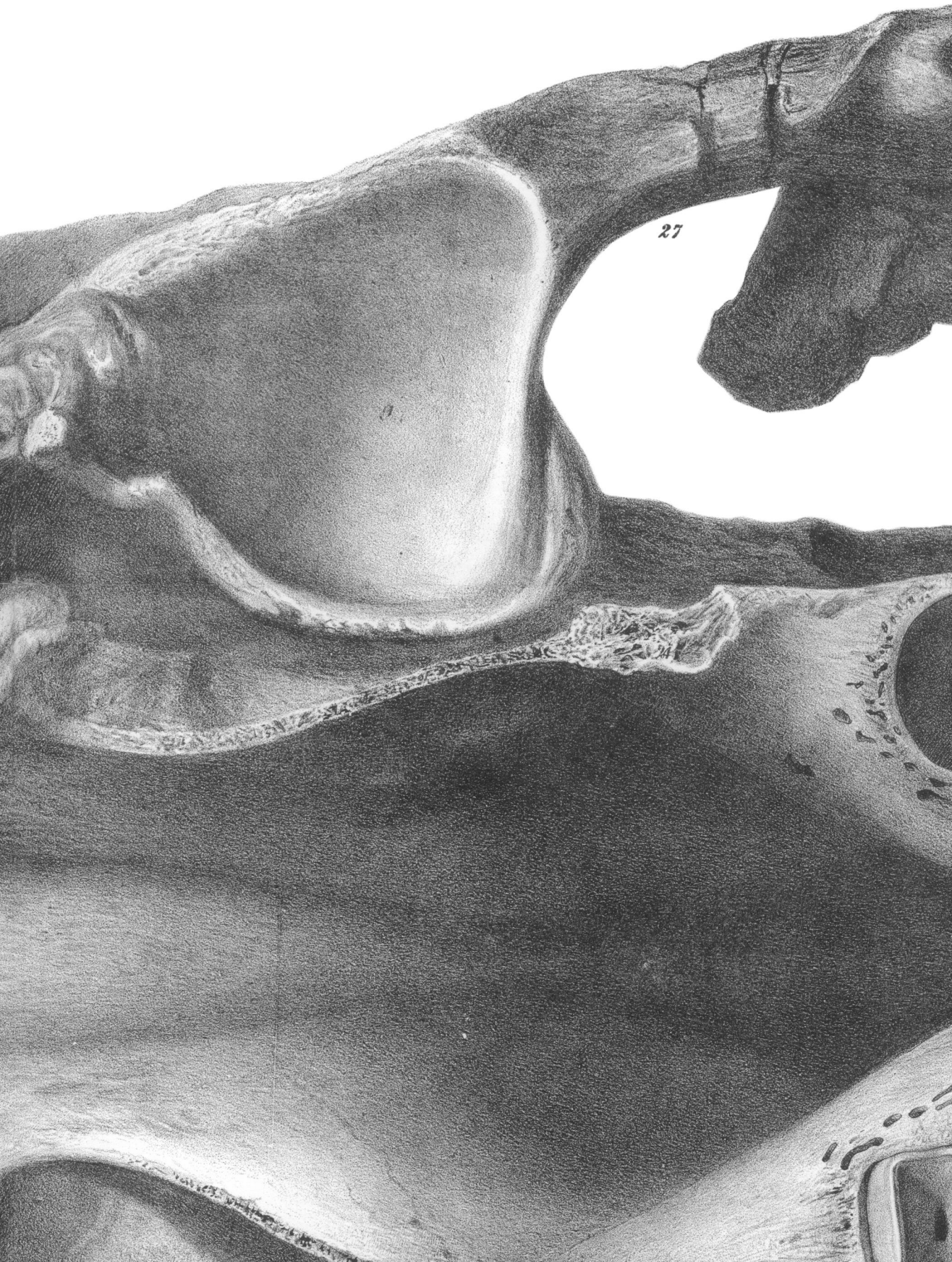
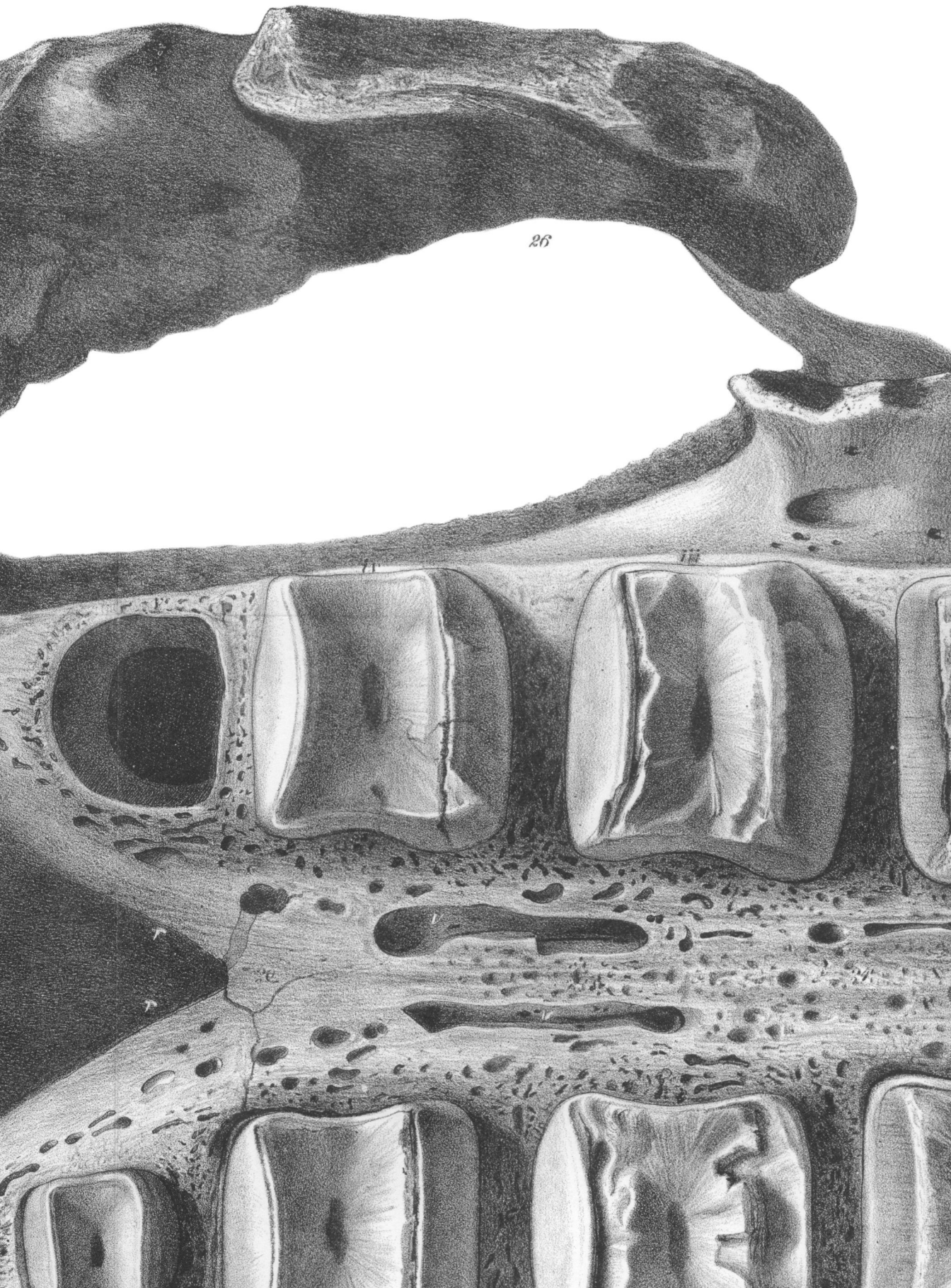


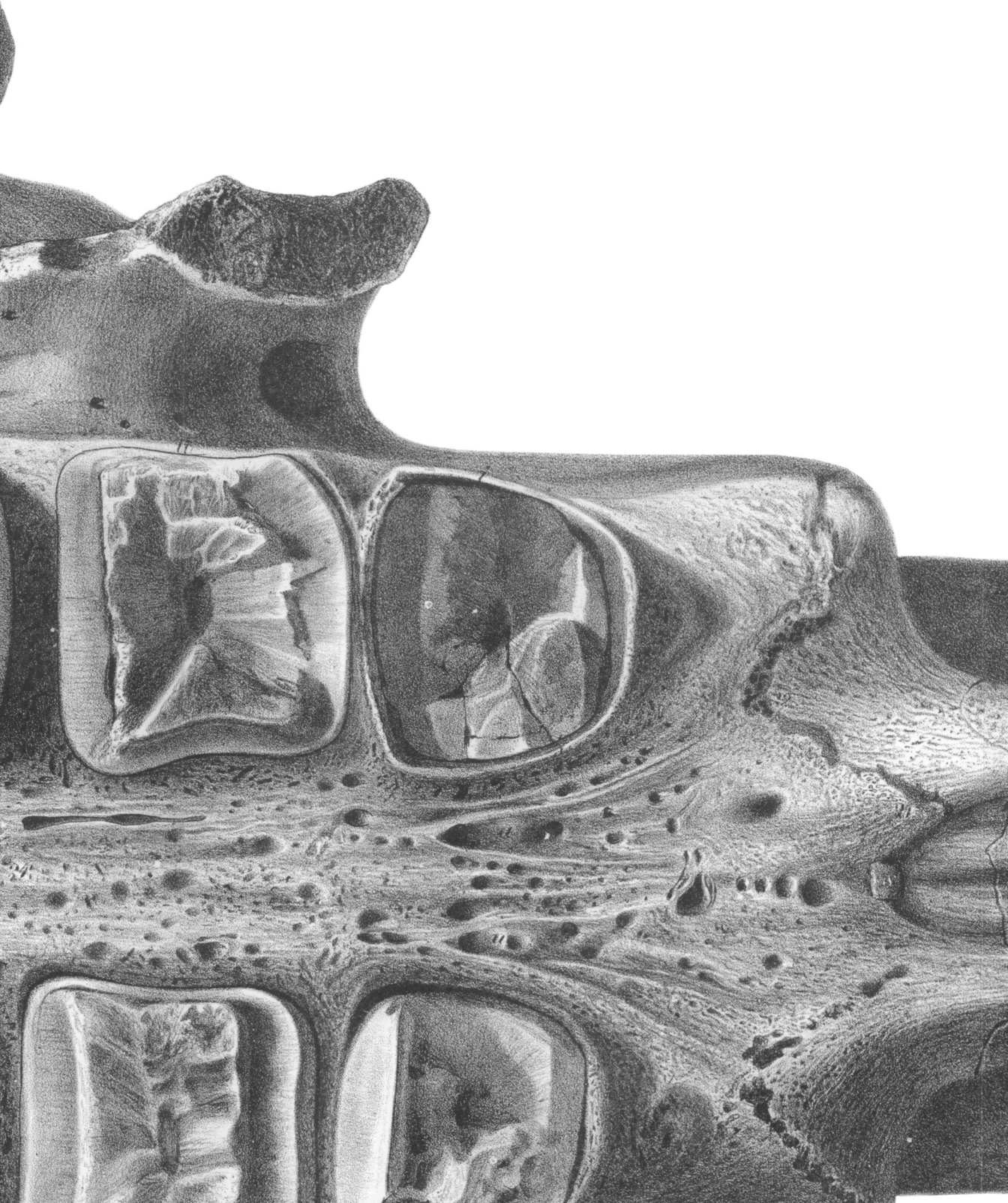Fig. 4.



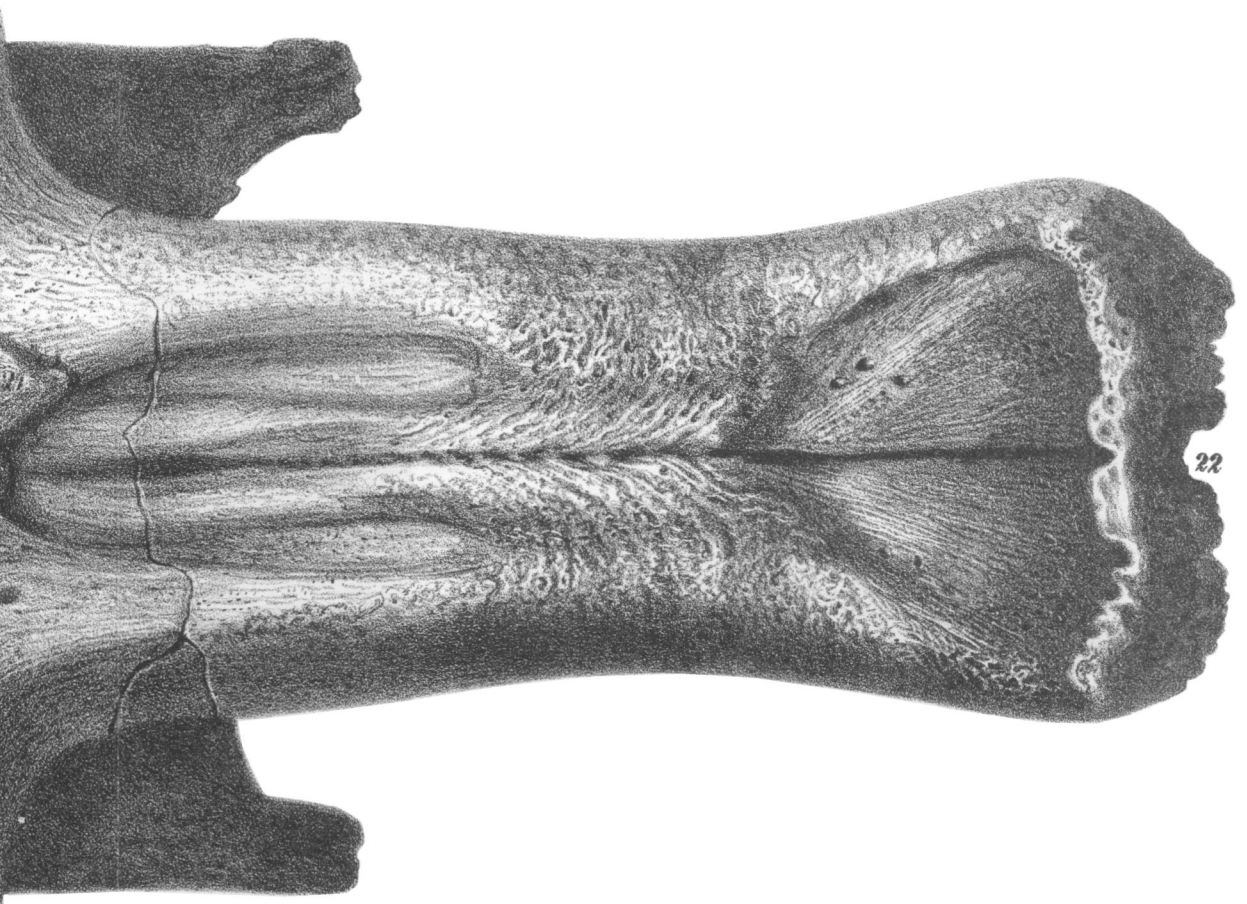


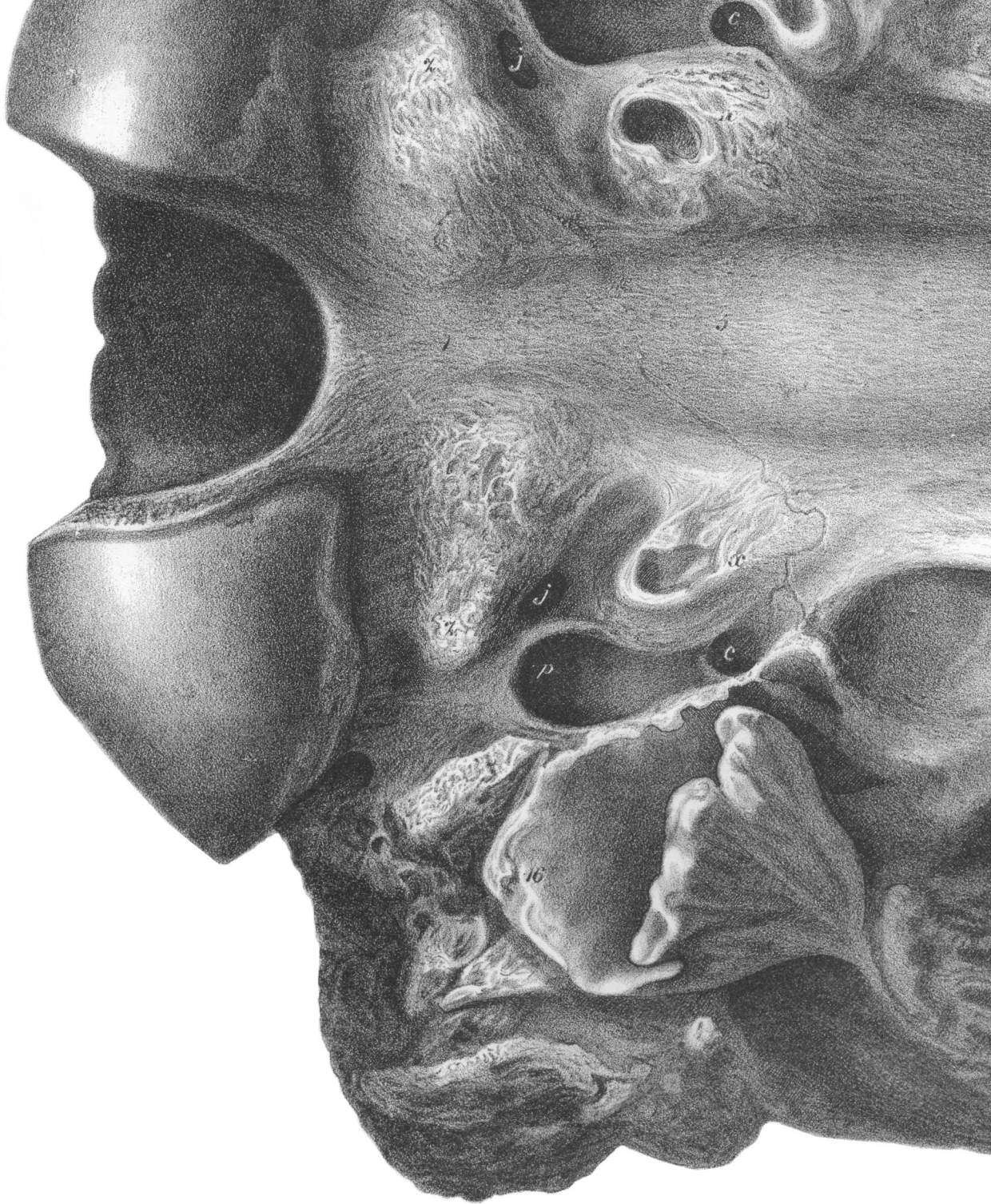


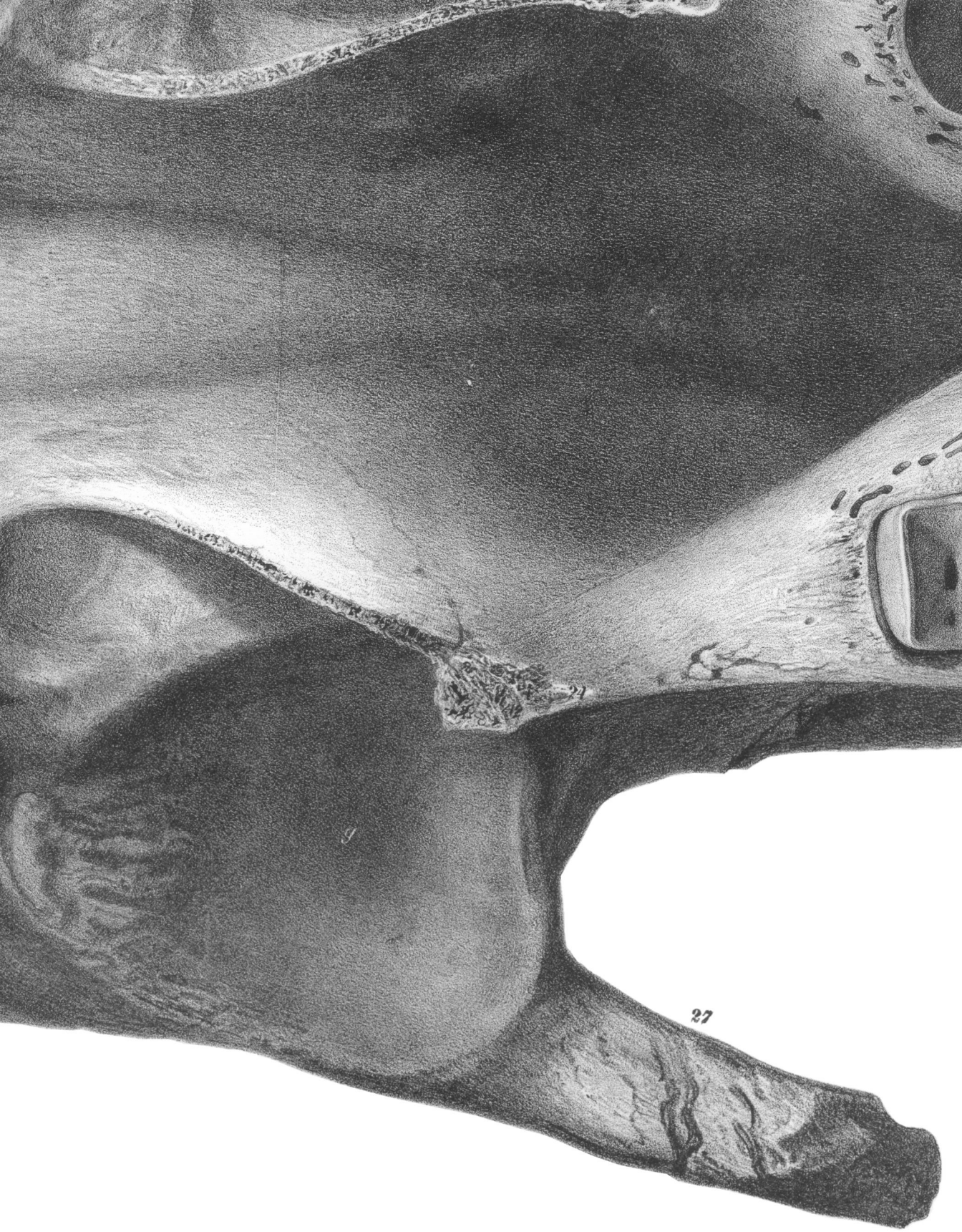




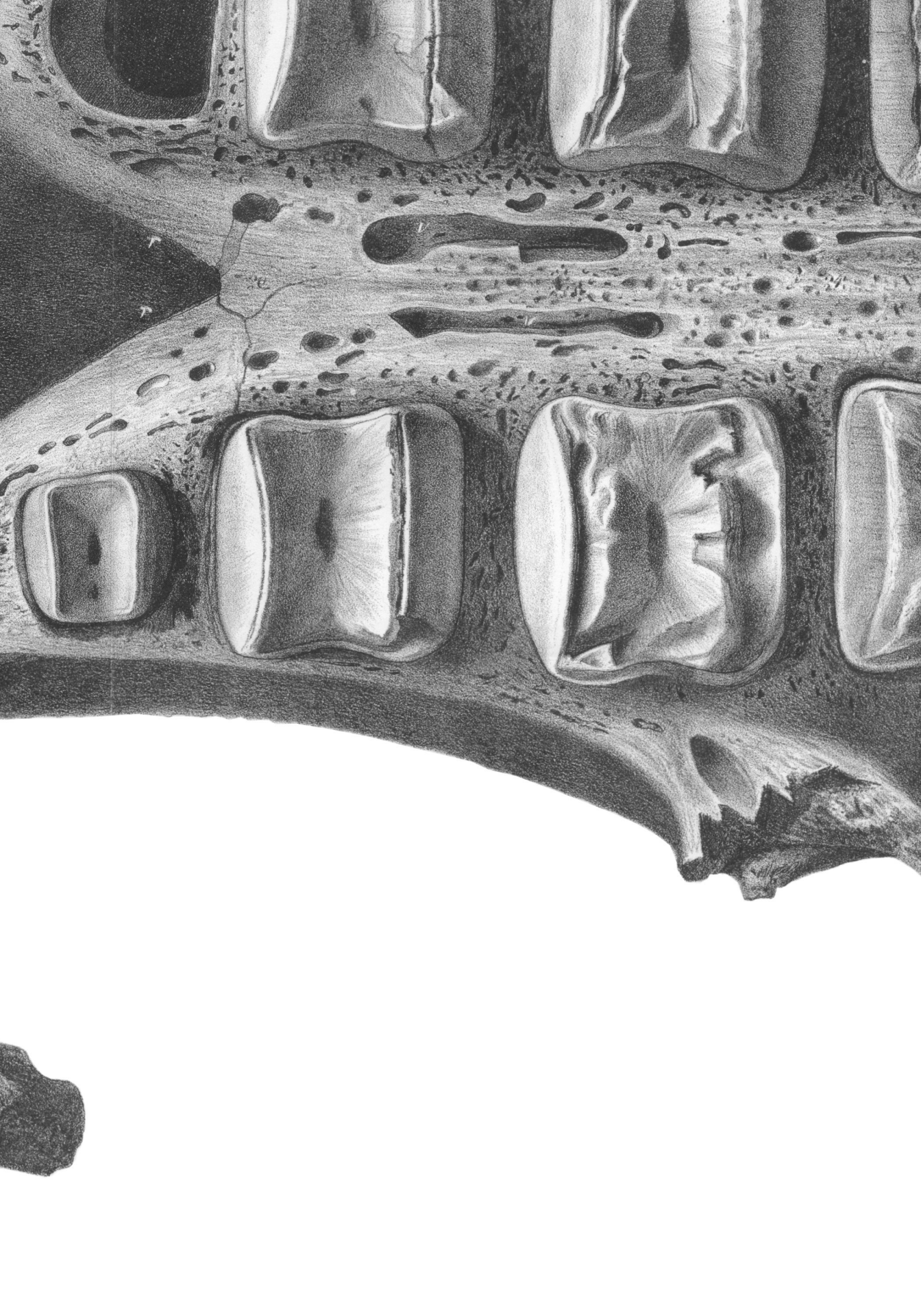Phil. Trans. MDCCLVI. *Plate* XXIV.

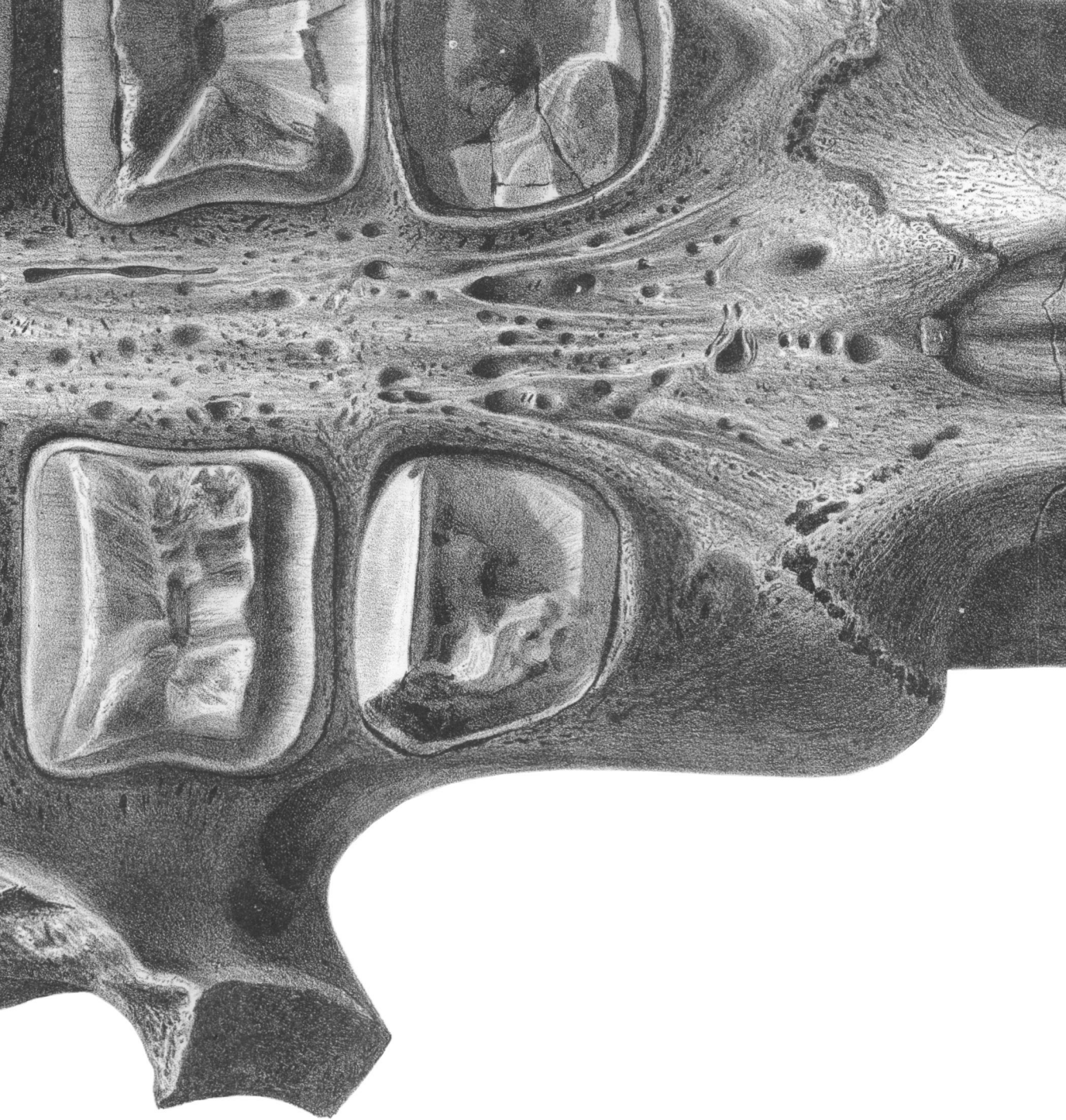


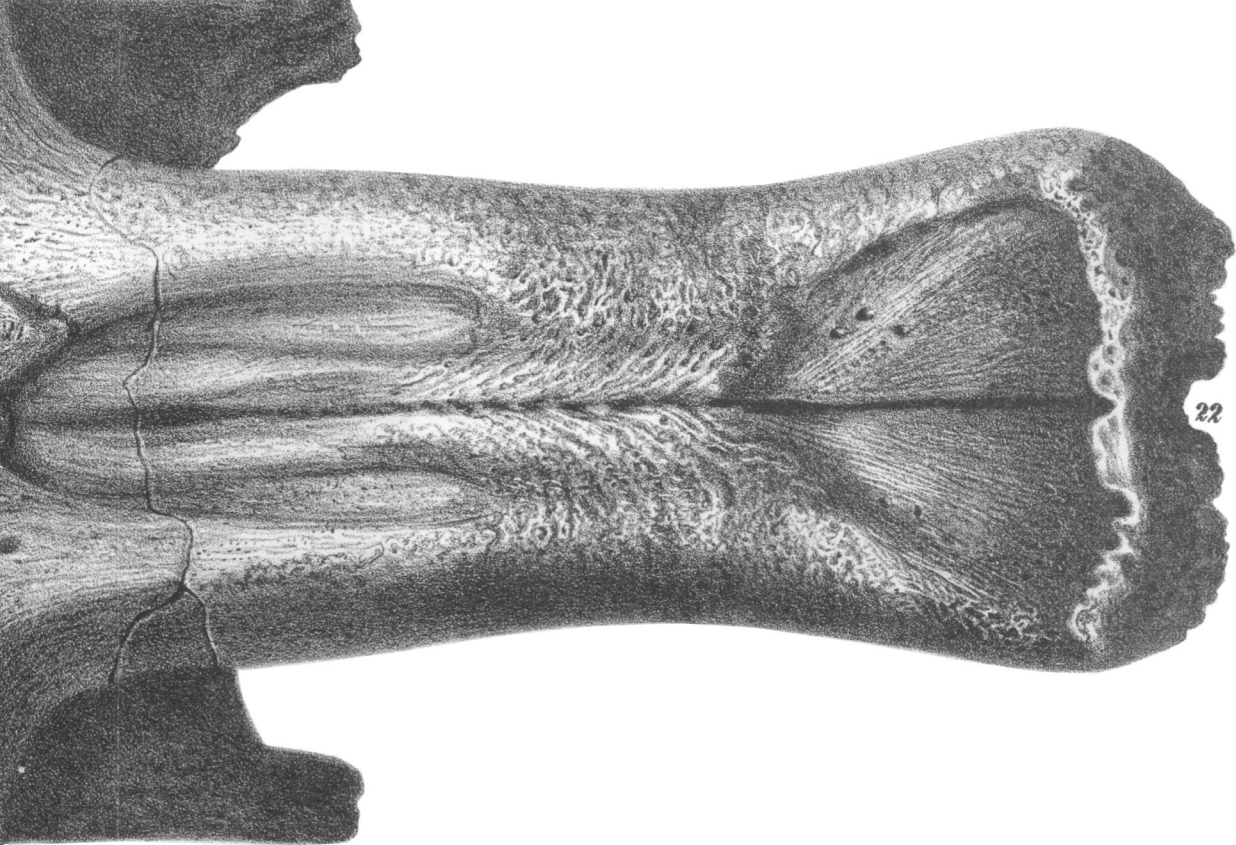




27







22

Fig. 1.




Fig. 2.

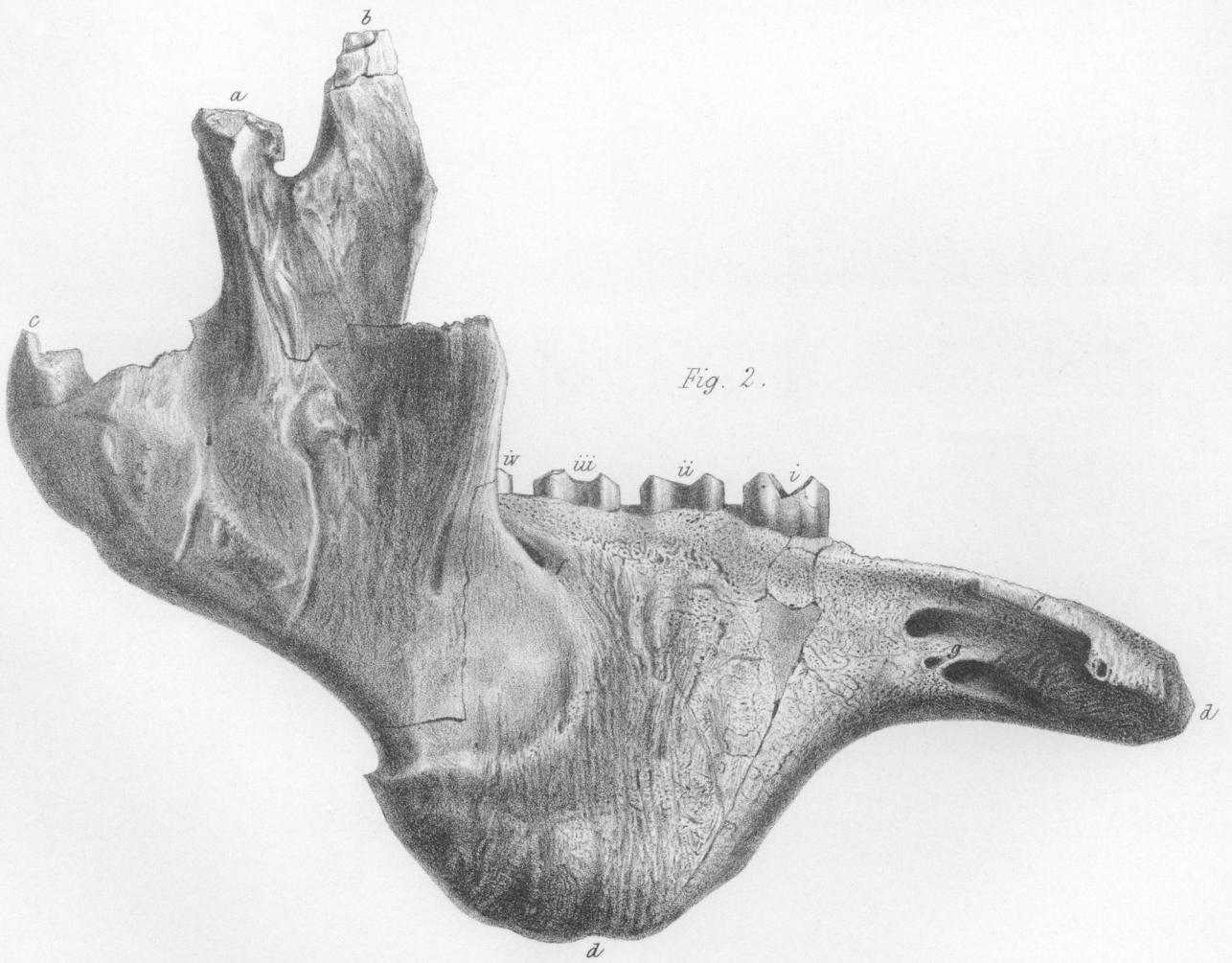
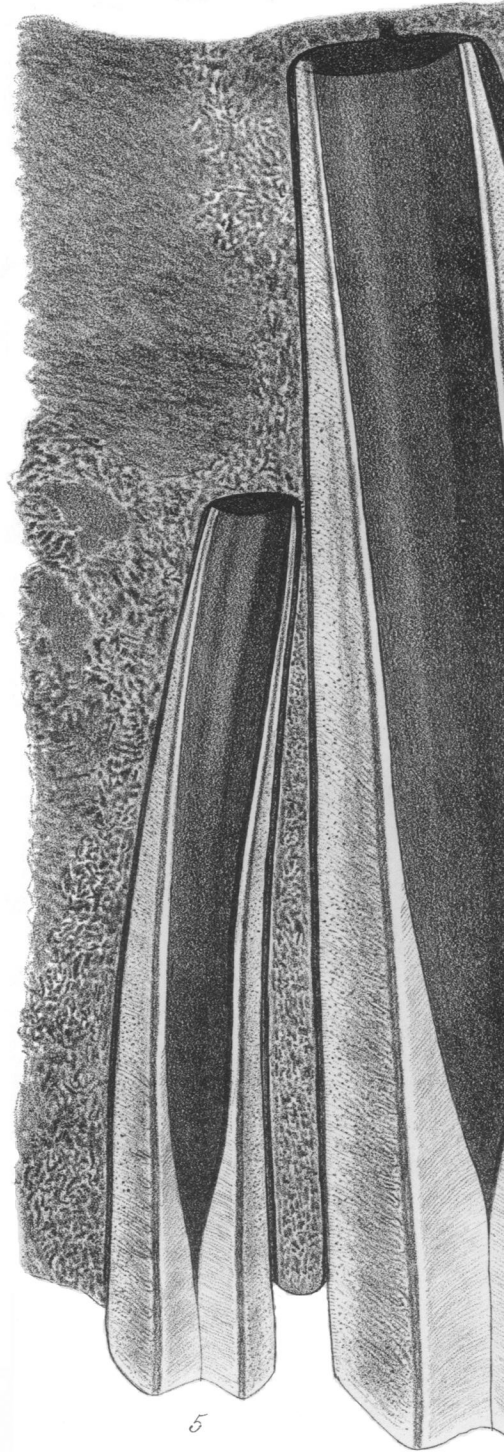



Fig. 1.



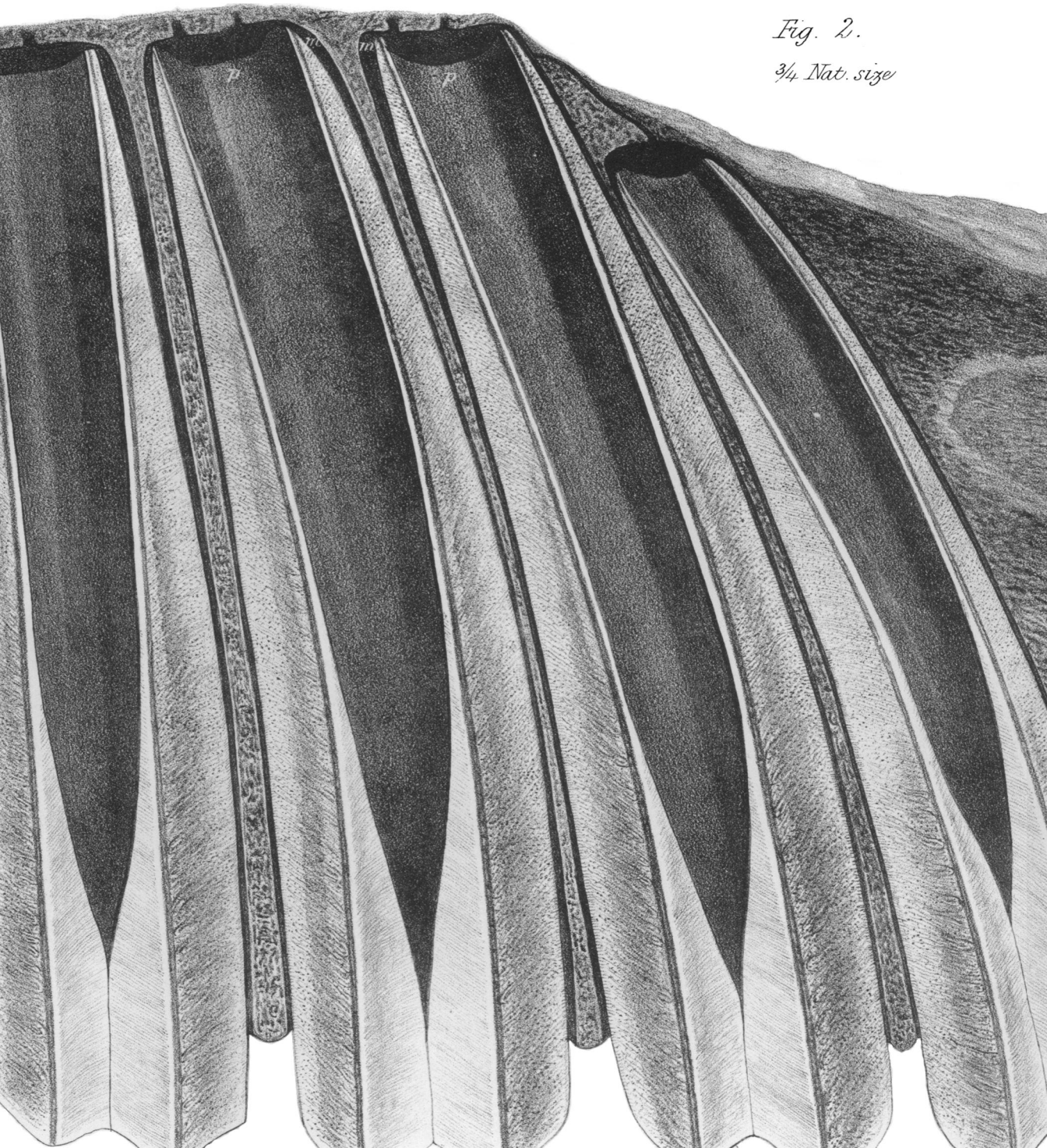


Fig. 2.

3/4 Nat. size

Fig. 3.

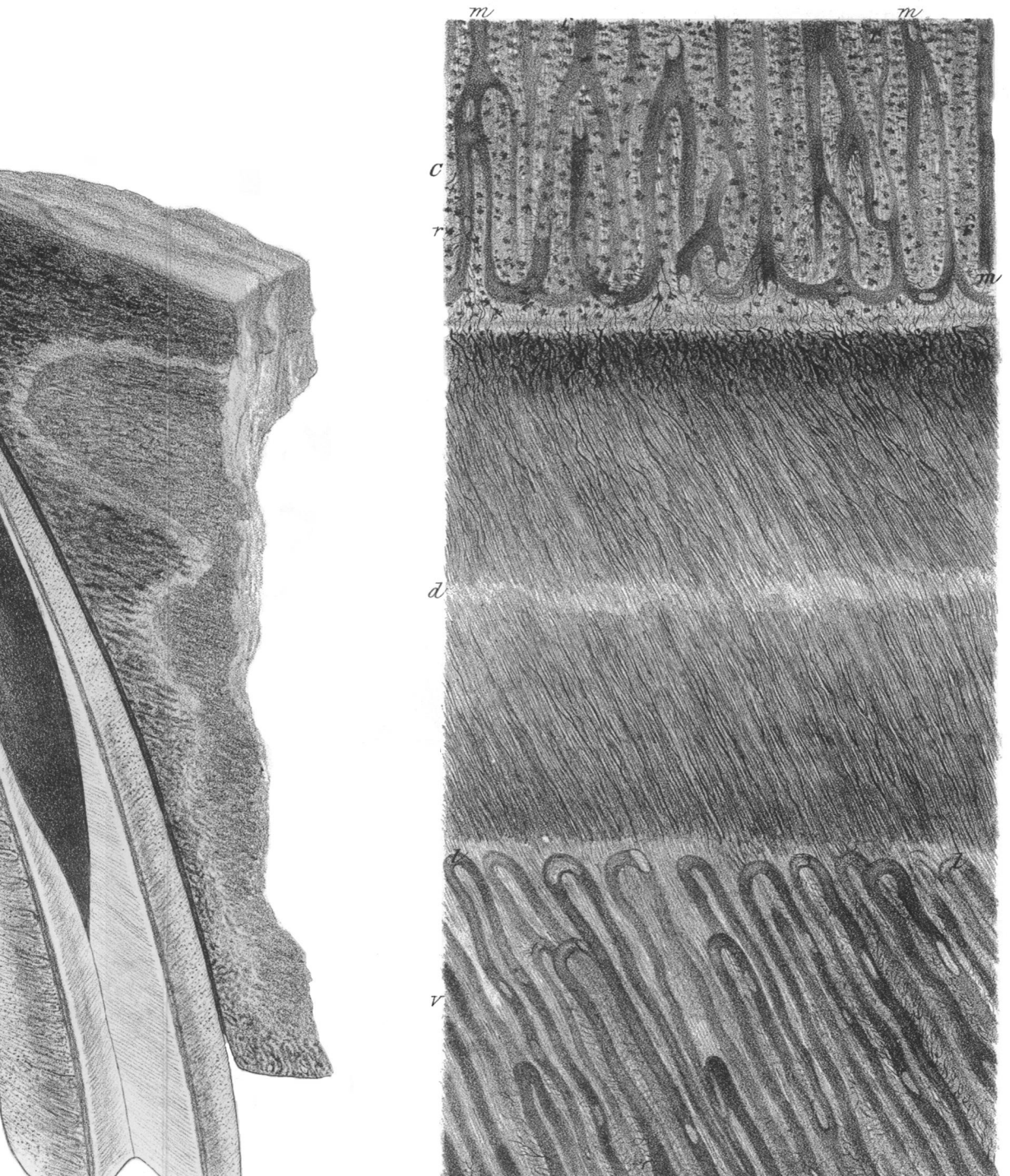


Fig. 1.

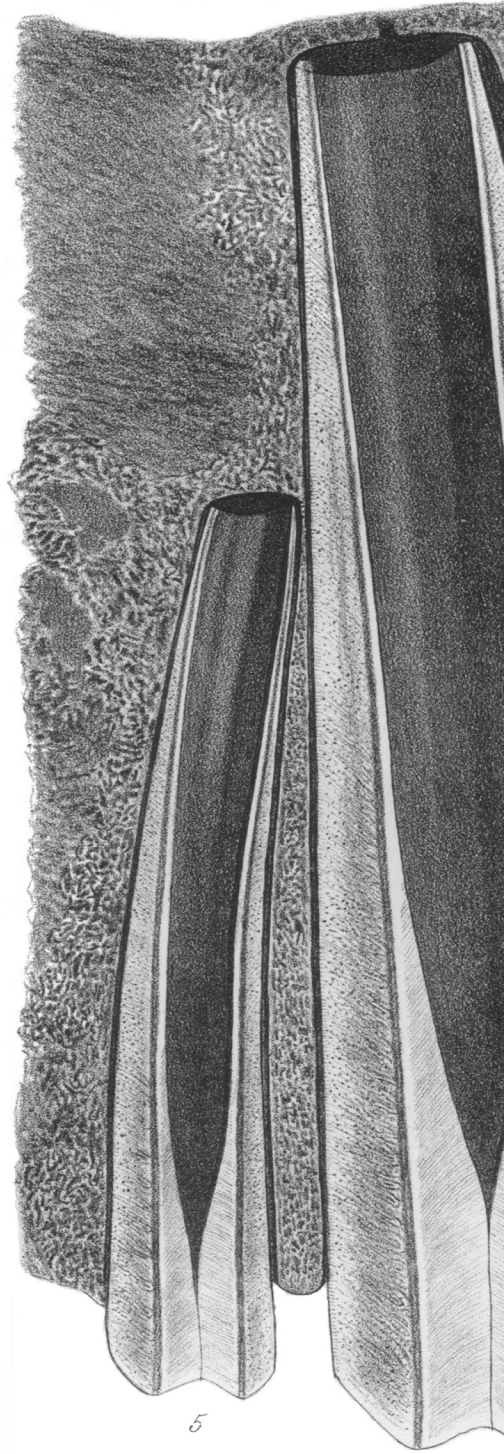



Fig. 2.

3/4 Nat. size




Fig. 3.

