



CORNELL  
UNIVERSITY  
LIBRARY



FROM

Wm. M. Leffingwell


Cornell University Library  
RG 104.3.E54

Vesico-vaginal fistula from parturition



3 1924 012 167 726

clin



## Cornell University Library

The original of this book is in  
the Cornell University Library.

There are no known copyright restrictions in  
the United States on the use of the text.





# VESICO-VAGINAL FISTULA

FROM

PARTURITION AND OTHER CAUSES :

WITH

CASES OF RECTO-VAGINAL FISTULA.

BY

THOMAS ADDIS EMMET, M.D.,

SURGEON-IN-CHIEF OF THE NEW YORK STATE WOMAN'S HOSPITAL,  
&c., &c.

NEW YORK :

WILLIAM WOOD & CO.

1868.

Entered according to Act of Congress, in the year 1868, by

**THOMAS ADDIS EMMET, M. D.,**

In the Clerk's Office of the District Court of the United States, for the Southern District  
of New York.



TO  
J. MARION SIMS, M. D.,  
MY INSTRUCTOR;  
AND TO THE  
LADY MANAGERS

OF THE NEW YORK STATE WOMAN'S HOSPITAL,

AS A TOKEN OF APPRECIATION OF THE EARLY LABORS OF THOSE WHO WERE THE FOUNDERS OF THE FIRST  
INSTITUTION DEVOTED EXCLUSIVELY TO THE TREATMENT OF THE DISEASES AND CASUALTIES  
PECULIAR TO THE SEX; AND AS A TRIBUTE OF PERSONAL ESTEEM TO THOSE WHO  
AFTERWARD MAINTAINED, BY THEIR EFFORTS DURING ITS GROWTH, A BENE-  
FACTION, WHICH WILL STAND AS A LASTING MONUMENT OF THEIR  
ZEAL FOR THE RELIEF OF SUFFERING HUMANITY, AND A  
RECOGNIZED LANDMARK IN THE CAUSE OF SCIENCE,

THIS WORK IS RESPECTFULLY DEDICATED.



## P R E F A C E .

---

The material presented to the profession in this form was collected with a view of furnishing, through the pages of the *American Journal of the Medical Sciences*, Philadelphia, a simple record of interesting cases, a portion of which, as an introduction, appeared in the number for October, 1867.

It was soon apparent, however, that this could not be sufficiently condensed, within the allotted space of a journal, to do justice to the subject. Had the change been contemplated in the beginning, a different arrangement might have been adopted, with a review at some length of the literature bearing on the subject.

I am fully satisfied that an analytical digest would have been an addition of great value, in tracing the labors of Jobert (de Lamballe), Follin, Verneuil, Herrgott, Desgranges, Bourguet d'Aix, Duboué, and Courty, of France; Deroubaix, of Belgium; Metzler, and G. Simon, of Germany; Gosset, Simpson, Spencer Wells, Baker Brown, Mathews Duncan, and Lane, of Great Britain; M. Collis, of Dublin; Heyward, J. B. S. Jackson, Mettauer, Sims, Bozeman, and Agnew, of the United States; together with many others.

Yet, with the fullest appreciation of the importance of their contributions to this branch of surgery, I found it impossible, amidst arduous professional duties, to undertake an additional task, without necessitating too great a delay in any attempt to do justice to their work.

I have, therefore, adhered to my original plan of offering simply my own experience as a contribution to the common stock. .

I have endeavored to illustrate, in as concise a manner as possible, the various difficulties which I have met with in operating for these injuries. Having, however, no wish to inflict upon the reader a mere array of cases, I have excluded all but those useful in demonstrating some practical point. To the reader only of the index, it may seem that this rule has not been strictly adhered to, by the introduction of much which may be deemed irrelative; yet the whole will be found intimately connected with the main

subject under consideration. As a sequel to the operation for vesico-vaginal fistula, we sometimes have cystitis, with the formation of calculi; these may cut through and reproduce the fistula; therefore the operation for removal of stone in the bladder is treated of, as well as for the relief of chronic cystitis, by establishing an artificial opening at a favorable point.

For the closure of a recto-vaginal fistula, situated near the sphincter, it becomes necessary sometimes to divide the perineum and muscle. In this connection, the operation, as practised for closing a lacerated perineum through the sphincter, is described at length.

Fistulæ from other causes than parturition are referred to:—the effect of malignant disease; syphilitic ulcerations; pelvic abscesses; the ulceration of the vesico-vaginal septum from calculi, happening after paralysis from injuries, and from the neglect and pressure of pessaries; with an interesting case of fistula caused by a pistol-shot.

Cases are given of congenital absence of the anus, with the rectum opening into the vagina; operation for forming an artificial anus; and the opposite condition, with a deficiency sometimes of the urethral canal, where the vagina and uterus are wanting; the operation for forming an artificial vagina before the urethral condition can be relieved; together with other subjects of minor importance.

It will be found that the needed preparatory treatment, the necessary instruments, the various modes of operation under modified conditions of the vaginal canal, with the after-treatment, have been reviewed at full length, with the object of presenting each point in as practical a form as possible.

The classification of cases has been entirely an arbitrary one, the order followed being merely for convenience in clinically illustrating some special subject, by beginning with the simpler examples, and gradually introducing the more complicated ones.

As it is impossible for exactly the same condition to exist ever in any two cases, I have endeavored to present only a sufficient amount of material to be suggestive to any one who will think for himself and study the peculiarities of the special case. With this view, therefore, I have felt that to attempt more would be merely unnecessary on my part.

So far as originality can be claimed, in resorting to various expedients which would be naturally suggested by the peculiarities of any individual case, the chapter on the formation of the urethral canal, with the operations within the bladder, will present many points of interest to the operator, while I hope my experience may encourage others to persevere in their efforts to relieve similar cases, which might be deemed incurable.

# CONTENTS.

	PAGE
PREFACE. - - - - -	i
<b>INTRODUCTION.</b>	
Result of the application of the metallic suture, and the introduction of Sims' speculum. Fistula, as a result of parturition, more common among the poorer class. But few cases are incurable. Number of cases operated upon and result. Classification. - - - - -	13
<b>CHAPTER I.</b>	
Definition and cause. Delay dangerous after impaction. Extent of injury due to position, and not always in proportion to the length of labor. Treatment after reception of injury. Preparatory operations in freeing soft parts previous to closing a fistula. - - - - -	19
<b>CHAPTER II.</b>	
INSTRUMENTS NECESSARY FOR THE OPERATION.	
Sims' speculum. The self-retaining speculum. Tenaculi. Perry's barb-pointed tenaculum. Blunt hooks. Scissors of various curves. Ball and socket-jointed knife. Needle forceps. Feeder. Forceps for bending the silver wire loop. Twisting forceps. Shield. Sponge-probang holders. Silver wire; its quality, and proper size. Self-retaining catheter; importance of a proper curve to suit each case. Relative size of instruments in comparison with the wood-cnts. - - - - -	24
<b>CHAPTER III.</b>	
GENERAL REMARKS ON THE OPERATION.	
The table, dress of the patient, and position. Mode of denuding the edges. Introduction of the needle, with a silk loop, the silver suture attached afterward. Interrupted suture the best. Great accuracy of introduction not necessary if properly "shouldered," and mode of doing so. Method of twisting and flattening the suture. Introduction of the catheter and washing out the bladder. After-treatment. Removal of the sutures. When the patient should sit up. - - - - -	33
<b>CHAPTER IV.</b>	
VESICO-VAGINAL FISTULÆ, WITH LACERATION OF THE CERVIX UTERI.	
The laceration along the vaginal surface being superficial, or extending entirely through the septum, with but little sloughing or loss of tissue afterward. The formation of calculi after injuries of the cervix, and mode of operating for their removal. Chronic cystitis to be treated by producing a vesico-vaginal fistula; method of doing so, and time of closing the opening afterward.	
CASE I. First pregnancy; in labor one hundred and three hours. Antero-posterior laceration of the cervix uteri, with a fistula extending in the median line from the cervix to the neck of the bladder. Cured by one operation. Stone in the bladder removed eighteen months afterward. - - - - -	39

	PAGE
CASE II. Second labor of one hour; natural delivery. Anterior laceration of the cervix uteri, extending in the median line along the base of the bladder. Fissure partially closed by nature, leaving a small fistula in front of the cervix. Cured by one operation. First living child born a year afterward. A suture removed from the cervical canal eighteen months after the operation.	45
CASE III. Fifth labor, of forty-five hours' duration. Instrumental delivery. Laceration of the anterior lip of the cervix, with a fistula in the median line an inch in diameter. Closed by one operation.	47
CASE IV. First pregnancy; natural delivery after a labor of three days. Laceration in the median line of the anterior lip of the cervix, and along the base of the bladder for an inch. Nature had nearly closed the opening. The original condition was reproduced and closed by one operation.	48
CASE V. Fourth pregnancy; forty-eight hours in labor. Delivery accomplished by hand. Fistula extended an inch and a quarter from the cervix in the median line, with laceration of the anterior lip of the cervix. First operation closed the fistula on the vaginal surface, but a sinus was formed afterward, communicating with the cervical canal. Second operation successful by dividing the cervix through to the sinus, and reproducing the original condition.	49
CASE VI. Sixth pregnancy. In labor eighteen hours; delivered by version. Laceration of the anterior lip of the cervix uteri and base of the bladder in the median line. Partially closed by nature, leaving a sinus communicating with the cervical canal above the vaginal junction. Cured by closing the os uteri.	51
CASE VII. Third pregnancy; natural delivery after a labor of thirty-seven hours. A sinus from the bladder entered the cervical canal above the vaginal junction, and, as in the previous case, from laceration of the anterior lip.	53
CASE VIII. First pregnancy. Twenty-four hours in labor; delivered by craniotomy. Anterior laceration of the cervix, which, becoming closed above, left a sinus communicating with the uterine canal from a large fistula in front. The original condition was reproduced and operation successful.	54
CASE IX. First pregnancy. Version, and head delivered by forceps; in labor about thirteen hours. Laceration of the cervix uteri on the right side, with a fistula an inch in length, and cicatricial bands extending from the opening into the cul-de-sac. Closed by one operation.	56
CASE X. Ninth pregnancy; delivered by forceps, after a labor of forty-two hours. Lateral laceration of the cervix on the right side. Fistula large, with cicatricial tissue extending into the cul-de-sac. First operation not entirely successful. Cured by the second operation after reproducing the original condition.	57
CASE XI. Fifth pregnancy. Delivered by efforts of nature; in labor three days. Lateral laceration of the cervix on the left side. Fissure through the cervix closed by nature, as well as part of the anterior edge of the fistula. One operation successful.	58

## CHAPTER V.

### LACERATION OF THE CERVIX, WITH EXTENSIVE LOSS OF THE SOFT PARTS PROM SLOUGHING.

CASE XII. Second pregnancy. Seventy-one hours in labor; delivered by the efforts of nature. Laceration of the anterior lip in the median line, with sloughing of nearly two inches along the base of the bladder. By contraction of cicatricial tissue, the vagina was drawn into a deep fold on each side of the fistula. Cured by one operation.	60
CASE XIII. First labor, lasting fifty hours; delivered by forceps. Laceration of the anterior lip of the cervix, together with a slough extending nearly to the neck of the bladder. Partially closed by nature from each end, and, by contraction of cicatricial tissue, reduced to a circular opening, situated about the centre of the base of the bladder. Closed by one operation.	61
CASE XIV. Third pregnancy; delivery by forceps, after a labor of forty-two hours. Laceration of the anterior lip of the cervix, and of the base of the bladder in	

	PAGE
the median line, with sloughing. Fissure in cervix united by granulation. Fistula reduced to a circular one, and vagina shortened by bands extending into the cul-de-sac. Closed by one operation.	62
CASE XV. Third pregnancy; delivered by version, after a labor of twenty-four hours. Laceration of the cervix in its antero-posterior diameter, with loss of about half the base of the bladder in front of the uterus. Fistula was to the right of the median line, in consequence of traction exerted by cicatricial bands extending into the cul-de-sac, which drew the uterus to the left side. Closed by two operations.	63
CASE XVI. First pregnancy. In labor about one hundred and four hours; delivered by the efforts of nature. Loss of two-thirds of the base of the bladder in front of the cervix, the posterior lip of the cervix and cul-de-sac. Laceration of the anterior lip of the cervix, with a false passage existing from the urethra into the vagina. First operation successful, but, by tension, an opening afterward occurred, which was closed by a subsequent operation.	66

## CHAPTER VI.

### FISTULÆ INVOLVING THE UPPER PORTION OF THE VAGINA, WITH SLOUGHING OF THE CERVIX UTERI.

CASE XVII. Sixth pregnancy; natural delivery, after forty-eight hours in labor. Transverse fistula in front of the cervix, which had sloughed. By cicatricial bands extending into the cul-de-sac, the vaginal tissue in front of the cervix was drawn into a fold so as to hide the opening into the bladder. Closed by one operation.	71
CASE XVIII. Sixth pregnancy; instrumental delivery, after sixty-seven hours in labor. Uterus retroverted; anterior lip lost, together with a large portion of the base of the bladder. By contraction of cicatricial tissue, the vaginal wall in front was drawn into a fold, so as to hide the fistula from view. Fistula closed by turning the cervix uteri into the bladder. Operation successful; small opening afterward, which was closed by a second operation.	72
CASE XIX. Fifth pregnancy; instrumental delivery, after forty-eight hours in labor. The posterior lip of the cervix was lacerated during labor backward into the cul-de-sac, with subsequent pelvic cellulitis. Sloughing of the anterior lip, and a portion of the base of the bladder, just in front of the cervix, took place. The uterus became gradually retroverted, and the base of the bladder doubled on itself from contraction of cicatricial tissue, so as finally to hide the fistula from view. Closed by one operation.	74
CASE XX. First pregnancy; instrumental delivery, after seventy-two hours in labor. A large portion of the base of the bladder lost, together with the cervix and cul-de-sac. By contraction of cicatricial bands, the vaginal tissue became drawn backward over the fistula. Closed by one operation.	76
CASE XXI. First pregnancy; natural delivery, after thirty-six hours in labor. Transverse fistula in front of the uterus, with loss of anterior lip. A fold existed in front of the opening, from cicatricial tissue extending forward toward the neck of the bladder. The cervix uteri was turned into the bladder, and the opening closed by one operation.	77
CASE XXII. Second pregnancy; instrumental delivery, after seventy hours in labor. Loss of the anterior lip of the cervix, with a large portion of the base of the bladder. By contraction of cicatricial tissue, the anterior wall of the vagina was drawn backward, and nature had nearly closed the fistula by uniting a portion of its edge with the posterior lip of the uterus, thus shutting up the uterine canal within the bladder. Two openings remained, which were closed by one operation.	80
CASE XXIII. Third pregnancy; natural delivery, after a labor of twenty-six hours. Loss of the cervix uteri, with the whole base of the bladder. By bands in the cul-de-sac, the fistula, which was three inches in length, was drawn into a crescentic form, with its cornua posterior to the cervix uteri. Closed by one operation.	82

	PAGE
CASE XXIV. Fifth pregnancy; natural delivery, after a labor of fifty-six hours. Loss of the anterior lip of the cervix and upper third of the base of the bladder. The vaginal tissue was drawn backward as a hood so as to hide the fistula. The fistula was brought into view and closed, but no union took place, as its edges were cicatricial. Second operation successful, by cutting out the fistula with the surrounding tissue, and bringing together healthy surfaces.	83
CASE XXV. Third pregnancy; instrumental delivery, after a labor of some forty-six hours. Loss of the anterior lip of the cervix and upper portion of the base of the bladder. By contraction, the vaginal tissue was drawn laterally into two folds over the cervix and fistula, and these extended in the long axis of the canal, from the cul-de-sac nearly to the neck of the bladder. Closed by one operation.	85

## CHAPTER VII.

### FISTULÆ CONFINED TO THE UPPER PORTION OF THE BASE OF THE BLADDER.

CASE XXVI. Second pregnancy; instrumental delivery, after a labor of forty-nine hours. A slough had extended in the median line, from the cervix uteri nearly to the neck of the bladder; but, by contraction of cicatricial bands, the opening became a transverse one in front of the cervix. Cured by one operation.	87
CASE XXVII. Seventh pregnancy; natural delivery, after sixty-seven hours in labor. Loss of the whole base of the bladder. Fistula was crescentic in shape, with its cornua drawn toward the cul-de-sac. The anterior lip of the cervix formed the posterior boundary of the fistula. Closed by one operation.	88
CASE XXVIII. First pregnancy; natural delivery, after a labor of one hundred and one hours. Loss of one-third of the base of the bladder in front of the cervix. By cicatricial bands extending into the cul-de-sac, the fistula was lessened in size, the vagina shortened, and a fold drawn backward over the opening, so as to hide it from view. Closed by one operation.	90
CASE XXIX. Third pregnancy; instrumental delivery, after thirty hours in labor. Loss of the upper half of the base of the bladder, with lateral laceration of the cervix uteri by a previous labor. The fistula was crescentic in shape, with its cornua extending into the cul-de-sac, and the anterior lip of the uterus formed its posterior boundary. Closed by one operation.	91
CASE XXX. First pregnancy; instrumental delivery, after a labor of some ninety-six hours. Loss of the upper third of the base of the bladder. The opening was contracted and surrounded by cicatricial tissue. The fistula and neighboring tissue shut in at the bottom of a deep pouch extending across the vagina. Operation successful.	93
CASE XXXI. Fifth pregnancy; delivered by version, after a labor of eight hours and a half. A vesico-vaginal fistula, where nineteen attempts had been made to close it previous to admission. Found no cervix uteri, but two openings in the median line, high up in the vagina, leading into the bladder, with a septum between the two, about half an inch in width. This septum was divided, when it was ascertained that the fistula was situated immediately in front of the remains of the cervix. Its edges were cicatricial, and the loss of tissue had been extensive. Healthy tissue was brought together from beyond over the opening, and closed by one operation in the axis of the vagina.	94
CASE XXXII. First pregnancy; instrumental delivery, after a labor of about ninety hours. Fistula in front of the cervix. Partially closed by an operation previous to admission, but, by the use of the cautery afterward, the surrounding tissue had become cicatricial. No union after the first operation. The second operation successful, by removing the unhealthy tissue.	96

## CHAPTER VIII.

### FISTULÆ INVOLVING THE BASE OF THE BLADDER.

CASE XXXIII. Fourth pregnancy; instrumental delivery, after a labor of twenty-one hours. Child weighing sixteen pounds. Loss of the whole base of the bladder. The fistula was more than three inches in length and extended ob-	
--	--



	PAGE
likely to the right, across the axis of the vagina, from contraction of bands in the cul-de-sac. Closed by one operation. A small opening subsequently occurred from getting up too soon. Second operation successful. By traction, a portion of the line separated which had been closed by the first operation. By the third operation, but partial union was obtained. Discharged for disorderly conduct, readmitted afterward, and discharged, cured by the next operation.	98
CASE XXXIV. Second pregnancy; instrumental delivery, after a labor of ten hours. The fistula extended obliquely across the axis of the vagina, from the right of the cervix uteri to the left of the neck of the bladder. Operation successful, and at the third month of pregnancy.	104
CASE XXXV. Fourth pregnancy; delivered by forceps, after a labor of fifty-one hours. Loss of the entire base, with the neck, of the bladder. The fistula was closed by bridging over the opening with vaginal tissue turned into the bladder.	106
CASE XXXVI. First pregnancy; in labor forty-five hours, and delivered by forceps. Loss of the whole base of the bladder. The fistula was closed, after dividing the bands in the cul-de-sac, by drawing down the cervix uteri, and uniting it to the neck of the bladder.	109
CASE XXXVII. Fourth pregnancy; one hundred and five hours in labor; delivery by forceps. The whole base of the bladder lost by sloughing, with the inner face of the left ramus denuded. The fistula was closed by three progressive operations.	110
CASE XXXVIII. First pregnancy; in labor about fifty-eight hours, and delivered by forceps. A fistula existed, involving a loss of the whole base of the bladder, with the face of each ramus nearly denuded; the inverted bladder, with a portion of intestine, frequently became strangulated by protruding through the fistula. Closed by one operation.	113
CASE XXXIX. First pregnancy; in labor two hundred and twenty-four hours; delivered by forceps. Loss of the whole base of the bladder, the cervix uteri, and cul-de-sac, with the inverted bladder protruding through the fistula in the midst of cicatricial tissue. By four operations the opening was nearly closed; she was discharged to recruit. Readmitted, and cured by the fifth operation.	114
CASE XL. First pregnancy; natural delivery, after a labor of twenty-four hours. Loss of nearly the whole base of the bladder, a portion of the neck of the uterus, and the cul-de-sac. The fistula crescentic in shape, and the vagina shortened, by contraction of cicatricial tissue, to an inch and a half in depth. After a preparatory operation, for enlarging the vagina and dividing the bands, the fistula was closed by two operations.	117
CASE XLI. Tenth pregnancy; ninety-five hours in labor; delivered by hand. Loss of right half of the base of the bladder, with shortening of the vagina, and the fistula hidden by folds. Closed by one operation.	120
CASE XLII. First pregnancy; in labor one hundred and five hours; delivered by forceps. Urine not voided during the time in labor. Loss of the left half of the base of the bladder. Closed by one operation.	122
CASE XLIII. Second pregnancy; in labor ninety hours; delivery accomplished by the efforts of nature. The left half of the base was lost by sloughing, with the neck of the uterus and cul-de-sac. The vagina was shortened and narrowed, with occlusion of the uterine canal. By two operations the fistula was closed. A small opening subsequently formed, which closed by contraction.	123
CASE XLIV. Fourth pregnancy; seven hours in labor; natural delivery. Loss of the entire base of the bladder, with bands extending from each side of the cervix uteri to the pubes, which, by contraction, shortened the vagina and drew down the cervix uteri nearly to the neck of the bladder. The first and second operations were but partially successful; the third one entirely so.	126
CASE XLV. First pregnancy; eleven hours in labor; delivered by forceps. Nearly the whole base was lost and the uterus left immovable. The fistula was closed by splitting its posterior edge and drawing forward the bladder or under portion, which was united to the anterior edge of the opening.	128

- CASE XLVI. In labor eighty-one hours; first pregnancy; natural delivery. Two fistulæ, one near the neck of the bladder, to the right, and the other near the cervix, on the same side. Vagina shortened by a cicatricial band extending from the lower fistula across the vagina to the left, around in the cul-de-sac, to the upper opening. Each closed by a single operation. - 130

## CHAPTER IX.

### FISTULÆ, WITH OCCLUSION OF THE VAGINA, PARTIAL OR COMPLETE, POSTERIOR TO THE OPENING INTO THE BLADDER.

- CASE XLVII. First pregnancy; in labor one hundred and two hours; delivered with forceps. A transverse fistula extended across the vagina, about two inches from the mouth of the urethra, and, from its posterior lip, the vagina was entirely occluded beyond. The uterus could be felt from the rectum, embedded in a mass of tissue resulting from pelvic cellulitis. The fistula was closed by uniting its anterior lip to the posterior wall of the vagina. - 134
- CASE XLVIII. First labor, lasting five days; delivery with forceps. A transverse fistula at the neck of the bladder, with occlusion of the vagina beyond. The fistula closed by one operation. The vagina was opened five times by the knife, each operation unsuccessful, with subsequent retention of the menstrual flow. Finally, a satisfactory result was obtained by laceration. - 136
- CASE XLIX. First pregnancy; no labor pains; delivery by forceps, six days after rupture of the membranes. The vagina was narrowed at the depth of an inch and a half, a transverse fistula beyond, with perfect occlusion of the canal from the posterior edge of the opening. The vagina was opened to over three inches in depth, without detecting the position of the uterus. The fistula into the bladder was closed after two operations, by bringing together the tissue along the axis of the vagina in two folds, and shutting up the fistula at the bottom of a pouch. - 143

## CHAPTER X.

### FISTULÆ, WITH PARTIAL OCCLUSION OF THE VAGINA ANTERIOR TO THE OPENING INTO THE BLADDER.

- CASE L. First pregnancy; in labor forty-eight hours, and delivery by forceps. Entrance to the vagina nearly closed, from contraction of a circular slough. Outlet opened, the whole base of the bladder was found to have been lost, with the cul-de-sac destroyed, and the vagina shortened to an inch and a half in depth. The vaginal canal was opened to the depth of three inches, and the fistula closed. Shortly after the sutures had been removed, the angle behind the right ramus separated; this was closed by a subsequent operation. 149
- CASE LI. First pregnancy; five days in labor; artificial delivery. The vagina was nearly closed at the depth of an inch. After this contraction had been divided, it was found that nearly the whole base of the bladder had been lost beyond, together with the cul-de-sac, the os uteri occluded and the vagina shortened, with evidence of previous pelvic cellulitis. Several operations were performed for opening the vagina, and the last was followed by an attack of pelvic cellulitis. The fistula was closed, but the sutures were removed soon afterward, in consequence of hemorrhage. A second operation was abandoned from excessive hemorrhage, but a third one was successful. 151
- Second pregnancy, twins; partial occlusion of the vagina, with the antero-posterior diameter found contracted to  $2\frac{5}{8}$  inches. Twenty-eight hours in labor; delivered by perforation, the first child presenting by the breech, the second by the head. Recurrence of the fistula in the old line, and subsequent contraction of the vagina. The fistula again closed, and the vagina allowed to contract after the operation, to guard against the recurrence of pregnancy. - 153

	PAGE
CASE LII. First pregnancy; about fifty-one hours in labor; delivery by forceps. Vagina shortened and partially occluded by bands crossing the vagina. After division of the bands, the fistula was exposed, and found situated in front of the cervix. The edges of the fistula, with the surrounding cicatricial tissue, were removed, and the opening closed by one operation.	155
CASE LIII. Sixth pregnancy; one hundred and fifteen hours in labor, and delivery by forceps. Vagina almost closed at the depth of an inch and a half, with destruction of the cul-de-sac. The vagina was fully opened after two operations, and the fistula in front of the cervix closed by one operation.	156

## CHAPTER XI.

### FISTULÆ, SITUATED IMMEDIATELY BEHIND THE RAMI.

CASE LIV. First pregnancy; fifteen hours in labor; delivery by forceps. The vagina was almost closed throughout its length, with loss of the cul-de-sac. Vagina opened by the scissors, laceration, and the knife. The fistula was found situated immediately behind the left ramus. Several days after removing the sutures used for the first operation, a small opening occurred from traction, in consequence of the surrounding cicatricial tissue. This opening remained closed after a second operation.	158
CASE LV. Fourth pregnancy; seventy-four hours in labor, and delivery by forceps. A triangular-shaped fistula situated immediately behind the left ramus. Before the opening could be brought fully into view or closed, it was necessary to dissect its base free from the bone. Closed by one operation.	161
CASE LVI. Fourth pregnancy; in labor forty-four hours; natural delivery. The fistula was similarly situated behind the left ramus, as in Case LV, but with less sloughing; while the soft parts being more yielding, it was closed by one operation, without being freed from the bone.	162
CASE LVII. Sixth pregnancy; about twelve hours in labor; delivery by traction. The fistula was situated behind the right ramus, lessened in size by the contraction of cicatricial tissue, and the vagina shortened by a cystocele. The fistula was closed by an operation for the relief of the cystocele.	163

## CHAPTER XII.

### FISTULÆ AT THE NECK OF THE BLADDER.

CASE LVIII. First pregnancy; natural delivery; forty-eight hours in labor. A transverse fistula was found at the neck of the bladder, with loss of the cervix uteri and cul-de-sac. By contraction of cicatricial bands extending along the lateral walls, from the cul-de-sac to the outlet of the vagina, the canal was shortened, with a resulting cystocele. The fistula was closed by the first operation, with the exception of a small opening. At the second operation the small opening was closed by the one instituted for the relief of the cystocele.	166
CASE LIX. Fourth pregnancy; in labor one hundred and two hours; delivery by forceps. After great loss of tissue and narrowing of the vagina, a small opening was left at the neck of the bladder, which was brought into view on separating two deep folds; these were formed by contraction of cicatricial tissue, and extended under the arch of the pubes, downward and backward on to the recto-vaginal septum. Fistula closed without dividing the bands, for had they been incised, incontinence of urine would have resulted, as the neck of the bladder had been lost.	168
CASE LX. First pregnancy; in labor seventy-one hours; natural delivery. An opening at the bottom of a sulcus, through the neck of the bladder, three inches in length, extended from one ramus across to the other, with its angles drawn up behind the bone, from contraction of a circular slough around the outlet of the vagina. After the operation, the catheter could not be passed beyond the	

- PAGE
- line of union, as the two sections of the urethra had not been brought together in perfect correspondence. By untwisting several of the sutures, this was accomplished, and the operation proved successful. 169
- CASE LXI. Second pregnancy; in labor sixty-two hours; delivery by forceps. After a loss of the whole base of the bladder, the fistula was closed by Dr. Sims. Several months after her discharge, the line of union separated. An opening found in front of the neck of the bladder was closed, but the operation was unsuccessful. Failure due to bands in the cul-de-sac, which produced tension while lying on the back; these were divided, and the second operation was successful. - 171

### CHAPTER XIII.

#### FISTULÆ INVOLVING THE URETHRA, FROM LACERATION OR SLOUGHING.

- CASE LXII. First pregnancy; the head born at the end of seventy-four hours; pains then ceased; body delivered fifteen hours afterward, by traction. The urethra lacerated entirely through, half an inch from the meatus. The distal portion of the canal was so dilated that a large portion of the mucous membrane protruded. The difficulties of the operation consisted in passing the sutures so as to bring perfectly into apposition the two sections of the canal, of different diameters. Operation successful. - 174
- CASE LXIII. First pregnancy; about ninety-eight hours in labor; breech presentation; instrumental delivery. An opening caused by sloughing at the neck of the bladder, with loss of a portion of the urethra. A new urethra made by puncture, and the fistula closed afterward. - 176

### CHAPTER XIV.

#### FORMATION OF A NEW URETHRA BY AID OF PLASTIC SURGERY.

- CASE LXIV. First pregnancy. The head born in ten hours, but the body remained undelivered for some fourteen hours afterward, when it was removed by traction. In labor about twenty-four hours. Outlet of the vagina nearly closed by a circular slough. Loss of nearly whole urethra, the sub-pubic tissue, and that posterior to the bone for half an inch. The whole base of the bladder, the neck of the uterus and the cul-de-sac were destroyed, with the vaginal canal shortened to an inch and a half in depth. During three years, and after some twenty operations, a new urethra was formed by aid of plastic surgery, the fistula closed, and the vagina opened to three inches in depth. She was discharged with perfect retentive power, but obliged to use the catheter. After several attacks of cystitis, at the end of eighteen months, a portion of the line was opened for the removal of calculi, and not again closed. 180
- CASE LXV. Second pregnancy; in labor about ninety-two hours, and delivery by forceps. Loss of the whole base of the bladder, the cervix uteri, and laceration in the median line almost to the vesico-uterine junction, with destruction of the neck of the bladder and nearly the whole urethra. The uterus was immovable and drawn to the right side.
- At the end of two years, and after eleven operations, the fistula was bridged over. A new urethra was then made throughout, and, after three additional operations, she was discharged, with voluntary retentive power. - 191

### CHAPTER XV.

#### RECTO-VAGINAL FISTULÆ, RESULTING FROM PARTURITION.

- Frequency of rectal fistulæ, generally smaller in comparison after contraction has taken place, than where the bladder has been involved. Usual shape; cul-de-sac generally injured. The preparatory treatment more tedious in recto-vaginal fistula. Proportion of cases, in the same subject, where both the rectum and

	PAGE
bladder have been injured. The vesico-vaginal fistula should be closed first. Operations on the rectal septum more difficult than on the opposite side of the vagina. Mode of operating. Detail of cases. Description of the operation after laceration of the perineum, when the same condition is produced by division of the parts for the closure of a small fistula situated immediately behind the sphincter muscle.	198
<b>CASE LXVI.</b> Eighth pregnancy; eighty-four hours in labor; delivery by forceps. A rectal fistula, crescentic in shape, with its cornua toward the cul-de-sac, and extending from half an inch beyond the fourchette to the cervix uteri. A vesico-vaginal fistula also existed, which was closed by one operation. From traction, the edges gradually separated after the first operation for closing the rectal opening. After the second operation, a small opening remained; the third operation was successful.	200
<b>CASE LXVII.</b> First pregnancy; time of labor unknown; delivery by craniotomy. Transverse vesical fistula, with loss of the neck of the bladder. Closed by one operation. A recto-vaginal fistula existed behind a fold of the posterior wall of the vagina, formed by contraction of cicatricial tissue around the outlet; this band could not be divided for the purpose of exposing the rectal opening, as its presence afforded a retentive power to the urethra. The cul-de-sac had been destroyed, with loss of the neck of the uterus. The rectal fistula was successfully closed by one operation, performed almost entirely by the sense of touch, as the opening could not be brought into view.	203
<b>CASE LXVIII.</b> First pregnancy; in labor sixty-five hours, and delivered by the efforts of nature. A recto-vaginal fistula, in the median line, an inch in diameter, with thin and tense edges. Two parallel incisions were made in the axis of the vagina to free its edges. Closed by two operations. There existed also a small vesico-vaginal fistula, which was not discovered until after the first operation for closing the rectal opening. When this had been closed, the second operation for the rectal fistula proved successful.	206
<b>CASE LXIX.</b> First pregnancy; in labor about one hundred and forty hours; delivery by forceps. A small recto-vaginal fistula, about an inch from the fourchette, and to the left side of the vagina. In consequence of its shape and position, it was closed by dissecting off a flap from the lateral wall, which was folded down over the fistula, so that, when secured, the vaginal tissue had been turned into the rectum.	210

## CHAPTER XVI.

### VESICO AND RECTO-VAGINAL FISTULÆ NOT RESULTING FROM PARTURITION.

The effects of malignant disease; abscesses between the bladder and uterus, or in the broad ligaments; stone in the bladder, following the operation for vesico-vaginal fistula, and from paralysis, cutting through the vaginal septum; syphilitic abscesses and ulcerations, perforating the rectal septum, and injuring the urethra; Hodges' pessary ulcerating into the bladder; a fistula remaining after the passage of a pistol-ball from the vagina through the base and fundus of the bladder. Absence of the anus, with the rectum opening into the vagina; operation. A patulous condition of the urethra sometimes found when the vagina and uterus are wanting.	217
<b>CASE LXX.</b> An abscess between the bladder and uterus, which discharged by an outlet communicating with the bladder and vagina. The sinus from the vagina was laid open into the bladder and closed by one operation.	219
<b>CASE LXXI.</b> A vesico-vaginal fistula behind the left ramus, caused by pressure of a pessary, which had been worn for five years. Opening closed by one operation.	220
<b>CASE LXXII.</b> Vesico-vaginal fistula, resulting from a pistol-ball, which entered the thigh, and passed from the vagina, through the bladder and abdomen. No union after the first and second operations, from the occurrence of cystitis. Third operation successful.	221

## CHAPTER XVII.

## CONGENITAL ABSENCE OF THE ANUS, WITH THE RECTUM OPENING INTO THE VAGINA. PATULOUS CONDITION OF THE URETHRA FOUND WHEN THE VAGINA AND UTERUS ARE WANTING.

Operation for forming an artificial anus in a child, the rectal opening into the vagina to be closed at puberty.

Congenital absence of the anus in the adult; this condition met with in two cases, with vesico-vaginal fistula resulting from parturition; in each case the fistula was closed, but no attempt was made to remedy the condition of the rectum. Supposed anatomical condition of the external sphincter, where the perineum is absent. Operation proposed for forming a false passage from the rectal opening, to prevent the presence of feces in the vagina. - 227

Urethral canal usually undeveloped in cases of congenital absence of the vagina and uterus. Cases cited. Patulous condition at the neck of the bladder, retentive power due to loose folds of cellular tissue. Case given where this condition existed, where the woman had lived as a wife for two years in ignorance of the absence of the vagina and uterus. Formation of an artificial vagina necessary in these cases, before an attempt can be made for extending the urethral canal. Operation for forming a vaginal canal; result in a case; subsequent marriage. 229

## CHAPTER XVIII.

## UNCLASSIFIED CASES OF VESICO-VAGINAL FISTULA.

DEATH FROM PYÆMIA FOLLOWING AN OPERATION FOR VESICO-VAGINAL FISTULA.  
DEATH FROM URÆMIA, AFTER ENLARGING, FOR THE RELIEF OF CYSTITIS, THE TRACT OF A PELVIC ABSCESS COMMUNICATING WITH THE BLADDER AND VAGINA.

ACCIDENTAL OPENING INTO THE PERITONEAL CAVITY, DURING AN OPERATION FOR VESICO-VAGINAL FISTULA, WITHOUT ANY BAD CONSEQUENCES.

CASE LXXIII. First pregnancy; delivery by craniotomy, after a labor of one hundred and three hours and a half. A small vesico-vaginal fistula existed about the centre of the base of the bladder. Peritonitis followed the operation. The use of catheter was discontinued after the second day, and the urine drawn at intervals. After the sutures were removed, the union was found perfect, and the bladder had full retentive power, until her death from pyæmia, six weeks after the operation. - 233

CASE LXXIV. Cystitis, resulting from cold of eighteen years' duration; followed by a pelvic abscess, which soon afterward opened into the vagina. Fifteen months previous to admission, incontinence of urine suddenly took place, with partial relief of the cystitis afterward.

The vesico-vaginal sinus was enlarged, so as to allow of the free escape of urine. Death from uræmia, forty-eight hours after the operation. 237

CASE LXXV. First pregnancy; one hundred and twelve hours in labor; instrumental delivery. Anterior wall of the vagina drawn into a fold in front of a small fistula, situated at the bottom of a cul-de-sac.

The neck of the uterus had been lost by sloughing, and the vagina terminated at the posterior edge of opening into the bladder.

During the operation for denuding the edges of the fistula, the peritoneal cavity was accidentally entered. This opening was closed in line with the edges of the fistula. No bad consequences supervened. Operation successful. 242

INDEX - - - - - 245

## INTRODUCTION.

---

PRIOR to the application of the metallic suture by J. MARION SIMS, and a proper mode of exploration furnished by his speculum, any attempt for the relief of the injuries under consideration was uncertain in result, and the operation regarded as an opprobrium by the profession. Since that time, however, it has become more certain of success than any other operation in surgery, and long since should have ceased to be confined to the hands of comparatively a few operators. In truth, no more brains or tact is needed in the execution of this than in many other operations of surgery which have long since become familiar to the many. The attempt will be made to satisfy the profession on this point, if possible, with the belief that the same fitting for a skilful operator elsewhere, will insure an equal success in at least half the cases which will come under observation. This will certainly apply in any case where the edges can be brought together without tension. In exceptional cases, where the loss of tissue has been great, I hope to point out the chief difficulties by such examples as may prove sug-

gestive to the ingenuity of the operator in an approximating case.

That I may not be deemed egotistical, it is proper I should state, from my connection with the Woman's Hospital, almost since its foundation, as Dr. Sims' assistant, and as Surgeon of the institution for the past six years, I can speak with some authority on this subject. With the benefit of his experience in probably several hundred operations, I find, during the past five years, that for nine months in each year I have averaged nearly two operations a week, in public and private practice. By far the greater number of these cases have been in hospital practice, and, with scarcely a single exception, each operation has been witnessed by different members of the profession unconnected with the institution. It may be a matter of surprise that the number of these cases should be so large, but the fact must not be lost sight of, that the institution was originally established for the relief of such cases, and that they are received from all parts of the continent, while for years the accommodation has not been equal to the supply.

In vindication of the profession it is but just to state, that among those who have had the benefit of proper care, and have been delivered in this country, the proportion is no greater than among those who had already received the injury previous to their emigration. It is true, however, that the greater number were natives of the country, or had been injured since their arrival; but as a class, they belonged to the poorest, had not received proper attendance, or were from the frontier or thinly-settled sections of the country; while in my experience the injury has been an exceedingly rare one among the better class.



It may be stated as a principle, that scarcely any case can be regarded as incurable, in consequence of the loss of tissue alone. If the case is undertaken, a retentive power of the urine will be gained in time, although it may be impossible to restore the vagina. The operator, however, like an engineer, must fully appreciate the peculiarities of the situation, and make each point available in his defense, and his success will be in proportion to his ingenuity in turning to the best account the peculiar features of each case. Unfortunately, nevertheless, in many difficult cases, the patient is either in indigent circumstances or unable to spare the necessary time from her home duties; and withal, during the many progressive operations so often requisite, the faith of the sufferer, as well as the patience of the operator, must often be severely taxed. The soft parts are susceptible of such great modification that it is often impossible for the surgeon to fully anticipate from the first what may be the result of his labors. It is only step by step, as the parts are relieved of tension, that they become moulded to their new condition. A full conception of what may be accomplished can only be formed with the gradual disappearance of the cicatricial tissue, and after a more healthy condition has been brought about by proper treatment.

Previous to October, 1867, I had had about two hundred and seventy cases under my charge. About two hundred had been cured, five I had regarded as incurable, and between fifty and sixty returned home improved, the greater proportion of which will be cured if they ever return. The cause which obliged me to abandon as wholly incurable several of the cases was not so much in conse-

quence of the actual extent of injury sustained, as from excessive obesity, which rendered it impossible to bring the parts in view. In others, from the fact that through great irritability of the nervous system, they were unable to bear a long operation on the knees, in the position necessary for their particular case. Many of those who returned home at different stages of treatment, did so by my advice, either to recuperate, or to await the efforts of nature in bringing about some desirable change in the parts, previous to another operation, and have never returned, from want of means or faith. Others have gone away, after months spent in careful preparatory treatment, without waiting for a final operation, being satisfied with their improved condition; and a small number have been discharged for disorderly conduct. Many of these cases have been relieved afterwards by an operation at home, and some have been placed on record as cases which were discharged incurable from the Woman's Hospital, while the operator did not realize how much had been accomplished for him, or that the mere closing of the fistula was not the most difficult part after the case had been already properly prepared.

Since November, 1867, to May 1st, 1868, twenty-six new cases have been admitted to the hospital, all of which required a certain time of preparation before an operation. Of these, ten cases have been cured, three have returned home without waiting for an operation, but will be cured without difficulty when readmitted. Two were discharged as incurable; one of these had lost the urethra from syphilitic sloughing. The other, a negro woman from Wilmington, N. C., where the whole base of the bladder had

been lost, together with the urethra and tissues under the arch of the pubis, while the vagina had been obliterated, and all trace of the uterus lost. The case could scarcely have been a worse one, and yet, in time, the vagina could have been restored, the fistula closed, and a new urethra formed. But, unfortunately for her, an exostosis, which no doubt was the cause of delay in her delivery, existed on the inner face of the pubis. In consequence of this growth, a new urethra could not be formed without opening so high, as to make it necessary to wash out the bladder daily. Without great care and this precaution, on the retention of phosphatic urine, calculi would have formed and the labor of months been soon lost. Case LXIV, with the exception of the growth, was a similar one in every respect, and although successful, the result demonstrated that the undertaking would be a waste of time without a sufficient intelligence on the part of the patient. Of the remaining cases in the hospital all will be cured within a few months, and three of the number have not yet been operated on.

After some general remarks on these injuries, the proper mode of preparing the patient will be treated of, with the necessary instruments, the method of operating which has proved most successful in my hands, and the after-treatment. A series of cases will then be presented, divided into chapters for convenience, but under the following general classification: 1st. *Fistulæ* from laceration of the cervix, with or without sloughing, and involving a portion of the base of the bladder. 2d. From sloughing of some portion or loss of the whole base, with cases of atresia of the vagina, partial or complete. 3d. Loss of the entire base of the

bladder, the cervix uteri, and the urethra. 4th. Some cases of Recto-vaginal Fistulæ, with points of difference in treatment or operation, not in common with the injuries of the bladder. 5th. Cases of Recto- and Vesico-Vaginal Fistulæ, not resulting from parturition.

## CHAPTER I.

DEFINITION AND CAUSE. DELAY DANGEROUS AFTER IMPACTION.  
EXTENT OF INJURY DUE TO POSITION, AND NOT ALWAYS  
IN PROPORTION TO THE LENGTH OF LABOR. TREATMENT  
AFTER RECEPTION OF INJURY. PREPARATORY OPERATIONS  
IN FREEING SOFT PARTS PREVIOUS TO CLOSING A FISTULA.

A VESICO-VAGINAL fistula following parturition may be defined as an opening from sloughing into the bladder, resulting from delay in delivery after impaction has taken place.

The exceptions to this rule are those caused by rapid labor, lacerating the neck of the uterus and extending beyond so as to involve the base of the bladder, together with lacerations at its neck, which sometimes occur on delivery by forceps.

The accepted teaching, to wait any given length of time after the occurrence of impaction, with the hope that nature may yet accomplish the delivery unaided, is, as a rule, attended with great danger.

After a careful review of all the recorded cases admitted to the Woman's Hospital, since its foundation (some twelve years ago), I could not satisfy myself that more than three cases out of the whole number should be regarded as having resulted from instrumental delivery. These were cases of malpractice, and of no value in a statistical point of view.

An escape of urine frequently follows immediately after delivery by forceps, but only as a result of the slough, which had already taken place, and at the time partially detached.

In accepting the teaching based on so large a record, I believe that, after impaction has occurred, a novice (if familiar with the mechanism of labor), would be likely to do less damage to the soft parts in applying the forceps or in using the perforator, than in leaving the case to nature, as is frequently done. I have known the greater part of the base of the bladder lost by subsequent sloughing, after an impaction of the head for only two hours; and again, we have cases on record which had been left to nature undelivered, from a week to ten days, and one over a week after the head had passed the vulva. It is evident therefore that the average duration of labor cannot be taken as a guide; for the injury had actually resulted long before delivery, although the slough may not have been separated for a week or two afterward, as is frequently the case. The only deduction that we can draw from experience is, that the lower the head is left in the pelvis, the greater is the danger, and that less than two hours even is sufficient to cause extensive loss of tissue; also, that the amount of injury is by no means in proportion to the length of labor. Therefore, the only safety consists in as speedy a delivery as the circumstances of the case will admit.

Unless the greatest care has been given to cleanliness, the sufferer, in a few weeks after receiving the injury, becomes a most loathsome object. From the irritation of the urine, the external organs of generation become excoriated and œdematous, with the same condition extending over the buttocks and down the thighs. The labia are frequently the seat of deep ulcerations and occasionally of abscesses. The mucous membrane of the vagina is in part lost, and the abraded surface rapidly becomes covered at every point with a sabulous or offensive phosphate deposit from the urine. If the loss of tissue has been extensive, the inverted posterior wall of the bladder protrudes in a

semi-strangulated condition, more or less incrustated with the same deposit, and bleeding readily. This deposit will frequently accumulate to such an extent in the vagina that the sufferer becomes unable to walk or even to stand upright, without the greatest agony.

The deposit must be carefully removed as far as possible by means of a soft sponge, and the raw surface brushed over with a weak solution of nitrate of silver. If, at any point, it cannot be at first removed without causing too much bleeding, the deposit itself must be treated in the same manner, or coated with the solid stick. Warm sitz-baths add greatly to the comfort of the sufferer. The vagina must be washed out several times a day with a large quantity of tepid water. After bathing, it is best for the patient to protect herself by freely anointing the outlet of the vagina and the neighboring parts with any simple ointment. She must be instructed to wash her napkins thoroughly when saturated with urine, and not simply to dry them for after-use. Time, and increased comfort of the patient, are gained by judicious attention to such details.

About every fifth day, the excoriated surfaces yet unhealed should be protected with the solution of nitrate of silver; and it is frequently necessary to pursue the same general course for many weeks, before the parts can be brought into a perfectly healthy condition. This point is not reached until not only the vaginal wall, but also the hypertrophied and indurated edges of the fistula, have attained a natural color and density. This is the secret of success; but the necessity is rarely appreciated; without it, the most skilfully performed operation is almost certain to fail.

When the proper condition has been brought about, the surgeon may then be able to decide upon some definite plan of procedure for the closing of the fistula.

The edges should be seized at opposite points with a tenaculum, held in either hand, and the degree of tension judged by an approximation in different directions. If, at any point, the edges do not come readily together, the finger can detect the seat of resistance, while the parts are kept on the stretch by a tenaculum in the other hand. When the bands are comparatively slight and superficial, or brought well up by traction, it is generally sufficient to divide them with scissors at the time of the operation for closure. But, on the contrary, when the tension is due to more extensive sloughing, or when the cul-de-sac has been destroyed, the parts can seldom be properly freed without more or less hemorrhage as a complication, and it will be necessary to make one or more preparatory operations.

Placing the patient on the back, with two fingers of the left hand introduced into the rectum as a guide, and the thumb into the vagina to make counter-pressure, freely snip with a pair of blunt-pointed scissors, point after point, as indicated by the pressure of the thumb. This can be done to any extent without the speculum, and without fear of entering either the rectum or the bladder, if the position of the uterus is recognized, and a proper use is made of the fingers in the rectum as a guide.

After opening up the vagina as freely as is deemed prudent at the time, a glass vaginal plug, only just long enough to put the canal well on the stretch, without fear of producing sloughing or pelvic inflammation by too great length, should be introduced, and secured in place by a T bandage. The instrument has a sufficient rim to prevent it from slipping into the vagina, with a depression to receive the urethra along its course and to protect it from pressure. This useful instrument was devised by Dr. Sims, and is fully described in his *Clinical Notes on Uterine Surgery*.

The hemorrhage is sometimes excessive, but is generally



controlled as soon as the plug is introduced; and, as the instrument is hollow, it possesses all the advantages of a speculum in exposing the condition above. If the blood, however, begins to escape along the sides of the plug, it can be controlled by introducing, with a pair of dressing forceps, portions of damp cotton along the depression made for the urethra while rotating the instrument, until the outlet of the vagina has been encircled by a tampon, and the starting point regained. It is remarkable how much can be accomplished by absorption in a few weeks with judicious pressure excited by this instrument on cicatricial tissue.

Experience has fully demonstrated that the use of the scissors is preferable to that of the knife; with less risk of inflammation and certainly less hemorrhage. Cicatricial tissue, lacerated or divided by scissors, as will be shown hereafter, does not heal so rapidly, and time is consequently gained wherein to bring about this absorption.

The patient should be lifted into bed and kept there for a week or ten days. Opium should be administered freely, if needed. The urine can be drawn by a catheter, if necessary, without removing the instrument, for, if there has been much hemorrhage, it is not well to do this until it has become somewhat loosened by the discharge. When it is deemed safe to remove the plug, then large warm water injections, with a little castile soap, should be continued daily, and oftener if the discharge is profuse. After the parts have been properly healed, if necessary, repeat the operation for enlarging the canal, until the object in view has been attained.

## CHAPTER II.

### INSTRUMENTS NECESSARY FOR THE OPERATION.

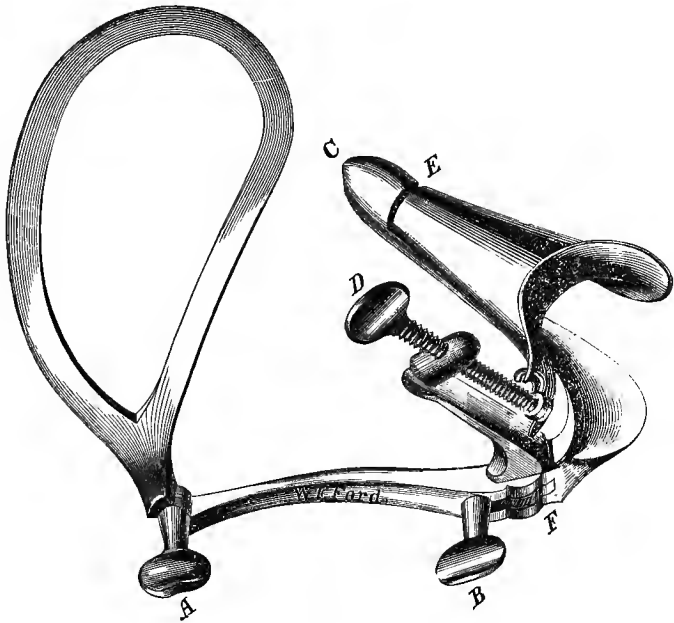
THE following instruments are needed:—a speculum, several tenaculi, a blunt hook, scissors of various curves, a ball and socket or universal-jointed knife, needles, needle forceps, a “feeder,” forceps for securing the wire in the silk loop, twisting forceps, a shield, and in addition, a number of probang sponges, proper silver wire, and two block-tin catheters.

Sims' speculum is by far the best instrument of all others for this operation, if properly held. If, however, a good assistant cannot be obtained, a very good substitute is a self-retaining speculum (Fig. 1), which I have lately perfected so as to answer exceedingly well in a large majority of cases. But, without several blades of different lengths are provided, it will not always answer so well as Sims' instrument, in consequence of frequent change in the depth of the vagina from sloughing, to which condition the latter instrument can be always regulated by the manner of holding it. The self-retaining speculum withdraws the perineum and elevates the upper labium, as is done with the other instrument, and for the treatment of uterine disease, will bring the cervix uteri into view with the same facility.

Where it fails to accomplish this, without there is something unusual in the case, the workmanship is imperfect, or it has been improperly introduced. The semi-prone position on the left side, as with Sims' instrument, is to be used; and it is equally as important that in detail the

proper position should be observed. If the patient is not

FIG. 1.



unusually stout, the thumb-screw at A is tightened so that the fenestrated blade will be held stationary at a right angle, as represented in Fig. 1. In proportion to the development of the buttock must the blade be opened or closed towards the vaginal portion. After fully opening the instrument by the screw B, it is to be introduced while the upper labium is elevated with the left hand. It is necessary that the forefinger of the right hand should occupy the whole extent of the portion introduced into the vagina, with the thumb of the same hand placed near the point F, at the outlet of the instrument. After the vaginal portion at C has been carried behind the cervix, the perineum must be firmly pressed backward, and held

until the instrument can be adjusted by the screw B, which beds the fenestrated blade on the upper buttock. Then by turning the screw D, the upper labium is elevated by this section, the joint being at E. If the finger has not been withdrawn from the vagina, and the perineum is kept back until the instrument has been fitted, the cervix will be almost always brought into view. If the vagina, however, is very deep, a depressor may be needed to push back a fold of the anterior wall just in front; then, by seizing the cervix with a tenaculum held in the other hand, and drawing it forward, it will remain in view. The only class of cases in which the instrument is apt to slip, is where the perineum has been lost to a great extent. It is then difficult to get the proper support for the vaginal portion which is turned into the hollow of the sacrum. I have frequently used the instrument for the operation of Fistula, and for that of Procidencia Uteri, where it has remained *in situ* for two hours. The vaginal portion should be of the same diameter nearly throughout its length, until a sudden flare is formed at the outlet to support the labium. The upper section of the instrument, which is lifted and drawn backwards by the screw D, is made much broader than the lower one, but gradually narrowed to the point E. This is to prevent a prolapse of the soft parts, as the section is drawn backwards. When the instrument is adjusted properly, the point A is imbedded in a portion of the lower buttock, while the direction of the sulcus lies between the lines A B and D E, so that the coccyx is not pressed upon.

Sims' tenaculum (Fig. 2) I have made much lighter and

FIG. 2.



FIG. 3.



smaller than the instrument introduced by him; and, in fact, it cannot be made too delicate if properly tempered.

The hook should not be gradually rounded, but somewhat angular, with a slight turn at the point. My friend, Dr. John G. Perry, of the Woman's Hospital, has devised a barbed-pointed tenaculum (Fig. 3), which is a most useful little instrument while denuding the edges, as it prevents the tissues from slipping off when once fairly caught up. The instrument is cleared by sliding the strip towards the handle until it tears out. The blunt hook (Fig. 4) should

FIG. 4.



be made of copper, and silver plated. Its chief use is that of a probe, for detecting small openings, or searching out and raising sutures to be removed, which have become imbedded in the tissues. The hook and tenaculum should be about seven inches in length.

I have for several years confined myself to the use of scissors for freshening the edges, to the exclusion of the knife. Although alike practiced in the use of both, I am satisfied that with the scissors I can complete the scarification in half the time; that no portion is left undenuded, and certainly with less bleeding, for I have not had to delay or abandon an operation, a frequent occurrence for-

FIG. 5.

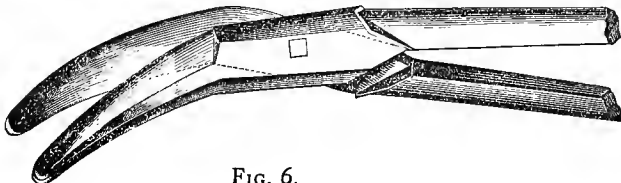
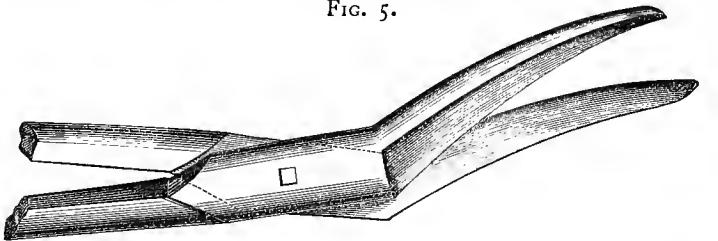


FIG. 6.

merly with the use of the knife. I use scissors with four curves, which are in fact but the reverse of two instruments, with the curve to the right and left. The scissors (Fig. 5) represented with the lesser curve, are those in more common use, and are well represented by the woodcut. The others (Fig. 6) are invaluable for denuding a surface high up and directly in front of the operator. The dip of the curve from the handles, is about 30 degrees, while that to either side, is a quarter of a circle, with the extremity or cutting surface somewhat prolonged at a tangent. It was only after frequent attempts that the surgical instrument maker, Mr. Ford, succeeded in furnishing me with the instruments, and it was accomplished by experiment in making each blade of a different curve, so that, in coming together, they would not bind, and only cut on the point. It has proved almost an impossibility to have this double curve accurately represented by a woodcut, so that I have been obliged to convey by description, the idea.


FIG. 7.



In addition, for dividing cicatricial bands, another pair of scissors (Fig. 7) is of frequent service. They are bent at an angle, but not curved in either direction. These scissors are the same which I use for dividing the posterior lip of the cervix backwards, when that operation is needed for the relief of Dysmenorrhœa. Occasionally the use of the knife is necessary at some inaccessible point. I use generally under these circumstances a ball and socket jointed knife (Fig. 8), which I devised several years ago for operat-

ing in the uterine canal. The blade is of the same shape, but

FIG. 8.




the application of the principle is an improvement on the instrument introduced by Dr. Sims for the same purpose. With a universal joint, the blade can be used in any direction; while his instrument, having a single joint, the blade can only move in the one plane. The woodcut represents the instrument at half size, but the blade is out of proportion: it is usually made an inch and a half in length.

I prefer that the needles should be made from one-half to three-quarters of an inch in length and round, with a slight curve near the point, thickest at the eye, and counter-sunk to receive the thread. These have the advantage of making a punctured wound, which will be perfectly filled by the wire. The needle in general use, which is spear-pointed, or triangular in shape, with a cutting edge, and of many times the diameter of the wire, frequently causes a troublesome oozing of blood after the sutures are secured, and sometimes a small fistula will remain along its track, if by chance its course has been too near the bladder.

The needle forceps (Fig. 9) first introduced by Dr. Sims,

FIG. 9.



can scarcely be improved in regard to firm grasp, and for inserting the needle at any angle. I have, however, modified the instrument somewhat by shortening the jaws, which gives greater facility for introducing the needle in a confined space. A spring has been placed between the handles, the fenestræ for the fingers removed, and a rough flattened surface substituted, so that it can be firmly grasped in the palm of the hand. The dressing forceps (Fig. 11) is made on the same principle, but much smaller than would answer for passing the needle. The surface to grasp the needle should be deeply serrated, and not filled with lead, as is usually done by the instrument makers of this city, with the idea, that as the needle is pressed into the metal it will be held firmer.

Frequently, when a suture is passed in a given direction, from the character of the tissues, the strain would cause it to cut out, if drawn through at a sharp angle. To overcome this difficulty, Dr. Sims devised a shallow forked instru-

FIG. 10.



ment (Fig. 10), which is usually called a "feeder." The suture, held in one hand, is passed by pushing with the instrument held in the other, so that one portion after another may be made to pass from the point of exit in the line of introduction. A small pair of forceps is needed for bending flat the silver wire loop when secured to the silk one,

FIG. 11.



which is passed first. For this purpose a strong pair of dressing forceps will answer, but the instrument I use (Fig. 11) is the modified needle forceps in miniature.



The twisting forceps (Fig. 12) I have somewhat modi-

FIG. 12.



fied from the shape used by Dr. Sims, by making the jaws quite straight, and have changed the manner by which the instrument is closed.

Sims' shield (Fig. 13) is used for steadying the suture,

FIG. 13.



and as a guide to the proper twisting point. I prefer that it should always be made of copper, in one piece, and plated, as it is frequently necessary to bend the shank so as to allow the instrument to rest flat over the surfaces to be secured. As usually sold it is seldom properly made, from the fact that the edge, at the bottom of the slit, over which the wire is to be twisted, is too thick. It is an important point, as will be shown hereafter, that this surface should be a thin edge.

A number of Sims' sponge probang-holders (Fig. 14)

FIG. 14.



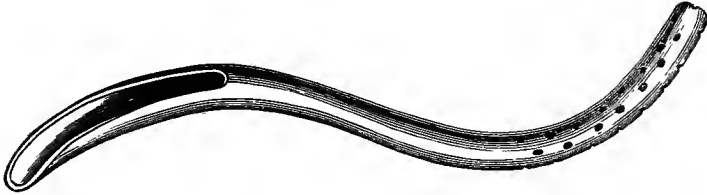
are necessary. They should be made about ten inches in length, of some composition which will not rust, not too heavy, and properly balanced, with the slit extending about half way to the handle, so that a large sponge can be used if necessary.

The silver wire, if properly annealed, and made of virgin silver, is far superior to any quality of iron wire; but the article usually sold by the instrument makers, and made from coin silver, possesses but little or no advantage over

the best quality of iron wire. Nos. 28 and 29 are the sizes used for this operation.

To Sims' sigmoid, or self-retaining, catheter (Fig. 15),

FIG. 15.



we are greatly indebted for success in this operation, as well as for much additional comfort to the patient. It should be made of block-tin, that the curve may be altered to fit each individual case; it should not touch the fundus of the bladder, yet of sufficient length, on being nicely balanced in the urethra, to lie close up behind the pubes. When the fundus of the bladder rests on the point of the catheter, or the instrument is not properly balanced, it will require but little tact to detect the condition or make the necessary alteration. A want of attention to this point, with the resulting irritation of the bladder, will cause a failure of the operation. Perforation of the bladder and death may result, for, I am informed, this happened in the hands of a most excellent operator a short time since.

The catheter is generally made five inches long before bending it to the proper curve; a greater length, however, is necessary if the patient is unusually fat. The instruments already described, are represented by the woodcuts, with as much accuracy as possible, in half size, without a statement to the contrary has been given in the text.

## CHAPTER III.

GENERAL REMARKS ON THE OPERATION. THE TABLE, DRESS OF THE PATIENT, AND POSITION. MODE OF DENUDING THE EDGES. INTRODUCTION OF THE NEEDLE, WITH A SILK LOOP, THE SILVER SUTURE ATTACHED AFTERWARDS. INTERRUPTED SUTURE THE BEST. GREAT ACCURACY OF INTRODUCTION NOT NECESSARY IF PROPERLY "SHOULDERED," AND MODE OF DOING SO. METHOD OF TWISTING, FLATTENING THE SUTURE. INTRODUCTION OF THE CATHETER AND WASHING OUT THE BLADDER. AFTER-TREATMENT. REMOVAL OF THE SUTURES. WHEN THE PATIENT SHOULD SIT UP.

BEFORE operating, the bowels must be thoroughly acted on by a cathartic.

A table, four feet long, thirty inches in height, and twenty-four inches wide, covered with several folds of blankets, should be prepared for the operation.

The patient ought to be dressed in a night-gown and drawers, with the abdomen free from any restraint about the waist.

It is rarely that any other position is needed than on the left side, with the knees flexed on the abdomen, the body well rolled over on the chest, the left arm turned up over the back, and the head elevated as little as possible. If covered with a sheet, and with drawers, the night-gown of the patient should be slipped up around the waist, so as to prevent it from becoming soiled, all of which can be arranged beforehand by a nurse or female attendant. The buttocks must be drawn down to the edge of the table, and a portion of the sheet on which the patient is lying thrown over her, the speculum introduced, and the edges of the sheet

properly tucked in between the legs, so as to prevent unnecessary exposure.

Having decided on the direction for closing the fistula, its edges are to be scarified by seizing with a tenaculum the most depending point, and, with a pair of scissors of proper curve, remove the inner edge in a continuous strip. It requires but little practice to make this in most cases continuous around the entire fistula to the starting point; and, if the denuded portion is not of sufficient width, another strip can be removed just outside of it. The scarification should be extended as near the mucous membrane of the bladder as possible, without actually involving it.

The point of the tenaculum should be introduced toward the fistula, at a convenient distance from its vaginal edge; then, by a rotation of the hand in the opposite direction, the bladder edge of the fistula will be turned out. Introduce the needle behind the tenaculum, bringing out its point just at the bladder surface, and, while still grasping it with the forceps, withdraw the tenaculum, pass its hook over the point of the needle to make counter pressure, while it is advanced as far as the forceps will allow, then seize the exposed portion of the needle, and draw it entirely through. On the opposite side, seize the edge with the tenaculum, in the same manner, and introduce the needle at a corresponding point near the bladder surface.

As a rule, from four to five sutures should be introduced to the inch, and one or more passed at each extremity beyond the fistula, according to the shape of the angle, the necessity for which will be hereafter demonstrated.

The needle should be armed with a short silk loop, and tied with a half-knot at the eye. As each suture is introduced, it is better to follow at once with the wire, for the silk soon becomes weakened after being saturated with the blood and urine. It is secured by hooking a small portion

into the silk loop, mashing it flat at the angle, and giving it one or more turns so that it may not slip.

As to the best method of securing the edges of the fistula, I have an unqualified preference for the simple interrupted suture. Dr. Sims, some ten years ago,\* abandoned his clamp, having demonstrated that the simple interrupted suture, while simplifying the operation, fulfilled every indication, a fact which my experience since has fully confirmed.

When the fistula is a large one, and a number of sutures are required, to save time and some confusion afterwards, shorten the suture by drawing it well through, make a small loop in the short end, and pass the long one through it, to be held behind the speculum by the assistant.

Dr. Sims has always insisted on the importance of introducing the sutures with great care, so that the points of entrance and exit should be at the same distance from the edges of the fistula. The principle is correct, in order to avoid the approximation of a scarified surface with an opposite portion which has not been denuded, in which case, of course, no union would take place. But, in reality, to introduce the sutures with any such degree of accuracy is almost impossible, even with constant practice, and with the fistula in a favorable position. Within a reasonable limit, this great accuracy is unnecessary, if the sutures are properly shouldered at the time of securing them, so that the point of twisting shall be immediately over the line of union. In other words, each end of the suture must be bent flat on itself to the vaginal surface at the point of exit, and at a right angle again just at the edge of the fistula. If this is done with care, and the suture is only twisted up to the angle formed at the edge of the fistula, it is evident that there can be no turning in of either border.

---

\* *Silver Sutures in Surgery*, (page 13,) by J. MARION SIMS, M. D. New York, 1858.

It is generally most convenient to secure, first, the suture nearest the outlet of the vagina. By following up an end from the fistula with a blunt hook or tenaculum, it can be readily disengaged from the others held by the assistant. As the long end is held in the left hand, shorten the loop by traction to about three-quarters of an inch in length. Seize the little slip-knot with the twisting forceps, so as to insure by so doing that both ends of the suture are included within its grasp, and cut off the excess of wire. Make sufficient traction to bring the edges of the fistula together, then shoulder properly with the blunt hook each strand, as already described. After introducing the loop within the slit of the shield, bring the forceps and the handle of the former close together, and twist until the angle formed by the crossing of the two strands of wire is lost just at the edge of the slit in the shield. If this edge has been made of the proper thickness, over which the suture is to be bent by moderate traction as the instruments are brought together, and the twisting is not carried beyond a given point, it is evident that with ordinary care the edges of the fistula will be only just brought into apposition.

The drawing up of the suture with too great traction, and continuing the twisting beyond the proper point, so as to strangulate the parts included within the loop, can be the only cause for a metallic suture ever cutting out, if the parts have been properly freed from tension before the operation.

As it is very necessary that each suture should lie flat on the vaginal surface, after it has been secured, withdraw the shield, and, while still grasping the suture, pass a tenaculum beneath the twisted portion, close to the line of the fistula, in order to lift it up; then bend the wire down by moderate traction over the hook used as a fulcrum, withdraw the tenaculum, and press the wire downward near the

end in the grasp of the forceps, as the latter is made to bend the wire upward in the opposite direction. Cut the wire just at the angle made by pressure of the tenaculum; it will be then found that by thus turning the suture over, and making pressure in the middle, as the free end is bent upward in the opposite direction, the suture will lie perfectly flat. The angle where the suture is to be cut off should be made about half an inch from the edge of the closed fistula.

When there is room to admit of doing so, it is well to turn every other suture to the opposite side, as a guide afterward when they are to be removed, should any of them have become imbedded in the tissues.

After completing the operation, turn the patient gently on the back, introduce a catheter, and, if the urine is discolored, inject tepid water into the bladder for the purpose of washing out any blood which may have accumulated.

The patient must lie the greater part of the time on the back, and, if possible, preserve this position until after the sutures have been removed.

It will add greatly to her comfort to have a double inclined plane, well padded, to support the lower limbs when drawn up; this can be removed from time to time, that the legs may be stretched at full length for change of position. The support should be opened at the ends, with a portion of the side removed, so as not to interfere with the catheter.

As a receptacle for the urine a large-sized oval bird bath-cup is generally used, such as is placed in cages. The catheter must be removed several times a day for the purpose of cleaning it; this is done by forcing from a large syringe a stream of water through it. The patient should be instructed to notice carefully that the urine has a free escape at all times. It is well to have two catheters, so

that one may be introduced immediately on the removal of the other.

A sufficient quantity of opium should be administered daily to keep the bowels constipated until the sutures are removed, and the diet, although a generous one, regulated with a view to this end.

The sutures are usually removed from the eighth to the tenth day, by gently elevating each in turn with the forceps, and clipping the nearest side of the loop, so that, as the suture is being withdrawn, it still continues to bind the parts until cleared.

Twelve hours afterward, a dose of castor oil should be given. The catheter must be continued in use for a few days longer, according to circumstances; and, from the fourteenth to the twentieth day, the patient may sit up.



## CHAPTER IV.

VESICO-VAGINAL FISTULÆ, WITH LACERATION OF THE CERVIX UTERI. THE LACERATION ALONG THE VAGINAL SURFACE BEING SUPERFICIAL OR EXTENDING ENTIRELY THROUGH THE SEPTUM, WITH BUT LITTLE SLOUGHING OR LOSS OF TISSUE AFTERWARDS. THE FORMATION OF CALCULI AFTER INJURIES OF THE CERVIX, AND MODE OF OPERATING FOR THEIR REMOVAL. CHRONIC CYSTITIS TO BE TREATED BY PRODUCING A VESICO-VAGINAL FISTULA; METHOD OF DOING SO, AND TIME OF CLOSING THE OPENING AFTERWARDS.

THIS complication, involving the cervix, is of more frequent occurrence among those who have borne a number of children, and have the abdominal parietes much relaxed, than as a result of a first labor. It may be suspected, therefore, that the cause is due somewhat to rigidity of the os, with an obliquity of the uterus.

In these cases there is always an effort of nature at reparation; a large part of the laceration of the base of the bladder is generally found to have been closed by granulation, and that of the cervix uteri often entirely so. Occasionally, the whole line will be found bridged over, leaving only a fistulous tract at the bottom of the original fissure, and opening into the cervical canal, a little above the line of junction with the vagina.

Anterior lacerations directly in the median line are those most frequently found.

CASE I. In labor one hundred and three hours. Antero-posterior laceration of the cervix uteri, with a fistula extending in the median line from the cervix to the neck of the bladder. Cured by one operation. Stone in the bladder removed eighteen months afterwards.

Mrs. C., aged 44, was admitted to the hospital from Moria, N. Y., Nov. 29, 1864. She menstruated for the

first time at fifteen, married at eighteen, and had given birth to fifteen children. Her general health had been always good until her last confinement.

Labor commenced at full term about noon, Saturday, August, 1864. Rupture of the membranes took place two hours afterwards. The head soon passed through the superior strait, but until midnight the pains were slight; after that time, they came on with more frequency and force, but beyond this point there seemed to be no progress in the advance of the head. A physician was sent for on Monday morning, but nothing was done until Thursday night, when her regular physician, who had been absent, arrived. After some manipulation by hand, in a few moments delivery took place. The child was still-born, and weighed fourteen pounds.

The pains had been almost constant for several days before delivery; she was in labor one hundred and thirty-three hours, while the head was low in the pelvis for one hundred and thirty-one hours. Until Tuesday morning, she had been able to empty the bladder, but from that time until four days after delivery, when it began to escape involuntarily in small quantities, retention of the urine had existed. On the ninth day after delivery she felt a sudden rupture in the vagina, and a large gush of urine immediately followed.

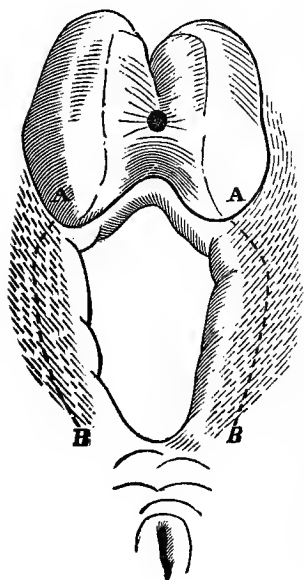
No slough was passed, but the urine, for a long time, was thick and very offensive. She was confined to her bed for eight weeks by debility and loss of power in her left leg.

*Pathological Condition.*—Just in front of the cervix a fistula existed, through which two fingers could be passed into the bladder; although it did not appear on inspection to be so large, yet it extended from the uterus to the neck of the bladder. Laceration of the cervix uteri had occurred in the median line, nearly to the vaginal junction. The

edges of the fistula were composed to a great extent of dense cicatricial tissue, and extended through the fissure in the neck to the os uteri. This band spread out over the vaginal surface in front of the cervix on either side, until it became lost in the tissue towards the cul-de-sac, thus rendering the uterus almost immovable. Through the fistula a large portion of the posterior wall of the bladder protruded in an almost strangulated condition.

From the character of the tissue, it was thought at first that it would be necessary to enlarge the fistula and turn the cervix into the bladder, so that the more healthy tissue in the cul-de-sac could be made available, by drawing it forward and uniting it to some portion of the vaginal wall in front of the fistula. She was, however, placed under a careful course of preparatory treatment, so that by January 27, 1865, her condition was considered favorable for an operation, as the urine had become clear and free from mucus, while the lacerated surfaces were perfectly healed.

FIG. 16.



*Operation.*—An incision was made along the dotted lines A B (Fig. 16), to some depth through the cicatricial tissue. When this was done, the traction of the bands on the outer side separated the edges, so as to present the same appearance as if a broad line of scarification had been made on the vaginal surface. This was continued from A on each side to the os, by removing all the surface lining the fissure, and the points B B were connected by removing a strip of the mucous membrane from the vaginal surface across the neck of the bladder. The tissue was so dense at the bot-

tom of the laceration across the neck, that it could not be entirely removed with the scissors, and it was necessary to freshen the part by scraping with the edge of the scalpel, until a perfectly denuded surface was obtained. By approximating the gaping lines A B, comparatively healthy tissue was brought in apposition, which could not have been obtained had the edges of the fistula itself been used. Ten interrupted silver sutures were introduced, and, when the surfaces had been drawn together, the line was a continuous one from the os uteri to the neck of the bladder.

Feb. 4. When the sutures were removed, the urine was detected escaping through a minute opening just in front of the os uteri, which doubtless ran along the bottom of the fissure, where the angle had not been properly scarified. The quantity of urine escaping gradually became less, and, when the patient was examined, Feb. 14, the opening had closed. She was discharged cured.

This case was re-admitted to the hospital in April, 1866, after suffering greatly for several months from irritability of the bladder. On the introduction of a sound through the urethra, a large stone was detected, on which the bladder was firmly contracted.

A few days after admission, I removed the stone through the base of the bladder in the presence of some members of the Consulting Board and other gentlemen. I will describe the simple method by which I have operated a number of times; and although it may be deemed somewhat foreign to the main subject under consideration, yet the frequent formation of calculi after these operations about the cervix, gives it a direct bearing on the point in question. Comparatively, I do not regard the removal of stone in the female by the urethra, as either a safe or a justifiable operation, in consequence of the great risk of incontinence of urine, which frequently remains permanent.

I have seen at least seven cases in support of this assertion, for which no relief could be afforded, and in which I am satisfied that the accident had not resulted from want of skill on the part of the operator.

A sound, somewhat abruptly curved an inch and a half from its extremity, was introduced through the urethra. While held by an assistant, with its point firmly pressing in the median line, against the base of the bladder, a little behind the neck, the projecting tissue on the vaginal surface was seized with a tenaculum, and divided by a pair of scissors directly on the point of the sound until it could be passed through into the vagina. With the sound remaining in the opening as a guide, one limb of a pair of scissors was passed alongside into the bladder, and the vesico-vaginal septum divided backward in the median line.

By this mode (especially where the vagina is of the natural size), the operation is extremely simple, and is completed in a few minutes. The object in cutting on the point of the sound is to be sure that the bladder and the vaginal surface are divided in correspondence, for there is so much mobility of one surface over the other, that it is exceedingly difficult to enter the bladder, unless the parts are transfixed.

In consequence of the great loss of tissue in this case, when the opening had been extended about an inch and a quarter, and the cervix uteri reached, it was yet too small for the removal of the stone unbroken; this was crushed with a pair of strong forceps, and, after removing the large pieces with a scoop, the bladder was thoroughly washed out.

I have frequently closed the opening immediately after removing a stone, as in the operation for fistula, with the same after-treatment. In this case, however, I determined to leave it open a year for the relief of the chronic

cystitis, as the bladder would thus be kept empty, and the chief source of irritation consequently removed, by remaining at rest, it would gradually recover its tone.

In regard to the facility of performing this operation, I am satisfied that any one who has the dexterity properly to crush a stone by the female urethra, can with much less difficulty close the fistulous opening, which is fully in view, with the edges already denuded and lying in apposition. In fact, I have always experienced the greatest difficulty in keeping the incision open, where I have wished to do so; and it has frequently closed entirely within a few days, when the case has been entrusted to an inexperienced assistant.

Judging from the number of pieces, this phosphatic calculus, when intact, could not have been smaller than a hen's egg; unfortunately, the pieces were thrown out and not weighed. There was no nucleus, but its formation was the result of the chronic cystitis, which originated from the long retention of urine, during the last labor, and at the time of closing the fistula, the disease, as was proved by the result, had not yet been entirely removed. I directed that the bladder should be washed out several times a day with large injections of warm water, slightly acidulated by adding a few drops of nitric acid, as the most direct way of correcting the alkaline state of the urine, due to the condition of the bladder itself.

After three months treatment, the patient had improved so much, and was so anxious to return home, that on the 20th of July, I reluctantly closed the fistulous opening, using eight sutures, which were removed on the fourteenth day. July 20, 1866, she returned home, apparently cured of the cystitis, and able to retain her urine without difficulty during the night. It remains to be seen whether the opening was closed too soon, for, with a recurrence of the inflammation, the calculus will form anew.

CASE II. Second labor of one hour; natural delivery. Anterior laceration of the cervix uteri, extending in the median line along the base of the bladder. Fissure partially closed by nature, leaving a small fistula in front of the cervix. Cured by one operation. First living child born a year afterwards. A suture removed from the cervical canal eighteen months after the operation.

Ann Murphy, a native of Ireland, aged 41, was admitted to the hospital Oct. 5, 1864, from the city.

In May, 1857, she had been discharged cured from the hospital after an operation by Dr. Sims, for the relief of a utero-vesico-vaginal fistula, resulting from a laceration directly through the anterior lip into the base of the bladder. Nine months after her discharge, she had a miscarriage at the third month, and a year after the last, another at two months.

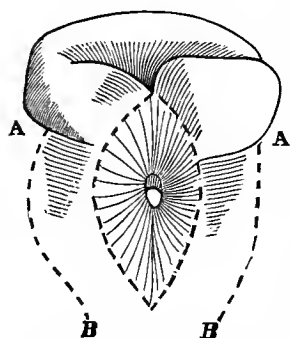
In her second pregnancy, at full term, labor commenced by a sudden rupture of the membranes on Tuesday evening, December, 1861. Until 9 P. M. of the Thursday following, the pains were slight and irregular. Labor then came on regularly, and within an hour afterward, she was delivered naturally of a still-born infant, of the average size, with the feet presenting. The urine began to escape involuntarily immediately after delivery. No slough was passed, and she recovered as if from a natural labor.

*Pathological Condition.*—Laceration had again taken place along the line of the previous operation, through the anterior lip, directly in the median line. The fissure through the cervix had, however, closed nearly to the uterine canal, leaving a small fistula in the base of the bladder a few lines in front of the neck.

Oct. 5. The opening being so small, little more than its edges were denuded, and the raw surfaces were brought together with three sutures. On removing these, an opening of about the same size was found near the cervix, leading forward into the fistula. In closing the fistula, a portion of the vaginal surface round the opening had been scarified, as well as its edges, for the purpose of increasing

the breadth of surface brought together. As the operation was so simple a one, either care had not been taken to pass a sufficient number of sutures to obliterate entirely the fold formed just in front of the cervix, on doubling the surfaces together, or the suture at this point had been twisted too tight, so as to cut out from below upward.

Oct. 30. For some distance around the opening (Fig. 16), the tissue was excavated with



a pair of scissors, so that the surfaces were made to slope inward from the dotted line to the opening of the fistula in the bladder. The rest of the fistulous edge was then removed, as well as a portion of the cervix, and the old cicatricial tissue was gotten rid of by this means. But before these surfaces could be

brought together, it was necessary to make an incision on each side from A to B, as shown in the diagram, to relieve the tension which would otherwise have existed. When the surfaces were folded together, the line of union extended to such a distance beyond each extremity of the fistula, that the fold thus formed was lost in the neighboring tissue. Nine sutures were used. The patient was discharged cured Nov. 18, 1864.

It is frequently more difficult to close a small fistula than it would be where a large portion of the base has been lost. From its size, the temptation is always great to remove simply the edges of the opening, instead of extending the scarification in the proposed line of union in the form of a long oval, so as to obviate the formation of the fold at each end.

This woman, about a year after her discharge, gave birth, by a natural labor, to her first living child. Some eighteen months subsequent to the operation, she came with her



child to see me. I made an examination for the purpose of ascertaining whether laceration of the anterior lip had again occurred, and was pleased to find that the line of union was perfect. On passing a sound into the uterine canal, I was surprised to feel a suture, which, from its length, I was unable to remove until it was bent upon itself. It proved to be the one which had been passed nearest the os, and which by some means had been turned over backward into the canal, with its end in the direction of the fundus. The portion nearest to the fistula had become buried in the cervix, with over half an inch of the other end free in the uterine canal. She had given birth to her child, and the suture had remained for over eighteen months without its presence causing her any trouble. It has occurred to me that the remaining of this suture, which was passed deep through the neck on a line with the vaginal junction, may have been a fortunate circumstance in preventing a recurrence of the laceration.

CASE III. Fifth labor, of forty-five hours duration. Instrumental delivery. Laceration of the anterior lip of the cervix, with a fistula in the median line an inch in diameter. Closed by one operation.

Mrs. M., aged 37, a native of Ireland, was admitted from Ithaca, N. Y., Oct. 4, 1865. She menstruated for the first time at 14, and had given birth to five children, and one miscarriage between the second and third pregnancy. Her labors had all been tedious, and the children were unusually large.

On Saturday, 6 P. M., May, 1865, the membranes suddenly ruptured while she was at work. Her pains came on at once, but they were not severe enough to confine her to bed. On Monday night, regular labor commenced, but with little progress. Wednesday, at 6 P. M., the forceps were applied, and she was delivered of a still-born child of large size. From Monday evening, the bladder was not

emptied until a gush of urine followed the delivery of the head. Two attempts had been made before applying the forceps to introduce a catheter, but without success. Previous to admission, she had menstruated regularly but twice since her confinement.

*Pathological Condition.*—The uterus was partially retroverted and low down in the vagina. The fistula was circular, but somewhat irregular in shape, and an inch in diameter. It was situated directly in front of the cervix uteri, which had been lacerated in the median line. The fissure had extended to the fistula, but a thin septum had been formed by a union of the vaginal surface of the anterior lip. The shape of the opening was due to the position of the uterus, and the shortening of the anterior wall of the vagina.

Oct. 31. The opening was closed. The only difficulty in the case was in consequence of its shape, for its edges could not be brought together without forming a fold of tissue at each angle. This difficulty was overcome by making two parallel incisions, as in the preceding case, and then extending the scarification on the vaginal surface for more than an inch beyond the anterior edge of the fistula, before the surfaces to be united became blended on a level with the neighboring tissue. Nine sutures were necessary, and, when the edges were secured, the line presented the appearance of a much larger opening, extending from the os uteri nearly to the neck of the bladder. The sutures were removed Nov. 9, and the case was discharged cured December 7, 1865.

CASE IV. First pregnancy; natural delivery after a labor of three days. Laceration in the median line of the anterior lip of the cervix, and along the base of the bladder for an inch. Nature had nearly closed the opening. The original condition was reproduced and closed by one operation.

Mrs. T., aged 26, a native of the United States, was

admitted from Binghamton, N. Y., Oct. 3, 1865. She menstruated for the first time at 13.

Labor with her first and only pregnancy took place in 1858. She was unable to give any date or history of her case, beyond the fact that she was in labor three days and nights, and that delivery was accomplished, unaided, of a very large still-born child. She was under the impression that the bladder had been frequently emptied during labor, and that the urine began to flow immediately after delivery.

*Pathological Condition.*—A small circular opening, not more than an eighth of an inch in diameter, existed immediately against the cervix. The original lesion had been a complete laceration in the median line through the anterior lip, extending along the base of the bladder for more than an inch; but nature had nearly succeeded in closing the opening from each extremity. Small as the opening was, in consequence of its position so close to the cervix, it could not be closed until the original condition had been reproduced. The edges were secured by nine interrupted sutures, three of which were passed through the cervix. The operation was performed Oct. 27. The sutures were removed on the tenth day, and the case discharged cured Nov. 24, 1865.

CASE V. Fourth pregnancy; forty-eight hours in labor. Delivery accomplished by hand. Fistula extended an inch and a quarter from the cervix in the median line, with laceration of the anterior lip of the cervix. First operation closed the fistula on the vaginal surface, but a sinus was formed afterwards, communicating with the cervical canal. Second operation successful by dividing the cervix through to the sinus, and reproducing the original condition.

Mrs. S., aged 36, from Cohecton, N. Y., was admitted Nov. 26, 1866. She married at 26 years of age, and had given birth to four children. The last child was born some five weeks previous to admission, after a labor of forty-eight hours. It was still-born, and delivered by

“ropes,” as she stated. She lost all control of the urine immediately after the delivery.

*Pathological Condition.*—A fistula was found in the median line, extending an inch and a quarter from the cervix, toward the neck of the bladder, and had resulted from laceration of the anterior lip of the cervix. The fissure through the neck was deeper at its terminus in the uterine canal, than on a line with the opening through the vaginal surface.

Dec. 4. After carefully scarifying the sides and angle of the fissure through the cervix, so as to include the entire tract at the bottom of the sulcus, the edges of the fistula proper were denuded, together with a portion of the vaginal surface in advance of its anterior angle. The whole line was then secured by seven sutures, two of which were passed through the cervix below the angle of laceration.

Dec. 14. The sutures were removed and the operation appeared successful; but on the next day, in consequence of the falling of a portion of the ceiling in the ward, the patient sprang from her bed, and the urine immediately afterward began to escape. On examination, the next day, the urine was seen escaping from the os uteri, while the cervical and vaginal line of the fistula remained closed. Jan. 6, 1867, she returned home on a visit.

Feb. 19. Operated again by splitting open the cervix down to the sinus, and restoring the parts to their original condition; otherwise it would have been impossible to have reached the fistulous tract. The previous operation was repeated, and the only difficulty in the case was experienced in passing the four deep sutures through the neck, so as to go below the bottom of the fissure.

March 4. The sutures were removed, and although a portion of the line, nearest to the uterine canal, gaped for a short distance on withdrawing the suture, the line of union remained perfect below. The case was discharged cured March 18, 1867.

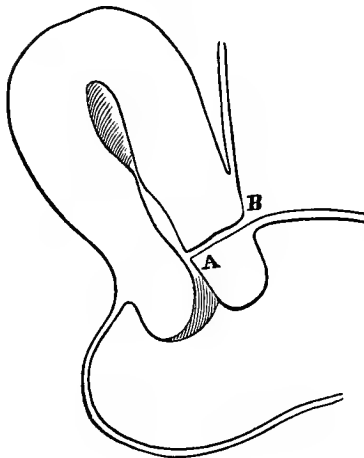
CASE VI. Sixth pregnancy. In labor eighteen hours; delivered by version. Laceration of the anterior lip of the cervix uteri and base of the bladder in the median line. Partially closed by nature, leaving a sinus communicating with the cervical canal above the vaginal junction. Cured by closing the os uteri.

Mrs. G., aged 32, a native of Ireland, was admitted from Astoria, L. I., March 8, 1863. She had been married eleven years, and had given birth to six children at full term, all still-born, and five had been delivered by forceps. Her general health had always been excellent. The pains of her sixth and last labor commenced on Saturday forenoon, May 15, 1858. The membranes (as in each previous labor except the first) had suddenly ruptured several days before the pains actually came on. As the pains were slight and but little progress was made, her physician, on Sunday, at 5 A. M., turned and delivered by the feet a still-born child of not more than an average size.

The bladder had been emptied on Sunday by means of a catheter, but the urine commenced to escape through the vagina on the day after delivery, and two weeks afterward, several small sloughs were passed. Since her confinement, menstruation had been both irregular and scanty, while for four months previous to admission, it had been totally absent.

*Pathological Condition.*—It was only after introducing the

FIG. 18.



speculum that the direction by which the urine escaped could be discovered. The cervix uteri had been lacerated laterally to the vaginal junction on each side, and the urine passed entirely from the uterine canal. After drawing the anterior lip forward, a small opening into the uterine canal, on a line with the vaginal junction, was detected behind the point A (Fig. 18).

A small probe was passed, but, after a most careful examination, the opening from the bladder could not be found. From its situation, an operation for closing the fistula at A was almost impossible, and to have attempted it by means of caustic, or a wire cautery, would have resulted in entire occlusion of the uteri canal at the same point.

After satisfying myself that pregnancy did not exist, I determined on the following procedure. March 22, the lacerated surfaces were wholly denuded across in front of the point A, including the angle at the bottom of the fissure. Nine deep sutures were passed from before backward, shutting up the cervical canal and firmly uniting together the flaps formed by the anterior and posterior lips. The sutures were removed on the eighth day, and the case was discharged cured May 20, 1863.

*Remarks.*—It is probable that in the first labor the lateral laceration occurred, and that this condition was the cause of the rupture of the membranes in each subsequent labor several days before labor commenced. In the last delivery, the anterior lip was lacerated in the median line, and, extending forward along the base of the bladder, caused a fistula of some extent. This gradually closed on the vaginal surface by granulation from the angle nearest the neck of the bladder, and, on extending to the cervix, the edges united from above downwards, leaving a mere sinus at the bottom of the original fissure. Under such circumstances, as will be seen hereafter, my usual mode of operating is to reproduce the original condition, if a probe can be passed as a guide through the sinus, in either direction, and, after freshening the course of the sinus, to bring the whole together again by deep sutures. In this case, without accurately measuring the diameters of the pelvis, by a digital examination, I felt satisfied that the antero-posterior one was narrowed. With the history of the case, showing that

in all her previous labors she had been delivered artificially of still-born children, I considered it a fortunate circumstance for her that the most advisable operation should have removed all risk of future pregnancy. Previous experience had already demonstrated that under such conditions the menstrual flow could pass readily into the bladder, and be voided with the urine without the slightest inconvenience. Although I have not seen this patient since her discharge, I feel satisfied that no bad result had followed the operation, for living as she does within a few miles of the city, she would have returned according to promise in case of any difficulty.

CASE VII. Third pregnancy; natural delivery after a labor of thirty-seven hours. A sinus from the bladder entered the cervical canal above the vaginal junction, and, as in the previous case, from laceration of the anterior lip.

Mrs. O'D., aged 26, a native of Germany, was admitted April 4, 1864, from Athens, N. Y. She had been married five years.

Labor at full term, with her third and last child, commenced on Thursday, August 1, 1862, at 6 A. M. The pains almost from the beginning were both frequent and severe until Friday, at 7 P. M., when she was delivered naturally of a still-born child, weighing twelve pounds. During the whole time in labor, the contents of the bladder were not evacuated.

Until August 16, fourteen days after delivery, she had perfect control of the urine; it then began to escape from the vagina, and for several weeks afterward, as she stated, from time to time small portions of tissue, which had been thrown off by sloughing, came away. During the winter of 1864, she was twice operated on by an eminent surgeon of Albany. She was benefited by each operation, and enabled to retain the urine in large quantities afterwards.

*Pathological Condition.*—The urine all escaped by the os

uteri, as in the preceding case, through a sinus opening into the cervical canal on a line with the vaginal junction. The uterus was also in the same position, and the illustration used for her case answers perfectly for the present one, with the exception that there had been no lateral laceration of the cervix. The cause was the same in both cases; viz., laceration of the anterior lip, which had been partially closed by the previous operations in Albany. The control of urine, for two weeks after delivery, was due to a close approximation of the edges from swelling, previous to the slough being thrown off.

April 8, 1864, after a little manipulation, a probe was passed along the sinus from the bladder until it was felt against a sound introduced into the uterine canal. The two being then held by an assistant as a guide, the anterior lip was steadied by a tenaculum, and divided in the median line with scissors, until the whole tract into the bladder was laid open. After removing the course of the sinus in a single strip, four deep sutures were passed through the flap around the bottom of the fissure, and a single one in the angle at the base of the bladder. These were twisted as interrupted sutures, bringing the two surfaces in perfect opposition.

The sutures were removed on the ninth day, and the case discharged cured May 1, 1864.

On the 24th of April, 1865, she was re-admitted to the hospital for treatment of hypertrophy of the uterus, a sequence of her last confinement, and in a few months was discharged much improved. The operation had proved a successful one in every respect.

CASE VIII. First pregnancy. Twenty-four hours in labor; delivered by craniotomy. Anterior laceration of the cervix, which, becoming closed above, left a sinus communicating with the uterine canal from a large fistula in front. The original condition was reproduced and operation successful.

Mrs. T., aged 20, native of the United States, was admitted from Worcester, Ohio, Oct. 2, 1865. Menstruated



for the first time at 14, married at 19. Labor with her first child began 8 A. M., Tuesday, March 1, 1865. She saw a physician on Wednesday morning. At 11 A. M. the membranes ruptured, and twenty-four hours afterward she was delivered by craniotomy. The urine had been allowed to accumulate from early Wednesday morning until after 12 o'clock on Thursday. No slough was passed, but on the third day after delivery a putrid and watery discharge came on; the quantity increased until, within a day or two afterward, the urine involuntarily escaped by the vagina. Menstruation returned three months before admission, and was regular afterwards.

*Pathological Condition.*—A fistula of about an inch in length, and half an inch in width, was situated in front of the cervix, and on a line with the vaginal junction, a sinus was found, communicating with the cervical canal from the fistula.

The case is of interest only in so far as it illustrates the reparatory efforts of nature. Originating as in the preceding cases, union took place through the lacerated anterior lip from above downwards, bridging over the fissure so as to leave a sinus at the bottom, while the fistula in the base of the bladder remained unchanged.

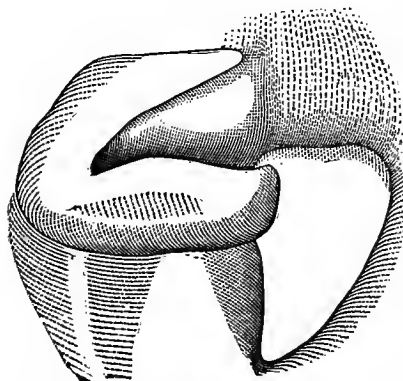
Oct. 6. One limb of a pair of scissors was passed along the sinus, and by cutting through the united edges, the original condition was reproduced. The tract of the sinus was then removed, and the edges of the fistula scarified beyond the angle of the fistula nearest the neck of the bladder, so that the whole could be brought together without puckering the edges at this point. Two sutures were introduced into the neck and six into the base of the bladder. They were removed Oct. 17, and the case was discharged cured soon afterwards.

CASE IX. First pregnancy. Version, and head delivered by forceps; in labor about thirteen hours. Laceration of the cervix uteri on the right side, with a fistula an inch in length, and cicatricial bands extending from the opening into the cul-de-sac. Closed by one operation.

Mrs. L., aged 33, a native of Ireland, was admitted from Jersey City, April 20, 1861. Her general health had always been good. Her first labor began at full term, about 6 P. M., December, 1861. A physician at once took charge, and, attempting version without success, remained all night. Early the next morning, a consultation was called and the child turned; the body was delivered by hand and the head by forceps. It was a still-born male, of the average size. She made a good recovery, and stated positively that no slough was passed, nor did the urine begin to escape for a month after delivery.

*Pathological Condition.*—Laceration of the cervix uteri on the right side through to the vaginal junction. As it reached the base of the bladder, its course turned in the direction of the vaginal axis, causing an opening of about an inch in length, through which the index finger could be readily

FIG. 19.



introduced. Behind and to the right of the posterior lip of the uterus and fistula, a band of cicatricial tissue existed, running around into the cul-de-sac. By the contraction of this band drawing the posterior flap backward, the fissure in the cervix gaped, and at the same time, by the same

traction on a portion of the edge of the fistula, it assumed a triangular shape, with its base at this point.

May 25. The posterior surface of the cervix (Fig. 19) was freed at the point where it blended with the cicatricial

tissue, and the course of the bands was divided entirely across behind the fistula. This allowed at once of a perfect approximation of the sides of the fissure through the cervix, and of the edges of the fistula, in one continuous line. The edges were scarified and closed by eight interrupted silver sutures, two of which were passed through the cervix. They were removed on the eighth day, and the case was discharged cured June 14, 1861.

*Remarks.*—The case had been originally a mere fissure, with the sides lying in close contact, through which a fold of the bladder protruded sufficiently to prevent an escape of urine until contraction of the bands gradually took place, and separating the edges of the fistula, gave it the appearance as if a large portion of tissue had been lost. If any slough was separated, it was from the cul-de-sac alone.

CASE X. Ninth pregnancy; delivered by forceps, after a labor of forty-two hours. Lateral laceration of the cervix on the right side. Fistula large, with cicatricial tissue extending into the cul-de-sac. First operation not entirely successful. Cured by the second operation after reproducing the original condition.

Mrs. A., aged 40, a native of Ireland, was admitted from Orange Co., N. Y., June 3, 1864. She had been married fourteen years, and was the mother of nine children.

Her labors had all been natural ones, except the last, which commenced at full term, at 5 A. M., Sunday, March 6, 1864, the membranes rupturing suddenly about two hours before the first pain. By evening the head reached the perineum, after frequent and severe pains during the day. Ergot had been administered several times, but her stomach rejected at least a portion of each dose. At 11 P. M., two attempts were made to bleed her from the arm, but without success. Twelve hours afterward (on Monday), three physicians were called in consultation, and delivery was accomplished by forceps of a very large still-born child.

During the whole time of labor, the bladder was not

emptied, and only a small quantity of urine was drawn by the catheter, just before the forceps were applied. The urine began to escape in small quantities immediately after delivery. At different intervals through the month, several sloughs were passed, and, after the last one, all control of the urine ceased.

*Pathological Condition.*—Lateral laceration into the bladder through the cervix on the right side, causing a fistula large enough to admit two fingers readily. This condition is fairly represented by the diagram given of the preceding case.

The fistula was closed, June 1864, in the presence of several members of the American Medical Association, by a similar method, nine sutures being used. On removing them, a small opening was detected close to the cervix, but not large enough to admit a probe.

Sept. 20. After spending the summer at home, the patient was re-admitted, and the same operation was performed, after entirely splitting open the surfaces previously united. This was necessary from the fact that the sinus did not directly enter the bladder; and, without dividing the cervix, so as to continue the line beyond the opening, there would not have been room to close the angle properly on that side. The bands behind the fistula and cervix were again properly divided. Nine sutures were used; they were removed on the eighth day, and the case was discharged cured May 20, 1864.

CASE XI. Fifth pregnancy. Delivered by efforts of nature; in labor three days. Lateral laceration of the cervix on the left side. Fissure through the cervix closed by nature, as well as part of the anterior edge of the fistula. One operation successful.

Mrs. L., aged 40, born in Ireland, was admitted to the hospital, from Belleville, N. J., Feb. 7, 1860.

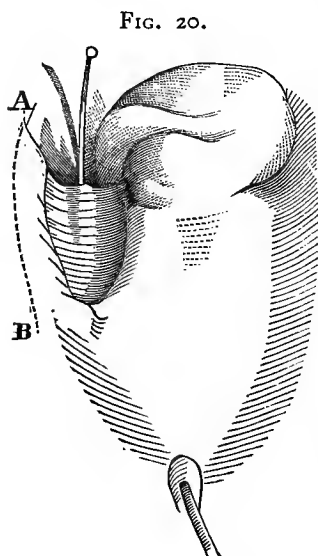
Her fifth labor commenced at full term, about 7 A. M., 1848. After having been three days in labor without a

physician, the child was still-born, "doubled by the back," as she described the presentation.

The bladder had been frequently emptied during the progress of labor. Two days after delivery, the urine began to dribble away, and no slough was passed. She could retain a larger quantity in the upright position than in any other.

She had ceased to menstruate two years before admission. Her general health had always been perfect.

*Pathological Condition.*—A fistula was found, large enough to admit the index finger, and resulted from laceration of the cervix uteri on the left side. The fissure through the cervix had closed, as well as part of the anterior wall of the fistula, which terminated in a thin edge, as shown by the diagram, or at this point, the laceration had not extended entirely through into the bladder.



The opening was closed March 15, 1860. Until an incision was made from A to B (Fig. 20), so as to free that side from the lateral wall, no approximation of the edges could be made. A line of scarified surface was then made just below this incision, extending beyond the edge of the fistula well into the cul-de-sac, back along the cervix, and around in front of the original angle of the fistula to B. The surface was entirely removed from the sulcus edge in front of the fistula, and the whole was brought together in the axis of the vagina by eleven sutures. They were removed on the ninth day, and the case was discharged cured April 1.

## CHAPTER V.

### LACERATION OF THE CERVIX, WITH EXTENSIVE LOSS OF THE SOFT PARTS FROM SLOUGHING.

CASE XII. Second pregnancy. Seventy-one hours in labor; delivered by the efforts of nature. Laceration of the anterior lip in the median line, with sloughing of nearly two inches along the base of the bladder. By contraction of cicatricial tissue, the vagina was drawn into a deep fold on each side of the fistula. Cured by one operation.

Mrs. McC., aged 40, was admitted from Clyde, Wayne Co., N. Y., March 7th, 1863. She was married at 32, and a year afterwards gave birth to a still-born child, at nearly full term. Five years previous to admission, her second labor commenced at full term, on Thursday, at 5 P. M. During the following day, the pains were slight and not very frequent. On Saturday, ergot was administered with slight effect, but the membranes were not ruptured until Sunday afternoon, and almost immediately afterwards delivery took place of a dead child.

. During the progress of labor, the bladder had been frequently emptied, and without difficulty until Sunday morning, two weeks after delivery, when several sloughs were passed from the vagina, with an involuntary escape of urine for the first time.

Previous to coming under my charge, she had been operated on three times, but with only partial benefit. Menstruation had continued regular after its return, but in less quantity since her confinement than had been her previous habit.

*Pathological Condition.*—A small fistula was situated just in front of the cervix uteri, and in the same line another

opening was found anterior to the first. The neck of the uterus had been lacerated anteriorly, and in the same line a slough had extended for nearly two inches along the base of the bladder. The edges of the fistula were formed of cicatricial tissue. In consequence of the sloughing, and by contraction in the neighborhood of the cervix, the vaginal tissue was drawn into two parallel folds, running nearly from the cervix to the neck of the bladder. On separating these folds at the bottom of the sulcus, the openings with some difficulty were brought to view.

The cause of failure in the previous operations had been due to an attempt to unite cicatricial surfaces in a position where the edges could not be brought fairly in view to scarify them properly.

March 11. The anterior lip was divided through nearly to the vaginal junction, and a broad line of scarification was made on the side of each fold, near the top, as the surfaces lay in contact. Three deep sutures were passed through the cervix, so as to bring the divided surfaces perfectly together, and eight were introduced into the base of the bladder, making a continuous line of two inches and a half from the os uteri, nearly to the neck of the bladder, thus shutting up the fistula at the bottom of a long pouch. The sutures were removed on the tenth day, and the case was discharged cured, April 15, 1863.

CASE XIII. First labor, lasting fifty hours; delivered by forceps. Laceration of the anterior lip of the cervix, together with a slough extending nearly to the neck of the bladder. Partially closed by nature from each end, and, by contraction of cicatricial tissue, reduced to a circular opening, situated about the centre of the base of the bladder. Closed by one operation.

Mrs. W., a native of Ireland, aged 24, was admitted from Willimantic, Conn., May 24, 1864. She had been married two years, and had given birth to one child.

Labor commenced at full term on Sunday, April 1,

1864. The pains soon became severe, but the membranes did not rupture until the following Tuesday. Two hours afterwards, the forceps were applied, and delivery took place of a large child, still-born, after a labor of about fifty hours.

During its progress, the urine had been passed regularly without difficulty, but voluntary retention continued afterwards for eighteen days, when it suddenly escaped by the vagina. A large slough was separated at this time, followed by several smaller ones within a day or two after.

Up to the time of admission, menstruation had not returned, and her general condition was still feeble.

*Pathological Condition.*—With a laceration through the anterior lip, a slough had extended from the cervix nearly to the neck of the bladder; but, granulating from both ends, the fistula contracted to a circular opening, only large enough to admit readily the index finger, and was situated about the centre of the base, in the median line.

June 14. Two parallel incisions were made with scissors on each side in the axis of the vagina through the cicatricial tissue, somewhat longer than the fistula, and of sufficient depth to admit of its edges being brought into contact free from tension. The edges of the fistula were then denuded, and the line of scarification extended on the vaginal surface toward the cervix uteri and neck of the bladder. Seven sutures were used, without puckering at either end after they had been secured. The sutures were removed on the ninth day, and the case was discharged cured, July 1, 1864.

CASE XIV. Third pregnancy; delivered by forceps, after a labor of forty-two hours. Laceration of the anterior lip of the cervix, and of the base of the bladder in the median line, with sloughing. Fissure in cervix united by granulation. Fistula reduced to a circular one, and vagina shortened by bands extending into the cul-de-sac. Closed by one operation.

Mrs. S., aged 29, was admitted from New Haven, Conn., April 2, 1864. Her third labor commenced :



full term, six weeks previous to admission, and was terminated in forty-two hours by means of forceps, the child weighing twelve pounds. Four weeks after delivery the urine escaped for the first time by the vagina, and a few days afterwards several small sloughs came away.

*Pathological Condition.*—A large circular fistula was found extending about three-quarters of an inch from the cervix uteri to the neck of the bladder, with lateral bands of cicatricial tissue extending from the fistula on each side into the sulci. Originally, there had been a laceration in the median line through the cervix uteri to the neck of the bladder, without extending entirely through the septum. Subsequently, superficial sloughing of the vaginal surface, with loss of tissue, took place, but the opening afterwards became circular through contraction of the cicatricial tissue. The laceration through the cervix had perfectly united with a portion of the base of the bladder, but the line of union could be traced without difficulty.

The parts were not in a proper condition for operating until the 26th of the following June. The bands were then freely divided on each side along the sulci in a continuous line for over two inches, and the edges of the fistula were united in the median line of the vagina by means of fifteen sutures. They were removed on the tenth day, and the patient returned home cured a few days afterwards.

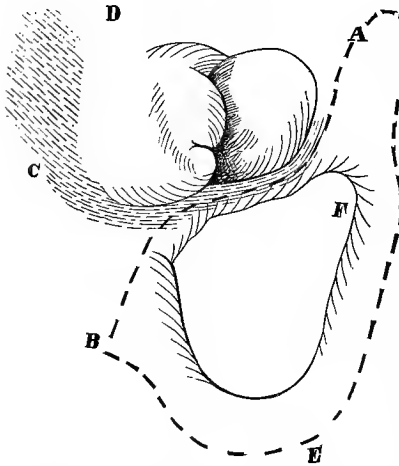
CASE XV. Third pregnancy; delivered by version, after a labor of twenty-four hours. Laceration of the cervix in its antero-posterior diameter, with loss of about half the base of the bladder in front of the uterus. Fistula was to the right of the median line, in consequence of traction exerted by cicatricial bands extending into the cul-de-sac, which drew the uterus to the left side. Closed by two operations.

Mrs. C., aged 34, a native of New York, was admitted from the city, Oct. 18, 1859. She was married at 18, and passed through her first and second labors without diffi-

culty. The third labor commenced at full term, about 7 P. M., Friday, February, 1858. Within an hour afterwards, rupture of the membranes took place. The pains soon became strong, and returned every five or ten minutes with great force. This condition continued, with a midwife in charge, until late on Saturday afternoon, when a physician was called, who turned, and delivered by the feet a still-born male of average size. She was but twenty-four hours in labor, and the bladder had been emptied naturally several times during its progress, but the escape of urine followed immediately on delivery. No slough was passed. She sat up six weeks after delivery, and menstruation returned at the end of the sixth month.

*Pathological Condition.*—The cervix uteri had been lacerated in its antero-posterior diameter, and had extended to

FIG. 20<sup>A</sup>.



some distance along the base of the bladder. Superficial sloughing of the vaginal surface as well as of the septum had occurred. On the left side, a dense band of cicatricial tissue was formed at C D (Fig. 20<sup>A</sup>), blending with the cervix on that side, but extending lower in the direction B than is represented by the diagram, and further around in front of

the neck to the opposite side. The fistula extended about half way to the urethra, and a little more on the right side. The angle E of the fistula could be brought nearly in apposition with the dotted line A B. At F, under the edge of the fistula, the mouth of the ureter on that side could be brought in view; this fact would indicate at least that

with the laceration a slough had been separated at this point. The shape of the fistula was due, in a great extent, to contraction of the bands already described.

Nov. 1. The surface *CD* was freely divided, and an incision made along the dotted line *AB*, so as to split the upper edge of the fistula for the purpose of reaching healthy tissue beneath, and at the same time gaining a broader surface than could be obtained by scarifying the thin edge in front of the cervix. The denuded line was then completed on the vaginal surface along the line *BEA*. The reason for extending it to *A*, at such a distance from the margin of the fistula *F*, was in consequence of the cropping out of the ureter at this point, which would have been transfixed by the sutures, had the edge of the fistula been followed. It would have been easier to have split up the mouth of the ureter for a short distance on the bladder side, as is sometimes done. I preferred, however, the course followed, to leaving a denuded surface within the bladder,—not always a safe practice, as it might furnish the nucleus for the subsequent formation of a calculus.

The sutures were passed at right angles to the line *AE*, as they approached the point *F*, where the course of the ureter became superficial; they were not introduced deep enough to reach the sound, which had been previously passed into the ureter as a guide. When the sutures were twisted, the portion of the line *AE* was carried beyond the course of the ureter, and doubled over to *AB*, so that the course of the ureter lay at the bottom of the fold. Fourteen sutures were used.

As the surface *BEA* was much longer than *BA*, when the edges were drawn together by bringing the anterior edge up to the cervix, the line was much lengthened, so that the lower line was fully three-fourths of an inch in advance of *B*, in continuation of the line *AB*.

Great hemorrhage ensued on making the incision from B to A, so that the line could not be extended as at first contemplated; consequently, when the sutures had been twisted, the tension was still so great, that it was feared the parts had not been sufficiently freed. The progress of the operation was delayed until the bleeding could be arrested, and experience has since taught me that it would have been comparatively trifling had the division been made with the scissors instead of the knife.

The sutures were removed on the tenth day, and the union was found perfect throughout, with the exception of a small opening at the bottom of a fold, formed in the extreme angle beyond the point B.

Nov. 30. Closed the opening with six sutures; although it was scarcely large enough to admit a small probe, it was found necessary to extend the line beyond, until the fold became lost in the neighboring tissue. On removing the sutures, December 8, a small opening was again found at the end of the line of union, which continued as a sinus for nearly an inch before entering the bladder. The catheter was continued, however, in use for several days longer, when, on examination, the opening was found closed, and the case was discharged cured, December 20, 1859.

CASE XVI. First pregnancy. In labor about one hundred and four hours; delivered by the efforts of nature. Loss of two-thirds of the base of the bladder in front of the cervix, the posterior lip of the cervix and cul-de-sac. Laceration of the anterior lip of the cervix, with a false passage existing from the urethra into the vagina. First operation successful, but by tension an opening afterwards occurred, which was closed by a subsequent operation.

Mrs. S., aged 27, a native of Boston, came under my charge, April 10, 1864, having been married three years. Her first labor commenced two weeks before the proper time, on Friday evening, September, 1861, with a sudden rupture of the membranes, occasioned by a fright. During the following Saturday, Sunday and Monday, the pains were

both frequent and severe in character. A physician was not in charge until Monday. On Tuesday morning, at 5 A. M., she was delivered by the efforts of nature of a very large child, still-born.

It was her impression that the bladder was not emptied of its contents from Friday evening at bed-time, until the following Tuesday, when it was drawn off by a catheter. At the end of two weeks after delivery, several large sloughs were passed, and immediately afterward she lost all control of the urine.

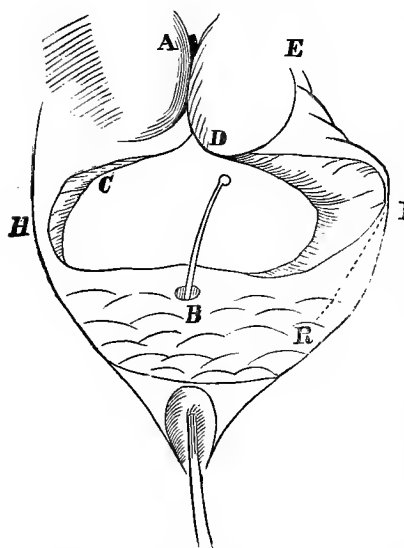
During the two years following the occurrence of the injury, she was operated on three times without receiving any marked benefit. The urine could only be retained for a short time while lying on the back.

*Pathological Condition.*—About two-thirds of the upper part of the base of the bladder had been lost, together with the posterior portion of the cervix and cul-de-sac, while the remaining part of the anterior lip had been lacerated through in the median line. The angle of the fistula on the right side, together with the surrounding parts, was a mass of cicatricial tissue. The transverse diameter of the fistula on the vaginal surface (Fig. 21) extended from one ramus to the other, but the edges receded (somewhat more on the right side), so that the actual opening into the bladder was much smaller. The urethra was impervious at the bladder extremity, while a false opening existed at B from the urethra into the vagina, about a third of an inch in advance of the anterior edge of the fistula. The triangular space on the posterior lip of the fistula in front of the cervix was too thin to be used in closing the fistula. Under the portion of the anterior lip at D a sulcus existed, extending nearly up to the os. The mouth of the left ureter was exposed at C, just at the edge of the fistula. The tissue in front of the fistula was thrown into a number of small folds, and was quite movable.

The false opening at B seemed to have been made by the introduction of a catheter, as the urethra was occluded just beyond, and its existence at this point greatly complicated the case.

In consequence of the fissure extending up to the os

FIG. 21.



uteri, and from the irregularity of the neighboring surface, it was at first thought impossible to close the fistula without shutting up the os uteri within the bladder.

April 29, 1864, a broad scarified surface was extended from B to H A F B. F was the only point at which any portion of the edge of the fistula was really included in the proposed line of union. The line E F R was dissected up by

scissors, so as to free the tissue along its course. From the fact that at F, the inner face of the ramus was almost denuded, the freeing of the line F R was necessary in order to make room for passing the sutures. When this line had been freed the point F could be stretched with a tenaculum across nearly to C. Some slight bands were then divided to the outside of the line H A. Fortunately, the cul-de-sac had been comparatively uninjured, and the uterus was consequently quite movable.

Fourteen sutures were then passed so as to close the opening, somewhat in the form of a triangle, by bringing together the surface B H and H A on one side, and B F and F A on the other. The side A F, however, was rather the longer, and when the surfaces had been approximated,

the line of union was somewhat in the position H D R; thus the points B and A were brought together in the neighborhood of D.

The urethra had been opened along its proper course a week before the operation, and the false opening at B was closed by being included in the line of scarification. The tension would have been much less if the line had been carried between this opening and the edge of the fistula, but there would have been greater difficulty in closing afterward, by a separate operation, the false passage with its thin edges, than by proceeding in the manner described.

On the tenth day the sutures were removed, and it was found, with some surprise, that the line of union was perfect throughout. Four days after, the patient menstruated. The catheter was still retained in the bladder, and all the urine passed in this direction, but it was found discolored by the menstrual flow, a circumstance which I was unable to explain at the time. After the flow had ceased and the catheter was removed, the urine then all passed by the vagina.

May 27. An examination disclosed a small opening in the course of the right side of the triangle, doubtless where the tissue at F was included in the line. The edge at this point was thin and cicatricial in character, without vitality in uniting to bear even a slight amount of tension. This, however, did not explain the presence of the menstrual flow in the bladder, which could only be accounted for by the supposition that a small sinus had existed at the bottom of the sulcus A D, passing from the os into the bladder, and which afterward closed.

A portion of the line E F R was again freely divided with the scissors, as, from the character of the tissue, it was now found necessary to do more than simply bring together again the edges of the opening. A broad oval scarification was then made on the vaginal surface in compara-

tively healthy tissue around and at some distance from the fistula, so that its edges would be rolled into the bladder when the raw surfaces were brought together.

Eleven sutures were used. The result was still deemed doubtful, from the character of the tissues included. June 6, however, the sutures were removed, and the parts found perfectly united.

The patient was retained under observation for several weeks longer, it being still feared that some portion of the line would gradually separate. This did not occur, however; she menstruated naturally at the end of the month, returned home well, and has continued so to the present time.

She was placed under ether, contrary to custom, for both operations, as the execution was exceedingly difficult, particularly the last one, which was tedious on account of the opening being situated so far to one side, behind the ramus. It should be stated that the diagram given of the case exactly represents the appearance of the part while on the knees and elbows, but when placed on the side for operating, the edges of the fistula were drawn closer together, giving it something of a crescent shape, with the concavity presenting.



## CHAPTER VI.

### FISTULÆ INVOLVING THE UPPER PORTION OF THE VAGINA, WITH SLOUGHING OF THE CERVIX UTERI.

CASE XVII. Sixth pregnancy; natural delivery, after forty-eight hours in labor. Transverse fistula in front of the cervix, which had sloughed. By cicatricial bands extending into the cul-de-sac, the vaginal tissue in front of the cervix was drawn into a fold so as to hide the opening into the bladder. Closed by one operation.

Mrs. O'H., aged 29, was admitted Sept. 27, 1866, from Birdsall, N. Y. Menstruated first at 15; had always been regular, lasting three days previous to marriage, and five days since, being always painful as well as profuse. Was married at 19, and had given birth to six children.

The last labor commenced March 19, 1866, and, with nothing of note occurring in its progress, terminated naturally in forty-eight hours. Two days afterward, the urine began for the first time to escape from the vagina.

*Pathological Condition.*—The fistulous opening was situated in front of the uterus. It was transverse, and a little less than an inch in length. The organ was in position and movable, but the anterior lip had wholly sloughed away, together with a great part of the posterior one, while the finger passed for some depth into the canal, as if a portion of the body had also been lost.

As in Case XVIII (Fig. 22), the fistula was entirely hidden, in consequence of the base of the bladder being folded on itself, from traction of a cicatricial band on each side, which passed to the cul-de-sac in the direction B E and C E. The opening could only be brought partially

in view by seizing with a tenaculum the point B, and drawing the fold forward.

Oct. 9. Operation. Prior to closing the fistula, the bands on each side, in the direction E B, were freely divided with scissors, so as to bring the opening perfectly in view; and, by so doing, the vagina was at the same time restored to its natural depth. The sides of the fistula were brought together on a level at C. The only difficulty in the operation resulted from the thin edge, which was all that remained of the anterior lip, and through which two sutures had to be passed, with barely tissue enough to withstand any tension. At this point it was feared that the operation might fail. Ten sutures in all were used. They were removed Oct. 19, and the patient discharged cured Nov. 2.

CASE XVIII. Sixth pregnancy; instrumental delivery, after sixty-seven hours in labor. Uterus retroverted; anterior lip lost, together with a large portion of the base of the bladder. By contraction of cicatricial tissue, the vaginal wall in front was drawn into a fold, so as to hide the fistula from view. Fistula closed by turning the cervix uteri into the bladder. Operation successful; small opening afterwards, which was closed by a second operation.

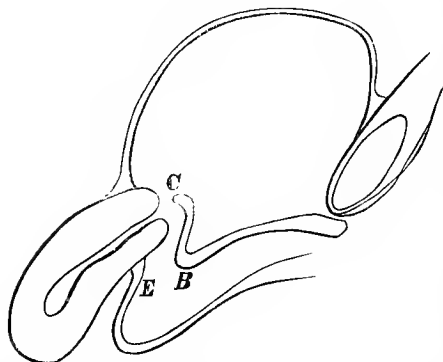
Mrs. M., aged 30, a native of the United States, was admitted from Illinois, Feb. 7, 1863. She had been married eleven years, and had given birth to six children. Her previous labors had been natural, and her general health always good.

The sixth labor commenced at full term, by a sudden rupture of the membranes, about 5 P. M., Monday, Sept. 25, 1862. The pains soon became regular and frequent. Her physician was sent for immediately, but, beyond making an examination, nothing was done until Wednesday evening. He then removed an arm from the child by means of a pocket-knife, but failed to get away the rest of the body. On Thursday, at noon, another physician was called in, who accomplished the delivery by means of a blunt hook. Immediately afterwards, she noticed an invol-

untary escape of urine. Throughout the progress of labor, the bladder had been emptied naturally and without difficulty.

*Pathological Condition.*—The fistula was situated at C (Fig. 22), across the axis of the vagina, immediately anterior to the uterus, and a little over an inch and a half in length, through which two fingers could be readily passed into the bladder. The anterior lip, which is not properly shown

FIG. 22.



by the diagram, had been destroyed, together with a large portion of the vagina. The uterus was retroverted and immovable, as well as the surface C B. Between the point B and each angle of the fistula, ran a band of cicatricial tissue backward to the

posterior lip of the uterus, and the whole anterior wall of the canal B C was as dense as cartilage. By contraction of this surface, the uterus had been retroverted, the base of the bladder in front of the fistula doubled on itself, and the uterus and this portion drawn together, so as to hide the fistula almost entirely from view. The posterior wall of the vagina had been uninjured; the cul-de-sac was deep and movable.

Feb. 23. A broad strip of the vaginal surface was removed on the plane B E, around in front of the angle B, backward, and on to the cul-de-sac to E. These surfaces were united by means of nine interrupted sutures. In other words, the cul-de-sac at E was drawn forward and united to B, thus shutting up the uterus in direct communication with the bladder. The sutures were removed on the eighth day, and the operation found successful.

Shortly after, the patient menstruated for the first time since her confinement. At first, all passed with the urine, but in a day or two it was noticed that a portion began to escape from the vagina. On examination, a small opening was detected by the escape of the menstrual flow, to the extreme right of the line of union. After menstruating, the urine only escaped in sufficient quantity to occasion a slight moisture at this point.

The opening was closed March 19, by four sutures, which were removed on the eighth day, when the operation was found successful. The patient was retained in the hospital until after the next menstrual period; the flow then all passed with the urine, and she was discharged cured, April 26, 1863.

CASE XIX. Fifth pregnancy; instrumental delivery, after forty-eight hours in labor. The posterior lip of the cervix was lacerated during labor backwards into the cul-de-sac, with subsequent pelvic cellulitis. Sloughing of the anterior lip, and a portion of the base of the bladder, just in front of the cervix, took place. The uterus became gradually retroverted, and the base of the bladder doubled on itself from contraction of cicatricial tissue, so as finally to hide the fistula from view. Closed by one operation.

Mrs. S., aged 28, was admitted from Franklin County, N. Y., Oct. 1, 1866. She had married at 18, and given birth to five children. After a labor of forty-eight hours with her last child, delivery was effected by means of forceps. Two weeks afterward, the urine escaped for the first time by the vagina. The history of her case is incomplete, beyond the fact that she made a tedious recovery.

*Pathological Condition.*—Midway in the axis of the vagina, the anterior wall was doubled on itself, as in the preceding case, with bands stretching from this point into the cul-de-sac. With some difficulty the posterior lip of the uterus could be brought in view, but not the fistula. The opening in the bladder was felt with the finger to extend nearly across the vagina, with unyielding edges, and separated

about a third of an inch in front of the cervix. In delivery, the posterior lip had been lacerated to the vaginal junction, extending some distance into the cul-de-sac; pelvic cellulitis had resulted, with extensive superficial sloughing of this portion of the canal. The uterus was retroverted, and immovable from adhesive inflammation of the vaginal wall to its posterior surface. In the median line, from the posterior lip along the cul-de-sac, the course of the laceration could be felt tense and like a cord.

From the character of the tissue where no union could be anticipated, the only feasible procedure seemed that of uniting the crest of the fold to some point along the cul-de-sac, leaving the cervix uteri within the bladder, as in Case XVIII. Nov. 30, the fistula was, however, closed differently. By snipping carefully along the course of the cicatricial surface on the lateral walls of the vagina, somewhat in the direction E C (Fig. 22, Case XVIII), the angle B then became sufficiently freed to expose the course of the fistula, the edges of which were found to be in a comparatively healthy condition. The anterior lip of the uterus, which had partially sloughed, and formed to a great extent the posterior edge of the fistula, was thoroughly denuded, together with the opposite side, and the opening closed by ten interrupted sutures. The operation occupied two hours.

To state that the day was cloudy, the patient restless, the fistula nearly out of reach, and that no portion of it could be brought in view without first drawing forward the fold with a tenaculum in front of any point to be inspected, would give but an imperfect idea of the difficulties of the case.

In twisting the sutures, I was guided almost entirely by the touch in deciding the point where they had been sufficiently tightened, consequently, three parted from too great tension; these had been passed through the cervix, and at a most important point. They were left *in situ*,

trusting to the integrity of the others, as fortunately they had not parted consecutively.

No fever, pain or tenderness followed the operation. Dec. 11, removed three sutures; the others could not be brought in view without making more traction than was deemed advisable. Dec. 14, the remaining sutures were extricated, and the use of the catheter discontinued. Dec. 26, the case was discharged cured.

CASE XX. First pregnancy; instrumental delivery, after seventy-two hours in labor. A large portion of the base of the bladder lost, together with the cervix and cul-de-sac. By contraction of cicatricial bands, the vaginal tissue became drawn backwards over the fistula. Closed by one operation.

Mrs. O'H., of Syracuse, N. Y., aged 28, was admitted from Bellevue Hospital, at the request of Drs. Barker and Elliot, May 14, 1866.

She had been married about two years, and had given birth to a still-born child three months and a half before admission. The labor lasted three days and nights, and delivery was accomplished by forceps. Three weeks after confinement, while walking about, a sudden gush of urine took place from the vagina, with subsequent incontinence.

*Pathological Condition.*—On introducing the finger into the vagina, a tense circular band was felt, a little less than an inch from the neck of the bladder, extending across the vagina backwards in a crescentic form to the cul-de-sac, where it became lost in a mass of cicatricial tissue. The first impression conveyed to the touch was the existence of a large circular fistula at this point, but on pushing the finger beyond, the true opening in the bladder was felt behind this fold, and nearly an inch from its edge. The entire cervix, and a large portion of the base of the bladder and cul-de-sac, had been lost by sloughing. As the tissue contracted, a portion of the base of the bladder gradually became doubled on itself, and was drawn backwards like a

hood over the fistula and the remains of the cervix uteri, so as to hide both entirely from view.

June 1, 1866. It being impossible to expose the fistula by any manipulation, the band on each side was freely divided laterally with scissors until the fistula was brought perfectly in view, and by so doing, the vagina was increased fully an inch and a half in depth. The fistula was a transverse one, extending nearly across the vagina, with receding edges, so that the actual opening in the bladder would not admit more than the point of the index finger. It was closed by eight sutures; they were removed on the twelfth day, and the case was discharged cured, June 29.

CASE XXI. First pregnancy; natural delivery, after thirty-six hours in labor. Transverse fistula in front of the uterus, with loss of anterior lip. A fold existed in front of the opening, from cicatricial tissue extending forwards towards the neck of the bladder. The cervix uteri was turned into the bladder, and the opening closed by one operation.

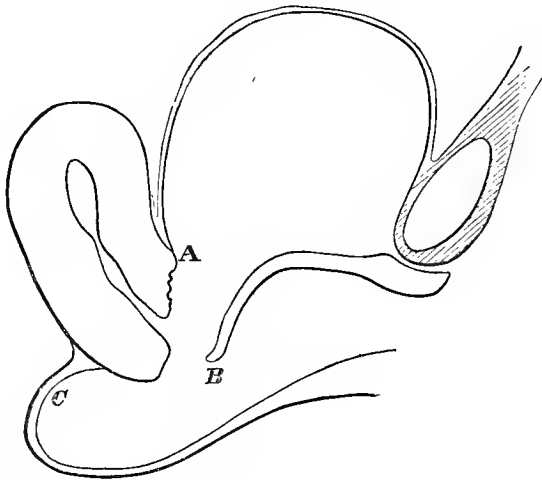
Mrs. B., aged 22, a native of Germany, was admitted from the city, Jan. 31, 1862. About three years and a half before admission, she was delivered, without instruments, by a midwife, of her first child, still-born, after a labor of thirty-six hours. Immediately afterward, the urine began to escape, and during the first week several sloughs were passed.

In the interval before admission, she had been operated on by two different surgeons, without receiving any benefit.

*Pathological Condition.*—On introducing the finger into the vagina, a tense band (Fig. 23) was felt at the point B. Beyond, by turning the finger upward, it passed directly into the bladder, through a transverse fistula, nearly the width of the vagina, with the cervix uteri forming a portion of its posterior boundary. The anterior lip of the cervix, together with about a third of the base of the bladder, had been lost by sloughing. At the point A, the uterus seemed fixed, while the anterior lip of the fistula at B was also to

a great extent immovable, in consequence of cicatricial bands running towards the outlet of the vagina.

FIG. 23.



These surfaces, therefore, could only have been approximated by a degree of tension which would have defeated any attempt at union. The cicatricial bands on each side were situated deep in the sulci formed by the base and lateral walls of the bladder, directly in the course of the large plexus of blood-vessels. It was therefore deemed inexpedient, from the inevitable hemorrhage which would result, as well as the risk of pelvic cellulitis, to attempt to free the anterior edge by dividing the bands in this direction. On the other hand, if it were possible to do so sufficiently, no little difficulty would have been experienced in properly adjusting the edges afterward, without at the same time occluding the uterine canal. For the anterior lip terminated in a much thinner edge than is represented in the diagram, while, from the character of the tissue itself, union was impossible.

After carefully taking into consideration all the facts of the case, it was evident that the patient could only be re-



lieved by turning the neck of the uterus into the bladder. Before any operation could be attempted, it was necessary to prepare the case properly, for the cervix was the seat of an extensive erosion, and the edges of the fistula were in an unhealthy condition from the want of proper care and cleanliness. By the use of large warm water injections several times a day, the occasional use of nitrate of silver in solution, rest, regulation of diet, and improvement of the general health, the parts were brought into a condition free from inflammation at the end of four months.

June 18. I commenced the operation by removing a broad strip on the anterior edge of the fistula, and extending it around into the cul-de-sac on the plane B C. When the surfaces were brought together by eleven sutures, with the line of apposition transverse to the axis of the vagina, the neck of the uterus had been turned through the fistula into the bladder, the uterus retroverted, and the points B and C came in contact without tension.

While introducing the sutures along the posterior line of scarification, some care was necessary to avoid passing through the vaginal wall into the peritoneal cavity. The history of a case will be hereafter presented wherein this accident resulted in an attack of peritonitis. In this case, the sutures were at once removed, and, on her recovery, the fistula was closed by a subsequent operation.

June 30. The sutures were taken out and the patient was discharged from the hospital cured, July 9, 1862.

*Remarks.*—I was assisted in the operation by Dr. Geo. A. Peters, of this city, who had previously operated on the case in the City Hospital, but without union taking place. I am satisfied that this result was in consequence of the existing condition of the soft parts at the time, for the operation had been performed by him with great care. This is the secret of the lack of success in many an opera-

tion, as I have previously stated; but, in this case, the circumstance of the failure was a fortunate one, for, had it been successful, a calculus would undoubtedly have soon formed in the bladder, from a nucleus furnished by the unhealthy condition of the cervix.

I have several times been obliged to make use of the cervix to fill up an opening where it was impossible either to free the edges sufficiently, or to obtain the necessary amount of tissue from the neighboring parts. From the great loss of tissue producing the fistula in such cases, no inconvenience whatever results from the mere position of the organ, if it is brought into a healthy condition previous to the operation. Menstruation, as a rule, takes place without pain or any indication beyond a discoloration of the urine. I have, however, never resorted to this procedure without first explaining the steps of the operation at length to the patient, and consent has always readily been granted.

CASE XXII. Second pregnancy; instrumental delivery, after seventy hours in labor. Loss of the anterior lip of the cervix, with a large portion of the base of the bladder. By contraction of cicatricial tissue, the anterior wall of the vagina was drawn backwards, and nature had nearly closed the fistula by uniting a portion of its edge with the posterior lip of the uterus, thus shutting up the uterine canal within the bladder. Two openings remained, which were closed by one operation.

Mrs. G., aged 33, a native of Ireland, was admitted, April 27, 1864, from North Andover, Mass. She had always been in excellent health; had been married six years, and had given birth to two children, in both cases by instrumental delivery.

The second labor commenced at full term, on Saturday morning, July 23, 1861, by sudden rupture of the membranes. Until 3 P. M., on Monday, the pains were almost constant; the forceps were then applied, and she was delivered of a still-born child weighing ten pounds. From the commencement of labor until a catheter was intro-

duced, previous to applying the forceps, the bladder was not emptied of its contents.

A week after delivery, the urine began to escape involuntarily, and, during the month, several sloughs were passed. The power of retention gradually increased, so that when lying on the back or sitting still, she was able to retain the urine for an hour at a time.

*Pathological Condition.*—The anterior lip had sloughed entirely away, together with a large part of the base of the bladder, thus forming a transverse fistula from one side of the vagina to the other. Nature had attempted to close the fistula by uniting a portion of its anterior edge to the posterior lip of the uterus and vaginal wall, on a line with the cervix. The opening on one side was quite small, and on the other nearly large enough to admit the index finger.

May 16. The larger opening was made sufficiently large to introduce the finger, when the above-described condition was verified, and moreover, it was found that the cul-de-sac had not been involved, but formed a pouch behind the point of union. From the fact, however, that the greater part of the tissue in the neighborhood of the fistula was cicatricial, and had already regained as healthy a condition as possible, it was deemed best to complete the work which nature had so nearly accomplished.

These bands formed the inner surface of the anterior edge of the fistula, and extended from each angle backwards, so as to become blended with the posterior lip of the uterus. Therefore, by contraction of this tissue, the anterior lip of the fistula was drawn backward over the cervix as a hood, in close contact with the vaginal wall. The chief feature of interest in the case was the unusual point at which these surfaces had become attached, for the points B and C (as shown in the diagram of the preceding case) had united, thereby producing the same result as was accomplished by art in that instance.

The closure was completed without difficulty, by extending the line of denuded surface around on the vaginal portion, somewhat outside of the edges of the openings, so that they would be rolled in. These edges were cicatricial, and but for this circumstance, the entire line might have been closed by the efforts of nature. Nine sutures were used for the larger opening and three for the smaller one. They were removed on the eighth day, and the patient returned home cured, early in June.

CASE XXIII. Third pregnancy; natural delivery, after a labor of twenty-six hours. Loss of the cervix uteri, with the whole base of the bladder. By bands in the cul-de-sac, the fistula, which was three inches in length, was drawn into a crescentic form, with its cornua posterior to the cervix uteri. Closed by one operation.

Mrs. L., aged 44, a native of the United States, was admitted from Russell, N. Y., May 25, 1865. She married at 22, and had given birth to three children.

The last labor commenced Jan., 1863, and delivery took place, without instrumental aid, at the end of twenty-six hours. The bladder was not emptied from the beginning of labor until several hours after delivery. On the third day after the birth of her child, the urine commenced to escape for the first time. According to her statement, no slough at any time was passed. But a very imperfect history of her case could be obtained beyond these facts.

*Pathological Condition.*—The greater part of the base of the bladder, together with the whole cervix, had been lost by sloughing. When the patient was placed on the knees and elbows, the fistula, about three inches in length, presented the form of a crescent, with its cornua running posterior to the os uteri. The cicatricial bands ran from the extremities around the circumference, between the pubes and the anterior edge of the fistula; while another, along the posterior lip of the fistula, blended with the lost cornua, and, passing backward, filled the cul-de-sac. The edges

of the fistula were separated in front of the cervix at some distance, but for an inch or more forward from each extremity the two surfaces were drawn in close contact, so as to conceal the angles at the bottom of a deep sulcus formed on each side between the base and lateral walls of the vagina. The inner face of each ramus was nearly bared of tissue, from the near approach at these points of the anterior edge of the fistula, which extended also to the neck of the bladder, without involving it.

The bands were freely divided by scissors until all portions of the fistula could be brought together without tension at any point. The tissue on the inner face of each ramus was carefully dissected off in the form of a flap, so that when the freed surfaces were drawn away from the bone, sufficient room was gained for securing the sutures after relieving the tension of the edges. The chief difficulty in the operation consisted in properly scarifying the angles buried in the sulci. To bring the parts into view, it was necessary to separate the sides by putting the opposite edge on the stretch with a tenaculum, in the hands of an assistant. The whole operation was difficult and tedious in execution, and had to be performed entirely on the knees and elbows, for no portion of the fistula could be readily brought in view while lying on the side. Fourteen sutures were used; they were removed June 25, and the case was discharged cured, July 3, 1865.

CASE XXIV. Fifth pregnancy; natural delivery after a labor of fifty-six hours. Loss of the anterior lip of the cervix and upper third of the base of the bladder. The vaginal tissue was drawn backwards as a hood so as to hide the fistula. The fistula was brought into view and closed, but no union took place, as its edges were cicatricial. Second operation successful, by cutting out the fistula with the surrounding tissue, and bringing together healthy surfaces.

Mrs. G., aged 38, from Dayton, Ohio, was admitted March 5, 1867. She married at eighteen, and was the mother of five children.

Her last confinement began November 26, 1866. The pains were frequent almost from the beginning, and terminated naturally in fifty-six hours. The bladder had been frequently emptied without difficulty during the progress of labor. On the ninth day after delivery she noticed, for the first time, that the urine was dribbling away; by the end of the second week, it all escaped, and, a few hours afterwards, she removed from the vagina a large irregular-shaped slough, which had been thrown off.

*Pathological Condition.*—The anterior half of the cervix had been lost, with a large portion of the vaginal septum, in front of the uterus. By contraction of the cicatricial tissue around the fistula, which was continuous on each side of the posterior lip into the cul-de-sac, the anterior wall of the vagina was drawn backwards like a hood, in a large fold over the cervix, so as to hide it entirely from view. By seizing this fold with a tenaculum and drawing it forward toward the outlet of the vagina, while depressing it at the same time toward the bladder, a small fistula, much reduced in size from contraction, was found situated immediately in front of the remains of the anterior lip, and with great difficulty was brought into view.

March 8. By means of the above manipulation, as the fold was put on the stretch to bring the parts in view, it was divided on each side just behind the neck of the uterus. The edges of the fistula were then scarified and secured by seven sutures, with the line in the axis of the vagina.

March 19. The sutures were removed, but the edges immediately separated, as no union whatever had taken place.

April 16. Operated again; the edges of the fistula being cicatricial for some distance outside of the original boundary, they were removed in one piece by the scissors to the healthy tissue. In addition, that the angle might not

terminate abruptly, it was deemed necessary to take out a V shaped portion from the stump of the anterior lip; the line of scarification extended then to the cervical canal at one extremity, and in the opposite direction on the vaginal surface towards the neck of the bladder, for half an inch beyond the anterior angle of the fistula. The edges were brought together by seven sutures. They were removed on the ninth day, and she was discharged cured, March 14.

CASE XXV. Third pregnancy; instrumental delivery, after a labor of some forty-six hours. Loss of the anterior lip of the cervix and upper portion of the base of the bladder. By contraction, the vaginal tissue was drawn laterally into two folds over the cervix and fistula, and these extended in the long axis of the canal, from the cul-de-sac nearly to the neck of the bladder. Closed by one operation.

Mrs. G., aged 27, from Stamford, Conn., was admitted April 12, 1867. She had been married four years, and had had three children.

Labor at full term commenced with her last child about 7 A. M., June 14, 1866. The pains continued with varied intensity until the afternoon of the following day, when they gradually ceased. After waiting, without any recurrence of labor pains, until the morning of the 16th inst., the forceps were applied, and she was delivered of a still-born child, size unknown.

During the time of labor, there had been no difficulty in emptying the bladder frequently. Two weeks after labor, she began to lose control of the urine, but it did not all escape until the end of the third week, when several sloughs came away.

*Pathological Condition.*—With the loss of the anterior lip and a large portion of the vaginal tissue, the fistula was situated immediately in front of the uterus, as in the preceding case. The vaginal wall was likewise thrown into two large folds, but their direction was in the long axis of the vagina, extending in the median line nearly from the neck of the bladder to the cul-de-sac, hiding from view the

fistula and almost the whole posterior lip of the cervix. The uterus was to a great extent immovable, while, by the contraction of bands in the cul-de-sac, the vaginal tissue was drawn into tense folds, the sides of which were forced into close apposition. By separating them, the fistula was exposed at the bottom of a sulcus about three-fourths of an inch deep.

The most feasible plan at first suggested for the operation was to unite the crest of the folds together as they lay in contact, thus shutting up the posterior lip and uterine canal within the sulcus below. On farther examination, however, it became apparent that by dissecting off the adhesions of these bands to the posterior lip, the tension could be relieved so that the cervix and fistula could then be readily brought to view.

April 23. This was done without difficulty by scissors, and the same mode of operation as in the preceding case was followed, extending the line of union to the cervical canal and to some distance in front of the anterior angle of the fistula. Nine sutures were introduced. They were removed May 4, and the case was discharged cured, May 11.



## CHAPTER VII.

### FISTULÆ CONFINED TO THE UPPER PORTION OF THE BASE OF THE BLADDER.

CASE XXVI. Second pregnancy; instrumental delivery, after a labor of forty-nine hours. A slough had extended in the median line, from the cervix uteri nearly to the neck of the bladder; but, by contraction of cicatricial bands, the opening became a transverse one in front of the cervix. Cured by one operation.

Mrs. G., aged 30, a native of Ireland, was admitted from Stamford, Conn., October 4, 1866. She married at 27, and had given birth to two children, and both by difficult labors.

The last labor commenced at 4 A. M., March 6, 1865, and was terminated, after forty-nine hours, by craniotomy. The bladder had not been emptied during the time of labor, and directly after delivery the urine began to escape through the vagina. On the third day after delivery, a large slough was thrown off and followed by a number of smaller ones during several days afterwards. She was confined to her bed for three months. At the time of her admission, menstruation had become normal, and her general health was perfectly restored.

*Pathological Condition.*—The fistula had originally extended from the neck of the uterus nearly to the neck of the bladder, with its long diameter in the axis of the vagina. In consequence, however, of cicatricial bands on each side of the fistula, which ran from its upper part forward to the lateral walls, the neck of the uterus was drawn down towards the outlet of the vagina, and consequently the opening

had become a transverse one. The cervix, lacerated laterally in the previous labor, had, without having suffered any great loss of substance, become in consequence a mass of cicatricial tissue, while the cul-de-sac was uninjured.

Nov. 14. It was at first deemed best to divide the bands in order to restore the vagina to its original depth and the fistula to its primitive shape. But as these bands served really to approximate the edges of the fistula, now almost in contact, and, if not thoroughly divided, might, by contracting, thus change the line of union and open some portion of it, they were simply scarified and united *in situ* by fourteen sutures. As the anterior lip formed part of the posterior edge of the fistula, it was necessary to carry the line of scarification just in front of the os, and the only difficulty in the operation consisted in properly adjusting the anterior lip to the irregularity in the line of union caused by its presence. Eight sutures were removed November 23, and three on the next day. The last one could not be found until December 4. On December 9, the patient was discharged cured.

CASE XXVII. Seventh pregnancy; Natural delivery, after sixty-seven hours in labor. Loss of the whole base of the bladder. Fistula was crescentic in shape, with its cornua drawn toward the cul-de-sac. The anterior lip of the cervix formed the posterior boundary of the fistula. Closed by one operation.

Mrs. M., aged 29, a native of Ireland, was admitted from Hartford, Conn., November 24, 1862. Her general health had always been excellent, and she had given birth to six children without difficulty.

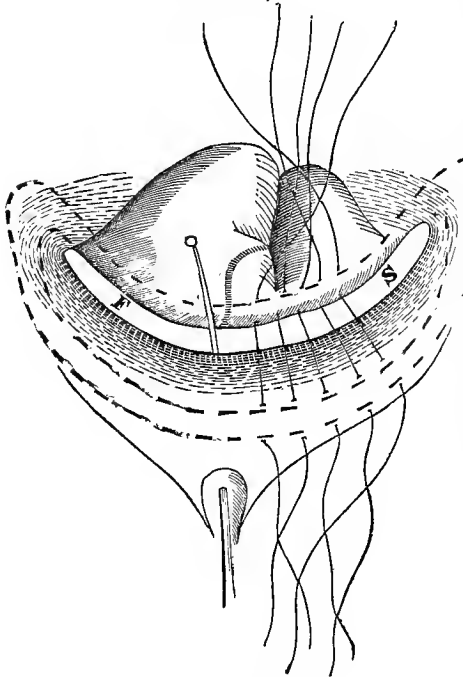
The seventh and last labor commenced at full term, about 11 P. M., Friday, September 8, 1860. The pains were slight until Saturday noon, when they came on with great force, and were almost continuous until delivery. Rupture of the membranes took place very early Sunday morning,

when a physician was sent for and placed in charge. Natural delivery was accomplished at 6 P. M., on Monday, of a still-born male, of very large size.

Until twenty-four hours before delivery, the bladder had been regularly emptied without assistance. On the eighth day after her confinement, involuntary escape of urine by the vagina was first noticed. During the next two weeks several large sloughs were passed. Seven weeks after delivery, menstruation returned, and continued regular afterward.

*Pathological Condition.*—The entire base had sloughed away from the cervix uteri to the neck of the bladder. The fistula (Fig. 24) was crescentic in form, in consequence of the traction excited by a band which extended from each angle into the cul-de-sac; and, by contraction, the sides of

FIG. 24.



the fistula were drawn nearly in contact with the shortened vagina. The opening was large enough to admit three fingers into the bladder, and its upper border was composed of more than half of the cervix. The neck of the uterus had been lacerated from before backward to the vaginal junction, and was supposed to have been the result of some previous labor.

Dec. 2. Closed the fistula with nineteen interrupted sutures. The lower border of the fistula

was composed almost entirely of cicatricial tissue. To avoid this it was necessary to remove a broad strip on the vaginal surface, nearly half an inch from the anterior edge of the fistula, and made continuous on the posterior lip in front of the cervix. As will be seen by the dotted lines in the diagram, it was extended for some distance beyond the angles of the fistula, so as to avoid the formation of a fold at these points. The denuded surface, across the cicatricial bands on each side, was made somewhat wider than represented, but superficial, as the object was not to cut through them; for, by their traction in drawing the edges of the fistula together, the sutures would be to a great extent relieved of tension. As the scarification in front of the anterior or lower edge of the fistula represented the greater arc of the circle, the sutures were all passed, converging, as it were, to a common centre. When they had been twisted, it will be seen that the cicatricial tissue forming the anterior lip was rolled entirely within the bladder. The sutures were removed on the ninth day, and the case discharged cured shortly afterwards.

CASE XXVIII. First pregnancy; natural delivery, after a labor of one hundred and one hours. Loss of one-third of the base of the bladder in front of the cervix. By cicatricial bands extending into the cul-de-sac, the fistula was lessened in size, the vagina shortened and a fold drawn backwards over the opening so as to hide it from view. Closed by one operation.

Mrs. McK., aged twenty-five, was admitted from the city, Oct. 10, 1862. About three years before admission, she was taken in labor with her first child on Friday afternoon. The pain continued severe from Friday night until Tuesday, 10 P. M., when she was delivered of a still-born child by the efforts of nature. On Saturday night her attendant attempted to apply the forceps, but failed.

The bladder was not emptied from bed-time on Friday night until during the day on Monday, when a catheter

was introduced, but the urine immediately afterward began to escape from the vagina. Two weeks from delivery, several large sloughs were passed.

*Pathological Condition.*—Behind a fold extending across the vagina a fistula was felt, about half an inch in length, but hidden from view. About one-third of the upper part of the vagina in front of the cervix had been lost, and, in addition, extensive sloughing had occurred on each side of the cervix into the cul-de-sac. The vagina was shortened and the opening reduced in size in consequence of the contraction of this cicatricial tissue, which drew a fold of the vagina anterior to the fistula backward toward the cul-de-sac over the opening.

Oct. 26. Divided this band through with scissors on both sides, in a line with the fistula; and, on then drawing the fold forward with a tenaculum, the opening into the bladder was brought into view. More than an inch was gained in the depth of the vagina by dividing these bands. The fistulous edges were scarified without difficulty, and united by eight sutures.

Nov. 3. The sutures were removed and the union was found perfect. Nov. 22. The case was discharged cured, with the incisions healed and the vaginal depth greater than before the operation.

CASE XXIX. Third pregnancy; instrumental delivery, after thirty hours in labor. Loss of the upper half of the base of the bladder, with lateral laceration of the cervix uteri by a previous labor. The fistula was crescentic in shape, with its cornua extending into the cul-de-sac, and the anterior lip of the uterus formed its posterior boundary. Closed by one operation.

Mrs. C., aged 30, was admitted from the city, Sept. 26, 1866. She married at 26, and had given birth to three children.

The last delivery was accomplished by forceps on the 24th of June, 1866, after a labor of thirty hours. Eight

days after the birth of her child, while walking about the room, a sudden gush of urine took place from the vagina. She stated that no slough was passed.

*Pathological Condition.*—Nearly one-half of the base of the bladder was lost, with complete lateral laceration of the cervix to the vaginal junction. The fistula was crescentic in form, and its cornua were drawn backward somewhat behind the cervix, in consequence of cicatricial bands filling the cul-de-sac, while the posterior edge or concave border of the fistula was formed almost entirely of the anterior lip of the cervix.

Oct. 27. The bands in the cul-de-sac were divided with scissors entirely across at a right angle to their course, so that, the edges being freed, the fistula became a transverse one, into which three fingers could be passed.

Without bringing the fistula into this form it would have been impossible to have closed it, as the edges in front of the cervix were separated for nearly an inch, and, with the arc of the anterior edge so much larger than the posterior one, the two surfaces could not have been approximated without forming a large fold at each extremity of the fistula. The anterior lip of the cervix still protruded into the fistula; to preserve the line, therefore, it was necessary to extend the scarification across the cervix, in front of the os. After freshening the edge of the posterior lip, the scarification was extended on the vaginal wall to some distance beyond each angle of the fistula, so as to compensate for its anterior edge, which was still somewhat longer than the posterior one. By doing this, the formation of an abrupt fold at each end was avoided; and it could be extended until it became lost on the vaginal level.

While the original fistula presented a crescentic form, with the concavity toward the cul-de-sac, when united by fourteen sutures, the line was reversed, with the concavity

toward the neck of the bladder, but forming a longer arc. The sutures were removed, October 12, and the case discharged cured, Oct. 25.

CASE XXX. First pregnancy; instrumental delivery, after a labor of some ninety-six hours. Loss of the upper third of the base of the bladder. The opening was contracted and surrounded by cicatricial tissue. The fistula and neighboring tissue shut in at the bottom of a deep pouch extending across the vagina. Operation successful.

Mrs. H., aged 36, a native of the United States, was admitted from the city, Sept. 16, 1864.

Labor commenced Oct., 1863, with the pains early becoming both severe and frequent, but no apparent progress took place, and on the third day puerperal convulsions came on. About twenty-four hours afterward, while still unconscious, her child was delivered by forceps, still-born.

She was unable to state whether the bladder was emptied during the time in labor, or before she recovered her consciousness, for several days after delivery. Two weeks from delivery, a number of sloughs were passed, immediately followed by escape of urine. Her general health remained feeble, with great prostration of the nervous system. Menstruation afterward became regular, but scanty.

*Patbological Condition.*—About one-third of the upper part of the base had been lost, just in front of the cervix, but by cicatrization and shortening of the vagina, the fistula had been so much reduced in size as only to admit the point of a large sound. It was situated in a mass of cicatricial tissue, which extended on each side nearly to the lateral wall of the vagina, and from each end for more than half an inch beyond, so that no hope of union could be anticipated by closing it *in situ*.

A concave incision was made in healthy tissue about half an inch from the neck of the bladder, entirely across the vagina, but gradually more superficial toward either extremity. The line of scarification was then extended along the

concave edge, but well outside of the cicatricial tissue and around posteriorly over the anterior lip, just in front of the os uteri, to the starting point. This denuded surface was brought together with nine sutures, leaving the fistula at the bottom of a long closed pouch, thus avoiding all tension from cicatricial tissue. The sutures were removed on the eighth day, and the case was discharged cured, Oct. 30.

CASE XXXI. Fifth pregnancy; delivered by version, after a labor of eight hours and a half. A vesico-vaginal fistula, where nineteen attempts had been made to close it previous to admission. Found no cervix uteri, but two openings in the median line, high up in the vagina, leading into the bladder, with a septum between the two, about half an inch in width. This septum was divided, when it was ascertained that the fistula was situated immediately in front of the remains of the cervix. Its edges were cicatricial, and the loss of tissue had been extensive. Healthy tissue was brought together from beyond over the opening, and closed by one operation in the axis of the vagina.

Mrs. B., aged 37, was admitted to the hospital from Clifton, Monroe County, N. Y., Nov. 28, 1867. She had married at 28 years of age and had given birth to five children, with one miscarriage. The first and second child were still-born at full term. The third was delivered alive at the full period of gestation, and the fourth, a breach presentation, was born dead, at about the seventh month. Two years afterward a miscarriage occurred at the third month.

With the last labor at full term, the membranes ruptured at 4 P. M., the arm presenting. Her physician did not interfere until about dark, but continued to manipulate until midnight, when her pains ceased entirely; shortly afterward, however, he succeeded in delivering her, by version, of a dead child.

On the next day she discovered that the urine all escaped by the vagina.

*Pathological Condition.*—The vagina was found unusually deep. In the median line, about an inch and a quarter from the neck of the bladder, an opening was found, into which the first joint of the index finger could be introduced, and



beyond, another about the same size, with a septum between about half an inch in width. The cul-de-sac was uninjured.

Dec. 20. Divided the septum between the two openings, with the view of ascertaining the condition below. At the bottom of a pouch about half an inch deep, the fistula was brought into view; its edges and the surrounding tissue were cicatricial. Its posterior border was formed by the remains of the cervix uteri, which had sloughed. It was found impossible to bring the edges of the fistula together in any direction, and from the character of the tissue and the amount of tension, it was remarkable, even with the perseverance of the previous operator, that a union of any portion of the line had been obtained.

From the neck of the bladder to some distance into the cul-de-sac, beyond the remains of the cervix, a denuded line was extended outside, in the form of a long ellipsis; then all the intervening surface was removed to the edges of the septum, previously divided. By doing so the stump of the cervix was not involved, for the position of the uterus was backward, so that the upper angle of the farthest opening left by the previous operation terminated just beyond, at the beginning of the cul-de-sac. Seventeen sutures were introduced, and after the edges had been drawn up together, the line measured exactly three inches. It was necessary to extend it to this length before the folds at each end became reduced to the level of the vagina. The denuded surface was extended inward, so as to include the raw edges of the divided septum, with a view of lessening the size of the pouch and at the same time to avoid leaving a raw surface in contact with the urine. These surfaces it was thought would doubtless unite firmly, notwithstanding the character of the tissue, from the fact that they were relieved of all tension. Dec. 30, removed eleven sutures, Jan. 7th the remaining five, and on the 16th inst. she returned home cured.

CASE XXXII. First pregnancy; instrumental delivery, after a labor of about ninety hours. Fistula in front of the cervix. Partially closed by an operation previous to admission, but by the use of the cautery afterward, the surrounding tissue had become cicatricial. No union after the first operation. The second operation successful, by removing the unhealthy tissue.

Mrs. B., aged 20, was admitted April 13, 1863, from the city. Labor at full term commenced on Thursday, Feb., 1862. The membranes ruptured on Friday, and delivery was accomplished by forceps on Tuesday, the child being still-born.

The urine had been drawn regularly previous to the introduction of the forceps. It began to escape soon after delivery, and several small sloughs were passed at the end of the third week.

She was subsequently operated on in one of the public institutions of the city with partial success, and afterward an attempt was made to close the remaining opening by means of the actual cautery.

*Pathological Condition.*—A fistula of an inch or more in length had existed across the vagina in front of the cervix; this had been closed, with the exception of a small opening at the upper angle. For some distance around the fistula, the soft parts had been recently converted into cicatricial tissue.

April 15. The fistula was closed by five sutures, after removing, as it was thought, the greater part of the cicatricial tissue in the form of a cone. On the eighth day the sutures were removed, and the edges immediately separated, as no union had taken place.

May 14. Passed the point of a pair of scissors through the fistula into the bladder, and enlarged the opening about half an inch in either direction. A portion of the base of the bladder, in the form of a cone and about a quarter of an inch in width, was then removed entirely around the fistula down to the edge of the opening into the bladder, without touching its mucous membrane. Seven sutures were in-

troduced; they were removed on the ninth day, and the case discharged cured, June 8.

This case is only of interest in showing the effects of the cautery as a means of closing an opening, however small; a very uncertain procedure, and one which generally converts a simple case into a complicated one—a result equally to be anticipated from caustics when used for the same purpose.

## CHAPTER VIII.

### FISTULÆ INVOLVING THE BASE OF THE BLADDER.

CASE XXXIII. Fourth pregnancy; instrumental delivery, after a labor of twenty-one hours. Child weighing sixteen pounds. Loss of the whole base of the bladder. The fistula was more than three inches in length and extended obliquely to the right, across the axis of the vagina, from contraction of bands in the cul-de-sac. Closed by one operation. A small opening subsequently occurred from getting up too soon. Second operation successful. By traction, a portion of the line separated which had been closed by the first operation. By the third operation, but partial union was obtained. Discharged for disorderly conduct, readmitted afterward, and discharged cured by the next operation.

Mrs. W., aged 31, a native of Ireland, was admitted, Oct. 11, 1864, from Brooklyn, on the application of Prof. Frank H. Hamilton. She married at 22, and had given birth to four children.

Labor with the last child commenced at 7 P. M., Saturday, March, 1860, by a sudden rupture of the membranes, and followed immediately by the first pains of labor. At 10 P. M., a physician took charge of her case. Shortly afterward, she began to suffer from severe cramps in the legs. Chloroform was administered, and she was kept under its influence for three hours; but, as soon as she became insensible, the action of the uterus ceased, with no return of the pain until the next day. Between 3 and 4 P. M., on the following day, while under the influence of an anæsthetic, the forceps were applied, and she was delivered of a still-born child, which she stated weighed sixteen pounds. She was not in labor more than twenty-one hours. The bladder was emptied several times during the progress of labor, and the catheter was introduced before the forceps were ap-

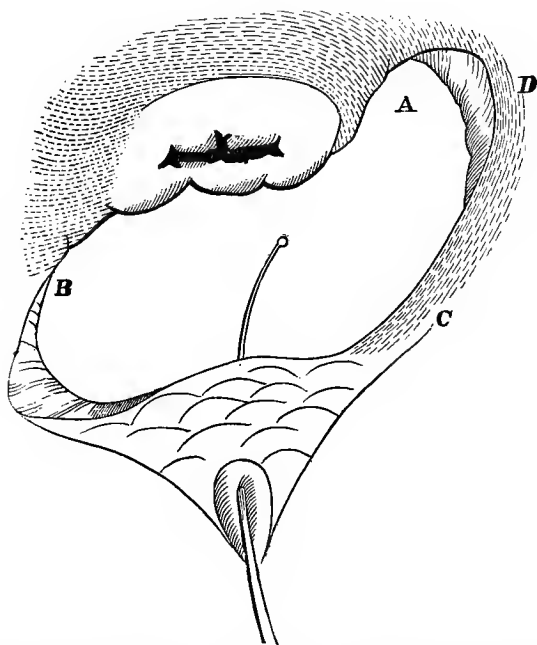
plied; but, on recovering her consciousness after the chloroform, she found the bed saturated with urine, which continued afterward to escape without any retentive power.

She could not recollect that any slough was passed; but she had an offensive discharge for a long time from the vagina, and for several months was unable to leave her bed.

In January, 1861, Prof. Hamilton operated, but without any marked result, except that she thought that, while lying on the back, the urine could be retained for a short time. During the following August, another surgeon of Brooklyn operated, but without gaining any benefit.

*Pathological Condition.*—The entire base (Fig. 25), with a portion of the anterior lip, of the uterus, had been lost, to the neck of the bladder. The posterior wall and fundus of

FIG. 25.



the bladder protruded through the fistulous opening into the vagina. The cervix uteri was in the midst of cicatricial

tissue, and its posterior lip was blended with a mass of the same character, filling up the cul-de-sac. The bands were more dense to the right side, and, spreading over the lateral wall of the vagina, extended forward along the sulcus, so as to involve a portion of the anterior lip of the fistula.

By the tension thus exerted, the fistula was drawn obliquely across the axis of the vagina, carrying the angle of the fistula on the right side into the cul-de-sac, somewhat posterior to the cervix uteri.

When the patient was placed on the knees and elbows, the fistula presented the appearance indicated in the diagram, being more than three inches in length and over an inch in breadth in its widest diameter, between the cervix uteri and the neck of the bladder. At each extremity of the fistula the edges were shelving, so as to narrow somewhat the opening on the bladder surface.

At A and B (Fig. 25), the mouth of the ureter on each side could be seen in the edge of the fistula. The cervix uteri was seared over, as if by the cautery; and, although the os had been lacerated, the canal, a line or two within, was too small to admit the most delicate probe. The uterus was almost immovable, while the anterior lip of the fistula, in the neighborhood of the neck of the bladder, was quite free. The urethra was uninjured.

For nearly a month, she was under preparation for the operation.

Nov. 19. In the presence of Prof. Hamilton and several other members of the profession, I operated for closing the fistula in the following manner. The cervix uteri was first freed of its adhesions behind, so that it could be readily drawn down toward the neck of the bladder. The division was then extended well toward B, and in the direction of A, nearly to the angle of the fistula on that side. The division, however, purposely, was not carried entirely across the vagina, in order that the remaining portion of the band

running from the cul-de-sac along the anterior lip, D C, might be made use of, by its traction, to keep the edges of the fistula together, free from strain, after twisting the sutures. But before this force could be brought into action, it was necessary freely to separate the attachment of this band, in the direction D C, from the neighboring cicatricial tissue on the lateral wall of the vagina. As soon as this was done, that side of the fistula was drawn nearly over to the neck of the uterus, and the opposite edges could be brought together, free from tension at any point.

As the bladder protruded through the fistula, so as to obscure it entirely when the patient was placed on the left side, it was necessary to perform every step of the operation on the knees and elbows, and nearly two hours were required for its accomplishment. With the exception of the shelving portion at each angle of the fistula, no other part of its edge was included in the line of scarification. It was extended a little outside on the vaginal surface, and across the cervix uteri in front of the os. A more uniform or regular line was thus obtained, and the cicatricial edges of the fistula were avoided. The cervix uteri was attached a little to the right of the neck of the bladder, and when the operation had been completed, from the traction exerted by the undivided portion of the band from the cul-de-sac extending along the point D, the united line was somewhat oblique, but at the same time nearly in the axis of the vagina.

The patient was corpulent, and in consequence of the great fatigue resulting from the position in which the operation could alone be performed, its execution was both tedious and difficult.

Ten days afterward, on examination, every portion of the line was found perfectly united; but, in consequence of its great length, it was deemed advisable to leave the sutures *in situ* a few days longer.

During the night, in an excess of joy at the prospect of being cured, she became intoxicated through the aid of some outside friends. It was impossible for the nurse to keep her in bed, and, throwing away the catheter, she danced about the ward for some time; in fact, she was on her feet for several hours. In the morning, the urine was found escaping freely from the vagina, in consequence of the tearing out of the last suture in the angle on the right side, leaving an opening through which the point of the sound could be passed.

Dec. 3. Removed all the sutures, and found that the opening had not enlarged.

Dec. 16. The patient was prepared for an operation to close the above-mentioned opening, but, on examination, it was found to have healed by granulation. Another opening, however, large enough to admit a No. 6 bougie, was detected a little to the right of the uterus, and about an inch from the end of the line. The scarification was extended some distance beyond the fistula in either direction, and directly across the previous line of union; this course was chosen as the one in which the least traction was exerted. The operation was performed with the patient lying on the left side; it was, however, difficult to keep the parts in view. The operation lasted an hour and a half, and required fourteen sutures to close the opening.

Dec. 28. Six sutures were removed. The line had united, but a small opening was now discovered in the other extremity to the left, in the angle nearest the outlet of the vagina, and at a point where the tissue was entirely cicatricial. Jan. 6, 1865. The remaining sutures were removed, with no increase in the size of the opening.

Jan. 24. Closed the small opening by extending the line of scarification at a right angle to the old one, along the sulcus formed by the base of the bladder and lateral wall of the vagina on that side. This was done for the



purpose of obtaining a flap of healthy tissue from the lateral wall, which was dissected off and folded down over the fistula, using seven sutures. The patient was very unruly while in bed after the operation, and but little benefit was anticipated.

Feb. 3. The sutures were removed. The opening had partially closed, and was not large enough to admit the point of a pocket-probe. When well enough, she was discharged for misconduct.

Nov. 7, 1865. The patient was readmitted under promise of good behavior. The character of the vaginal tissue had improved, in the mean time, to a remarkable degree.

The previous operation of Feb. 3 was repeated, using eight sutures. They were removed on the eighth day, and the case was discharged cured, early in December.

This case beautifully illustrated a mode of procedure of which I always avail myself of when possible: by so directing the line of tension exerted by a band of cicatricial tissue, that the newly approximated edges will be forced together by its traction, and thus aid in relieving the strain, which might otherwise be too great for the sutures to bear.

I am satisfied that this case could not have been cured by any other method. Another point of interest is that the edge united presented the longest continued line I have ever seen brought together in the vagina, with the exception of a case of laceration, lately discharged cured from the hospital, where the child's head had passed into the rectum, lacerating the whole recto-vaginal septum from the cul-de-sac through the sphincter ani and perineum. This was closed by twenty-three sutures in the vagina and five through the perineum, and united perfectly throughout; but in the case there had been no sloughing, and the edges within the vagina lay almost in contact.

In many respects, the shape of the fistula and plan of procedure adopted bear a close resemblance to the case of Mrs. S., Case XVI.

CASE XXXIV. Second pregnancy; instrumental delivery, after a labor of ten hours. The fistula extended obliquely across the axis of the vagina, from the right of the cervix uteri to the left of the neck of the bladder. Operation successful, and at the third month of pregnancy.

Mrs. G., aged 31, a native of Ireland, was admitted from Norfolk, Conn., Dec. 11, 1862. She had been married twelve years; her first child was born nine years after marriage; she then had two miscarriages, and her last child, by the birth of which she was injured, was born a year before admission.

Labor at full term commenced early Monday morning, Dec. 24, 1861. About noon the pains became frequent and severe; they continued, without progress, until 3 A. M., on Tuesday, when the forceps were applied. The child was born alive and weighed twelve pounds, but died four hours after birth.

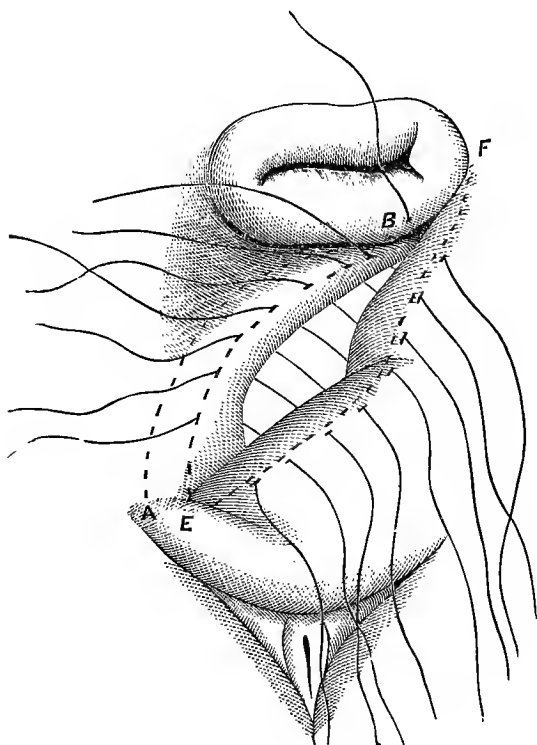
She passed her urine on Monday morning, but the bladder was not again emptied until the catheter was introduced, just before the forceps were applied. A week after delivery she noticed a slight moisture, but incontinence did not occur until three weeks afterwards, when a large slough was separated. At the time of admission she was about three months pregnant, and was anxious to have the fistula closed before being again confined.

*Pathological Condition.*—A fistula, from a few lines to the right of the os uteri, extended obliquely across the vagina to the left, where a portion of its course became hidden in the sulcus on that side. It had originally extended along the base, in the direction of the neck of the bladder, but had become deflected to the left by the contraction of cicatricial bands, which extended on that side from the left or

lower extremity of the fistula toward the cul-de-sac and lateral wall of the vagina. Its edges were receding and had contracted, but the opening in the bladder was still large enough readily to admit two fingers.

Dec. 17. The vaginal tissue was snipped by scissors the whole length of the fistula, on the left side, about a third of an inch from its edge, along the line A B, so as to free it perfectly from the bands drawing it in that direction. The edges of the opening were then freshened between the dotted lines E to F. They were very thick,

FIG. 26.



and the vaginal tissue lax and free from all tension; as soon as the band had been divided but eight sutures were needed. The suture at the upper extremity was passed

through the neck of the uterus. The case presented but little difficulty, except in properly scarifying the lower edge E, running into the sulcus. The chief feature of interest in the case was the fact that the patient was pregnant. No bad symptoms followed the operation; the sutures were removed on the eleventh day, and, January 14, 1863, she returned home, cured.

CASE XXXV. Fourth pregnancy; delivered by forceps, after a labor of fifty-one hours. Loss of the entire base, with the neck, of the bladder. The fistula was closed by bridging over the opening with vaginal tissue turned into the bladder.

Mrs. M., aged 32, a native of England, was admitted from Northampton, Mass., Dec. 21, 1864. She married at 25, and had given birth to four children by natural labors, with the exception of the last.

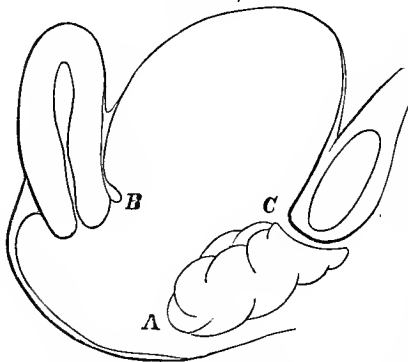
Labor commenced by a sudden rupture of the membranes between 2 and 3 A. M., Saturday, September 12, 1859. The pains came on immediately, and were both strong and frequent from the beginning. An irregular practitioner was placed in charge of the case on Sunday, 10 A. M. The head reached the perineum about 5 P. M., and, although the pains continued with great force, no farther progress took place in the delivery. On Monday, at 2 A. M., convulsions set in. The attendant was discharged and a physician sent for, who at once applied the forceps and delivered her of a large male child, still-born.

She had two convulsions before delivery, and four immediately afterwards. She was unable to state whether a slough was thrown off, but recollected that for a week or more after delivery the vaginal discharge was exceedingly offensive, and that it was accompanied from time to time with hemorrhage for over two weeks. It was not until three weeks after delivery that the urine began to escape from the vagina, and at first, for a few days, in very small

quantities. During the whole following winter she remained extremely feeble, and was confined to her house.

*Pathological Condition.*—The fistula extended from the neck of the bladder to the cervix uteri, and from one side of the vagina to the other. At each angle the edges sloped inward from the vaginal surface, so that the opening in the bladder was much smaller, and not more than an inch and a quarter long by about an inch in width. Cicatricial bands extended from in front of the fistula to the urethral outlet, and backward along the angles to the lateral walls into the cul-de-sac. The vaginal tissue in front of the fistula was hypertrophied (Fig. 27), and presented a singular condition, as mass of loose tissue; it was thrown into numerous folds like a cystocele. By contraction of the lateral bands, in shortening the vagina, this mass was drawn backward so as to override the anterior lip and entirely hide it from view, giving the impression, at first sight, that the fistula was little more than a transverse fissure.

FIG. 27.



From the anterior lip of the fistula at C, the sloughing had extended on the bladder surface for nearly half an inch, so as to involve a portion of its neck; and it was feared, in consequence, that incontinence would still exist after closing the opening.

Dec. 23. Operation. From the condition of the urethra, the main point was to close the fistula in such a manner that traction would not be exerted on the bladder extremity of the urethra; for, being already patulous, if drawn straight there could be no retentive power whatever. To obviate this difficulty (which could not have been avoided had the

true edges of the fistula been brought together), the loose tissue in front of the fistula was made available.

The points A and B could be brought together without difficulty; the line of scarification was extended, therefore, from A, around the vaginal surface, in front of each angle of the fistula to the anterior lip of the uterus, so that the whole line, when completed, was nearly in the same plane. The denuded surfaces were then brought together with nine sutures, three of which were passed through the anterior lip of the uterus, and the whole formed a continuous line entirely across the vagina just in front of the cervix.

By this means, no portion of the edges of the fistula was involved, except at the angles. They were left undisturbed and free from traction, while a large part of the vaginal tissue forming the mass had been turned into the bladder as a plug. Although the angles were to a great extent composed of cicatricial tissue, yet, from the fact of their sloping inward, a much broader surface was brought in contact at these two points than at any other.

The cicatricial bands were not divided at any point, for it was obvious that any traction exerted by them on the vaginal surface, in this direction, would only aid the object in view by keeping the sides of the urethra together. By their action, also, the mass was forced well up against the inner face of the arch of the pubes, so as to keep the bladder extremity of the urethra closed as by a valve.

The uterus was perfectly movable, and the edges B and C could have been brought together without the slightest difficulty by a very simple operation, had it been deemed proper to follow the line of the fistula. Without a full appreciation of the condition of the neck of the bladder, with the mechanical result produced when drawn backward so as to cause a patulous urethra by straightening the canal, the edges of the fistula would unquestionably have been simply brought together as the proper operation, and continence must have been the result.

In the whole course of my experience, I have never seen a case which more beautifully demonstrated the absolute necessity of studying closely the points of each individual case as a distinct problem, or a result more satisfactory when, as such, it was solved.

The sutures were all removed, Jan. 2, and the patient returned home, Jan. 23, with perfect control of the urine. The vagina remained of natural depth, which would not have been the case had the neck of the uterus been united to the neck of the bladder in closing the edges of the fistula.

CASE XXXVI. First pregnancy; in labor forty-five hours, and delivered by forceps. Loss of the whole base of the bladder. The fistula was closed, after dividing the bands in the cul-de-sac, by drawing down the cervix uteri, and uniting it to the neck of the bladder.

Mrs. B., aged 24, a native of England, was admitted from the city, July 9, 1862. She married at 18, and had three children, with two miscarriages afterward, at four and seven months.

She received her injury in the first labor, which commenced at full term at 8 P. M., Saturday, May 30, 1857. Its progress was tedious, and at 5 P. M., on the Monday following, the forceps were applied, and she was delivered of a still-born child, size not noted.

The bladder was not emptied from Friday evening until Tuesday morning, when a catheter was introduced, and, immediately after, the urine began to escape by the vagina. One month after delivery, a large slough was separated. The two miscarriages resulted from overwork and lifting while washing; the last one was two years previous to admission.

*Pathological Condition.*—Loss of the entire base of the bladder. A cicatricial band extended from the neck of the bladder along the lateral wall near the cervix uteri, and into the cul-de-sac, on each side.

As the patient was in good condition for an operation, on the day after admission the cervix uteri was divided laterally to the vaginal junction, and the bands on each side were cut entirely through behind, so as to free the cervix. The edges of the fistula were then scarified, seventeen sutures were introduced, and the cervix uteri was drawn down and united to the neck of the bladder; the line of union being in the form of a crescent, with its concavity toward the cul-de-sac. The operation was performed with the patient only partially under the influence of ether, as, from some individual peculiarity, it was impossible to bring her wholly under its effect.

July 19. The sutures were removed, the operation was successful, and the patient was discharged, cured, with a vagina some three inches in depth.

CASE XXXVII. Fourth pregnancy; one hundred and five hours in labor; delivery by forceps. The whole base of the bladder lost by sloughing, with the inner face of the left ramus denuded. The fistula was closed by three progressive operations.

Mrs. Van R., aged 40, a native of Ireland, was married at 28; had given birth to four children, all still-born.

The last labor commenced at full term, at 7 A. M., Saturday, in the fall of 1857, by a sudden rupture of the membranes. The pains continued, almost without intermission, from the beginning until the following Wednesday, when the forceps were applied at 4 P. M., and delivery was accomplished of a very large child, still-born. During the progress of labor, the bladder had been frequently emptied, but, immediately on delivery, the urine began to escape, and continued to do so in small quantities until three weeks afterward, when an immense slough was thrown off.

Dr. Sims and myself saw the case, at the request of the physician who effected the delivery. She was very much prostrated, and was admitted to the hospital as soon as she



could be moved, but it was some four or five months before she recovered her health, and she then left the institution without an operation. She was readmitted from the city, Jan. 28, 1864.

*Pathological Condition.*—The whole base of the bladder was lost by sloughing, from the neck of the uterus to the neck of the bladder. The left ramus, along the fistula, was entirely denuded of all tissue except its periosteum, while on the right side there still remained a slight covering. The posterior wall and the fundus of the bladder protruded from the fistula. The cul-de-sac, cervix uteri, and neck of the bladder had been uninjured.

Feb. 5. Closed a portion of the fistula, as it was impossible to bring the edges together in any continuous line. The upper edge of the fistula, from a little to the left of the cervix, was denuded, and the line extended around its margin to the front of the right ramus. The tissue against the right ramus was dissected off with scissors for some distance in either direction (see Case LV, Fig. 30), so that the flap could be drawn well out into the centre of the vagina. The scarified edges were then brought together by thirteen sutures.

When thus secured, the uterus had been drawn nearly an inch nearer the neck of the bladder, and the line of apposition extended from a little to the right of the cervix, obliquely across the axis of the vagina, toward the left acetabulum. The fistula was about half closed by this procedure. The remaining portion of the opening was somewhat in the shape of a right-angled triangle, the perpendicular, represented by the lateral wall on the left side, and the base, by the anterior edge of the fistula in front of the neck of the bladder.

A catheter was introduced, and the case treated in every respect as if the whole had been closed. Nearly all the urine passed by the catheter.

When the sutures were removed on the twelfth day, it was found that all had united, and the bladder no longer prolapsed.

March 9. The scarification was begun in front of the cervix uteri, at about the centre of the edge represented by the longer side of the triangle, and, extending into the angle toward the right acetabulum, continued along the base or lower portion of the fistula to a distance corresponding to the opposite denuded surface. Seven sutures were used, and the line, when secured, extended obliquely across the axis of the vagina, in an opposite direction from that of the first operation.

The remaining portion of the fistula was now represented by a segment of a circle, with its arc formed by the left lateral wall of the vagina. The two edges of the opening were not more than half an inch apart in the centre, while at the same time the vagina had not been materially narrowed in diameter, in consequence of the elasticity and previous moulding of the parts.

April 30. The remaining portion of the fistula was closed in the axis of the vagina by ten sutures. The edge along the base of the bladder was scarified, and the denuded surface extended on to the lateral wall in the form of an arc, the centre of which was at least half an inch above the edge of the fistula on that side. This was necessary, in consequence of the ramus, on a line with the edge of the opening, being stripped of tissue, while above, the movable lateral wall could be doubled down to meet the edge of the fistula, and, as its scarification was in the form of an arc, it readily conformed to the curved edge on the opposite side formed by the base of the bladder. Behind the surfaces thus brought together, a pouch, communicating with the bladder, was left, nearly two inches in length.

The direction of the three lines of union by the dif-

ferent operations may be represented by the letter K; the first operation being the upper limb; the second, the lower one; and the last, the upright part.

The sutures were removed on the eleventh day, and the union was found perfect, except a small opening caused by the cutting out of a suture. This, however, closed in a few days, and the case was discharged, cured, shortly afterward.

CASE XXXVIII. First pregnancy; in labor about fifty-eight hours, and delivered by forceps. A fistula existed, involving a loss of the whole base of the bladder, with the face of each ramus nearly denuded; the inverted bladder, with a portion of intestine, frequently became strangulated by protruding through the fistula. Closed by one operation.

Mrs. O'D., aged 27, a native of Ireland, was admitted from Manhattanville, N. Y., April 3, 1866. She married at 25, and gave birth to a still-born child five weeks previous to admission.

She was in labor from Tuesday morning until Thursday night, when she was delivered by forceps. On the second day afterward she noticed the escape of urine by the vagina.

*Pathological Condition.*—A fistula involving the whole base of the bladder, with but a few lines of tissue covering the inner face of each ramus. A thick band of cicatricial tissue extended on each side, from near the ramus, along the sulcus, to the cervix uteri. The inverted bladder protruded through the opening to the vulva. The cervix uteri, cul-de-sac, and neck of the bladder, were uninjured. The vaginal tissue was swollen and sensitive, and the vulva and nates were very much excoriated from the urine and a want of proper attention.

In two instances after her admission, prior to closing the fistula, she was suddenly seized with a violent colic and nausea, due to a partial strangulation of the inverted bladder protruding through the fistula, but was instantly relieved on its being returned.

May 15. The fistula was closed. Previously to doing this, the above-mentioned bands were freely divided by scissors, and the edge of the fistula dissected off from the inner face of the right ramus. The edges, thus freed from tension, were then brought together in a line running obliquely across the axis of the vagina, from the left ramus to the right of the cervix uteri.

When the edges had been secured by eleven sutures, a continuous line was presented of nearly three inches in length. The cervix uteri was drawn down to within an inch of the neck of the bladder; but, as the cul-de-sac was in its integrity, and rather deeper than usual, the vagina was still of good depth.

May 25. The sutures were all removed and the operation found successful. June 9. The case was discharged, cured.

CASE XXXIX. First pregnancy; in labor two hundred and twenty-four hours; delivered by forceps. Loss of the whole base of the bladder, the cervix uteri, and cul-de-sac, with the inverted bladder protruding through the fistula in the midst of cicatricial tissue. By four operations the opening was nearly closed; she was discharged to recruit. Readmitted, and cured by the fifth operation.

Mrs. C., aged 27, a native of Ireland, was admitted from Brooklyn, Oct. 17, 1864. She had been married two years, and had given birth to one child.

Labor commenced at full term, 3 A. M., Friday, May, 1863, by the sudden rupture of the membranes. For the following week she was in "hard labor," without any apparent progress. On Saturday, the eighth day, a physician was placed in charge, but the pains soon after entirely ceased. On Sunday the forceps were applied, and she was delivered of a very large child, in a putrid condition. The placenta was removed at the same time.

For ten days afterward there was a free bloody discharge from the vagina, which was very offensive. She was confined to her bed for three weeks, from an entire loss of

power in her right leg. The urine had frequently been passed without difficulty during the progress of labor. For a number of days after delivery she had no desire to micturate, and the bladder was not emptied, but, on attempting to stand, a very large quantity of urine, which had been accumulating during this time, suddenly gushed from her, and she had no control afterward. Up to the time of admission there had been no return of menstruation.

*Pathological Condition.*—Loss of the whole base, and destruction of the cul-de-sac, with complete inversion of the fundus of the bladder, protruding from the fistula through the labia. From the ramus on the right side, along the edge of the fistula, on the lateral wall, into the cul-de-sac, a thick and dense fold of cicatricial tissue extended, binding down the remains of the cervix uteri.

Oct. 25. This band was freely divided in several places, the cervix was freed from its adhesions, the cul-de-sac was opened up as far as possible, a glass plug was introduced, and secured by a T bandage.

Nov. 22. Attempted to close the fistula. The preparatory operation had only been partially successful, as the patient had persisted in loosening the bandage whenever she could do so. It was necessary to perform the operation entirely on the knees and elbows, as, when on the side, the vagina became filled with the protruding bladder. After succeeding in scarifying the edges of the fistula, the patient became so nervous and restless that I was forced to place her on the side and administer ether. It was with difficulty that she could be brought under its influence. Before she was sufficiently so, it became too dark to proceed with the operation, and the attempt was abandoned.

Jan. 13. After a daily drill on the knees and elbows by the house surgeon, it was thought that the operation

might be attempted. The patient, however, was as nervous as before, and, with much delay and difficulty, at the end of two hours and a half, the scarified edges were secured by the sutures. The tension exerted by the bands in the cul-de-sac had not been entirely relieved by the previous operation, and, from the character of the tissue forming a portion of the line, perfect union throughout was not to be anticipated.

Jan. 21. Eight sutures were removed; the other two had cut out. The parts had united well, except toward the left, at the extremity of the fistula, against the ramus; at this point the edges were thin, tense, and in the midst of cicatricial tissue.

Feb. 14. Second operation. The opening was again closed by ten sutures. The line of union was along the sulcus, at a right angle to the previous one, and parallel to the course of the bands, so that no direct tension could be exerted by them. A portion of the base was brought up in a fold against the lateral wall, forming a long pouch in the axis of the vagina, at the bottom of which the opening into the bladder was left. By this procedure the tension was lessened, as the lateral wall was more yielding at a distance from the sulcus, and healthier tissue was brought in apposition. At the same time, the scarified surfaces being at a greater distance from the bone, more room was gained to turn the needles while introducing them. The operation was a very tedious one, from the patient being almost ungovernable.

Feb. 23. The sutures were removed. Three were found loose in the vagina, with as many small openings.

April 12. Again operated. The execution was more difficult than before, as, by contraction of the cicatricial tissue, a fold had been formed along the axis of the vagina, just in front of the openings, so as to hide them from view. The previous operation was repeated, after cutting open

with scissors the partially closed line, and in such a manner as to unite these three openings into one. The scarified surface was extended beyond each extremity of the opening. Eleven sutures were used; they were removed April 20. The line had united at but a single point.

May 23. Fourth operation. The vaginal surface around the fistula was scarified, with a corresponding portion on the side of the fold nearest the opening. The fold was then doubled over the fistula and secured by ten sutures. The opening was so close to the muscle that several of the sutures must have included portions of its fibres, and with any movement of the leg on that side, the strain would have been so great that it was feared they would be torn out. As a precaution, the patient's legs were tied, and a support was put under her knees while flexed, so as to relax the muscles as much as possible.

June 2. The sutures were removed. The operation had proved a failure. June 6. The patient was discharged to recruit her health during the summer, and to return in the autumn.

She was readmitted, and operated on, Oct. 17, 1866. The opening had not enlarged, and her condition was favorable in every respect. The last operation was repeated, and eleven sutures were employed; they were removed, Oct. 31. The operation was entirely successful, and the patient was discharged, cured, Nov. 14.

CASE XL. First pregnancy; natural delivery, after a labor of twenty-four hours. Loss of nearly the whole base of the bladder, a portion of the neck of the uterus, and the cul-de-sac. The fistula crescentic in shape, and the vagina shortened, by contraction of cicatricial tissue, to an inch and a half in depth. After a preparatory operation, for enlarging the vagina and dividing the bands, the fistula was closed by two operations.

Mrs. L., very slight and under-sized, aged 20, a native of the United States, was admitted from Manchester, Va.,

Feb. 21, 1866. She was married at 17. In March, 1865, she gave birth to a still-born child, weighing fourteen pounds, after a labor of twenty-four hours. On the third day after delivery, the urine escaped by the vagina for the first time. It was not noticed that any slough was thrown off. In March, preceding her admission, she was operated on by a surgeon in Richmond, but without any benefit in controlling the free escape of urine.

*Pathological Condition.*—The loss of tissue extended from the neck of the bladder to within a quarter of an inch of the cervix, and from one ramus to the other. The cul-de-sac had been destroyed, and a band extended from each side of the cervix to the posterior lip, and to each angle of the fistula. The vagina was shortened, from contraction of these bands, to an inch and a half in depth. The opening was crescentic in shape, with the concavity toward the uterus, and although the edges of the fistula were but a few lines apart, they were almost immovable.

March 24. The bands in the cul-de-sac were freely divided wherever any degree of tension was felt by the index finger, introduced as a guide to put the parts on the stretch. The cicatricial surface was also divided on each side, just outside of the angles of the fistula, and prolonged somewhat anterior to each, in a line extending from the cervix uteri to the vaginal sulcus. The cervix uteri, in addition, was incised laterally to the vaginal junction. This preparatory operation was performed entirely with the scissors, and the bleeding, consequently, was slight. As the patient was very nervous, it became necessary to administer ether before the operation could be completed. With the cul-de-sac now freely opened to its natural depth, a glass plug three inches long was introduced and retained by a T bandage, for the purpose of keeping the canal on the stretch while the divided surfaces were healing.



April 18. Operation. The surfaces had now become well healed, and, through the modifying effect of pressure on the cicatricial tissue, the vaginal parietes were soft and yielding. The edges of the fistula were scarified and secured by sixteen interrupted sutures. The line was crescentic, conforming to the curve of the anterior lip of the uterus, but its arc became greater than before, in consequence of the tension being freed at the angles. Two sutures, just at the neck of the bladder, parted while twisting, from the bad quality of the wire used. They were left, however, *in situ*, but with almost a certainty that an opening would occur, in consequence, at this point.

April 28. The sutures were removed. A small opening existed at the above-mentioned point, while the union elsewhere was perfect throughout.

May 22. The patient was placed under ether, and the opening closed with eleven sutures, in a line somewhat oblique to the axis of the vagina, but nearly at a right angle to the previous line of union. It was found necessary to extend the scarified surface on the vaginal tissue at some distance beyond each angle of the opening. In consequence of the edges being thin, the vaginal tissue had to be brought together in two folds over it, and it was necessary to introduce a number of sutures beyond, until these folds at each extremity could be reduced to a level with the surrounding tissue.

May 30. The sutures were removed, the operation was found successful, and the patient returned home on the 15th of June.

Although the neck of the uterus was drawn down nearly to the neck of the bladder, yet, at the time of discharge, the vagina was almost four inches deep, from the bands in the cul-de-sac having been divided. I was apprehensive, however, that, gradually, sufficient contraction might occur

to reproduce the opening, but, six months after her discharge, the condition had remained unchanged.

CASE XLI. Tenth pregnancy; ninety-five hours in labor; delivered by hand. Loss of right half of the base of the bladder, with shortening of the vagina, and the fistula hidden by folds. Closed by one operation.

Mrs. L., aged 46, was admitted from Baltimore, Md., Oct. 10, 1864. She married at 21, and had given birth to ten children. Her labors were all tedious; eight were natural, and two were terminated by craniotomy.

Two weeks before her last labor, the size of the abdomen diminished so suddenly during the night, that she felt doubtful of the existence of pregnancy; as her bed was dry and there had been no rupture of the membranes, she was at a loss to account for her condition. For three days previous to the first pain, and until after the termination of labor, an exceedingly fetid discharge continued from the vagina.

This labor commenced during Thursday night, March 18, 1860, and, as it was supposed, some three weeks after the death of the child. During Friday and Saturday, the pains were almost incessant. On the Sunday following, she became alarmed at her condition, and employed a physician, who, within a few hours, bled her twice, until nausea and vomiting resulted, and ergot was afterward administered several times. On Monday she was very much exhausted, and, between 10 and 11 P. M., became insensible. She was then delivered, as she states, by hand, of a very large female child, in a putrid condition.

Until Friday, the bladder had been frequently emptied, but from that time until the following Tuesday after delivery, it became very much distended, without any inclination to empty the organ. She then made an effort to relieve herself, but only succeeded in passing a small quantity. Her physician made an examination, and, as he

withdrew his finger, a gush of urine followed, with no control afterward.

For several weeks after delivery, there was an offensive discharge from the vagina, and a number of small sloughs were passed from time to time. She was confined to her bedroom for four months, and, when able to sit up, was obliged to use crutches, in consequence of an almost complete paralysis of the left leg. She menstruated at the end of the first month, continued regular afterward, and, at the time of admission, was in a fair condition of health. Beyond the points stated, she was unable to give, in detail, a more accurate account of her case.

*Pathological Condition.*—About half of the base of the bladder, lying to the right of the median line, had been lost; but, by contraction, the fistulous opening had been so diminished as to admit only the index finger. Two deep folds of vaginal tissue, formed by the shortening of the canal, extended from each extremity of the fistula obliquely across the vagina, in front of the cervix, to the left side, and the fistula could only be brought fully in view by separating these folds.

By the 23d of November, the parts had been properly prepared for closing the fistula. Its edges were found cicatricial in character, thin and tense; while, from its position, it would have been exceedingly difficult, if not impossible, to have properly scarified a surface of sufficient breadth. The operation, however, was simplified by removing a broad strip of the mucous membrane from the vaginal surface, just within each fold, as the surfaces lay in contact. The denuded surfaces were made much wider at each extremity of the fold than in the centre; this was done with a view of lessening the size of the long pouch, which would otherwise have existed as a receptacle for stale urine, and at some future day may have furnished a bed for the formation of a calculus. When the folds were fully separated, the inner

edge of the scarified surface extended in a circle to within half an inch from the edge of the fistula, while its outer one formed an ellipse some three inches long, with the vaginal surface entirely removed between these two lines. Sixteen sutures were introduced, so as to bring into apposition every portion of the denuded surfaces; and, when they were twisted, the folds were so far obliterated that the line was nearly on the vaginal level.

Nov. 3. The sutures were removed, and the case was discharged, cured, Nov. 17.

CASE XLII. First pregnancy; in labor one hundred and five hours; delivered by forceps. Urine not voided during the time in labor. Loss of the left half of the base of the bladder. Closed by one operation.

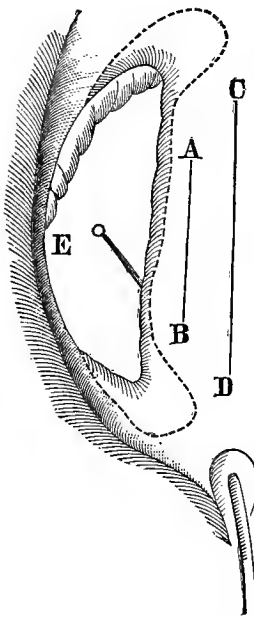
Mrs. K., aged 25, a native of Ireland, was admitted, Dec. 18, 1863, from Syracuse, N. Y.

She had been married about two years, when labor with her first child commenced at full term, on Thursday evening, July, 1863. The pains, from the beginning, were both frequent and severe, but no apparent progress was made in the labor. During Saturday night her physician ruptured the membranes, with the effect of stopping the pains almost entirely. On Sunday morning a consultation was called; she was placed under the influence of chloroform, the forceps were applied, and delivery was effected of a large child, still-born.

Four days afterward, the urine began to escape involuntarily, and a number of small sloughs were thrown off from the vagina for two weeks subsequently. The bladder had not been emptied during the one hundred and five hours that she was in labor, and she had no knowledge of the introduction of a catheter at the time of applying the forceps. For nine weeks after delivery, she was confined to her bed from paralysis of the lower limbs.

*Pathological Condition.*—A large fistula (Fig. 28) existed,

FIG. 28.



from the loss of little less than half the base of the bladder on the left side, as shown by the diagram. It was nearly semicircular in shape, about two inches long, and a little less than an inch wide.

January 4. Operation. Although at any given point the opposite sides could be brought together without tension, yet the chord could not have been approximated by sutures to the arc, without throwing the latter surface into a number of folds, from the difference in the length of the two edges.

As the point E, along the sulcus of the vagina on that side, was immovable, two incisions, A B and C D, were made in the vaginal tissue, parallel to the chord, the inner one being the shorter of the two. The edges of the fistula were then carefully denuded, and the scarification extended beyond each angle (as shown by the dotted line); this was done to obviate the formation of a fold at each of these points, with a consequent opening, if the sutures had been introduced merely to the actual length of the fistula. Ten interrupted sutures were passed, radiating, as it were, somewhat from a common centre, outside of the line C D, and, when they had been twisted, the two surfaces came together almost in perfect apposition.

The sutures were removed on the thirteenth day, and the case was discharged, cured, the last of January, 1864.

CASE XLIII. Second pregnancy; in labor ninety hours; delivery accomplished by the efforts of nature. The left half of the base was lost by sloughing, with the neck of the uterus and cul-de-sac. The vagina was shortened and narrowed, with occlusion of the uterine canal. By two operations the fistula was closed. A small opening subsequently formed, which closed by contraction.

Mrs. J., aged 31, a native of the United States, was ad-

mitted from Hannibal, N. Y., Oct. 14, 1864. She had been married nine years, and had given birth to two children, both still-born.

In March, 1861, the last labor commenced at full term on Wednesday, about midnight, by a sudden rupture of the membranes. During the night the pains were slight, but they gradually became so severe that a physician was placed in charge. Beyond administering ergot several times, nothing was done, and delivery took place by the efforts of nature on Sunday morning at eight o'clock. She was in labor ninety hours, and during this time the urine was neither passed nor drawn, but, as the child's head was born, it escaped from the vagina in immense quantities. During the last twenty-four hours of her confinement, she had suffered greatly from cramps in both legs; and the left leg was paralyzed for many weeks after delivery.

During the first week or ten days, several large sloughs were removed from the vagina, and, for a much longer time, a number of shreds escaped with the urine. She was confined to her bed for three months, and had not menstruated since her last pregnancy, nearly four years previous to admission.

*Pathological Condition.*—On examination, the vagina was found less than three inches in depth. The neck of the uterus had entirely sloughed away, the cul-de-sac destroyed, and was occupied by a mass of cicatricial tissue. The left half of the base of the bladder was gone, from the neck of the uterus to the inner face of the ramus; but, from the contraction of cicatricial bands, the edges of the fistula were drawn in contact, greatly narrowing, at the same time, the diameter of the vagina. The uterus was atrophied, with occlusion of its canal; the urethra was pervious.

Nov. 12. Operation. The edges of the fistula were scarified and brought together by nineteen interrupted su-

tures. In the posterior portion, the tissue was so dense and unyielding that four needles were broken in attempting to introduce them. Along the anterior portion, on the inner face of the ramus, so little tissue remained that several sutures tore out from tension while twisting others beyond. Their place had to be supplied with new ones, after a number had been already secured, and, with the utmost care, it was impossible to introduce them properly without endangering the integrity of the others. The operation was tedious and difficult, lasting an hour and three quarters, and, as no anæsthetic was given, the patient was very much exhausted at its completion.

Nov. 24. The patient had kept perfectly dry after the operation while the catheter had been in use, but on introducing the speculum, for the purpose of removing the sutures, an opening was discovered large enough to admit a No. 6 bougie, through which the urine then began to escape. Twelve sutures were removed at this time, but as the others could not readily be brought in view, it was not deemed advisable to put the parts more on the stretch for that purpose. Nov. 29. The remaining sutures were removed without difficulty, and it was found that the opening had not increased in size.

Dec. 14. This opening was closed by seven sutures. A broad oval scarification was made so as to include the edges and a portion of the vaginal surface, while the direction was not exactly over the previous line of union, but a little oblique to it. As the opening was closed to the ramus, and the vagina very much narrowed, it was found impossible to turn the needle, in carrying it through from one side to the other, without tearing it out from the tissues. To obviate this difficulty, a needle was introduced through each edge of the fistula, at opposite points, from within outward; into the loop of silk attached to one needle was passed that of the other, and on drawing one entirely

through, the other was thus made to include both edges of the fistula.

Dec. 17. The patient had a chill, followed by nausea, with great restlessness. A large dose of opium was given by enema. Dec. 18. She had passed a good night, and was more comfortable. Dec. 24. The sutures were removed, and the operation was found successful.

Jan. 8. A slight moisture was found in the vagina, and, after a careful examination, a small opening was discovered under a fold to the right of the uterus, through which scarcely a bristle could have been passed. As her health was very feeble, she was advised to return home, and at the end of two months, if the same condition existed, to be readmitted to the hospital for another operation. She never returned; from the fact of the opening being so small, and situated in the midst of cicatricial tissue, it doubtless closed by contraction, as we were satisfied would be the case when she was discharged.

CASE XLIV. Fourth pregnancy; seven hours in labor; natural delivery. Loss of the entire base of the bladder, with bands extending from each side of the cervix uteri to the pubes, which, by contraction, shortened the vagina and drew down the cervix uteri nearly to the neck of the bladder. The first and second operations were but partially successful; the third one entirely so.

Mrs. S., aged 35, a native of Ireland, was admitted from Shaholy, Pike Co., Pa., Oct. 7, 1863. She had married at 16, and had given birth to five children. The fistula was produced seven years before admission, as a result of the fourth confinement, and the fifth child was born by a natural and easy labor, two years after she received the injury.

On Thursday, Dec., 1856, about 10 A. M., the membranes were ruptured by the first pain. At noon the head was born, but the body was not delivered for five hours afterward, and the placenta until midnight, twelve hours



after the birth of the head. With the passage of the body, the urine began to escape by the vagina, and, three weeks after, several sloughs were separated.

*Pathological Condition.*—Loss of the entire base of the bladder by sloughing. Bands of cicatricial tissue extended from the cervix uteri on each side along the rami to the pubes; these, by contraction, had shortened the vagina so as to make the fistula transverse to the axis of the vagina, bringing the cervix uteri and the neck of the bladder almost in contact. From each angle, the edges receded, so that the actual opening into the bladder was not more than an inch in length.

Oct. 11. The edges of the fistula were closed *in situ* by seven sutures, without dividing the bands, as the cul-de-sac was uninjured and the vagina remained of good depth. On removing the sutures the edges separated, leaving a small opening at the extreme angle, behind the right ramus.

Nov. 9. This opening, which had contracted so as only to admit a small probe, was closed by seven sutures. The operation was extremely difficult of execution, as, from its locality, the opening could not be brought perfectly into view. The line of union was made at an oblique angle to the previous one, by bringing the vaginal tissue up in a fold against the tissue covering the ramus, after making a parallel incision outside, along the base of the bladder. On removing the sutures, it was found that several sutures had cut out from too great tension, and the opening remained unchanged in size.

Dec. 18. Again closed the fistula in the same line, using eight sutures. Before introducing the sutures, however, the tissue in the midst of which the fistula was situated was dissected off by scissors (see Fig. 30, Case LV), in a free flap, for an inch and a quarter in length, from the face of the ramus, so that the freed portion could be drawn more than half an inch away from the bone. The parts were thus

brought fully into view and the tension relieved, while, at the same time, sufficient room was gained to introduce the needles properly, which could not be done in the previous operation. The sutures were removed, Dec. 25, and the case discharged, cured, Jan. 18, 1864.

The chief point of interest in this case is the short duration of labor. The head was born two hours after the first pain; the pains then ceased, and on their return the body was delivered in a few moments, the whole labor being completed in seven hours from the beginning. The recorded history of the case does not give either the size of the child, the difficulties of the case, or whether there was proper medical care; but the labor could have doubtless been terminated sooner, and it is fair to assume that the child was not of unnatural size, as it was born unaided and rapidly, as soon as the pains returned.

CASE XLV. First pregnancy; eleven hours in labor; delivered by forceps. Nearly the whole base was lost and the uterus left immovable. The fistula was closed by splitting its posterior edge and drawing forward the bladder or under portion, which was united to the anterior edge of the opening.

Mrs. S., aged 28, a native of the United States, was admitted from Hampton, N. Y., Dec. 11, 1858. She married at 25, and had been always in excellent health.

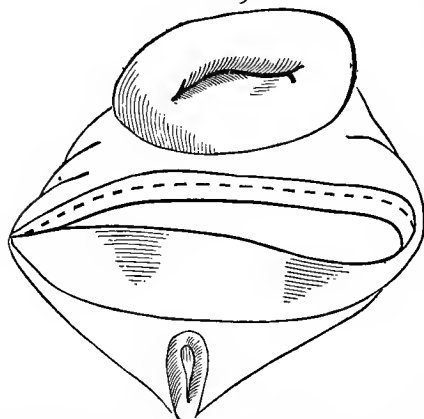
Labor pains with her first child commenced at full term at 10 A. M., June 19, 1858, after the liq. amnii had been escaping in small quantities since the midnight previous. At 11 A. M., a physician took charge of the case, and pronounced the position a natural one, but the mother "too small" for an easy delivery. The pains continued normal until late in the afternoon, when they wholly ceased. A consultation was called, but nothing was done until 9 P. M., when the forceps were applied, and delivery of a large male, still-born, was accomplished.

The bladder had been frequently emptied until a short

time before delivery; the patient became much swollen afterward; retention took place for twenty-four hours, when the urine began to dribble away. A single slough, as long and wide as four fingers, according to her statement, was separated five weeks after delivery. The urine could only be retained a short time, when lying on the back, or the right side.

*Pathological Condition.*—The entire base of the bladder

FIG. 29.



was lost (Fig. 29), from a short distance in front of the cervix uteri to the neck of the bladder, but, by cicatricial contraction, the edges of the fistula were drawn together within three-fourths of an inch, so as to present in shape a transverse opening. From the angle of the fistula, on the left

side, a dense band extended around, under the arch of the pubes.

Dec. 12. Closed the fistula. Although the vagina was so much shortened, it was impossible to bring the two edges of the fistula together without exerting a degree of traction too great for the suture to withstand. This was due to the uterus being immovable and fixing the posterior edge, while the band under the arch of the pubes rendered the anterior one unyielding at every point, except just at the neck of the bladder. The posterior lip of the fistula (as shown by Fig. 29) was split along the dotted line, through the cicatricial edge, backward toward the uterus, with the view of freeing the lower portion in connection with the bladder, from the immovable vaginal surface above.

The vesico-vaginal septum or base of the bladder, as

already referred to, consists to a great extent of two surfaces connected together by loose cellular tissue, so that one surface is movable in part, independent of the other, and, at the point in question, more movable than in any other portion. When the posterior lip had been sufficiently divided, the lower flap, thus freed from tension above, could be drawn forward in advance of the vaginal surface, to the anterior edge of the fistula.

The edge of the lower flap was denuded continuously with the line of scarification around the angles, at each end of the fistula, and along the extent of the anterior lip to the starting point, preserving a relative width throughout. After the cicatricial band under the arch of the pubes had been divided at several points, the two edges of the fistula thus freed, lay in contact. Eleven sutures were introduced; they were removed on the twelfth day, and the patient was discharged, cured, Dec. 28.

CASE XLVI. In labor eighty-one hours; first pregnancy; natural delivery. Two fistulæ, one near the neck of the bladder, to the right, and the other near the cervix, on the same side. Vagina shortened by a cicatricial band extending from the lower fistula across the vagina to the left, around in the cul-de-sac, to the upper opening. Each closed by a single operation.

Mrs. H., aged 19, a native of Ireland, was admitted from Hart's Corners, N. Y., Dec. 2, 1864. She married at 18, and became pregnant shortly afterward.

Labor commenced at full term about 4 A. M., Tuesday, August 15, 1858. Her physician stated, after an examination, that the pains were false, and that labor would not come on for two weeks. An anodyne was administered, but the pains continued, although weak and infrequent, until 3 P. M., Thursday. The physician remained all night, with the expectation of a delivery within a few hours. At seven the next morning, ergot was administered every ten minutes until nine doses had been taken. The pains soon

became violent, and at 1 P. M. delivery was accomplished of a very large still-born male, after a labor of eighty-one hours.

The bladder was not emptied from bed-time, Monday night, until after the labor had terminated. Soon after delivery, the urine began to escape, but at first in very small quantities; the loss, however, daily increased until, at the end of two months, all retentive power was lost. No single slough was thrown off at any time, but the vaginal discharge long continued exceedingly offensive. Up to the time of admission, menstruation had not returned since her pregnancy.

*Pathological Condition.*—With a vagina much shortened and contracted, a broad band of cicatricial tissue extended from behind the right ramus obliquely across the vagina to the left side, behind and around the cervix uteri, until lost in the sulcus on the right side, a little in advance of the neck. In the midst of this band, just above the neck of the bladder and a little to the right of the median line, a fistula existed, into which the first joint of the index finger could be introduced. Its edges were tense, and could not be approximated in any direction.

Shortly after admission, the band was freely divided across at several points, in front of and behind the uterus, for the purpose of freeing the edges of the fistula, and at the same time increasing the depth of the vagina. A plug was then introduced, long enough to put the canal well on the stretch, and was worn until the parts had perfectly healed.

Feb. 20, 1859. Closed the fistula. The upper edge being thinner than the lower one, it was split through its length by increasing its width to correspond with that of the opposite edge. Eight sutures were used. They were removed on the thirteenth day. Although the edges had united perfectly, it was yet feared, from the character of the

tissue, that some separation might occur. Shortly after discontinuing the use of the catheter, the urine began to escape in small quantities.

March 23. Preparations were made for closing the opening which was supposed to have occurred after the operation; but, as it was found perfectly closed, the escape of urine was at first attributed to a patulous condition of the urethra, arising from a certain amount of tension exerted by the band running across the vagina. On making a careful examination, however, an opening, which had been overlooked, was discovered on the right side, near the cervix, a little in front and at the bottom of a deep sulcus composed of cicatricial tissue. With great difficulty, the scari-fication of its edges and a portion of the vaginal surface was accomplished, in the form of a funnel-shaped oval. As the tissue around this opening possessed but little vitality, in order to relieve its edges from tension, it was necessary to make quite a deep incision, outside of the opening and parallel to the sulcus on that side, and to divide, antero-posteriorly, the cervix to the vaginal junction on the other. The surfaces were then brought together, somewhat oblique to the axis of the vagina, free from tension, and secured by five sutures. April 2. The sutures were removed. The union was perfect, and the patient was discharged, April 29, 1865.

*Remarks.*—The two openings were supposed to have resulted from a lateral laceration of the cervix on the right side, which extended along the base, without dipping entirely through into the bladder. Afterward, sloughing occurred, forming a single fistula, which gradually united in the centre to some extent, when there was but little traction or cicatricial tissue, but leaving an opening at each end. During the two months before all retentive power was lost, the band was gradually contracting, and enlarging the lower opening, until it reached the size presented. But as the

cicatricial surface extended around and in front of the upper opening, its edges were kept in contact by the tension exerted, yet could not close entirely, from the character of the tissue. When this band had been divided, and the bladder began to expand after the use of the catheter was discontinued, the edges were separated, and the urine then began to escape at this point, which it could not have done so long as the band remained intact.

## CHAPTER IX.

### FISTULÆ, WITH OCCLUSION OF THE VAGINA, PARTIAL OR COMPLETE, POSTERIOR TO THE OPENING INTO THE BLADDER.

CASE XLVII. First pregnancy; in labor one hundred and two hours; delivered with forceps. A transverse fistula extended across the vagina, about two inches from the mouth of the urethra, and, from its posterior lip, the vagina was entirely occluded beyond. The uterus could be felt from the rectum, embedded in a mass of tissue resulting from pelvic cellulitis. The fistula was closed by uniting its anterior lip to the posterior wall of the vagina.

Mrs. H., aged 21, a native of Ireland, was admitted from the city, March 1, 1862.

In March, 1860, labor with the first child commenced on Friday, between 4 and 5 A. M. The pains did not become severe enough to confine her to her bed until the following Sunday evening, when a physician was sent for, and took charge of her case. From this time, the pains continued frequent and violent until between 11 and 12 P. M., Tuesday, when the forceps were applied, and delivery was effected of a very large female child, still-born. Chloroform was frequently administered during Monday and Tuesday.

Until Monday, during the day, the bladder had been repeatedly emptied without difficulty; but, as she was in almost an unconscious condition from that time until several hours after delivery, when she found the urine escaping, she could give no account of her condition.

She was confined to her bed for a month after delivery. Her general health was good, although she had not menstruated since her pregnancy. She, however, had the pre-



monitory symptoms for a year or more afterward, but without a recurrence for a long time previous to admission.

*Pathological Condition.*—About two inches from the mouth of the urethra, a transverse fistula extended almost entirely across the vagina; beyond its posterior edge, the vagina was completely occluded. Nothing definite was gained by a rectal examination, beyond the fact that the uterus was so blended with a mass of cicatricial tissue that its position could not be ascertained, and that a previous pelvic cellulitis had existed, which had still more obscured the actual condition.

With my present experience, I should not hesitate now, in such a case, freely to open up the parts, by means of scissors, until the uterus was reached, or, at least, a vagina gained of a natural depth. But previous experience had fully demonstrated that no permanent benefit would result from the use of the knife, in opening up a false passage through a dense mass of cicatricial tissue several inches in depth, and that, by subsequent contraction, every trace of the operation would disappear as soon as the parts had healed. Now, we know that when incised with the scissors, or the tissue lacerated, a better result can be anticipated, as will be shown in the history of the following case.

It was scarcely to be expected but that the entire cervix had been lost, and the uterine canal, as well as the body, had undergone a serious change, as the result of inflammatory action. In such cases it is not unusual, even when the amount of injury received had been less, that the menstrual function is ever afterward restored. The age of the patient seems to exercise no effect on the result, and the "change of life" is as complete, under these circumstances, as when occurring in the usual course of nature. As there had been no menstrual nusus for over two years, and she continued in good health, it was deemed best simply to close the vagina in front of the fistula.

This was done, March 29, by scarifying the anterior edge of the fistula, and extending the line in healthy tissue around one angle, across the posterior wall of the vagina, to the opposite one of the opening. The denuded surfaces were then drawn together by a continuous suture, or whip-stitch, extending entirely across the vagina. The canal thus became a cul-de-sac some two inches deep, shutting up the fistula in a small pouch, immediately behind the line of union.

April 6. The suture was removed in sections, by clipping each turn of the wire presenting. The union was perfect, but the patient was kept under observation until May 6, when she was discharged, with perfect retentive power, all having been accomplished that had been undertaken.

CASE XLVIII. First labor, lasting five days; delivery with forceps. A transverse fistula at the neck of the bladder, with occlusion of the vagina beyond. The fistula closed by one operation. The vagina was opened five times by the knife, each operation unsuccessful, with subsequent retention of the menstrual flow. Finally a satisfactory result was obtained by laceration.

Mrs. B.,\* of Newark, N. J., was admitted to the Woman's Hospital, April 27th, 1863, with a vesico-vaginal fistula following her first labor of five days duration, and delivery by forceps.

Although three years had elapsed since her confinement, there had been no return of menstruation, and, with extreme

---

\* The report of the above case is taken at length from a late paper by the author—“Accidental and Congenital Atresia of the Vagina, with a mode of Operating for Successfully Establishing the Canal”—read before the New York Obstetrical Society, June 19, 1866, and reprinted from the “Richmond (Va.) Medical Journal,” August, 1866.

It is deemed advisable, not only to cite the history of the case as bearing directly on the subject under consideration, but also from its connection with atresia of the vagina, which existed, together with the principles set forth in relation to the mode of operating. This will be appreciated, in connection with the treatment of subsequent cases given, where the complication of atresia also existed, and had to be overcome before the fistula could be closed.

prostration of the nervous system, her general health had become much impaired.

On introducing the finger between the labia, at the depth of less than an inch, it passed directly into the bladder, through a transverse fissure situated at its neck, about two inches in length. From the posterior margin of the fistula, the vagina was entirely occluded. Nothing definite was gained by a rectal examination, beyond the fact that pelvic cellulitis had previously existed, and the position of the uterus could not be detected.

May 10. With the patient etherized and lying on the back, two deep incisions outward and downward were made on each side of the fourchette, through a dense cicatricial band, involving this portion of the vaginal outlet. An assistant seized the posterior edge of the fistula by means of a tenaculum, and it was drawn upwards in the direction of the pubes, and put on the stretch. The vaginal tissue was then carefully divided laterally with a scalpel, in the supposed direction of the uterus. As the canal was opened up, the thumb of the left hand of the operator was advanced to put the posterior wall of the vagina on the stretch by pressure backward, and with two fingers of the same hand in the rectum as a guide, the relative thickness of the rectal septum was preserved. A depth of nearly five inches was gained, when the hemorrhage became so excessive that a farther attempt to reach the uterus was abandoned. A hollow glass plug, five inches in length by two in diameter, was introduced, and retained *in situ* by a perineal bandage.

The patient was placed in bed, and opium administered, after the effects of the ether had passed off. For several days she suffered much from constitutional disturbance, irritability of the bladder, and a feeling of soreness over the lower portion of the abdomen. Retention of urine resulted, in consequence of the pressure exerted, but, without

removing the plug, the bladder was emptied by means of a gum-elastic catheter. As the plug had controlled the hemorrhage, it was not taken out for several days, until loosened by suppuration, and afterwards large vaginal injections of tepid water were used daily until her discharge.

At the end of ten days, it was found that absorption of the tissue had gradually taken place, by pressure of the vaginal plug, until the cervix could be felt through a thin septum, a little to the left of, and about four inches from, the mouth of the vagina.

June 3. The septum was caught up on a tenaculum, and divided by scissors; the vagina, which had been closed throughout by adhesions, was thus opened, with the exception of a small cavity immediately around the cervix uteri, into which the latter protruded, uninjured.

June 26. The artificial vagina being now properly healed, the edges of the fistula were pared by scissors, and approximated with eight interrupted silver sutures. The edges of the fistula were sloping, as is usually the case when situated at this point, and, although two inches long on the vaginal surface, receded until the actual length of the opening was not more than half so much at the entrance to the bladder. On the ninth day the sutures were removed, and, with the union perfect, she was discharged, cured, July 15.

Oct. 8. She was readmitted to the hospital, in consequence of a gradual closure of the vagina. It was found the original condition of atresia existed up to the posterior edge of the closed fistula, which, however, had remained intact, with perfect control of the urine.

On the next day, the previous operation was repeated, until the os was again reached, and a glass plug of the same size introduced. During the night, she had a violent chill, followed by an attack of pelvic cellulitis. The plug was

removed, and at the end of two weeks she recovered, with closure again of the vagina nearly to the original condition.

Nov. 8. She was examined, and it was found that about an inch had been gained. At the bottom of this canal, nearer to the base of the bladder, a small opening was detected, only large enough to admit an ordinary probe. After passing some two inches, its point could be felt, from the rectum, in the neighborhood of the cervix uteri. A straight, blunt-pointed bistoury was passed along the probe as a guide, and on withdrawing it, an incision was made in the median line, to the depth of half an inch, directly through the septum, on the support given by the index finger in the rectum. A similar incision was made laterally to the right and left, thus again opening the canal to the cervix uteri, so as to admit a plug nearly two inches in diameter.

The hemorrhage was so great, that it became necessary to remove the plug and introduce a larger one into the rectum; this kept the cut surfaces in contact, and controlled the hemorrhage. The opening, however, gradually contracted, although vaginal plugs were used afterward as soon as it was safe to introduce them.

Dec. 5. The small sinus which still existed was dilated by a sponge tent, so as to admit the index finger, and free incisions were again made through the septum, for three inches in length.

Jan. 9, 1864. She returned home to recover her health, having just menstruated for the first time since her pregnancy, after an interval of nearly four years. The vaginal surface had become well healed, over the plug which had been in use since the operation, and which was only removed at the time of receiving the daily injections of tepid water.

May 25. She was again admitted, suffering from constant pain and a feeling of fulness in the pelvis. There had been no menstrual flow since leaving the hospital, although the nismus had been regular. The use of the plug

had been continued, until gradually it became impossible to introduce it without great pain. The canal was again closed; through the rectum a mass, slightly fluctuating, was detected, filling up the pelvis; and with the other hand over the abdomen, the uterus was felt enlarged nearly to the umbilicus. As it was near the regular time for menstruating, she was kept in bed, and under the influence of opium.

June 6. In the presence of some of the members of the American Medical Association, a trochar was passed from the vagina through the septum, now only an inch in thickness, in consequence of the accumulation behind. More than a quart of retained menstrual fluid was evacuated with great relief, the opening was enlarged, and the cavity of the dilated uterus washed out freely by injections of tepid water. After ten days the discharge all ceased. With the septum so thin, and having been freely divided, every hope of success was anticipated in being able to keep it open permanently. In July she was discharged, after menstruating freely, and with her general condition much improved.

She returned to the hospital, December 2, after menstruating each month with increasing pain and difficulty. Through the septum, a little over an inch thick, a small sinus still remained, but only large enough to admit a very small probe. Its tract was somewhat enlarged by a bistoury, and four ounces of retained fluid evacuated. She was placed under ether, and after introducing two fingers of the left hand into the rectum, well behind the mass as a fixed point, the index finger of the other hand was forced with much difficulty through the small opening. The canal was opened by laceration, with the addition of one finger after another, until almost as much was thus gained as had been previously done by means of the knife. The hemorrhage was slight; she was kept in bed for a week, partially under the influence of opium, without any bad

symptoms following the operation. Early in January, 1865, she was discharged.

Feb. 23. She reported herself for examination, after menstruating twice without pain. The vagina was now four and a half inches deep, the surface well healed, and with but little discharge. She was directed to continue the use of the glass plug for some time.

I lost sight of the case until May 23, 1866, when she visited the hospital. She was in perfect health, regular, and living with her husband happily. On examination, the vagina was found well opened, its parietes soft and perfectly healed, although of a much deeper color than natural. The plug had not been worn for several months, and was only passed occasionally as a precaution.

This case is one of great interest. Between May 10, 1863, and December 2, 1864, she had been operated on by means of the knife five times, yet, with the greatest care, occlusion gradually occurring by contraction after each operation. From December 2, 1864, when the canal was opened by laceration, to the present time\* (nineteen months), there has been no perceptible change in the size of the vagina.

It can scarcely be supposed that the canal would have remained as open had she entirely discontinued the use of the plug, or were she not married; but the point not to be lost sight of is, that under the same circumstances, after each of the previous operations with the knife, the atresia became perfect in a few weeks.

As a result of a large experience in operating for vesico- and recto-vaginal fistulæ, I have become fully satisfied that in the preparatory operations, when it is necessary to divide extensive bands of adhesions before the edges

---

\* To August 1st, 1867, I had seen the case several times since her discharge, and although a vaginal examination was not made, I know that she is still living with her husband, and would have reported herself at once, if any change had taken place in her condition.

can be approximated, inflammation rarely follows a division by scissors, or laceration by means of the fingers. In addition, it was observed, that with less hemorrhage, the vaginal tissue, when divided by scissors or lacerated, had not the same tendency to contract during the process of healing as when separated by means of a clean cut.

I became so fully impressed with these facts, that I have for several years entirely discarded the use of the knife in all operations about the female pelvis, wherever it is possible to do so. I am aware that the impression generally received is, in opposition to this experience, that the risk of inflammation, and I may add of pyæmiá, is lessened by the laceration of tissues, but a large number of the profession have witnessed the practical results in the hospital, and its records will bear me out in the assertion.

It is not claimed, if a mass of cicatricial tissue be divided either by scissors or by simple laceration, the character of the tissue can thus be so altered by the mode of division, that there will be no tendency to contraction if the parts be left to themselves; the action is only not so rapid or complete. It is believed that the constant pressure of the glass plug gradually changes the character of the structure, through the agency of absorption, or by a metamorphosis of tissue.

When incised by the knife, the surface granulates so rapidly that it is impossible to prevent adhesion, while, on the contrary, when divided by scissors or lacerated, this action is not so rapid, and we thus gain the time necessary to bring about this modification by pressure.

Why the tissue divided by a clear cut should granulate so rapidly and become as dense as before, while by the scissors the process is slower, and a return to the original condition is not the rule, we can only explain by speculation, but the fact, I think, we must accept, as taught by experience.



Formerly, when these bands were divided by the knife, before the edges of a vesico-vaginal fistula could be brought together, for instance, the preparatory operations were often a question of many months. They frequently failed, from excessive hemorrhage at the time, or a negative result by contraction, and many cases were then regarded, in consequence, as incurable. Now, these bands are divided by scissors, as a rule, at the time of closing the fistula, generally with but little hemorrhage; and the edges, if properly scarified, are firmly united before the surface so divided is healed, and without the same tension afterward.

In conclusion, I will state, therefore, that in proportion as the knife has been abandoned in the different operations about the female pelvis, and the use of the scissors, laceration, and the *écraseur* substituted, the field of surgery has been extended by results not hitherto obtained.

CASE XLIX. First pregnancy; no labor pains; delivery by forceps, six days after rupture of the membranes. The vagina was narrowed at the depth of an inch and a half, a transverse fistula beyond, with perfect occlusion of the canal from the posterior edge of the opening. The vagina was opened to over three inches in depth, without detecting the position of the uterus. The fistula into the bladder was closed after two operations, by bringing together the tissue along the axis of the vagina in two folds, and shutting up the fistula at the bottom of a pouch.

Mrs. R., aged 34, was admitted to the hospital, April 5, 1867, from Bridge Hampton, L. I. She had been married eighteen months.

Labor with her first child, at full term, commenced by rupture of the membranes, about noon, on Saturday, Oct. 28, 1866. But no pains came on and she did not remain in bed, until her physician was called in, the following Wednesday, who stated that she was in labor.

On Friday, Nov. 2, the forceps were applied, and she was delivered of a still-born child, *without having experienced a single labor pain at any time during its progress*, as she positively affirmed to have been the case. Before using the

forceps an effort was made, but without success, to empty, by a catheter, the distended bladder.

Immediately after delivery, she noticed, for the first time, the escape of urine by the vagina. After the first week, a number of sloughs were passed with the lochia, and the last, a very large one, came away at the end of the fourth week. During four months she was confined to her bed.

*Pathological Condition.*—The vagina was found contracted so as to barely admit the index finger to the depth of an inch and a half. After introducing a portion of the speculum, the anterior border of an opening into the bladder was seen, just in front of a fold formed by the posterior wall of the vagina, but, beyond this, nothing definite could be ascertained of the extent of the fistula. But as the sound could not be passed beyond the fold in any direction, except directly into the bladder, it was evident that occlusion of the cul-de-sac, if not obliteration of all the upper portion of the vagina, existed. By the rectum a firm mass of tissue was felt extending across the pelvis along the course of the broad ligaments, and a sound passed into the bladder could be felt by the finger high up in the rectum, at the point which should have been occupied by the fundus if the uterus had been in position. The vaginal surface and outlet were much excoriated from irritation of the urine, and covered by the sabulous deposit.

Until May 10, after the use of vaginal injections of warm water several times a day, she was not in a proper condition for a satisfactory examination. Ether was then administered, and a most thorough examination made, but without being able to detect the position of the uterus.

With the patient on the back, a Sims' speculum was introduced under the arch of the pubes, and, by depressing the perineum with a finger of the left hand, a fold of the posterior wall, extending across the fistula, was seized with

a tenaculum and held on the stretch by an assistant. The angles of the fold on each side, where the two walls of the vagina became blended, were then carefully snipped with scissors, until the outline of the fistula was brought into view. It was oval in shape, transverse to the axis of the vagina, with firm cicatricial edges, and scarcely large enough to admit the first joint of two fingers.

This fold was formed by the posterior wall of the vagina becoming doubled on itself, from contraction of cicatricial tissue, and extended around the vagina to each extremity of the fistula. It was freely divided by scissors, and lacerated, until almost the natural diameter of the canal had been gained to the border of opening into the bladder. The vagina, however, terminated along the posterior edge of the fistula.

One index finger was passed through the fistula into the bladder, and the other into the rectum, with the view of discovering the position of the uterus, but without gaining any evidence of its location. It was, however, determined to increase the depth of the canal, with the hope that the remains of the cervix uteri might be exposed.

The posterior edge of the fistula was held on the stretch by a tenaculum in the hands of an assistant, and, as the posterior wall of the vagina was depressed by two fingers of the left hand, the tissues were divided by scissors in a line across the vagina, along the posterior edge of the fistula. This line was extended upward and backward, so as to preserve a relative thickness of the flap, as indicated by the introduction of the finger from time to time through the fistula into the bladder. After an advance had been made to the depth of an inch, it became evident that the cervix had been passed, and that it could not be extended farther without entering the rectum.

A glass plug, about three inches and a half in length, was then introduced, and after it had been secured by a

bandage, the bleeding, which had been quite profuse, became arrested by its pressure.

June 15. The divided surfaces had healed, and the cicatricial tissue had become much softened, while the vagina remained two inches and a half deep from the mouth of the urethra, without putting the canal on the stretch. As the uterus could not be found, it was decided that the plug should be continued in use, with the hope that much might yet be accomplished by absorption of the tissues from pressure.

It was evident that the organ was not in position, and that after sloughing of the cervix had taken place, the uterus, from pelvic cellulitis, became bound down by adhesions to one side or the other.

July 2. She returned home to await the result, with the hope that if menstruation became established, it might force an outlet, or, at least, should any accumulation take place, a solution of the difficulty would be rendered easy.

Oct. 20, 1867. She was readmitted to the hospital, in excellent condition, but, although a year had already elapsed since her confinement, there had been no effort at a return of the catamenia.

Nov. 27. Ether was administered for the purpose of closing the fistula. Before the vaginal canal had been opened by dividing the fold, the fistula had been a transverse one, but, by the long-continued use of the plug, which had kept the canal well on the stretch, and had greatly modified the cicatricial tissue by its pressure, the long diameter of the opening now extended in the long axis of the vagina. The edges of the fistula, however, still remained unchanged in character, and could not be brought together without much tension.

Under the circumstances, a denuded surface was removed around the opening, at some distance outside, over tissue in a comparatively healthy condition, and in the form of a

long oval, which extended from the neck of the bladder to an inch or more beyond the fistula. The surface, between the boundary of the scarification at each extremity, was entirely denuded, and more widely at these points than along the sides, yet it was removed all around the fistula, as near to its edge as any union could be expected, with the view of lessening, as far as possible, the size of the pouch, which could not be obliterated.

Thirteen sutures were introduced entirely across, beneath the denuded surface, and, as they were secured, the two sides became folded up together in the long axis of the vagina. Although the tension by this method was great, and the tissues cicatricial to a great extent, yet, as so broad a surface had been denuded, with the introduction of an extra number of sutures, it was hoped that union would be obtained throughout the line.

On the second day, the urine became discolored, and as she suffered from more pain in the back than usual, it was suspected that menstruation had come on through some outlet into the bladder. But as the urine began to escape by the vagina shortly afterward, it was thought that the presence of blood in the urine was due to the cutting out of one of the sutures. The show, however, continued for some four days, and gradually ceased, as at the menstrual period.

Dec. 4. The sutures were removed, and it was found that nearly an inch had separated at the distal extremity of the line. Dec. 12. She sat up, and at the end of the month again had a show, which lasted for several days, but the point of escape was evidently somewhere in the bladder, and could not be detected.

Jan. 7, 1868. The opening was closed by nine sutures, without administering an anæsthetic. The line was extended farther back toward the termination of the vagina, as in the previous operation it had terminated too abruptly,

without reducing the folds to a level with the vaginal surface. Jan. 14. The sutures were removed, the operation proved successful, and she returned home shortly afterward, with perfect retentive power.

A few years ago, when the knife would have been the only means resorted to (from fear of hemorrhage, pelvic cellulitis, and the almost certainty of a negative result from contraction afterward), occlusion of the vagina would have been the only operation attempted for her relief. The crest of the fold would have been denuded, and the surface extended around the vagina in front of the fistula, so as to unite the two walls together at this point, thus shutting up the canal at the depth of not more than an inch. By opening the vagina to the extent gained, and closing the fistula in the axis of the canal, now more than three inches deep, she is still enabled to remain a wife; to become of mother is, of course, impossible, even were it desirable under the circumstances, when the destruction of the soft parts had been so great.

With the recurrence of the second show, I was doubtful as to the proper course to pursue. But, after full reflection, and with the sanction of the patient, I determined that it was best to perform the second operation, and await the result; for, under any circumstances which might occur, it would be easy to reproduce the original condition at any time, should the result of the operation prove a complication in the case.

## CHAPTER X.

### FISTULÆ, WITH PARTIAL OCCLUSION OF THE VAGINA ANTERIOR TO THE OPENING INTO THE BLADDER.

CASE L. First pregnancy; in labor forty-eight hours, and delivery by forceps. Entrance to the vagina nearly closed, from contraction of a circular slough. Outlet opened, the whole base of the bladder was found to have been lost, with the cul-de-sac destroyed, and the vagina shortened to an inch and a half in depth. The vaginal canal was opened to the depth of three inches, and the fistula closed. Shortly after the sutures had been removed, the angle behind the right ramus separated; this was closed by a subsequent operation.

Mrs. M., aged 36, of Jordan, N. Y., was admitted, Jan. 19, 1867. She married at 19, and, two years afterward, was delivered by forceps of a still-born female child, after a labor of forty-eight hours. About the end of the first week, a large quantity of urine suddenly gushed from her, with no control subsequent. After a lapse of fifteen years, she was unable to give a more detailed history of her case.

*Pathological Condition.*—The vaginal outlet was found so much contracted by a slough behind the perineum, that the index finger could not be introduced; but just within the passage, was seen a portion of the bladder wall, prolapsed.

Jan. 22. The index finger of the left hand was introduced into the rectum, and, as the band was pressed up to the vaginal outlet, it was freely snipped at several points by scissors. As an advance was gained, it was found that the cicatricial surface encircled the greater part of the canal, and, extending along the lateral walls, invaded the cul-de-

sac. The whole base of the bladder had been lost, and, by contraction, the vagina was shortened to an inch and a half, drawing down the uterus to the neck of the bladder. A transverse vesico-vaginal fistula extended from one ramus to the other, the anterior lip of the cervix forming, to a great extent, the posterior boundary of the opening. The cicatricial surface was freely divided by scissors at various points, and the cul-de-sac was opened up, so that a glass plug of over three inches was readily introduced.

Feb. 19. It was found that, by the continued use of the plug, the vaginal walls had become much softer, and in a more healthy condition.

Feb. 22. Closed the fistula with fifteen sutures. It was with much difficulty that the angles, which extended somewhat upon the lateral walls and almost out of sight behind the ramus, could be properly scarified, or the sutures introduced. The edges of the fistula lay nearly in contact, and the line of scarification on its posterior edge was extended entirely across the anterior lip of the cervix, just in front of the os uteri. From the fact that so large a portion of the neck of the bladder had been lost, as much as possible of the cervix was intentionally turned into the bladder, against the mouth of the urethra, to aid mechanically in the retentive power; for with any accumulation of urine in the bladder, causing it to rise with the uterus in the pelvis, the urethra would necessarily be pressed up against the arch of the pubes.

March 5. The sutures were removed, and the line of union was found perfect. March 15. The urine began to escape in small quantities, due, it was feared, to the tension of the bands drawing the urethral outlet downward and backward, so that, by straightening the canal, the retentive power became to some extent impaired. On examination, however, this was found not to be the case. The escape was due to the separation, for a short distance, of the edges



forming the angle behind the right ramus, where the bone was sparingly covered with cellular tissue.

April 9. This opening was closed in the long axis of the vagina, after freely dissecting off the angle of the fistula from the face of the bone, and, by the same means, bringing the parts fully into view. Five sutures were used.

April 20. The operation was found successful, but the patient was retained, for fear that some portion of the line might again separate. She returned home, cured, the last of May.\*

CASE LI. First pregnancy; five days in labor; artificial delivery. The vagina was nearly closed at the depth of an inch. After this contraction had been divided, it was found that nearly the whole base of the bladder had been lost beyond, together with the cul-de-sac, and the os uteri occluded and the vagina shortened, with evidence of previous pelvic cellulitis. Several operations were performed for opening the vagina, and the last was followed by an attack of pelvic cellulitis. The fistula was closed, but the sutures were removed soon afterward, in consequence of hemorrhage. A second operation was abandoned from excessive hemorrhage, but a third one was successful.

Subsequent pregnancy; admitted to Bellevue Hospital; vagina found partially closed, pelvis contracted, and in labor with twins. Recurrence of the fistula in the old line, and subsequent contraction of the vagina. The fistula again closed, and the vagina allowed to contract after the operation, to guard against the recurrence of pregnancy.

Mrs. C., aged 30, a native of England, was admitted from the city, Feb. 1, 1861. She married at 18. Labor

---

\* Mrs. M. was again admitted to the hospital, March, 1868. Within a few weeks she had noticed a moisture, the quantity of urine escaping increasing until, at the time of admission, the escape of urine was quite marked. No opening was at first found, and the escape of urine was attributed to the short urethra. After several examinations, a small one was discovered, not larger than a good-size bristle, near the end of the old line of union to the right, and at the seat of the last operation. From it a tense band of cicatricial tissue extended on to the lateral wall, and, on pressure, rolled under the finger like a string of catgut. This was divided and the fistula closed, after removing its edges in one piece. When the sutures were removed, the union was apparently perfect, but in a few days the original condition was found to exist. She was advised to return home for the present, as her health had become very much impaired, in consequence of an accidental attack of sickness. On readmission, it is proposed, before attempting to close the opening, to remove in a mass the cicatricial band, and to bring together, along its course, healthy tissue secured by silver sutures. It will then be a simple matter, in closing the fistula, after removing a sufficient quantity around its edges, to reach healthy tissue.

at full term with her first child commenced at 11 A. M., Wednesday, March, 1860. After frequent and severe pains, the vertex reached the vulva on Friday, but made no farther advance until the following Monday, when the physician effected delivery by means unknown to her. The child was still-born, weighed ten pounds and a half, and, when delivered, the greater portion was perfectly black, but whether from decomposition or pressure she was unable to state.

The bladder was not emptied from the commencement of labor until after delivery. The urine began to escape involuntarily a week after her confinement. A large single slough was thrown off in three weeks, and a number of shreds during the following month.

*Pathological Condition.*—The vagina, at the depth of an inch or more, was found almost entirely closed, by the contraction of a thick cicatricial band encircling the canal. The passage through the constricted portion, although large enough to allow of the free escape of urine, was too small to admit the finger. This band was incised at several points until the canal was perfectly opened. It was then found that nearly the whole base of the bladder had been lost, together with the cul-de-sac. The cicatricial tissue behind the cervix was continuous, along the posterior wall of the vagina, with the circular band, and, by contraction, the edges of the opening were drawn nearly in contact, so as to form a fistula entirely across the vagina. The cervix uteri formed a part of the upper boundary of the fistula. The os was occluded by a superficial slough on the neck, and the body of the uterus seemed to be bound down, far over to the left side, by adhesions.

A large plug was introduced into the vagina, with directions that, until the parts were perfectly healed, it should only be removed during the administration of vaginal injections. The tendency to contraction was so great that

the operation had to be repeated several times. After the last time (early in April), the patient had a severe attack of metritis, with pelvic cellulitis, and was so much reduced that she was sent home to recruit.

May 16. On her return, the fistula was closed, as the parts were found in a comparatively healthy condition. The greatest difficulty in the operation was in consequence of the line of the upper edge of the opening being broken by a portion of the cervix projecting beyond it into the fistula. Eight sutures were used.

About two hours after the operation, hemorrhage suddenly came on from the vagina. An injection of ice water was thrown into the canal, but without arresting the bleeding. A solution of alum was then used; afterward, persulph. of iron, and finally the vagina was tamponed, and as firmly packed as was deemed possible without tearing open the recently approximated edges. All means having failed, and it being impossible to see from what point the hemorrhage came, at midnight the tampon was taken out, the sutures were removed, and the canal packed firmly with damp cotton, moistened with a solution of alum.

June 4. Again attempted to close the fistula, but the hemorrhage was so great on denuding the edges with the knife, that the operation had to be abandoned and the vagina tamponed.

June 24. The fistula was successfully closed by six sutures, and the case discharged, cured, July 16, 1862.

Second pregnancy, twins; partial occlusion of the vagina, with the antero-posterior diameter found contracted to  $2\frac{5}{8}$  inches. Twenty-eight hours in labor; delivered by perforation, the first child presenting by the *breech*, the second by the head.

On the 8th of the following May, I was called on by Dr. Fordyce Barker, who was then on duty at Bellevue Hospital, for some history of the case, as she was in labor at the time in that institution. He stated that while it was

evident, from auscultation, that she was pregnant with twins, yet the vagina was apparently closed. After giving him her history, I remarked that, unless perfect occlusion existed, it was likely that the cicatricial tissue would, for the time, soften down, and almost entirely disappear during the progress of labor, as I had observed the same result in a similar case. On examining her, several hours afterward, the vagina was found in nearly a natural condition, but the pelvis too much contracted for natural delivery.

A consultation was called, and delivery accomplished; after the birth of the breech, by Dr. Tayler perforating the head of the first child; and as the head of the other presented, it was delivered in the same manner by Dr. Geo. T. Elliot, Jr.\* It was found, on measuring the pelvis, that the antero-posterior diameter was scarcely two and three-quarter inches. Immediately after delivery, the urine began to escape by the vagina.

June 8, 1863. The patient was readmitted to the Woman's Hospital. She stated that menstruation ceased the day before leaving the hospital, July 16, 1862, and that she became pregnant during the following week, for her husband left on a voyage about that time after her discharge, and consequently she was ignorant of the closing again of the canal.

The vagina had contracted nearly to the condition prior to delivery, and, on incising the bands, a fistula about half an inch in diameter was found, nearly in the old line. It was closed by eight sutures; they were removed on the eighth day; the operation had proved successful, and she was discharged from the hospital a few days afterward.

In consequence of the condition of the pelvis, and the likelihood of her death if she again became pregnant and could not receive the same care in delivery, no effort was

---

\* See reported case 152, page 349. *Obstetrical Clinic*: by Geo. T. Elliot, Jr., M. D., &c. N. Y., 1868.

afterward made to prevent contraction of the canal, which, with this view, had only been opened sufficiently to close the fistula.

CASE LII. First pregnancy; about fifty-one hours in labor; delivery by forceps. Vagina shortened and partially occluded by bands crossing the vagina. After division of the bands, the fistula was exposed, and found situated in front of the cervix. The edges of the fistula, with the surrounding cicatricial tissue, were removed, and the opening closed by one operation.

Mrs. M., aged 22, was admitted from Hackensack, N. J., having been in this country only three weeks. After a marriage of two years, she had given birth to one child three months previous to admission.

Labor at full term began on Friday morning. The membranes ruptured early on Saturday, from which time the pains were frequent and severe for two hours, when they ceased entirely. On Sunday morning, ergot was given, but as no progress was made in the labor, the forceps were applied, and she was delivered of a dead child about noon.

Two days afterward, the urine escaped in small quantities, and continued to do so, until between the second and third weeks, when several sloughs were thrown off, after which time she had no control of the bladder, except for a little while, when lying on the back.

*Pathological Condition.*—It was several weeks after her admission before she could be properly examined, in consequence of excessive excoriation, and tumefaction of the labia, together with the surrounding parts, from irritation of the urine and lack of cleanliness. It was then found that the vaginal canal was shortened, and partially occluded by a number of thin bands or folds stretching from side to side in different directions. A small fistula was felt, a little in front of the cervix, but could not be brought in view.

Dec. 15. These bands were divided with scissors, one after another, until the fistula was reached. It was only

large enough to admit a No. 12 bougie, but there had originally been a great loss of tissue, which had contracted, leaving the edges entirely cicatricial. The fistula was removed entire, with about one-third of an inch of the surrounding tissue. The denuded surface was extended to an ellipse, transverse to the axis of the vagina, and its edges were brought together with six sutures.

The case is only of interest from the peculiar character of the bands, and from the fact that, with so little bleeding after dividing them, the fistula was closed without having to use a plug previous to the operation. The sutures were removed, December 24, and the case discharged, cured, Jan. 4, 1864.

CASE LIII. Sixth pregnancy; one hundred and fifteen hours in labor, and delivery by forceps. Vagina almost closed at the depth of an inch and a half, with destruction of the cul-de-sac. The vagina was fully opened after two operations, and the fistula in front of the cervix closed by one operation.

Mrs. H., aged 32, was admitted from the city, Oct. 18, 1863. She had been married twelve years, and had given birth to six children.

In May, 1863, the membranes suddenly ruptured on Saturday, while she was scrubbing, but the pains of labor did not come on until 5 A. M., the following Wednesday. They continued frequent and severe from the beginning until 4 A. M., Thursday, when she was delivered by forceps of a large still-born child.

The urine escaped immediately on delivery, and, a week afterward, several large sloughs became separated.

Up to the time of admission, there had been no return of menstruation.

*Pathological Condition.*—Almost perfect occlusion of the vagina, at the depth of an inch and a half, with the urine escaping through an opening, in the centre of the constriction, only large enough to admit a small sound. By the

rectum, the uterus was felt retroverted, and bound down by adhesion, with the cul-de-sac filled by cicatricial tissue, which was apparently continuous with the mass, involving the vagina.

Oct. 25. A speculum was introduced, the edges of the sinus leading to the fistula were seized with a tenaculum, and the constricted portion freely divided by scissors. This was done chiefly on the posterior wall of the vagina, as on that side, after some advance had been made, the touch indicated that the sloughing had been more extensive. After a mass, an inch thick, had been cut through, and the vagina opened freely to the cervix uteri, the seat of the fistula could not be discovered.

A large plug was worn, until Nov. 10, when a small opening in the bladder was found, in front of the cervix. As it could not be brought properly into view, on account of its situation just behind a fold formed at the seat of the previous constriction, this band was, at the time, freely divided, and a larger plug introduced.

Dec. 5. The vagina, from the continuous pressure of the plug, and by daily injections, had been brought into a healthy condition. Its walls were soft, from the disappearance of the cicatricial tissue, except to some extent in the cul-de-sac. The fistula was easily closed by six sutures, with the line of union transverse to the axis of the vagina. The sutures were removed on the ninth day, and the case discharged, cured, Dec. 30, 1863.

## CHAPTER XI.

### FISTULÆ, SITUATED IMMEDIATELY BEHIND THE RAMI.

CASE LIV. First pregnancy; fifteen hours in labor; delivery by forceps. The vagina was almost closed throughout its length, with loss of the cul-de-sac. Vagina opened by the scissors, laceration, and the knife. The fistula was found situated immediately behind the left ramus. Several days after removing the sutures used for the first operation, a small opening occurred from traction, in consequence of the surrounding cicatricial tissue. This opening remained closed after a second operation.

Mrs. McC., aged 29, was admitted from the city, Nov. 5, 1864. She had been married sixteen months, and was in good health until after the birth of her child.

Labor at full term began at 8 A. M., Wednesday, May 26, 1864. The membranes ruptured at midnight, but the pains were slight during the rest of the night. Ergot was administered several times, yet little progress in the labor took place afterward, and an attempt was subsequently made to apply the forceps, but without success. Another physician was employed, who, at 11 A. M., Thursday, administered chloroform, applied the forceps, and successfully delivered her, the child being still-born.

The bladder had been frequently emptied previous to applying the forceps for the first time, but not subsequently. Immediately after delivery, all retentive power was lost, except for a short time when in the recumbent position. She was confined to her bed for two months before she recovered the use of her lower limbs. She also stated that, during this time, she had no control over the contents of the rectum; as her strength increased, however, she gradually regained the power of retention.



*Pathological Condition.*—The vagina was so occluded at its outlet, by sloughing, that the index finger could not be introduced.

Nov. 29. The bands at the mouth of the vagina were freely divided, when it was discovered that the canal beyond, in front of the cervix, was also narrowed. This constricted portion was opened by snipping the bands at different points, where the tension was greatest, and afterward lacerated by introducing one finger in addition to another, at the same time controlling the extent and course of the laceration by the degree and direction of the pressure exerted. A suitable glass plug was afterward inserted. When the parts had healed, she was allowed to return home, and directed to continue the use of the vaginal plug until her readmission.

Feb. 3. It was now found that the canal had contracted somewhat, from a mass of cicatricial tissue in the cul-de-sac, which extended on the posterior wall of the vagina; much, however, had been gained, and the lower portion of the vaginal canal was now soft and in a healthy condition.

Feb. 7. Operated for increasing the depth, and the diameter of the upper part of the vagina. The scissors were used to a great extent, and laceration afterward; but the position being somewhat beyond the reach of the finger as a guide, the deeper tissues were incised with a knife. At a point where the tissues were very dense, the resistance was overcome so suddenly, that it was feared the rectum had been opened. A digital examination of the rectum proved, however, that such was not the case. The hemorrhage was excessive, but, without making any application directly to the bleeding point, a large glass plug was introduced, and the plan was adopted, as already described, of introducing a tampon around the outlet of the plug.

Although it is seldom that the cotton causes much

inconvenience, yet it is well, if there is no bleeding, after a few hours carefully to remove it, as was done in this case, in the same manner as it was introduced, and trust to the clot encircling the plug at the upper part of the vagina. The instrument was not withdrawn for twenty-four hours, when the vagina was carefully syringed out with tepid water.

March 7. The vagina was now found open, and in a healthy condition. The fistula was situated to the left of the neck of the bladder, behind the ramus on that side. It readily admitted the index finger, and the extremity toward the bone terminated in a sharp angle. The surface of the bone at this point was barely covered with cellular tissue.

The nearest extremity of the fistula was seized with a tenaculum, and, as the parts were thus put on the stretch, its vaginal connection was divided with a pair of scissors, close to the bone, so as to leave little more than its periosteum. The length and depth of the incision was extended along the face of the ramus, until the whole fistula could be drawn well out into the vagina (see Fig. 30, Case LV), thus giving sufficient room for the introduction of the sutures. The needles were passed from within outward at opposite points, and then, by placing the loop of one suture into the loop of the other, and drawing the latter through, it was made to include both lips. Seven sutures were used. After they had been removed a few days, an opening was found in the angle nearest to the bone, where the tissue had been all cicatricial. This was but a mere pin-point in size, but, in order to close it, it was necessary to remove, to some extent, the surrounding tissue.

April 4. The opening was caught up on a tenaculum, and a portion of the vaginal surface cut out with the scissors, so as to remove the entire fistula in its midst. While the opening on the bladder surface was but little

enlarged, its vaginal boundary was nearly an inch long, with its edges funnel-shaped. The edges were brought together by eight sutures, with the line of union nearly transverse to that of the previous operation. On the twelfth day, the sutures were removed, and the case was discharged, cured, April 22.

CASE LV. Fourth pregnancy; seventy-four hours in labor, and delivery by forceps. A triangular-shaped fistula situated immediately behind the left ramus. Before the opening could be brought fully into view or closed, it was necessary to dissect its base free from the bone. Closed by one operation.

Mrs. H., aged 30, was admitted from the city, Oct. 26, 1862. She had given birth to four children, with a tedious labor in each case.

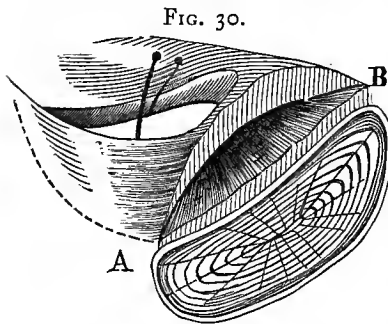
About a year before admission, the last labor commenced by a sudden rupture of the membranes, on Thursday, at one o'clock, P. M. As no labor pains came on until Friday noon, she continued in the mean time to attend to her household affairs. During the night, and throughout Saturday, until 4 P. M., Sunday, the pains continued severe and frequent. The forceps were then applied, and she was delivered of a dead child.

Seventeen days after delivery, a large slough came away, and she had no control of the urine afterward.

*Pathological Condition.*—A triangular-shaped fistula (Fig. 30), through which the index finger could be passed, existed behind the ramus. Its base extended along the bone, with the apex, formed by a cicatricial fold, running obliquely across the vagina to the opposite side of the cervix uteri. Originally, the loss of tissue had been great, and the fistula much larger, but nature had closed the edges of the opening for some distance along the fold, until the influence of the unyielding tissue, near the bone, had been reached, when a farther approximation was prevented; whence the peculiar triangular shape of the

fistula. The extent of the opening could not be fully exposed, and, from its awkward shape, together with the scarcity of tissue along the inner face of the ramus, it was evident that it could not be closed *in situ*.

The base of the fistula was, therefore, carefully dissected off from the bone, as close to the periosteum as possible. When the incision had been extended, from A to B, a little more than an inch, the fistula, by the tension of the band running from the apex, was drawn well out into view, with its edges almost in contact. After denuding the edges, a



closure was effected without difficulty, by means of five interrupted sutures. Although the edges of the fistula were to a great extent cicatricial, yet, as all tension had been thus relieved, the prospect of union was very favorable. On the ninth

day, the sutures were removed, and the case was discharged, cured, the last of November.

CASE LVI. Fourth pregnancy; in labor forty-four hours; natural delivery. The fistula was similarly situated behind the left ramus, as in Case LV, but with less sloughing; while the soft parts being more yielding, it was closed by one operation, without being freed from the bone.

Mrs. C., aged 30, came under my charge in the fall of 1863. She had married at 24, and given birth to four children without difficulty, except in the last labor.

Her pains came on at full term, about 9 A. M., Friday, Feb. 11, 1859, and, from the first, were strong and frequent. At eleven o'clock, a physician took charge, and, during his first examination, accidentally ruptured the membranes. The pains of labor soon after became almost incessant and changed in character; for the pressure, as she described, seemed directed entirely against the rectum and

back. As no progress took place, her physician, during Friday night, gave her several doses of ergot. By Saturday evening, she was much prostrated, and the pains became less frequent, yet they gradually expelled the head by 5 A. M., Sunday, the labor having lasted forty-four hours. The child was a male, of very large size, and still-born.

During the progress of labor, the bladder had been frequently emptied without difficulty. She sat up on the eighth day, and soon recovered her strength. On the twenty-fourth day after delivery, she noticed a slight discharge of blood, which continued for several days. As the lochia had been very slight, she attributed the show to its return; but, as the color became lighter, she noticed that the urine also was escaping by the vagina. The quantity gradually increased until, at the end of a few days, she lost all control. No slough was passed. Menstruation returned at the end of a year.

*Pathological Condition.*—The fistula was situated behind the left ramus, similarly to that in Case LV, with a like fold extending across the vagina. The opening was as large, but not so near the bone, nor had the surrounding tissues sloughed to the same extent. Although it was difficult to bring the parts fully into view, yet, as the tissues were more elastic, there was sufficient room to turn the needles on introducing them between the edge of the fistula and the bone. The fistula was closed by six sutures; they were removed on the eighth day. The operation had proved successful, and the patient was discharged, cured, after closing an extensive laceration of the perineum.

CASE LVII. Sixth pregnancy; about twelve hours in labor; delivery by traction. The fistula was situated behind the right ramus, lessened in size by the contraction of cicatricial tissue, and the vagina shortened by a cystocele. The fistula was closed by an operation for the relief of the cystocele.

Mrs. R., aged 42, a native of Ireland, was admitted from Adamstown, Iowa, Nov. 10, 1864.

She married at 32, and had given birth to six children, without difficulty, except in the case of the last labor, which commenced at full term, 5 A. M., Wednesday, June 3, 1864. A physician took charge at 3 P. M., and, finding the breech presenting, he made an attempt to deliver by turning, but, failing in his efforts, he administered an anodyne. A consultation was called, the child was found dead, and after giving chloroform, another effort was unsuccessfully made to turn. A rope was then placed around the child's neck, the patient states, and, with hooks in the body, it was dragged out by main force. There had been but little or no liquor amnii, while, from the beginning, the pains had been violent and frequent up to the time of administering the anæsthetic.

She was unable to remember whether the bladder had been emptied, until a short time after delivery. Two weeks afterward, she was seized with a severe headache and vomiting. During a paroxysm of the latter, she felt a sudden rupture in the vagina, and a gush of urine followed, with no subsequent control. Several sloughs and clots of blood were found in her bed, which had passed with the escape of urine. She was confined to her bed eight weeks. Menstruation had appeared twice since her confinement, but irregular and too free.

*Pathological Condition.*—A fistula, large enough to admit the index finger, was found, about half an inch behind the inner face of the right ramus. The loss of tissue had been extensive, as was indicated by the amount of cicatricial tissue in the neighborhood of the fistula. By contraction, it had reduced the size of the opening, and, at the same time, shortened the vagina. The loss of tissue being so much to one side, and with a partial destruction of the perineum, a portion of the vagina had become formed into a cystocele.

Dec. 6. Operation. A broad oval surface was removed

from the anterior wall of the vagina around the fistula, so as to extend to the right of the cervix, and a little beyond the median line. Seventeen sutures were introduced, and when the surface had been folded on itself, the edge which had been in the median line was carried over nearly to the sulcus on the right side. The excess of tissue was thus disposed of, the fistula closed, and a firm support given the uterus.

Dec. 20. The sutures were all removed, and the surfaces found firmly united.

Jan. 3, 1865. The patient was discharged, cured.

To have closed the fistula, by cutting out the cicatricial surface and uniting the edges, would have been a simple process, but, by adopting the procedure described, the vagina was restored to its natural condition, and procidentia uteri prevented.

## CHAPTER XII.

### FISTULÆ AT THE NECK OF THE BLADDER.

CASE LVIII. First pregnancy; natural delivery; forty-eight hours in labor. A transverse fistula was found at the neck of the bladder, with loss of the cervix uteri and cul-de-sac. By contraction of cicatricial bands extending along the lateral walls, from the cul-de-sac to the outlet of the vagina, the canal was shortened, with a resulting cystocele. The fistula was closed by the first operation, with the exception of a small opening. At the second operation the small opening was closed by the one instituted for the relief of the cystocele.

Mrs. McG., aged 30, was admitted from Johnstown, N. Y., May 15, 1858.

Labor at full term commenced during Tuesday night, Feb., 1858, but her physician stated that the head did not enter the superior strait until Wednesday evening. On Thursday morning early, it began to press on the perineum, but did not pass the vulva until about 9 P. M. At the time of its delivery, the pains were very slight, but the body soon followed with little delay. The labor had been protracted, in consequence of a want of proper action in the uterus, and lasted about forty-eight hours. Three days after delivery, the urine first escaped from the vagina, followed shortly by the contents of the bowels in the same direction.

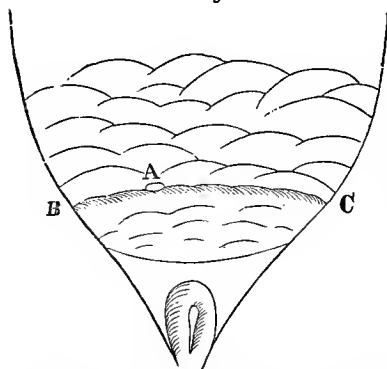
*Pathological Condition.*—A transverse fistula extended across the urethra, just in front of the neck of the bladder, with the urethra impervious at its extremity, through the anterior flap. The entire neck of the uterus, together with the posterior cul-de-sac, had been lost by sloughing. Cicatricial bands extended forward from behind the uterus to



the lateral walls of the vagina, and along the rectal septum. In consequence of this contraction, the anterior wall, or base of the bladder, was thrown into a number of folds forming (Fig. 31) a cystocele, and the vagina became much shortened. An extensive loss of the rectal septum had also resulted.

May 20. After opening the closed extremity of the

FIG. 31.



urethral canal by forcing the passage of a large sound, the fistula was closed from B to C by seven sutures, without difficulty, as there was a superabundance of tissue. On the eleventh day, the sutures were all removed, with perfect union throughout, except a small opening at the point A, where a suture

had been twisted too tight.

July 17. Second operation. Two sutures could have closed the opening, which was scarcely large enough to admit a probe, but, in consequence of the cystocele, which might eventually have produced procidentia uteri by its weight, a different procedure was adopted. Nearly the whole mass represented in the diagram (Fig. 31) was denuded of its mucous surface in the form of an ellipse, with its long diameter in the axis of the vagina. Seven sutures were then introduced from one side to the other, and the edges were brought together in the median line, thus folding the superabundant tissue on itself, and at the same time closing the fistula.

The sutures were removed on the twelfth day, and the operation was found to have been perfectly successful. The patient was discharged from the hospital, to return in the autumn for the purpose of having the rectal opening closed, which was then successfully accomplished.

CASE LIX. Fourth pregnancy; in labor one hundred and two hours; delivery by forceps. After great loss of tissue and narrowing of the vagina, a small opening was left at the neck of the bladder, which was brought into view on separating two deep folds; these were formed by contraction of cicatricial tissue, and extended under the arch of the pubes, downward and backward on to the recto-vaginal septum. Fistula closed without dividing the bands, for had they been incised, incontinence of urine would have resulted, as the neck of the bladder had been lost.

Mrs. W., aged 35, residing in Scott, Ogle Co., Ill., was admitted, Nov. 27, 1863. She had been married seven years, and had given birth to four children, all by severe and painful labors. The first and last deliveries were terminated by the aid of the forceps.

The last labor commenced on Monday morning, Sept. 29, 1862. The membranes ruptured about 3 p. m., and the pains afterward became less frequent. According to the history of the case, nothing was done until the following Friday, when, at 2 p. m., the forceps were applied, and she was delivered of a dead child, under the average size.

She stated that its head and arm were much lacerated in the delivery. The bladder was emptied naturally a short time before the rupture of the membranes took place, but not again until the delivery of the head, when the urine escaped, with no control afterward, except for a short time, while lying on the back or sitting still. Three weeks after delivery, several large sloughs were thrown off.

*Pathological Condition.*—There had originally been great loss of tissue, but, by contraction of cicatricial bands, the vaginal outlet, as well as the diameter of the fistula, had been much narrowed. The fistula, which was large enough to admit a No. 12 bougie, was situated at the neck of the bladder, and became exposed on separating two folds forming a sulcus half an inch deep. These folds were due to the shortening of the vagina, in consequence of contraction of the cicatricial surface, which extended under the arch of the pubes, and along the vaginal sulci on each side, downward and backward, until lost on the recto-vaginal septum.

The inner face of each fold, as it lay in contact with its fellow, was denuded entirely across, under the arch of the pubes. The only difficulty in the operation consisted in doing this thoroughly. Had the band been divided on each side, the surface to be scarified would have been readily exposed. This, intentionally, was not done; for the neck of the bladder had been lost, and the urethra consequently shortened, and, without making a proper use of the traction thus exerted, there would have been no retentive power after closing the fistula.

When the folds were united together, the sides of the urethra, from the closed fistula to the meatus, were kept in contact by pressure; in proportion to the accumulation of urine, and the consequent ascent of the bladder in the pelvis, the retentive power would be increased by this traction crowding the canal close under the arch of the pubes.

Six sutures were used; four were passed to the bottom of the sulcus; but the one on each side of the urethra was more superficial, and was so introduced that the point of exit, from one flap near the urethral passage, should enter at a corresponding distance from the edge of the opening in the bladder. This precaution insured an accurate adjustment of the edges of the openings. The sutures were removed on the fourteenth day, and the case was discharged, cured, Jan. 25.

CASE LX. First pregnancy; in labor seventy-one hours; natural delivery. An opening at the bottom of a sulcus, through the neck of the bladder, three inches in length, extended from one ramus across to the other, with its angles drawn up behind the bone, from contraction of a circular slough around the outlet of the vagina. After the operation, the catheter could not be passed beyond the line of union, as the two sections of the urethra had not been brought together in perfect correspondence. By untwisting several of the sutures, this was accomplished, and the operation proved successful.

Mrs. E., aged 28, was admitted from Galena, Ill., April 22, 1865. She had been married ten years, and had had one child, and a miscarriage afterward at four months.

Labor commenced at 3 P. M. on Sunday, but no further particulars of date were recorded of the history of her case. A physician was in attendance from the beginning. Nothing of importance occurred in the progress of the labor, beyond the fact that it was rendered tedious from a want of force in the pains. About noon on the Wednesday following the head was born; the pains then entirely ceased, and, at the end of two hours, the body was delivered by traction.

At the time of delivering the body, she felt "as if something was tearing inside of her." The urine had been passed several times during labor, but only in small quantities. As the body was drawn away, however, it gushed from her profusely. A few days afterward, several sloughs were thrown off. She sat up on the tenth day, and menstruated in about a year.

*Pathological Condition.*—A fistula, some three inches in length, extended through the neck of the bladder across from ramus to ramus, with its edges drawn up about half an inch behind the bone, on to the lateral walls of the vagina, by a connecting cicatricial surface on the recto-vaginal septum. In fact, the vaginal outlet had been encircled with a slough, and the only portion lacerated was through the urethra. It was evident that, from sloughing, there had been quite a serious loss of vaginal tissue, from the urethra to the ramus on each side, but, as the cicatricial surface contracted, the edges were drawn in close contact.

April 24. Operation. The chief difficulty consisted in properly scarifying the opening at the bottom of the sulcus and the angles, almost out of sight, on each side behind the rami. Twelve sutures were used.

On attempting to introduce a catheter after the operation, it was found impossible to pass it beyond the seat of laceration. This was due to the manner in which the su-

tures, on each side of the urethra, had been introduced, so that when they had been twisted, the two sections of the urethra did not correspond perfectly. There was no alternative but to remove a suture on each side; then, after careful manipulation, the catheter was passed into the bladder. It was allowed to remain for twenty-four hours without removal. No difficulty was afterward experienced, as the parts had then become moulded. Fortunately, a sufficient number of sutures had been inserted to prevent any gaping of the edges.

The sutures were removed, May 3. The entire line had united perfectly, except in the extreme angle to the left, behind the ramus, where two sutures had been twisted too tight. The catheter was continued, however, in use for a few days longer, when it was found that the little opening had closed. The patient was discharged, cured, May 13, 1865.

CASE LXI. Second pregnancy; in labor sixty-two hours; delivery by forceps. After a loss of the whole base of the bladder, the fistula was closed by Dr. Sims. Several months after her discharge, the line of union separated. An opening found in front of the neck of the bladder was closed, but the operation was unsuccessful. Failure due to bands in the cul-de-sac, which produced tension while lying on the back; these were divided, and the second operation was successful.

Mrs. L., aged 38, was admitted, Feb. 4, 1867, from Glen Cove, L. I. She married at 27, and had given birth to two children, both still-born.

The last labor commenced at full term, 7 P. M., Friday, March 25, 1858. She stated that she was in "hard labor" throughout, but that nothing was done until Monday morning, when she was delivered by forceps. The child was a male, with a very large head.

The bladder was not emptied from Saturday evening until after delivery, when the urine immediately began to escape. She had no recollection that any slough was thrown off.

*Pathological Condition.*—Nov. 19, 1860, she was admitted to the Woman's Hospital, with loss of the entire base of the bladder, from the cervix uteri to the neck of the bladder, and with the inverted fundus protruding through the fistula. Dr. Sims closed the fistula by two operations, on Feb. 6 and April 5, and the case was discharged, cured, April 18, 1861.

Several months after her discharge, she noticed a slight moisture, which increased in a few weeks, until at length she lost all control of the urine.

When readmitted to the hospital in February, 1867, it was found that about half an inch in front of the neck of the bladder had separated; there was an opening with very thin edges.

Feb. 12. Operated by extending the line of scarification on the vaginal surface outside of the opening, and over the old line of union across the vagina. The surfaces were folded up together, and secured by ten sutures.

It was not evident why the line of union had separated after her previous discharge, for, while lying on the left side, at the time of the operation, there was apparently no tension, but, on the contrary, an excess of tissue; for, with a tenaculum, the surface in front of the neck of the uterus could be drawn forward over in a fold, at some distance in advance of the opening.

Feb. 22. The sutures were removed; there had been but an imperfect union, and, by degrees, the whole line separated, until the original condition was attained, and, March 2, the patient returned home.

April 5. She was readmitted. While lying on the back, with the posterior edge of the fistula drawn forward in contact with the anterior portion, a band was then felt on each side of the cervix, extending toward the cul-de-sac on to the lateral wall of the vagina, which could not be detected when on the left side. This fact explained the cause of failure,

as the tension had been constant while lying on the back, after the operation.

The bands were freely divided, and the previous operation was repeated, using nine sutures. They were removed on the tenth day, and the case was discharged, cured, April 20.

On the 1st of June following, she remained in the same condition, there being no tension, with a gain of nearly an inch in the depth of the vagina since the division of the bands.

## CHAPTER XIII.

### FISTULÆ INVOLVING THE URETHRA, FROM LACERATION OR SLOUGHING.

CASE LXII. First pregnancy; the head born at the end of seventy-four hours; pains then ceased; body delivered fifteen hours afterward by traction. The urethra lacerated entirely through, half an inch from the meatus. The distal portion of the canal so dilated that a large portion of the mucous membrane protruded. The difficulties of the operation consisted in passing the sutures so as to bring perfectly into apposition the two sections of the canal, of different diameters. Operation successful.

Mrs. H., aged 18, was admitted from Cold Spring, L. I., April 27, 1867. She had been married two years, and had given birth to a still-born child.

Labor at full term commenced Wednesday, Jan. 24, 1867. The pains, however, were not very strong or frequent until the following Sunday. At 2 P. M. the head was born, but the pains entirely ceased afterward, and the body remained undelivered, until Monday morning, when the labor was terminated by traction.

Previous to delivery, the bladder had not been emptied for forty-eight hours; four days afterward, the urine began to dribble away. It was not noticed that any sloughs were passed from the vagina.

*Pathological Condition.*—Directly across the urethra, about half an inch from the meatus, a fissure extended (Fig. 32) from one ramus to the other, dividing the urethral canal entirely through. The distal portion of the urethra was so dilated that the index finger could be introduced for some distance within the canal.

The mucous membrane anterior to the neck of the blad-

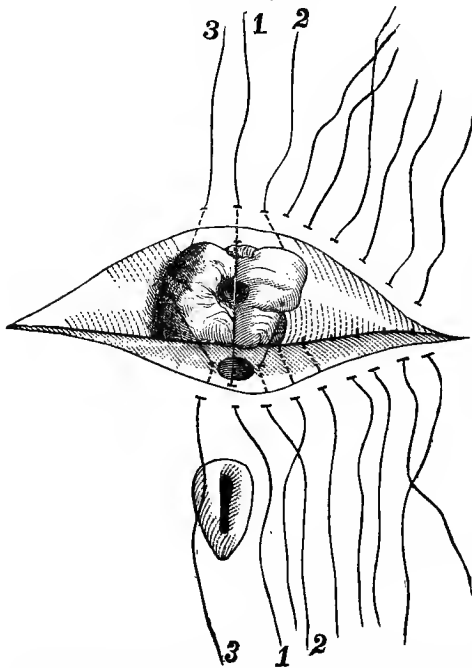


der protruded in a hypertrophied mass as large as an almond, resembling a prolapsed anus. In the centre of the prolapse, the orifice of the canal, just in front of the neck of the bladder, remained undilated, and corresponded in diameter to the portion of the urethral canal through the anterior flap.

This condition was an unusual complication, as the prolapsed mass filled up the sulcus, and, although it could easily be returned, it was with great difficulty kept within the canal for the purpose of scarification. The temptation was strong to remove a portion of it with the *écraseur*, and wait until the surface had healed before operating; this was, however, deemed unadvisable, from the extent of cicatricial tissue, and the uncertain amount of contraction which would have resulted.

May 7. Operation. The whole extent of the sulcus was denuded around the edge of the urethra on each side,

FIG. 32.



with care, so as not to wound the mucous membrane of the canal. Thirteen sutures were introduced.

The only point of interest was in regard to the manner of passing those nearest the urethra. On reference to the diagram (as shown by the dotted lines), it will be seen that while the sutures 1, 2 and 3, corresponded in relation to their entrance and exit on

the vaginal surface, Nos. 2 and 3 diverge from the edge of

the undilated portion of the urethra, to enter, at a corresponding point, on the margin of the dilated portion.

Six sutures on each side, from the angles toward the urethra, were first twisted; a large sound was then introduced into the bladder, to keep back the prolapsed portion while securing Nos. 2 and 3 on each side of the urethra. Lastly, No. 1 was twisted, but before doing so, the slight prolapse was pushed back, and kept from protruding by the point of a blunt hook passed under the suture and retained until it was secured.

On reflection, it will be evident that in securing the sutures on each side of the urethra, they must necessarily approximate to a parallel course in relation to each other, and in so doing the excess of tissue would be rolled thus into the bladder. While the dilated outlet was doubtless folded somewhat on itself between the five sutures which embraced the diameter of the urethra, yet, as they were passed so as to bring the edges of the canal at each point into exact apposition, the catheter met with no obstruction, and the excess of tissue soon retracted.

May 17. The sutures were removed, and the operation was found successful.

May 29. A sound was passed along the urethra, and, after a careful examination, it was found impossible to detect the line of union, as not the slightest irregularity existed. The case was discharged, cured, June 1, 1867.

CASE LXIII. First pregnancy; about ninety-eight hours in labor; breech presentation; instrumental delivery. An opening caused by sloughing at the neck of the bladder, with loss of a portion of the urethra. A new urethra made by puncture, and the fistula closed afterward.

Mrs. S., aged 23. Labor with her only child commenced Wednesday, Jan., 1860. The pains, however, were slight during the first twenty-four hours, and a physician was not placed in charge until Friday night,

when it was supposed that labor had set in and would soon be terminated. He at once administered ergot, which greatly increased the force of the pains, but without any progress being made in the labor.

On Saturday morning, it was discovered to be a breech presentation, the pains continuing very violent in character, and anodynes were freely given. On Saturday night, an attempt was made to bring the feet down, it is supposed, but failed. Nothing further was done until Sunday morning, when she was delivered by "instruments," but she was in too exhausted a condition to understand the method.

The child was still-born, and weighed, she was told, twelve pounds, with a hydrocephalic head.

She was unable to state whether the bladder had been emptied previous to delivery, at which time a catheter was introduced. The urine was afterward retained for twenty-four hours, and on Tuesday it began to escape by the vagina.

About four weeks after delivery, she removed from the mouth of the vagina a slough, as she stated, about three inches long and half an inch wide. This was the only one passed, and she afterward had no retentive power.

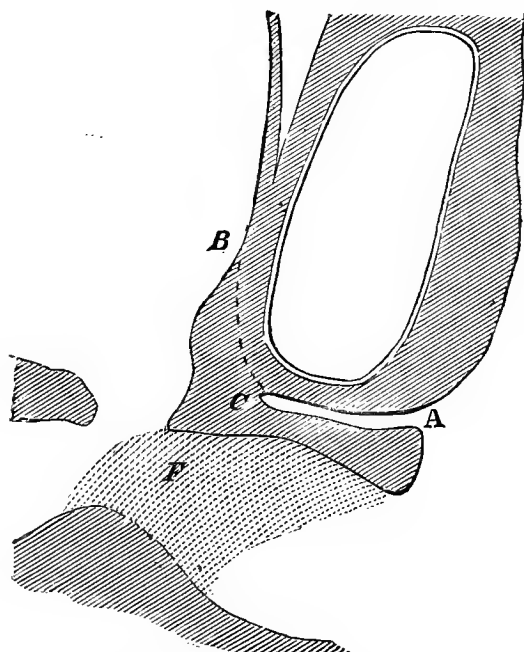
*Pathological Condition.*—There had been a slough under the arch of the pubes, entirely across the vagina, which had destroyed the neck of the bladder. As this surface cicatrized, the fistula just at the neck of the bladder was left only large enough readily to admit a No. 12 bougie. The urethra at the point crossed by the slough was closed. A dense, semi-lunar-shaped band extended under the arch of the pubes, from the fistulous opening on each side, downward and backward toward the posterior wall, so as to contract the diameter of the vagina about two inches from its outlet, as is shown by the dotted surface in the diagram.

Dec. 10. The bands were freely snipped through by

scissors at several points, and a glass plug introduced to keep the parts well on the stretch while healing.

The fistula could have been easily closed without dividing any part of the bands, but experience had fully taught that no retentive power could have existed, as the traction here exerted would destroy the proper sweep of the urethra

FIG. 33.



under the pubes, by drawing the meatus downward and backward, and leaving it patulous.

The urethra was not opened, therefore, along its original course, but its pervious portion was continued by a false passage into the bladder, higher up, at the point B (Fig. 33), in the direction C B.

A glance at the diagram will show that any lateral tension excited by the bands along the dotted surface at F, would tend, by crowding the tissues upward, to keep the false passage closed in the direction of B.

As the sloughing had been deep, these bands could not be divided so thoroughly as to overcome this action, while, with a view to turning the force which they exerted to account, they were divided only at such points as would increase the size of the vaginal canal, without interfering with the desired action. It is impossible more fully to explain the steps of the operation by any description to the reader, yet to an operator, who appreciates the available points in a similar case before him, the necessary steps would be apparent.

A catheter tube, properly bent to the sigmoid-curve, was retained in the false passage for some ten days, until it had perfectly healed.

A month afterward, the little fistulous opening at the neck of the bladder was closed by five sutures, and the patient returned home, cured, Feb. 12, 1864.

## CHAPTER XIV.

### FORMATION OF A NEW URETHRA BY AID OF PLASTIC SURGERY.

CASE LXIV. First pregnancy. The head born in ten hours, but the body remained undelivered for some fourteen hours afterward, when it was removed by traction. In labor about twenty-four hours. Outlet of the vagina nearly closed by a circular slough. Loss of nearly whole urethra, the sub-pubic tissue, and that posterior to the bone for half an inch. The whole base of the bladder, the neck of the uterus and the cul-de-sac were destroyed, with the vaginal canal shortened to an inch and a half in depth. During three years, and after some twenty operations, a new urethra was formed by aid of plastic surgery, the fistula closed, and the vagina opened to three inches in depth. She was discharged with perfect retentive power, but obliged to use the catheter. After several attacks of cystitis, at the end of eighteen months, a portion of the line was opened for the removal of calculi, and not again closed.

Mrs. McD., aged 20, from Port Berwell, Canada, was admitted, Sept. 26, 1862. She had given birth to one child, but the recorded history of her case does not state the time previous to admission.

Regular labor at full term commenced early on Saturday morning, with frequent and severe pains. During the afternoon a physician took charge of her case, who, at his first examination, intentionally ruptured the membranes, as she stated, and afterward gave ergot several times "to hurry up the pains." Before dark the head was born, but no effort was made to deliver the body until Sunday morning, when another physician was placed in charge. She was at once delivered, but having become much swollen in the meantime, quite an amount of force had to be exerted in accomplishing it. The child was dead at

the time of its birth, and weighed eleven and a half pounds.

The urine was retained some eighty-four hours, from Friday night until the following Tuesday, when a catheter was introduced, and regularly afterward for a week, at which time the urine began to escape from the vagina.

For three weeks, portions of sloughs were daily thrown off.

*Pathological Condition.*—The mouth of the vagina was much narrowed by a tense circular band, the result of a slough, which had destroyed the whole course of the urethra, with the exception of a line or two at the meatus. Through the constricted vaginal outlet, the fundus and posterior wall of the bladder protruded in a partially strangulated condition. The vagina was narrowed throughout, and but an inch and a half in depth. The cul-de-sac had been destroyed, with the entire cervix uteri, as well as the whole base of the bladder from one ramus to the other. Behind the pubis a slough had extended up about half an inch, leaving but little covering to the bone than its periosteum. From this point forward, to the remnant of the urethra, there remained but a portion of the sub-pubic ligament and a little cellular tissue.

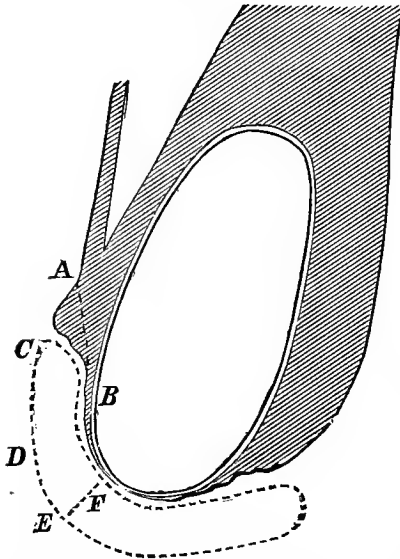
Her general health was good, but she was short in stature and exceedingly corpulent. Altogether her case was a most unpromising one.

Oct. 7. Free incisions were made through the band around the vaginal outlet, and a plug, as large in diameter as could be borne, was introduced.

Oct. 26. A false passage was made with a trocar through the soft parts from B to A (Fig. 34), to serve as a part of the tract for a new urethra. A section of lead tubing was introduced, with the two ends bent together in the direction C, and left in the passage until the sixth day, when the canal seemed perfectly healed.

Nov. 8. Made free incisions through the mass of cicatricial tissue filling the cul-de-sac, and inserted a plug into the canal of sufficient length to keep the parts on the stretch by aid of a T bandage.

FIG. 34.



the stretch by aid of a T bandage.

Nov. 21. Found that the false passage for the urethra had gradually closed; a larger puncture was made, and it was directed that a catheter tube should be retained for a longer time, until the canal had perfectly healed.

It is exceedingly difficult to convey an exact idea, as it were, of the topography.

From B forward to the urethral outlet, a slough

had removed the soft parts as if with a scoop or gouge, the excavation being deeper in the median line, and wider as it extended forward toward the vaginal outlet. At B, where the slough commenced, which may be designated as the apex, the tissues were of their natural thickness; while at the base, near the remains of the urethra, but little more than the periosteum covered the bone.

A false passage had been made above, through healthy tissue, for a portion of the urethra, with the intention of continuing this forward under the arch of the pubis, but to do so it was necessary to fill the sulcus or excavation lost by sloughing. The false passage, however, gradually closed, and the attempt was abandoned to keep it open.

To accomplish the object, the opposite sides of the triangle, forming the sulcus, were scarified, leaving only a narrow strip at the bottom, between the denuded surfaces, to



serve as the urethral tract. Two diverging incisions, from above downward, were then made through the cellular tissue behind the pubis, parallel to the edges of the sulcus. The denuded sides of the sulcus were then slid together in the median line, and secured by seven sutures at C D E, leaving an undenuded tract behind the two flaps for the urethra.

It was remarkable that the hemorrhage was comparatively slight. After the mucous membrane had been divided in line by scissors, any portion of the flap in the loose cellular tissue behind the pubis, when put on the stretch by a tenaculum, was easily lacerated in line, as directed by the tension, with but slight aid from the handle of a scalpel.

The operation had to be performed entirely on the knees and elbows, and required about two hours for its execution.

The line brought together, an inch in length, was composed of the tissue forming the anterior wall of the bladder, and extended entirely within the cavity.

The operation was performed, Dec. 12; a week afterward the sutures were removed, and the operation proved a success.

Dec. 29. Extended the incisions into the cul-de-sac, so as to increase the depth of the vagina over half an inch, and freed, at the same time, the remains of the cervix uteri from adhesions on each side; the use of the plug was continued.

Jan. 9. Endeavored to place her under the influence of ether, to close the fistula, but, after an attempt of two hours, and using more than a pound of ether, it was abandoned, finding it impossible to get her sufficiently relaxed.

Jan. 16, 1863. Administered chloroform, but with no better success; there was no relaxation of the muscles, and although at times apparently fully under the influence of the anæsthetic, yet, as soon as any attempt was made to

introduce the speculum, she would immediately straighten out of position.

Feb. 1. Without an anæsthetic, after two hours, with much delay from the great nervousness of the patient, the uterus was retroverted, drawn forward, and the remains of the anterior lip of the cervix united along the line D E, composing the new urethral canal, recently formed behind the pubes. The line of union was crescentic, with its cornua extending an inch or more posterior to the cervix on each side.

Thirteen sutures were used, but a gap was left in the line in front of the uterus for the urine to escape, while the urethra was being afterward extended. The sutures were removed on the ninth day; the union was perfect nearly throughout, and the operation was successful, so far as it was expected to be—in retaining the uterus in its new position, so that the neighboring parts could become properly moulded, for after use.

May 17. After a large anodyne, to aid the action of the anæsthetic, ether was again administered. By tying the patient in position on the left side, with sheets, it was hoped that the difficulty might be overcome. She was brought fully under the influence of the anæsthetic, yet so great was the reflex irritation on introducing the speculum, that it was impossible, even when securely tied, with, in addition, the full strength of several gentlemen present, to keep her in position.

She was at length allowed to become conscious, and I proceeded to operate with great difficulty, as she was unable to bear a sufficient amount of traction on the perineum from the speculum, to freely open the vagina.

The operation was to close a portion of the line united, Feb. 1, which was situated behind, and to the right side of, the cervix uteri, where, being in the midst of cicatricial tissue, it had separated in a number of small openings.

After dividing to some extent the tissues beyond in the cul-de-sac, so as to relieve all tension, the openings were extended into one, by a cut of the scissors. The edges were then carefully denuded, so as to remove each point where union had not taken place. The sides of the opening were secured by fourteen sutures, and the operation completed at the end of three hours and a half.

On removing the sutures, it was found that the urine was escaping in small quantities at several points, but, by continuing the use of the catheter for a few days longer, the openings closed by contraction.

June 26. The remains of the old urethra at the meatus removed, preparatory to an operation for extending forward the new canal. In principle, the procedure was the same as adopted at the previous operation behind the pubes. Two parallel lines of freshened surface were made, extending from E F forward under the arch of the pubes, a little beyond the termination of the old urethra, leaving an unscarified strip between them, about half an inch in width, to serve as the tract of the new canal. Outside, and parallel to each denuded line, a free incision was made inward, and somewhat beneath the raw surfaces, in the direction of the symphysis pubis. These incisions were extended beneath to free the soft parts sufficiently, that the freshened surfaces on the flaps could be rolled over in contact. The surfaces were secured by seven sutures over a catheter, passed in the course of the new urethra, and held by an assistant until all had been twisted.

She was then placed in bed on her back, with her knees flexed and tied together. The catheter was retained in the canal, and supported in a sling of sticking plaster from above the pubis, so that the line of union in its integrity might not be impaired by the weight.

When the sutures were removed, it was observed that one at each end had nearly cut out, from being twist-

ed too tight; a difficult matter to avoid, as the soft parts at each end of the line were so yielding as to render the point uncertain at which the suture had been properly secured.

The result was that quite an opening was left at E, where the two sections had been joined; but, forward for an inch, the canal was perfect.

July 20. She returned home for the summer, and was readmitted to the hospital, Oct. 25, 1863.

A few days afterward, she had an operation for increasing the depth of the vagina.

Dec. 2. Closed the opening in the urethra, by six sutures, in a line transverse to the axis of the vagina. The sutures were removed on the sixth day, and the operation was found to have been successful.

She was now in a condition to be discharged cured, as she remained perfectly dry; but, from the character of the tissue throughout the vagina, I determined to keep her under observation for a month or two longer, before returning home.

Jan. 12, 1864. The urine began to escape, it was found, from a number of minute openings about the centre of the line of the urethra. They were all opened into one by the scissors, and the edges, which were now very thin, were freshened with as little loss of tissue as possible. Twelve sutures were introduced, as it was necessary, in consequence of the thin edges, to extend the denuded surface on the vagina, from the meatus nearly to the cervix uteri, so as to bring together two folds up over the line. The tissues were so friable and soft that it was impossible to judge as to the proper twisting point for the sutures. The knees were tied together as before, a precaution still more necessary, as the tension was now so great that they could not be separated to any extent without making traction on the sutures.

On the eighth day, the sutures were carefully removed, but with difficulty, as the parts had become much swollen and inflamed.

Feb. 22. Closed a small opening which had again formed in the urethra. Its edges were too thin to be brought together alone, therefore the vaginal surface was denuded at some distance around, while, as in the first operation, two parallel incisions were made outside, and the flaps doubled over together along the old line.

Seven sutures were used; they were removed on the tenth day, and the operation was apparently successful.

March 18. Operated to close an opening, smaller, but at the same point.

She had kept perfectly dry some time after the last operation, but, when the catheter had been discarded, she found that the urine would accumulate in large quantities, without any power or desire to empty the bladder. The catheter was resorted to by her for relief, but I was satisfied that it was not used at proper intervals, and to the traction thus exerted the opening was due.

April 19. The urine began to escape from a large opening, which suddenly formed on the right side behind the cervix, at the extreme angle of the line made where the uterus was drawn forward, to be united under the arch of the pubis.

Through this opening a portion of the fundus of the bladder now protruded. It was closed by nine sutures, and with but little hope of success, as its edges were entirely cicatricial. The operation, however, proved perfectly successful.

May 20. Closed the opening in the urethra, the only one now remaining, using eleven sutures.

This operation was also successful, but, when the sutures were being removed, a small opening was detected at the seat of the previous operation, to the left of the neck

of the uterus. The catheter was, however, continued in use for some ten days longer, when the opening was found to have closed by contraction.

July 4, 1864. She returned home, keeping perfectly dry, but without any voluntary power of emptying the bladder.

Her condition was as follows: The vagina had been opened to a depth of over three inches; the fistula had been closed, and an entire new urethra formed, with perfect retentive power, but inability to empty the bladder, except by means of a catheter.

Feb. 15, 1865. She was readmitted, giving the following history. Until January, she had remained perfectly well, when she began to suffer from tenesmus and irritability of the bladder, requiring the frequent introduction of the catheter. The urine became thick and offensive, with such an accumulation of mucus, that the catheter would become obstructed almost as soon as it was introduced. In a short time afterward the urine began to escape by the vagina, with great relief to her sufferings.

On examination, it was found that an opening existed in front of the uterus, at the junction of the line with the urethra, and through which a No. 12 bougie could be readily passed.

The cystitis was treated by frequently washing out the bladder with tepid water, and she improved rapidly.

She had never menstruated since her pregnancy, nor was it anticipated that she would again, from the fact that atrophy of the uterus had taken place, as a result of the inflammation by which the entire cervix had been lost, leaving the organ barely an inch and a half in depth. I have already referred to this fact, and have observed the result frequently. The earliest instance which passed under my notice was a case, where, at the age of 36, menstruation had not returned after an interval of fourteen years from

the reception of the injury, and yet the woman had remained in good health.

In this case, however, from the beginning of the cystitis, there had been a regular menstrual nixus, but with no flow. It was suggestive, and, in connection with the treatment for the cystitis, a small sponge tent was introduced into the uterine canal every other day, and removed at the end of twelve hours. After these had been used for two or three weeks, the discharge following their removal became more profuse, and with great relief to the pain in the back, and to the constant feeling of weight about the organ.

By the beginning of April, the uterus had increased so much in size that the canal was two inches deep, and, with an allowance for the lost cervix, the organ had now become nearly of normal size. At this time, after removing a tent, the show was more than usual; it continued and lasted for several days. Without speculating as to cause and effect, it is an interesting feature in the history of her case, that all symptoms of irritation of the bladder ceased as soon as the menstrual flow became established, and, in fact, lessened from the first discharge following the use of the tents.

April 7. With seven sutures, the opening into the urethra was closed, by bringing together two folds of vaginal tissue over it, in a line transverse to the axis of the vagina.

On the eighth day the sutures were removed, and she returned home in excellent condition, May 9, 1865.

On the 14th of February, 1866, she was again admitted to the hospital, and presented the following statement. For six months after her return, she remained perfectly well, and had five menstrual periods. Gradually, however, after this time, irritability of the bladder came on with the cold weather, and she then suffered from the same train of symptoms as before.

Her difficulty increased, until January, when suddenly the urine again escaped by the vagina, but without affording the same relief as before.

An opening from the urethra into the vagina was found, situated in front of the cervix uteri as at first, with another opening from the urethra into the bladder about at the point D. On introducing a sound, a mass of calculi was detected in the pouch, or most depending portion of the bladder, formed by the anterior wall of the retroverted uterus. The opening was enlarged, and nine phosphatic calculi were removed; the whole number in bulk were sufficient to fill an ordinary wine glass.

The cystitis was treated as before, but with the injections acidulated with dilute nitric acid. She was soon entirely relieved, and returned home, April 17, 1866.

The fistulous opening was not closed, and it was advised that it should remain open for a year, thus enabling the bladder, by rest, to regain its tone. At the end of that time she was to return for an operation, as I contemplated changing the course of the urethra. She never returned, however, and I am ignorant of her present condition.

In connection with the following case, the subject will be illustrated of establishing a most important point, resulting from the practical teaching gained by this failure. After taking into consideration how much was accomplished in this case, it must be regarded as a triumph for plastic surgery, for indeed it would be difficult to conceive that another could be presented with a greater destruction of tissue, except with the loss, in addition, of the recto-vaginal septum.

I am not aware that the attempt has ever been made, or been before successful, toward the formation of an entire urethral tract, as in this case, where the tissues were all lost under the arch of the pubis; or that a similar operation was ever performed within the bladder itself.



As a surgical procedure, it was a success, for the retentive power existed six months at a time. The formation of calculi resulted from the presence of stale urine in the bladder, because it could never be emptied below the point at which the false passage entered it; and yet the result might have been different, with the exercise of proper care on the part of the patient. The difficulty in having to trust so much to the after-care of the patient, I hope, has now been obviated, for relief has been gained by the method in other cases since, and, which I hope may yet be put in practice in the one under consideration.

CASE LXV. Second pregnancy; in labor about ninety-two hours, and delivery by forceps.

Loss of the whole base of the bladder, the cervix uteri, and laceration in the median line almost to the vesico-uterine junction, with destruction of the neck of the bladder and nearly the whole urethra. The uterus was immovable and drawn to the right side.

At the end of two years, and after eleven operations, the fistula was bridged over.

A new urethra was then made throughout, and, after three additional operations, she was discharged, with voluntary retentive power.

Mrs. F., aged 30, was admitted from Bearndam, Wis., Nov. 30, 1864. She married at 22, and had given birth to two children at full term, both still-born.

The mother stated that the first labor was a natural one, with nothing unusual in its course beyond the unknown cause for death of the child.

The pains of the second labor commenced Sunday, 5 A. M., August, 1860, and continued until rupture of the membranes, on the following Tuesday, when they ceased entirely. During Wednesday night, the forceps were applied successfully.

The bladder had not been emptied for twenty-four hours previous to delivery.

The placenta was retained for three days, and immediately after its removal, she found that she had lost all control of the urine. She was confined to her bed for eight

weeks, during which time she had a profuse vaginal discharge, with the passage of a number of sloughs for several weeks after delivery.

*Pathological Condition.*—The whole base, the cervix uteri, the neck of the bladder and urethra, to within a third of an inch of the meatus, had been lost by sloughing. The uterus was immovable, and the cervix bound down by adhesions, just beyond the right ramus, with the loss of the neck. A deep fissure extended up the anterior wall of the uterus, nearly to the termination of the vesico-uterine junction. The shape of the fistula resembled that of Case XXXIII, but was only about half as large, with hard cicatricial edges. The cul-de-sac was ample in size, and comparatively uninjured. An inversion of the bladder through the fistula filled the whole vagina, and the mouth of the left ureter was exposed. The tissues behind the neck of the bladder had not been destroyed, but the adjoining portion of the urethra had sloughed away, while the remaining part of the canal was split up, as if it had been cut by scissors.

As several other cases somewhat similar have already been described at length, it will be unnecessary to give more than a general outline of the mode by which the fistula was closed.

After several months of preparation, the fissure through the anterior wall of the uterus was closed on the bladder side, and commencing within its cavity, so as to extend the uterine canal up to the vaginal level.

We have seen that the cervix was immovable on the right side behind the ramus. Fortunately, the cul-de-sac and the left side of the vagina were quite free. Therefore the right side of the fistula was denuded from the cervix uteri toward the outlet of the vagina, with a corresponding length from the cervix along the left border. At the termination of the scarified line on the left side, the edge

was seized by a tenaculum, and drawn forward toward the outlet of the vagina. When thus placed on the stretch, a line of incision was made by snipping with the scissors, just above the freshened surface, along the lateral wall of the vagina, from behind the left ramus toward the cul-de-sac, until the parts had been sufficiently freed to allow of an approximation between the two denuded surfaces.

By this means a portion of the cul-de-sac from the left side could be swung around, as on a pivot, to the right, in front of the cervix; the left wall of the vagina was consequently drawn somewhat toward the opposite side, while the flap which had been dissected off from the left lateral wall was turned over to the right side, with its mucous membrane, into the bladder.

The incision was carried down along the course of the muscle, with comparatively little hemorrhage, except from the vaginal surface, for a greater part was lacerated by the traction, with but slight aid from the scissors. The wounding of many blood vessels running in the same course was thus avoided, which would have been an impossibility, if the scalpel had been resorted to.

The edges of the fistula had now been brought together somewhat in the form of a right-angled triangle. The perpendicular line had just been secured, leaving the base still open as a transverse opening across the vaginal outlet.

This was afterward closed by a single operation on each side up to the point where the urethra was to enter the bladder.

During the subsequent two years, eleven operations were performed to close as many openings, which were reproduced from time to time by traction at various points, where the tissue was cicatricial in character.

Jan. 8, 1867. Operated to form a new urethral canal, the remains of the original having been removed several months before.

At first it had been determined to leave it, as, with the meatus in its integrity, the weight of the catheter after the operation could not drag open the canal, but it had been divided entirely across in its diameter, and to have joined this irregular and thin edge to a new section would have been almost impossible.

As in the last case, from D forward, a little beyond the point from where the meatus had been removed, two denuded surfaces were made. They were not made parallel, however, but the space between was nearly twice as wide posteriorly as at the termination, with somewhat of a trumpet-shaped flaring at the bladder. Outside and parallel to the line, a deep incision was made on each side, but not beneath their course, as in the previous case, and the flaps were drawn together over a sound by seven sutures. Into the vaginal fold thrown up on bringing the flaps together, two sutures were introduced beyond the point where the new canal became continuous with the bladder.

To the right, in the angle at the junction of the two lines formed by bringing together the sides of the fistula, in the second operation, a small opening remained, and had not been closed, with a view of using it while the urethral canal was uniting. Through this opening the catheter was inserted into the bladder, and retained in use as under other circumstances. In fact, two openings existed, but with so thin a septum between, that one became closed by a catheter introduced into the other.

The sutures were removed, Feb. 9, and the operation proved to have been successful.

April 12. As the new urethra was deemed strong enough to bear the introduction of a catheter, the openings above mentioned were closed by nine sutures, after the edges had been relieved from tension by a division of some bands on the opposite side of the vagina. The operation,

however, proved a failure, as at this point the tension had been greater than at any other along the line.

May 31. Again operated, and as several minute openings were found above, about half an inch in front of the cervix uteri, the following plan was pursued.

As in Case XXXVII, a denuded strip was made along the base of the bladder, just outside of the old line of union, and extended beyond the openings at either extremity; when this had been completed, a corresponding surface was removed from the lateral wall above. In the same manner, but not to the same extent as had been done on the opposite side of the vagina, a flap was then freed from the lateral wall, and folded over the openings.

By long traction, the tissues forming the first line of union had become very thin, and the edges of the several openings were too much so to be closed without including a portion of the vaginal surface. It was therefore easier thus to shut in a pouch the whole line by one operation, which would relieve the parts below of all tension.

Ten sutures were used, and removed, June 10. The operation was successful, but, by the weight of the catheter, that portion of the new urethra which had been extended upward in advance of the natural position of the outlet, gradually separated backward, until the latter point had been reached. When the use of the catheter was discarded, however, it was found that the retentive power was perfect, and she returned home, cured, July 2, able to void the urine at will.

Formerly it had been my impression that there could be no retentive power, where the neck of the bladder had been lost, without the new passage was made to enter at as high a point as possible; on the principle that, as the urine accumulated, the bladder must rise out of the pelvis, and, in doing so, the patulous passage would be drawn tight under the arch of the pubis, thus gaining a retentive

power, before the urine could reach the level of the opening. The risk from a retention of stale urine in the bladder was, of course, fully appreciated, and that the occurrence could only be avoided, when it was possible to impress the patient with the necessity for washing out the bladder daily.

In Case LXIV, the opening into the bladder was made, from necessity, at a higher point than in any other previous case where I had followed this plan, and, beyond the inconvenience of having to use the catheter, I was ignorant that any other difficulty would be likely to occur, with ordinary care. The result of this case, however, necessitated a resort to some other expedient to obviate the risk of trusting to the judgment of the patient.

On reflection, it occurred to me, with the entrance to the bladder at the most dependent part, but with the canal extended upward in advance of the natural point of outlet, the traction from the cicatricial tissue might be so regulated as to gain a controlling power.

Therefore the new canal was made somewhat trumpet-shaped, with the view that if the traction proved sufficient to create a retentive power, when the pressure of the abdominal muscles was exerted for expulsion, the first portion of urine forced into the funnel extremity would, with readiness, open the canal. It was also thought that the stream, being once started, would continue from the force behind, and that the retentive power, which had increased with the accumulation, would lessen in proportion as the bladder became emptied.

The incisions were made to diverge from without inward, and directly downward, instead of passing obliquely behind the flaps. For it had been noted that when the flaps were dissected up, there could be but little lateral traction exerted by the cicatricial tissue on the diameter of the canal, as it was all lost behind, and under, the arch of the pubis.

By separating the lines of incision, the lateral force exerted was greatest toward the outlet, and sufficient in the beginning to arrest the escape of urine, unless forced open with a stream by pressure of the abdominal muscles; with the accumulation, an increasing retentive power was established along the whole canal, in its axis, but which, at the same time, was readily overcome at will. In other words, by obtaining the greatest amount of traction which could be exerted by the cicatricial tissue, the triangular surface between the two incisions was drawn tense, and would consequently flatten together the two sides of the canal beneath, while, with the base of the triangle toward the bladder, any force exerted in that direction would be uniform along the whole length of the canal, and must increase with the traction.

## CHAPTER XV.

### RECTO-VAGINAL FISTULÆ, RESULTING FROM PARTURITION.

Frequency of rectal fistulæ, generally smaller in comparison after contraction has taken place, than where the bladder has been involved. - Usual shape; cul-de-sac generally injured. The preparatory treatment more tedious in recto-vaginal fistula. Proportion of cases, in the same subject, where both the rectum and bladder have been injured. The vesico-vaginal fistula should be closed first. Operations on the rectal septum more difficult than on the opposite side of the vagina. Mode of operating. Detail of cases. Description of the operation after laceration of the perineum, when the same condition is produced by division of the parts for the closure of a small fistula situated immediately behind the sphincter muscle.

The occurrence of recto-vaginal fistulæ, in my experience, has been about six per cent. of all the cases which have passed under my observation.

As a rule, the opening left after the edges have fully contracted is much smaller than where the opposite side of the vagina has been involved. Not that the loss of tissue is usually less, but, from the greater mobility of the parts, contraction can take place to a greater extent, leaving the line of the opening, as a rule, transverse to the long axis of the vagina.

It is seldom that the cul-de-sac is left in its integrity, if the sloughing has been at all extensive, and it is generally obliterated to the cervix, while the latter frequently forms a portion of the boundary of the fistula.

In consequence of the greater amount of cicatricial tissue, these cases require usually a longer preparatory course of treatment than when the base of the bladder has been involved.



A little more than half of the cases which I have seen, where a rectal fistula existed, had also sustained a loss of some portion of the base of the bladder.

When both walls of the vagina have been injured, it is always better to close the vesical opening first, as the escape of urine over recently-united surfaces is far more irritating than the presence of feces would be.

It is an exception to the rule, when the edges of a rectal fistula, however small, can be brought together free from tension, without a division at some point of cicatricial tissue.

The execution of any operation on the posterior wall of the vagina, however simple, is, in comparison, far more difficult than on the opposite side. This is due to the limited means we yet possess of exposing properly the rectal septum, for the perineum can not be retracted without hiding to some extent, at least, the opening from view, by the instrument used.

The usual position is to place the patient on the back, with the knees well drawn up, or flexed on the abdomen, with a large size Sims' speculum introduced under the arch of the pubis, and the labia held open by an assistant on each side. In the greater number of cases, by this means, the fistula will be exposed, from the fact that, in consequence of contraction, the lower border of the opening is usually just beyond the sphincter muscle.

The same general rules already cited are equally as applicable to the closure of rectal fistulæ. The operator must decide in reference to the extent necessary, and as to the proper time at which the bands, if present, should be divided. If the cul-de-sac has been destroyed, and it is deemed necessary to open it up, for the purpose of relieving the edges of the fistula from tension, the use of the glass plug must be resorted to, and under the same circumstances as before referred to.

As a rule, it will be found that, in consequence of the greater amount of loose tissue, a far less extensive division of the soft parts will be needed, in comparison, to free a flap properly, than is the case on the opposite side of the vagina. This is due, also, to the fact that the cicatricial tissue is generally more superficial, but, if such is not the case, the bleeding, in comparison, will prove far more profuse, if so extended a dissection is attempted, as is necessary frequently, before closing a vesico-vaginal fistula, and it will be greater in the neighborhood of the sulcus on either side.

Under ordinary circumstances, however, the danger of hemorrhage is less, for after the vaginal surface has been divided by putting the parts on the stretch, it will require but little aid from the scissors to lacerate the tissues sufficiently. By laceration, the larger vessels are, to a great extent, not involved, while the knife must necessarily divide all lying in the course of the incision.

CASE LXVI. Eighth pregnancy; eighty-four hours in labor; delivery by forceps. A rectal fistula, crescentic in shape, with its cornua toward the cul-de-sac, and extending from half an inch beyond the fourchette to the cervix uteri. A vesico-vaginal fistula also existed, which was closed by one operation.

From traction, the edges gradually separated after the first operation for closing the rectal opening. After the second operation, a small opening remained; the third operation was successful.

Mrs. M., aged 38, came under my charge in October, 1863. She had married at 14, and had given birth to eight children.

Labor at full term commenced during the forenoon of Jan. 5, 1863. The pains were slight at first, but, for twenty-four hours, the progress of the labor was natural; gradually, however, they increased in frequency, and became violent in character. During the following two days, nothing was done, and for a greater part of the time she was unconscious.

About noon, on the 8th inst., a large anodyne was given, with the view of lessening the violence of the pains, but without any effect.

At 7 P. M., ergot was administered, with no effect in advancing the head, which had been low in the pelvis for some thirty-six hours.

By midnight, as she had become completely exhausted, a consultation was called, the forceps applied, and delivery accomplished of a large still-born male child. The placenta was not removed, and did not come away for three days.

She was unable to state at what time the membranes were ruptured, or if the bladder was emptied at all during the process of labor.

At the end of two weeks, a large slough was separated, with a number of small pieces during a week afterward. From this time there had been no control over the contents of either the bladder or rectum, but flatus had escaped by the vagina several days before.

*Pathological Condition.*—The vagina was found shortened from contraction of cicatricial tissue, which extended from near the outlet of the vagina on each side to the cul-de-sac. About a third of the lower portion of the vagina in front of the neck of the bladder had been lost; but, by contraction, the edges lay almost in contact, and extended in line across the vagina nearly from one ramus to the other.

The rectal opening was situated about half an inch from the fourchette, and in front of the cervix uteri; it was crescentic in shape, with its cornua in the direction of the cul-de-sac. In the centre, the edges were about three-quarters of an inch apart, and the opening large enough to introduce two fingers; but there had been evidently a great loss of tissue, from the fact that the edges were tense, and cicatricial in character.

Oct. 25. Closed the opening into the bladder with

eleven sutures. The difficulties of the case presented nothing different from what has already been detailed in the description of several operations in this neighborhood.

On the eighth day, the sutures were removed, and the operation proved successful.

Jan. 3, 1864. Closed the rectal opening. The edges of the fistula were simply scarified, but the surface was increased in width by extending it around on the vaginal surface, and brought together by nine interrupted sutures. Although it was recognized that a certain amount of tension was exerted on the posterior lip, from the cicatricial bands in the cul-de-sac, it was not deemed necessary to divide them. The cicatricial tissue extended from the cul-de-sac down the lateral wall of the vagina, somewhat forward of the anterior lip, therefore it was thought that the tension exerted could not be sufficient to endanger the integrity of the suture, after taking the precaution to make a broad line of scarification around the edges of the fistula.

On the eleventh day, the sutures were removed, and the edges were apparently united firmly. In a few days afterward, however, they gradually separated, and the original condition was reproduced.

As her general health had become somewhat impaired, the second operation was not undertaken until Jan. 11, 1864. The bands in the cul-de-sac were divided entirely across behind the cervix, and also on the lateral wall in front of the anterior edge of the fistula on each side. As the posterior lip was about half the thickness of the anterior one, it was split along its length, to compensate for this difference by presenting a broader surface. The edges were then brought together by eight sutures, and were apparently free from all tension.

The sutures were removed on the twelfth day. A few days afterward, flatus began to escape by the vagina. On

examination, a small opening was found in the extreme angle on the left side.

March 2. The posterior lip of the opening was split, while the anterior one, the thinner of the two, was denuded, but the surface was extended beyond to increase the width. Over this surface the split anterior lip was doubled, and secured by four sutures.

They were removed on the tenth day, and the patient returned home, cured, April 11.

CASE LXVII. First pregnancy; time of labor unknown; delivery by craniotomy. Transverse vesical fistula, with loss of the neck of the bladder. Closed by one operation.

A recto-vaginal fistula existed behind a fold of the posterior wall of the vagina, formed by contraction of cicatricial tissue around the outlet; this band could not be divided for the purpose of exposing the rectal opening, as its presence afforded a retentive power to the urethra. The cul-de-sac had been destroyed, with loss of the neck of the uterus.

The rectal fistula was successfully closed by one operation, performed almost entirely by the sense of touch, as the opening could not be brought into view.

Mrs. A., aged 23, came under my charge early in 1865. After a very severe and prolonged labor with her first child at full term, she had been delivered by craniotomy, about a year before my first examination.

Beyond these facts, I unfortunately neglected to preserve a more detailed account of her previous history, and only recorded her pathological condition and after-treatment.

It was found that she had lost the greater portion of the base, with the neck, of the bladder, but by contraction of cicatricial bands, extending the whole length of the vagina, the canal had become shortened, so that the two sides of the fistula lay almost in contact, at the bottom of a deep sulcus.

Just within the vagina, a superficial slough surrounded the outlet, so as to extend from across the urethra, downward and backward, while spreading out over the lower

portion of the rectal septum. By contraction of this surface, the lower part of the recto-vaginal septum was drawn forward into a large transverse fold, which almost closed the outlet of the vagina. Immediately behind this fold, in the axis of the vagina, an oval rectal fistula existed, about an inch and a half in length, and not more than an inch in width, with thin and tense edges. Its posterior border was occupied in part by the remains of the cervix uteri, as the cul-de-sac had been entirely destroyed, and the depth of the vagina terminated at this point.

When placed on the left side, by means of Sims' speculum this fold could be retracted sufficiently to expose the opening at the neck of the bladder, but it was impossible by any means to bring more than a portion of the posterior border of the rectal fistula into view.

I succeeded with but little difficulty in closing, by nine sutures, the vesical opening, after denuding the sides of the sulcus down to the edges of the fistula. When the line had been secured by the sutures, it extended nearly from one ramus across to the other. The sutures were removed on the ninth day, and the operation proved successful.

About six weeks afterward, on the 24th of March, 1865, with the assistance of my friend, Dr. John G. Perry, I proceeded to close the rectal fistula.

In consequence of the loss of the neck of the bladder by sloughing, I decided not to divide the bands which doubled the posterior wall on itself, for its presence across the urethra for nearly its whole extent, kept the sides of the canal, by its tension, flattened in close contact against the arch of the pubis, and was, in fact, the only retentive power. The presence of the fold, however, was a serious complication, and I anticipated a negative result from the operation for closing the rectal fistula, as the opening could not be brought fully into view.

The patient was placed on the back, near the edge of

the table, with her lower limbs well flexed, and ether was administered.

The first step was to open the cul-de-sac sufficiently to free the posterior edge of the fistula, so that it could then be drawn forward to the anterior border, which, under the circumstances of the fold in front, was immovable. The remains of the posterior lip of the uterus were seized with a tenaculum, and kept on the stretch, while held over the pubes by the hand of an assistant. The posterior edge of the fistula, near to the rectal surface, was then caught up by a tenaculum, and held with the thumb and forefinger of the left hand of the operator, while the third finger was passed into the rectum, and through the fistula as a guide, to judge of the advance made in freeing the posterior flap by scissors held in the other hand.

The vaginal surface was first snipped in line along the outer edge of the fistula, entirely across the vagina. While the lower flap was kept on the stretch by the tenaculum in the hand of the operator, and the upper one by the assistant, I was thus able, with the finger passed through the fistula from the rectum, to judge of any resisting point to be divided by the scissors.

I was able also to bring the parts in the centre partially in view, by depressing the fold with the shaft of the tenaculum held in the left hand. Fortunately there was but little bleeding, which was venous in character, and soon ceased.

At length the posterior edge of the fistula was freed sufficiently in the centre to draw it forward in contact with the anterior one, so that the line then became crescentic in shape, with the cornua toward the neck of the uterus. The posterior edge of the fistula was soon denuded with but little difficulty, as one portion after another could be brought fairly in view as the fold was depressed at any point.

The real difficulties of the operation were, however, now

experienced, for the whole anterior border had to be denuded without being able to see any portion of it whatever. I was guided entirely by the sense of touch. As a portion of tissue was caught up by the tenaculum held in the left hand, the third finger of the same hand was advanced just in front of the point of the scissors, as a guide, and also to enable me to judge of the amount of surface to be removed.

After this had been accomplished, thirteen sutures were introduced entirely by the sense of touch, and in such a manner that all converged toward the cervix uteri as a common centre. They were twisted, and the operation completed at the end of two hours and a half.

April 5. The sutures were removed, and the surfaces were found united. Shortly afterward, some flatus escaped by the vagina, but this ceased by contraction in a few days, and I have since been informed that the parts have maintained their integrity.

Although the operation would have been a difficult one under more favorable circumstances, the result was particularly gratifying from the fact that more than two-thirds of it had been accomplished entirely by the touch, and really so little aid had indeed been gained by being able to bring any given portion partially in view, that the whole operation could have been accomplished with but little more difficulty entirely in the dark by the same faculty.

CASE LXVIII. First pregnancy; in labor sixty-five hours, and delivered by the efforts of nature. A recto-vaginal fistula, in the median line, an inch in diameter, with thin and tense edges. Two parallel incisions were made in the axis of the vagina to free its edges. Closed by two operations.

There existed also a small vesico-vaginal fistula, which was not discovered until after the first operation for closing the rectal opening. When this had been closed, the second operation for the rectal fistula proved successful.

Mrs. B., aged 27, U. S., was admitted to the hospital from Meridian, N. Y., Feb. 2, 1864. She had married at



19, and had given birth to her first child about two years previous to admission.

Labor at full term began on Wednesday night, by a sudden rupture of the membranes. The labor soon became severe; a consultation was called, and she had four physicians in attendance until Saturday afternoon, when she was finally delivered by the efforts of nature, after having been in labor 65 hours.

According to her statement, the bladder was not emptied from bed-time on Wednesday night, until twenty-four hours after the termination of labor, when a catheter was introduced, from which time, for a while, she lost all control.

Gradually, however, after a few weeks, she regained the retentive power, and the urine ceased to pass by the vagina.

Two weeks after delivery, several large sloughs were thrown off from the vagina, when all control over the contents of the rectum was lost.

*Pathological Condition.*—A rectal fistula was found in the median line, about three-quarters of an inch beyond the fourchette. It was circular in shape, about an inch in diameter at the rectal surface, and with receding edges, which were thin and tense.

There had evidently been at some previous time inflammation of the pelvic cellular tissue. From this cause, with the presence of cicatricial tissue in the cul-de-sac, and along the lateral walls, the edges of the fistula could not be brought in apposition from any direction.

Feb. 12. Closed the fistula. Its boundary was much larger on a level with the vaginal surface, than on the rectal one, and, in fact, its outline could not be easily defined, as it became blended with a mass of superficial cicatricial tissue, extending on the vaginal surface along the sulcus on each side for nearly its whole length. To free the edges, it was necessary to make, through this cicatricial tissue, an incision in the axis of the vagina on each side between the

sulcus and the edge of the fistula. About the centre of the fistula, the edge was seized with a tenaculum, and while held on the stretch, the line was extended with scissors along the vaginal surface in either direction, until the flap could be drawn across to the opposite side. As soon as the cicatricial surface had been divided, and healthy tissue reached below, the parts yielded to quite a superficial incision, but in extent its length was nearly two inches. The bleeding was but slight, and soon ceased, except at the lower end of the lines, nearest to the outlet of the vagina; here, for a time, it was quite profuse, and delayed the operation.

While the edges of the fistula were being denuded, and the sutures introduced, an assistant made pressure on one side, where the oozing continued longer than on the other. A little cotton, saturated in a solution of alum, was laid in the incision at this point, and retained in place by the pressure of a sponge-probang in the hand of an assistant, above the pubes. The fistula was closed by nineteen sutures; so large a number was necessary, as the line had to be extended on the vaginal surface, more than half an inch beyond either extremity of the opening.

It should be noted also that the denuded surfaces brought together were, to a great extent, composed of vaginal tissue, as the edges proper of the fistula were too thin to have answered alone.

No anæsthetic was used, as a large dose of opium had been administered just previous to the operation, and it was thought that this would be sufficient; but, before the termination, she became much exhausted, and in an exceedingly nervous condition.

For a week or ten days afterward, there was a great deal of febrile irritation, which was entirely out of keeping with the usual condition following even a more extended operation.

About the fifth day, the case became also complicated by the free escape of urine from the vagina, a condition which was unexplainable at the time.

On the sixteenth day, the bowels were acted on by a saline cathartic, with the operation assisted beforehand by a warm enema of flax-seed tea.

On the next day, the sutures were removed; before doing so the line seemed perfectly united, but afterward, from tension, a portion separated about midway, leaving a small opening.

Behind the left ramus, a vesico-vaginal opening was discovered, nearly circular in shape, and large enough to admit a No. 12 bougie.

The perfect retention of urine, which had existed until after the cicatricial bands were divided, was due to the fact that so long as the whole remained intact, the sides of the fistula were kept in close proximity, but after a portion had been divided, so as to relieve the tension in one direction, the other portion, extending beyond on the lateral wall of the vagina, drew the sides apart.

March 9. Closed the vesico-vaginal fistula with eight sutures; they were removed on the ninth day, and the operation proved successful.

The general health having become somewhat impaired, it was decided to defer the final operation until she had regained her strength.

May 10. The rectal opening was found much enlarged, from the traction exerted by the tissue along the lateral wall, and sufficiently to admit the first joint of the index finger.

An incision was made on each side of the fistula, as in the previous operation, but not more than an inch and a quarter in length. This was sufficient to free all tension, so that its edges could be brought readily in contact. After denuding the edges, thirteen sutures were intro-

duced, and the opening closed along the previous line of union.

The sutures were removed on the tenth day; the operation proved successful, and she was discharged, cured, June 12, 1864.

**CASE LXIX.** First pregnancy; in labor about one hundred and forty hours; delivery by forceps. A small recto-vaginal fistula, about an inch from the fourchette, and to the left side of the vagina. In consequence of its shape and position, it was closed by dissecting off a flap from the lateral wall, which was folded down over the fistula, so that, when secured, the vaginal tissue had been turned into the rectum.

Mrs. V., aged 33, U. S., was admitted from Shelburne Falls, Mass., Nov. 13, 1862. She married at 27, and had given birth to one child, about three years previous to admission.

Labor at full term commenced during the afternoon of Saturday, Oct. 14, 1859. The pains were slight, until the next day, when the membranes ruptured. On Monday, the pains had become frequent, and a midwife was placed in charge. Chloroform was administered on Tuesday, and she was kept almost entirely under its influence until the following Friday, when a consultation was called, and she was delivered by forceps of a dead child.

Her impression was, that the bladder had not been emptied during the whole time of labor, but she was uncertain of the fact, and was unable to give a more detailed account of her case.

About three days after delivery, she noticed for the first time that feces passed from the vagina. No slough was thrown off, but the vaginal discharge was quite profuse, and of longer duration than usual. She suffered from great irritability of the bladder, and pains down both legs, for many months after delivery.

*Pathological Condition.*—A recto-vaginal fistula, in the shape of a half circle, was found on the left side, about an inch beyond the fourchette, and scarcely large enough to

admit the first joint of the index finger. Its boundary, from the vaginal surface, receded toward the rectal edge, while the cord of the arc formed by the lateral wall of the vagina was tense, as if from cicatricial tissue beneath. From its awkward shape, it was impossible to bring the edges in a continuous line together, from any direction.

Nov. 17. A flap of sufficient size, and of a proper shape, was dissected off from the lateral wall of the vagina, down to the level of the fistula. The receding edges of the opening were then denuded, together with a corresponding portion around the vaginal surface of the flap.

Nine sutures were introduced around the edge of the fistula, and at corresponding points through the border of the flap, so that when they were secured, the flap had been patched, as it were, over the fistula, with the vaginal surface turned into the rectum.

The operation was one easy of execution, and with but little bleeding; the only difficulty in the case consisted in passing the sutures in such a manner that, by converging toward a common centre at the base of the flap, no portion of either edge became drawn into a fold.

Nov. 25. The six sutures nearest the outlet of the vagina were removed, and on the 28th inst., the rest. The edges had united perfectly, and she was discharged, cured, Dec. 11, 1862.

*Remarks.*—A frequent seat of fistula through the rectal septum is immediately behind the sphincter, and, in fact, the anterior boundary of the opening is generally formed by the edge of the muscle. Although the opening is usually small, yet it is at this point, from action of the muscle, far more difficult to obtain a successful result than above, where a greater loss of tissue may have been sustained.

If the fistula is thus situated, and of a large size, it is frequently easy, by interrupted sutures introduced through

the vaginal tissue, to obtain union throughout the line without division of the sphincter. But when small, and in the median line, I usually divide the perineum and muscle entirely through with a pair of scissors, to the opening, and, after denuding its edges, bring the whole line together by deep interrupted silver sutures, as in the operation for lacerated perineum.

Formerly, after the operation for lacerated perineum, the occurrence of an opening in the angle, just beyond the muscle, was not an unusual result, while the perineum and sphincter had united perfectly. It was then customary, in following the practice of Dr. Sims, to always retain in the rectum a straight catheter tube, about four inches in length, with a view of allowing the flatus to have a free escape. When an opening then remained after an operation, it was considered due to the carelessness of the nurse in allowing the end of the tube to become obstructed by feces, or that the line of union in its integrity had been disturbed by the mode of introducing the instrument. I have since satisfied myself that the tube is unnecessary, with a great gain in comfort to the patient by dispensing with its use, and that the accident was due to the manner in which the sutures had been passed.

These lacerations had been closed by the use of a needle but little more than an inch in length, which necessitated the exit and second introduction in the neighborhood of the angle of the fissure. Therefore, at this point, less tissue could be included in the bound of the suture than elsewhere, and, with the swelling of the soft parts, which took place subsequently to a greater or less extent, the suture was drawn so far forward, by the increased tension, that in cutting clear of the angle, this point was left unsupported.

The lowest needle was also introduced, and passed around the denuded surfaces on the same level with the

rectal edge. The result was that when the other sutures were secured above, the tissues were crowded down in the direction of the least resistance, so that, by forcing this suture apart, a greater or less portion of the denuded surfaces became rolled out into the rectum. This not only increased the amount of tension at the angle, but also diminished the breadth of surface to be united.

I now use a hollow needle, awl-shaped, with a handle, and of a proper curve, through which the wire can be passed, so that a single sweep can be made entirely around the surfaces to be brought together; and, beyond the angle, more tissue can be included, if desirable, than at any other portion.

The point of the instrument is introduced nearly half an inch below, or farther back toward the coccyx, than in the usual mode of operating. The result is that when it is secured, a line of unscarified rectal surface is brought together, with the effect of crowding upward the denuded surfaces firmly together in contact throughout. As this is the longest, or outer one, it bears the brunt, as it were, for the protection of the other sutures, while, at the same time, from the additional breadth of surface brought in contact, the uniting edges above are protected from the danger of flatus escaping in this direction. Before this suture is twisted, however, all the others must be introduced. The first in order will be the one passed around the fissure on a level with its rectal edge, and another, just above, will be needed to include also the recto-vaginal septum. In addition, two more are introduced merely through one labium, and across on the same level in exit through the opposite one. When these five sutures have been twisted, the perineum and sphincter will be brought into perfect apposition, as well as the whole line along the rectal surface.

I have occasionally divided the perineum, where the fistula has been a large one, and extending down to the muscle; being guided by the shape of the angle of the

opening against the sphincter. When the sides lie nearly in contact, and terminate in an oblique angle, the probabilities are great that the line can be closed throughout by bringing the surfaces together in the usual method, as if situated elsewhere in the canal. On the contrary, if the sides are well separated at this point, so as to represent somewhat a triangle with the base along the edge of the muscle, an opening will almost certainly remain, if closed without dividing the perineum through in a continuous line. This shape is generally due to lateral tension exerted by a superficial cicatricial surface, which, as it were, glazes over the tissues at some distance from the edges of the opening; a sequæe sometimes of superficial sloughing, but generally a consequence of laceration of the perineum, which has not extended through the sphincter. The parts can be well freed by snipping through this surface with scissors in a continuous line, at some little distance outside of the edges of the opening, yet this is not sufficient of itself. The tissues are unyielding to a great extent, so that the edges cannot be freely rolled out, as can be readily done higher up in the canal. Moreover, it will be frequently found that the rectal surface has retracted so much, that the opening will be larger in the rectum, while, from the vagina, the edges of the fistula are apparently very thin, and therefore cannot be properly denuded.

After the perineum, however, has been divided, every portion of the edge of the fistula can be readily turned out by the tenaculum, and properly denuded to the rectal surface. A sufficient number of interrupted sutures are introduced until the muscle is reached. We then have a choice of two modes of procedure—either to continue throughout the line with interrupted sutures, so as to include the fibres of the muscle, until the external surface had been reached, or resort to the deep perineal sutures, introduced as already described. If the latter, the first



suture, or the one nearest to the coccyx, should be introduced, so as to pass between the second and third interrupted suture nearest to the edge of the sphincter, while the second one should pass between the first and second sutures of the series. I generally resort to the first method in fleshy subjects, from the fact that the interrupted sutures left within the canal prove a less source of irritation than when brought outside. Afterward, if necessary, for a proper support to the vagina and uterus, the perineum can be closed as in a case of simple laceration, not extending through the muscle.

The knees should be tied together, the diet regulated, and the bowels constipated with a moderate quantity of opium. Of course, previous to the operation, it is necessary that the bowels should be in a proper condition.

In consequence of the sympathetic irritation of the intestinal tract, with tympanitis, which frequently follows any operation about the female genital organs, I have been in the habit, for several years past, of using inspissated ox gall by the mouth for several days before the operation, then administering a dose of castor oil, and, a few hours before, a large enema of warm water with ox gall, given to the patient on the knees and elbows. After the operation for closing a recto-vaginal fistula, or laceration of the sphincter, the accumulation of flatus will frequently cause a failure, by its escape through into the vagina. If a patient has been properly prepared in this manner, she will be rendered more comfortable, and the bowels can remain constipated for two weeks or longer, if necessary, with no inconvenience.

The urine must be drawn regularly by a catheter, and with great care, for there will be no union, if it is allowed to flow over the edges.

The perineal sutures are to be removed on the sixth or seventh day, for, by this time, they have accomplished

their work; and with great comfort to the patient, by their removal, the risk of a labial abscess will be avoided, for even with great care, it is difficult to protect the projecting sutures from violence, so that they may not prove a source of irritation from this cause. They should be withdrawn by making traction on the suture, from the side on which the loop has been divided, so that it will continue to bind the parts until its exit.

The patient should be replaced in bed, with her knees still tied together, for several days longer.

From the tenth to the fourteenth day, the bowels may be acted on by a cathartic, and it is most important that the nurse, during the act of evacuation, should properly support the parts, between the grasp of the thumb and forefinger. The success of the operation will be aided by a few ounces of warm olive oil, or flax-seed tea, carefully thrown into the rectum, just previous to the passage. Have the patient carefully placed on the side, with her hips drawn to the edge of the bed, so that the nurse, while standing behind, can properly direct the nozzle of the syringe by elevating with one hand the buttock, and in such a manner, that the integrity of the recently-united surfaces is not endangered. With these precautions, and with a proper support of the parts, the surfaces will have united by this time sufficiently to sustain no injury from the action of the bowels.

I have occasionally pursued an opposite course, by the administration of a mild cathartic, to obtain daily a fluid evacuation of the bowels. It is unsafe, however, to follow a medium course; no accumulation must be allowed to take place, and only fluid stools, or the bowels must be kept constipated until the parts have properly united. I prefer the latter course, so long as there exists no indication to follow the opposite one, and have been more successful in the results obtained.

## CHAPTER XVI.

### VESICO AND RECTO-VAGINAL FISTULÆ NOT RESULTING FROM PARTURITION.

The effects of malignant disease; abscesses between the bladder and uterus, or in the broad ligaments; stone in the bladder, following the operation for vesico-vaginal fistula, and from paralysis, cutting through the vaginal septum; syphilitic abscesses and ulcerations, perforating the rectal septum, and injuring the urethra; Hodges' pessary ulcerating into the bladder; a fistula remaining after the passage of a pistol ball from the vagina through the base and fundus of the bladder. Absence of the anus, with the rectum opening into the vagina; operation. A patulous condition of the urethra sometimes found when the vagina and uterus are wanting.

In connection with the occurrence of vesico and recto-vaginal fistulæ, as a result of parturition, it will be of interest to refer briefly to a few cases, which have passed under my observation, where the injury had been sustained from other causes.

During the progress of malignant disease, the vesical septum, as well as the rectal one, frequently becomes perforated, but as the condition is not amenable to surgical means, we may dismiss its further consideration.

Abscesses about the uterus, while seeking an outlet in the direction of the vagina, frequently at the same time perforate the bladder. After the abscess has become emptied, and gradually contracted, the vesico-vaginal opening will require surgical interference for its closure.

\* Occasionally, as we have seen, the existence of calculi in the bladder will cause perforation of the septum. The formation has generally been subsequent to the operation for the closure of a fistula, through which means the

nucleus had been furnished, and frequently a pouch in which the stone at first became encysted.

A few months since, I was consulted in the case of a young lady from Norfolk, Va., where, after a fall, paralysis of the lower limbs resulted. Four months afterward, urine began to escape by the vagina, and in a few days, a sufficient number of calculi passed to fill a large-sized tumbler. I found on examination that the whole base of the bladder had been lost, as well as the urethra, the sub-pubic tissue up to the periosteum, and the vagina almost occluded. The occurrence of phosphatic urine doubtless furnished a nucleus for the calculi, and with the low grade of vitality resulting from the paralysis, sloughing followed as a result of pressure exerted by the foreign body. No attempt was made for her relief, as the paralysis had not yet disappeared, for had it been possible in her condition to have closed the opening, sloughing again would have followed in a few weeks.

Syphilitic abscesses and ulcerations frequently perforate the rectal septum low down near the vaginal outlet, but I have never seen a case extending into the bladder, except by loss of the urethra. In all such cases, which have passed under my observation, the injury sustained by the tissues have been most extensive. Although these cases can be greatly benefited, yet, from the condition of the soft parts, and especially of the rectum, I have never succeeded in preserving a union of the edges, even after the most careful constitutional treatment.

Pessaries occasionally ulcerate into the bladder, but rarely, if ever, into the rectum. A case of perforation of the base of the bladder will be presented as resulting from the use of Hodges' "horse-shoe" pessary.

The concluding case, under this division, will be one where the fistula resulted from a pistol ball, and of interest in connection with the cause of failure, after several attempts, to close the opening.

CASE LXX. An abscess between the bladder and uterus, which discharged by an outlet communicating with the bladder and vagina. The sinus from the vagina was laid open into the bladder and closed by one operation.

Mrs. A., of Wheatsport, N. Y., aged 36, consulted me in November, 1864. She had married at 18, given birth to ten children, and had always been in good health previous to the ninth pregnancy.

In November, 1862, she was delivered, after a labor of three days, having suffered exceedingly for several weeks previous, so as to necessitate the constant use of morphine. Shortly afterward, an abscess burst into the vagina, followed immediately by an involuntary escape of urine. She again became pregnant, and, nine months previous to coming under my case, she was delivered of her tenth child by a natural labor.

*Pathological Condition.*—From an opening into the vagina, situated about half an inch behind the neck of the bladder, the urine all escaped. A sound was passed along the sinus, until it reached the side of the uterus, when, after some manipulation, its point was passed into the bladder. The seat of the abscess could be still felt, but it had already contracted with but little discharge.

The point of a pair of scissors following a probe was introduced into the sinus, and its course divided up for some two inches, until the opening into the bladder had been reached. The edges of the opening into the bladder were then freshened, the tract of the sinus removed in one strip by scissors, and the whole line closed by eleven interrupted sutures. They were removed on the ninth day; the union was perfect, and she returned home shortly afterward.

Under other circumstances, to have closed the opening would have been at the risk of re-establishing the cystitis, but as the abscess had been kept emptied by the opening, situated at its most dependent point, and with but little or

no discharge which could still have an escape by the bladder, it was deemed unnecessary longer to delay its closure.

CASE LXXI. A vesico-vaginal fistula behind the left ramus, caused by pressure of a pessary, which had been worn for five years. Opening closed by one operation.

Miss M., aged 47, from Rush, N. Y., consulted me, May 19, 1866.

She came under the observation of Dr. Hammond, of her neighborhood, some two years before, in consequence of incontinence of urine, from which she had begun to suffer a short time previous. He removed from the vagina a corroded "horse shoe" pessary, one limb of which had entered the bladder. She had been ignorant of the fact that any instrument had ever been introduced, and had not been examined for over five years previous to its removal.

An attempt was made to close the opening by the use of caustic, but without success. He then operated, but with only partial success, and recommended her afterward to my charge.

*Pathological Condition.*—An opening, through which a No. 12 bougie could be easily passed, was found situated behind the left ramus at the bottom of the sulcus on that side formed between the lateral wall, and the base, of the bladder. The edges of the fistula were thin and tense, being formed entirely of cicatricial tissue, and to this condition the failure of the operation was doubtless due.

May 22. The opening was closed by nine sutures. As there was no prospect of obtaining union by bringing together the edges of the fistula, the vaginal surface on each side of the sulcus was scarified in either direction, at some distance from the opening, but as near the edge as possible, without including the cicatricial tissue. The surface, when thus denuded, represented a long oval, about an inch and a half in length, and less than an inch in width. As the sutures were twisted, a fold of the lateral wall was

doubled down over on to the base of the bladder, so as to enclose the fistula in a long pouch below.

June 1. Five sutures were removed, but the others were not, until June 9, as the tension exerted by bringing the surfaces together was sufficient to make it advisable that they should remain longer. June 12. She sat up, and on the 19th inst. returned home, cured.

CASE LXXII.\* Vesico-vaginal fistula, resulting from a pistol ball, which entered the thigh, and passed from the vagina, through the bladder and abdomen. No union after the first and second operations, from the occurrence of cystitis. Third operation successful.

Miss H., aged 25, was admitted to the Woman's Hospital, from Virginia, Dec. 18, 1866, with the following history. In March, 1865, while resisting the attempt of a soldier to buckle a holster of pistols around her waist, a navy revolver fell out, and on striking the floor, it was discharged, with the muzzle upward. As a number of persons were in the room at the time, she did not inform her friends that she had been injured, and the fact was not known, until she fainted from the loss of blood.

On examination, it was ascertained that the ball had entered the right thigh, and, passing into the body, was found lodged immediately under the skin on the left side, just above the crest of the ilium. She was confined to her bed for five weeks, during which time the track of the ball through the thigh healed, but with incontinence of urine remaining.

Several months afterward, Dr. Fisher, of Warrenton, Va., operated for the purpose of closing the vesico-vaginal fistula, but with only partial success.

*Pathological Condition.*—The point of entrance into the right thigh was about five inches below Poupart's ligament, and two inches outside of the femoral artery. The ball

---

\* Published in the the Richmond (Va.) *Medical Journal*, October, 1867.

had crossed the course of the artery, and entered the pelvis to the vagina, apparently through the thyroid foramen, thence obliquely into the bladder, perforating its base in the median line, about midway between the neck and cervix uteri. After examining carefully the bladder with a sound, quite a prominent fold or shelf was felt on its posterior wall, stretching across the cavity, just above the line of peritoneal reflexion from the bladder to the uterus. It was therefore evident that the ball had escaped from the bladder at this point, into the abdominal cavity, and, striking the uterus obliquely below the fundus, had glanced off nearly at a right angle, and, passing among the intestines, lodged under the skin, just below the crest of the ilium, on the left side.

The ball was conical in shape, and weighed half an ounce.

At the time of the accident, the bladder contained but a small quantity of urine; it was immediately emptied, and remaining in this condition, in consequence of the opening below, no urine escaped into the abdominal cavity. The point of exit was soon closed by adhesive inflammation, while the bladder was in a collapsed state, with one portion lying doubled on another at this point, thus forming the fold felt with the sound.

The fistula was nearly circular, and still large enough to admit the first joint of the index finger. Its edges were tense and formed of cicatricial tissue, extending to some distance from the opening.

On the day after her arrival, as she was in excellent condition, I operated, and was assisted by Dr. Fisher. There was no difficulty, the aid of an anæsthetic was not needed, and the opening was closed by nine interrupted silver sutures.

On the third day, the urine became phosphatic, and it was with great difficulty that the catheter could be kept



sufficiently free from the large quantity of mucus for the proper passage of the urine.

On the sixth day, the urine began to escape by the vagina, but only in a small quantity. The sutures were removed on the eighth day, and it was then found that no union had taken place, as the edges separated as soon as the sutures were withdrawn.

From the fact that the edges had been brought together readily without tension, the cause of failure was attributed to the long and tedious journey which she had taken just previous to the operation.

Dec. 26. The fistula was again closed at right angles to the long diameter of the vagina, by thirteen sutures, the patient being under the influence of ether. After the vomiting depending on the anæsthetic had ceased, she had not a bad symptom, and the urine all passed by the catheter.

On the ninth day, the speculum was introduced for the purpose of removing the sutures, but, as a slight moisture was noticed about the centre of the line of union, it was deemed advisable to allow them to remain a few days longer.

January 9. The sutures were removed, and apparently the operation had been successful.

Jan. 11. The use of the catheter was discontinued.

On the twelfth inst., she sat up, and had perfect control of the urine.

Jan. 15. After an examination, she was pronounced cured, and made her preparations to return home in a few days.

Shortly afterward, however, possibly in consequence of the last examination, the urine began to escape from the vagina; gradually the edges separated, and, in a few days, the parts were nearly in their original condition.

March 31. The previous operation was repeated, but

without an anæsthetic, and thirteen sutures were introduced.

A few days afterward, cystitis came on, as in the first instance.

The sutures were removed April 9, and, although but little had been gained by the operation, the opening gradually, by contraction, lessened to half its original size. It was now evident that the recurrent symptoms of cystitis were due to chronic inflammation of some portion of the bladder, which was quiescent so long as the urine had a free outlet for escape at the most dependent point; that with the cystitis, and from the cicatricial character of the tissue forming the edges of the opening, the cause of failure was evident. It was directed that the bladder, by means of a double catheter, should be carefully washed out several times a day, using a large quantity of warm water, until after the next period.

May 25. It was thought that her condition had improved sufficiently to justify another operation, which was performed with an anæsthetic in the following manner. A point, somewhat in advance of the old line of union, was seized with a tenaculum, and, with scissors, the cicatricial tissue was removed in a single piece, about three-quarters of an inch wide, so as to include the entire length of the vaginal fistula. The opening into the bladder was not enlarged, but as much of the tissue was removed as possible, without doing so.

A practical point was involved in not touching the mucous membrane of the bladder. Apart from the bleeding, as a complication, the membrane would have retracted from the edges when divided, and could not have been included with any certainty by the sutures, without passing them entirely through the tissues, with retraction of the lining membrane, so as to leave a denuded surface. A nucleus would thus have been furnished for the formation of a

calculus, with the risk, if the lesser evil did not present itself, of the bladder becoming so distended with a clot, as to render it necessary to remove the sutures, to arrest the bleeding.

As an additional precaution, to relieve all tension, the edge of the fistula on each side was put on the stretch by a tenaculum to be snipped with scissors, in a parallel line along the vaginal tissue, somewhat longer than the opening, and about an inch from its border.

Eleven interrupted silver sutures were introduced, farther back than usual from the edges, so as to include a fair portion of tissue, and the line, when secured, was about an inch and a half in length.

A smaller number of sutures were required in this operation, although the opening had been made larger. This was due to its oblong shape, which allowed its edges to close naturally together, while the former, being circular, could not have been closed without forming on the vaginal surface a puckering fold at each extremity. To obviate this condition, it was necessary to remove a portion of the vaginal tissue at some distance beyond each end, and to include the extended line in the sutures, until the fold was smoothed down to the general line of the vagina. Without an appreciation of this condition, an opening will frequently remain at each extremity of the line, the fistula having been only bridged over, as it were, in the middle. For this reason, it is often more difficult to close a small opening than a larger one.

The operation was finished in about three-quarters of an hour, and with but little bleeding, as the scissors had been used entirely.

After the bowels had been opened by a mild cathartic, the night before, the sutures were removed on the tenth day. Two days afterward she sat up, and returned home, cured, June 18.

Apart from the interest of this case, in connection with the literature of gun-shot wounds, it is an instructive one from the evident causes of failure, in an exceedingly simple case in other respects.

Seven months after her return home, I learned that she was about to be married, and perfectly well.

## CHAPTER XVII.

CONGENITAL ABSENCE OF THE ANUS, WITH THE RECTUM OPENING INTO THE VAGINA. PATULOUS CONDITION OF THE URETHRA, FOUND WHEN THE VAGINA AND UTERUS ARE WANTING.

Occasionally we find an absence of the anus, with an opening from the rectum into the vagina, just beyond the apparent posterior commissure of the canal.

I have met with two cases in the adult applying for the relief of vesico-vaginal fistula following childbirth. The opening into the bladder in each case was closed, but no attempt was made to relieve the rectal condition. On examination, in these cases, there seemed, from the thinness of the posterior edge, to be no remains of the sphincter muscle, therefore it was thought the formation of an artificial opening might result in even less retentive power.

Some three years ago, a child, about five years of age, came under my observation, where this condition existed, and I felt that the case was one where a favorable result might follow surgical interference. I punctured with a trocar, about a third of an inch in diameter, the posterior border of the opening into the vaginal canal, so as to enter the rectum at the point which should have been occupied by the anus. Into the wound a portion of block tin-tubing was inserted, and passing out of the vaginal opening, a half section of the two ends were flattened, and bent in contact, so that, by retaining the tube *in situ*, until the parts had healed, the diameter of the false passage would be maintained. The contents of the bowels were kept in

a fluid condition, and as the outlet into the vagina was only occupied by a portion of the tube bent over its edge, with the diameter of the tube itself unobstructed, a free escape was provided for. At the end of ten days, the tube was removed, and the mother was instructed to pass, daily, a bougie of a proper size through the false passage, to guard against any contraction. I have watched this case from time to time with great interest. At present there seems to exist certainly some sphincter power at this point, and, with a movement of the bowels, the contents pass by both openings, but in less quantity by the vaginal one, while the latter opening is smaller than it was formerly. I have advised no farther interference until puberty, at which time, with a proper development of the surrounding soft parts, I feel satisfied that the opening into the vagina may be safely closed. In addition, it may be advisable to operate as in a case where the perineum has been partially lacerated to the sphincter without involving the muscle itself.

I have never had an opportunity of demonstrating the condition, anatomically, but, in theory, it would seem that in the absence of the perineum, as the circle had not been completed, the undeveloped muscle, stretching from one side to the other, would form the posterior border of the opening into the vagina. Therefore, by establishing, at an early age, an artificial opening into the rectum between the fibres of the muscle, it is reasonable to suppose that some retentive power of the external sphincter might be gained.

In the adult, if the opportunity ever again presents itself, I will denude, from without inward, two parallel surfaces on the vaginal wall, to extend beyond the opening into the canal, until they can be run together. Then, by interrupted silver sutures, the vaginal surface can be folded up together, as in the operation practised by me, and already

referred to, for extending the urethra. This canal will prevent the feces from escaping into the vagina; by it a perineum will be formed, and, at the same time, if any fibres of the muscle be present, the circle of the external sphincter will be thus completed. Such an operation certainly can not impair the action of the internal sphincter, which is supposed to be present in its integrity, even if the fibres of the external one be absent, and if the new canal be extended, so as to equal the capacity of the outlet into the vagina, the danger of obstruction could be but slight. Certainly, if by this means the presence of feces in the vagina could be prevented, with no other advantage, the compensation thus gained would be great indeed.

In connection with this subject, and as a mere matter of curiosity, a somewhat similar condition of the urethra, existing in the absence of the uterus and vagina, may be briefly referred to.

In these cases, judging from the position of the clitoris, it would seem as if the vaginal portion of the urethra was absent to the neck of the bladder. Although a perfect retentive power of the urine exists, from a superabundance of cellular tissue, yet the entrance into the bladder is so patulous that the index finger can be introduced without difficulty, and the canal might be readily mistaken for the vaginal outlet.

Several years since I was consulted by a young married lady, who had never menstruated. She became engaged soon after the period of puberty, and, by the advice of her physician, she married, with his assurance that by this means the menstrual function would become established. She lived happily with her husband, but, as the prediction had not been verified, at the end of the second year of married life, she came under my observation. I found the vagina and uterus absent, with the dilated condition referred to of the outlet from the bladder. In connection, the

bladder had been entered, without either party having been aware of the malformation.

Some nine years ago, I saw a case with Dr. Sims, where a similar condition existed in an unmarried female. She had previously consulted a surgeon, in consequence of the absence of menstruation, who, unfortunately mistaking this outlet for the vaginal entrance, made several deep incisions, with incontinence of urine afterward. Nothing could be done for her relief, as it was impossible by any surgical means, in narrowing the passage, to imitate the natural folding together of the soft parts, by which a valve-like arrangement could be formed.

When on the subject of atresia, in connection with vesico-vaginal fistula, a paper on accidental and congenital atresia of the vagina, and published in the *Richmond (Va.) Medical Journal*, was referred to. In this article, a case is detailed, where, in the absence of the vagina and uterus, an artificial passage was established by lacerating the recto-vesical septum to an extent equal in depth and capacity to the vaginal canal. She had been engaged to be married for some time, and, from this fact, I was induced to operate, with the understanding that, as an experiment, marriage should not be thought of until a sufficient time had elapsed to judge of the result from contraction. At the end of seven months, I gave my consent to the marriage; when the case was reported a year after the operation, no change had taken place in the size of the artificial canal. Dr. Thomas F. Cock, of this city, assisted me at the operation, and examined the case afterward with me. Nearly two years have now elapsed since her marriage, and, although I have not examined her condition for a year, I am certain that no change has taken place, as she resides within twenty miles by railway of the city, and would have reported herself if there had been.

With the experience taught by the result of the oper-



ation in this case, an attempt to form an artificial vagina would be proper in the cases referred to, where the urethra was absent. In the case where incontinence of urine resulted from incising the bladder outlet, this operation would afford the only means by which she could have been relieved. In either case, by establishing an artificial vagina, a new urethra could then be formed afterward on the same principle as proposed for the canal on the other side, where the rectum entered the vagina. Thus the two conditions would be analogous, and by forming a urethra, the loose cellular tissue in the neighborhood of the neck of the bladder, on being thus confined, would naturally fold together, so as to form a valve, with retentive power of the urine, and act the part of the internal sphincter of the rectum, if no other power was gained by prolonging the canal.

## CHAPTER XVIII.

### UNCLASSIFIED CASES OF VESICO-VAGINAL FISTULA.

DEATH FROM PYÆMIA FOLLOWING AN OPERATION FOR VESICO-VAGINAL FISTULA.

DEATH FROM URÆMIA, AFTER ENLARGING, FOR THE RELIEF OF CYSTITIS, THE TRACT OF A PELVIC ABSCESS COMMUNICATING WITH THE BLADDER AND VAGINA.

ACCIDENTAL OPENING OF THE PERITONEAL CAVITY, DURING AN OPERATION FOR VESICO-VAGINAL FISTULA, WITHOUT ANY BAD CONSEQUENCES.

It had been a source of no little gratification to me that not a single death in my practice had ever followed any of the primary operations, or from the operation of vaginal fistula itself; and I might add that the experience of Dr. Sims had been similar to my own.

Within a few weeks, however, a death from pyæmia has followed an operation performed by me in a very simple case of vesico-vaginal fistula.

Death, as a consequence of this operation, is comparatively a rare accident, yet a sufficient number of cases have been already placed on record, for us to estimate its occurrence as one of the possible dangers.

To a most careful preparatory treatment in each individual case, with good ventilation, and proper nursing, I have attributed our success, and almost entire exemption from the many evil consequences which have so frequently followed the various operations about the female pelvis, in the hands of others.

With increased experience, the necessity becomes more apparent that, with even more care, the risk can be greatly

lessened, yet we cannot fully guard against accidental or endemic causes.

During the past winter, which was a long and cold one, with a very late and wet spring, there has been a more marked tendency to peritonitis and pyæmia, in both public and private practice, arising frequently from the most trivial exciting causes, than I have observed for fifteen years.

I am therefore disposed to attribute the death, in this instance, rather to an accidental cause, since the case was a most simple one and entirely uncomplicated.

CASE LXXIII. First pregnancy; delivery by craniotomy, after a labor of one hundred and three hours and a half. A small vesico-vaginal fistula existed about the centre of the base of the bladder. Peritonitis followed the operation. The use of catheter was discontinued after the second day, and the urine drawn at intervals. After the sutures were removed, the union was found perfect, and the bladder had full retentive power, until her death from pyæmia, six weeks after the operation.

Mrs. M., aged 27, a native of Wales, was admitted to the hospital, April 8, 1868, from Geneva, Wis. She had married at 23, and had given birth to one child two years previous to admission.

Labor at full term commenced about 6 P. M. on Wednesday. A physician was placed in charge, but nothing was done, as she stated, until the following Friday morning, when he ruptured the membranes, but no progress in the labor took place afterward. A consultation was called on Saturday evening, and an attempt made to apply the forceps, but without success; the effort was repeated on Sunday morning, but with the same result. Sunday night, craniotomy was performed, and the body of the child had to be dragged away by main force, the operation lasting from seven P. M. until half past one o'clock A. M.

The urine had not been passed during the whole time in labor, and she suffered greatly from distention. The bladder was emptied after delivery; but, as the soft parts

were much bruised, she soon became so swollen that retention again took place for a week. At the end of that time, urine began to escape by the vagina, which was followed by a profuse discharge, and the separation of a number of sloughs.

She was greatly prostrated for a long time after delivery, and was partially paralyzed for several months.

June, 1866. She was operated on by a skilful surgeon of Chicago, by whom the greater portion of the fistula was closed.

In July, the opening was again closed by the same gentleman, but great irritability of the bladder was produced by the use of the catheter, and no union was obtained.

The same operation was repeated during the following November, with apparent success at first, but the edges soon separated from the neglect of the nurse, as was stated, to draw the urine regularly.

The fistula was again closed by subsequent operations in February, June, and September, 1867, but in each instance the sutures all cut out.

On admission, her general condition was apparently good, although her complexion was exceedingly sallow, and she still complained of numbness in the toes of the right foot.

*Pathological Condition.*—A vesico-vaginal fistula was found situated in the median line, half way between the neck of the bladder and cervix. The opening was circular and about half an inch in diameter. A laceration of the anterior lip of the uterus had occurred in the median line, and had extended along the base of the bladder for some distance beyond the lower edge of the present opening.

May 1, 1868. The fistula was closed, without difficulty, by six interrupted sutures. The edges were removed, to some extent, as they were cicatricial, and a portion of the vaginal surface was included in the form of an ellipse.

After the sutures had been secured, the line was about an inch and a quarter in length, and extended in the direction of the vaginal axis. No anæsthetic was used.

May 3. Without any previous bad symptoms, the patient began to complain of pain in the back and hypogastrium, which was followed by a slight chill.

May 4. In the morning, with a high fever, her pulse was 120. Spinach vomiting and purging had supervened. Her countenance was pinched, and the tongue coated. She complained particularly of pain in the right iliac region, but the whole abdomen was tender, on pressure.

May 6. The vomiting and purging ceased, but she had become delirious, and, being very restless, the catheter was removed, and directions were given to draw the urine at regular intervals.

May 10. Her condition had much improved, and the pulse had fallen to 100 per minute. The bowels had not been moved for four days, and, although tympanitis existed, there was much less pain, on pressure, over the abdomen.

May 11. A relapse took place, with delirium, hot skin, and the pulse 135. At 7 P. M., the pulse was feeble, and reached 150 per minute; the tongue was dry, and delirium increased.

May 12. Her condition remained unchanged. The abdomen was more distended from flatus, but with little tenderness on pressure. The sutures were removed, and, notwithstanding the extreme illness of the patient, the edges were found perfectly united, the parts healthy in appearance, with no evidence of pelvic inflammation. The result was certainly remarkable, and one not to have been anticipated, for the catheter had been removed two days after the operation, and, with frequent vomiting, the patient had repeatedly been out of bed in consequence of the delirium.

After the more acute symptoms of peritonitis had subsided, pelvic cellulitis supervened, and, for several days, her death was expected at any moment.

May 28. The peritoneal cavity became distended with fluid. No albumen was found in the urine, and the kidneys continued to perform their function.

June 2 and 3. The patient had a number of copious watery discharges from the bowels, after which scarcely any fluid could be detected in the abdominal cavity. Her general condition did not, however, improve. The pulse continued to range from 120 to 140 per minute, and life was only prolonged by the closest watching and nursing.

June 6. Symptoms of pyæmia presented themselves. In consequence of difficulty of breathing, the chest was examined, and it was discovered that both lungs were compressed from the presence of fluid in the pleural cavity.

June 8. Detected a collection of pus among the muscles of the left forearm. The patient had become extremely emaciated, the countenance haggard, and a marked cadaverous smell emanated from the body, which could be detected in any part of the ward.

June 11. Pulse 160; abdomen enormously distended from flatus, with fluctuation detected low down, as if in the pelvis. The stomach had rejected everything since the day previous. The patient remained in a low delirium, and died at half past four P. M., forty-two days after the operation.

*Post-mortem Examination.*—On opening the abdomen, the peritoneal cavity was found distended with gas; it contained about six quarts of sero-purulent fluid, and the intestines were empty. The inflammation of the peritoneum had been general, but more recent in the pelvis. The uterus was found fixed from the surrounding inflam-

mation, but with no evidence of metritis. The pelvis of the right kidney, and its ureter, were somewhat enlarged. The liver was enlarged and fatty. An abscess was found in the spleen, and several in both lungs. There was some fluid in the pleural cavity, with a number of adhesions, which were not recent. The valves of the heart were normal, but its walls were unusually thin. The brain was not examined.

CASE LXXIV. Cystitis, resulting from cold of eighteen years' duration; followed by a pelvic abscess, which soon afterward opened into the vagina. Fifteen months previous to admission, incontinence of urine suddenly took place, with partial relief of the cystitis afterward.

The vesico-vaginal sinus was enlarged, so as to allow of the free escape of urine. Death from uræmia, forty-eight hours after the operation.

As the operation for the relief of cystitis, by producing a vesico-vaginal fistula, has been treated of at some length, and advocated as a proper procedure, the detail of the following case, with a fatal termination, will not be inapplicable.

In connection also with the history of Case LXX, where a similar pelvic abscess existed, communicating with the bladder and vagina, it will prove of double interest.

Without entering into a consideration of cause and effect, I still find myself no less an advocate for the operation, as being both a safe and justifiable one.

I have felt, however, that the case should be placed on record, although, with the result of the post-mortem examination, it can scarcely be claimed that the issue, as an effect, was more than a coincidence.

Mrs. S., aged 39, a native of England, was admitted to the hospital, from New London, Conn., June 22, 1868.

She menstruated at 15, and became regular from the first period. At 17 years of age, she arrested the menstrual flow by putting her feet into cold water, with no return for four years afterward. Since this time, she had never

more than a slight show at irregular intervals, with several years intervening.

She married at 21, but never conceived.

Shortly after marriage, she caught cold; this resulted in an attack of cystitis, from which she did not recover.

After suffering four years from cystitis, pelvic cellulitis supervened, with the formation of an abscess, which soon afterward opened into the vagina. She was confined to her bed for several months, and never regained her strength entirely afterward.

With no abatement in her suffering from the cystitis, the abscess refilled from time to time, and never entirely ceased to discharge.

Fifteen months previous to admission, suddenly, incontinence of urine occurred; the constant irritation of the bladder, which had existed for so many years, was at once lessened, but not completely removed.

June 23. She was placed under the influence of ether, as it was found impossible to make a proper examination, in consequence of her exceedingly nervous condition.

*Pathological Condition.*—From the vagina to the left, the remains of the old abscess could be distinctly felt, extending between the uterus and bladder, under the broad ligament toward the ovary on that side. The bladder was found contracted, and the uterus small and immovable.

The urine was all escaping, and it was at first thought that it passed by the urethra, which had become patulous from an extension of the chronic inflammation of the bladder. She was placed on the left side, but, on the introduction of a speculum, the point of escape was detected just in front of the neck of the uterus. The opening was large enough to admit readily a large-sized sound into the bladder. It was noticed, however, that, either in consequence of some valve-like arrangement of the tissues, or from the direction of the sinus itself, a half ounce or more



of urine would collect in the bladder before it was expelled ; this condition explained the fact why she had not been entirely relieved after the urine began to escape involuntarily.

It was found that the probe could not be passed from the bladder into the abscess, until its point had been nearly withdrawn. There was no communication between the two cavities, except just below the line of the vaginal septum.

One sound was introduced by the urethra into the bladder, and held by an assistant, while another was passed through the vesico-vaginal sinus. The two, on being brought together, as a guide, removed all doubt as to the fact that the bladder had been entered.

The blade of the ball-and-socket knife being set at a proper angle, was passed into the bladder along the sound, and on its withdrawal, the vesico-vaginal septum, from the sinus, was divided anteriorly in the median line, about three-quarters of an inch. The opening was barely large enough to admit the passage of the index finger.

The bladder was felt to be well contracted, with its walls thickened, and its mucous surface roughened, as if in a state of chronic ulceration.

She recovered readily from the effects of the ether, but with nausea, and in a feeble condition, with a more rapid pulse than was natural.

June 24. In the morning, she complained of much pain in the hypogastric region. Pulse 140, full and bounding. The skin was dry, but without fever. The tongue was moist and coated. There had been no chill, but constant nausea.

She was ordered the tincture of aconite, with milk and lime water. Later in the day, she was placed on quinia.

June 25. Pulse 140, but not so full. The tongue was dry, the abdomen was tender on pressure, but without

tympanitis. The nausea was still persistent, but without vomiting. A certain amount of urine was secreted, but it was impossible to judge, from the wet clothes, as to the quantity.

Warm fomentations were kept over the abdomen. She had a sub-cutaneous injection of morphine, and was placed on the free use of beef-tea and brandy.

She lay in bed with the knees flexed, and the muscles of the abdomen tense. She was drowsy, but easily roused, and free from delirium.

As the day advanced, she became more stupid; the respiration less frequent, and more labored; the pulse increased in frequency, and with less force.

About half past nine P. M., a quart or more of fluid was suddenly ejected from the stomach, and she sank immediately.

Death, fifty-five hours after the operation.

*Post-mortem Examination.*—On opening the abdomen, the existence of chronic tuberculous peritonitis was revealed, there being extensive effusion of lymph and pus throughout the cavity, with numerous old adhesions.

The diagnosis in regard to the position of the pelvic abscess, its size and relation to the bladder, was confirmed by the examination.

The left kidney was found enlarged, and in a state of fatty degeneration. Its pelvis was sufficiently dilated to contain three or four ounces of fluid, and the ureter on that side was dilated throughout its course, from the obstruction long exerted by the pelvic abscess below. The forefinger could be readily introduced into its cavity, at any point between the kidney and the seat of the abscess.

The right kidney was enlarged and lobulated; it had been entirely destroyed by tuberculous deposition, and had done no work for many years. It was with some difficulty

that the ureter on that side could be found, as it had almost entirely disappeared.

The liver was enlarged, and had undergone fatty degeneration.

Tubercles were found in both lungs.

The heart was enlarged and fatty, with a greater amount of fluid in the pericardium than natural.

The brain was not examined.

The kidneys were examined microscopically by Dr. Francis Delafield, who furnished the following statement:

“Of the two kidneys, the right one was the seat of very extensive tuberculous deposit, the tubercles having undergone cheesy degeneration. Scarcely a trace of the kidney structure remained. The pelvis of the other kidney was dilated, the epithelium of the calices and convolutions was in a state of fatty degeneration, and some of the Malpighian bodies were contracted and hard.”

The general appearance and condition of the patient promised little for the future, yet, as a palliative, from an operation which had never been followed by any constitutional trouble, in my hands, it was considered, under the circumstances, a proper one.

But if the condition of the kidneys could have been ascertained, the propriety of any surgical interference would have been questionable. For experience in general surgery has taught us that the state of these organs exerts a very important influence, on the result of a most trivial operation. Therefore, with the danger always to be feared that the inflammation from the bladder may have extended along the ureters to the kidneys, it is advisable that a careful microscopic examination of the urine should be made in every case of long-standing cystitis. An examination, under such circumstances, may frequently be of the utmost value, but, in the case under consideration, the appearance of neither the ureter nor kidney after death indi-

cated that their condition was otherwise than accidental in relation to the cystitis. The fact of fatty degeneration might have been pointed out, but without the means of estimating either the extent of disease in one kidney or the true condition of the other.

CASE LXXV. First pregnancy; one hundred and twelve hours in labor; instrumental delivery. Anterior wall of the vagina drawn into a fold in front of a small fistula, situated at the bottom of a cul-de-sac.

The neck of the uterus had been lost by sloughing, and the vagina terminated at the posterior edge of opening into the bladder.

During the operation for denuding the edges of the fistula, the peritoneal cavity was accidentally entered. This opening was closed in line with the edges of the fistula. No bad consequences supervened. Operation successful.

Mrs. M., aged 35, a native of Ireland, was admitted, Jan. 3, 1868, from Port Jervis, N. Y. Seven months previous to admission, she had given birth to her child, at eleven months after marriage.

Labor at full term began at 9 A. M. on Sunday, but the membranes did not rupture until Monday night at 10 P. M.

A physician was placed in charge of her case at the beginning, but no advance was made until Saturday, at 1 P. M., when a consultation was called, and delivery was accomplished, with much difficulty, by forceps, of a large child, still-born.

On the third day after delivery, she had a chill, followed by an attack of illness, from which she remained in a critical condition for a month. During this illness, the urine began to escape involuntarily, but she was unable to give any additional information in regard to her case.

*Pathological Condition.*—As in Case XVIII, Fig. 22, a fold of the anterior wall stretched across the axis of the vagina, behind, a small circular opening into the bladder was felt, but it could not be exposed, except by flattening, with difficulty, the fold in front, by the aid of the depressor, or by placing the patient on the knees and elbows.

The neck of the uterus and the cul-de-sac had been

destroyed by sloughing, so that the vaginal canal terminated immediately around the edges of the fistula.

At a third of an inch to the left, and a little posterior to the opening, a slight elevation was felt, which, from its greater hardness, in comparison with the surrounding tissue, was supposed to be the remains of the cervix uteri, but the os could not be detected. By a rectal examination, the uterus was felt to be retroverted and immovable to the left side, in consequence of a previous attack from pelvic cellulitis.

March 13. Closed the fistula tranverse to the axis of the vagina, using eight sutures. The operation had to be performed entirely on the hands and elbows, this being the only position in which the fistula could be fully exposed.

March 23. The sutures were removed. After the operation, she kept perfectly dry, the urine all passing by the catheter, but, on introducing the speculum, the vagina was found filled with bloody urine. From her nervousness, by rendering the proper introduction of the instrument impossible, the integrity of the line of union had been destroyed.

May 10. Second operation. It was found that the fistula had nearly closed, with the exception of a small opening at the end of the line toward the rectum. Its relative position to the supposed remains of the cervix uteri had, however, changed. At the previous operation, it was situated somewhat anterior to this point, but it was now found rather behind it, and as if on the posterior wall of the vagina.

She was placed on the knees and elbows, and the edges of the opening denuded, with a portion of the vaginal surface, in the form of an ellipse. The patient was nervous and very unruly. The scarification had to be extended beyond the opening for more than half an inch; the vaginal surface, at this point, resembling the termination of the cul-

de-sac, was a concavity, and it was necessary to include a certain amount of the vaginal tissue to avoid forming a fold at the end of the line.

While denuding the vaginal surface at the farthest angle, the patient gave a sudden start, as she had done frequently before during the operation, and a cavity was entered. It occurred to me that I had entered the upper portion of the vagina, and a sound was introduced, but, after passing it for several inches, I felt satisfied that the rectum had been opened. As the sound was withdrawn for the purpose of turning her on the back, for examination, flatus was heard, as it was supposed, escaping from the rectum. To my surprise, after introducing my finger into the rectum, I found that the peritoneal cavity had been opened, and I felt, by depressing the handle of the sound, its point against the abdominal wall above the pubes.

She was again placed on the knees and elbows, when, as soon as the speculum was introduced, the peritoneal cavity became distended with air from the first expiration of the lungs, while none escaped with inspiration. The upper portion of the vaginal canal soon became pressed down so near to the outlet, that I was enabled with great readiness to introduce, rapidly, eleven sutures, and close in the same line along the axis of the vagina, both openings. She was placed in bed after the operation, with serious apprehension for the result. Within a few hours, however, the distention disappeared without any bad consequence resulting, or the condition of the patient in any respect differing from that after an ordinary operation of the kind. The sutures were removed May 20, and, June 10, the case was discharged, cured.

I was assisted in the operation by Drs. Barrett and De Wolf, the house surgeons, and in the presence of Drs. Trask, of Astoria, Herrick, Carroll Lee, and other gentlemen from the city.

# INDEX.

---

- ABSCESS** between the bladder and uterus, 219, 238.  
    Opening into the vagina, 237, 238.  
    And ulcerations, syphilitic, effects of, 218.
- ANUS**, congenital absence of the, and operation for, 227.
- ATRESIA OF THE VAGINA**, 136, 230.
- BANDS** used to increase retentive power, 169, 178, 204.
- BLADDER**, fistula cured by turning the neck of the uterus into the, 77.  
    In loss of neck, importance of properly directing line of traction on closing fistula, 108.  
    Strangulation of inverted, 113.  
    Its condition after making new urethra, 187.  
    Vaginal surface turned into the, 106, 193.  
    Perforation of the base, caused by pressure of a horse-shoe pessary, 220.
- BLUNT HOOK**, 27.
- CALCULI**, frequent formation of, after operations about the cervix, 42.  
    Operation for removal of, 43.  
    Formation of, from retained urine, 190.  
        After paralysis, 218.
- CATHETER**, the sigmoid or self-retaining, 32.  
    Perforation of the bladder by, 32.
- CAUSTICS**, use of, for closing fistulæ, 97.
- CAUTERY**, use of, for closing fistulæ, 96.
- CELLULITIS, PELVIC**, following operation for vaginal atresia, 138, 153.
- CERVIX UTERI**, laceration of, complicating vesico-vaginal fistula, 39.  
    Cases narrated, 39, *et seq.*  
    Supposed cause of, 39.  
    Laceration of, with extensive loss of soft parts by sloughing, 60, *et seq.*  
    Sloughing of, with fistulæ involving upper portion of the vagina, 71, *et seq.*  
    Operation for turning the cervix into the bladder, 72, 77.

- CERVIX UTERI**, loss of, causing an early change of life, 135, 188.  
 Shut up in a pouch, 95.  
 Utero-vesical fistulæ, from laceration of, 51, 53.
- CHILD**, unusual size of, 40, 98, 118.  
 Passage of, through the recto-vaginal septum, 103.
- CICATRICAL TISSUE**, traction from, made use of, 101, 103.  
 Effect of labor upon, 154.  
 Result of pressure on, 119.
- BANDS**, resection of, 151.
- CONTINENCE OF URINE**, with partial loss of urethra, 107.
- CYSTITIS**, treatment of, 44, 188, 190.  
 Failure of operation for fistula, owing to, 223.  
 Operation for relief of, 237.  
 Importance of microscopic examination of the urine in cases of long standing, 241.
- CYSTOCELE** with Fistula, operation for, 164, 167.
- DELIVERY**, delay in, dangerous after impaction has taken place, 19.  
 Instrumental, not necessarily a cause of vesico-vaginal fistula, 19.
- DRESS** of the patient for operation, 33.
- "FEEDER,"** the, an instrument for aiding the introduction of sutures, devised by Dr. Sims, 30.
- FISTULA**, difficulties in closing a small one, 46.  
 Edge of, increased in width by splitting, 65, 129, 131, 202.
- FISTULÆ**, complicated, with laceration of the cervix uteri, 39, 45, 47, 48, 49, 51, 53, 54, 56, 57, 58.  
 Laceration of cervix, with extensive sloughing of soft parts, 60, 61, 62, 63, 66.  
**UTERO-VESICAL**, from laceration of cervix uteri, 51, 53.  
 Involving the upper portion of the vagina, with sloughing of the cervix uteri, 71, 72, 74, 76, 77, 80, 82, 83, 85.  
 Hidden by anterior or lateral folds, 61, 71, 72, 74, 76, 77, 80, 84, 85, 90, 120, 168, 169, 203.  
 Confined to the upper portion of base of bladder, 87, 88, 90, 91, 93, 94, 96.  
 With the cervix shut up in a pouch by efforts of nature, 95.  
 Involving the base of the bladder, 98, 104, 106, 109, 110, 113, 114, 117, 120, 122, 123, 126, 128, 130, 180, 191.  
 With occlusion of vagina, posterior to the opening, 134, 136, 143.  
 With partial occlusion of the vagina anterior to the opening into the bladder, 149, 151, 155, 156.



- FISTULÆ, situated immediately behind the rami, 158, 161, 162, 163, 220.  
 With cystocele, 163, 167, 186.  
 At the neck of the bladder, 136, 166, 168, 169, 171.  
 Involving the urethra, from laceration or sloughing, 174, 176, 180, 191.  
 RECTO-VAGINAL, resulting from parturition, 198.  
 VESICO AND RECTO, from various causes, 217.  
 Unclassified cases, 232.  
*And see Vesico-Vaginal Fistula.*
- FORCEPS, the needle, described, 29, 30.  
 For securing the suture in the silk loop, 30.  
 Twisting, 31.
- GRANULATION, less rapid after division of tissues with scissors than by the knife, 142.
- HEMORRHAGE, method of controlling, 22.  
 From vagina, checked by rectal plug, 137.  
 Sutures removed in consequence of, 153.
- INSTRUMENTAL DELIVERY, not necessarily a cause of vesico-vaginal fistula, 19.  
 INSTRUMENTS necessary for the operation, described, 24.
- KNIFE, ball-and-socket jointed, 28.  
 Use of, to be dispensed with, whenever possible, in all operation about the female pelvis, 142.
- LABOR PAINS, absence of, 143.
- LACERATION OF CERVIX UTERI, complicating cases of vesico-vaginal fistula, 39, *et seq.*  
 Of entire recto vaginal septum, and through the perineum, 103.
- MALIGNANT DISEASE, effect of, 216.
- MENSTRUAL FLOW, effect of its escape by the bladder, 53, 80.  
 Cessation of, after loss of the cervix uteri, 135, 188.  
 Retained, operation for, 140.
- NEEDLE FORCEPS, description of the, 29, 30.  
 Hollow, for closing lacerated perineum, 213.
- NEEDLES, size and shape best adapted for use, 29.  
 Mode of introduction in a confined space, 125, 160.
- OBSTETRICAL CLINIC, by Geo. T. Elliot, M. D., report of case from, 154.
- OCCCLUSION OF THE VAGINA, operation for, 137, 141.

- OPERATION for vesico-vaginal fistula, more certain of success than any other operation in surgery, 13.  
 Statistics of cases, 15.  
 Size, &c., of table used for, 33  
 Dress of patient for, 33.  
 Description of the, 33.  
 After-treatment, 37.  
 For recto-vaginal fistula, 205.  
 Primary, for freeing edges, 207.  
 For lacerated perineum, 212.  
 After-treatment, 215.  
 Failure of, for vesico-vaginal fistula, due to cystitis, 223.  
 Success of, due to careful preparatory treatment, 232.
- OS UTERI, utero-vesical fistula cured by closing the, 52.
- OX GALL, use of, 215.
- PARALYSIS after labor, 40, 121, 124.
- PARTURITION, recto-vaginal fistulæ resulting from, 198.
- PATIENT, dress and position of the, 33, 199.
- PELVIC CELLULITIS following operation for vaginal atresia, 138, 153.
- PERINEUM, operation for lacerated, 212.
- PERITONEAL CAVITY accidentally entered, without bad consequences, 242.
- PERITONITIS, case of, after operation for vesico-vaginal fistula, 79, 233.
- PISTOL-BALL, vesico-vaginal fistula resulting from wound by a, 221.
- PROLAPSE of the mucous membrane of the bladder through a lacerated urethra, 175.
- PYÆMIA, death from, following an operation, 236.
- RAMI, fistulæ situated immediately behind the, 158, *et seq.*
- RECTAL PLUG, vaginal hemorrhage checked by, 139.  
 TUBE, use of, 212.
- RECTO-VAGINAL FISTULÆ, description of, 198.  
 Statistical relation of, 198.  
 Preparatory treatment, 198.  
 Operation, 199, 205.  
 After operation, proper time of moving the bowels, and mode of doing so, 215.  
 After operation, careful use of catheter necessary, 215.  
 Resulting from parturition, 200, 203, 206, 210.  
 Not resulting from parturition, 217, *et seq.*  
 Congenital, 227.

- RECTO-VESICO-VAGINAL FISTULÆ, 199.
- RECTUM, vaginal surface turned into the, 211.  
Opening into the vagina, with congenital absence of the anus, 227.
- SCISSORS, to be used in preference to the knife, 23, 27, 66, 135, 142.  
Various kinds described, 28.
- SHIELD, Sims', described, 28.
- SILVER WIRE, kind and size required, 31, 32.
- SIMS' glass vaginal plug, 22.  
Speculum, 24.  
Tenaculum, 26.  
Needle-forceps, 29.  
"Feeder," 30.  
Shield and sponge-probang holders, 31.  
Sigmoid or self-retaining catheter, 32.  
Silver sutures in surgery, by, 35.
- SLOUGHING of the soft parts, with laceration of the cervix, 60, *et seq.*
- SPECULUM, Sims', 24.  
Self-retaining, 24.
- SPONGE-PROBANG HOLDERS, 31.  
TENTS, development of uterus by means of, 189.
- STATISTICS of operations, 15, *et seq.*
- STRANGULATION of inverted bladder, 113.
- SUTURES, simple interrupted the best, 35.  
Whip-stitch, 136.  
Method of introducing and securing, 30, 35.  
Removal of, 38, 216.  
Removed in consequence of hemorrhage, 153.  
Case of peculiar difficulty in passing, 175.
- SUTURE, retained in the cervical canal for eighteen months, 47.
- TAMPON around vaginal plug, method of introduction and removal, 23, 159.
- TENACULUM, Sims', described, 26.  
Perry's barb-pointed, 27.
- TRACTION, from cicatricial tissue, made use of, 101.
- TREATMENT, after reception of injury, 21.  
Preparatory, 23, 198.  
After operation, 37, 215.
- TWISTING FORCEPS, the, 31.
- URÆMIA, fatal case of, 237.
- URETER in the edge of fistula avoided, 65.

- URETHRA, continence gained with partial loss of, 107.  
 Impervious from sloughing, 68.  
 Fistulæ involving the, from laceration or sloughing, 174.  
 Formation of a new, by puncture, 179.  
     by plastic surgery, 180, 191.  
 Patulous condition of, when vagina and uterus are wanting, 229.  
 Laceration of, with prolapse of the mucous membrane of the bladder, 175.
- URINE, calculi formed from retained, 191.  
 Cause of failure frequently after operation for rectal fistula, 215.  
 Retention of, for eighteen days, 62.  
 Importance of microscopic examination of, in cases of long-standing cystitis, 241.
- UTERUS, development of, by means of sponge-tents, 189.  
 Absence of, 229.  
 Washing out cavity of, after operation, for retained menstruation, 140.  
     *And see Cervix Uteri.*
- VAGINA, fistulæ involving upper portion of the, 71, *et seq.*  
 Atresia of the, 136, 230.  
 Operation for occlusion, 137, 141.  
 Hemorrhage from, checked by rectal plug, 137.  
 Obstructed by band crossing the canal, 155.  
 Partial occlusion, 158.  
 Absence of the, 229, 230.
- VAGINAL GLASS PLUG, 22, 159.
- VESICO-VAGINAL FISTULA, defined, 19.  
     How caused, 19.  
     Early treatment, 21.  
     Preparatory operations, 22.  
     Operation, and after-treatment, 33, 38.  
     Description of cases, 39, *et seq.*  
     General success of the operation for, 32.  
     With congenital absence of the anus, 227.  
     *And see Fistulæ.*
- WIRE, SILVER, kind and size used, 31, 32.
- WHIP-STITCH SUTURE, 136.

















