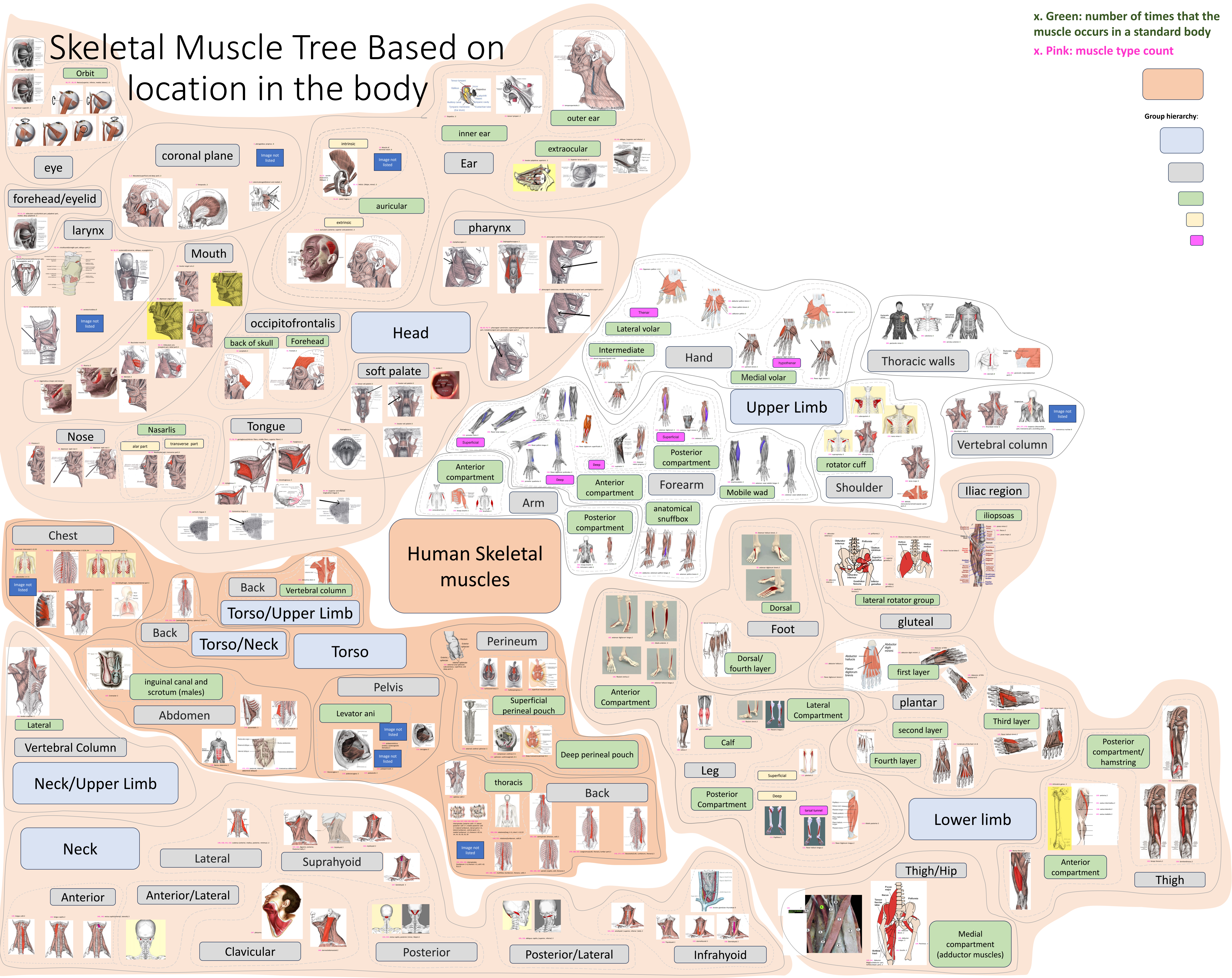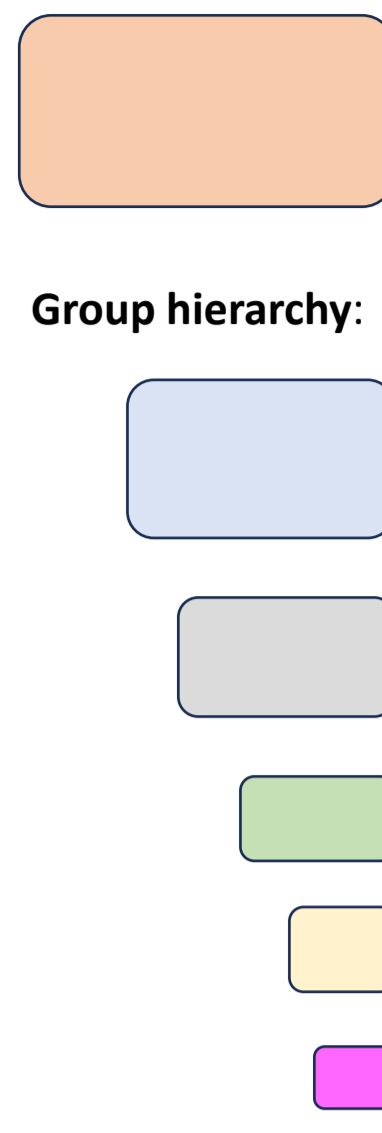


Skeletal Muscle Tree Based on location in the body

x. Green: number of times that the muscle occurs in a standard body
 x. Pink: muscle type count



Human Skeletal muscles

Head

- Orbit
- eye
- forehead/eyelid
- larynx
- Mouth
- occipitofrontalis
- back of skull
- Forehead
- soft palate
- Tongue
- Nose
- Nasalis
- alar part
- transverse part
- coronal plane
- intrinsic
- Image not listed
- auricular
- extrinsic

Torso/Upper Limb

- Chest
- Back
- Vertebral column
- Torso/Neck
- Torso
- Pelvis
- Levator ani
- Image not listed
- Image not listed
- Abdomen
- inguinal canal and scrotum (males)
- Lateral
- Vertebral Column
- Neck/Upper Limb
- Neck
- Lateral
- Suprahyoid
- Anterior
- Anterior/Lateral
- Clavicular
- Posterior
- Posterior/Lateral
- Infrahyoid

Upper Limb

- Hand
- Intermediate
- Lateral volar
- Therax
- hypothenar
- Medial volar
- rotator cuff
- Shoulder
- Forearm
- Anterior compartment
- Deep
- Superficial
- Posterior compartment
- Mobile wad
- anatomical snuffbox
- Anterior compartment
- Deep
- Superficial
- Posterior compartment
- Arm
- Anterior compartment
- Deep
- Superficial
- Posterior compartment

Lower limb

- Foot
- Dorsal
- Dorsal/fourth layer
- Anterior Compartment
- Calf
- Leg
- Posterior Compartment
- Superficial
- Deep
- lateral rotator group
- gluteal
- first layer
- plantar
- second layer
- Fourth layer
- Posterior compartment/hamstring
- Third layer
- Thigh
- Anterior compartment
- Medial compartment (adductor muscles)

Torso

- Thoracic walls
- Vertebral column
- Iliac region
- iliopsoas

Lower limb

- Thigh/Hip
- Medial compartment (adductor muscles)