

ar V  
17131

POST-MORTEM

EXAMINATIONS.



VIRCHOW

# ROBERTS' Practice of Medicine.

THE FIFTH ENLARGED EDITION. JUST READY.

*Recommended as a Text-book at University of Pennsylvania, Long Island College Hospital, Yale and Harvard Colleges, Bishop's College, Montreal, University of Michigan, and over twenty other Medical Schools.*

A HANDBOOK OF THE THEORY AND PRACTICE OF MEDICINE.

By FREDERICK T. ROBERTS, M.D., M.R.C.P., Professor of Materia Medica and Therapeutics and of Clinical Medicine in University College Hospital; Assistant Physician in Brompton Consumptive Hospital. The Fifth Edition, partially rewritten, and carefully revised throughout.

Price, in Cloth, \$3.00; Leather, \$6.00.

## RECOMMENDATIONS.

"I have examined it with much care, and find its arrangement simple, but systematic, and its treatment of subjects concise, but thorough."—*E. D. Hudson, Jr., M.D., Professor of Practice, Medical College of New York.*

"It is with great pleasure that I commend it to both students and practitioners, as a clear yet concise, scientific and practical work. It is a capital compendium of the classified knowledge of the subject."—*Professor J. Adams Allen, Rush Medical College, Chicago.*

"After due and careful examination and use, I have become thoroughly convinced of its great value, and have cordially recommended it to my class in Yale College."—*Professor David P. Smith.*

"I have examined it with some care, and think it a good book, and shall take pleasure in mentioning it among the works which may properly be put in the hands of students."—*A. B. Palmer, M.D., Professor of the Practice of Medicine, Ann Arbor University, Michigan.*

"I have never met with a work on Practice that seemed to me so well adapted for students. While concise, nothing is omitted that is important to be known."—*Professor J. A. Thacker, Cincinnati.*

"I shall include it among the text-books of the College of Physicians and Surgeons, and strongly recommend it to my classes."—*Professor John S. Lynch, Baltimore.*

"It is unsurpassed by any work that has fallen into our hands, as a compendium for students preparing for examination. It is thoroughly practical, and fully up to the times."—*The Clinic.*

"Our opinion of it is one of almost unqualified praise. The style is clear, and the amount of useful and, indeed, indispensable information which it contains is marvelous. We heartily recommend it to students, teachers, and practitioners."—*Boston Medical and Surgical Journal.*

"That Dr. Roberts' book is admirably fitted to supply the want of a good handbook of medicine, so much felt by every medical student, does not admit of a question."—*Students' Journal and Hospital Gazette.*

**P. BLAKISTON, SON & CO., Publishers and Booksellers,  
1012 WALNUT STREET, PHILADELPHIA.**

Cornell University Library  
arV17131

Post-mortem examinations,



3 1924 031 255 304  
olin,anx

---

THE FIFTH EDITION.

# Holden's Anatomy.

208 WOOD ENGRAVINGS.

A MANUAL OF THE DISSECTION OF THE HUMAN BODY. By LUTHER HOLDEN, M.D., Late President of the Royal College of Surgeons of England; Consulting Surgeon to St. Bartholomew's Hospital. Fifth Edition. Edited by JOHN LANGTON, M.D., F.R.C.S., Surgeon to, and Lecturer on Anatomy at, St. Bartholomew's Hospital; Member of the Board of Examiners, Royal College of Surgeons of England; With 208 fine Wood Engravings. Octavo. About 880 pages.

Bound in Cloth, \$5.00; Leather, \$6.00.

\* \* \* This new edition has been revised with the object of making it a more thorough text-book. Over one hundred pages new matter have been added, and many new illustrations, some of which are very finely engraved and printed. Notwithstanding these new features, the price of the book has been lowered.

---

## GILLIAM'S ESSENTIALS OF PATHOLOGY.

JUST PUBLISHED.

*The object of this book is to explain to the student, in a plain, practical way, the fundamentals of Pathology, as an introduction to larger books.*

THE ESSENTIALS OF PATHOLOGY. By D. TOD GILLIAM, M.D., Professor of Physiology, Starling Medical College, formerly Professor of General Pathology, Columbus Medical College, Columbus, Ohio. 12mo. 296 pages. 47 Illustrations.

Price, Cloth, \$2.00.

---

**P. BLAKISTON, SON & CO., Publishers and Booksellers,**  
1012 WALNUT STREET, PHILADELPHIA.

**METHOD OF PERFORMING POST-  
MORTEM EXAMINATIONS.**

**A NEW TEXT-BOOK.**

# MEDICAL JURISPRUDENCE

AND

## TOXICOLOGY.

By JOHN J. REESE, M. D.,

Professor of Medical Jurisprudence and Toxicology in the University of Pennsylvania; Vice-President of the Medical Jurisprudence Society of Philadelphia; Physician to St. Joseph's Hospital; Member of the College of Physicians of Philadelphia; Corresponding Member of the New York Medico-Legal Society.


**Demi-octavo. 606 Pages. Cloth, \$4; Leather, \$5.**

This book has been written to meet the want of a compact, practical Hand-book, a Text-book for the student, and a work of reference for the practitioner. The author is aware that the field has already been occupied by able and popular treatises on medical jurisprudence; but an experience of over twenty years as a public teacher of this branch of science has convinced him that students who desire to acquire a knowledge of medical jurisprudence, are too often deterred from their purpose by being confronted by the ponderous works of recognized masters, extending to three, and even six large octavo volumes. To avoid the above objection, he has endeavored to condense in a handy volume all the *essentials* of the science, presenting the topics in a readable and familiar style, giving greater prominence, of course, to those of the greatest practical importance.

The *N. Y. Medical Record* says:

“ Professor Reese is so well known as a skilled medical jurist, that his authorship of any work virtually guarantees the thoroughness and practical character of the latter. And such is the case in the book before us. A very extensive field is traveled over by one acquainted with all its parts, and all the main and essential landmarks are plainly pointed out to the reader. We might call these the essentials for the study of medical jurisprudence. The subject is skeletonized, condensed, and made thoroughly up to the wants of the general medical practitioner, and the requirements of prosecuting and defending attorneys. If any section deserves more distinction than any other, as to intrinsic excellence, it is that on toxicology. This part of the book comprises the best outline of the subject in a given space that can be found anywhere. As a whole, the work is everything it promises and more, and considering its size, condensation and practical character, it is by far the most useful one for ready reference that we have met with. It is well printed and neatly bound.”

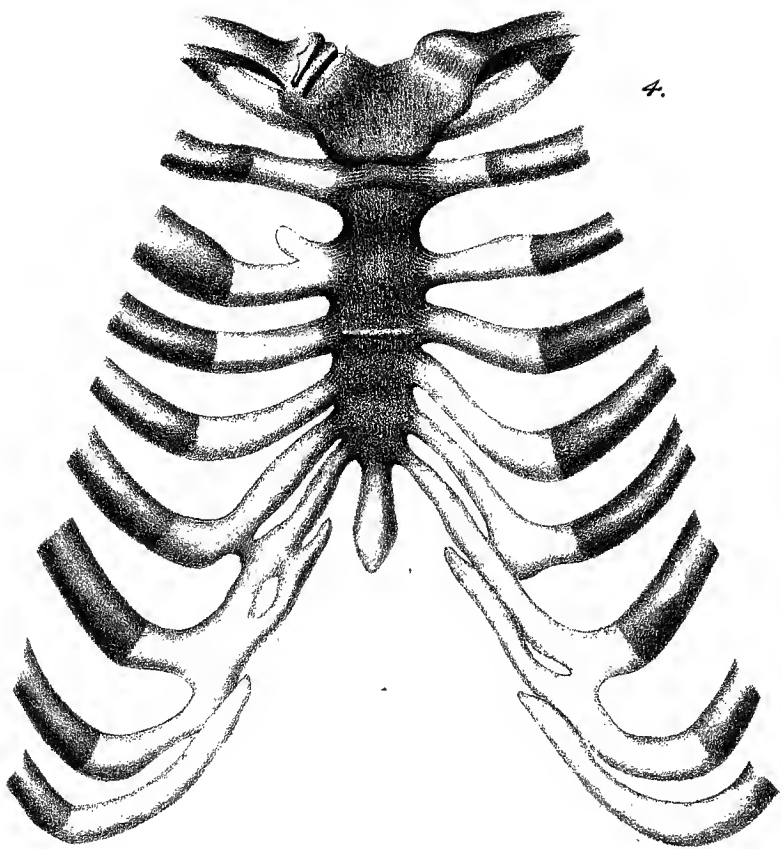
**P. BLAKISTON, SON & CO., Publishers, Philadelphia.**



Cornell University  
Library

The original of this book is in  
the Cornell University Library.

There are no known copyright restrictions in  
the United States on the use of the text.



4.



# POST-MORTEM EXAMINATIONS,

WITH

ESPECIAL REFERENCE TO MEDICO-LEGAL  
PRACTICE.

BY

PROFESSOR RUDOLPH VIRCHOW,

OF

*The Berlin Charitè Hospital.*

TRANSLATED BY

<sup>W. P. Smith</sup>  
T. P. SMITH, M. D.,

*Member Royal College of Surgeons of England.*

WITH ADDITIONAL NOTES AND NEW PLATES.


FROM

THE FOURTH GERMAN EDITION.

PHILADELPHIA:  
P. BLAKISTON, SON & CO.,  
1012 WALNUT STREET.

1885.





Copyrighted, 1885, by P. BLAKISTON, SON & Co.

## TRANSLATOR'S PREFACE.

---

IN the following paper Prof. Virchow gives some account of his early experience as Prosector in the dead-house of the Berlin Charité Hospital, and traces the subsequent development, under his auspices, of a systematic method of conducting post-mortem examinations. He also criticises, explains, and illustrates the regulations which have been promulgated throughout Germany for the guidance of medical jurists in performing autopsies and drawing up reports. (*Regulativ für das Verfahren der Gerichtsärzte bei den gerichtlichen Untersuchungen menschlicher Leichname. Herausgegeben von der Königl. wissenschaftlichen Deputation für das Medicinalwesen, 8, 1875.*) He also gives three interesting cases in which the post-mortem examinations were performed by himself, the order of sequence enjoined by the regulations being closely adhered to. An examination of these cases will show that nothing has been omitted which could throw any possible light on the cause of death. They may be

taken as examples of the way in which all post-mortem examinations for medico-legal purposes should be conducted. Lest the length of the notes should seem excessive, Prof. Virchow expressly states that three hours are sufficient, even for complicated cases. It will be obvious, on referring to the details, that only by following out a systematic plan could a thoroughly complete examination be performed in that time. Such an examination, however, would be infinitely more satisfactory than one in which important points were overlooked, and only discovered on subsequent investigation. It is much to be wished that a method similar to the one which has received the high sanction of Prof. Virchow were adopted in this country.

T. P. SMITH.

# CONTENTS.

	PAGE.
HISTORICAL INTRODUCTION . . . . .	9
AUTOPSIES FOR CLINICAL AND MEDICO-LEGAL PURPOSES . . . . .	11
THE REGULAR METHOD, AND DEVIATIONS IN INDIVIDUAL CASES . . . . .	15
RELATION OF THE SKULL-CAP TO THE DURA MATER. . . . .	15
ORDER OF SEQUENCE AND PLAN TO BE PURSUED . . . . .	16
POSITION OF THE DIAPHRAGM. . . . .	16
OPENING OF THE THORAX AND ABDOMEN . . . . .	17
COLOR OF THE PARTS, ESPECIALLY OF THE BLOOD . . . . .	20
FULLNESS OF THE VESSELS . . . . .	22
ABNORMAL CONTENTS OF THE CAVITIES . . . . .	25
EXAMINATION OF THE THORAX. . . . .	26
EXAMINATION OF THE ABDOMEN. . . . .	28
INTESTINES, LIVER, DUODENUM . . . . .	28
STOMACH, PANCREAS, URINARY AND GENERATIVE ORGANS . . . . .	31
THE METHOD OF MAKING PATHOLOGICAL INCISIONS. . . . .	33
INSTRUMENTS . . . . .	35
NUMBER OF INCISIONS. . . . .	40
PRESERVATION OF THE CONNECTIONS OF THE DIVIDED PORTIONS . . . . .	40
DISSECTION OF THE BRAIN. . . . .	42
DISSECTION OF THE HEART . . . . .	45
CASES AS EXAMPLES. . . . .	54
I. A MAN UNKNOWN. DEATH FROM SUFFOCATION, CAUSED BY PULMONARY HEMORRHAGE AND ŒDEMA. . . . .	55
II. A MAN KNOWN. GUNSHOT WOUND OF HEAD (SUICIDE). DEATH FROM PULMONARY ŒDEMA . . . . .	66
III. A MAN KNOWN. GUNSHOT WOUND OF CHEST (SUICIDE). DEATH FROM DOUBLE PLEURITIS, PERI- AND MYO-CARDITIS, PHLEGMONOUS MEDIASTINITIS, AND PERITONITIS . . . . .	82
IV. A TWIN CHILD, STILL-BORN, AT THE MIDDLE OF THE TENTH (LUNAR) MONTH. INDICATIONS OF IMMATURITY. ERYSIPELAS OF THE SCROTUM, PHARYNX, AND BRAIN. INCIPIENT WHITE HEFATIZATION OF THE LUNGS. . . . .	99

	PAGE.
METHOD OF OPENING THE THORAX . . . . .	112
INCISION THROUGH THE STERNO-CLAVICULAR JOINT, THE FIRST AND OTHER COSTAL CARTILAGES. . . . .	113
REGULATIONS (JANUARY 6, 1875, CONFIRMED FEBRUARY 13, 1875) FOR THE GUIDANCE OF MEDICAL JURISTS IN CONDUCTING POST-MORTEM EXAM- INATIONS FOR LEGAL PURPOSES . . . . .	115
I. GENERAL DIRECTIONS, §§ 1-8 . . . . .	115
II. PROCEEDINGS AT POST-MORTEM EXAMINATIONS, §§ 9-26 . . . . .	117
EXTERNAL EXAMINATIONS, § 13 . . . . .	119
INTERNAL EXAMINATIONS, §§ 14-22. . . . .	120
THE HEAD, §§ 15, 16 . . . . .	121
THE VERTEBRAL COLUMN, § 17. . . . .	122
THE NECK, THORAX, AND ABDOMEN, §§ 18-22 . . . . .	123
GENERAL DIRECTIONS, § 18 . . . . .	123
THE THORAX, § 19 . . . . .	124
THE NECK, § 20. . . . .	126
THE ABDOMEN, § 21. . . . .	127
CASES OF POISONING, § 22 . . . . .	130
NEW-BORN CHILDREN, §§ 23, 24 . . . . .	132
EXAMINATION OF OTHER PARTS, § 25 . . . . .	135
CLOSURE OF THE CAVITIES, § 26 . . . . .	135
III. DRAWING UP OF THE PROTOCOL AND REPORT OF THE EXAMINA- TION, §§ 27-31. . . . .	135

•

METHOD OF  
PERFORMING  
POST-MORTEM EXAMINATIONS.

---

ON taking up my appointment, in the year 1844, as assistant to Robert Froriep, the Prosector at the Charité, I found that the autopsies were at that time somewhat irregularly and unmethodically performed. The Prosector himself made but few examinations, and these only by special requisition; the greater number were performed, without any technical plan, by the Charité surgeons—young medical men, subsequently styled “assistants,” who had not yet passed the State examination. No minutes of the proceedings were made at the time, and only when the examination was over were notes taken down from memory. Froriep himself but very rarely gave a course on post-mortem examinations; he did so only once during my experience. Notwithstanding his eminent scientific attainments and his great manual dexterity (perhaps, indeed, on account of these his qualifications—at any rate, as a consequence of their limited practical employment), there was but little thoroughness in Froriep’s method; in many respects, indeed, it was so ill adapted for the purpose that it was a matter of difficulty to make any discoveries by its means.

Thus, to take only one example, it was his custom, when examining the spinal cord, to divide it longitudinally, from before or behind, by one long, straight

cut, and to dissect it in two equal lateral halves. This certainly made a very elegant section, and to do it properly required practice and care; but, however well it was performed, there were but very few cases in which it was of any use. The natural consequence was that Froriep's attention was directed principally to the membranes and roots of the nerves, and that the commonest and most important alterations in the white substance remained unnoticed.

I therefore had a double task to perform, especially after I became Prosector, in 1846. On the one hand, I aimed at causing the autopsies to be made by one person, at introducing a system of regular note-taking, and of collecting these notes, in order to obtain a useful series of reports. This was a matter of no great difficulty, after many startling incidents had shown how thoroughly erroneous were the results obtained in the absence of technical skill. It very soon happened that every clinical teacher and class director became interested in the fact that the post-mortem examinations were made by my hand. When, in the year 1849, I accepted the call to Würzburg, I left behind me a large collection of reliable reports. Unfortunately, only a few fragments of these were forthcoming when I was recalled to the Charité, in 1856.

On the other hand, it was necessary to discover a regular method for pathologico-anatomical investigation, and to introduce a definite employment of technical terms, which could be adhered to as a rule for all ordinary cases. Such a method I have perfected as years have rolled on, and it has now been sufficiently long in use for its value to have been tested by experience. It has naturally been formed into shape from a double point of view. The first requirement was that it should permit of the most complete insight possible into the extent of the alterations in every organ; and, in the second place, in order to provide for a distinct demon-



stration, adapted for educational purposes, such an arrangement was necessary as would cause the least possible disturbance in the connection of the parts examined. There were, therefore, these two problems, to some extent opposed to each other. They have, nevertheless, been solved in a satisfactory manner.

I have at present no intention of discussing this method in all its details. This has been done, to a certain extent, in the recent regulations drawn up for the guidance of the medical jurist when making autopsies for legal purposes, by the Royal Committee of Science for Medical Affairs, under date of January 6th of this year (1875), and confirmed by the Minister of the Ecclesiastical, Educational and Medical Departments, under date February 13th of the same year, and which are appended to this work.

It is true that these regulations do not correspond in all particulars with our system. This depends, in part, upon the difference in the nature of the tasks, which, for example, is very striking in every step of the external inspection, this latter being far more important for the medical jurist than for the pathological anatomist. Another point is that it has been thought expedient, in the deliberations of the Committee, to make certain alterations, which permit of a more simple and rapid manipulation of those organs which are less important for legal purposes. Taken as a whole, the regulations are invariably an expression of the knowledge, acquired through long experience, of the most suitable arrangements for conducting post-mortem examinations.

The necessity for superseding the old rules of November 15, 1858, had gradually become very urgent. Strictly speaking, these were already antiquated at the time of their issue. They had no sooner appeared than I pointed out their defects, and drew particular attention to the necessity of insisting—in autopsies for medico-legal purposes, as in everything else now—upon

completeness of examination and exactness of method, both in the investigation and in note-taking, so that it might be decided subsequently, though not in anticipation, whether there was any significance or importance in what was observed, or whether it was accidental and unessential (*Deutsche Klinik*, 1859, No. 2). There was, in truth, even at that time, no difference of opinion on these points. The regulations certainly continued in force for fifteen years; this, however, is accounted for, not merely by the legitimate bias of the authorities against too frequent changes, but still more so by the recognition of the fact that, before making demands which in no trifling degree exceeded the limits of that amount of technical medical training which had previously been deemed sufficient, it would be necessary first to train a larger number of well-educated medical jurists. This held good, not merely with regard to the microscopical examination necessary in so many cases, but even with reference to the ordinary anatomical technicalities of post-mortem examinations.

So long ago as 1859, I indicated in my lectures the direction which the change should take. I then stated as follows: "The present generation is conversant with pathological anatomy only as a supplement of the clinic. As a rule, the clinical teacher determined while the patient was alive which organ was to be the object of investigation; and the autopsy likewise was usually confined to that organ, or at least dealt with all the others only in a secondary manner. The clinical anamnesis, consequently, decided the course of the anatomical examination. We all know what was the result. The fact is, that we can further the advance of medical science in the most essential manner by acquiring the habit of submitting all the other organs of the body to a minute examination; for it is obvious that we can do as much by anatomical as by clinical examination." I ought, indeed, perhaps to have said that we have to do

more by anatomical than by clinical observation, for the one reason that the anatomical examination must be completed once for all, and does not admit of repetition ; whereas we can at the bedside, as a rule, return again and again to the same case, and if any omission has occurred in one examination, it can be remedied in the next or a subsequent one. But, irrespective of this, there is a great difference between being able to get directly at an internal organ and examine it in every particular, and having to content ourselves with following out and realizing certain symptoms.

Medico-legal technics—with all due deference to the independence of forensic medicine—will, however, always go hand in hand with pathological anatomy, for this latter is the more universal ; it has to deal with cases of all kinds, and for that reason is a great protection against that one-sidedness with which medico-legal practice is so much encumbered. As a matter of fact, it must be conceded that the great majority of medico-legal reports have exhibited such an astonishing sameness even in their phraseology ; such a very peculiar style, nowhere else to be found ; such a want of real objectivity, that it was an extremely tedious business to read through any number of them consecutively. There was such an amount of similarity among many of them that it might have been thought that they all referred to the same case.

The number of better educated physicians has gradually increased. The new examination for the North German Bund, and more recently for the German Empire, recognizes pathological anatomy as a special subject, and also tests the candidates in pathological histology. A more intimate knowledge of pathologico-anatomical technics and microscopical manipulation has been thereby introduced ; and it was therefore high time, considering that the examination rules of September 25th, 1869, had now been six years in force, to lay

down similar directions for the forensic examination, and afterward to institute regulations for conducting autopsies for medico-legal purposes. This has now been done, and it is to be hoped that the innovation will prove very beneficial, and promote the efficacy of the laws ; for a not insignificant portion of the administration of the criminal law is entirely dependent upon a correct and objective examination on the part of the medical jurist.

Experience, indeed, teaches us that the great majority of cases in which the Courts are compelled to appeal for advice to the Medical Colleges, and to the Committee of Science for Medical Affairs, refer to those autopsies in which either the examination or the note taking has been so irregularly performed that the nature of the case still remains ambiguous. It would, I am sure, be a matter of no difficulty to collect a great number of examples in which the faulty performance of the autopsy has rendered obscure cases in themselves clear and simple, and has made unintelligible those which are at all ambiguous. This observation explains the increasing number of the revision remarks which are so complained of by many of the physicians, and also the necessity for inserting many detailed directions—perfectly obvious, but not always attended to—in the regulations for the due performance of autopsies. The revision remarks having been brought to the cognizance of the State Attorney and the Court, the prosecution of an accused person can be resumed ; this, for a long time, had not been possible, owing to faulty examinations and the very arbitrary opinions expressed by those who performed them.

After such experiences—which, considering the evidence obtained in the medical examinations, with reference to the ordinary way in which cases are investigated and observed, may easily extend in various other directions—the practical necessity of laying down strict rules

appeared quite imperative. In like manner, there could be no doubt that, for educational purposes and for the majority of ordinary cases, a methodical procedure in post-mortem examinations presupposes the establishment of a definite plan.

It is scarcely necessary to point out that there are many cases in which deviations from this method are not merely allowable, but also absolutely necessary. The individuality of the case must often determine the plan of the examination. But we must not begin with individualizing, nor make a rule of the exceptions. The expert may allow himself to make alterations, supposing they are well grounded, but he must be able to remember his motive for so doing, and also to state it.

For this purpose, however, a full and intimate acquaintance with the reasons why the plan or rule has been laid down is quite imperative. The method should be practiced, not mechanically, but systematically, as it has for its basis well-weighed experience, and not mere casual observations. He who is conversant with these reasons will also be able to judge of their correctness, and of the occasions when a departure from the rule is indicated. Thus the rule will be that when the cranial cavity is opened, the exposed parts—viz., the dura mater, the great longitudinal sinus, the pia mater, the surface of the cerebral hemispheres—must be first examined, and described in succession. But if the dura mater is adherent to the skull cap, the best plan is to divide the former before forcibly detaching the latter, and to remove the skull cap with the dura mater adhering to it; for if long and violent attempts be made to separate the skull cap from the still closed and adherent dura mater, this latter usually gets torn, the brain itself crushed, and the parts so altered that sometimes their original condition is quite undiscoverable. In new-born infants and in children these parts are, as a rule, adherent; so that in these young subjects, if we

wish to avoid the risk of converting the brain into a mass of pulp, we must make an alteration in the method adapted for examining adult cases. But if these adhesions are found in adults as individual appearances in exceptional cases, we must also in such cases make an alteration in the method to be pursued.

In a systematic and scientific performance of an autopsy nothing is more difficult, and at the same time more important, than the insight into the reasons for pursuing a definite order of sequence in every detail of the examination. Let us therefore consider this point somewhat minutely. The course of the examination is generally dependent upon the order of succession. If for ordinary cases we require a definite process and a prescribed order, we do so not merely because such an arrangement is the surest guarantee for the completeness of the examination, and the best preventive against omitting important parts, but for the still greater reason that an unmethodical plan is the greatest possible obstacle to the subsequent collection of valuable reports. An unmethodical examination artificially and prematurely obliterates the existent condition of the parts.

Let us take a few examples. In many examinations the position of the diaphragm is of the greatest importance. This, generally speaking, cannot be determined if we open the thorax before the abdomen, or even at the same time; or if, after first opening the abdomen, we do not examine the diaphragm before opening the thorax. In former times, when the physicians allowed the assistants to make the post-mortem examinations, the custom was almost universal for a dissecting-room servant to open the thorax and abdomen before the arrival of the medical staff. The object was to save time and trouble. It soon became evident in forensic practice that such a proceeding as this made it impossible to define exactly the state of the thorax and its contents. In new-born children especially, it

is necessary to ascertain carefully the position of the diaphragm, because in them the main question hinges upon the establishment of respiration; and not merely this, but the extent to which respiration has been carried is the important point. On this account the direction was that the abdomen should be opened first. The regulation of 1858 was in this respect quite correct. Section 17, *a*, ran as follows: "After the abdomen has been opened, the position of the diaphragm is to be noted with reference to the corresponding ribs; and to ascertain this correctly in new-born children the abdomen should be opened first, and subsequently the thorax and head." Unfortunately, this very proper direction was made obscure by the words immediately preceding it. They ran thus: "The respiration test must now be commenced, and for this purpose, (*a*) after the abdomen has been opened," etc. This preface was altogether out of place, for we do not determine the position of the diaphragm with a view to the respiration test, but both are co-ordinate means for establishing the fact that respiration has been performed. Still worse, however, was the ambiguity involved in the choice of the expression "opening." Taken by itself the word is not synonymous with "dissection," but the medical jurists made use of "opening" in the sense of "dissection," and instead of opening and dissecting the thorax immediately after opening the abdomen and determining the position of the diaphragm, they finished the dissection of the abdomen before they even opened the thorax. Indeed, this bad practice was so universal that even when, as occasionally happened, a more enlightened physician examined the thorax first, and then dissected the abdomen, he was blamed for so doing by the medical boards, in their revision reports.

What, however, is the consequence of thus first dissecting the abdomen? I will assume that in the removal of the spleen, the stomach and the liver, the

diaphragm has not been cut, although this indeed frequently happens; but on cutting through the veins of the liver (in removing this organ), and on opening, as particularly directed, the inferior vena cava, it is impossible to prevent the blood escaping partially, or, if not coagulated, completely, from the right auricle, through the large venous trunks which have been opened. If, after this has been done, the thorax be examined, it is quite possible that the right auricle and the right side of the heart may be found collapsed and containing little or no blood, in cases where proper examination would have revealed an entirely opposite state of things. How often it happens that the report is, in consequence, very different from what it ought to be, and the opinion based thereon also falsified!

For this reason the new regulation directs, what I have for years taught, that, under all circumstances, the abdomen is to be first opened, but not dissected. It is only necessary in this stage to determine the position of the diaphragm, as well as that of the organs, any abnormal contents of the abdomen which may possibly be present, and the color of the parts exposed. Then the thorax is immediately to be examined, unless there is some cogent reason for departing from the rule. The suspicion of poisoning is always admitted to be a reason of this nature, as in this case the whole of the examination centres in the stomach; and every precaution must be taken to place it and its contents, without loss or change, at the disposal of the law.

The regulation that, as a rule, the dissection of the abdomen is to follow that of the thorax, but, on the other hand, that the abdomen is to be opened and its general state determined before the opening of the thorax, has necessitated, in the new regulations, the altering of certain directions referring to the minutes of examinations. It is to be hoped that medical jurists will readily familiarize themselves with these changes,



and it is not necessary further to allude to them. On the other hand, it appears to me that it is not superfluous to explain why it is that we ought to determine the general condition of the abdominal organs before opening the thorax. In reference to this, the new regulations order as follows, in Section 18, para. 2: "In addition to this, the position, color, and other appearances presented by the exposed intestines, and also the occurrence of any abnormal contents, are next to be specified, and the position of the diaphragm to be determined by examining it with the hand."

It is evident that the position of the abdominal viscera cannot be exactly determined after the thorax has been opened and the anterior attachments of the diaphragm, to a great extent, divided. The further the examination of the thorax proceeds, the more numerous the organs which are removed, and the more freely the connections between the diaphragm and parts of the thorax are divided, the looser does this muscle become, and the greater the displacement of the abdominal viscera toward the thoracic cavity. A further examination may reveal something previously unnoticed, and necessitating a comparison between the position of the abdominal viscera and injuries of the abdominal walls, and we may wish to examine thoroughly the relations to each other of two of the abdominal viscera; but the previous opening of the thorax will render all such attempts nugatory. I need only mention those by no means rare cases in which incipient peritonitis is discovered, and where it becomes necessary to ascertain whether the peritonitis was caused by injury or was due to a pathological process in any one of the abdominal viscera. In a case where the spot which exhibits the signs of a limited peritonitis is not exposed when the abdomen is opened, it will scarcely be possible to determine the causal connection if the position of the viscera has been much disturbed before the spot has been discovered.

With regard to the color of the abdominal viscera, it should be especially remembered that the color of many parts is entirely due to the blood, though there are not a few organs whose tissue has a distinct color of its own, entirely independent of the blood which they contain; they are colored by a specific color—a pigment. To the latter class belong the muscles, the pulp of the spleen, the liver, the testicles, the skin in part, and to a certain extent, also, the lungs. The color is then derived from two elements, the color of the blood and that of the tissue (parenchyma) combined, and the medical jurist should always be perfectly certain as to which of these elements, or whether both, are to be taken into consideration. It should also be remembered that in diseased conditions, there may be a third element, the presence of pathological coloring matters, such as pus, bile, extravasations, etc. It is highly important, therefore, to recognize the color caused by the *intra-vascular* blood, and in this connection it is to be remarked that the idea is still very prevalent that arterial blood, and even the arteries themselves, both in the dead body and in the living, may be distinguished by their deep red or bright-red color. This notion is founded on a primary error. Arterial blood in a dead body is always of a dusky-red color. This is just as true with regard to the blood of the pulmonary veins and left side of the heart as to that of the aorta and peripheral arteries. Any one who has carefully noticed the large arteries on the base of the brain, which, on account of their relatively free and superficial course, are very convenient for observation; any one who has been impressed with their bluish-red, thoroughly venous appearance; any one who has carefully observed in the left auricle the dusky-red blood which has just come from the lungs and just been aërated, and this in persons who have not died from suffocation, ought forever to be cured of the mistake of supposing that a dead body contains bright-red arterial blood. No

recently exposed portion of a dead body has a bright-red color; the lung certainly may form an exception to this statement, but only when filled with air, in which case, even after death, a certain quantity of oxygen may be absorbed. And even in the lung this is not usually the case to the extent supposed. In this organ the tissue containing the blood is full of alveoli containing air, and thus, as when froth is formed, a whitish color is produced, which, mixed with dusky-red, produces a bright-red shade. This is beautifully seen in the lungs of new-born children.

It follows, as a matter of course, and in individual cases it can be directly proved, that in no portion of the viscera of a dead body can arterial injection be recognized by the color test. Even when the arterial injection is very considerable, the color of the part may be just as bluish-red or blackish-red as in venous hyperæmia. Whoever wishes to assure himself on this point may do so by examining the kidneys, where, with the naked eye, or with a simple lens, he will easily see the Malpighian corpuscles, purely arterial structures, appearing as very dark red points or granules, in consequence of the fullness of their vessels.

After death, however, the blood does not lose its power of absorbing oxygen, and of thereby assuming an arterial appearance, *i. e.*, a deep-red color. This statement, indeed, must be taken with certain limitations, for there are some cases in which the blood, even before death, possesses a much diminished power of absorbing oxygen; and there are others in which it becomes so altered after death that its capacity in this respect is entirely lost. In both cases it is, however, arterial blood. On the other hand, even in ordinary cases, venous blood in the dead body possesses the power of absorbing oxygen. Thus it may happen that a part affected with venous hyperæmia becomes, when exposed to the air, after a time, deep red in color, and exhibits

the appearance of an arterial injection. Naturally, the change takes place much less readily and quickly in large and very full veins than in small ones; it is, therefore, of most frequent occurrence in the plexuses formed by the venous radicles.

What a great number of erroneous judgments have been due to want of knowledge of these very simple facts! How often has irritation or even inflammation been inferred, merely because of a deep-red color of the parts, or of a deep-red injection of the small vessels, whereas this coloration has really arisen in the course of the dissection! For the time usually required for the examination of the thoracic organs is amply sufficient for the change from dark red to bright red, to take place in those viscera of the abdomen which have been exposed. Hence the requirement in the Regulations that the color of the exposed portions of the abdomen is to be determined directly the cavity has been opened, that is, before the oxygen of the air that has gained access has had time to exert its influence.

As I have just touched upon this subject, I may say a few words more with reference to the much misused term, "fullness of the vessels." With regard to this, it appears to me important, considering the only too frequent incidents impressed on my memory, to lay great stress on the following points:

1. Capillary injection cannot be recognized as such, in a general way, with the naked eye. The finest vascular network which the naked eye is able to discriminate is either arterial or venous, and in the majority of cases, venous. This holds good especially of mucous membranes, in which the comparatively superficial position of the venous radicles very frequently causes them to be mistaken for capillaries. All capillaries are microscopic objects, and, when filled with blood, it is not red capillaries but red tissue which is observable. This redness really gleams out from the interior of the tissue,

and we can here, in a certain sense, justly say that the tissue is injected. Nowhere can this condition be so well observed as in the cerebral substance, especially in the soft, translucent gray matter. All shades, from the faintest reddish tinge up to a dark hydrangea red, are here met with; and, though single fine vessels filled with blood may be distinguished in the red spots, we can easily demonstrate that the color of the tissue is not due to these vessels. To this category belongs that peculiar mottled redness which is not unfrequently found in the white medullary substance, and in the optic thalamus and corpus striatum, and which is very similar to the first symptom of frost redness on the surface of the body. In my "Cellular Pathology" (fourth edition, page 107, Fig. 35), I have given an illustration of such a condition; it can easily be understood from this; only the few larger vessels which are shown in the drawing could with difficulty be made out with a lens; all the other vessels were only visible on careful examination with the microscope. It is, therefore, intelligible that to an expert there is something absurd in the expression "inflammatory hyperæmia" (occurring as it does in numerous reports), referring to anything which can be directly discovered with the naked eye. Nowhere is this expression more absurd than when it is used in reference to the stomach, as it can be proved, in the majority of the reports, that what the observer has noticed have only been veins.

2. The venous or arterial character of a vessel is never to be determined by the quality of the blood therein contained; but in all cases we must be guided only by its structure, its connections and its position. In other words, it is not to be discovered at the autopsy whether a vessel is an artery or a vein; but, with regard at least to all larger vessels, this ought to be known previously. It is true that it once occurred to me that a practicing physician who presented himself for examin-

ation was very much astonished when (in consequence of various wrong answers) I asked him a question as to the nature of some of the larger vessels of the brain. His answer was that he had not prepared himself on that subject, because he had not expected to be asked any questions, in this examination, in normal anatomy. However, I think I can maintain the proposition that inasmuch as without a correct knowledge of angiology, and even of the smaller vessels, the results of a medico-legal investigation may so easily be false, no one can possibly be a good medical jurist who is not thoroughly conversant with these matters. In referring especially to medical jurists, I do not, of course, mean to imply that such knowledge ought not to be possessed by ordinary physicians; but what I wish to express is that it is still more obligatory in the former class. In puzzling cases (which, I admit, do occur to the expert, and even to the anatomist) there is one plan which will be found to be of the greatest assistance, and that is to follow the course of the vessel until a point is reached where the size becomes a sufficient guide as to its nature, even to the less experienced observers; and particularly if in a membrane we meet with a smaller vessel filled with blood, we can, by displacing the blood, often succeed in ascertaining the course and connection of the vessel.

3. A statement with reference to the quantity of blood contained in a part can be regarded as approximately exact only when the description indicates not merely the kind of vessels in which the blood is contained, but also, to some extent, the degree of their fullness. By this I do not assert that we are able, without minute examination—which is not in all cases possible—to make such statements with regard to all parts; and with reference to many of them I confess that a general description of their appearance and color is all that is required. This holds good, for example, of the spleen, with regard to which no one, by simply looking

at the surface of a section, could properly estimate which of the small vessels were filled, and the extent of their fullness. But there are many parts of the body—and this refers especially to the mucous and serous membranes, consequently, to the majority of the internal surfaces—which can very easily be examined, and in which, in important cases, the attempt should always be made to ascertain positively the nature of the vessels concerned. It is certainly easier to pronounce an opinion than to give such a description; but the experience of the slight utility of such opinions has caused the Committee of Sciences to include the following direction in their new Regulations, section 28, para. 5:

“In all cases a statement must be given with reference to the amount of blood contained in each important part; and what is required is a terse description, not merely an opinion couched in such terms as ‘profuse,’ ‘moderate,’ ‘slight,’ ‘much reddened,’ ‘full of blood,’ ‘bloodless,’ etc.”

This explanation may suffice to illustrate the way in which statements should be made with reference to the color of the exposed abdominal viscera, and to what extent it is important that this should be determined immediately after the abdomen is opened. I will only make one more remark—that every manipulation of the intestines and other parts of the abdomen, by which their position is altered, their mutual pressure diminished or increased, or even any direct pressure with the hand, alters the amount of blood contained, and not only of this, but also of the gaseous, fluid, or more solid matter contained in separate portions of the intestines.

Still more important than the determination of the color is the immediate ascertaining of any foreign substance which the abdomen may happen to contain. If there be gas, it is very obvious that its existence can be generally proved only at the moment of opening the abdomen. If it be a liquid, there is the danger of

losing some of it unless it be collected at once. In every case, however, when the thorax is opened and its contents removed, it is almost impossible to prevent blood and other fluids from getting into the abdomen, and thus, when this latter cavity is examined, the appearances are obscured or directly falsified. The like holds good of those cases in which the subsequent examination has particularly to be directed, not to the thorax, but to single parts of the abdomen; for example, the stomach. It is extremely difficult, in removing and opening this organ, to avoid soiling the abdomen; and therefore, if the existence or non-existence of any anomalous contents has not been previously determined, it is scarcely possible to do this after the stomach has been interfered with.

I can be much more brief in my remarks with regard to the first portion of the examination of the thorax. Nevertheless, clear as the conditions are, I know from manifold experience how difficult it is to arrange a definite method of procedure. In explanation, I must first make the apparently paradoxical remark that "thorax," strictly speaking, is quite an abstract term. In reality, there is nothing which corresponds to it, except in the skeleton, or in a cadaver from which the viscera have been removed. In the living subject and in the ordinary condition of a dead body, there is not one, but several, thoracic cavities. For there are, in the first place, two quite separate pleural sacs, and therefore, also, pleural cavities; and, in the next place, a pericardium, and in it a pericardial cavity.

Therefore, in a dead body we never really open the "thoracic cavity," but rather, if in removing the breast bone we do not somewhat awkwardly cut and "open" the pericardium as well, the result is that when the sternum, together with the cartilages of the ribs, has been detached, we come on each side into a pleural cavity or space. The so-called mediastinum is no cavity



in this sense, but a septum filled with loose tissue, and it would be far more intelligible if we represented the mediastinum as a septum and did not speak of it as a space. As, therefore, in opening the thoracic cavity we really come into the pleural sacs, our duty is here, as in the abdomen, immediately to examine both these sacs, with regard to the position, color, etc., of their contents, and also to look very particularly for any possible foreign body which may be present. This examination is much more important here than in the abdomen, for it happens only too often that in cutting through the first rib and the sterno-clavicular articulation, as well as in the actual removal of the sternum, large veins (such as the internal mammary, the internal jugular, and the innominate) are pierced, cut, or torn, and fluid or coagulated blood escapes. In a short time this finds its way into one or even both of the pleural sacs, and no matter whether these previously contained anything or not, it is subsequently impossible to express a positive opinion, either as regards the quantity or the quality, or in many cases even to decide as to the pre-existence of any contents whatever. I need not explain how very important the demonstration of any anomalous contents in one or both pleural sacs may be in helping us to form an opinion with regard to a case, and I therefore think that it is certainly proper always to commence the examination of the thoracic cavity by ascertaining the condition of the pleural sacs, and to leave the lungs and the pericardium for subsequent observation. For he who would open the pericardium and dissect the heart before determining whether hæmatothorax or hydrothorax or pleuritis be present, is a man who ought not undertake a post-mortem examination at all.

But it is just as evident that the lungs ought not to be removed from the thorax before the heart has been examined, for this cannot be done without separating the pulmonary artery and veins. Unless ligatures are pre-

viously applied to these vessels—and it is neither customary nor needful to do so—their division will be immediately followed by the escape of a certain amount of the contents of the left auricle, of the trunk of the pulmonary artery, and of the right ventricle; and just the same thing happens as when we remove the liver and open the inferior vena cava before opening the thorax—viz., a diminution in the quantity of blood contained, or else a complete emptying of important parts of the heart.

Reflections such as these very naturally, and for certainly sufficient reasons, lead to the formation of a definite plan of examination of the parts, which is in no way dependent upon personal caprice or considerations of convenience, but follows necessarily from the nature of the thing itself.

I do not here intend to offer any exhaustive exposition of the reasons why I adopt precisely that order of sequence of which the Regulations are the authoritative expression. I may venture to give, however, a few more explanations with regard to the order of sequence which is directed to be observed in examining the organs of the abdomen.

*a.* For cleanliness' sake I examine the intestines last. To deal with the contents of the intestines is, in itself, a very disagreeable matter. Even with the greatest care, one can scarcely avoid soiling one's self, the instruments and receptacles, the subject, and the table on which it lies. I will say nothing about the sense of smell, though it is a great puzzle to me how it is that some persons, when making autopsies, seem to have completely lost this sense. There is no possible disadvantage in examining, as a rule, the intestines last; for all the other parts can be conveniently examined, removed and dealt with, without the intestines being interfered with. If, however, any one attaches less importance to cleanliness; if, perhaps, the physician is

in a great hurry, and wishes especially to see the intestines examined; there is no technical reason why this should not be done before meddling with the other viscera, for the intestines also can be removed without injuring the other parts. There is an exception in the case of the duodenum, inasmuch as the excretory ducts of the liver and pancreas open into it, and its removal is impossible without cutting through these ducts and even a portion of the pancreas.

*b.* The order of sequence which I adopt differs in one main point from that which was previously and formerly almost universally employed, inasmuch as I usually make the removal of the liver the last part but one of the examination. I am well aware that in so doing I depart essentially from the favorite custom. If the dissector places himself, as he usually does, on the right side of the body, having the head to his left, the liver is so immediately in front of his hand that it undoubtedly requires a sort of resignation to make up one's mind to leave it alone. But, irrespective of what I have already enlarged upon (that in the removal of the liver the large veins are injured, and for the most part, the diaphragm as well), there is also this to be considered; that the hepato-duodenal ligament (the small omentum), and the tubes therein contained, especially the vena portæ and gall duct, are injured more considerably and to greater disadvantage. I confess that these two last-mentioned structures are, in the great majority of cases, of no importance to the medical jurist, and if the order of sequence necessary for a clinical case were to be enjoined on him, it might certainly appear superfluous. On the other hand, however, it will be no disadvantage to him, and it will involve neither more time nor more trouble, whether he examines the liver first, or last but one; and even granting that the cases are but few in which the more correct method is requisite for the medico-legal investigation, this is quite a

sufficient ground for requiring it to be universally adopted. For clinical investigation, the preservation of the hepato-duodenal ligament is of the greatest importance, because, if once divided, it is a mere chance if we succeed in replacing the parts in their natural position in such a way as to be able positively to elucidate their condition. It is here, however, that we have to look for thrombosis and obliterations of the vena portæ, and to estimate the condition, as regards perviousness, of the ductus communis choledochus, particularly of its intestinal portion, and also of the cystic and hepatic ducts. I may refer to a former paper of mine on these subjects. In my *Archives*, 1865, vol. xxxii., page 117, I have discussed the various conditions of the ductus communis choledochus and its intestinal portion, and have alluded to the importance of these for explaining the origination of jaundice; and in the *Transactions of the Würzburg Physico-Medical Society*, 1857, vol. vii., page 21, and in my "Gessammelten Abhandlungen," page 620, I have treated of obstructions of the vena portæ. The nature of the circumstances necessitates the following order of sequence in examining these parts. First we should open the duodenum, taking care to do so *in situ*; then determine its contents above and below the papilla biliaria; then this papilla should be examined and its contents gently pressed out; then, by pressing on the gall bladder, we should determine the presence or absence of obstacles to the flow of bile; and lastly, the ductus communis choledochus should be slit up. Then the vena cava should be examined; and all this having been done, the liver should be removed. It is quite useless to pass a probe along the gall duct, for our being able to introduce a probe into the orifice is no evidence whatever that the portio intestinalis was pervious during life. It should be especially remarked that both before and during the time when the duodenum is ex-

amined, especial care should be taken that no rupture be caused. In order to expose the duodenum it is only necessary to separate and lay back the hepatic flexure of the colon. This is best done by freeing the whole ascending colon and cæcum by an incision outwards and to the right, so that it may be drawn out of the abdominal cavity, with the small intestine, on the left side. None of these parts need be freed from their mesenteric attachments; it is only necessary to cut through the retro-peritoneal tissues on the right side, in order to render possible the removal of the ascending colon on the left. It should be remembered that pathological adhesions are frequent in the region of the hepatic flexure, especially with the gall-bladder, the hepato-duodenal ligament, the liver, the colon, the duodenum and even the pylorus, which should be very carefully severed in order to prevent wounding of the hepato-duodenal ligament and the vessels contained therein.

*c.* The examination and opening of the stomach are closely connected with the above-mentioned operations. The simplest plan is to open the stomach at the same time as the duodenum, by continuing the incision; and this should, as a rule, be done *in situ*. Cases of poisoning, especially those which come under legal investigation, may require a different course. In other cases there is no danger in allowing the stomach to remain untouched until its turn comes. The spleen, the only organ closely connected with it, may, with moderate care, be so easily separated that there is no fear of causing damage. On the other hand, as is easily intelligible, the examination of the pancreas will follow that of the stomach and duodenum. The slight importance of this organ, in a pathologico-anatomical point of view, causes its examination to be of little consequence.

*d.* All the urinary organs should, as a matter of course,

be examined one after the other. We take them, therefore, in this sequence—the kidneys, the ureters, the urinary bladder, and the urethra. At all events, their condition will in this way be much more attentively examined than if some other object of an entirely different nature be allowed to intrude itself while the examination is going on. It is also perfectly evident that the supra-renal capsules and the generative organs must be examined in connection with the urinary organs. They are immediately connected, inasmuch as portions of the generative organs are portions also of the urinary organs; so that for the sake of continuity of plan, and also for convenience in the removal of the parts, the examination of the generative and of the urinary organs should be performed at one and the same time.

The order, therefore, which I adopt in examining the abdominal organs is as follows:—

1. The omentum.
2. The spleen.
3. The left kidney, supra-renal capsule, and ureter.
4. The right kidney, supra-renal capsule, and ureter.
5. The bladder, prostate gland, vesiculæ seminales, urethra.
6. (a) Testicles, spermatic cord, and penis.  
(b) Vagina, uterus, Fallopian tubes, ovaries, parametria.
7. The rectum.
8. The duodenum, portio intestinalis of the ductus communis choledochus.
9. Stomach.
10. Hepato-duodenal ligament, gall ducts, vena portæ, gall bladder, liver.

11. Pancreas, coeliac (semi-lunar) ganglia.
12. Mesentery, with its glands, vessels, etc.
13. Small and large intestine.
14. Retro-peritoneal lymphatic glands, receptaculum chyli, aorta, vena cava inferior.

However useful and convenient it may be to keep to such a regular plan, it is impracticable in a small number of cases, in which considerable changes have taken place in the relations and connections of the parts. Chronic adhesive peritonitis, whether occurring *per se*, in a simple, tuberculous, cancerous, or other form, or connected with tumors (*e. g.* ovarian), or with aneurism of the abdominal aorta, usually makes it impossible to dispense with the considerations peculiar to the case, and to adopt any general rule. Even in such cases it will be advisable to complete in the usual way the examination of those organs which can be easily reached, and thus to lessen gradually the special alterations which are requisite. But a departure from the rule is finally requisite, because it is, generally speaking, most convenient to remove together the remainder of the organs, and to examine them more particularly outside the body, in whatever way is the easiest.

So much with regard to the order of sequence in which the organs are to be examined, and the method of dissection.

The answer to the question, how to make incisions, belongs to quite another side of the subject. What I have to say in reference to this is the primary result of simple experience, acquired by frequent practice and constant endeavors directed toward simplifying the operative portion of our task. But also, in addition to this, I endeavored to account to myself for the reasons for my usual *modus operandi*. Thus became developed a systematic practice of the proper method of making in-

cisions. The description which I shall now give is based upon grounds which were originally purely empirical, and which have only gradually become modified by additional theoretical considerations. In the first place, I assert emphatically that there must be an essential difference between the method of making incisions for pathological purposes and that which is adapted for the anatomical theatre or dissecting room. In the ordinary way of making preparations the young student is taught to hold his knife as he would a pen. The object is to make short, fine cuts, in order to expose muscles, nerves and vessels, and to follow them out and show them clearly. Holding the knife in this way, the young student keeps his fingers in the position which became habitual to him, up to a certain point, when he was taught to write. The movements are confined almost entirely to the joints of the fingers—at any rate, to those of the hand. The arm itself is fixed generally in such a way that the elbow joint is brought close to the trunk, and often to the thorax, unless, indeed, it rests on the crest of the ilium. In this way, short, quick cuts may be made with great steadiness, the result of which is that neatness of appearance in a preparation which is appreciated in a moment by the sharp glance of the anatomical teacher. If such fine work be required for pathological anatomy—and this is the case pretty often—not only is there no objection to this method, but it is absolutely requisite.

This, however, must not be considered to be the rule. An autopsy in which short incisions only are employed, is an unduly tedious affair, and both the pathological anatomist and the medical jurist have far less time at their disposal than is the case with the descriptive anatomist. On the other hand, numerous short incisions cause the larger organs to be too much divided, and partial cuts in no way assist the inspection, and appear to be adapted rather for kitchen purposes than for those



of science. In examinations for pathological purposes, we save time, and gain increased insight and clearness, by making free incisions, and, when possible, such as involve the whole of the organ to be examined.

When this had become evident, I very soon perceived the necessity for holding the knife in a different manner. For all ordinary purposes of pathological dissection I now grasp the handle of the knife in the palm of my hand, so that when I stretch out my arm the blade appears as a direct prolongation. I fix then, relatively, if not absolutely, the joints of the fingers and hand, and making the cutting movements with the entire arm, so that the principal movements occur in the shoulder joint, the secondary ones in the elbow joint. In this way I am able to make long and useful incisions, and smooth ones as well, for I can utilize the whole force of the arm, and especially of the muscles about the shoulder; and it is only on surfaces produced by such incisions as these that we are able to see anything really satisfactory.

After I had got so far, I then perceived that in many roundabout ways I had reached the point which our predecessors in dissection, the butchers, had so long ago attained. I was not a little astonished when, one day, not very long ago, I went into a slaughter house and watched the men at their work. I then learned something else, which I have since brought into practice, viz: that the knife should be wider and longer than that commonly used.

A knife of such length and breadth, so well adapted for the butcher's purpose, is certainly inadmissible for ours, and it is only for the brain, and even then only in particularly important cases, that we require a very large, flat-bladed knife, which exceeds the dimensions even of those used in the slaughter house. But a knife for making sections should always be very considerably larger than the ordinary knife used in making preparations.

The latter is too short, both in the handle and in the blade, for making really large cuts. On the other hand, the blade is still too large for ordinary preparation purposes; for, when held as a pen, the point only of the knife is used—a portion measuring scarcely fifteen millimetres. The rest of the blade is so superfluous that the beginner in pathological technics who comes to me to learn the art of dissecting, immediately takes the knife (which I place in his *hand*) between his *fingers*, and then moves them in a wriggling way forward on the handle, until their points touch the steel of the blade. It is then naturally impossible to use the whole of the edge, for a large part of it is covered by the hand. As the dissector now finds himself confined to the point of his knife, and can use no other part of it, it is easy to understand that he very soon blunts it; and whereas a good pathological anatomist is perfectly able to dissect all the viscera of one subject, or even of two, with one knife, a pathological “layman,” holding his knife as he would a pen, requires three or four knives for one autopsy.

The modified section knife (*Secirmesser*) which I have introduced differs from the ordinary dissecting knife (*Präparirmesser*), both in the blade and handle. Both these latter are not only longer, but stronger—that is, thicker and broader. The anterior part of the blade does not form an acute angle, but is rounded off; the very broad surface terminates with a considerable curve in the slightly projecting point. Thus, not only is the cutting edge still further lengthened, but, at the same time, the risk of pricking one’s self or others, or of getting a prick from others during the examination, is considerably diminished. The number of dangerous wounds (and pricks are always more dangerous than cuts) has been very much diminished among us since we have adopted this useful kind of knife. As regards the back part of the knife, the blade is narrow and strong

near its insertion, for this portion of it is generally not much used ; the handle is flatter posteriorly, and much curved inward from both edges, so that it may lie more conveniently in the hand. Such a knife is, in its original condition, before it has been ground down, twenty-three to twenty-four centimetres long, of which nine centimetres and a half belong to the blade.

This knife should really be used for making incisions with a traction movement. It should not be pressed or pushed into the parts, but should be drawn through them with comparative rapidity. When necessary, we may employ the whole force of the muscles of the shoulder in this movement, and much power can be thus exerted. But the greater the force employed, the quicker must be the movement, or else the parts are liable to become crushed. Nowhere can this be better proved than in the brain. Even a very sharp knife pressed into the brain crushes the parts to a certain extent, and the resulting cut surface is, at least in some measure, useless for examination ; often, indeed, the appearance it presents leads directly to false conclusions.

An incision made by traction differs from one made by pressure, primarily in this: that in the former every point of the edge glides over or through a certain spot in the organ ; whereas in the latter the same point in the edge always presses upon the same spot of the organ. Whoever chooses to make incisions by pressure always, possibly involuntarily, places his forefinger on the back of the knife. He who makes incisions by traction places his forefinger on the surface of the handle, or he grasps the whole handle. At all events, it is a good practice, especially for beginners, to place the handle between the thumb and finger only, so that great pressure is impossible.

Where it is necessary really to exercise great pressure, we require another kind of knife—namely, one with a broader back, to which the forefinger or even the thumb

may be conveniently applied. I have for this purpose made a further improvement on the ordinary cartilage knife; the one which I use has a thicker and more bulging blade, and a much stronger handle. This latter is formed of two strong plates of wood or horn, one of these being applied to each side of a flat prolongation of the blade, reaching the entire length of the handle. The back of such a knife, sixteen millimetres broad, is a convenient support when pressure is required. The free end also of the handle is flattened and broad, so that for certain purposes, such as for separating the sterno-clavicular joint, it can be placed vertically in the palm of the hand, and can be conveniently used for making punctures.

I therefore require for each examination three different knives—an ordinary dissecting knife (*Präparirmesser*), a peculiar section knife (*Secirmesser*), and a very strong cartilage knife. I use the last for all the coarser sort of work—not merely for dividing cartilages, but also for large incisions through skin, muscle, and joints. The section knife (*Secirmesser*) serves especially for dissecting the large viscera; the dissecting knife (*Präparirmesser*) for the finer parts, vessels, nerves, etc. But inasmuch as the examination of the large viscera is the primary object of a pathological dissection, it is evident that the section knife in its present modified form is the principal instrument. In order to use it, the right arm must be allowed to be quite free. The elbow must be raised quite away from the trunk, so that the flexed forearm may be moved freely, and in any direction, backward or forward. It is then, easily practicable to divide the integuments of the trunk by one single long incision from the chin to the symphysis pubis. So, also, one incision is sufficient to display the lung from apex to base, in two halves. Perhaps this “dodge” (*Schwabensreich*)—I use the word in the sense of the worthy Frederick Barbarossa

—may appear to some improper and culpable. But I candidly own that I am a fanatical admirer of a large incision. The freer the incision—always supposing that it is an even one—the larger will be the field of view, the more numerous will be the points of comparison between normal and abnormal parts, and the more exactly shall we be able to estimate the extent of the pathological territories.

I maintain, indeed, that a free incision, even when wrongly done, is, as a rule, to be preferred to a small though accurate one, and is almost always better than several or many small cuts. The large even cut is peculiarly the one for demonstration purposes. To make it, I look carefully at each separate organ, to find where I can get the largest surface on section. I therefore cut through a spleen from above downward, over the middle of its outer (convex) surface, a kidney from without to within (from the external to the internal border), a liver from right to left in a horizontal direction; the testicle I cut into two nearly equal parts in a perpendicular direction, from its free to its attached border, and snap the parts asunder. I divide each lobe of the lung by a perpendicular incision directed from above downward, and from its thick border toward its inner (anterior, medial, sharp) one. Each hemisphere of the brain I divide by an incision beginning internally just over the corpus striatum, and directed somewhat obliquely outward. Each hemisphere of the cerebellum I divide by an incision which commences in the fourth ventricle, in the direction of the crus cerebelli, and is carried obliquely outward.

For many cases, and for several organs, one such cut is sufficient in order to show all that is essential. It very often happens that alterations in the liver, spleen, and kidneys are diffused so uniformly throughout the entire organ that one single cut affords us a sufficient insight into the internal structure of the parts. It is

true that in other cases and in other organs—for example, always in the brain—we have to make a larger number of cuts in order to be sure that nothing has been overlooked. Indeed, in the case of the brain, we can, properly speaking, never positively assert that it is quite normal, unless we divide it into quite microscopic portions, according to the new method of Herr von Gudden. But as this is only practicable in exceptional cases, we must perforce be content with approximative methods. This epithet, however, cannot be applied to any method where sections five millimetres thick are made of important parts. In the interior of such a section there is always plenty of room for foci of morbid material sufficient to produce paralysis or convulsions. The less we find, the greater the number of sections we ought to make.

But whether we make few or many incisions, it seems expedient in every case not to carry them so far as completely to separate the portions of the organ. Even if we only make one single cut, it is always useful to leave in one spot so much of the parts connected as to be able easily to restore the external form of the organ by merely placing the parts together and adjusting them. Many an idea with reference to external appearances has occurred only after the inspection of internal changes has directed our attention to certain conditions; and it is much easier to restore the form and general appearance of an organ when the natural continuity of the parts has been to some extent preserved, than when their connections have been completely severed.

In those instances in which the necessity of the case demands that the incisions should be greatly multiplied—as, for example, in the brain and spinal cord—it would be utterly impossible to form any further opinion as to the extent of certain changes, or even as to their exact locality, or their relation to the vessels, etc., if

the parts have been completely divided. It often happens here that only at a late stage of the examination changes become prominent which render it desirable to re-examine, once or more frequently, all the cut parts in their natural order of sequence, to convince ourselves that nothing has been overlooked in our first examination. Very simple precautions are required to rearrange the parts of an organ thus dissected; it resembles a book, the leaves of which can be opened here and there, or even entirely separated, and then again closed. But the object in having a book bound is to secure to every leaf a definite place, where it can be found in a moment without much trouble.

The question now arises as to the place to be selected for the "binding of the book." A close consideration of the relations of each separate organ enables us to answer this question with facility. The continuity must be in all cases preserved exactly where the connection between the organ and adjoining parts is the most important.

In all the large glandular organs, as in those which resemble glands (the spleen and lungs), the incision should be made from the outside, and we should take care of the spots where the vessels enter and leave, where the excretory ducts make their exit, and where the nerves reach the organ. These spots are called the hilus, porta, or root—the name varying with the organ. If, after the incision has been made, the organ is found to exhibit any important alteration, which may possibly be due to a primary vascular lesion, or be the result of some slow morbid process in the excretory ducts, we can, if the hilus has been preserved, either probe, dissect, inject, or use the blow-pipe from the more distant portions of the vessels or canals. If one of these methods is unsuccessful, another of them will be practicable.

The circumstances are different in the case of the

brain and spinal cord. Here the only "binding" is the pia mater, which supports the vessels. Transverse incisions must therefore be made on the spinal cord, leaving the pia mater attached on the anterior or posterior surface, according as the incision has been made from the one or the other aspect. In the brain the incisions should always be directed through the hemispheres from within to without; so that, notwithstanding the number of cuts which it may be necessary to make in the internal parts, it may always be practicable, at the close of the examination, to put the brain together again. My general rule is that each successive incision should be made across the middle of the existing cut surface, and that each new half should be again and again divided.

This procedure is naturally not practicable in the large ganglia. The optic thalamus and corpus striatum cannot be so divided that the pia mater may serve as a "binding" to them. The reticulated membrane which reaches them, the velum interpositum, with its choroid plexus, comes in contact with only a small streak, the so-called stria, or lamina cornea, and must be stripped off before the dissection of the large ganglia is commenced. These latter I divide by fan-shaped radial incisions, whose common starting point is the peduncle of the cerebrum. However great the number of these incisions may be—and it is necessary here to make numerous cuts—the relationship of the parts may always be closely preserved, in consequence of the connection between each separate portion and the peduncle of the cerebrum.

Before I go on with my description, this appears to me to be the place to say a few more words with reference to the examination of the cerebral ventricles, in order to conclude in some degree my account of the method of dissecting the brain. My opinion is that the examination of the brain, after the membranes have



been finished, should commence with the opening of the ventricles, since, apart from any tearing or squeezing caused by manipulation, the very weight of the organ increases the liability to laceration as time goes on, and the consequent risk of the escape of the fluids. The first incision, therefore, which I generally make into the brain, is carried directly into a lateral ventricle.

This incision, however, is not to be made in the way very common, even now, in examining the lateral ventricles for descriptive anatomy. The custom is, first to expose the so-called centrum semi-ovale of Vieussens, and then to create cerebral ventricles—perhaps by digging, almost in mining fashion, with the handle of the scapel. We ought rather to bear in mind that between the middle portions (*cellæ mediæ*) of the lateral ventricles there is only the very thin septum lucidum to form a partition wall, and that is exactly under the raphe of the corpus callosum. If we, therefore, make a lateral incision, at a distance of one millimetre from this raphe, perpendicularly into the corpus callosum, we come directly into a *cella media* at a depth of two to three millimetres. This incision, which forms a right angle with the plane of the centrum semi-ovale, should be the first one made in the brain, unless a deviation is rendered necessary by any peculiar circumstances.

But this incision is naturally not sufficient to open the ventricle completely. In order to open the anterior and posterior cornua, or, at least, to demonstrate their condition (for the posterior cornua are more frequently completely or partially obliterated than open), it is necessary to make particular incisions anteriorly and posteriorly. These should not be made vertically, but horizontally, the anterior one higher, the posterior one deeper, in the anterior and posterior lobes of the brain. Then only we obtain a view of the lateral ventricles in their whole extent, for the entrance, at least, to the descending cornu is also exposed by the incision toward the posterior cornu.

Having determined the contents of the lateral ventricles, the state of their walls and venous plexus, and the condition of the septum, the latter is taken hold of with the left hand close behind the foramen of *Monro*, the knife is pushed in front of the fingers through this aperture, and the corpus callosum cut through obliquely, upward and forward, and then all these parts (*corpus callosum*, *septum lucidum* and *fornix*) are carefully detached from the *velum interpositum* and its choroid plexus. After these two latter have been exposed, we have to examine the state of their vessels and tissue. Then the handle of the scalpel is passed from the front, under the *velum*, which is thus detached from the pineal body and *corpora quadrigemina*, the state of these parts is determined, and the third ventricle now exposed. Lastly, with a long perpendicular incision, we divide the *corpora quadrigemina* and the cerebellum as far as the aqueduct of *Sylvius* and the fourth ventricle.

In the case of the brain, the pathologico-anatomical examination has to take a course peculiar to itself, and one which differs in many respects from that adopted in descriptive anatomy; and the above statement may suffice to demonstrate the most convenient and rapid method of dissecting with a view to a certain object. It at the same time most clearly shows that here also a free incision is to be preferred to any other mode of division, and, as I again repeat, the incision should be made by traction. It is of the greatest consequence that the incisions should be even and smooth, in an organ like the brain, where the separate portions are of so great importance, and where one part is distinguished from another by peculiarity of function. How could we possibly demonstrate small foci of softening or induration upon an uneven, crushed, or torn surface? And these two are exactly those changes most frequently occurring in the brain. Therefore I say to my students, "Smooth though wrong incisions rather than correct

and uneven ones!" It is true that with an incision made in a wrong direction we can scarcely tell what we are about, but an incision badly made is entirely worthless.

On account of the importance of the subject, I shall now describe in detail the examination of a second organ, in order to explain the peculiarity of my method and the reasons for adopting it.

What I refer to is the dissection of the heart; and although the general principles which I have laid down apply also to this organ, yet the details to be taken into account are so multifarious that numerous modifications of the general rules become requisite.

After we have opened the pericardium and determined its condition, and also ascertained the external appearance and the position of the heart, its size, shape, color, consistence, the amount of blood contained in the superficial vessels, the amount of fat in the sub-pericardial tissue, etc., we have then to open the heart—and we should do this *in situ*. In making this first opening, we have in view two objects: the determination of the quantity of blood in the separate cavities, and the examination of the capacity of the auriculo-ventricular orifices. Such an examination is, of course, indispensably necessary. The determination of the quantity and quality of the blood contained in the different parts of the heart is of decisive importance for ascertaining the kind of death. It is in the highest degree probable, even if not absolutely certain, that two of the most important kinds of death—that from asphyxia (*Erstickungstod*), and that from the paralysis of the heart (*Herzschlag, Apoplexia cordis*)—occur in consequence of the over-filling, in the first case, of the right ventricle, in the second, of the left. We must, however, for clinical, and partly for forensic purposes, examine the capacity of the auriculo-ventricular orifices, especially of the one on the left side.

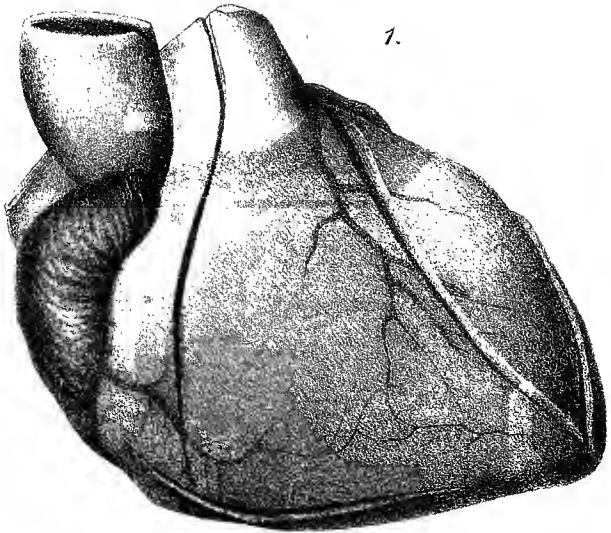
Another question which may be raised with reference to the auriculo-ventricular orifices can, unfortunately, only in certain cases be answered from sufficient evidence. I refer to the question with regard to their capacity for closing (*continentia*, less accurately though more frequently described as *sufficiëntia*). In an ordinary post-mortem examination no method can be adopted whereby the capacity for closing of the auriculo-ventricular valves can be thoroughly tested. We must content ourselves with supplying this deficiency by a minute examination of the valvular parts; and I will here remark that for this purpose it is absolutely requisite to preserve in their integrity all the parts belonging to the auriculo-ventricular valves, therefore also the cordæ tendineæ and the muscoli papillares.

A consideration of the two objects to be kept in view in making the first opening in the heart teaches us that on both sides the base of the organ must be preserved, for to the base on the right side the slips of the tricuspid valve are attached; on the left side, those of the mitral; and, therefore, if we cut through the base we injure at least one of the slips of these valves on each side. In addition to which, it would be quite impossible to estimate the quantity of blood contained in each side, therefore, also, in each auricle and each ventricle, unless we open each of them separately. It therefore follows that for the first portion of the examination of the heart four separate incisions are required.\*

There can scarcely be any dispute as to the position and direction of these incisions. The mechanism of the heart allows no great choice with regard to the spots to be selected. Variations are possible only within certain limits. My method of dissecting the heart may be described under the following heads:

1. The right border of the heart is the natural and

\* See Pl. I.



1.



recognized place of incision for examining the right ventricle. The incision must here begin close to the base, and must be carried at once deeply and forcibly into the interior of the ventricle ; toward the apex the knife must be brought out without going too far down, for otherwise there is considerable risk of cutting the septum.

2. This incision is at the same time the guide for the three others, and the place for the incision for each separate portion of the heart is to be found in a plane taking the direction of the first incision.

3. The incision for the right auricle commences halfway between the places of entrance of the venæ cavæ, and ends just in front of the base.

4. The incision for the left auricle commences at the left superior pulmonary vein, and ends in like manner just in front of the base, which is usually indicated by the very prominent coronary vein. We should carefully avoid injuring the coronary vessels.

5. The incision through the left ventricle begins just behind the base, and ends just short of the apex. It must be carried deeply and forcibly through the wall of the heart.

6. To bring the heart into the right position for the dissection, when the incisions for the right side are to be made, I extend firmly the forefinger of the left hand, and push it under the heart, and keep it against the base, so that the ventricular portion hangs down over the forefinger, which is as a fulcrum to it (*Hypomochlion*). Then I turn the heart on its axis toward the left until the right border presents anteriorly, and I press the thumb of the left hand just behind this border at the base. When the heart is thus fixed, I make, one after the other, both the incisions for the right side.

7. In dealing with the left side, I seize the apex of the heart, draw it upward and to the left, and place the heart in the left hand in such a way that my fingers can encircle it. Then, with gentle pressure, I make the posterior wall to bulge out a little, and withdraw itself from the septum. Then I make in like manner, one after the other, the incisions for the left side.

So much for the method to be adopted in making the incisions. I have now described in a connected way all that is necessary; but in practice the determination of the quantity of blood contained in the chambers, and of the size of the auriculo-ventricular orifices, intervenes during these operations. That is to say, after making the incisions in the right side of the heart, I first remove the blood from the right auricle, and determine its quantity and quality; then I insert two fingers of the left hand (the index and middle fingers) from the auricle through the tricuspid opening into the ventricle, and endeavor to open this latter cavity. Then I remove the blood from the right ventricle, and determine it as before. I then do the same on the left side.

With reference to the examination of the auriculo-ventricular orifices, I may again remark that in this first stage nothing but their size should be ascertained. The examiner must therefore not be tempted to introduce his finger at present, for the purpose of feeling whether, and to what extent, the valves are altered. This can be done later on, when the parts can not only be felt and handled, but are also fully exposed to view. Every attempt now made to ascertain, by feeling or rubbing, the condition of the borders of the valves is calculated to produce alterations or to remove any that may be present: any adherent coagula, for example, may be easily broken up or altogether detached. When the two fingers have been introduced, and the size of the orifice determined, they must be withdrawn as gently as possible. I shall here remark that each individual



examiner must find out for himself, by experience, how far his fingers are a measure of the normal size of the orifices. For thin fingers, as in my own case, we may assume that the tricuspid orifice permits the introduction not merely of the index and middle fingers in apposition, but that we may separate the two fingers to such a distance from each other as to be able to introduce between them, from the ventricle, a third finger, *e. g.*, the index finger of the right hand. With large and thick fingers this is not practicable. We have, moreover, on the left side to take into consideration the contracted condition of the heart. If the left ventricle is strongly contracted, the contraction will extend to the base of the heart, which is equivalent to the base of the orifice. We must then gently press the walls asunder, in order to overcome the contraction and the rigor mortis which is also very often present; this can be done without difficulty. It is only after the state of contraction has been overcome that we are able to form an opinion as to the actual size of the orifice.

These investigations terminate the first act in the examination of the heart. The removal of the heart is the first step of the second act. To do this we seize the organ by introducing the index finger of the left hand into the left ventricle, and the thumb into the right, through the already existing incisions. We then raise up the apex, and with it the whole of the heart, and then, with three or four long, free, horizontal incisions, we divide the *venæ cavæ* and the pulmonary veins, the pulmonary artery, and the aorta, all together, taking care that the incisions are not too close to the heart. When the heart has been removed, we first examine the cut openings of the aorta and pulmonary artery, determine the size of these vessels and the thickness of their walls, and remove from them any existing coagula.

Then we investigate the capacity for closure of the arterial orifices by pouring water into the aorta and pul-

monary artery. Before we do this, we must be always certain that all coagula have been removed, not only from the vessels, but also from the orifices and ventricles. For it is clear that coagula in any of these parts may so occlude an insufficient orifice as to give the impression of one that is sufficient. When the water is poured in, the heart must be held freely suspended in the air, for, if it is supported, a portion of the wall of the heart may be brought in contact with, and may stop up, the orifice we are examining. We must also avoid taking the heart in the hand and encircling it with the fingers, for we should in that way compress it, and prevent the escape of water through the orifice. The proper plan is to fix the heart by applying the points of the fingers of both hands either to the vessels to be examined, or externally near the base of the valves, in such a way that the plane of the orifice is exactly horizontal, and not drawn to any side. For in an oblique position of the orifice the weight on the separate portions of the valve becomes unequal, and fluid may escape through a valve which would otherwise close; and if the parts be dragged or stretched in a lateral direction, so that the circular lumen of the vessel is made to assume a crescentic form, the conditions of normal closure which involve the coming together of corresponding parts of the valve no longer exist. We must, therefore, always use both hands in order to suspend the heart properly, and the water must be poured in by a second person.

The best way to suspend the heart, when we are examining the aortic orifice, is to find a series of points where the tips of the fingers can be closely applied round it, and these are to be found on the right and left auricles and pulmonary artery. To apply one's fingers simply to the edges of the opening in the aorta is always somewhat hazardous, for there is then only room to hold the vessel in two places; and if we limit

ourselves to these, we are always apt to stretch the parts unequally. Moreover, in every case the aorta should be again divided at a distance of four or five centimetres above the orifice, by an incision parallel to the plane of the aperture. We are then able, while the water is being poured in, to observe the condition of the separate portions of the valve, and to ascertain positively the spots where the water escapes. I make, in conclusion, one remark—that sometimes the water sinks, and finally quite disappears, without passing away through the orifice. In this case it usually escapes through the coronary arteries, which are often divided when the left side of the heart is first opened. Particular attention must therefore be paid to this point.

In the pulmonary artery the majority of these difficulties do not exist; we can, therefore, without any further preparation, almost always contrive to suspend the heart for the purpose of testing the pulmonary orifice by fixing between the fingers the edges of the opening into the vessel.

We now come to the third part of the examination of the heart: the opening of both the ventricles.

For this purpose, the best plan is to place the heart exactly in the position which it occupied in the body, upon a board or table, and then to make the necessary incisions. This has the advantage of exposing to view the directions the incisions are to take. The interior of the heart ought, by means of the following incisions, to be made so far accessible to eye and finger that the parts remaining to be examined can be conveniently reached. Among these we must mention, in the first place, the auriculo-ventricular valves, with their chordæ tendineæ and muscoli papillares. Afterward come the cavities themselves, their endocardial investment, the arterial valves, the septum between the ventricles and that between the auricles, and the muscular substance itself. The auriculo-ventricular valves are here first

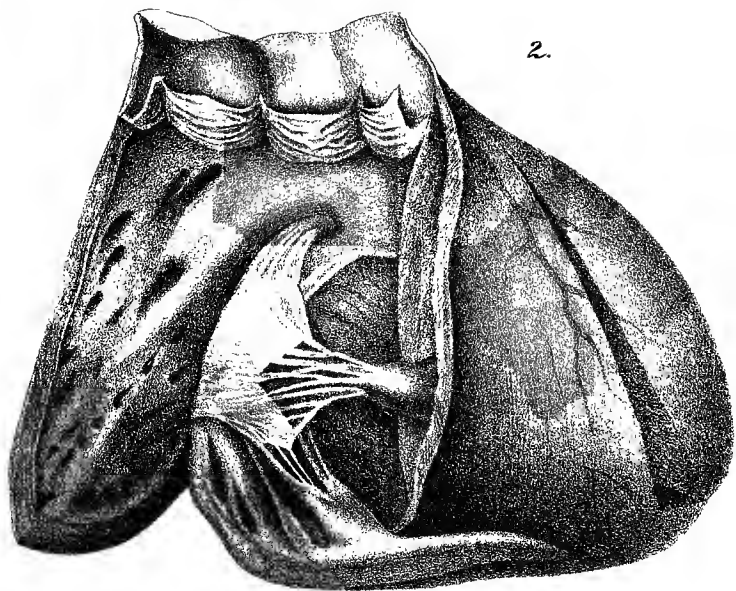
mentioned, not on account of their peculiar importance, but because the want, previously alluded to, of a proper closure test for them makes it requisite to subject them to a much more minute examination, and to preserve them in their integrity until this has been done. With regard to the arterial valves, which have meanwhile been thoroughly tested and examined with reference to their capacity for closing, the same kind of care is no longer necessary. These considerations determine the directions of the incisions requisite for the complete opening of the ventricles.

(a) The incision for the right ventricle\* is in a straight line prolonged from the pulmonary artery, and near the base of the heart. The best instrument for this purpose is a long pair of scissors, such as those used for examining the intestines. One blade of the scissors is inserted into the previous incision made in the right border, and carried in a direction toward the pulmonary artery. There is just one thing to bear in mind, and that is, that in this direction we come upon the anterior papillary muscle of the tricuspid valve with its chordæ tendineæ; and this must be carefully preserved. If this or its chordæ tendineæ be cut through, we shall not be able subsequently to demonstrate perfectly the arrangement of the valves of the tricuspid opening. The blade of the scissors must be introduced in front of this papillary muscle, and the incision through the anterior wall of the ventricle and of the pulmonary artery must, as described, be carried close to the base.

(b) The incision for the left ventricle, † which should also be made with a long pair of scissors, is in a straight line prolonged from the ascending aorta, and close to the septum ventriculorum. It commences at the apex of the heart, and divides the anterior wall of the ven-

\* See Pl. 2.

† See Pl. 3.



2.



tricle and of the aorta. The part which here requires the greatest care and attention is the base of the mitral valve; and the explanation of this is as follows: If we cut directly upward from the apex of the heart to the aortic orifice, keeping too close to the septum, the incision will cross the pulmonary orifice, and, by simply continuing the same, we shall cut through the valves of the pulmonary artery. This can be avoided by drawing the pulmonary artery to the right when making the incision, and by continuing this to the left, close to and behind the artery. But we must not go too far toward the left; there is a *Charybdis* here to be avoided. The right border of the base of the mitral valve is inserted quite close to this spot, and this valve, as is well known, is connected immediately with the left border of the aortic orifice. If the incision goes only a few millimetres too much to the left, we shall cut off that portion of the mitral valve which forms the above-named junction; and then, if we attempt to put together the divided portions of the heart, we shall find an aperture in the mitral valve. Externally, this spot corresponds exactly with the right border of the base of the left auricle. This should be our guide. The incision must, therefore, be carried through midway between the pulmonary orifice and the left auricle.

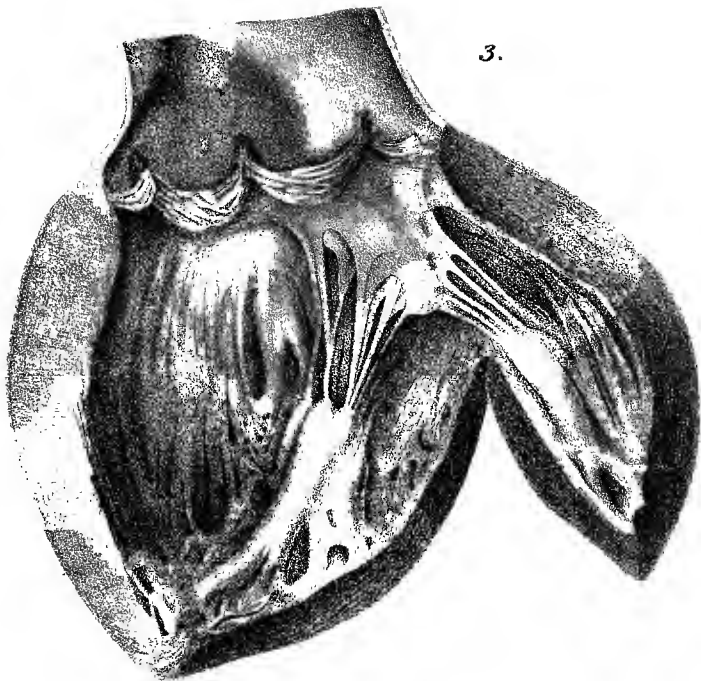
The principal part of the examination is now finished. The auricles can, however, be still further opened by cutting through their wall with the scissors, between the openings of the *venæ cavæ* on the right, and of the pulmonary veins on the left side. Further incisions can also be made into the muscular substance; for example, some very important ones running parallel to the surface from those last made in the ventricles, and which divide the wall of the heart into an inner and an outer half. The coronary arteries can also be further slit up, the incisions hitherto made having, upon the whole, but little interfered with these vessels. In exceptional and pe-

cular cases, such steps as these may have to be taken ; but, as a general rule, the examination is completed in the three acts which have been detailed, and which are also indispensable. The heart cannot possibly be regularly examined unless these three acts are properly performed.

One might suppose, after reading the long description which I have just given, that it would take a long time for all this to be carried out. The reader's idea might be similar to that of an unfortunate district physician, who, after studying the new Regulations, came to the conclusion that to make an autopsy in the prescribed manner would require at least two days. The one notion is as erroneous as the other. Ten minutes are sufficient to examine the heart in the way I have described, and an autopsy can be performed according to the new Regulations in three hours, and even in two where there are but few complications.

In order to be able to judge for myself as to the requirements of the Regulations, I have taken a few suitable cases, and made the post-mortem examinations in the prescribed form. I give, by way of a supplement, the notes of these examinations as instances, and also, in a certain sense, as models. I do not mean that they should (like Caspar's autopsies) serve as examples of diction and technics, and should relieve those who make examinations from describing and specifying in their own way what they find before them ; but what I intend is that they should show what a report is like when the Regulations have been carried out. A certain amount of freedom has been used in dictating these notes, and a very critical eye may possibly discover a few places where the Regulations have not been complied with, and some strictures may be made thereupon. But these, I hope, are such subordinate points that there will be at least no necessity for any "revision notes" (*Revisionsbemerkingen*) in the sense in which this word is used by the Committee of Sciences.





3.



The cases which I have selected are also of some interest in other respects, and I shall take the liberty of interpolating a few critical remarks.

### CASE I.

A man unknown. Dead when brought in; face covered with blood; left side of face, particularly about the ear, of a bluish-red color. Death from suffocation caused by pulmonary hemorrhage and œdema.

Length of time occupied in the examination two hours and five minutes. November, 1875.

#### A. *External Examination.*

1. The body is that of a man apparently from forty to fifty years of age; height 1.75 metre (68.89 inches); very strongly built; adipose tissue slight in quantity; muscles greatly developed—those of the arm and thigh less so in proportion than those of the forearm and leg.

2. Body generally pale in color; abdomen slightly green; flanks posteriorly, scrotum and glans of a uniform bluish-red; dorsum the same, and pale only where exposed to pressure; on pressing with the finger this bluish-red color can be made to disappear, not easily, though tolerably completely. On an incision being made, only distended vessels are visible in the skin and subcutaneous tissues, from which fluid blood escapes.

3. The body being turned over for the purpose of this examination, a thin, sanguineous fluid escapes from the nose and mouth.

4. The face, particularly the left side as far as the ear, and the beard are much soiled with dried blood, the largest quantity being on the nostrils and lips. A brownish-red, dry, powdery substance, on the left side converted into larger coherent crusts of dried blood, covers the neck and upper part of the chest.

5. Hair of head abundant, curly, light brown in color; numerous scattered gray hairs. The beard full, especially about the chin; whiskers strongly developed, color more reddish-brown; eyebrows thick, and, like the eyelashes, of a dark grayish-brown color; pupil pale grayish-blue; face large; forehead prominent; nose large and straight; high cheek bones; front teeth perfect; molar teeth more or less carious and defective; no traces of recent injury; lips pale and thin.

6. The body presents no other particular characteristics, only that the prepuce is unusually short, and covers no more than the edge of the glans; there is, however, no cicatrix of any kind to be seen.

7. The hands large; the nails long and bluish, the projecting edges filled up with thick black dirt, traces of which are seen also in the palms of the hands.

8. There is some amount of mobility in the principal joints of the extremities, but there are signs of rigor mortis in all the smaller articulations.

9. The eyelids are only partially closed; the corneæ transparent, and comparatively tense.

10. No foreign body about the nostrils, with the exception of the blood already mentioned.

11. The lips, as well as the teeth, are slightly parted; the tongue is behind the teeth, and, like the palate, covered with fluid blood.

12. External parts of ears unusually large; the left ear of a dark brown-red color. On an incision being made, blood flows everywhere copiously from the divided vessels, but there is no sign of extravasated blood in the tissue; auditory meatus empty.

13. Neck not very easily movable; no change perceptible.

14. Chest full ; abdomen slightly distended.

15. Cutis anserina slightly marked on the extremities, especially on the lower ones ; the legs above the ankles rather large, pitting on pressure ; the tissues on section found to be infiltrated with fluid. Just above the ankles there is a loose knotted piece of cord, twisted round each of them ; corresponding to this there is a transverse indentation on the inner and anterior aspects. This, when cut into, exhibits no extravasation of blood.

16. The parts about the anus much soiled with brown excrement ; the anus closed.

17. In conclusion, there is no perceptible mark of external injuries.

B. *Internal Examination.*—I. *The Cranial Cavities.*

18. The soft parts covering the skull are divided, as directed, by an incision carried transversely over the head, and reflected back. All these parts are then seen to be somewhat red in color, the alteration being more marked posteriorly than in front—the redness, however, not being sufficiently distinct on any one spot for it to indicate extravasation ; on the other hand, thick blood exudes everywhere from the divided vessels, and the soft parts appear to be uniformly infiltrated with reddish serum.

19. The skull cap, very broad and much arched, exhibits posteriorly a similar reddish infiltration of its tissue, especially at the sutures, which are deeply indented, and furnished in various places with ossa triquetra. The color of the remaining portions of the skull cap is a dirty yellowish-gray, somewhat more whitish in isolated spots.

20. The skull cap is sawn through with difficulty, and when divided, cannot be taken off from the tough

dura mater. The latter is therefore immediately cut through. On attempting to detach the bone and dura mater, the brain also follows, and this latter has to be removed by separating methodically its connections in the base of the skull.

21. The brain being removed, there is no appearance of serum nor of any other effusion on the basis cranii. The large sinuses in that situation contain only a moderate amount of fluid blood.

22. There is some difficulty in separating the tough dura mater from the base of the skull and the posterior portions. There is no sign of any kind of injury to the bones of the base.

23. There is no change, also, on the base of the brain itself. The great arteries are large, but flat and empty. The pia mater everywhere fine and soft, and its veins only filled with blood near their origin.

24. After the removal of the brain from the roof of the skull, the inner surface of the dura mater is found to be everywhere of a pale color. There is no deposit connected with it; it is somewhat thick and tendinous; the longitudinal sinus large, but filled throughout with fluid blood.

25. The dura mater is then removed from the roof of the skull. Its external surface is also pale; the blood vessels very prominent, but empty.

26. Neither fissure nor injury of any kind visible in the roof of the skull; diploë scanty in amount. The bones, on an average, are from five to six millimetres thick. Fine, red, very vascular, soft growths on the inner surface of the frontal bone in the middle line.

27. The surface of the brain well formed; the pia mater delicate throughout; the veins filled with blood, tumid even to roundness on the left side, somewhat less so upon the right.

28. On cutting into them, the lateral ventricles are found to contain a small, inappreciable quantity of clear fluid. Cavities of normal size; posterior cornua obliterated. Septum soft, and easily torn; choroid plexus and vessels of the velum of a dark-red color, owing to great distention. The vessels separable only with difficulty from the corpora quadrigemina.

29. On cutting into the hemispheres of the brain the tissue is found to be moist and glistening; the white substance exhibits numerous bloody points, from which drops of blood exude on pressure; these drops can be washed away with water. The gray substance of the cortex pale reddish; that of the corpus striatum and of the thalamus similar in appearance, and also moist. No other change. Consistence of the brain good.

30. Corpora quadrigemina pale. Pineal gland small and red.

31. The fourth ventricle empty; its surface pale and soft, its choroid plexuses reddened.

32. The cortex of the cerebellum reddened throughout, though the vessels are not perceptible; the medullary substance, on the contrary, traversed by congested venous branches. Consistence good; moisture moderate in quantity. No change.

33. At the base of the brain, all the lobes cut through by numerous parallel transverse incisions; no alteration of any kind apparent. The gray substance slightly reddened throughout.

34. The gray substance of the pons Varolii and the cerebral peduncles of a reddish color; the white substance traversed by numerous congested veins. Consistence good.

35. The medulla oblongata pale; the gray matter of the rhomboid fossa somewhat more reddened.

II. *Thorax and Abdomen.*

36. A long incision is made from the chin to the pubic symphysis as directed, the integuments divided, and the cavity of the abdomen laid open. Adipose tissue slightly developed ; muscles somewhat pale.

37. No foreign body in the abdominal cavity. Position of the parts normal. Cæcum, transverse colon, and the ascending portion of the large intestines are much distended ; also a portion of the small intestine—in part with gas, and in part, apparently, with fluid. All these parts are pale in color ; the omentum only presents a few distended veins.

38. The arch of the diaphragm on each side is between the fourth and fifth ribs.

(a) *The Thorax.*

39. After removal of the sternum the lungs come into view, somewhat distended, particularly the left one ; position of the parts normal in other respects. The pericardium to a great extent covered by the lungs.

40. On the left side several very firm adhesions between the surface of the lung and the wall of the thorax. A tablespoonful of thin reddish fluid in the most posterior part of the pleural cavity.

41. On the right side the adhesions to the upper lobe are somewhat more extensive, but equally firm, and traversed by vessels. A smaller amount of fluid than on the left side. Internally, near the pericardium, the adhesions are still more extensive.

42. The pericardium contains a tablespoonful of a slightly reddish but clear fluid.

43. The heart about the size of a man's fist, its right surface flattened, a slight amount of tendinous deposit (*Sehnenflecke*, maculæ albidæ), the right ventricle mod-



erately covered with fat, pale, and only the coronary veins somewhat distended with blood. The right auricle contains particularly fluid blood, mixed with a very small quantity of soft, friable, buffy clot. The quantity of blood collected from the right side of the heart and the large veins amounts to 150 cubic centimetres. The right ventricle contains fluid blood only, inappreciable in quantity. The left auricle contains fluid blood and a small quantity of thick blood. The left ventricle quite empty. The blood everywhere equally dark. The aorta three centimetres in diameter, its walls thick, inner coat especially thickened. The pulmonary artery about the same size, but with thin walls. The valves at the mouths of both vessels close. On section, right ventricle found to be dilated, left ventricle large. Muscular tissue somewhat dark; a little paler on the right side. Valves without alteration, but of a deep-red color.

44. The large veins of the neck moderately distended with fluid blood; arteries empty. The large nerves apparently unaltered.

45. The cavity of the mouth opened, as directed, from beneath; the tongue drawn away, and the upper part of the throat exposed. All these parts covered with a layer of bloody mucus, which, however, can be easily rubbed off; after its removal the mucous membrane appears slightly reddened, but otherwise unchanged. Lingual follicles large, whitish. Tonsils slightly swollen.

46. A considerable quantity of bloody froth with large bubbles in the larynx and upper portion of the air tubes. This removed, the mucous membrane appears only slightly reddened; on the posterior aspect of the tubes the vessels of the mucous membrane distended with blood, but no other change.

47. The remaining thoracic viscera, with the lungs, are now removed, together with the costal pleura.

48. Lower portion of the œsophagus is covered with reddish fluid, which can be easily taken off. After its removal, no alteration visible in the subjacent mucous membrane.

49. There is slight dilatation, and thickening of the internal coat, of the thoracic portion of the aorta, but no breach of surface. The same may be said of the large branches of the artery going to the neck.

50. The upper part of the air tubes, as well as their large ramifications, are filled with frothy and bloody matter.

51. The lungs seem large, very concave on their diaphragmatic surface, studded over, especially on the right side, with smooth projections of their tissue greatly dilated (emphysematous). The lungs, in general, are gray in color, pale anteriorly, reddened posteriorly. Numerous furrows, due to absorption, on the anterior surface. These latter places feel harder to the touch; the rest of the tissue is soft, but only slightly crepitant.

52. On section, in the apex of the right lung is found a ramified cavity of irregular shape, about six centimetres and a half in diameter, consisting of two compartments, separated by a thin septum, and each of them four centimetres and a half in horizontal diameter. Each contains a bloody, slightly frothy liquid, which can be easily removed by water. The walls of both these cavities are irregular and rough, and, on water being poured upon them, they are seen to be covered with adhesions, which readily float. Many large eroded vessels, some of them lying free like rafters, are found in these cavities, into which branches of the air tubes may be directly traced. In other parts of the lung there are single smaller cavities with smoother walls, and also separate circumscribed spots, externally hard

to the touch, some of which appear, on section, dense, dull, grayish-red, and finally granular; others dry, grayish-white, and caseous. The rest of the pulmonary tissue is full of frothy, whitish fluid, which can be easily pressed out.

53. On the left side, below the apex, more toward the centre of the upper lobe, there are several similar cavities, varying in size from that of a walnut to a hen's egg, containing also fluid, slightly frothy blood, and connected with the air passages. The wall of these cavities is irregular and ragged; the remains of the large vessels appear as whitish projections. There is a similar cavity about as large as a walnut in the upper part of the lower lobe. Throughout the remainder of the lung there are numerous nodules of varying size—some as large as peas; a few with cavities in their interior; others solid and caseous; others, again, solid and dark gray.

(b) *The Abdomen.*

54. Spleen closely adherent to the diaphragm and omentum; fourteen centimetres long, nine centimetres broad, three centimetres and a half thick; externally, gray steel-colored. On section, dark brown-red; pulp abundant, with numerous dark-red spots; follicles slightly enlarged.

55. Left kidney thirteen centimetres long, six centimetres and a half broad, three centimetres and a half thick. Capsule slightly dull, thin. Surface of the kidney smooth, brownish-red, bright; consistence firm. On section, the medullary and cortical substance very red, not dull; no other change. Malpighian corpuscles bloodless. Supra-renal capsule with a small amount of cortical and medullary substance; the tissue connecting it with the kidney firm and well supplied with blood.

56. On separating the parts surrounding the right kidney a fibrous adhesion between the large intestine and the under surface of the right lobe of the liver brought into view.

57. Right kidney of same size as left, and resembling it in other particulars. Supra-renal capsule in a similar condition.

58. Bladder contracted, and containing only a few drops of whitish urine. No change in mucous membrane.

59. Left testicle somewhat mis-shapen, in consequence of fibrous adhesions on its surface. An offset from the right one at the upper part of the epididymis.

60. The stomach distended, and containing a large quantity (about 200 cubic centimetres) of thick, clot-  
ted, bloody fluid, mingled to some extent with large air bubbles.

61. Fluid of a similar kind in the commencement of the duodenum, but extending only as far as the opening of the gall duct. After this the contents are of a pale-yellowish color. Opening of gall duct normal.

62. The mucous membrane of the stomach tinged throughout with blood, but without any lesion; only the large veins distended with blood.

63. In the upper part of the intestine a large amount of a gray fluid resembling gruel, slightly colored with bile. This becomes thinner and more scanty in the upper part of the jejunum. The ileum contains a very large quantity of fluid of a brownish color. This part of the bowel is so soft that it tears when cut into with the scissors. The lowest part of the ileum contains a quantity of very fluid fæces. The large intestine from the ileo-cæcal valve full of thick, pulpy fæces. The mucous membrane throughout the ileum thin and pale;

the glands slightly tumid. In the jejunum the mucous membrane is thicker. Here and there a single gland appears tumid, but in other respects normal. In the upper part of the jejunum the mucous membrane has a whitish appearance.

64. The liver (twenty-eight centimetres broad, twenty-three centimetres from front to back, and eight centimetres thick) is firm to the touch, its surface of a pale-brownish color, somewhat firm under the knife; breaks with difficulty, and appears on section uniformly red. The lobules are large, and their color uniform.

65. The inferior vena cava contains fluid blood.

This case is a remarkable instance of ulcerous consumption of the lung, occurring in a man in other respects vigorously developed, and in whom the disease, though obviously of long standing, had confined itself to the lungs. Owing to the advanced stage of the disease, it cannot be ascertained whether the morbid process primarily originated in bronchiectasis or caseous pneumonia; at any rate, caseous pneumonia finally supervened. It is a matter of great interest that, notwithstanding the amount of hemorrhage from the lung, the fatal result was not due simply to loss of blood (anæmia) nor to simple occlusion of the air passages by the extravasated blood, but really to the supervention of œdema—a complication which is explained, on the one hand, by the robust condition of the patient; and, on the other, by the slow course of the hemorrhage. Not a single ruptured blood vessel could be discovered.

The conclusions to be drawn from the foregoing statement are as follows:

1. That death occurred from suffocation caused by pulmonary hemorrhage and œdema.
2. That no signs of any external injury were revealed by the autopsy.

## CASE II.

A person known. Gunshot wound of head (suicide). Death in twelve hours, or rather more, from œdema of the lungs. On examination post-mortem, the track of the wound found to be through the right hemisphere, and involving the extra-ventricular part of the corpus striatum. Extensive œdema and interstitial emphysema of the lung. Numerous manifestations of older affections; irregularly-shaped cranium; unsymmetrically formed brain; contracted aorta; endocarditis mitralis; herpes zoster; chylification going on in the intestines.

B. W., aged twenty-one, a tradesman's assistant, had shot himself through the head with a pocket pistol, above the middle of the left eyebrow. Quite insensible when brought to the Charité, at 6 a. m.; breathing stertorous; pulse scarcely perceptible; urine passed involuntarily; loud tracheal râles; heart sounds scarcely audible; no albumen or sugar in the urine; the left pupil larger than the right. From time to time a whitish greasy matter, mixed with blood, exudes from the small wound. At midday the pulse had somewhat risen; the respiration was still stertorous, though a little easier. In the afternoon the man's condition rapidly changed for the worse, and he died at four o'clock.

Post-mortem examination (occupying two hours and three-quarters), Nov. 3, 1875:

*A. External Examination.*

1. Body generally well developed; appears to be that of a man twenty years of age; height, 1.7 metre.

2. Anterior surface generally pale, but the left half of the face, the left ear, the adjacent part of the neck, the arms and forearms, and the thighs and legs, much discolored, and exhibiting large, bluish-red, irregularly shaped spots, of varying size, generally more marked

on the left side; but on those parts of the back which have not been exposed to pressure the discoloration is uniform and of a deeper red. On pressing firmly with the finger the redness almost entirely disappears: on an incision being made, a few large drops of semi-fluid blood escape from the skin and subcutaneous tissue, but there are nowhere any permanent reddened patches, such as cannot be removed by water. There is one place on the left thigh, a hand's breadth above the patella, where, on incision, we find a small spot extending through the adipose layer, and infiltrated with blood which cannot be pressed out. On the right shoulder blade there are a few dry, brownish-red spots running obliquely from above, and externally in a direction downward and inward. These on section appear to be only thin, dry crusts, involving the corium proper.

3. On turning the body over, a large quantity of yellowish-brown fluid, containing dark-brown particles, escapes from the mouth.

4. Rigor mortis marked in the extremities and in the muscles of the neck and abdomen.

5. Numerous grayish-brown spots—not removed by washing—on the anterior surface of the body, especially on the breast. On the left side, near the seventh, eighth, and ninth ribs, there is a broader zone of these spots; this is continued to the arm, where the patches are brownish, and covered with thick masses of epithelium. Other parts, also, of the surface of the body, especially the lower extremities, are covered with gray spots, completely removable by washing. Blackish marks on many parts of the face, neck, arms, and trunk; some of the larger size on the abdomen; these appear, on section, to extend no further than the cuticle.

6. A few pale-greenish faint spots on the abdomen,

and in the neighborhood of the groins. Cadaveric odor not perceptible.

7. Hairs dark brown, on right side stained red; much matted together, and their roots covered with dry blood.

8. On the forehead, a finger's breadth above the middle of the left eyebrow, a small hole, three millimetres in diameter, surrounded by a dry, blackish-brown, somewhat depressed border of the skin, one to two millimetres broad, around which externally and toward the left side the integument is slightly reddened, and the cuticle abraded. The parts surrounding the wound are slightly swollen. A long transverse incision carried down to the bones shows extensive separation of the connections of the tendinous expansion and the subjacent connective tissue, extending in one spot to the periosteum, and corresponding with a hole in the bone. There is here a flat splintered piece of bone, triangular in shape, five millimetres long, four millimetres wide, retained in its place. The separation thus caused in the parts forms no regular cavity; the wound is traversed by numerous projecting filaments and cross bands of tissue. For five centimetres around this the soft parts are infiltrated with blood, which cannot be pressed out. The tissues for some distance beyond this contain a watery fluid.

9. Eyelids open; corneæ firm and transparent.

10. Nostrils filled with a great quantity of dried blood, which also covers the adjacent parts of the skin.

11. Mouth slightly open at the middle. Lips somewhat red. The teeth closely shut.

12. No other foreign bodies discovered in the apertures of the head.

13. A pale streak on the neck, three millimetres



broad, over the larynx, increasing toward the left side to a breadth of fifteen millimetres, and terminating here under the ear ; neither a groove, nor injury of the surface, nor any change of color, to be perceived. There is nothing of the kind to be seen on the right side. The skin and subcutaneous tissue quite pale on section.

14. Thorax somewhat flat.

15. Abdomen somewhat retracted.

16. Penis small ; much contracted ; very little prepuce. The glans and what remains of the prepuce dark red and rather dried. The scrotum likewise small and much wrinkled ; externally, on both sides some appearance of blood. On incision, the integuments of these parts dry superficially, and very red.

17. Anus closed.

*B. Internal Examination.—I. The Cranial Cavities.*

18. Scalp divided by an incision across from one ear to the other, and reflected forward and backward. A few drops of blood seen emerging from the anterior portion—these more numerous posteriorly ; in front also a close network of distended vessels in the aponeurosis and pericranium. No other spots of extravasated blood, with the exception of those mentioned (in No. 8), in the left frontal region.

19. The aperture mentioned in No. 8 is now seen more distinctly, but there are no fissures surrounding it, and no increase in the quantity of blood in the perios-teal vessels.

20. The skull cap is now removed, the saw being carried horizontally round below the aperture. The bones are difficult to saw through, and, on being removed, are found to be almost entirely composed of compact substance, and six, or even seven or eight, millimetres

thick. The left frontal sinus is filled with pulpy matter, consisting of whitish, soft, brain-like substance, and dark-red clots, which are partly separable. The right frontal sinus is empty. No fissures are visible in the bones forming the sinuses, but the vessels, as far as they can be made out with the naked eye, are much distended with blood. The external opening (the transverse diameter of which in the outer table is eight millimetres, the diameter from above downwards being six millimetres) has an irregular hexagonal shape, and leads directly into the left frontal sinus. In this sinus there is another opening, having the same direction, and passing through the inner table just above the orbital plate. This opening is almost completely closed by fragments of cerebral matter and clots of blood; after these are cleared away, a somewhat irregular, but here rather triangular, opening is found, the sides averaging six millimetres. At the upper part, and close to the opening, there are two larger and two smaller scales of bone, splintered off from the inner table; these are, however, still loosely connected with the bone.

21. The form of the skull is seen, on section, to be somewhat oblique, the right half becoming wider posteriorly; the left narrower in front. On the left side there is incipient obliteration of the coronal, as well as of the sphenoparietal suture. The right lambdoidal suture is completely obliterated. On removing the pericranium, recent red osseous deposits on various parts of the surface of the skull, especially numerous on the posterior upper part of the temporal ridge. The inner surface of the calvaria dotted over with numerous large pits, principally in the neighborhood of the anterior fontanelle.

22. The dura mater everywhere thin and diaphanous, except in the neighborhood of the longitudinal sinus, where it is of a dull-whitish color, and traversed by numerous red vessels. On the left side, in front of the

anterior part of the brain, there is an aperture in the dura mater, very irregular in shape, out of which protrude soft, broken-up masses of brain substance, mixed with blood; these are continuous with the previously mentioned *débris* in the aperture in the skull. The opening in the dura mater is on an average from six to seven millimetres wide; its margins are somewhat dentate and wrinkled. There is no blood extravasated anywhere else between the dura mater and the bone.

23. The superior longitudinal sinus anteriorly narrow and empty; posteriorly, rather wide, and filled with dark semi-fluid blood.

24. On the right side the dura mater much distended by a bluish mass, which gleams through it. The arteries of the dura mater filled with blood as far as their small ramifications, and projecting considerably above the surface of the membrane,

25. On separating the dura mater on the right side, a large clot of blood, dark colored, is found to overlay the whole right hemisphere of the brain. It is slightly moist; its own weight causes it to slide from its position; and it amounts in quantity to twenty-five cubic centimetres. Some portions adhere pretty firmly to the surface both of the dura mater and of the pia mater. On washing the parts with water, the source of the hemorrhage is found in an aperture in the brain, situated nearly at the posterior part of the middle lobe, two fingers' breadth behind the end of the fissure of Sylvius; clots of blood protrude from this opening. The pia mater all around this spot is infiltrated with blood, especially at the anterior perforated spot; also to a less degree in the sulci of the middle and posterior lobes, and to some extent in those of the anterior lobe.

26. At the anterior extremity of the right anterior lobe, close to the falx cerebri, the pia mater appears

more thickly and deeply infiltrated. This appearance is not connected with those above described ; it is more marked inferiorly and in front, where, at the same time, the consistence of the cerebral substance is softer and more yielding.

27. A third, apparently also independent, spot is quite close to the longitudinal fissure at the top of the vertex, under a somewhat thickened part of the pia mater ; it projects somewhat, and is surrounded by a quantity of fluid blood, which spreads also freely toward the dura mater.

28. The head being raised and drawn forward, a leaden bullet, measuring in one direction eight, in the other six millimetres, falls from the parts described in No. 25. This bullet is quite flattened, and bright on one side.

29. Sulci of brain on right side very deep ; perceptible beveling off of the convolutions just behind the vertex.

30. The dura mater being removed on the left side, blood is found effused on the surface in much less quantity ; it is, however, equally coagulated, and is more adherent to the membranes, especially to the dura mater. The pia mater infiltrated with blood, but only to a slight extent, anteriorly near the spot where the external opening touches the brain, the infiltration extending no further than a finger's breadth toward the base, and not quite so far toward the convexity of the brain. A clot of blood eleven millimetres long and five millimetres thick in a small depression of the surface close by the side of the falx cerebri, on the margin of the longitudinal fissure at the vertex ; this extends a finger's breadth further backward than toward the right side. All around the spot the vessels are much distended, and posteriorly the pia mater infiltrated with blood.

31. There is, in addition, an extravasation of blood in shallow layers between the falx cerebri and the projecting wall of the left hemisphere, amounting in quantity to scarcely a teaspoonful.

32. The left hemisphere of the brain also appears depressed; the surface of the convolutions is even flatter than on the opposite side.

33. The brain being removed, its base is seen to be infiltrated with blood to an irregular extent; this is especially marked in the direction from the aperture in the anterior lobe toward the olfactory nerve, at the anterior part of the middle lobe, around the infundibulum, as far as the medulla oblongata. The blood for the most part is contained in the meshes of the pia mater, but in several places there are clots obviously non-adherent.

34. The pia mater delicate throughout, its vessels filled with blood up to the smaller branches.

35. The brain itself appears shorter, and the convolutions more simple, on the left side than on the right. The consistence good, with the exception of those spots already mentioned.

36. Behind the above-mentioned (No. 22) opening in the dura mater, corresponding to the aperture in the bone, and which is just below the anterior part of the left anterior lobe, there is also a large perforation in the pia mater, fourteen to eighteen millimetres in circumference. Beneath this there is a funnel-shaped excavation, surrounded by soft *débris* of brain substance, and a few large clots of blood. An oblique incision being made, extending from this spot transversely across to the opening (mentioned in No. 25) in the outer part of the right hemisphere, a continuous canal is exposed; this has a total length of thirteen centimetres, and extends through the middle of the brain substance, par-

ticularly through the base of the corpus striatum, and has a diameter anteriorly of twelve millimetres, posteriorly of eighteen millimetres; it is filled with coagulum and copious *débris* of brain matter. The wall of the canal is soft throughout, formed directly of brain substance, and dotted over with numerous spots of extravasated blood.

37. The point on the vertex of the right hemisphere (described in No. 27) turns out to be a sanguineous infiltration of the pia mater, five millimetres deep. Nothing abnormal found below the other spot particularly referred to in No. 26.

38. The cerebral ventricles are empty, the choroid plexus and the large vessels of the walls of the ventricles filled with blood. The upper vessels of the velum delicate and transparent.

39. Optic thalamus and corpus striatum pale, but not dry.

40. The white substance of the hemispheres is pale and dry; in a few places only blood escapes from the divided vessels. The gray substance for the most part pale, but in places reddened to some depth.

41. The fourth ventricle is empty; the cerebellum generally pale, but less so on the left side, where the gray substance is somewhat reddened; and the white substance appears to be more infiltrated with a watery fluid.

42. The pons is pale and firm, as is also the medulla oblongata.

43. In the posterior fossa of the base of the skull a large quantity of fluid blood has collected during the examination; this has escaped from the large blood vessels of the vertebral canal.

44. The transverse sinus almost empty. In the

middle fossa of the base of the skull, on the left side, the dura mater much covered with blood.

45. On removing the dura mater, it is found that several fissures of the inner table extend from the opening in the skull (No. 19, 20,) to the orbital plate. The cracks are filled with coagulated blood, but they extend for a distance of only seventeen to eighteen millimetres in a backward direction.

## II. *Thorax and Abdomen.*

46. A continuous incision, carried as directed, from the chin to the pubic symphysis, and the abdominal cavity first laid open. Abdominal organs in their normal position. The intestines lie very far back. No foreign body in abdomen. The parts exposed of a pale color generally; only the small intestines slightly reddened.

47. The diaphragm on both sides reaches the lower border of the fifth rib.

### (a) *Thorax.*

48. The sternum having been removed, as directed, the lungs recede very slightly from the wall of the thorax; their anterior portions distended with air, and buoyant, much reddened in places. Between the lobules there are rows of large air bubbles; and in some spots these coalesce, and form large, continuous level patches.

49. The left lung is free throughout. The pleural sac contains, at a rough guess, forty-five cubic centimetres of a thin, watery liquid, of a dirty-red color.

50. On the right side the upper parts of the lungs are somewhat bound down by connective tissue; at the base and back part of the pleural cavity there is a very minute quantity of fluid of a similar kind to that found on the other side.

51. The heart, just the size of a man's closed fist, is very rigid, and somewhat flattened on its anterior aspect and over the right auricle. The coronary arteries empty; the coronary veins distended only in their primary ramifications, and somewhat deeply placed. Only a small amount of fat about the pericardium, on which there are a few detached spots of a deep-red color, scarcely as large as a millimetre.

52. About forty cubic centimetres of dark blood, for the most part fluid, containing a small buffy clot, escapes from the right auricle. The right ventricle contains blood of a similar kind, dark-red in color, not more than twenty cubic centimetres, with very faint traces of coagula. In the left auricle the quantity of blood amounts to thirty cubic centimetres, and it is more coagulated and as dark, with a few spots of a faint buffy color. On the other hand, only a very slight clot, with a gelatinous buffy coat, occupies the left ventricle.

53. The aorta so narrowed as only to be capable of admitting the tip of the ring finger. The pulmonary artery only a little more capacious. A stream of water being poured in, none passes into the ventricles. Valves on both sides thin; not discolored by blood. Narrowing of the mitral valve, which will not admit of two fingers, caused by thickening, contraction, and adhesion of the slip of the valve posteriorly. Muscular tissue much attenuated, of a brownish-red color.

54. On the left lung rows of air vesicles in great abundance (as described in No. 48) on the lower part of the anterior border, and at the tongue of the upper lobe, and also in various places at the lower border of the lung at the base. Posteriorly, both lobes appear to contain but little air, and are of a tolerably uniform bluish-red color; the lower lobe somewhat grayish-white, owing to thickening and serous infiltration, here



and there, of the investing membrane. Numerous small, slightly raised patches of extravasated blood scattered about over both lobes.

55. A large quantity of thick bloody froth escapes from the left bronchus. On cutting through the lung, entire portions appear red and filled with frothy liquid, but in other respects unchanged.

56. The same appearances are found on the right side, but the rows of air vesicles are less numerous. On the other hand, all parts of the lung contain serous exudation, and the lung tissue is of a deep-red color.

57. The tongue, retracted behind the jaws, is covered with a dirty-brown coating, but normal in other respects. Some bloody mucus in the pharynx. Both tonsils very large, projecting almost like tumors, and seen on section to contain friable masses in the follicles; parenchyma much increased.

58. Veins of the neck filled with dark fluid blood. Arteries empty. Nerves normal.

59. Œsophagus contains only a small quantity of light-brownish matter.

60. Epiglottis slightly compressed laterally; glottis open. Larynx and air passages filled with thick frothy fluid, containing a few yellowish-brown flakes. These being removed, the mucous membrane of the upper part is seen to be traversed by an open net-work of vessels. In the lower parts the vascular network is close, and of a deep-red color.

61. Aorta narrow, walls thin; contains only fluid blood. The superior vena cava has similar contents.

(b) *Abdomen.*

62. The spleen is 14.5 centimetres in length, 10 centimetres in its greatest breadth, and 2.7 centimetres in

its greatest thickness; it is very flabby, and somewhat wrinkled. On section, blood exudes from a few large vessels. The Malpighian corpuscles are unusually large, reaching even 1 millimetre in diameter. Splenic pulp scanty and brownish-red.

63. Left kidney 10 centimetres long, 4.5 centimetres broad, 2.9 centimetres thick; flabby; capsule easily separable; surface smooth, of a dark, brownish-red color; veins easily distinguishable. The tissue on section very dark red; Malpighian corpuscles very prominent, but no other change.

64. Left supra-renal capsule firm; cortical substance slightly developed, medullary substance more so.

65. Right kidney 9.2 centimetres long, 4 centimetres broad, 2.5 centimetres thick; in other respects, as on the left side.

66. Right supra-renal capsule resembles left one.

67. Bladder not much distended. Urine clear, and amounting to about 80 cubic centimetres. Bladder normal.

68. A little clear fluid in both tunicae vaginales. The substance of the testicles pale, but normal.

69. The stomach somewhat distended, its pyloric portion contracted; the veins on the external aspect but slightly distended, and only the larger ones manifest; its general aspect pale. It contains about 150 cubic centimetres of a greenish, thick fluid. The mucous membrane of the fundus is stained greenish-yellow, in the other parts pale red, and toward the pylorus somewhat granulated.

70. The small intestine is contracted almost throughout its extent, only the most deeply situated portions are somewhat distended, and contain liquid. On the

external aspect the large veins appear very full, as also some lacteal vessels in the upper portions of the bowel.

71. The mesenteric glands small and slightly reddened. Mesentery loaded with fat.

72. The upper part of the duodenum contains a whitish fluid; lower down, the contents are decidedly yellow. On pressing the gall bladder, greenish-yellow bile flows freely from the orifice of the gall duct; pancreas pale; normal.

73. On opening the jejunum it is found to contain some light-gray matter, here and there yellowish and consistent; in its lower portion some thinner fluid deeply tinged with bile. The ileum is almost empty, and contains only a few greenish, tolerably consistent fecal lumps.

74. The large intestine contains pulpy, greenish-brown fluid masses, mixed with hard masses, as far as the descending colon; in this latter portion, consistent and formed fæces.

75. Mucous membrane of the jejunum very thick; the villi in the upper part enlarged and milky, from absorption of chyle. Lower down, marked reddening of the valvulæ conniventes as far as the place where the contents are colored with bile; the mucous membrane here becomes also deeply bile colored. Lower down, and as far as the beginning of the ileum, the villi are faintly red. Peyer's patches slightly injected, and the glands enlarged in the lower portion of the ileum. There is also enlargement of the solitary glands close to the ileo-cæcal valve.

76. The mucous membrane of the large intestine very pale, and only in the lower part of a greenish-gray color.

77. Liver about seventeen centimetres from front to

back, twenty-three centimetres broad, and eight centimetres thick; externally grayish-red; smooth and tense; on section, very uniformly reddened, but only a small quantity of blood escapes on the whole, and that merely from the larger vessels. Acini scarcely perceptible, but on closer examination they are seen to be surrounded by a faint light-gray bile.

78. Gall bladder filled with a somewhat ropy, but otherwise clear, dark-gray gall.

79. Inferior vena cava moderately distended with blood, for the most part fluid.

This case is a truly remarkable example of the tolerance exhibited by the brain toward injuries of the gravest character. It seems almost miraculous that any one could possibly live twelve hours with a gunshot wound extending from the left frontal region and the apex of the anterior lobe to the external aspect of the middle lobe on the right side (just above the parietal eminence), completely traversing, therefore, in an oblique direction, the right hemisphere of the brain, and also the extra-ventricular part of the corpus striatum. It is only to be accounted for by the smallness of the projectile, and to some extent, also, perhaps, by the slight force which it possessed. The projectile must have been about the size of a pea (five millimetres in diameter), judging from an unused bullet which was found upon the man. The width of the track of the wound in the brain (anteriorly twelve, posteriorly eighteen millimetres), is therefore quite out of proportion to the width of the aperture of entrance in the integument (three millimetres), and in the bones (six to eight millimetres), and also to the projectile. There can, therefore, be no doubt that the track of the wound in the brain was originally much narrower, and that the width which it finally attained was due to the increasing effusion of blood. The symptoms, therefore, of

compression of the brain gradually developed as the extravasation increased.

That the force of the projectile was very slight is evident from the fact that not only was there no injury to the bone in the neighborhood of its place of exit from the brain, but there was even no laceration of the dura mater. The force of the bullet, primarily weak, was still further reduced by its having traversed two layers of bones in its passage through the left frontal sinus; and, on the other hand, the fact that both blood and cerebral matter found an exit through the frontal sinus may well have assisted to retard the development of the symptoms of compression. It thus happened that death resulted not from the brain primarily, but (in a medico-legal sense) from the lung, and, strictly speaking, was due to suffocation. Just as so often occurs in injuries to the head caused by contusion, a fatal œdema of the lung became developed in consequence of the pressure of the extravasated blood upon the medulla oblongata. How greatly the respiration was affected is shown by the interstitial emphysema, which was more extensive in this case than I have ever seen it in the asphyxia of cholera. We should notice, by the way, a combination in itself so very unusual, for, according to current notions, œdema and interstitial emphysema ought strictly to exclude each other.

The widespread indications that the digestive process had not yet terminated allow us to suppose that the suicide had taken his last meal shortly before the commission of the deed. In addition to this, there are various appearances, which I have grouped together in the summary, indicating the occurrence, in a very early stage, of numerous natural deficiencies, which amply warrants us in drawing conclusions as to the psychological development. The chlorotic condition of the aorta, which may well be connected with the endocarditis mitralis, certainly not very common in so young

a man; the obliquity of the cranium, together with the want of symmetry and somewhat defective formation of the brain, are all of them appearances well worthy of observation.

If there were any doubt about the case, and had it been made the subject of legal inquiry, we might summarize our opinions provisionally as follows:

1. That death resulted from œdema of the lung, consequent upon a gunshot wound of the brain.

2. That there is no evidence from the autopsy to contradict the assumption that the deceased came to his death by his own hand.

### CASE III.

A person known (suicide). Gunshot wound of the chest. Death occurring in twelve days. Double pleuritis, pericarditis and myocarditis, phlegmonous mediastinitis, exudative peritonitis.

F. K., a tradesman's assistant, twenty years of age, shot himself in the chest, on the afternoon of November 8, with a revolver held at a distance of six inches from his breast, he at the time having nothing on but his shirt. He was immediately brought to the Charité. The aperture of the wound is close to the left nipple, and measures eight millimetres in diameter: it is filled up with clots of blood, and the parts around are emphysematous. The patient complains of difficulty of breathing, and pain all over the left side, where there is also dullness on percussion over the posterior and inferior parts of the chest, extending to the angle of the scapula, with bronchial expiration. The bullet was found in the back, above the eighth rib, at a distance of four fingers' breadth from the vertebral column on the left side, and was removed on the following day. It was conical in shape, eleven millimetres long, and seven millimetres in diameter at its base, quite flattened on

one side, especially toward its apex. The opinion of the physicians in charge of the case was, that the bullet had passed in the soft parts outside the chest, and had been stopped by the rib.

On the third day pain came on quite suddenly in the region of the left colon, with great soreness. Manifest improvement on the subsequent days, but great mental excitement and restlessness. The aperture of the bullet's entrance closes, but inflammation and swelling occur round the opening which has been made in the back. The symptoms of inflammation in the left breast gradually diminish. Bowels somewhat confined. On the eighth day a red-colored serum commences to escape from the wound in the back, and flows more freely during expiration. At the same time there are evident symptoms of pleuritis on the right side, and also of pericarditis. Increased fever and difficulty of respiration. On the eleventh day a puncture was made in the left side of the thorax, in the fifth intercostal space, in the anterior axillary line, and 900 cubic centimetres of a dirty brownish-red serum evacuated. The respiration then for a short time became easier, but very soon after all the serious symptoms became much aggravated, and the patient died on the thirteenth day.

Post-mortem examination (lasting three hours) Nov. 22, 1875:

#### A. *External Examination.*

1. The body is that of a man of about twenty years of age; the height is 1.68 metre; bony conformation slight; adipose tissue in small quantity; muscles moderately developed.

2. Color generally pale, faintly yellow; lower part of abdomen greenish. The posterior parts of the body, the head and trunk generally, and also the extremities, covered with large, pale-bluish-red spots, interrupted

by white patches where exposed to pressure. The intensity of the color of these spots can be only slightly diminished by pressure. On an incision being made, numerous small veins filled with blood can be seen extending from the skin into the substance of the muscles. Fluid blood escapes from these, but there is nowhere any blood extravasated in the tissue.

3. Slight cadaveric odor; rigor mortis in the extremities.

4. Eyelids half closed; eyeballs tense; corneæ transparent.

5. No foreign body in nose or auditory meatus.

6. Lips open; teeth separated—the latter, in the upper jaw, very irregular. The tongue lying behind the teeth, and pale; the teeth of a brownish hue. No foreign body in the mouth.

7. Nothing abnormal to be found about the neck.

8. On the right side of the breast a line of four small brownish-red crusts, one after the other, but separated by intervals of various lengths. The first of these is over the fifth rib, the second over the sixth, the third and fourth are over the seventh. The upper one begins a finger's breadth below the right nipple, and at about the same distance on the inner side. The whole line is ten centimetres in length; its direction is somewhat obliquely downward and outward. On cutting into these spots there is neither deposit, tumefaction, nor redness. On cutting through them there are no spots of blood, but only desiccated patches, extending in the highest crust through the whole thickness of the corium, in the others only through its most superficial layers. There is a faint, quite superficial, crescentic, red spot, rather more than a thumb's breadth, on the outer side of the right nipple. This, on being cut through, is found to involve only the outermost layers



of the corium. There are also a few more brown marks on the external aspect of the lower part of the thorax on the right side.

9. On the left side, two millimetres above the nipple, but within the areola, a small round spot about 1.5 millimetre in diameter, somewhat depressed, of a dirty brownish color, and covered with a dry pellicle. When this is cut into, a somewhat hard cord, traversed by numerous small vessels filled with blood, and showing minute spots of blood, is found to extend obliquely outward and backward through the substance of the gland into the subcutaneous fat. No canal can be discovered, but in a direction outward and downward there are some scattered spots, slightly moist, and blackish-red in color, both in the subcutaneous adipose tissue and in the pectoral muscles, extending down to the ribs, in a circumference of about seven centimetres. They are most strongly marked in the direction toward the axilla, where a few of these sanguineous infiltrations extend to the lymphatic glands. These latter are enlarged, hard, bluish-red externally. On being cut through they are found to be very moist, and the whole of their cortical layers of a dark bluish-red color.

10. Posteriorly, on the left side of the chest, at a distance of two fingers' breadth from the middle line, on the tubercle of the ninth rib, the skin is separated from the subjacent parts, and exhibits a wound with sharply defined edges. The wound is four centimetres long and two centimetres and a half wide, taking almost the exact direction of the rib—viz., from within above, outward and downward. It is covered with slightly dull grayish-red serum, and looks quite clean where this latter has been removed; it penetrates the soft parts in a terrace-like form, to a depth of eight millimetres, and terminates in the muscles. The base of the wound is pale and smooth in the external portion; internally it

is covered with a soft, velvety, very red film, which contrasts distinctly with the neighboring parts. Only in an upward direction is there any blood infiltration of the muscular tissue seen on incision being made into the parts around.

11. On cutting more deeply into the muscular layers lying externally, we come into a shallow cavity which communicates by a narrow opening with the base of the wound above described; it measures four centimetres and a half transversely, and three centimetres perpendicularly; its outer surface is tolerably smooth, and, like the base of the external wound, covered with a similar soft, velvety, red membrane. On opening this cavity, the body being placed on its side, air emerges from beneath with an audible sound, and a small round opening not quite two millimetres in diameter is found on the upper part of the base of the cavity. This penetrates deeply the intercostal space between the eighth and ninth ribs, but on introducing a fine probe it cannot be passed directly into the thoracic cavity. The spiral direction of the track of the wound makes it difficult to pass the probe deeply.

12. The two spots described in Nos. 9 and 10 are now connected by means of a free incision carried transversely round the thorax. The muscular septa in the neighborhood only of the first spot are found to be distended with dark-red serum, but otherwise there is no trace of any connection between the two wounds.

13. Four fingers' breadths external to and below the left nipple there is a roundish opening, scarcely one millimetre in diameter; the borders of the wound are sharp and rather dry. On incisions being made in various directions, dark-red bloody discolorations are found in the corium below this opening, and these are continuous with those described under No. 9. (This is the aperture of the puncture, as stated by the assistant physician

in charge, Dr. N.) No distinct canal can be traced inward from this opening. On the other hand, on cutting somewhat more deeply into the intercostal muscle, serum and bubbles of air escape from beneath, and there is a softish, reddish streak to be seen traversing the tissues.

14. Nothing abnormal about the external organs of generation.

15. Anus closed; some fecal matter round about it.

16. No traces of any other external injury.

*B. Internal Examination.—I. Thorax and Abdomen.*

17. An incision is carried from the chin to the symphysis pubis, dividing the integumentis of the neck and thorax, and opening the abdominal cavity. Adipose layer slight; muscles of a dull-red color.

18. The omentum found to be connected by adhesions, which are easily separable, with the anterior part of the abdominal wall and the right border of the liver. This latter organ is somewhat deeply placed, and completely covered by a delicate false membrane, which can be easily stripped off; on the left side it is dry and translucent; on the right side more greasy-looking, dull and yellowish in color. The omentum is of a deep-red color, its veins being particularly full (this most marked on the right side); in the neighborhood of the gall bladder it is covered with opaque, yellow false membrane, that cannot be stripped off, and this extends as far as the lumbar region.

19. The intestines distended with gas, covered in many places with fine, very superficial, red, vascular networks—generally, however, pale; the viscera of the pelvis only dense bluish-red, with numerous large, prominent veins.

20. The pelvis contains about a tablespoonful of slimy, yellowish-red, opaque serum.

*(a) The Thorax.*

21. During the time that has elapsed since the examination of the wound described in No. 10, a quantity, amounting to eighteen cubic centimetres, of thin, pale-reddish, turbid serum, has escaped from this spot into a vessel placed to receive it.

22. On removing the integuments from the thorax, the tissues are found to be considerably infiltrated with blood, on the left side, in the fourth and fifth intercostal spaces; in the first of these at a distance of three, and in the second at a distance of two fingers' breadth from the sternum.

23. On cutting into the wall of the thorax on the right side, fluid escapes. This is immediately collected from the pleural sac. It is found to amount to 800 cubic centimetres, is thin, relatively only slightly turbid, and of a yellowish-red color. It contains numerous large, very loose flakes, yellowish-white in color. The surface of the pleura on this side is everywhere covered with somewhat soft, dirty-yellowish deposit, which can be stripped off.

24. The sternum being removed, the whole of the mediastinum is found to be tough and difficult to cut, many of its smaller vessels filled with blood, and the tissue throughout of a gelatinous appearance and of a dull, brownish-yellow color.

25. On the left side the anterior portion of the lung is agglutinated to the wall of the thorax for a length of eight centimetres. After it has been separated we come to a space filled with fluid. The fluid is ladled out; it measures 900 cubic centimetres, is somewhat thick, but flows freely, is of a palish-red color, has a faint odor, and contains a few flakes. This cavity is the pleural sac, the walls of which, except where they are agglutinated, are covered with thick, dirty reddish-yellow,

closely adherent deposits, with red infiltration in some places. The upper and lower lobes are agglutinated together below. There are also adhesions, which can be easily broken up, between the thoracic wall and the lower part of the upper, and the anterior and lower part of the lower lobe. These adhesions extend over a surface as large as a child's hand. In front, between the pericardium and lungs, is a closed space, containing large shreds of gelatinous coagula. This cavity is found to be an incapsulated part of the pleural sac.

26. The pericardium much thickened externally. Internally, extensive deposit of rough, stiff, elastic membrane, both on the parietal and visceral layer. The cavity contains about forty cubic centimetres of pale-reddish serum, mixed with yellowish flakes. The firm deposit is most abundant on the anterior portion of the parietal layer; and corresponding to this the heart is covered anteriorly by similar false membrane.

27. The heart itself is somewhat larger than the closed fist of the man. It is rigid, its surface slightly arched, comparatively pale in color. The right auricle contains about ninety cubic centimetres of dark-red coagulated blood. The right ventricle contains a very small quantity of fluid blood, but a few large, gelatinous, buffy masses. The left auricle contains scarcely two tablespoonfuls of dark blood, very slightly coagulated. The left ventricle is almost empty.

28. The heart is then removed. The arterial valves close. On being opened, a marked red infiltration throughout the lining membrane. The muscular tissue firm; on the right side grayish-red; eighteen millimetres thick. On the posterior wall it is closely marked, to a depth of eight millimetres, with very extraordinary yellow spots and stripes. These spots being immediately subjected to microscopical examination show the primitive muscular fasciculi to be without

cross-markings and filled with coarse fat granules. No other abnormal appearances.

29. A very large quantity of dark, partly buffy coagula escapes from the larger vessels of the thorax.

30. The left lung is rather flat, and contains but little air. Its serous covering on the upper and anterior parts is thickened, opaque, here and there yellowish; on the inferior and posterior parts of a dull-red color, softer and more lubricous, dotted over in several places with soft, gray, roundish granulations. In three places the covering of the lung is relatively smooth, and shows scarcely any deposit. These places are circumscribed by tolerably sharp edges, with salient and receding angles. There are similar places corresponding to these on the wall of the chest. The first of these spots is close to the anterior border of the upper lobe, near the agglutination described in No. 25. The second spot is on the lower tongue of the upper lobe. The surface of the lung is here induplicated in two directions, meeting in an angle, and taking a course toward the spot immediately to be described. The third spot is on the lower and anterior aspect of the lower lobe, and here, in a line, one below the other, we find (*a*) on the surface, turned to the cleft between the upper and lower lobes, one centimetre from the border, a roundish depression of a reddish color, three millimetres in diameter, exhibiting, on incision, a perforation of the pleural investment; (*b*) two round spots close to one another, two and a-half to three millimetres in diameter; one of which is upon, the other close in front of, the border. These being cut through, are found to be yellowish-white channels in the pleural membrane and the adjacent pulmonary tissue. The latter is on this spot somewhat firmer, and of a deep-red color to a depth of eight millimetres. On section, the tissue in the upper lobe is found to contain very little air, is of a red color

throughout; but it is only from the larger vessels that any blood escapes. The lower lobe contains still less air, and is moderately red; dark thick blood escapes from the vessels.

31. The right lung is covered throughout its whole extent with firmly adherent but separable deposit; on the upper and middle lobes the pleural covering is whitish and thickened. On section, the tissue is found to contain but little air, and is somewhat gray in color; this is the case also in the lower lobe.

32. On the inner aspect of the thoracic wall on the left side, exactly upon the eighth rib, at a distance of four fingers' breadth externally from the vertebral column, there is a solution of continuity, twelve millimetres long and five millimetres wide, of a somewhat long oval form, the long diameter being parallel to the axis of the rib, the borders gradually sloping off, and of a yellowish color. In the base of this wound the bone lies exposed. In order to examine the parts more closely, this rib and the ninth are removed together, and it is now seen that, at the spot corresponding to the external wound, the inner surface of the eighth rib, for a length of fourteen and a breadth of ten millimetres, is quite laid bare, and the soft parts stripped off. At this spot there are two small linear fragments of lead, the larger three, the smaller one and a-half millimetres long, wedged into the compact tissue of the bone. Round the denuded portion of the rib the tissue is raised up like a wall, thickened and much reddened. Beyond this wound, anteriorly, and on the same rib, a triangular, grayish-yellow spot is found on the costal pleura, which exactly corresponds with a similar triangular spot on the inferior lobe of the lung, immediately below the smooth spot described in No. 30, and in the direction of the appearances detailed under (*a*) and (*b*) in the same paragraph. A continuous canal connects

the denuded portion of bone with the cavity mentioned in No. 11.

33. In the anterior lateral portion of the circumference of the left pleural cavity, in the intercostal space between the fourth and fifth ribs, three centimetres from the attachment of the cartilages, is a deepened cleft, placed transversely to the course of the third rib, seven millimetres long, and rather more than three millimetres wide; running somewhat obliquely from above and within, downward and outward, ending above the border of the fifth rib, and separating the fasciæ superficially. The floor of this cleft is tolerably smooth, slightly scaly. The borders of the cleft are sharp, neither thickened nor reddened; in its base several small, angular, blackish fragments of lead are contained in the tissue. This spot corresponds to an area of the pulmonary pleura, free from deposit, and which had previously been adherent (No. 25).

34. Lower down in the intercostal space, between the fifth and sixth ribs, and almost exactly in the middle, there is a somewhat long cleft, with tolerably straight borders; it is scarcely two millimetres long, and its lateral edges are close together. It leads directly externally into a small canal through the muscles. Its position corresponds to the external wound described under No. 13, but there is no open passage from one to the other.

35. The veins of the neck are tumid, and contain thick blood; arteries and nerves normal.

36. The œsophagus contains a yellowish-gray fluid, and numerous fragments of food. Mucous membrane pale. Palate much reddened, with very prominent venous networks; follicles of the tongue slightly swollen.

37. The larynx contains a few similar yellowish-green fragments of food. Below, a little frothy liquid in the



air tubes. Mucous membrane somewhat thick ; that of the air tubes very red, owing to numerous vascular networks, which are distinctly visible.

38. No change in the walls of the aorta ; only a little thick blood in its descending portion.

(b) *The Abdomen.*

39. The spleen adherent on its upper aspect,  $12\frac{1}{2}$  centimetres long,  $7\frac{1}{2}$  centimetres broad, 3.6 centimetres thick, firm on section, and pale ; the pulp rather grayish-red and uneven, containing much blood, and slightly indurated, but only in a part which is covered externally by dirty, yellowish-white membrane. Follicles small and gray.

40. Left kidney 12 centimetres long, 5 centimetres broad, 3.2 centimetres thick. The capsule easily separated ; surface smooth, brownish-gray-red in color, superficial veins slightly distended. On section, somewhat general faintly-gray cloudiness of the cortical substance, which appears bluish-red. The Malpighian corpuscles prominent on the cut surface, slightly reddened.

41. The left supra-renal capsule reddish-gray in its cortical substance ; tissue between it and kidney abundant and full of blood.

42. Right kidney 11 centimetres long, 6 centimetres broad, 3.2 centimetres thick. The surface somewhat more darkly red than on the other side. In other respects, the same appearances both here and in the supra-renal capsule as on the other side.

43. Urinary bladder strongly contracted ; contains a tablespoonful of dark, yellowish-brown urine. In other respects normal, as are also the prostate and vesiculæ seminales.

44. Testicles, both superficially and in their substance,

somewhat bluish-red in color, owing to numerous veins ; in other respects normal.

45. Stomach rather capacious, containing a large quantity of greenish liquid and numerous fragments of food. Mucous membrane pale, whitish-gray, tolerably thick, somewhat wrinkled toward the pylorus.

46. The duodenum contains a large quantity of bilious, pasty fluid. A drop of bile exudes on pressure from the orifice of the gall duct, and also when the gall bladder is pressed.

47. The liver twenty-five centimetres broad, twenty-two centimetres from front to back, and eight centimetres thick ; the whole of its external surface covered with yellowish-white false membrane. On incision, the large vessels only found filled with blood. The tissue pretty uniformly brownish-gray, brittle, somewhat dull-looking. The acini large, externally yellowish, internally grayish-red. Gall bladder slightly colored ; bile grayish-brown, with yellow flakes.

48. Pancreas somewhat flabby ; its posterior portion infiltrated with blood.

49. The mesenteric glands somewhat enlarged ; their cortical portions somewhat white. But little fat about the mesentery.

50. The small intestine contains a large quantity of pasty, bilious matter ; in the lower portion the contents are feculent and foul-smelling. The mucous membrane is rather thick ; in the jejunum reddened only in a few spots ; a few turgid veins in other places. The only change in the glands is a very slight swelling of the solitary follicles in the lower part of the ileum.

51. The large intestine contains soft fæces ; mucous membrane rather thick ; some difficulty in removing the adherent fæces ; nothing abnormal.

II. *The Cranial Cavity.*

52. The soft parts cut through according to the directions, and reflected backward and forward ; nothing abnormal.

53. The skull of a somewhat long oval form, much reddened posteriorly, and presenting a pitted depression on the frontal bone, just in front of the coronal suture, and to the right of the mesial line. On section, diploë scanty but red. Bones of skull four millimetres thick. Internal surface somewhat irregular, in consequence of various depressions in the middle part of the frontal bone and along the sagittal suture ; these are apparently due to elevations of the pia mater.

54. The dura mater translucent, thickened, and copiously supplied with blood in the middle and anterior portion. The longitudinal sinus rather large, filled with buffy coagula. Inner surface of the dura mater on both sides smooth, exhibiting in places networks of distended vessels, but no abnormal deposit.

55. The surface of the cerebral hemispheres symmetrical in shape. The convolutions rather large. Veins very large, much distended with dark blood, particularly at the back of the head.

56. Pia mater everywhere translucent, exhibiting large, wart-like excrescences along the median longitudinal fissure and under the frontal bone.

57. Scarcely any fluid in the lateral ventricles. Posterior cornua obliterated. Choroid plexus and vessels of the velum of a dark-red color.

58. On section, the cerebral hemispheres found to be very moist, and the veins much distended. From these latter large drops of blood exude all over the cut surface. Gray substance shining and of a dark reddish tinge.

59. The gray substance of the large ganglia reddened; the tissue very moist throughout. Corpora quadrigemina pale.

60. Fourth ventricle empty. Cortical portion of cerebellum uniformly reddened; veins of medullary substance distended.

61. The arteries at the base of the brain regular in their course, filled with dark blood. In the pia mater of this part nothing abnormal.

62. The gray substance of the pons Varolii and medulla oblongata slightly reddened.

63. The sinuses at the base of the skull with dark, thick blood. The dura mater thin and delicate. Condition of the bones normal.

There is much that is worthy of remark about this case. Apart from the fact that the extensive peritonitis did not occur as a clinical symptom (we must now regard as such the pain in the region of the left colon, which was noticed on the third day of the disease, but which afterward quite subsided), the rapidity with which death occurred must obviously be explained by the pericarditis and the resulting myocarditis. Some time ago (in my *Archiv*, 1858, vol. xiii., page 266), I reported several cases of malignant pericarditis, in which I demonstrated acute fatty metamorphosis of the muscular tissue, and showed that the morbid process advanced from without to within. I have several times since observed this very dangerous complication, of which the case before us is another and a very instructive example.

The peritonitis, and also the pericarditis, and the pleural inflammation on the right side, have no immediate connection with the wound caused by the bullet. The probability is that all of these are the result of the phlegmonous mediastinitis, which in this case quite takes the form of a malignant erysipelas. The occurrence,

however, of this mediastinitis is not a little extraordinary, for the bullet did not immediately injure the mediastinum; and, moreover, the anterior portion of the track of the bullet showed no indications of mischief, for it was completely closed by the first intention. There is, therefore, nothing else but to assume that all these morbid processes have extended themselves from the posterior part of the track, which was certainly in an unhealthy condition, and which was converted into a perforating wound when the bullet was excised. It is, therefore, very extraordinary that when the examination was made there was no disagreeable odor about the opening in the back.

Notwithstanding this, however, a propagation of infectious matter from this quarter is indicated by the extensively diseased appearance of the left pulmonary pleura, and the alterations so unusually great for so comparatively short a period as twelve days. The pleura was so thickened, dull and wrinkled, and so dotted over posteriorly with real sprouting granulations, and in large area almost trachomatous, as to present an appearance such as is only met with in very malignant forms of inflammation. Those portions of the pleura primarily agglutinated appeared, after separation, both on the lung and on the wall of the chest, so smooth and delicate that they looked quite normal when contrasted with what has just been described.

The autopsy has not confirmed the supposition that this was a case in which the bullet, in consequence of the retracted position of the left side of the chest, took a curved direction through the external soft parts from the place of entrance near the nipple, until it was stopped posteriorly by the eighth rib. Certainly, it appeared at first as if the sanguineous infiltrations (No. 9) extending to the axilla corresponded with the course taken by the bullet. But the further examination showed that the bullet had taken an entirely opposite direction,

and that the infiltrations were caused only by the loose cellular tissue being filled with blood in the direction of the lymph current. Even the axillary glands were so infiltrated with blood as to prove distinctly that their appearance was due to absorption. I draw particular attention to this, inasmuch as I am well aware that in medico-legal practice due regard is not paid during life to this form of propagation of sanguineous infiltrations, so very important, and yet so often misleading, owing to the great possibility of a false interpretation.

The shot has entered just above the left nipple, and taken an oblique direction outward, downward, and backward; it has left the wall of the chest, first of all, in the fourth intercostal space, and then entered the pleural cavity; it has then grazed the lung, but only a small portion of it—viz., the surface of the left lower lobe turned toward the cleft between the two lobes; it has then passed over the internal surface of the eighth rib, at a distance of four fingers' breadth from the vertebral column, and close to this spot perforated the eighth intercostal space. Here it remained lying in the soft parts under the skin of the back until its early removal.

Strange to say, at the end of the channel of entrance, just where it passes obliquely over the upper border of the fifth rib, several small pieces of lead, obviously portions of the bullet, were found covered up in the soft parts. At the first glance they might be compared with the fragments of lead embedded in the bone at the posterior part of the circumference of the thorax, where the rib has been laid bare by the bullet. However, a closer examination proves that their origin is different. The latter were obviously splintered off when the bullet struck against the rib, and they correspond probably to the small scratches found on the smooth compressed surface of the much-flattened bullet. The former, on the other hand—those which are closed up in the an-

terior wound—could not have been splintered off by the rib, for its border, although very close to the bullet's course, has not been touched by it. These must, therefore, have been stripped off previously, perhaps in the grooved barrel of the revolver, and driven into the wound when the shot was fired.

The medico-legal conclusions in this case are as follows:

1. That death was caused by a series of violent inflammatory attacks in the thoracic and abdominal cavities, inflammation of the heart being the principal factor.
2. That these inflammatory attacks were the result of a gunshot wound of the thorax.
3. That there is nothing to contradict the assumption that the fatal shot was fired by the deceased himself.

#### CASE IV.

A twin child, still-born at the middle of the tenth (lunar) month. Indications of immaturity. Inflammatory oedema (erysipelas) of the scrotum, pharynx, and brain. Incipient white hepatization of the lungs.

The case is peculiarly interesting, from the fact that the other child was born alive and throve well, and that the mother, to all appearances, had never suffered from syphilis or from any puerperal affection.

Post-mortem examination (lasting one hour and a half), December 13, 1875:

##### *A. External Examination.*

1. The body is that of a new-born male child, and is 46 centimetres in length, 2120 grammes in weight; for the most part regularly formed, though the limbs are rather short. The subcutaneous fat is moderate in quantity; the muscles somewhat poorly developed. The legs slightly curved.

2. The umbilicus projects about  $1\frac{1}{2}$  centimetres, and has the remains of the umbilical cord, properly ligatured, attached to it. This latter is  $10\frac{1}{2}$  centimetres in length, and averages  $1\frac{1}{2}$  centimetres in thickness; its extremity presents a flattened surface, the cord itself is rounded, tense, gelatinous, and presents no appearance of dryness.

3. The color of the body is generally pale, even over the abdomen; yellowish about the head, of a washy pale-red over the back, and likewise (though of a darker red) over the right side of the head and face. Pressure, however, has caused portions of these latter parts, the right external ear especially, to look quite pale. Firm pressure with the thumb causes the greater part of the redness to disappear; on incision, the venous network for some depth is seen to be filled with blood, and a small quantity of fluid blood escapes.

4. The skin of certain portions of the trunk, especially about the groins, is covered with a white caseous layer.

5. Rigor mortis well marked in the upper extremities and lower jaw; less marked elsewhere.

6. The head of oblong shape, the occiput rather small. The long diameter  $11\frac{1}{2}$  centimeters, the transverse  $9\frac{1}{2}$  centimetres, the oblique 11 centimetres. Pretty well covered with short, dark-brown hair, up to two centimetres in length, and extending rather far over the forehead and face. The bones of the head are readily movable, somewhat overlapping each other, the right parietal bone especially projecting over the left. Both fontanelles small, the anterior one 2 centimetres broad,  $3\frac{1}{2}$  centimetres long; the posterior 1 centimetre each way.

7. The eyelids closed. The eyeballs tense, the corneæ slightly cloudy, the pupils large and quite open; no trace of pupillary membrane.



8. The nasal cartilages firm, the nasal openings free.
9. Mouth closed, upper lip very prominent, both lips slightly red. Tongue behind the jaws pale reddish. No foreign body in the mouth.
10. Ears large, cartilages deficient in firmness, passages empty.
11. Neck movable, but within the ordinary limits; nothing abnormal in other respects.
12. Thorax somewhat convex. Circumference at lower part 27 centimetres, measurement across shoulders 13 centimetres.
13. Abdomen flat. Anterior spinous processes  $6\frac{1}{2}$  centimetres apart, crests of the ilia  $7\frac{1}{2}$  centimetres at greatest distance apart.
14. External organs of generation properly formed, both testicles descended. The scrotum pale, swollen, translucent; its subcutaneous tissue, on section, found to be infiltrated with a deep yellow, watery fluid, which escapes in abundance on pressure.
15. Anus closed; no foreign body present.
16. The finger and toe nails somewhat soft; the former reaching the tips of the fingers, the latter not extending to the end of the toes.
17. The cartilaginous layer having been gradually removed, no centre of ossification discoverable in the lower extremity of the right femur. The same deficiency observable on the left side on making a longitudinal incision. At the boundary between the bone and cartilage a small, slightly yellowish layer visible.
18. Incisions having been made into the upper ends of the tibia, fibula, femur, and humerus on both sides, nothing abnormal discovered at the margin of ossification. No formation of nuclei in the epiphyses.

19. No sign of any injury to the body.

B. *Internal Examination.*—I. *Thorax and Abdomen.*

20. The integuments divided by an incision from the chin to the pubic symphysis and carried to the left of the umbilicus; the abdominal cavity opened. The diaphragm found to correspond to the lower border of the fourth rib.

21. The umbilical vessels almost empty; on incision only a drop of semi-fluid blood escapes.

22. The liver fills the whole of the epigastric region, so that the stomach is not visible. The large intestine distended by meconium, and of a green color; the greater part of the transverse colon, the cæcum, and a loop of the sigmoid flexure prominently visible, but in their normal situation. The interval between the two latter filled by the much-distended bladder. Numerous loops of the small intestines occupy the remainder of the space; these are somewhat flattened, from mutual pressure, apparently empty, of a rosy grayish-white color; a few congested veins to be seen only in the omentum, which is devoid of fat, and in the mesentery. On turning up the liver, the stomach is seen to be pale and closely contracted.

23. No foreign body in the abdominal cavity.

(a) *Thorax.*

24. The trachea having been ligatured in the prescribed manner, and the sternum (still almost entirely cartilaginous) having been removed with the costal cartilages, the thoracic organs are found to be in their regular position. The upper part of the mediastinum is occupied by the very large thymus gland, the left lung is withdrawn behind the pericardium, so that an interval

almost as wide as the little finger separates the thoracic wall from the latter structure; the right lung covers the lateral portion of the thymus and of the pericardium, and almost all the right portion of the diaphragm.

25. The prominent portions of both lungs present a pale grayish-red, clearly lobulated appearance, the more distinct by reason of the dark congested state of large superficial vessels; in many places the color is almost yellowish-red. These parts are flabby, and do not crepitate when handled.

26. The pleuræ empty, their surface moist. On the diaphragm, especially on the left side, small, dark-red, injected patches visible.

27. The pericardium contains about half a teaspoonful of a dark brownish-yellow, but clear fluid, The internal surface pale and smooth. The heart somewhat larger than the closed fist of the child, firm, its surface slightly arched, pale in color; the superficial veins filled with blood up to their roots; the auricles, with their appendages, bluish-red, moderately distended.

28. On incision the right auricle found to contain scarcely a teaspoonful of fluid blood. Also the right ventricle contains only fluid blood, but in less quantity. The left ventricle is almost empty; about half a teaspoonful of fluid blood in the auricle.

29. The heart is now removed and further incisions made. All the valves are regular in form, of a slightly reddish tinge (from imbibition). The foramen ovale still perfectly open. The muscular tissue pale, somewhat grayish-red.

30. Rather less than a teaspoonful of dark fluid blood escapes from the large vessels of the thorax.

31. The thymus gland is now carefully removed. It is  $4\frac{1}{2}$  centimetres broad, 4 centimetres long, and 9

millimetres thick, grayish-white, medullary-looking in color, and presenting the same appearance on section.

32. The veins of the neck tumid with dark fluid blood. The arteries also contain blood of a similar character. The large nerves are pale and apparently normal.

33. The tongue, with the organs of the neck, removed from below, as directed. The posterior portion of the mouth contains no foreign body. The uvula and soft palate found to be much swollen, pale and gelatinous; on incision a yellowish fluid escapes.

34. The mucous membrane of the epiglottis and aperture of the larynx is similarly, though less, swollen and thickened by watery infiltration; similar though less decided swelling of the mucous membrane of the pharynx, which part is somewhat reddened throughout, owing to a superficial fine network of vessels.

35. The upper part of the œsophagus contains some yellowish fluid; mucous membrane decidedly pale.

36. The epiglottis folded together laterally. The glottis very narrow; larynx and trachea empty, mucous membrane delicate and thin; on the softer spots superficial vascular network visible.

37. After dividing the trachea above the ligature, the remaining thoracic viscera were removed together and placed in a vessel with water. They were found to sink.

38. The external surface of the lung posteriorly is of a uniform, rather bluish-gray-red color, but without marked congestion of the superficial vessels. The surface of these posterior portions, especially on the left side, is for the most part perfectly smooth. On closer examination no air vesicles are to be seen, but on many of the lobules small, whitish-gray, racemose marks.

39. Each separate lung sinks in water, as do also separate lobes and small fragments, even from the generally bright-colored portions of the anterior border.

40. The lower portion of the trachea and its branches are empty but deeply reddened.

41. Incisions being made, the tissue of the lung appears grayish-red, very moist and glossy, and exhibits clusters of small, firm, whitish-gray spots corresponding to the internal parts of the lobules. There is no crepitation, and neither froth nor air bubbles escape by pressing the sides of the cut surfaces, but only a little clear fluid and a few drops of blood. Even when incised under water no air bubbles escape from the tissue. The lungs were set aside for microscopical examination.

42. The lower portion of the œsophagus is empty and pale.

43. The aorta contains a little fluid blood; its internal surface is somewhat reddened. The vessels are given off irregularly from the thoracic portion.

44. The foramen ovale is perfectly open (12 millimetres in circumference), and presents on its anterior wall an oblong, flat, dark, grayish-red projection, which, on section, is found to consist of coagulated blood deposited in the wall of the heart.

(b) *The Abdomen.*

45. The spleen 4.1 centimetres long, 2.2 centimetres in its greatest breadth, 8 millimetres in its greatest thickness; its upper end wrinkled and turned inward, dark brownish-red in color, flabby consistence on section, the follicles small; pulp fragile, abundant, brownish-red.

46. The left supra-renal capsule 25 millimetres long, 32 millimetres broad; on section, very vascular,

brownish-red almost throughout, the different portions distinguished with difficulty, scarcely any fat in the cortex.

47. The left kidney, 50 millimetres long, 20 millimetres broad, 18 millimetres thick. The capsule easily separable, the surface showing deep divisions, but otherwise smooth, pale, and with a faint brownish-red tinge. On section, the cortical substance similarly colored; the medullary substance for the most part grayish-red, without cloudiness or deposit, but of a deeper red in the external portions. A little urine in the pelvis of the kidney and ureter.

48. The same organs on the right side in much the same condition.

49. The urinary bladder contains clear fluid; the mucous membrane pale.

50. Both testicles in the scrotum, of normal size and somewhat bluish-red appearance.

51. The duodenum now opened on its anterior aspect. It is seen to be full of soft pultaceous contents, whitish in color, with a slight tendency to yellow. The mucous membrane itself is faintly reddened. The papilla of the biliary duct is open and very prominent, and from it a drop of watery bile exudes on pressing the gall-bladder.

52. A thin transparent layer covers the wall of the stomach; the mucous membrane is thrown into marked longitudinal folds, which exhibit patches of redness. On some of these patches fine vascular networks are visible; other patches are uniformly dark red.

53. Pancreas somewhat firm, pale anteriorly, slightly reddened posteriorly.

54. The liver 10 centimetres broad, 58 millimetres long, and 22 millimetres in thickness, pretty uniformly reddened, exhibiting at one spot on the anterior sur-

face both of the right and left lobe a flattened extravasation of fluid blood under the capsule. The substance of the organ flabby, uniformly grayish-red on section, turning to a uniform gray after pressing out the blood, which escapes pretty freely. The lobules not clearly recognizable. At the portal fissure a small whitish firm body, the size of a hemp-seed, is firmly adherent to the capsule of the liver.

55. The mesentery contains many whitish-looking, slightly enlarged lymphatic glands.

56. The small intestine contains flocculent, pul-taceous, slightly yellowish-white, epithelial matters. The ileum is much contracted; its contents are brownish-yellow, feebly resembling meconium, and are more abundant near the ileo-cæcal valve. The large intestine is filled with meconium. The mucous membrane throughout is tolerably thick, faintly reddened, greenish in the parts containing meconium; no other change.

57. The large vessels on the vertebræ are almost empty.

## II. *The Cranial Cavities.*

58. The integuments having been divided as directed, and turned aside, are seen to be infiltrated with a yellowish fluid, the infiltration extending to the periosteum. On the right side, especially at the posterior part, there is also a pale-reddish infiltration of all the tissues down to the periosteum. Congestion of the veins up to their small branches. The scalp exhibits in places thick red spots, as large as a flea-bite or a lentil; these, on incision, are found to be the result of uniform sanguinary infiltration.

59. The skull cap is now sawn through, the dura mater divided, and the brain, which is very soft, removed. A teaspoonful of clear fluid found at the base of the skull, but nothing else abnormal in this part.

60. The bones of the skull relatively thin, movable.

61. On the inner surface of the dura mater, near the coronary suture, there are a few minute red specks of blood in the tissue. The longitudinal sinus contains only fluid blood.

62. The brain itself regularly formed; the pia mater delicate, and containing everywhere very numerous venous networks.

63. After cutting through the hemispheres, each lateral ventricle is found to contain a small quantity of fluid; the lining membrane of these cavities somewhat firm, the veins on the surface congested, as are also those of the velum and choroid plexus.

64. The section through the hemispheres shows a remarkably pale tissue of a peculiar yellowish-white color; the medullary substance being with difficulty distinguished from the cortex, the only difference being that the latter appears paler and whiter than the former. The medullary substance is also very moist and shining, and of gelatinous appearance. These parts put aside for microscopical examination.

65. The optic thalamus, corpus striatum, and the corpora quadrigemina are pale-yellowish in color and moist throughout.

66. The cerebellum in the same condition; a few congested veins visible only in the corpus dentatum. The fourth ventricle empty.

67. At the base of the brain very marked congestion of the veins of the pia mater, especially at the fissure of Sylvius.

68. The pons Varolii somewhat firmer in consistence, pale on section.

69. The medulla oblongata very firm, but at the same time very pale.



70. There are no injuries to the bones at the base of the skull.

*a.* On microscopical examination of the lungs we find that the ends of the bronchioles, the infundibula, and the alveoli, are completely packed with dense accumulations of epithelial cells, some of which are full of fine, shining granules (myelin).

*b.* On examining the brain, the white substance is found to contain scattered, highly refractile globular granules; the gray substance numerous pale-gray nucleated cells.

This case presents a series of post-mortem appearances of an extremely singular character. The most important are those which, even at first sight, appeared to be connected together, viz., the œdema of the scrotum, the œdema of the uvula, soft palate, pharynx, and upper parts of the larynx, and likewise the œdema of the brain. All these parts were found to contain a clear but yellowish fluid, abundant in quantity, and removable by pressure; in the brain the yellow color somewhat less marked, but unusually decided in the scrotum and uvula. There can be no doubt as to the acute nature of these appearances. But what is their import? The absence of venous hyperæmia in the affected parts is most decisive evidence against attributing the appearances to effusion, the results of passive congestion. We may, however, with some show of truth, refer the symptoms to a general dropsy. If we consider by itself the state of the soft palate, pharynx and larynx, there need be no scruple about designating it as acute laryngopharyngeal œdema. This œdema, however, belongs to the class of the so-called active processes; as a general rule, it is purely an erysipelas. In my work on "Special Pathology and Therapeutics" (Erlangen, 1854, vol. i., pp. 209, 217) I have minutely discussed the conditions of this form of œdema, and I can only

say that my subsequent and much-enlarged experience has convinced me of the relationship between this affection and erysipelas ; or, I should rather say, of the identity of the two processes. I have repeatedly observed in new-born infants, even clinically, a primary œdema of the scrotum followed by acute œdema of the pharynx and larynx, sometimes, indeed, assuming a phlegmonous type. These are allied branches of that affection which, when it occurs in a more diffused form, occasionally presents the appearance of the so-called sclerema, or induration of the cellular tissue (see my "Gesammelten Abhandlungen," pp. 112, 701).

In the case before us there are two appearances indicative of the existence of several general derangements of an allied kind. The first of these is that peculiar infiltration of the soft parts of the head with a deeply yellowish fluid, the signification of which was suggested in the external examination, and the second is that peculiar, almost brownish coloration of the pericardial fluid. That these appearances were not due to post-mortem changes is evident from the fact that there were no signs of decomposition present.

Very unusual, and likewise very remarkable, is the œdema of the brain, a condition which was found to be associated with general paleness of the organ, and marked fatty metamorphosis of the cells of the neuroglia of the medullary substance. I have no hesitation in assigning this condition to the same group as before, and in describing it as acute œdema, or even as erysipelas, of the brain.

Had the mother suffered from puerperal fever, the further interpretation of the morbid appearances could have presented less difficulty. But not only was the mother perfectly healthy, but the other child was free from all similar symptoms. The fact is, therefore, that the case is one of a congenital affection which must have become developed *in utero*. As I have before

shown (see my *Archiv*, vol. xxxviii, p. 135, 1867; vol. xlv, p. 472, 1878; *Geschwülste*, vol. ii, p. 469), fatty metamorphosis of the white substance of the brain, and more especially incipient white hepatization of the lungs, are very frequently met with in syphilitic cases. But I have already alluded to the fact that the mother showed no signs of syphilis, and although syphilis in the father was not excluded by such evidence, there was no real support for such an assumption. Besides, as I have before mentioned, both the conditions in question occur in new-born children, free from any suspicion of syphilis. We cannot, therefore, go further into the question of causation. The case may be provisionally described as a rare example of congenital erysipelas, involving visceral as well as external organs.

From a legal point of view the case is extremely interesting, not only because, in an otherwise viable child, death was the result of such latent morbid processes, but also from the fact that there were such extraordinary signs of immaturity in a child of the tenth month. Not only were the nails imperfectly developed, and the cartilages of the ears very delicate and movable, but there was no trace of any centre of ossification in the inferior epiphysis of the femur. We have, it is true, other observations with reference to this defect: I refer especially to G. Hartmann's "*Dissertation*" (*Beiträge zur Osteologie der Neugeborenen*, Tübingen, 1869, p. 18). So complete a defect, however, in the ossification of the extremities (and in the sternum), co-existing with the advanced stage of the same process in the bones of the skull, is well worthy of attention.

The case well illustrates the importance of microscopical examination for the decision of medico-legal questions, for by this means we were enabled to detect changes both in the brain and lungs. Owing to the proliferation of epithelium in the infundibula and alveoli, the lungs appeared so bright-red in color that I was

at first inclined to believe that respiration had taken place. But on very close examination I noticed that the air cells were occluded, and my observation was confirmed by the microscope.

The medico-legal conclusions to be drawn in this case would be as follows :—

1. The body was that of a new-born child.
2. The question whether the child was of the full term or not could not positively be determined by the examination.
3. Respiration had not taken place, either during or after birth.
4. The child was not capable of living out of the womb of its mother ; its death *in utero* was caused by disease implicating the lungs, larynx, and brain.
5. There were no signs of any external violence.

This concludes my list of cases, though it might easily be enlarged. Those given will suffice to indicate the method pursued.

I should like to add a few words with regard to one point in conducting an autopsy, and that is the method of opening the thorax. It is evident to me that not a few young practitioners, in common with the majority of students, sometimes experience great difficulties in this part of the examination, simply because they do not clearly appreciate the anatomical conditions.

In opening the wall of the thorax, the division of the cartilages should be made at a point as distant as possible from the sternum. As a matter of course, this direction applies only to non-ossified cartilages.

If, however, the cartilages are even only partially ossified, the bone forceps must generally be substituted for the knife, and under these circumstances we may with advantage go further outward, and divide the

bones of the ribs, in order to obtain free access to the viscera of the thorax. It may be observed that the sterno-clavicular joint is, as a rule, not ossified unless it has been the seat of severe disease. This joint is, therefore, always to be cut through; and inasmuch as it is crescentic in form, and its surfaces are separated by an inter-articular cartilage (see Fig. 4), separation is to be effected by means of steady strokes of the knife, directed in a crescentic curve round the sternal end of the clavicle.

The cartilage of the first rib, on the other hand, is very frequently ossified, even in cases where the other costal cartilages are free from bony deposit. As a rule, what we meet with here, as in the other costal cartilages, is a supra-cartilaginous, *i. e.*, a perichondrial ossification, of great hardness, always enough to spoil the knife.

If there be no ossification, we first cut through the costal cartilages on each side, close to their union with the ribs, the knife being held horizontally, so that its point may not penetrate deeply into the thorax. The important point is to obtain as large an opening as possible into the thoracic cavity. The line of incision, therefore, describes on each side a curve, the convexity of which is toward the sternum, its lower end being continued for some distance in an outward direction, so as to strike the insertions of the cartilages of the last false ribs. A glance at Plate 4 will clearly show that from the second rib downward the point of insertion of each successive rib becomes somewhat more distant from the mesial line. If these points are taken as a guide for the incisions, on removing the sternum and costal cartilages we obtain a wide opening into the thorax, the width being much increased below.

The first rib, however, requires exceptional notice, for if the incision, as above described, be prolonged toward it, the knife will generally come against the

bony *manubrium sterni*, which increases much in width at this part. Corresponding to the increase, the cartilage of the first rib extends much further externally than that of the second, and the incision for its division must therefore be carried from one to two centimetres further outward than that for the second costal cartilage. The best way to proceed is to insert the knife, with its edge looking upward and forward, under the cartilage of the first rib, below its inferior border, and then cut upward and forward. This is the best way of avoiding injury to the vessels which are close beneath. Even in cases in which the perichondrial ossification is far advanced, the bony investing layers can often be readily cut through, if the knife is used in the above manner.

It is, therefore, always impossible to cut through the sterno-clavicular articulation and the first and second costal cartilages, by means of a single straight incision. Each of these parts must be divided separately and specially, and the knife must be directed in a suitable manner. Plate 4, which, moreover, shows partial duplication of the third costal cartilage on the right side, plainly illustrates the anatomical conditions, and any one who will carefully study it will be able, without difficulty, to draw the line by which the incisions are to be guided.

In conclusion, something should be said of a very often overlooked or misunderstood condition, the fluidity of the capillary blood in dead bodies (Cellular Pathology, 4. Auflage, S. 194). Even in cases in which the blood is firmly coagulated in the large vessels, the capillaries are usually filled with completely fluid blood. As a rule this does not coagulate outside the body, when removed after death. Hence there are most important practical differences between coagulated extravasations which have taken place during life, and the fluid extravasations blood-masses which escape after death.

REGULATIONS  
FOR THE  
GUIDANCE OF MEDICAL JURISTS  
IN CONDUCTING  
POST-MORTEM EXAMINATIONS FOR  
LEGAL PURPOSES.

---

I. *General Directions.*

§ 1. *The Examining Medical Officers and their Duties.*—The examination of a dead body for legal purposes is, in accordance with the existing regulations, to be undertaken by two medical practitioners only; as a general rule, one of these is to be a district physician (Physicus Gerichtsarzt) and the other a district surgeon (Gerichts-Kreis-Wundarzt). A magistrate is to be present during the examination.

Those performing the examination are charged with the duties of legal experts.

Should any doubts arise as to the method of performing the examination, they are to be decided by the district physician or his substitute; but the surgeon shall have the right of expressing his dissentient view in the minutes of proceedings.

§ 2. *Substitutes.*—Only when lawfully hindered from performing their functions may the above-mentioned medical officers delegate their duties to substitutes. When possible, a physician who has passed the *pro physicatu* examination is to be selected as a substitute.

§ 3. *Time of Performance.*—Autopsies should not, as a rule, take place until twenty-four hours after death; but the mere inspection of the dead body may be made earlier.

§ 4. *Course to be adopted when Putrefaction has set in.*—The presence of putrefaction is not, as a general rule, a sufficient reason for omitting the examination, and does not justify the medical jurist in refusing to proceed with his duties. For even if putrefaction be very far advanced, abnormalities and injuries of the bones can still be ascertained, and likewise many other circumstances, such as the color and state of the hair, the absence of limbs, etc., which may assist in establishing the identity in doubtful cases. Foreign substances within the body may also be discovered, as also the presence or absence of pregnancy and of poisons. When, therefore, the question arises of disinterring a dead body for the purpose of gaining information on matters of this kind, it is the duty of the physicians to recommend the exhumation, regardless of the time that has elapsed since death took place.

§ 5. *Instruments.*—It is the duty of the medical jurists to take care that the following instruments, which are requisite for the performance of the examination, are forthcoming and in good order: Four to six scalpels—two small, with a straight edge, and two large, with a curved edge. One razor. Two strong cartilage knives. Two pairs of forceps. Two double hooks. Two pairs of scissors—one pair large, having one blade with the point rounded off, the other sharp; the other pair small, one blade probe-pointed, the other sharp-pointed. One pair of scissors, for laying open intestines. One blow-pipe, furnished with a stop-cock. One thick probe and two fine ones. One saw. A mallet and chisel. A pair of bone forceps. Six curved needles of various sizes. A pair of calibre compasses. A metre



measure, divided into centimetres and millimetres. A measure graduated into divisions, showing 100, 50, and 25 cubic centimetres. A pair of scales, with weights up to 10 pounds. A good magnifying glass. Blue and red test paper.

The cutting instruments must all be perfectly sharp. Physicians performing a post-mortem examination should, in addition, have at their command a microscope with two objectives, magnifying at least 400 diameters, as well as the various instruments required for making preparations; also glasses, reagents, etc.

§ 6. *Place for the Examination, and Light.*—For the examination a sufficiently spacious and light room should be chosen, where the body can be placed in a suitable position, and in a quiet situation. It is not allowable to perform autopsies by artificial light, except in cases which admit of no delay. In such a case the fact must be expressly alluded to in the protocol (§ 27), and mention made of the reason which rendered the performance at such a time imperative.

§ 7. *Frozen Bodies.*—If the body is frozen, it is to be brought into a warm room, and the examination is not to be proceeded with until the parts are sufficiently thawed. The employment of warm water, or other warm materials for expediting the thawing, is not allowable.

§ 8. *Transport of Dead Bodies.*—In moving the dead body in any way, and particularly in moving it from place to place, the greatest care must be taken to avoid applying any great pressure to any portion of it; and the large cavities should be kept as nearly as possible in a horizontal position.

## II. *Proceedings at Post-mortem Examinations.*

§ 9. *The Judicial Objects of the Examination.*—Those charged with making the examination must

keep their attention fixed upon the judicial objects in view, and all things which are subservient to these objects must be investigated with minuteness and completeness.

Everything that appears important, before being noted down in the minutes, must be shown to the magistrate.

§ 10. *Duties of the Examiners with Reference to the Investigation of any Peculiar Circumstances connected with the Case.*—Before commencing the examination, those charged with its performance should, whenever it appears necessary, request the magistrate for permission to inspect the place where the body was found, and ascertain the position which it occupied, and also to examine the clothes which were found on the deceased. As a general rule, however, they need not undertake these investigations unless requested to do so by the magistrate.

They are also entitled to request the judgment of the magistrate with regard to all other circumstances previously ascertained which may be of importance for the examination, and the opinions to be formed thereupon.

§ 11. *Microscopical Examination.*—In all cases in which a microscopical examination is necessary in order to decide rapidly and positively as to any doubtful appearance—for example, to distinguish blood from colored fluids (holding hæmatin in solution)—such examination must be made while the autopsy is going on. When, owing to circumstances, this is impossible, or when it is necessary to make a difficult microscopical examination (*e. g.*, of portions of tissue) which cannot be done at once, the portions required are to be set aside in proper custody, and submitted to examination as soon as possible. In the report, the time at which this subsequent examination was made is to be definitely stated.

§ 12. *The Examination of the Body.*—The examination of the dead body consists of two principal parts:

- A. The external examination (inspection).
- B. The internal examination (dissection).

§ 13. *External Examination.*—The external examination includes that of the external surface of the body in general, and of its separate portions.

With reference to the condition of the body generally, the following are the points to be ascertained and noted:

1. Age; sex; size; bodily conformation; general state of nutrition; any signs of disease, such as ulcers about the legs, peculiar abnormalities, as spots, cicatrices, marks of tattooing, excess or deficiency of limbs.
2. The signs of death and of any decomposition which may be present.

Should the body be soiled with blood, fæces, dirt, and the like, these must be washed off, and it must then be ascertained whether rigor mortis is present or not; the color of the skin generally must be noticed, and the kind and degree of any coloration or discoloration due to decomposition that may be present in any part, also the color, position, and extent of the post-mortem stains, which must be cut into, examined, and carefully described, in order to discriminate between such appearances and those due to extravasation of blood.

With reference to individual portions of the body, the following points must be attended to:—

1. When the body is that of a person unknown, the color and other peculiarities of the hair (of the head and beard), and likewise the color of the eyes, are to be noted.
2. The presence of any foreign substances in the nat-

ural apertures of the body, the state of the teeth, and the condition and position of the tongue.

3. The following parts are then to be examined: the neck, chest, abdomen, back, the anus, the external organs of generation, and lastly, the limbs.

Should there be an injury on any portion of the body, a description must be given of its shape, position and direction, with reference to fixed points; also its length and breadth, in metric measurement. In this external examination any probing of wounds and injuries is, as a general rule, to be avoided, inasmuch as the depth can be readily ascertained during the internal examination of the body and of the injured parts. If those performing the autopsy deem it necessary to introduce a probe, they must do this very carefully, and state their reasons for so doing in the notes of the proceedings (§ 27).

When wounds have been discovered, the condition of their borders and surrounding parts is to be determined, and after the examination and description of the wound in its original state, it should be enlarged, in order to ascertain the internal conditions of its borders and base.

When the body presents wounds and injuries which have clearly nothing to do with the cause of death—for example, marks made in attempts at rescue, bites of animals, and the like—it is sufficient that such appearances should be summarily noted.

§ 14. *Internal Examination—General Directions.*—In the internal examination, the three principal cavities of the body, viz., the head, thorax, and abdomen, are to be opened.

The opening of the vertebral canal, or of separate joints, is never to be omitted in cases in which any information may be expected from such examination.

When there is any definite suspicion with regard to the cause of death, that cavity is first to be opened in

which the principal changes are supposed to exist ; but in other cases the head is to be opened first, then the thorax, and lastly, the abdomen.\*

In each of these cavities, the first thing to be done is to determine the position of the organs therein contained; then the color and condition of their surfaces, the presence or absence of any unnatural contents, especially of foreign bodies, gases, fluids or coagula : and with regard to the two last substances, their quantity should be determined. Each separate organ is finally to be examined, both externally and internally.

§ 15. *The Cavity of the Cranium.*—Unless there are any injuries which have to be avoided by the knife, and which would necessitate some other method of procedure, the head is to be opened by means of an incision carried across the middle of the skull, from one ear to the other ; the soft parts covering the head are then to be reflected backward and forward.

Attention having been paid to the condition of the soft parts, and of the surface of the bones, these latter are to be sawn through in a circular manner, and the skull cap is to be removed. The cut surface, the internal surface, and the general condition of the cranial arch, are to be examined.

In the next place, the external surface of the dura mater is to be examined, the superior longitudinal sinus opened, and its contents determined; the dura mater is then to be divided on one side, and turned back, and its inner surface examined, as also the condition of the exposed portions of the pia mater.

After this has been done on the other side, the brain is to be carefully removed, and the base of the skull is to be examined for any unusual contents. Attention must be paid to the condition of the dura and pia mater at the base and sides of the skull, and to that of the large arteries.

---

\* With regard to new-born children, see sections 23 and 24.

The transverse sinuses are next to be opened, and also the other sinuses (if there is any cause for so doing), and their contents are to be determined. The size and shape of the brain are next to be ascertained, and the color, the fullness of the vessels, and the consistence and structure of the organ, are to be determined by means of a series of incisions through individual portions, viz., the hemispheres of the cerebrum, the great ganglia (the optic thalamus and corpus striatum), the corpora quadrigemina, the cerebellum, the pons Varolii, and the medulla oblongata.

In addition to this, attention must always be paid to the condition of the tissue and vessels of the velum interpositum and choroid plexus.

The size and contents of the different ventricles, and likewise the condition and amount of fullness of the various venous plexuses, are to be carefully ascertained, and the presence or absence of any coagula external to the vessels is to be determined.

Finally, the bones of the base and lateral portions of the skull are to be examined, for which purpose the dura mater must be previously removed.

§ 16. *The Face, Parotid Gland, and Ear.*—When it is necessary to lay bare the internal parts of the face, and to examine the parotid gland or the ear, the incision carried over the head is to be prolonged behind the ears to the neck, and the skin is to be dissected forward, in order to spare it as much as possible. Particular attention is to be paid to the condition of the large arteries and veins.

§ 17. *The Vertebral Column and the Spinal Cord.*—The vertebral column (§ 14, par. 2) is to be opened from the posterior aspect. The skin and the subcutaneous fat are first to be divided exactly over the spinous processes; the muscles are then to be removed from the sides of these latter, and from the arches of the verte-

bræ. Extravasations of blood, lacerations and other injuries, particularly fractures of the bones, are to be carefully looked for.

Then by means of a chisel, or a vertebral saw, if at hand, the spinous processes, together with the adjoining portions of the vertebral arches, are to be detached and removed. The dura mater is now exposed, and after its external surface has been examined, is to be carefully slit open longitudinally, and the presence of any serum, or extravasated blood, or other abnormal matters, is to be determined. The color, appearance, and general condition of the posterior portion of the pia mater are next to be noticed, and the resistance to pressure of the spinal cord is to be ascertained by gently passing the finger over it.

The roots of the nerves are next to be divided on both sides by a longitudinal incision; the lower end of the cord is to be carefully taken out, its anterior connections are next to be gradually separated, and finally, the superior extremity is to be removed from the occipital foramen.

In carrying out these directions, great care must be taken that the spinal cord be neither pressed nor bent. When removed, the condition of the pia mater on the anterior aspect is first to be examined, then the size and color (external) of the spinal cord are to be noted; and, lastly, numerous transverse incisions are to be made with a very sharp and thin knife, to determine the internal condition of the spinal cord, both of its white strands and of the gray substance. The dura mater is then to be removed from the bodies of the vertebræ, and the dissector is to examine for extravasation of blood, injuries or alterations in the bones or intervertebral cartilages.

§ 18. *Neck, Thorax, and Abdomen—General Directions.*—In opening the neck, thorax, and abdomen, it is generally sufficient to make one long incision from the

chin to the pubes, passing to the left of the umbilicus. In ordinary cases, the incision is to be carried right into the abdominal cavity, care being taken not to injure any of its contents. The best plan is to make at first a very small incision into the peritoneum. Notice must be taken whether any gas or fluid escapes. First one, and then a second finger are introduced, the integuments are raised from the intestines, and the further incision through the peritoneum is to be made between the two fingers.

This being done, the position, color, and other appearances presented by the exposed viscera, and also the occurrence of any abnormal contents are next to be specified, and the position of the diaphragm is to be determined by examining it with the hand.

The examination of the abdominal organs is not to be continued at this stage, unless there be particular reasons for believing that the cause of death will be found in the abdominal cavity (§ 14). As a general rule, the examination of the thorax must precede the further examination of the abdomen.

§ 19. *The Thorax.*—For opening the thorax, it is necessary that the soft parts of the chest should first be dissected back beyond the points of attachment of the cartilages to the ribs. The cartilages are then to be divided with a strong knife a few millimetres internal to their attachments. Care must be taken to avoid injuring the lung or the heart. When the cartilages are ossified, the best plan is to divide the ribs with a saw or bone forceps a little external to the attachments of the cartilages. The clavicles are then to be separated from the manubrium of the sternum by means of a crescentic vertical incision, and the junction with the first rib, whether cartilaginous or bony, is to be divided with the knife or bone forceps, the greatest care being taken to avoid injuring the vessels lying beneath. Then the attachments of the diaphragm between the ends of the



two incisions are to be divided close to the cartilages of the false ribs and the ensiform cartilage ; the sternum is to be turned upward, and the mediastinum cut through, care being taken to avoid injuring the pericardium and large vessels.

After removing the sternum, the condition of the pleural cavities is to be determined ; the presence, condition, and quantity of any abnormal contents, the state of distention, and the general appearance of the exposed portions of lung are to be noticed. If, in the removal of the sternum, any vessel has been injured, this must be tied, or a piece of sponge must be applied, to prevent the blood from escaping into the pleural sac, where its presence might give rise to mistakes. The condition of the mediastinum, the state of the thymus gland, and likewise the condition of the large vessels outside the pericardium (which vessels, however, are not yet to be opened) are now to be noticed.

Then the pericardium is to be opened, and its condition noticed, and the heart examined. With regard to the latter, its size, the fullness of the coronary vessels, and of its separate cavities (auricles and ventricles), its color and consistence (post-mortem rigidity), are all to be noticed before any incision is made, and before the heart is removed from the body. Then, while the heart is still unsevered from its connections, each ventricle and each auricle are to be separately opened, and the contents of each cavity are to be determined with regard to their quantity, state of coagulation and general appearance, and the size of the auriculo-ventricular valves is to be tested by introducing two fingers from the auricle. Then the heart is to be removed ; the condition of the arterial openings is first to be tested by pouring in water, and then, by slitting them up ; the condition of the muscular tissue of the heart is to be determined with reference to its color and general appearance. If there be reason to suppose that the muscular

structure has undergone considerable alteration—fatty degeneration, for example—a microscopical examination must always be made.

The examination of the heart is to be followed by that of the large vessels, but the descending aorta is to be left until the lungs have been examined. In order to examine the lungs minutely, they must be removed from the thoracic cavity. Their removal must be effected with great care, and the lung tissue must not be torn or squeezed. If extensive adhesions exist, and particularly if they are old standing, they must not be divided, but a portion of the costal pleura should be removed with the attached adhesions. After removal of the lungs, their surface is to be again carefully examined, in order that recent changes—for example the commencement of inflammatory exudation—may not be overlooked. The capacity for air, the color, and the consistence of each partion of the lungs, are to be noticed; finally, large, smooth incisions are to be made, and the following points attended to: The state of the cut surfaces; the amount of air, blood, and serum; the presence of any solid contents in the pulmonary vesicles; the condition of the bronchial tubes and pulmonary artery, with especial reference to obstruction, etc., in the latter. For this purpose the air passages and the large branches of the pulmonary artery are to be divided with the scissors and followed out to their finer ramifications.

In cases where it is suspected that foreign matters have entered the air passages, and where substances the nature of which is not evident on simple inspection are found in the air tubes, recourse must be had to the microscope to determine their nature.

§ 20. *The Neck.*—According as circumstances may require the neck may be examined, either before or after the opening of the thorax or the removal of the lungs. Those performing the autopsy may, if they think fit, make a special examination of the larynx and air tubes,

if such investigation be of particular importance, as, for instance, in cases of death from strangulation or drowning.

As a general rule, the best plan is first to examine the large vessels and the nerve trunks, and afterward to open the larynx and trachea by an incision carried along their anterior aspect, and to examine their contents. In cases where it is especially important to examine these parts, they should be looked to before the lungs are removed from the body, and pressure should be carefully made upon these latter organs, in order to see whether any liquid matters, etc., ascend into the trachea.

The larynx is then to be removed, together with the tongue, the soft palate, the pharynx, and the œsophagus; each of these parts is to be incised and its condition ascertained, the state of the mucous membrane being particularly noticed. The thyroid gland, the tonsils, the salivary glands, the cervical lymphatic glands, are all to be examined.

In cases where the larynx or trachea has been injured, or where important changes are supposed to exist in these parts, an incision is not to be made into them until they have been removed from the body, and they are then to be opened from their posterior aspect.

Where death has resulted from strangulation, or presumably from suffocation, and the carotid arteries are opened in order to ascertain whether there is any injury of the lining membrane, the vessels should be examined while still in their natural position.

Finally, the state of the cervical vertebræ and of the deep muscles of the neck should be noticed.

§ 21. *The Abdomen.*—In the further examination of the abdominal cavity and of its contents (§ 18), a certain order of sequence is always to be adopted, so that the removal of an organ shall not interfere with the minute investigation of its relations to other parts. Thus the duodenum and biliary ducts should be exam-

ined before the removal of the liver. As a general rule, the following order of sequence is advisable: 1. The omentum. 2. The spleen. 3. The kidneys and suprarenal capsules. 4. The urinary bladder. 5. The organs of generation (in the male subject the prostate gland and vesiculæ seminales, the testicles, the penis, with the urethra; in the female, the ovaries, Fallopian tubes, uterus, and vagina). 6. The rectum. 7. The duodenum and stomach. 8. The gall-ducts. 9. The liver. 10. The pancreas. 11. The mesentery. 12. The small intestines. 13. The large intestines. 14. The large blood vessels in front of the vertebral column; their contents to be examined and determined.

*The Spleen.*—The length, breadth, and thickness of the spleen are to be ascertained while the organ is lying free, and not when placed in the hand, and the spleen is not to be compressed by the measure. A longitudinal incision is then to be made, and if any alterations of structure are manifest, the organ should be incised in various directions. The quantity of blood is always to be noticed.

*The Kidneys.*—Each kidney is to be removed by a vertical incision through the peritoneum, external to and behind the ascending or descending colon, the intestine is to be pushed aside, and the kidney detached from its connections. The capsule is then to be carefully removed, a long incision being made into it over the convex border of the kidney. The surface thus exposed is to be noticed with reference to the size, shape, color, quantity of blood contained, and any morbid appearances that may be present. A long incision is then to be made through the kidney, as far as its pelvis, the cut surface is to be washed with water, and described with reference to the condition of the cortical and medullary substance, vessels, and parenchyma.

*The Pelvic Organs.*—The organs of the pelvis (the

bladder, rectum, and generative organs therewith connected) are best removed together, but the bladder should first be opened *in situ*, and its contents determined. Then the parts should be further examined, the generative organs being taken last. The vagina should be opened and examined before the uterus. In examining the body of a woman who has died after delivery, special attention should be paid to the condition of the veins and lymphatics, both on the inner surface of the uterus and in its walls and appendages, the size and contents of the vessels being especially noted.

*The Stomach and Duodenum.*—The external condition of the stomach and duodenum is first to be ascertained while the parts are *in situ*. Then, with a pair of scissors, the duodenum is to be slit up on its anterior aspect, and the stomach along the great curvature; the contents are then to be examined, the permeability of the gall duct and any matter contained therein are also to be noticed, and then the parts are to be removed for further examination.

*The Liver.*—The external appearance of the liver is first to be described, and the organ is to be removed after the examination of the excretory ducts. Long, smooth incisions are then to be carried transversely through the organ, and the amount of blood and general condition of the parenchyma are to be ascertained. The description is to contain a short account of the general condition of the lobules, the appearance of their centres and circumference being particularly noticed.

*The Small and Large Intestines.*—The small and large intestines are to be examined with reference to the degree of distention, color, and other external appearances of their various parts; they are then to be removed together, the mesentery being cut through close to the intestine. After removal, the intestine is to be slit up with the scissors along the line of attachment of

the mesentery. As this is being done, the contents of each portion are to be noticed and estimated. Then the intestine is to be well cleansed with water, and the condition of the various portions noticed, particular attention being paid to the agminate and solitary glands, the villi, and valvulæ conniventes of the small intestine. In every case of peritoneal inflammation examine carefully the vermiform appendage.

§ 22. *Cases of Poisoning.*—In cases where poisoning is suspected, the abdominal cavity is first to be examined. Before anything further is done, attention is to be paid to the external appearance of the principal viscera, their position and size, the fullness of their vessels, and also as to whether there be any odor perceptible.

With regard to the vessels, the points here to be determined, as in other important organs, are as follows: Are the vessels arteries or veins? Does the congestion prevail in the finer ramifications, or only in the trunk and branches of a certain size? Are the intervacular spaces of considerable extent or not?

Double ligatures are then to be placed around the terminal portion of the œsophagus, just above the cardiac orifice, and two more around the duodenum, below the opening of the gall duct. The parts are to be divided between the ligatures. The stomach is then to be removed with the duodenum, care being taken to avoid injuring the parts. They are then to be opened as described in § 21.

The contents are to be immediately examined with regard to the quantity, consistence, color, composition, reaction, and smell, and placed in a clean porcelain or glass vessel.

The mucous membrane is then to be washed with water, and its color, thickness, surface and consistence are to be noticed. Particular attention is to be paid to the state of the blood vessels, and to the tissue of the

mucous membrane generally, and of each of the principal portions of the stomach. Particular care should be taken to ascertain whether any blood that may be present is within the vessels, or extravasated, also whether it is recent, or altered by putrefaction or digestion, and under these circumstances has penetrated by imbibition into the parts around. If extravasated, its situation should be determined—whether on the surface or in the tissue, and whether coagulated or not.

The surface of the mucous membrane is to be carefully examined for any breaches of continuity, such as loss of substance, erosions, or ulcers. The question as to whether the alterations manifested may have occurred after death, from natural decomposition, or from the action of the fermenting contents of the stomach, is to be carefully kept in mind.

This examination having been completed, the stomach and duodenum are to be placed in the vessel which contains the contents (see above), and delivered to the magistrate for further investigation. The œsophagus having been tied in the neck and divided above the ligature, and subjected to examination, is also to be placed in the same vessel. In a case where the stomach contains but very little, the contents of the jejunum should be reserved in like manner.

Lastly, other materials and portions of organs, such as blood, urine, pieces of liver, kidneys, etc., are to be taken from the body, and made over to the magistrate separately, for further examination. The urine is to be placed in a separate vessel. The blood is to be kept separately only in cases where a definite conclusion may be anticipated from spectrum analysis. Portions of other organs reserved are to be placed together in one vessel.

Each vessel is to be carefully closed, sealed, and marked.

If on simple inspection the gastric mucous membrane

appears particularly opaque and swollen, no time should be lost in examining it with a microscope, especial attention being paid to the condition of the peptic glands.

The microscope is also to be used in cases where the stomach contains any suspicious substances, such as portions of leaves or other vegetable matters, the remains of animal substances taken as food, etc.

Where trichinosis is suspected, the contents of the stomach and upper part of the jejunum are first to be subjected to microscopical examination, but portions of the muscular tissue (of the diaphragm, cervical and pectoral muscles) are to be put aside for further investigation.

§ 23. *New-born Children. Determination of Maturity and Period of Development.*—In the post-mortem examination of new-born children special attention is to be directed to the following points, in addition to the above-mentioned general rules:

In the first place, the signs indicative of immaturity and period of development must be looked for.

These are: the length and weight of the child, the condition of the general integuments and of the umbilical cord, the length and state of the hair of the head, the size of the fontanelles, the diameter of the cranium (longitudinal, transverse and diagonal), the condition of the eyes (membrana pupillaris), the state of the cartilages of the nose and ear, the length and condition of the nails, the transverse diameter of the body at the shoulders and hips; in male infants, the condition of the scrotum and position of the testicles; in females, the condition of the external organs of generation.

Finally, we must examine the size of the centre of ossification (if present) in the inferior epiphysis of the femur. For this purpose, the knee joint must be opened by means of a transverse incision below the patella, the joint fully bent and the patella removed;



thin layers are then to be cut from the cartilaginous end of the femur, till the greatest transverse diameter of the centre of ossification (if present) be reached; this is to be measured in millimetres.

Should the condition of the foetus be such as clearly to prove that it was born before the completion of the thirtieth week, it is not necessary to proceed further with the examination, unless the magistrate distinctly requires it.

§ 24. *Determination of the Question whether the Child has Breathed.*—If it shall appear that the child has been born after the thirtieth week, the next step is to ascertain whether it has breathed during or after birth. For this purpose the respiration test must be applied, and the proceedings conducted in the following order:

(a) Immediately on opening the abdominal cavity the position of the diaphragm is to be ascertained, with reference to the corresponding rib, and on this account, in new-born children the abdomen is always to be opened first, and afterward the thorax and cranium.\*

(b) Before opening the thorax a ligature is to be placed around the trachea above the sternum.

(c) The thorax is then to be opened, and attention must be paid to the degree of dilatation of the lungs, and their position dependent upon such dilatation, particularly with reference to the pericardium. The color and consistence of the lungs should also be ascertained.

(d) The pericardium is then to be opened, and its condition and that of the heart externally are to be ascertained.

(e) The cavities of the heart are then to be opened,

---

\* The *dissection*, however, of the abdominal organs is never to precede the opening and examination of the thorax.

and their contents to be examined, and the condition of the heart in other respects is to be determined.

(*f*) The larynx and that portion of the trachea above the ligature are then to be opened by means of a longitudinal incision, the condition of their walls is to be ascertained, and any contents are to be examined.

(*g*) The trachea is to be divided above the ligature and removed, together with all the organs of the thorax.

(*h*) After removing the thymus gland and the heart, the lungs are to be placed in a capacious vessel filled with clean, cold water, in order to test their buoyancy.

(*i*) The lower part of the trachea and its subdivisions are to be laid open and examined, especially with reference to their contents.

(*k*) Incisions are to be made in both lungs, and notice taken whether any crepitating sound be heard, and also with reference to the amount and quality of the blood issuing from these cut surfaces on slight pressure.

(*l*) Incisions are to be made into the lungs below the surface of the water, in order to see whether any air-bubbles rise from the cut surfaces.

(*m*) Both lungs are next to be separated into their lobes, and these are to be divided into several small pieces, the buoyancy of each of which is to be tested.

(*n*) The œsophagus is to be opened and its condition ascertained.

(*o*) Lastly, in cases where it is suspected that air cannot gain access to the lungs, in consequence of the filling up of their cells and passages with morbid products (hepatization) or foreign substances (mucus, meconium), the lung tissue is to be examined with the microscope.

§ 25. *Other Examinations.*—In the last place, it is the duty of those performing the autopsy to examine all other organs or parts not mentioned by name in the regulations, in any case in which the parts in question are found to be injured or otherwise abnormal.

§ 26. *End of the Examination—The Cavities to be Closed.*—The examination being completed and the body cleansed as far as possible, it is the duty of the district surgeon, who is relatively the junior of the medical examiners, to close up carefully those cavities of the body which have been opened.

### III. *Framing the Protocol and Report of the Examination.*

§ 27. *Drawing up of the Protocol of the Examination.*—A protocol of everything connected with the post-mortem examination must be drawn up by the magistrate upon the spot.

The physician (*Gerichtsarzt*) has to take care that the appearances in all details, as determined upon by the inspectors, are literally described in the protocol.

The magistrate is to direct that this should be done in such a way that the description and the report of each separate organ are to be placed on record before another portion is submitted to examination.

§ 28. *Arrangement and Drawing up of the Protocol.*—The technical portion of the protocol of the autopsy must be dictated by the physician; it must be clear, definite, and intelligible to non-medical persons. And for this latter purpose, especially in the description of the appearances found, the use of foreign scientific terms is to be avoided, when this can be done without loss of distinctness.

The two principal divisions—the external and internal inspections—are to be distinguished by large capitals (A & B); the sections describing the opening of

the cavities, in the order in which this has been done, by Roman numerals (I, II). The opening of the thoracic and abdominal cavities will come under one number. In the section which deals with the thorax and abdomen, the general appearances, mentioned in the last paragraph of Section 18, are first to be described, then under *a* and *b* the appearance of the thoracic and abdominal organs respectively.

The result of the examination of each separate part is to be contained in a distinct paragraph headed with Arabic numerals. The numerals run consecutively from the beginning to the end of the protocol.

The appearances found must be accurately described as matters of fact, and not in the form of mere opinions (*e. g.*, "inflamed," "gangrenous," "healthy," "normal," "a wound," "an ulcer," and the like). But the inspectors may, if they please, for the sake of distinctness, add to their statement of actual observations expressions of this kind in parenthesis.

In all cases a statement must be given with reference to the amount of blood contained in each important part, and what is required is a terse description, not merely an opinion couched in such terms as "intensely," "moderately," "somewhat," or "very reddened," "full of blood," "bloodless." In the description, the size, shape, color, and consistence of the various parts are to be mentioned *seriatim* before making any incisions.

§ 29. *Provisional Opinion.*—At the conclusion of the autopsy the medical inspectors must enter in the protocol their provisional opinion regarding the case, summarily, and without the addition of any reasons.

If any particular facts influencing their opinion have come to their knowledge, whether from the proceedings or otherwise, these must be briefly mentioned.

If any particular questions have been put to them by the magistrate, it must be shown in the protocol that the answer is the result of such questions.

In every case the cause of death as evidenced by the objective appearances is first to be set forth in the opinion, and next the question of criminality is to be dealt with.

If the cause of death has not been discovered, the fact must be expressly mentioned. It is never sufficient to say that the death has resulted from internal causes or from disease ; the disease must be specified.

In cases where further technical examination is necessary, or where there are any doubtful circumstances, a special opinion, giving reasons, is to be formally deferred.

§ 30. *Supplementary Explanation with regard to Weapons.*—If there be any injuries on the dead body which may have been the cause of death, and if it be suspected that a weapon found has been used to cause the injuries, then the medical inspectors, at the request of the magistrate, must institute a comparison between them, and must state whether and what injuries could have been caused by the weapon, and whether any conclusions can be drawn, from the position and condition of the injury, as to the mode in which the perpetrator has acted, and as to the force used.

Should weapons not be forthcoming, the inspectors must express an opinion, as far as the appearances will permit, with regard to the way in which the injuries have originated, and with reference to the nature of the weapon employed.

§ 31. *Report of the Examination.*—Should a report (a reasoned opinion) of the examination be required from the inspectors, it is to be furnished in the following form :

All useless formalities being avoided, and after a statement of what has been done, it is to be commenced with a condensed, but minute history of the case, so far as their cognizance permits. They must

then incorporate in this report the protocol of the autopsy, but only so much as is necessary for the elucidation of the case, using the exact words of the protocol and the same numerals, expressly drawing attention to any deviations in this respect.

The style of the report must be concise and clear, and the ground on which the opinion is formed must be displayed in such a way as to be intelligible and convincing, even to non-medical men. The inspectors must employ, therefore, as far as possible, expressions and terms in popular use. Especial references to literary authorities are, as a rule, to be avoided.

If the magistrate has placed definite questions before the inspectors for their opinion, these must be answered as fully and literally as possible, or reasons given why this cannot be done.

The report of the examination must be signed by both inspectors, and if a district physician has assisted at the autopsy, his official seal must be affixed to the report.

Every report, when required, must be furnished by the inspectors within four weeks at latest.

BERLIN, *January 6, 1875.*

*The Royal Scientific Commission for Medical Affairs.*

The foregoing regulations are hereby approved, and their observance is rendered obligatory upon all medical officers who may be concerned. The regulations of the 15th of November, 1858, are abolished.

BERLIN, *February 13, 1875.*

*The Minister for Ecclesiastical, Educational and Medical Affairs.*

FALK.















CATALOGUE No. 7.

MAY, 1888.



A CATALOGUE  
OF  
BOOKS FOR STUDENTS;

INCLUDING A FULL LIST OF

*The ? Quiz-Compend's?,*

MANUALS,

Text-Books and Students' Aids,

PUBLISHED BY

P. BLAKISTON, SON & CO.

*Medical Booksellers, Importers and Publishers.*

LARGE STOCK OF ALL STUDENTS' BOOKS, AT  
THE LOWEST PRICES.

No. 1012 WALNUT STREET,

PHILADELPHIA.

---

\*.\*For sale by all Booksellers, or any book will be sent by mail, postpaid, upon receipt of price. Catalogues of books on all branches of Medicine, Dentistry, Pharmacy, etc., supplied upon application.

# ? QUIZ-COMPENDS?

A NEW SERIES OF COMPENDS FOR STUDENTS.

For Use in the Quiz Class and when  
Preparing for Examinations.

Price of Each, Bound in Cloth, \$1.00 Interleaved, \$1.25.

Based on the most popular text-books, and on the lectures of prominent professors, they form a most complete set of manuals, containing information nowhere else collected in such a condensed, practical shape. The authors have had large experience as quiz-masters and attachés of colleges, with exceptional opportunities for noting the most recent advances and methods. The arrangement of the subjects, illustrations, types, etc., are all of the most improved form, and the size of the books is such that they may be easily carried in the pocket. They are constantly revised, so as to include the latest and best teachings, and can be used by students of any college.

## No. 1. ANATOMY. (Illustrated.)

THIRD REVISED EDITION.

A Compend of Human Anatomy. By SAMUEL O. L. POTTER, M.A., M.D., U. S. Army. With 63 Illustrations.

"The work is reliable and complete, and just what the student needs in reviewing the subject for his examinations."—*The Physician and Surgeon's Investigator*, Buffalo, N. Y.

"The arrangement is well calculated to facilitate accurate memorizing, and the illustrations are clear and good."—*North Carolina Medical Journal*.

## Nos. 2 and 3. PRACTICE.

NEW REVISED EDITIONS.

A Compend of the Practice of Medicine, especially adapted to the use of Students. By DAN'L E. HUGHES, M.D., Demonstrator of Clinical Medicine in Jefferson Medical College, Philadelphia. Second Edition. Enlarged and thoroughly Revised. In two parts.

PART I.—Continued, Eruptive, and Periodical Fevers, Diseases of the Mouth, Stomach, Intestines, Peritoneum, Biliary Passages, Liver, Kidneys, Intestinal Parasites, etc., and General Diseases.

PART II.—Diseases of the Respiratory System, Circulatory System and Blood, Nervous System, etc.

Price of each Book, Cloth, \$1.00. Interleaved for Notes, \$1.25.

\* \* \* These little books can be regarded as a full set of notes upon the Practice of Medicine, containing the Synonyms, Definitions, Causes, Symptoms, Prognosis, Diagnosis, Treatment, etc., of each disease, and including a number of new prescriptions. They have been compiled from the lectures of prominent Professors, and reference has been made to the latest writings of Professors FLINT, DA COSTA, BARTHOLOW, ROBERTS, etc.

"It is brief and concise, and at the same time possesses an accuracy not generally found in compends."—*Jas. M. French, M.D., Ass't to the Prof. of Practice, Medical College of Ohio, Cincinnati.*

"The book seems very concise, yet very comprehensive. . . . An unusually superior book."—*Dr. E. T. Bruen, Demonstrator of Clinical Medicine, University of Pennsylvania.*

"I have used it considerably in connection with my branches in the Quiz-class of the University of La."—*J. H. Bemiss.*

"Dr. Hughes has prepared a very useful little book, and I shall take pleasure in advising my class to use it."—*Dr. George W. Hall, Prof. of Practice, St. Louis College of Phys. and Surgeons.*

#### No. 4. PHYSIOLOGY. Illustrated.

THIRD REVISED EDITION.

A Compend of Human Physiology, adapted to the use of Students. By ALBERT P. BRUBAKER, M.D., Demonstrator of Physiology in Jefferson Medical College, Philadelphia. Third Ed. Enlarged and Revised.

"Dr. Brubaker deserves the hearty thanks of medical students for his *Compend of Physiology*. He has arranged the fundamental and practical principles of the science in a peculiarly inviting and accessible manner. I have already introduced the work to my class."—*Maurice N. Miller, M.D., Instructor in Histology, formerly Demonstrator of Physiology, University City of New York.*

"'Quiz-Compend' No. 4 is fully up to the high standard established by its predecessors of the same series."—*Medical Bulletin, Philadelphia.*

"I can recommend it as a valuable aid to the student."—*C. N. Ellinwood, M.D., Professor of Physiology, Cooper Medical College, San Francisco.*

"This is a well written little book."—*London Lancet.*

#### No. 5. OBSTETRICS. Second Ed.

A Compend of Obstetrics. For Physicians and Students. By HENRY G. LANDIS, M.D., Professor of Obstetrics and Diseases of Women, in Starling Medical College, Columbus. New Revised Ed. New Illustrations.

"We have no doubt that many students will find in it a most valuable aid in preparing for examination."—*The American Journal of Obstetrics.*

"It is complete, accurate and scientific. The very best book of its kind I have seen."—*J. S. Knox, M.D., Lecturer on Obstetrics, Rush Medical College, Chicago.*

Price of each Book, Cloth, \$1.00. Interleaved for Notes \$1.25.

"I have been teaching in this department for many years, and am free to say that this will be the best assistant I ever had. It is accurate and comprehensive, but brief and pointed."—*Prof. P. D. Vost, St. Louis.*

### **No. 6. MATERIA MEDICA. Revised Ed.**

A Compend on Materia Medica and Therapeutics, with especial reference to the Physiological Actions of Drugs. For the use of Medical, Dental, and Pharmaceutical Students and Practitioners. Based on the New Revision (Sixth) of the U. S. Pharmacopœia, and including many unofficial remedies. By SAMUEL O. L. POTTER, M.A., M.D., U. S. Army.

"I have examined the little volume carefully, and find it just such a book as I require in my private Quiz, and shall certainly recommend it to my classes. Your Compend is all popular here in Washington."—*John E. Brackett, M.D., Professor of Materia Medica and Therapeutics, Howard Medical College, Washington.*

"Part of a series of small but valuable text-books. . . . While the work is, owing to its therapeutic contents, more useful to the medical student, the pharmaceutical student may derive much useful information from it."—*N. Y. Pharmaceutical Record.*

### **No. 7. CHEMISTRY. Revised Ed.**

A Compend of Chemistry. By G. MASON WARD, M.D., Demonstrator of Chemistry in Jefferson Medical College, Philadelphia. Including Table of Elements and various Analytical Tables.

"Brief, but excellent. . . . It will doubtless prove an admirable aid to the student, by fixing these facts in his memory. It is worthy the study of both medical and pharmaceutical students in this branch."—*Pharmaceutical Record, New York.*

### **No. 8. VISCERAL ANATOMY.**

SECOND EDITION. ILLUSTRATED.

A Compend of Visceral Anatomy. By SAMUEL O. L. POTTER, M.A., M.D., U. S. Army. With 40 Illustrations.

\*\* This is the only Compend that contains full descriptions of the viscera, and will, together with No. 1 of this series, form the only complete Compend of Anatomy published.

"This work is very happily arranged, very thorough in practical details, and will no doubt prove universally popular with medical students."—*Medical Herald.*

"I believe it will prove of great usefulness to the busy teacher or student; short, concise helps are always welcome."—*Dr. R. N. Hall, Demonstrator of Anatomy, College of Physicians and Surgeons, Chicago.*

"It is a very concise and convenient help to the memory, and quite accurate."—*Prof. L. B. How, Medical Department, Dartmouth College.*

Price of Each Book, Cloth, \$1.00. Interleaved for Notes, \$1.25.



**No. 9. SURGERY. Second Edition.****ILLUSTRATED.**

A Compend of Surgery; including Fractures, Wounds, Dislocations, Sprains, Amputations and other operations, Inflammation, Suppuration, Ulcers, Syphilis, Tumors, Shock, etc. Diseases of the Spine, Ear, Eye, Bladder, Testicles, Anus, and other Surgical Diseases. By ORVILLE HORWITZ, A.M., M.D., with 62 Illustrations. Second Edition. Enlarged and Revised.

\*.\* This compend has been prepared with great care, from the standard authorities on Surgery and from notes taken by the author during attendance on lectures by prominent professors. The rapid sale of the first edition allowed the addition of much valuable matter, besides a thorough revision of the whole book.

**No. 10. ORGANIC CHEMISTRY.**

A Compend of Organic Chemistry, including Medical Chemistry, Urine Analysis, and the Analysis of Water and Food; etc. By HENRY LEFFMANN, M.D., Professor of Clinical Chemistry and Hygiene in the Philadelphia Polyclinic; Professor of Chemistry, Pennsylvania College of Dental Surgery; Member of the N. Y. Medico-Legal Society. Cloth. \$1.00.

Interleaved, for the addition of Notes, \$1.25.

"Compact, substantial and exact; well suited as a remembrancer to students."—*Pacific Medical and Surgical Journal*.

"This neat, handy and exceedingly useful volume is a valuable aid to the student."—*Pharmaceutical Record*.

"It contains, in compact form, the most of modern organic and medical chemistry essential to the student of medicine, and will be of great value in bringing this subject within his grasp."—C. C. Howard, *Prof. of Chemistry, Starling Medical College, Columbus, Ohio*.

"It has the decided merit of being written in a clear and understandable language."—*Dr. J. Sickels, Instructor in Chemistry, University Medical College, New York*.

**No. 11. PHARMACY.**

A Compend of Pharmacy. Based upon "Remington's Text-Book of Pharmacy." By F. E. STEWART, M.D., PH. G., Quiz Master in Chemistry and Theoretical Pharmacy, Philadelphia College of Pharmacy; Demonstrator and Lecturer in Pharmacology, Medico-Chirurgical College; Member of the American Pharmaceutical Association, etc.

\*.\* The ? Quiz Compend? are adapted to students of any college, because they are based upon the text-books in use throughout the country. They contain the latest and best information, in such a shape that it can be easily memorized.

Price of Each Book, Cloth, \$1.00; Interleaved for Notes \$1.25.

## ANATOMY.

**Holden's Anatomy.** A manual of Dissection of the Human Body. Fifth Edition. Enlarged, with Marginal References and over 200 Illustrations. Octavo. Cloth, 5.00; Leather, 6.00  
Bound in Oilcloth, for the Dissecting Room, \$4.50.

"No student of Anatomy can take up this book without being pleased and instructed. Its Diagrams are original, striking and suggestive, giving more at a glance than pages of text description. \* \* \* The text matches the illustrations in directness of practical application and clearness of detail."—*New York Medical Record*.

**Holden's Human Osteology.** Comprising a Description of the Bones, with Colored Delineations of the Attachments of the Muscles. The General and Microscopical Structure of Bone and its Development. With Lithographic Plates and Numerous Illustrations. Sixth Edition. 8vo. Cloth, 6.00

**Heath's Practical Anatomy.** Sixth London Edition. 24 Colored Plates, and nearly 300 other Illustrations. Cloth, 5.00

## CHEMISTRY.

**Bartley's Medical Chemistry.** A text-book prepared specially for Medical, Pharmaceutical and Dental Students. With 40 Illustrations, Plate of Absorption Spectra and Glossary of Chemical Terms. Cloth, 2.50

\*.\* This book has been written especially for students and physicians. It is practical and concise, dealing only with those parts of chemistry pertaining to medicine; no time being wasted in long descriptions of substances and theories of interest only to the advanced chemical student.

**Bloxam's Chemistry, Inorganic and Organic, with Experiments.** Fifth Edition, nearly 300 Illustrations. Cloth, 3.75; Leather, 4.75

**Muter's Practical and Analytical Chemistry.** 8vo. Cloth, 2.50

**Richter's Inorganic Chemistry.** A text-book for Students. Second American, from Fourth German Edition. Translated by Prof. Edgar F. Smith, PH.D. 89 Wood Engravings and Colored Plate of Spectra. *Just Ready.* Cloth, 2.00

**Richter's Organic Chemistry, or Chemistry of the Carbon Compounds.** Translated by Prof. Edgar F. Smith, PH.D. Illustrated. *Just Ready.* Cloth, 3.00

**Trimble. Practical and Analytical Chemistry.** A Course in Chemical Analysis, by Henry Trimble, Prof. of Analytical Chemistry in the Phila. College of Pharmacy. Illus. 8vo. Cloth, 1.50

**Wolff's Applied Medical Chemistry.** By Lawrence Wolff, M.D., Demonstrator of Chemistry in Jefferson Medical College, Philadelphia. *Just Ready.* Cloth, 1.50

☞ See pages 2 to 5 for list of ? Quiz-Compends ?

**CHILDREN.**

**Goodhart and Starr.** *The Diseases of Children. A Manual for Students and Physicians.* By J. F. Goodhart, M.D., Physician to the Evelina Hospital for Children; Assistant Physician to Guy's Hospital, London. American Edition, Revised and Edited by Louis Starr, M.D., Clinical Professor of Diseases of Children in the Hospital of the University of Pennsylvania; Physician to the Children's Hospital, Philadelphia. Containing many new Prescriptions, a List of over 50 Formulæ, conforming to the U. S. Pharmacopœia, and Directions for making Artificial Human Milk, for the Artificial Digestion of Milk, etc. Just Ready. Demi-Octavo, 738 Pages. Cloth, 3.00; Leather, 4.00

The **NEW YORK MEDICAL RECORD** says:—"As it is said of some men, so it might be said of some books, that they are 'born to greatness.' This new volume has, we believe, a mission, particularly in the hands of the younger members of the profession. In these days of prolixity in medical literature, it is refreshing to meet with an author who knows both what to say, and when he has said it. The work of Dr. Goodhart (admirably conformed, by Dr. Starr, to meet American requirements) is the nearest approach to clinical teaching, without the actual presence of clinical material, that we have yet seen. The details of management so gratefully read by the young practitioner are fully elucidated. Altogether, the book is one of as great practical working value as we have seen for many months."

**Day.** *On Children. A Practical and Systematic Treatise.* Second Edition. 8vo. 752 pages. Cloth, 3.00; Leather, 4.00

**Meigs and Pepper.** *The Diseases of Children.* Seventh Edition. 8vo. Cloth, 6.00; Leather, 7.00

**Starr.** *Diseases of the Digestive Organs in Infancy and Childhood.* By Louis Starr, M.D., Prof. of Diseases of Children, Hospital of the University of Pennsylvania. Illus. Cloth, 2.50

**DENTISTRY.**

**Flagg's** *Plastics and Plastic Filling.* 2d Ed. Cloth, 4.00

**Gorgas.** *Dental Medicine. A Manual of Materia Medica and Therapeutics,* by Professor F. J. S. Gorgas, M.D., D.D.S., Professor of the Principles and Practice of Dental Science, in Dental Department, University of Maryland. 8vo. Second Edition. Revised and Enlarged. Cloth, 3.25

**Harris' Principles and Practice of Dentistry.** Including Anatomy, Physiology, Pathology, Therapeutics, Dental Surgery and Mechanism. Eleventh Edition. Revised and enlarged by Professor Gorgas. 744 Illustrations. Cloth, 6.50; Leather, 7.50

**Richardson's Mechanical Dentistry.** Third Edition. 185 Illustrations. 8vo. Cloth, 4.00; Leather, 4.75

**Stocken's Dental Materia Medica.** Third Edition. Cloth, 2.50

*See pages 2 to 5 for list of ? Quiz-Compends ?*

*Dentistry:—Continued.*

**Tomes' Dental Anatomy, Human and Comparative.** Second Edition. 191 Illustrations. Cloth, 4.25

**Tomes' Dental Surgery.** New Revised Edition. *Preparing.*

**Taft's Operative Dentistry.** A Text-book for Dental Students and Practitioners. Fourth Edition. Over 100 Illustrations. Cloth, 4.25; Leather, 5.00

**DICTIONARIES.**

**Cleveland's Pocket Medical Lexicon.** Thirty-first Edition. Giving correct Pronunciation and Definition of Terms used in Medicine and the Collateral Sciences. Very small pocket size, red edges. Cloth, .75; pocket-book style, 1.00

**Longley's Pocket Dictionary.** The Student's Medical Lexicon, giving Definition and Pronunciation of all Terms used in Medicine, with an Appendix giving Poisons and Their Antidotes, Abbreviations used in Prescriptions, Metric Scale of Doses, etc. 24mo. Cloth, 1.00; pocket-book style, 1.25

**Harris' Dictionary of Medical Terminology and Dental Surgery** By Prof. Gorgas. Fourth Edition. Cloth, 6.50; Leather, 7.50

**EYE.**

**Arlt. Diseases of the Eye.** Including those of the Conjunctiva, Cornea, Sclerotic, Iris and Ciliary Body. By Professor Fred. Ritter von Arlt. Translated by Dr. Lyman Ware. Illustrated. 8vo. Cloth, 2.50

**Higgins. Ophthalmic Practice.** A Handbook for Students and Practitioners. 16mo. Cloth, .50

**Macnamara. On Diseases of the Eye.** Fourth Edition, revised, with Marginal References, numerous Colored Plates and Diagrams, Wood Cuts and Test Types. Cloth, 4.00

**HYGIENE.**

**Parke's Practical Hygiene.** Sixth Edition, enlarged. Illustrated. 8vo. Cloth, 3.00

**Wilson's Handbook of Hygiene and Sanitary Science.** Fifth Edition. Revised and Illustrated. Cloth, 2.75

**MATERIA MEDICA AND THERAPEUTICS.**

**Biddle's Materia Medica.** Tenth Edition. For the use of Students and Physicians. By the late Prof. John B. Biddle, M. D., Professor of Materia Medica in Jefferson Medical College, Philadelphia. The Tenth Edition, thoroughly revised, and in many parts rewritten, by his son, Clement Biddle, M. D., Past Assistant Surgeon, U. S. Navy, assisted by Henry Morris, M. D., Demonstrator of Obstetrics in Jefferson Medical College. 8vo., illustrated. *Just Ready.* Cloth, 4.00; Leather, 4.75

See pages 2 to 5 for list of ? *Quin-Compendis?*

*Biddle's Materia Medica and Therapeutics:—Continued.*

"The larger works usually recommended as text-books in our medical schools are too voluminous for convenient use. This work will be found to contain in a condensed form all that is most valuable, and will supply students with a reliable guide."—*Chicago Med. J.*

**Merrell's Digest of Materia Medica.** 8vo. Half Calf, 4.00

**Roberts' Compend of Materia Medica and Pharmacy.** By the author of "Roberts' Practice." Cloth, 2.00

"It contains an immense amount of matter."—*The National Druggist.*

**Headland's Action of Medicines.** 9th Ed. 8vo. Cloth, 3.00

**Waring. Therapeutics.** A Practical Manual. Fourth Edition, revised and enlarged. *In Press.*

## MEDICAL JURISPRUDENCE.

**Reese.** A Text-book of Medical Jurisprudence and Toxicology. By John J. Reese, M.D., Professor of Medical Jurisprudence and Toxicology in the Medical and Law Departments of the University of Pennsylvania; Vice-President of the Medical Jurisprudence Society of Philadelphia; Physician to St. Joseph's Hospital; Corresponding Member of The New York Medico-legal Society. Demi-Octavo. Cloth, 4.00; Leather, 5.00

"Professor Reese is so well known as a skilled medical jurist, that his authorship of any work virtually guarantees the thoroughness and practical character of the latter. And such is the case in the book before us. \* \* \* \* We might call these the essentials for the study of medical jurisprudence. The subject is skeletonized, condensed, and made thoroughly up to the wants of the general medical practitioner, and the requirements of prosecuting and defending attorneys. If any section deserves more distinction than any other, as to intrinsic excellence, it is that on toxicology. This part of the book comprises the best outline of the subject in a given space that can be found anywhere. As a whole, the work is everything it promises, and more, and considering its size, condensation, and practical character, it is by far the most useful one for ready reference, that we have met with. It is well printed and neatly bound."—*New York Medical Record.*

**Abercrombie's Students' Guide to Medical Jurisprudence.** 12mo. Cloth, 2.50

**Mann's Manual of Psychological Medicine, and Allied Nervous Diseases, Their Diagnosis, Pathology and Treatment, and their Medico-Legal Aspects.** Illustrated. 8vo. Cloth, 5.00; Leather, 6.00

**Woodman and Tidy's Medical Jurisprudence and Toxicology.** Chromo-Lithographic Plates and 116 Wood engravings. Cloth, 7.50; Leather, 8.50

☞ See pages 2 to 5 for list of Quiz-Compend?

## MISCELLANEOUS.

- Beale.** Slight Ailments. Their Nature and Treatment. Illustrated. 8vo. Paper cover, .75; Cloth, 1.25
- Dulles.** Surgical and other Emergencies. Illustrated. Second Edition. 12mo. Cloth, .75
- Fothergill.** Diseases of the Heart and Their Treatment. Second Edition. 8vo. Cloth, 3.50
- Tanner.** Memoranda of Poisons. Their Antidotes and Tests. Fifth Edition. 12mo. Cloth, .75
- Allingham.** Diseases of the Rectum. Fourth Edition. Illustrated. 8vo. Paper covers, .75; Cloth, 1.25

## OBSTETRICS AND GYNÆCOLOGY.

**Byford.** The Diseases of Women. By W. H. Byford, A.M., M.D., Professor of Gynæcology in Rush Medical College; of Obstetrics in the Woman's Medical College; and Surgeon to the Woman's Hospital, Chicago. Third Edition. Over 160 Illustrations. Octavo. Cloth, 5.00; Leather, 6.00

"The treatise is as complete a one as the present state of our science will admit of being written. We commend it to the diligent study of every practitioner and student, as a work calculated to inculcate sound principles and lead to enlightened practice."—*New York Medical Record.*

**Cazeaux and Tarnier.** Obstetrics; the Theory and Practice of; including the Diseases of Pregnancy and Parturition, Obstetrical Operations, etc. By P. Cazeaux, Member of the Imperial Academy of Medicine, etc. Revised, with additions, by S. Tarnier, Prof. of Obstetrics and Diseases of Women and Children in the Faculty of Medicine, of Paris. A New American, from the Eighth French and First Italian Editions. Edited and enlarged by Robert J. Hess, M.D., Physician to the North-ero Dispensary, Philadelphia; Member of the College of Physicians of Philadelphia, etc. 1100 pages, 4to, with 12 Full-page Lithographic plates, 5 of which are Colored, and over 175 Wood Engravings.

Sold by subscription only. Full information and Four-page Circular upon application to the publishers.

**Galabin's Midwifery.** A New Manual for Students. By A. Lewis Galabin, M.D., F.R.C.P., Obstetric Physician to Guy's Hospital, London, and Professor of Obstetrics in the same Institution. 227 Illustrations. Cloth, 3.00; Leather, 3.50

**Rigby's Obstetric Memoranda.** By Alfred Meadows, M.D. 4th Edition. Cloth, .50

See pages 2 to 5 for list of Quiz-Compend's

*Obstetrics and Gynecology:—Continued.*

- Meadows' Manual of Midwifery.** Including the Signs and Symptoms of Pregnancy, Obstetric Operations, Diseases of the Puerperal State, etc. 145 Illustrations. 494 pages. Cloth, 2.00
- Swayne's Obstetric Aphorisms.** For the use of Students commencing Midwifery Practice. 8th Ed. 12mo. Cloth, 1.25

**PATHOLOGY AND HISTOLOGY.**

- Rindfleisch's General Pathology.** For Students and Physicians. By Prof. Edward Rindfleisch, of Würzburg. Translated by Wm. H. Mercur, M.D., of Pittsburg, Pa., Edited by James Tyson, M.D., Professor of Pathology and Morbid Anatomy in the University of Pennsylvania. 12mo. Cloth, 2.00
- Gilliam's Essentials of Pathology.** A Handbook for Students. 47 Illustrations. 12mo. Cloth, 2.00

\*.\* The object of this book is to unfold to the beginner the fundamentals of pathology in a plain, practical way, and by bringing them within easy comprehension to increase his interest in the study of the subject. Though it will not altogether supplant larger works, it will be found to impart clear-cut conceptions of the generally accepted doctrines of the day, and to prevent confusion in the mind of the student.

- Gibbes' Practical Histology and Pathology.** Third Edition. Enlarged. 12mo. Cloth, 1.75

**PHYSICAL DIAGNOSIS.**

- Bruen's Physical Diagnosis of the Heart and Lungs.** By Dr. Edward T. Bruen, Assistant Professor of Clinical Medicine in the University of Pennsylvania. Second Edition, revised. With new Illustrations. 12mo. Cloth, 1.50

\*.\* The subject is treated in a plain, practical manner, avoiding questions of historical or theoretical interest, and without laying special claim to originality of matter, the author has made a book that presents to the student the somewhat difficult points of Physical Diagnosis clearly and distinctly.

**PHYSIOLOGY.**

- Yeo's Physiology.** The most Popular Students' Book. By Gerald F. Yeo, M.D., F.R.C.S., Professor of Physiology in King's College, London. Small Octavo. 750 pages. Over 300 carefully printed Illustrations. With a Full Glossary and Index.

Cloth, 4.00; Leather, 5.00

"The work will take a high rank among the smaller text-books of Physiology."—*Prof. H. P. Bowditch, Harvard Med. School, Boston.*

"The brief examination I have given it was so favorable that I placed it in the list of text-books recommended in the circular of the University Medical College."—*Prof. Lewis A. Stimpson, M. D., 37 East 33d Street, New York.*

☞ See pages 2 to 5 for list of ? Quiz-Compend ?

*Physiology:—Continued.*

**Kirke's Physiology.** 11th Ed. Illus. Cloth, 4.00; Leather, 5.00

**Landois' Human Physiology.** Including Histology and Microscopical Anatomy. 2 volumes. Cloth, 10.00

"So great are the advantages offered by Prof. Landois' Text-book, from the exhaustive and eminently practical manner in which the subject is treated, that, notwithstanding it is one of the largest works on Physiology, it has yet passed through four large editions in the same number of years. Dr. Stirling's annotations have materially added to the value of the work. . . . Admirably adapted for the practitioner. . . . With this Text-book at his command, no student could fail in his examination."—*Lancet*.

**Sanderson's Physiological Laboratory.** Being Practical Exercises for the Student. 350 Illustrations. 8vo. Cloth, 5.00

**Tyson's Cell Doctrine.** Its History and Present State. Illustrated. Second Edition. Cloth, 2.00

**PRACTICE.**

**Roberts' Practice.** Fifth American Edition. A Handbook of the Theory and Practice of Medicine. By Frederick T. Roberts, M.D.; M.R.C.P., Professor of Clinical Medicine and Therapeutics in University College Hospital, London. Fifth Edition. Octavo. Cloth, 5.00; Leather, 6.00

\*.\* This new edition has been subjected to a careful revision. Many chapters have been rewritten. Important additions have been made throughout, and new illustrations introduced. Recommended as a Text-book at University of Pennsylvania, Long Island College Hospital, Yale and Harvard Colleges, Bishop's College, Montreal, University of Michigan, and over twenty other Medical Schools.

"I have become thoroughly convinced of its great value, and have cordially recommended it to my class in *Yale College*."—*Prof. David P. Smith*.

"I have examined it with some care, and think it a good book and shall take pleasure in mentioning it among the works which may properly be put in the hands of students."—*A. B. Palmer, Prof. of the Practice of Medicine, University of Michigan*.

"A clear, yet concise, scientific and practical work. It is a capital compendium of the classified knowledge of the subject."—*Prof. F. Adams Allen, Rush Medical College, Chicago*.

"It is unsurpassed by any work that has fallen into our hands, as a compendium for students preparing for examination. It is thoroughly practical, and fully up to the times."—*The Clinic*.

**Aitken's Practice of Medicine.** Seventh Edition. 196 Illustrations. 2 vols. Cloth, 12.00; Leather, 14.00

**Fagge's Principles and Practice of Medicine.** A Complete Text-book. 2 vols. *Now Ready.*

**Tanner's Index of Diseases, and Their Treatment.** Cloth, 3.00

"This work has won for itself a reputation. . . . It is, in truth, what its Title indicates."—*N. Y. Medical Record*.

☞ See pages 2 to 5 for list of Quiz-Compendis ?



### PRESCRIPTION BOOKS.

- Wythe's Dose and Symptom Book.** Containing the Doses and Uses of all the principal Articles of the *Materia Medica*, etc. Sixteenth edition. 32mo. Cloth, 1.00; Pocket-book style, 1.25
- Pereira's Physician's Prescription Book.** Containing Lists of Terms, Phrases, Contractions and Abbreviations used in Prescriptions, Explanatory Notes, Grammatical Construction of Prescriptions, etc., etc. By Professor Jonathan Pereira, M.D. Sixteenth Edition. 32mo. Cloth, 1.00; Pocket-book style, 1.25

### SKIN DISEASES.

- Van Harlingen on Skin Diseases.** A Handbook of the Diseases of the Skin, their Diagnosis and Treatment. By Arthur Van Harlingen, M.D., Prof. of Diseases of the Skin in the Philadelphia Polyclinic; Consulting Physician to the Dispensary for Skin Diseases, etc. With colored plates. 12mo. Cloth, 1.75

\*.\* This is a complete epitome of skin diseases, arranged in alphabetical order, giving the diagnosis and treatment in a concise, practical way. Many prescriptions are given that have never been published in any text-book, and an article incorporated on Diet. The plates do not represent one or two cases, but are composed of a number of figures, accurately colored, showing the appearance of various lesions, and will be found to give great aid in diagnosing.

"This new handbook is essentially a small-encyclopædia. \* \* \* We heartily commend it for its brevity, clearness and evidently careful preparation."—*Philadelphia Medical Times*.

"This is an excellent little book, in which, for ease of reference, the more common diseases of the skin are arranged in alphabetical order, while many good prescriptions are given, together with clear and sensible directions as to their proper application."—*Boston Medical and Surgical Journal*.

- Bulkley. The Skin in Health and Disease.** By L. Duncan Bulkley, Physician to the N. Y. Hospital. Illus. Cloth, .50

### SURGERY.

- Heath's Minor Surgery, and Bandaging.** New Edition. With many Illustrations. \* *In Press.*

- Mears' Practical Surgery.** Second Edition. Enlarged. 490 Illustrations. Cloth, \$3.75; Leather, \$4.75

- Pye's Surgical Handicraft.** A Manual of Surgical Manipulations, Minor Surgery, Bandaging, Dressing, etc., etc. With special chapters on Aural Surgery, Extraction of Teeth, Anæsthetics, etc. 208 Illustrations. 8vo. Cloth, 5.00

- Watson on Amputation of the Extremities, and their Complications.** 2 colored plates and 250 wood cuts. 8vo. Cloth, 5.50

See pages 2 to 5 for list of ? Quiz-Compends ?

## THROAT.

**Mackenzie on the Throat and Nose.** By Morell Mackenzie, M.D., Senior Physician to the Hospital for Diseases of the Chest and Throat; Lecturer on Diseases of the Throat at the London Hospital, etc.

Vol. I. Including the Pharynx, Larynx, Trachea, etc., with Formulæ and 112 Illustrations.

Vol. II. Diseases of the Oesophagus, Nose and Naso-Pharynx, with Formulæ and 93 Illustrations.

The two volumes, Cloth, 6.00; Leather, 7.50

Vol. II, separately, Cloth, 3.00; Leather, 4.00

"It is both practical and learned; abundantly and well illustrated; its descriptions of disease are graphic and the diagnosis the best we have anywhere seen."—*Philadelphia Medical Times*.

**Cohen. The Throat and Voice.** Illustrated. Cloth, .50

**James. Sore Throat.** Its Nature, Varieties and Treatment. 12mo. Illustrated. Paper cover, .75; Cloth, 1.25

## URINE AND URINARY ORGANS.

**Acton. The Reproductive Organs.** In Childhood, Youth, Adult Life and Old Age. Sixth Edition. Cloth, 2.00

**Beale. Urinary and Renal Diseases and Calculous Disorders.** Hints on Diagnosis and Treatment. 12mo. Cloth, 1.75

**Ralfe. Kidney Diseases and Urinary Derangements.** 42 Illustrations. 12mo. 572 pages. *Just Ready.* Cloth, 2.75

**Legg. On the Urine.** A Practical Guide. 6th Ed. Cloth, .75

**Marshall and Smith. On the Urine.** The Chemical Analysis of the Urine. By John Marshall, M.D., Chemical Laboratory, University of Pennsylvania, and Prof. E. F. Smith, Ph.D. With Colored Plates. Cloth, 1.00

**Thompson. Diseases of the Urinary Organs.** Seventh Edition. Illustrated. Cloth, 1.25

**Tyson. On the Urine.** A Practical Guide to the Examination of Urine. By James Tyson, M.D., Professor of Pathology and Morbid Anatomy, University of Penn'a. With Colored Plates and Wood Engravings. 5th Ed. Enlarged. 12mo. Cloth, 1.50

## VENEREAL DISEASES.

**Hill and Cooper. Student's Manual of Venereal Diseases.** Fourth Edition. 12mo. Cloth, 1.00

**Durkee. On Gonorrhœa and Syphilis.** Illus. Cloth, 3.50

See pages 2 to 5 for list of ? Quiz-Compends ?

# Richter's Chemistries.

AUTHORIZED TRANSLATIONS.

By EDGAR F. SMITH, M.A., Ph.D.,

*Prof. of Chemistry in Wittenberg College, Springfield, Ohio; formerly in the Laboratories of the University of Pennsylvania and Muhlenberg College; Member of the Chemical Societies of Berlin and Paris; of the Academy of Natural Sciences of Philadelphia, etc., etc.*

EACH VOLUME SOLD SEPARATELY.

**INORGANIC CHEMISTRY.** Second American, from the Fourth German Edition; thoroughly revised and in many parts rewritten. With 89 Illustrations and Colored Plate of Spectra. Cloth, \$2.00

**THE CHEMISTRY OF THE CARBON COMPOUNDS, or Organic Chemistry.** First American, from Fourth German Edition. Illustrated.

Cloth, \$3.00

The success attending the publication of the first edition of Richter's Inorganic Chemistry encourages the translator and publishers to believe that the companion volume will have an equally warm reception. Professor Richter's methods of arrangement and teaching have proved their superiority, abroad, by the very large sale of his books all over the Continent, translations having been made in Germany, Russia, Holland and Italy.

From PROF. B. SILLIMAN, Yale College, New Haven, Conn.

"It is decidedly a good book, and in some respects the best manual we have."

From JOHN MARSHALL, M.D., NAT. SC. D. (Tübingen), Demonstrator of Chemistry in the University of Pennsylvania, Medical Department.

"The work is of undoubted value. The theory of chemistry, which is generally the bugbear of students, is, in this book, very clearly explained, and the explanations are so well distributed through the book that students are brought easily from the simplest to the most difficult problems.

"That part descriptive of the elements and their compounds is full, and all that could be desired in a text-book, while the cuts, with which the work is profusely illustrated, are an excellent aid to the student. Altogether, it is one of our best modern works on chemistry."

# Yeo's Physiology.

A MANUAL FOR STUDENTS.

---

By GERALD F. YEO, M.D., F.R.C.S.,  
*Professor of Physiology in King's College, London.*

WITH OVER 300 CAREFULLY PRINTED ILLUSTRATIONS AND A GLOSSARY.

Small Octavo. Cloth, \$4.00; Leather, \$5.00.

---

## RECOMMENDATIONS.

"After a careful examination of this manual of Physiology, I can truthfully say that it is a most valuable addition to the list of text-books upon this subject. That it should and will receive a welcome from both students and teachers there can be no doubt; for, in addition to the familiar but well presented facts of most text-books, it contains all the more important facts of physiological science which have been established in the last few years. The author presents his subject in a manner that is clear, concise and logical. Each section has had a careful revision, and reveals the author's familiarity with the scope and tendencies of modern physiology. It will prove an interesting and instructive book to those commencing the study of this subject."—*A. P. Brubaker, M.D., Demonstrator of Physiology at Jefferson Medical College, Philadelphia.*

"The writer has endeavored to 'avoid theories which have not borne the test of time, and such details of methods as are unnecessary for junior students.' His experience as a teacher and as an examiner has led him to lay stress on the points which are hard to grasp and are commonly misunderstood, and he has directed attention more to those subjects which have a practical medical or surgical application than to those relating to abstract physiological subjects. \* \* \* We have pleasure in recommending this book, as a most excellent manual, being what it pretends to be—elementary, and yet containing all that is really of importance to the student of medicine. It is difficult to devise an original method of treating such a well worn subject as physiology, but the present volume undoubtedly has originality in its method. We think the author treats his subject in the best manner possible when he combines microscopical anatomy intimately with the discussion of strict physiology."—*The Medical Times and Gazette.*

# VAN HARLINGEN

# On Skin Diseases.

WITH COLORED ILLUSTRATIONS.

A HANDBOOK OF THE DISEASES OF THE SKIN, their Diagnosis and Treatment. By ARTHUR VAN HARLINGEN, M.D., Professor of Diseases of the Skin in the Philadelphia Polyclinic, Consulting Physician to the Dispensary for Skin Diseases, etc. Illustrated by colored lithographic plates.

12mo. 284 pages. Cloth. Price, \$1.75.

## RECOMMENDATIONS.

"It is a most useful compendium of the knowledge to be had at the present time upon the important subjects to which it is devoted; and is in all respects a credit to the well recognized abilities of its author."—*James Nevins Hyde, M.D., Professor of Skin and Venereal Diseases, Rush Medical College, Chicago.*

"This new handbook is essentially a small encyclopedia of pathology and treatment of Skin Diseases, in which the subjects are arranged alphabetically. This arrangement was that followed by the late Tilbury Fox, of London, in his handbook, which we believe was remarkably successful; and we have no doubt it will be equally appreciated in the present work, which (compendious in form) contains a very complete summary of the present state of dermatology. Dr. Van Harlingen's position in the profession, being at present vice-president of the American Dermatological Association, which he served as secretary for several years, and the high standard of his communications to his department, are sufficient to warrant the confidence in his teachings, which is fully sustained by an examination of this handbook, which we heartily commend for its brevity, clearness and evident careful preparation."—*Philadelphia Medical Times, October 18th, 1884.*

## RINDFLEISCH.

# The Elements of Pathology.

A Text-Book in the University of Pennsylvania.

THE ELEMENTS OF PATHOLOGY. For Students and Physicians. By EDWARD RINDFLEISCH, M.D., Professor of Pathological Anatomy in the University of Wurzburg. Authorized translation by WILLIAM H. MERCUR, M.D., of Pittsburgh, Pa. Revised by JAMES TYSON, M.D., Professor of General Pathology and Morbid Anatomy in the University of Pennsylvania.

12mo. 263 pages. Cloth, \$2.00.

## RECOMMENDATIONS.

"The practical views of one of the best of the modern histologists is placed before the profession in this admirable work, in a most careful and systematic manner. The author, who is one of the leading pathologists, sets forth not only the ground-work in his department, but treats and makes clear many of the more difficult points of the study of pathological processes. The work is divided into a consideration, *first*, of the local outbreak of diseases; *second*, into the anatomical extension of disease; *thirdly*, into the physiological extension of disease, and lastly, into an examination of special parts."—*The Medical Bulletin.*

**P. BLAKISTON, SON & CO., Publishers and Booksellers,**  
1012 WALNUT STREET, PHILADELPHIA.

# BIDDLE'S Materia Medica.

TENTH REVISED EDITION.

Contains all Changes in the New Pharmacopœia.

*Recommended as a Text-book at Yale College, University of Michigan, College of Physicians and Surgeons, Baltimore, Baltimore Medical College, Louisville Medical College, and a number of other Colleges throughout the United States.*

BIDDLE'S MATERIA MEDICA, For the Use of Students and Physicians. By the late PROF. JOHN B. BIDDLE, M.D., Professor of Materia Medica in Jefferson Medical College, Philadelphia. The Tenth Edition, thoroughly revised, and in many parts rewritten, by his son, CLEMENT BIDDLE, M.D., Assistant Surgeon, U. S. Navy, assisted by HENRY MORRIS, M.D., Demonstrator of Obstetrics, Jefferson Medical College, Philadelphia. Containing all the additions and changes made in the last revision of the United States Pharmacopœia. 8vo.

Bound in Cloth. Price \$4.00; Leather, \$4.75.

## RECOMMENDATIONS.

"It will be found a useful handbook by students, especially, who may be under the instruction of its able and accomplished author."—*American Medical Journal*.

"In short, it is just the work for a student, embracing as it does what will be discussed in a course of lectures on materia medica."—*Cincinnati Medical News*.

"In truth, the work is well adapted to the wants of students."—*The Clinic*.

"Nothing has escaped the writer's scan. All the new remedies against disease are duly and judiciously noted. Students will certainly appreciate its shapely form, grace of manner, and general *multum in parvo* style."—*American Practitioner*.

"Biddle's 'Materia Medica' is well known to the profession, being a standard text-book in several leading colleges."—*New York Medical Journal*.

"It contains, in a condensed form, all that is valuable in materia medica, and furnishes the medical student with a complete manual on this subject."—*Canada Lancet*.

"The necessity for a new edition of this work in so short a time is the best proof of the value in which it is held by the profession."—*Medical and Surgical Reporter*.

"The standard 'Materia Medica' with a large number of medical students is Biddle's."—*Buffalo Medical and Surgical Journal*.

"The larger works usually recommended as text-books in our medical schools are too voluminous for convenient use. This work will be found to contain in a condensed form all that is most valuable, and will supply students with a reliable guide."—*Chicago Medical Journal*.

\* \* \* This Ninth Edition contains all the additions and changes in the U. S. Pharmacopœia, Sixth Revision.

**P. BLAKISTON, SON & CO., Publishers and Booksellers,  
1012 WALNUT STREET, PHILADELPHIA.**

# REESE'S Medical Jurisprudence AND TOXICOLOGY.

A TEXT-BOOK FOR STUDENTS AND PHYSICIANS. By JOHN J. REESE, M.D., Professor of Medical Jurisprudence and Toxicology in the University of Pennsylvania; Vice-President of the Medical Jurisprudence Society of Philadelphia; Member of the College of Physicians of Philadelphia; Corresponding Member of the New York Medico-Legal Society 606 pages. Demi-octavo.

Bound in Cloth, \$4.00; Leather, \$5.00.

## RECOMMENDATIONS.

"I have just concluded a careful review of Dr. John J. Reese's 'Text-Book of Medical Jurisprudence and Toxicology,' and I take great pleasure in saying that it is by far the best book of its size on this subject which I have ever seen. \* \* \* It is, for the medical student and the general practitioner, a much more convenient, readable, and in most respects better book than the voluminous treatises, to say nothing of the fact that it is a much less costly book than are these."—*Willis G. Tucker, M. D., Professor of Inorganic and Analytical Chemistry and Medical Jurisprudence, Albany Medical College.*

"There has long been needed a work like this one. The student of the subject has had to choose between very prolix and expensive treatises by American writers, or those prepared by foreigners, whose customs and laws differ so much from ours that it materially detracts from their usefulness.

"In this single volume, printed in clear type and on excellent paper, Dr. Reese presents all that the student or the general practitioner will have occasion to learn about the subject."—*The Medical and Surgical Reporter, Philadelphia, October 11th, 1884.*

"I have examined the work, and find it to be a well compiled manual of the various doctrines obtaining, both in law and in medicine, upon the subject of which it treats. In a field so wide as that of medical jurisprudence, it is a matter largely of individual choice as to the scope which shall be given by an author to the treatment of its several topics. Professor Reese seems to me to have struck the golden mean in this respect, and to have combined lucidity of style with brevity of statement, so as to give to each topic its due proportion of development. It cannot fail to become a most useful handbook for students who desire to have in outline the whole body of medical jurisprudence, including even the special department of toxicology, with all which that now embraces."—*John Ordronaux, Professor of Medical Jurisprudence in Columbia College, New York, and in Dartmouth College, Hanover, N. H.*

"It may be called a practical encyclopædia, giving just those things which are wanted in medico-legal inquiries. \* \* \* \* The thoroughness and skill of the author is apparent on every page, and the work may be especially commended as the best single volume on this subject in print."—*Quarterly Journal of Inebriety, October, 1884.*

"It not only treats of the medical side of the subject, but gives much valuable legal information as to the rights and duties of physicians in such cases."—*Popular Science News, October, 1884.*

"It comes to the profession at an opportune time, as a valuable addition to the subject of State medicine, and the volume should be in the hands of every medical man."—*Prof. James F. Harrison, University of Virginia.*

"We might call these the essentials for the study of medical jurisprudence. \* \* \* \* If any section deserves more distinction than any other, as to intrinsic excellence, it is that on toxicology. This part of the book comprises the best outline of the subject in a given space that can be found anywhere. As a whole, the work is everything it promises and more, and considering its size, condensation and practical character, it is by far the most useful one for ready reference that we have met with. It is well printed and neatly bound."—*N. Y. Medical Record, Sept. 13th, 1884.*

**P. BLAKISTON, SON & CO., Publishers and Booksellers,  
1012 WALNUT STREET, PHILADELPHIA.**

